

17. Enteritis, colitis

Enteritis and colitis are inflammatory diseases of the intestinal loops. They can be divided into **acute** and **chronic**.

Acute inflammation of the intestinal wall is an acute response to antigenic stimuli. Infectious inflammations, inflammatory reactions to antigenic components of food, post-radiation inflammations, and chemical inflammations can be included

Chronic inflammation of the intestinal wall represents a large group of diseases with different genesis. Chronic intestinal inflammations include, for example, idiopathic intestinal inflammations (Crohn's disease and ulcerative colitis), ischemic colitis and enteritis, enteritis and colitis in autoimmune diseases, allergic enterocolitis, and others.

*Infectious inflammations of the intestinal loops can affect the small intestine (enteritis), the large intestine (colitis), or the small and large intestine (enterocolitis). Toxic intestinal inflammations can be caused by toxins, bacteria, viruses, protozoa, and parasites. Of the infectious causes of intestinal inflammation, the gram-positive sporulating anaerobic bacterium *Clostridium difficile* and its toxins, which are a common cause of nosocomial intestinal infections (Clostridial colitis) and are closely related to previous antibiotic treatment, have a special place. The most serious complication of Clostridial colitis is the toxic megacolon.*

Idiopathic inflammatory bowel loops (Morbus Crohn's and ulcerative colitis).

*Morbus Crohn is a chronic nonspecific granulomatous inflammation of the **small intestine or colon, or other parts of the digestive tube**. The most common site of involvement is the **terminal ileum, an ileocecal junction often involving the adjacent caecum**. It is a **transmural inflammation** that affects **all layers of the wall**. Typical for Morbus Crohn is a **segmental involvement**. Common complications are stenoses, fistulas, abscesses, ileus.*

*Ulcerative colitis is a chronic non-specific intestinal inflammation that affects the **large intestine**. The most common locality of **the lesion** is the **area of the rectosigmoid, it almost always affects the rectum**. Pathologically, it is a necrotizing ulcerative inflammation that **typically affects the mucosa of the intestinal wall**.*

Continuous involvement is typical for ulcerative colitis. The complications of ulcerative colitis are abscess, stenosis, ileus, toxic megacolon, perforation.

Ischemic enteritis and colitis can be divided into occlusive (embolization or mesenteric artery thrombosis or mesenteric vein thrombosis) and non-occlusive (shock, heart failure).

Diagnostic imaging methods in enteritis and colitis:

Ultrasonography (UZ)

Ultrasonography is the imaging method of choice for acute intestinal inflammation, it is a tool for differentiating other causes of abdominal pain. The extent of the intestinal inflammation can be assessed at ultrasound, depending on the nature of the finding, it is possible to narrow the differential diagnosis of the aetiology of inflammation. In the ultrasound image **we can evaluate the intestinal wall** (its width, individual layers, wall echogenicity, vascularization in Doppler mode), the **surroundings of the intestinal loop** and **possible complications of inflammation**.

*Acute inflammation on ultrasound is visualised as a thickening of the hypervascularized intestinal wall while preserving the contours of individual layers, there is a reactive swelling of fat in the surroundings, sometimes also lymphadenopathy and free fluid. In **chronic inflammation**, a typical picture is the thickening of the intestinal wall (predominantly submucosa) while hypervascularisation, fat swelling and free fluid are absent. If a complication or suspected complication of an inflammatory bowel disease (abscess, fistula, ileus) is found, ultrasound is then often followed by computed tomography.*

Another application of ultrasonography is in the **monitoring of idiopathic intestinal inflammation** – monitoring the activity and extent of inflammatory bowel disease, the exclusion of possible inflammatory complications, monitoring the response to therapy, follow-up.

Computed tomography (CT)

CT of the abdomen is mainly used for the investigation of acute complications of intestinal inflammation and to clarify unclear findings on ultrasound. Complications of inflammatory bowel disease can be abscesses, fistulas, or ileus. Computed tomography is usually preceded by ultrasonography.

Computed tomography allows targeted imaging of the small intestine as **CT enterography**. We perform this examination as an alternative to MR enterography, in young patients only if MR enterography is not available resp. it cannot be performed due to contraindications of MRI.

CT enterography, in contrast to classical enteroclysis, does not require the introduction of a nasojejunal probe for the application of contrast agent into the small intestine, but the patient drinks 1-2 litres of "negative contrast agent" (usually Mannitol or Fortrans solution) one hour before the examination, which fills and dilate the loops of the small intestine. To reduce peristalsis, a spasmolytic drug (eg Buscopan) is administered before the examination.

Magnetic resonance imaging (MRI)

MR enterography is preferred for targeted examination of intestinal loops. Its advantages include the absence of radiation. **The main indications** are the evaluation of extent and severity of idiopathic intestinal inflammation, the evaluation of the activity of idiopathic intestinal inflammation, the assessment of stenoses and fistulas in idiopathic intestinal inflammation.

The nasojejunal probe is not inserted during the examination, the patient for the application of contrast agent in the small intestine the patient drinks 2 litres of hyperosmolar solution to fill the intestinal loops (again usually mannitol). To reduce peristaltis spasmolytic drug is administered before the examination. Movement artifacts can limit evaluation of the of examination. The disadvantage of the examination may also be its length.

Magnetic resonance imaging has its use in targeted **pelvic examination**, where it is used in the assessment of perianal fistulas and abscesses, which often accompany idiopathic intestinal inflammation (especially M. Crohn).

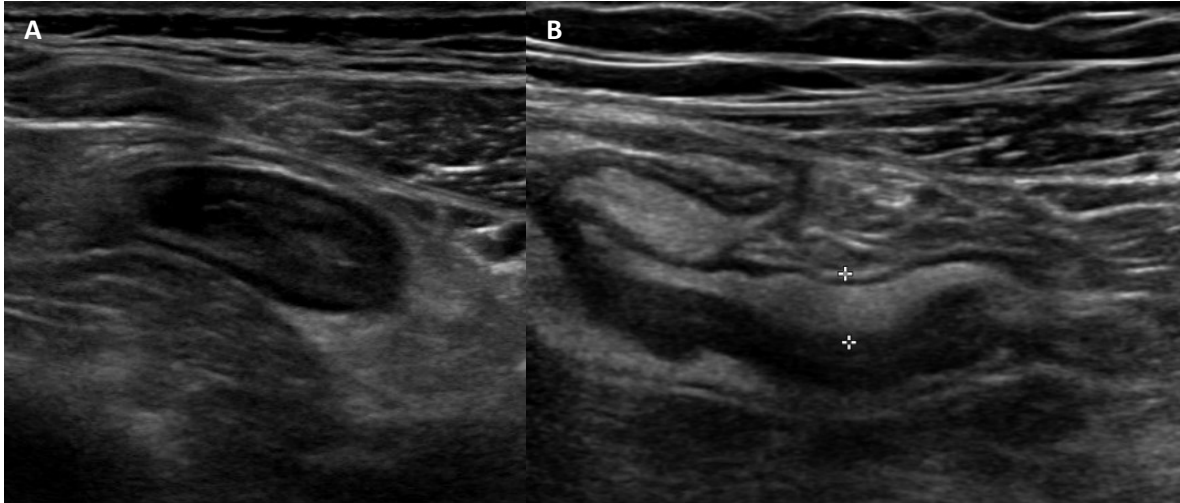


Fig. A – Bowel ultrasound, linear high-frequency probe. Thickened and edematous wall of aboral ileum, which is due to edema more hypoechoic and contours of wall layers are blurred. In the surrounding is hyperechoic swelling of fat - corresponds to **active inflammation** in patient with **Crohn's disease**.

Fig. B - Bowel ultrasound, linear high-frequency probe. Thickening of bowel wall, dominant is hyperchoic submucosa, no swelling of the wall or adjacent fat – corresponds to **chronic changes** in **Crohn's disease**.

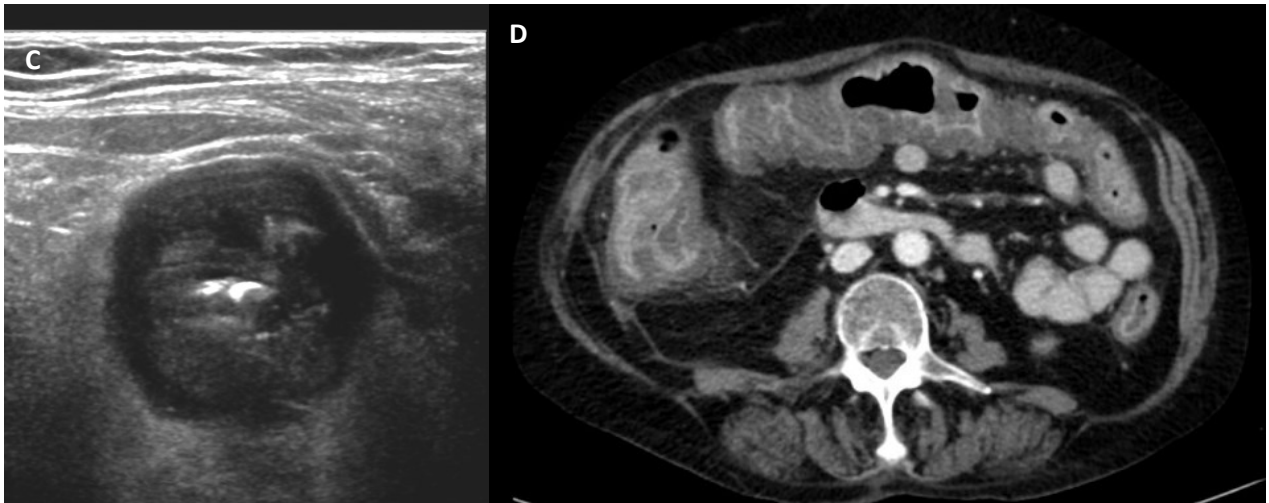


Fig. C – Bowel ultrasound, high-frequency linear probe. **Clostridium colitis** – thickening and edema of the large intestine wall (layers of the wall are visible). Extensive thickening of the hypoechoic large bowel wall due to edema, edema causes blurring of wall layers (but are distinguishable). There is also edema of adjacent fat.

Fig. D – Contrast-enhanced CT in portal phase, axial plane. Image of **Clostridium colitis** – diffuse thickening of large bowel wall with extensive enhancement of mucosa and swelling of the bowel wall and adjacent fat

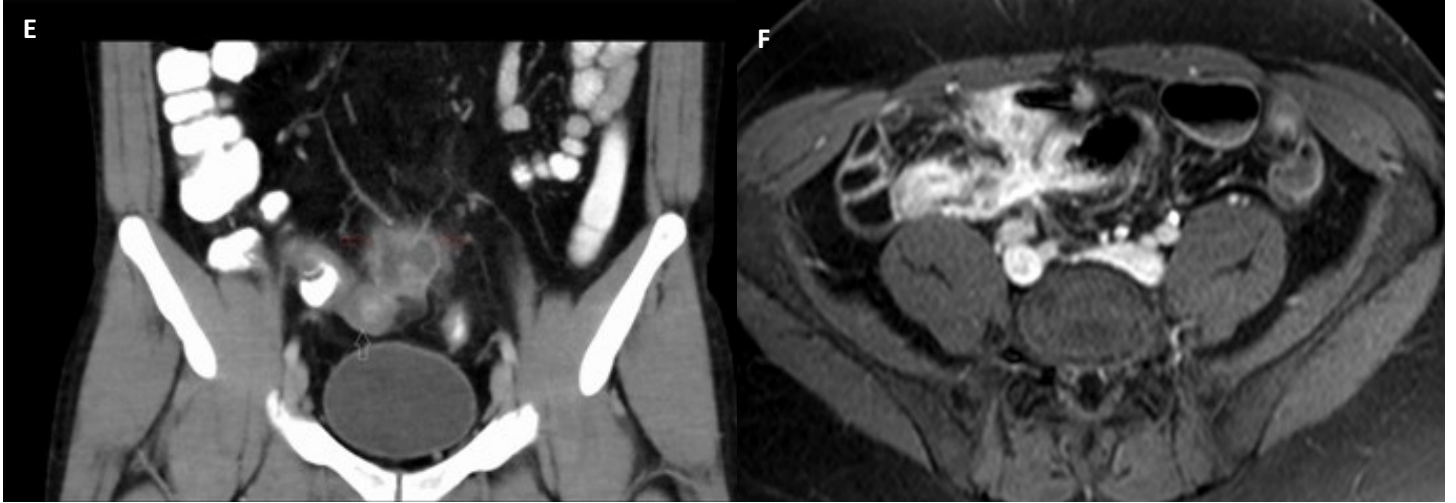


Fig. E – Contrast-enhanced CT of the abdomen, coronal plane, portal phase, positive peroral contrast. Thickening and edema of terminal ileum with swelling of adjacent fat and adjacent abscess (fluid collection with enhancing rim and swelling of adjacent fat) – image of active inflammation of Crohn’s disease complicated by abscess.

Fig. F - MR enterography, T1 contrast-enhanced sequence in axial plane. Inflammatory changes of terminal ileum and aboral ileum with a fistula between these small bowel loops.