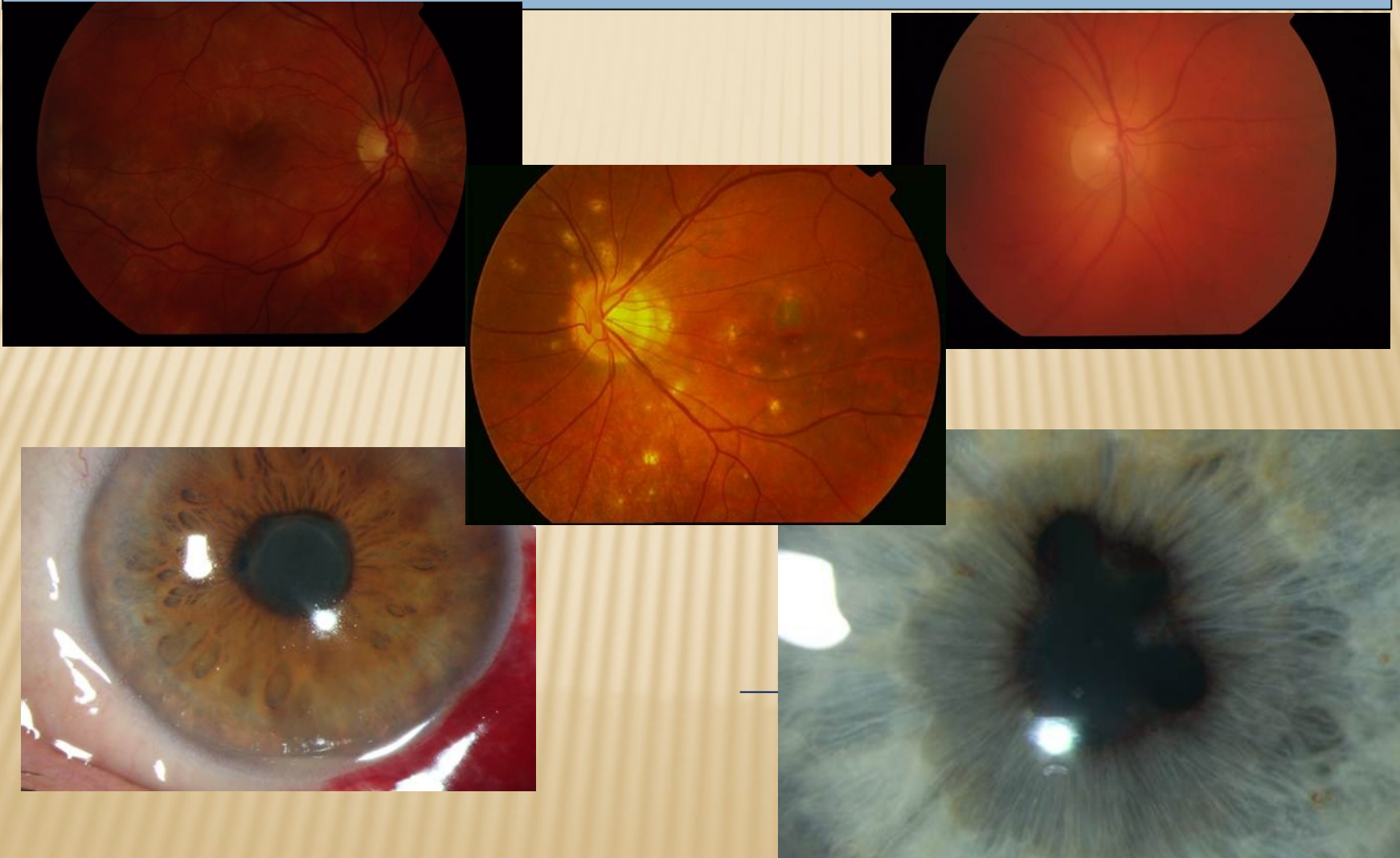


INFLAMMATION OF THE UVEA - UVEITIS



ANATOMY AND PHYSIOLOGY OF THE UVEA

3 parts:

- iris (iris)
- ciliary body (corpus cilliare)
- choroid (choroidea)

Function:

- regulation of the entry of the light into the eye (pupil)
- accomodation
- production of aqueous humor

DEFINITION OF UVEITIS

Uveitis – inflammation of the uvea

- Intraocular inflammation causes damage of the endothelium of intraocular vessels with the collapse of the blood-barrier.
- There is a dilation of blood vessels, leakage intravascular content into the intravascular space, migration of leukocytes and other cells.

CLASSIFICATION OF UVEITIS

Anatomical:

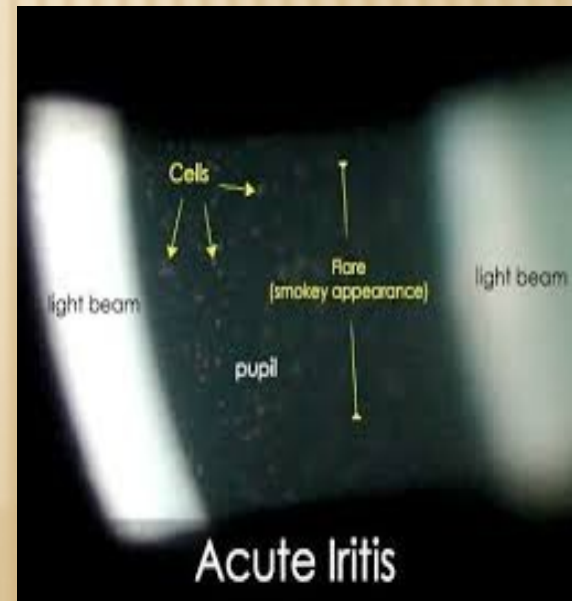
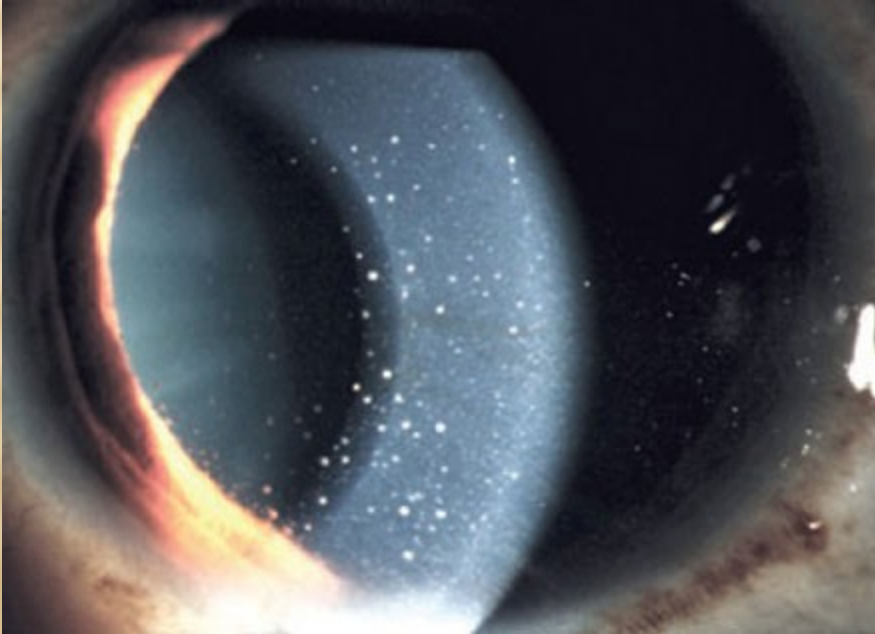
- anterior (iritis, iridocyclitis)
- intermediate (pars planitis, cyclitis, vitritis)
- posterior (choroiditis, chorioretinitis)
- all parts (panuveitis)

Clinical:

- acute - symptoms suddenly, lasting no longer than 6 weeks
- chronic - gradual onset of symptoms, duration of more than 6 weeks

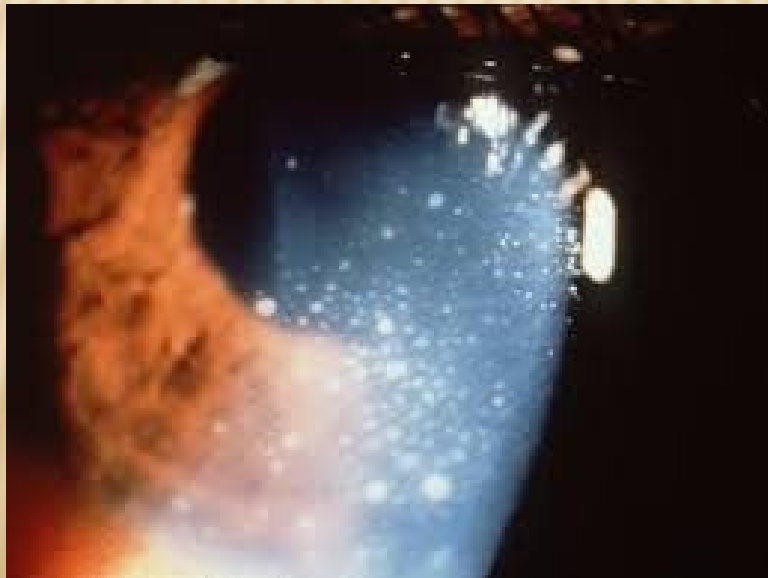CLASSIFICATION OF THE UVEITIS

- nongranulomatous – acute formation, short duration, significant ciliary injection, small precipitates on the corneal endothelium, cells in the anterior chamber, fibrinous exsudate



CLASSIFICATION OF THE UVEITIS

- granulomatous – slow formation, protracted course, significant ciliary injection, precipitates on the corneal endothelium, iris nodules, vitritis, often affected choroid



CLASSIFICATION OF THE UVEITIS

According to the etiology:

Exogenous (injury uvea, microorganism invasion from the outside)

Endogenous (inner, systemic inflammatory origin)

- uveitis associated with systemic disease (eg. ankylosing spondylitis, sarcoidosis, tuberculosis, multiple sclerosis)
- uveitis associated with parasitic infection (eg. toxokarosis)
- uveitis associated with viral infection (eg. herpes simplex)
- uveitis associated with fungal infection (eg. candida)
- idiopathic uveitis (comprises about 25% of all uveitis)

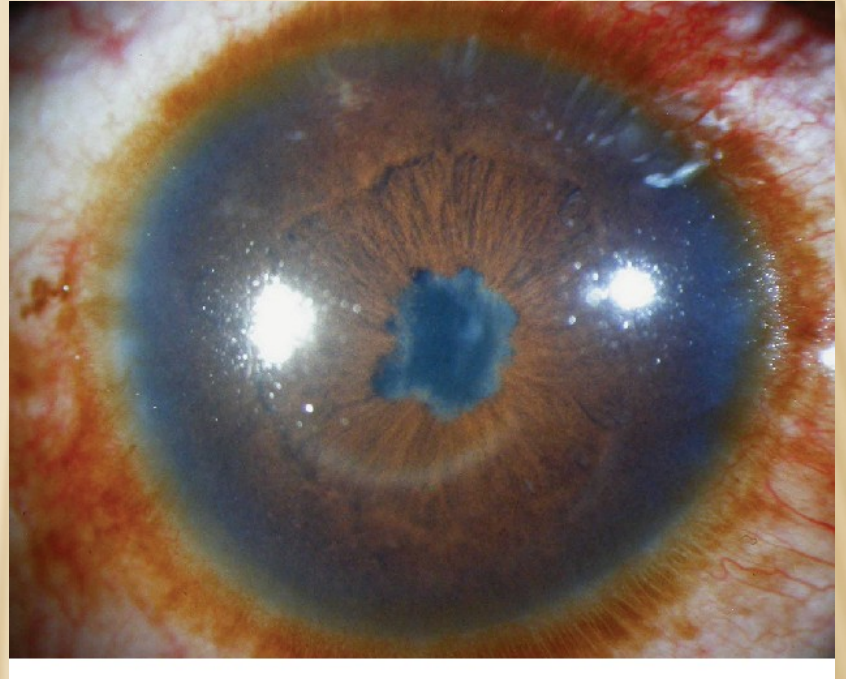
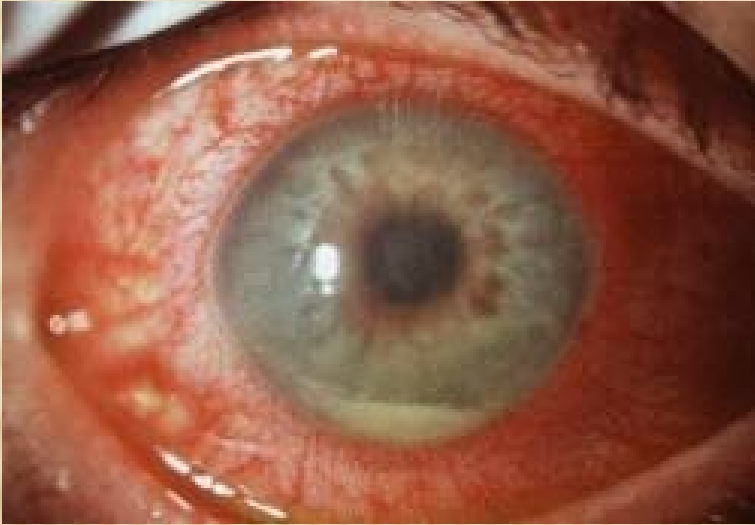ACUTE NONGRANULOMATOUS IRIDOCYCLITIS

Signs and symptoms:

- eye pain, photophobia, epiphora
ciliary injection
- small precipitates on the corneal endothelium, abundant cells in the anterior chamber, in the course of severe fibrinous exudate in the anterior chamber
- hypopyon
- synechiae formation (adhesions between the iris and lens)
- dilation of blood vessels in the iris

- Chronic complications (formation of synechiae in case of delayed treatment, complicated cataract development)

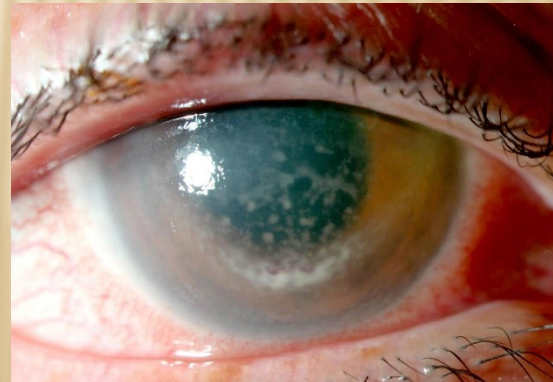
- Treatment: corticosteroids locally, parabolbar, if necessary, generally, mydriatics, in the case of viral etiology antivirals



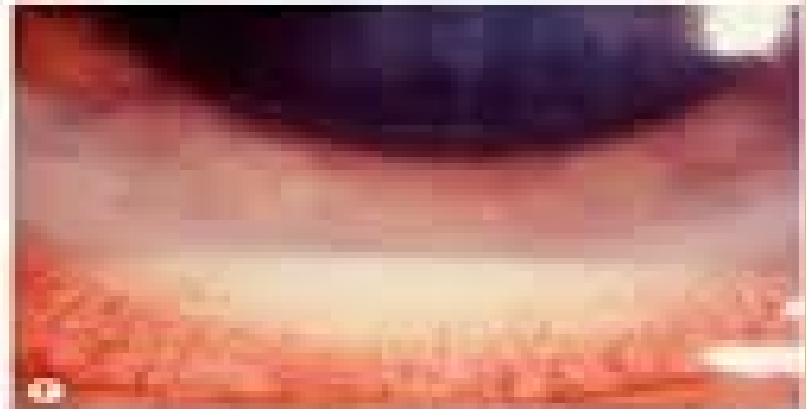
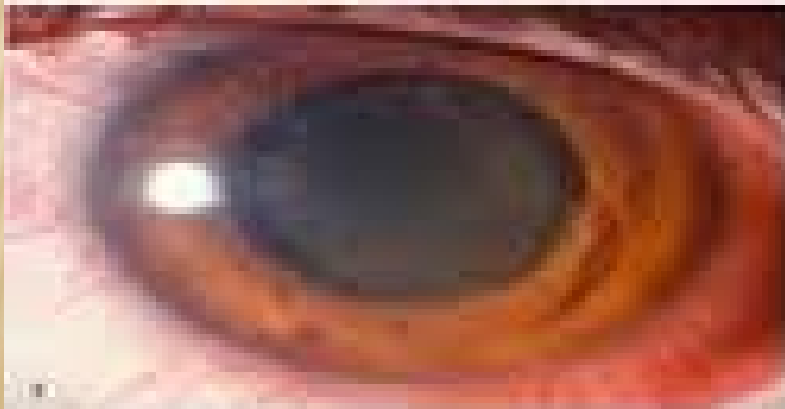
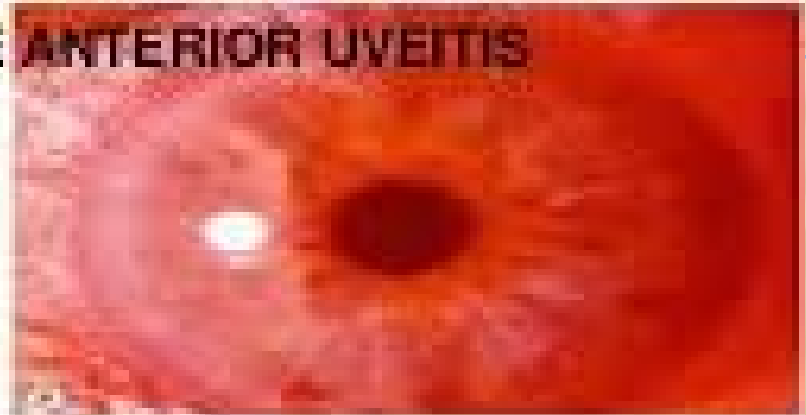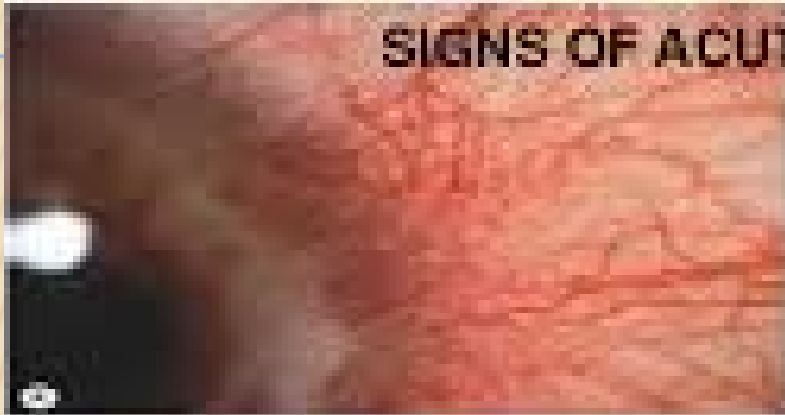ACUTE ANTERIOR NONGRANULOMATOUS IRIDOCYCLITIS

Etiology:

- **HLA B27+** izolation, Ankylozing spondilitis (M. Bechtěrev), Reiter syndrom, M. Crohn, Colitis ulcerosa, Psoriatic artritis
- **Phacoanafylaktic uveitis** – imunological reaction on free proteins of the lens
- **Viral diseases** – Herpes simplex, herpes zoster in combination with keratitis



SIGNS OF ACUTE ANTERIOR UVEITIS

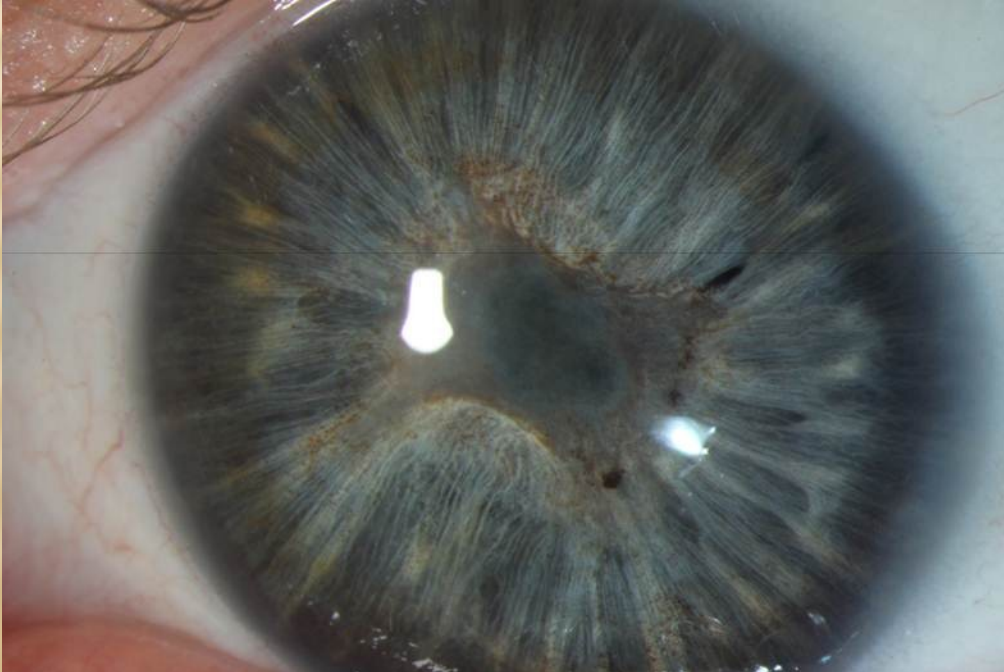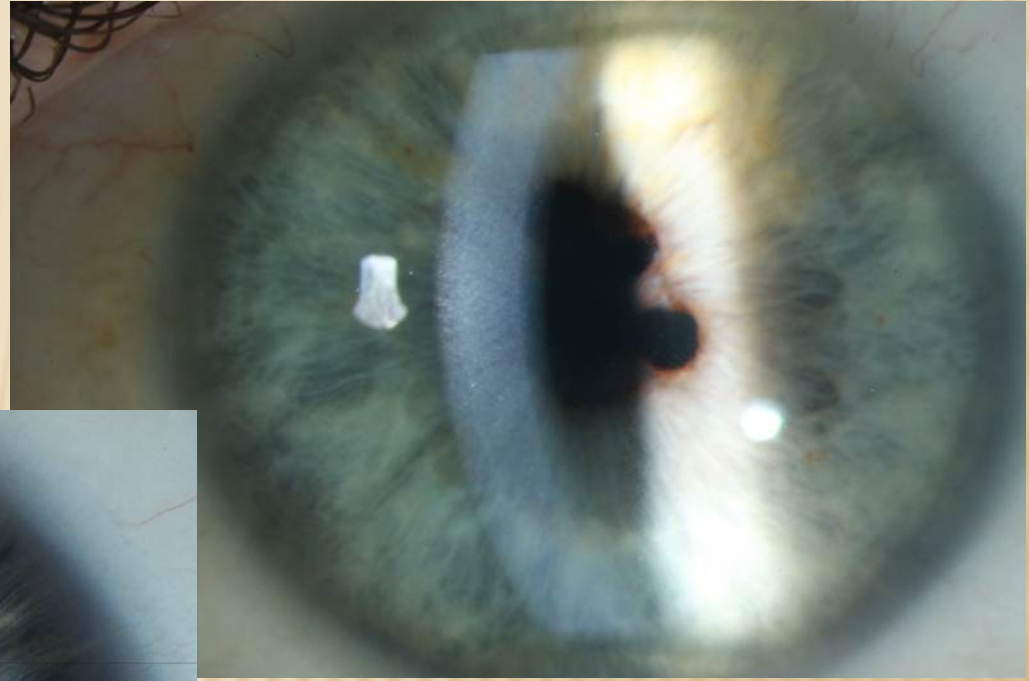


CHRONIC ANTERIOR IRIDOCYCLITIS

Signs and symptoms:

- creeping course, variable symptoms, usually no pain or only mild pain
- mild ciliary injection, mostly pale bulb, a small amount of precipitates on the corneal endothelium, a small number of cells in the anterior chamber
- lower tendency to the formation of the synechiae, chronic complications according to the disease activity (formation of complicated cataract, secondary glaucoma)
- Treatment: corticosteroids and nonsteroidal anti-inflammatory drugs locally, if necessary parabolbar or systemic, mydriatics, and according to etiology

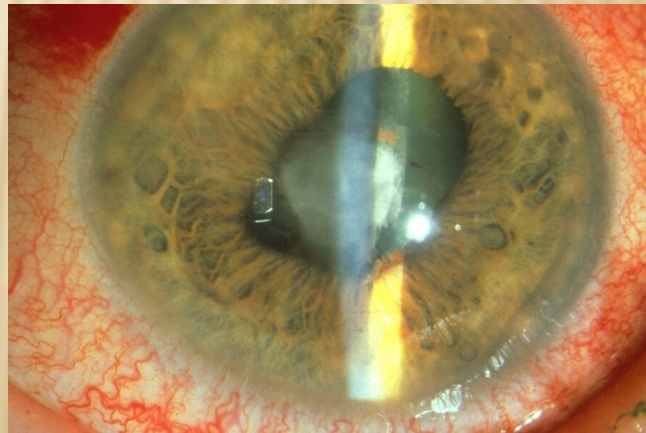
CHRONIC ANTERIOR IRIDOCYCLITIS



CHRONIC ANTERIOR IRIDOCYCLITIS

Etiology:

- Juvenile rheumatoid arthritis
- Sarcoidosis (granulomatous inflammation type)
- Syphilis (roseolae of iris)
- Lyme disease
- TBC (granulomatous inflammation type, yellow nodules on iris)

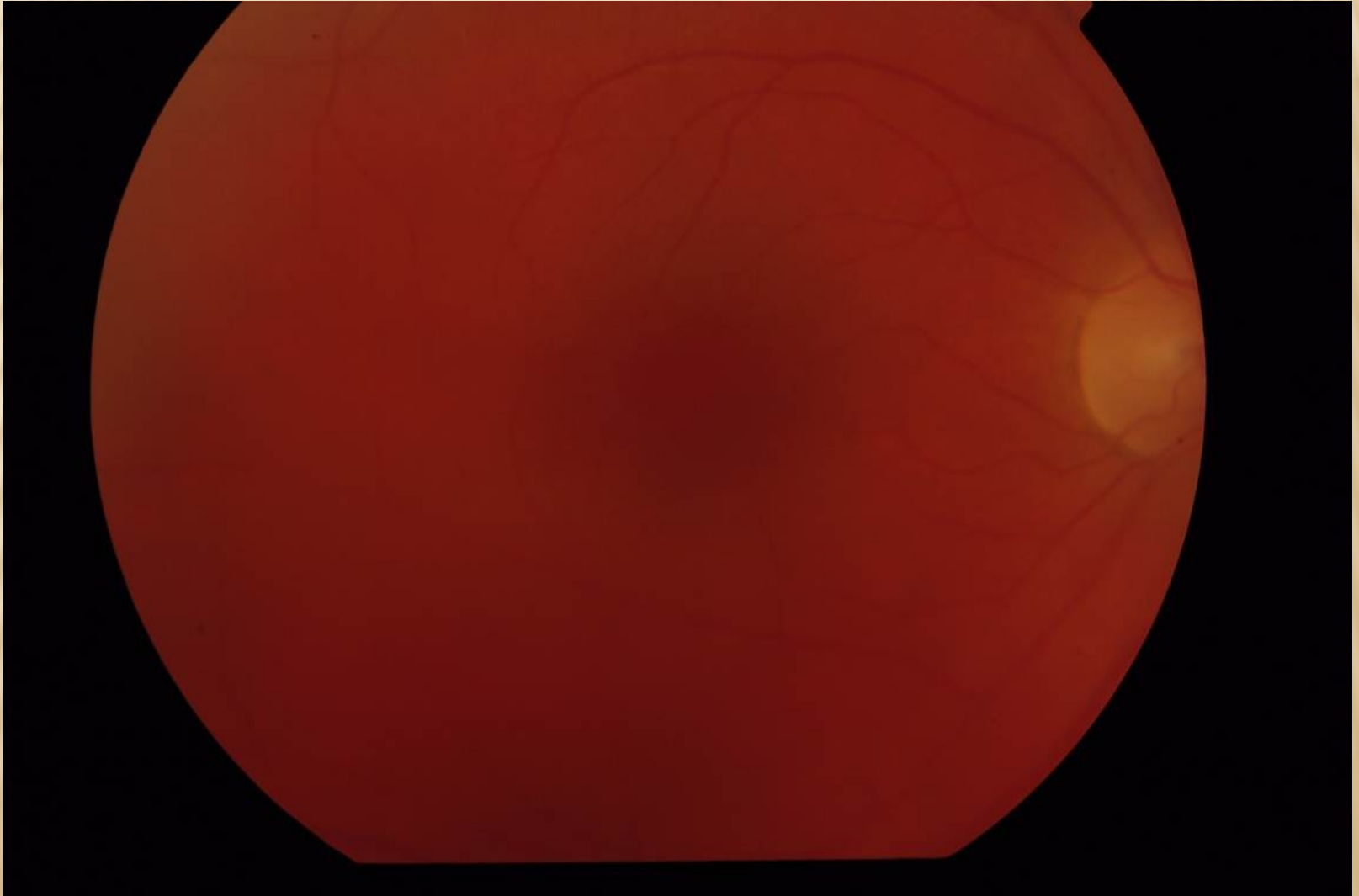


INTERMEDIATE UVEITIS (CYCLITIS, PARS PLANITIS)

Manifestations, symptoms, etiology:

- creeping course, without pain, decrease vision- opacities, fog
- mostly pale bulb
- vitritis - vitreous opacities (snowballs, snow benches)
- with increased activity of inflammation macular edema
- chronic complications (development of complicated cataract, macular epiretinal membranes, preretinal and subretinal neovascular membranes)
- Treatment: according to the disease activity monitoring, corticosteroids overall or intravitreal corticosteroids, immunosuppressants (cyclosporine), biological therapy, PPV
- possible link with MS or Lyme disease or unclear

INTERMEDIATE UVEITIS (CYCLITIS, PARS PLANITIS)

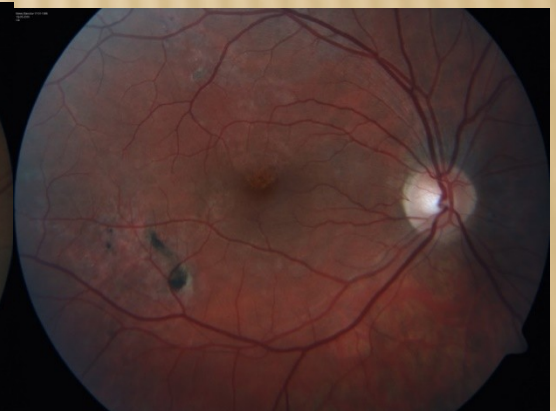
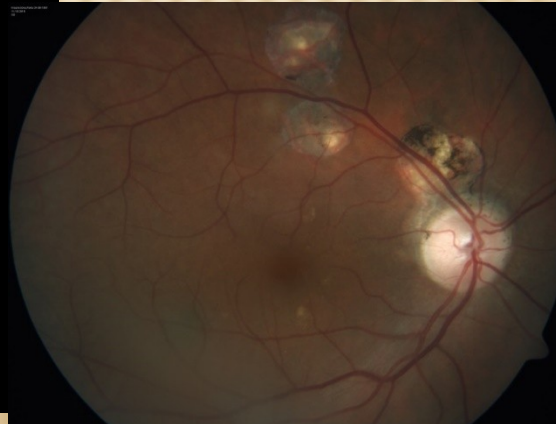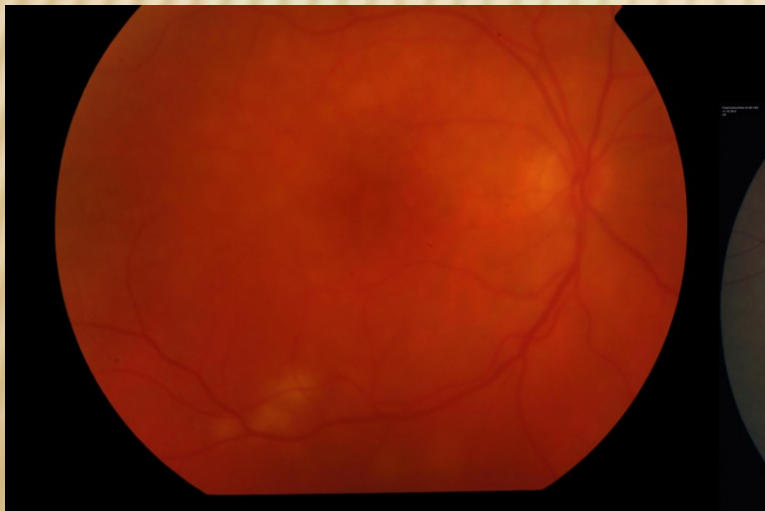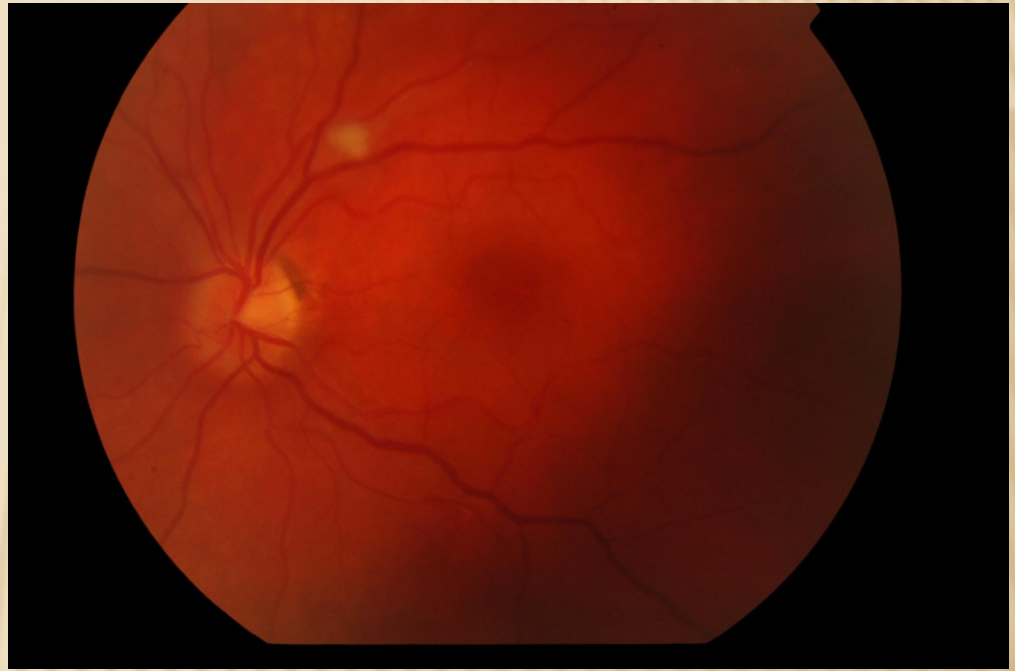


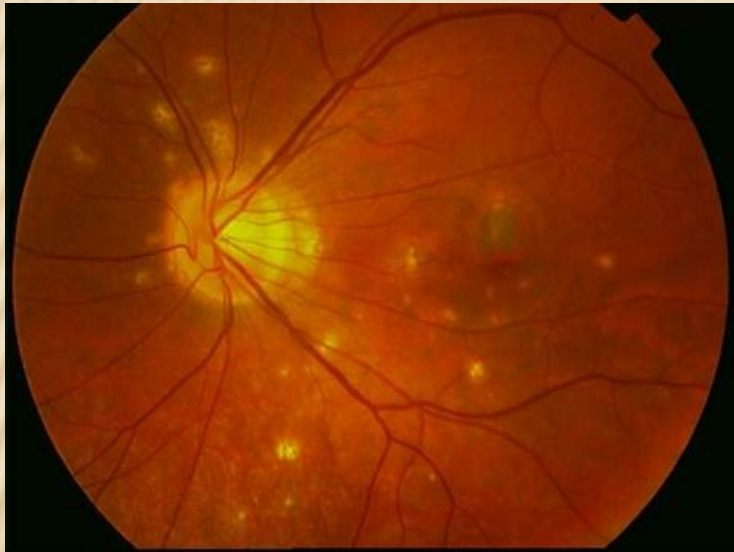POSTERIOR UVEITIS (CHORIORETINITIS, CHOROIDITIS)

Manifestations symptoms:

- beginning acute without pain, decrease vision- vitreous opacities, fog
- mostly pale bulb
- vitritis - vitreous opacities
- Well demarcated lesions affecting retina and choroid (focal or multifocal)
- with increased activity of inflammation macular edema
- chronic complications (development of chorioretinal scars)
- Treatment: due to etiology, in infectious etiology causally antibiotics, antivirals systemically, in autoimmune etiology systemic corticosteroids or systemic immunosuppressants

POSTERIOR UVEITIS (CHORIORETINIS, CHOROIDITIS)



POSTERIOR UVEITIS (CHORIORETINITIS, CHOROIDITIS)

Etiology:

- Toxoplasmosis (frequently)
- Toxocarosis
- Candidosis (in patient with decreased immunity)
- Sarcoidosis, TBC (granulomatous inflammation type)
- Herpes simplex, zoster retinitis
- CMV retinitis (in immunocompromised patients)
- White dot syndroms (isolated autoimmune inflammation against retinal structures)
- Sympathetic ophthalmia

ENDOPHTHALMITIS

Severe form of intraocular inflammation affecting intraocular tissue structures, but does not go beyond the sclera.

- **Exogenous** - postoperative (acute 1-14 days after surgery, chronic two weeks up to two years after surgery), post-traumatic
- **Endogenous** - hematogenous transmission of pyogenic bacteria or mold (candida) for generalized septicemia

Frequently agent: Staphylococcus, Streptococcus, Candida, Propionibacterium, Klebsiella, Haemophilus, Escherichia

ENDOPHTHALMITIS

Manifestation, Symptoms:

- **Acute endophthalmitis** – pain, sudden decrease in vision, conjunctivitis, edema of the eyelids, corneal edema, hypopyon, vitritis, necrosis of the retina
- **Chronic endophthalmitis** – without pain, visual acuity decreased only slightly, hypopyon just sometimes, mild vitritis

Treatment:

- ATB, antimycotics in infusions, eventually intravitreal
- PPV



