

Class II. – modifications for amalgam

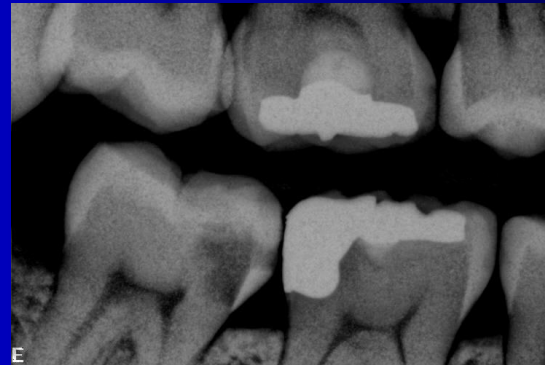- Conventional preparation
- Slot
- Large cavities – replacement of the cusp (cusps), combination with the cavity on vestibular/oral surface

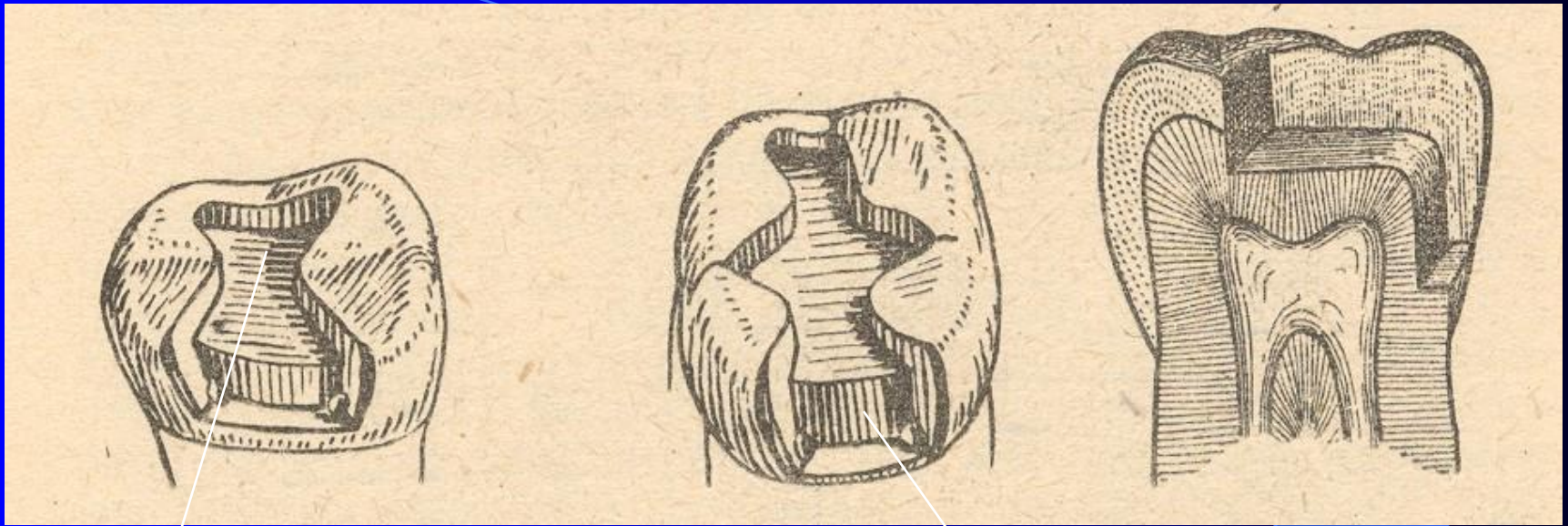
Class II.

Origin:

Proximal surface below the contact point

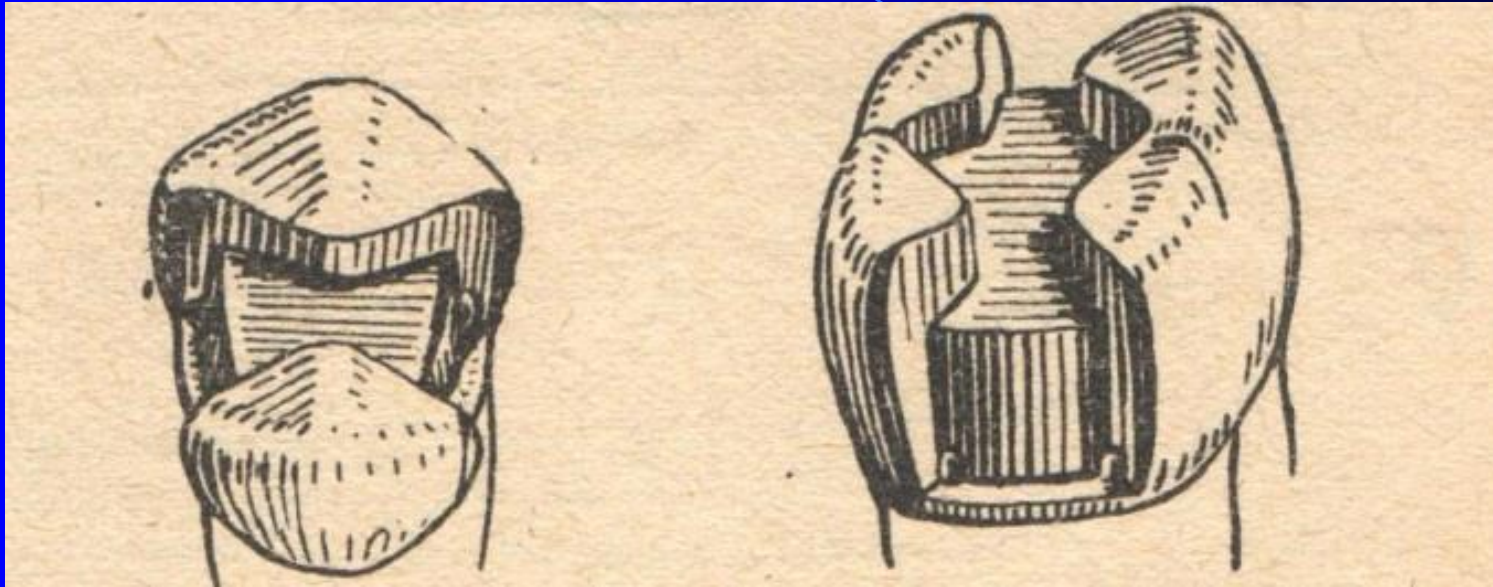
Propagation of dental caries from
the occlusal surface



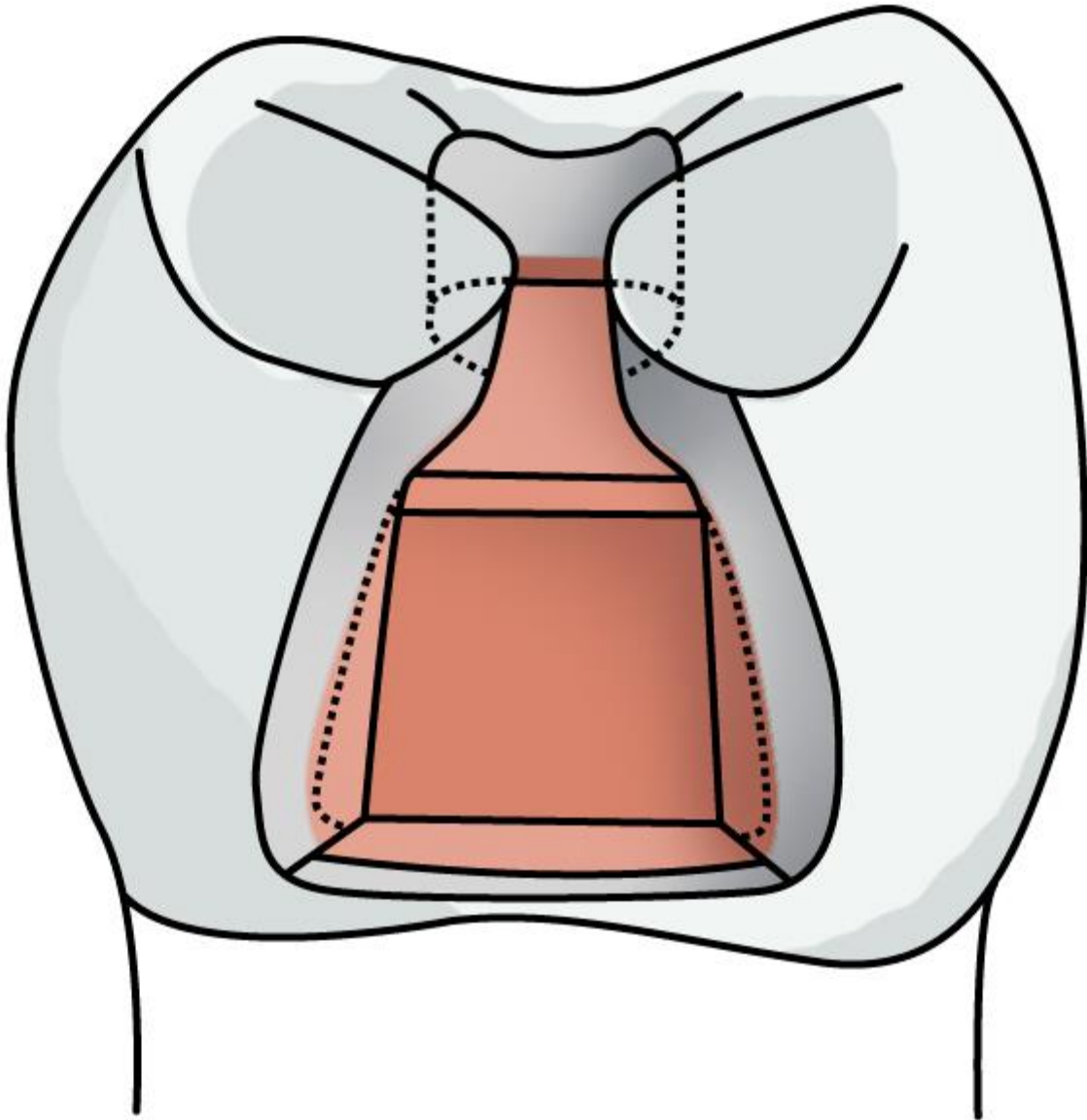


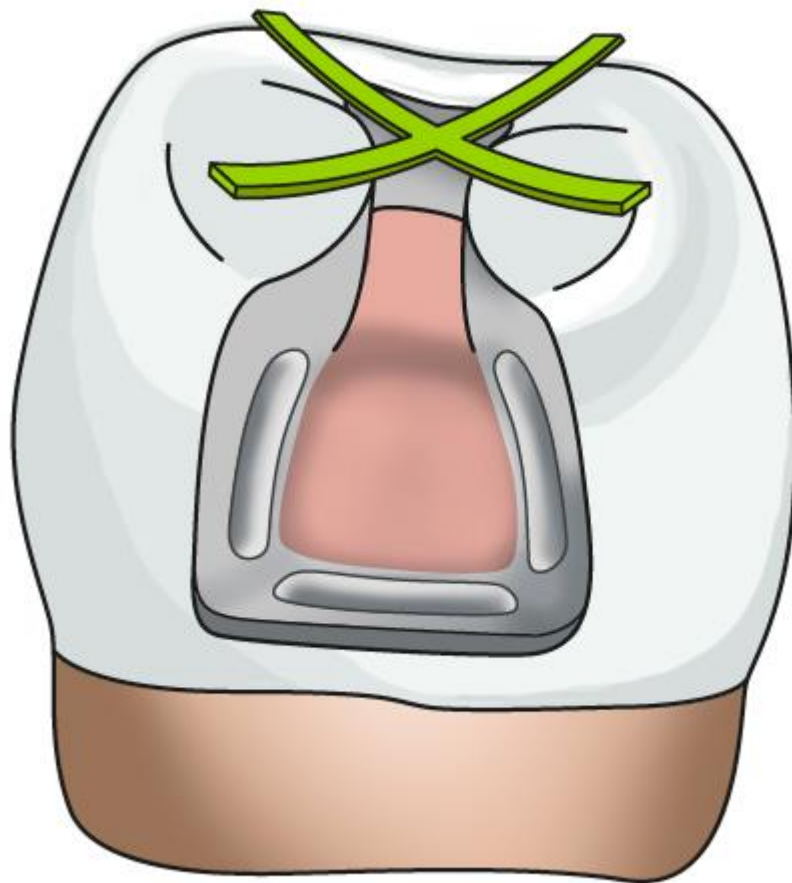
Occlusal cavity

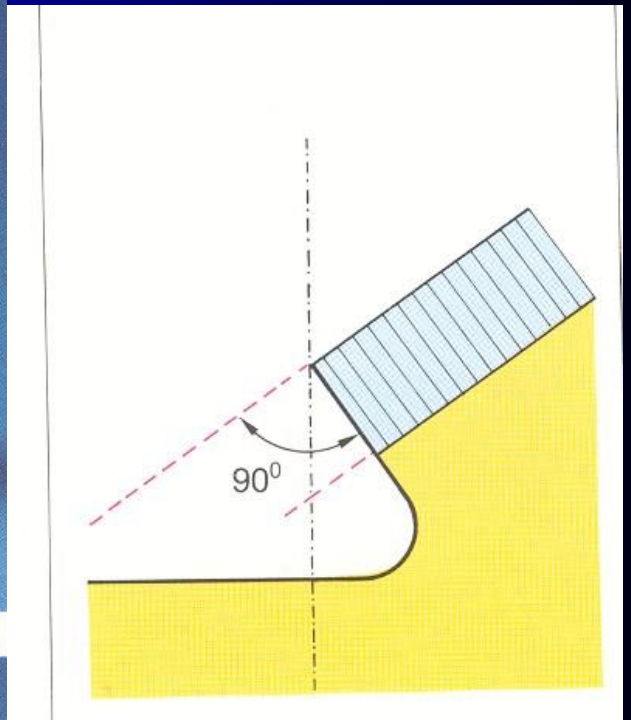
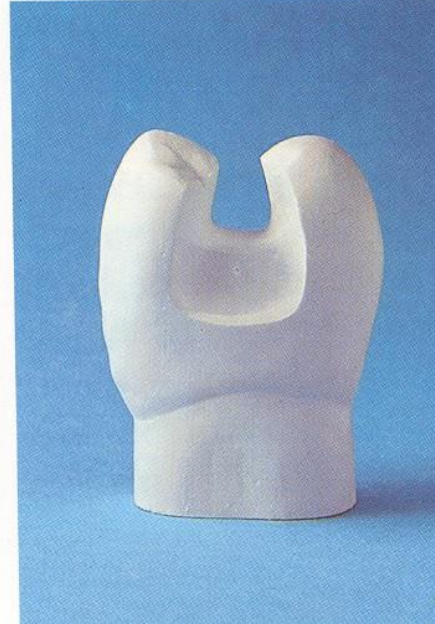
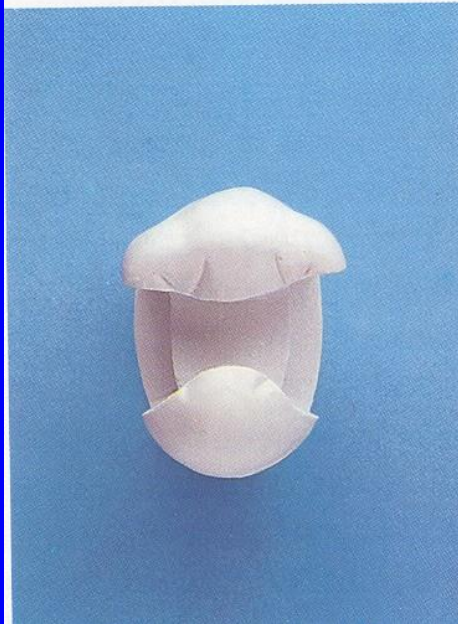
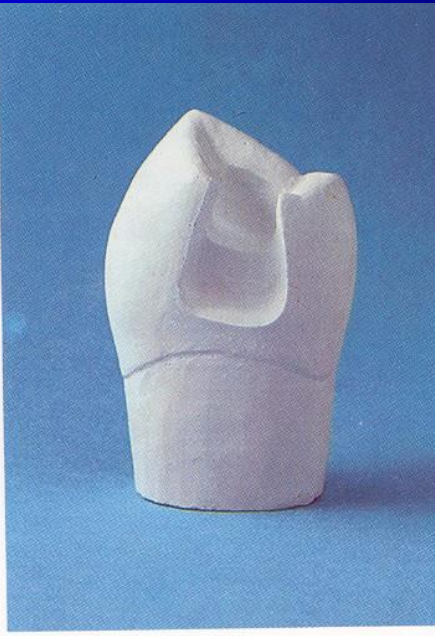
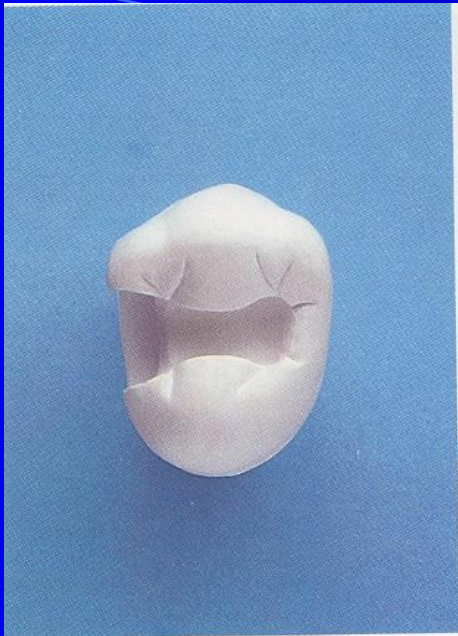
Proximal cavity




MOD





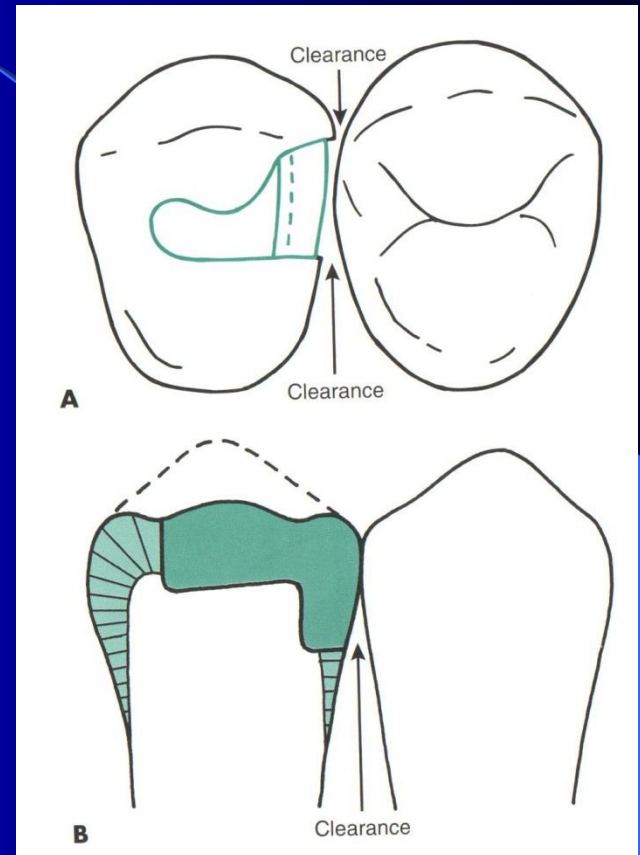




Cavosurface angle

Slight reverse curve

Clearance of the proximal surface



Matrix placement

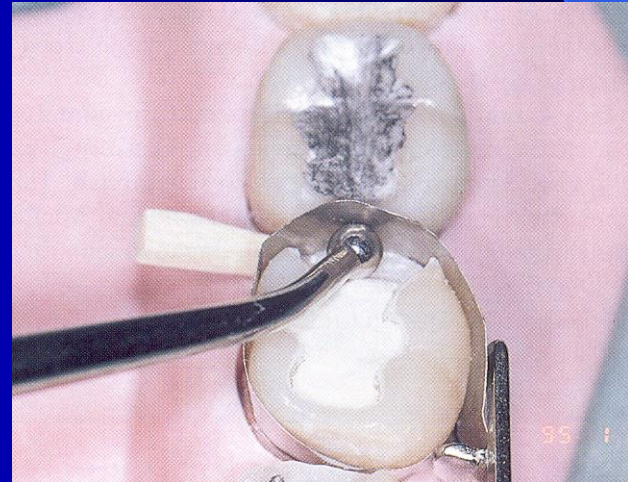
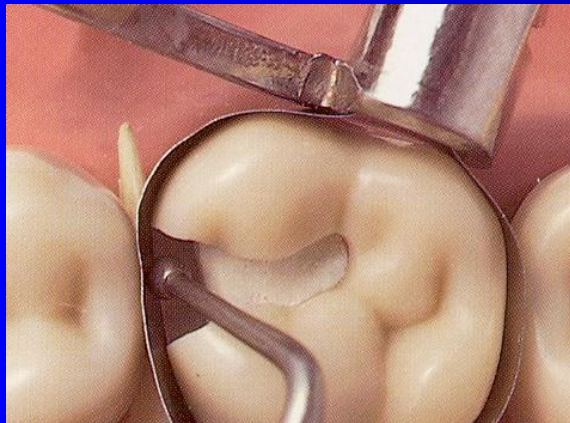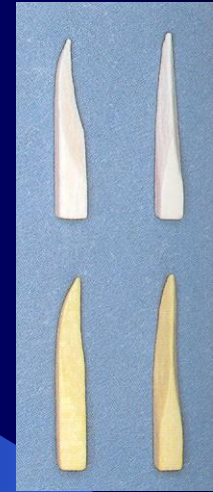- Matrix primarily is used when a proximal surface is to be restored

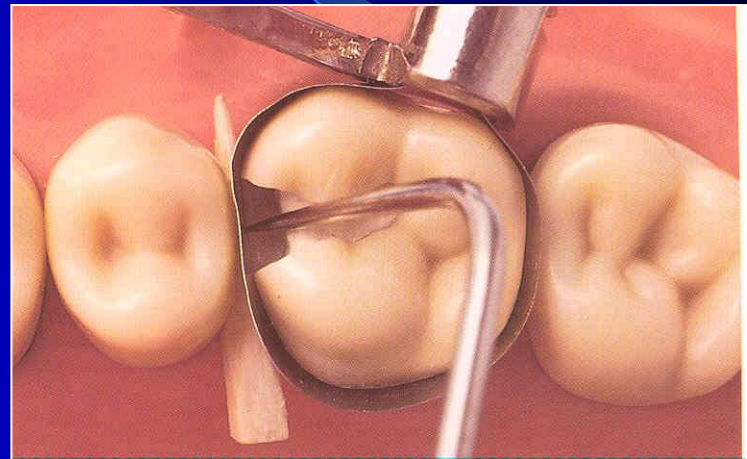
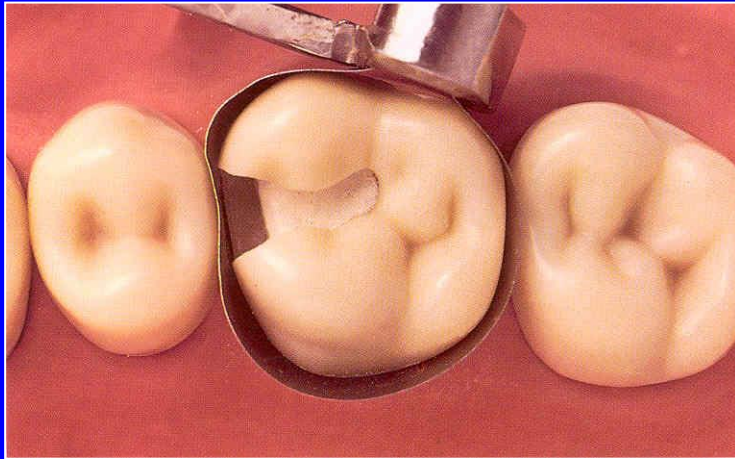

The objectives:

- Provide proper contact
- Provide proper contour
- Confine the restorative material
- Reduce the amount of excess material

Matrices

- Ivory I retainer Ivory 1
- Hawe Neos retainer Ivory 8
- Tofelmire matrix and retainer

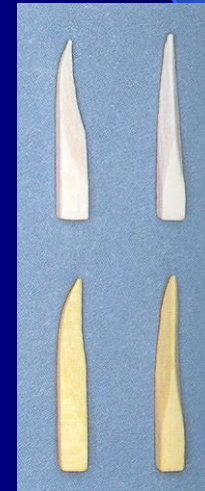




Wedges


➤ Wooden wedges

- tighten the matrix band
- compress the gingiva
- separate the teeth



Wedging

- Slip the matrix band over the tooth
)apical to the gingiva margin – 0,5, - 1 mm)
- Tighten the matrix, check it with probe
- Place a wedge
- Turn the retainer $\frac{1}{4}$ counterclockwise
- Contour the band

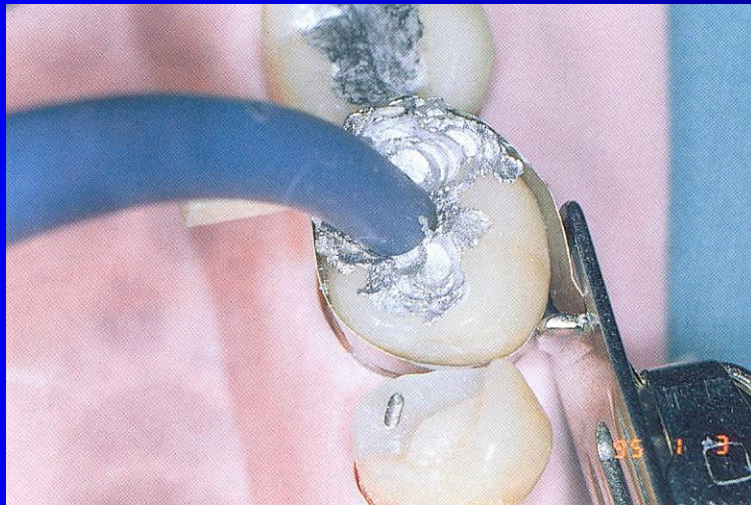
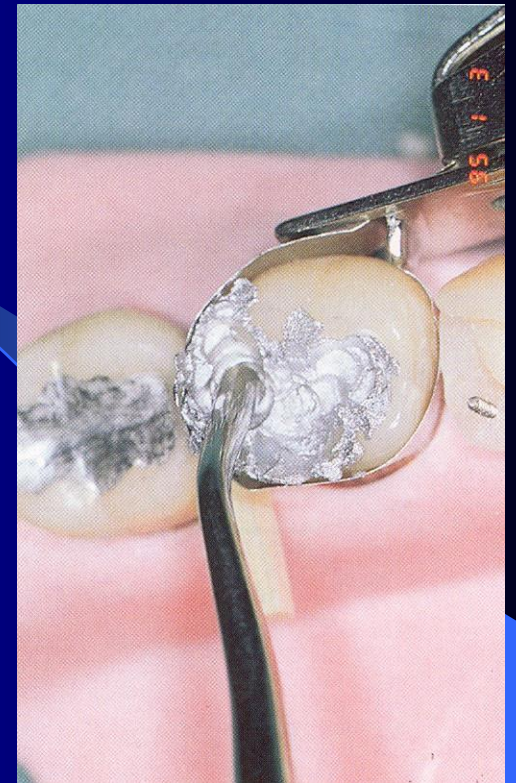


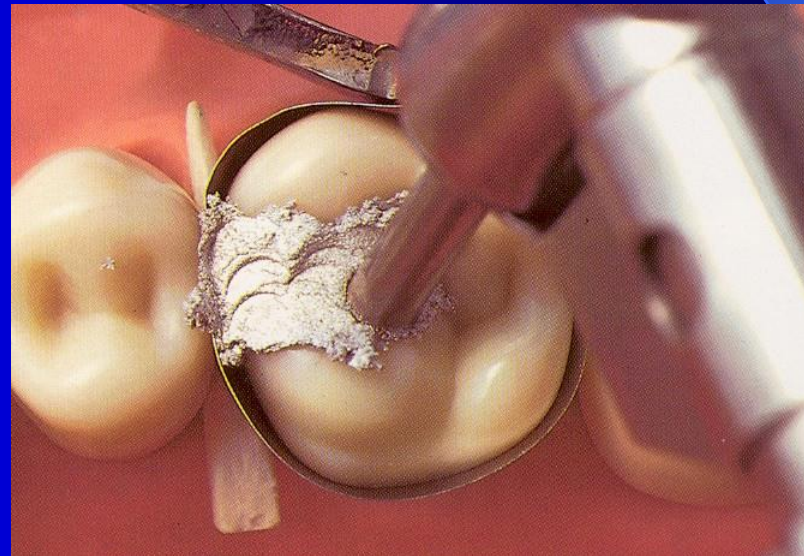
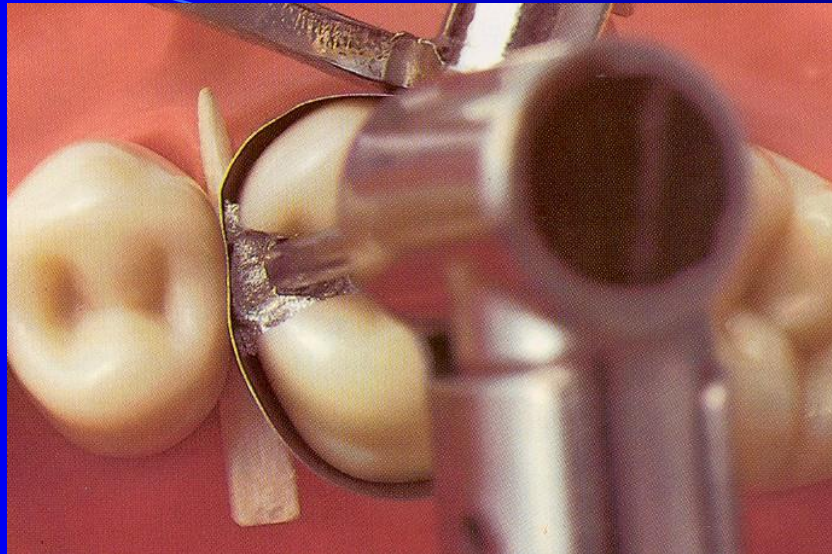
Amalgamators

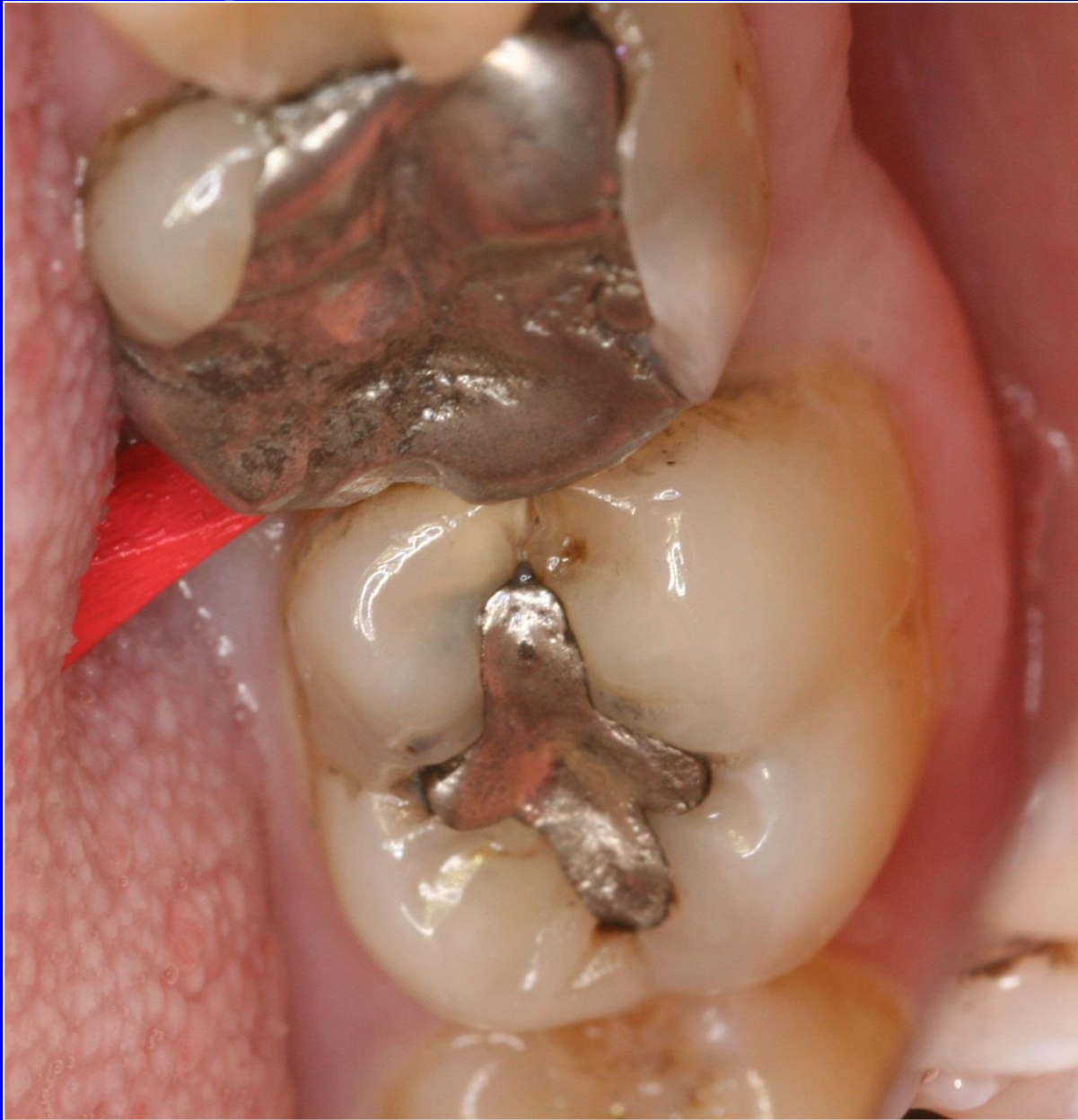Condensation of amalgam

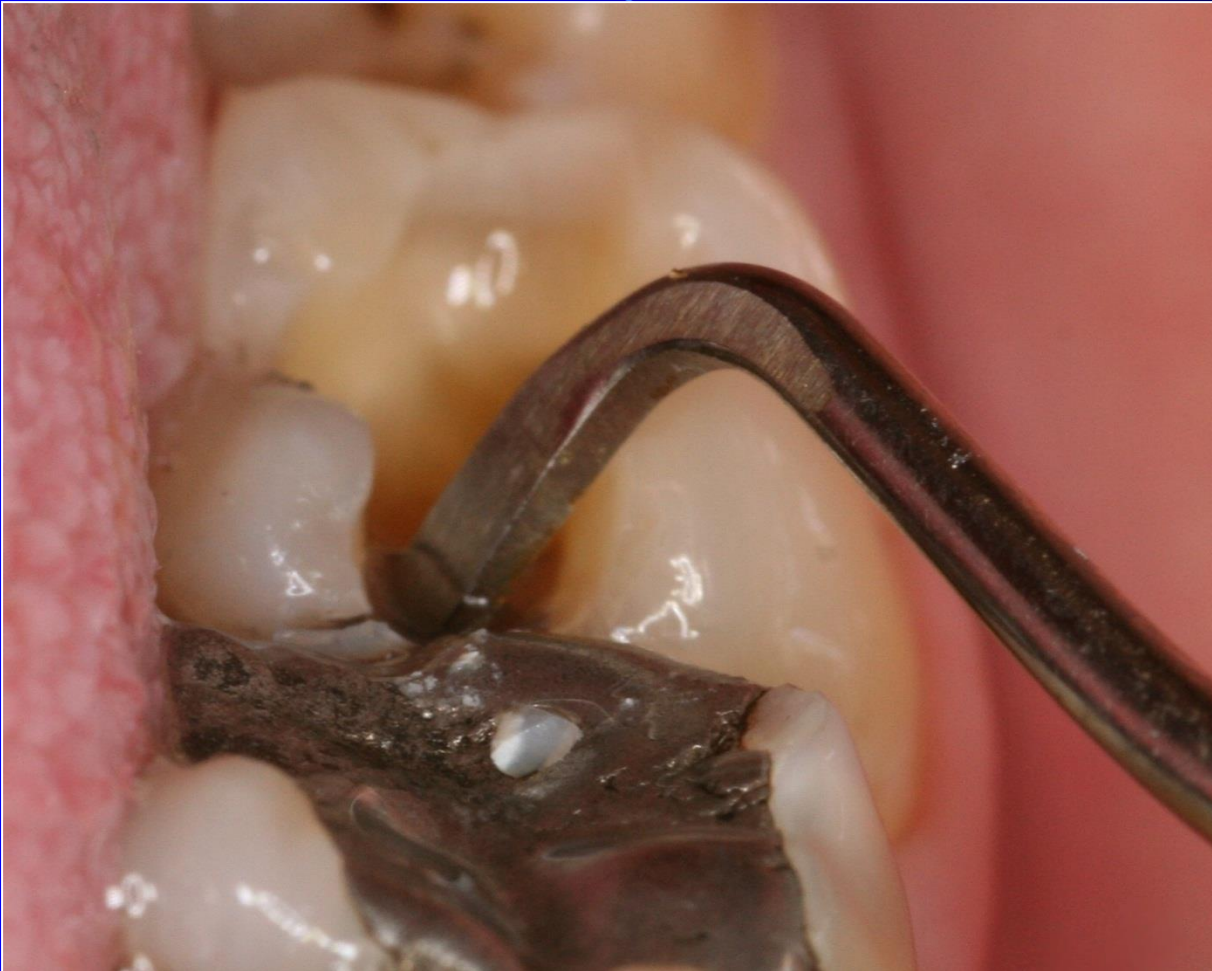- Condensor – with the straight front
- Power driven condensation

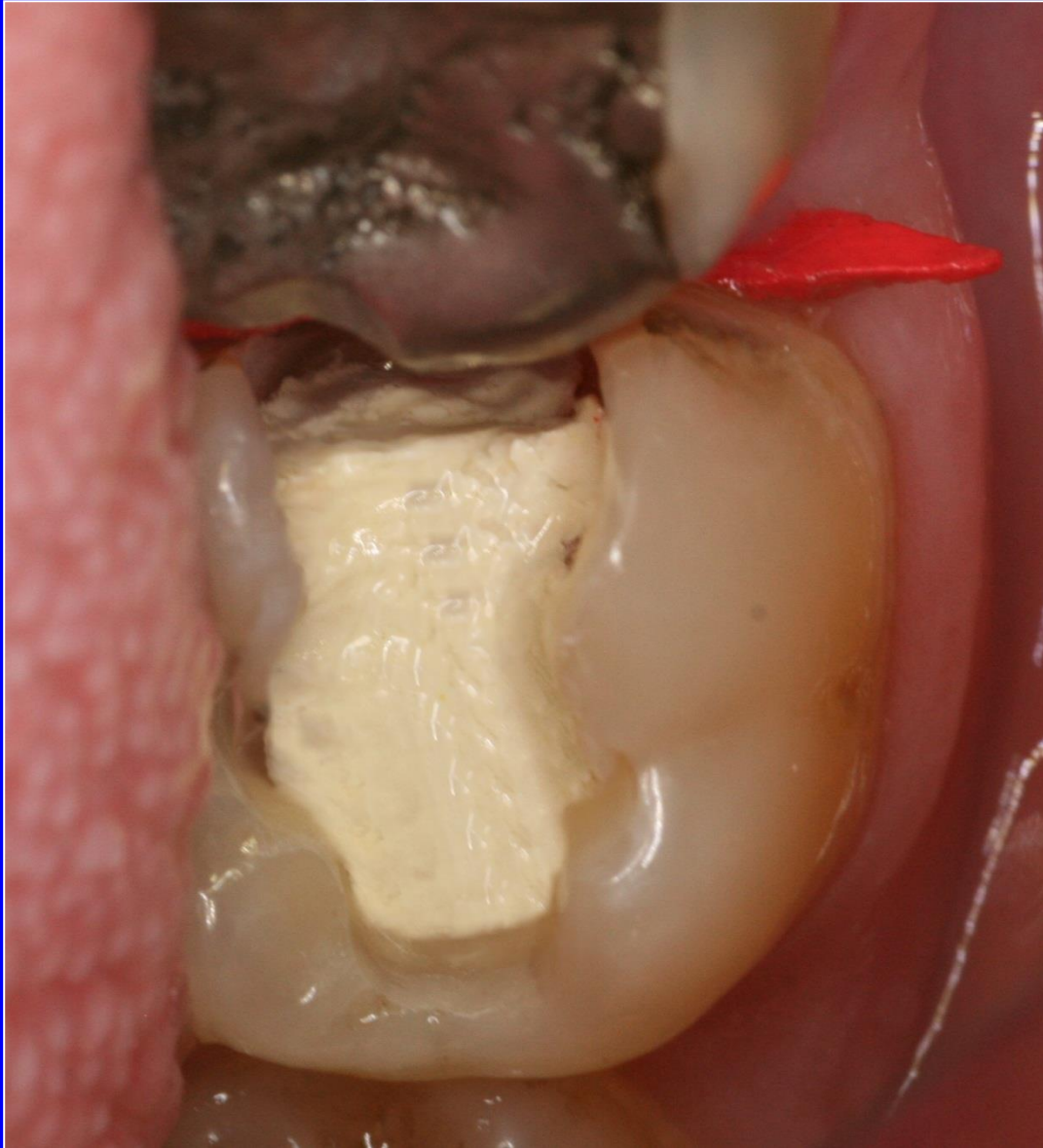How big should the front be?

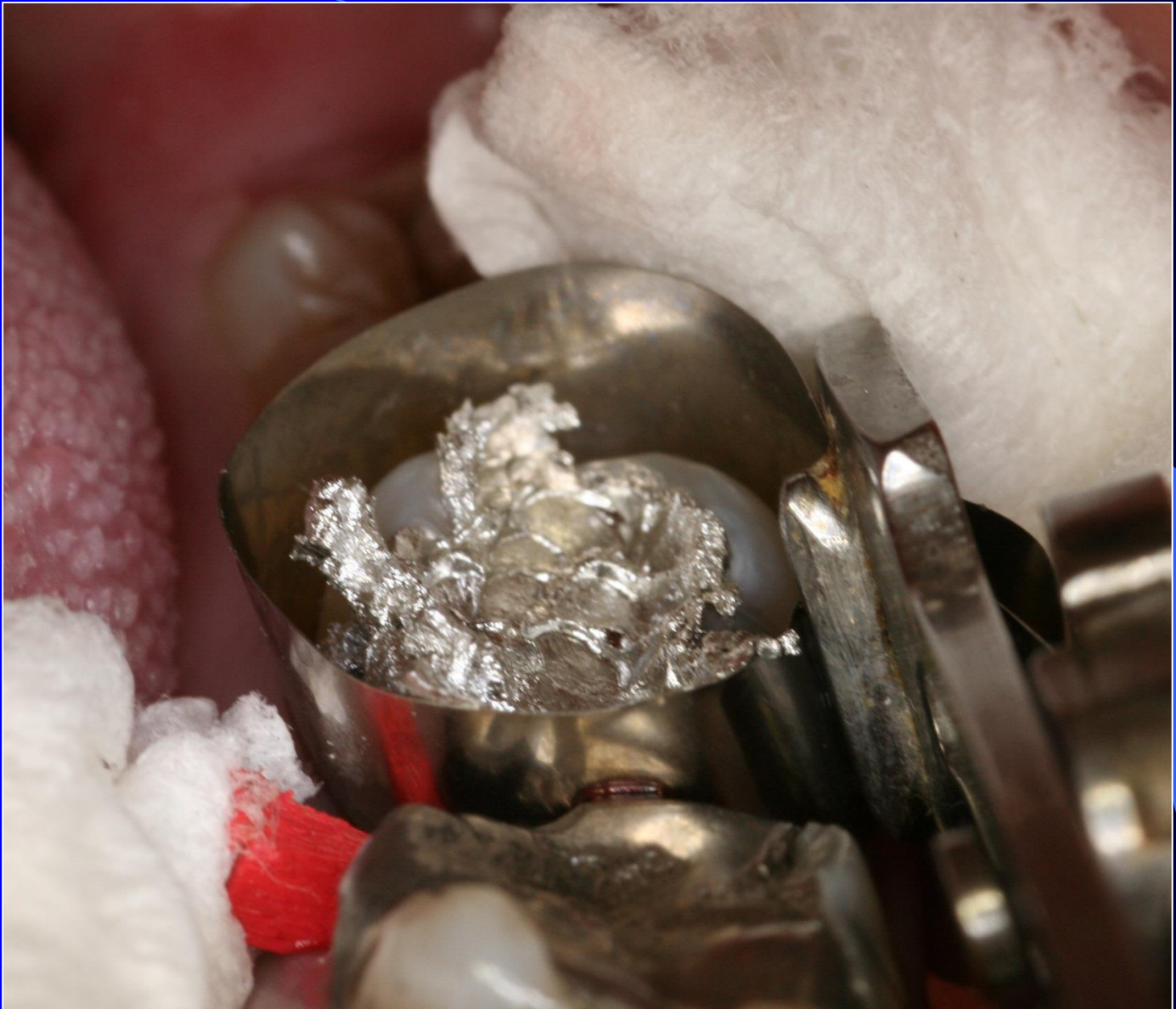


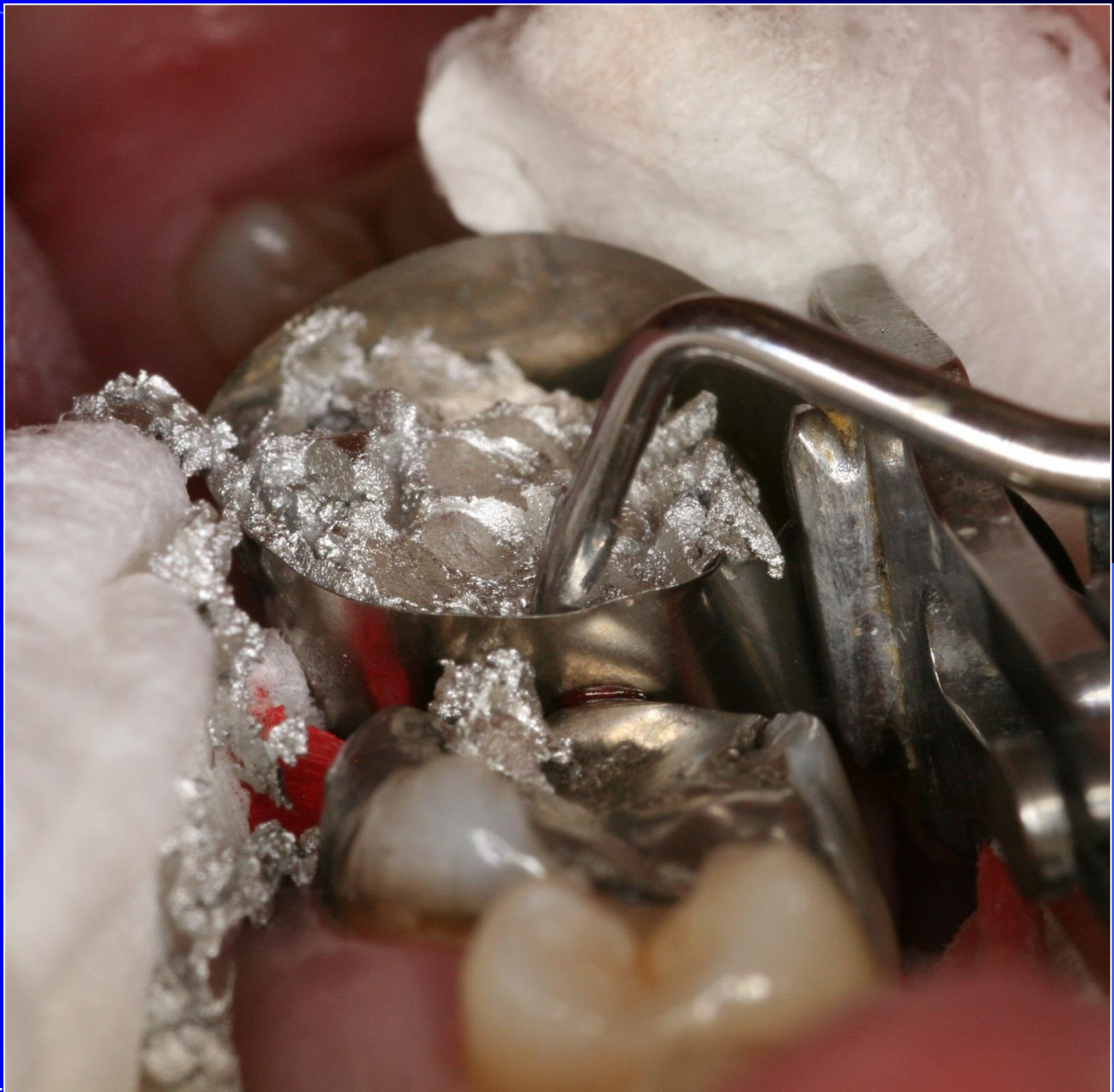


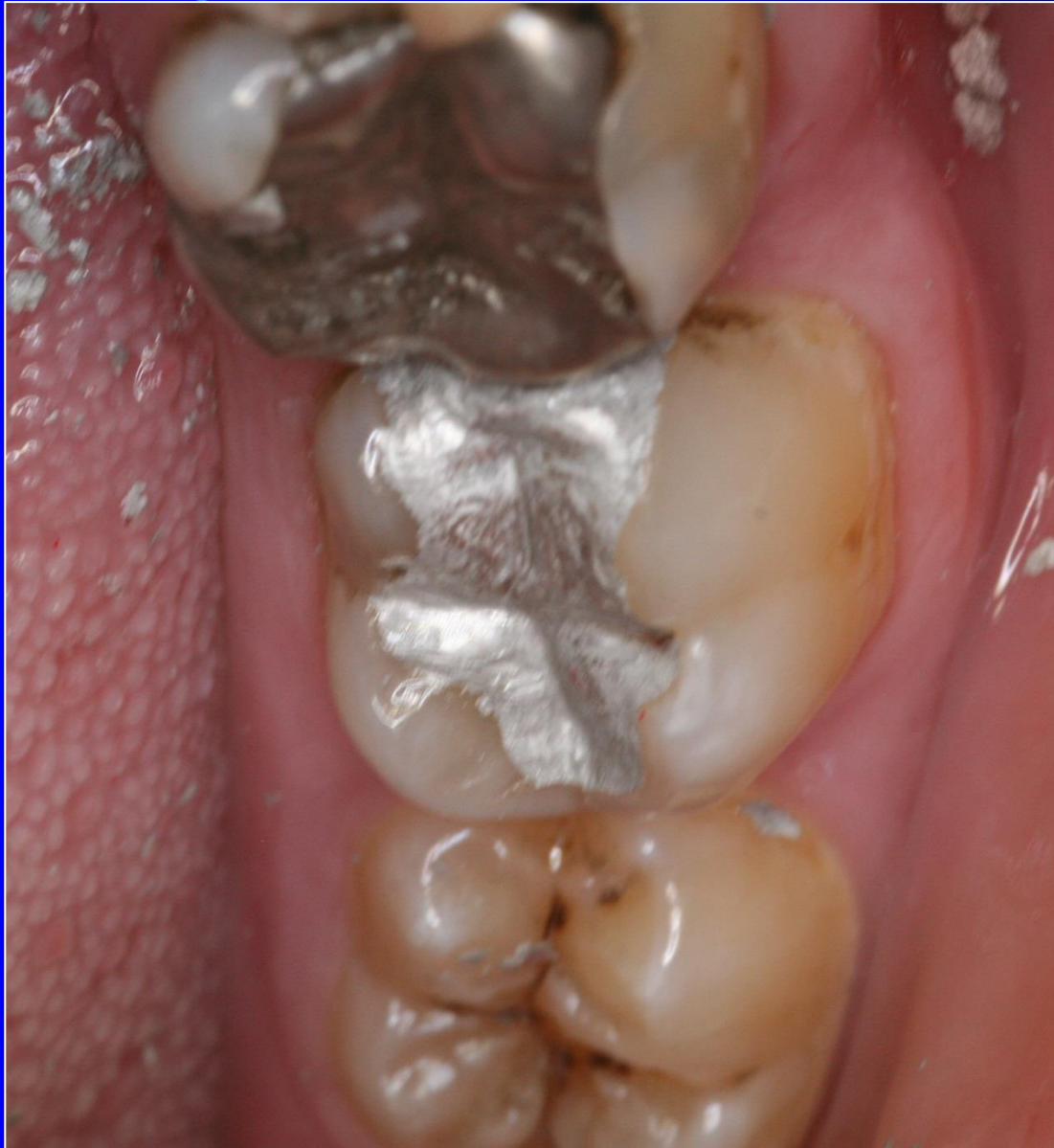





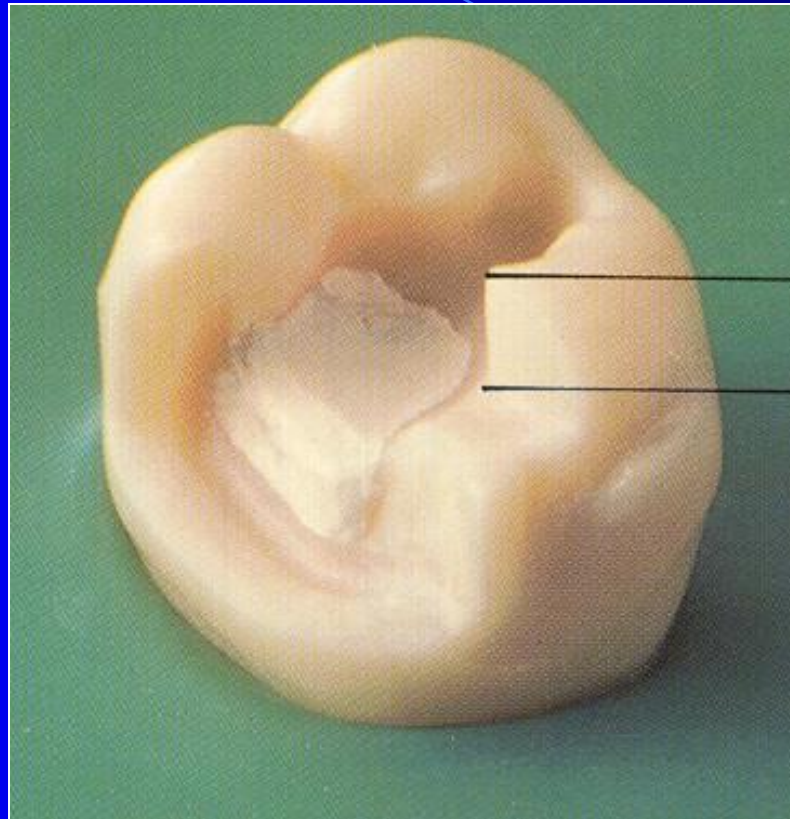


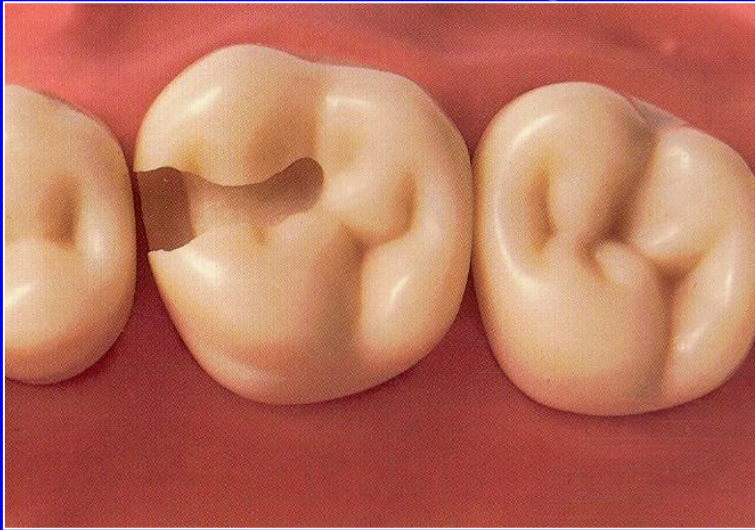


Base

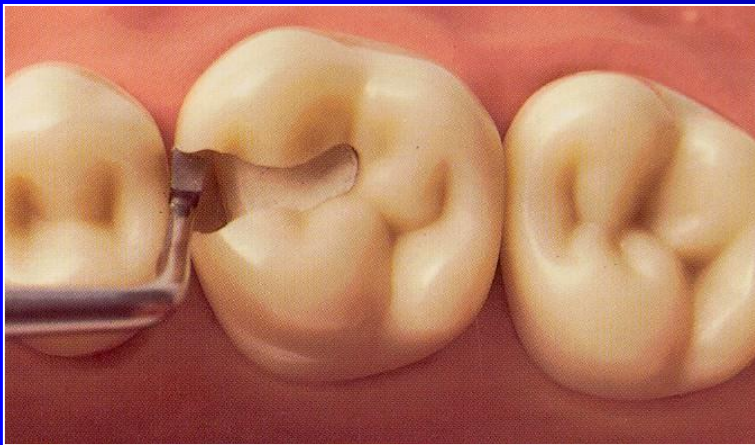- Zinkoxidphosphate cement
- Zinkoxidkarboxylate cement
- Glass ionomer cement
- Zinkoxideugenol

On pulpal walls only!



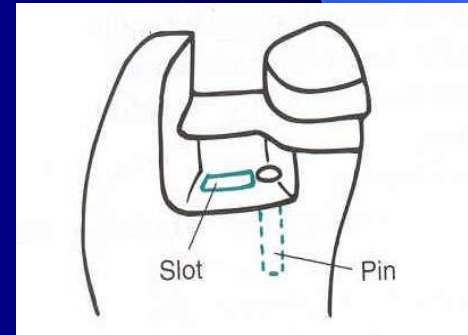
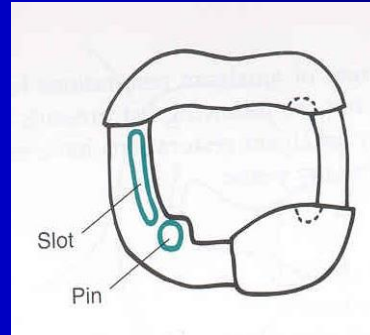
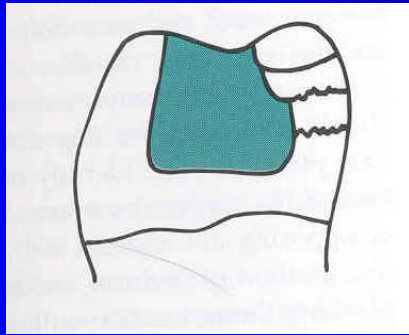
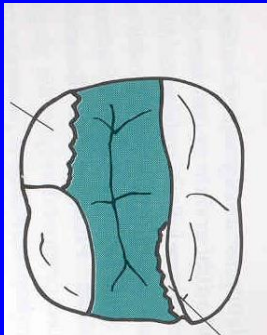


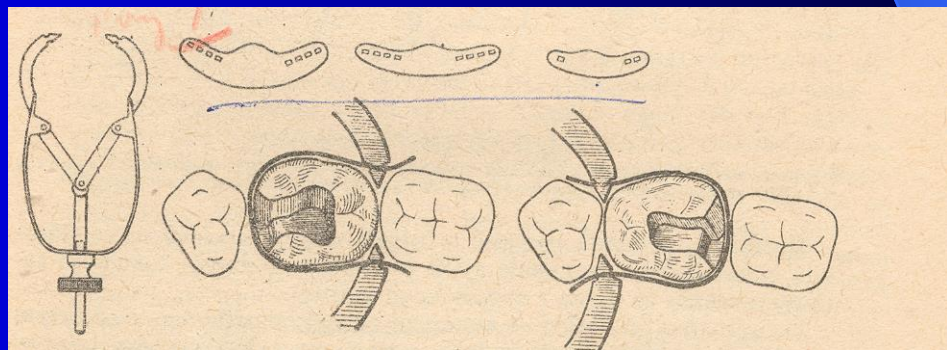
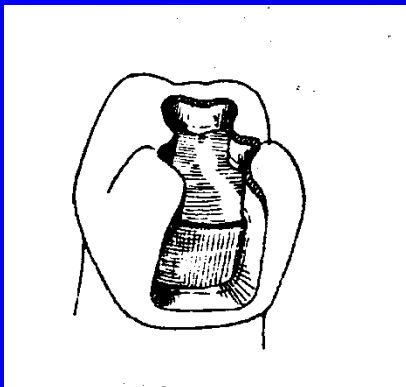
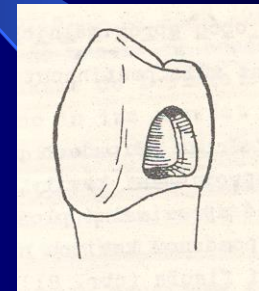
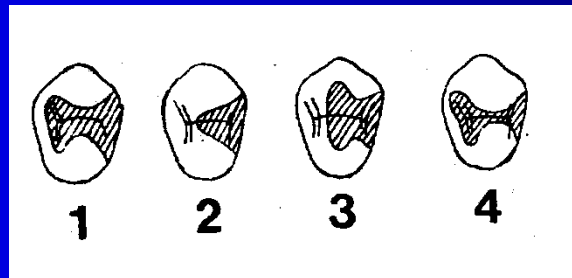
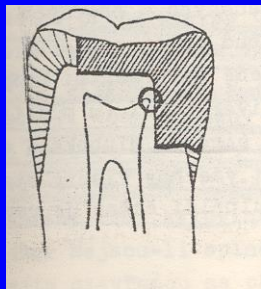
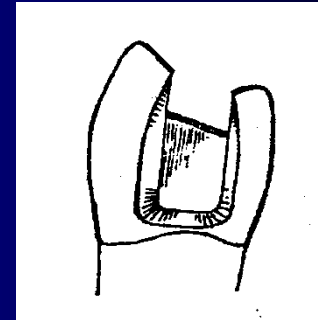
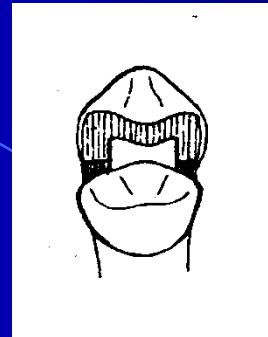
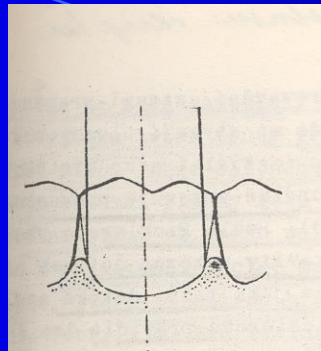
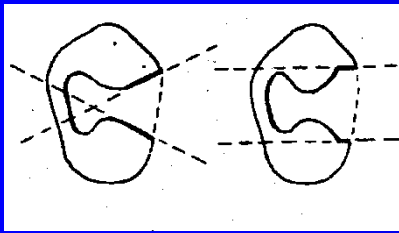
The base must be hardened

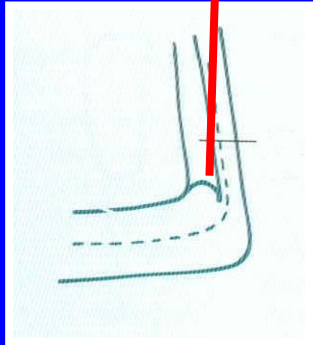
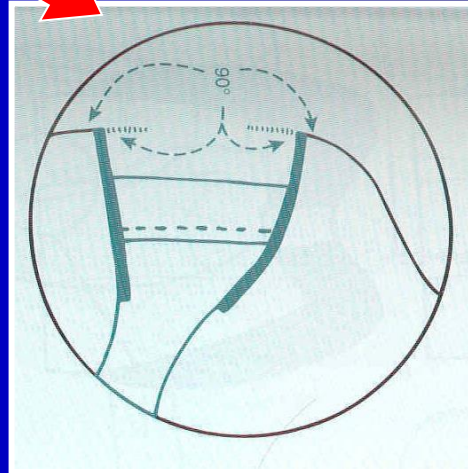
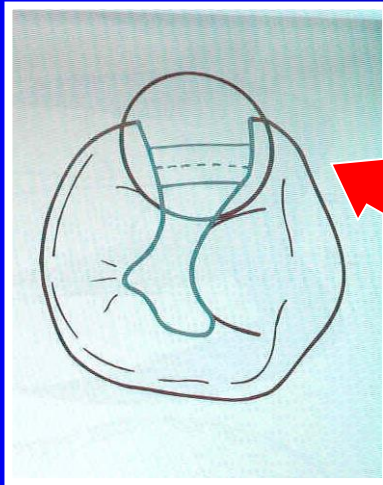
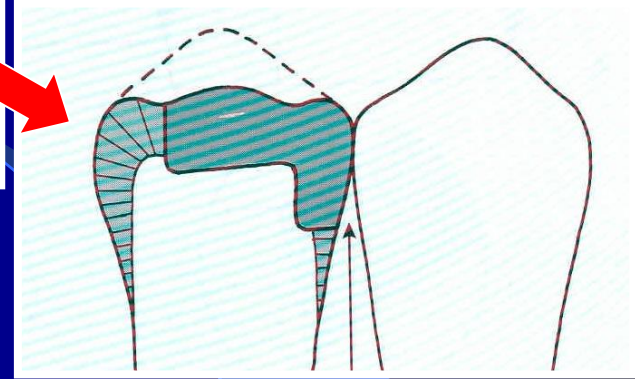
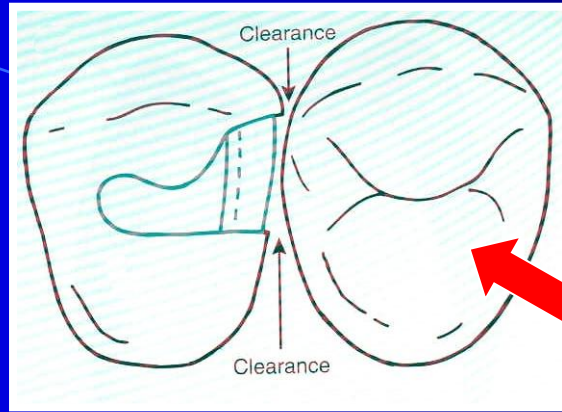
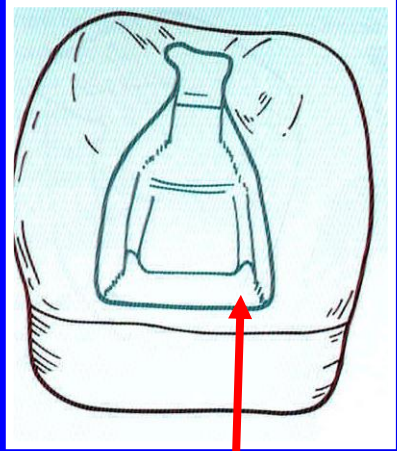



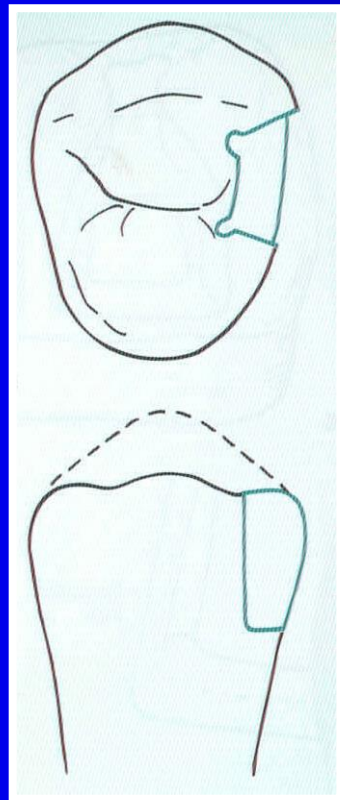
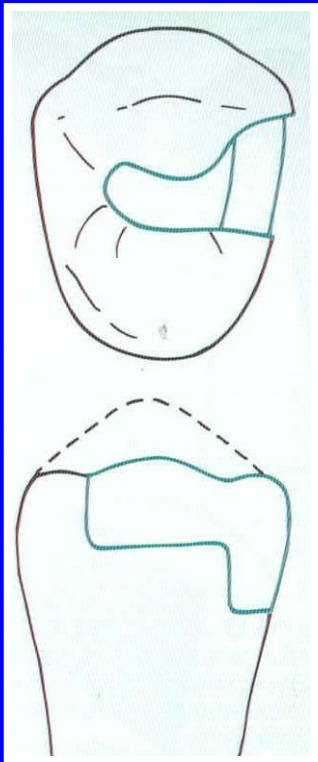
Amalgam

Retention










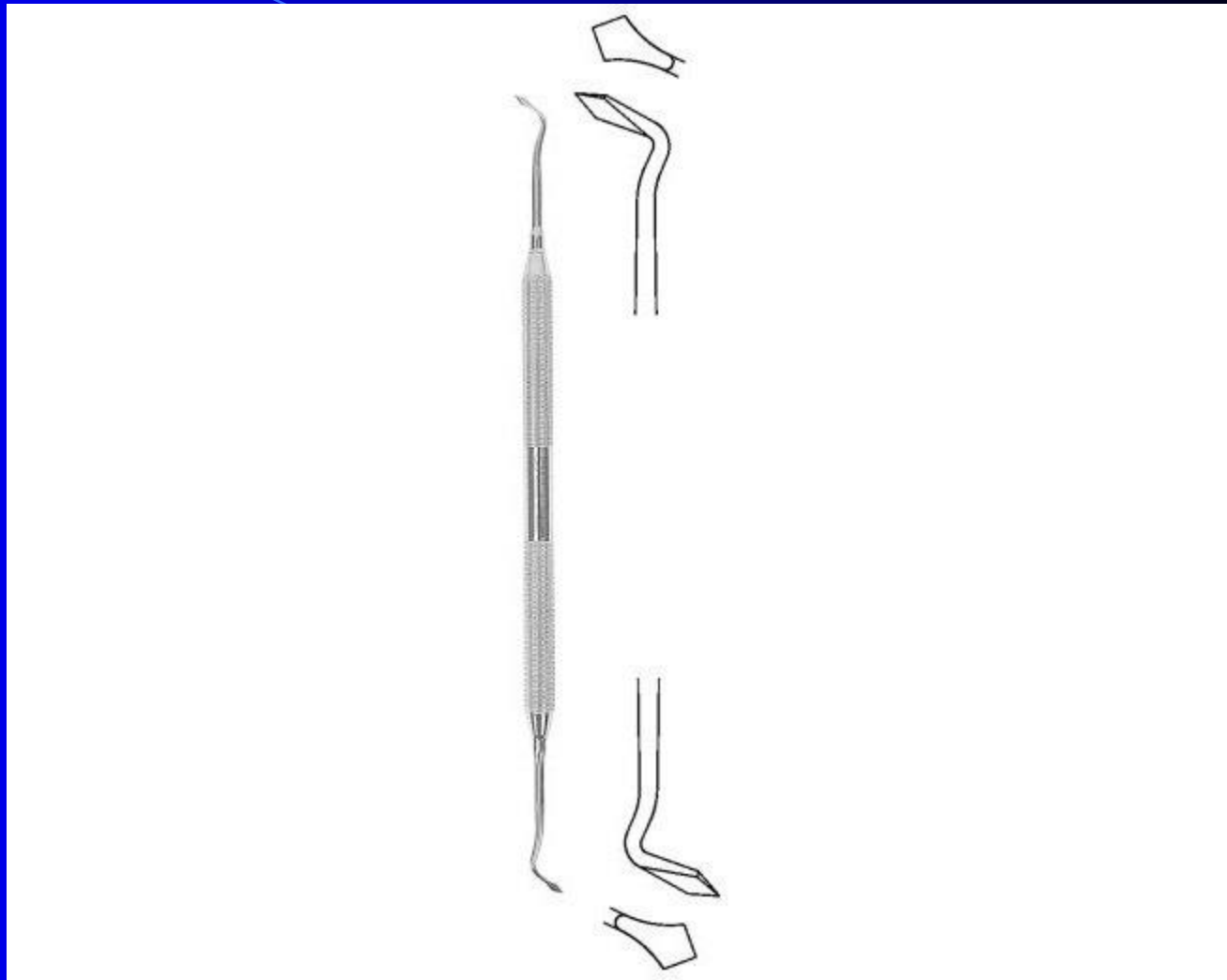
Instruments

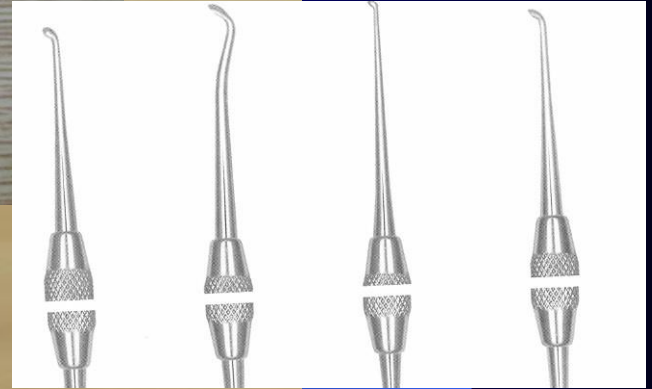
- Preparation
- Filling
- Finishing and polishing

Cpátko tyčinkové

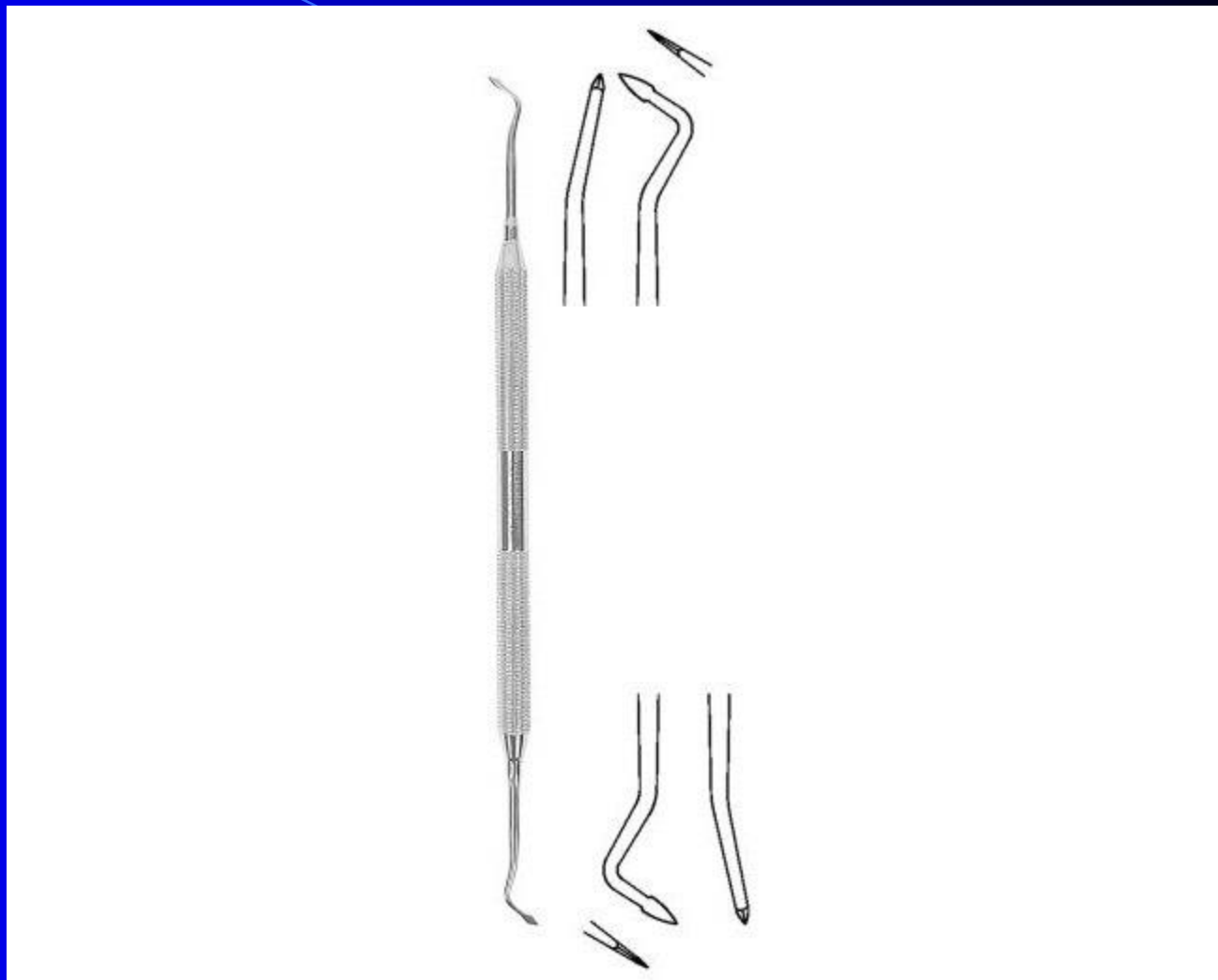

Ořezávač -Frahm







Sapin

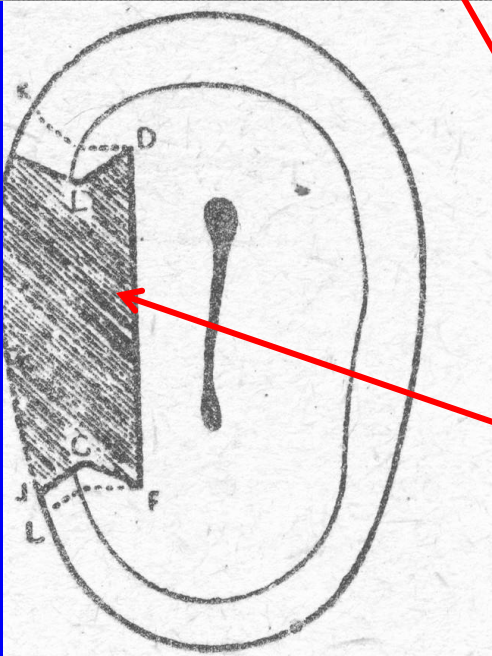
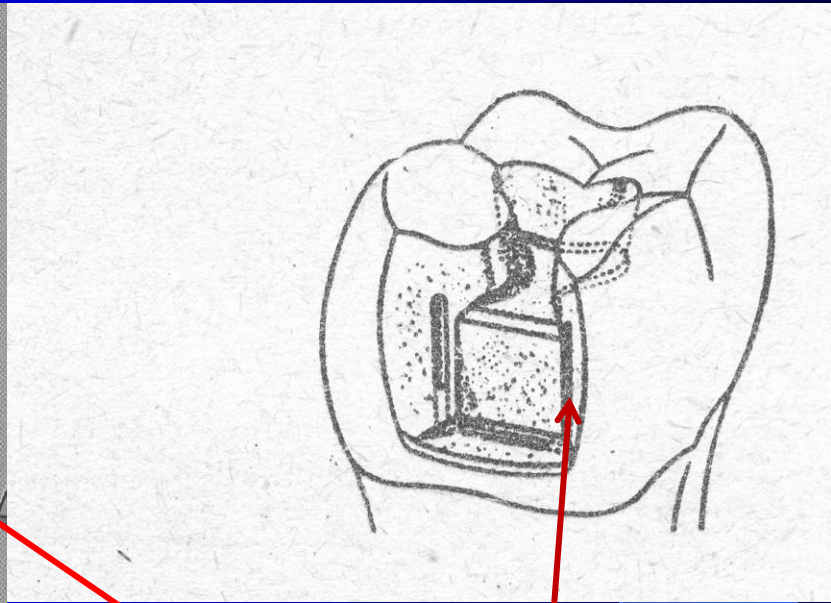
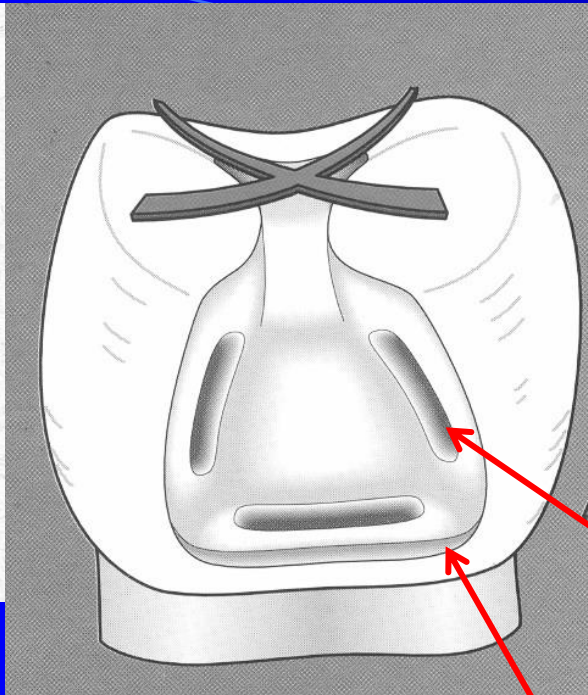


Discoid-cleoid



Amalgam carrier

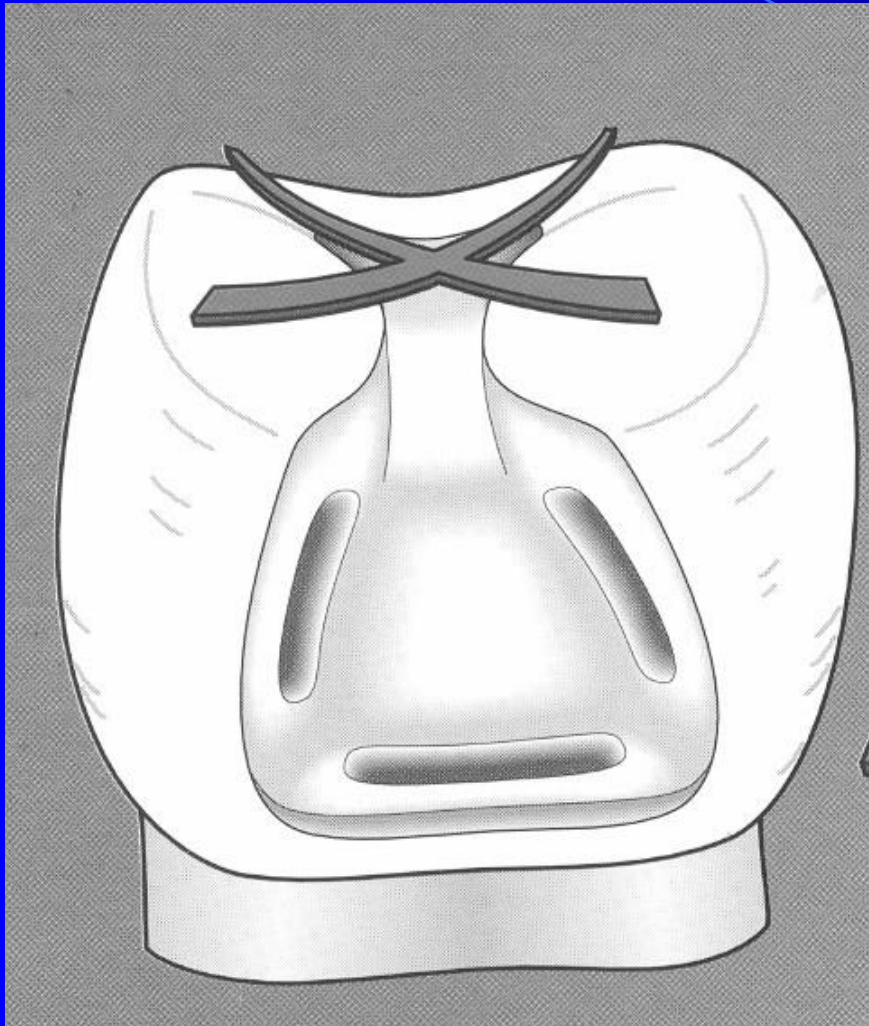




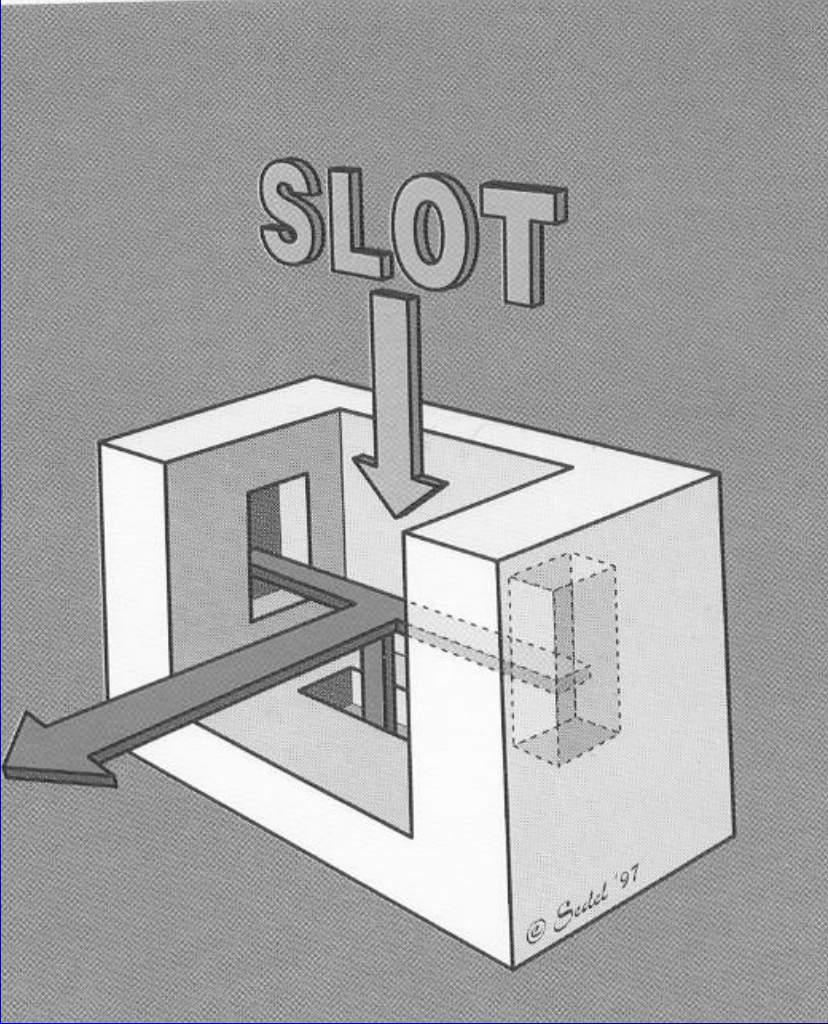
Retention – grooves
in the proximal cavity

Divergency of axial walls
towards gingiva and

Convergency - divergency
towards proximal space.

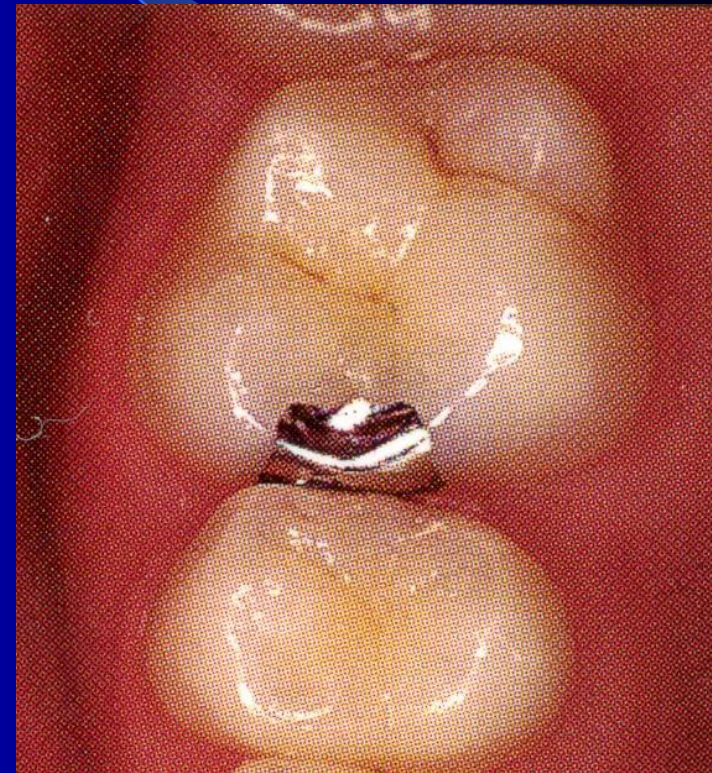

Autoretention



Slot preparation

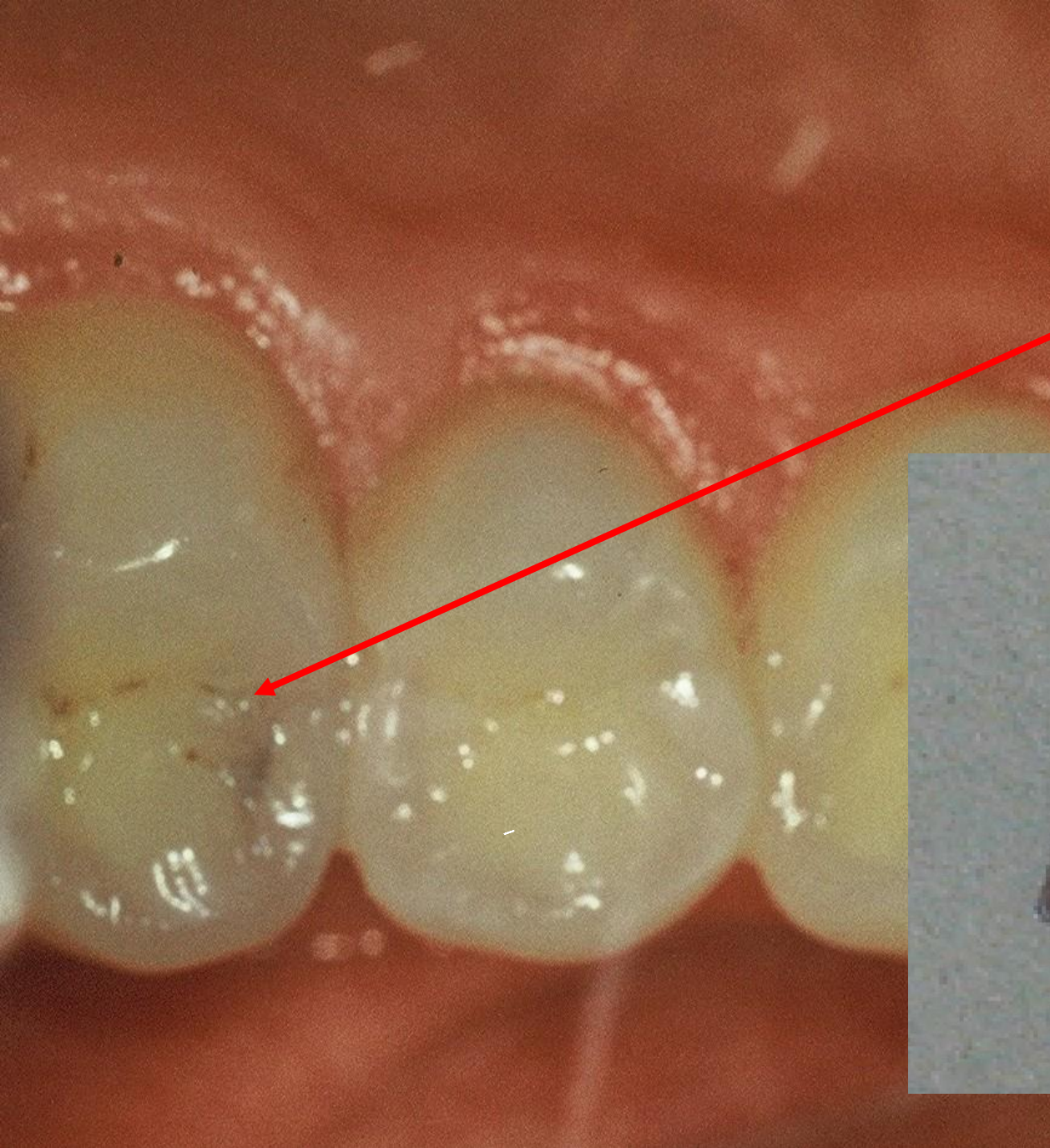
Slot is a cavity that is open on occlusal surface.
It is limited on the proximal ridge

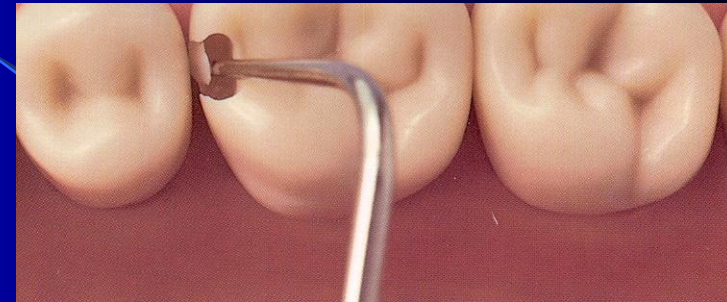
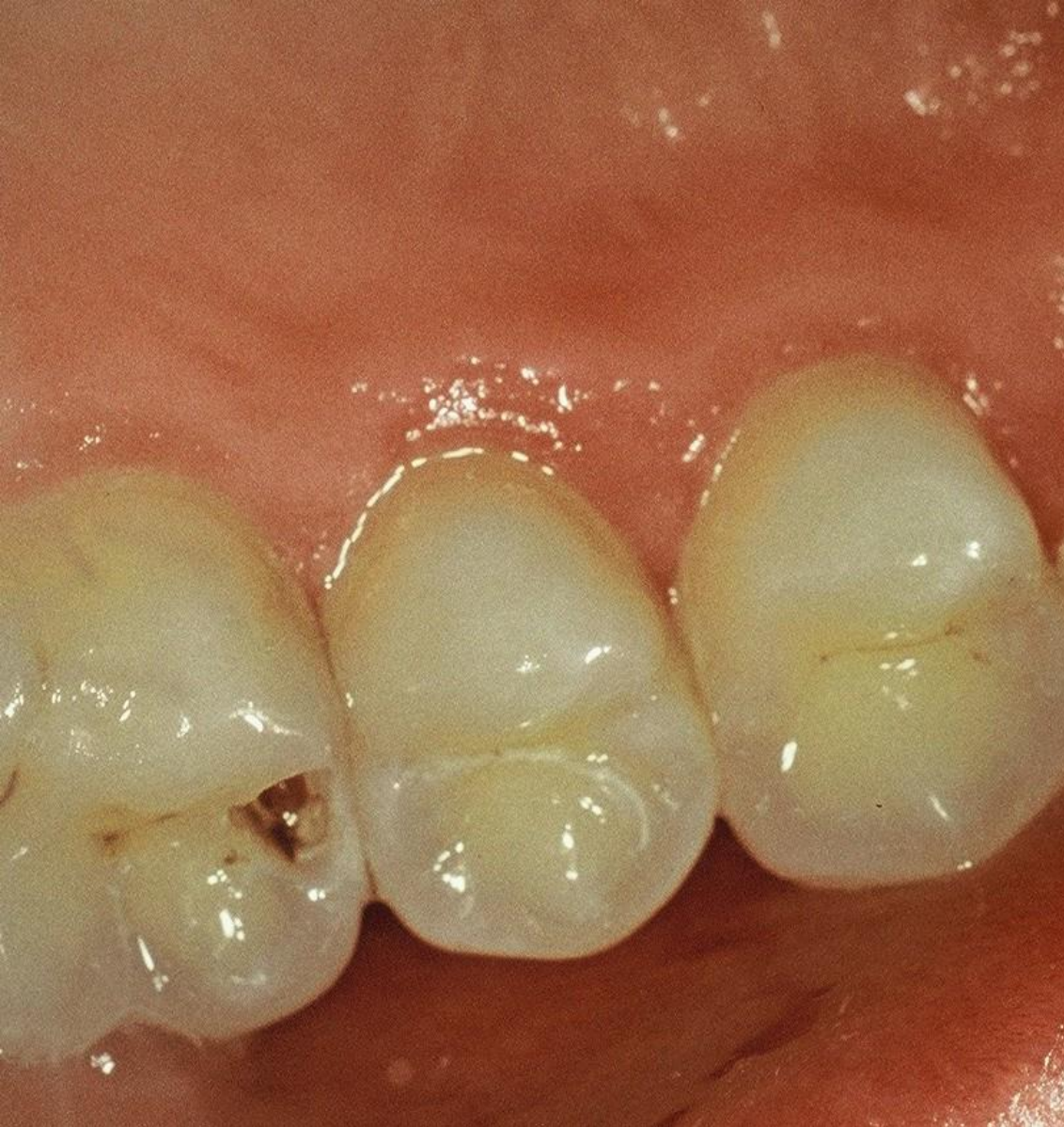
Slot for amalgam

- Access to the caries lesion
 - through the enamel wall
 - breaking out of the enamel lamella
 - excavation of carious dentin

Pre op





Access to the cavity

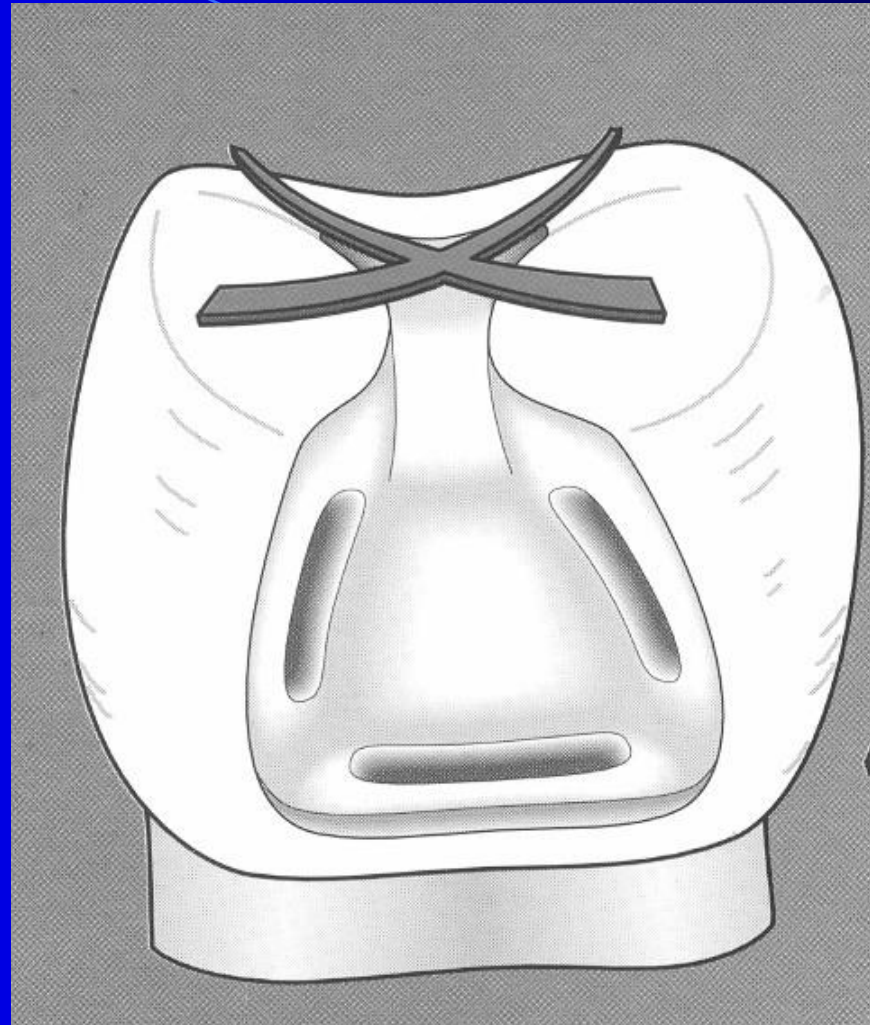
Slot for amalgam

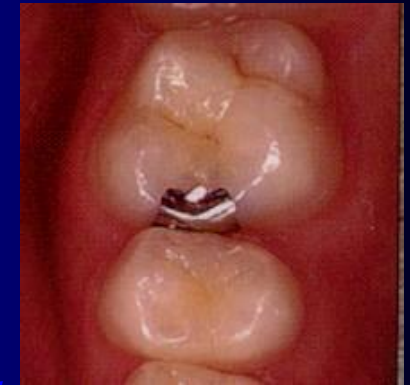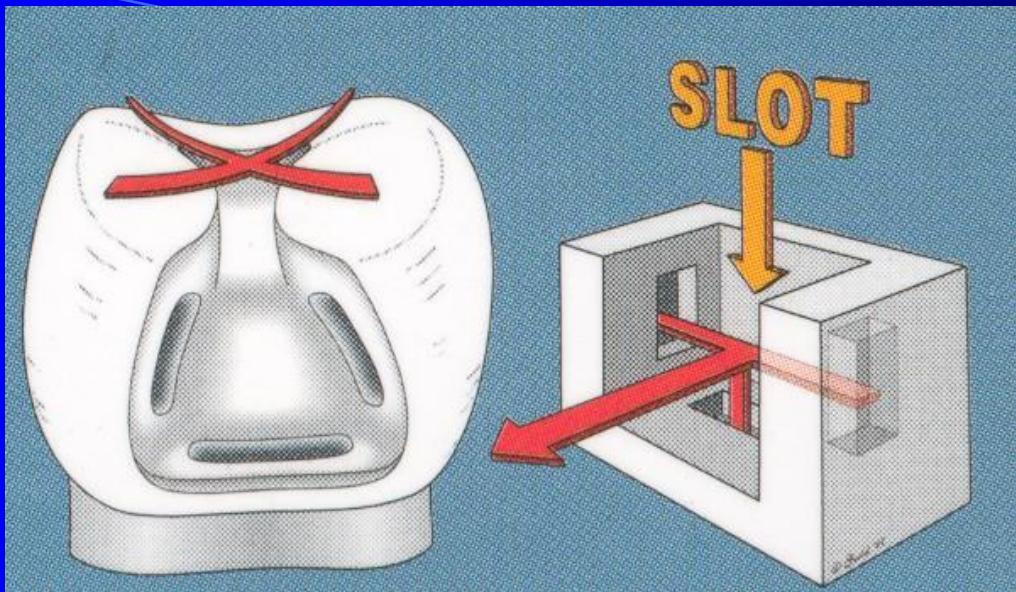
Autoretention

- Grooves
- Divergency towards gingiva
- Convergency and divergency of axial walls in horizontal plane(towards proximal space)

Slot for amalgam

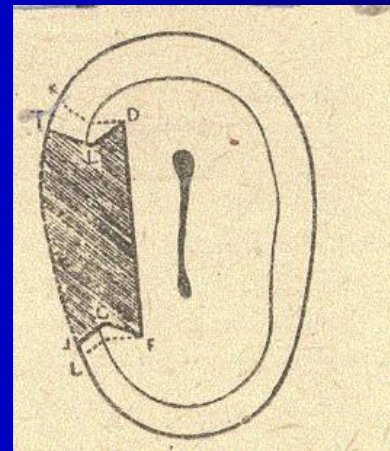
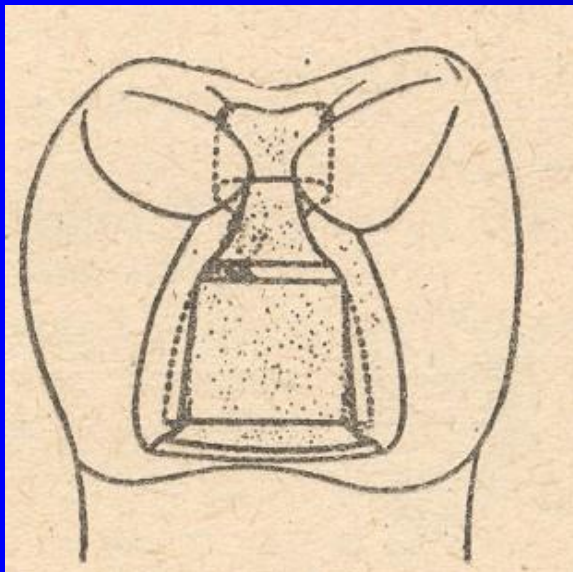
- Rule of the gingival wall
 - 1 mm wide
 - 90° angle towards the pulpal wall
 - outer line beveled if in enamel
 - horizontal groove





Sedelmayer

*Sedelmayer J. Amalgám – zapomenuté řemeslo.
Brno, 2000.*



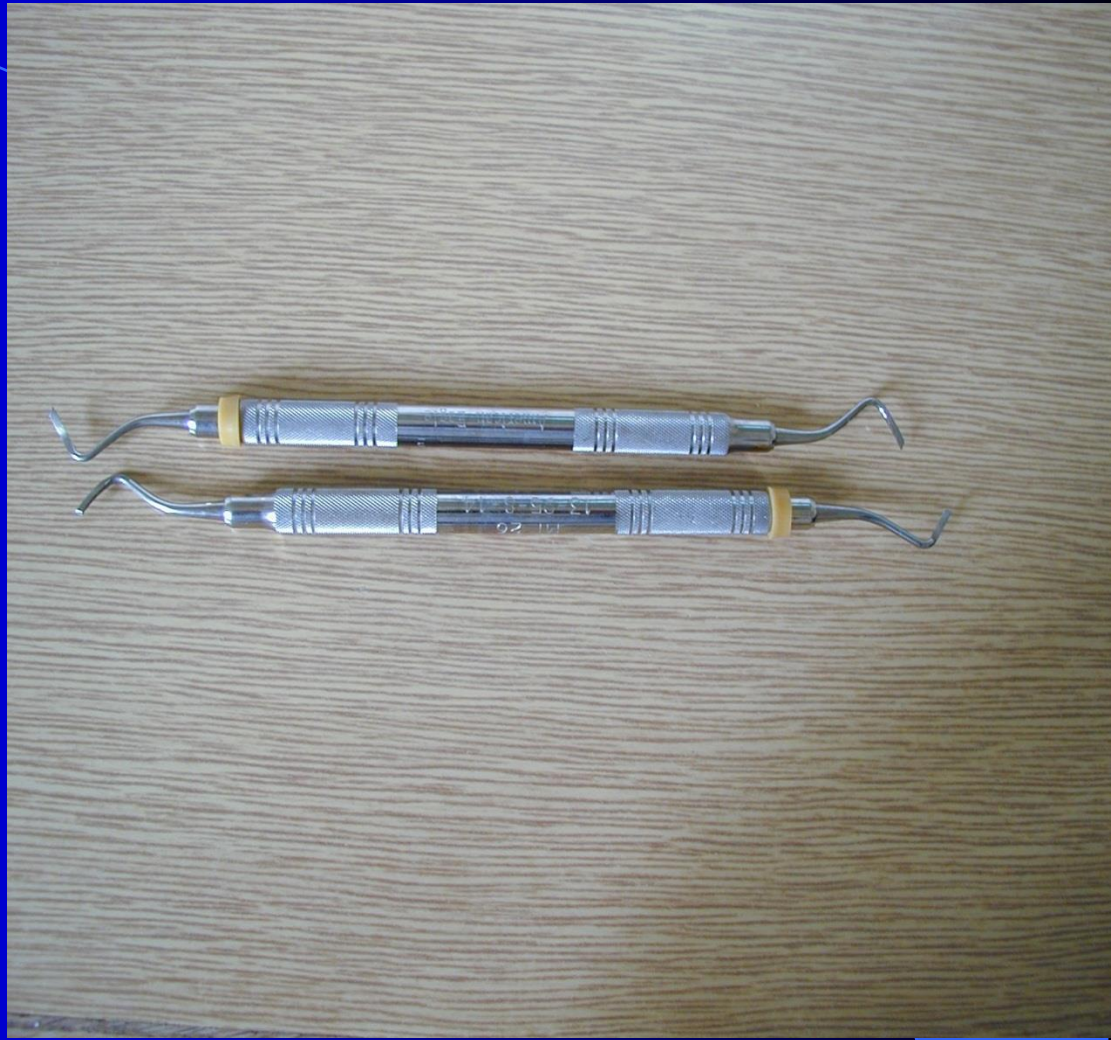
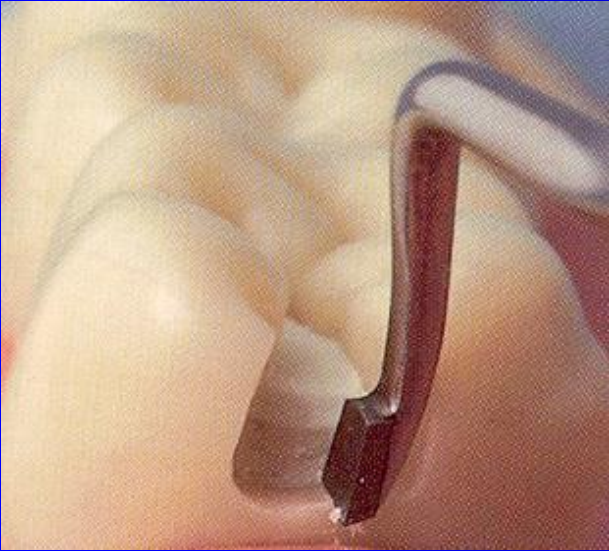
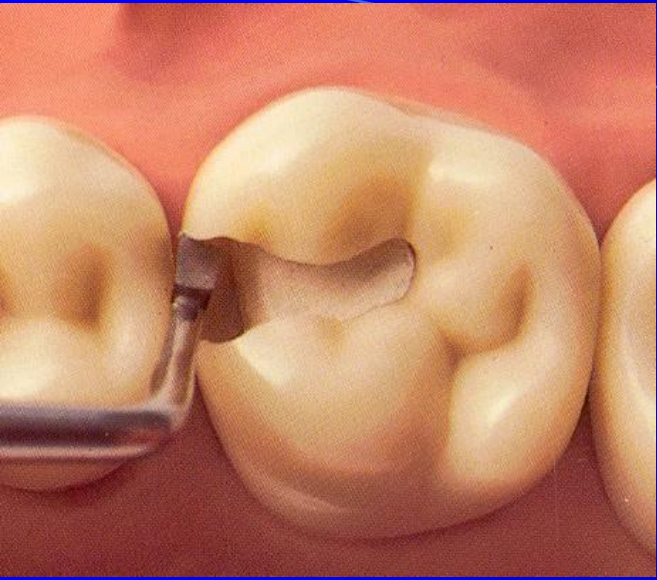
Bažant V.

Konservační zubní lékařství, SPN Praha, 1962.

Slot cavity

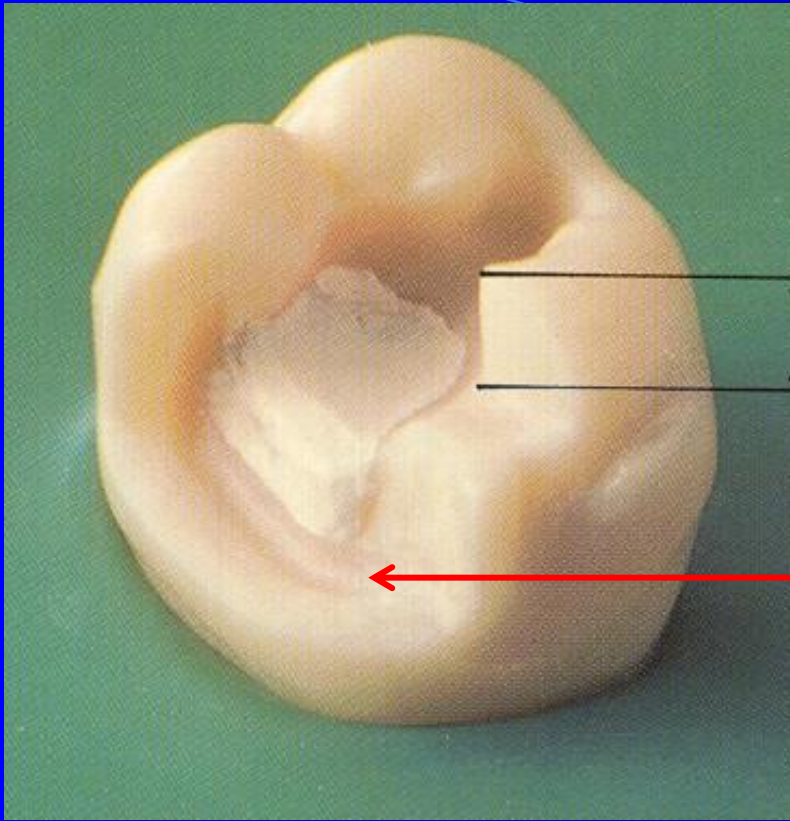
- Limited on proximal ridge
- Axial walls are divergent towards gingiva
- The proximal box has a typical picture of fish tail
- There are grooves:
 - One horizontal in gingival wall
 - Two vertical in axial walls





Large defects

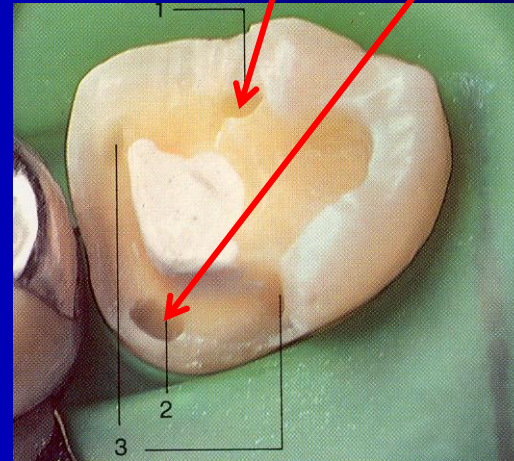
- In vital teeth if the cusp has been undermined due to dental caries
- Large defects in non vital teeth – amalgam overlays
- Combination with the cavity on vestibular/oral surface



Cusp has been removed

The thickness of the filling
3 – 4 mm (at the cusp)

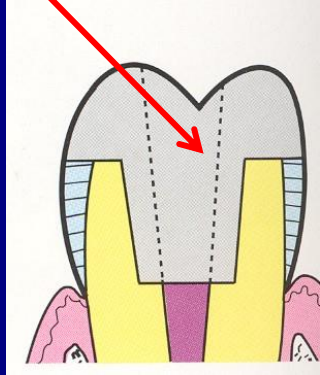
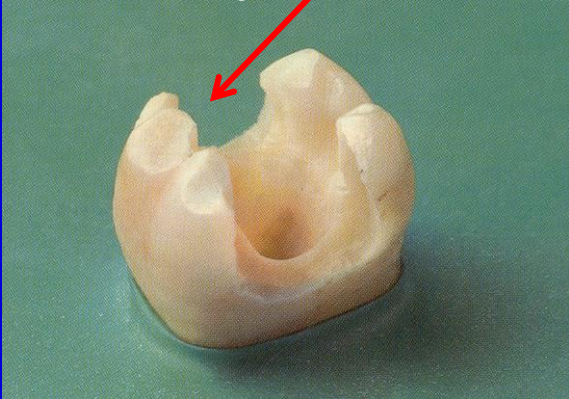
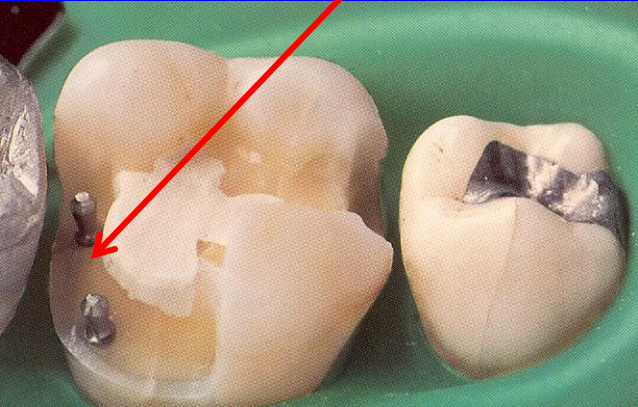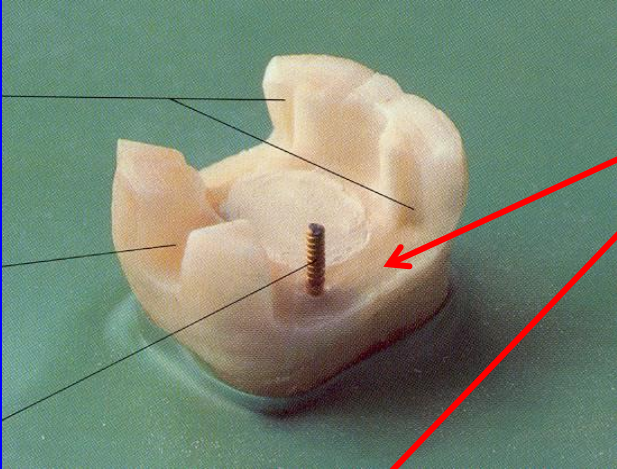
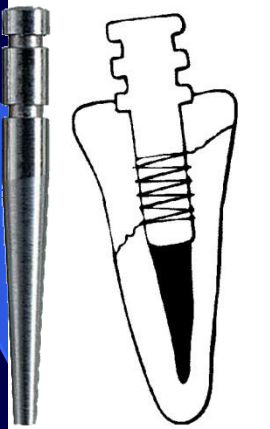
Retention
Grooves, pins, slots



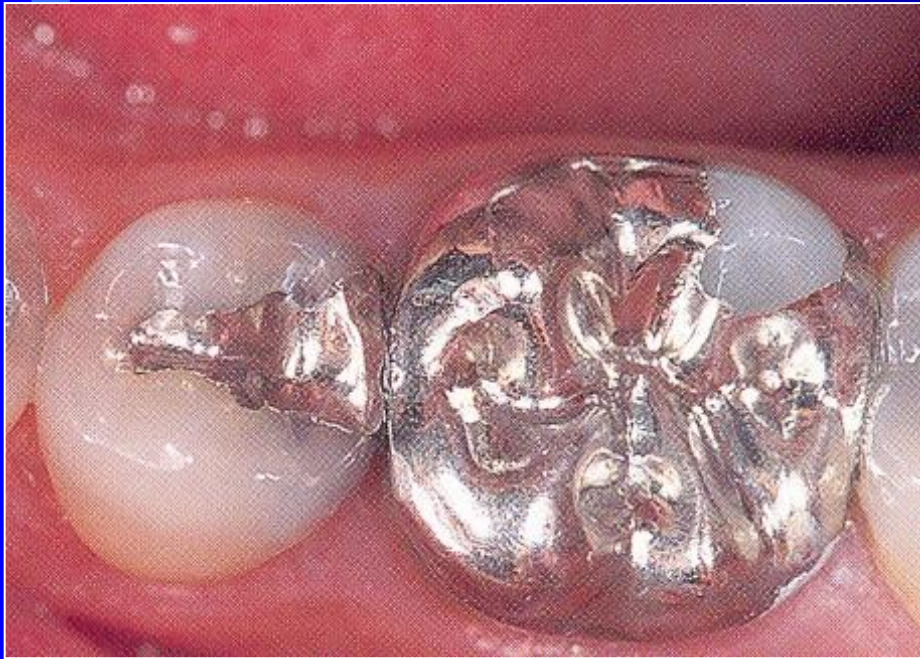
Parapulpal pins

Intrapulpal posts (root canal posts)

Retention in the endodontic cavity

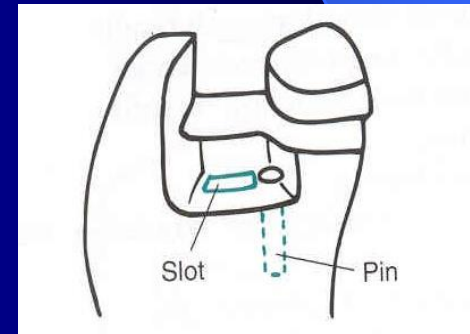
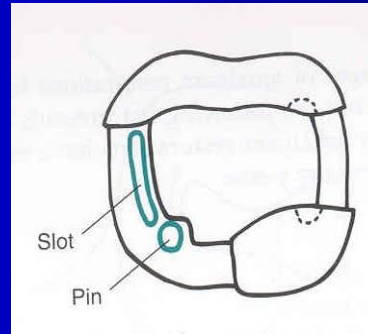
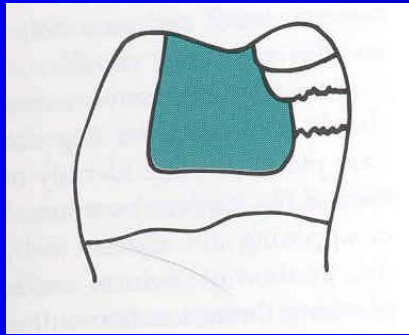
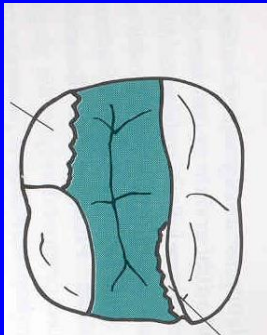


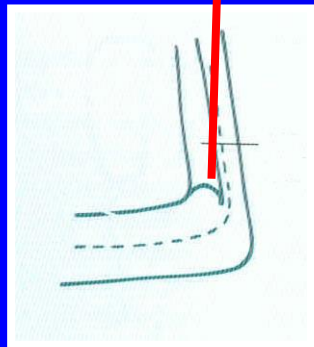
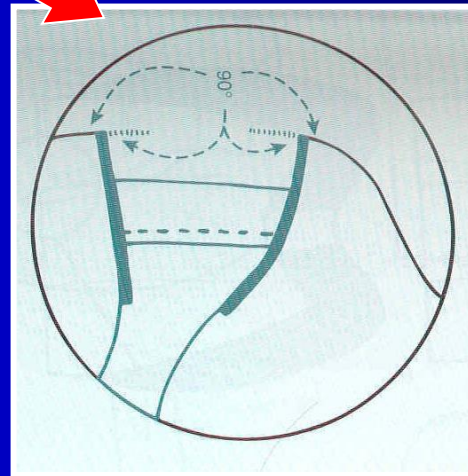
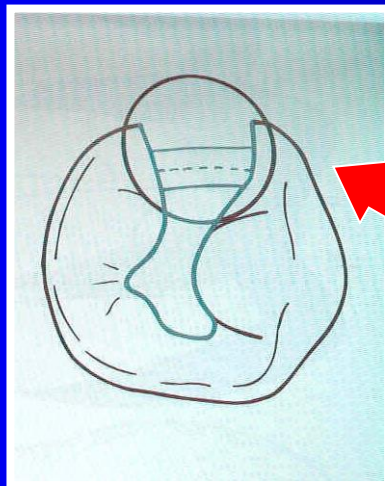
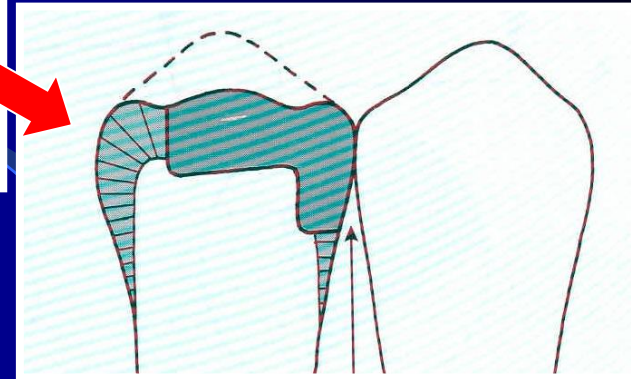
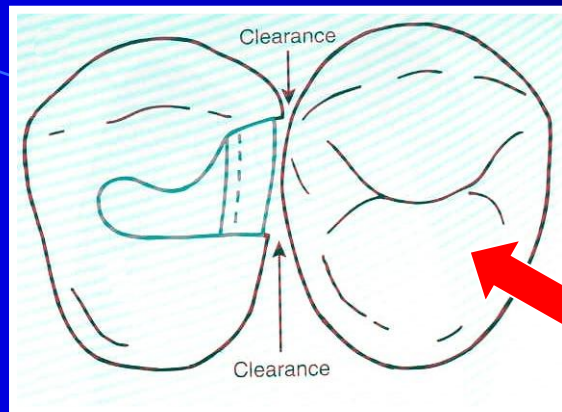
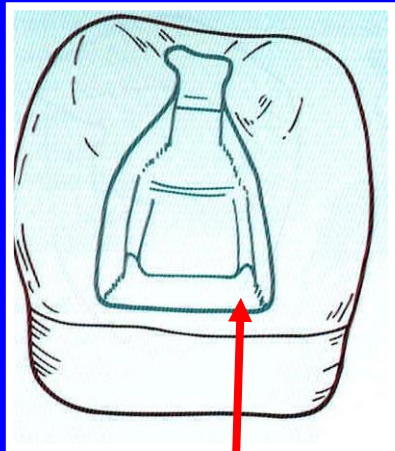
Large amalgam restoration - overlays



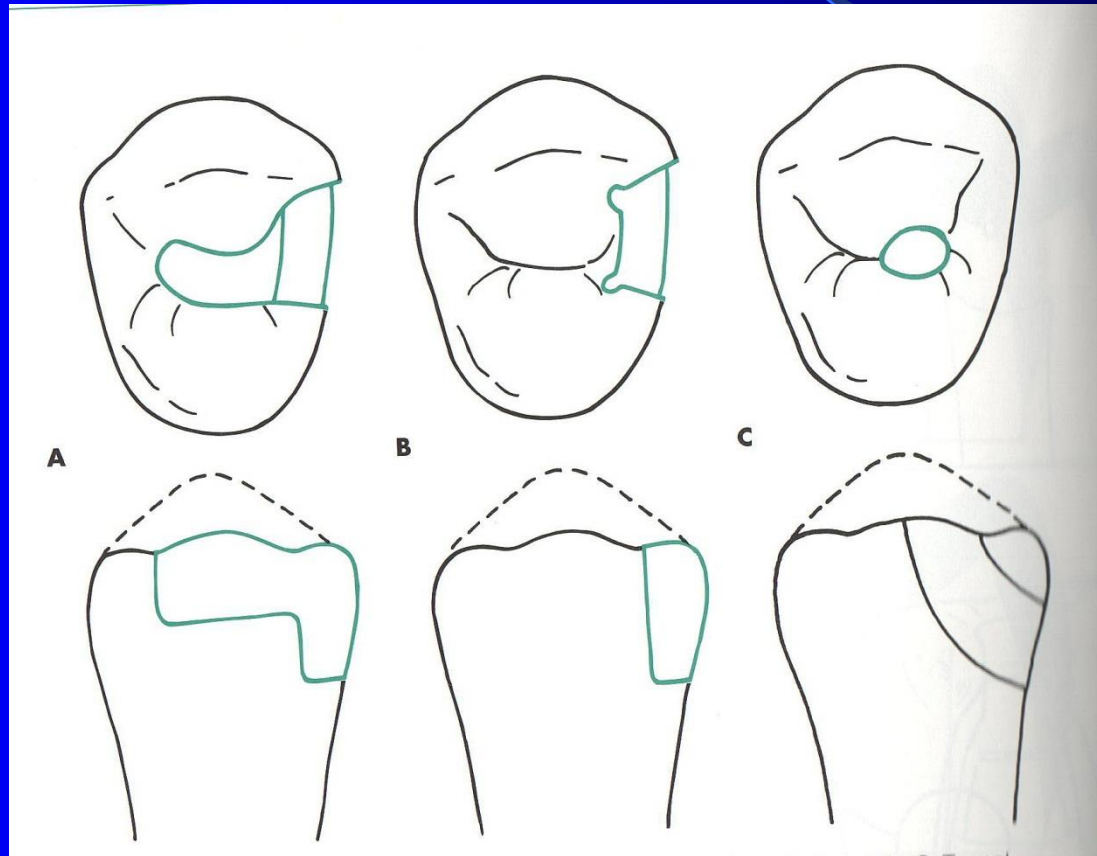
Amalgam

Exact work!





Basic modifications



Rules for large restorations

- Clear and sharp outlines – cavosurface margin

Thickness of the amalgam (the cusp 3 – 4 mm)

- Autoretention
 - Grooves
 - Pins, slots
 - Parapulpal pins
 - Intrapulpal posts – root canal posts

Resistance – acc to general rules

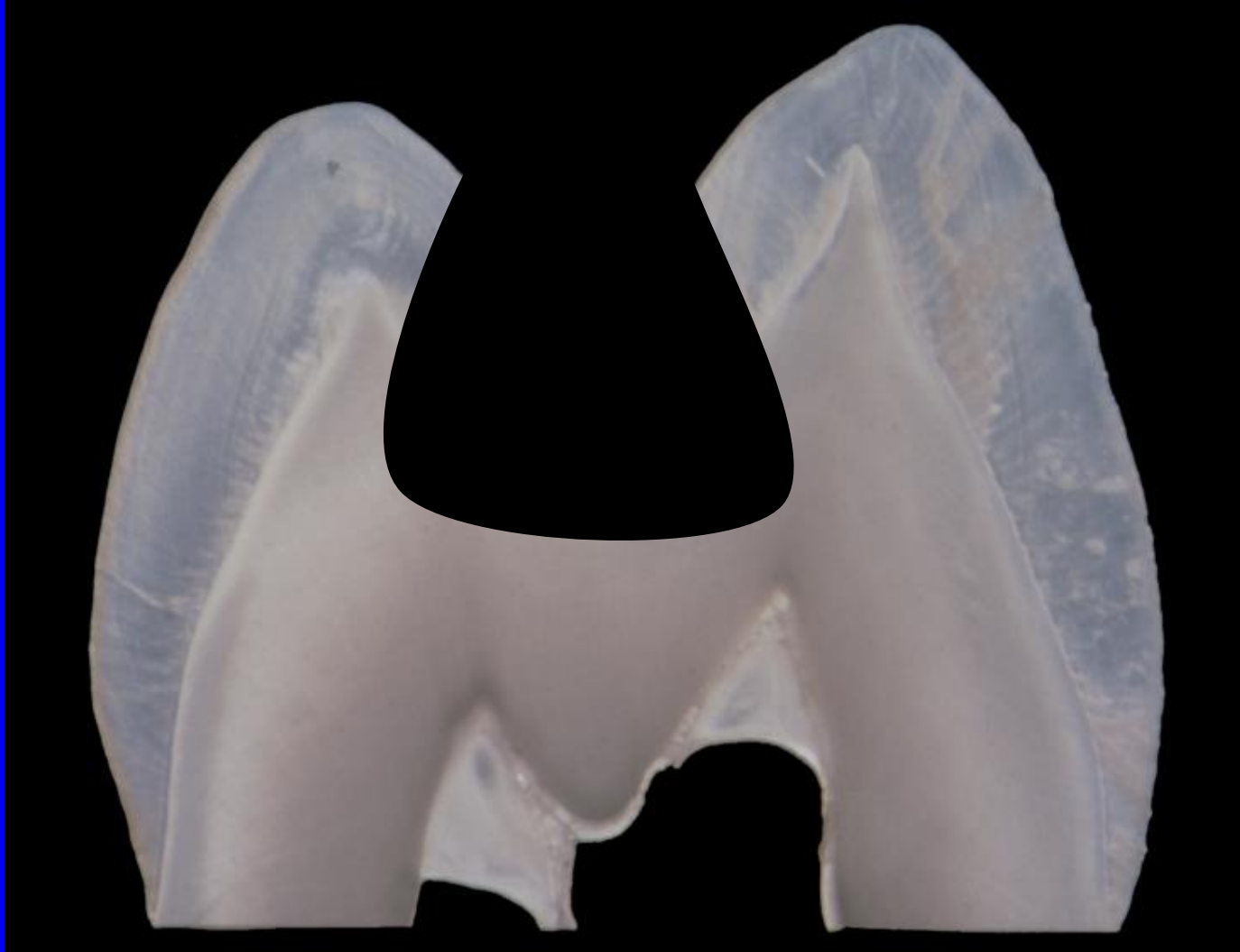Composites - indication

- Small – moderate cavities
 - Good level of oral hygiene
 - No heavy occlusal stress
 - Dry operating field

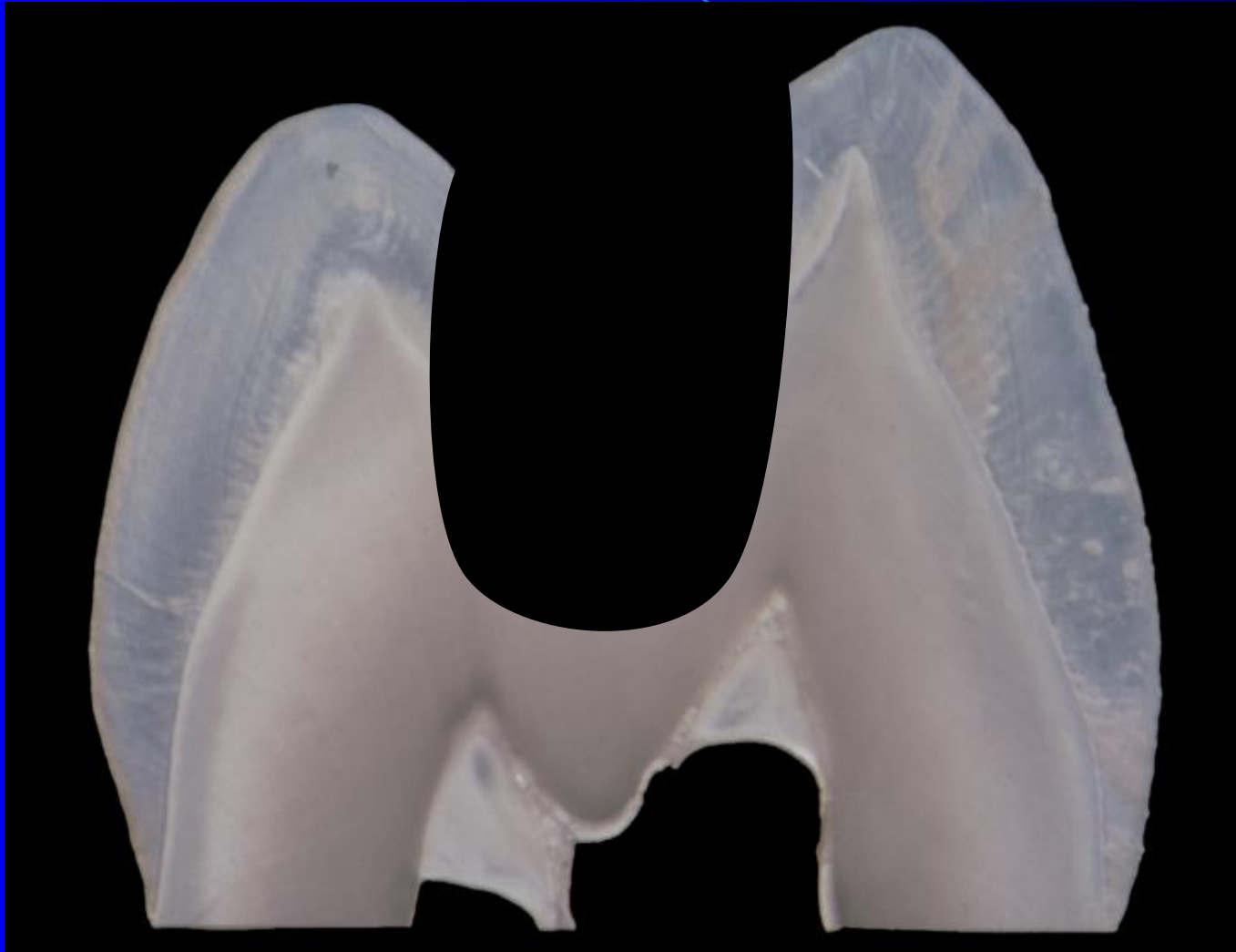
Preparation for adhesive materials – composites

- No extension for prevention (adhesion)
- No grooves
- No undercuts
- Rounded box
- Bevel the axial walls and the outer edge of the gingival wall
- Small isolated cavities are possible

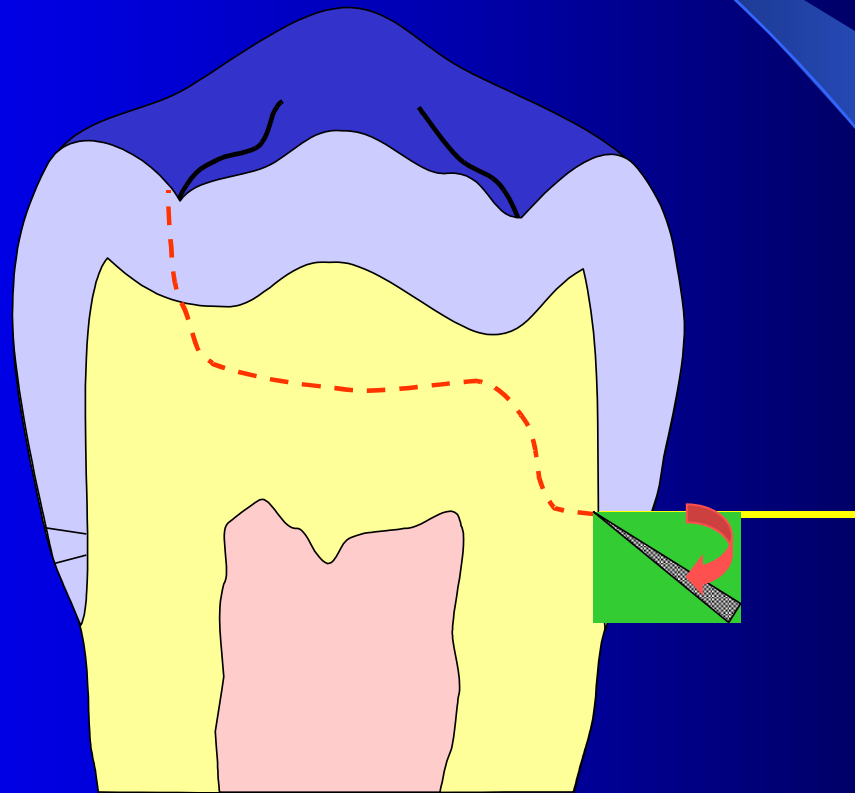
Cavity for amalgam



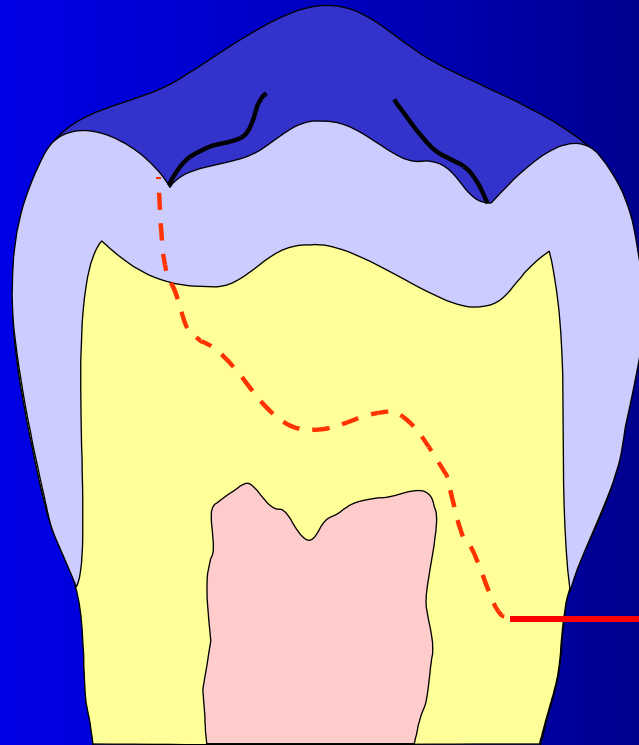
Cavity for composite



Bevel on the gingival wall





If out of enamel



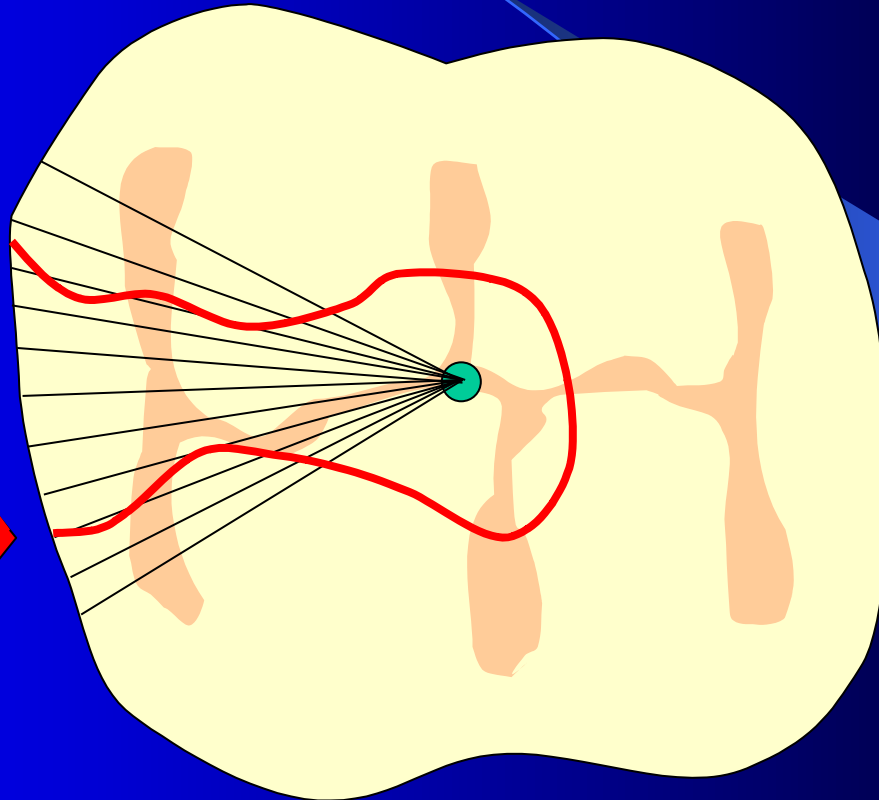
**Preparation
do not bevel!!!**

Bevel of enamel on axial walls

Composite material



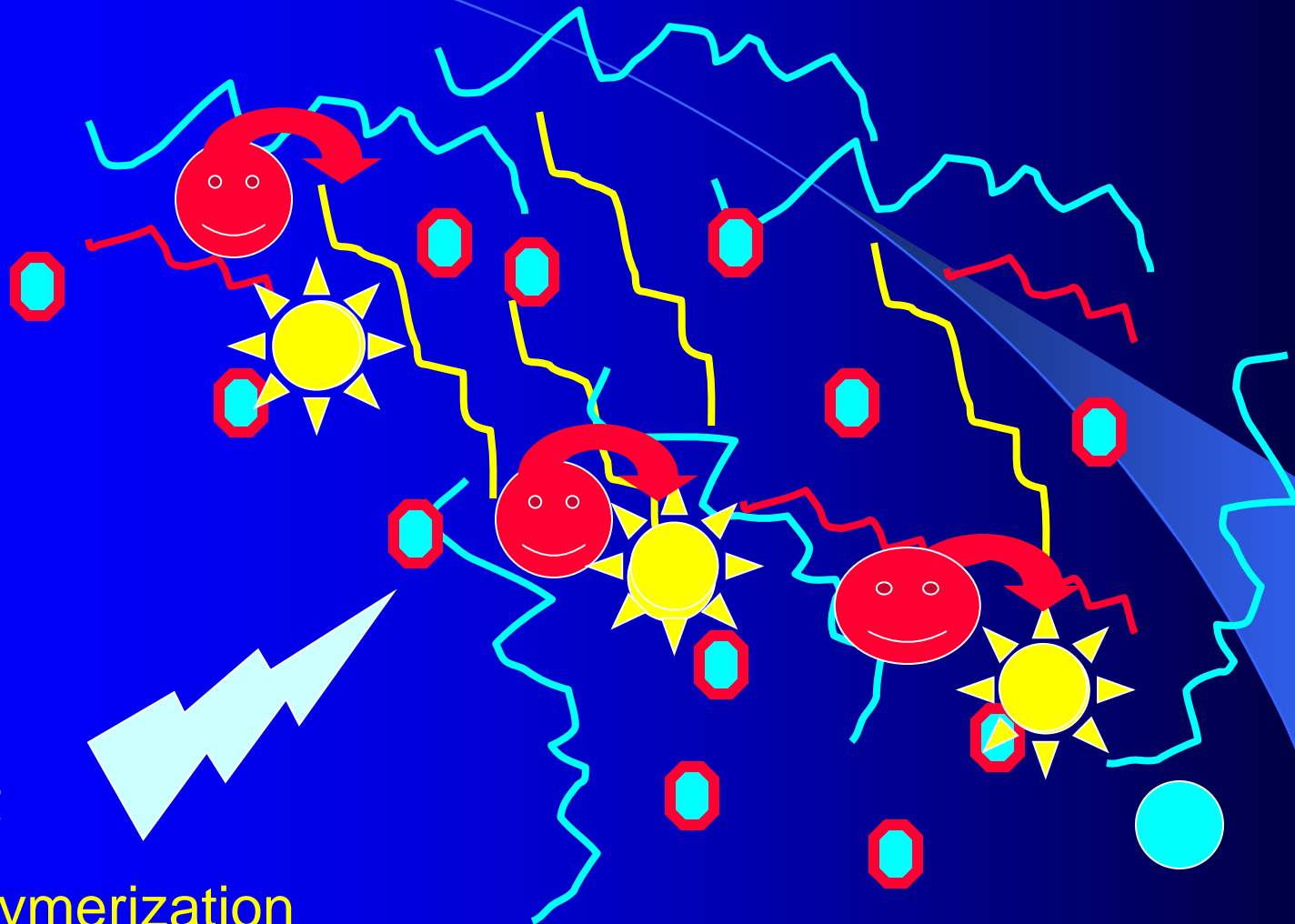
Amalgam



Light

Polymerization

Monomer \longrightarrow Polymer



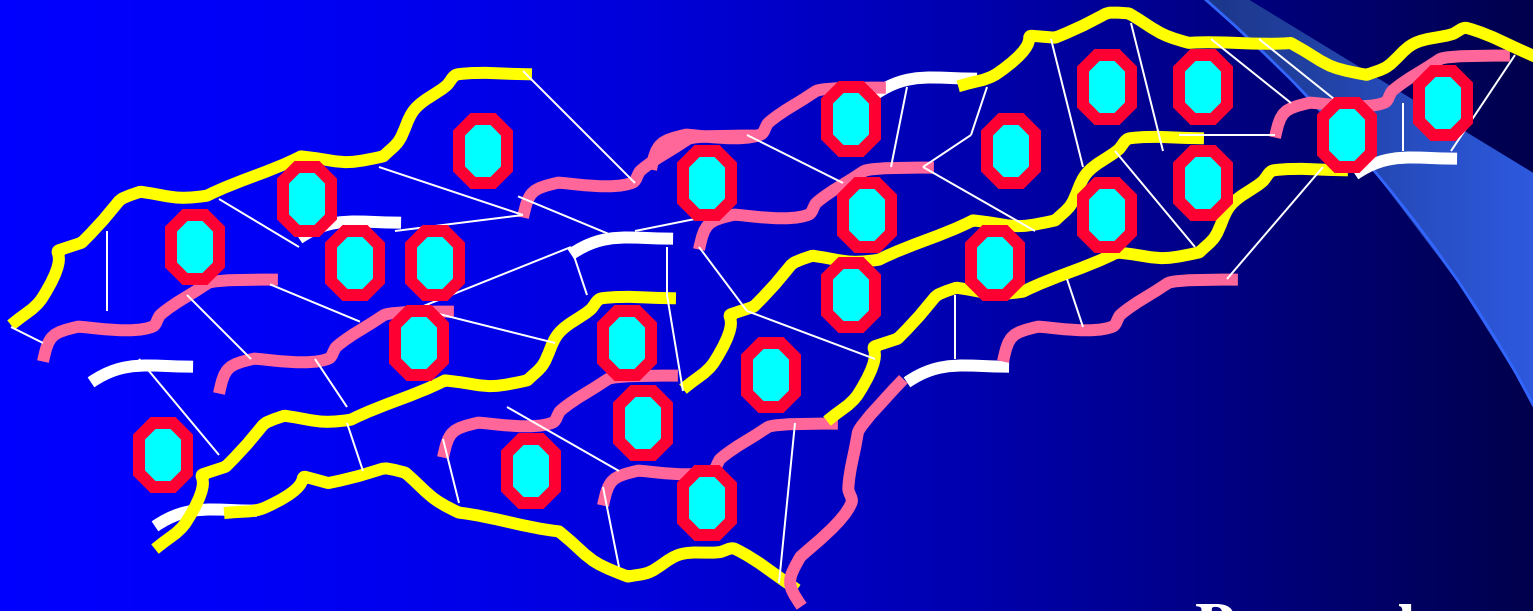
Polymerization – light curing composites

- Mode of polymerization

Phases

- Pre-gel
- Gel-point
- Post –gel phase

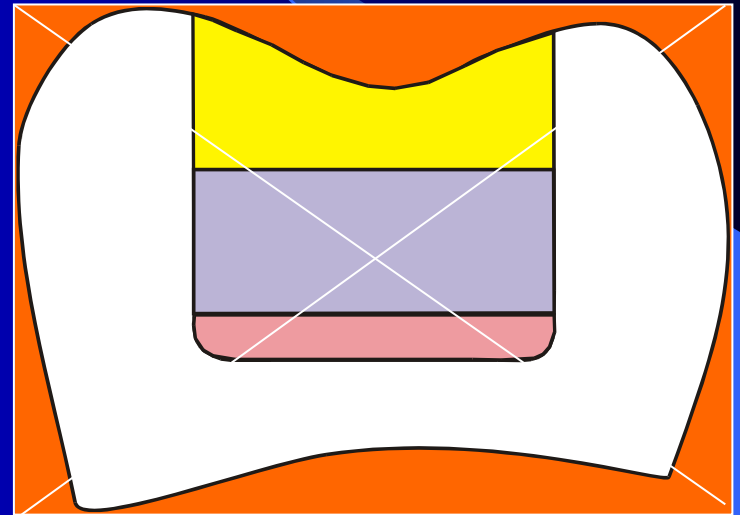
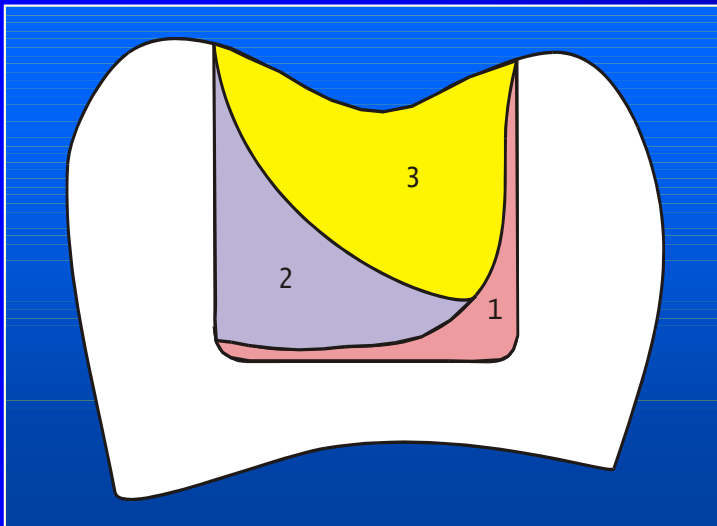
Pre gel phase should be long – soft start

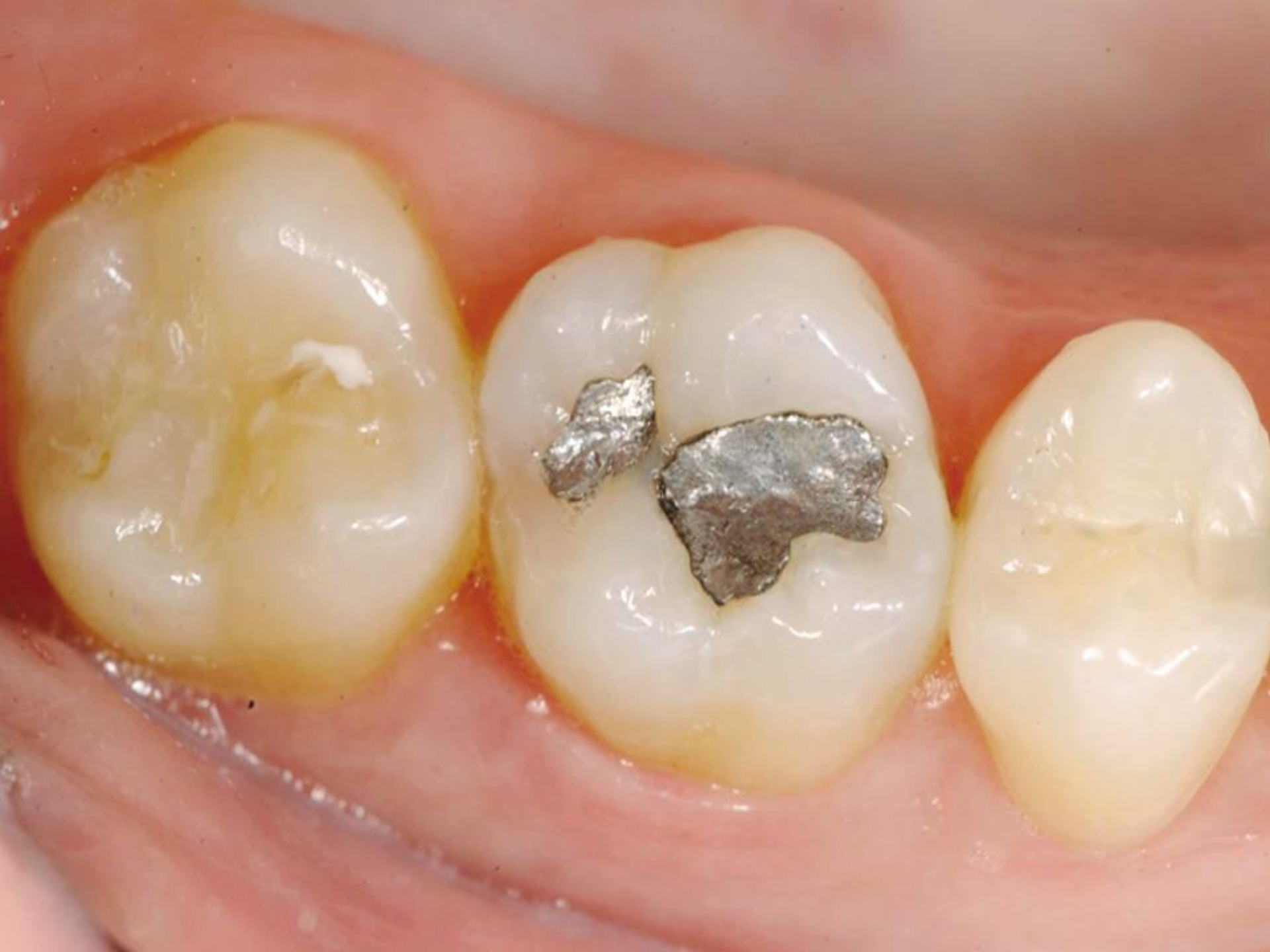

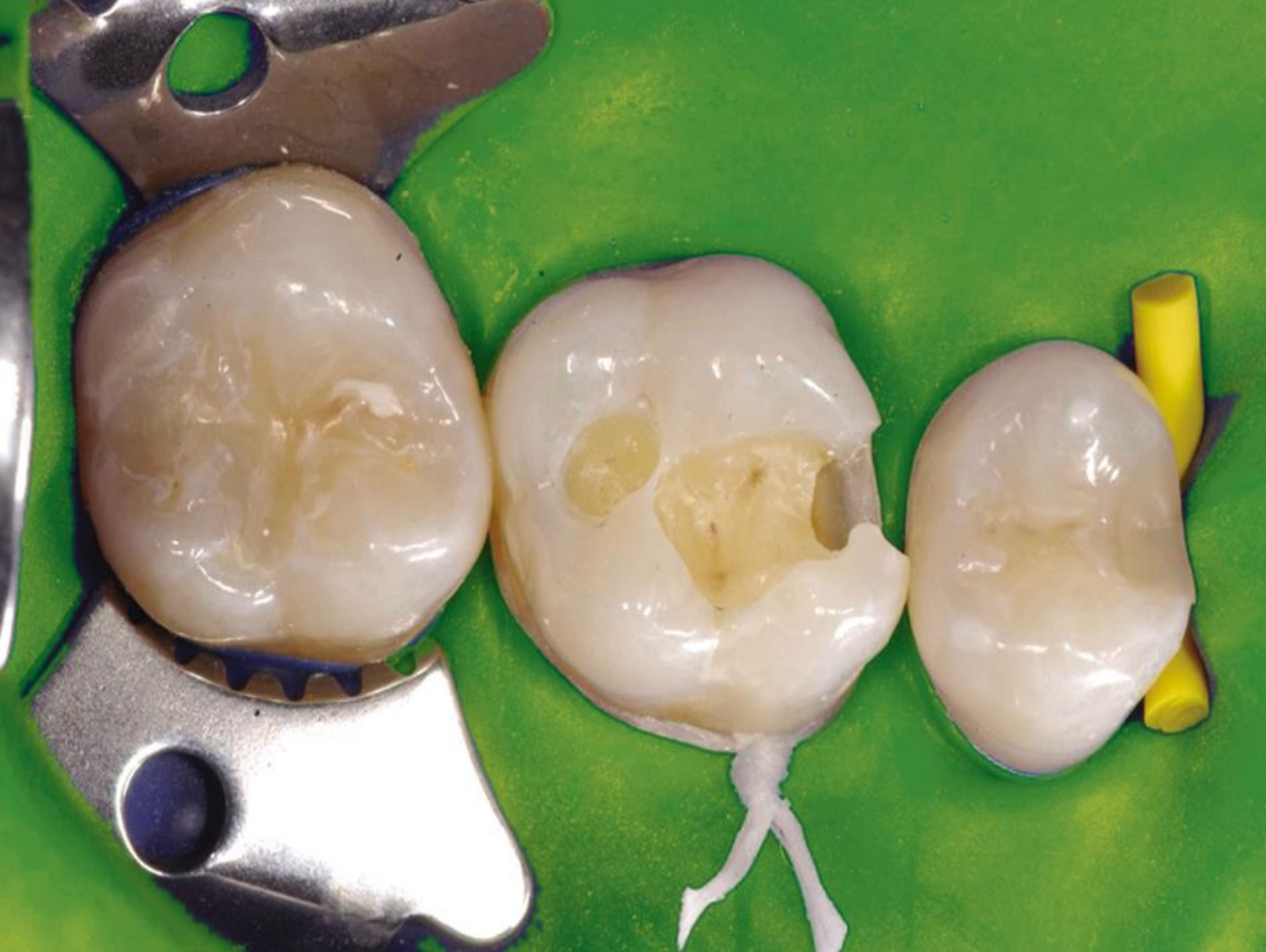Pre -gel
Gel
Post -gel

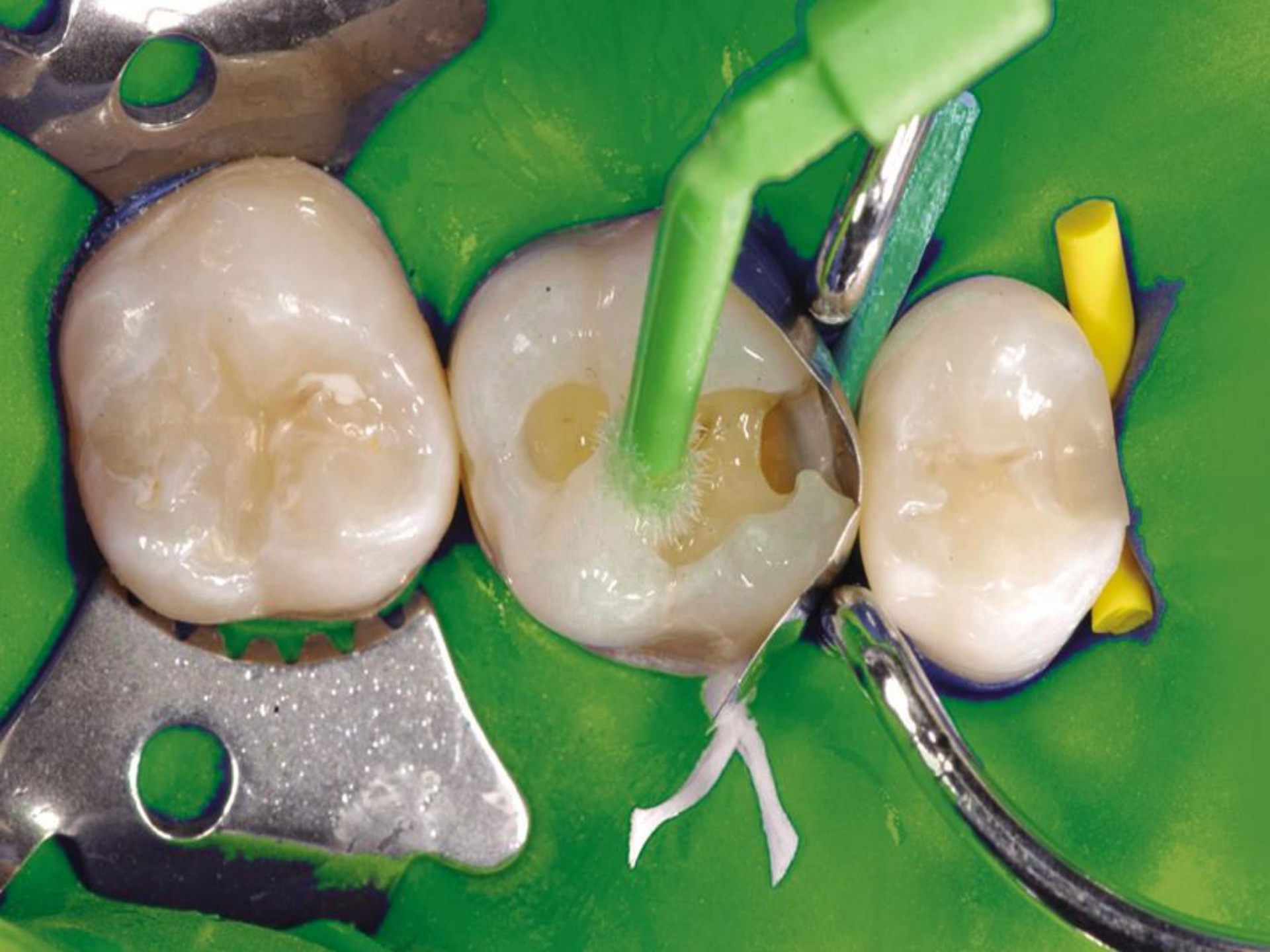Placement of the material

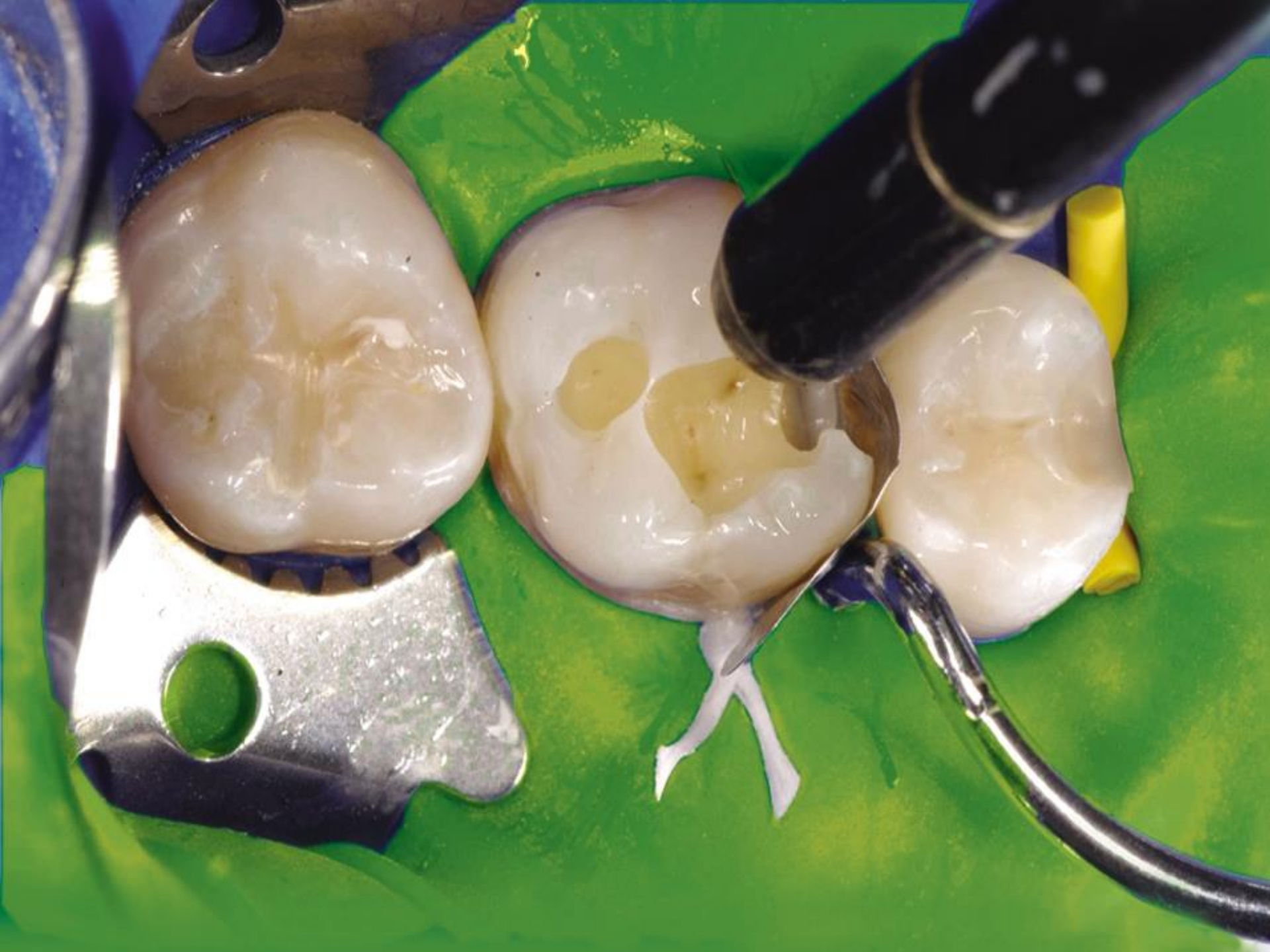Correct

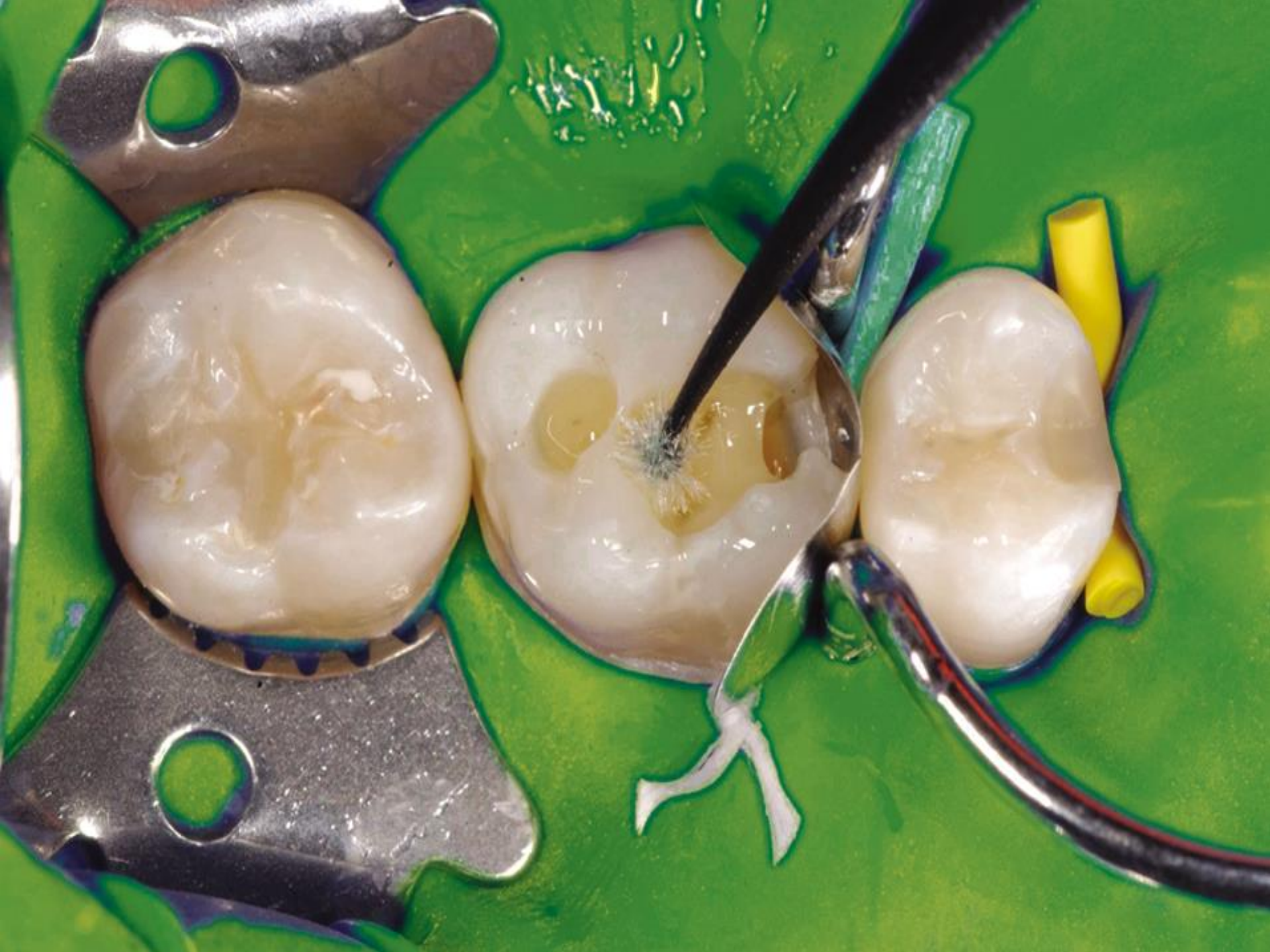


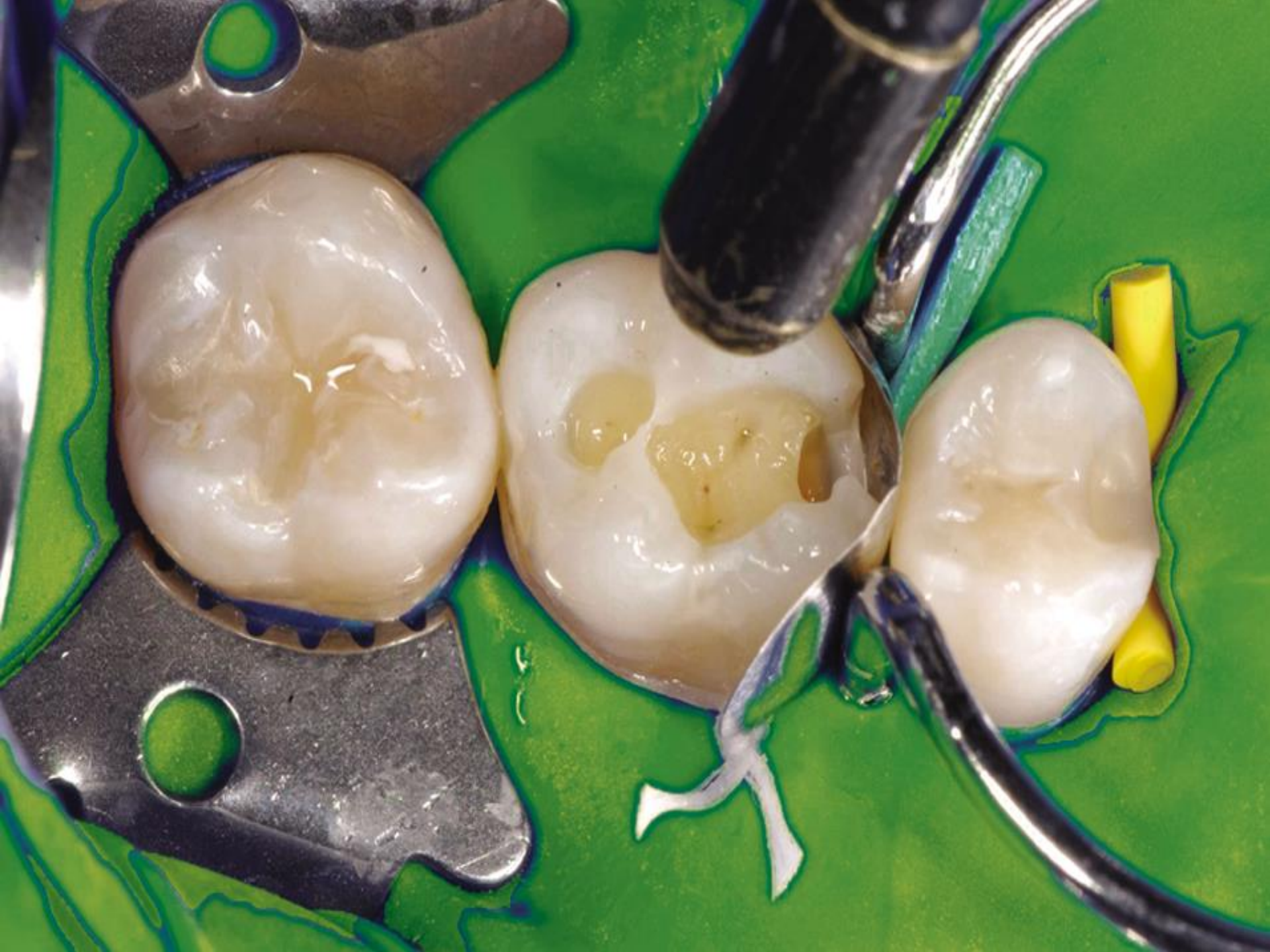


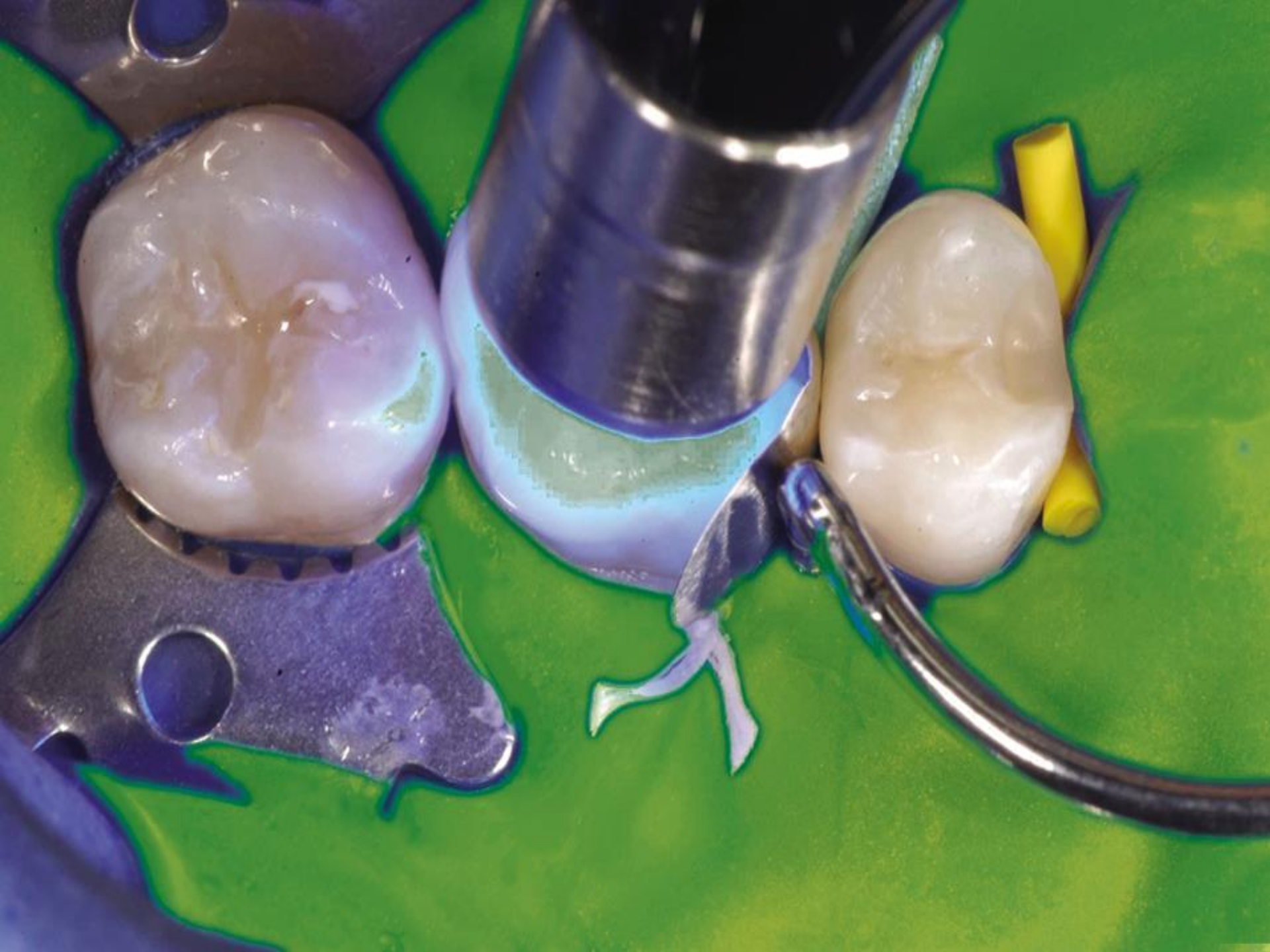


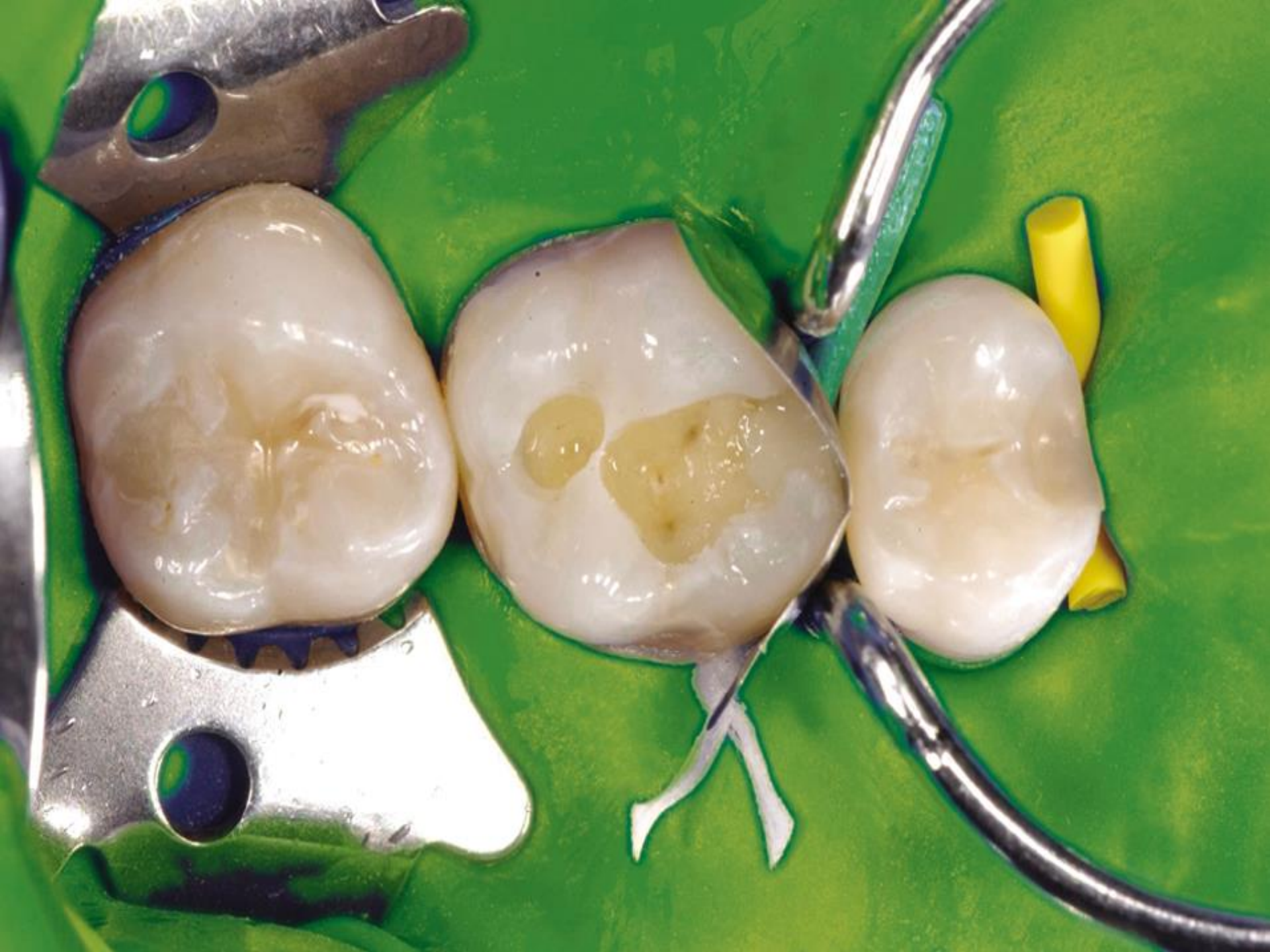


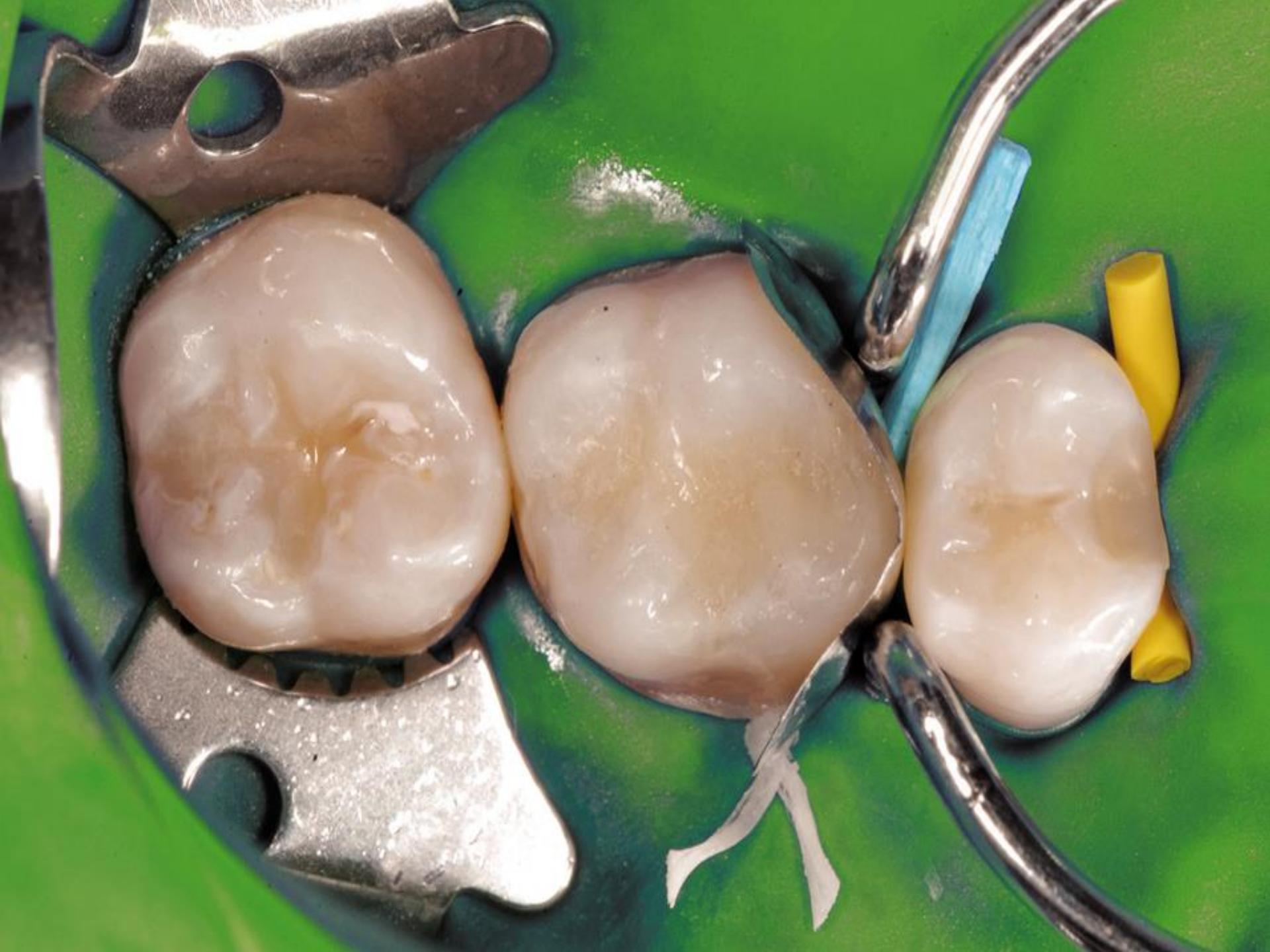


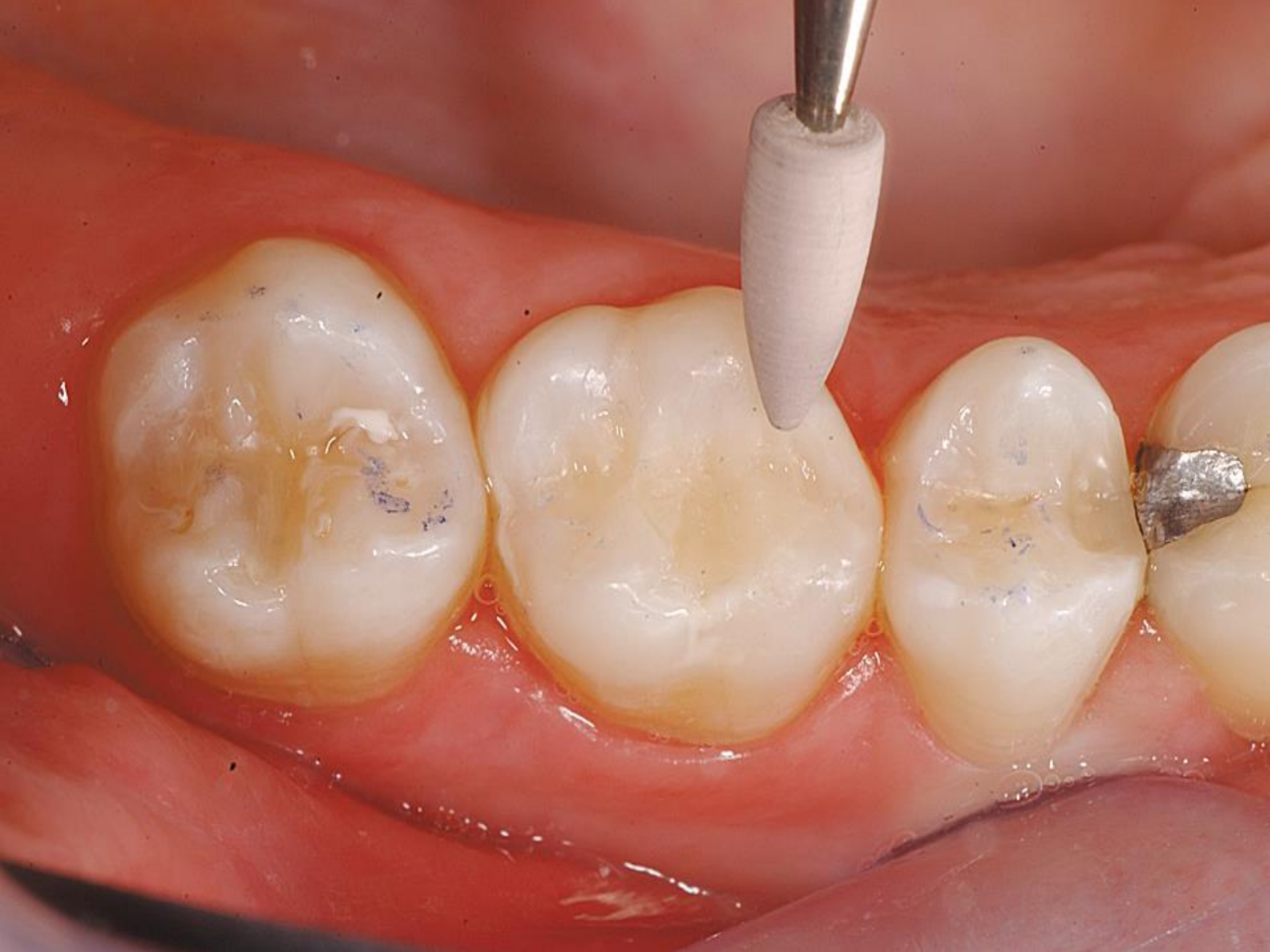
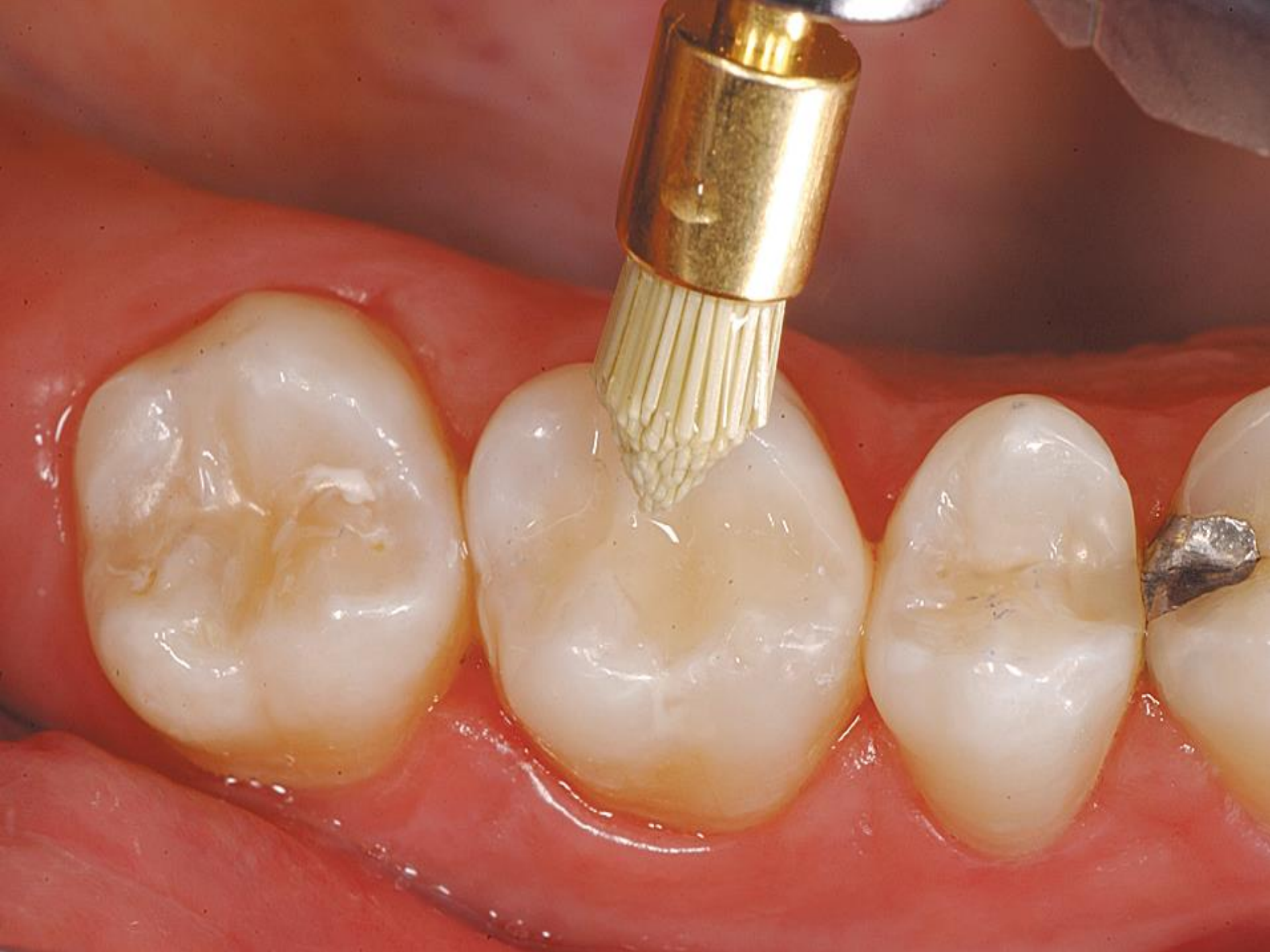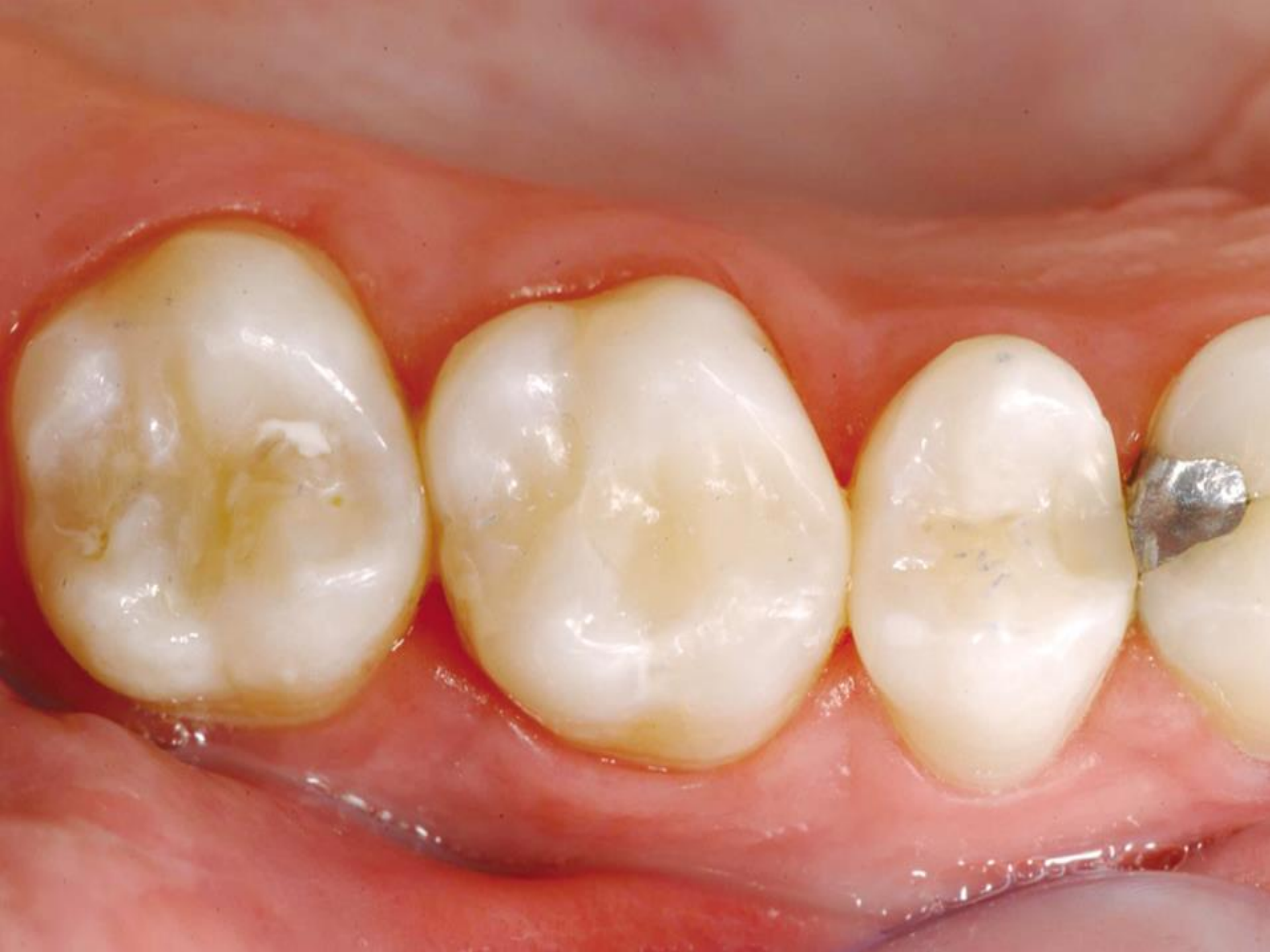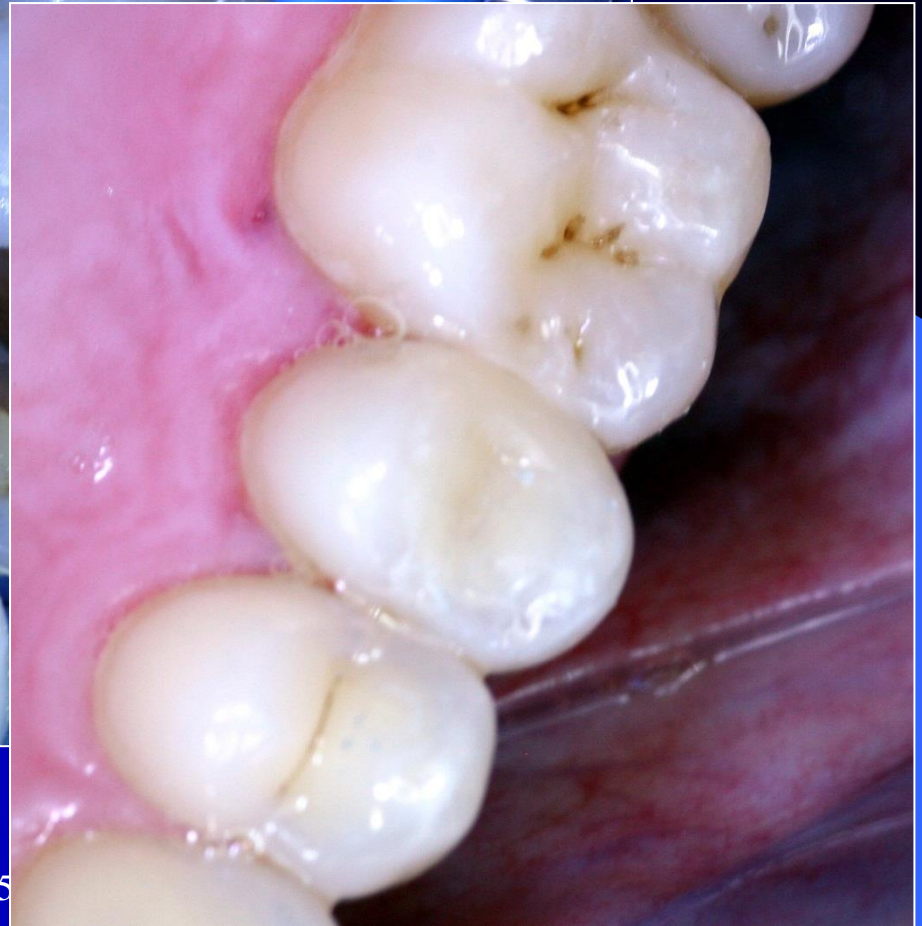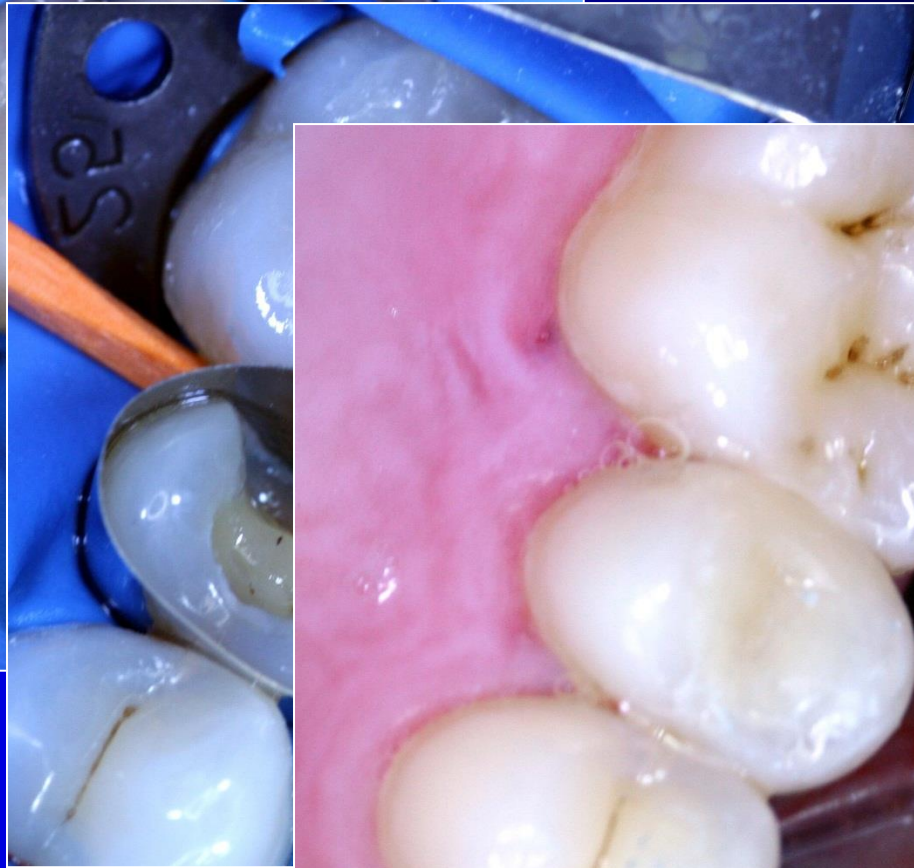
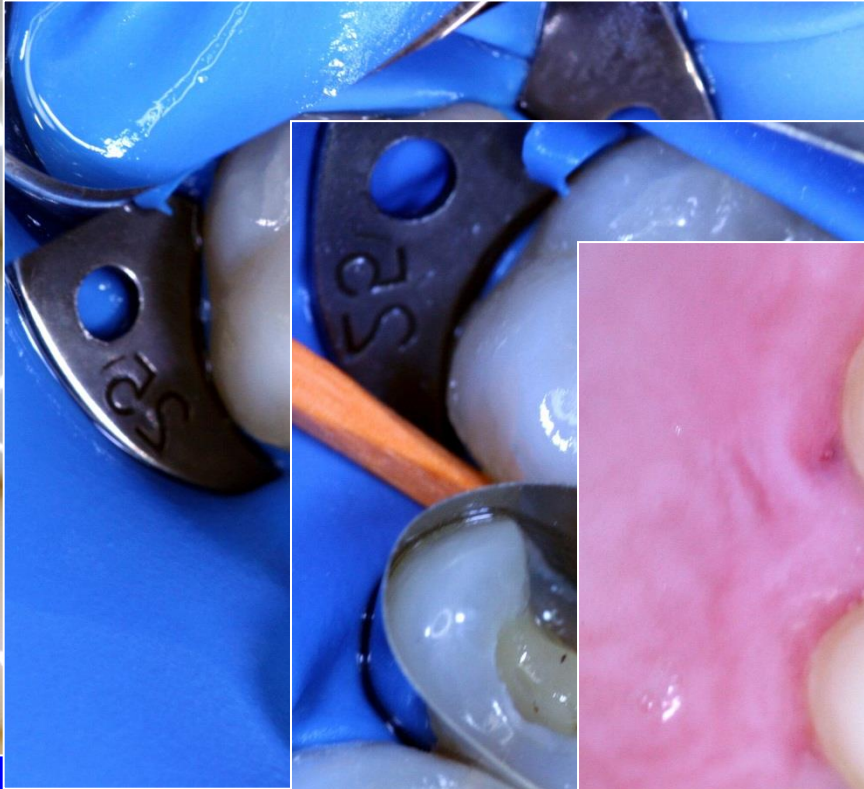
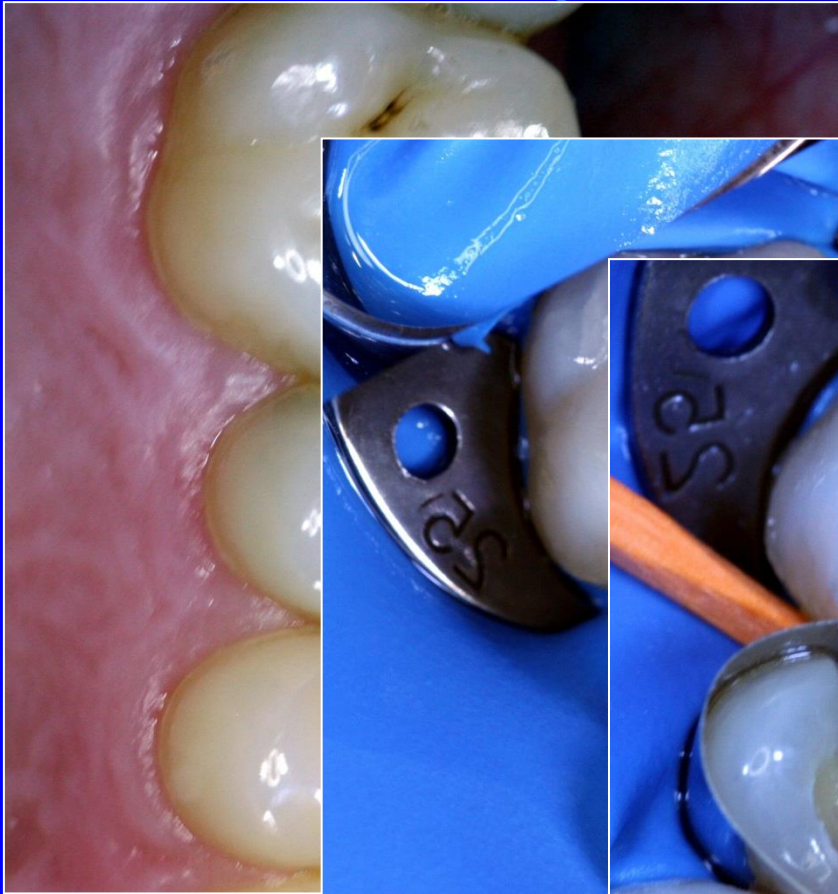











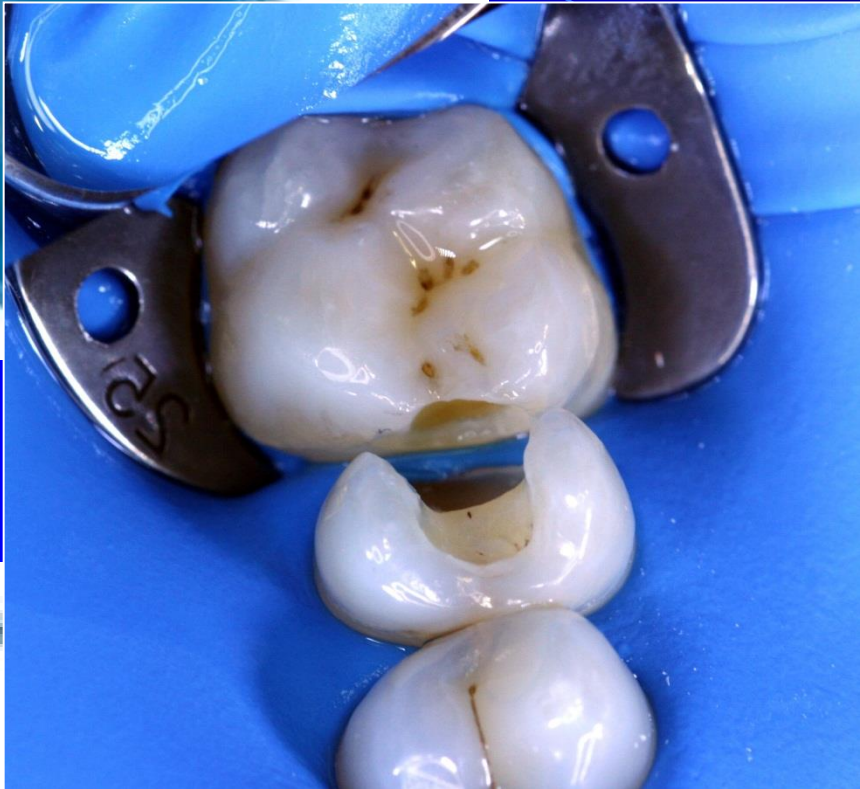
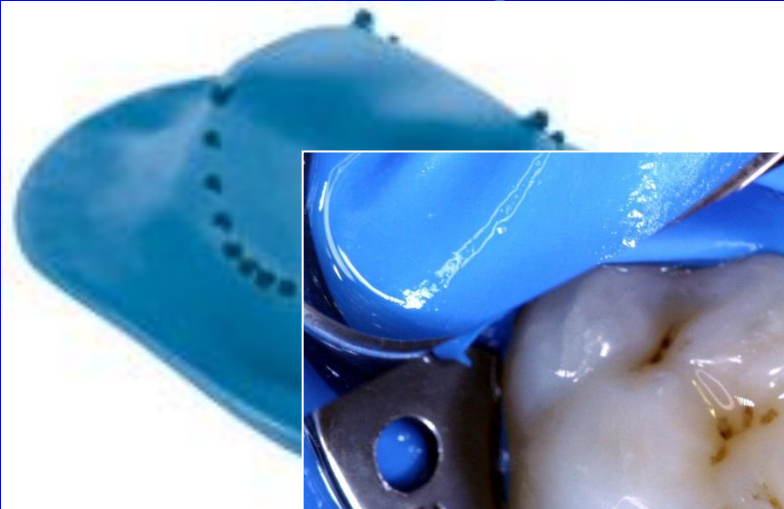

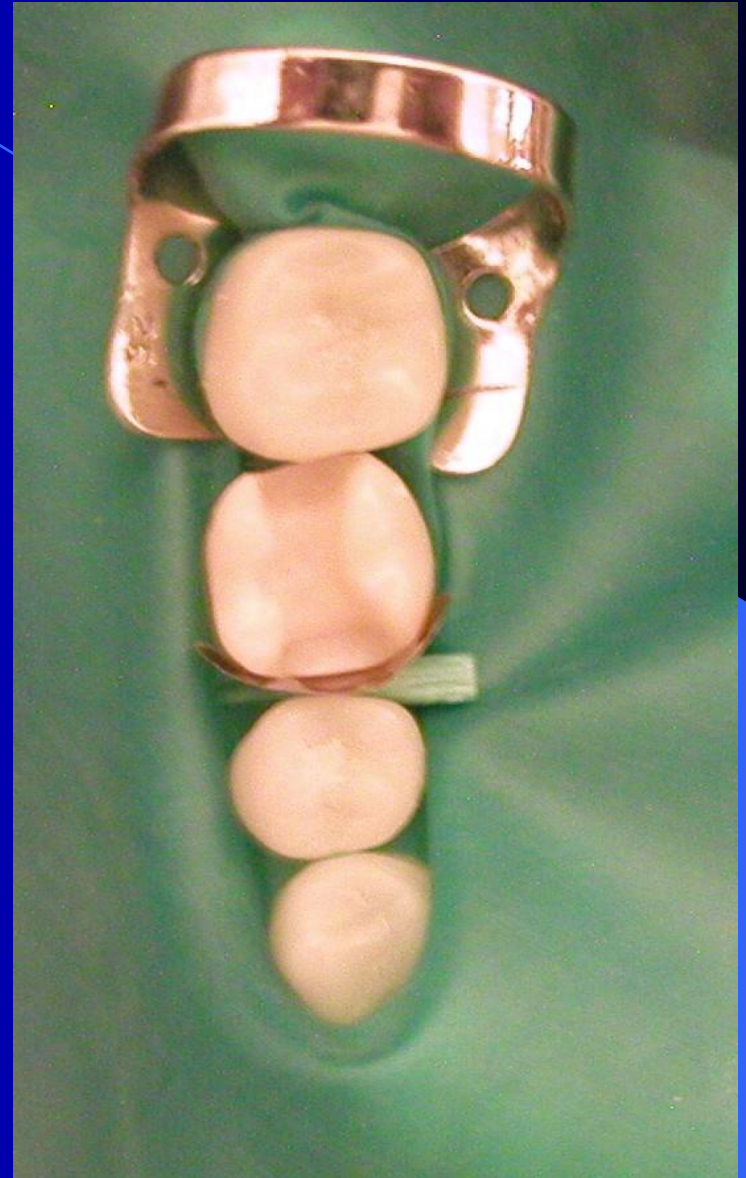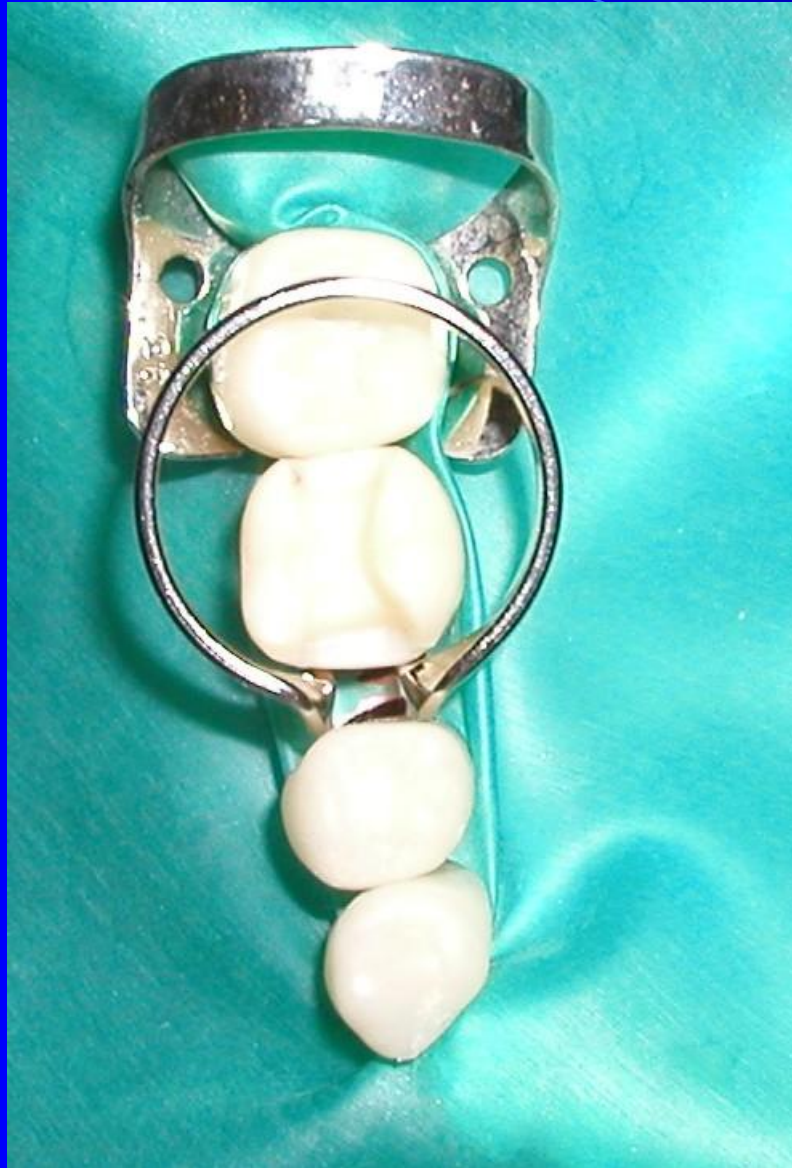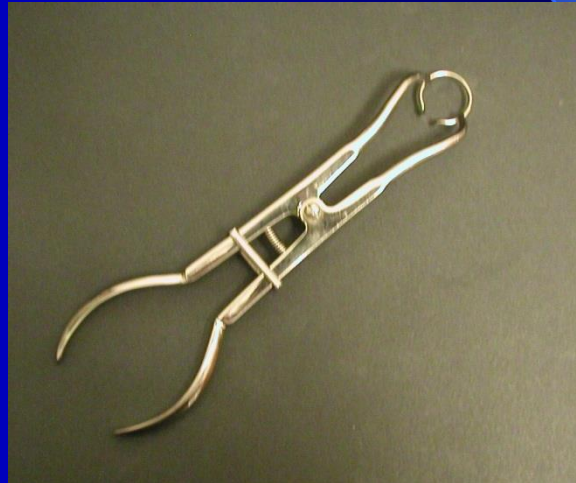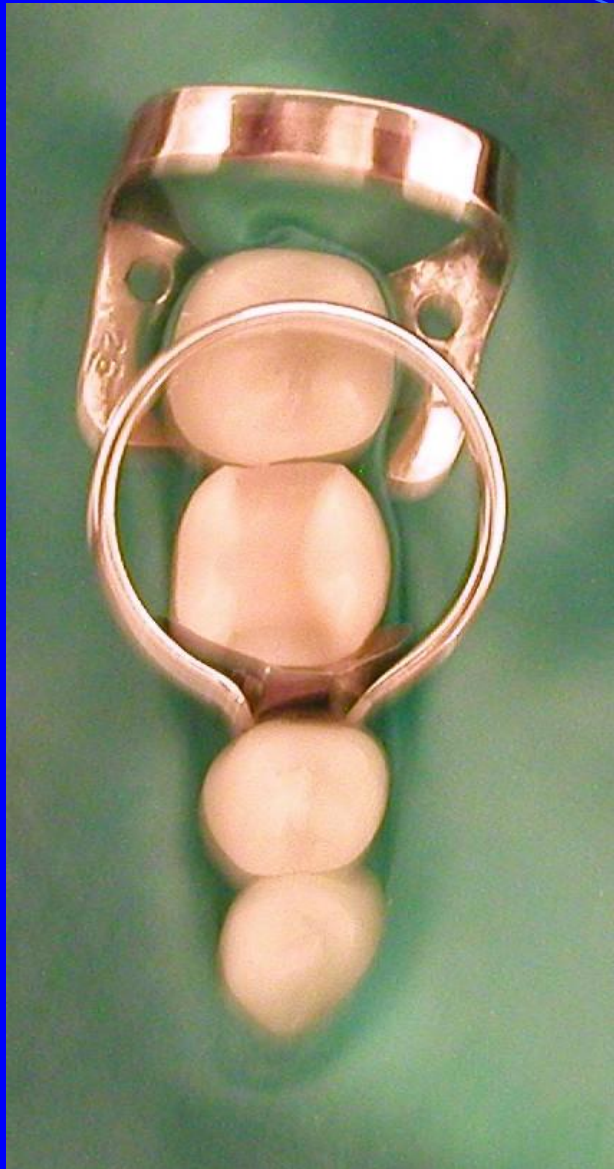Matrices for composites in class II.

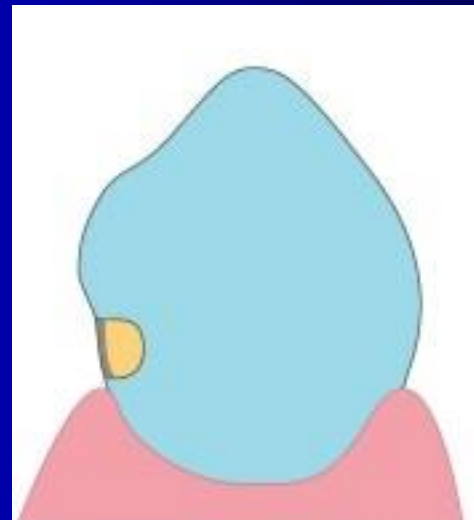
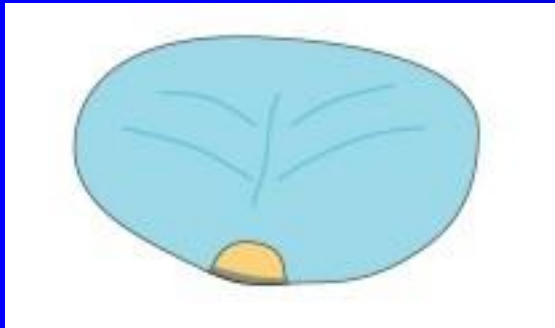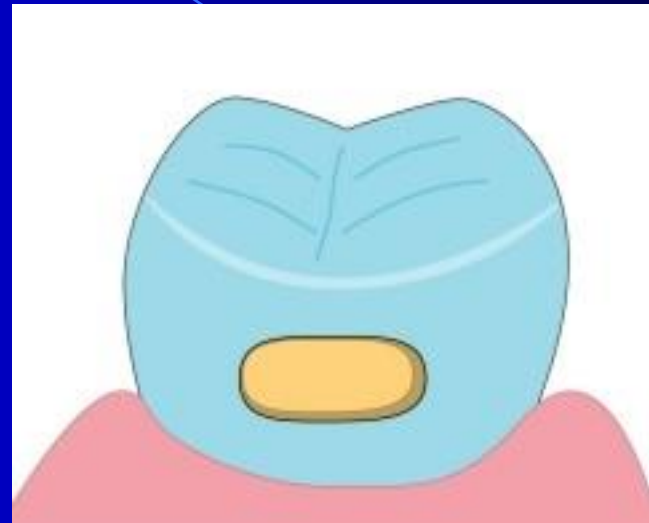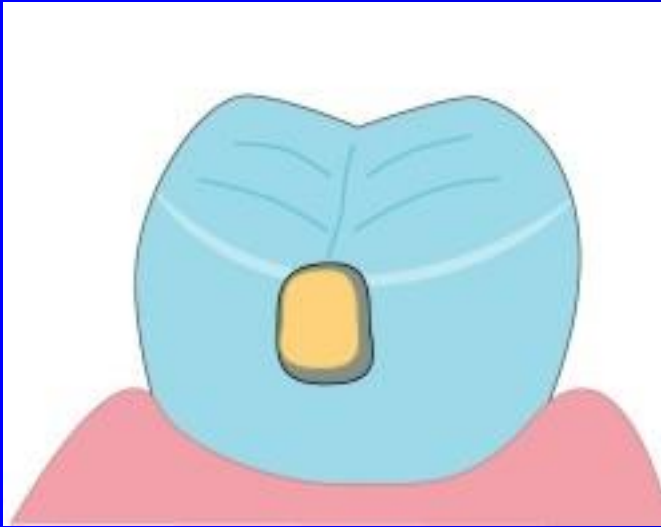
- Matrix band + matrix retainer
- Segmental matrix + separator

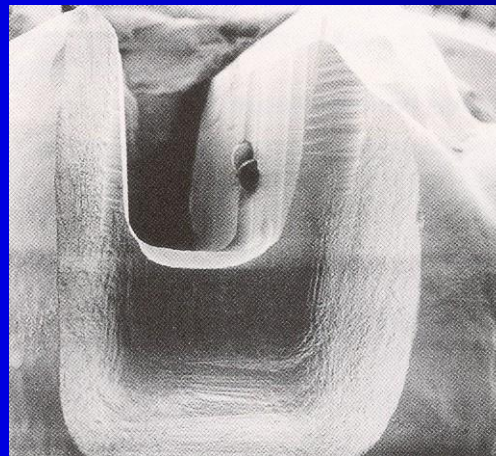
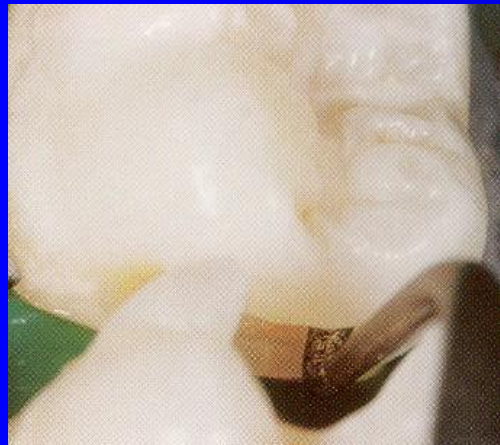
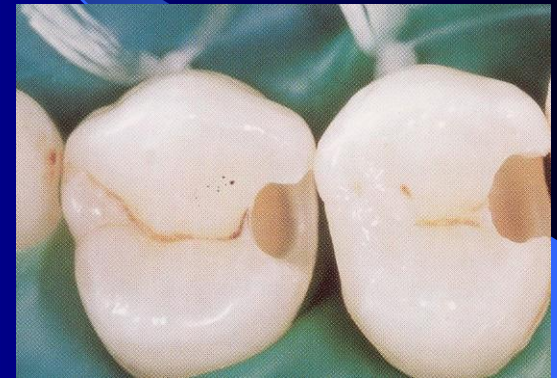
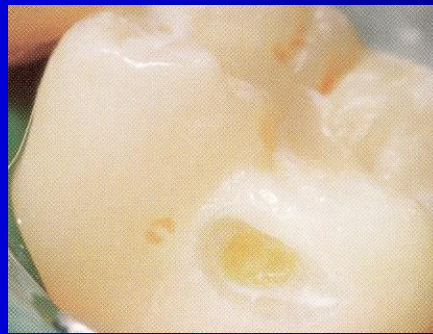
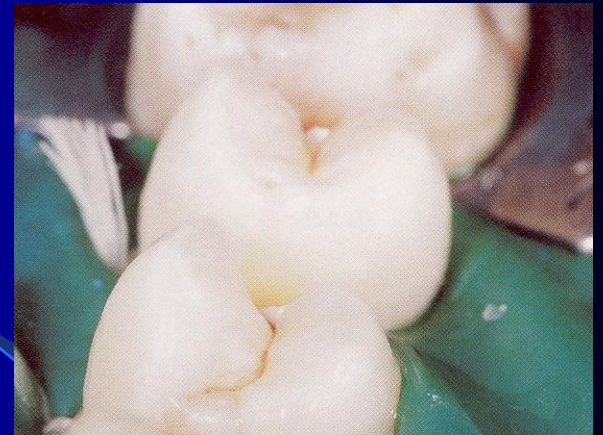
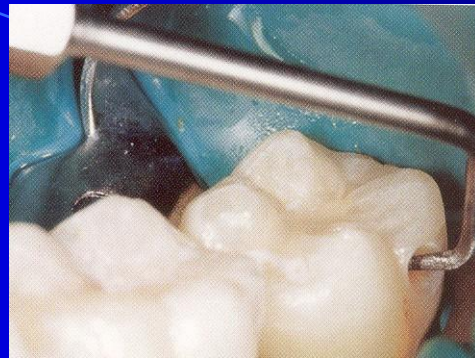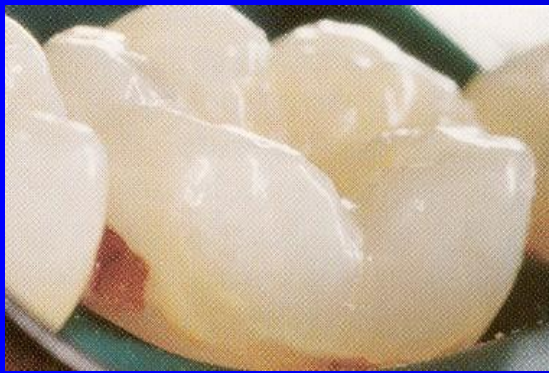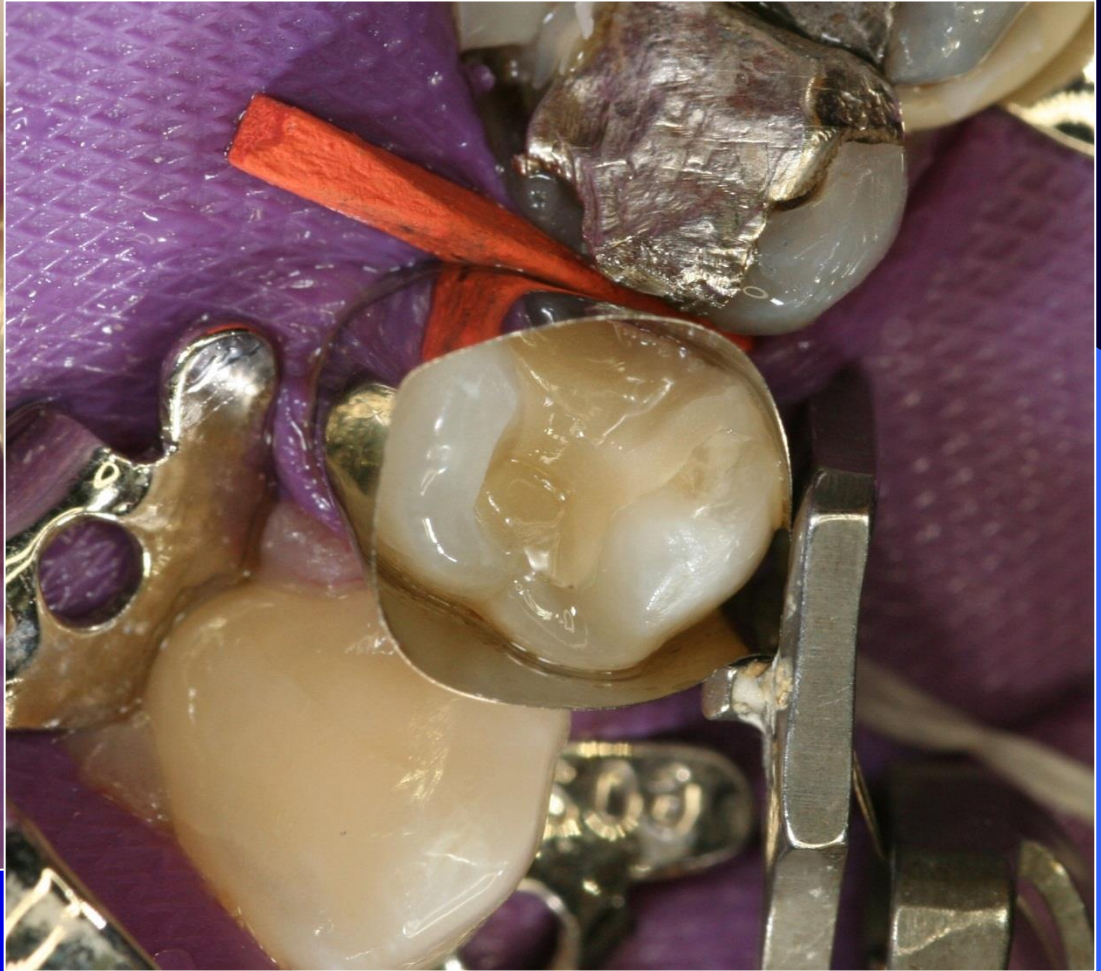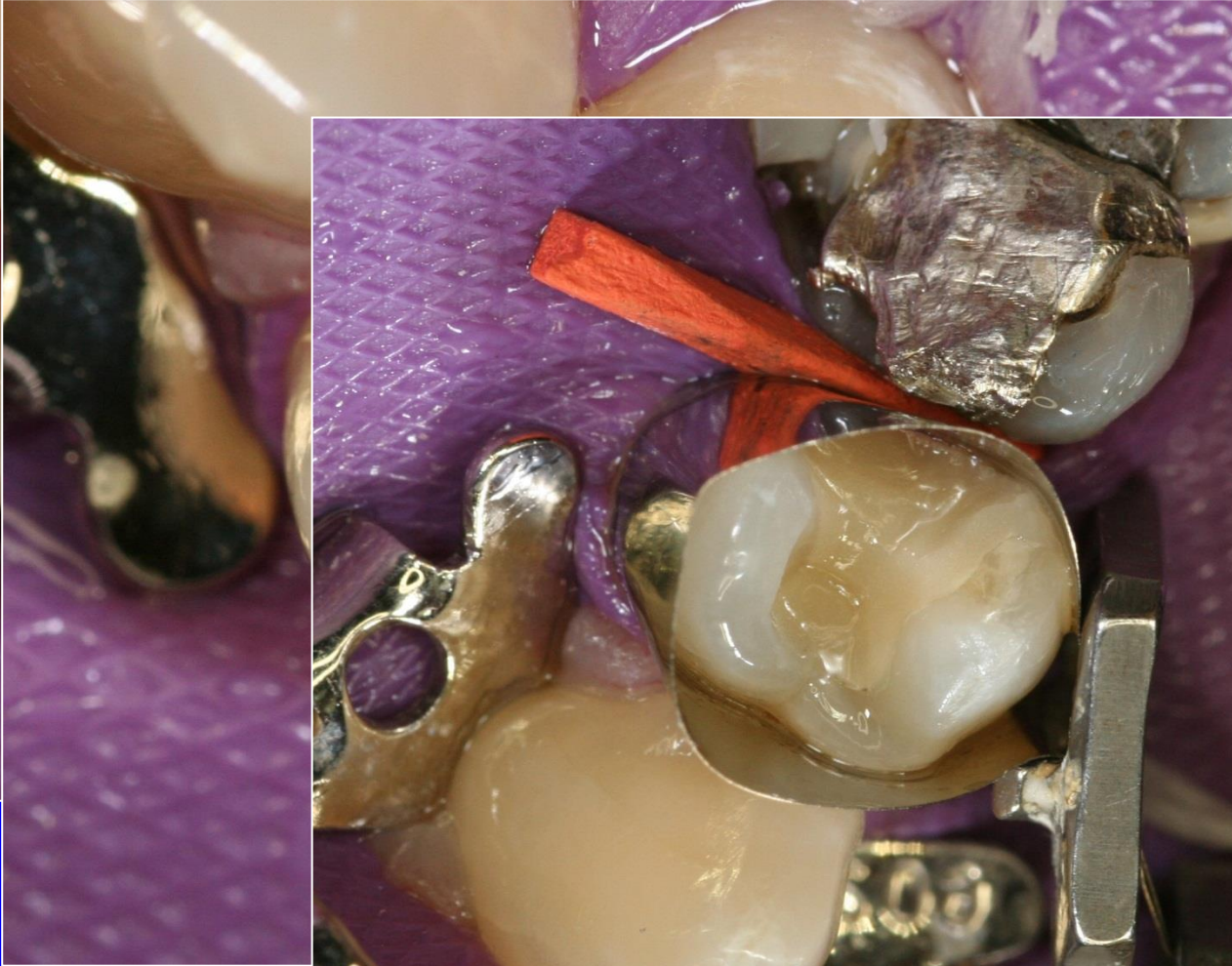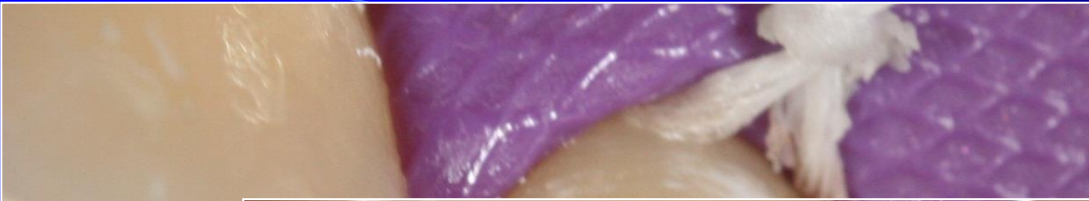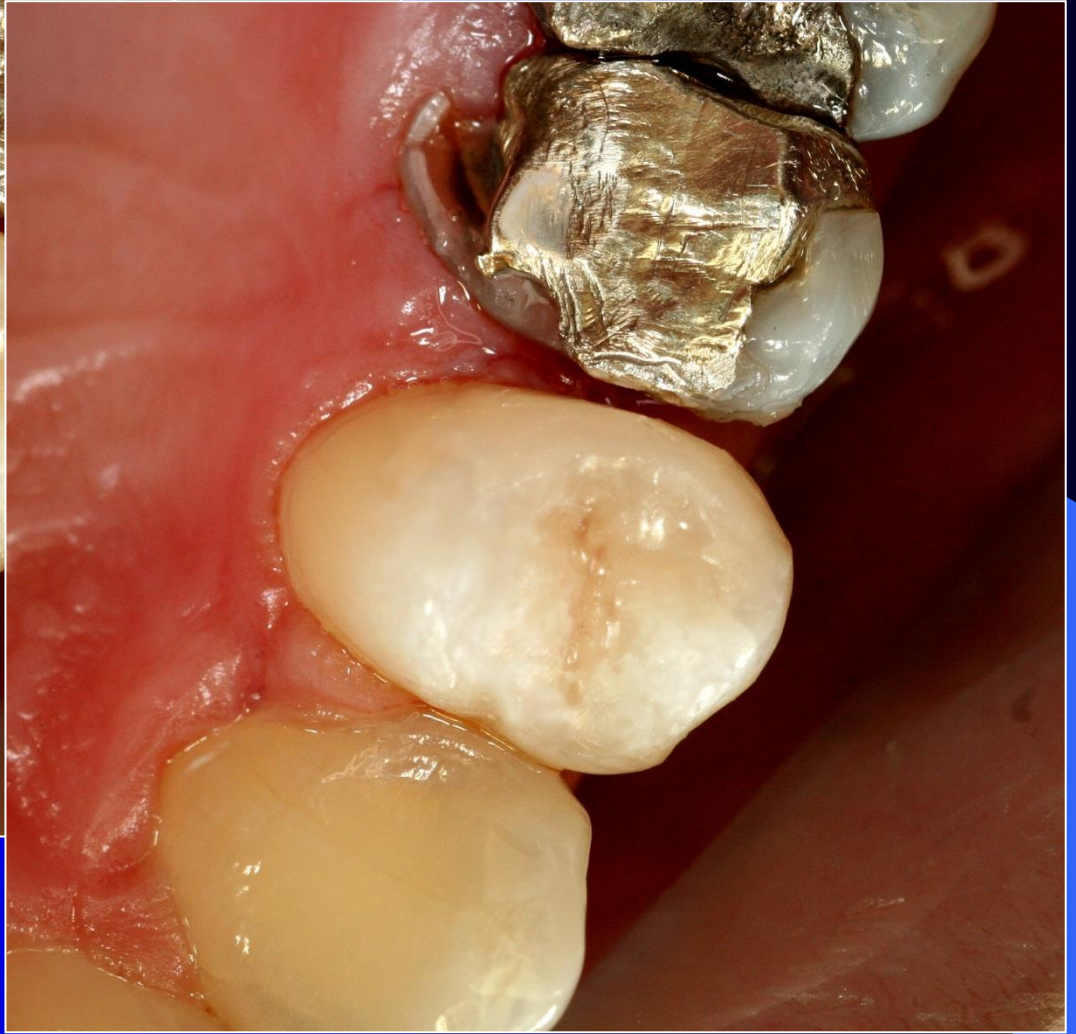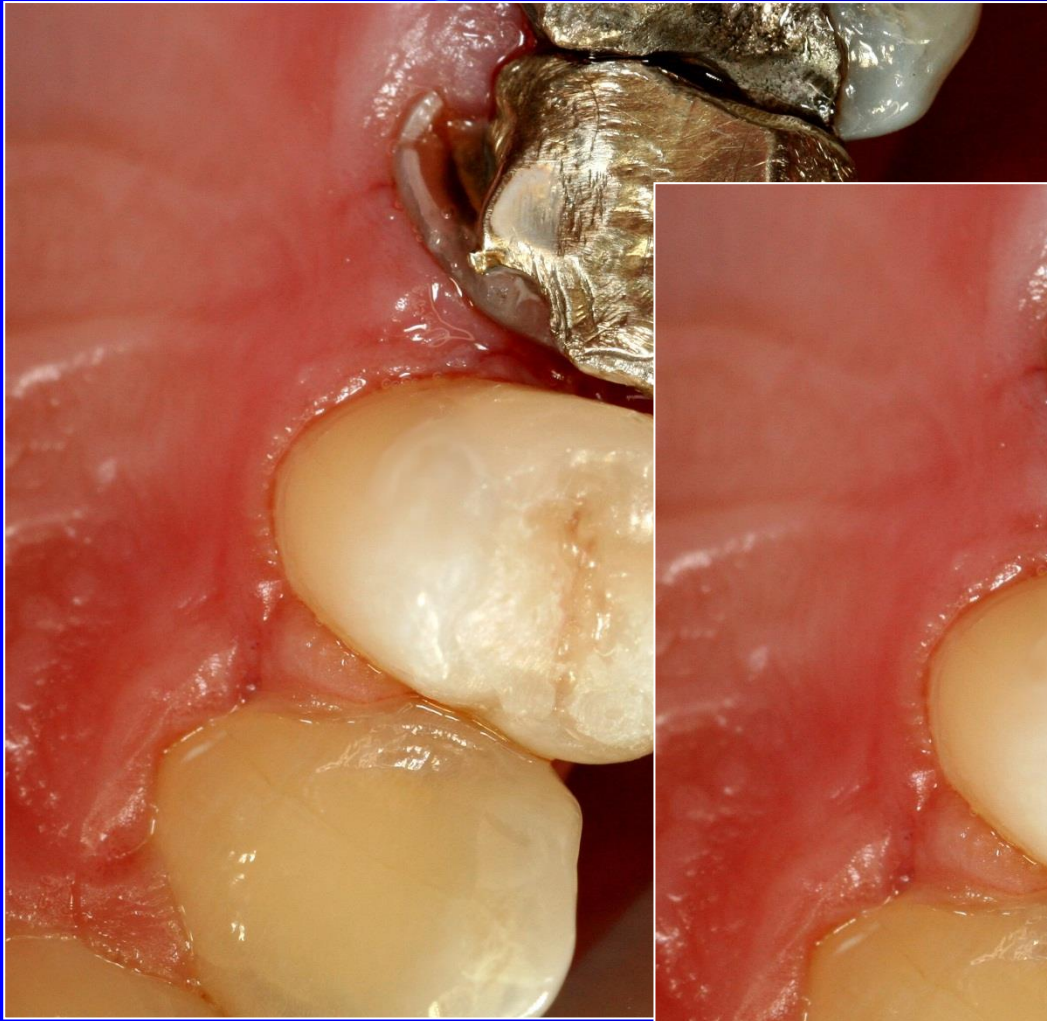


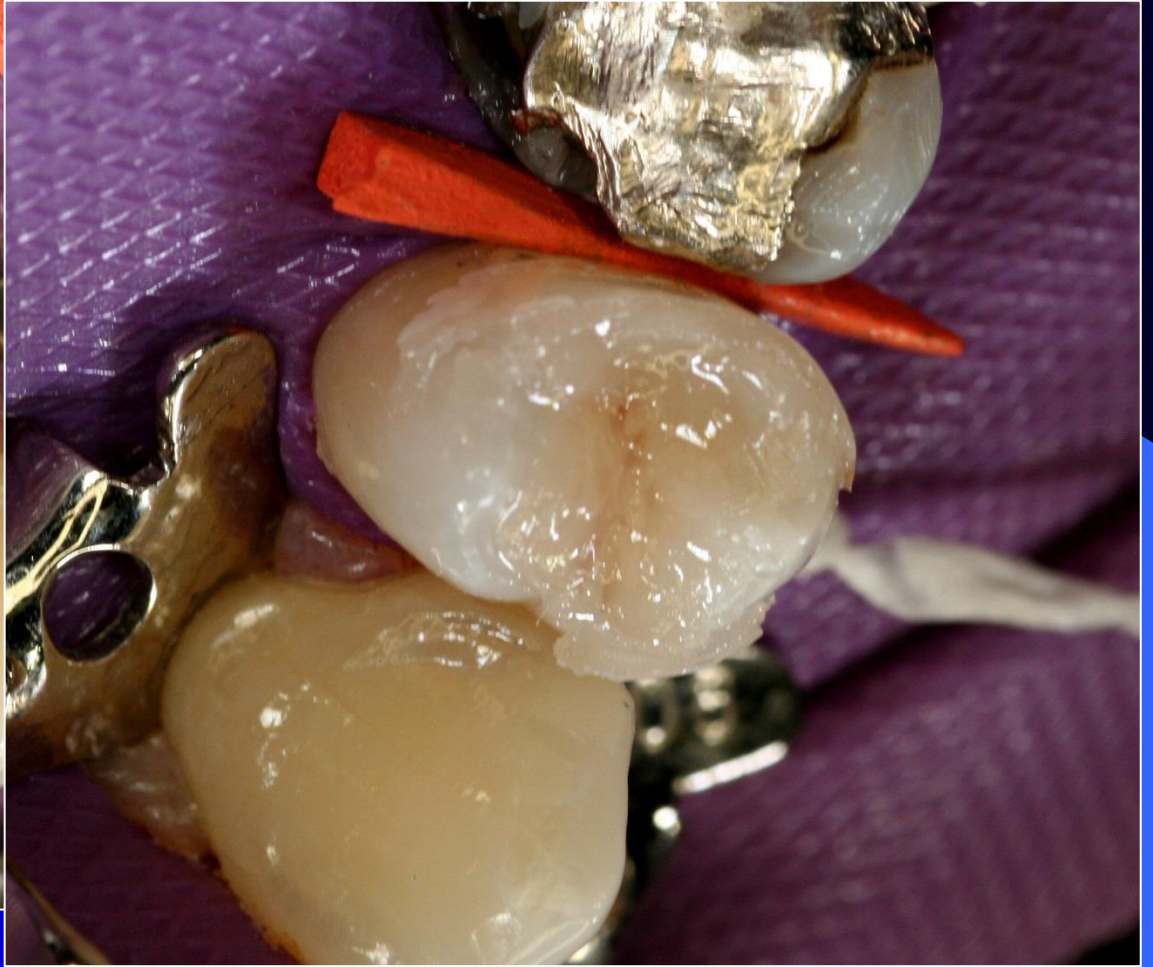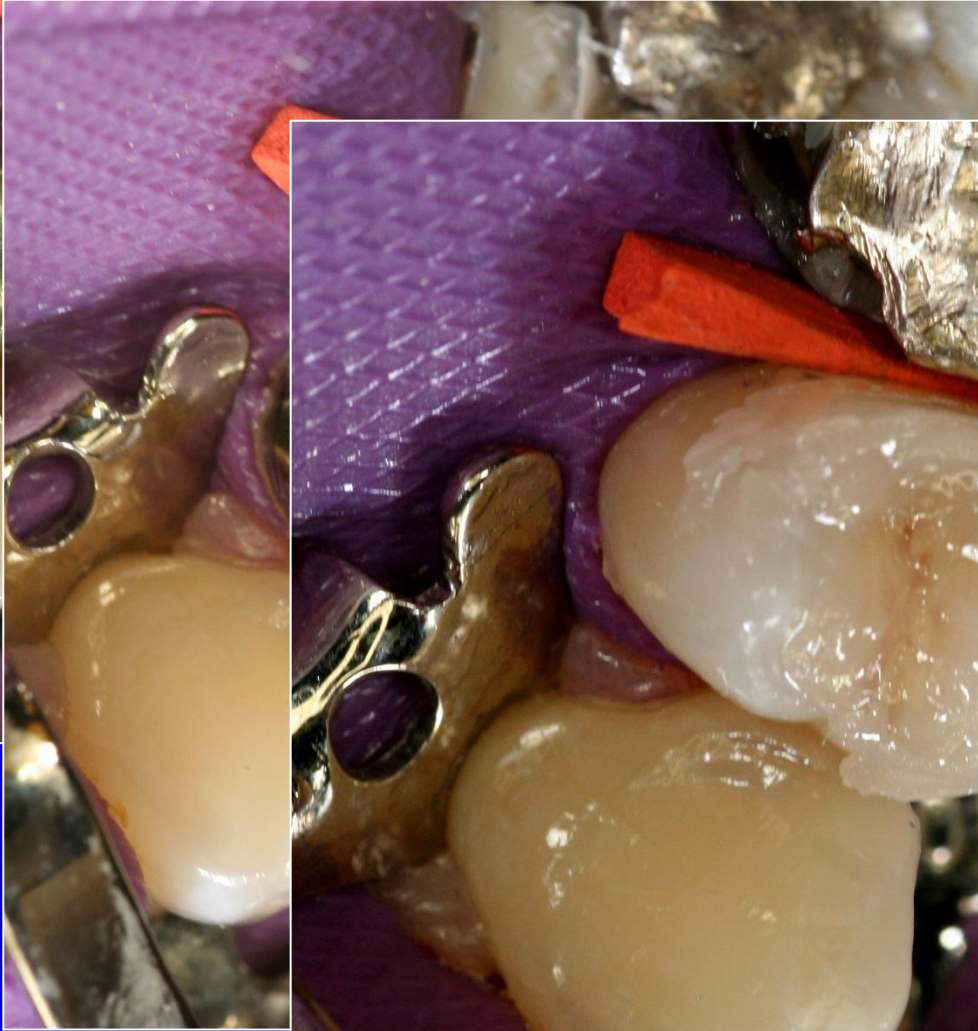Alternative preparation – adhesive slot



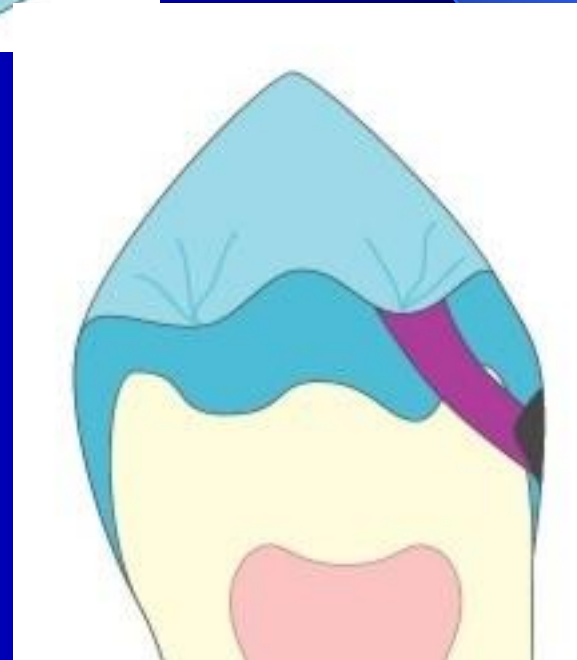
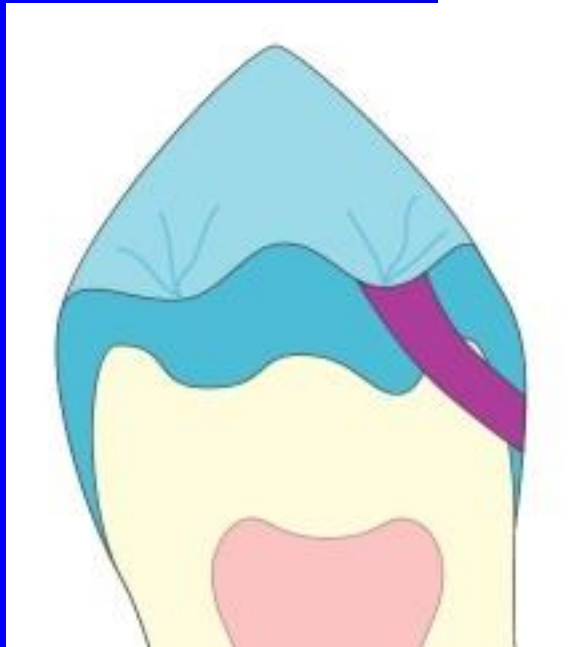
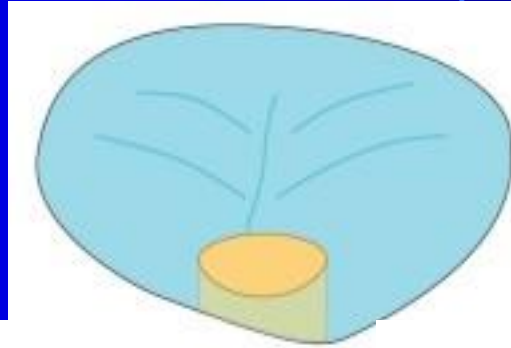






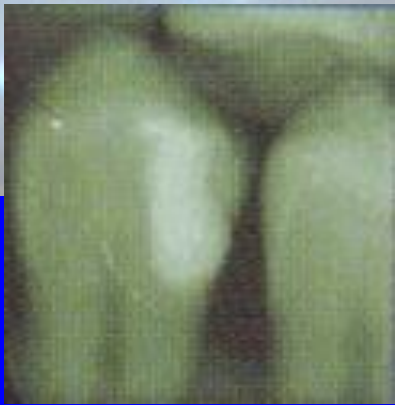
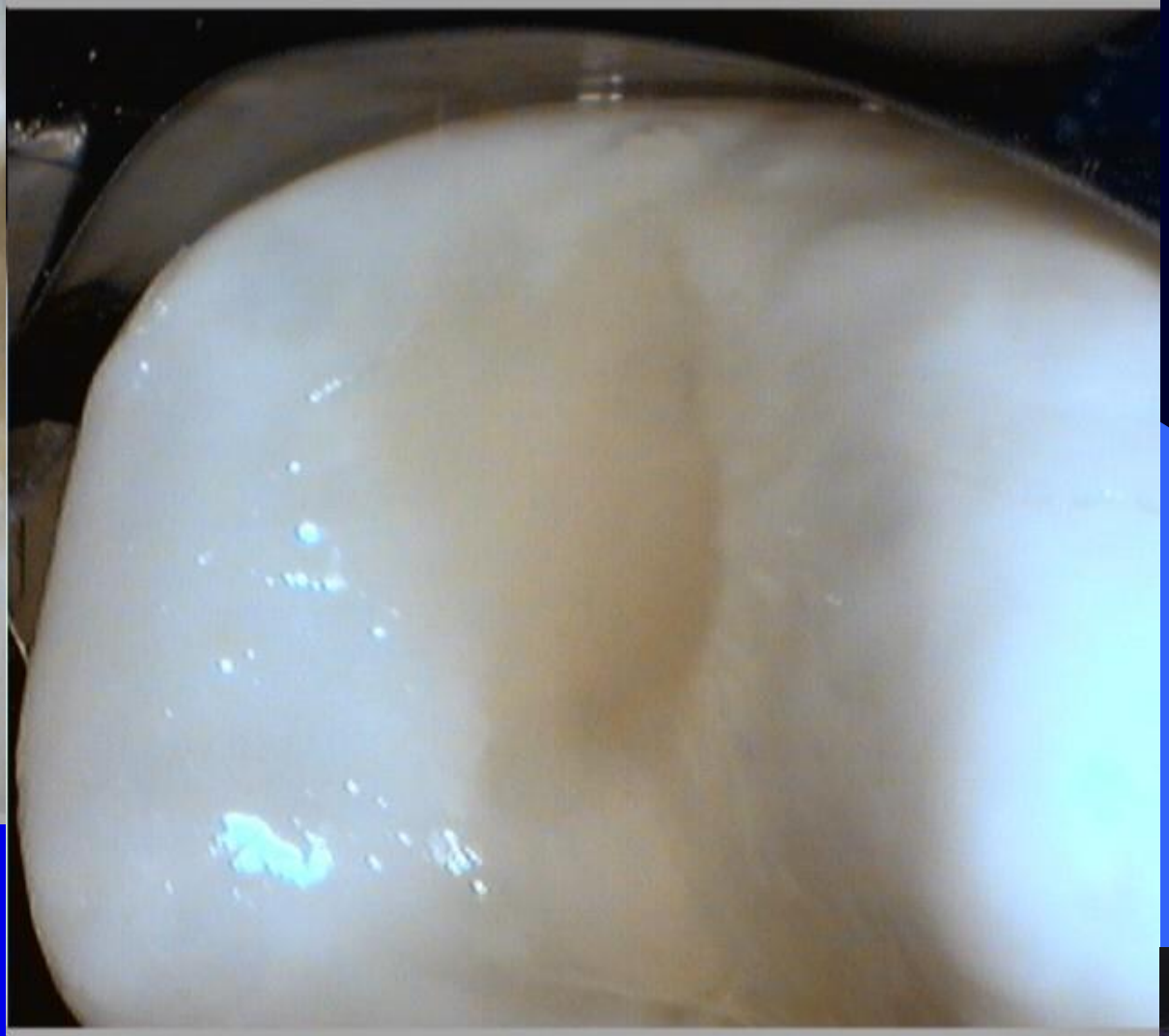
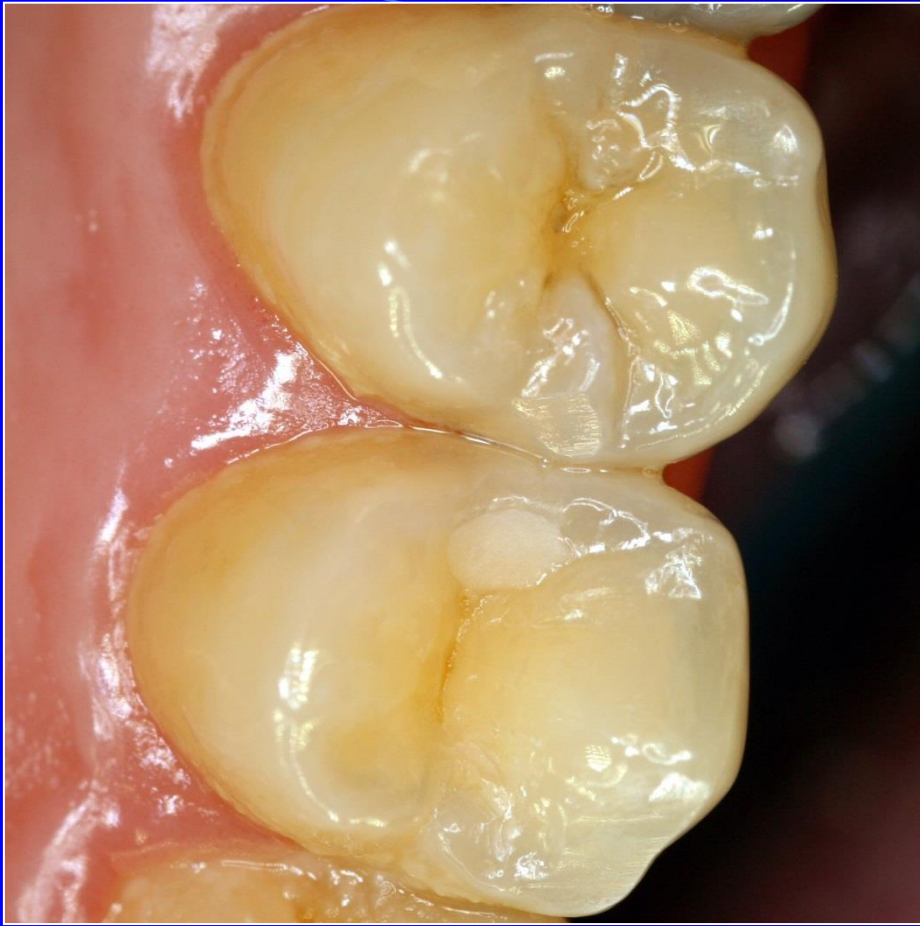



Tunnel preparation

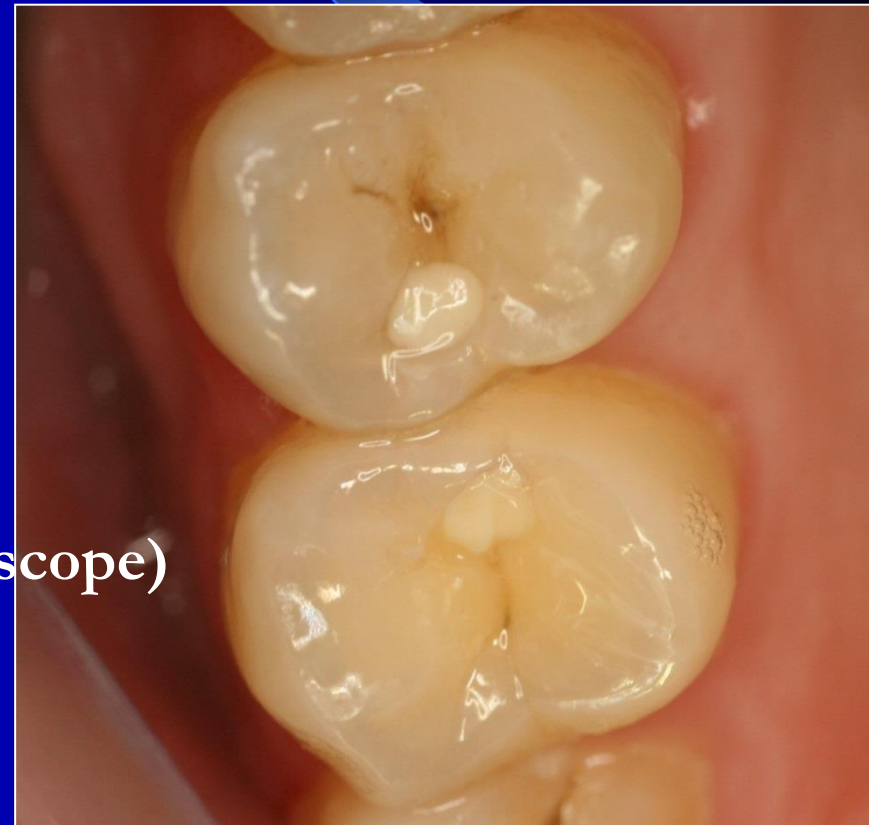







1. Low caries risk
2. Proximal ridge without infrapulpal
3. Good cooperation
4. Small caries lesion



1. Magnification(Loups or microscope)
2. Miniinstruments
3. Dezinfection
4. GIC in capsules or composite
5. BW post op

Glassionomer and class II.

- Temporary filling – first phase for the sandwich technique
- Tunnel filling (preparation)



