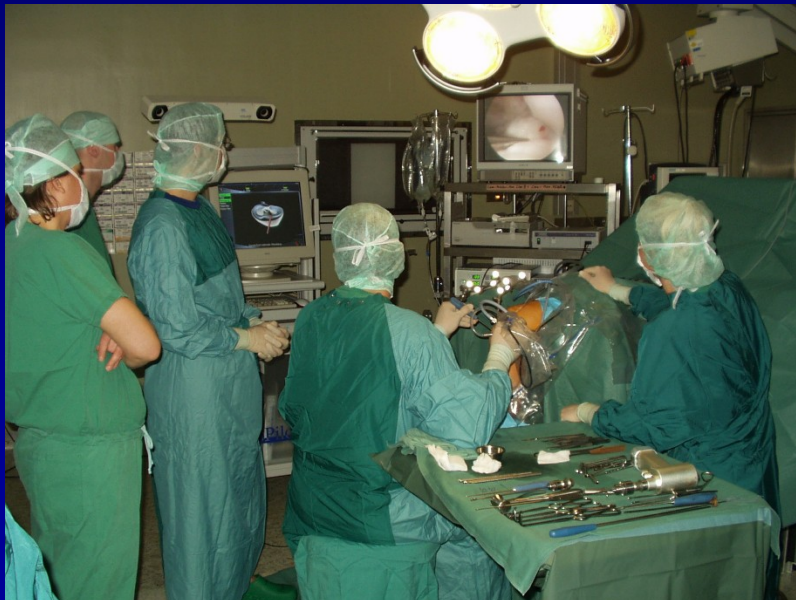

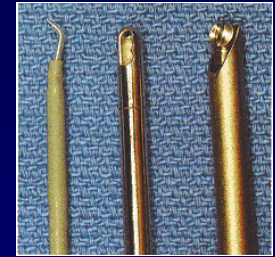
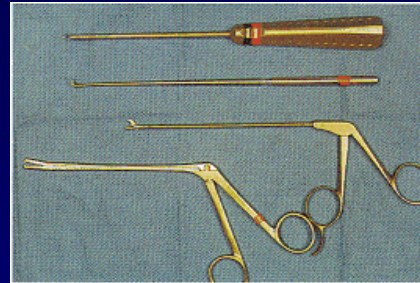

ARTROSKOPIE

- Endoskopická metoda, miniinvazivní
- Zobrazení a léčba
- Celková nebo spinální anestezie

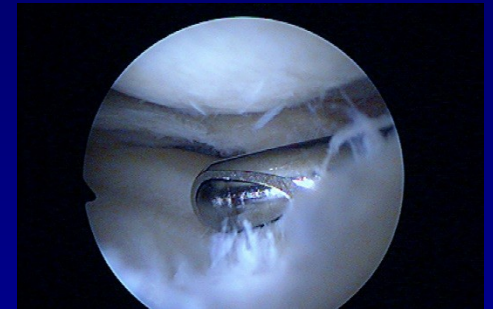

- koleno
- rameno
- hlezno
- loket
- zápěstí
- kyčel
- malé klouby

Artroskopie



- Artroskop
- Xenonové světlo s optickým kabelem
- Kamera
- ASK pumpa
- Nástroje
- Shaver, vaper
- Tisk, video



Artroskopie

Menisky

Chondropathie

Plastika vazů

Sutura rotátorové manžety

Instabilita ramene

Ošetření transchodrálních lézí

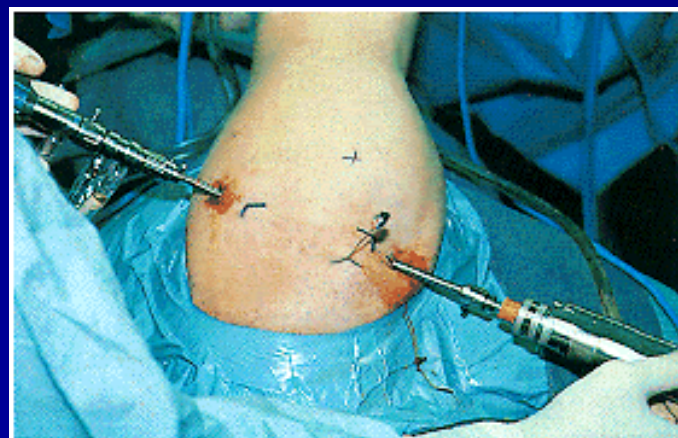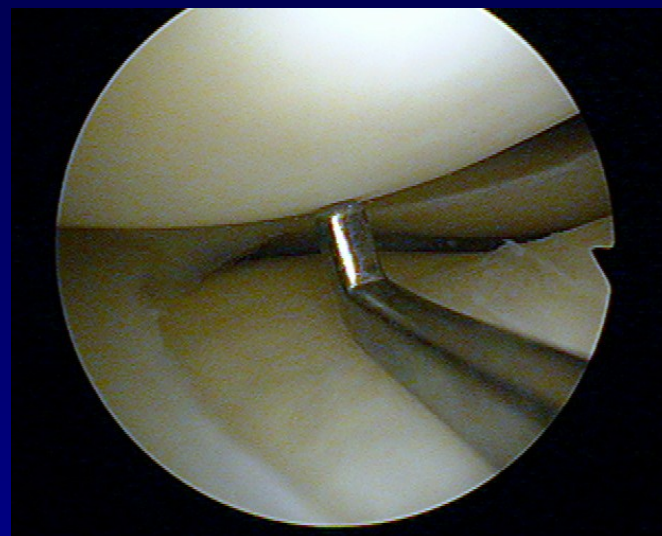
Synovektomie

Podpora při léčení nitrokloubních zlomenin

Biopsie

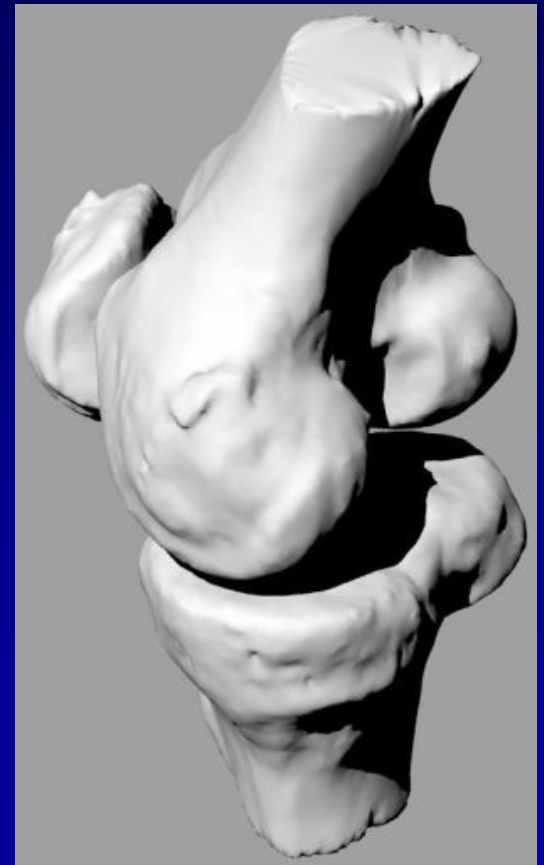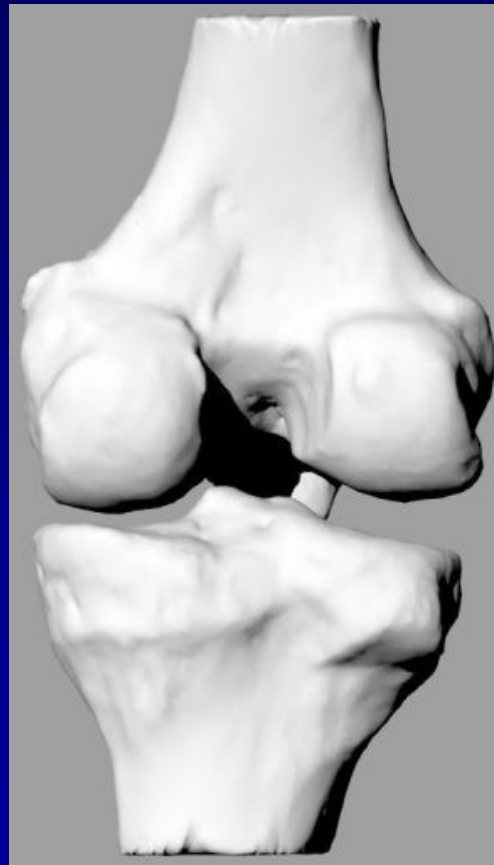
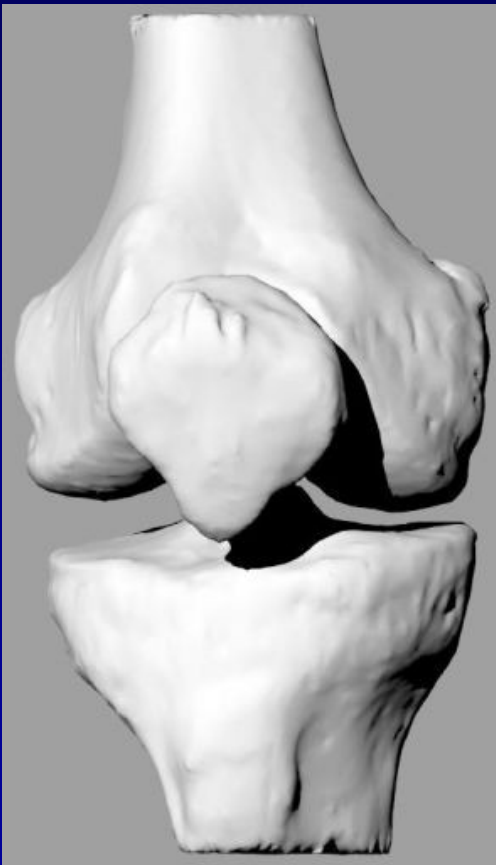Výhody

- Perfektní vizualizace
- Menší bolest po výkonu
- Rychlá rehabilitace
- Malá incise

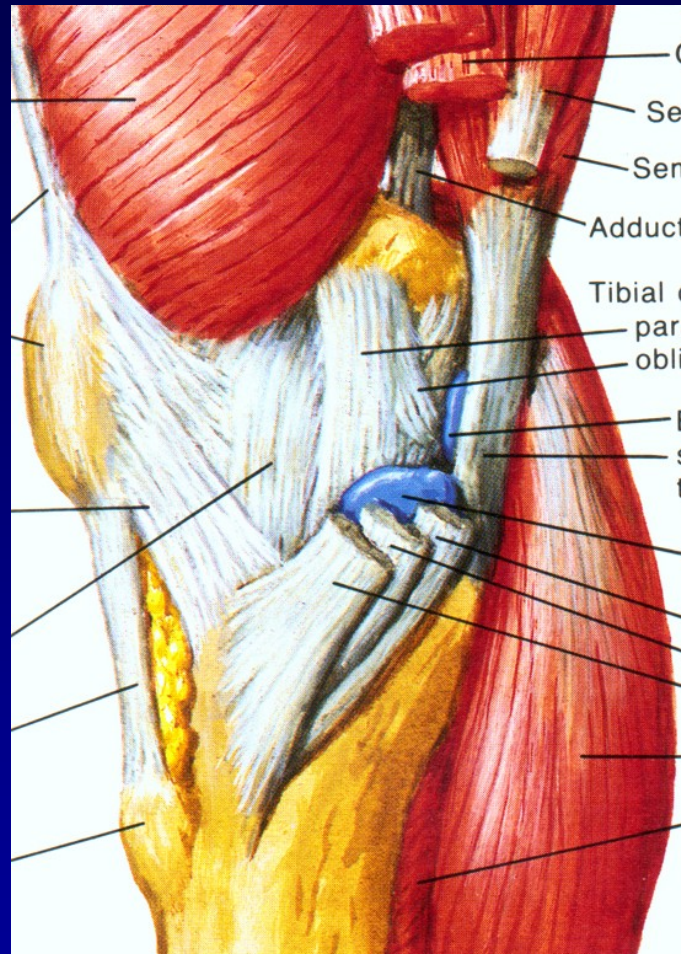


Koleno- složitá struktura

Artikulující kosti: Femur, tibie and patela

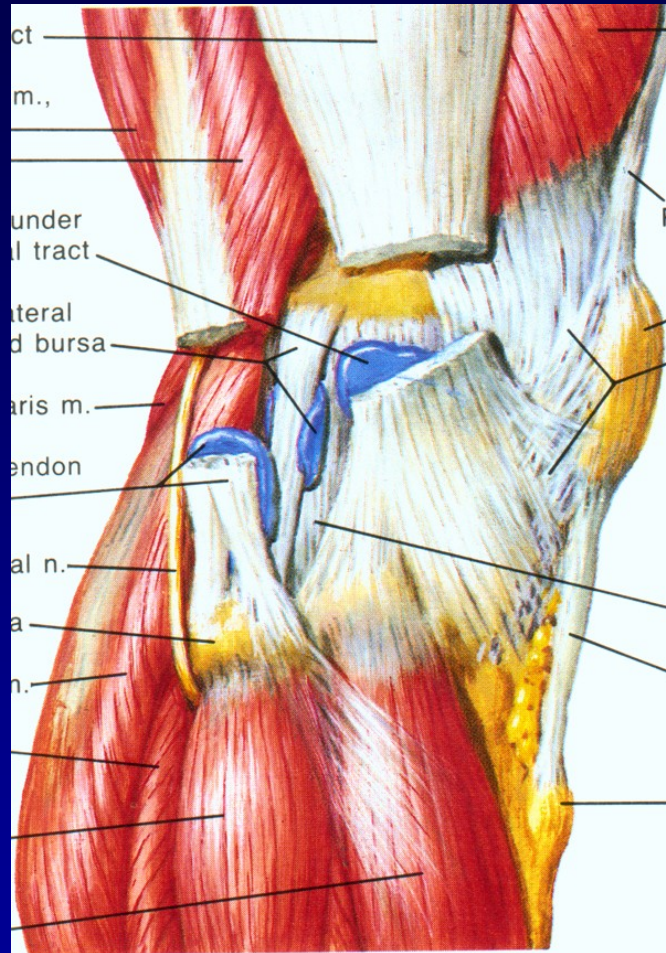


Stabilita



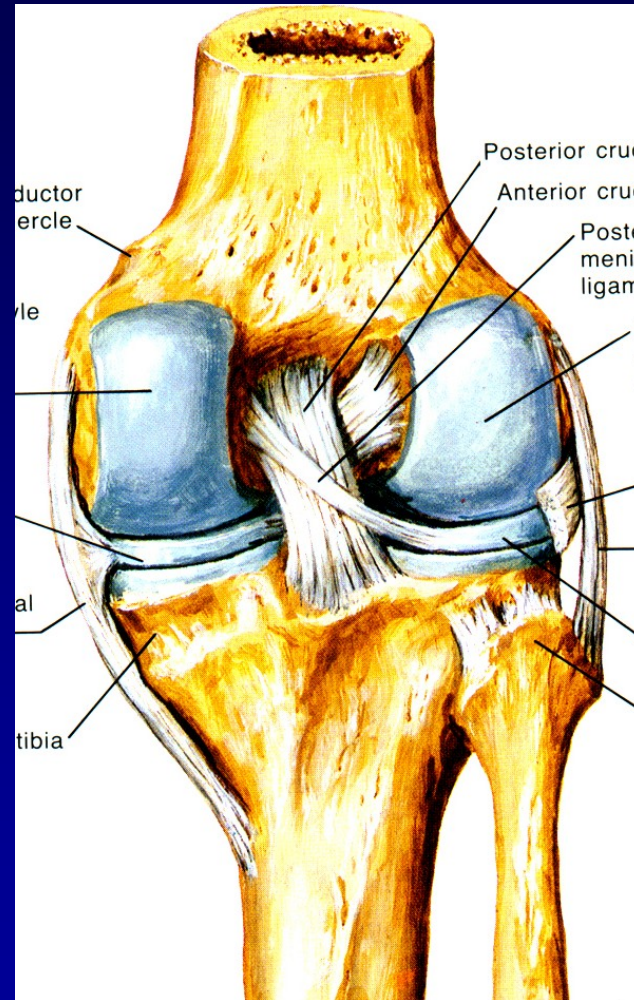
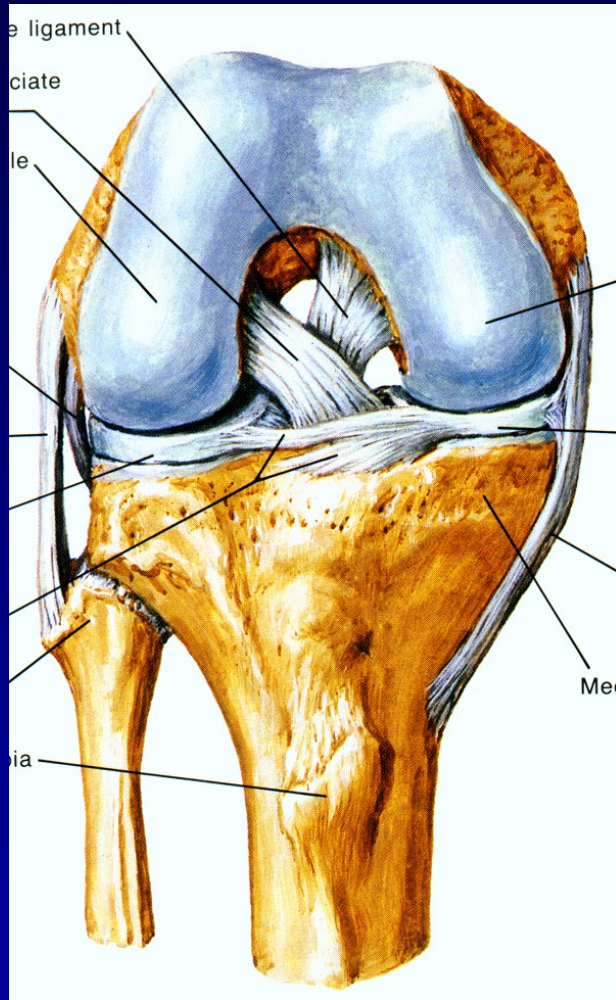
Medialní strana

Stabilita



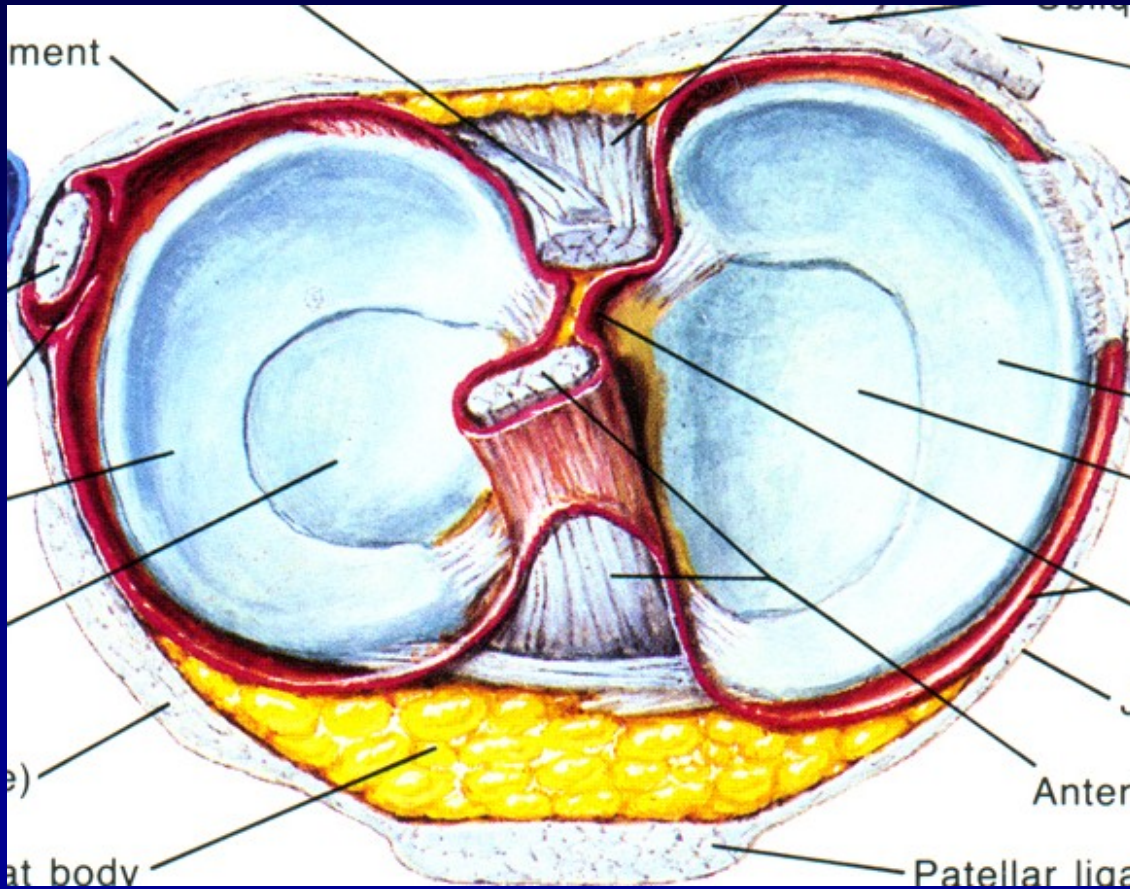
Laterální strana

Stabilita



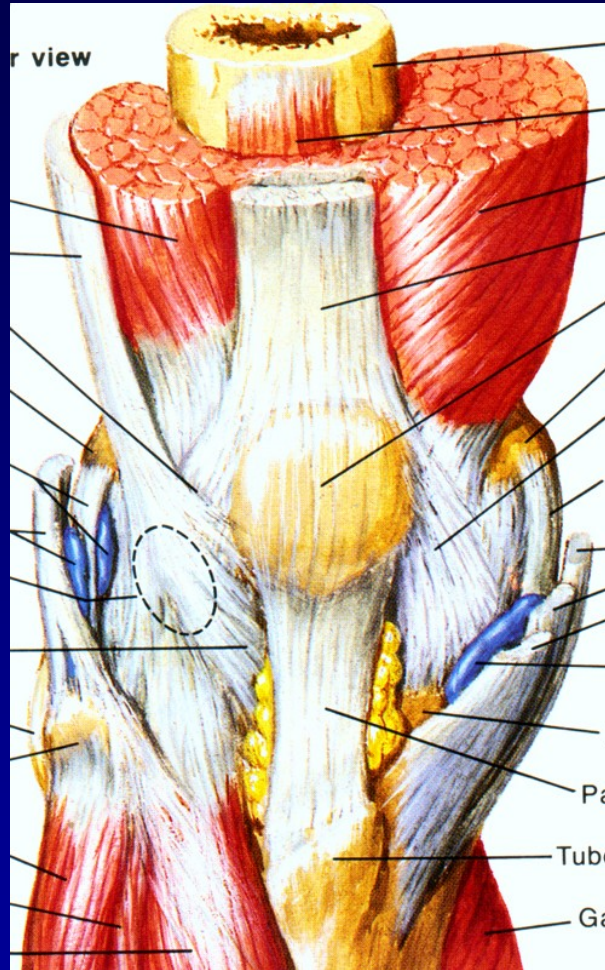
Zkřížené vazy

Stabilita



Menisky

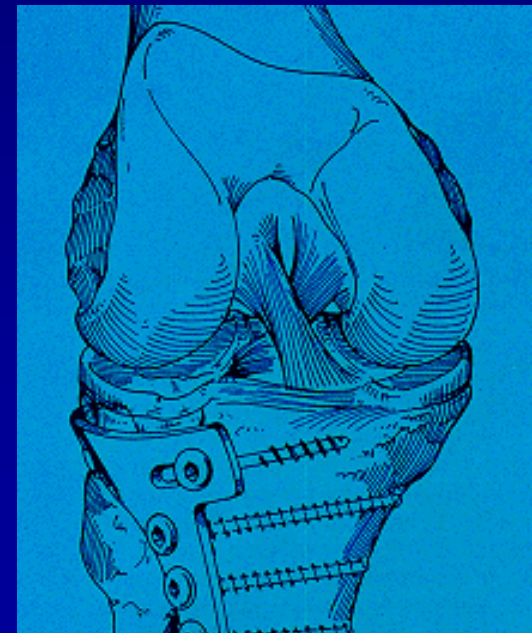
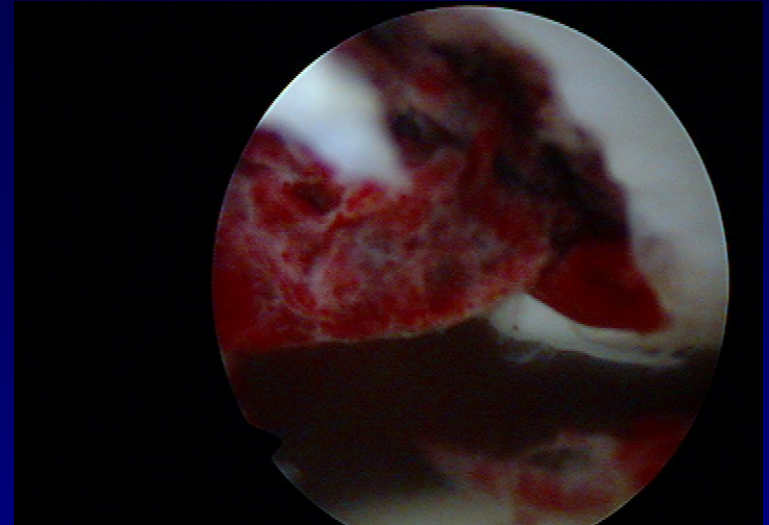
Stabilita



Svaly

Koleno

- Traumatologie
- Chondropatie
- Degenerativní změny
 - artróza



Traumatologie

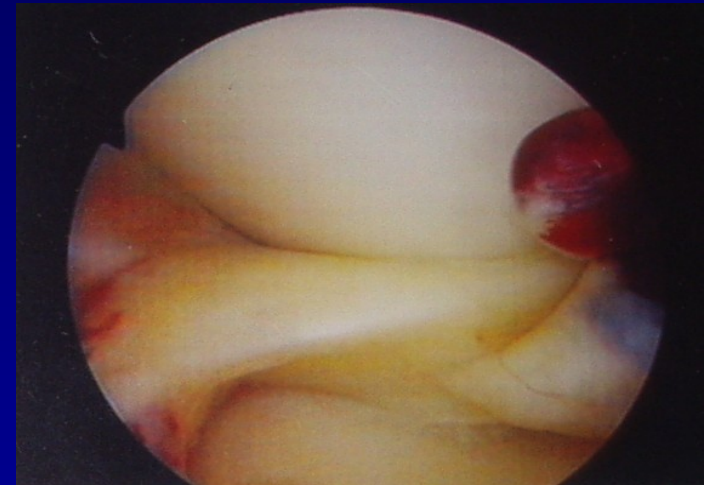
Haemarthros

Léze menisků

Ruptury vazů

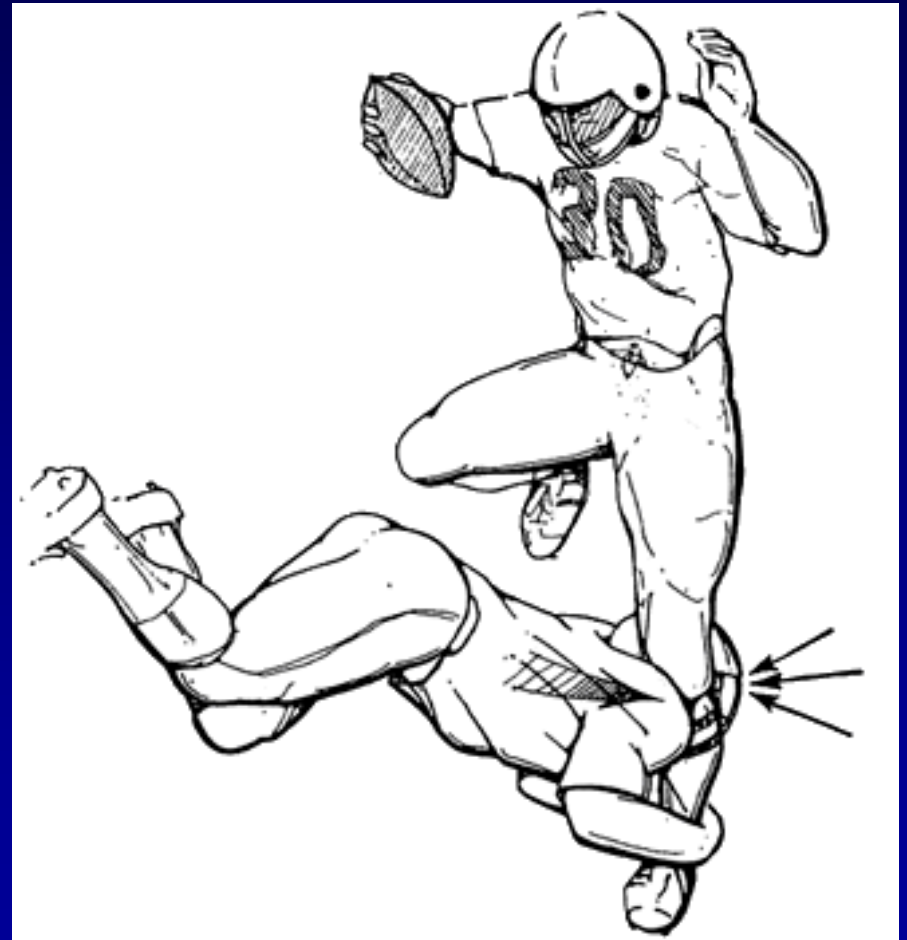
Luxace pately

Transchondrální zlomeniny



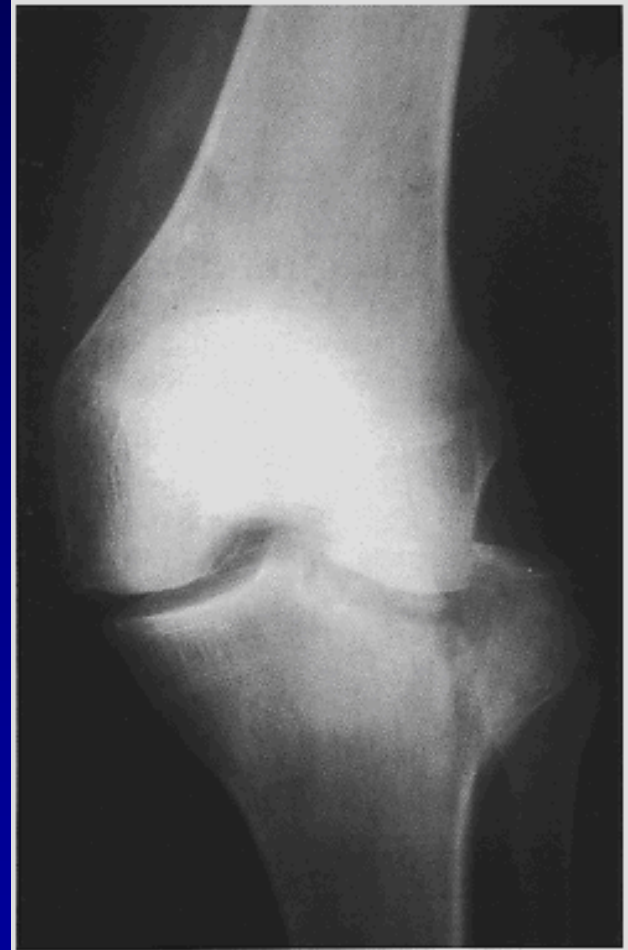Anamnéza

- Kde
- Kdy
- Okolnosti úrazu
- Mechanismus úrazu



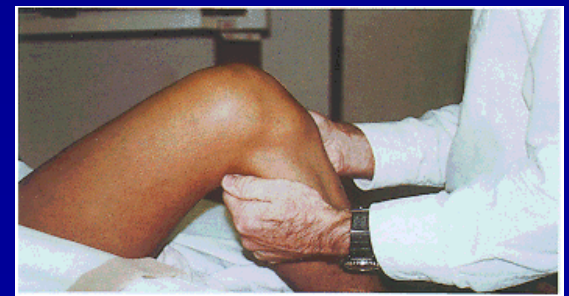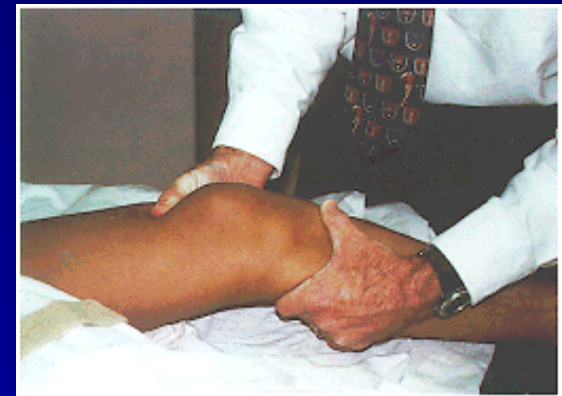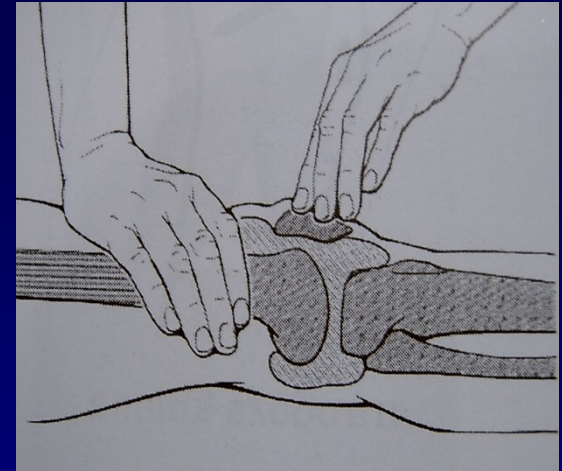
Vyšetření

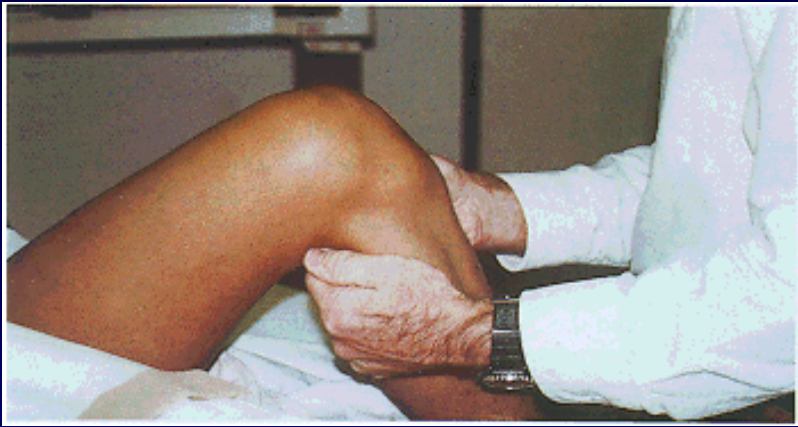- Klinické vyšetření
- Punkce kloubu
- Mastné skvrny v krvi
- RTG
- MRI
- Ultrasonografie



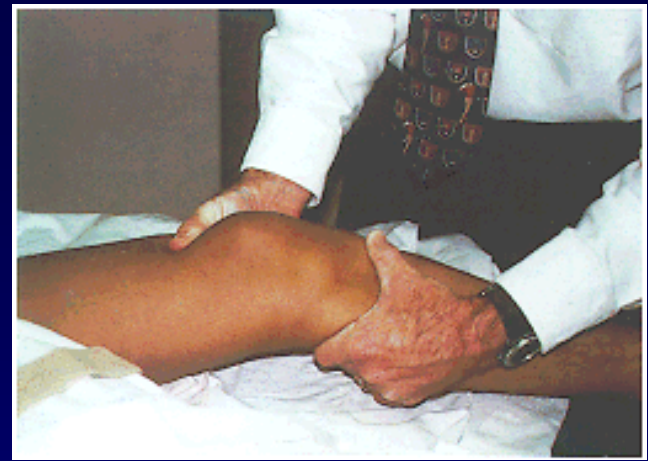Klinické vyšetření

- Otok , hematom
- Výpotek
- Pohyb
- Palpační bolest
- Testy stability
- Manévry
- Vyšetření pately

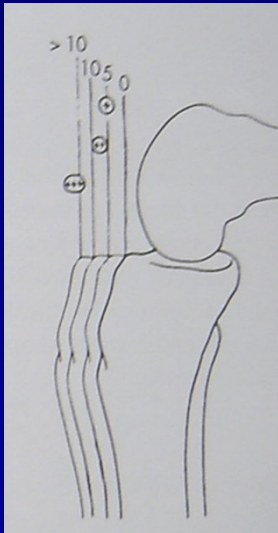




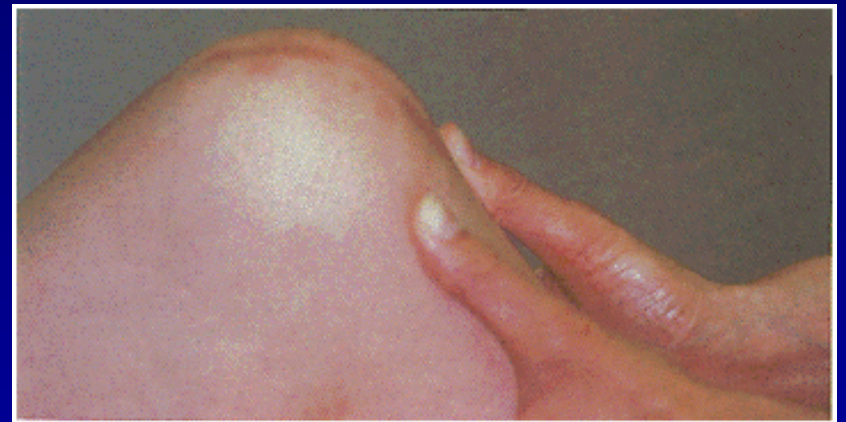Přední zásuvka



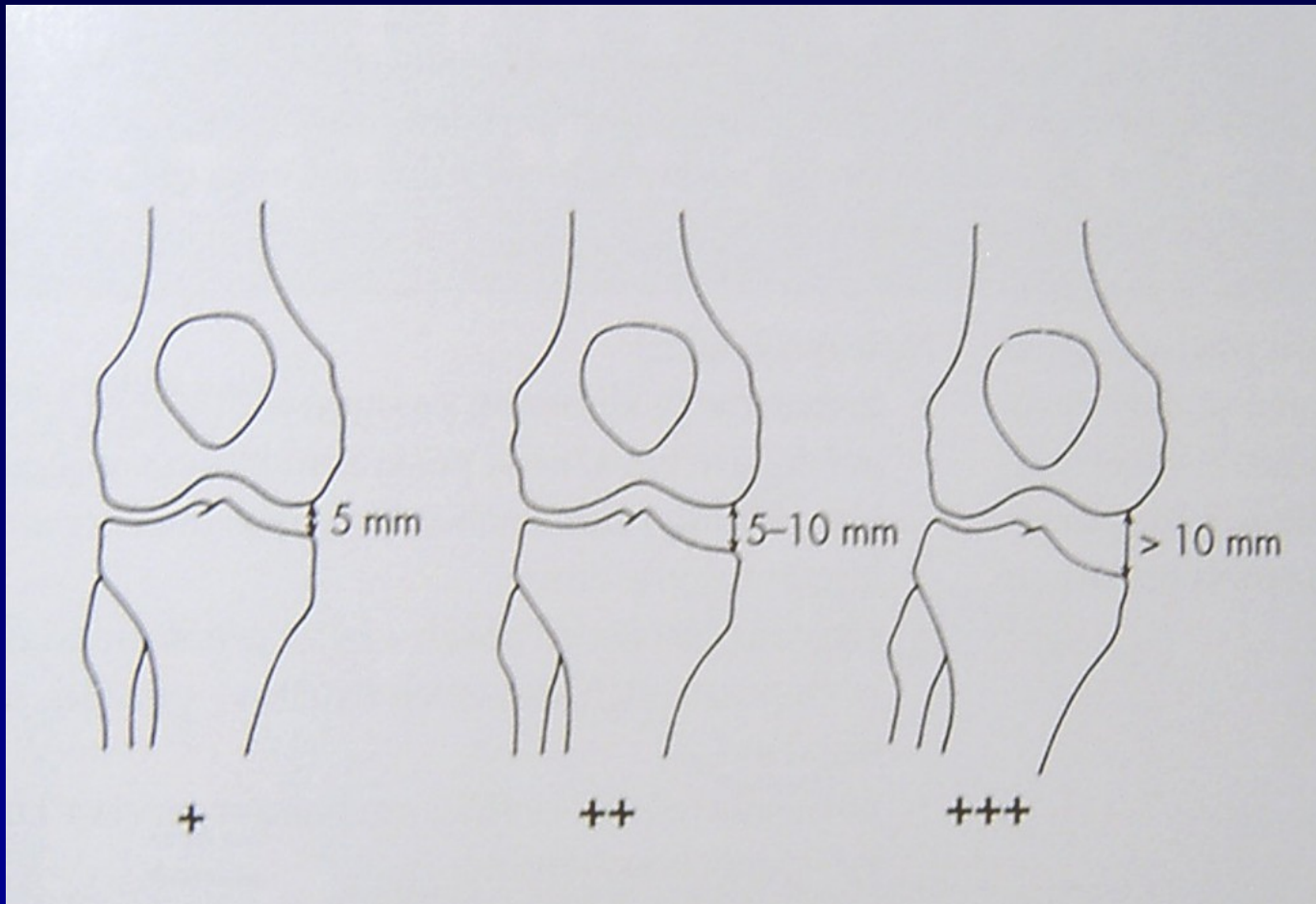
Lachmanův test



Přední zásuvka, pivot shift test



Zadní zásuvka



Valgóní stres test
Varóní stres test

Menisky

Mechanismus úrazu

Testy: Mc Murray

Steinmann I

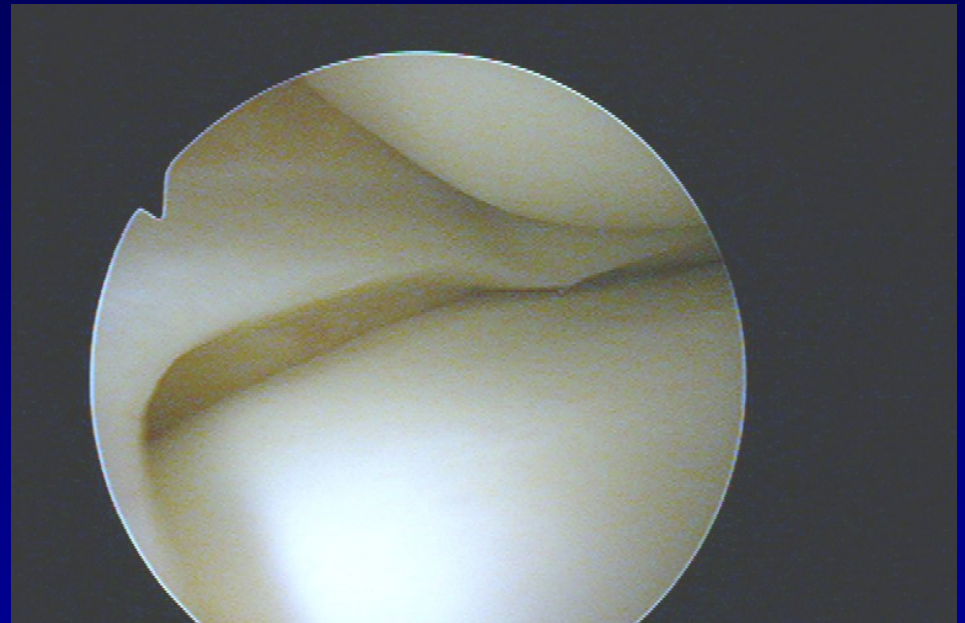
Steinmann II

Appley

Turner

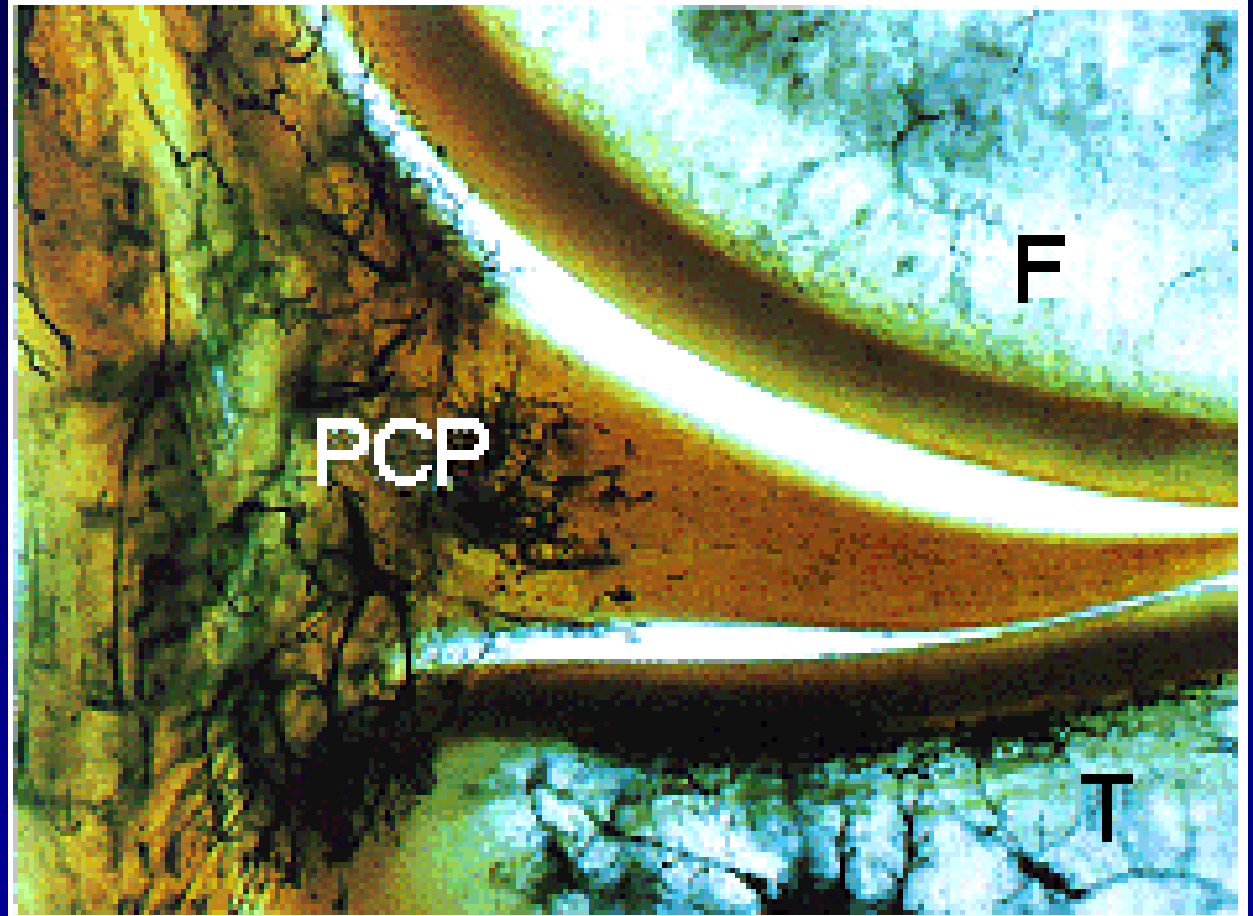
Payer

Childress- squat test



Meniskus

- Fibrocartilago
- Vysoká elasticita
- Parakapsulární zóna- cévy

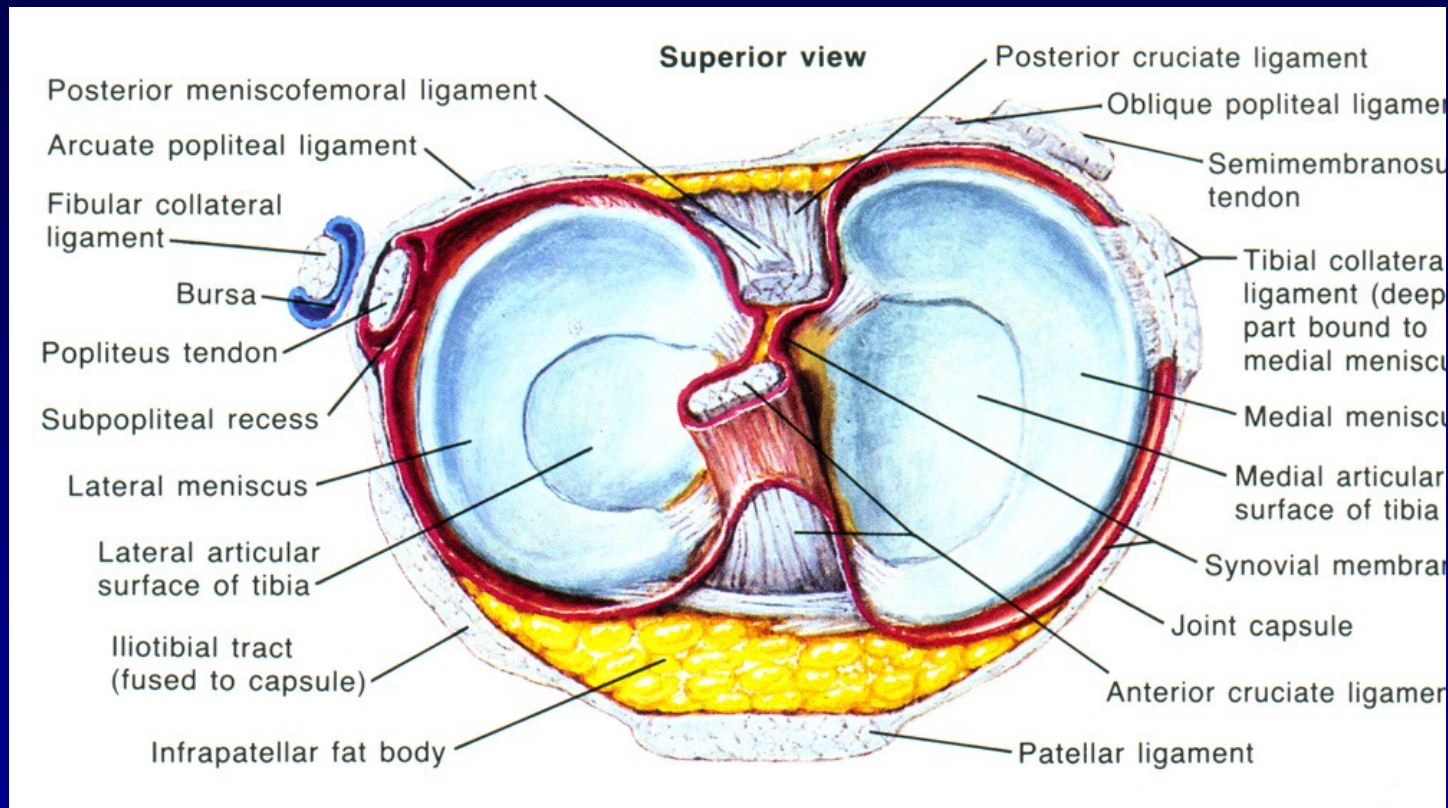


Red zone

red- white zone

white zone



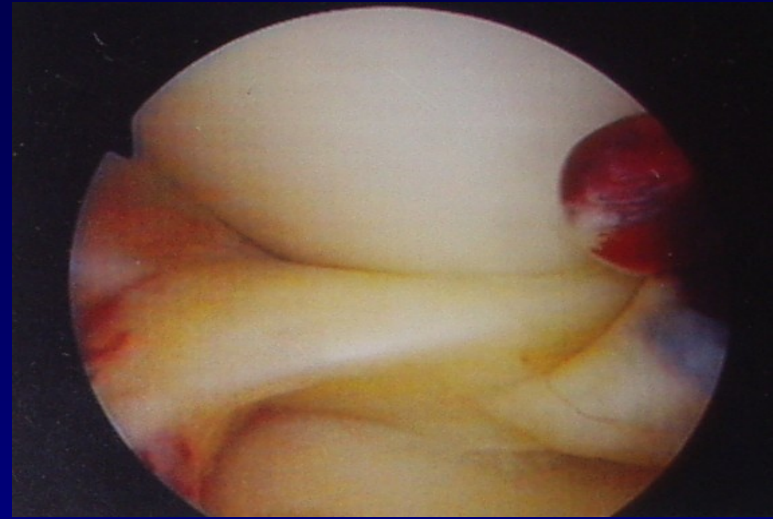
Funkce



- nárazník
- stabilizátor
- vyrovnávač kloubních ploch
- rozdělovač kloubní tekutiny
- LM – mobilnější
- MM - zranitelnější

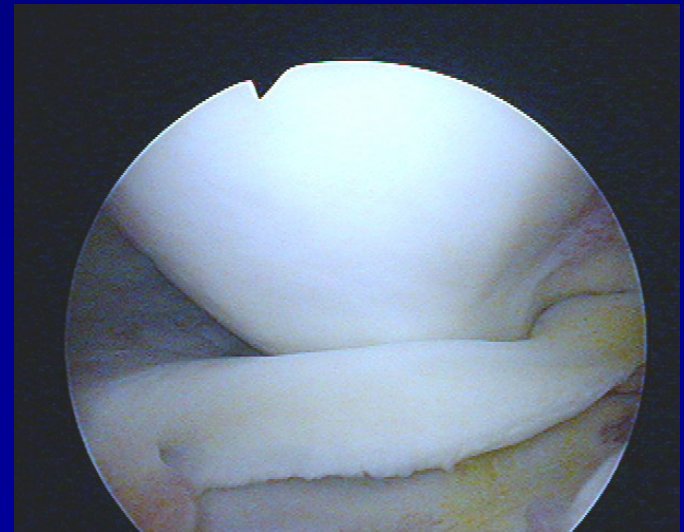
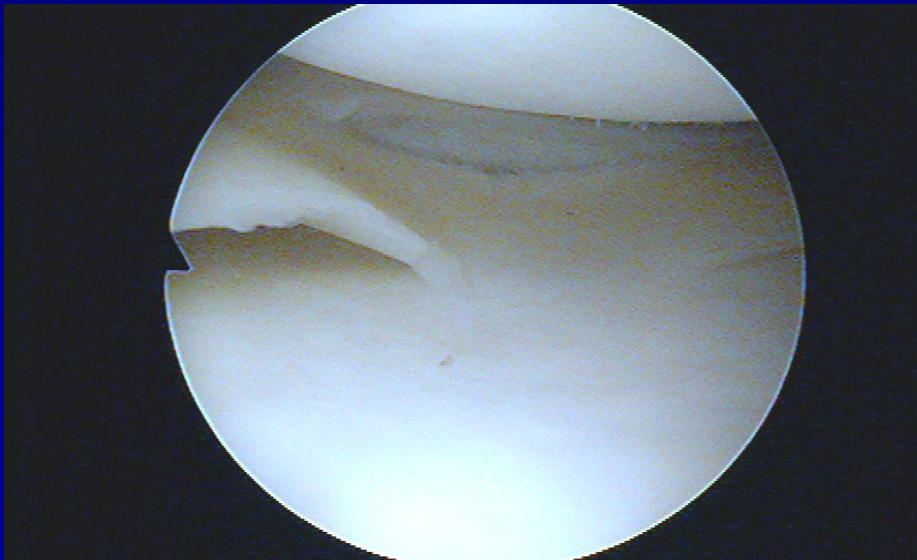
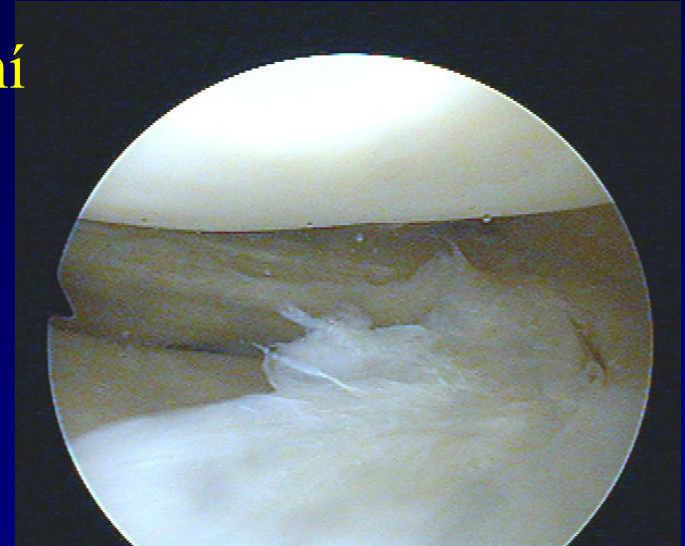
Ruptury menisků

- Longitudinální, horizontální, radiální
- Typ ucho od koše
- Degenerativní léze
- Diskoidní meniskus



Ruptury menisků

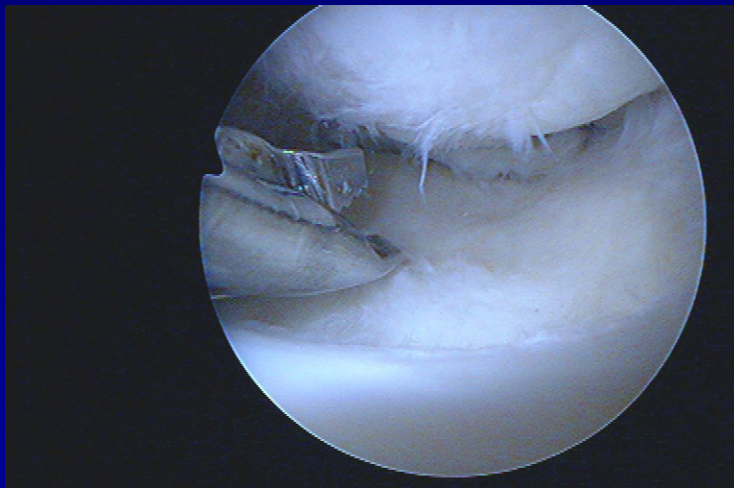
- Longitudinální, horizontální, radiální
- Typ ucho od koše
- Degenerativní léze
- Diskoidní meniskus



Ošetření menisků

Menisektomie

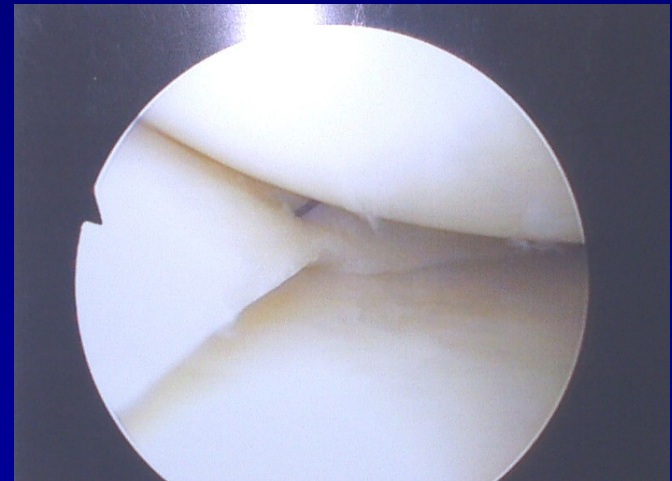
- parciální
- subtotální
- totální



Punch „v akci“

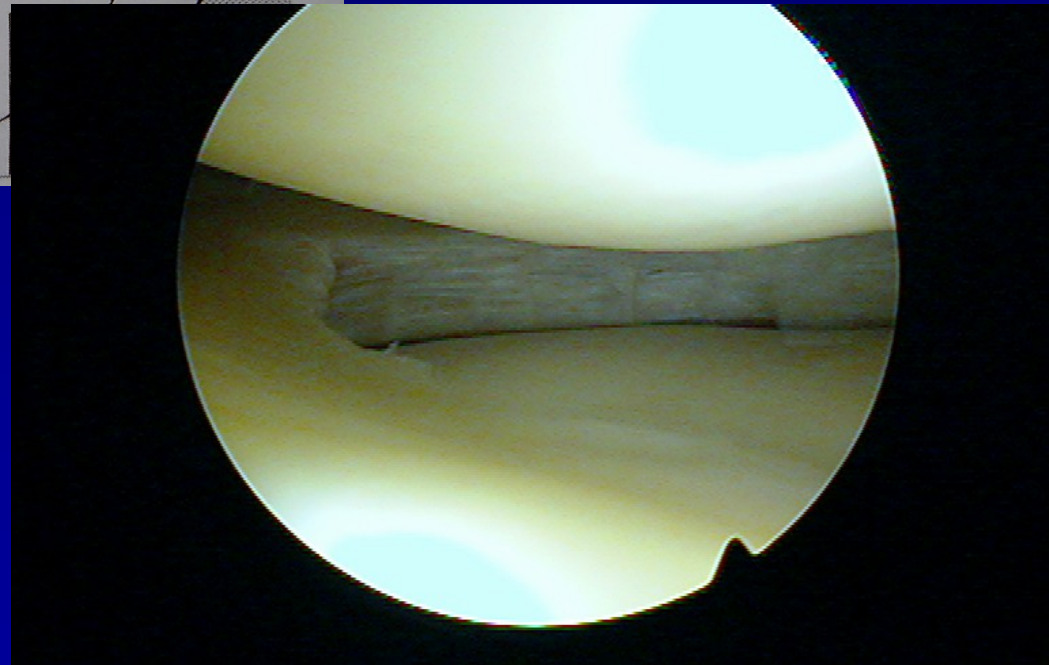
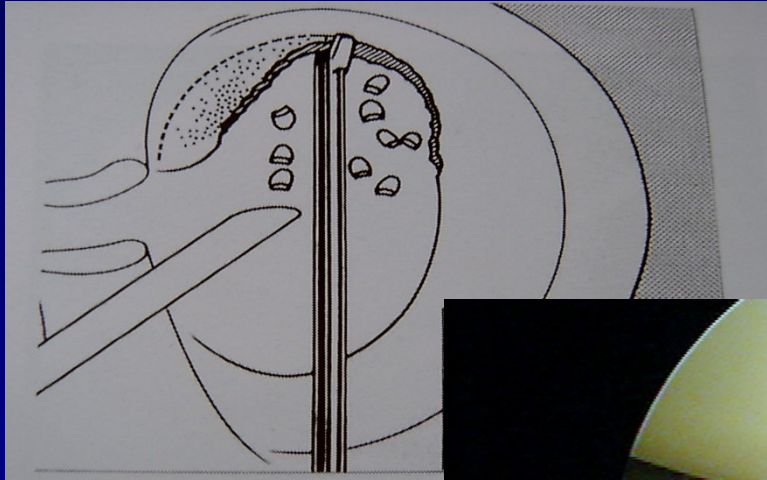
Meniskopexe

- outside-in
- inside-out
- all-inside

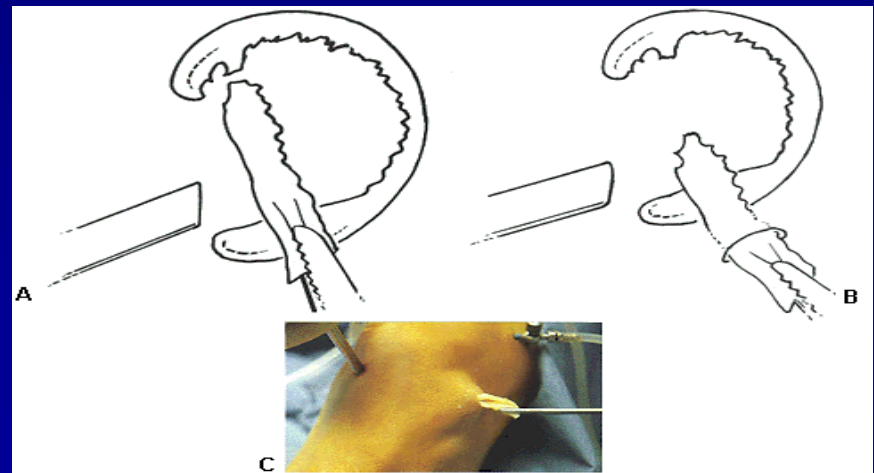
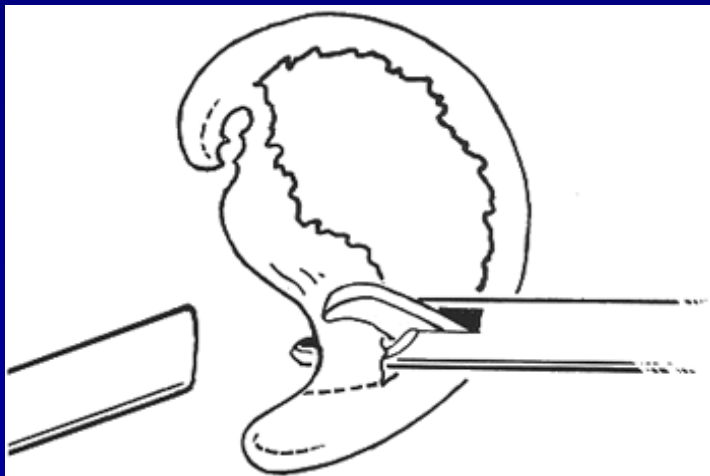
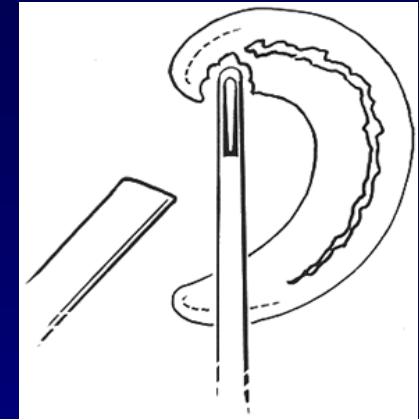
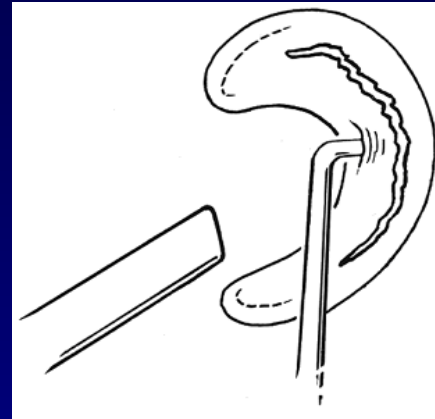
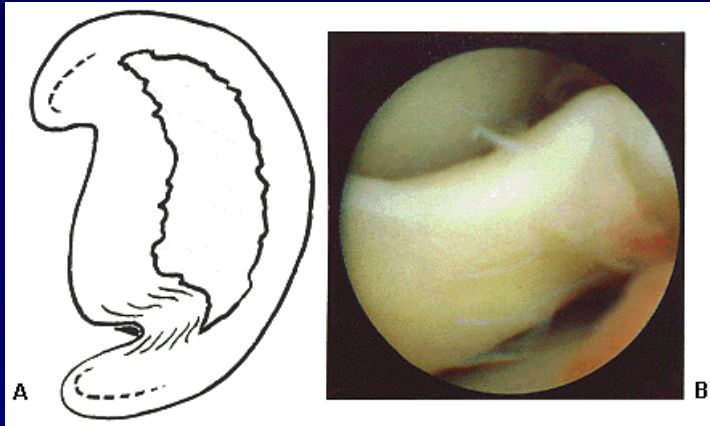


Přišitý meniskus

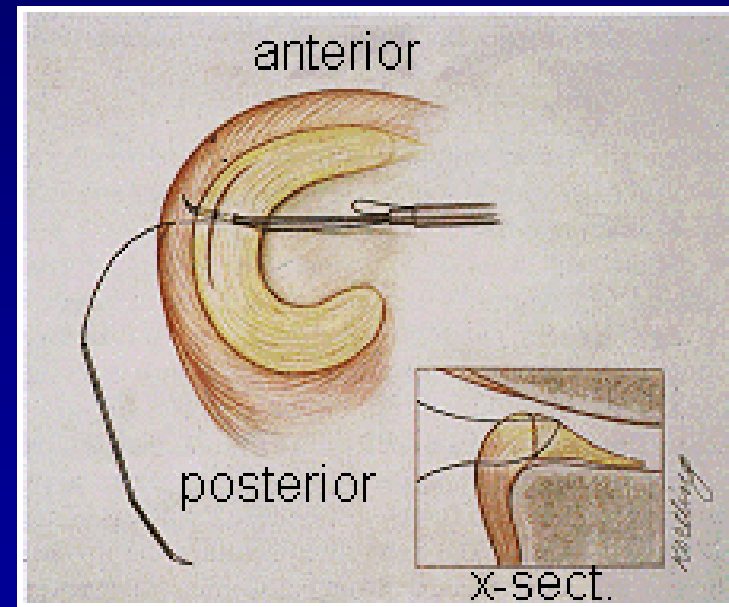
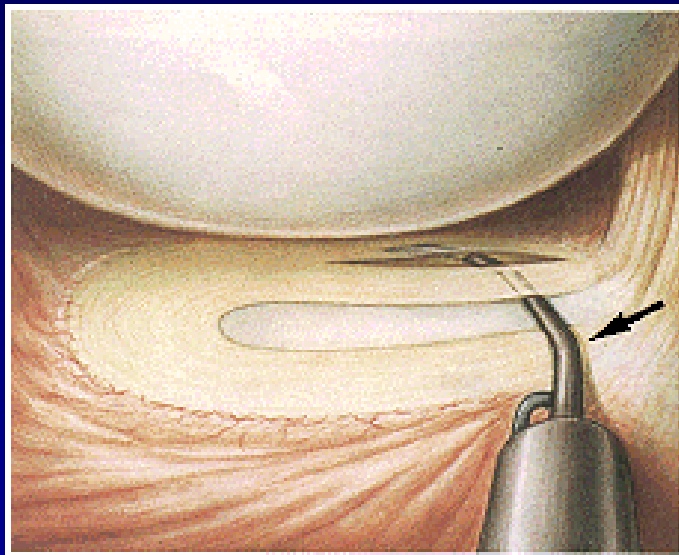
Parciální menisektomie



Subtotální menisektomie



ASK meniskopexe

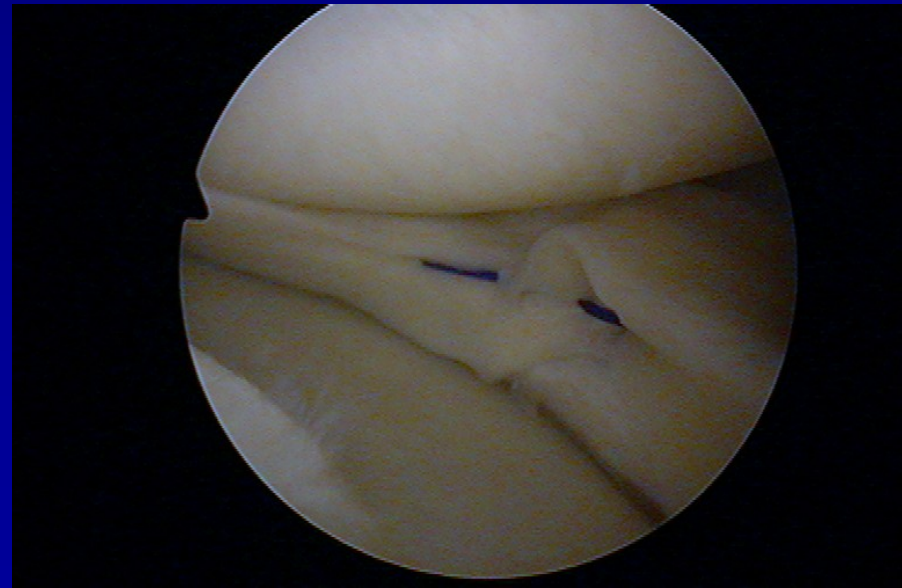
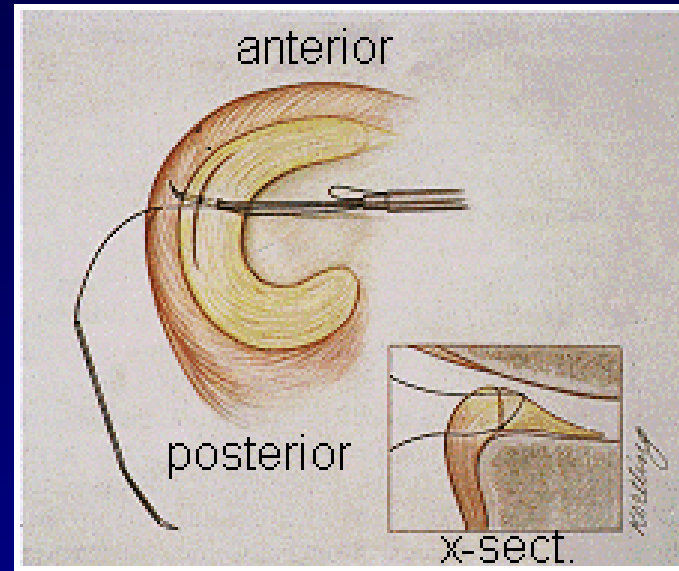


Sutura menisku- meniscopexis

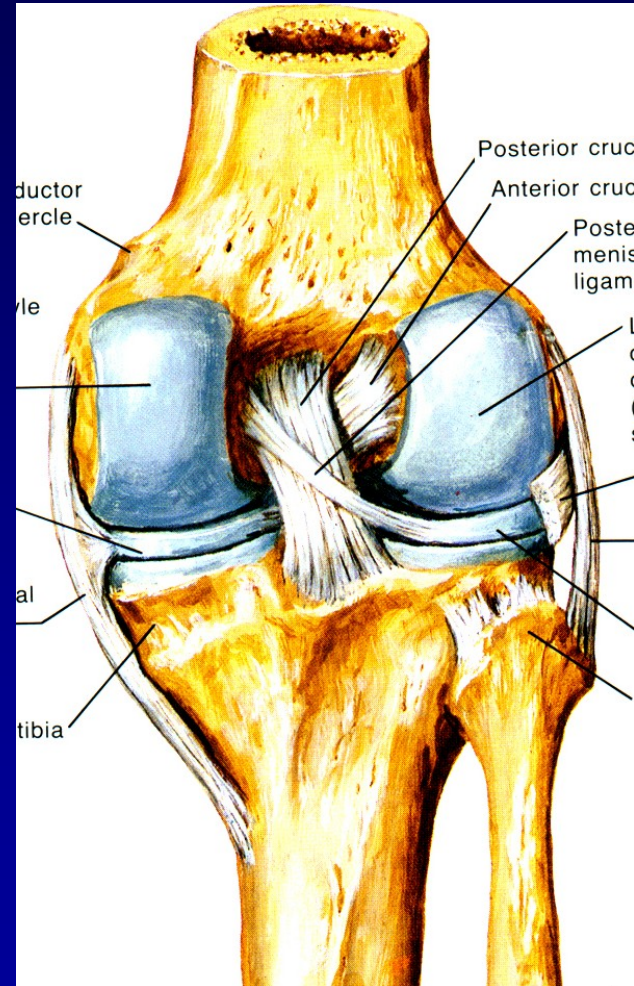
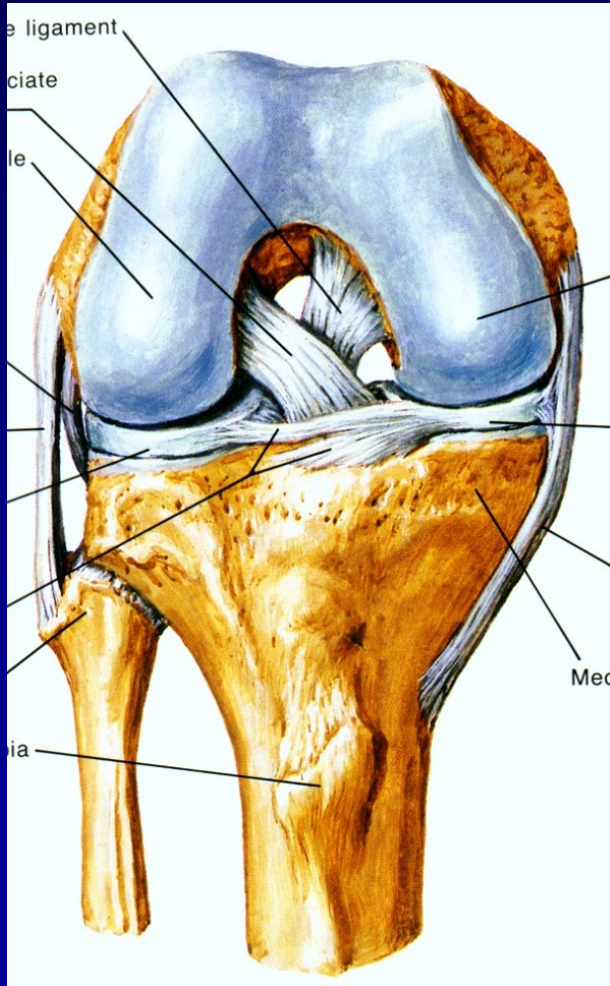
outside-in

inside-out

all-inside

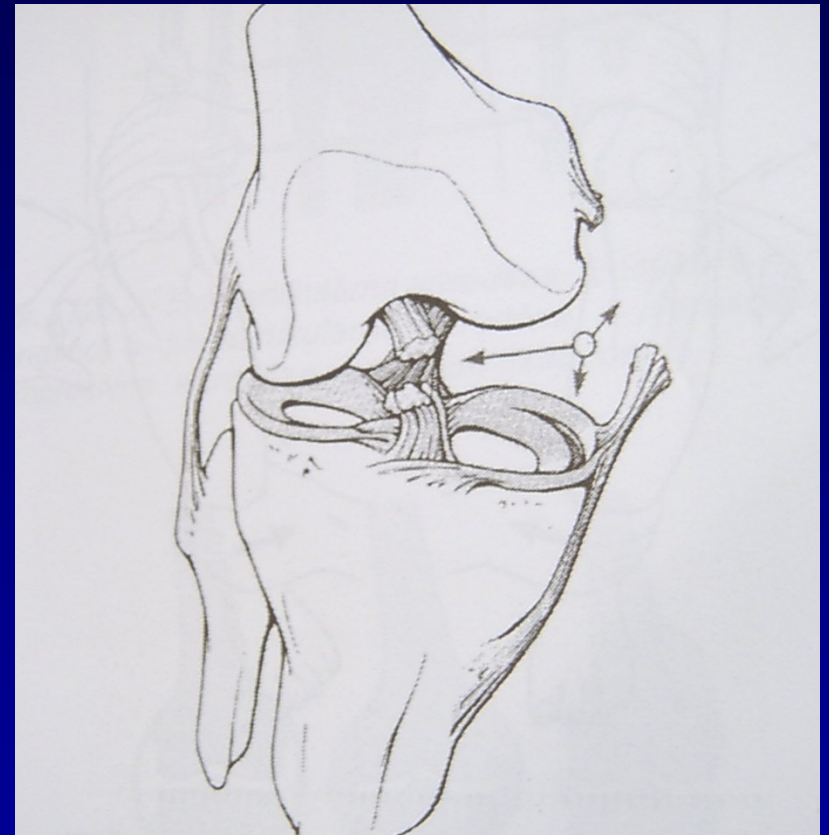

Zkřížené vazy- ACL, PCL



Ruptury vazů

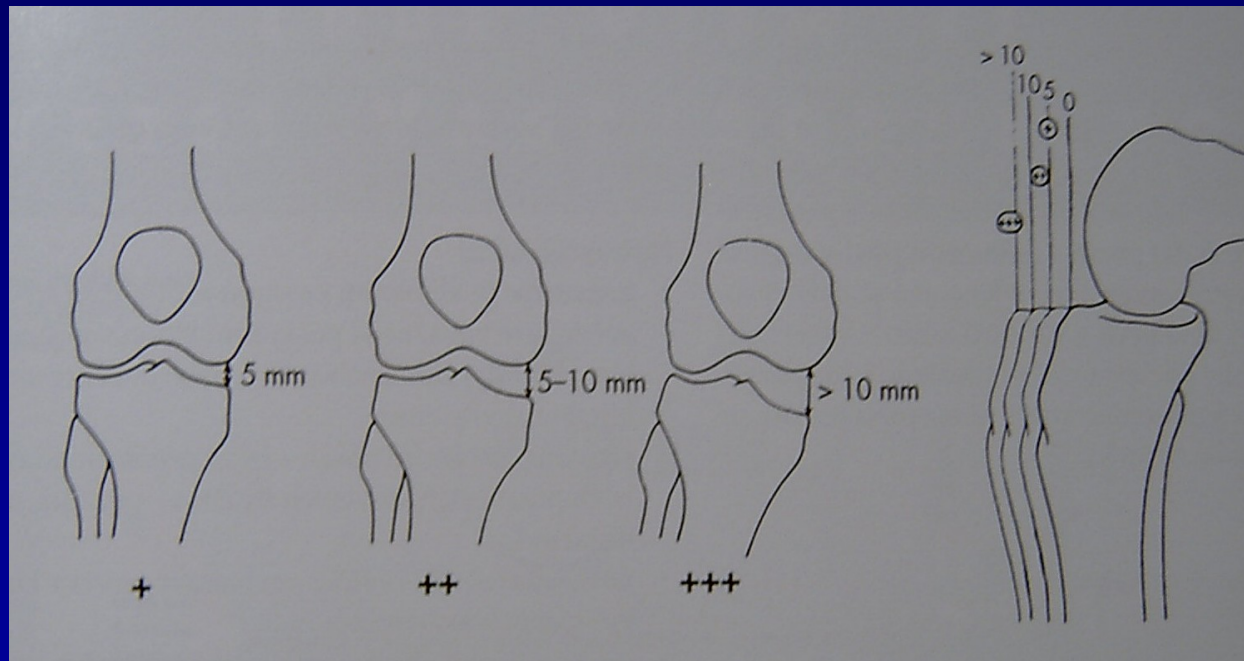
- **Distenze**
- **Parciální ruptura**
- **Totální ruptura**
- Mechanismus poranění
- Testy stability



„Unhappy trias“

Instabilita anteromediální

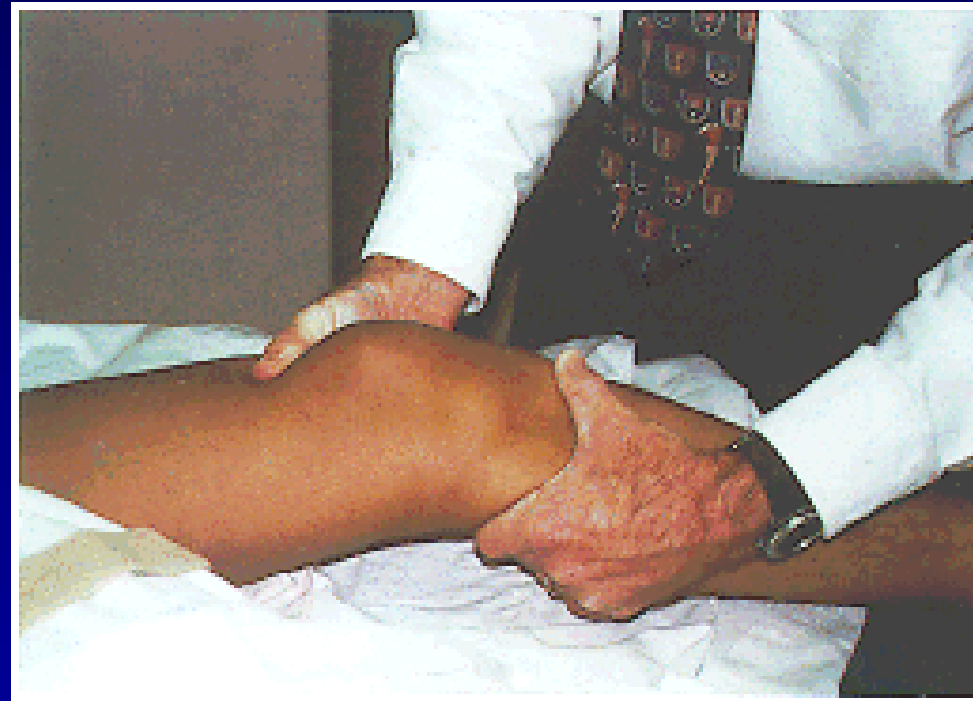
- v praxi nejčastější typ instability kolena
- následek páčení do valgozity – unhappy trias



valgus stress test + přední zásuvka

Ruptura ACL

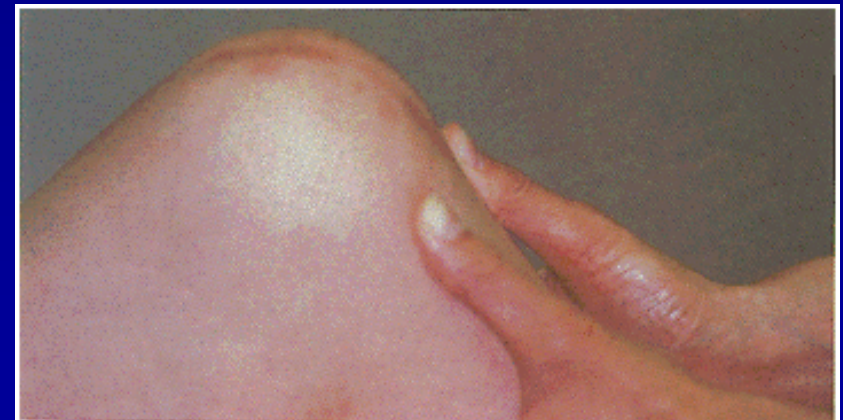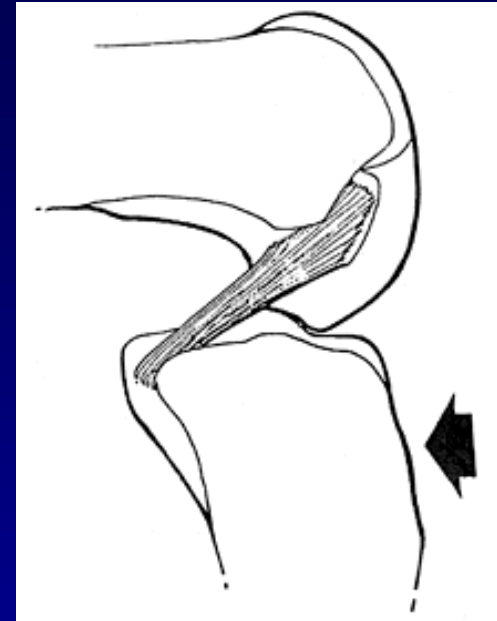
- Testy stability
- Lachmanův test
- Přední zásuvka
- Pivot-shift test



Lachman test

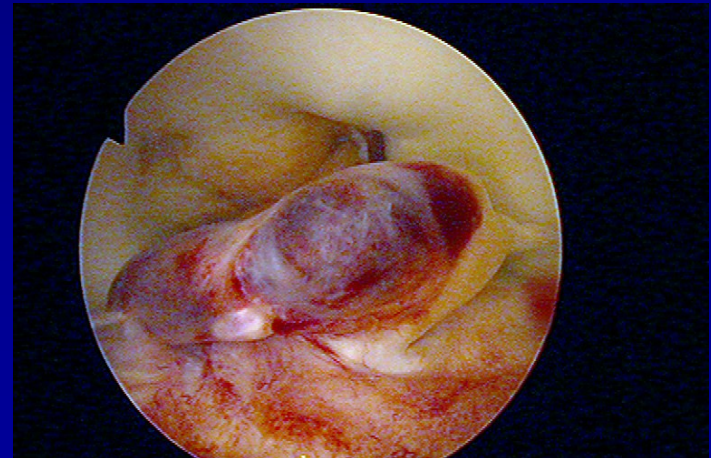
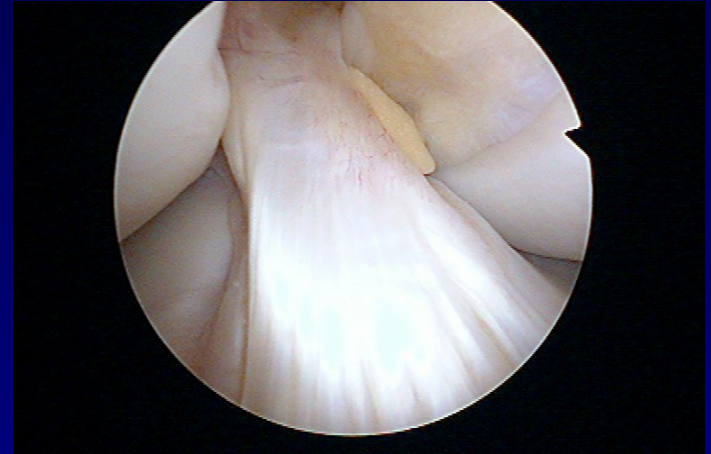Rupture PCL

- Náraz na palubní desku
- Zadní zásuvka



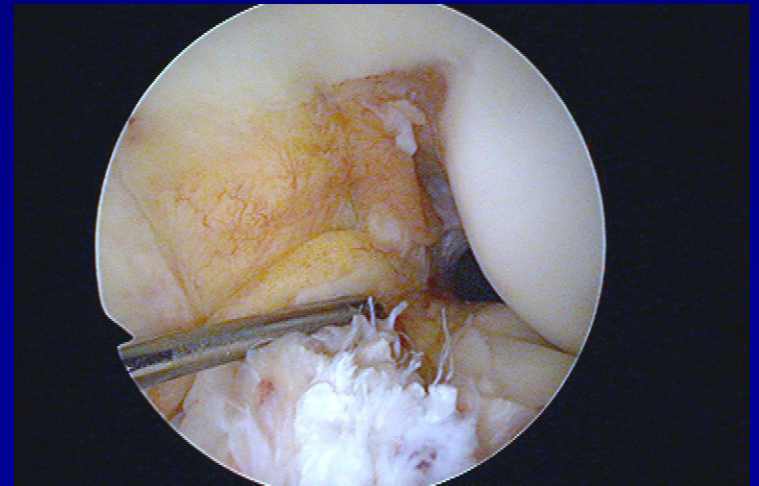
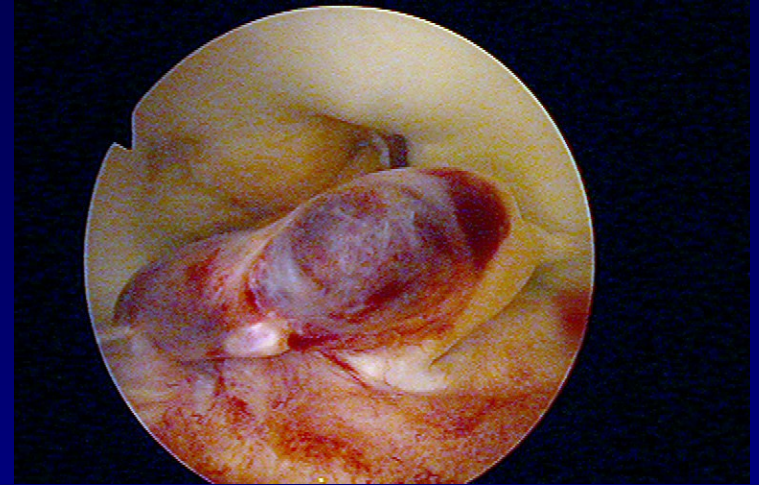
Rupture ACL

- Časté poranění



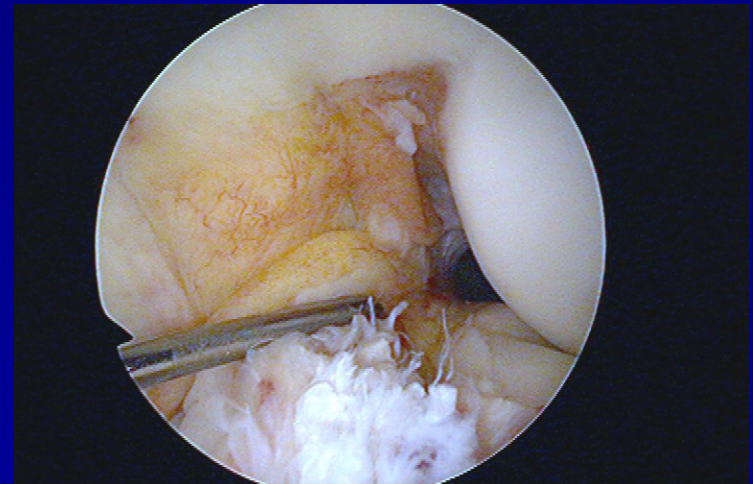
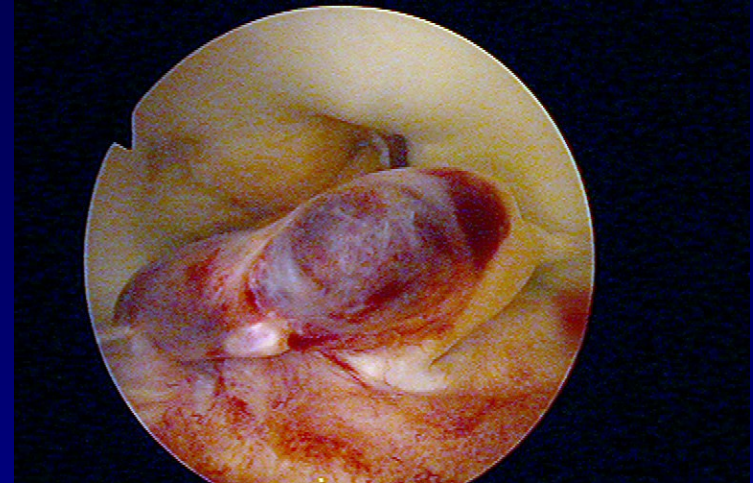
Akutní ruptura ACL

- Debridement
- Fyzioterapie
- Omezená aktivita
- Ortéza



Akutní ruptura PZV

- **Artroskopie**
 - debridement PZV
 - ošetření přidružených poranění (menisků, chrupavek)
- **Pooperační režim**
 - RHB program - hamstringy
 - propriocepce
- **Modifikace sport. aktivit**
 - omezení rizikových sportů
 - ortéza



Rehabilitace

- dynamická stabilita kolene s poškozeným PZV
- reedukace reflexních mechanismů

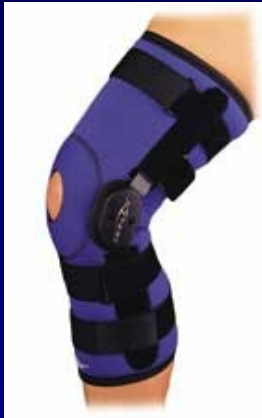↓ absolutní síla hamstringů

↑ propriocepce



RHB → closed kinetic-chains cviky

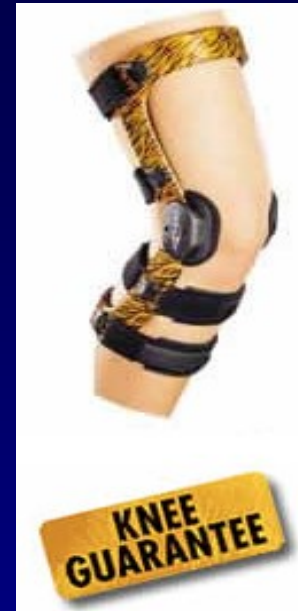Kolenní ortézy



postranní výztuhy



skořepinové

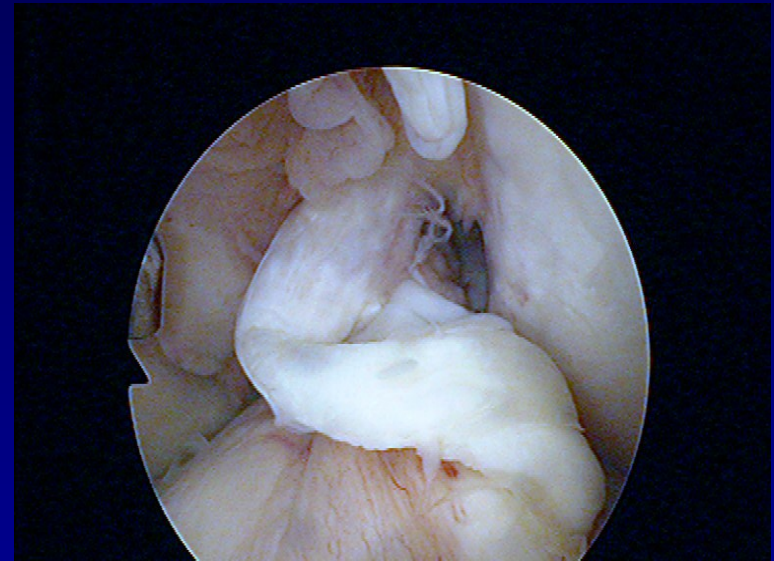


individuální

- proprioceptivní mechanismy
- psychologický efekt

Indikace k rekonstrukci

- 1/3 kompenzovaná i na sport
- 1/3 kompenzovaná jen po modifikaci sport. aktivit
- 1/3 nutnost rekonstrukce PZV
 - klinicky významná nestabilita



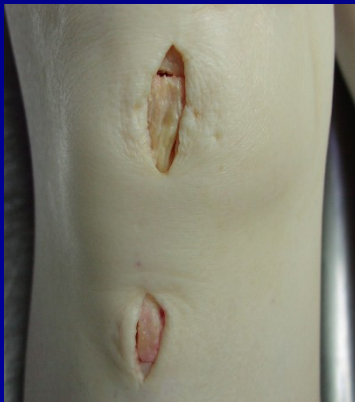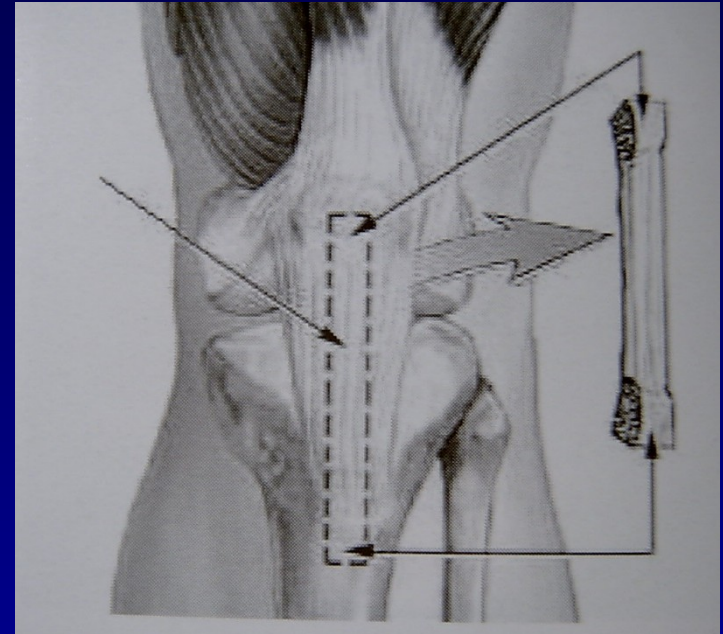
⇒ **individuální přístup k pacientovi**

Typy štěpů a fixace

- štěp z kadaveru
- autoštěp – vlastní tkáň
- štěp z lig. patelae /**BTB**/
- šlachy **hamstringů**
- fixace titanovými nebo vstřebatelnými materiály
- press-fit fixace

BTB štěp = zlatý standard

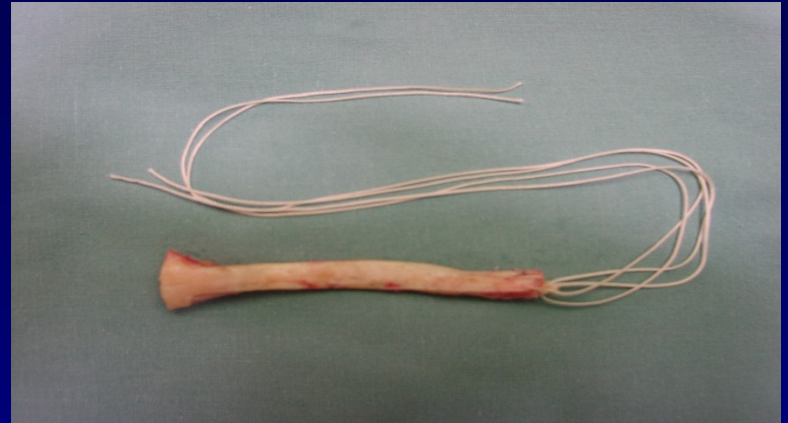
- **Bone-Tendon-Bone**
- autoštěp ze střední třetiny ligamentum patellae
- vhojení kostních bločků
- potíže z odběrového místa



- **miniincize** - šetří r. infrapatellaris n. sapheni

BTB štěp pro **press-fit** fixaci

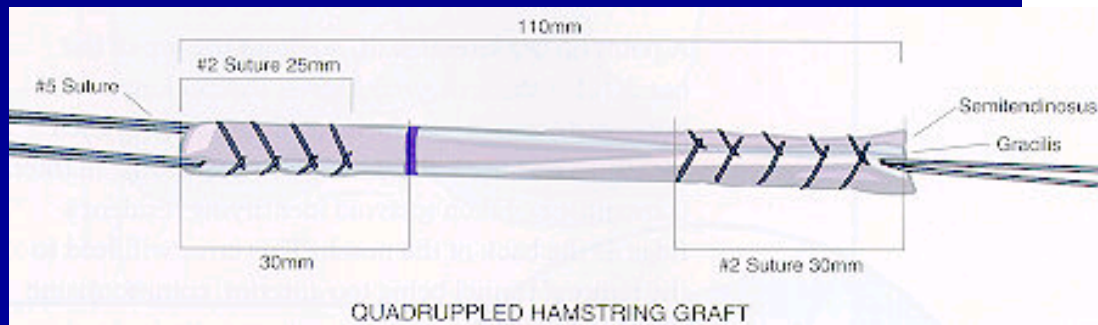
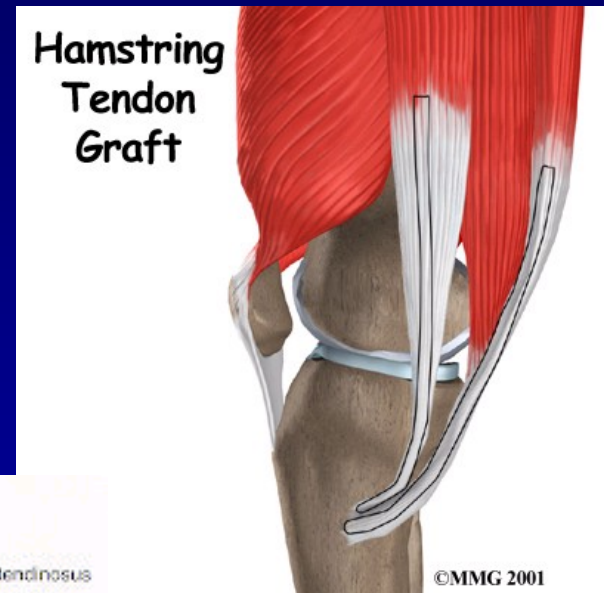
- proximální konec na řezu
lichoběžníkovitý tvar
- **press-fit** fixace v
zuzujícím se femorálním
kanálu



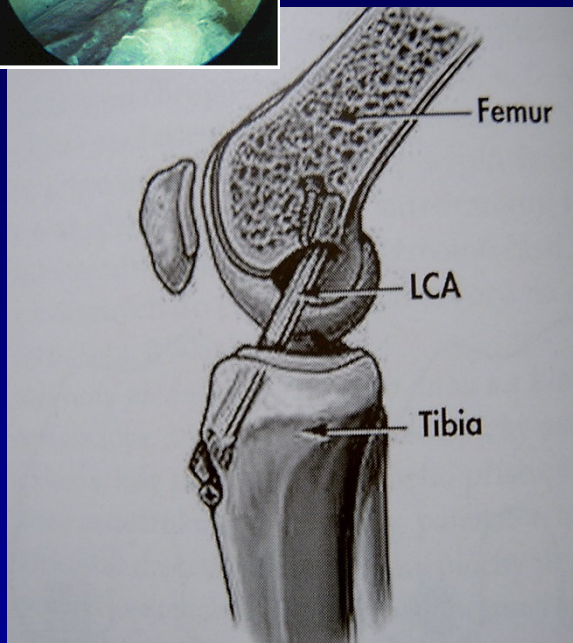
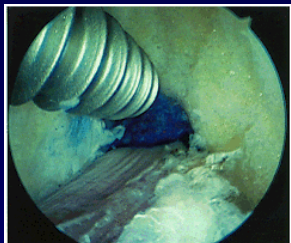
Hamstringy

(m. semitendinosus + m. gracilis)

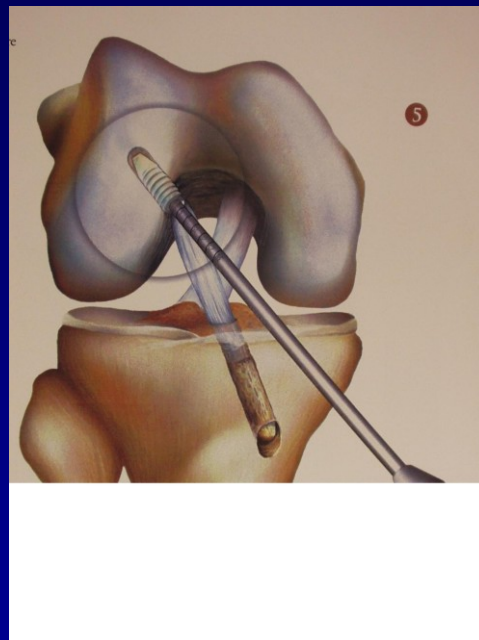
- nejsou potíže z odběrového místa
- oslabení flexorů
- častější selhání
 - B-T-B **1,9 %**
 - hamstringy **4,9%**



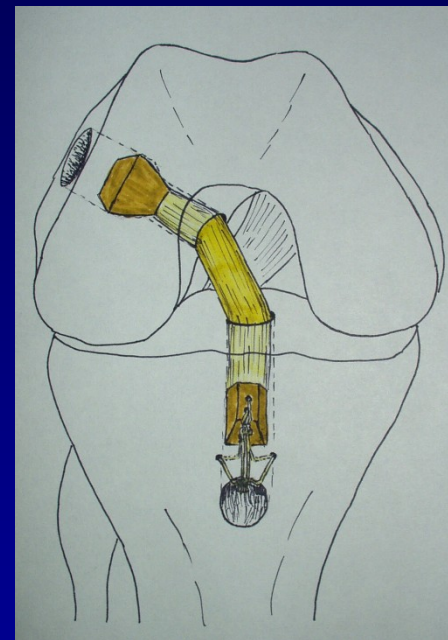
Fixace štěpu



interferenční šroubky



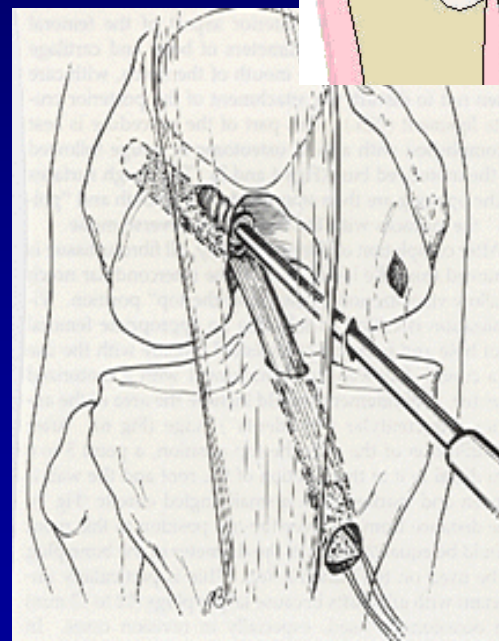
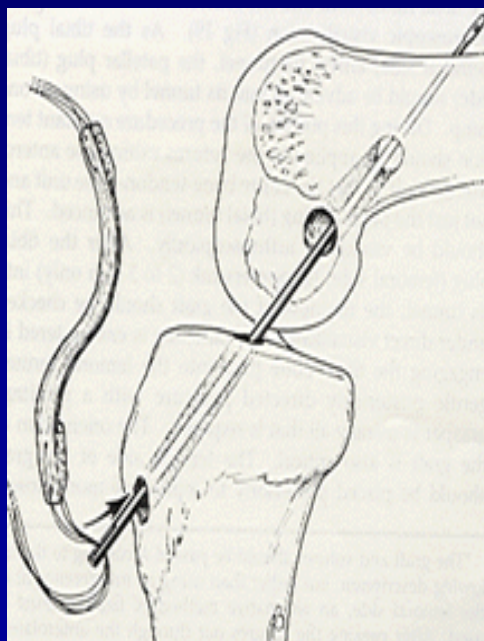
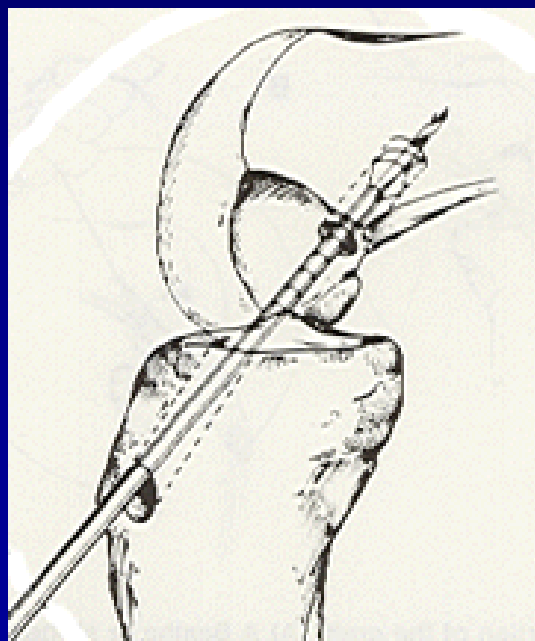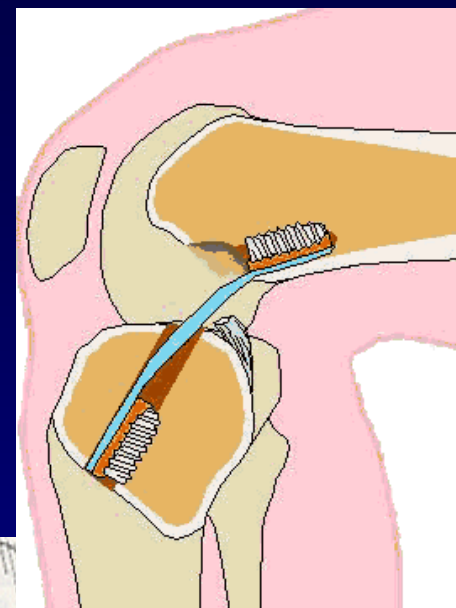
vstřebatelné klínky



press-fit

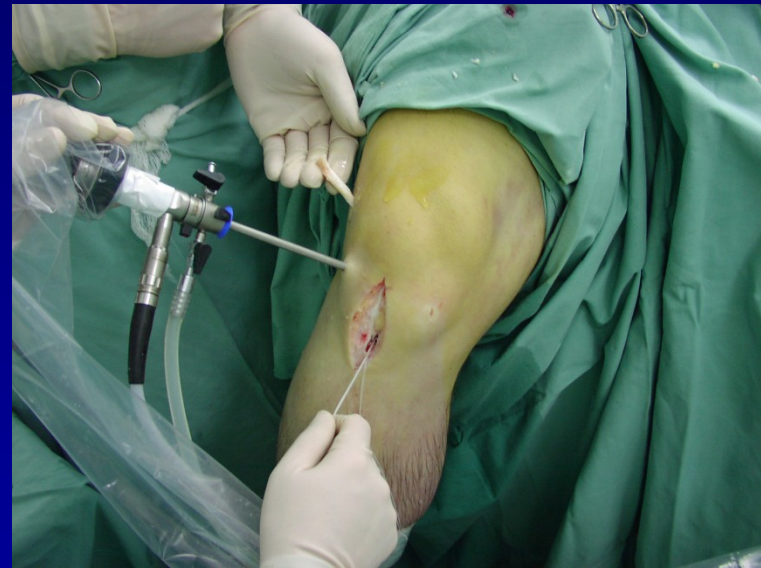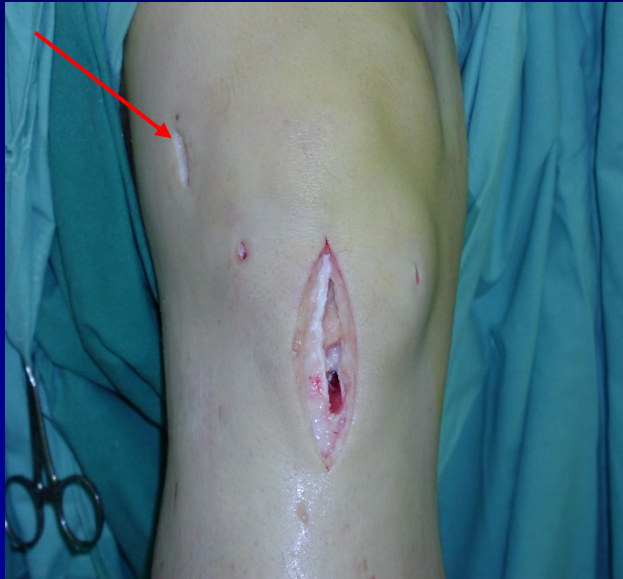Techniky operace

- **transtibiální techniky** - štěp se protahuje přes T kanál do F kanálu

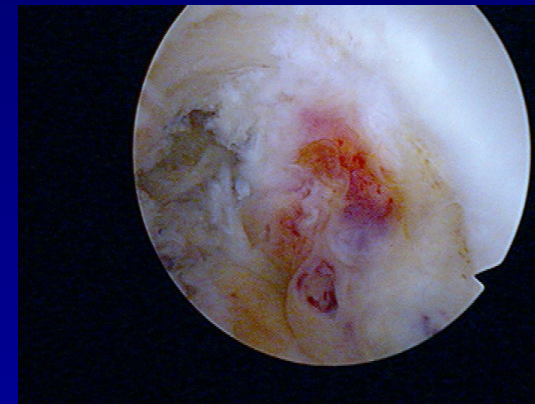
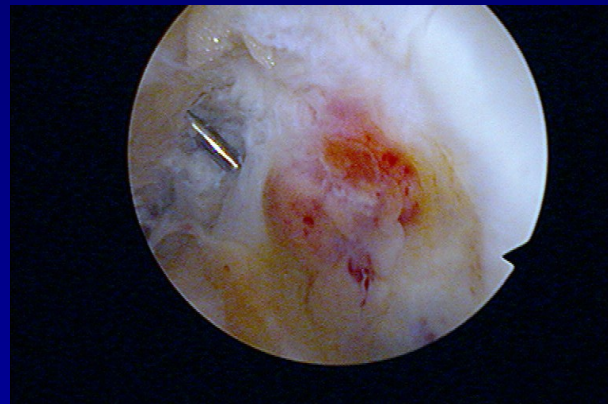
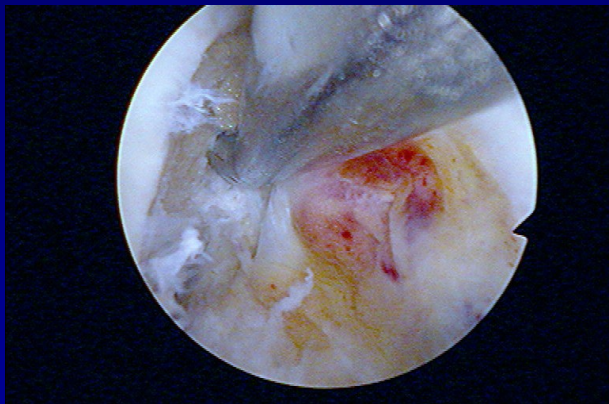
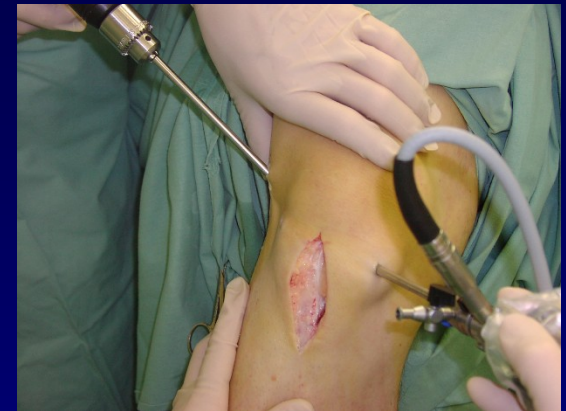
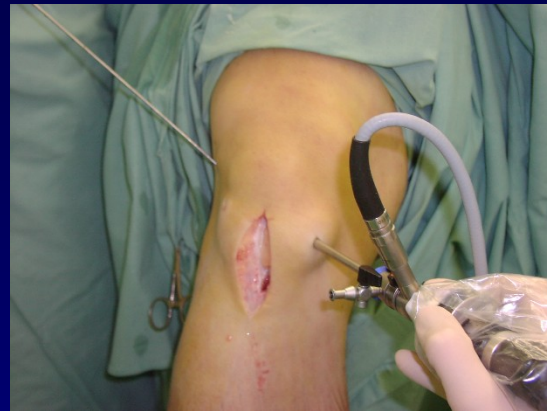
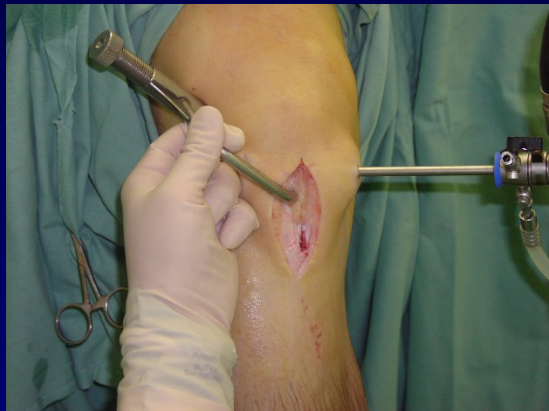Techniky operace

- s pomocnou laterální miniincizí - štěp se protahuje přes F kanál do T kanálu

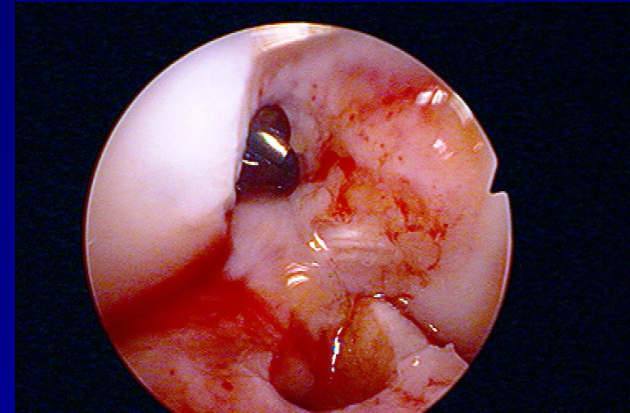
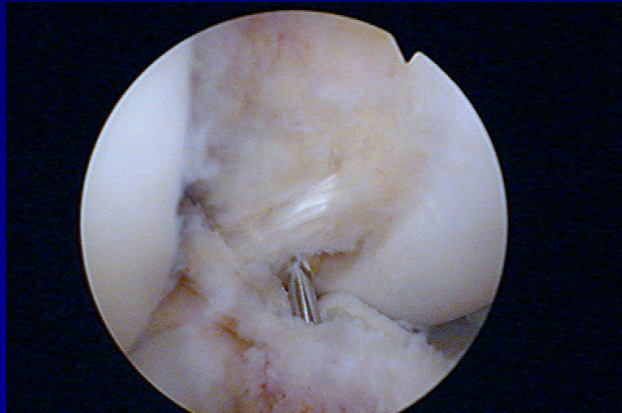
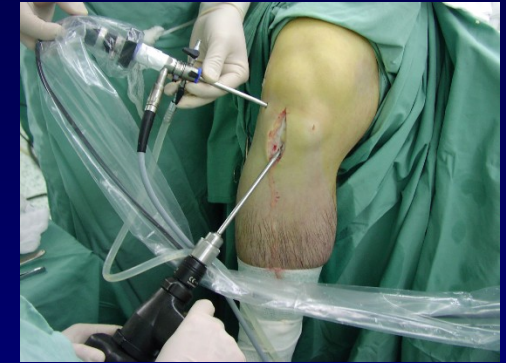
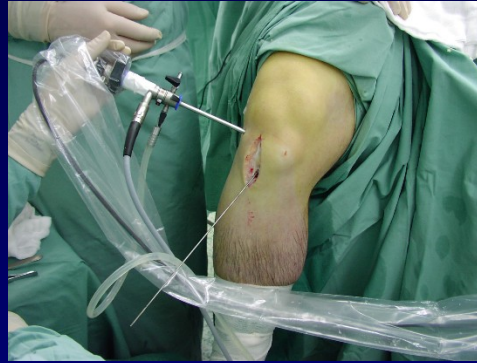
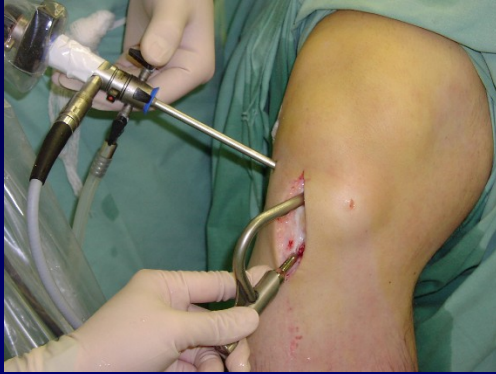Femorální kanál



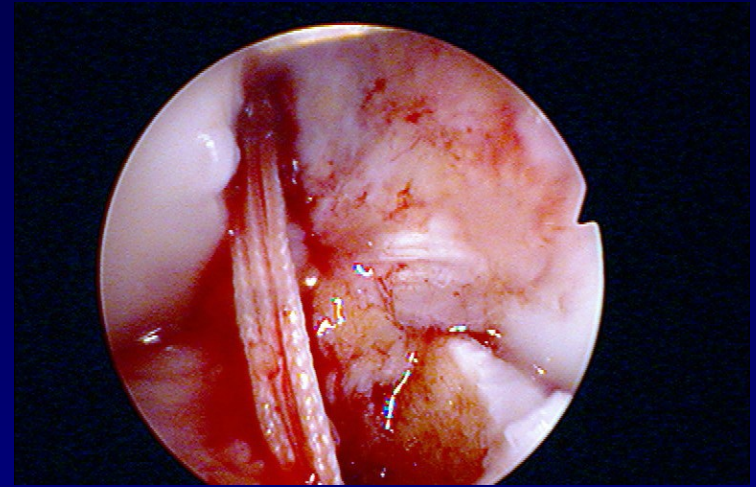
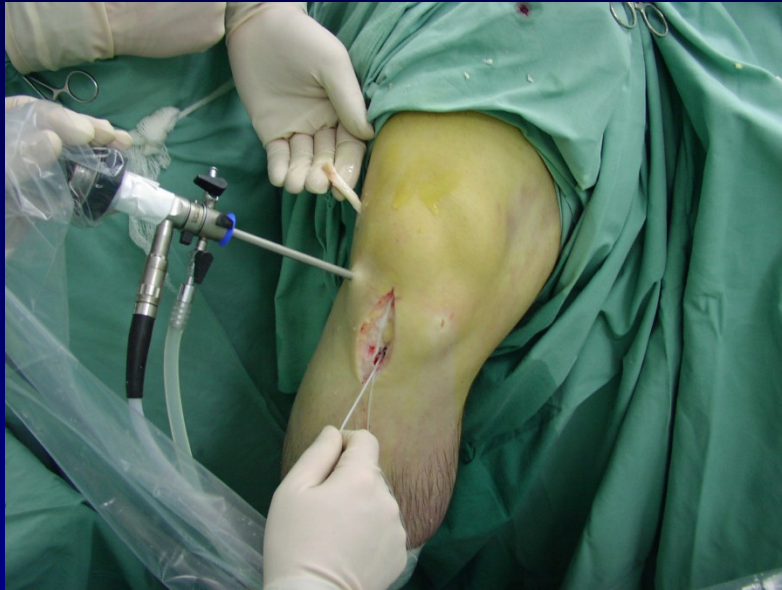femorální cílič + vrtání femorálního kanálu pod
ASK kontrolou

Tibiální kanál

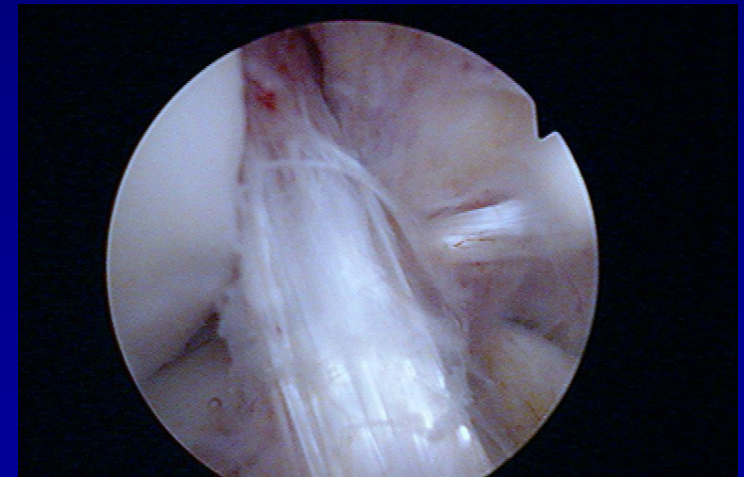


tibiální cílič + vrtání tibiálního kanálu pod ASK
kontrolou

Protažení štěpu



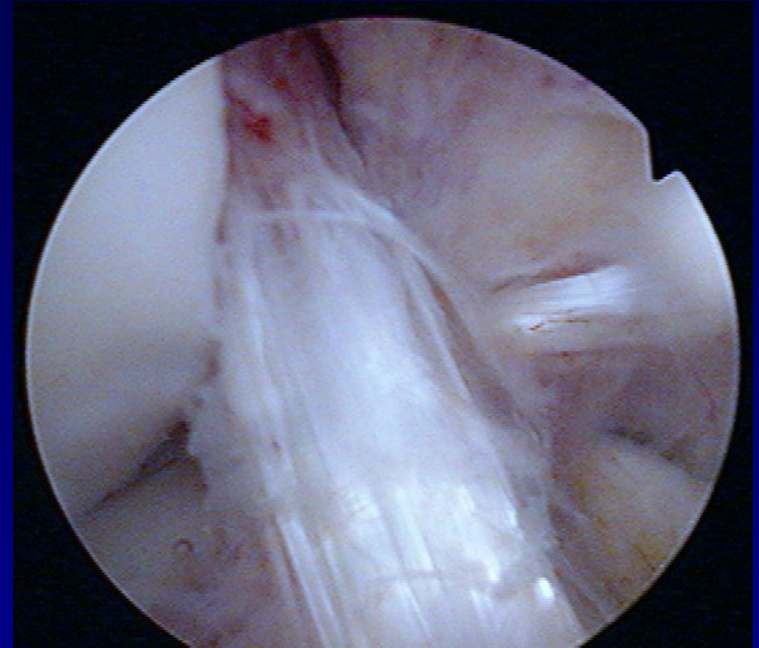
- protažení vláken nejprve přes femorální kanál a poté přes tibiální kanál



- protažení štěpu tahem za vlákna pod ASK kontrolou

REHABILITACE

- pooperační **RHB protokol**
 - ortéza 0-30 st.
 - pohyb ihned po operaci
 - polohování do plné extenze
 - 6 týdnů dlouhá ortéza s kloubem
 - revaskularizace štěpu = přestavba
 - **rizikové sporty až za 8 - 10 měsíců**



Rekonstrukce PZV ve II. době

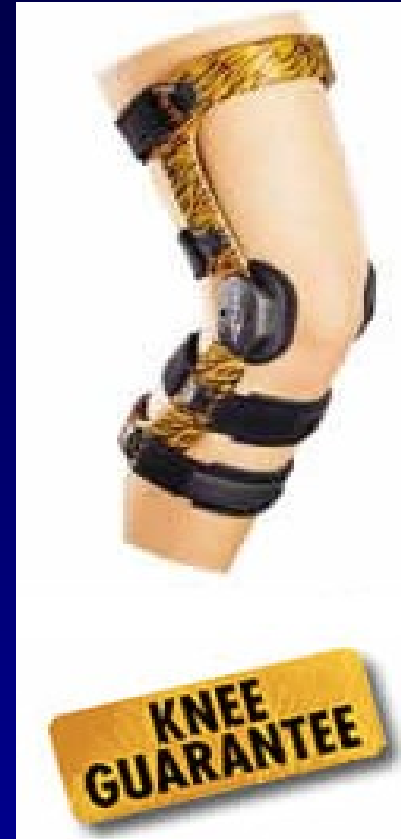- selhání konzervativního postupu

výhody:

- motivovaný, spolupracující pacient, který má realistické představy o operaci, čas na RHB
- koleno s plným pohybem bez hypotrofie stehenního svalstva = **předoperační RHB**



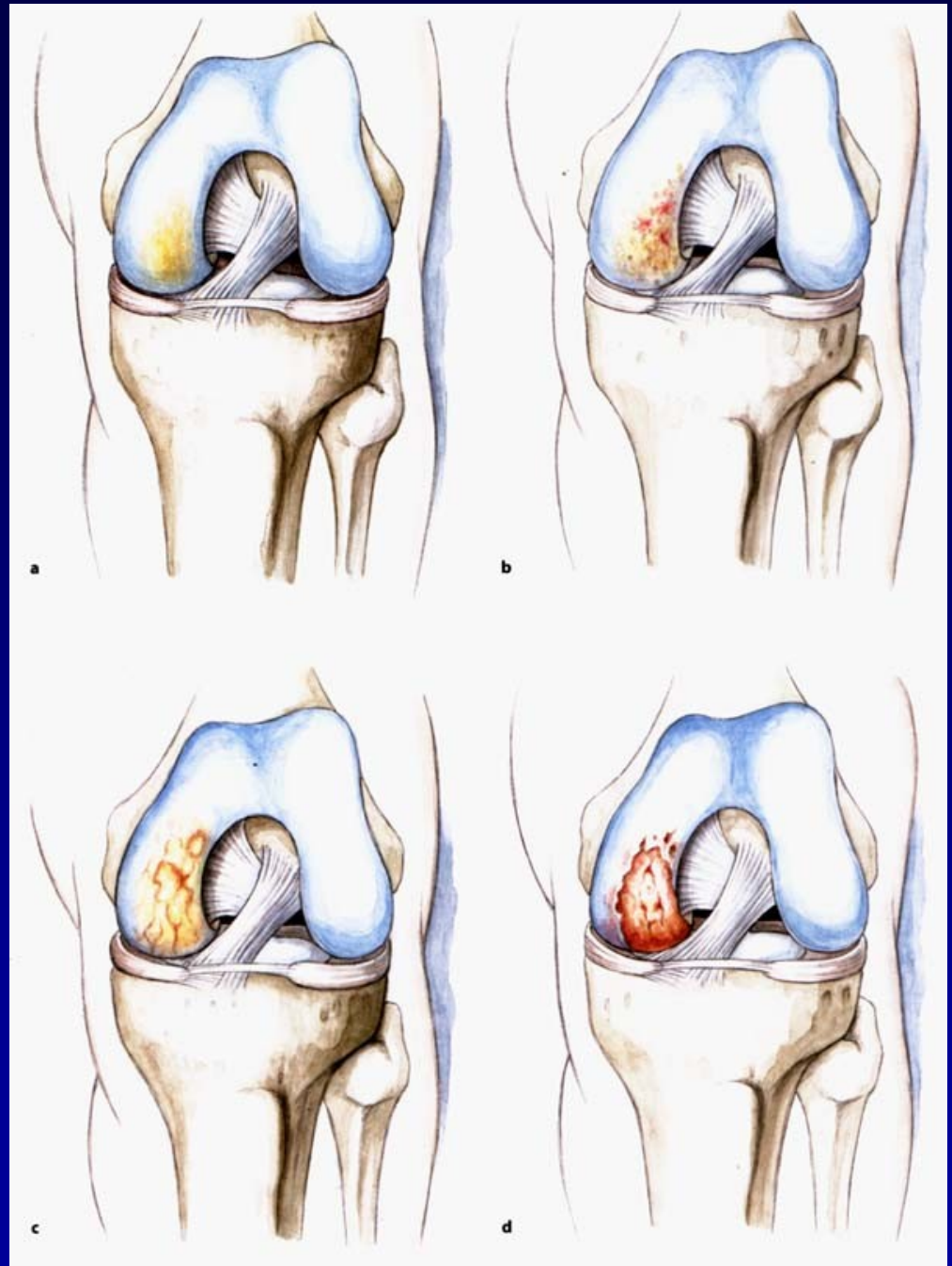
Fyzioterapie



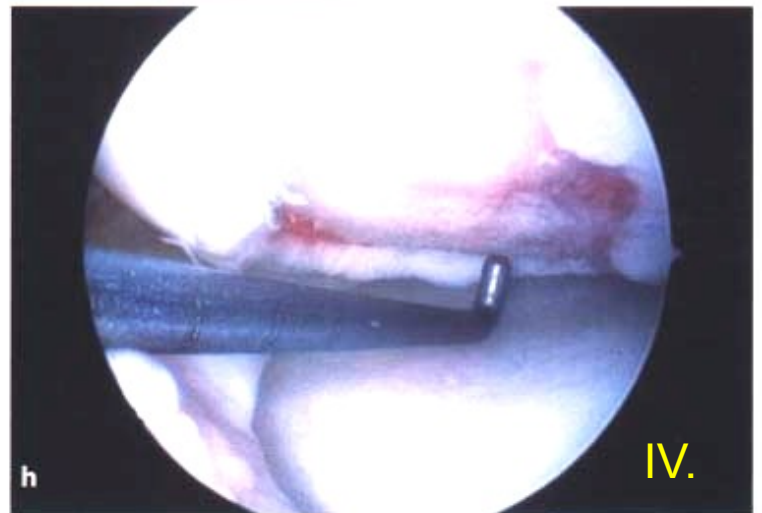
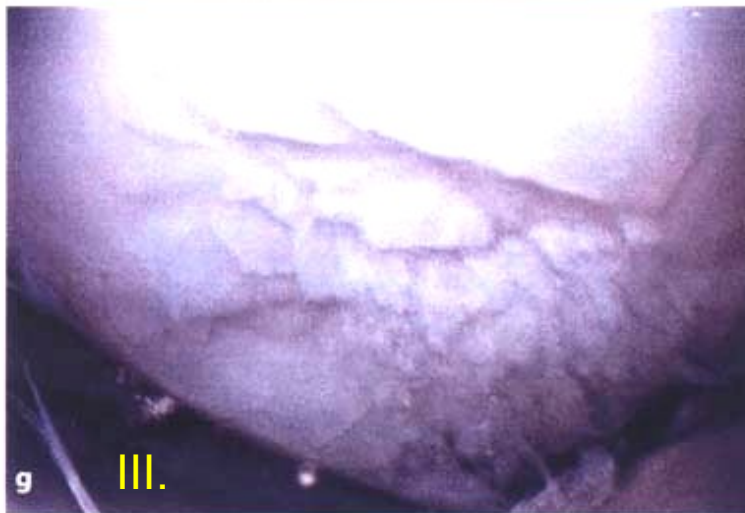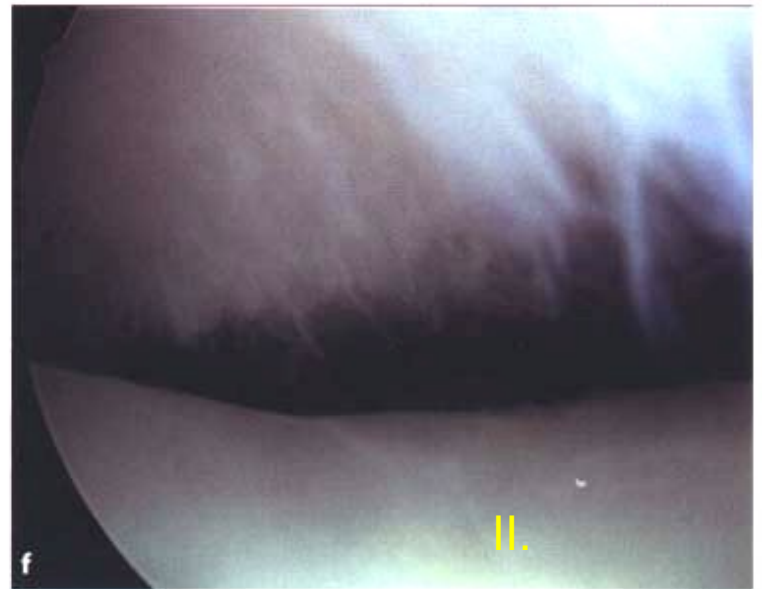
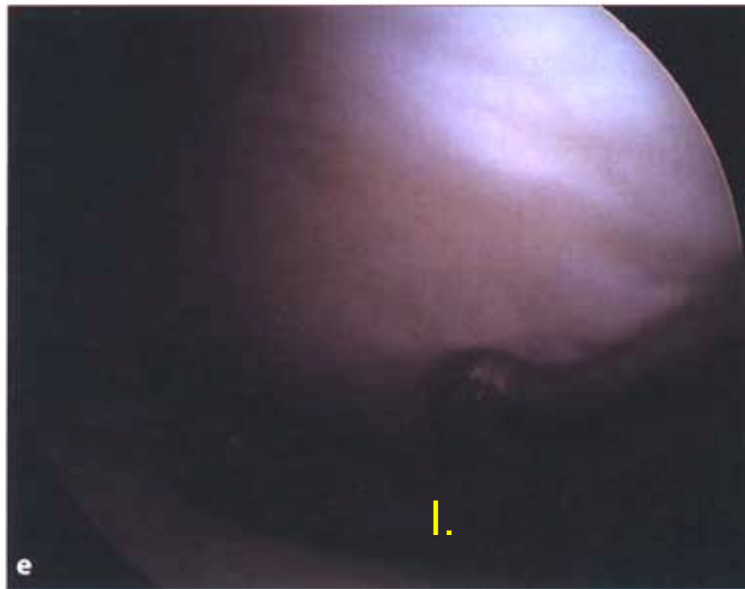
Ortéza

Chondropathy

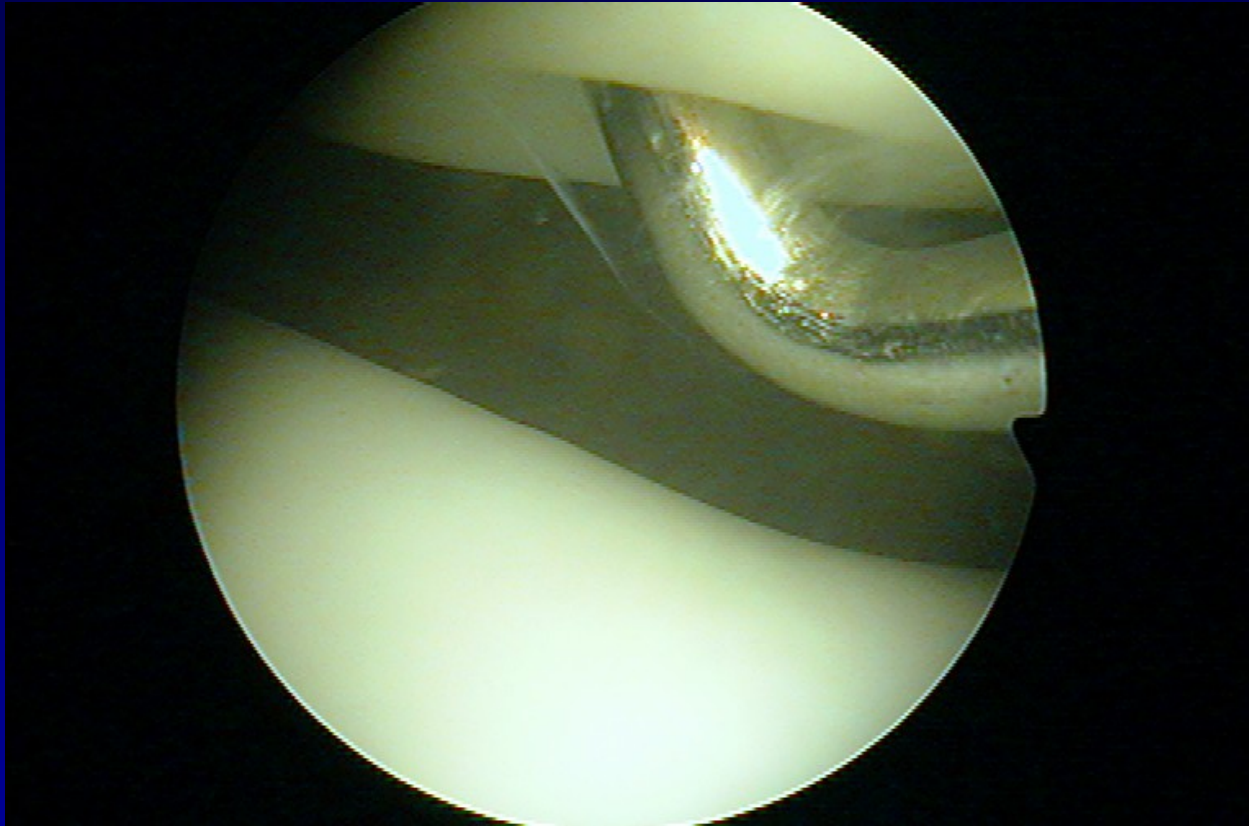
Outerbridge. H.K.



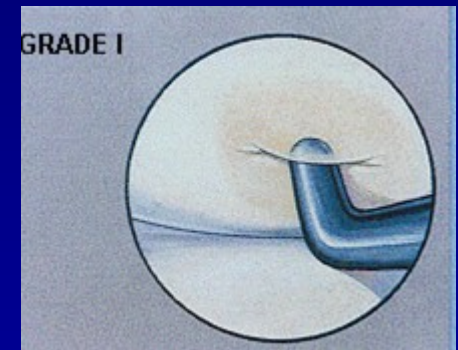
Chondropathy



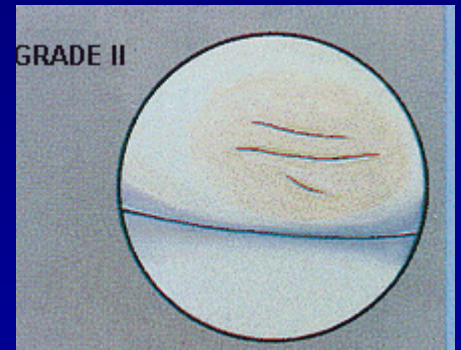
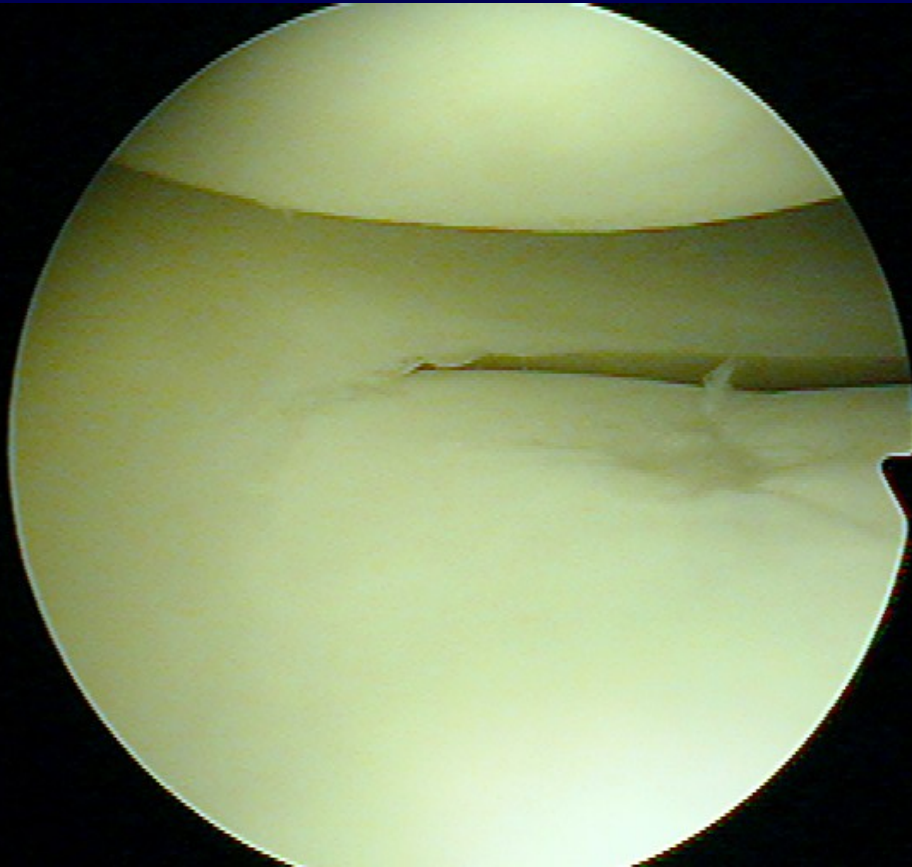
Chondropathy I. st.



Soft cartilage

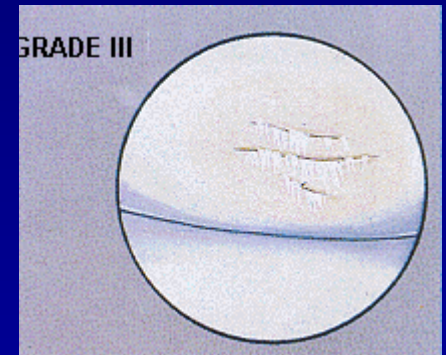
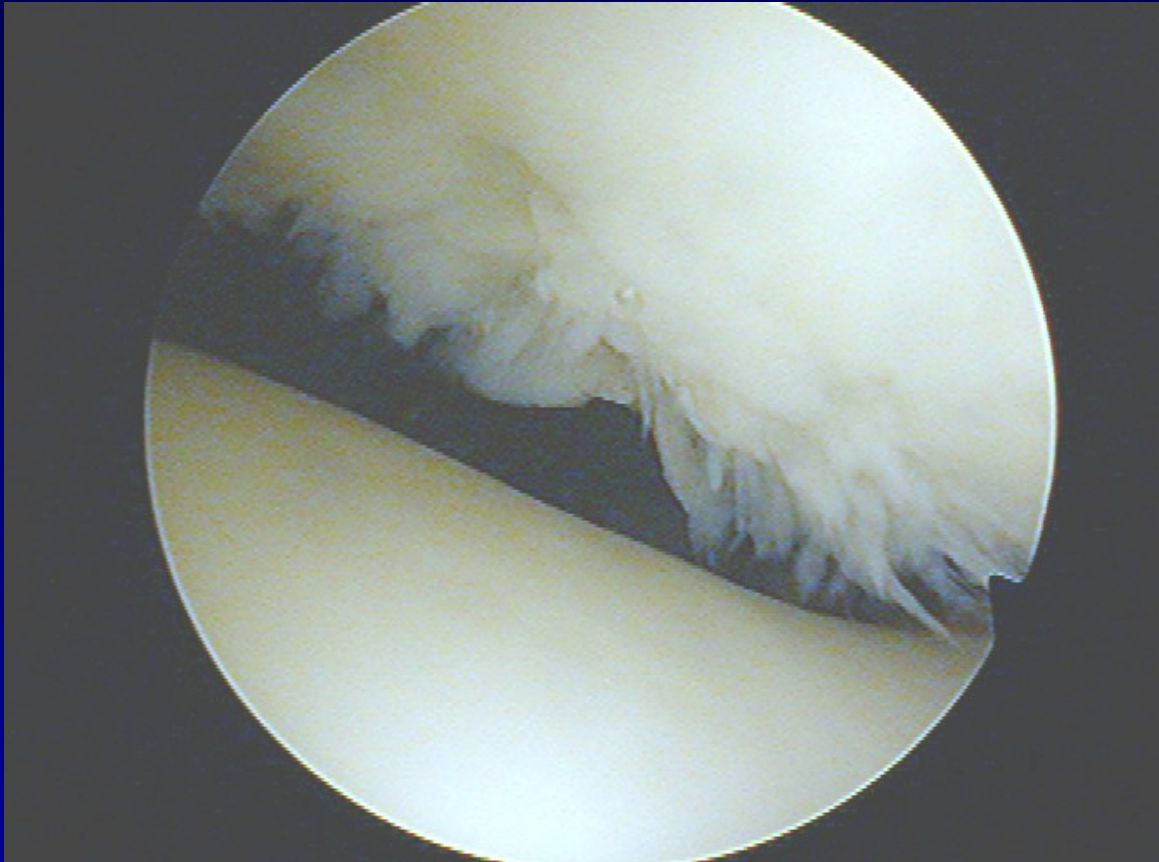


Chondropathy II. st.



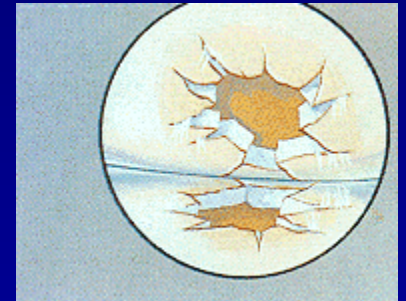
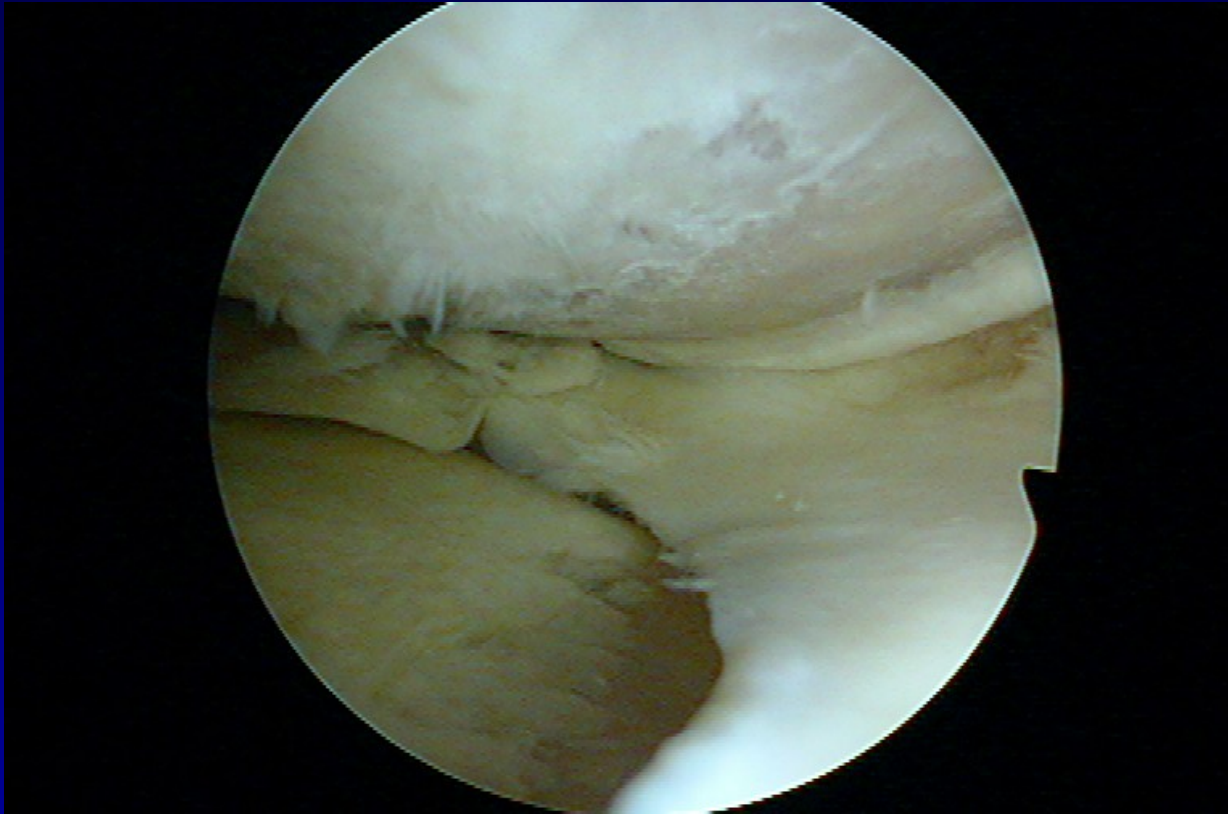
Fissures in the cartilage

Chondropathy III. st.



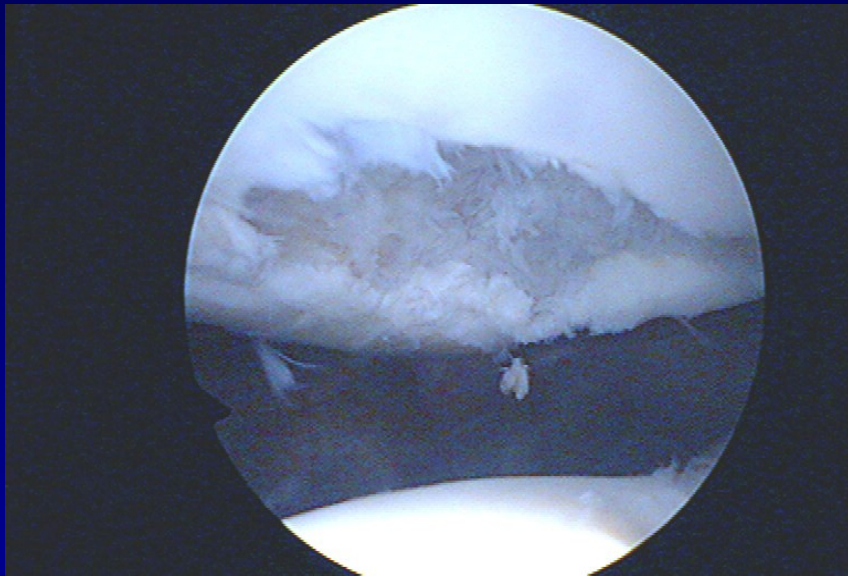
Fibrillation- „ crab meet“

Chondropathy IV. st.

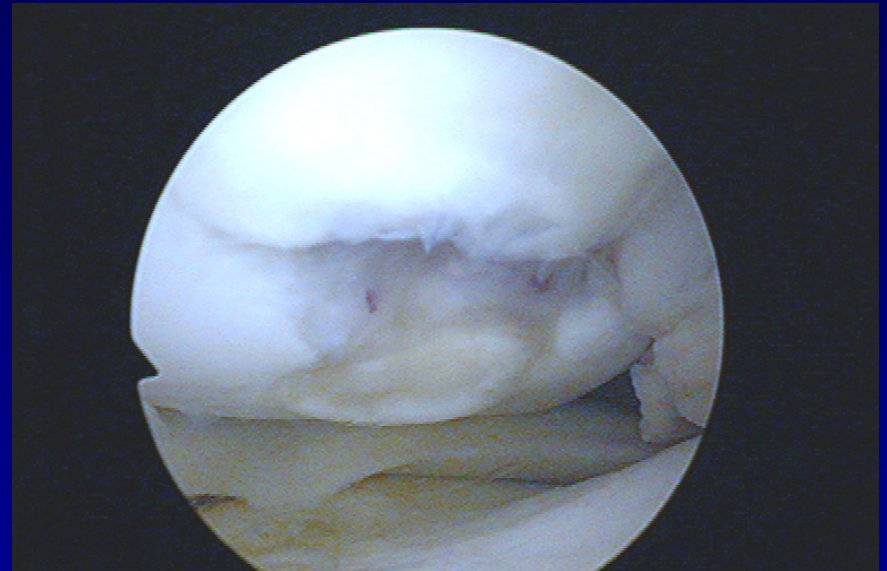


Defects to subchondral bone

Defects of cartilage

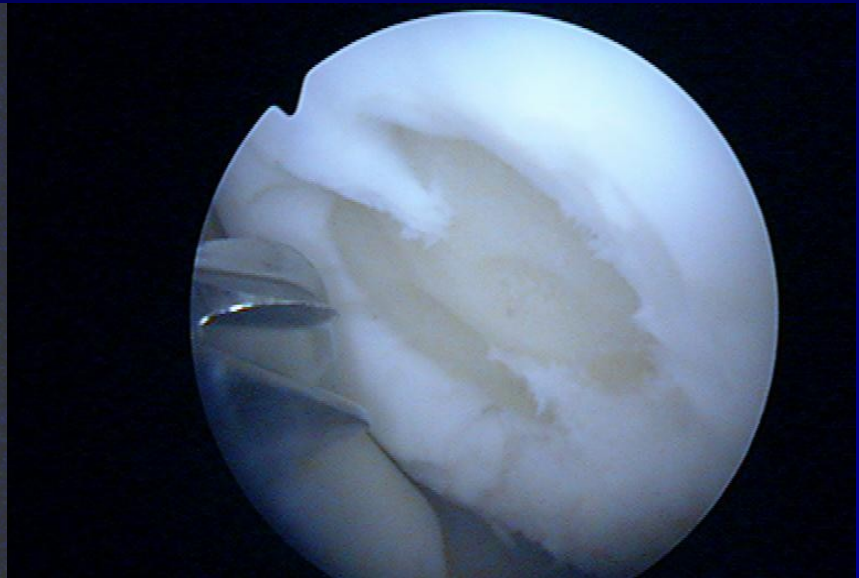
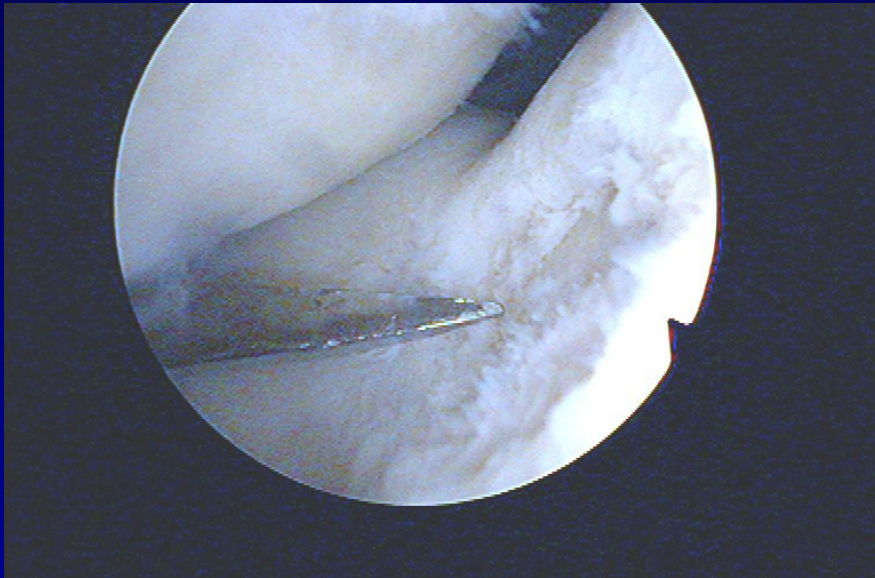


Patella



Medial condyle

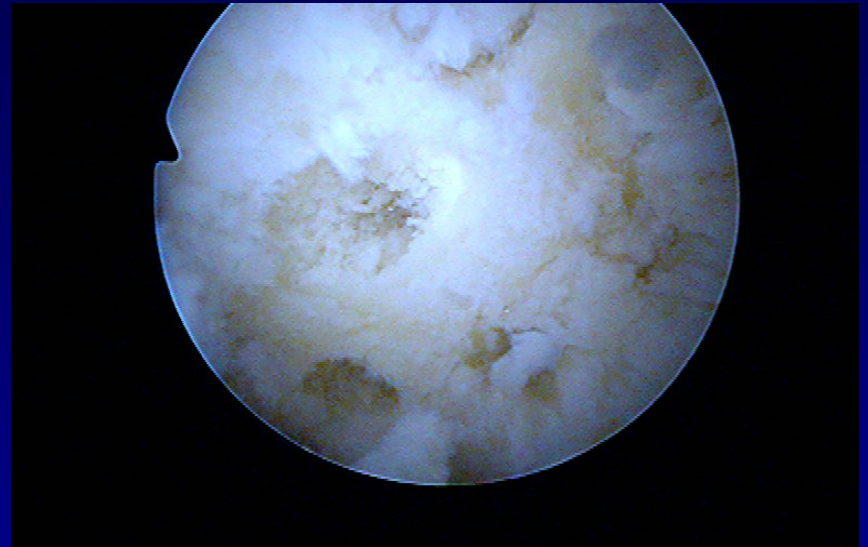
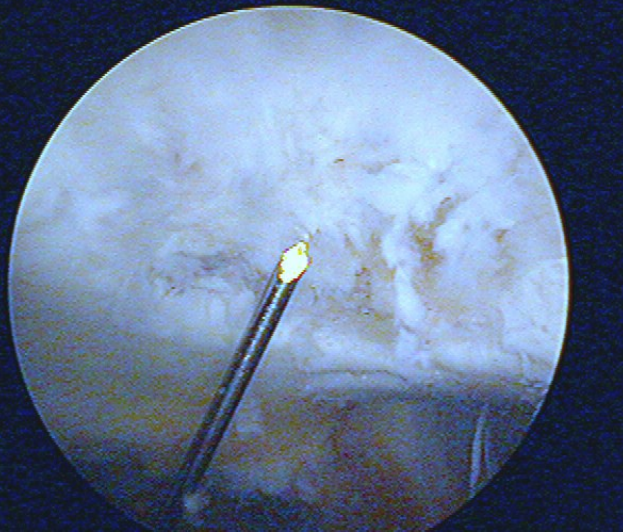
Shaving and drilling



-

-

Drilling

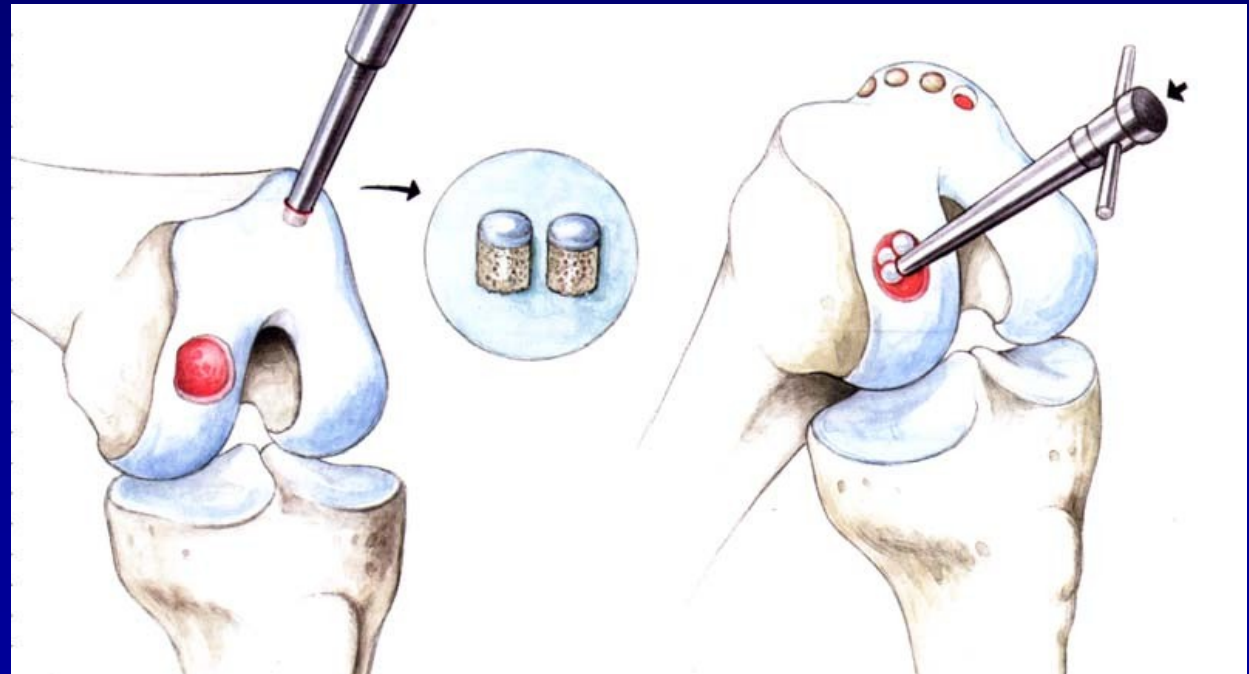


-

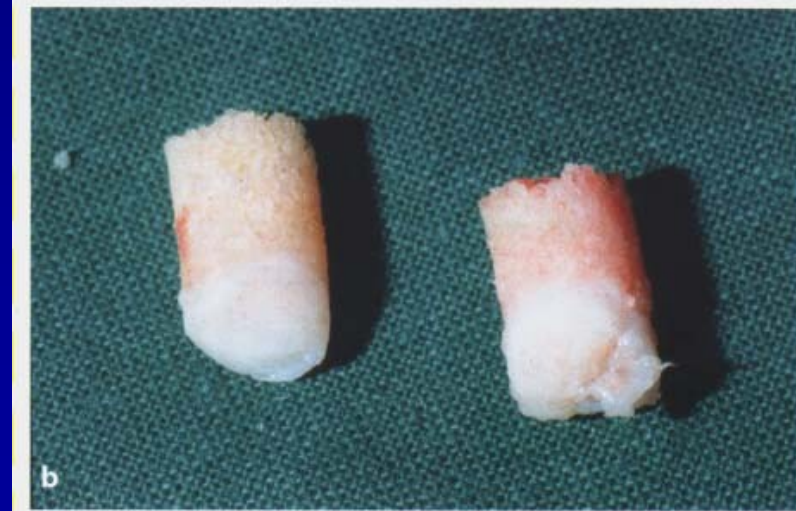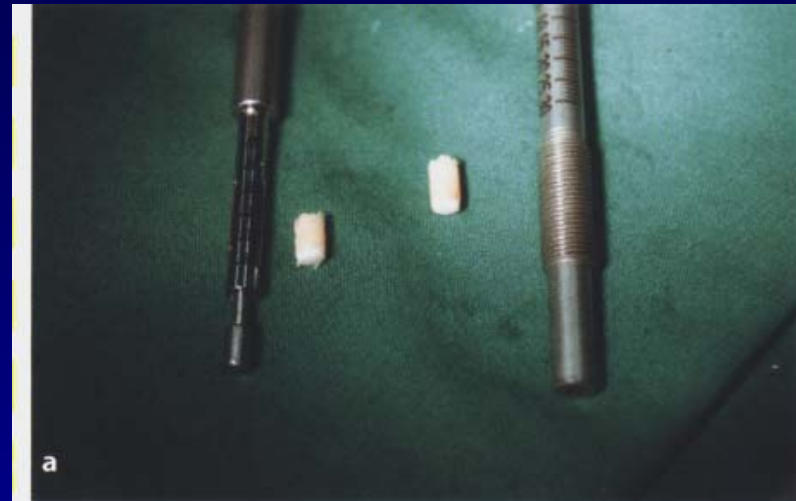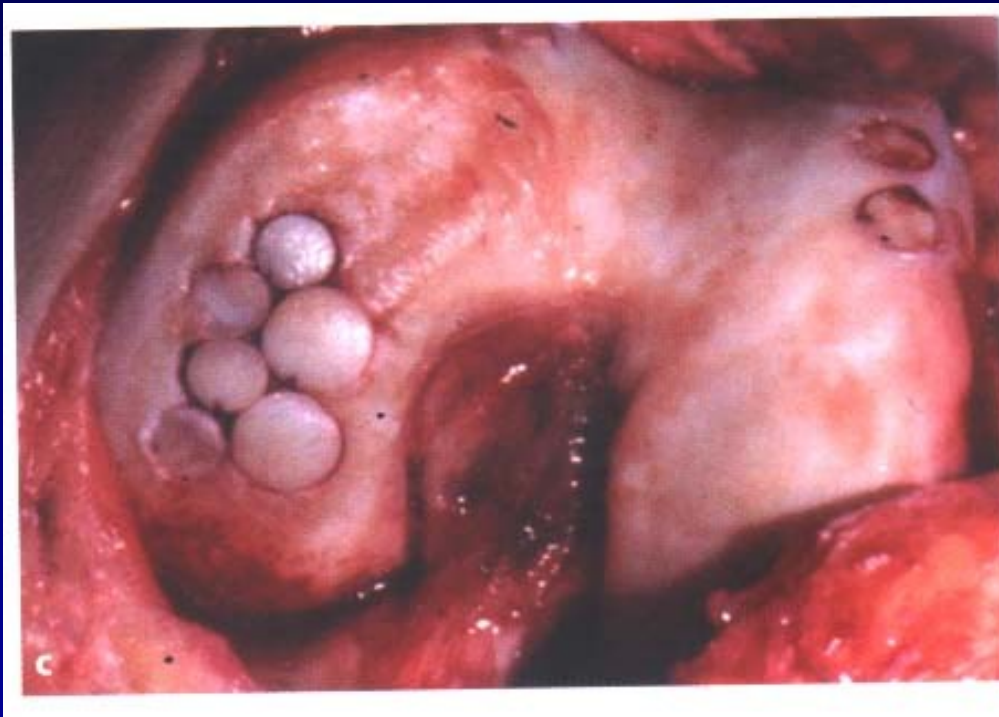Osteochondral autograft transfer- OAT Mosaicplasty

Hangody, L., 1992

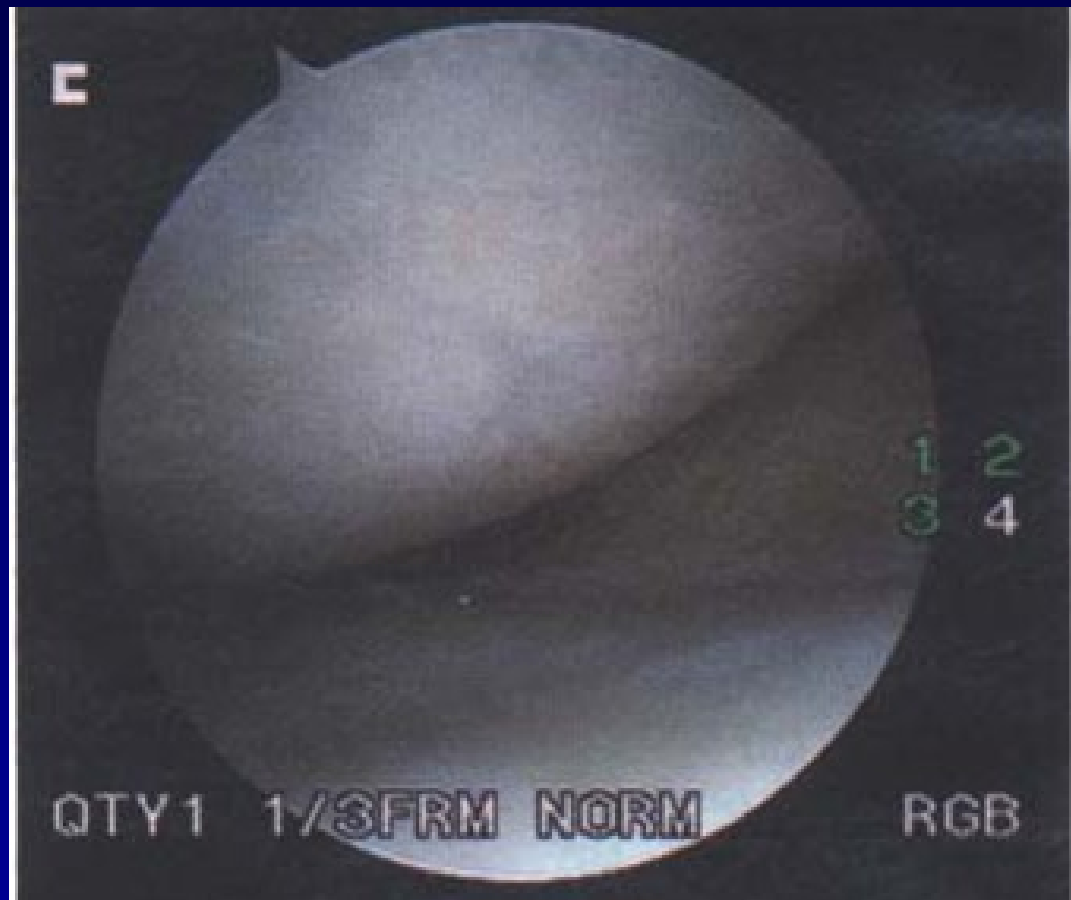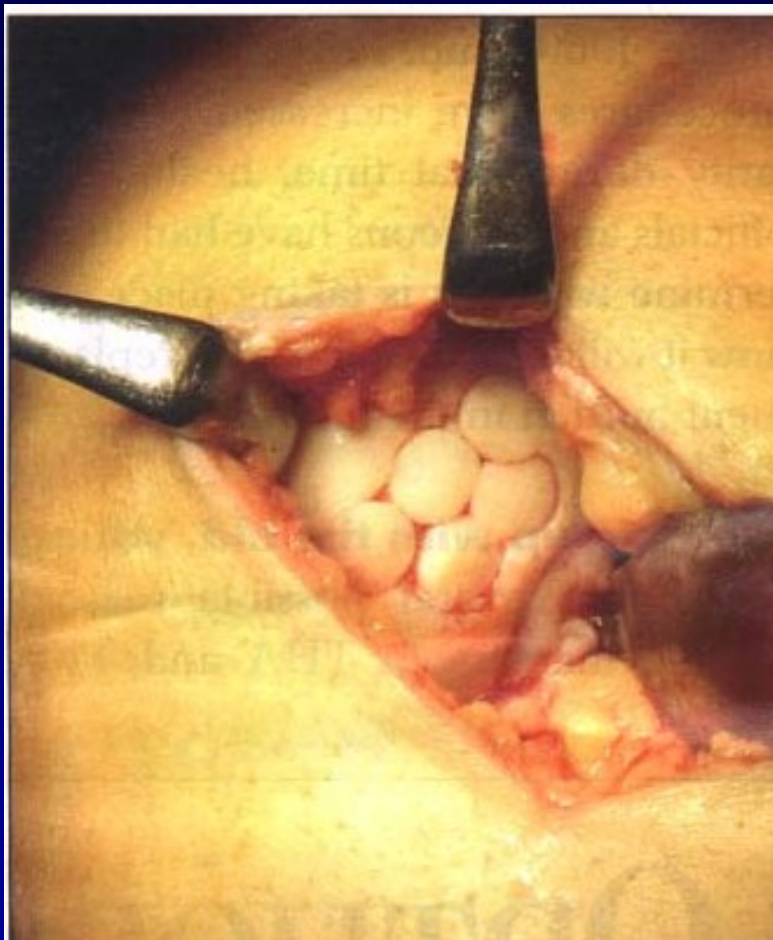
Defects up to 2 - 4 cm²



Osteochondral autograft transfer- OAT



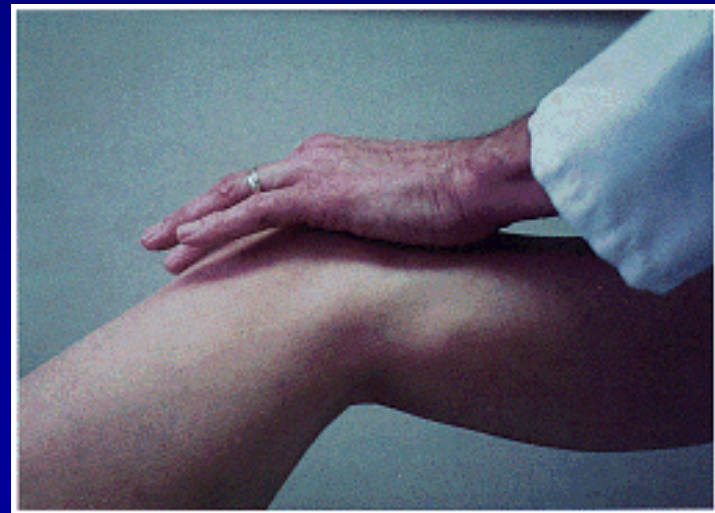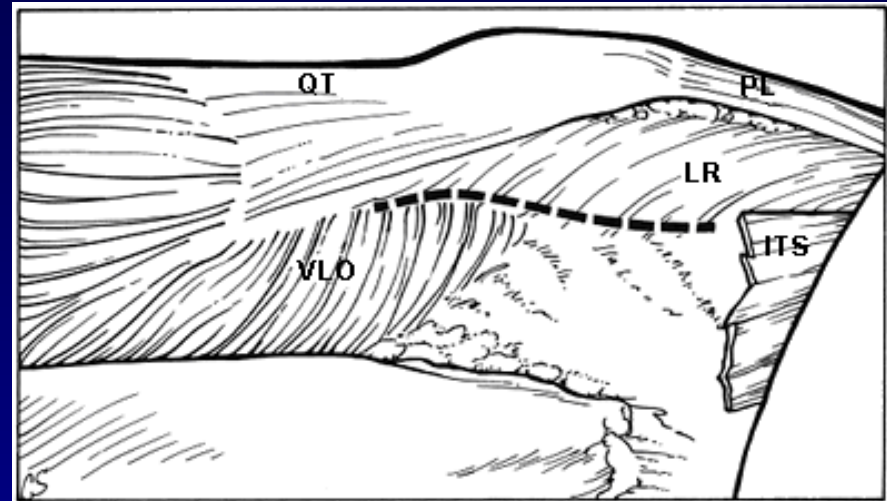
OAT



4 years after surgery

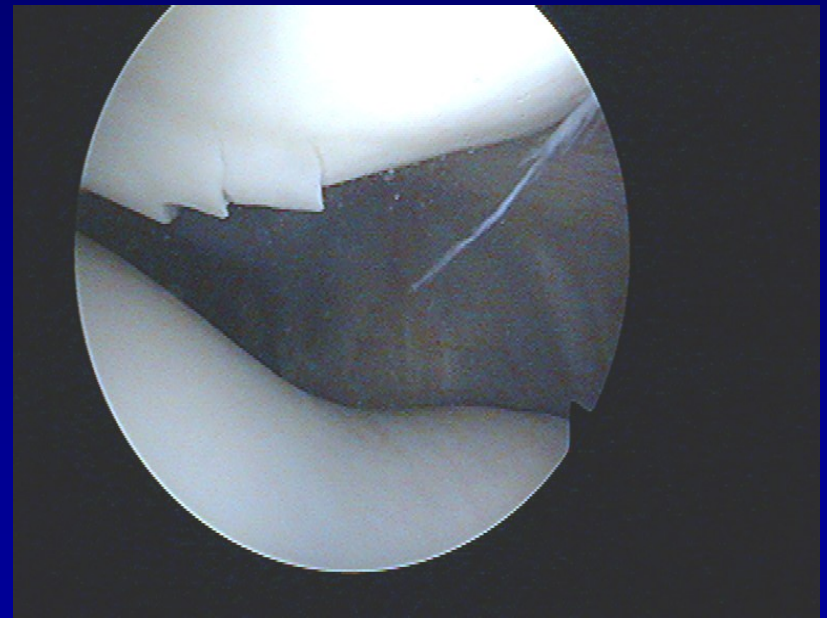
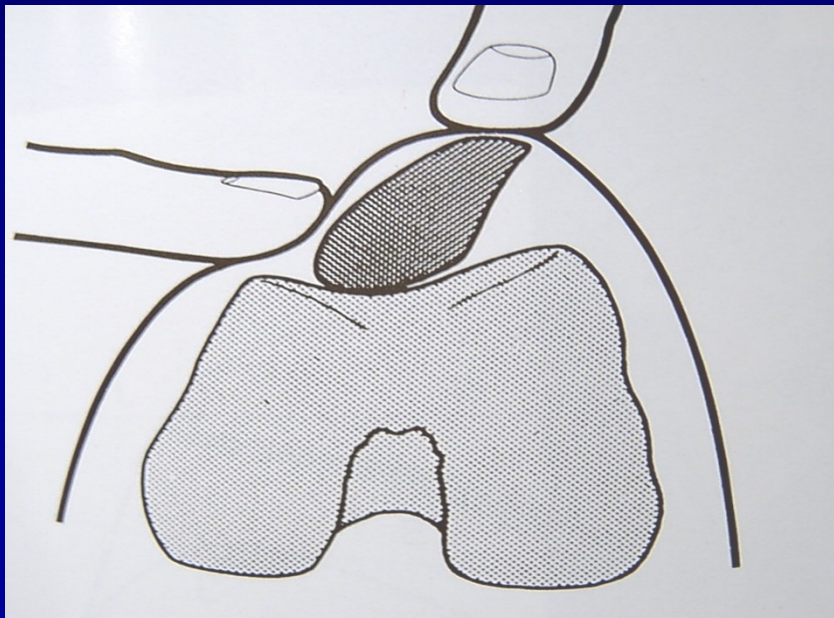
Patella

- Chondropathy
- Subluxation
- Dislocation



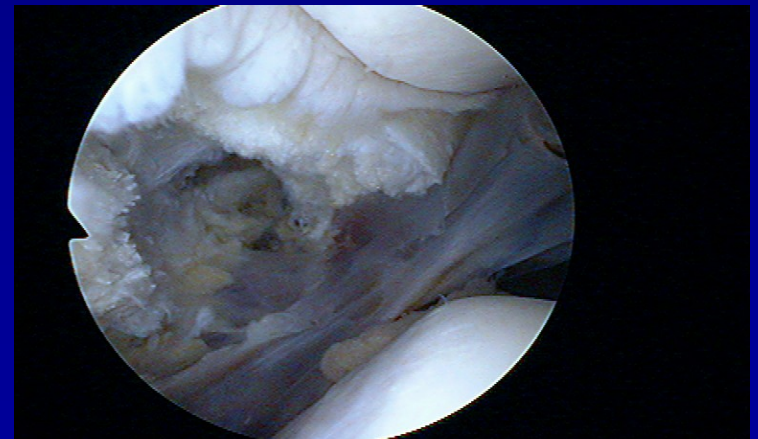
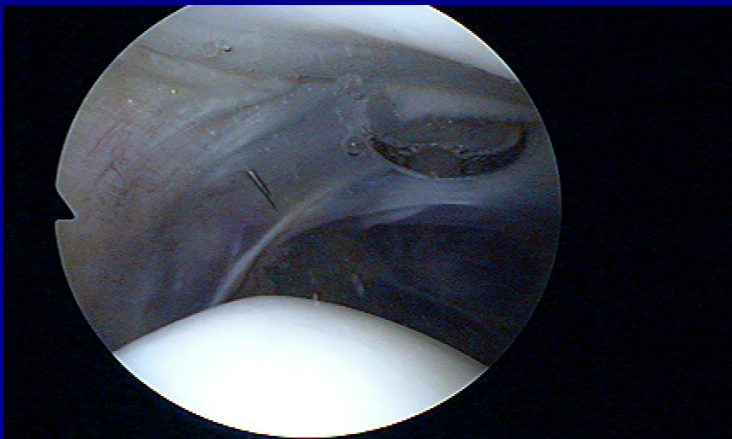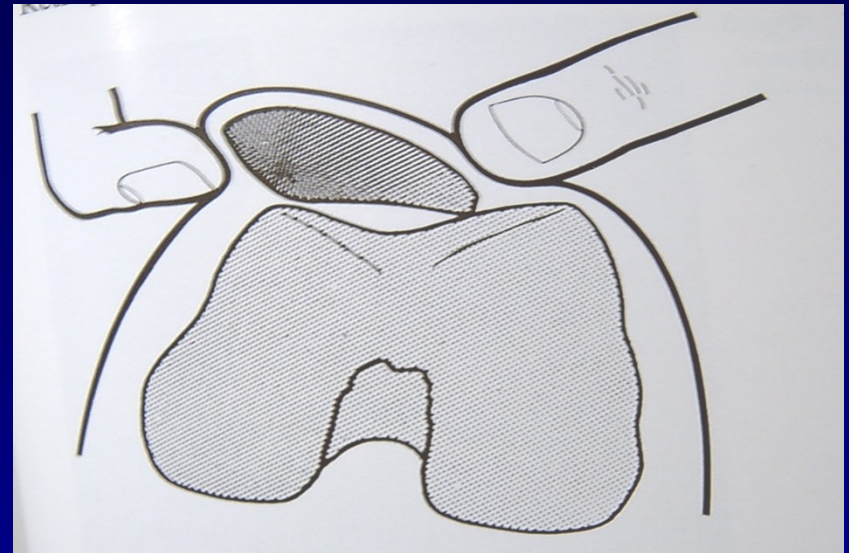
Chondropathy of the patella

Clinical symptoms

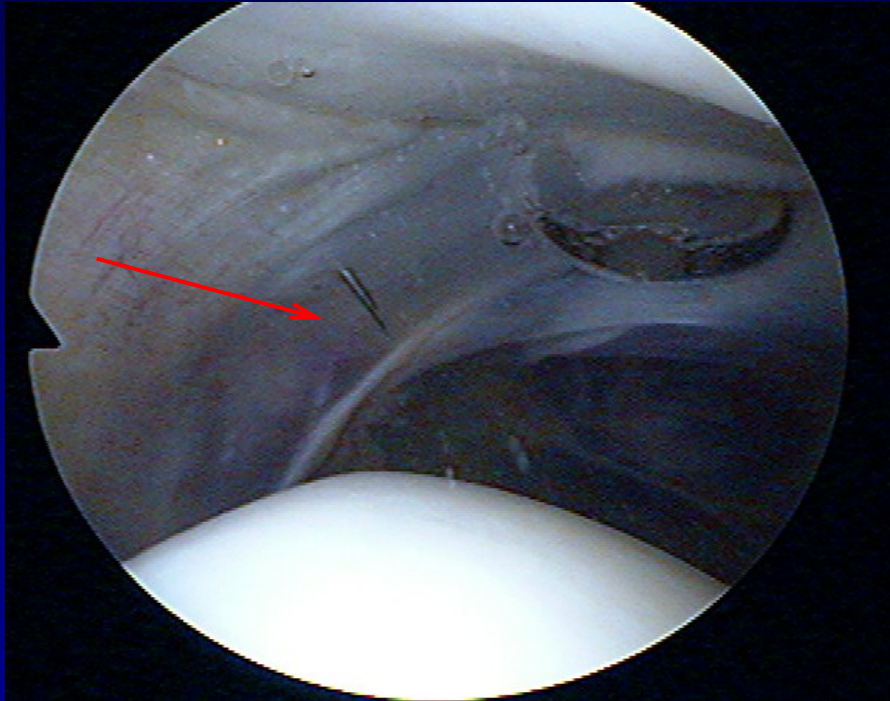


Chondropathy of the patella

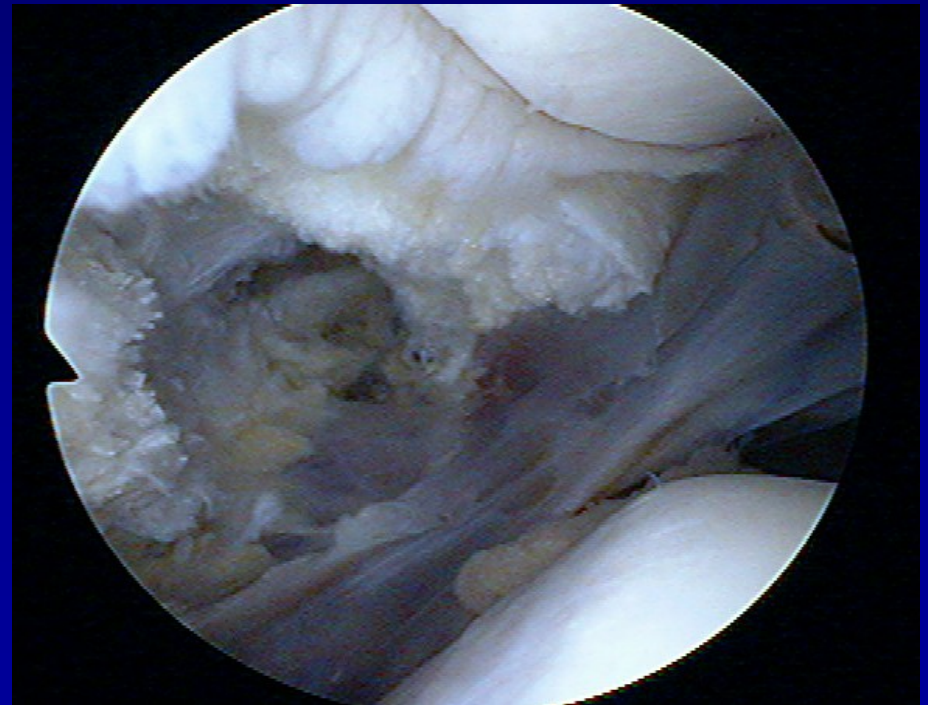
- Lateral hyperpression
- Lateral release



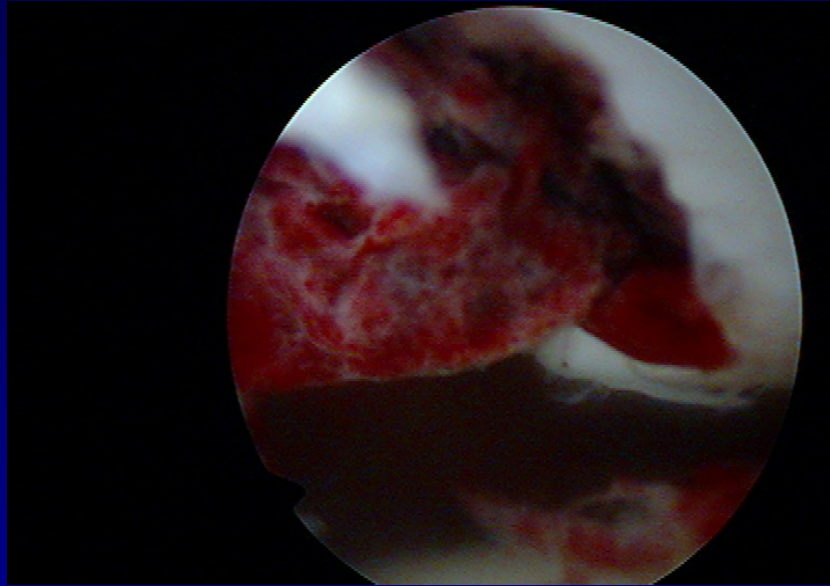
Lateral release



- Incision of lateral retinaculum

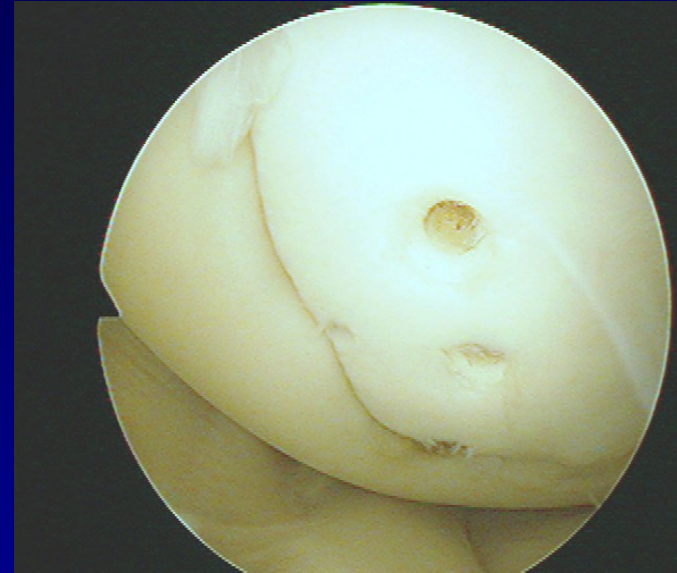
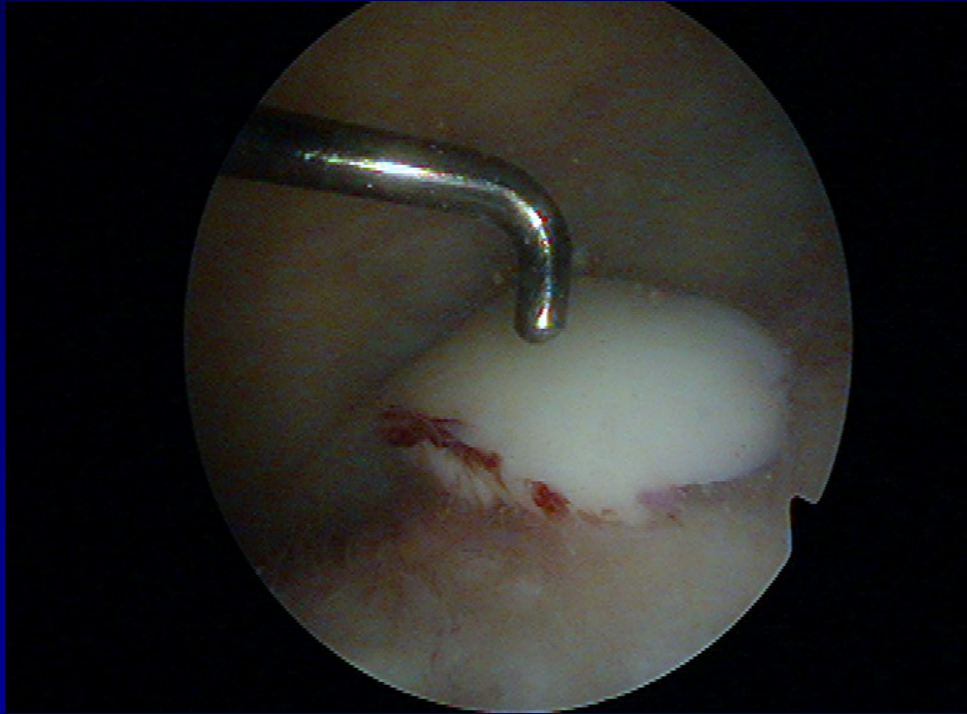


Transchondral fracture



Removal of destroyed cartilage

Osteochondral fractures



Fixation by pins



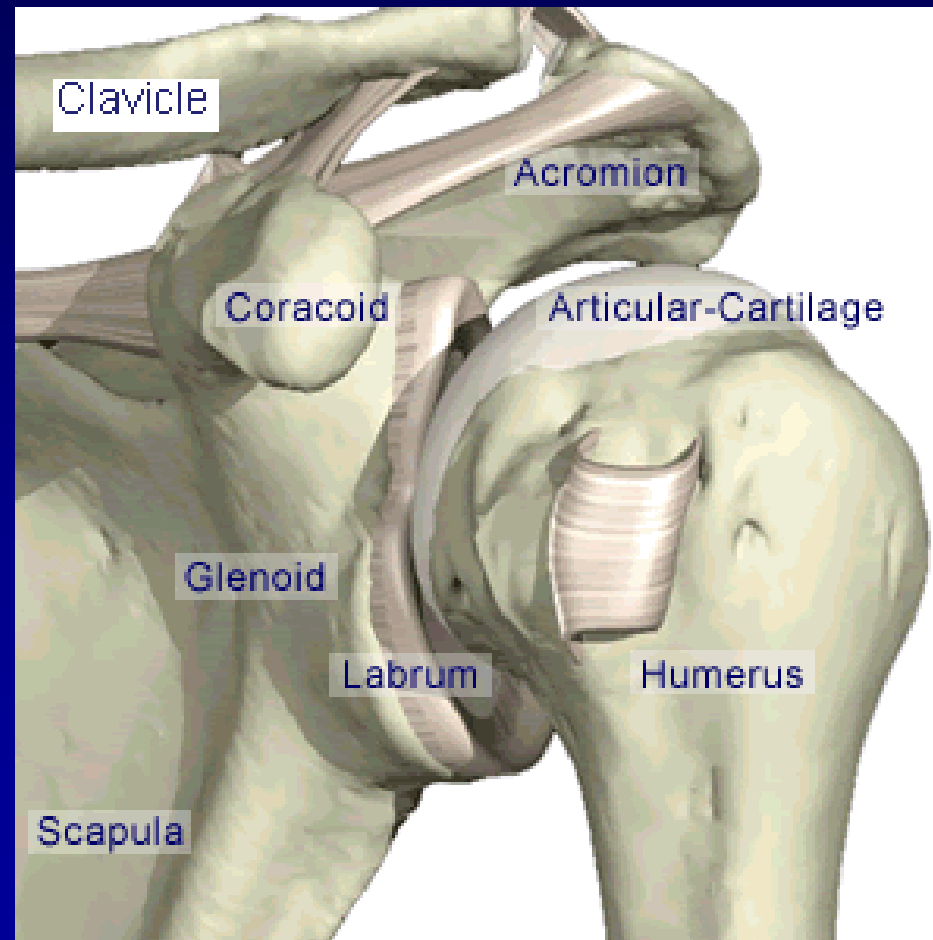
Arthroscopy of the shoulder

Subacromial decompression

Suture of rotator cuff

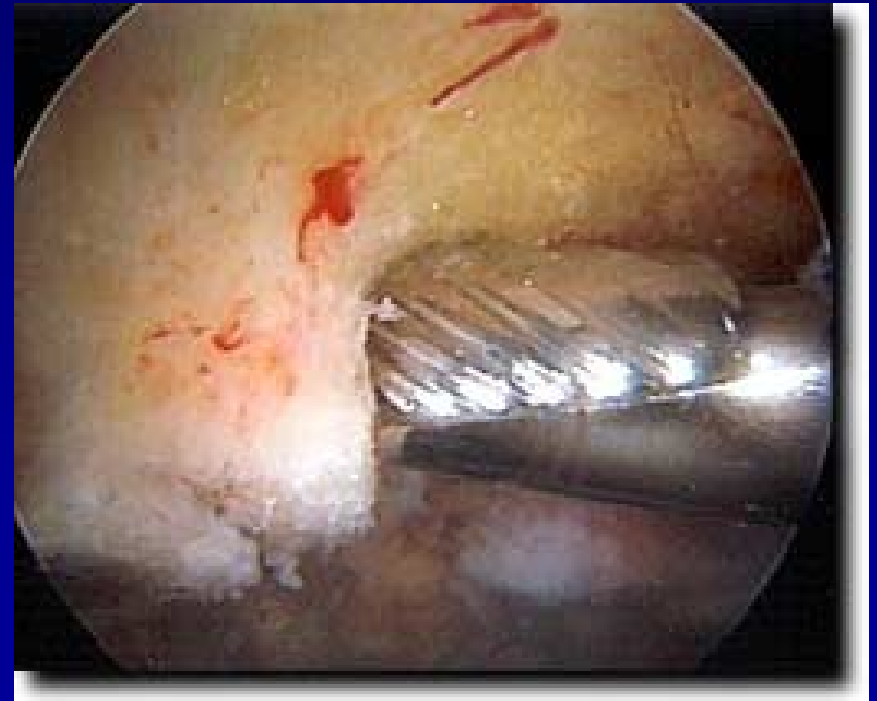
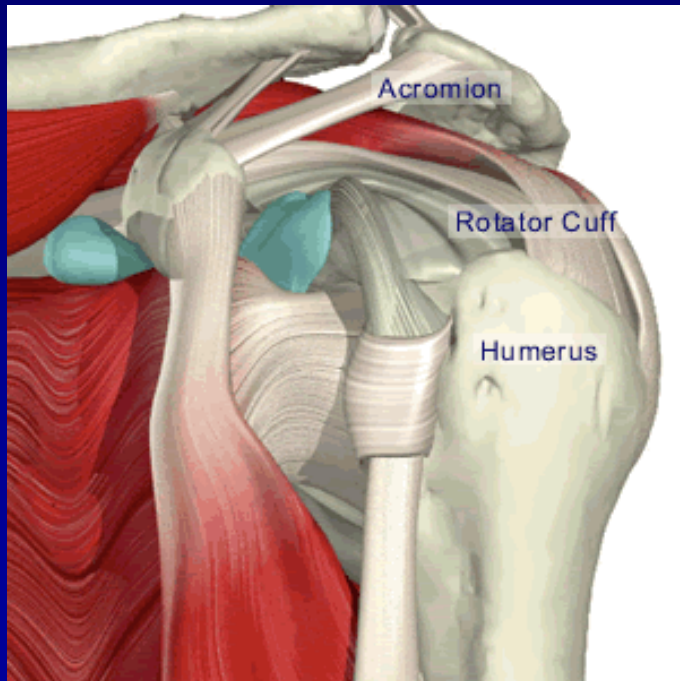
Chronic instability

SLAP lesion



ASAD – arthroscopic subacromial decompression

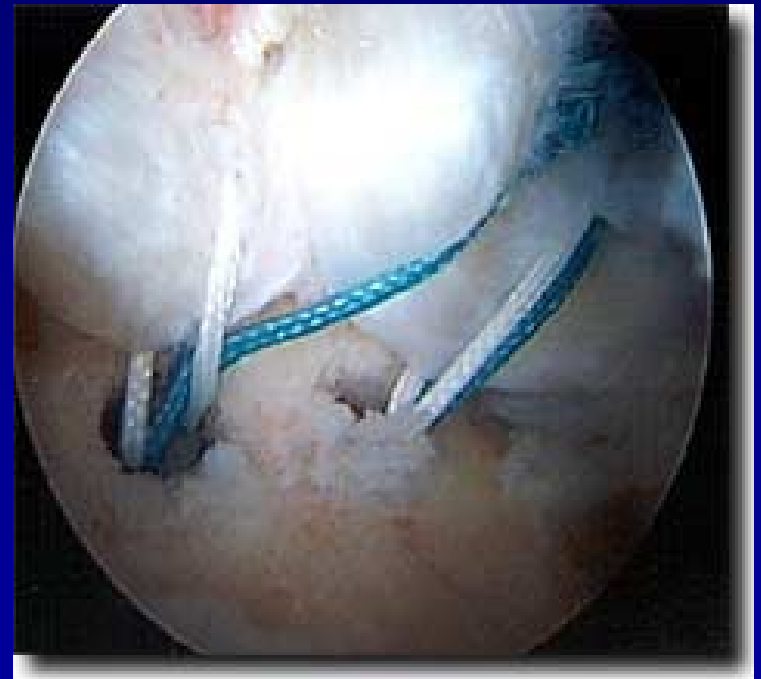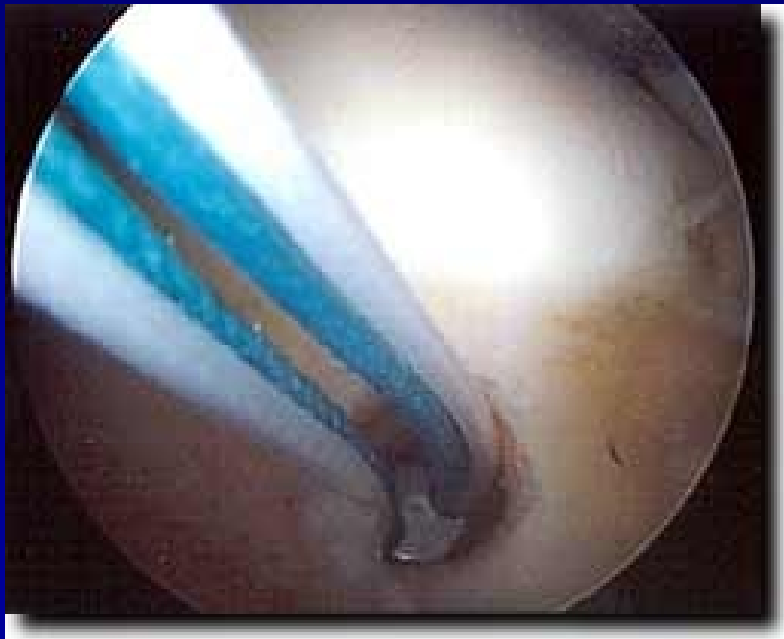- Removal of bursa
- Acromioplasty - shaver



Rupture of rotator cuff

Suture:

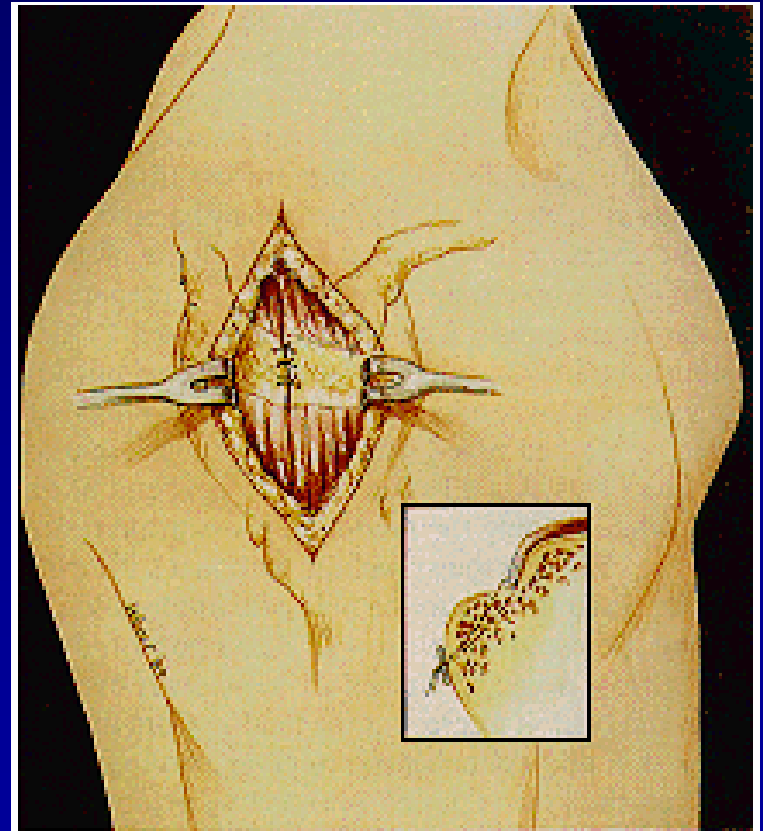
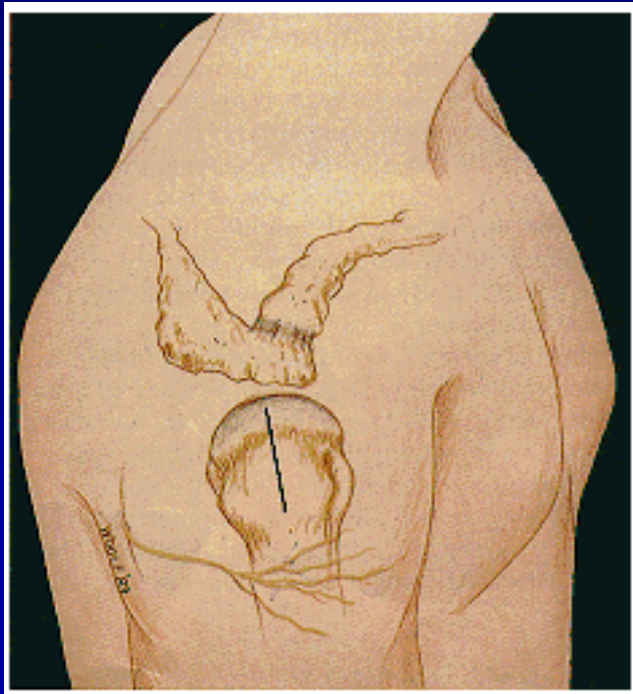
- arthroscopically



Rupture of rotator cuff

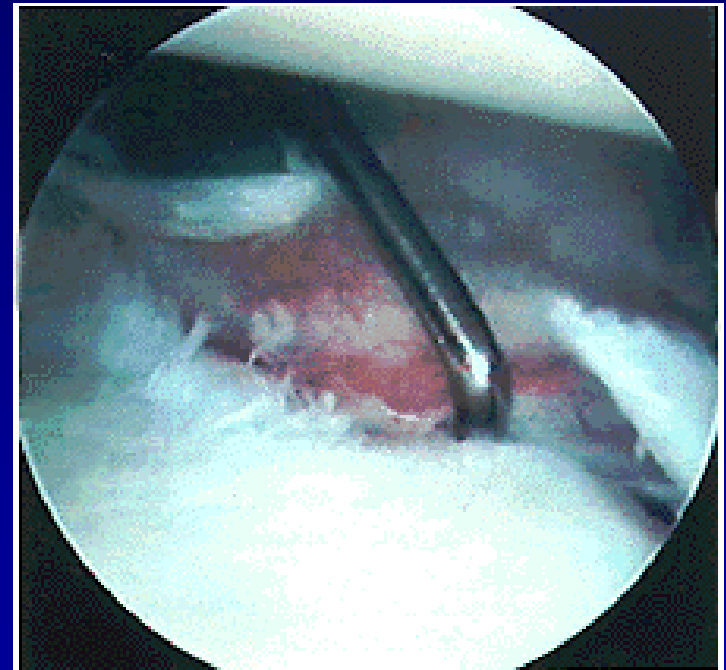
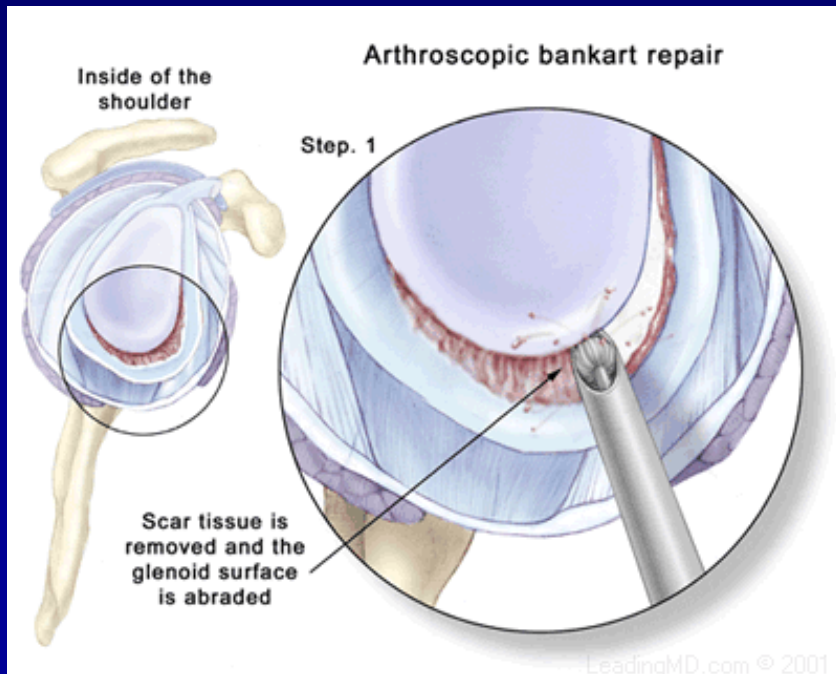
Suture:

- from small incision



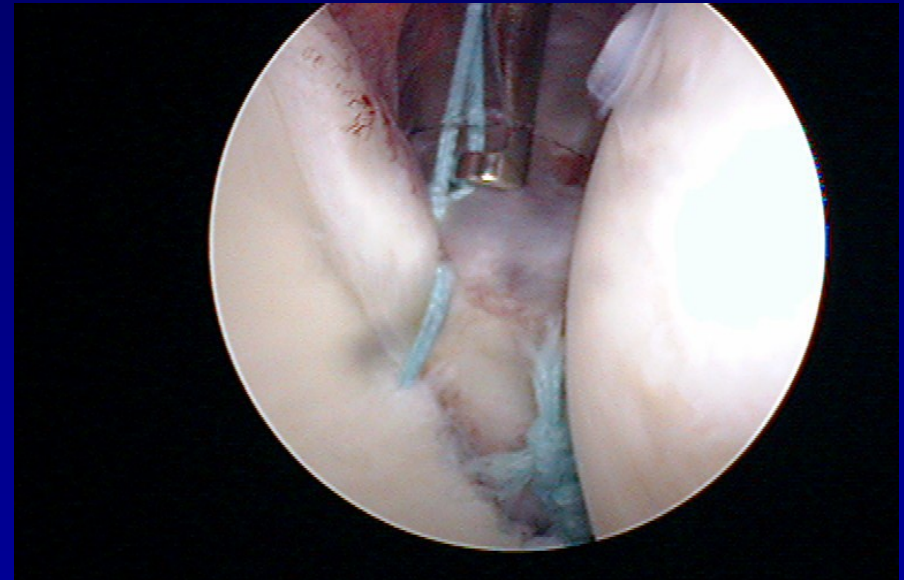
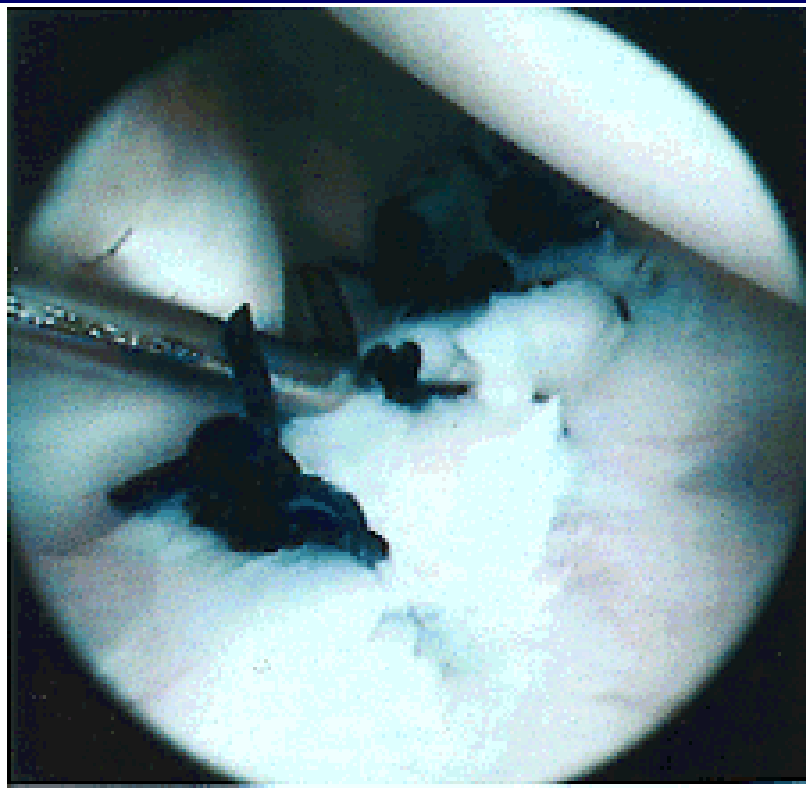
ASC- stabilisation

Fixation of the labrum to the bone – stitches and arrows



ASC- stabilisation

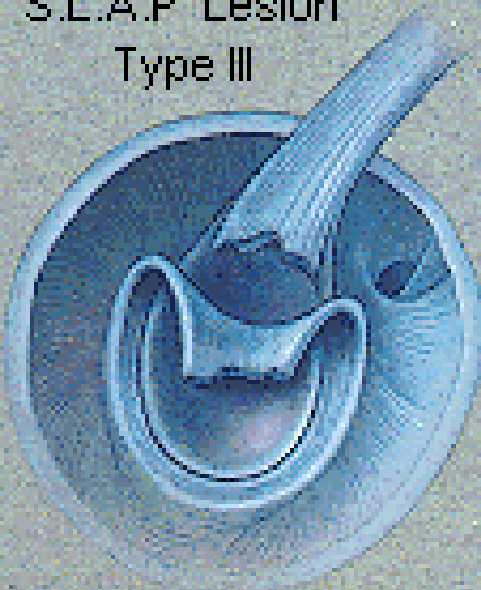- Fixation of the labrum to the bone – stitches, arrows



SLAP lesion

Rupture of insertion of the tendon of long head of biceps

S.L.A.P. Lesion
Type III



S.L.A.P. Lesion
Type IV

