

14. Lower limb pain

Lower limb pain can be divided into traumatic and non-traumatic.

Traumatic pain

Traumatic pain: when **skeletal trauma** is suspected, the first choice method is **X-ray** of injured bone or joint in at least **2 projections**. **CT** is indicated if the skeletal trauma is not confirmed but it is in spite of negative X-ray still suspected or the fracture is complex and more detailed anatomical evaluation is needed. CT show fracture line with practically 100% sensitivity. The advantage of CT is the possibility of 3D reconstructions facilitating the planning of operations.

Example: CT of the knee can be indicated in case of negative X ray and significant clinical suspicion of a fracture. In intraarticular fractures (typically of the knee), there is usually fluid effusion containing blood and fat (it is possible to see fat globules in the aspirated effusion - fat is released from the bone marrow into the effusion during intraarticular fracture).

If **muscle trauma** is suspected, the method of choice is **ultrasound**, which can reveal tear of tendons (eg Achilles) and muscles and hematomas in soft tissues (intramuscular hematoma is always present in case of recent muscle tear).

In muscle rupture, there is a palpable defect at the site of rupture. In complete rupture, both muscle/tendon stumps shorten towards their attachments.

A sonographer educated in musculoskeletal radiology is also able to assess injuries of the collateral ligaments of the knee or the ligaments of the ankle joint. The ultrasound can also display the **joint effusion**, which can be aspirated under ultrasound control.

Magnetic resonance imaging is indicated in suspected cartilage and ligament injuries, and in case of unclear ultrasound findings of tendon and muscle injuries. One of the most common indications of MRI is suspected injury of the cruciate ligaments or menisci of the knee.

Among the chronic injury pain can be counted stress fractures, which usually occur in metatarsal bones or tibia. A discrete fracture line (already in the stadium of healing) or a non-specific thickening of the periosteum is usually present on the X-ray image, which needs to be further investigated on MRI.

Non-traumatic pain

Non-traumatic lower limb pain is usually chronic, sometimes may manifest acutely (eg deep vein thrombosis, bleeding / rupture of Baker's pseudocyst, arthritis). In the diagnosis of skeletal pathologies, depending on the etiology X-ray and MRI is used. In non-skeletal pathologies is mostly used ultrasound and MRI (MRI in degenerations of the menisci, cartilage and ligaments - see above).

CT is used in the diagnosis of non-traumatic limb pain only to display arteries (CT angiography) before a possible intervention (angioplasty, bypass). Typical indication is a patient with muscle pain after tens to hundreds meters of walking (intermittent claudication). Otherwise, on CT cannot be evaluated cartilage and ligaments and therefore gives in non-traumatic pain only a little additional information compared to X-ray.

Non-traumatic limb pain requiring urgent examination is usually caused by **occlusion of deep veins or arteries**. These units have typical clinical symptoms: in venous thrombosis, asymmetric swelling is present and the limb is usually warm, in arterial occlusion the limb is cold. The first choice method is ultrasound, which clarifies the presence and extent of the occlusion. Diagnosis of the lower limb ischemia can be confirmed by CT angiography, which is used for planning the surgical or radiological intervention.

Superficial thrombophlebitis can be easily diagnosed clinically, ultrasound is indicated if the thrombus in the deep venous system is suspected.

Chronic pain in the popliteal cavity can be caused by **Baker cyst**. It is a cystic formation in the medial part of the popliteal cavity filled with synovial fluid that communicates with the knee joint. When bleeding or rupture, it may mimic the symptoms of deep vein thrombosis. It is easily accessible by **ultrasound**. It is usually found during ultrasound examination of the veins of the lower limbs to rule out deep vein thrombosis.

The most common cause of lower limb joint pain is **osteoarthritis**. This is the most common degenerative disorder of the musculoskeletal system. X-ray is enough for the diagnosis. For large load-bearing joints (hip and knee), a four-level classification of degenerative changes based on X-rays is used. Chronic osteoarthritis can be acutely exacerbated, which is clinically manifested by swelling and joint pain even at rest. On X-ray, the image of decompensated osteoarthritis is the same as for chronic, other imaging methods are usually not needed.

Osteoarthritis manifests itself on X-rays in the initial stages as a narrowing of the joint space (corresponding to a reduction of the cartilage), later in response to chronic overload develop marginal osteoproduction (osteophytes at the edges of the joint that may restrict movement and cause pain) and subchondral sclerotization (reactive intensification of subchondral bone) with subchondral cysts (cavities of fluid below the articular surface filled with synovium); the last stage is deformation of the bony joint parts.

Chronic painful changes of the joints can also be caused by inflammatory (eg septic arthritis, rheumatic diseases) or systemic diseases (eg gout). In case of pain of skeletal origin, we must not forget bone cancer, namely primary at a younger age and secondary (metastases) rather at an older age and in a known oncological disease (typically prostate cancer). Tumorous lesions can be diagnosed on X-ray with possible subsequent follow-up on MRI. Bone scintigraphy is also important, on which most malignant tumors appear bright (accumulate radiopharmaceutical due to locally increased metabolism; osteolytic deposits in multiple myeloma do not accumulate radiopharmaceutical and are usually not visible on bone scintigraphy).

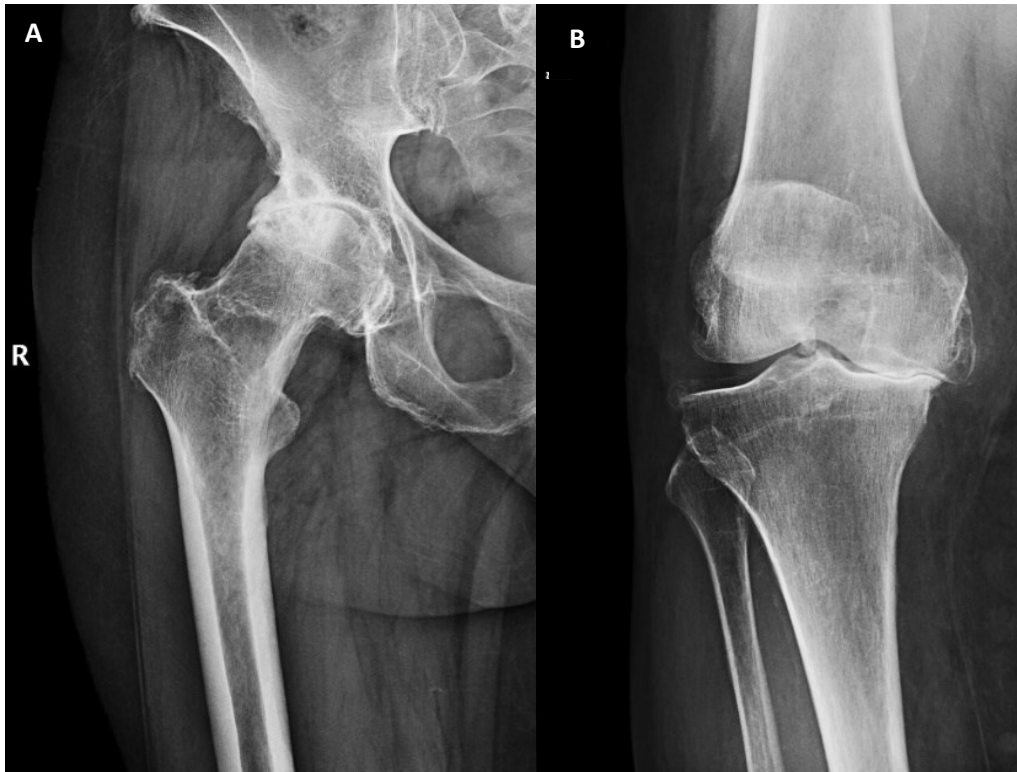

Fig. A – X-ray osteoarthritis of the hip grade 3

Fig. B - X-ray osteoarthritis of the knee grade 3

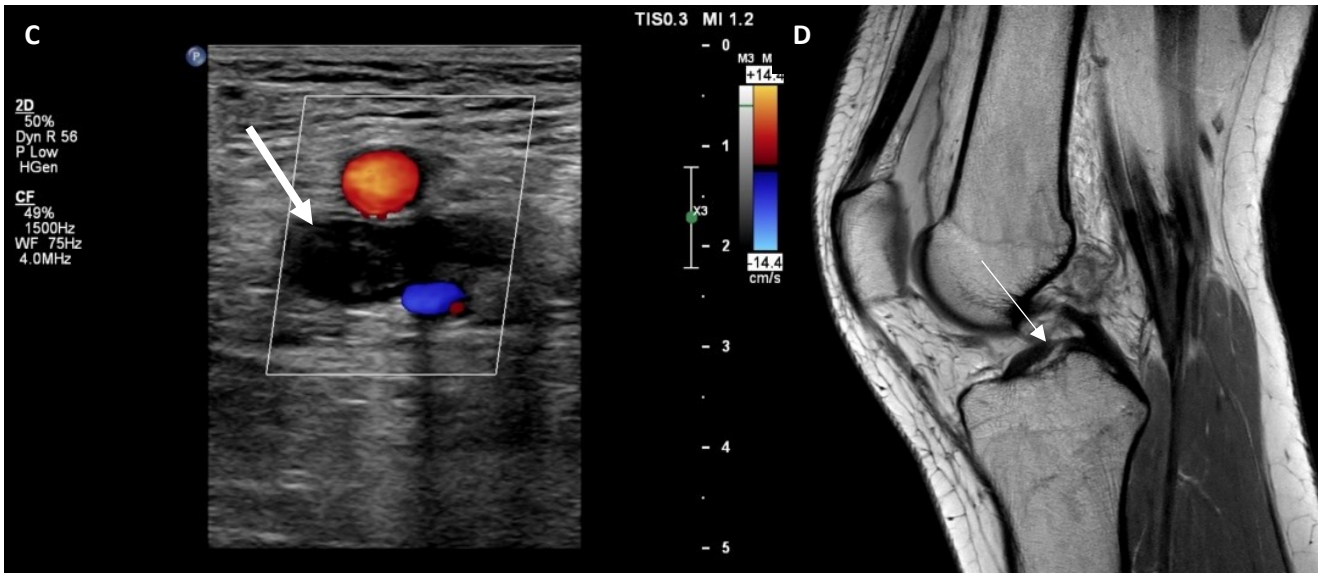


Fig. C - Ultrasound image of deep vein thrombosis –dilated incompressible lumen of the vein filled with the hypochoic thrombus (white arrow), surrounding arteries with visualised flow

Fig. D – MRI of knee (proton density weight image, sagittal plane) – anterior cruciate ligament rupture (white arrow, the proximal part of the ligament is missing), posterior cruciate ligament is smooth with no signs of injury (homogenic low signal)