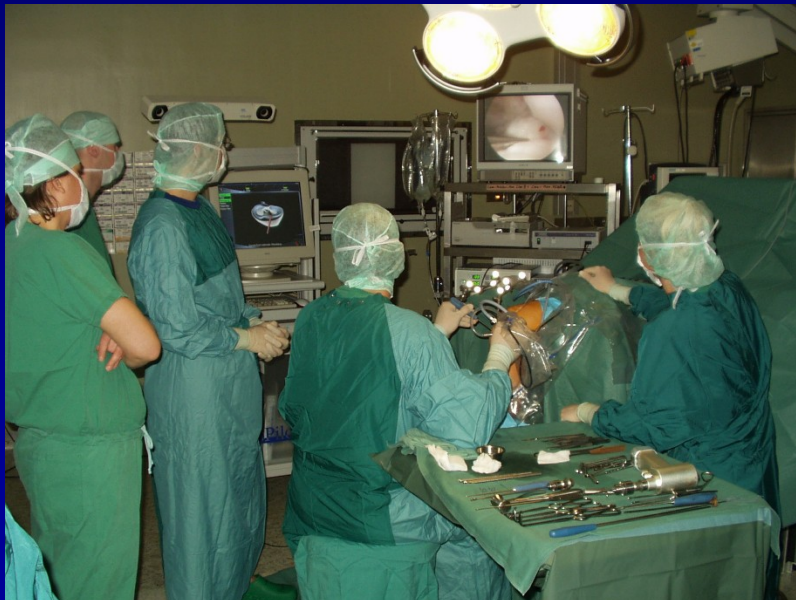

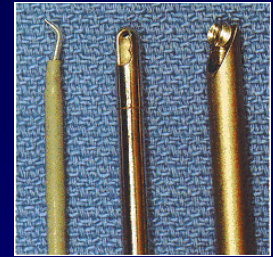
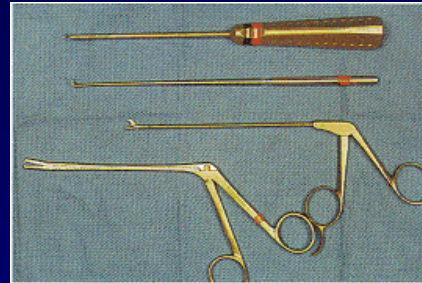

# ARTHROSCOPY

- Endoscopic method
- Imaging and treatment
- In general or spinal anesthesia

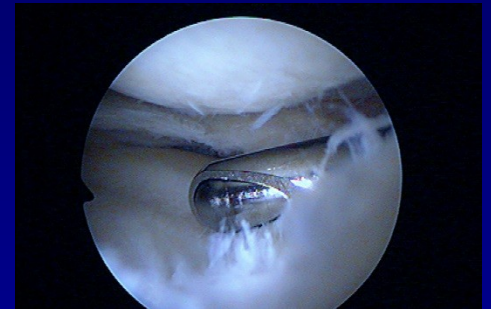

- knee
- shoulder
- ankle
- elbow
- wrist
- hip
- small joints

# Arthroscopy



- Camera
- Arthroscope – rigid tube with a lens 30° or 70 °
- Xenon light with optic cable
- ASC pump
- Instruments
- Shaver
- Vaper
- Printer, VIDEO, DVD



# Arthroscopy

Menisci

Chondropathy- shaving, debridement,  
abrasion arthroplasty,  
microfractures

Plasty of ligaments

Suture of rotator cuff

Instability of shoulder

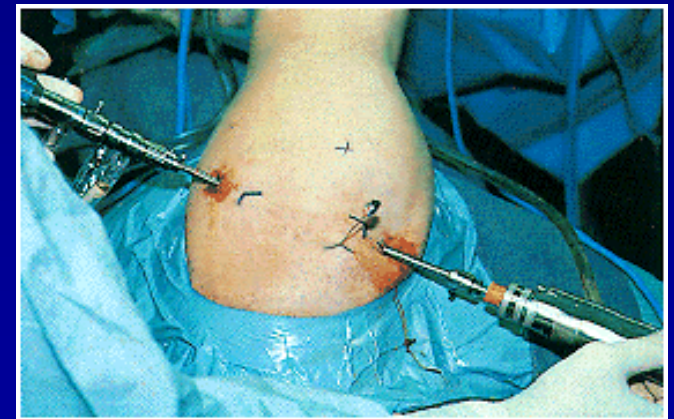
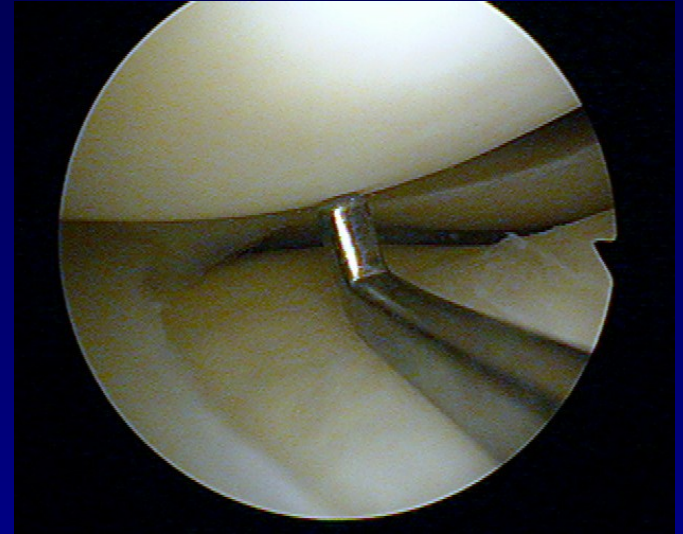
Repair of transchondral lesions

Support in treatment of intraarticular fractures

Biopsy

# Advantages

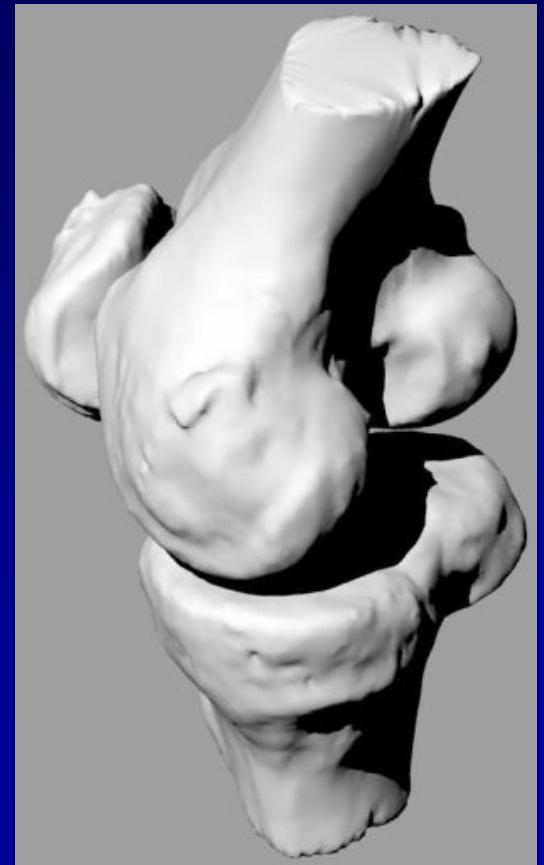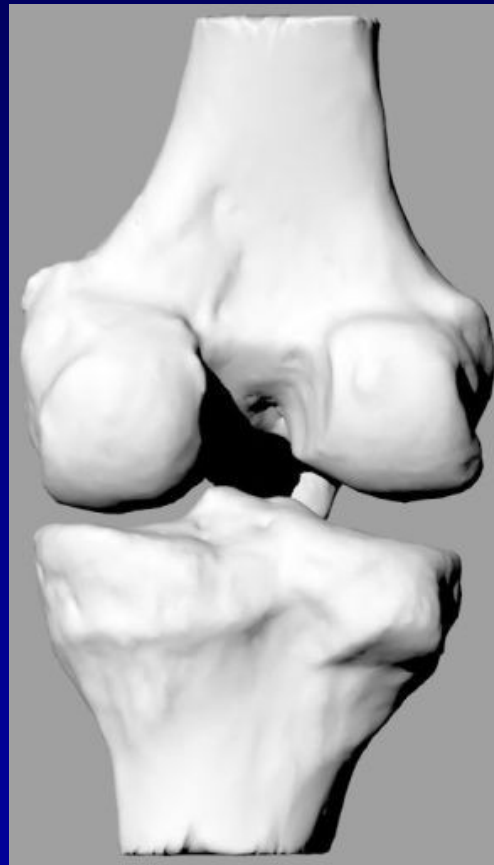
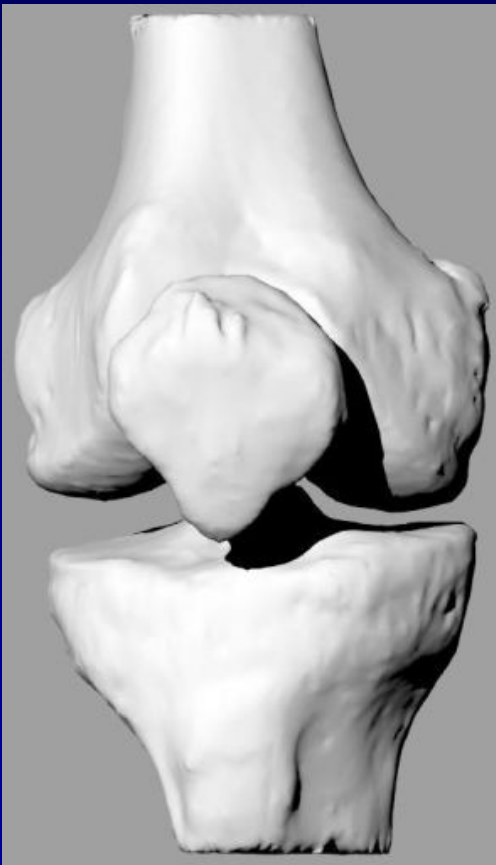- Perfect visualisation
- Less postoperative pain
- Fast physiotherapy
- Small incision



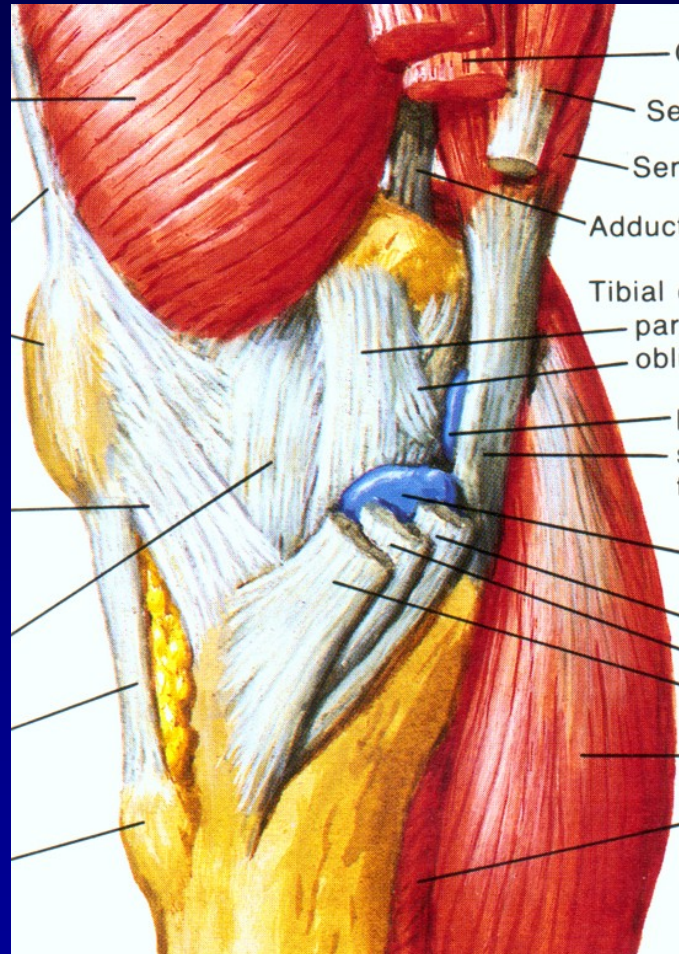


# The knee joint- complicated structure

Articulating bones: Femur, tibia and patella



# Stability of the knee

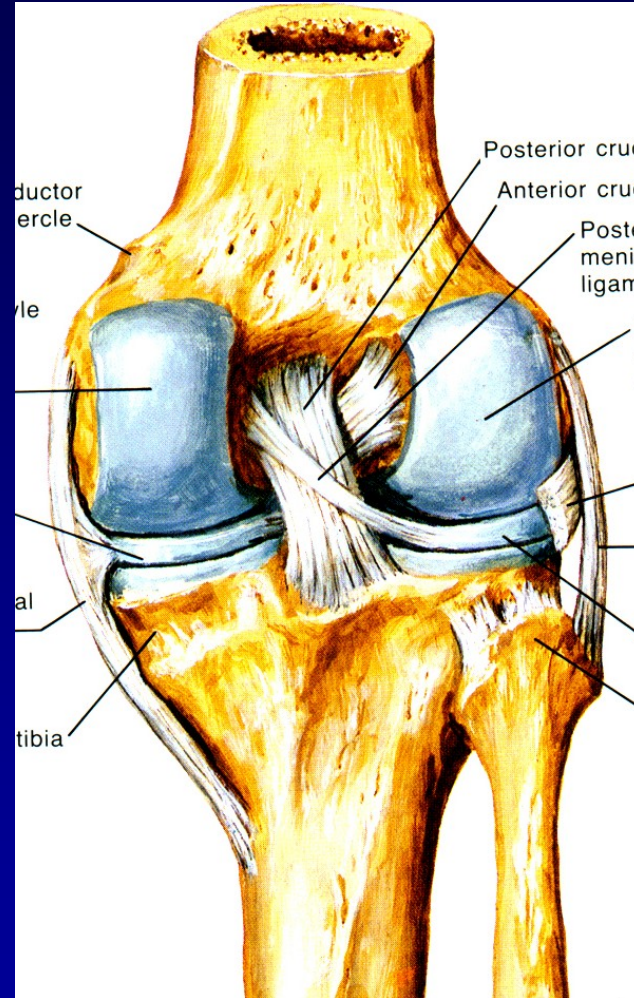
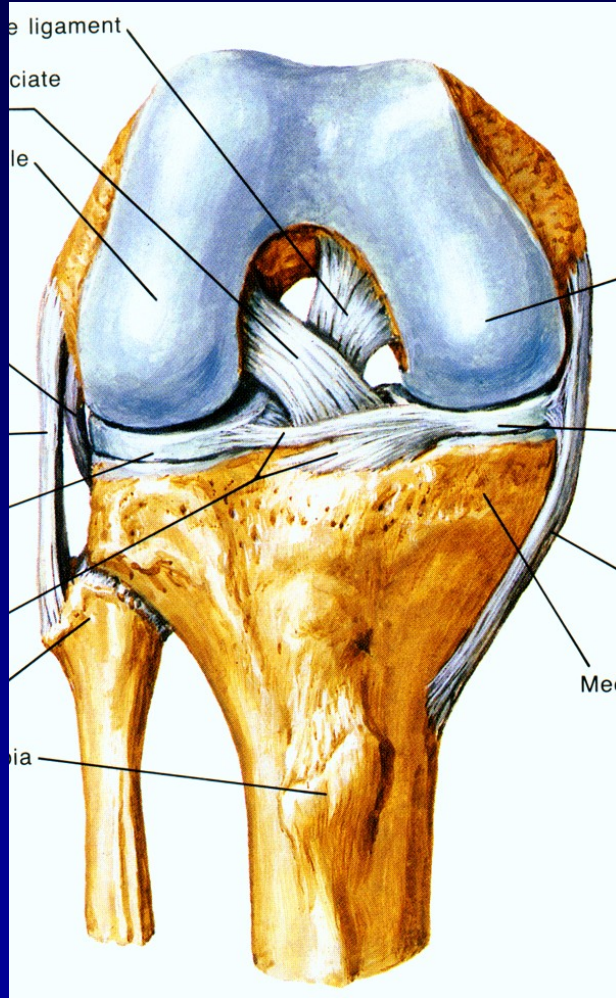


Medial side





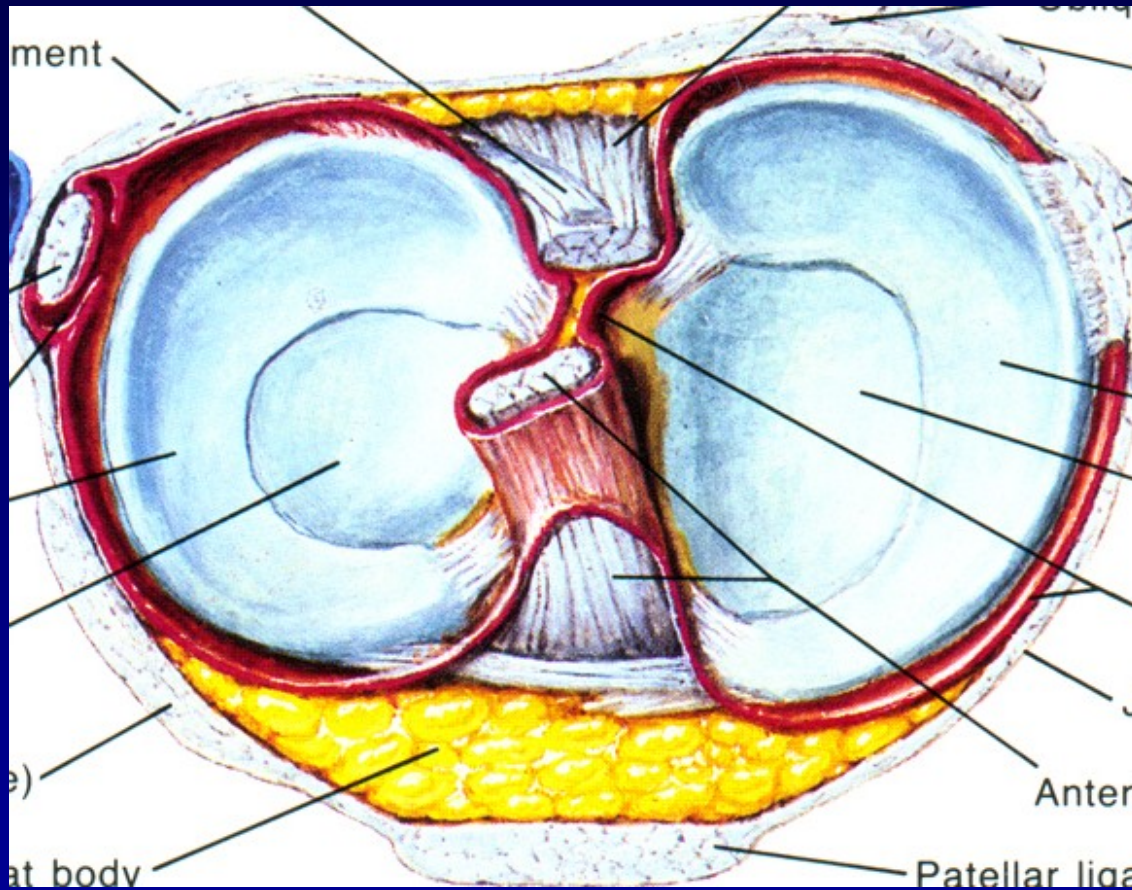
# Stability of the knee



Cruciate ligaments

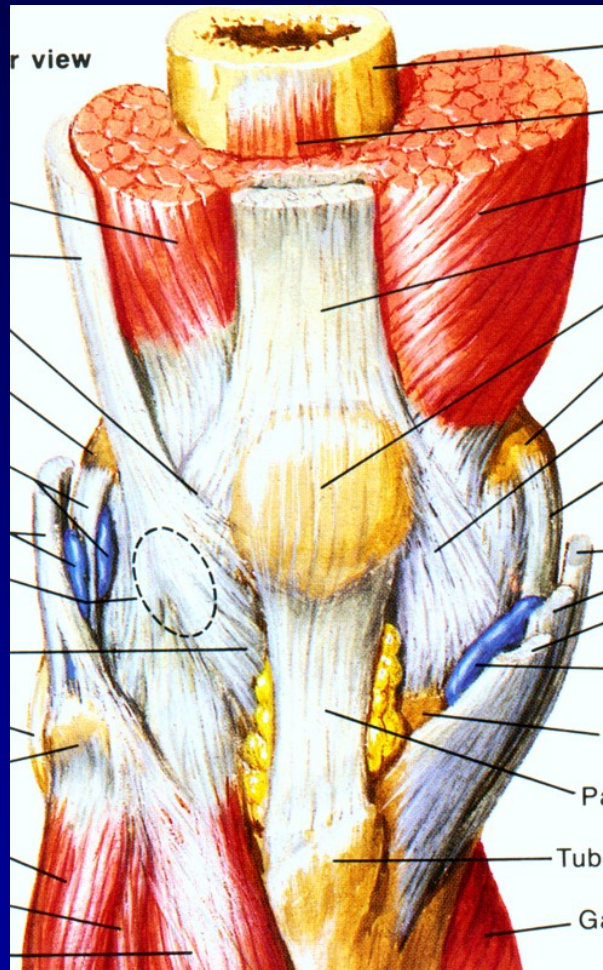


# Stability of the knee joint



**Menisci**

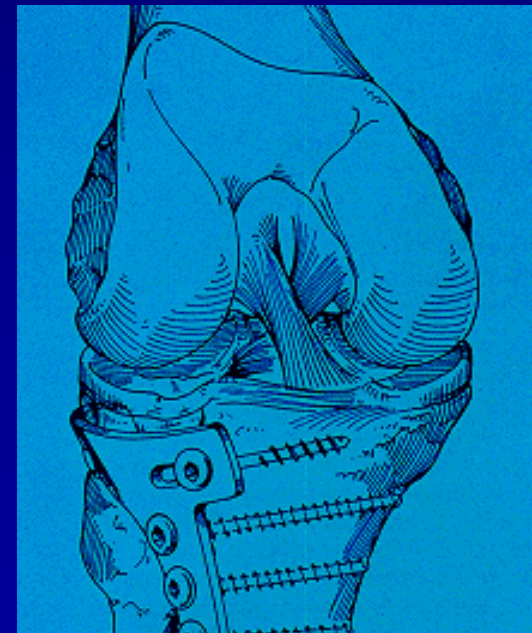
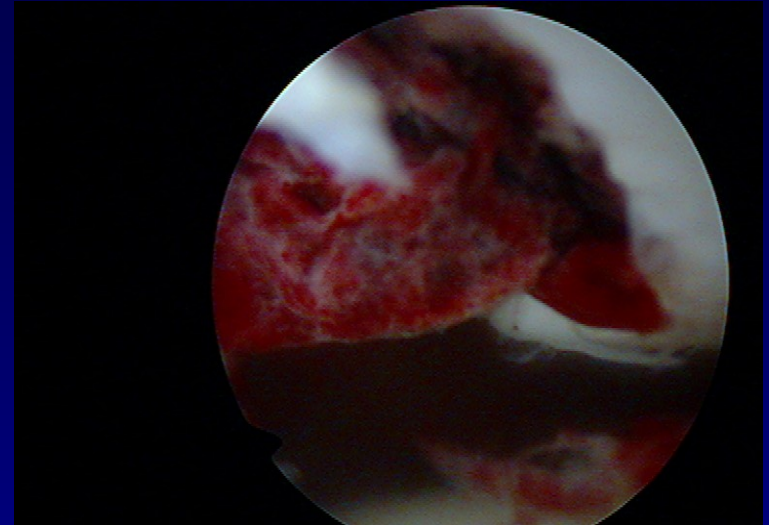
# Stability of the knee



Muscles

# The knee joint

- Traumatology
- Chondropathy
- Degenerative findings



# Traumatology

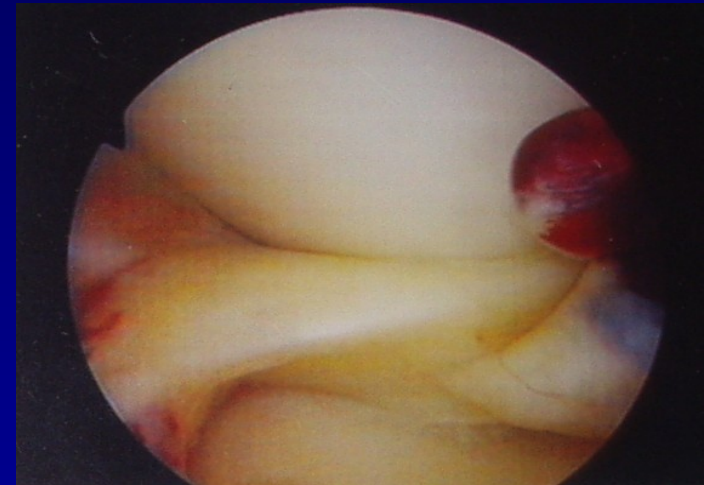
Haemarthrosis

Meniscus lesion

Rupture of ligaments

Dislocations of the patella


Transchondral fractures





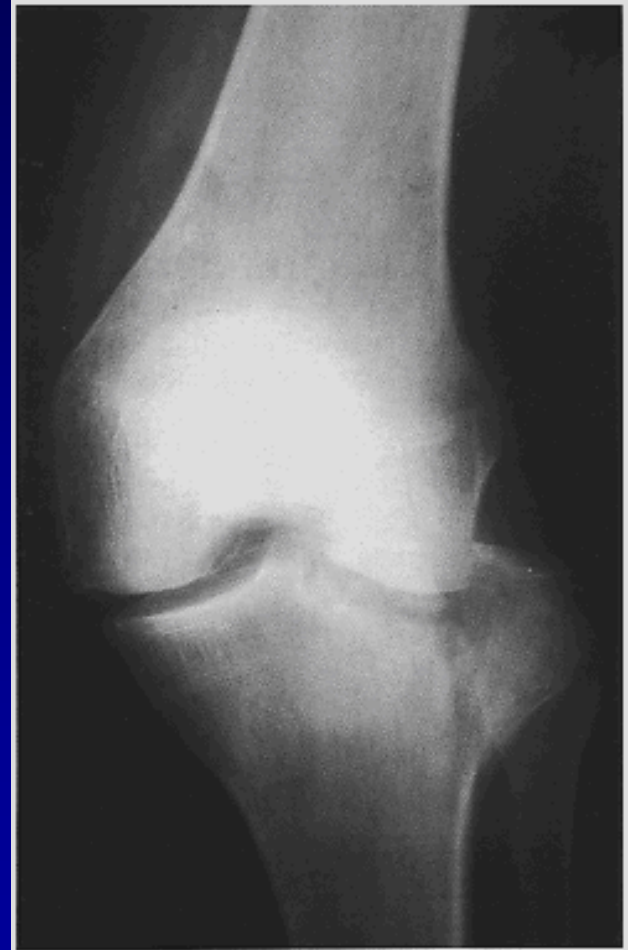# History

- History
- Mechanism of injury



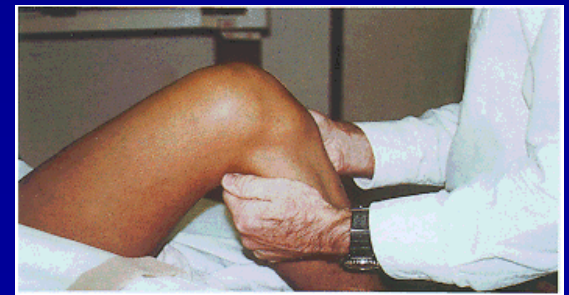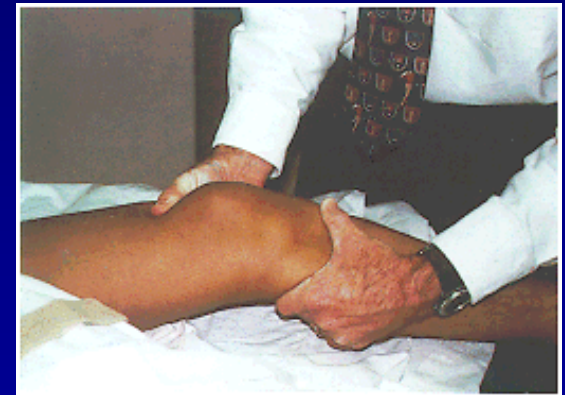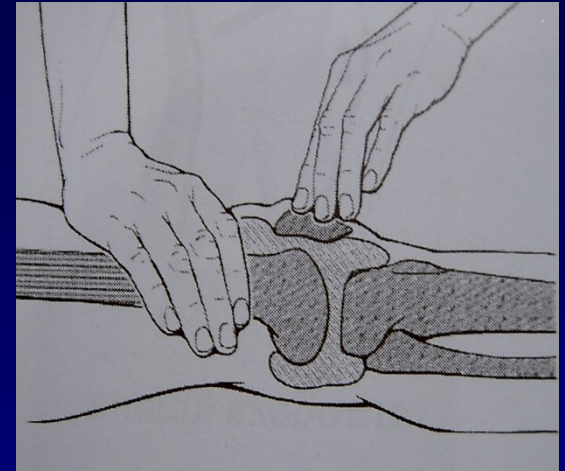
# Examination

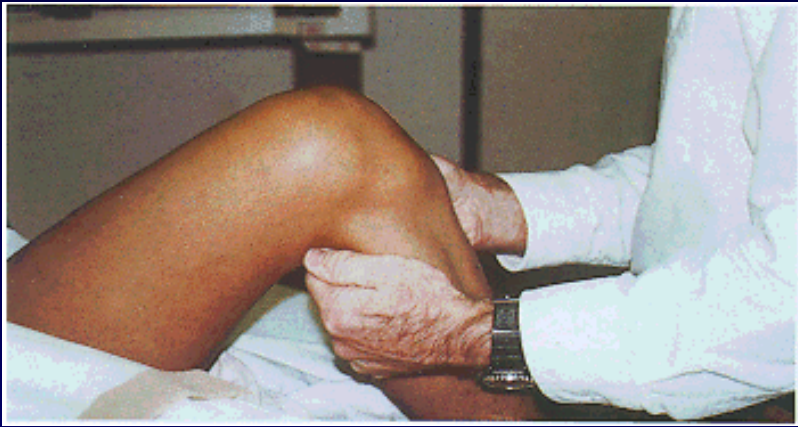- Clinical examination
- Aspiration
- Blood patches
- X- ray
- MRI
- Ultrasonography



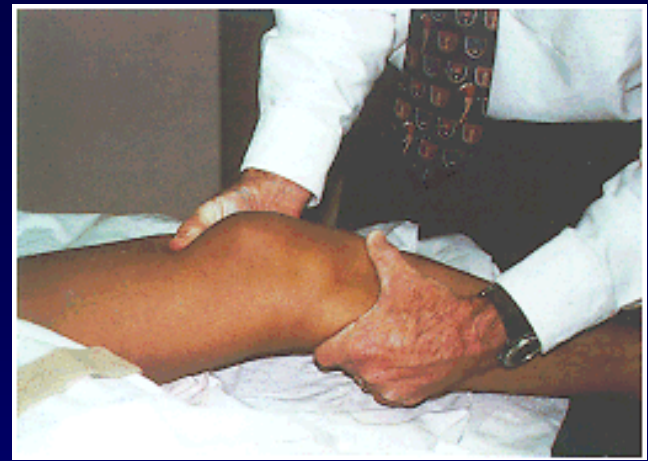# Clinical examination

- Swelling, haematoma
- Effusion
- ROM
- Tenderness
- Stress test for stability
- Maneuvers
- Patella examination

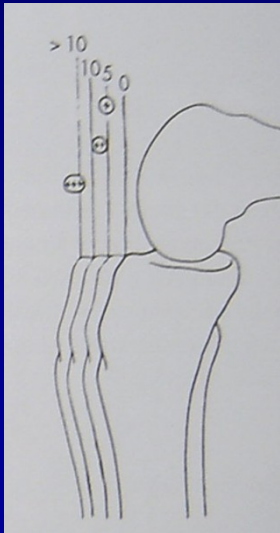




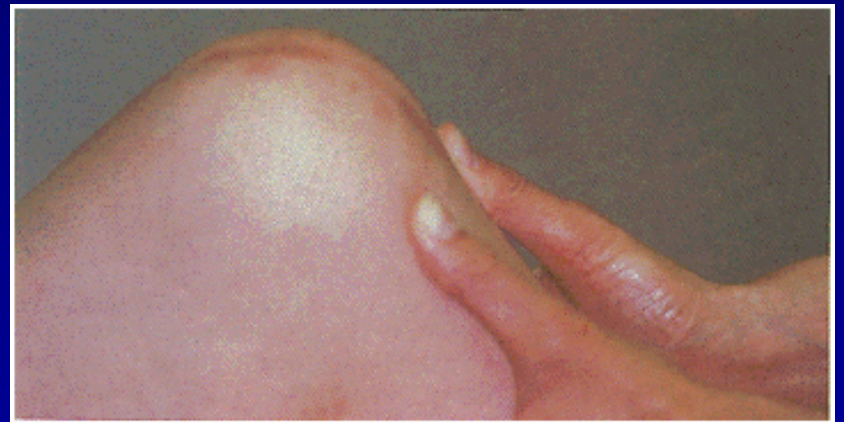Anterior drawer sign



Lachman test

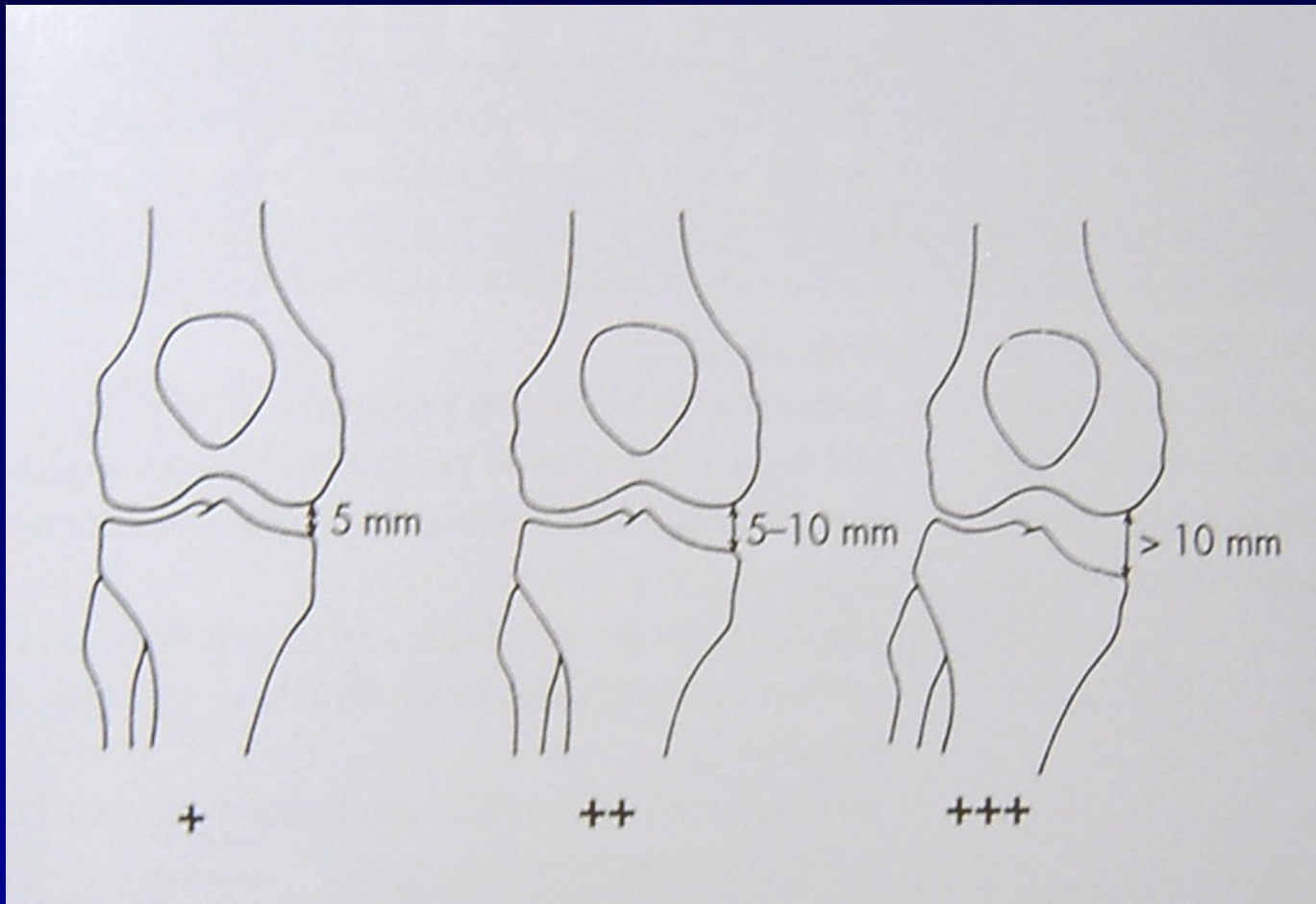


Anterior drawer sign, pivot shift test



Posterior drawer sign





Valgus stress test  
Varus stress test

# Meniscus

Mechanism of injury

Tests: Mc Murray

Steinmann I

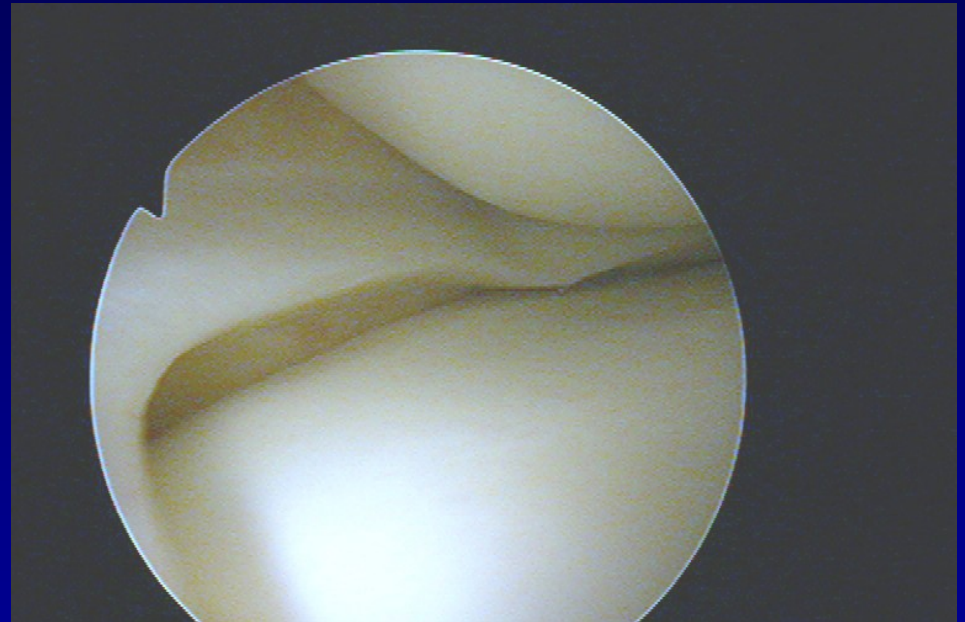
Steinmann II

Appley

Turner

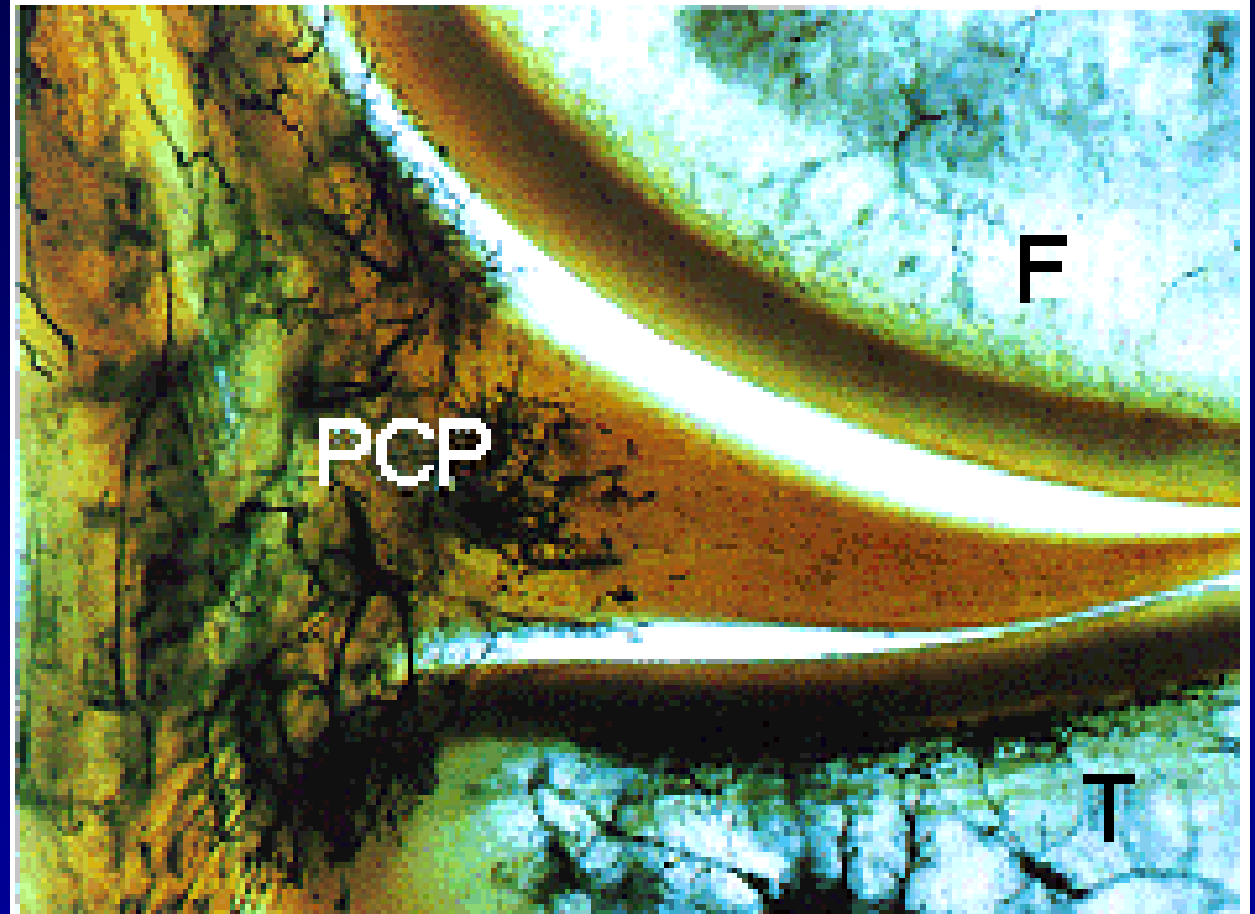
Payer

Childress- squat test



# Meniscus

- Fibrocartilago
- High elasticity
- Paracapsular zone
  - vessels

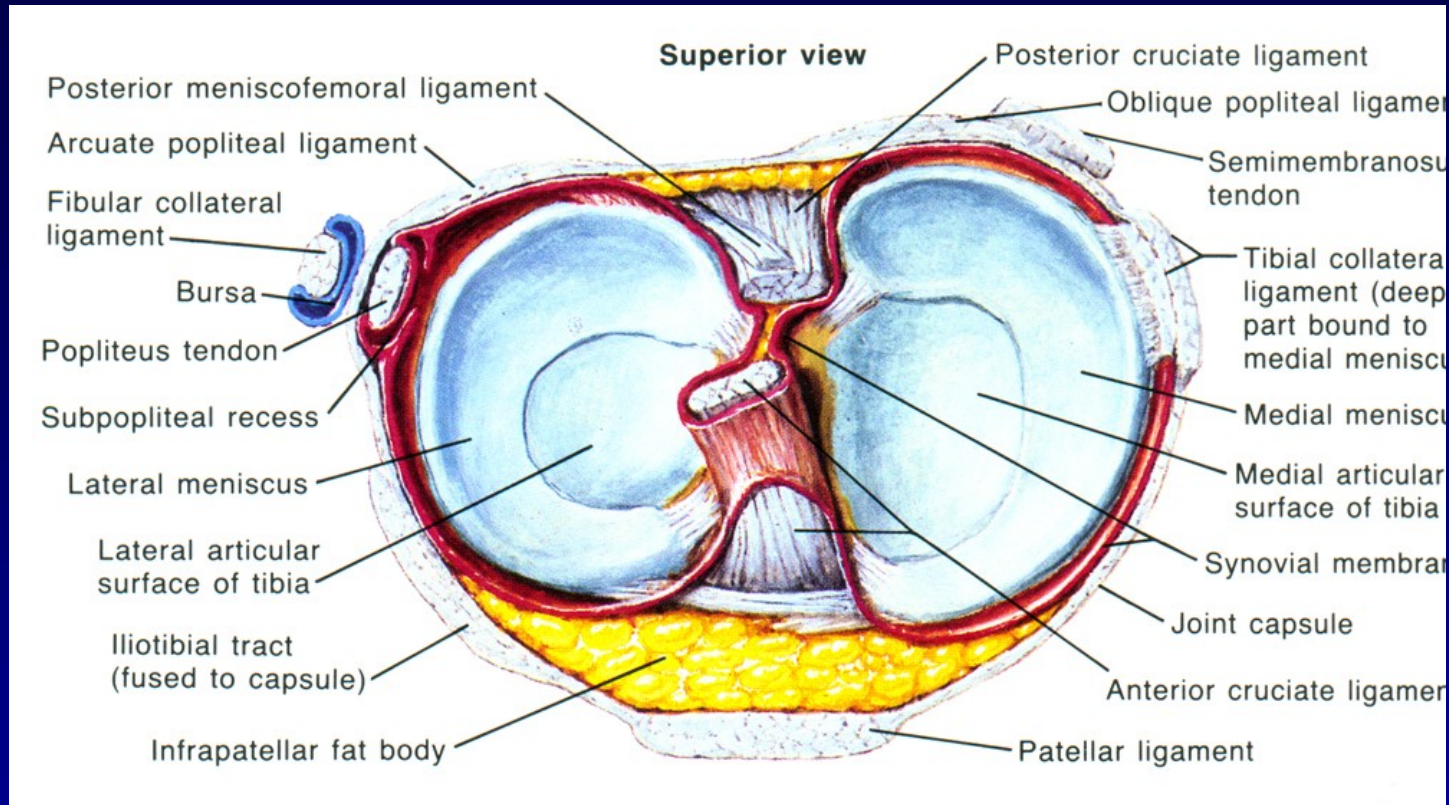


Red zone

red- white zone

white zone

# Functions

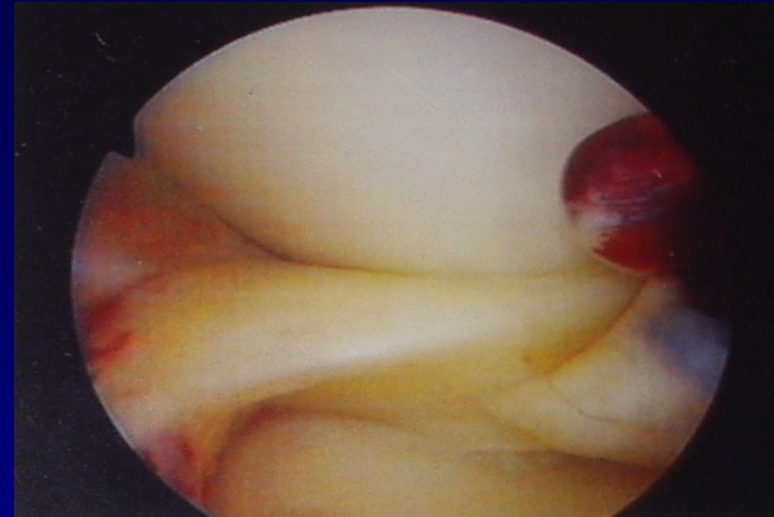


- Bumper
- Stabilisator
- More congruency
- Distribution of synovial fluid
- LM – more mobile
- MM – prone for injury



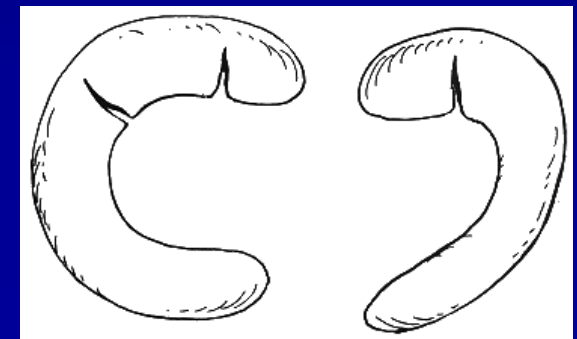
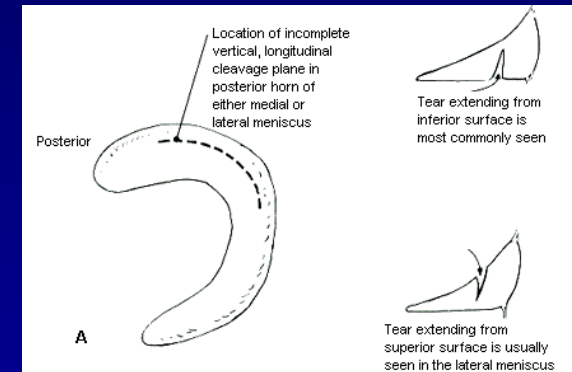

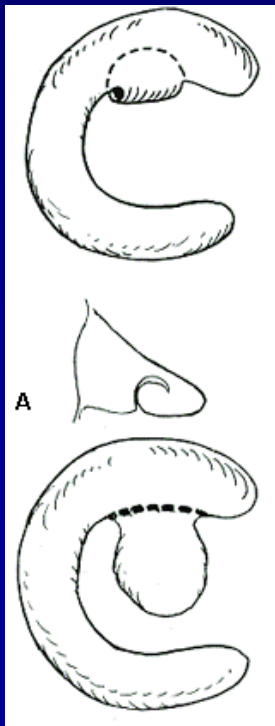
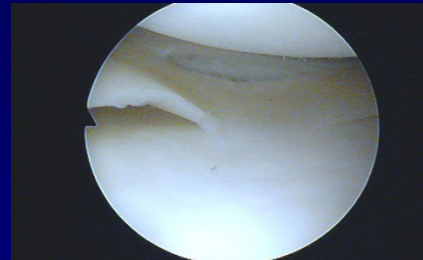
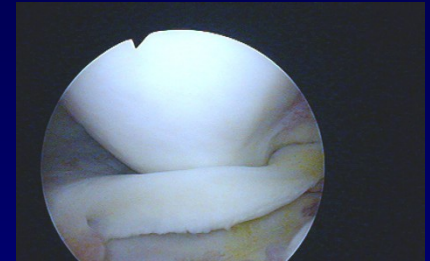
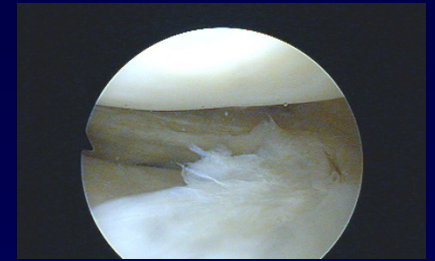
# Ruptures of menisci

- Longitudinal, horizontal, radial
- „bucket handle type“
  - Typical blockage
- Degenerative lesions
- Discoid meniscus



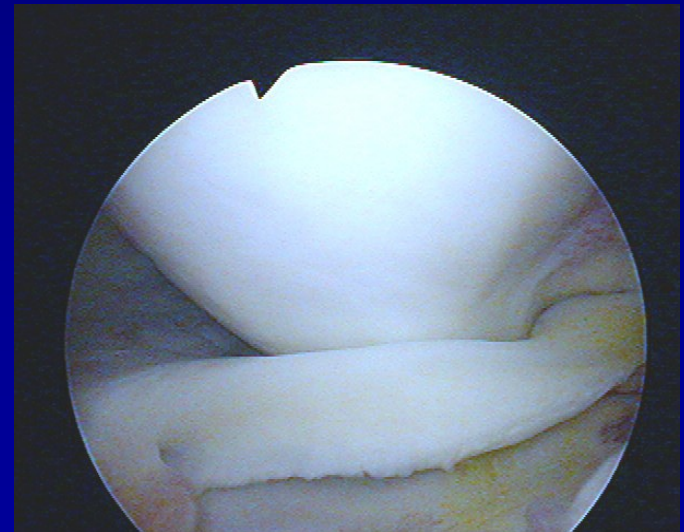
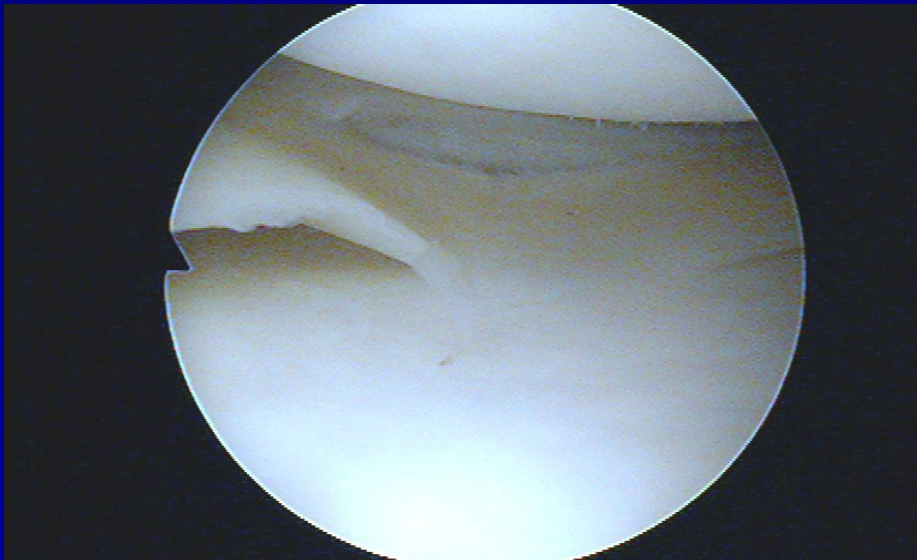
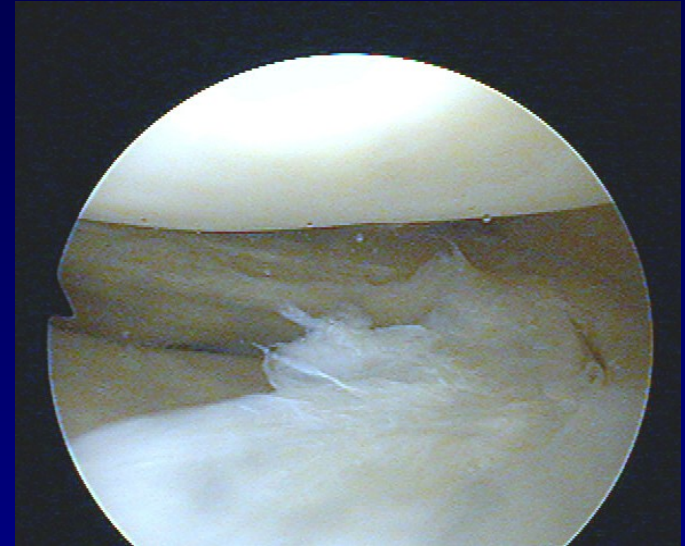
# Ruptury menisků

- longitudinální, horizontální, radiální
- „ucho od koše“
  - typické bloky kolena
- degenerativní léze



# Ruptures of menisci

- Longitudinal, horizontal, radial
- „bucket handle type“
  - Typical blockage
- Degenerative lesions
- Discoid meniscus

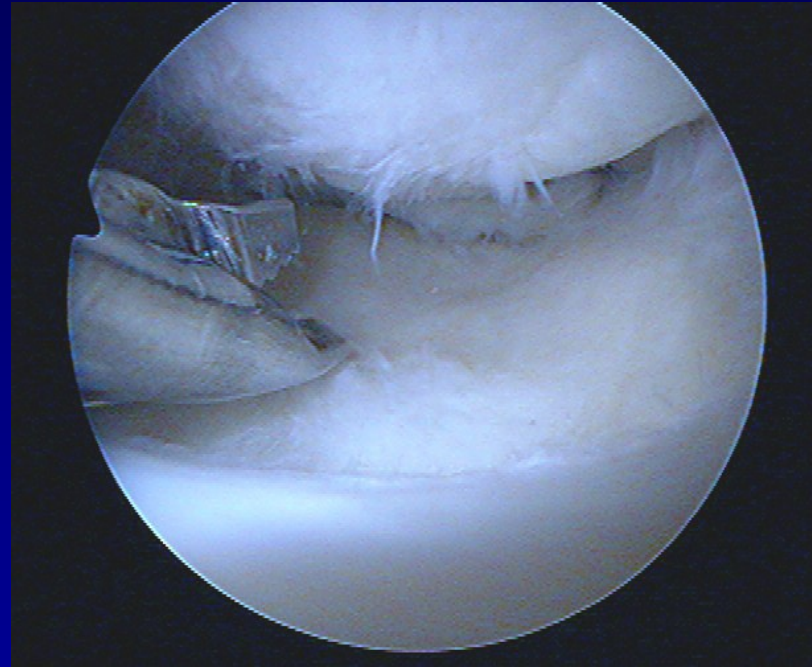




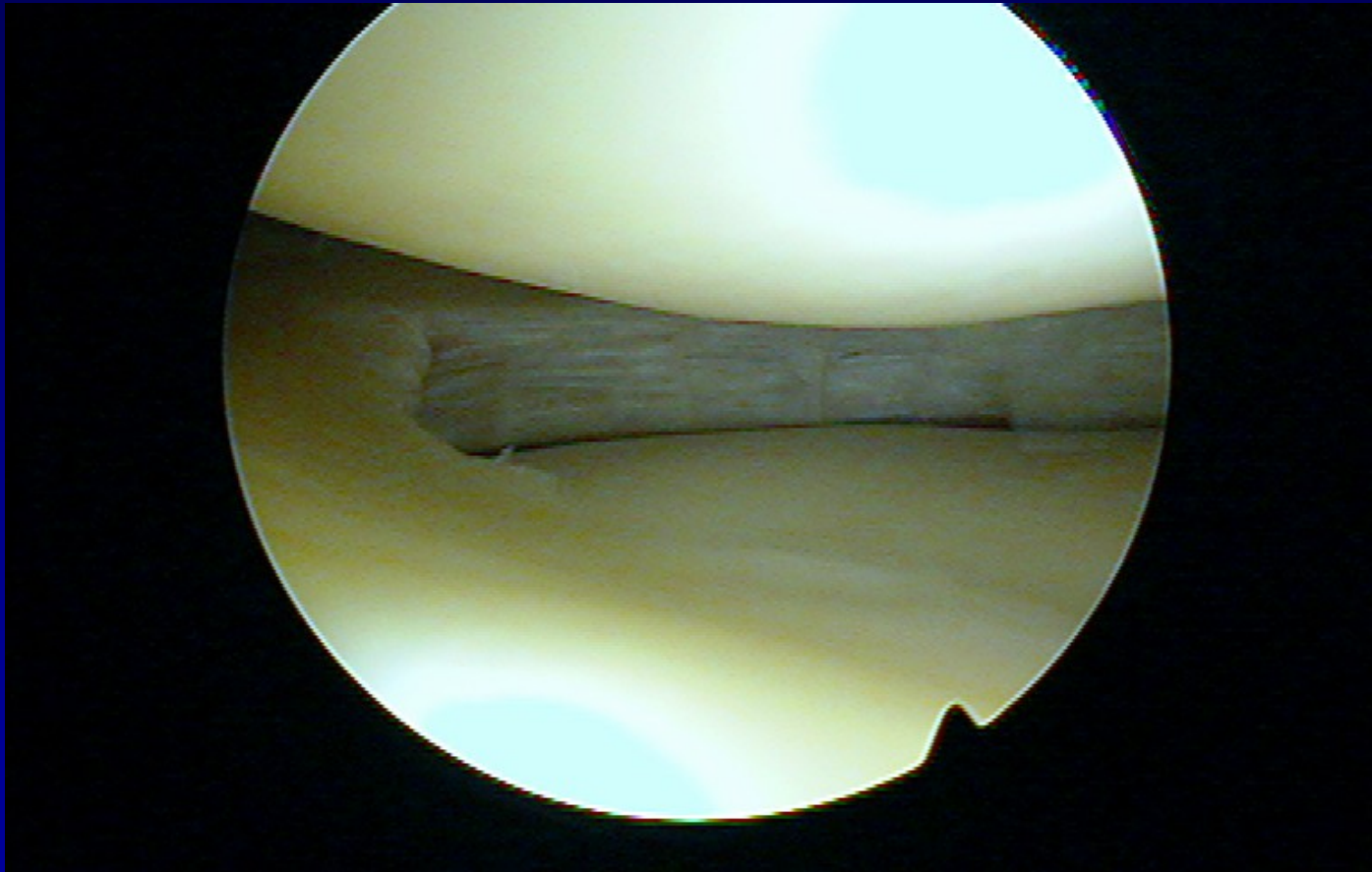
# Meniscus treatment

## Meniscectomy

- partial
- subtotal
- complete

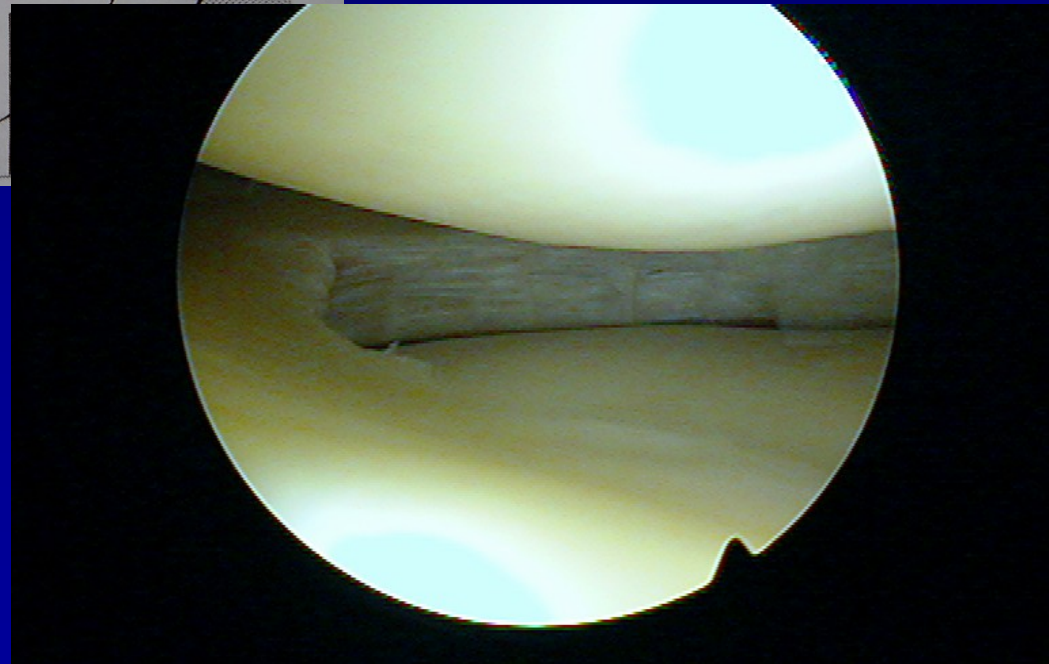
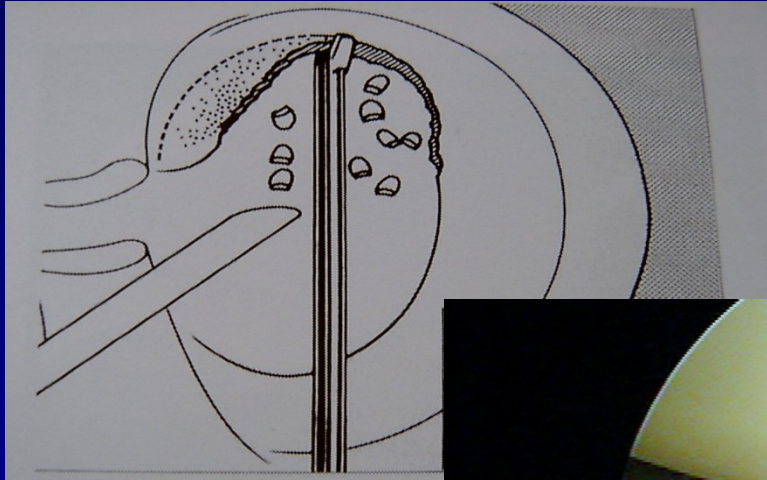


# Partial meniscectomy

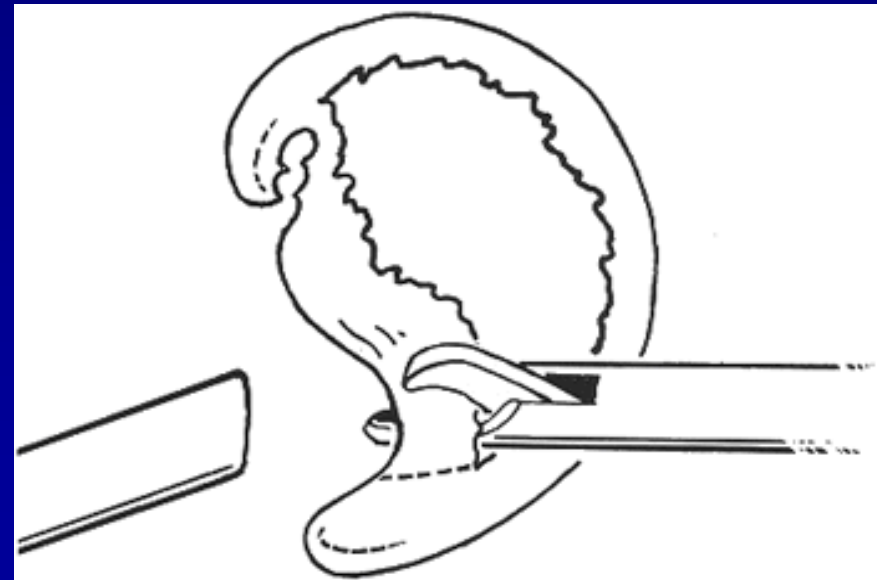
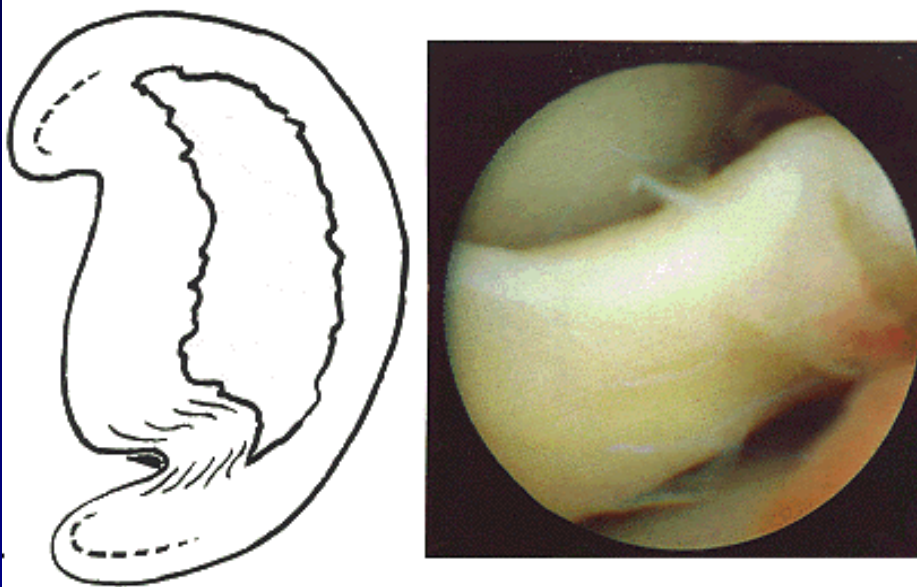




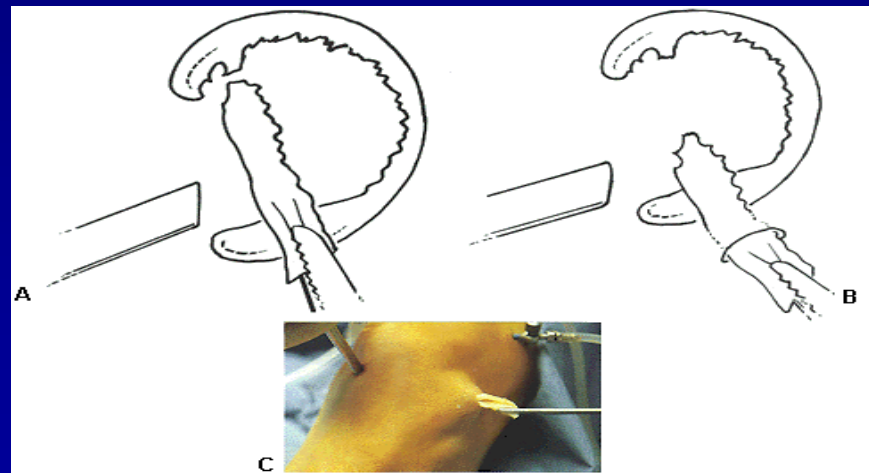
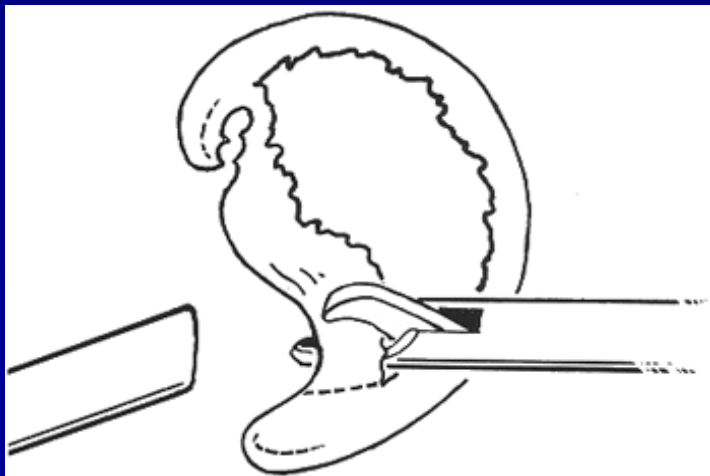
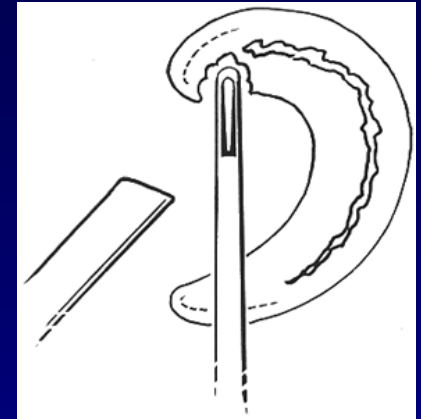
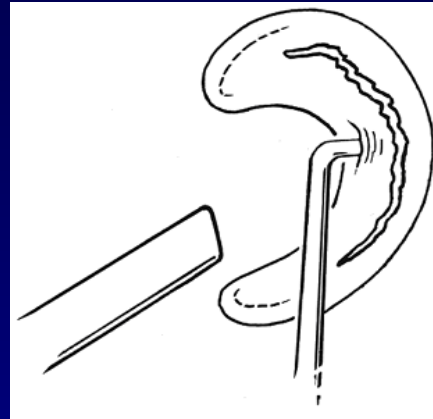
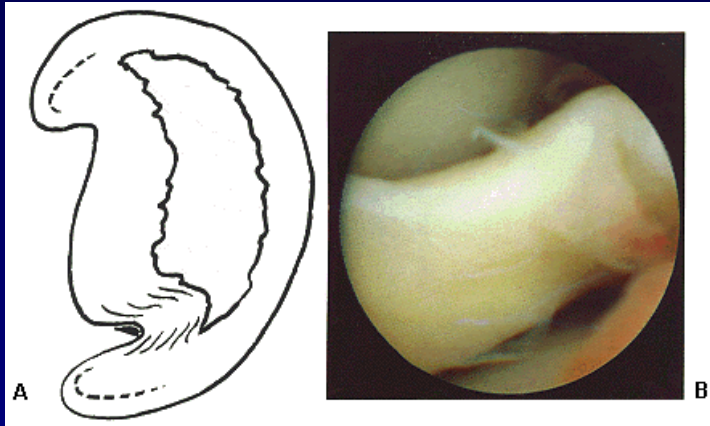
# Parciální menisektomie



# Subtotal meniscectomy



# Subtotální menisektomie

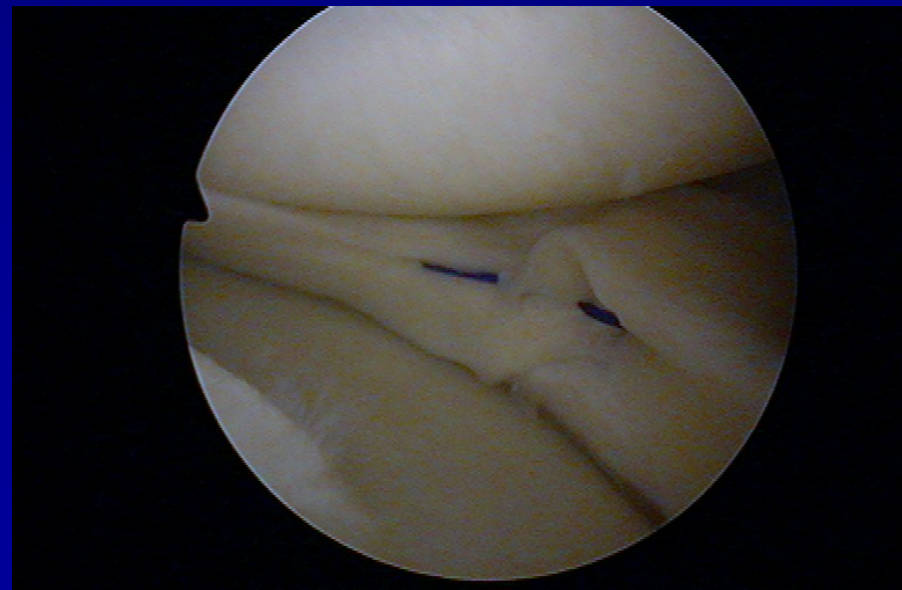
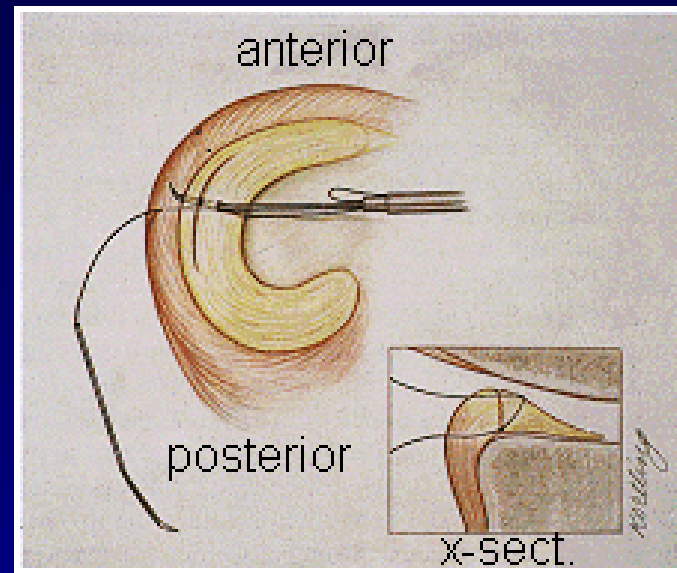


# Suture of meniscus- meniscopexis

outside-in

inside-out

all-inside

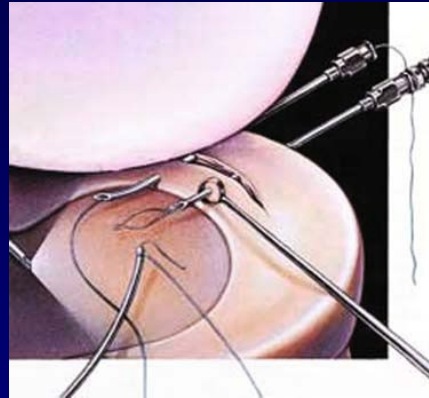




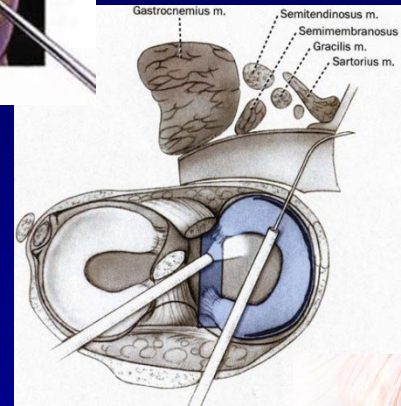
- Limitována kapacita hojení menisku
- Nejlepší výsledky v red zóně
- Trhliny v rozsahu 0-2mm od pouzdra – nejlepší potenciál k zhojení
  - sutura v avaskulární zóně – poop. 75% pac. asympt.  
/ follow-up 51m /
- Vertikální horizontální rpt. - ↑ potenciál k zhojení
- Traumatická vs. degenerativní ruptura

# Techniky sutury

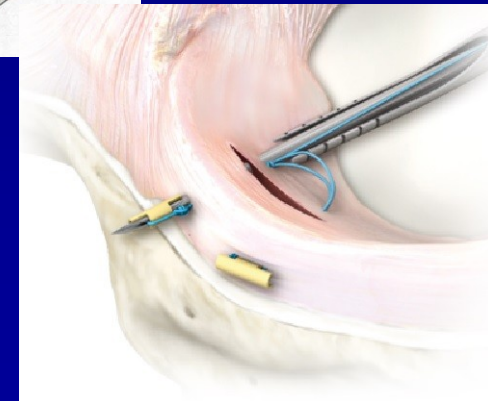
Outside – in



Inside – out

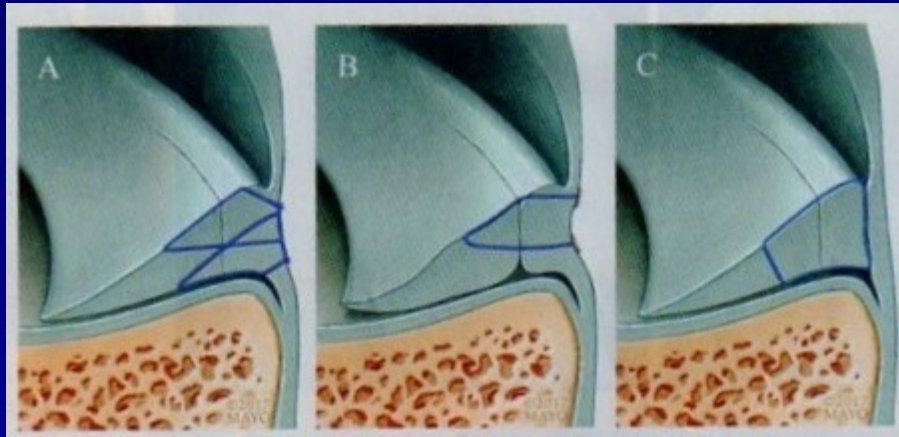


All – inside



# Vertikální longitudinální ruptura

- Resekce vede k 3x ↑ kontaktnímu tlaku
- Zlatý standard – inside-out
- Dop. vertikální matracový steh, odstup 3-5mm
  - biomechanicky výhodnější než horizontální steh



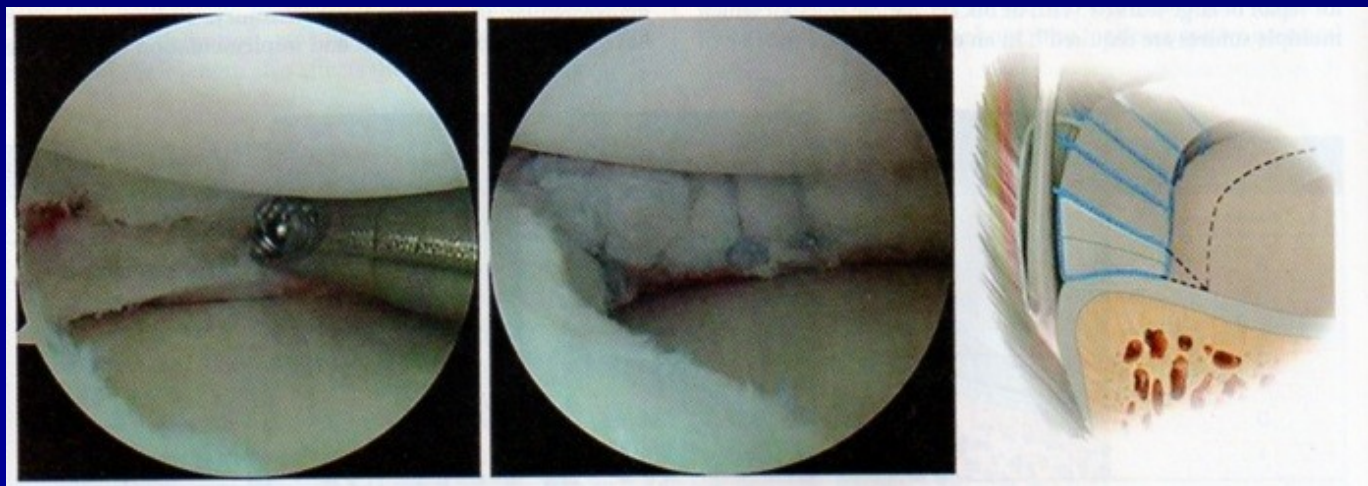- A: Inside-out B: All-inside C: All inside knot tying tech.

# Horizontální ruptura

- Nevede k ↑ tlaku
- Resekce 1 lišty => redukce kontaktní plochy o 59 % => ↑ tlaku
- Sutura horizontální rpt. snižuje kontaktní tlak k minimálním hladinám
- Menší potenciál k zhojení
- Snaha o zachování obou lišt menisku
- Healing rate 78,6 %

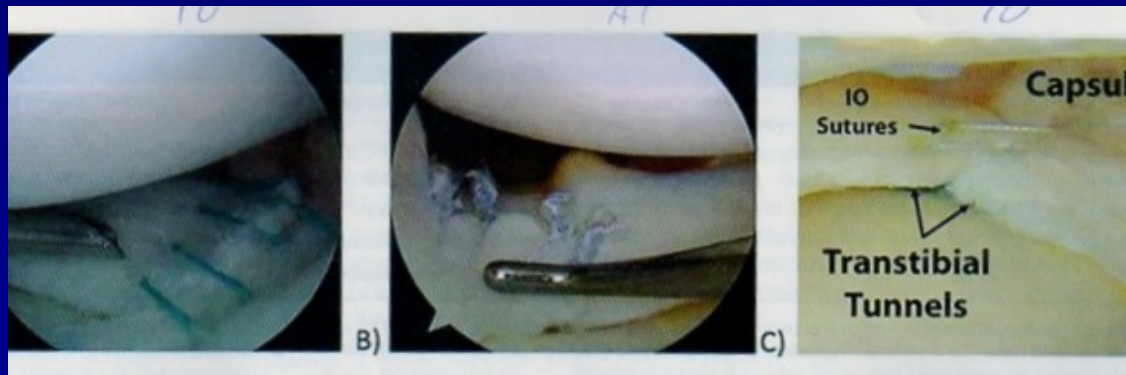


- Excelentní výsledky zhojení u mladých pac.
- All – inside – kompresní cirkumferentní steh po obvodu léze



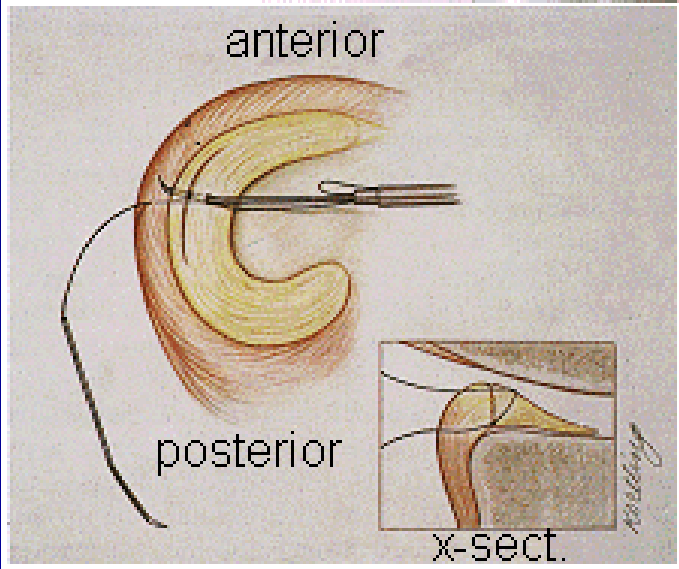
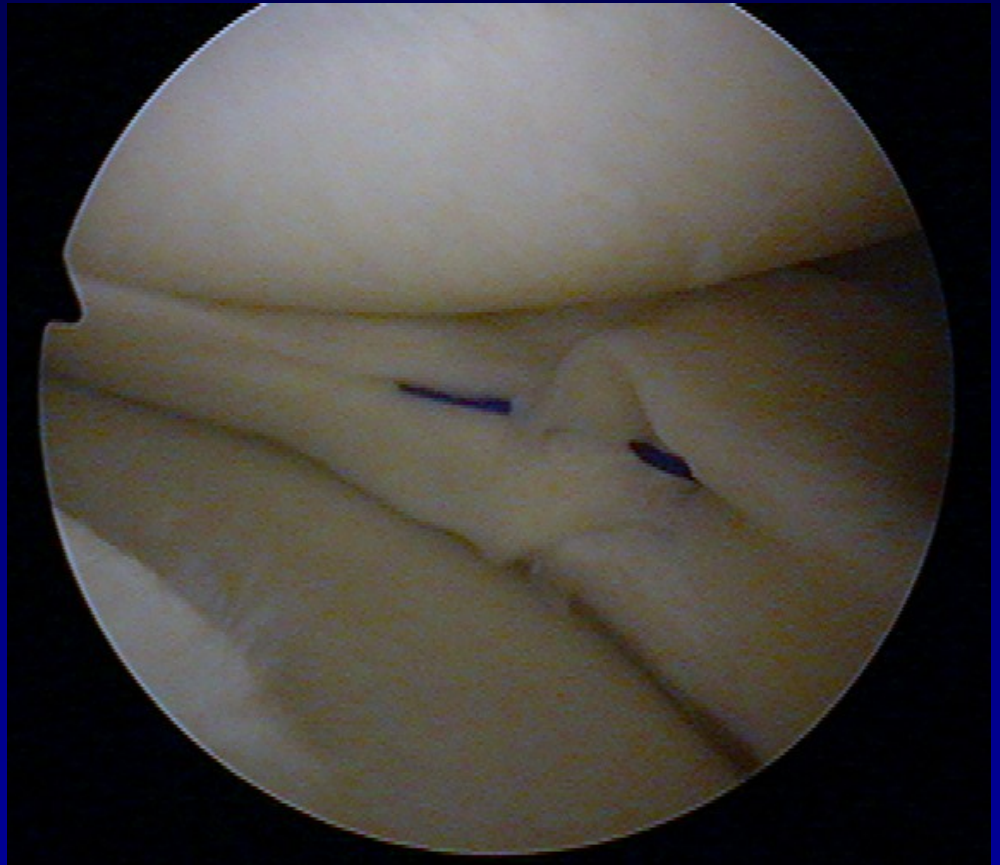
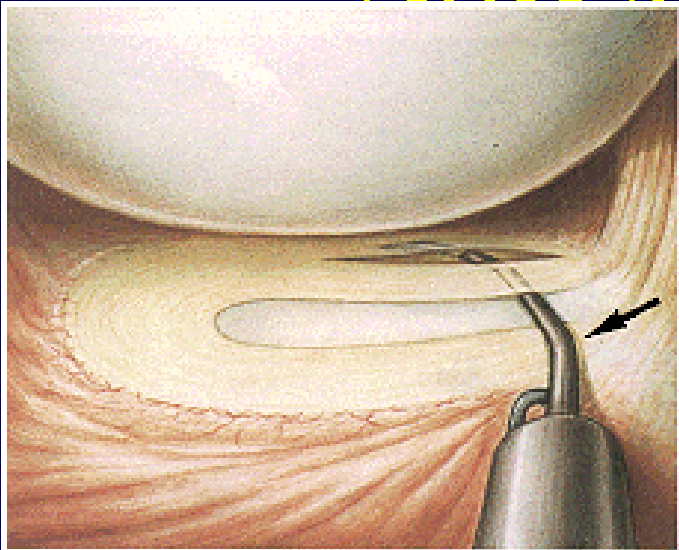
# Radiální ruptura

- Rpt. 60 % centrální zóny nemá vliv na  $\uparrow$  tlaku  
- parc. menisektomie
- Rpt 90 % siginifikantně  $\uparrow$  tlak  
- sutura

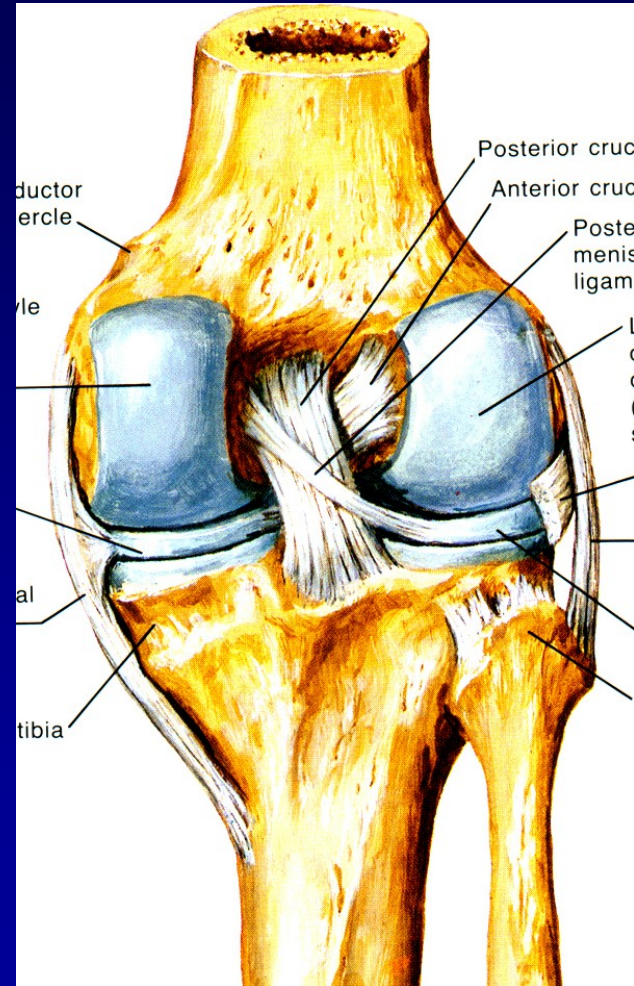
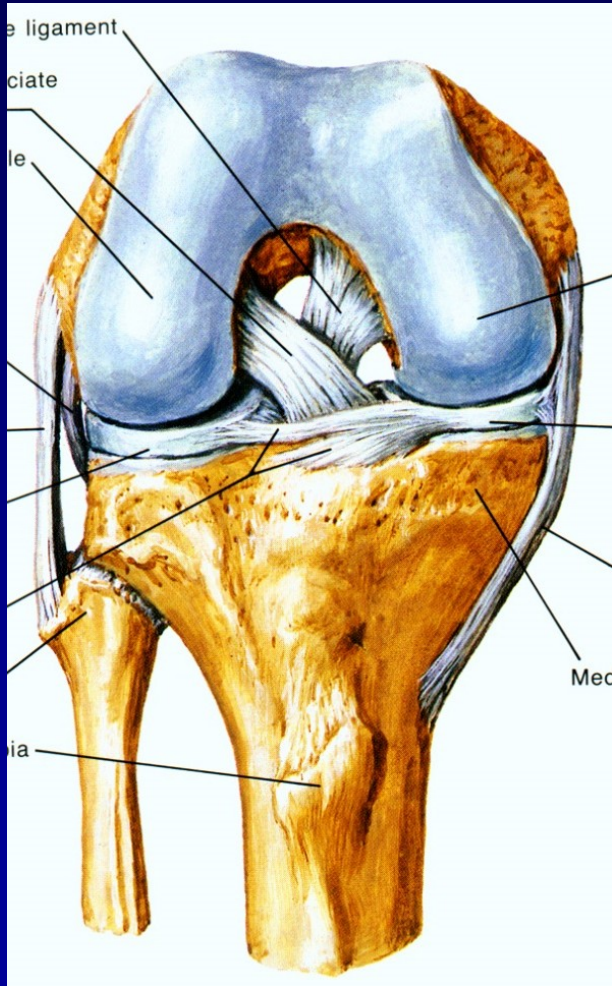


- A: Inside-out -horizontální matracový steh
- B: All-inside knot tying
- C: Transtibiální technika

# ASK sutura menisku



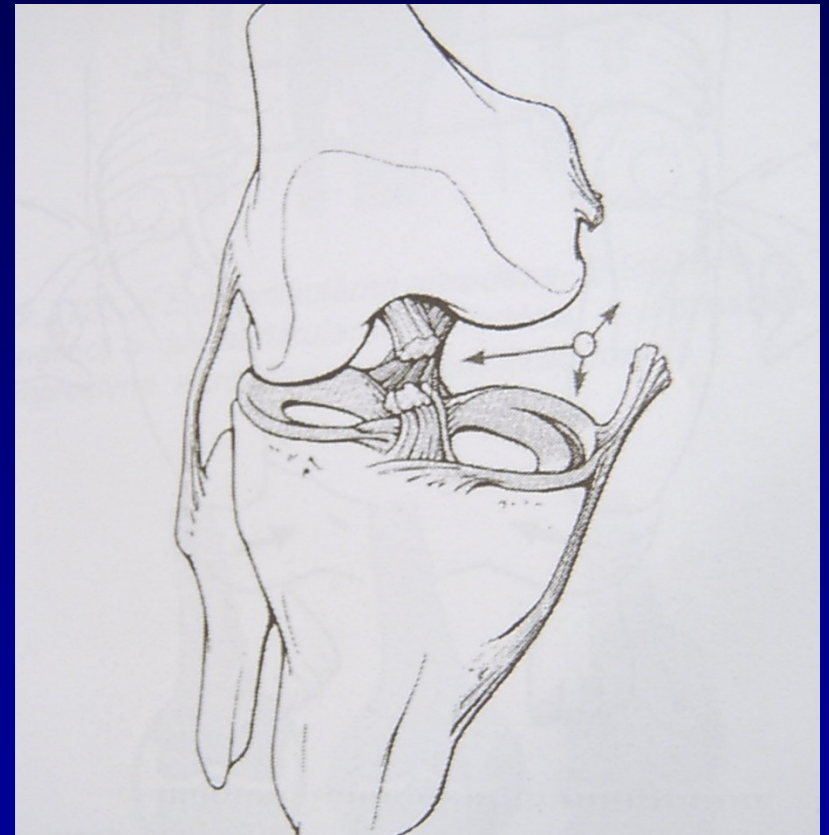# Ligaments- ACL, PCL





# Rupture of ligaments

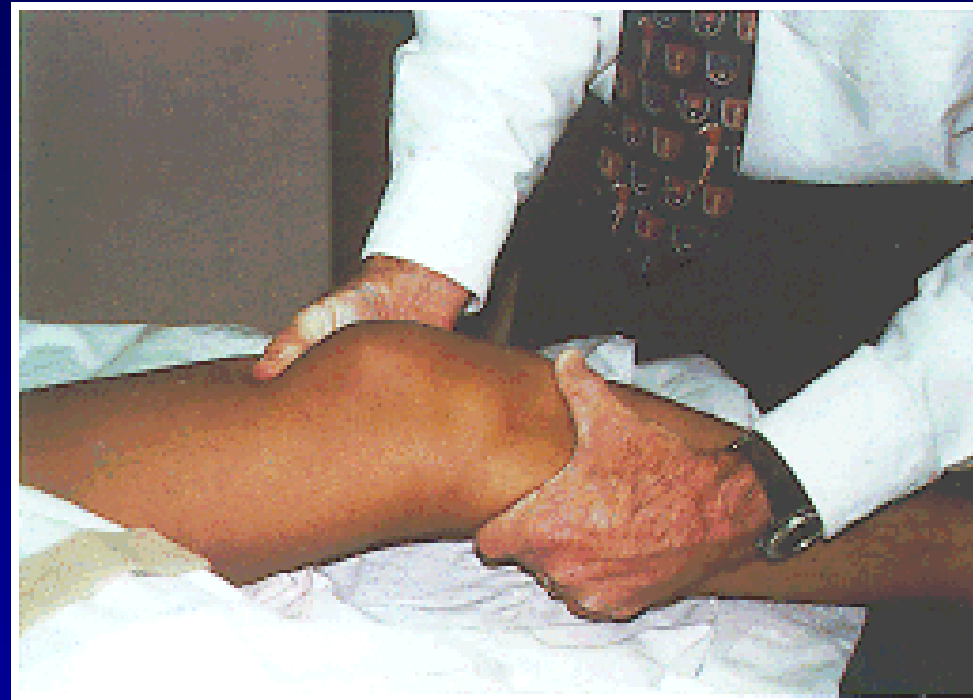
- **Sprain**
- **partial rupture**  
**total rupture**
- Mechanism of injury
- Tests of stability



„Unhappy trias“

# Rupture of ACL

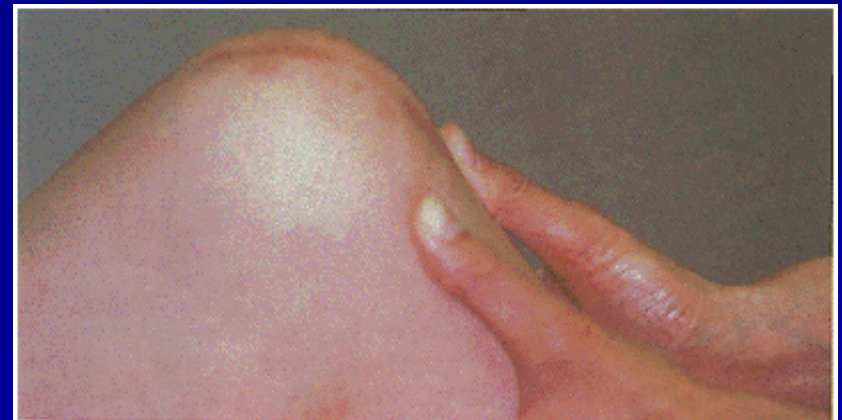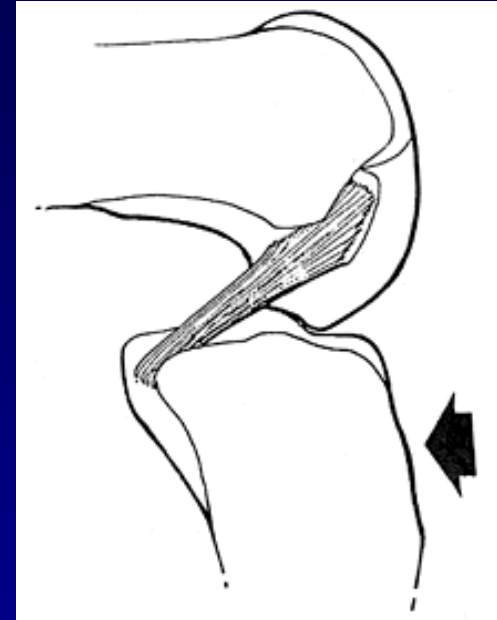
- Tests of stability
- Lachman test
- Anterior drawer sign
- Pivot-shift test



Lachman test

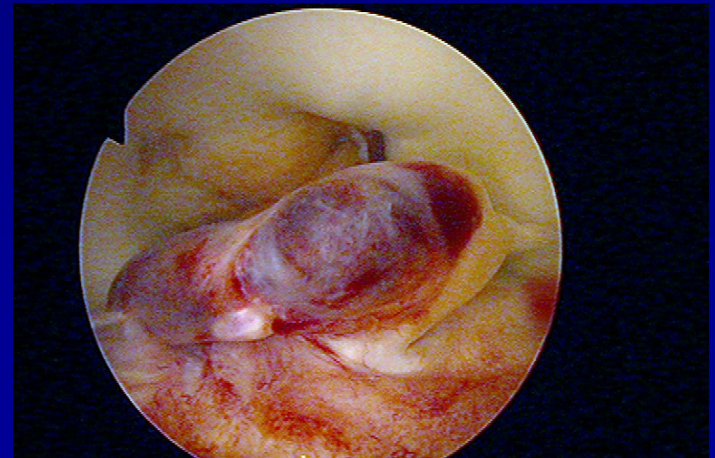
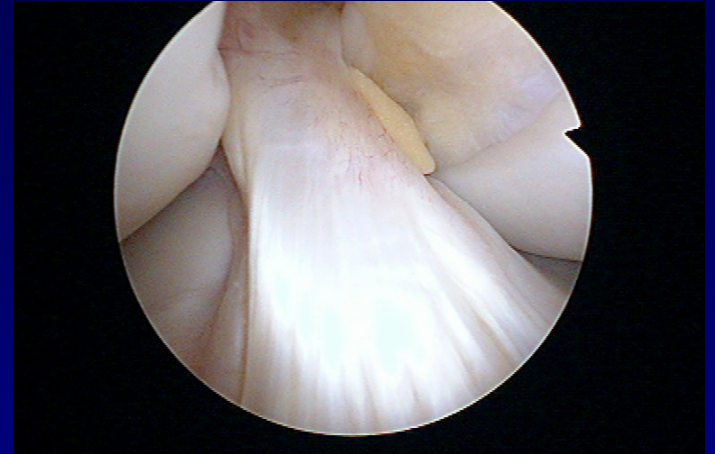# Rupture of PCL

- In **dashboard injury**
- Posterior drawer sign



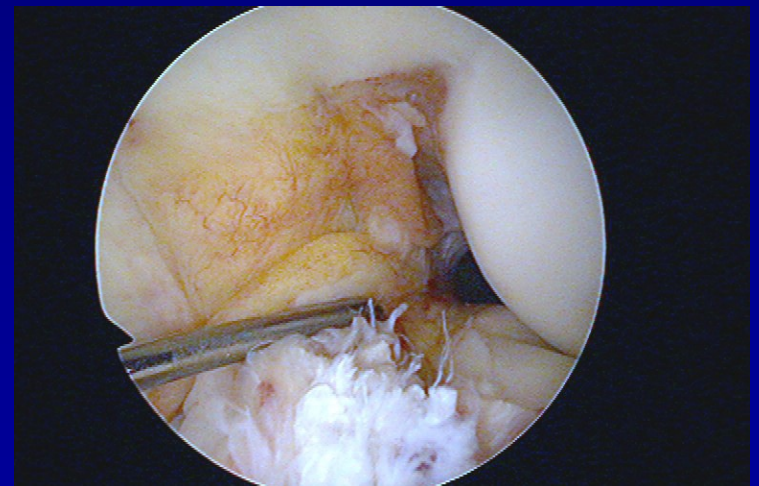
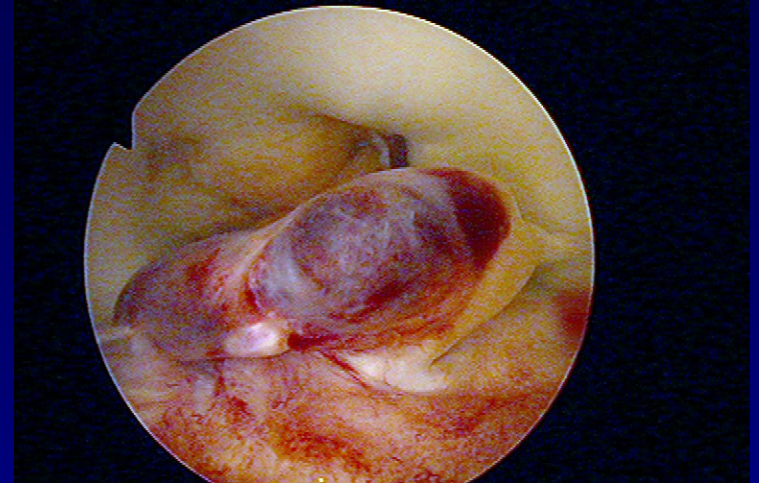
# Rupture of ACL

- Frequent injury



# Acute rupture of ACL

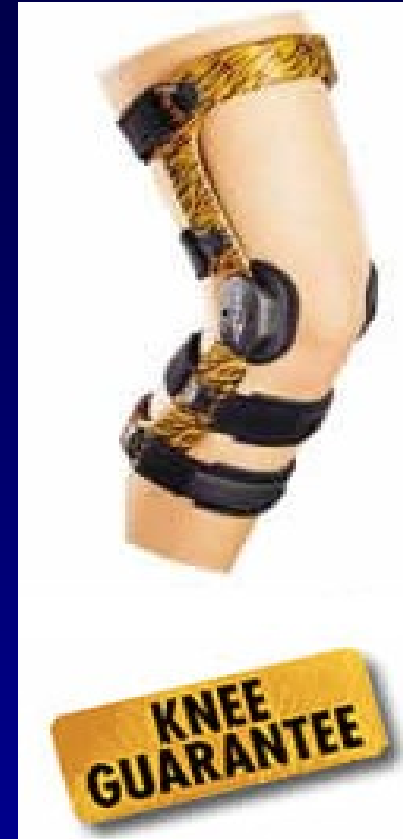- Debridement
- Physiotherapy
- Limited activity
- Orthosis







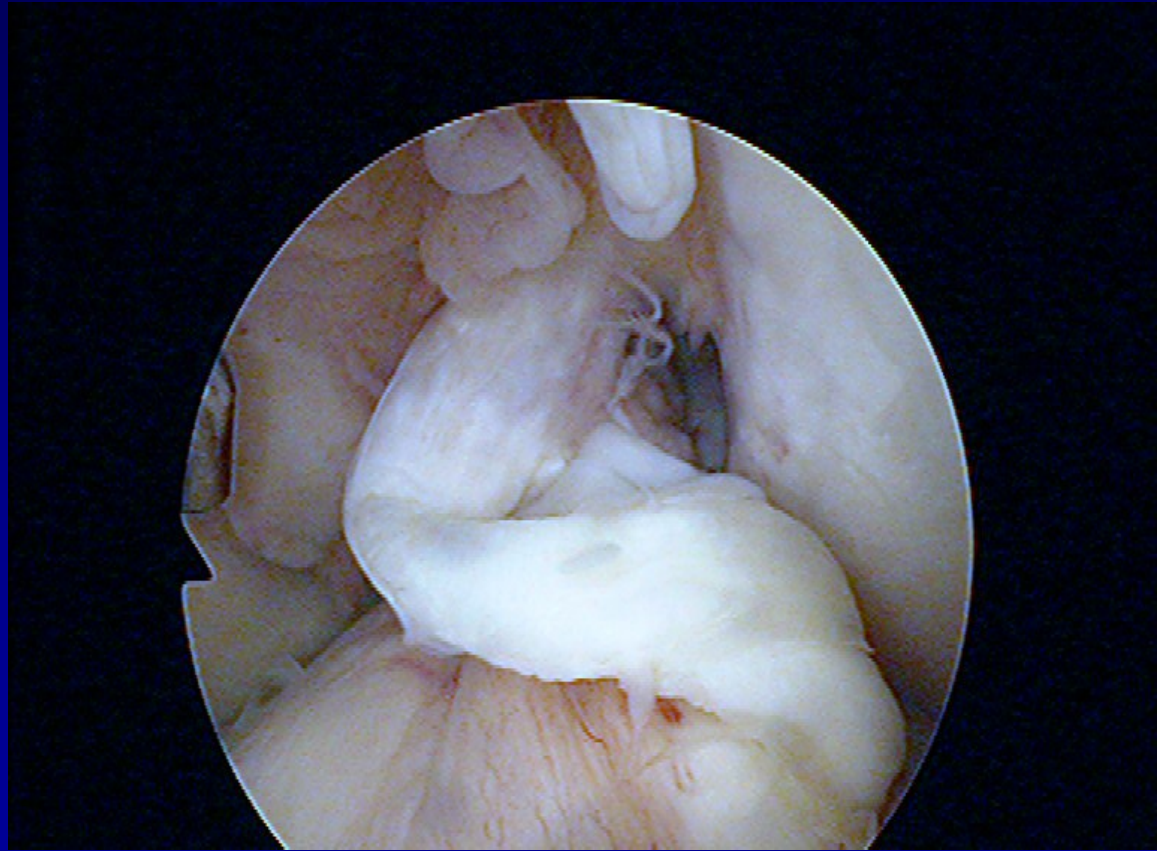

Physiotherapy



Orthosis

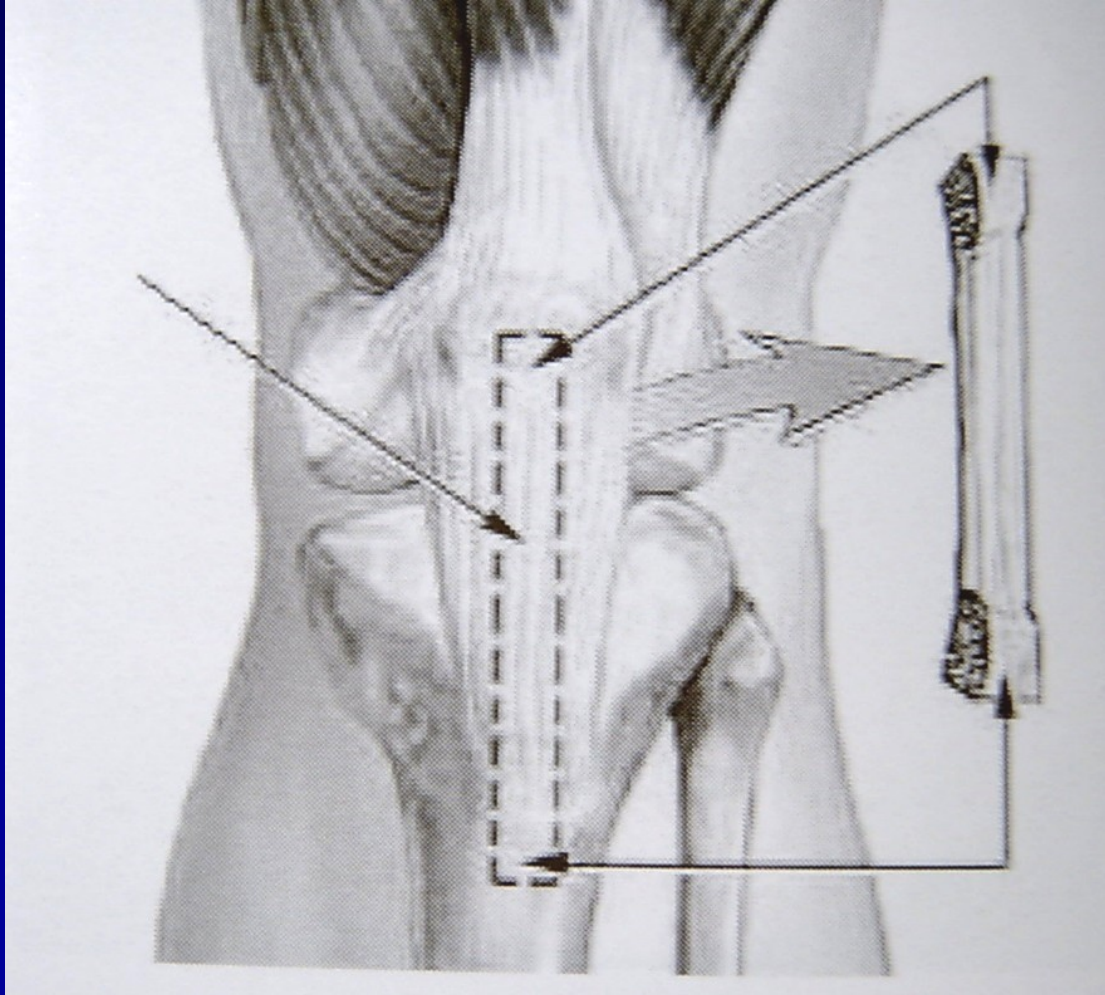
# Indication for reconstruction

- 1/3 of cases



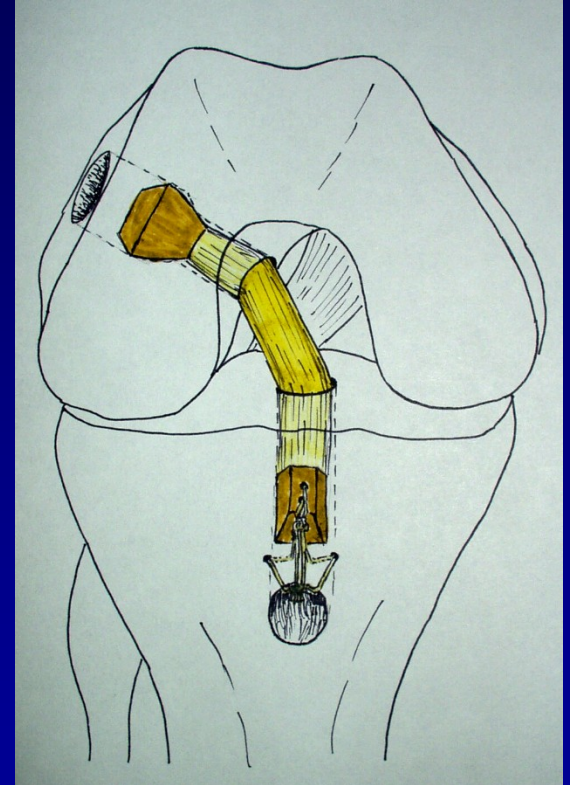
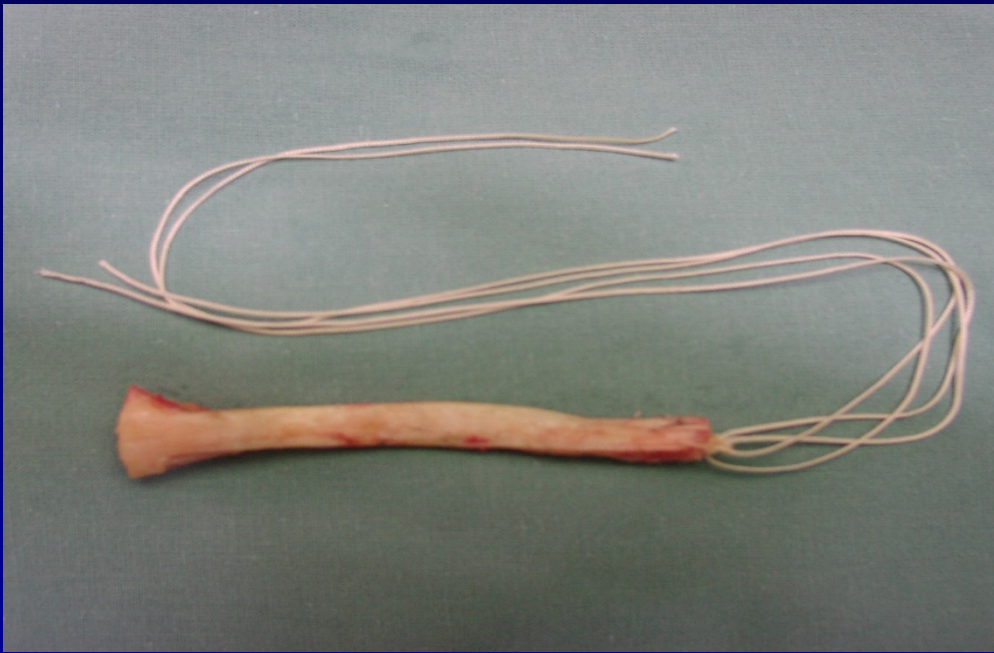
# BTB graft

- Bone-Tendon-Bone



# BTB graft

- Bone-Tendon-Bone

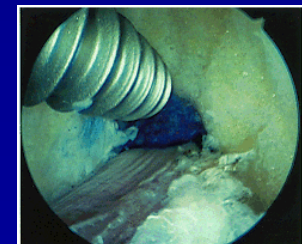
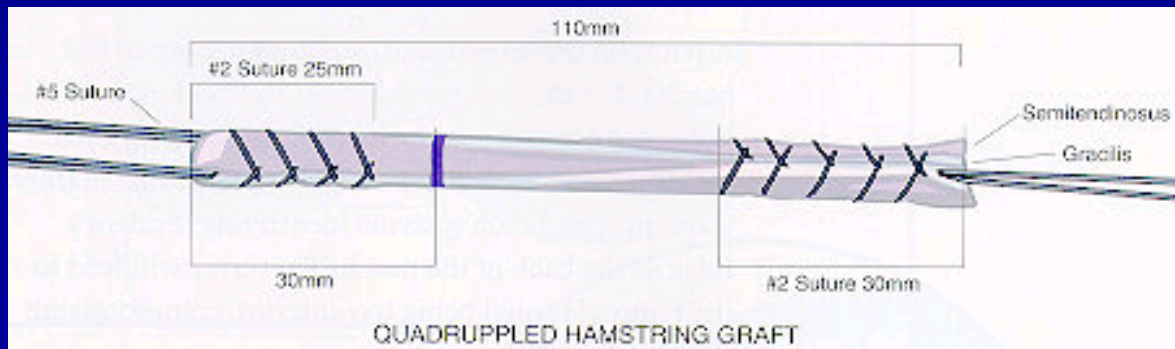
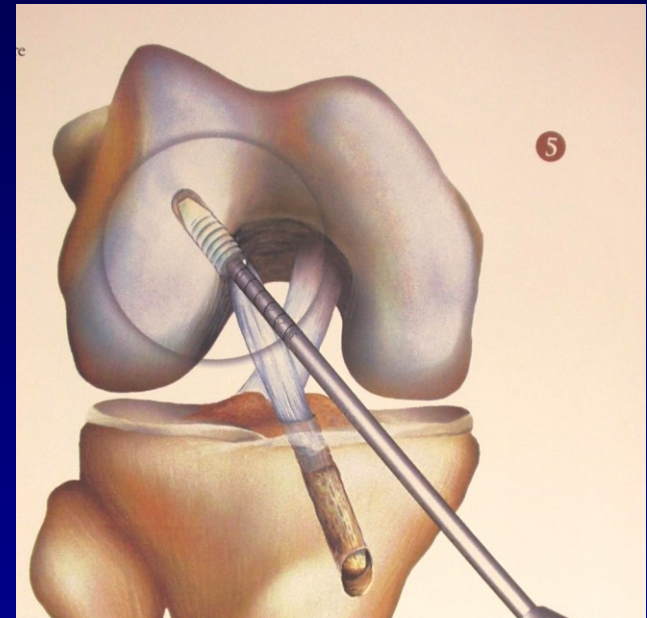
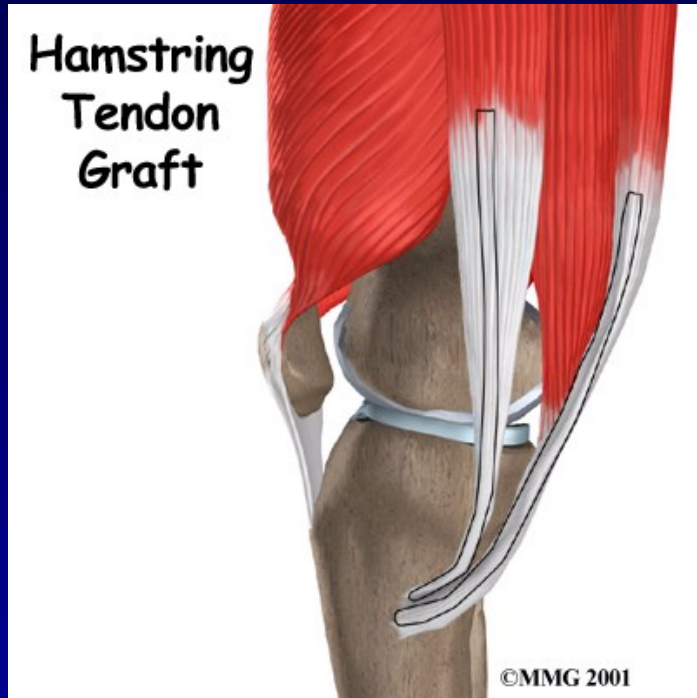


Press fit technique



# Hamstrings

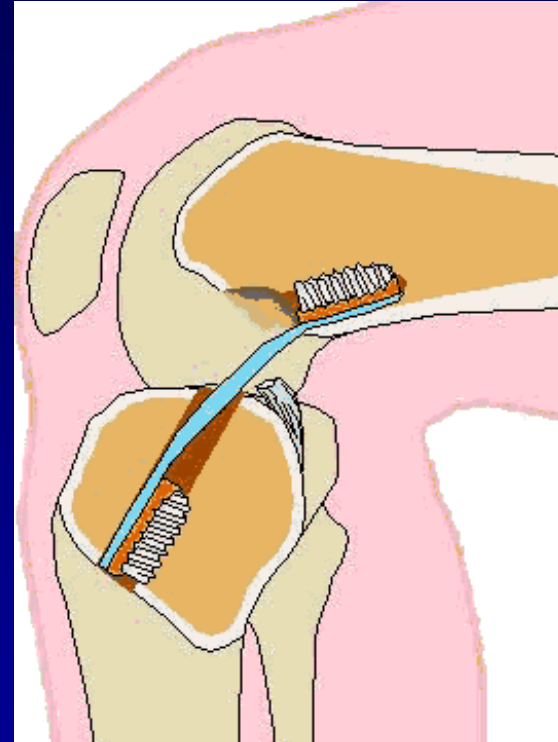
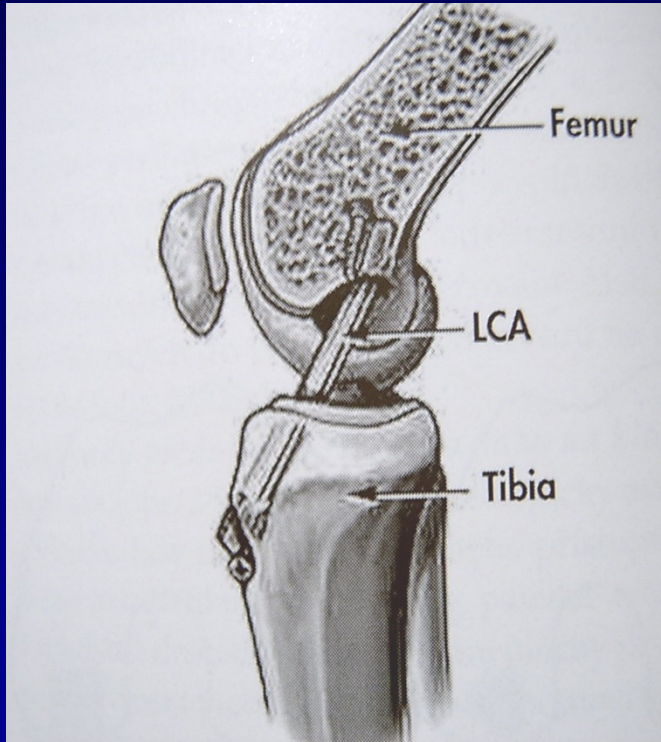
(m. semitendinosus + m. gracilis)



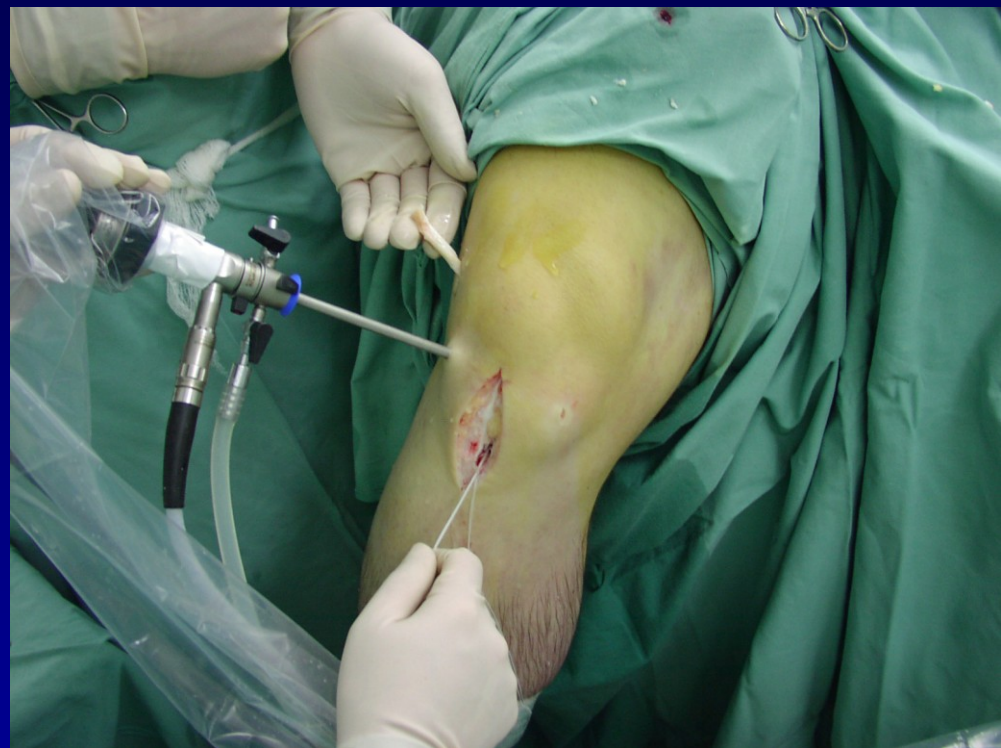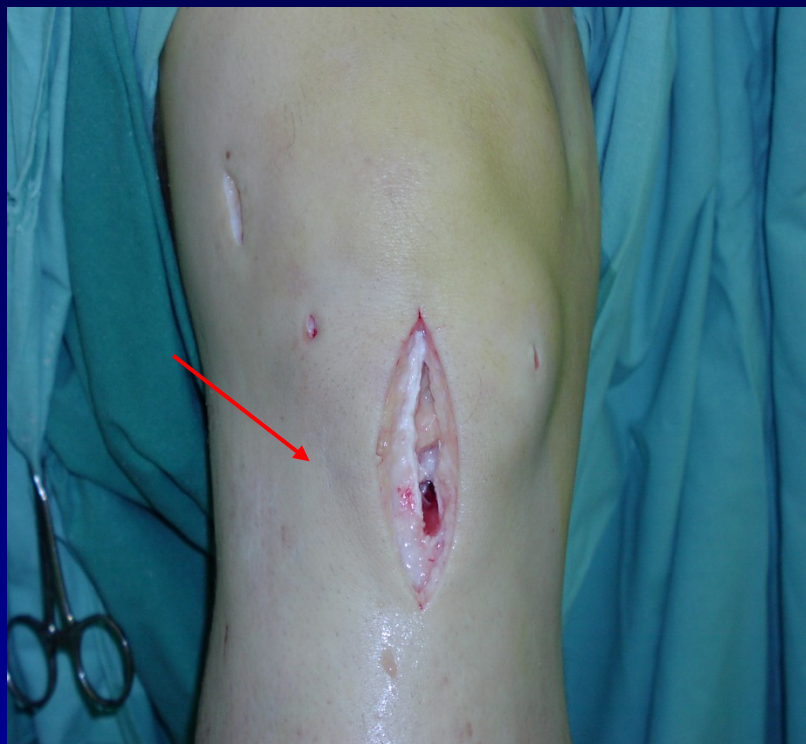Fixation by screws



# Technique

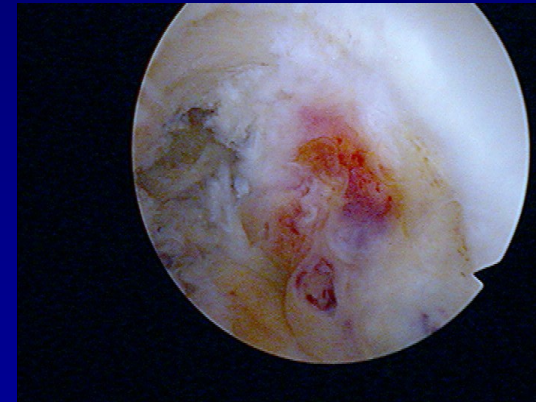
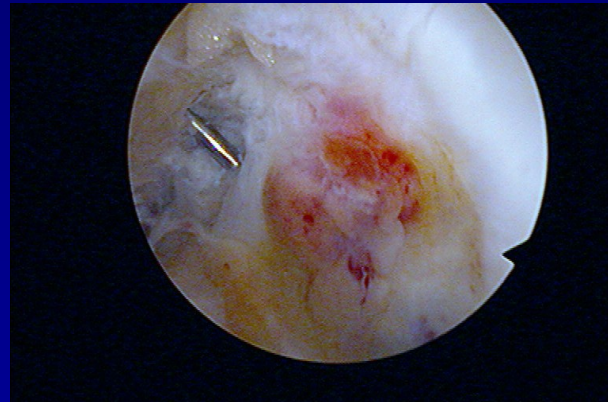
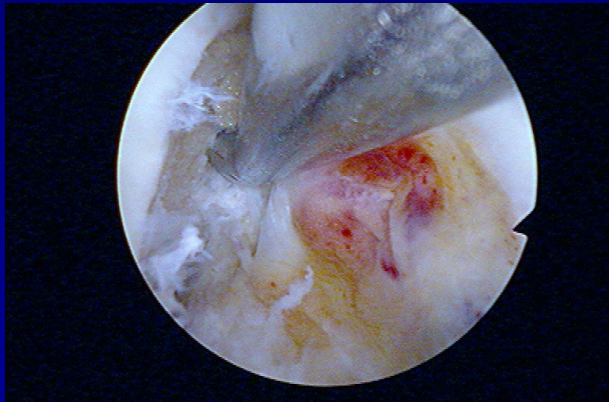
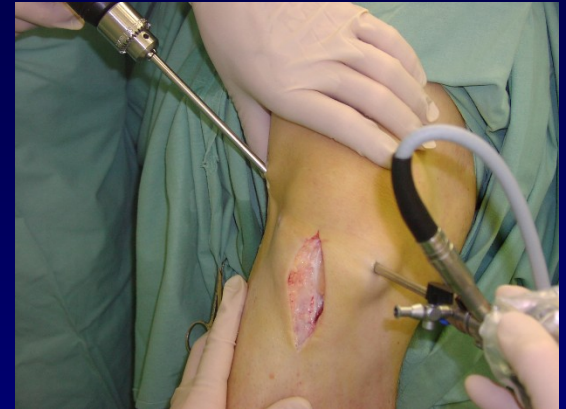
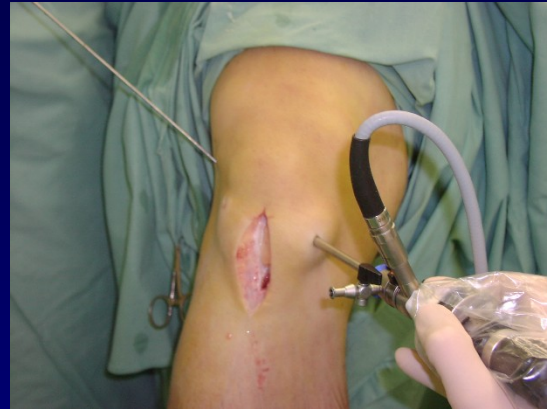
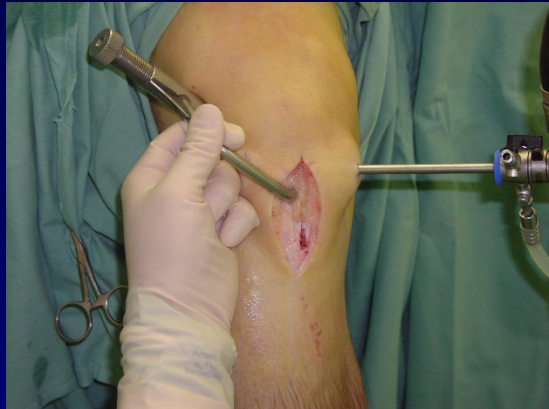# ACL plasty- press fit technique

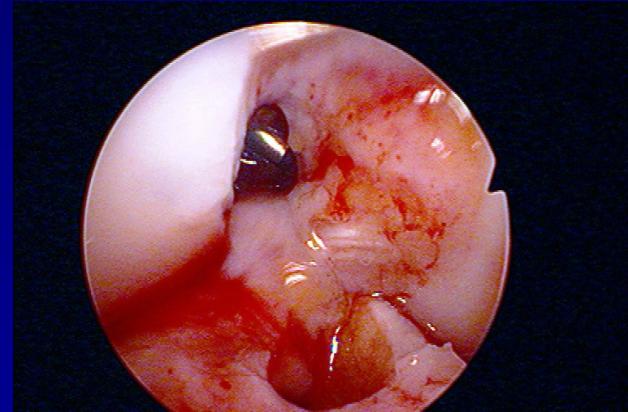
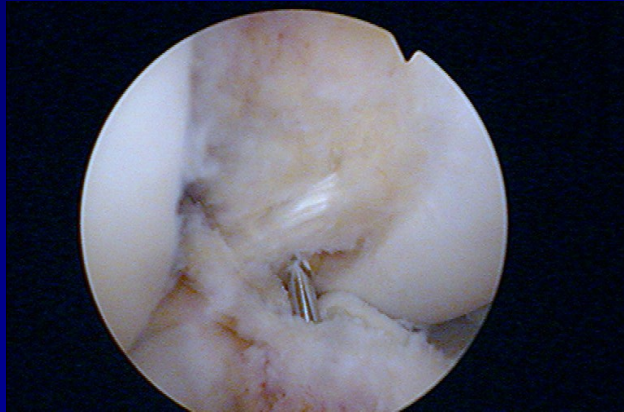
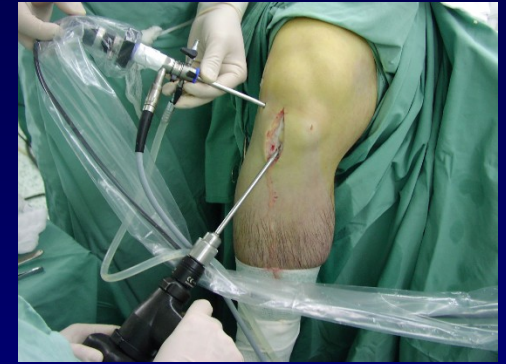
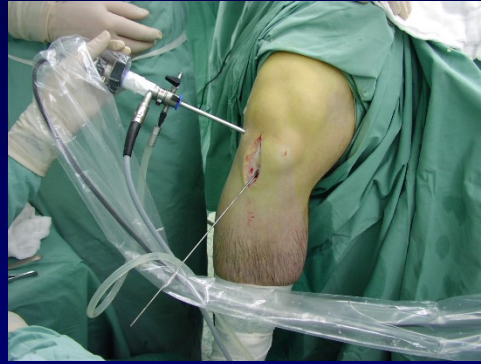
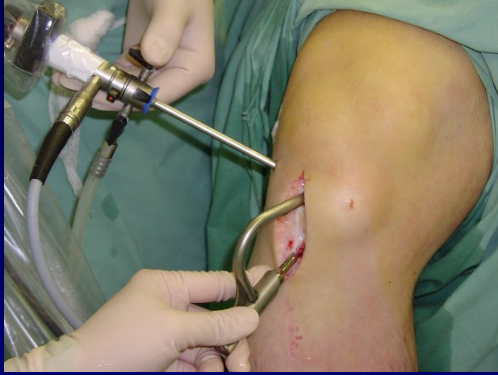

# Femoral canal

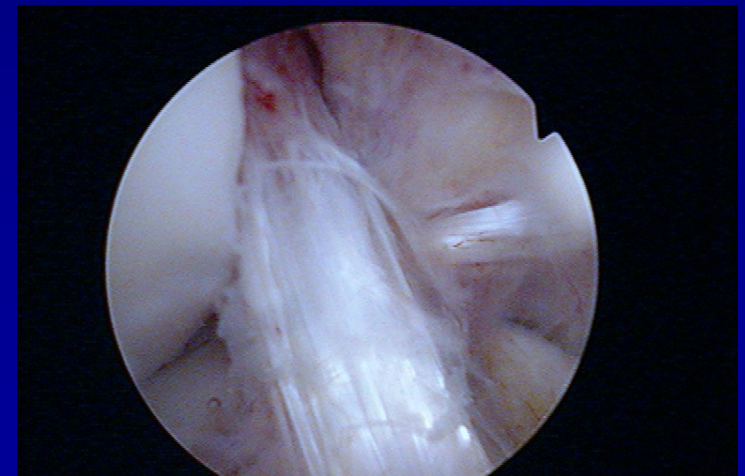
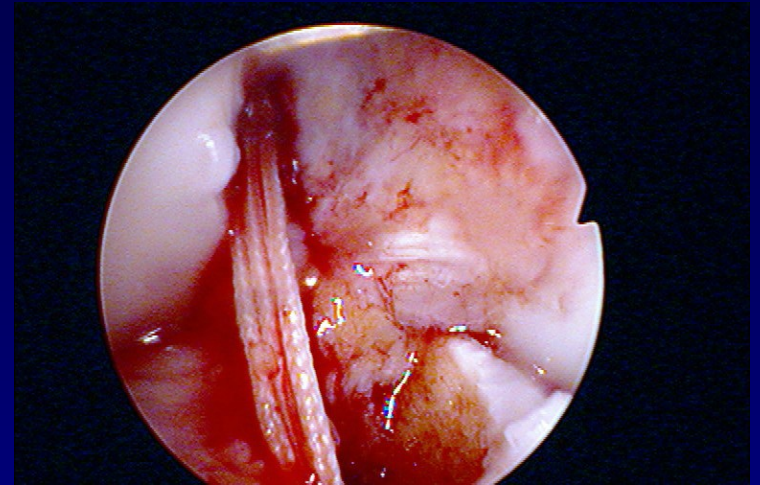
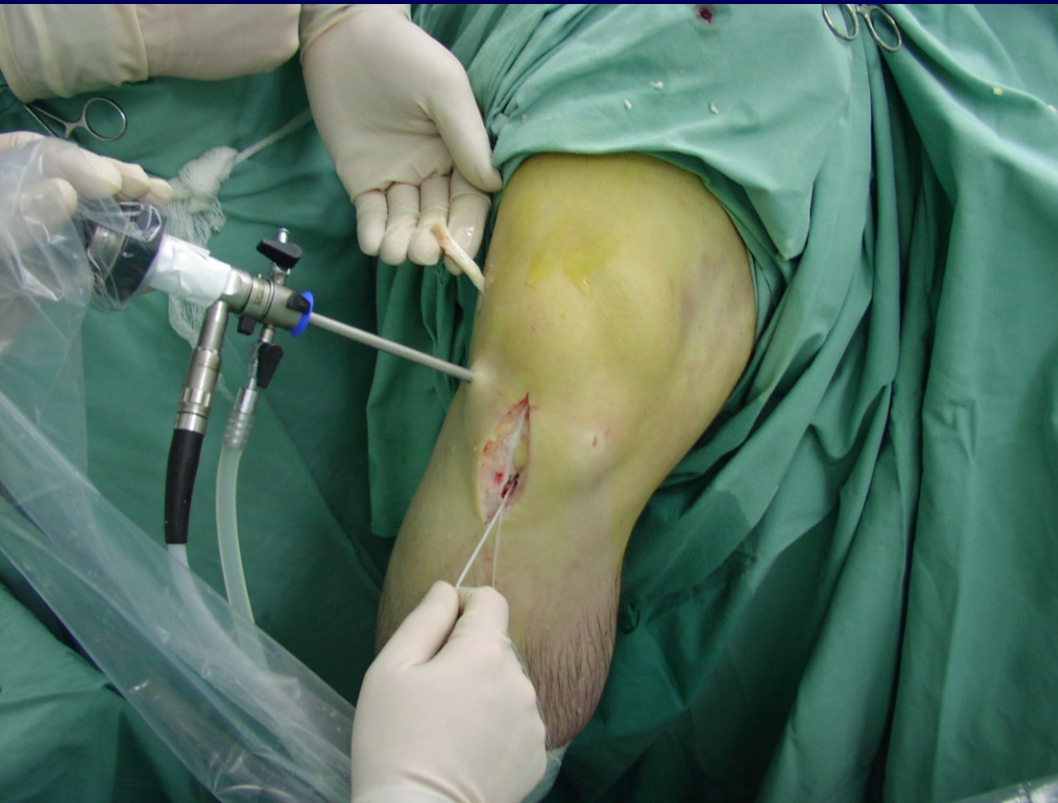

# Tibial canal





# Tightening of the graft

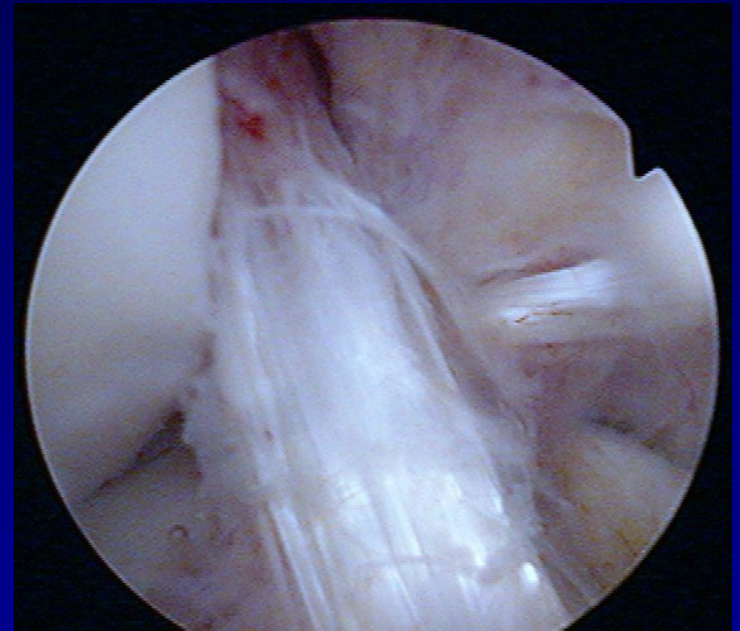


Graft in situ



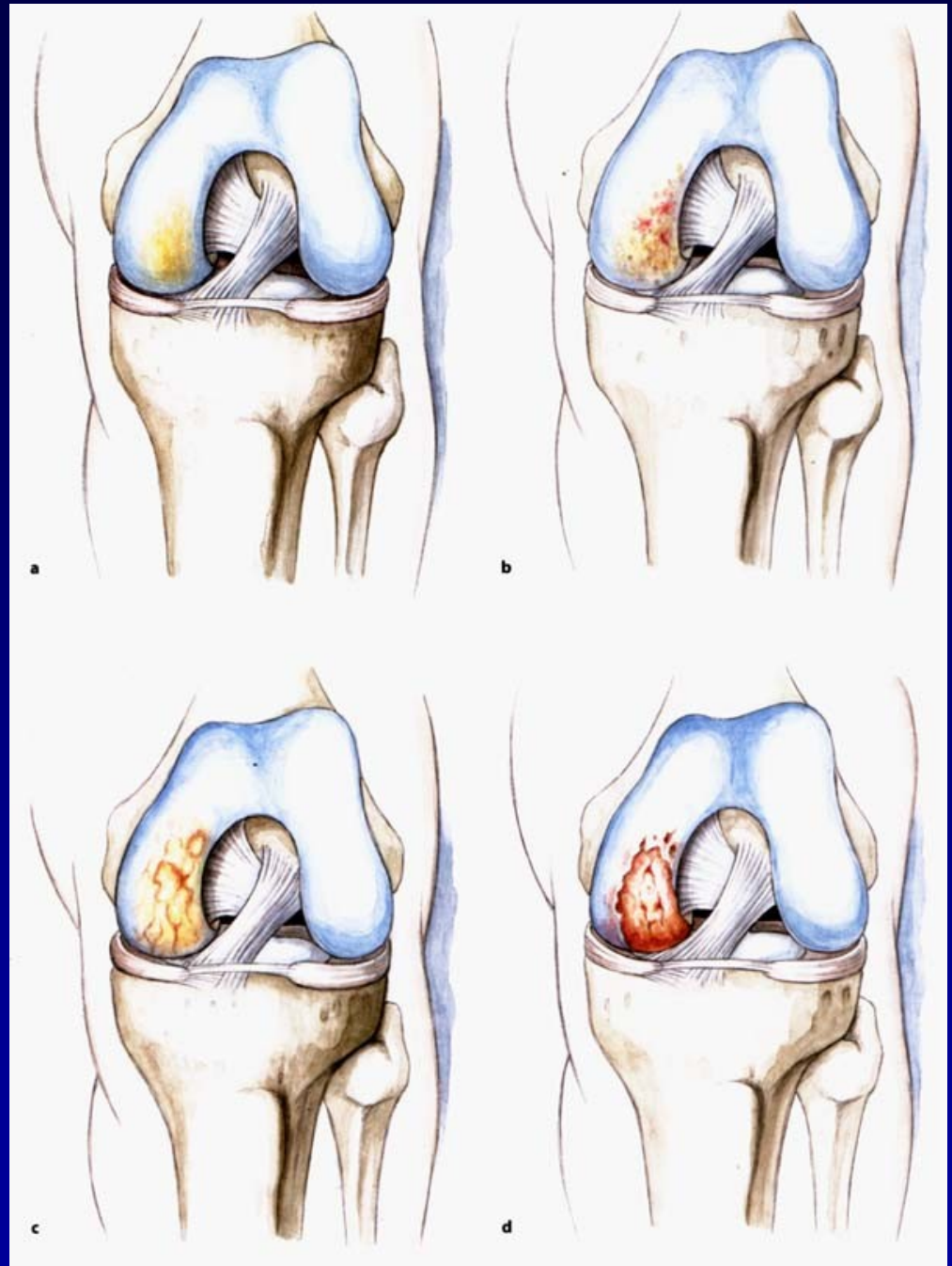
# Aftertreatment

- 6 weeks orthosis
- Weight bearing after 6 weeks
- Sports activity after 9 months

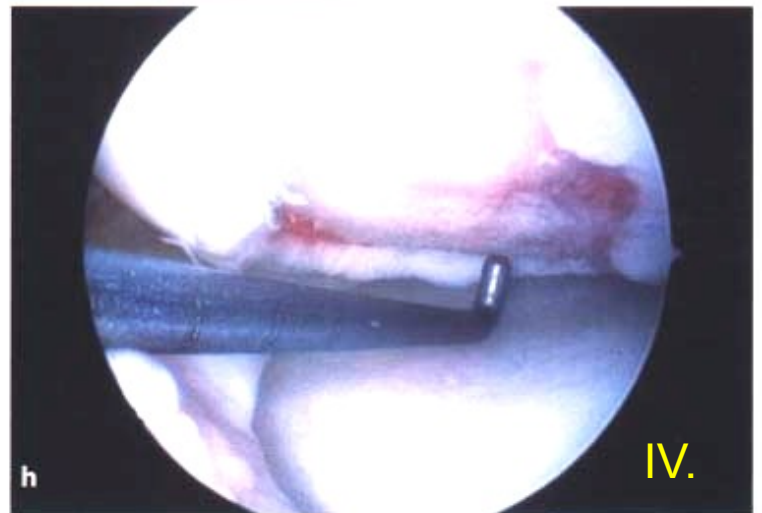
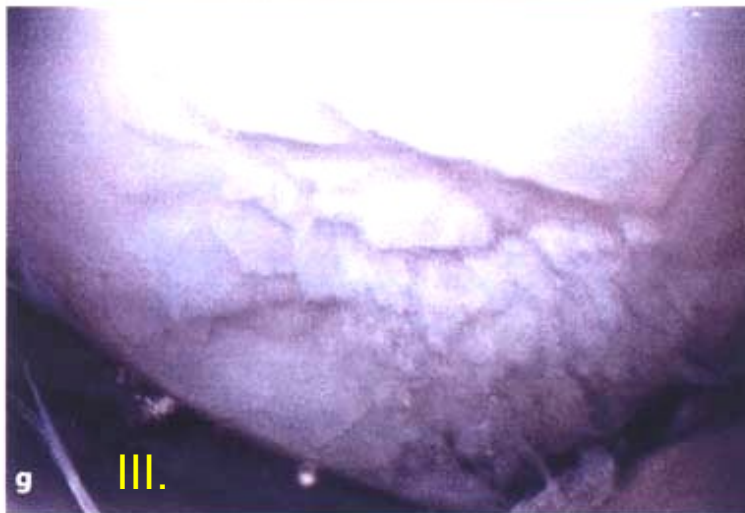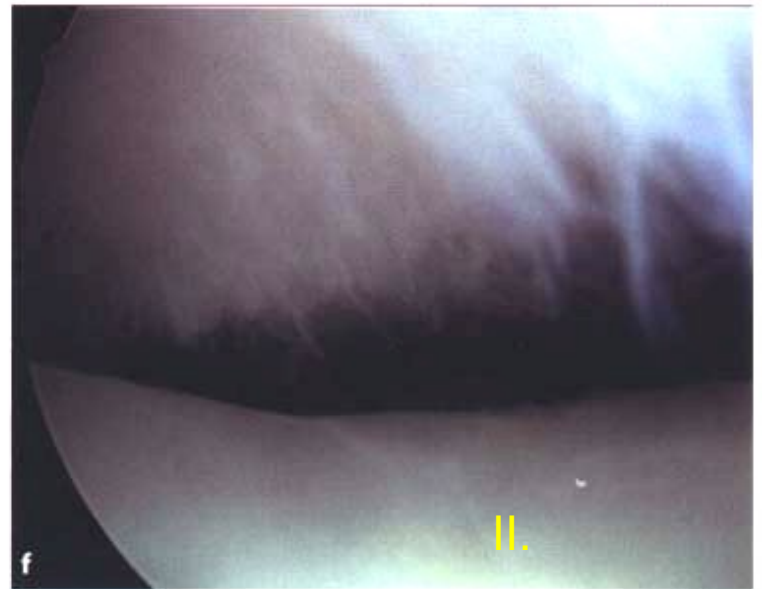
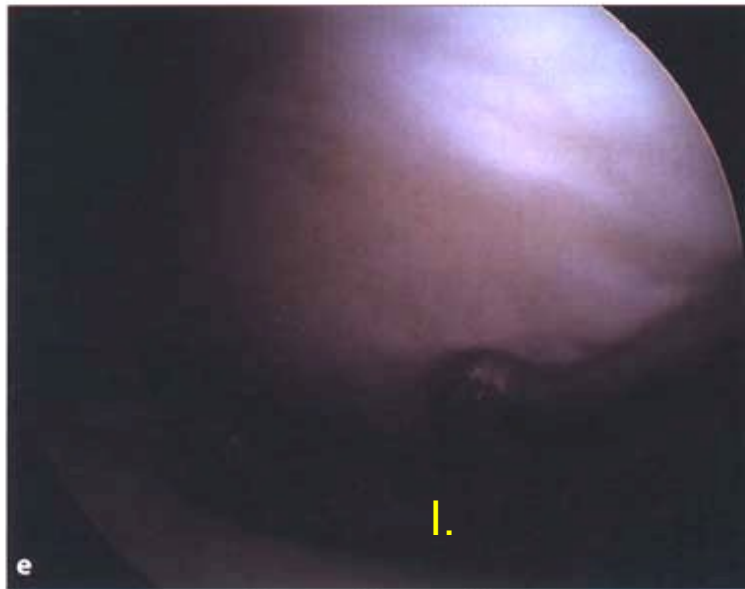


# Chondropathy

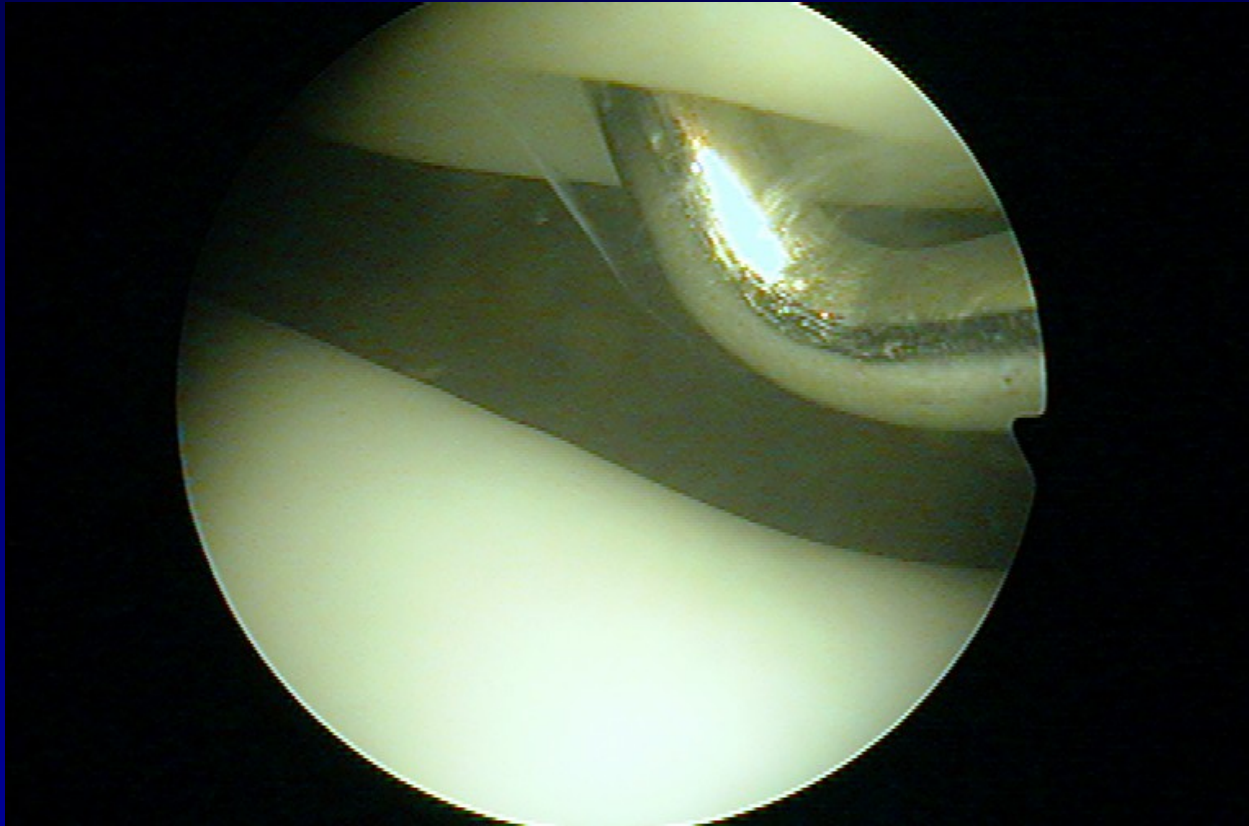
Outerbridge. H.K.



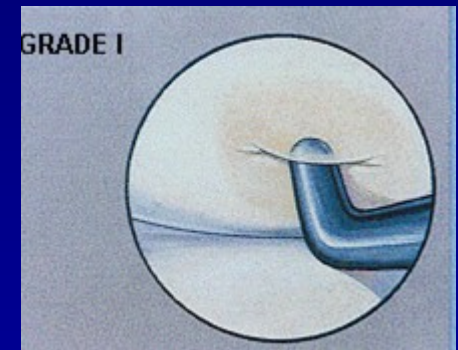
# Chondropathy



# Chondropathy I. st.

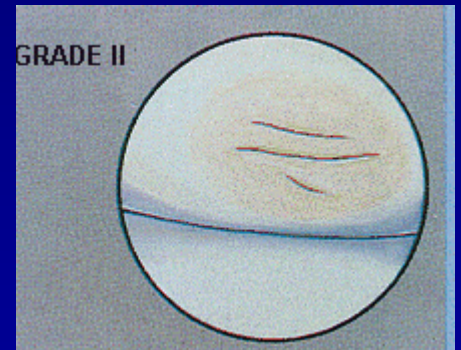
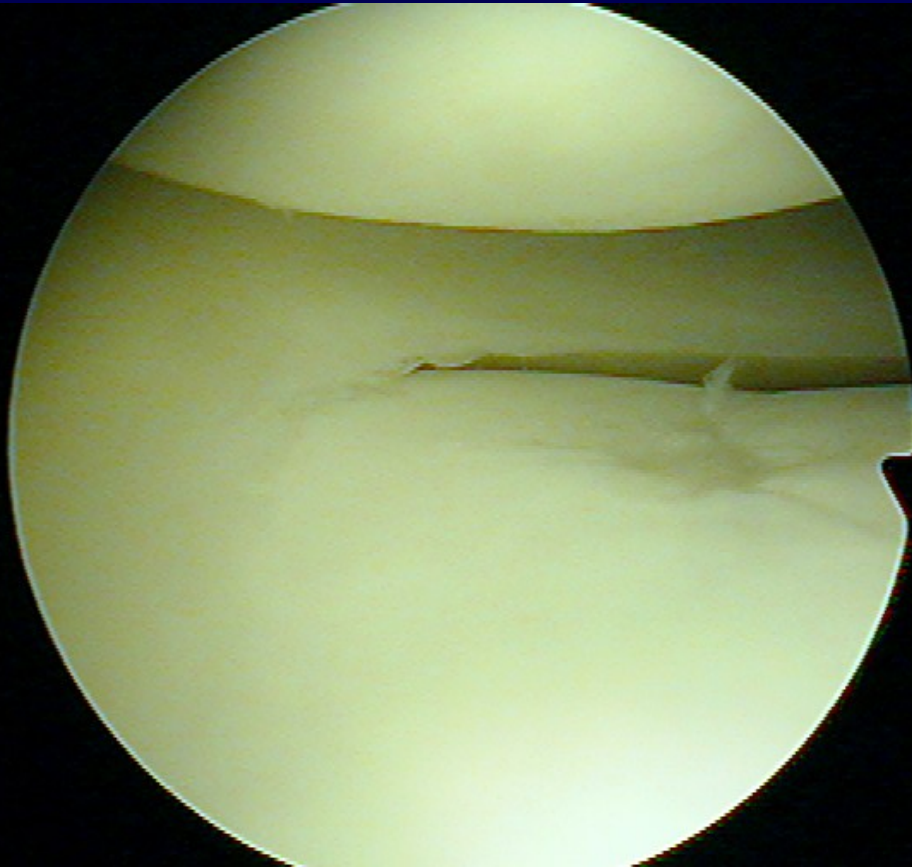


**Soft cartilage**



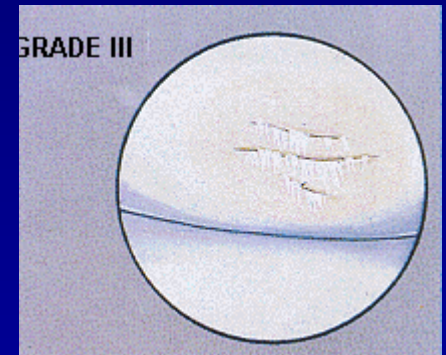
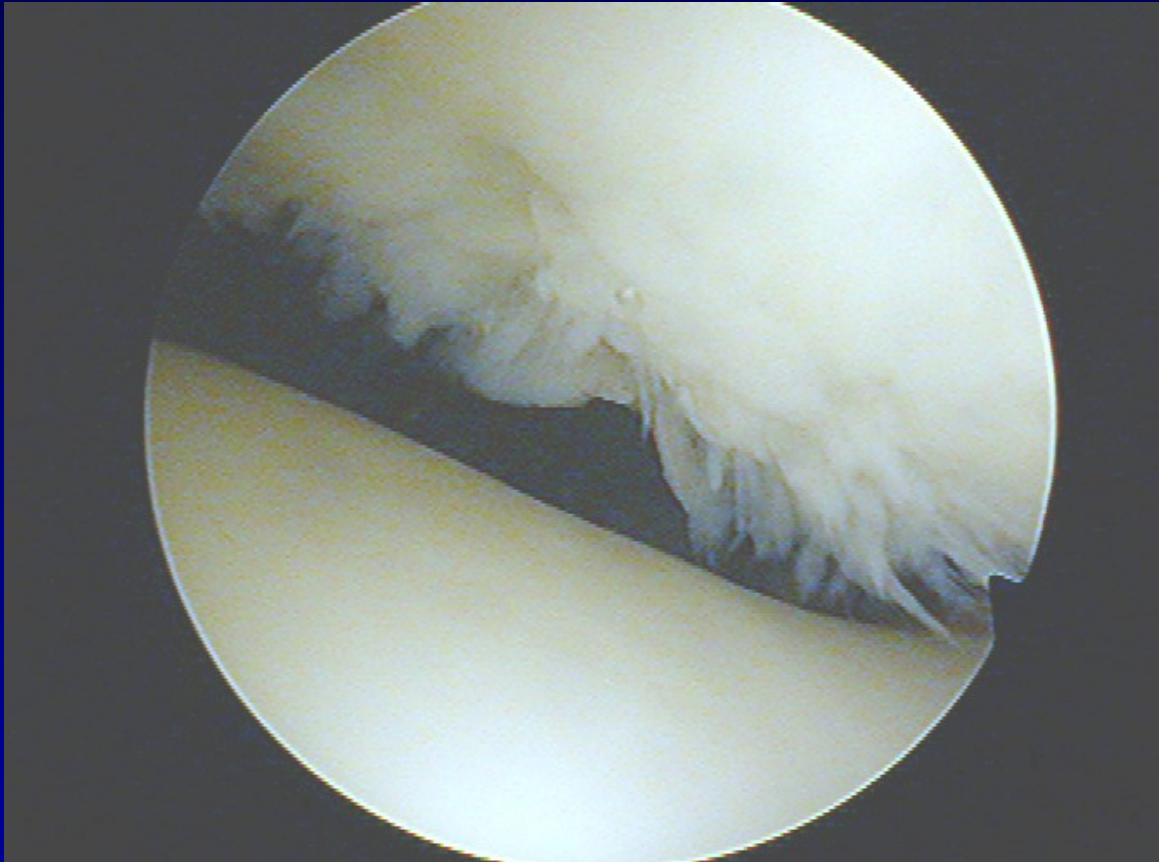


# Chondropathy II. st.



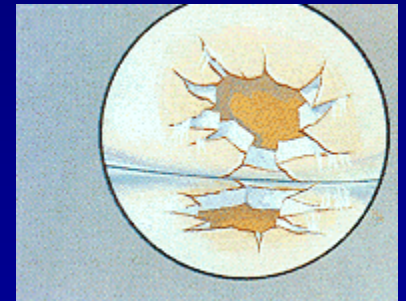
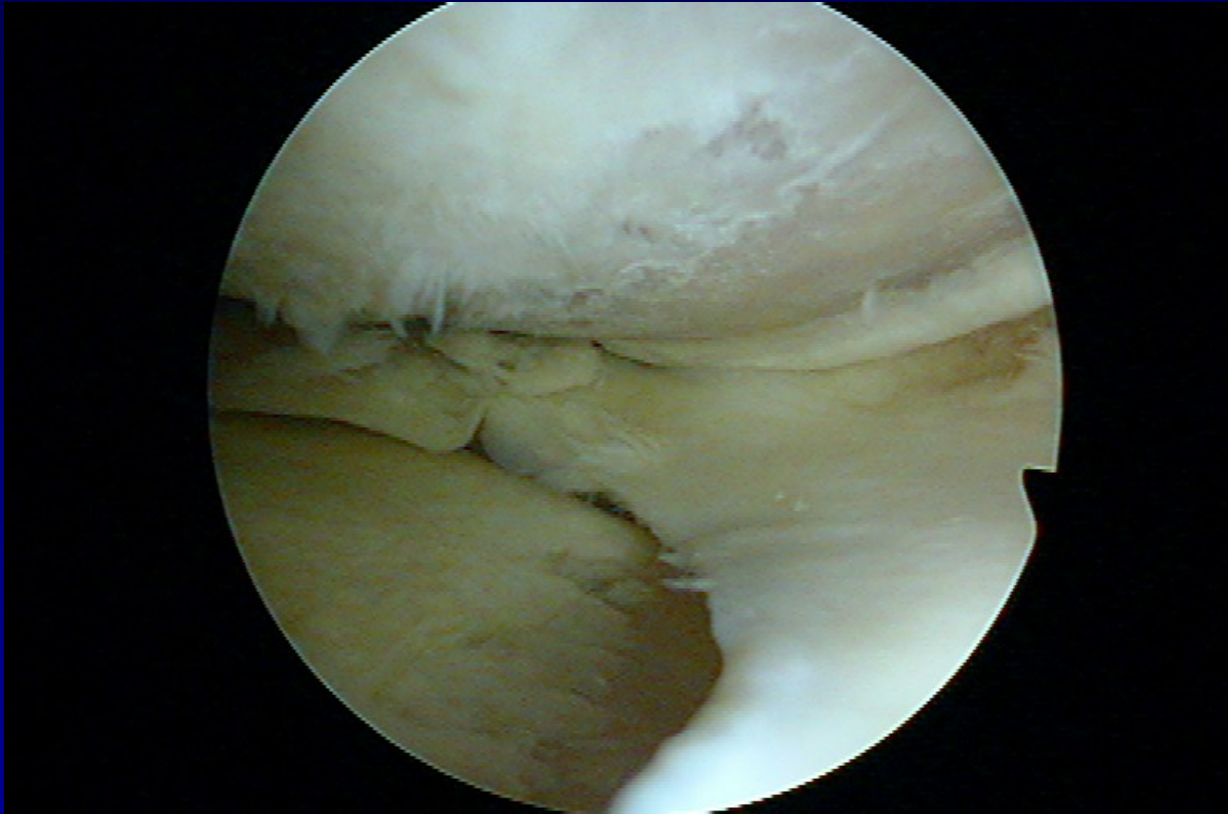
**Fissures in the cartilage**

# Chondropathy III. st.



**Fibrillation- „ crab meet“**

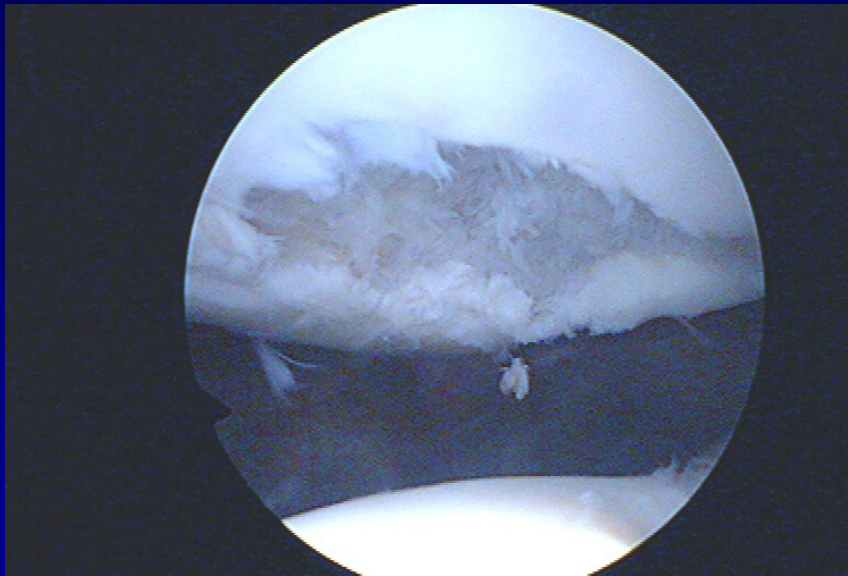
# Chondropathy IV. st.



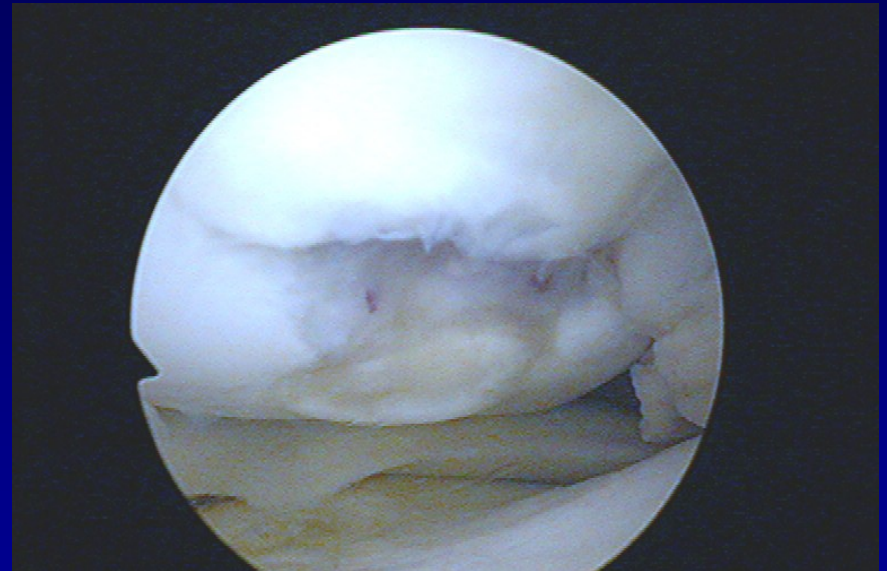
**Defects to subchondral bone**



# Defects of cartilage



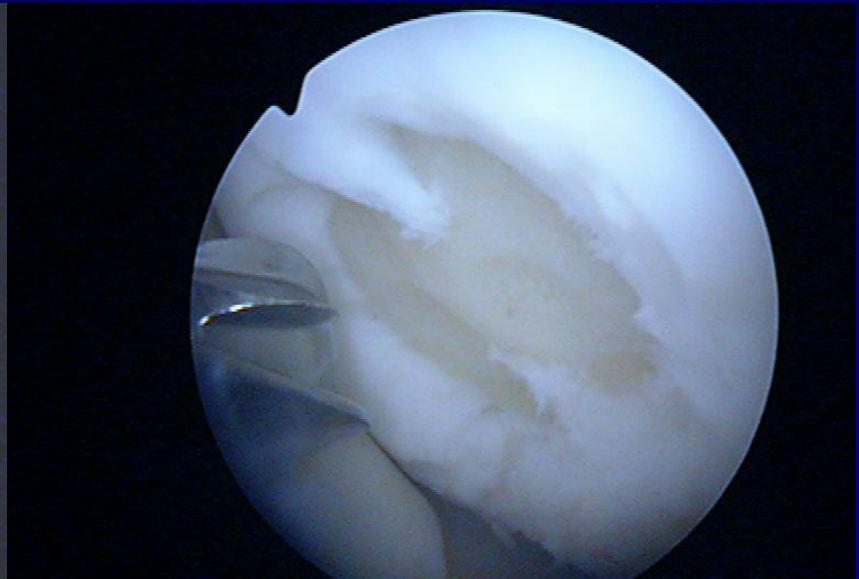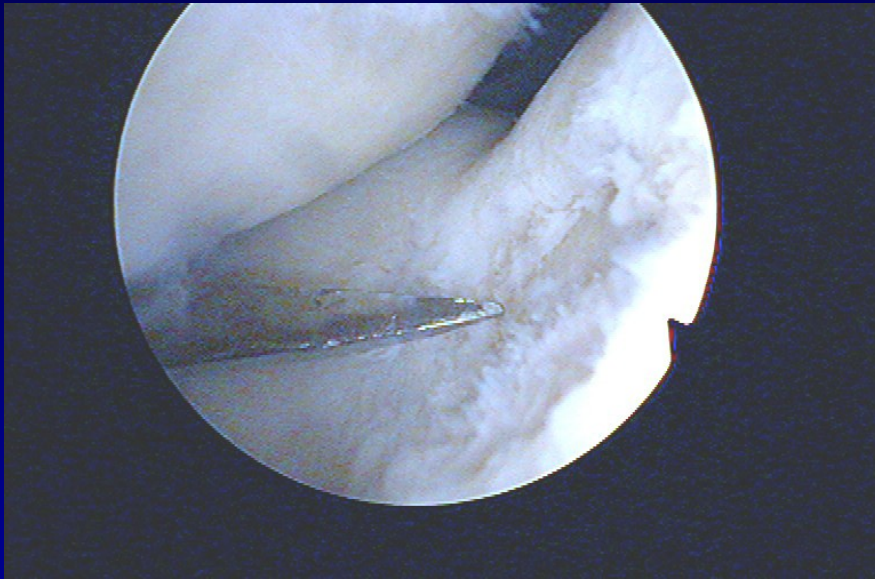
**Patella**



**Medial condyle**



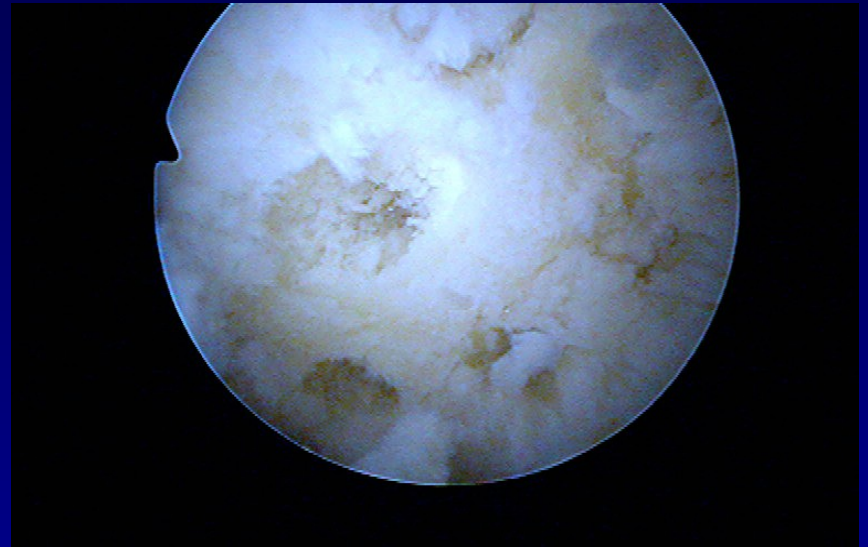
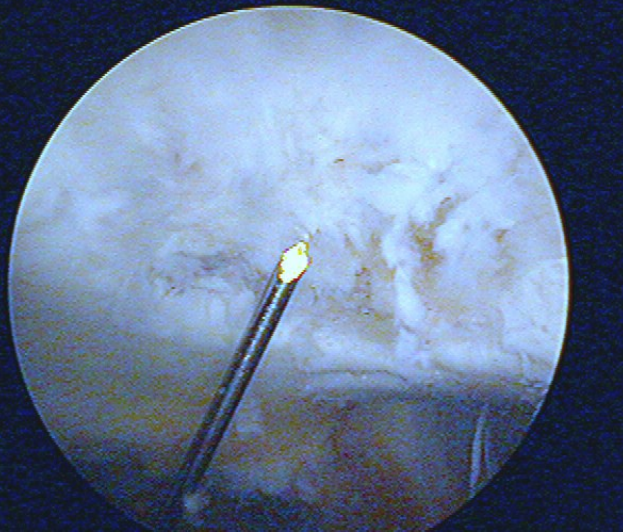
# Shaving and drilling



-

-

# Drilling

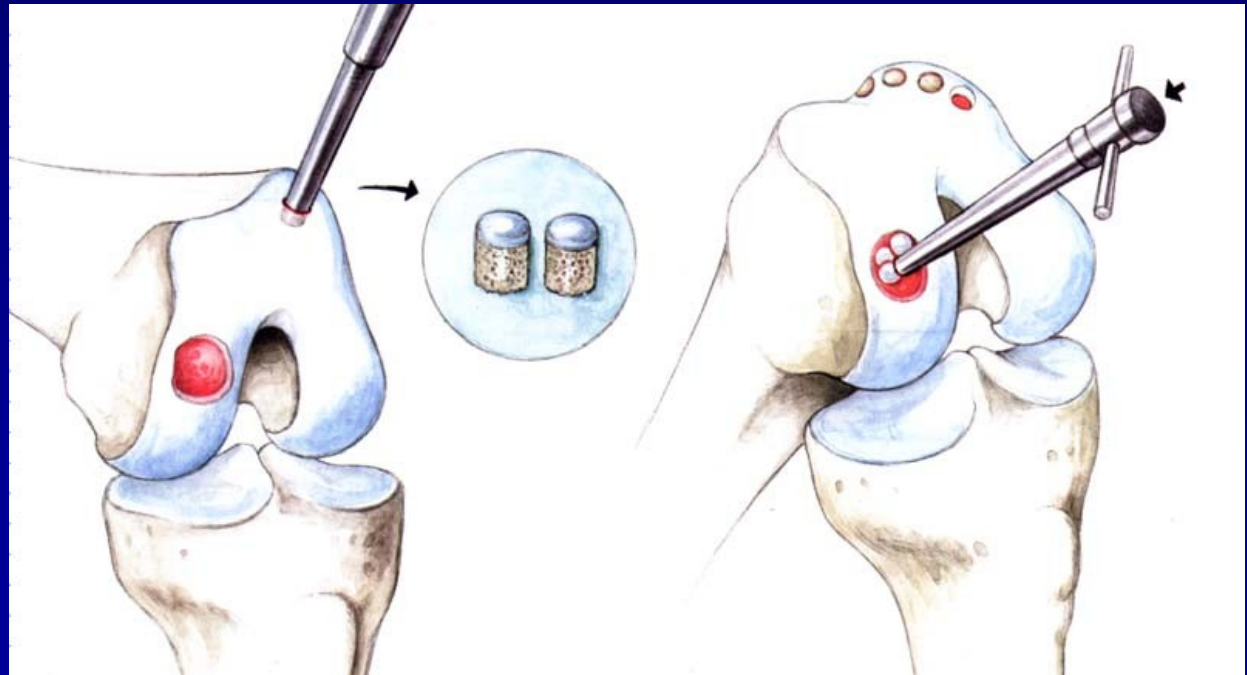


-

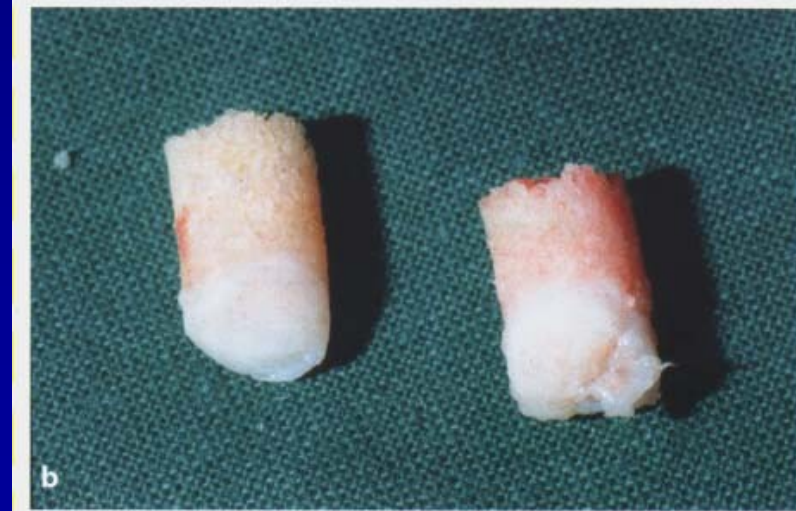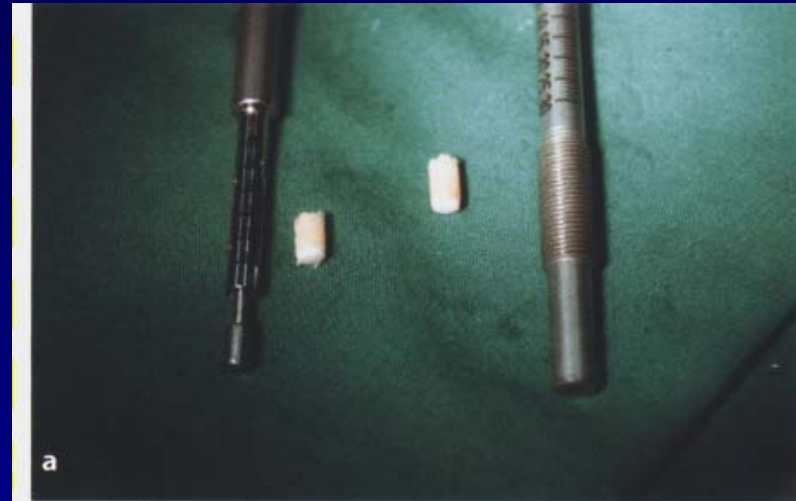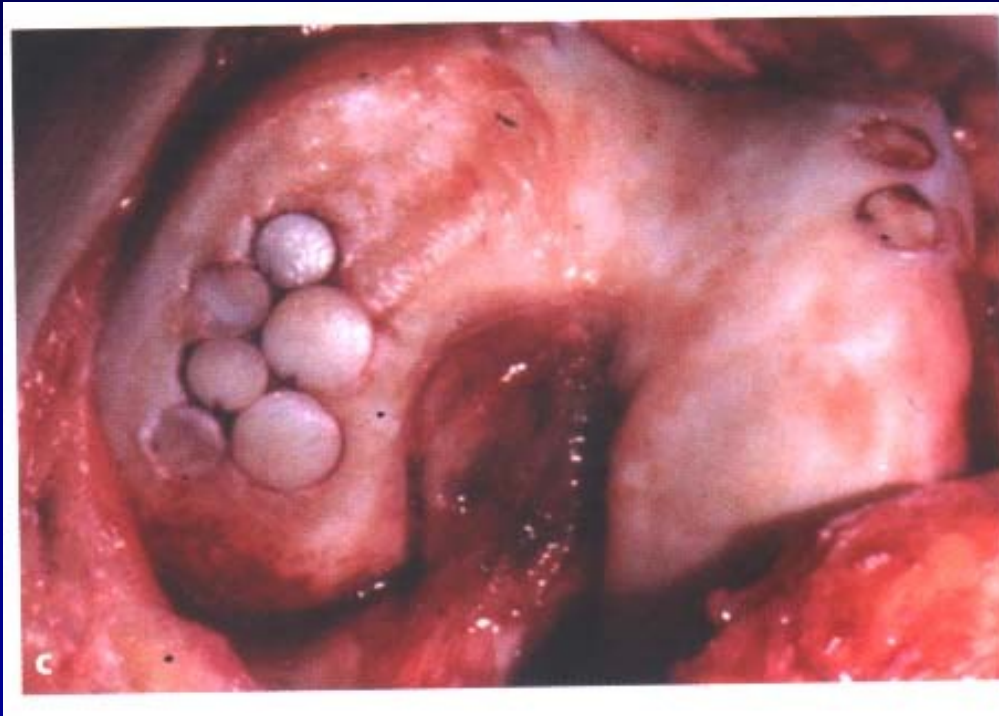# Osteochondral autograft transfer- OAT Mosaicplasty

Hangody, L., 1992

Defects up to 2 - 4 cm<sup>2</sup>

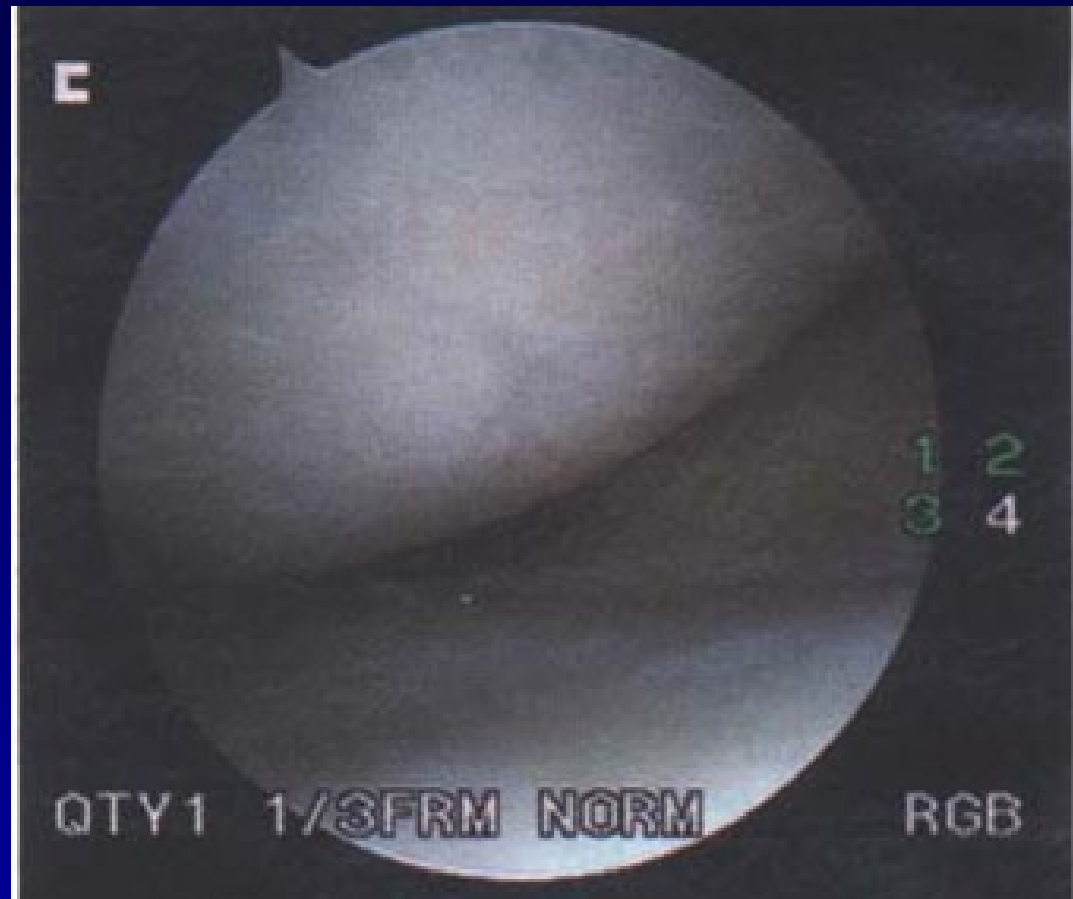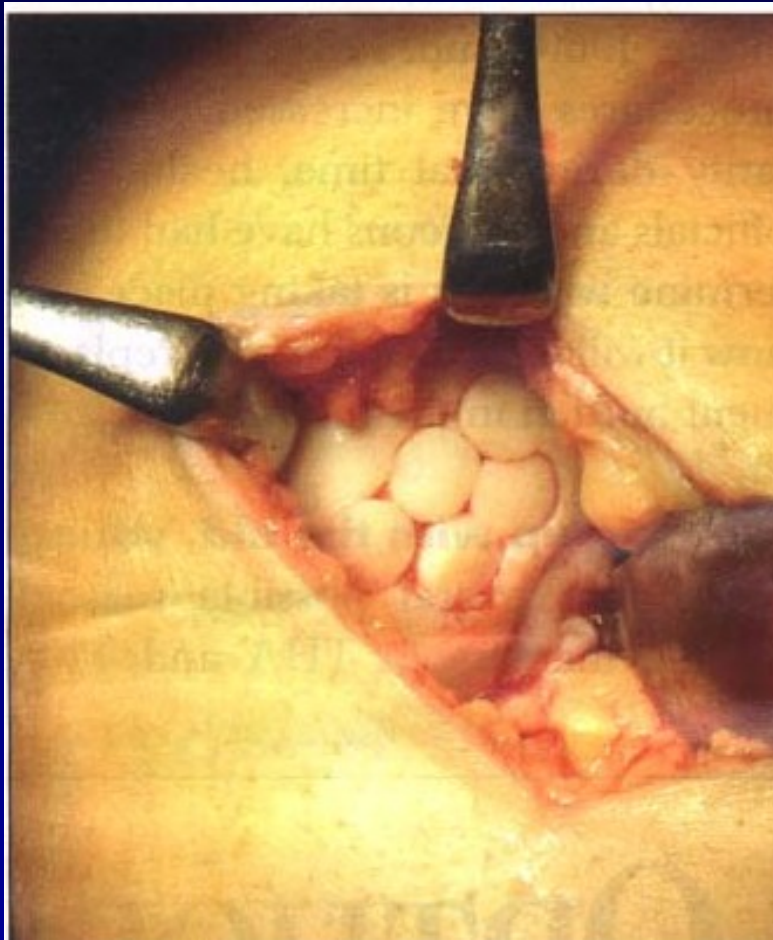


# Osteochondral autograft transfer- OAT





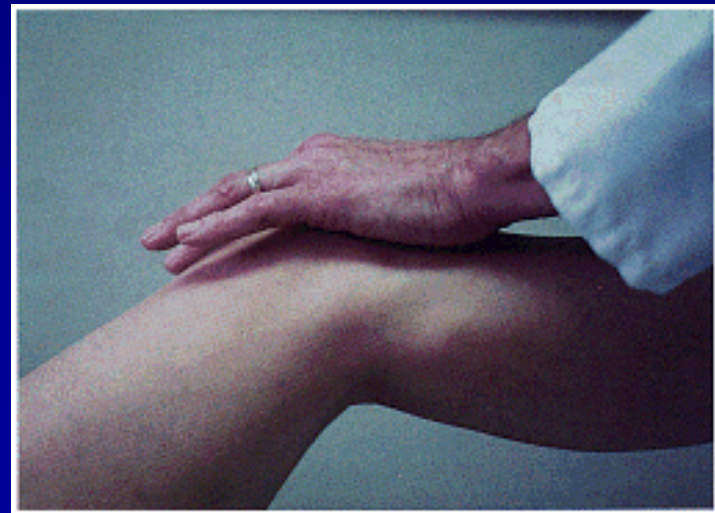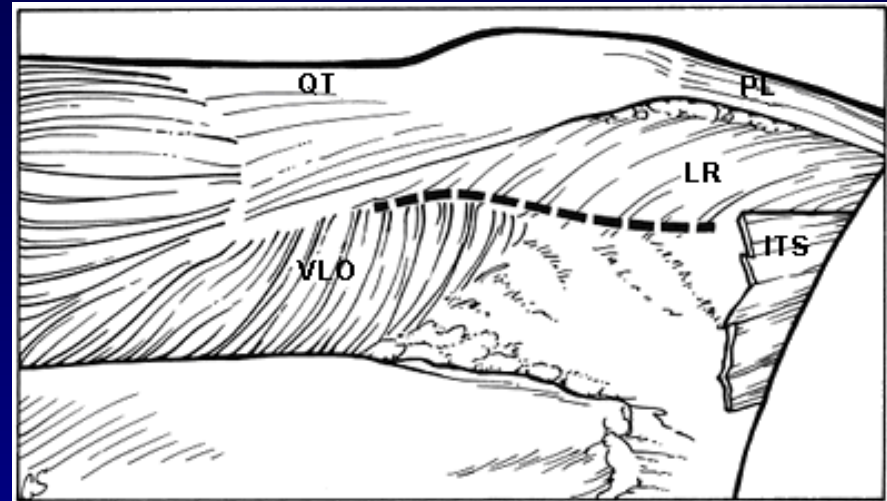
OAT



4 years after surgery

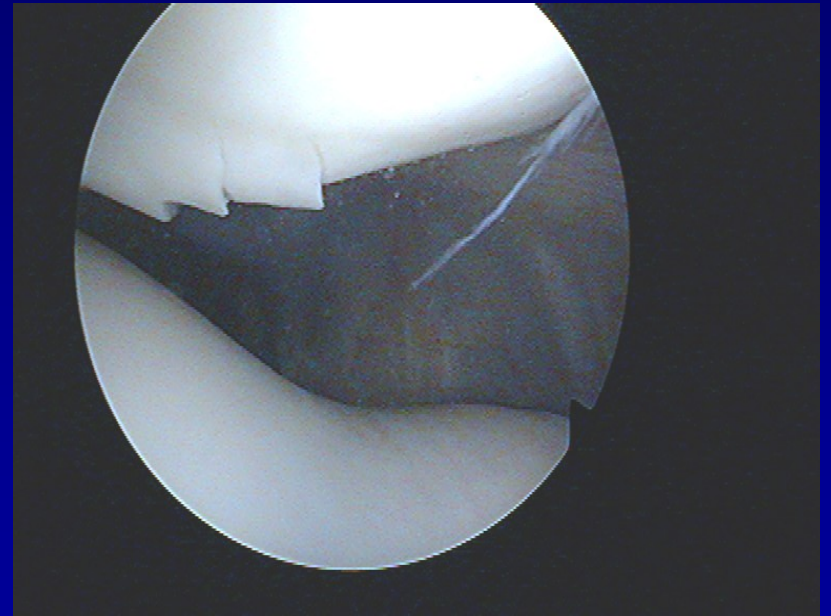
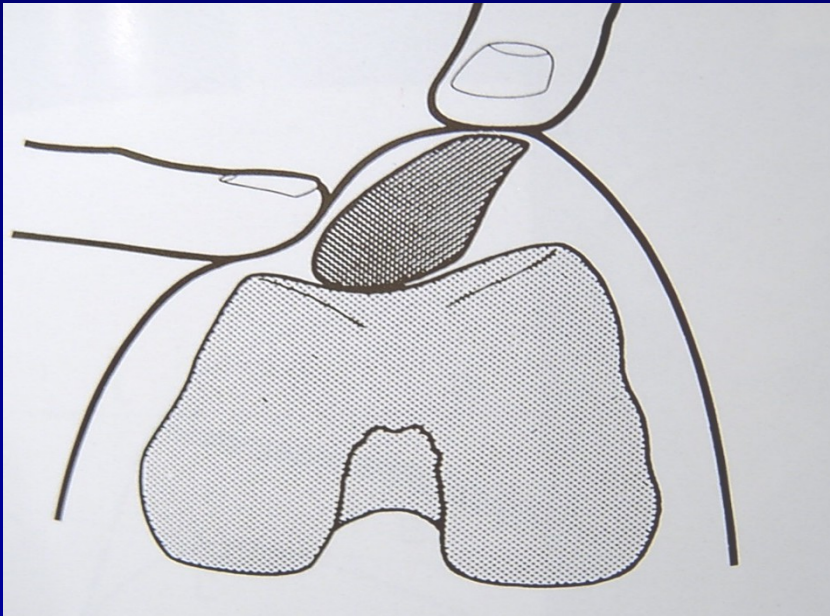
# Patella

- Chondropathy
- Subluxation
- Dislocation



# Chondropathy of the patella

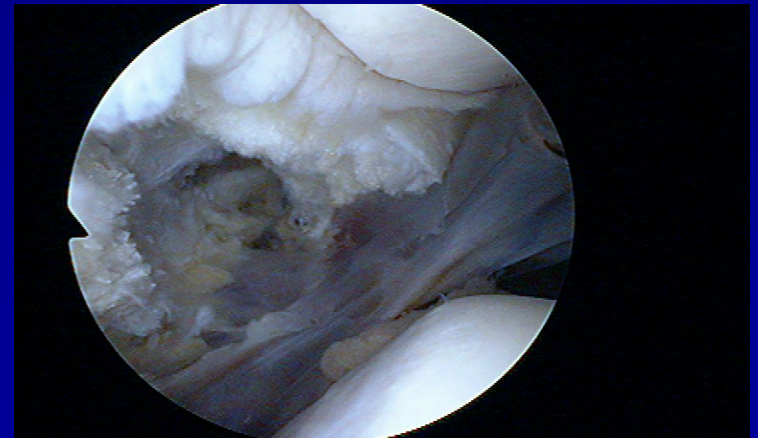
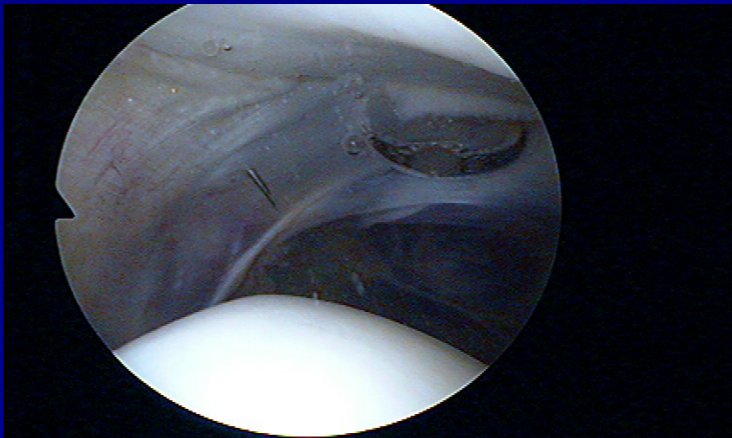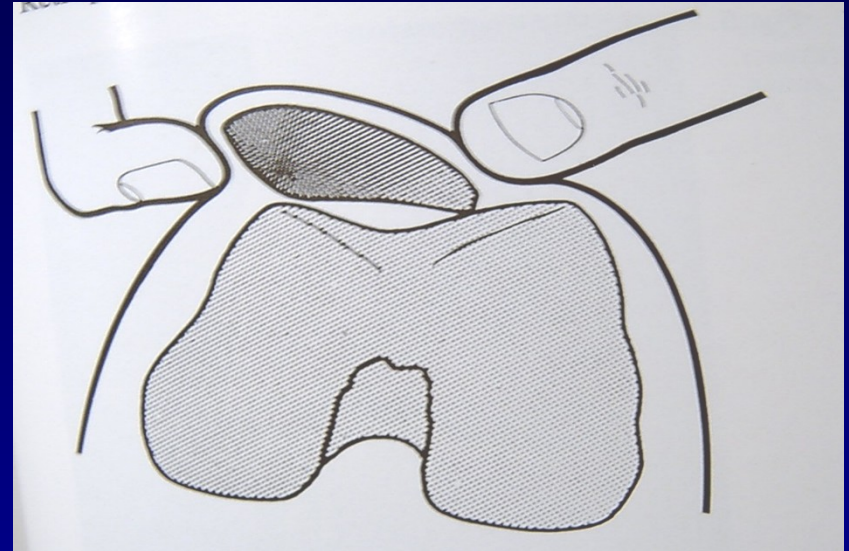
## Clinical symptoms





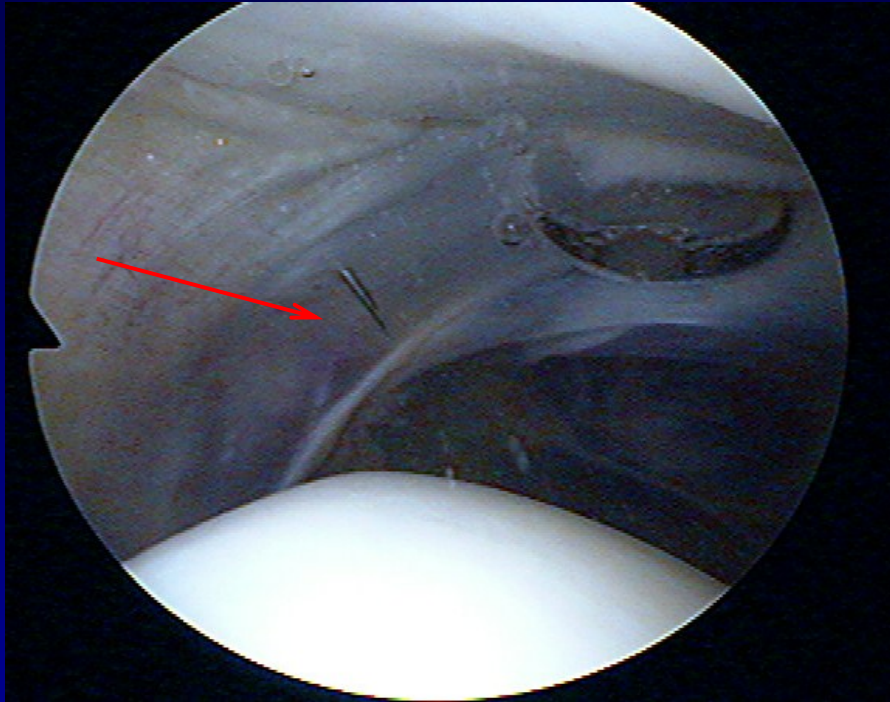
# Chondropathy of the patella

- Lateral hyperpression
- Lateral release

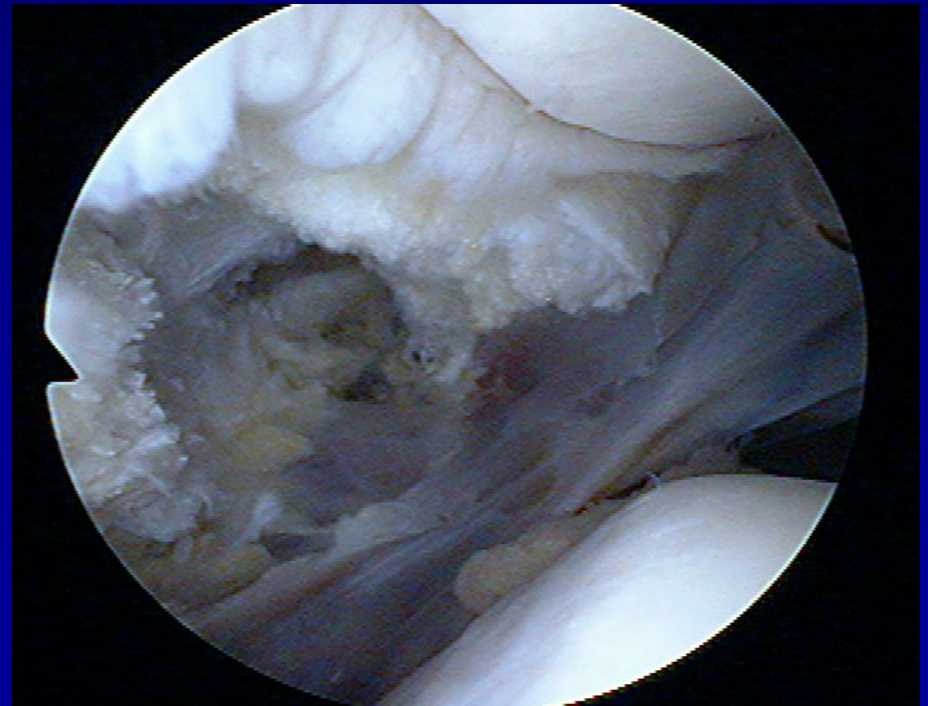




# Lateral release

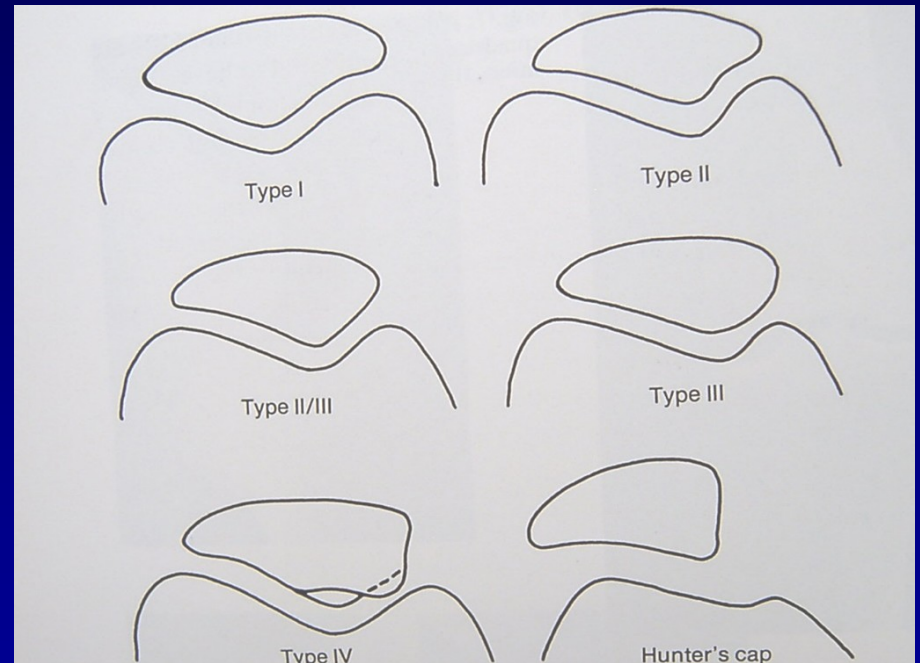


- Incision of lateral retinaculum



# Traumatic dislocation of the patella

- Always laterally
- Conservative treatment
- Operative treatment

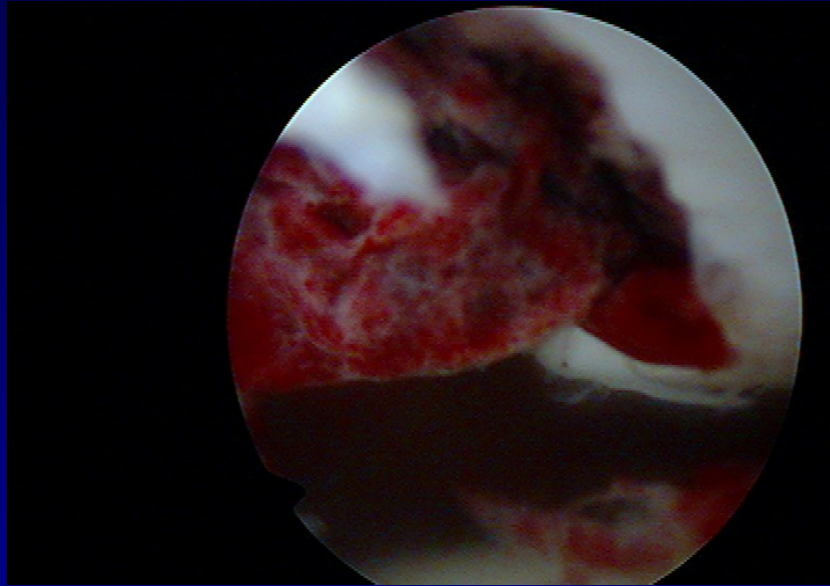


Types of patella

# Recurrent dislocation of the patella

- posttraumatic
  - congenital
  - habitual
- ASK – lateral release + medial capsuloraphy
- Open surgery

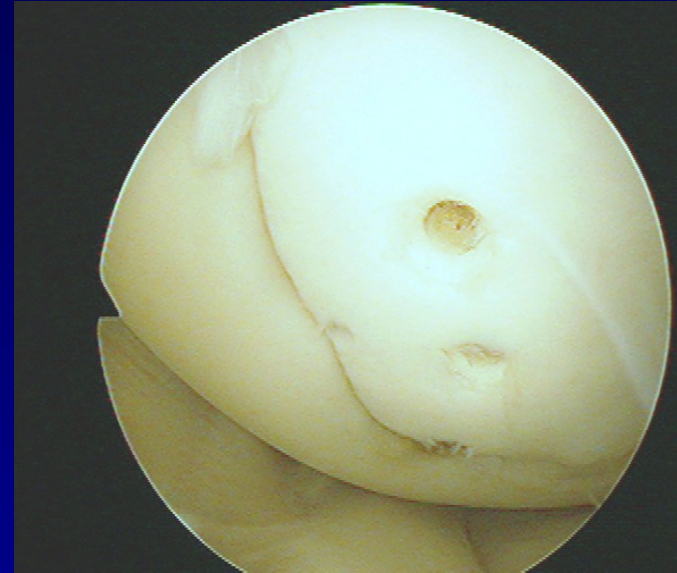
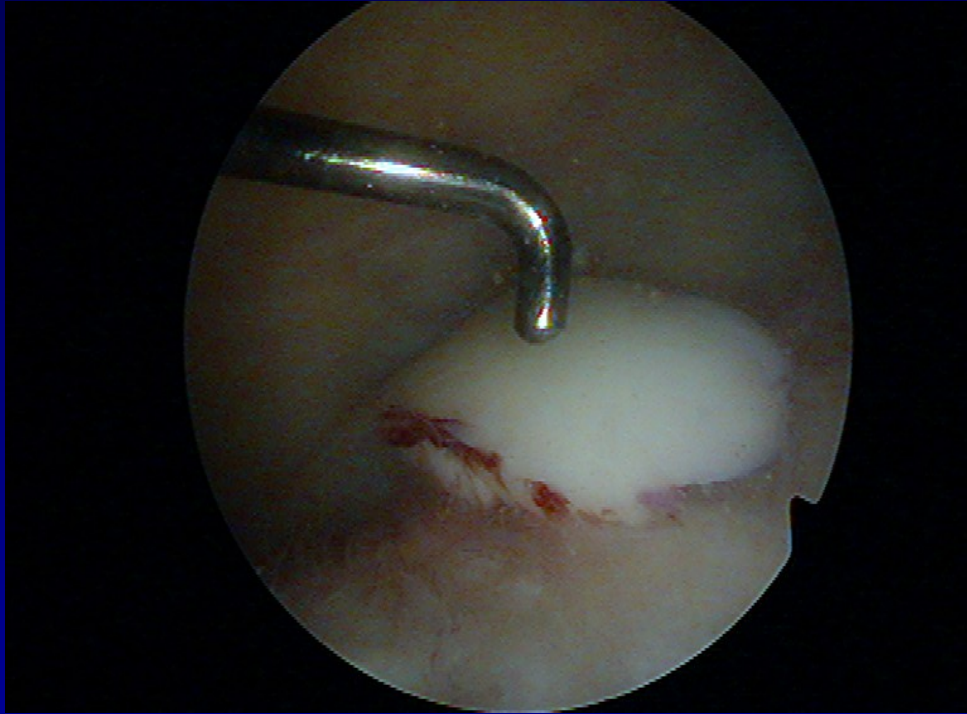
# Transchondral fracture



**Removal of destroyed cartilage**



# Osteochondral fractures



Fixation by pins



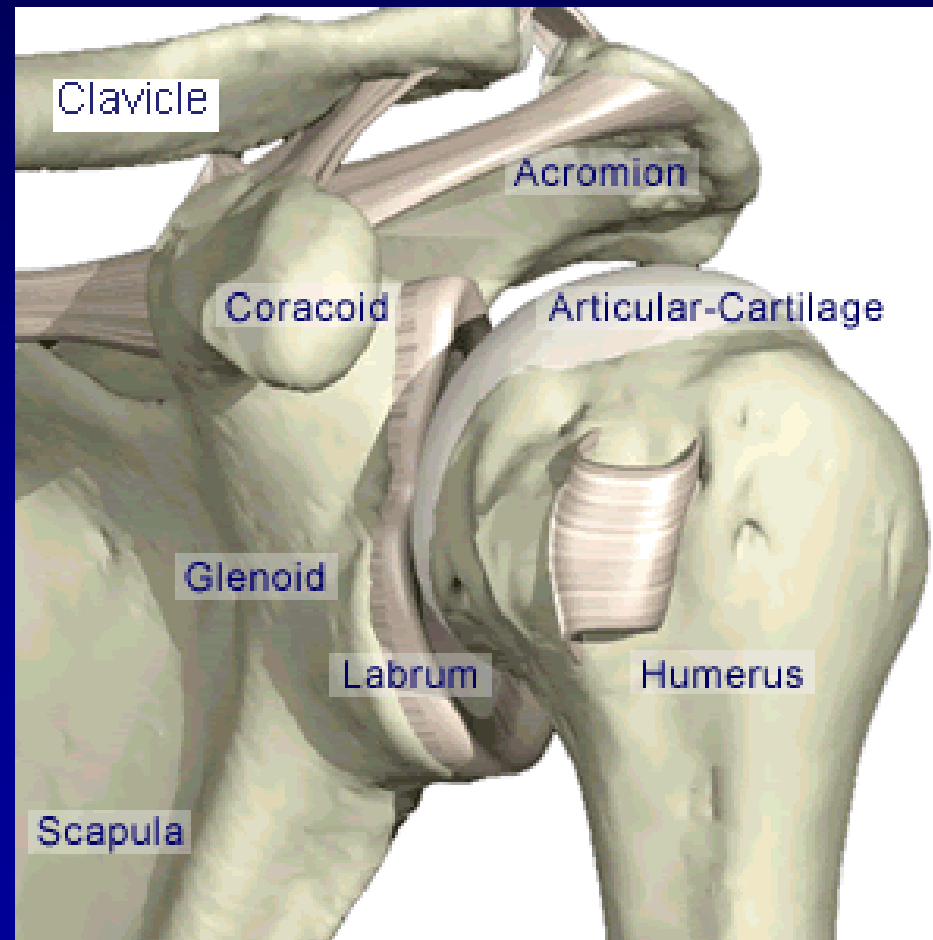
# Arthroscopy of the shoulder

Subacromial decompression

Suture of rotator cuff

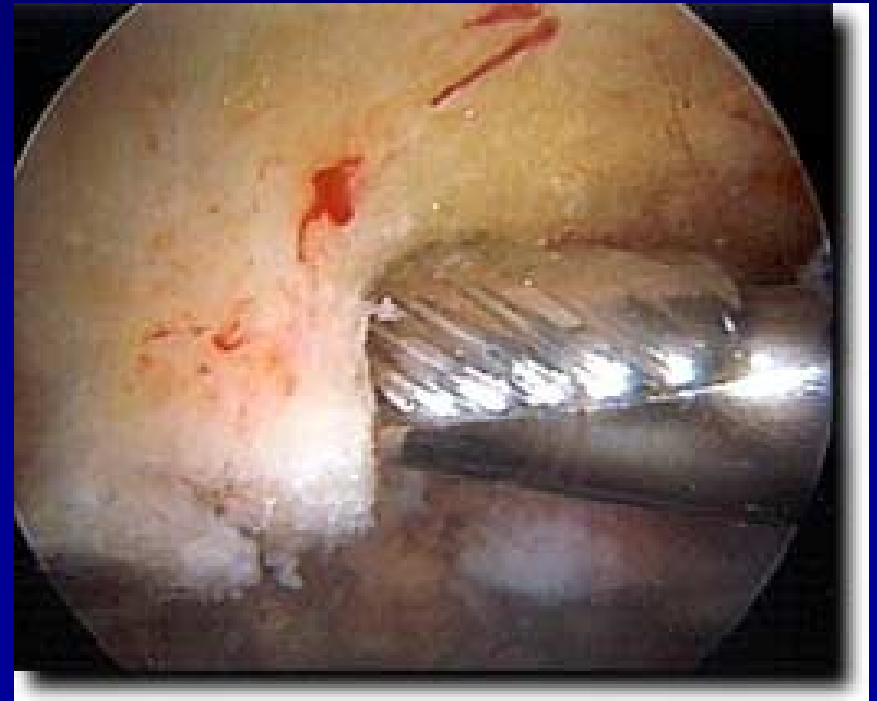
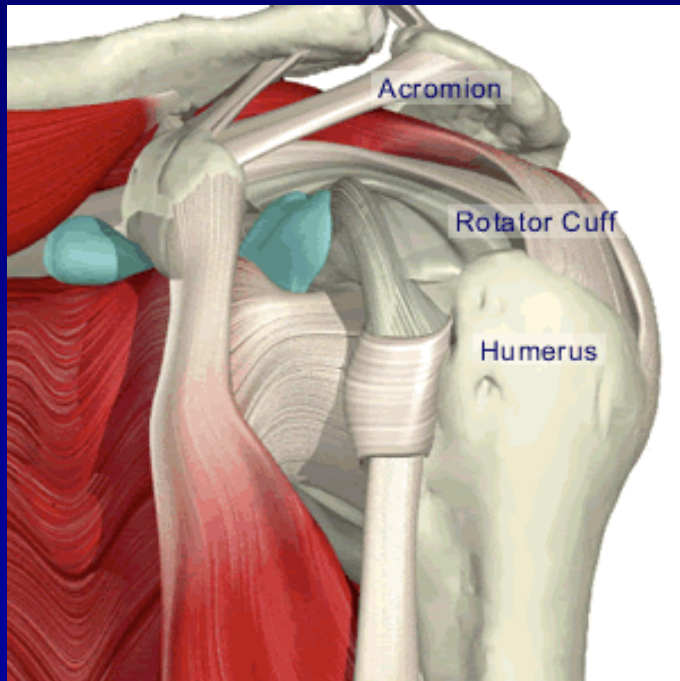
Chronic instability

SLAP lesion



# ASAD – arthroscopic subacromial decompression

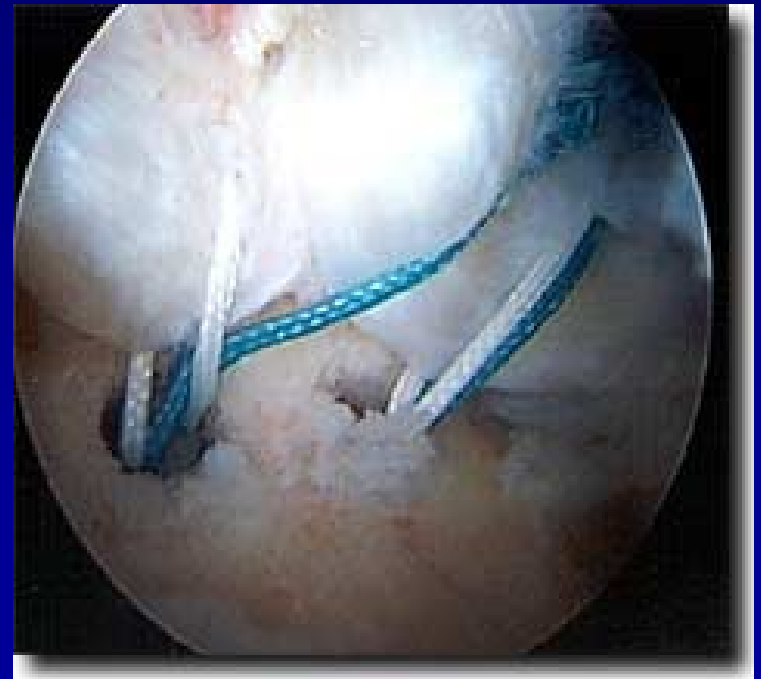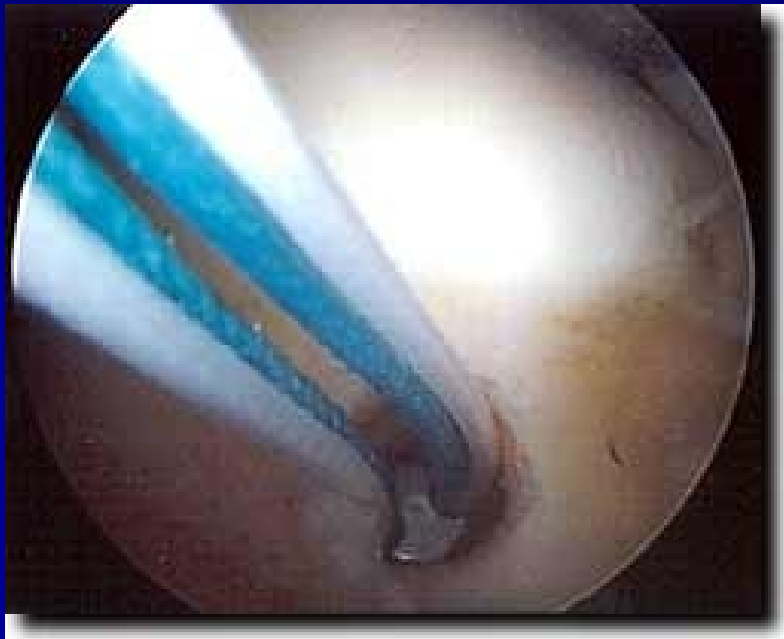- Removal of bursa
- Acromioplasty - shaver



# Rupture of rotator cuff

Suture:

- arthroscopically

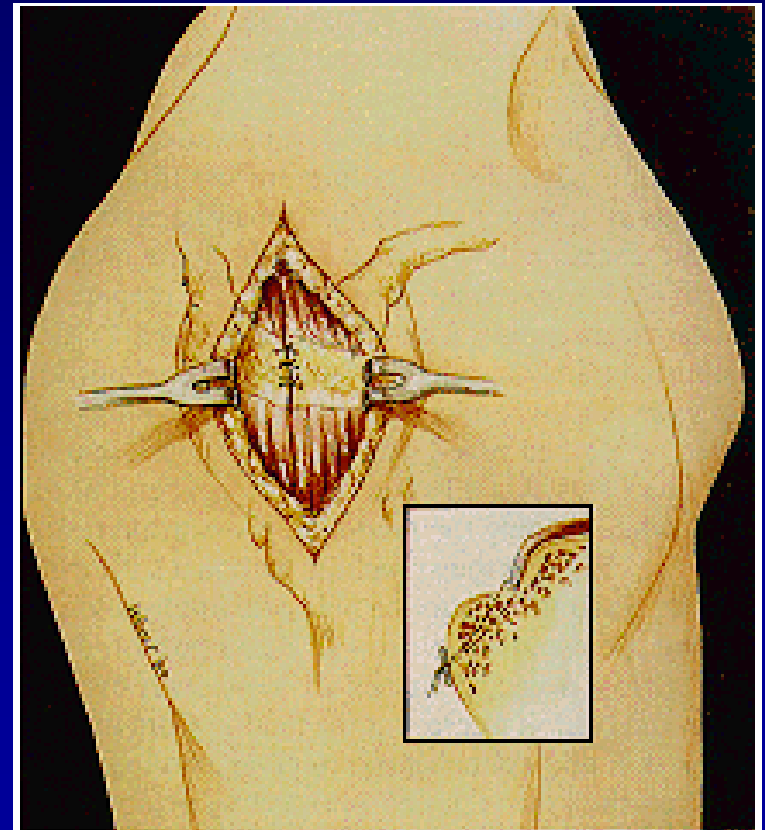
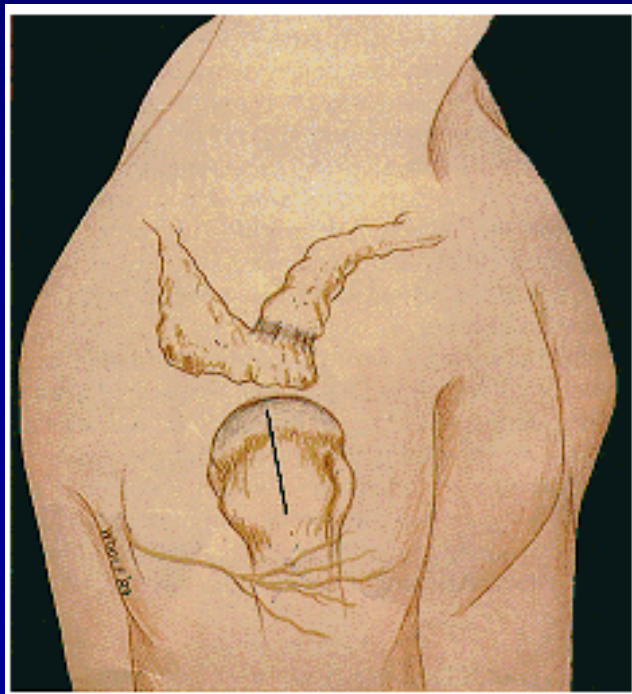




# Rupture of rotator cuff

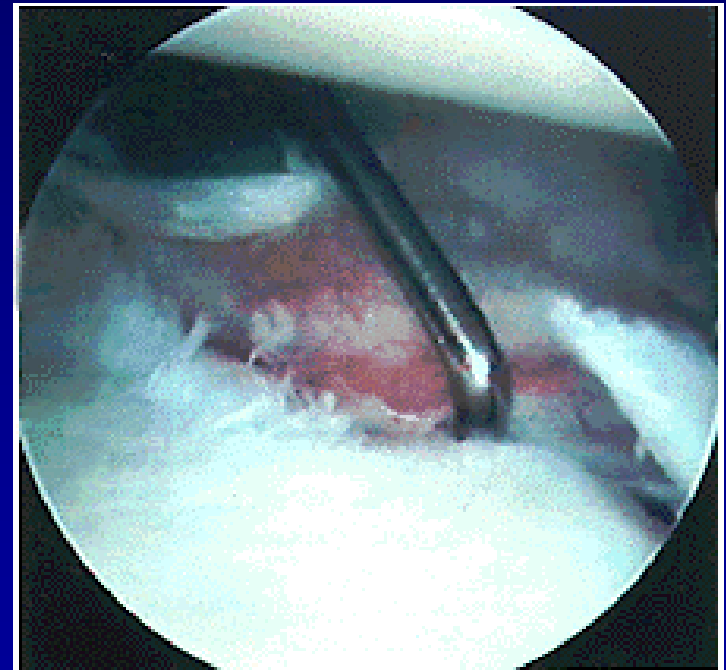
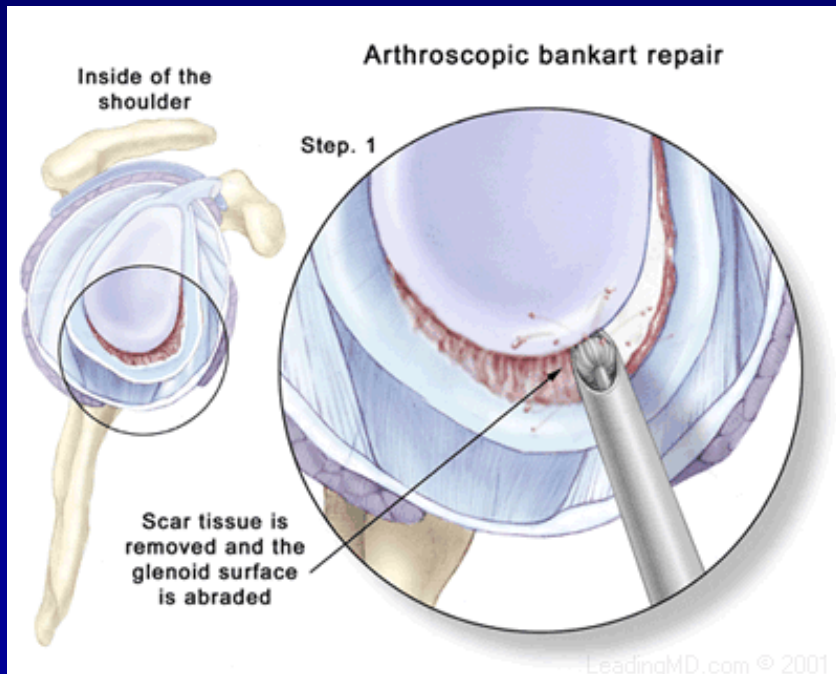
Suture:

- from small incision



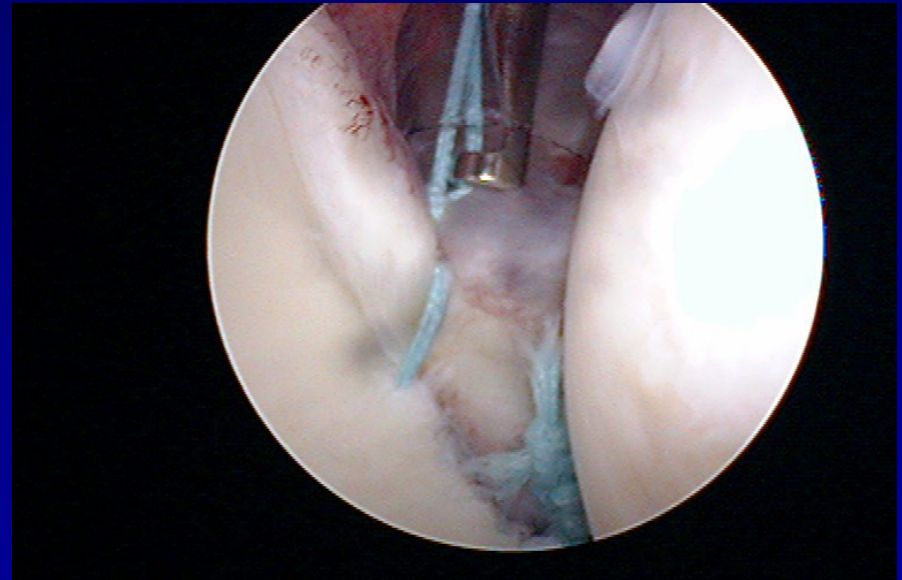
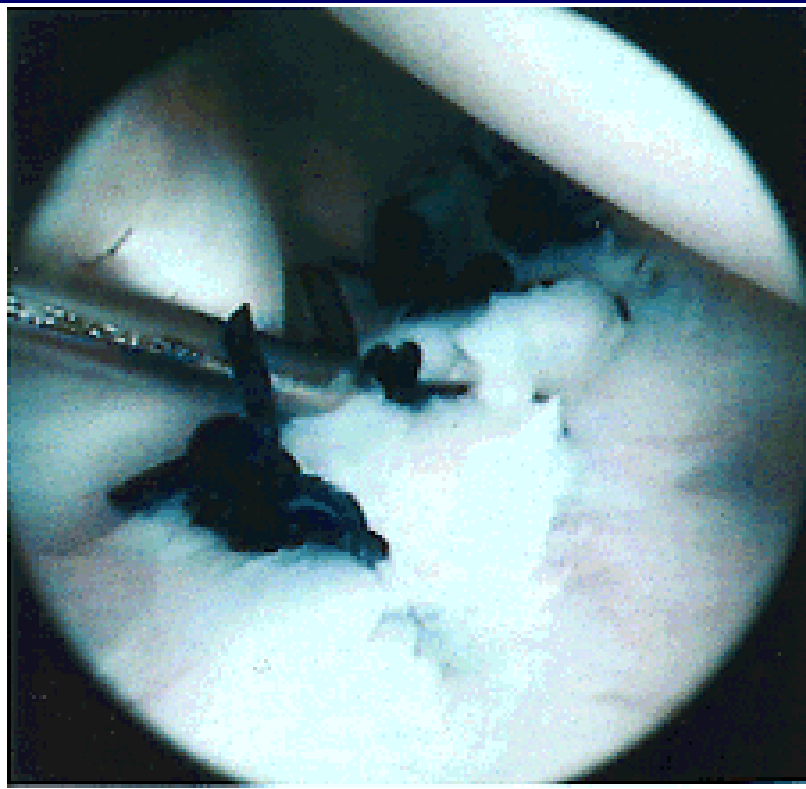
# ASC- stabilisation

Fixation of the labrum to the bone – stitches and arrows



# ASC- stabilisation

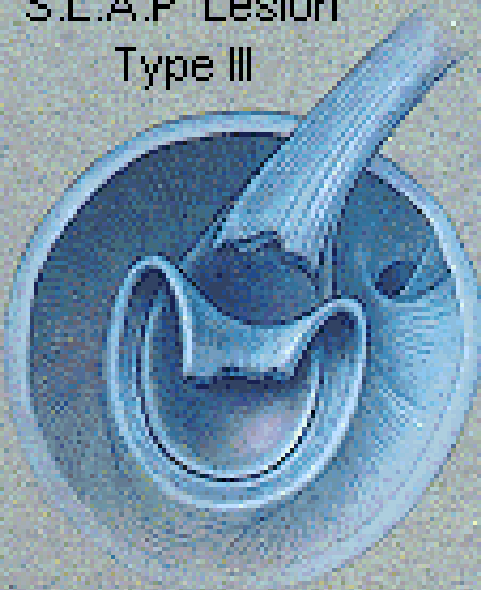- Fixation of the labrum to the bone – stitches, arrows



# SLAP lesion

Rupture of insertion of the tendon of long head of biceps

S.L.A.P. Lesion  
Type III



S.L.A.P. Lesion  
Type IV

