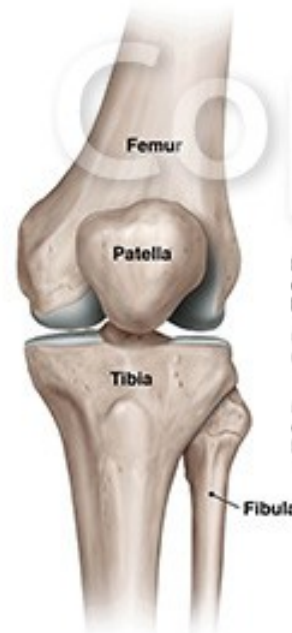



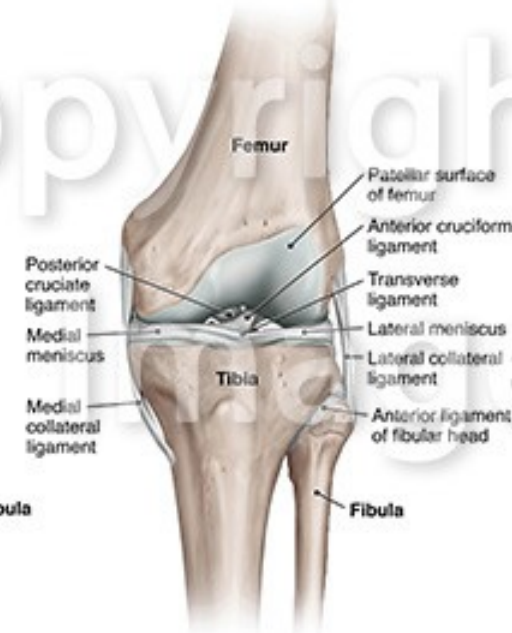MUDR. JAN EMMER, I. ORTOPEDICKÁ KLINIKA FNUSA V BRNĚ

# Knee Joint Anatomy

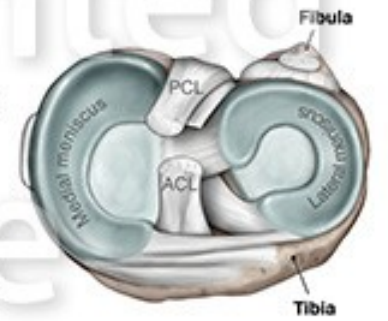**Anterior View of Knee  
(Bone Anatomy)**

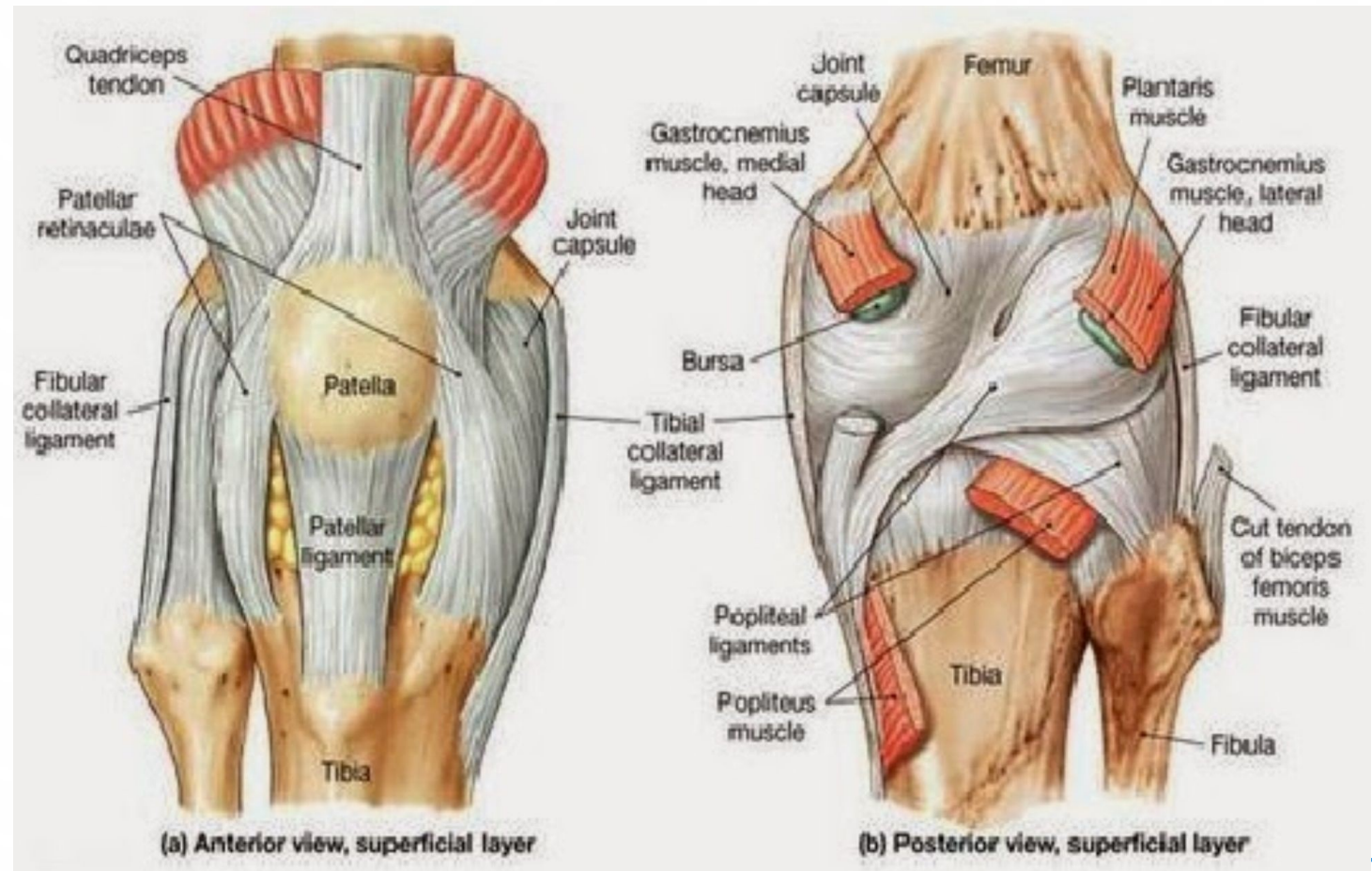


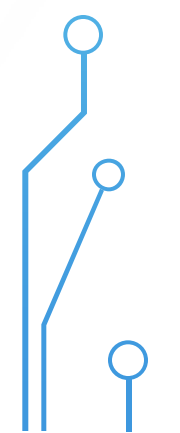

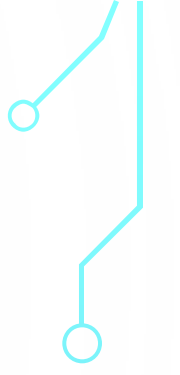
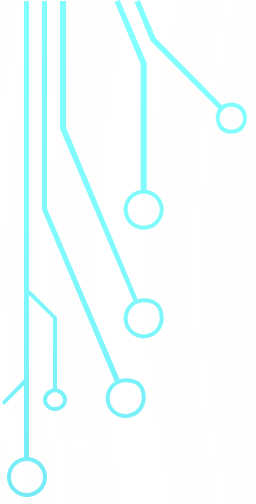
**Anterior View of Knee  
(Ligament Anatomy-Patella Removed)**



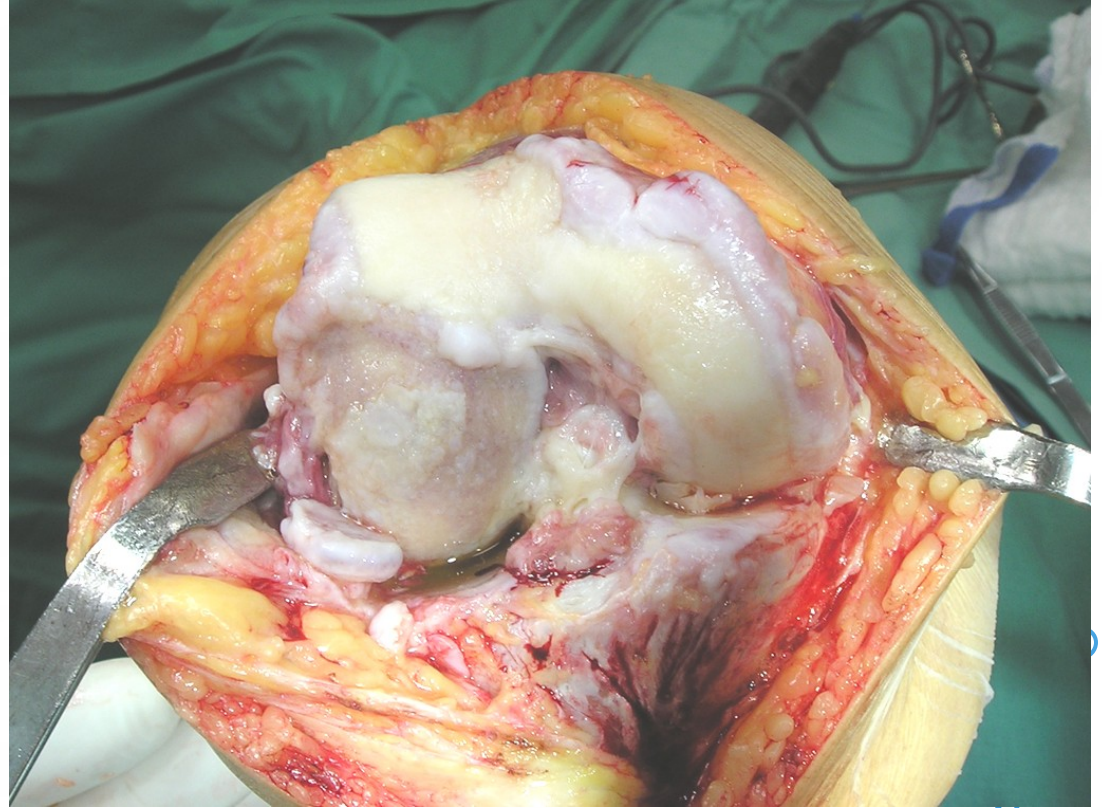
**Superior View of Tibial Plateau**



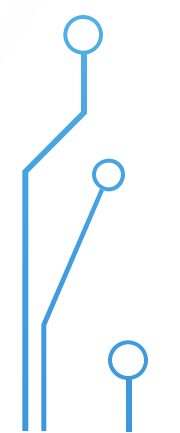

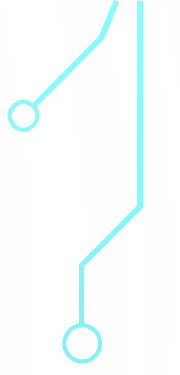
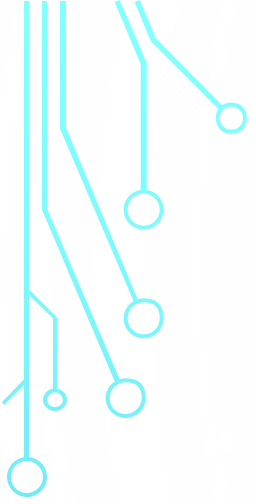






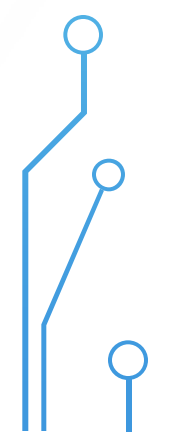

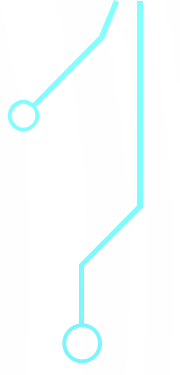
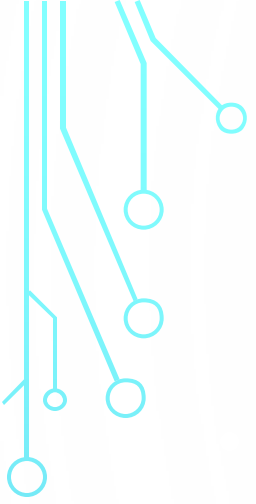


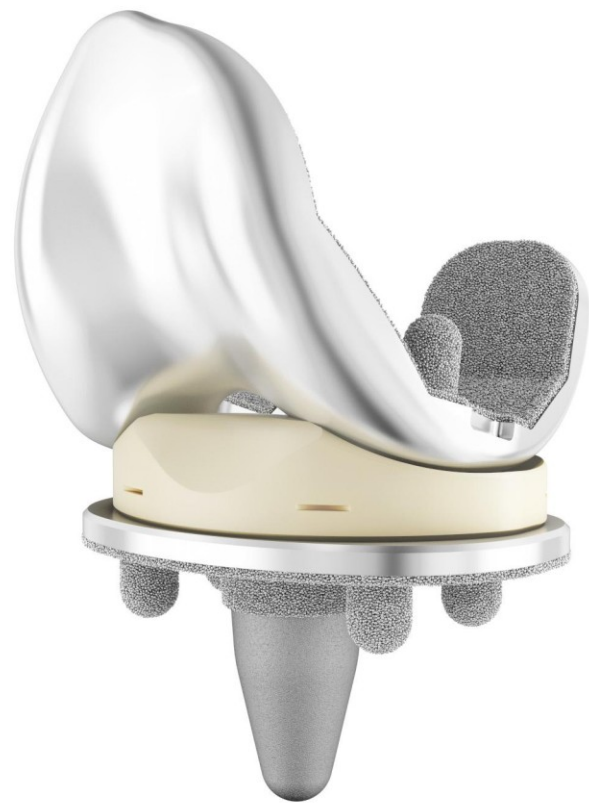



# VISIONS RESEARCH







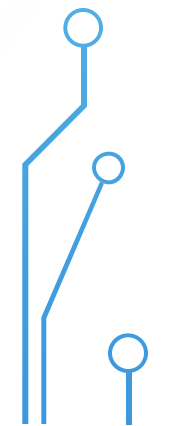
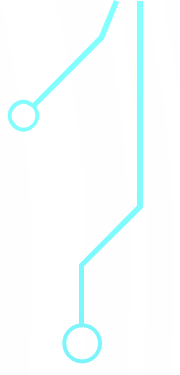
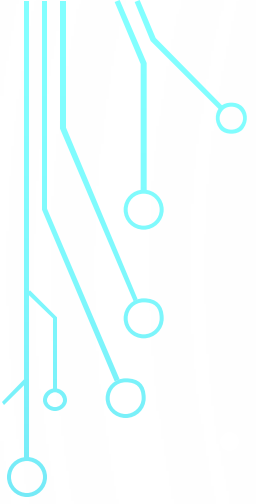


# ENERGY



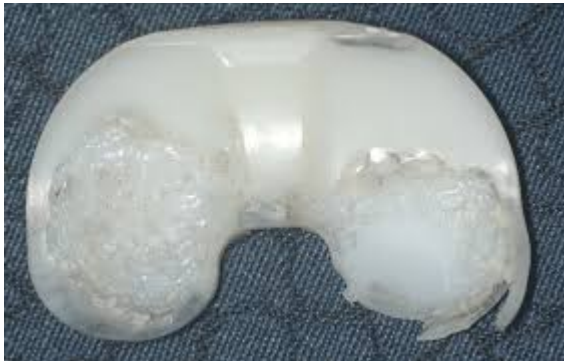






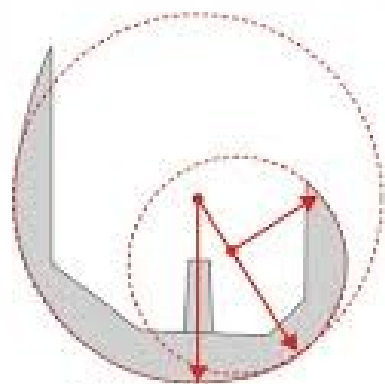




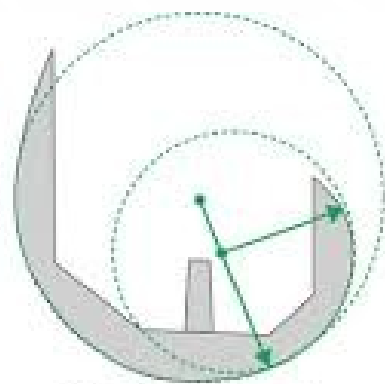









Multi-radii of curvature



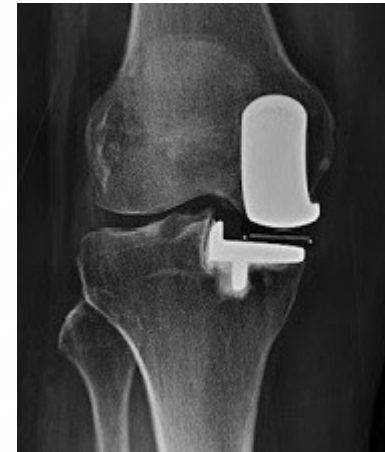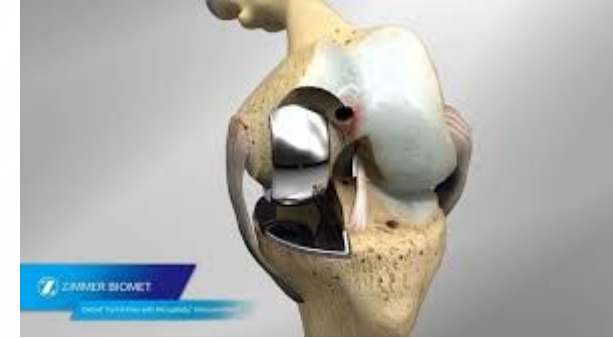"Single" radius of curvature

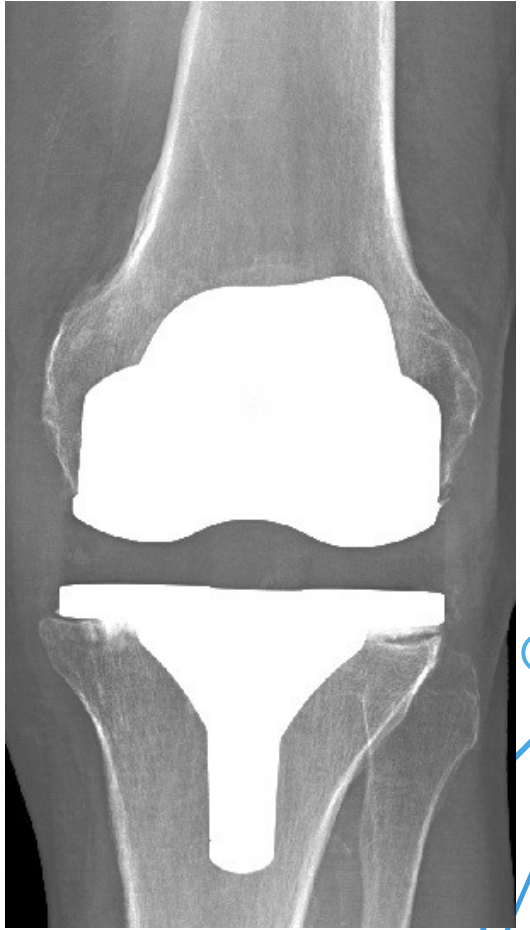
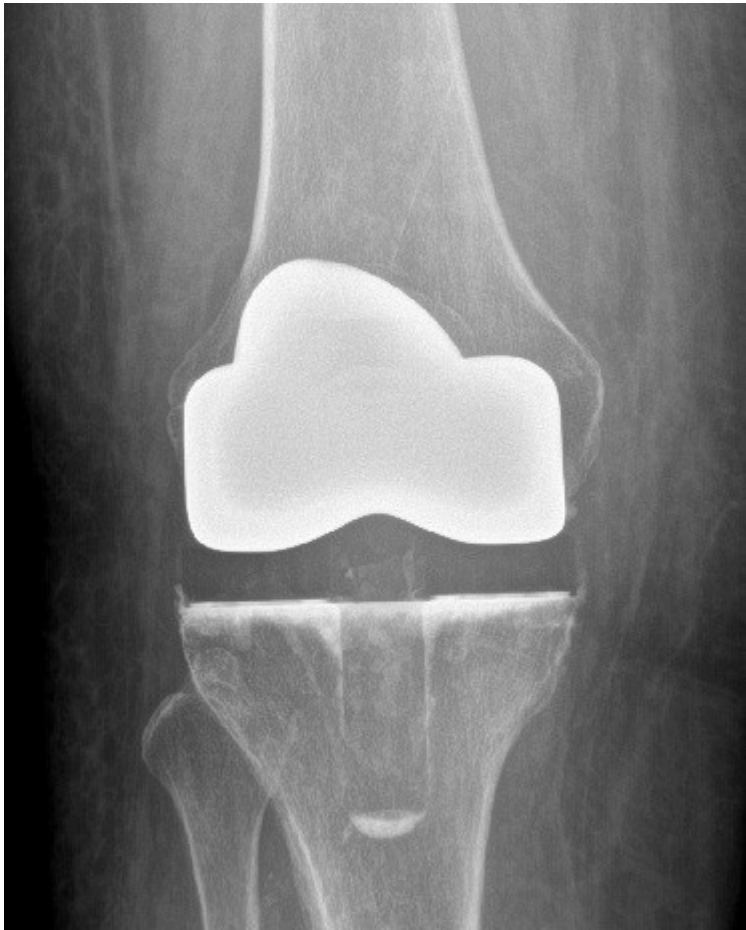

ATTUNE GRADIUS™ curve

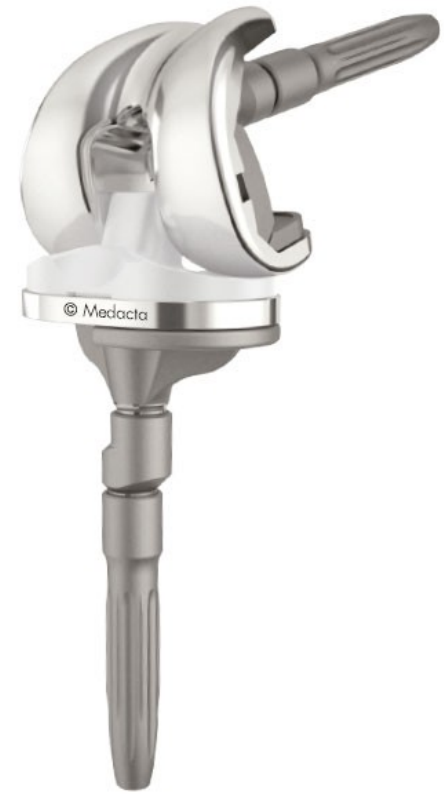

Asymmetric femoral condyles assist in recreating a medial pivot motion.

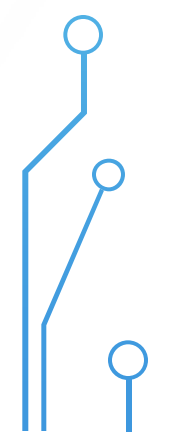

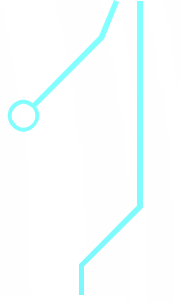
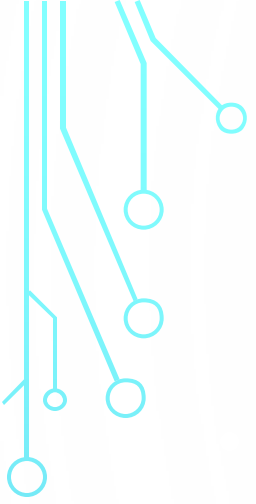




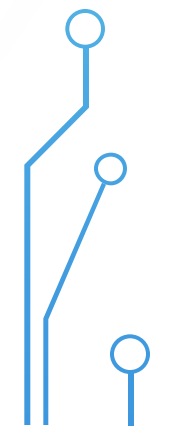
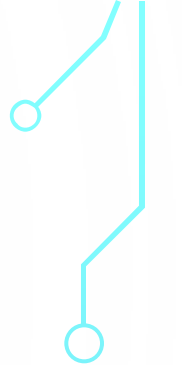
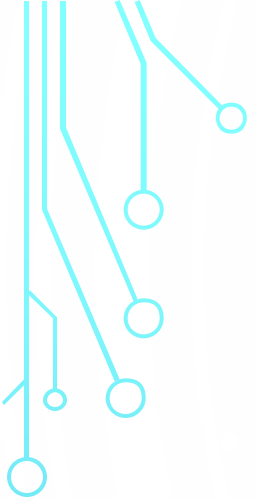


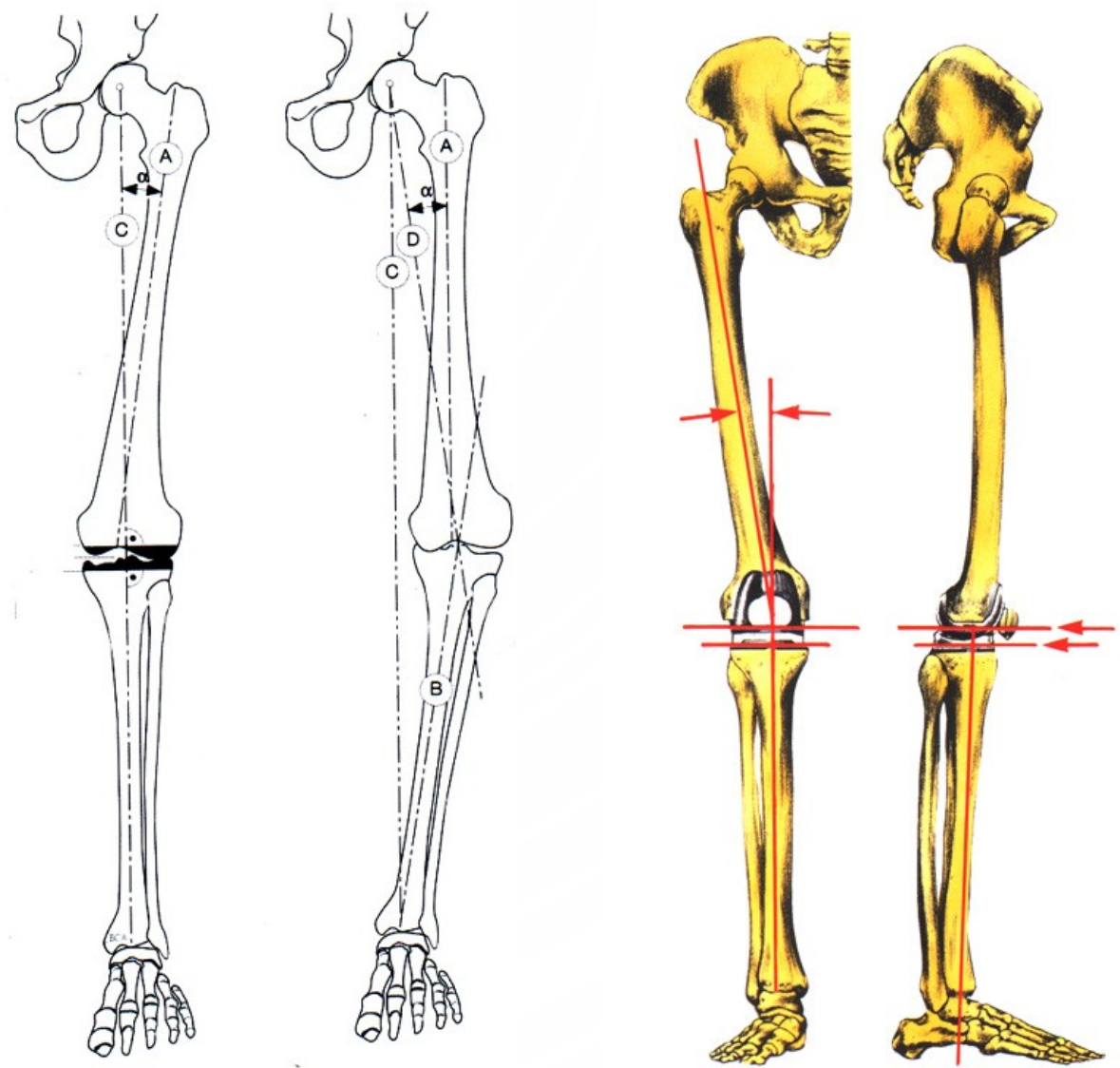


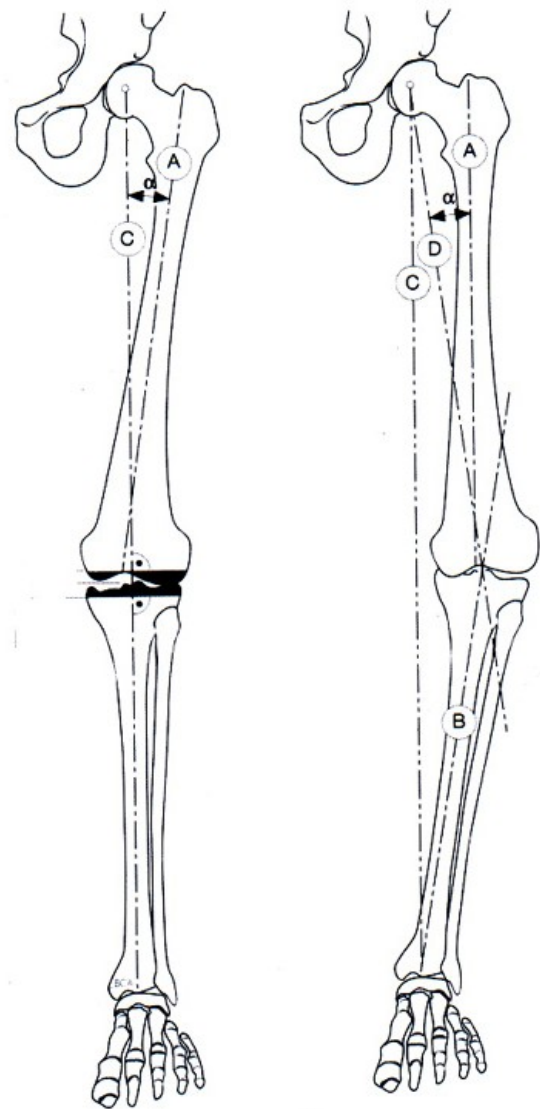


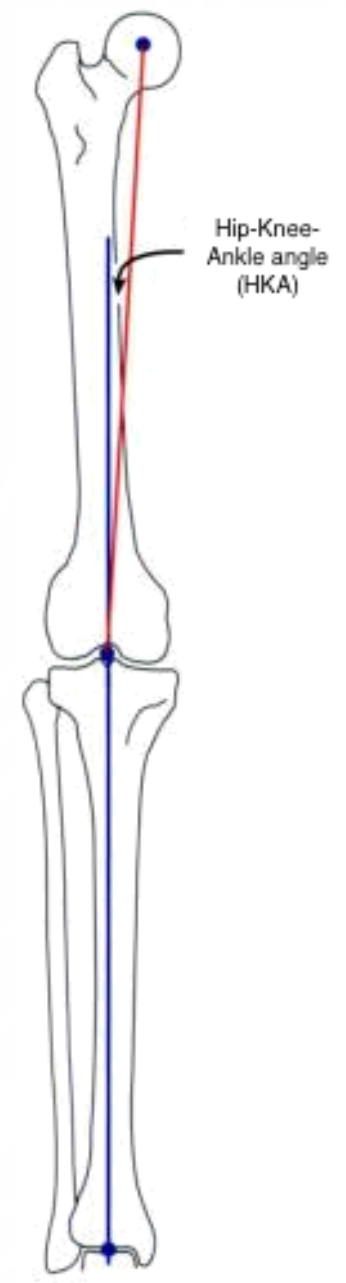

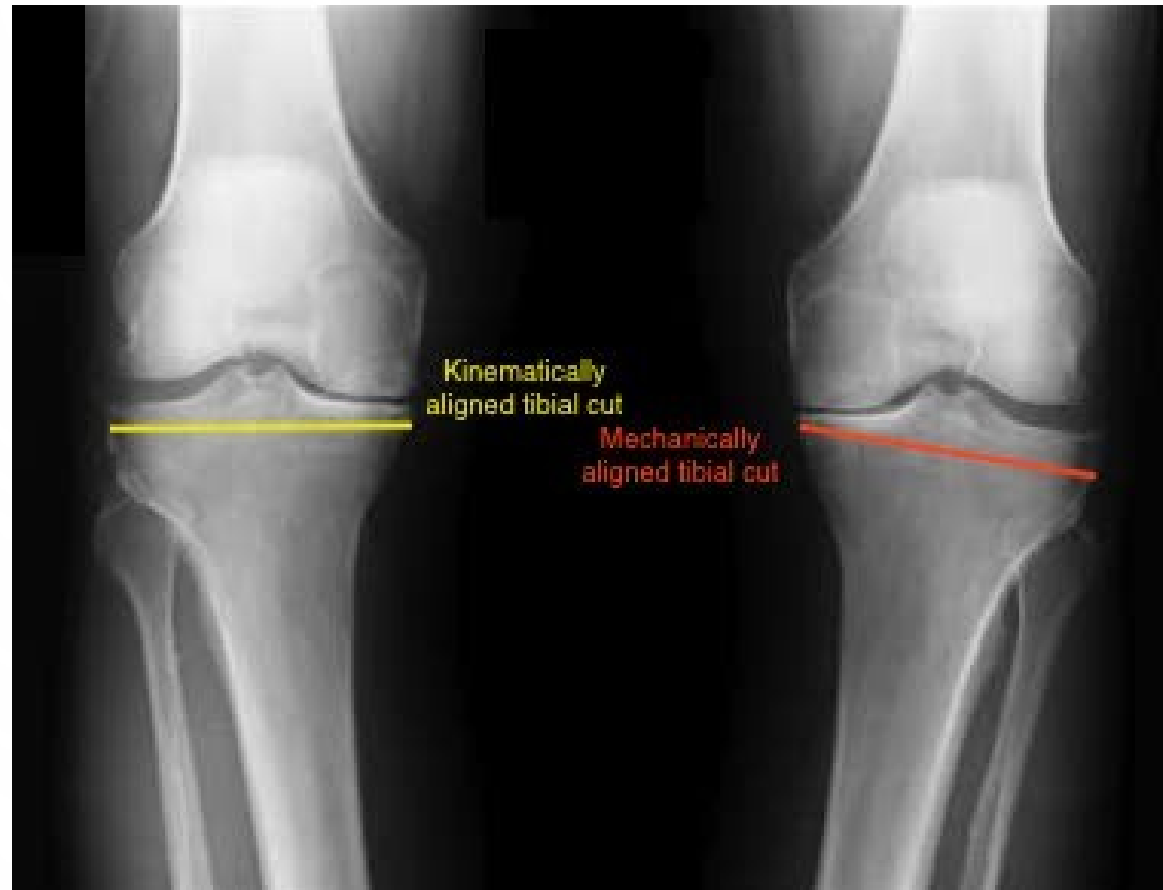
©AMINATI.COM

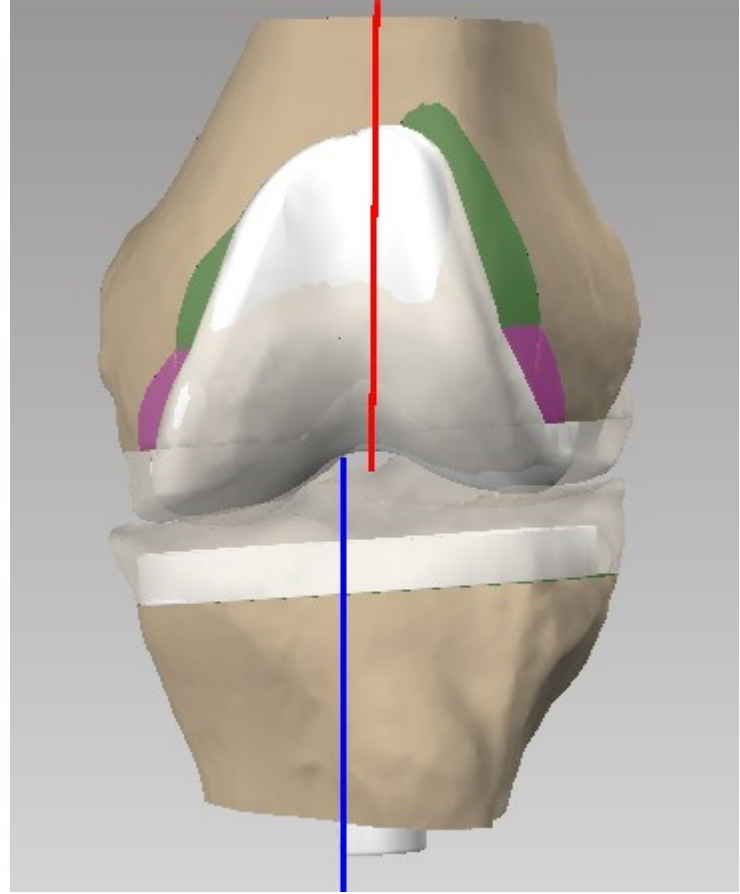
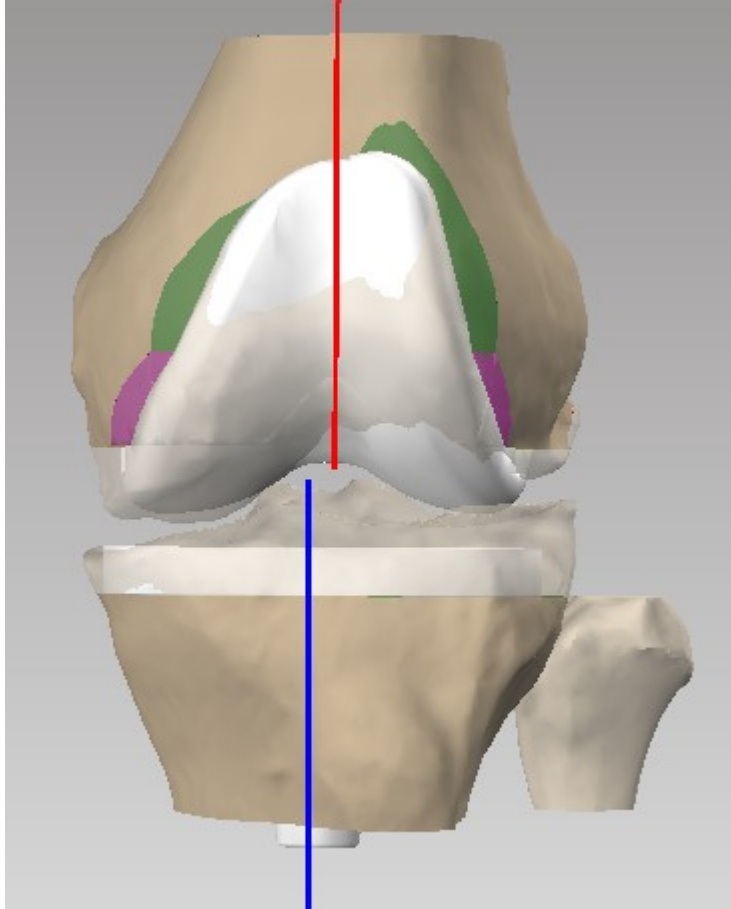


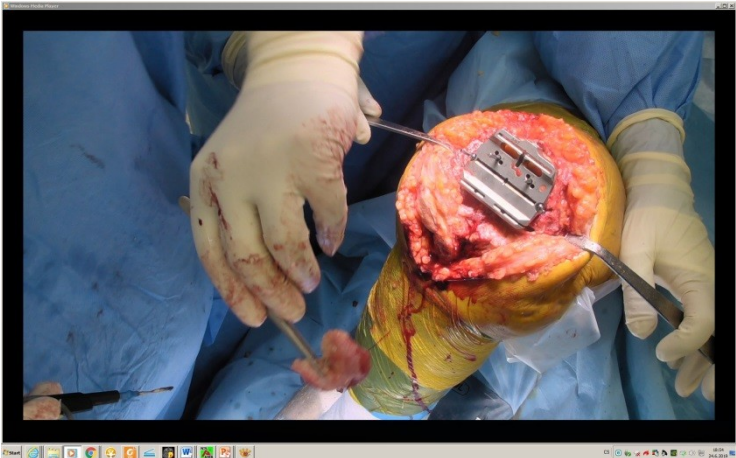
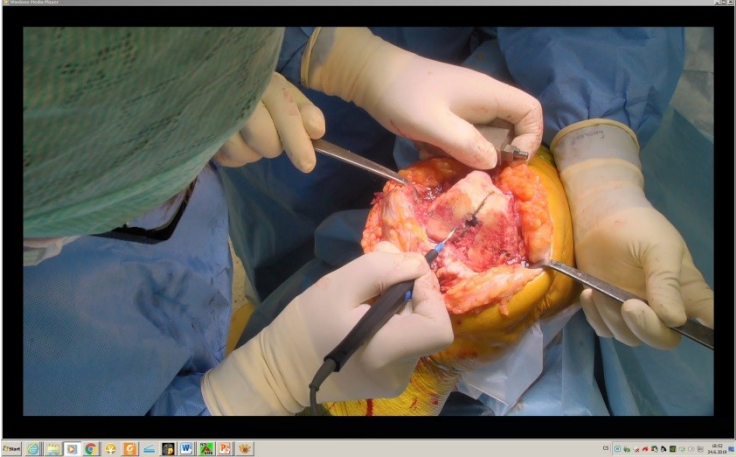




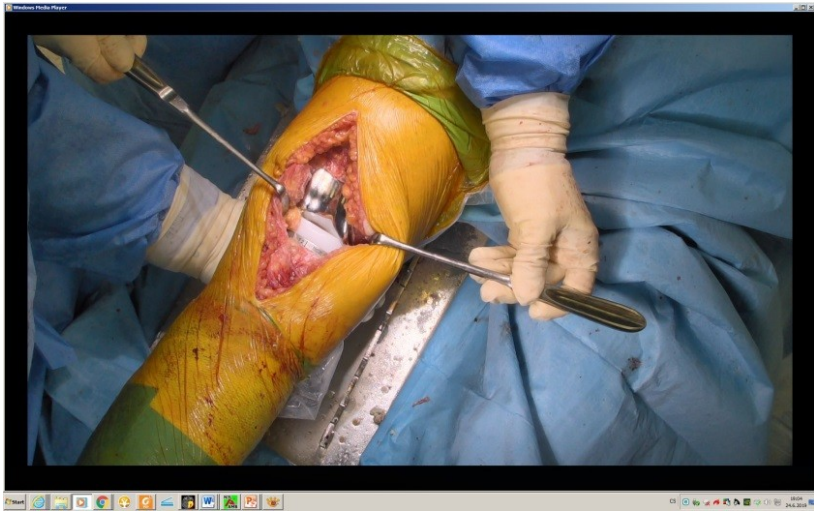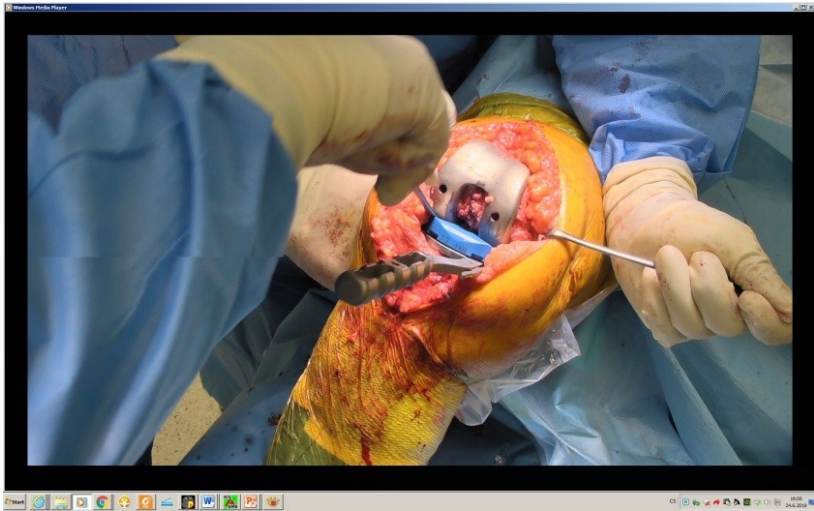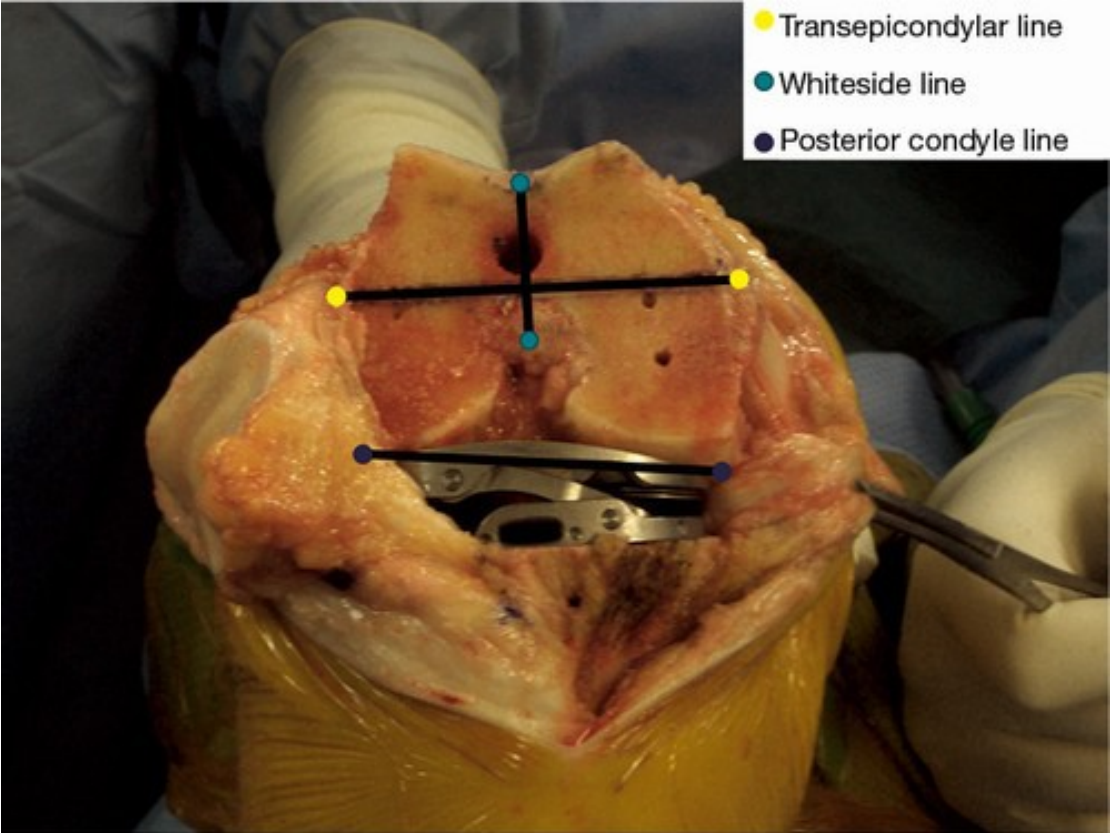




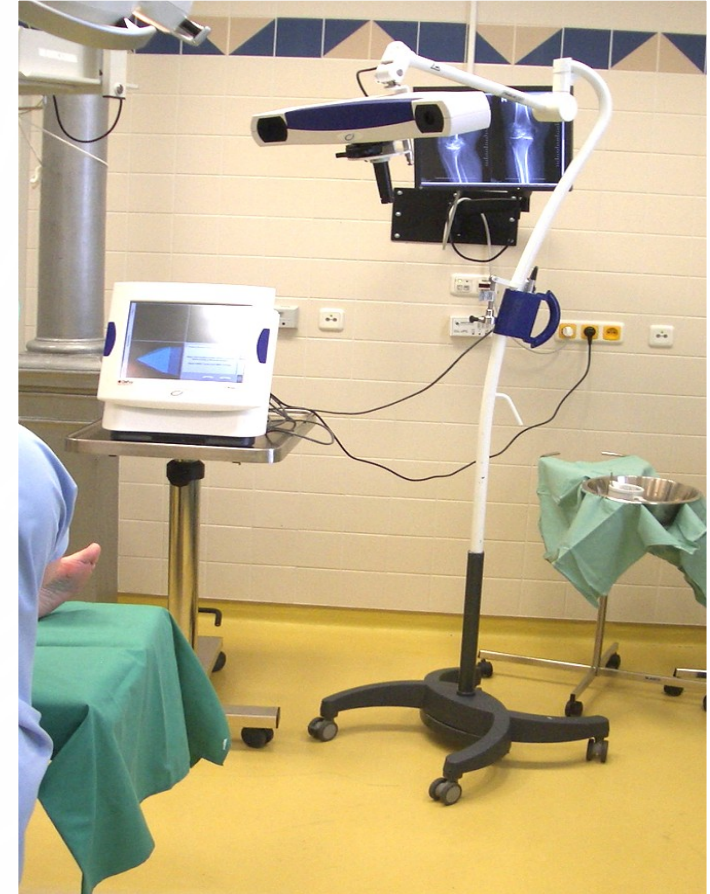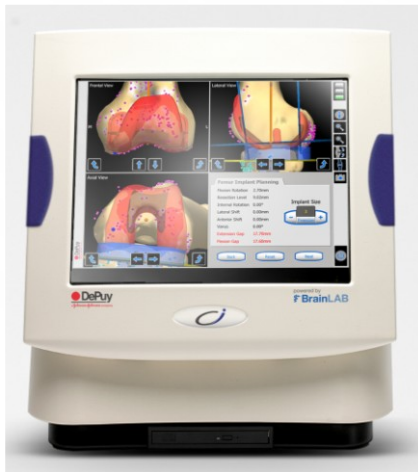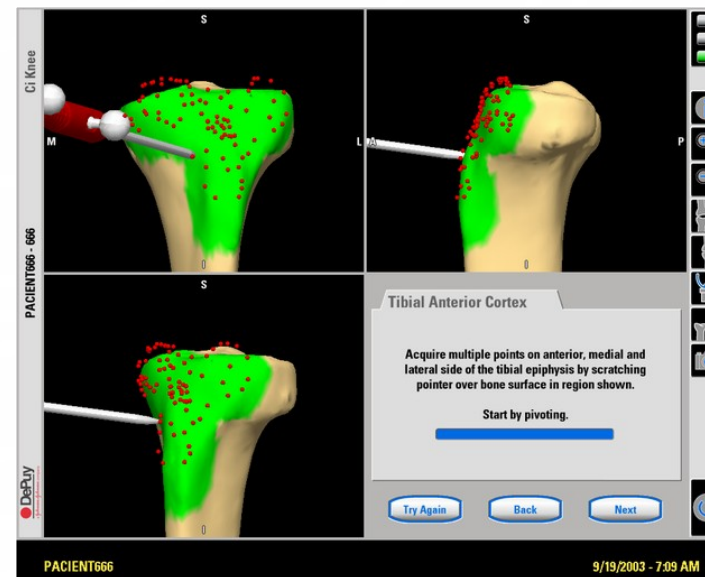
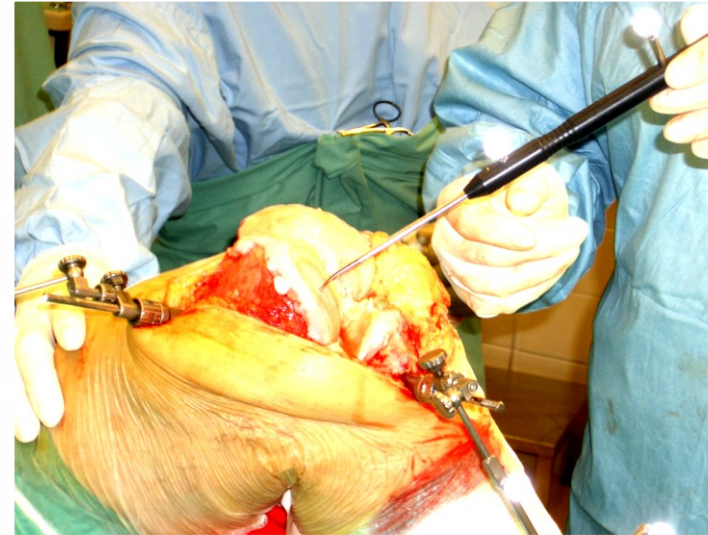




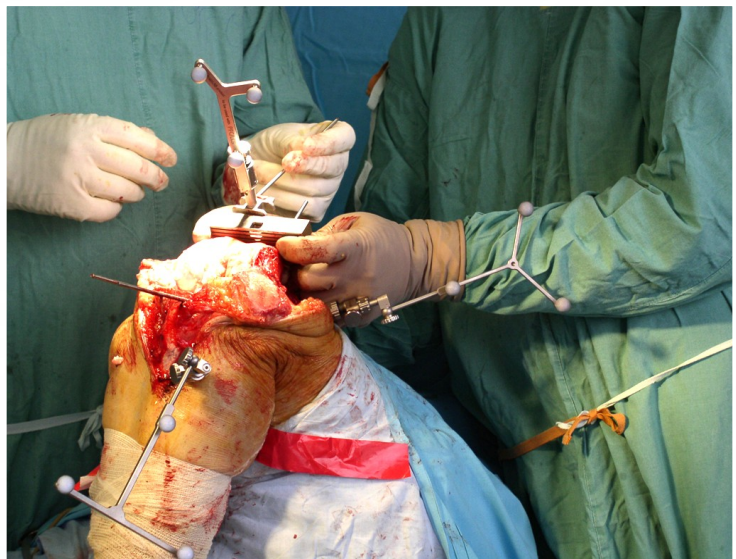
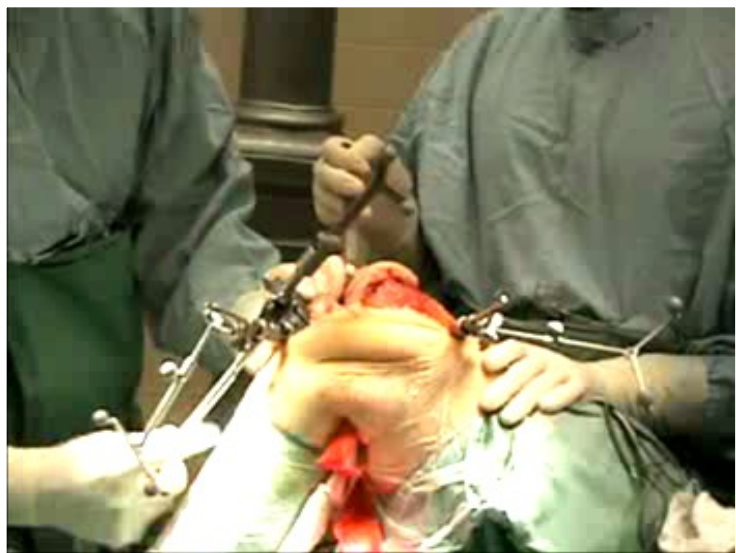










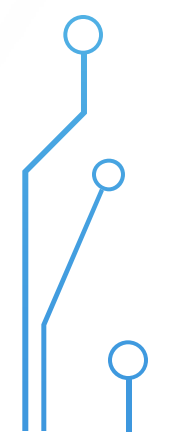
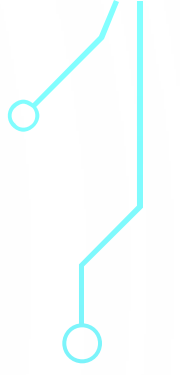
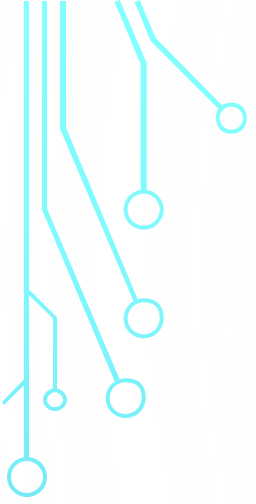








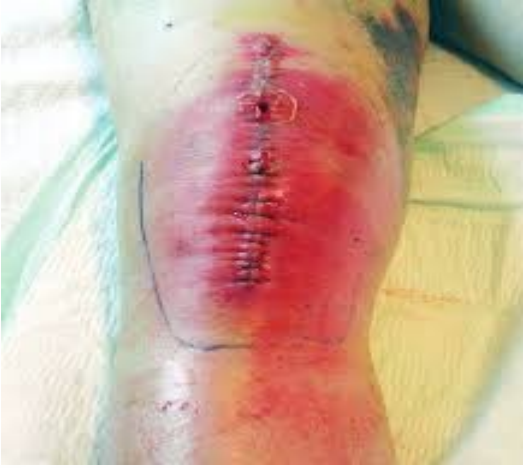
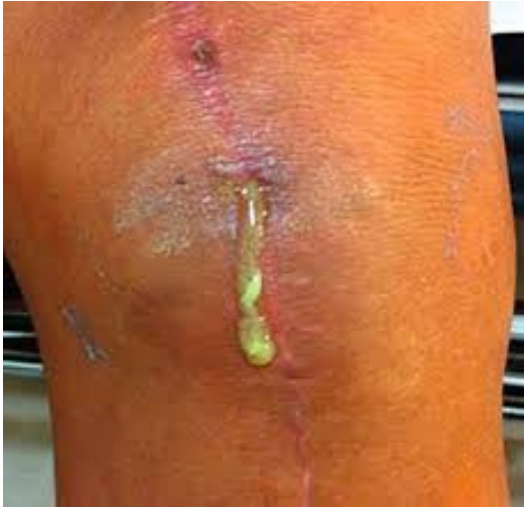
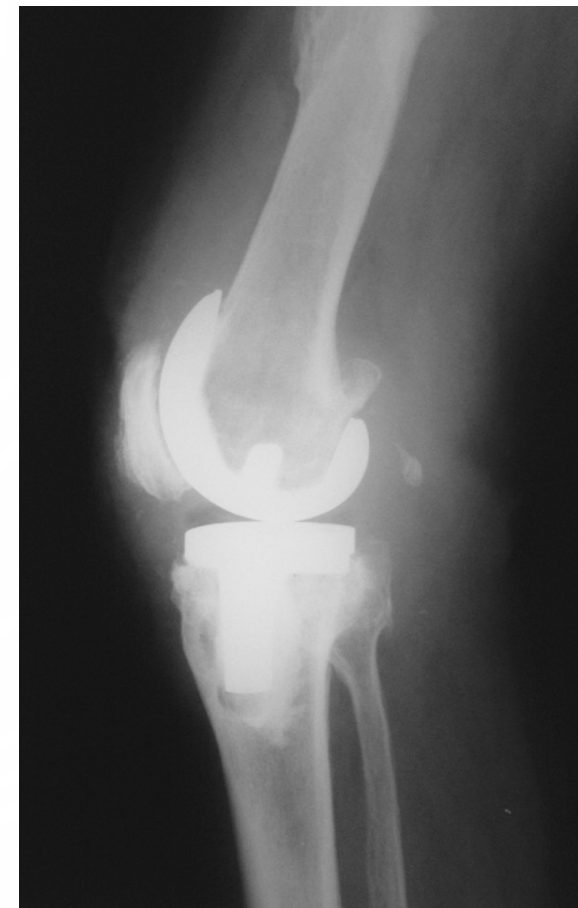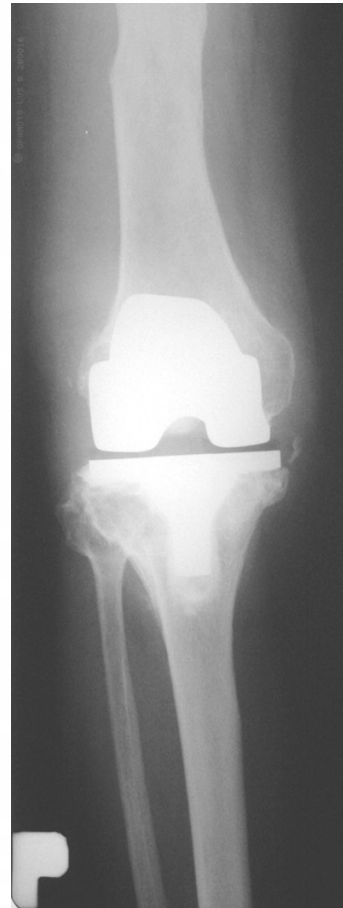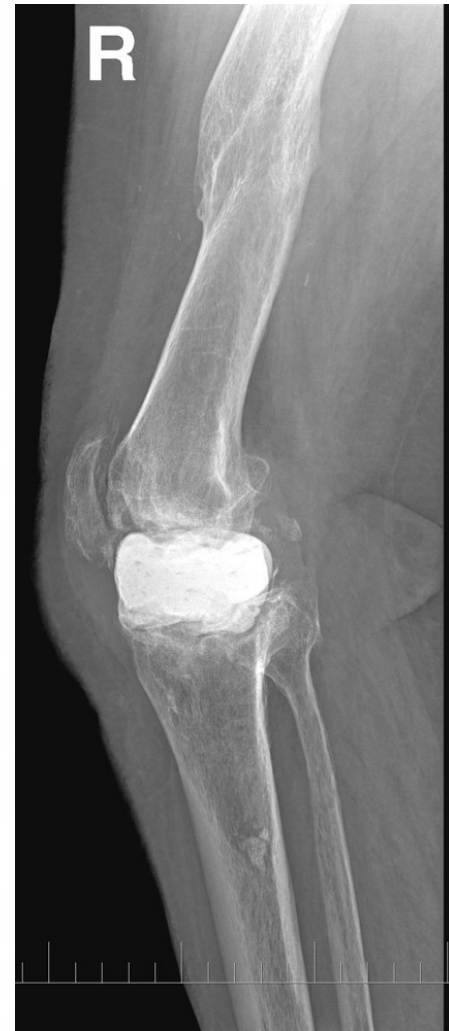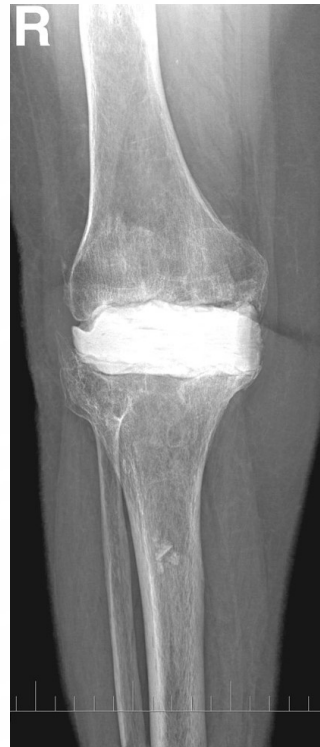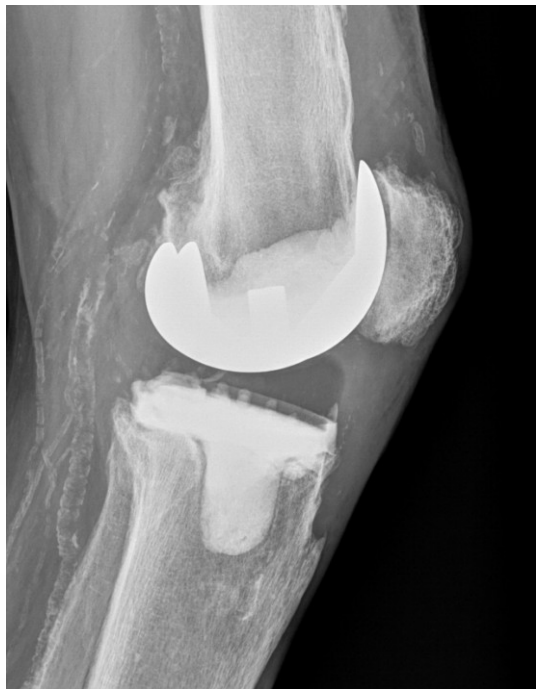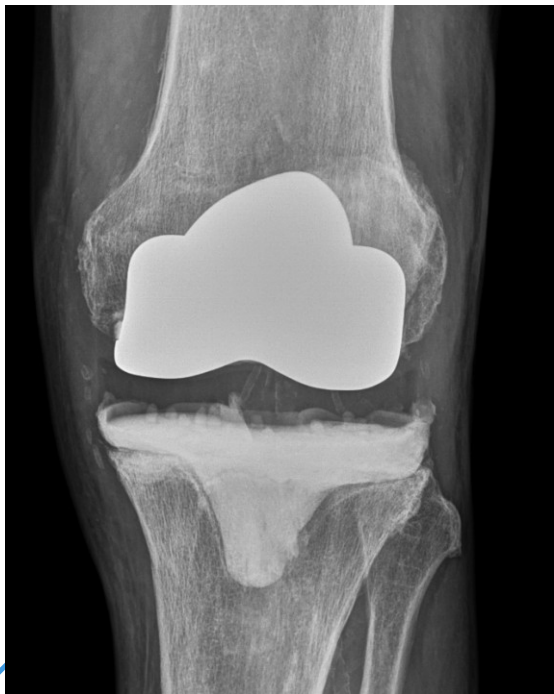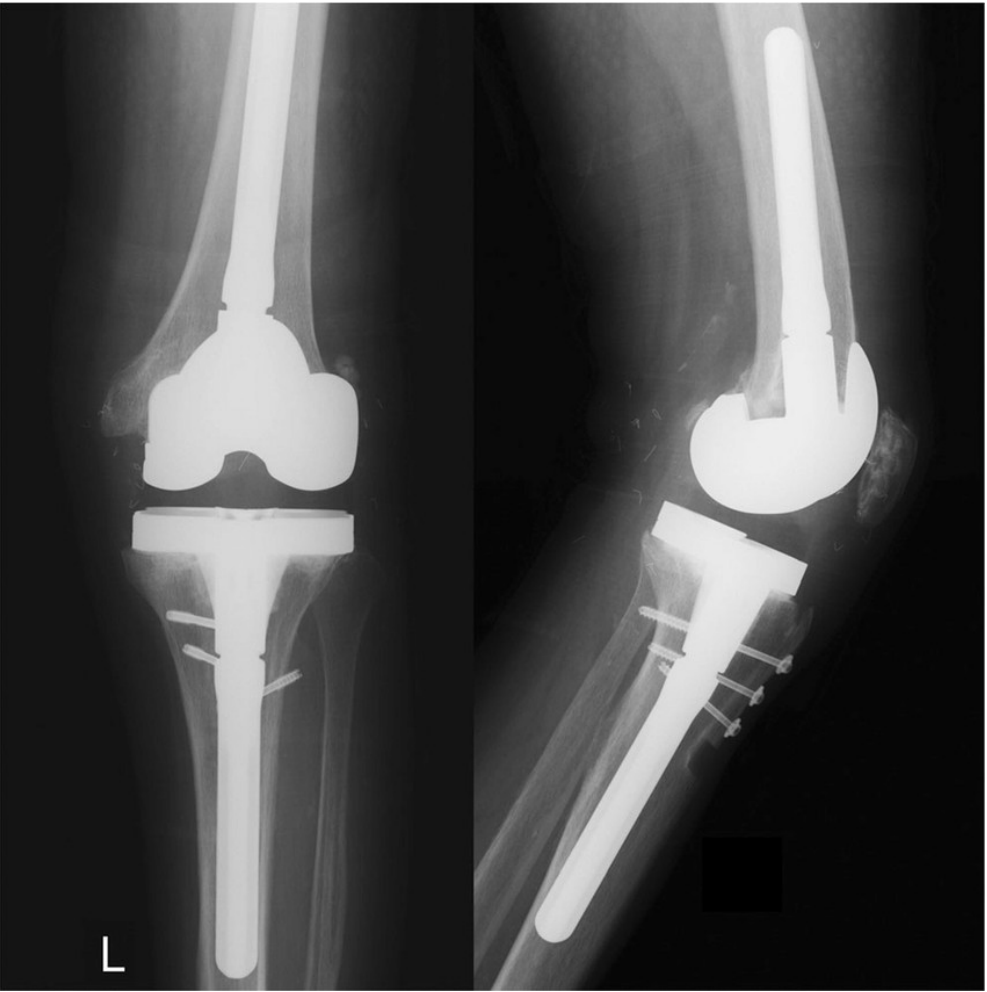










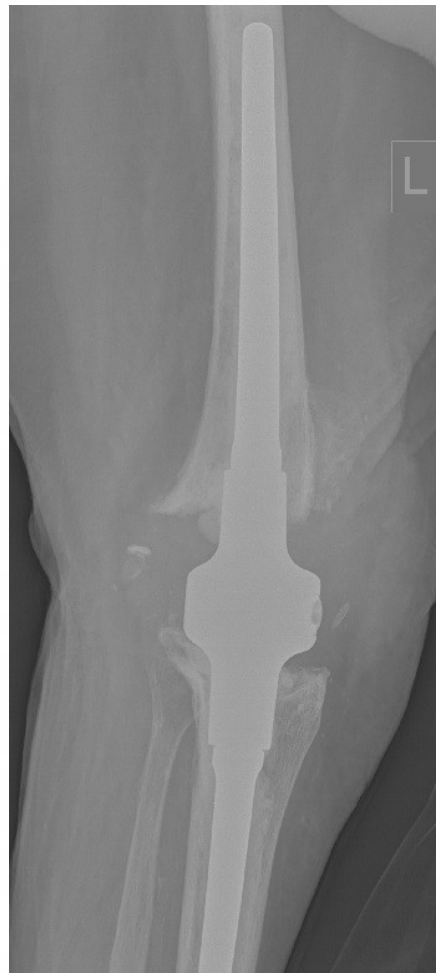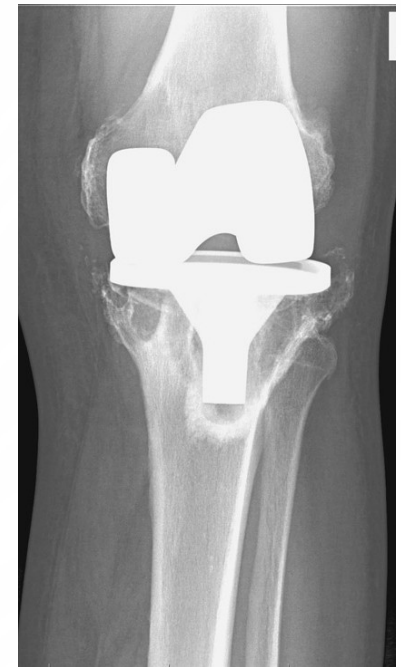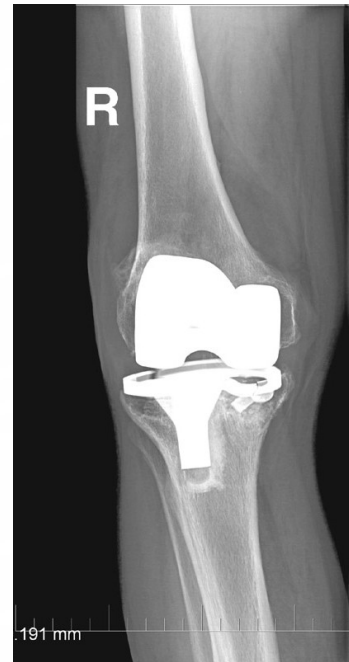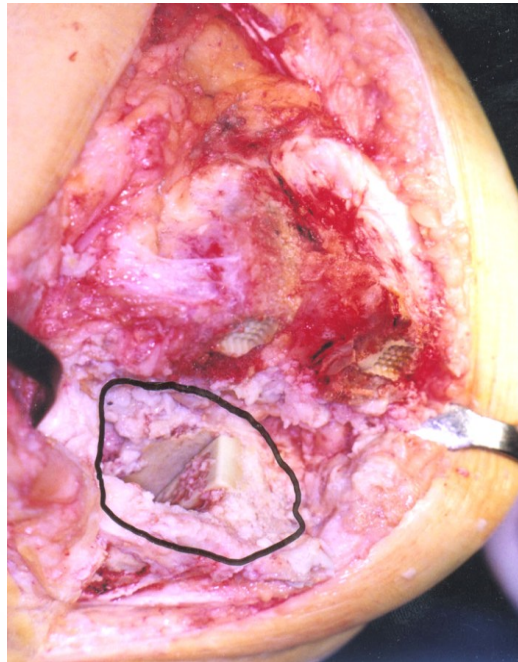




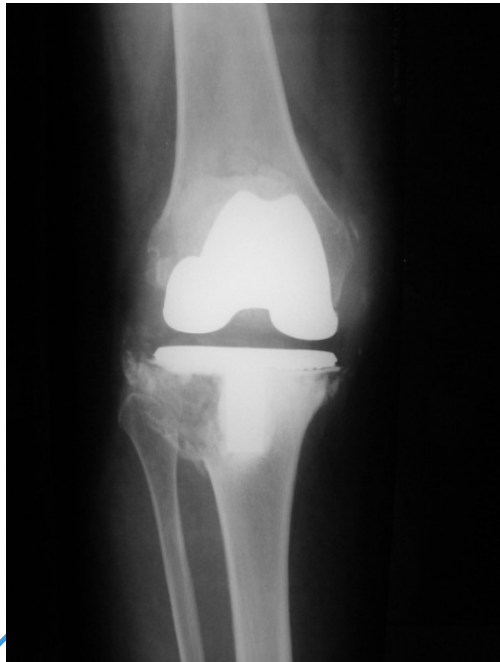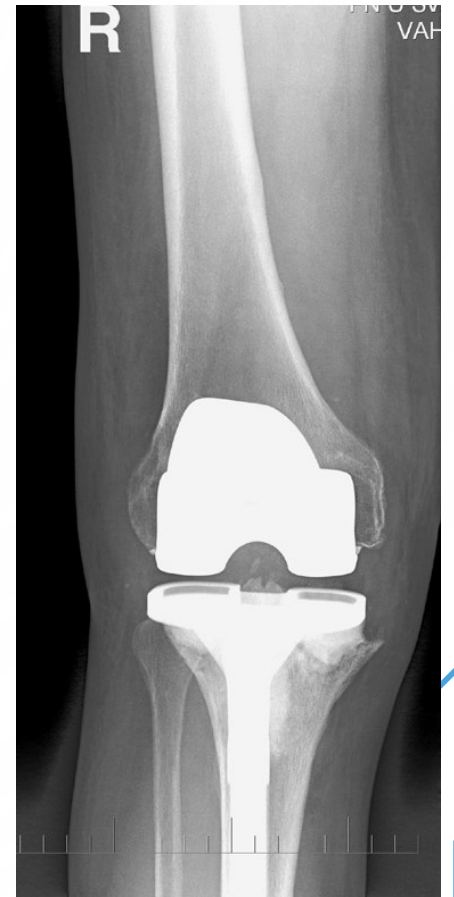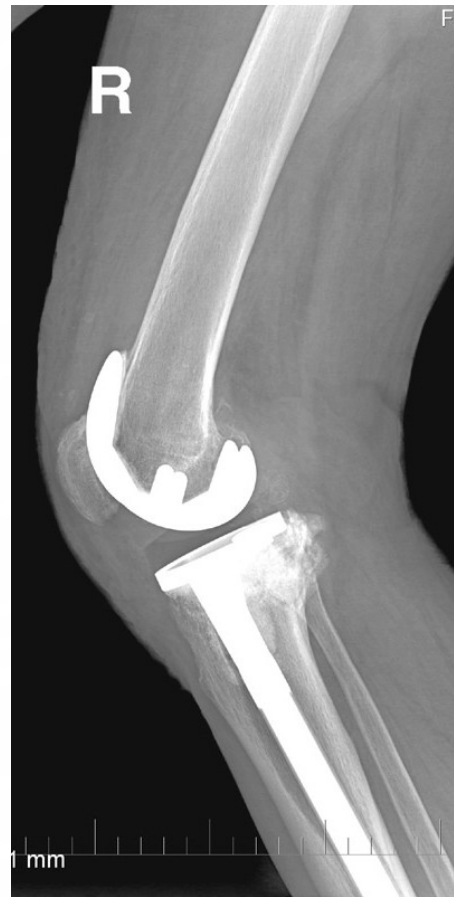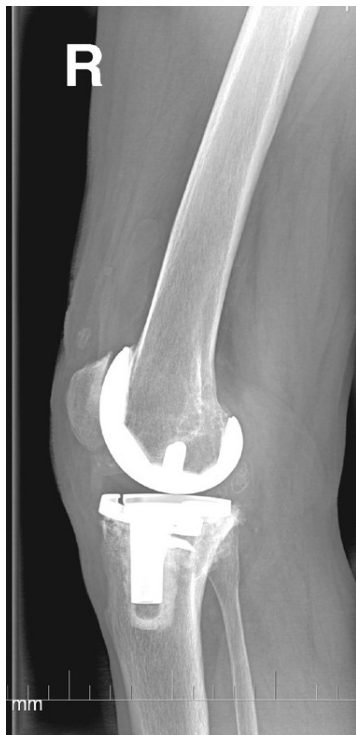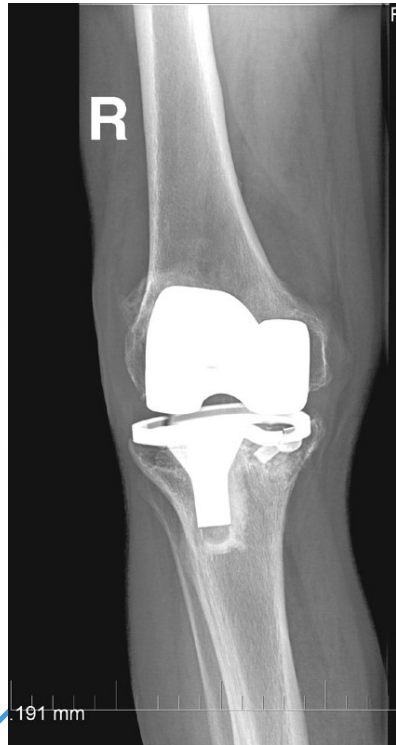© Copyright [www.attri.co.za](http://www.attri.co.za)

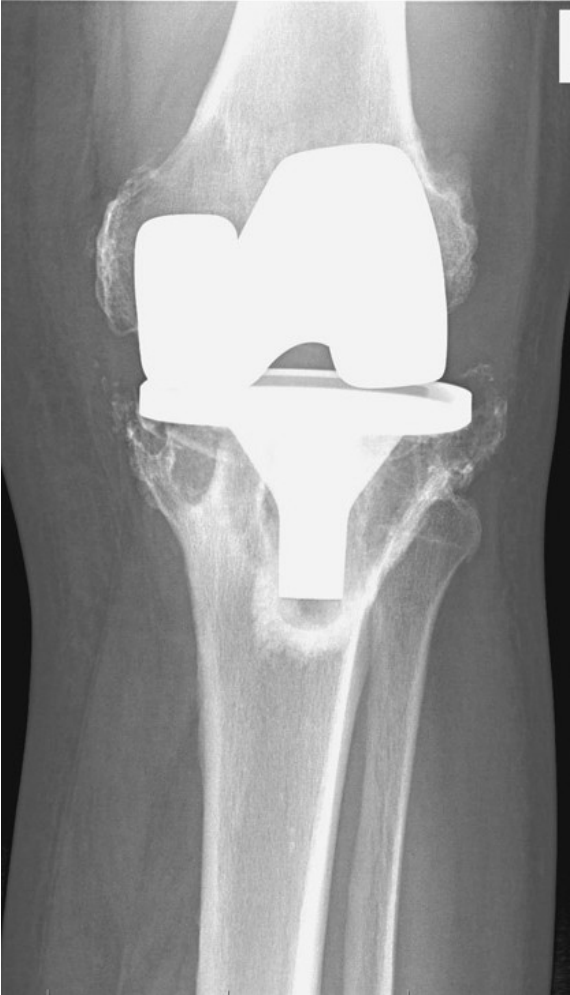


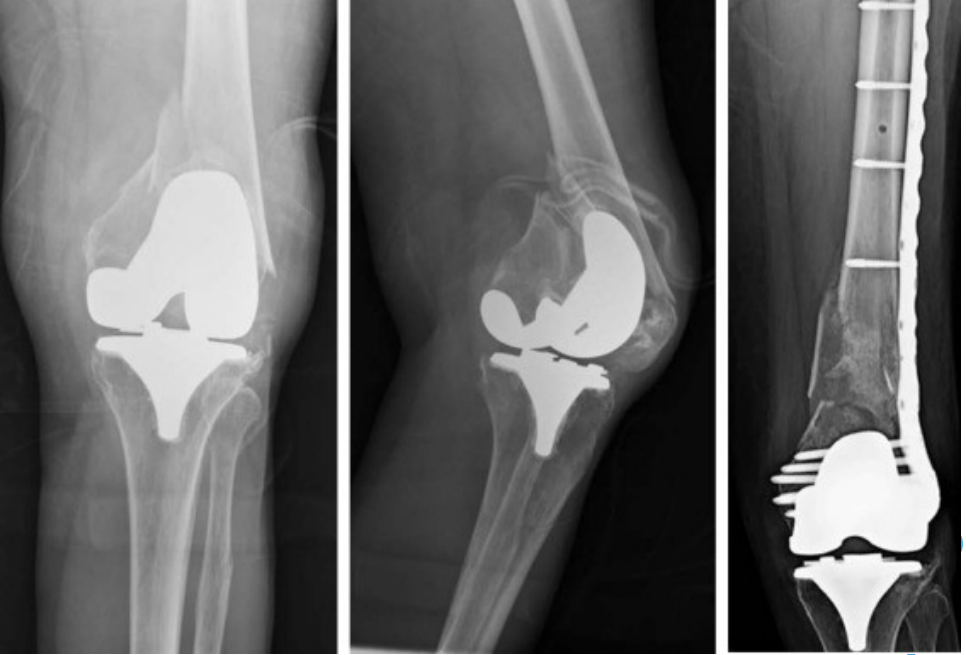
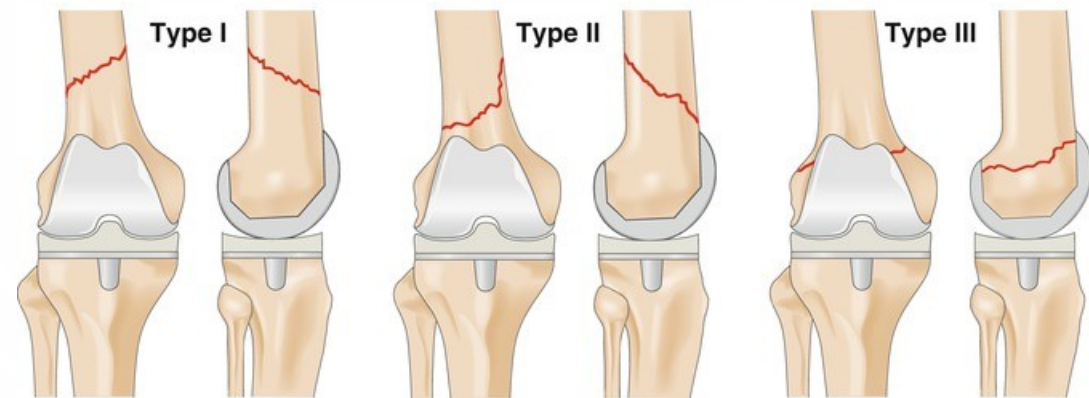


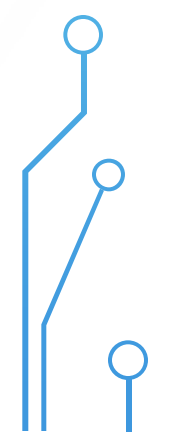

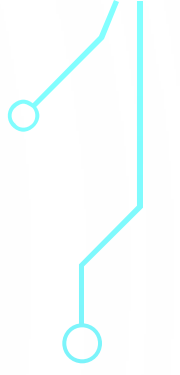
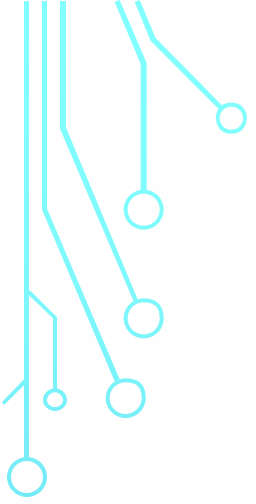












# COMPONENTS OF THE BUSINESS PLAN

## 1. EXECUTIVE SUMMARY

### 1.1. BUSINESS DESCRIPTION

### 1.2. MARKET ANALYSIS

### 1.3. FINANCIAL PROJECTIONS

### 1.4. MANAGEMENT TEAM

### 1.5. FUNDING REQUIREMENTS

### 1.6. RISK ANALYSIS

### 1.7. CONCLUSION

## 2. BUSINESS DESCRIPTION

### 2.1. BUSINESS MODEL

### 2.2. PRODUCTS AND SERVICES

### 2.3. OPERATIONAL PLAN

### 2.4. LEGAL STRUCTURE

