

Nose and paranasal sinuses

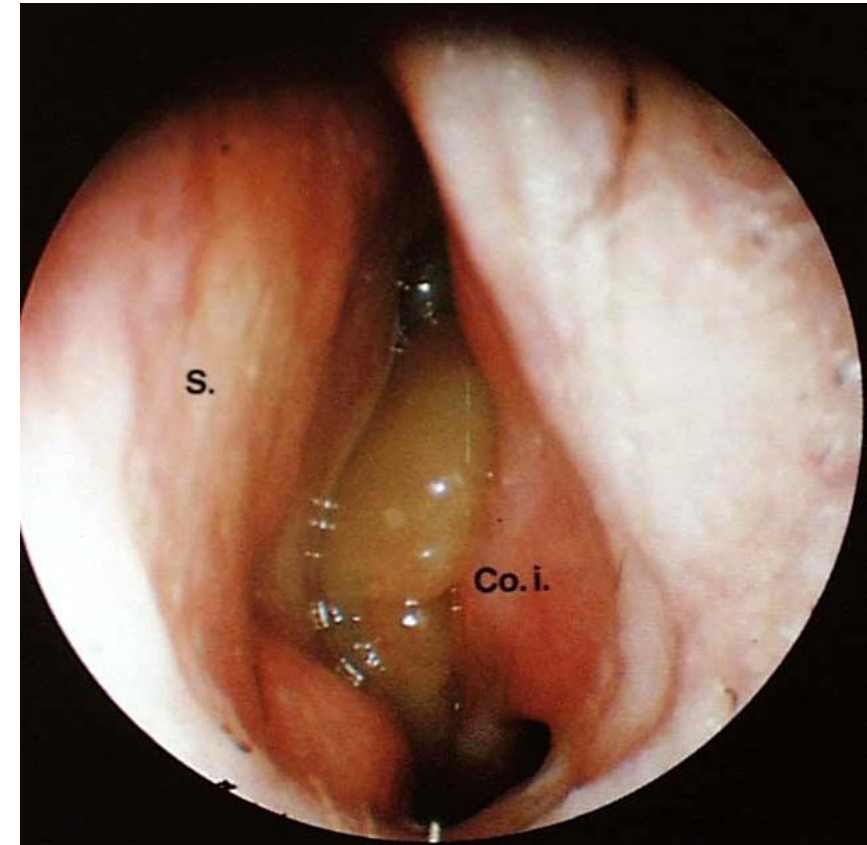


Ass.prof. Pavel Smilek, MD, Ph.D.

**ENT Clinic of Masaryk university, Brno
Faculty St. Ann Hospital**

Head: Ass.prof. Gál Břetislav, MD, Ph.D.

Pekařská 53, Brno , 656 91



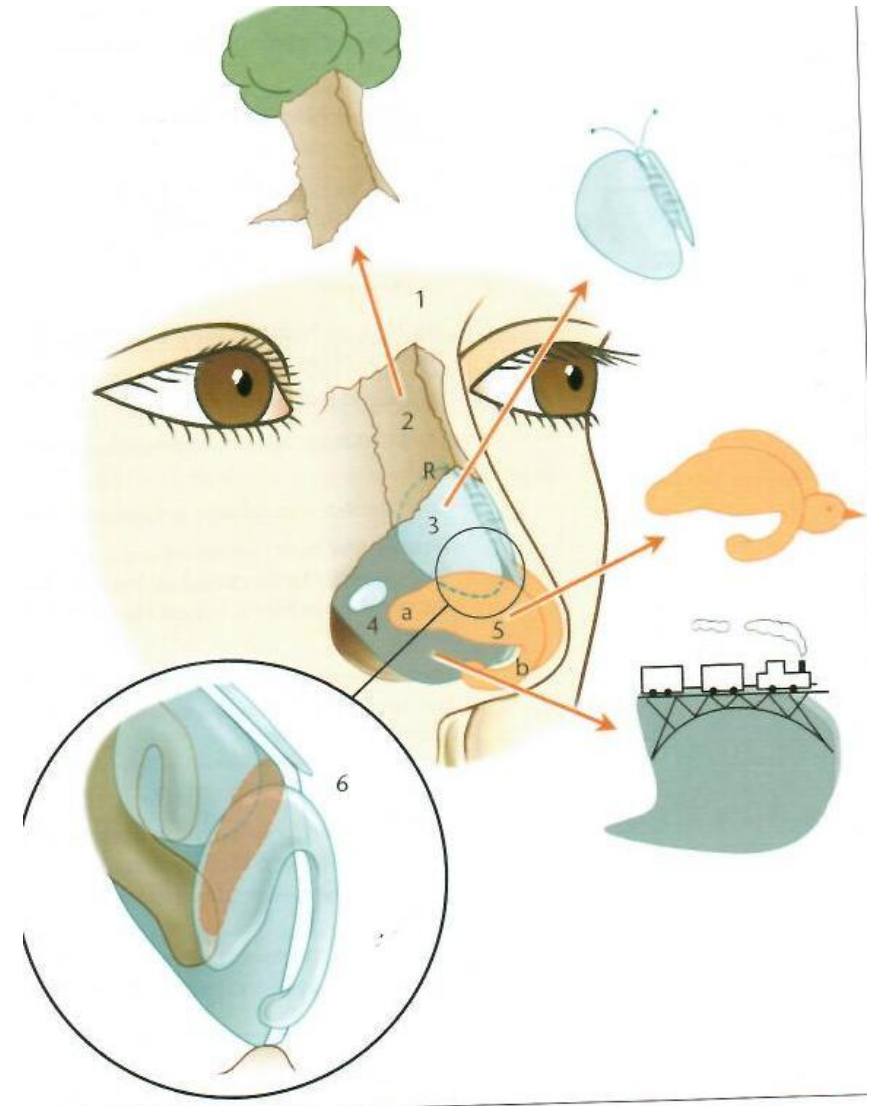


Function: vital (respiration), social (phonation, smell), protection and climatization of upper airways (reflexes)

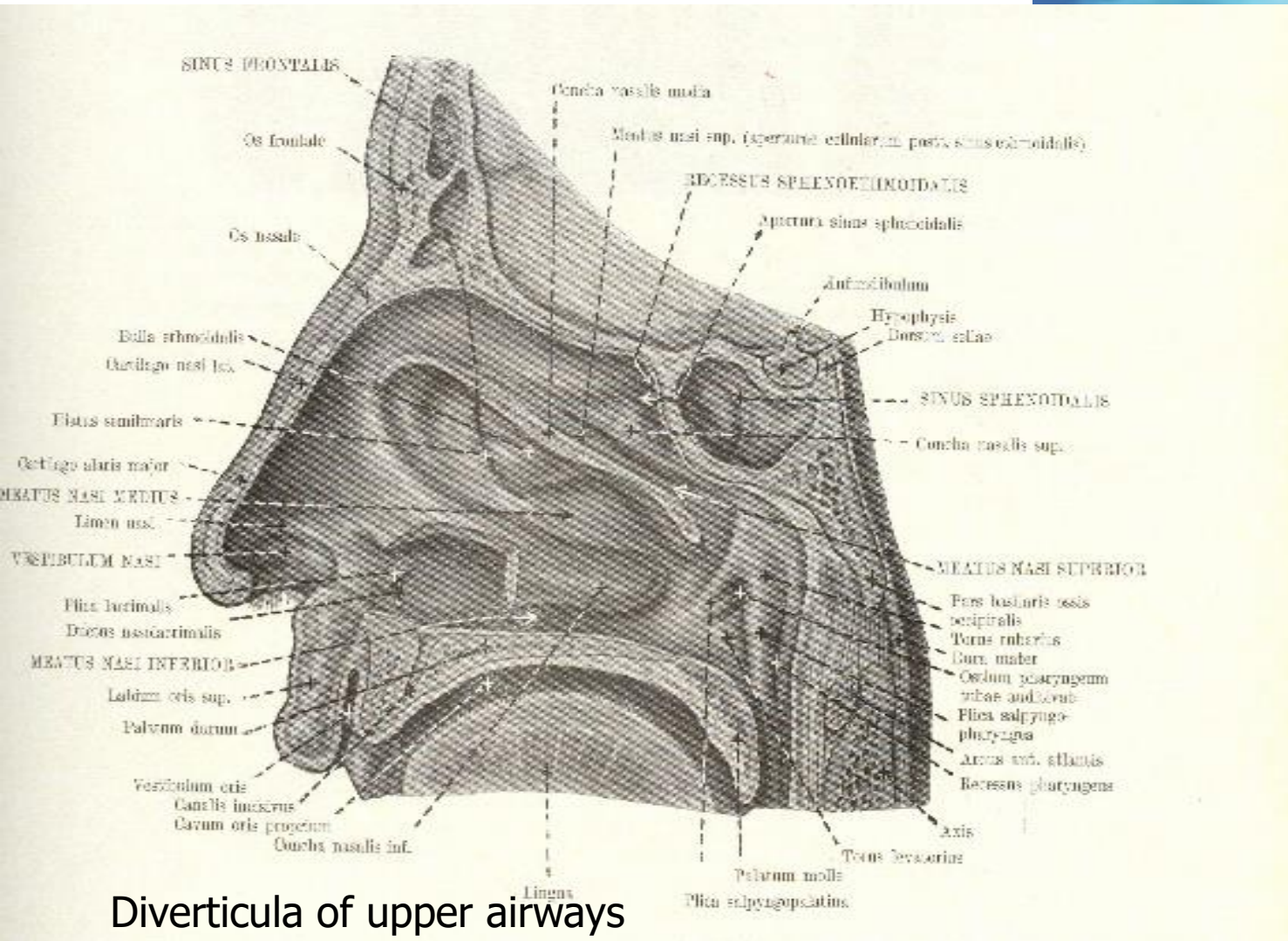
- **Respiratory** organ – ability to increase exchange of breathing gases 8-90 l/min, aerodynamic shape of the nose
- Perform both physical and immunologic **protection** from the environment, „mucociliar escalator“ – from more than 50 % are filtrated particles from 1 to 10µm
- **Air-conditioning function** – regulation of temperature on 34° C from -10 into +42 °C; moisturing – until 80% relative air humidity
- Sensory olfactory organ – **sense of smell**
- Involved in the formation of **speech sounds**
- The nose – major **esthetic** unit in the center of the nose

Applied anatomy

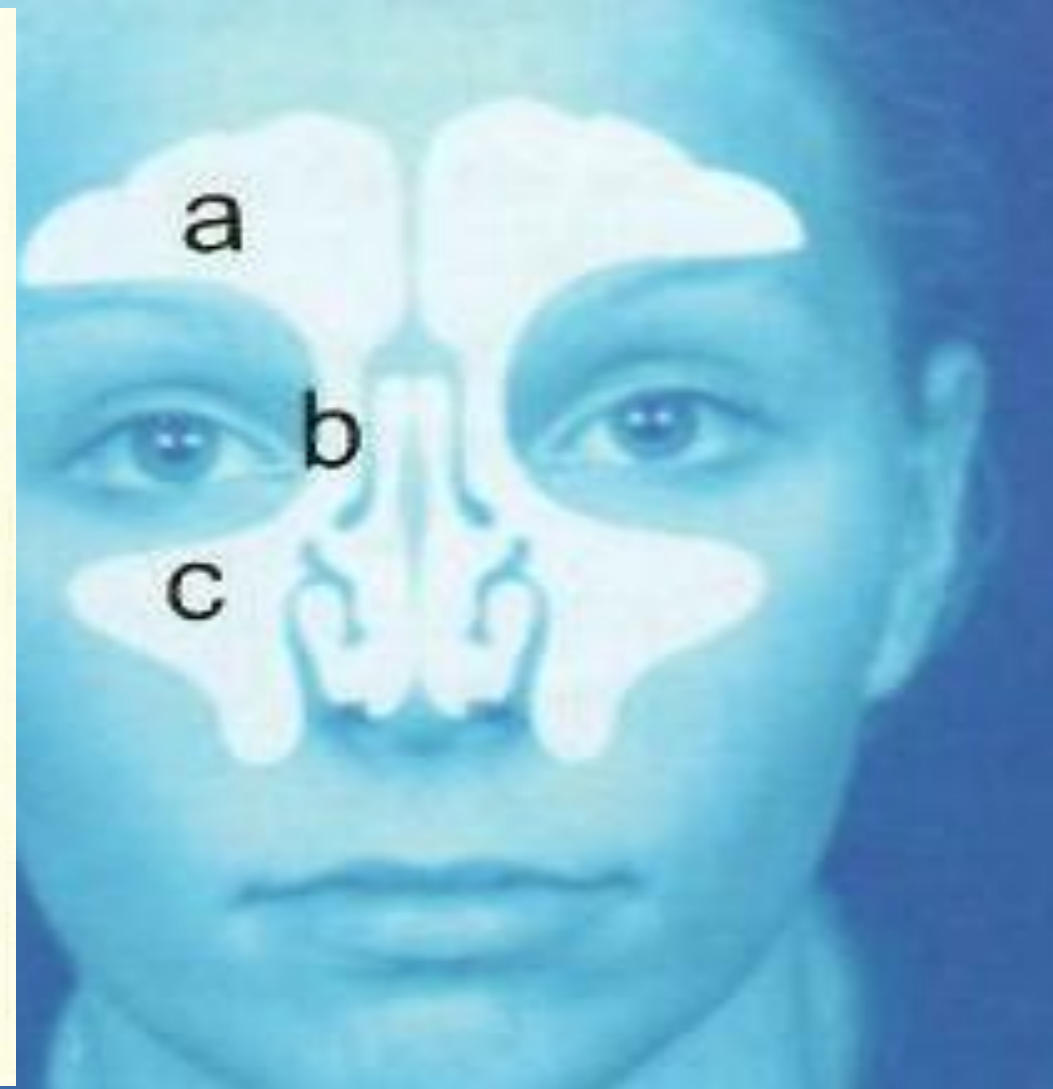
- External nose, the nasal skeleton, nasal bone, cartilages
- Nasal cavity (cavum nasi proprium)
 - Vestibulum naší, „limen nasi“ (the internal nasal valve), junction of vestibule and cavum nasi, prominence of the upper lateral cartilage)
 - Meatus nasi inferior, medius, superior
 - Meatus nasi comunis



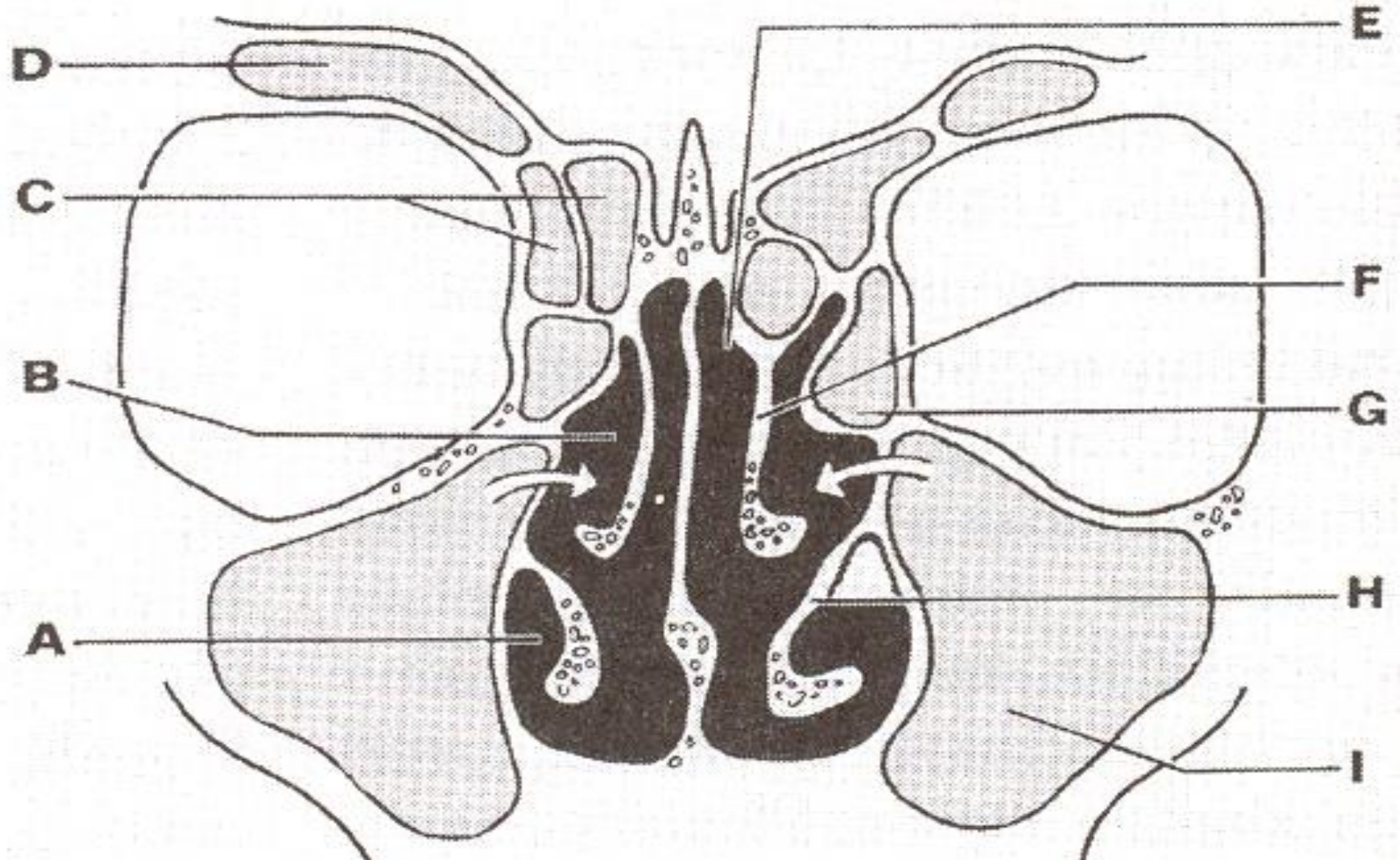
Paranasal sinuses



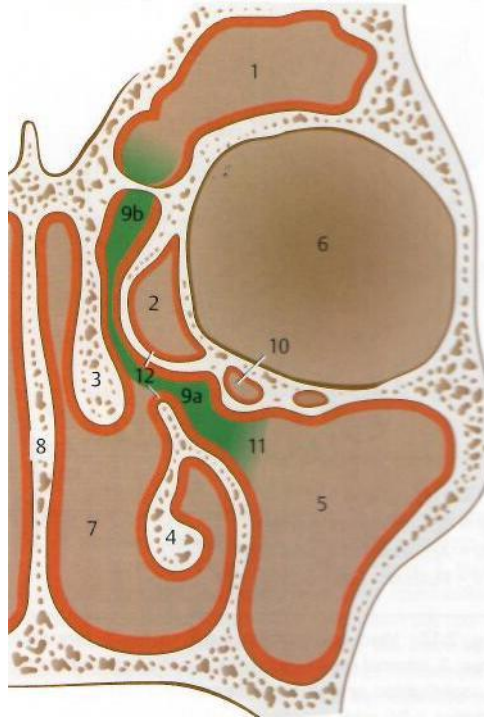
Diverticula of upper airways



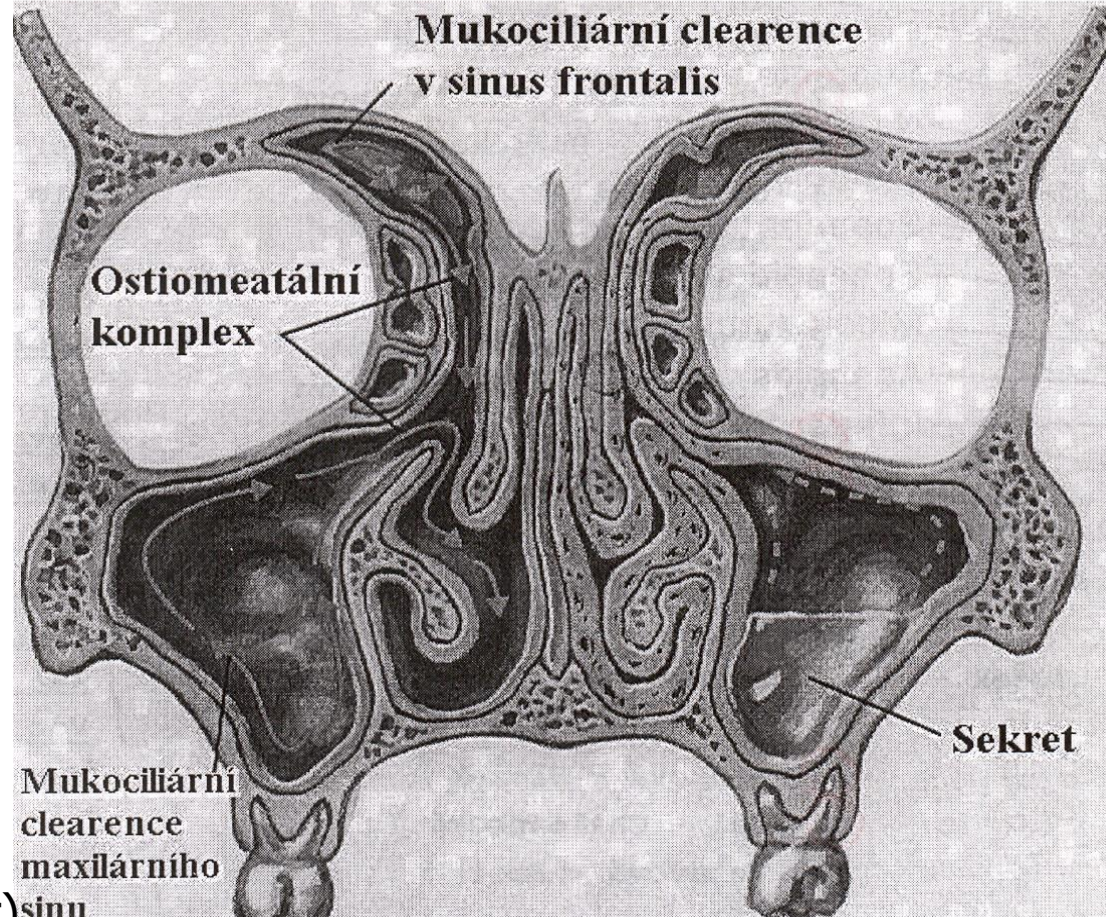
Lateral wall of nasal cavity



Ostiomeatal unit (green)

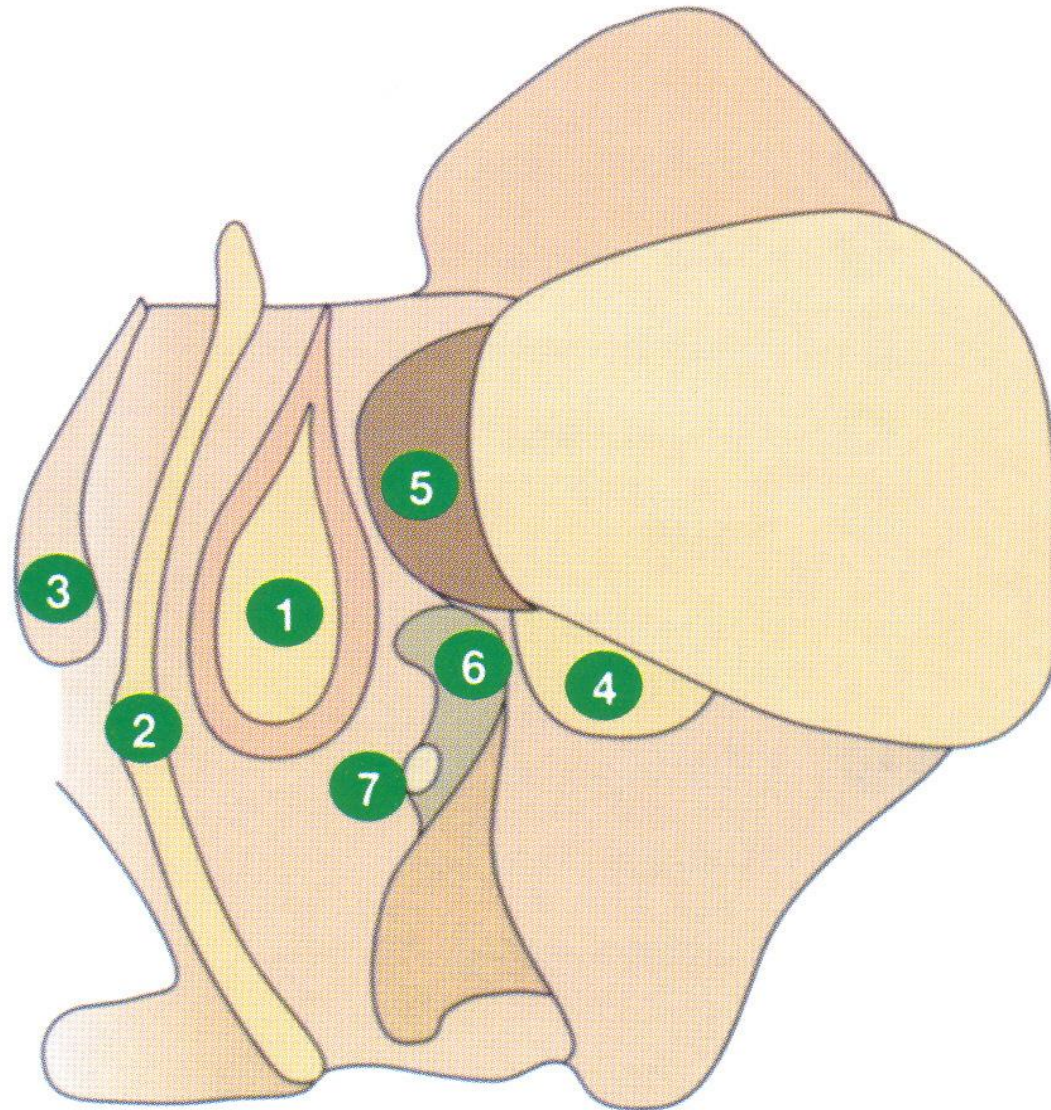


- 9a ethmoidal infundibulum
- 9b frontal recess
- 10 orbital ethmoidal cell (Haller)
- 11 natural ostium
- 12 semilunar hiatus



Anatomical variations causing dysfunction of ostiomeatal complex

- 1 Concha bullosa
- 2 Deviace septa
- 3 Paradoxně zakřivená
střední skořepa
- 4 Hallerovy buňky
- 5 Prominující etmoidální bula
- 6 Deviace processus uncinatus
- 7 Akcesorní ostium
maxilární dutiny



Blood supply

Upper third nasal cavity blood supply from **a. carotis interna** - *a. ophthalmica* - *a. ethmoidalis anterior* *a posterior*.

Posterior and inferior nasal cavity **a. carotis externa** via *a. maxillaris* and *a. sphenopalatina* - *a.a. nasales posteriores lat. et septi*.

A. carotis externa - *a. maxillaris* - *a. palatina descendens* - *a. palatina maior* - *a. nasopalatina*.

Locus Kiesselbachi (plexus)

Nasopharyngeal Woodroff plexus

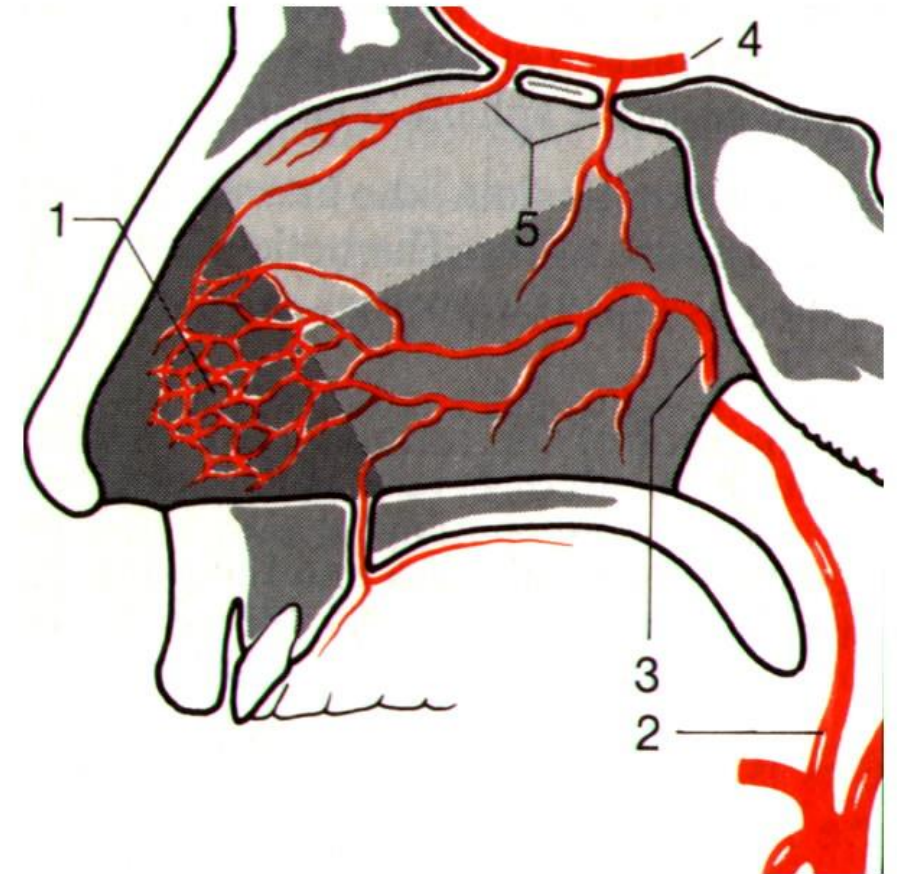
1-Locus Kiesselbachi

2-a.maxillaris

3-a.sphenopalatina

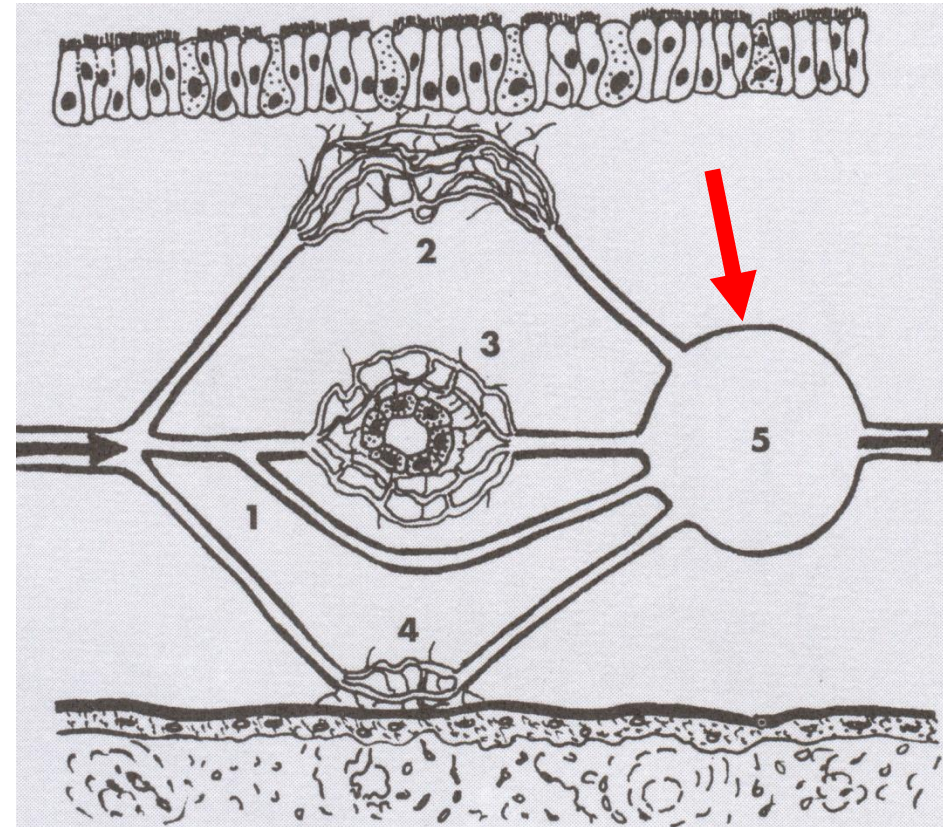
4-a.ophthalmica

5-a.ethmoidalis ant. et post.



Venous sinusoids (cavernous venous plexus)

Localised between capilars and venules – surrounded by smooth muscles, which causis their vasodilatation and vasoconstriction...



1. Arterioloventose short circuit
2. subepithelial capillary plexus
3. capillars surrounding gland
4. periostal capillars
5. cavernous venous plexus



Fibres of smooth muscles of arteriols and venous plexus supplied by autonomic nervous system.

Parasympathetic stimulation


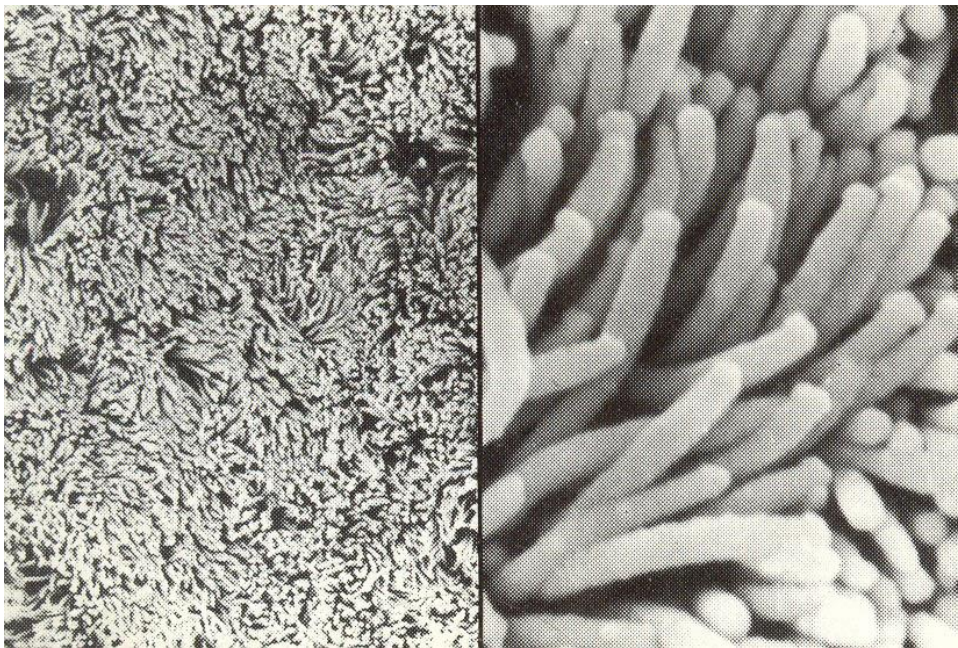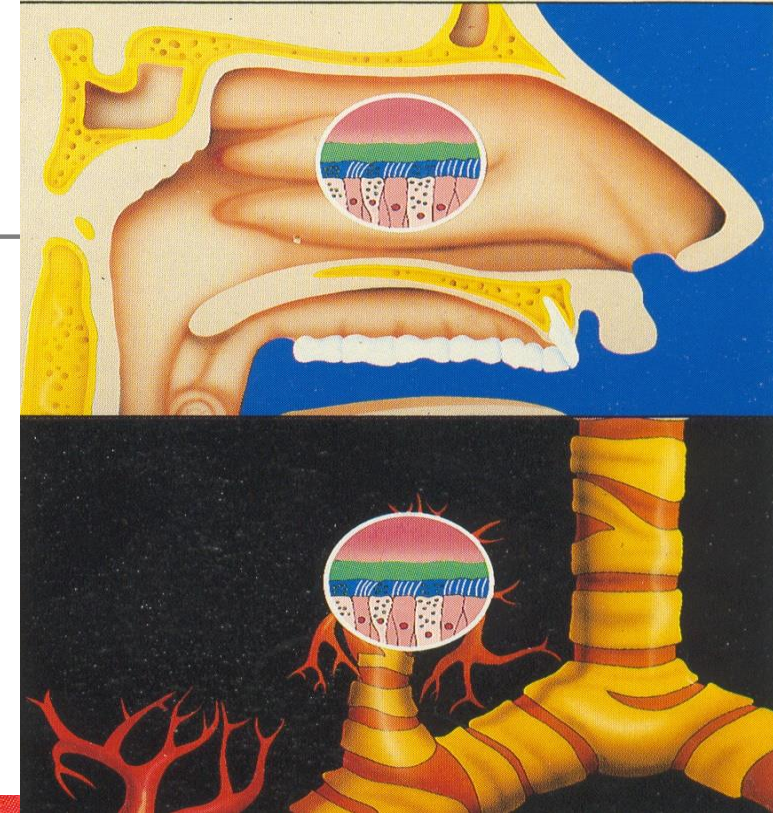
- **vasodilatation**, filling of venous plexus with blood – congestion and discharge.

Sympathetic stimulation

- **vasoconstriction**, leading to empty venous plexus with blood – not blocked and lower discharge.

„Mucociliar escalator“

Epithelium of the nose: respiratory epithelium
columnar-ciliated with goblet cells and a layer of
mixed glands





Examination of the nose and paranasal sinuses

Morphology

- aspection, palpation
- rhino-endoscopy
- ultrasound
- radiology (X-ray examination), CT, MRI
- sinuscopy
- lavage of the sinuses
- (diaphanoscopy)

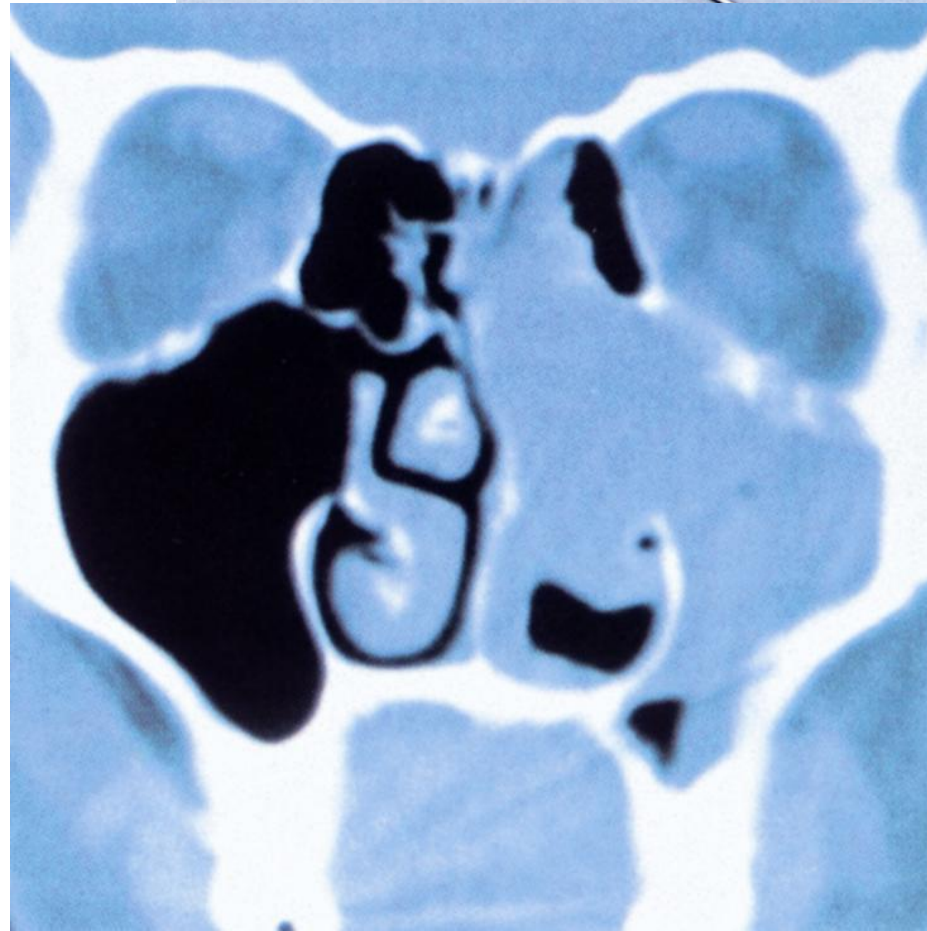
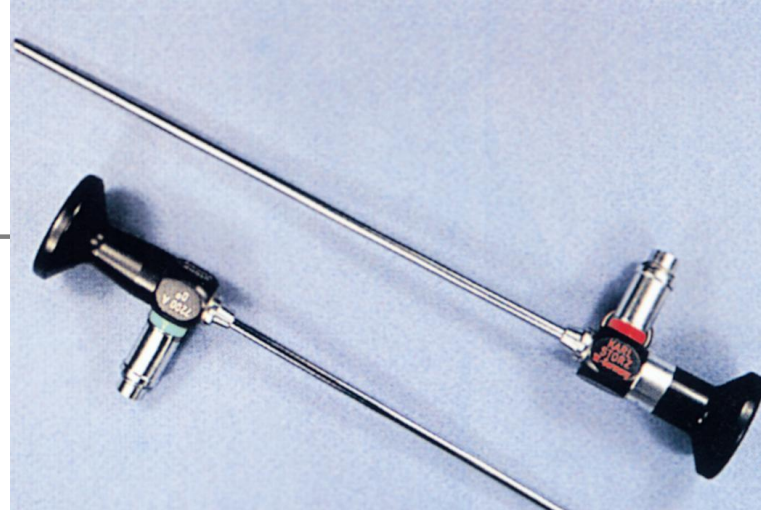
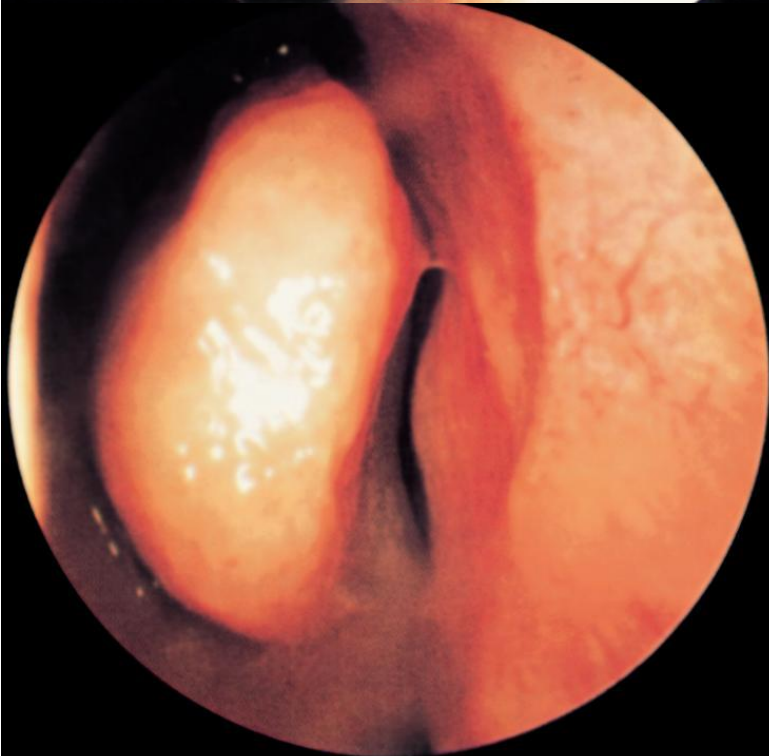
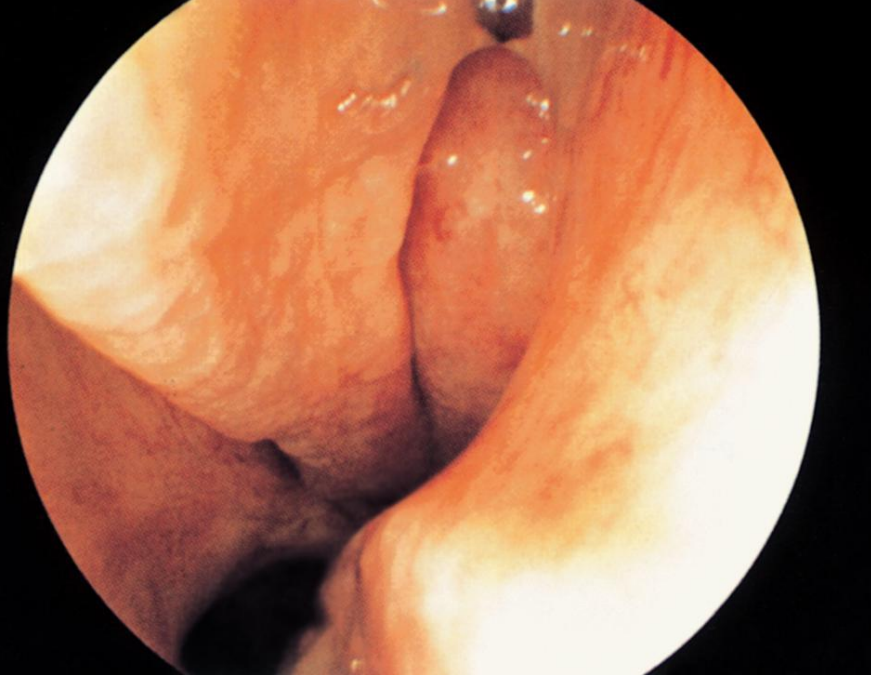
Nose function

Mucociliar transport – sacharin test

Smell – olfaktometry

Patency

- Glatzell desk
- Rinomanometry



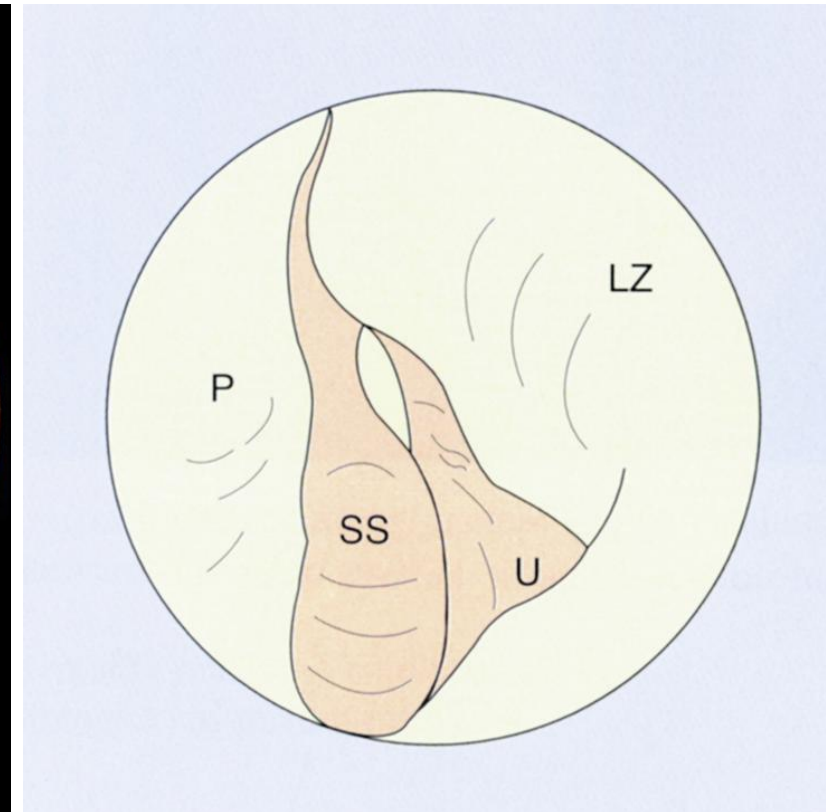
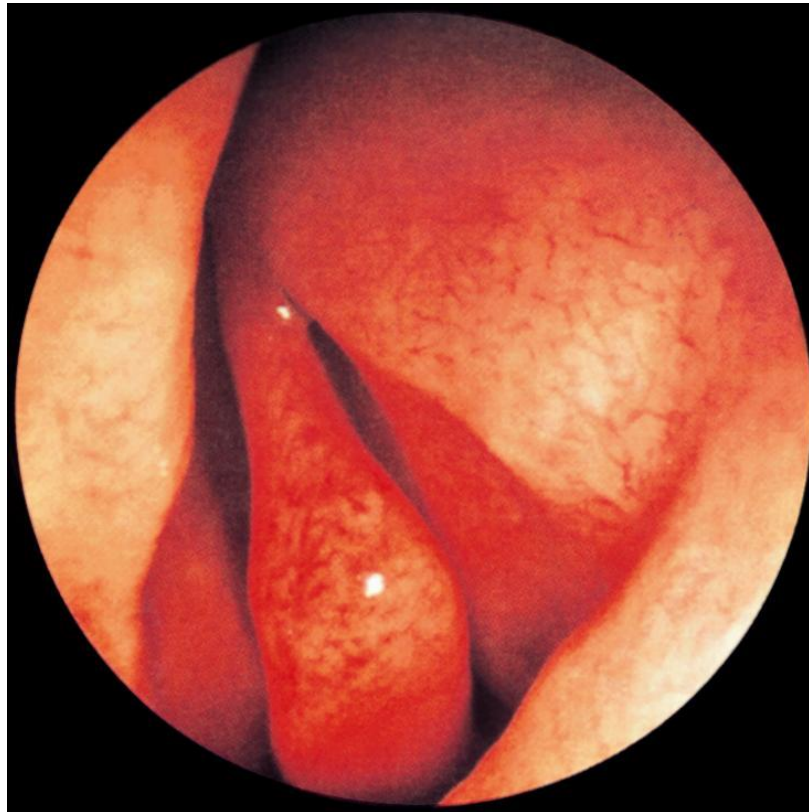
Physiologic endoscopic view

LZ – sulcus lacrimalis

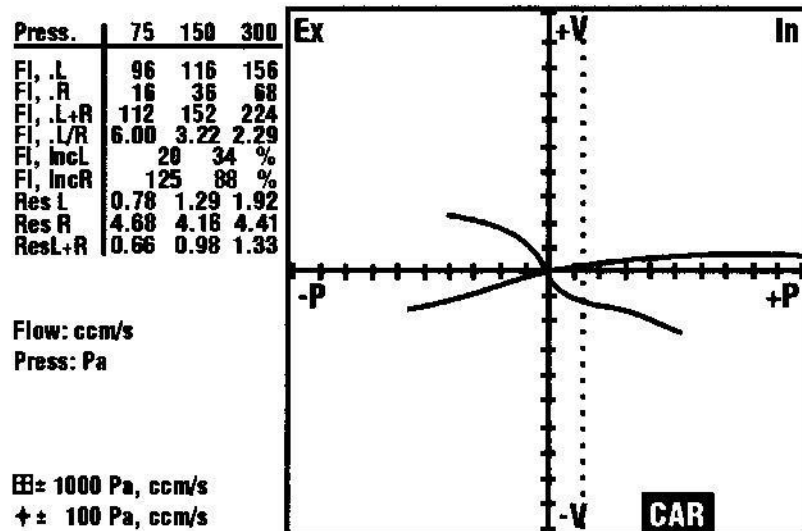
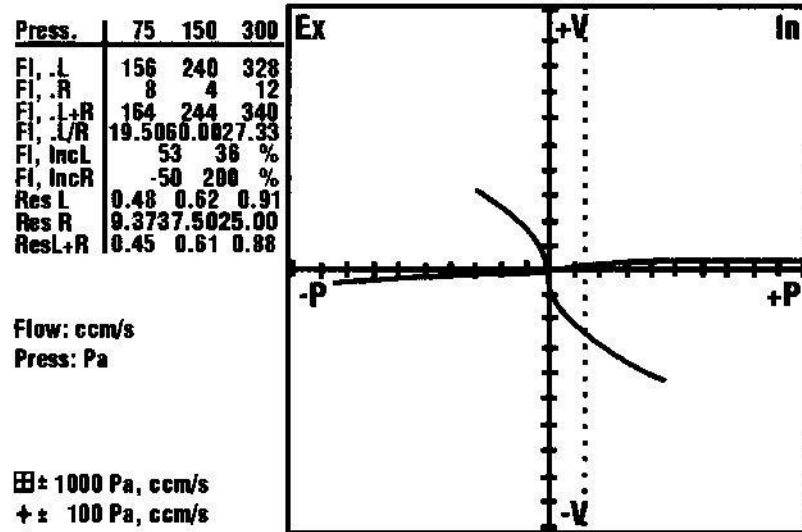
U – processus uncinatus

SS – middle turbinate

P – nasal septum



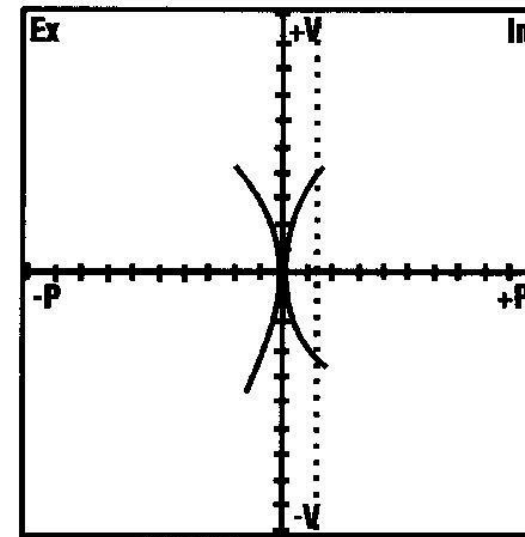
Rhinogram of septum deviation to the right and narrowing of nasal valve



Press.	75	150	300
Fl, .L	232	324	0
Fl, .R	264	488	0
Fl, .L+R	496	732	0
Fl, .L/R	0.87	0.79	
Fl, IncL	39	100	%
Fl, IncR	54	100	%
Res L	0.32	0.46	
Res R	0.28	0.38	
ResL+R	0.15	0.20	

Flow: ccm/s
Press: Pa

⊞ ± 1000 Pa, ccm/s
⊕ ± 100 Pa, ccm/s

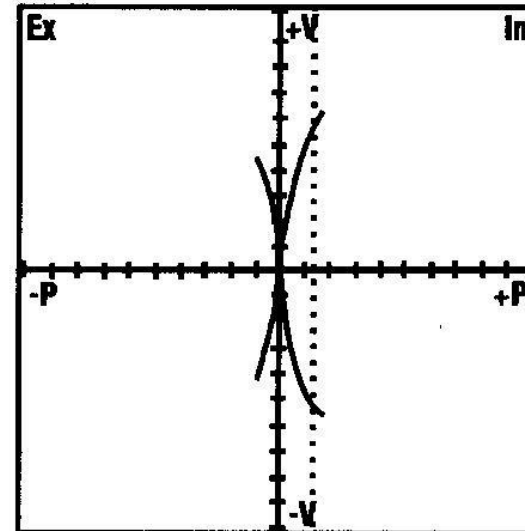


Rhinogramm with normal values

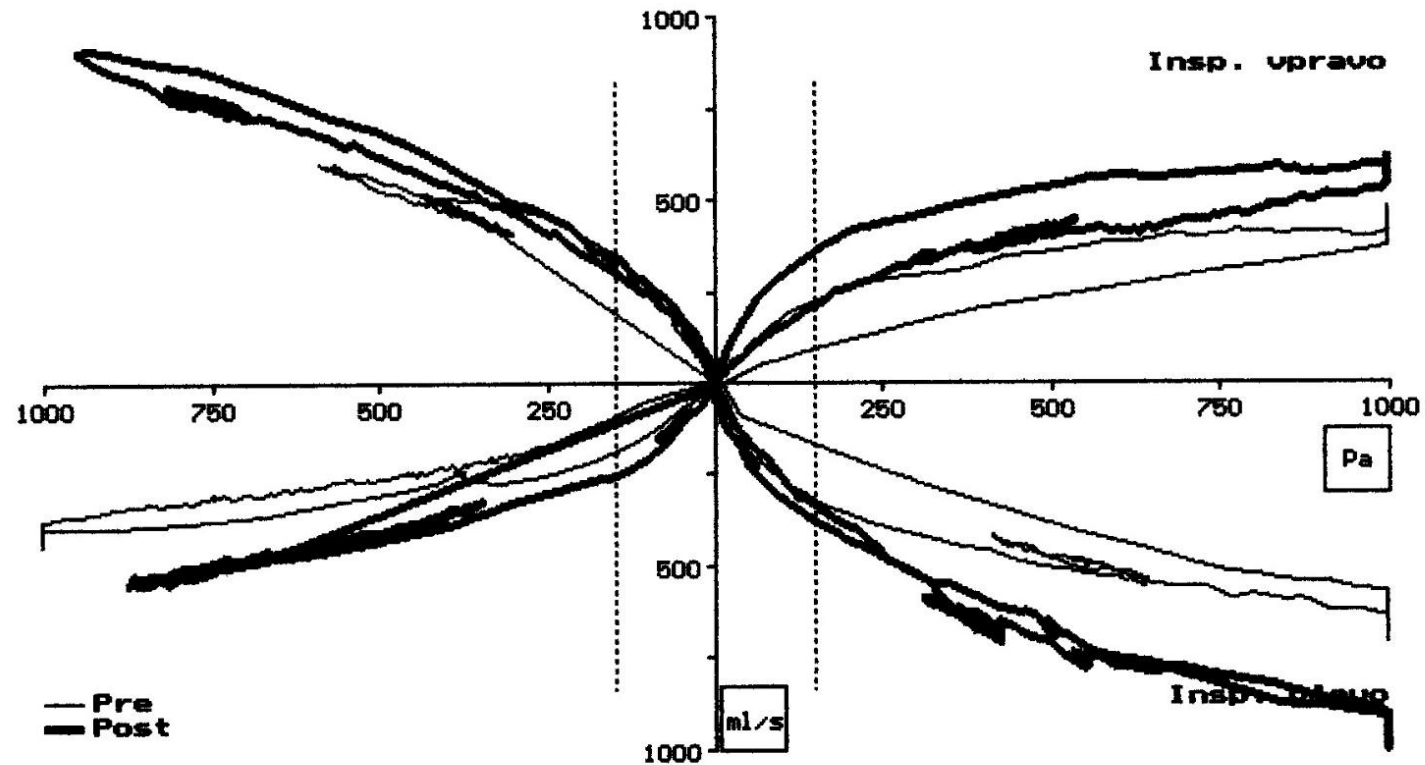
Press.	75	150	300
Fl, .L	484	536	0
Fl, .R	404	612	0
Fl, .L+R	888	1148	0
Fl, .L/R	1.08	0.87	
Fl, IncL	32	100	%
Fl, IncR	51	100	%
Res L	0.18	0.27	
Res R	0.18	0.24	
ResL+R	0.09	0.13	

Flow: ccm/s
Press: Pa

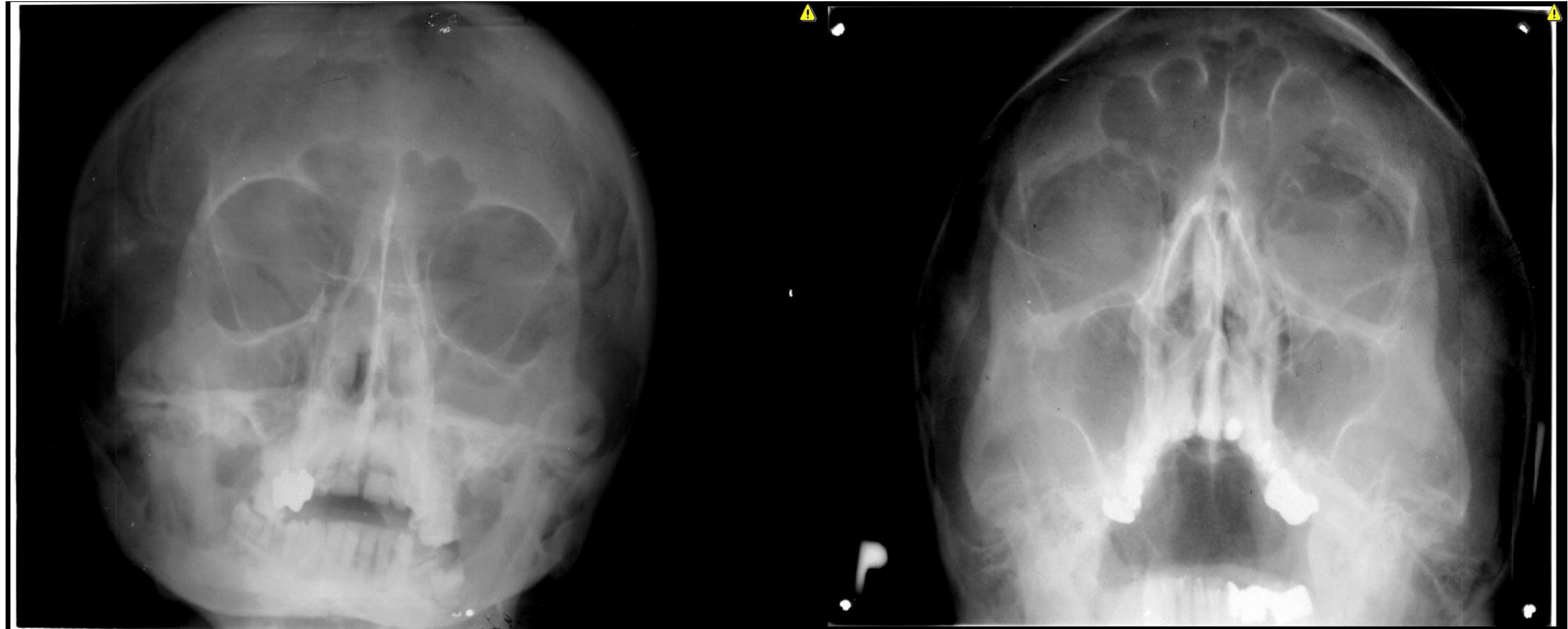
⊞ ± 1000 Pa, ccm/s
⊕ ± 100 Pa, ccm/s

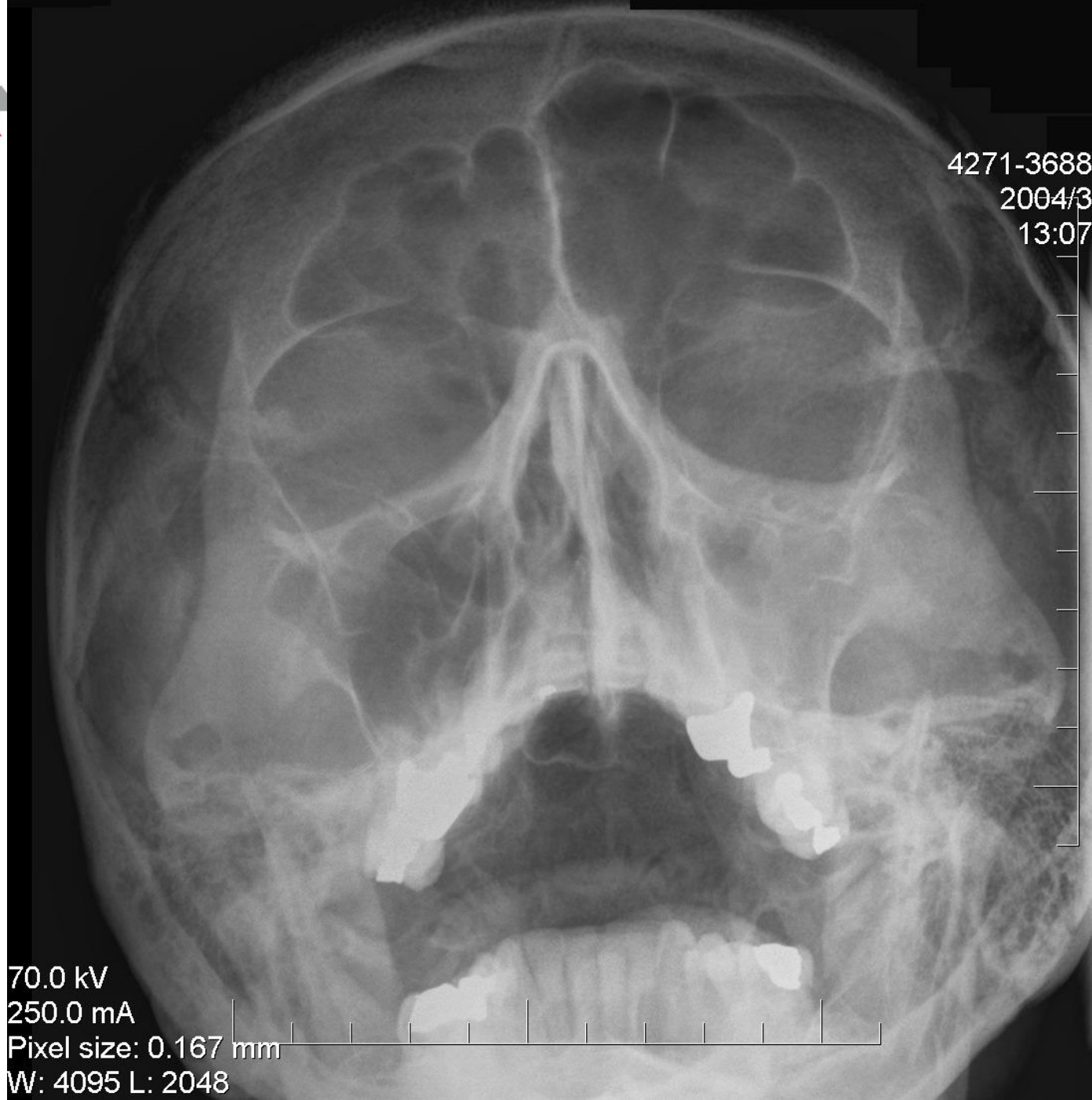

Rhinogram normal values after anemisation



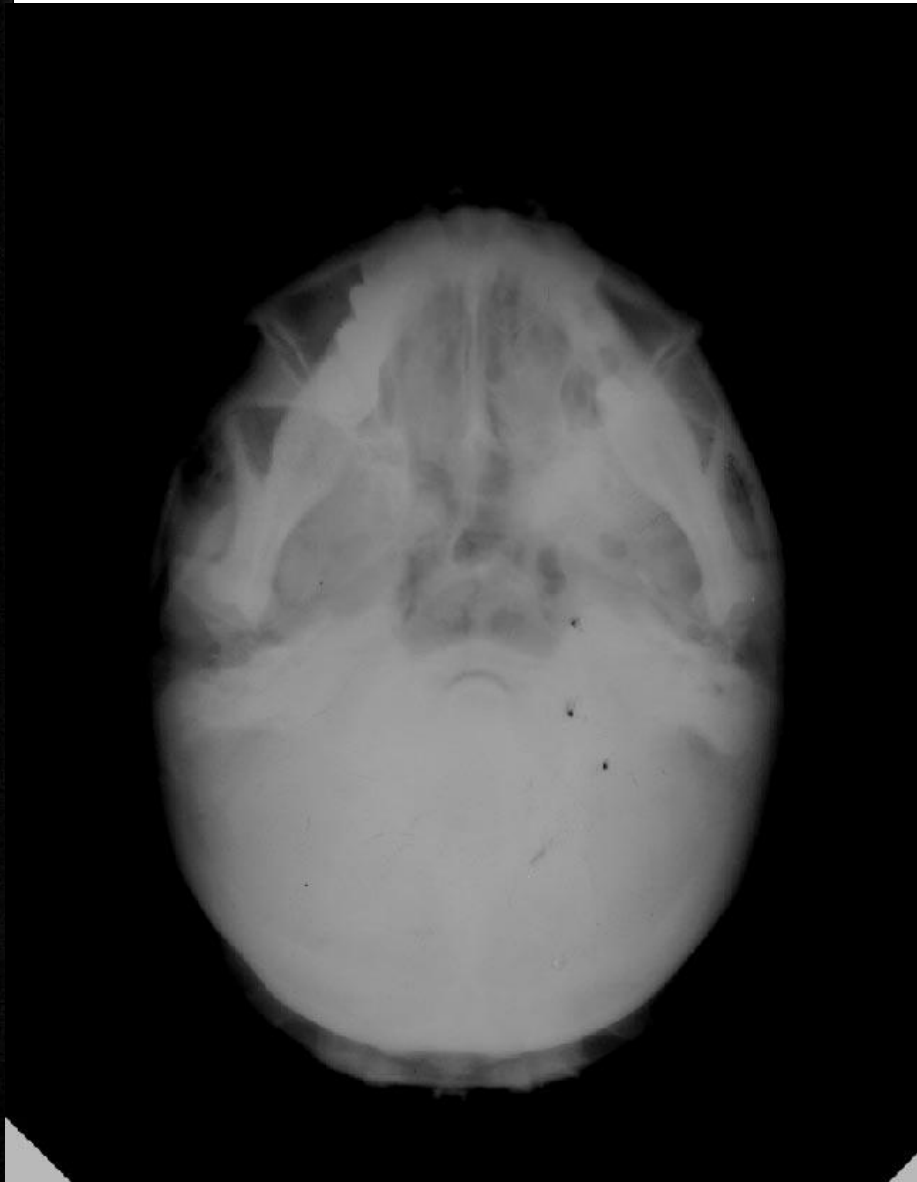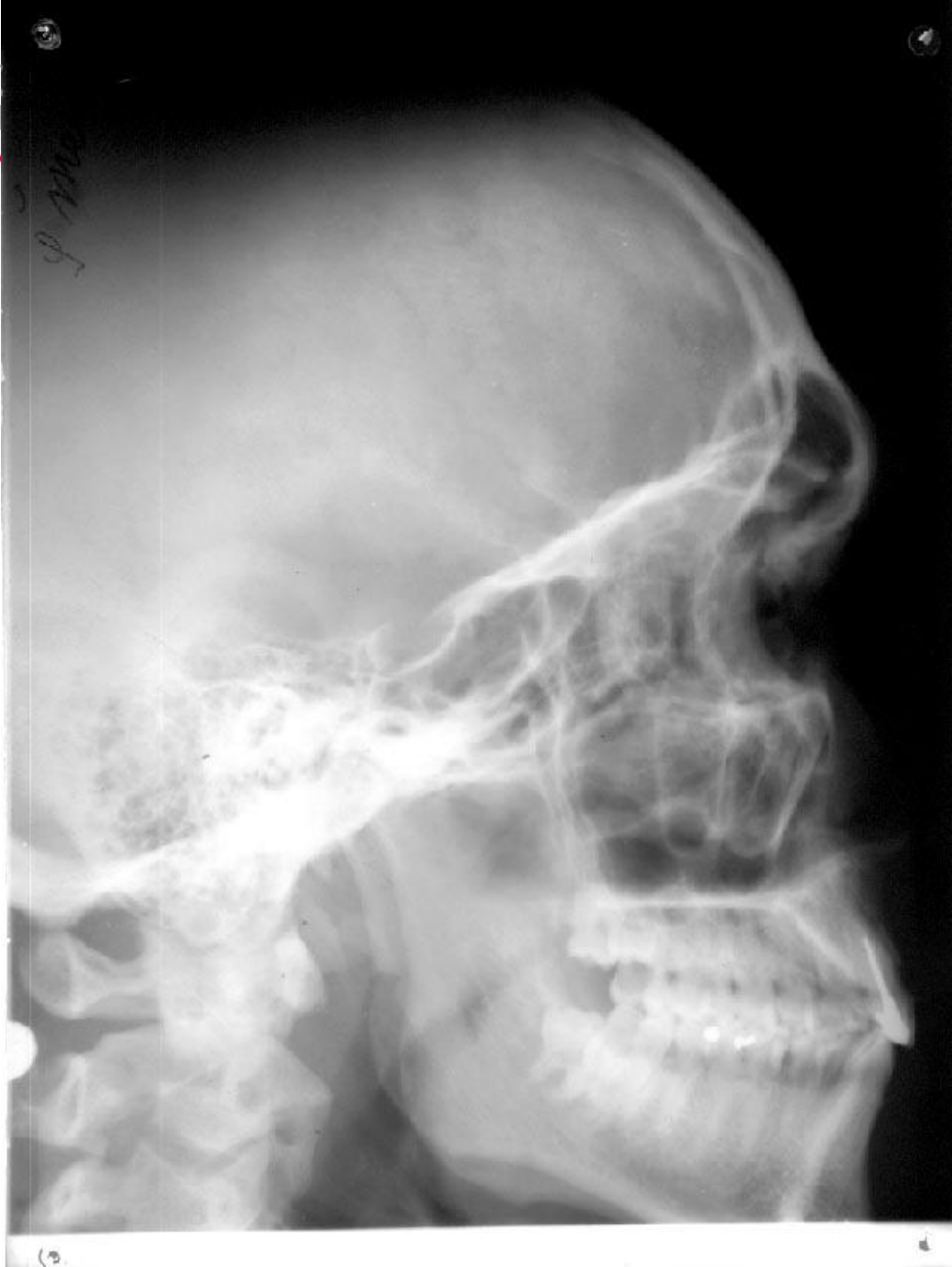Měřené hodnoty Parametr	Na l. hodn	07.11.2000		Pre/Na l. [%]	07.11.2000		Post/Pre [%]
		Pre-hodn	10:01		Hodn. Post	10:31	
L150	ml/s	450	250	56	351	78	+41
R150	ml/s	450	171	38	292	65	+71
SUM150	ml/s	900	421	47	644	72	+53
RES-L150	Pa/ml*s		0.60		0.43		-29
RES-R150	Pa/ml*s		0.88		0.51		-42



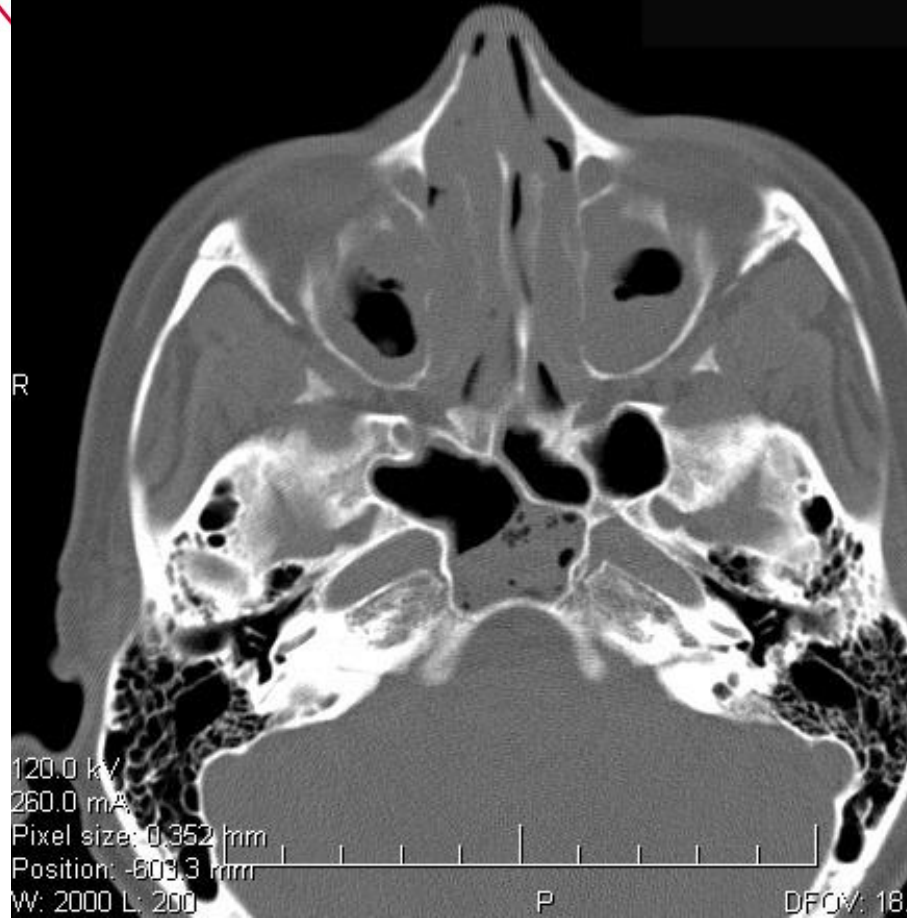


4271-3688/04
2004/3/22
13:07:00

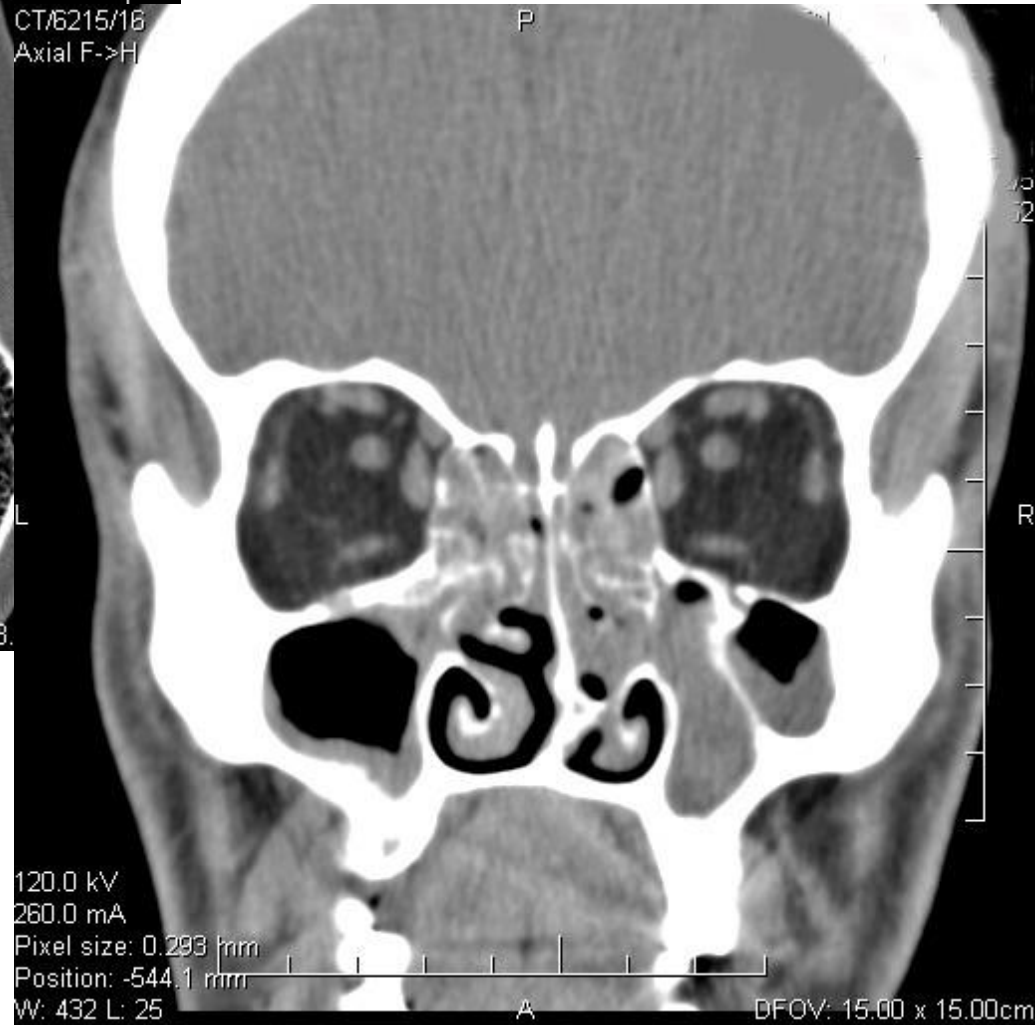
70.0 kV
250.0 mA
Pixel size: 0.167 mm
W: 4095 L: 2048

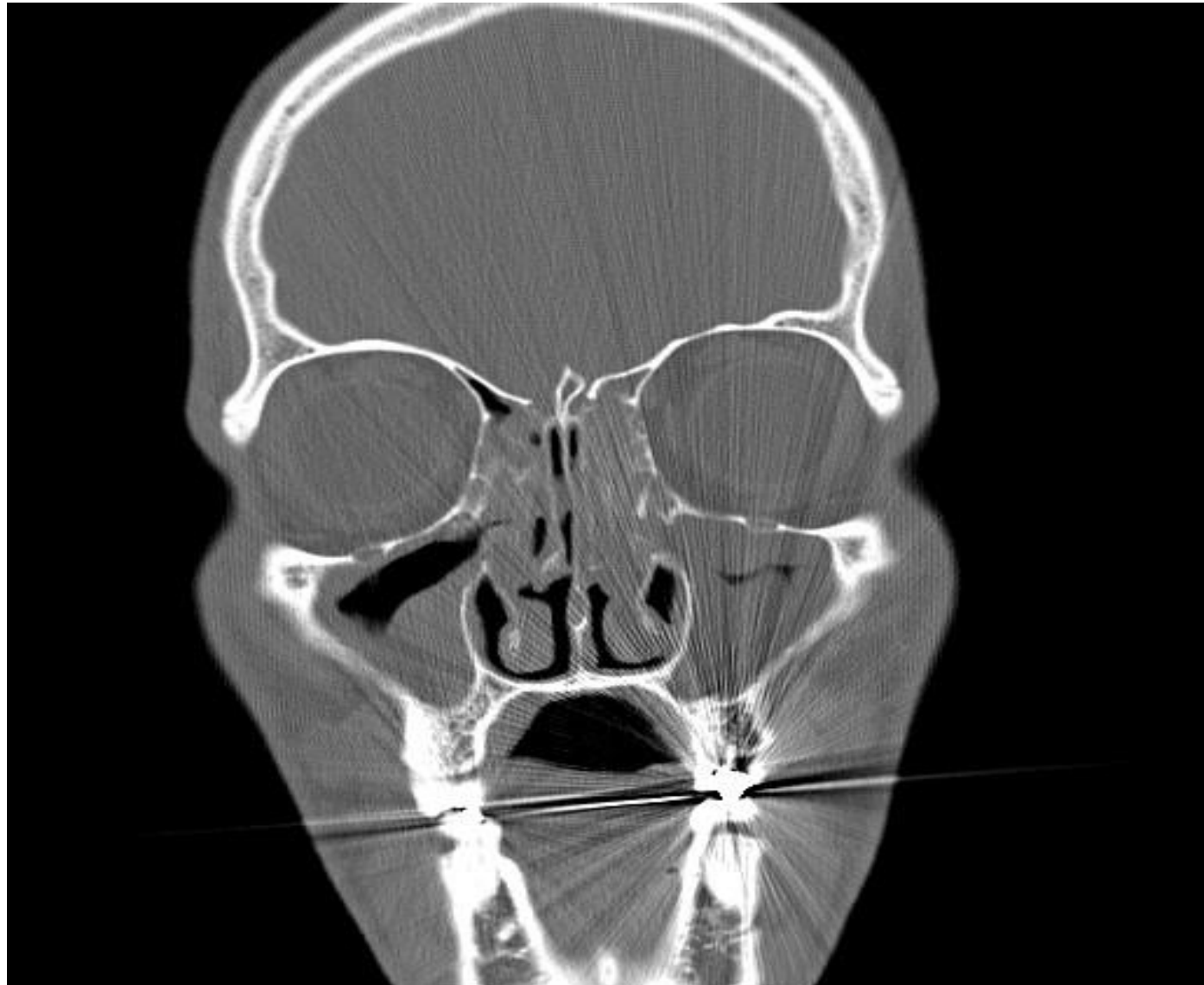
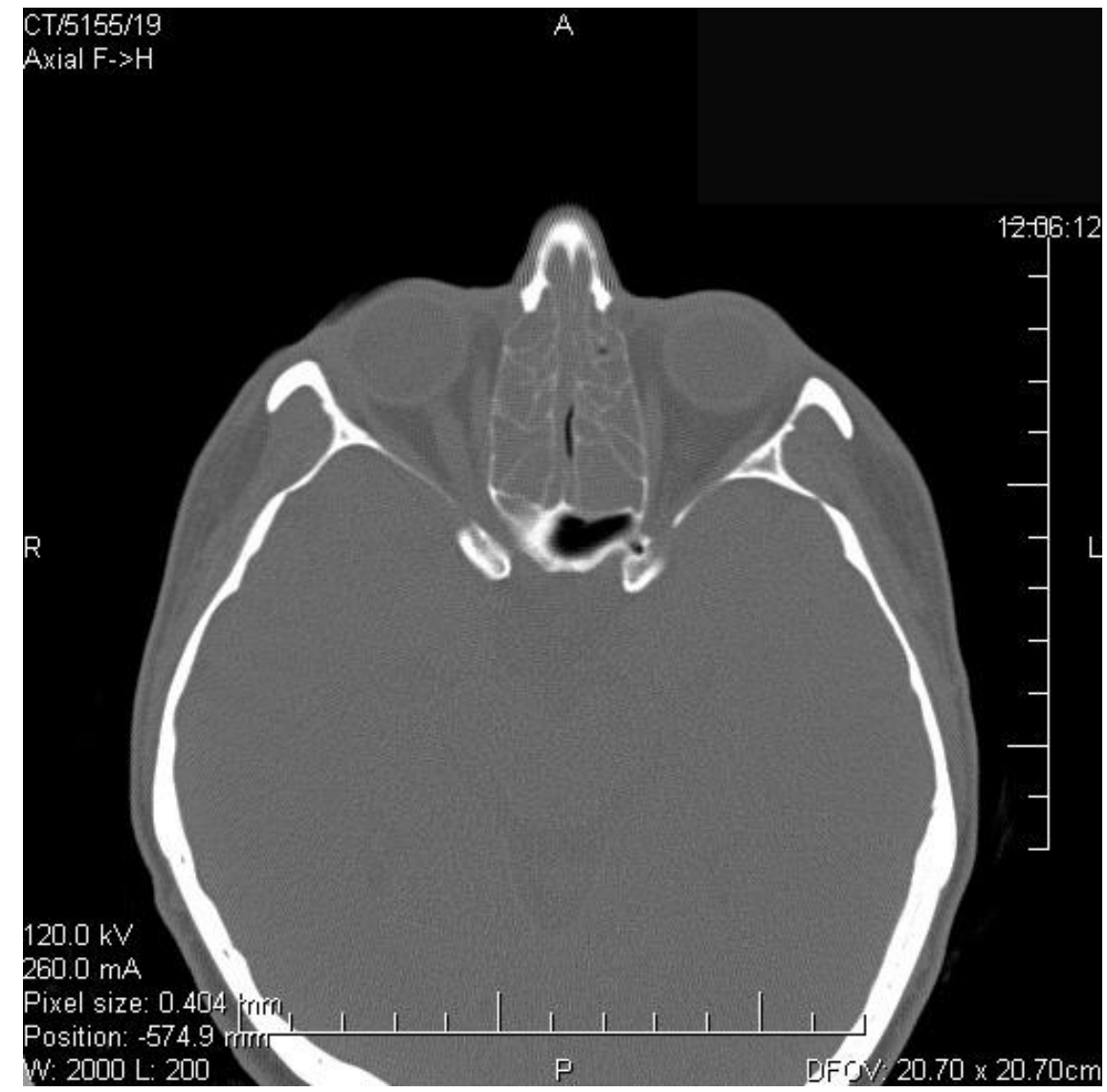


CT/4805/14
Axial F->H



CT







Clinical definition of rhinosinusitis in adults

Inflammation of the nose and the paranasal sinuses characterized by two or more symptoms, one of which should be either **nasal blockage**/obstruction/congestion or **nasal discharge** (anterior/posterior nasal drip). Another symptoms:

- ± **facial pain/pressure**
- - ± reduction or **loss of smell** and either
- and
- endoscopic signs of: - nasal polyps, and/or - mucopurulent discharge primarily from middle meatus and/or - oedema/mucosal obstruction primarily in middle meatus
- and/or
- CT changes: - mucosal changes within the ostiomeatal complex
- Symptoms should last until 12 weeks in **acute rhinosinusitis** and at least 12 weeks in **chronic rhinosinusitis**.

EPOS 2020: European position paper on rhinosinusitis and nasal polyps 2012 (Witske Fokkens, Valeria Lund et al.)

Classification of rhinosinusitis

1. Alergic

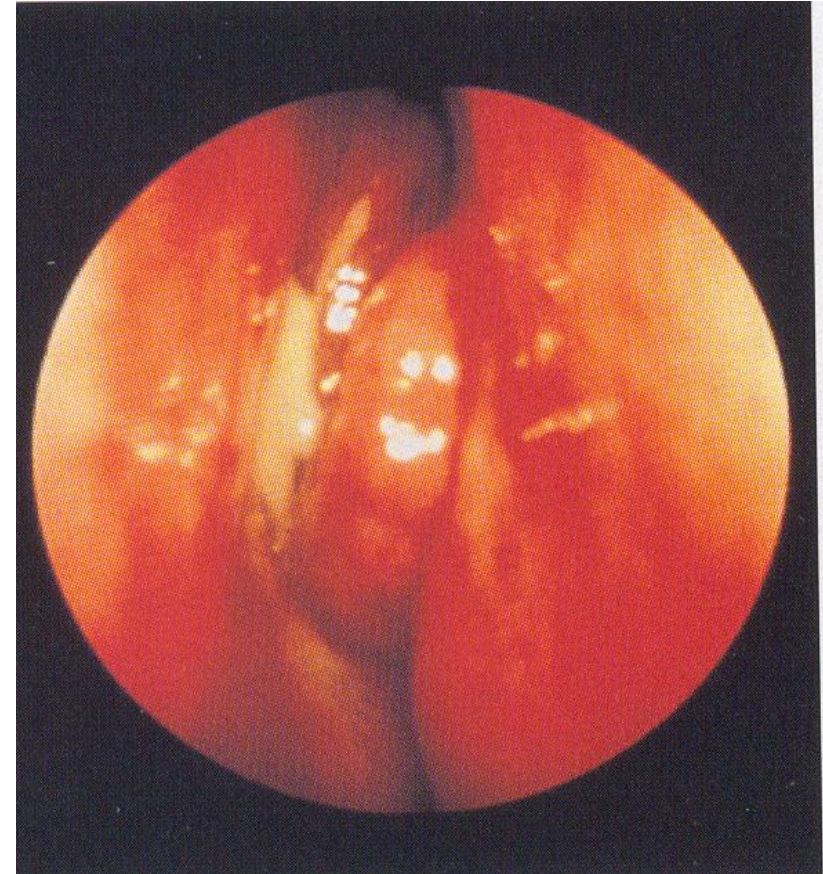
- Intermittent
- Persistent

2. Infectious

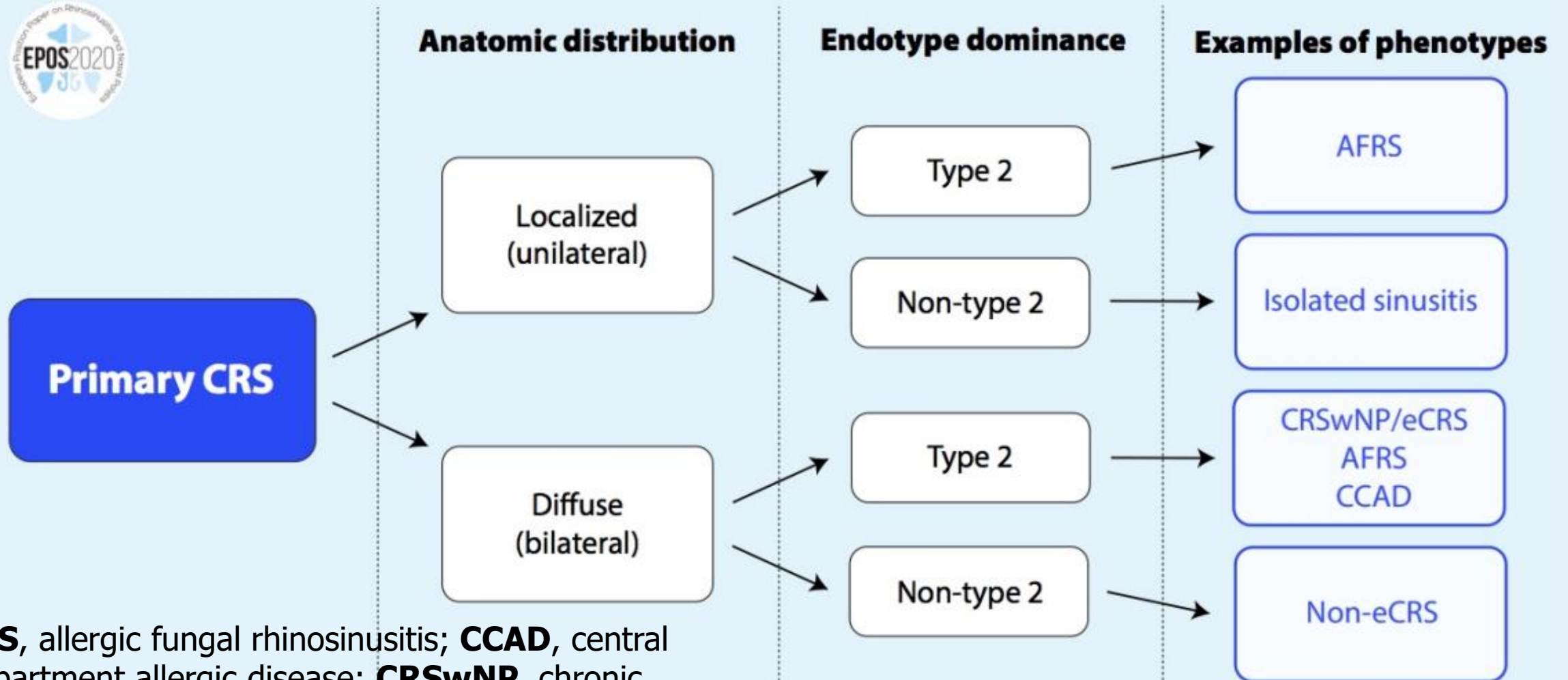
- acute
- chronic
 - specific
 - nonspecific

3. Other

- Vasomotor (professional, hormonal, drug induced, irritant, Alimentary, psychogenic, NARES (non allergic rhinitis with eosinophilia syndrome)
- Atrophic
- Idiopathic

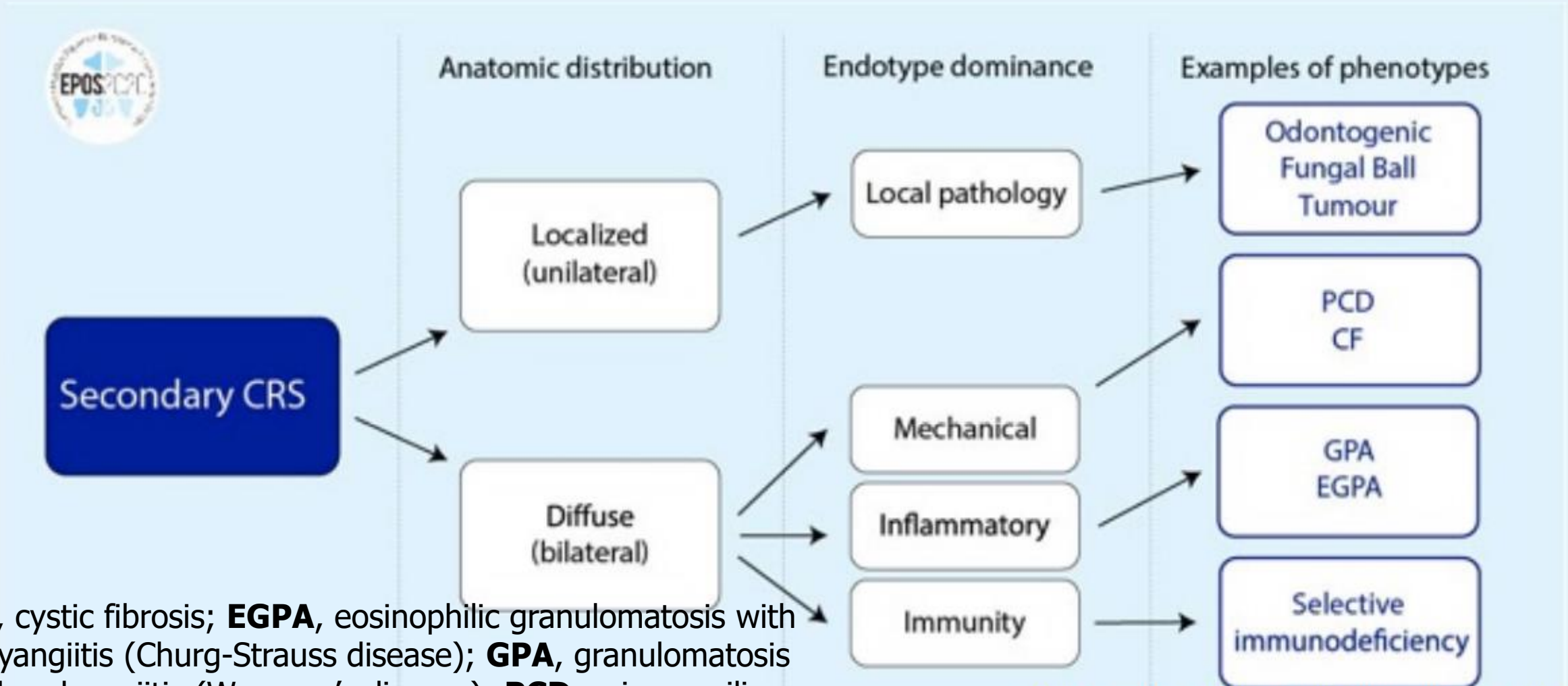


New Classification of CRS



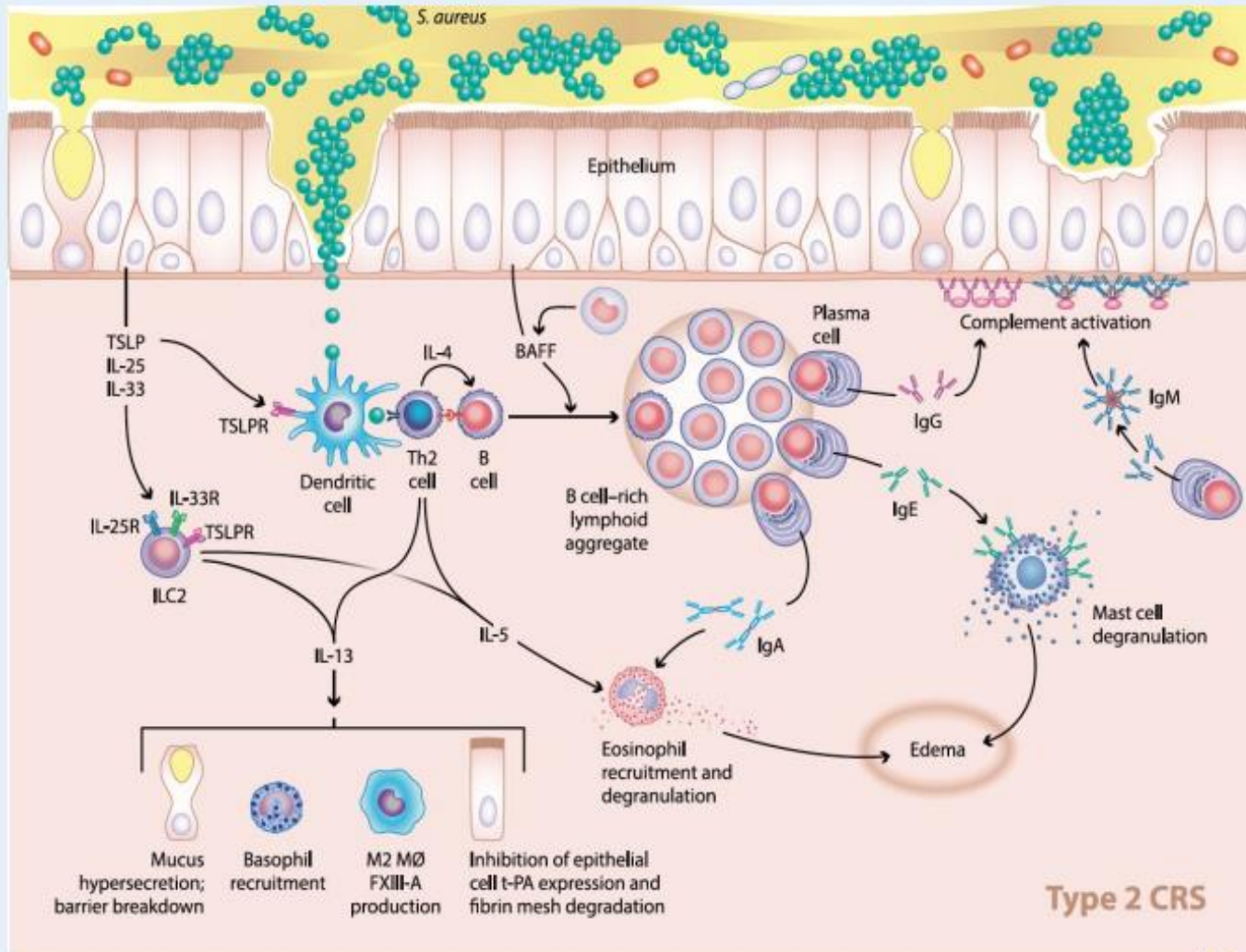
AFRS, allergic fungal rhinosinusitis; **CCAD**, central compartment allergic disease; **CRSwNP**, chronic rhinosinusitis with nasal polyps; **eCRS**, eosinophilic CRS.

New Classification of CRS



CF, cystic fibrosis; **EGPA**, eosinophilic granulomatosis with polyangiitis (Churg-Strauss disease); **GPA**, granulomatosis with polyangiitis (Wegener’s disease); **PCD**, primary ciliary dyskinesia.

Treatment of Type 2 Inflammation in Chronic Rhinosinusitis



- anti- IL-5
- mepolizumab
- reslizumab.
- anti-IL-4/anti-IL-13
- dupilumab
- anti-IgE
- omalizumab



Epidemiology of chronic rhinosinusitis

- Allergic and chronic nonallergic rhinosinusitis belongs to civilization diseases
- Frequency about 25 % population
- Incidence is higher in town inhabitants
- about 50 % of chronic noninfectious rhinitis is allergic rhinosinusitis



Classification of intensity of chronic rhinosinusitis

Degree

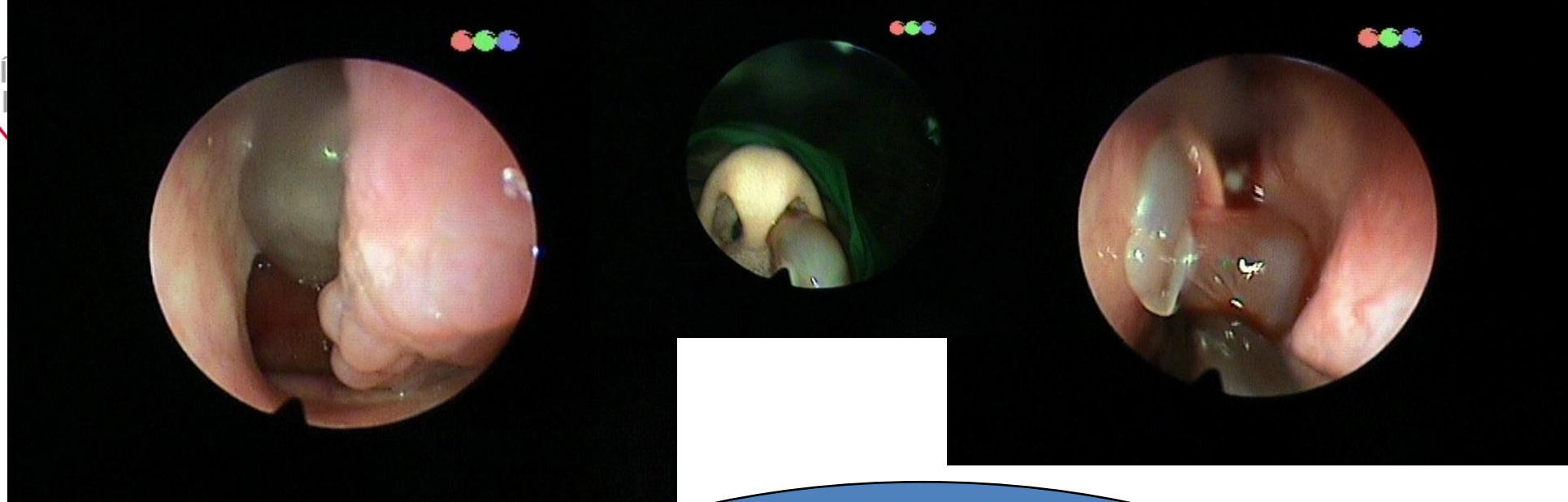
- mild
- moderate
- sever

Visual analog scale (VAS)

A section 10 cm long

Without symptoms

Most intensive symptoms



Chronic rhinosinusitis

nasal polyposis

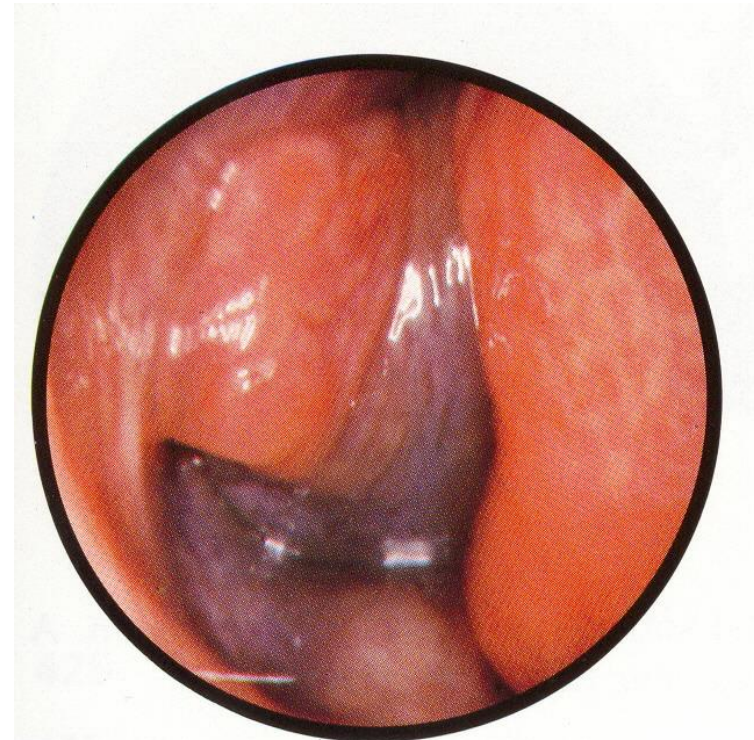
Eosinofilia, IL-5

Allergic rhinitis (primary CRS endotype dominance type 2)

Persistens **Intermitens**

Degree

- mild
- moderate
- sever






Allergic rhinitis (primary CRS endotype dominance type 2)

- Proof of IgE – mediated mechanism
- Symptoms as a result of immune reaction mediated by specific IgE antibodies
- Cellular inflammation of mucose membrane (T-lymfocyty, eozinofils)
- Cause of production of IgE antibodies - atopic genetic predisposition (HLA antigens of atopic patient)

Domestic acarid

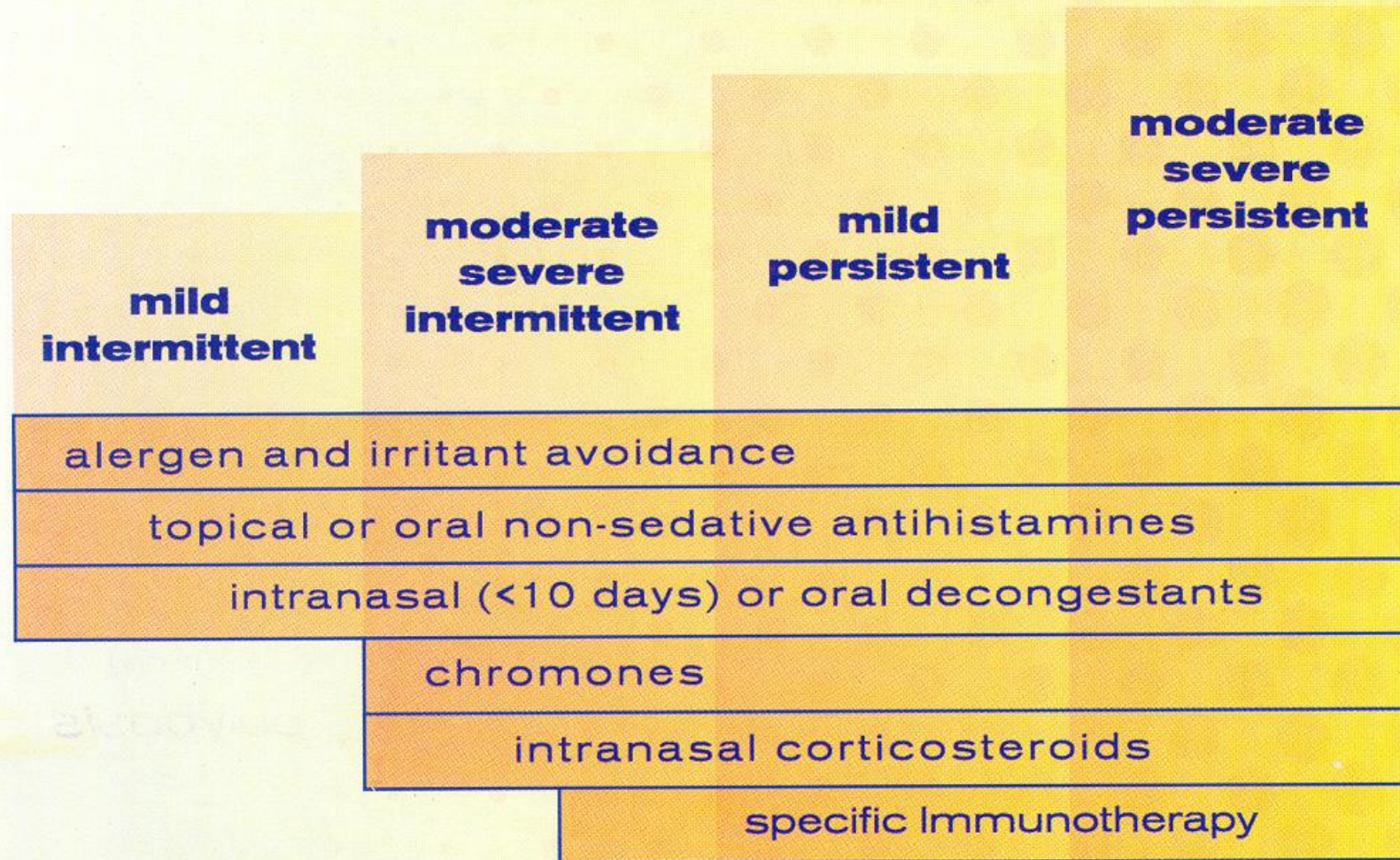
(*Dermatophagoides pteronyssinus*,
in electron microscope)

The most frequent cause of allergy – „domestic dust“





Rhinitis allergica - treatment



adapted from: Management of Allergic Rhinitis and its Impact on Asthma 2001. ⁽¹⁾



Comparison of local decongestant

Drug	Time to effect (min.)	lasting of effect (hod.)	Undesirable side affects
Efedrin	10	3-4	+++
Fenylefrin	15	1-2	+++
Nafazolin	15	2-6	++
Xylometazolin	20	10-11	++
Oxymetazolin	20	10-12	++
Tramazolin	5	11-12	+



Rhinitis vasomotorica

- Disorder of mucos membrane without structural background, not infectious, autoimune neither allergic in traditional sense.
- The same symptomatology as persistans allergic rhinitis.
- Cause- faktors of none-imune character.

(Charles W. Cummings, et al. Otolaryngology—Head & Neck Surgery, Mosby)



Vasomotor rhinitis

- Neurovascular reaction on various stimulus: mechanical, chemical, psychic stress.
- Manifestation of
sympathic-parasympathic neurovascular disbalance

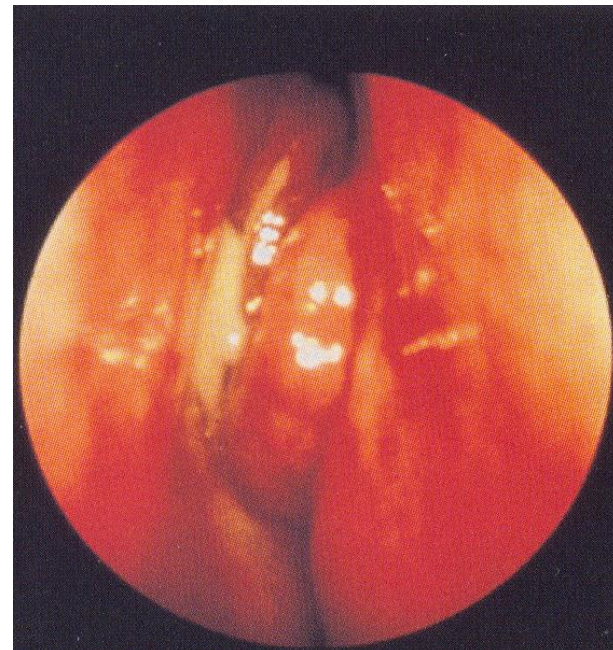
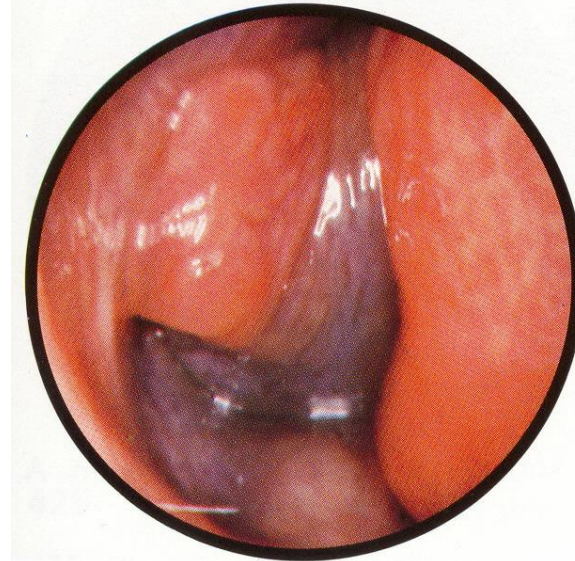


Symptoms of vasomotor rhinitis

- „blocked nose“
- Watery discharge - rhinorrhea –
 - Výtěr z nosu s velkým množstvím eozinofilů typický pro alergii nebo NARES
 - Žlutý hnisavý – bakteriální infekce (neutrofily)
 - Krvavý nebo krustózní a ulcerace typické pro bakteriální infekci, nádor nebo granulomatózu
- Itching in nose, sneezing
- Smell disorder
- Feeling of dryness in nose
- Eye symptoms
- Headache
- General symptoms

Anterior rhinoscopy

- **Alergic and vasomotor rhinitis** livid or pale, diffus swollen mucose
- **Irritation or abuse** of nasal spray – red mucose
- **sinusitis** red mucose with pus





Vasomotor rhinitis – diagnosis

- X-ray evaluation is normal
- Higher amount of inflammatory mediators and cells
 - Histamines, leukotrienes, prostaglandins, neuropeptides aj.
- In nasal secretion not present eosinophils
- Negative skin allergen tests
- Positive answer on histamine skin test

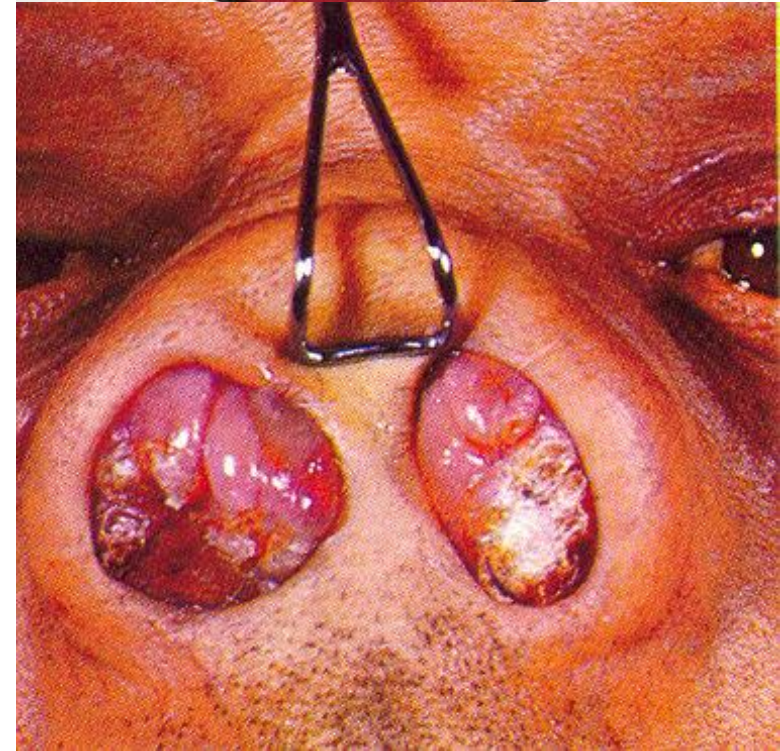
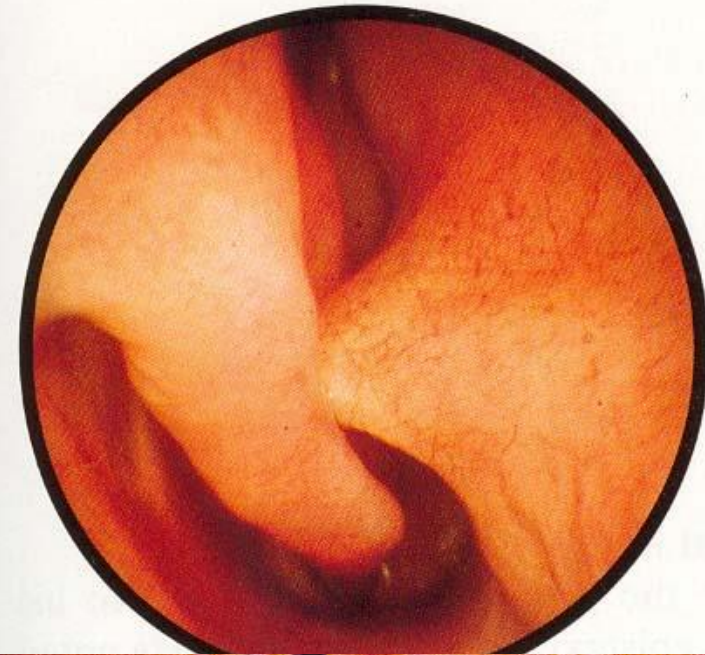


1. Drug provoked rhinitis
 - a. Antihypertensive treatment
 - b. abuse of nasal drops/sprays
 - c. Cocain
 - d. Hormones
2. Pregnancy and “premenstrual rhinitis”
3. Hypothyroidisms
4. Emotional causes
5. Temperature changes
6. Rhinitis from irritation and external influences
7. Rhinitis from olfactory perception
8. End phases of vascular atonia in chronic allergic and infectious rhinitis
9. Rhinitis from position
10. Rhinitis in nasal obstruction and nasal cycle
11. Rhinitis in non-ventilated nose (laryngectomy, choanal atresia, vegetations adenoideae)
12. Compensatory hypertrophic rhinitis
13. Eosinophilic and basophilic nonallergic rhinitis
14. other systemic reasons: syndrome vena cava sup., Horner’s syndrome, cirrhosis, uremia

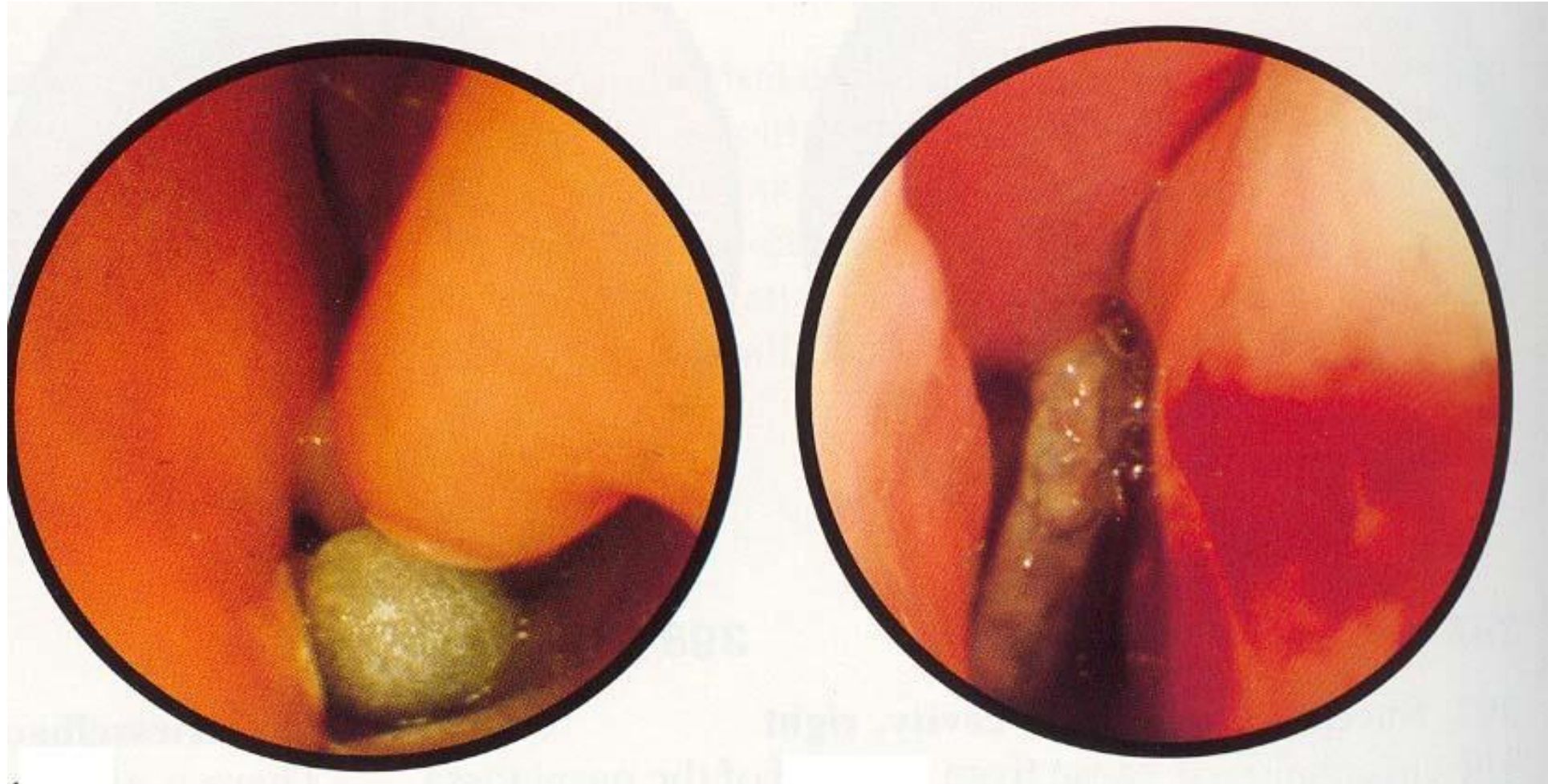
Morphologic causes of nasal obstruction

crista septi nasi

papilloma invertens

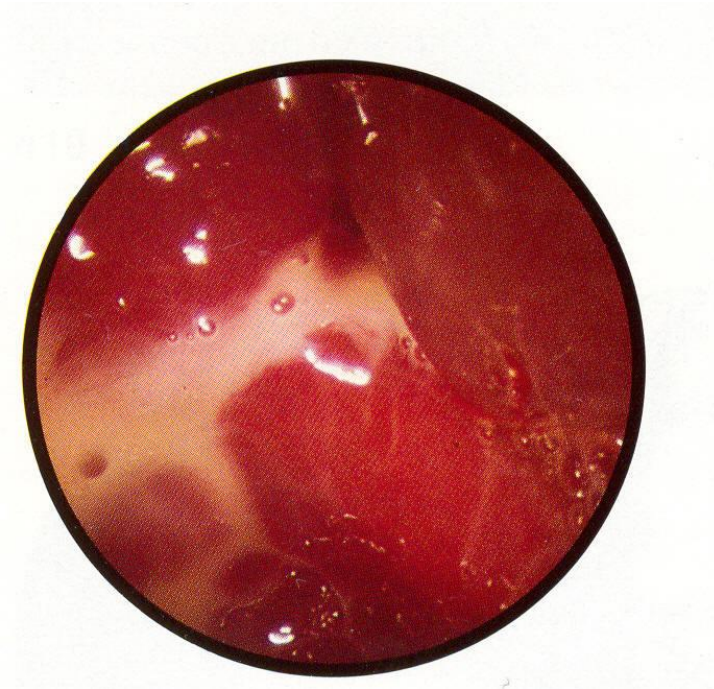
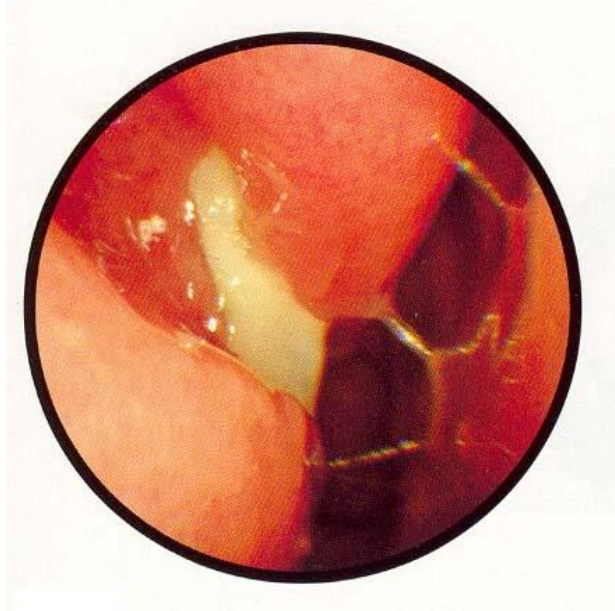


Intranasal foreign bodies

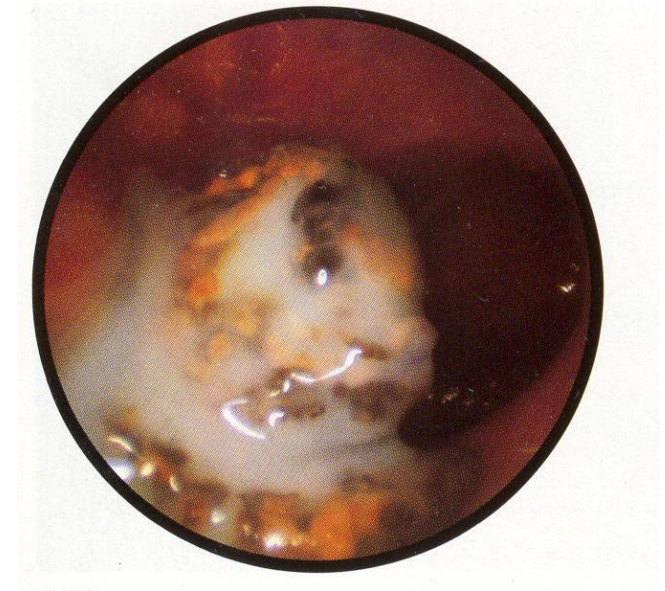


Inflammations

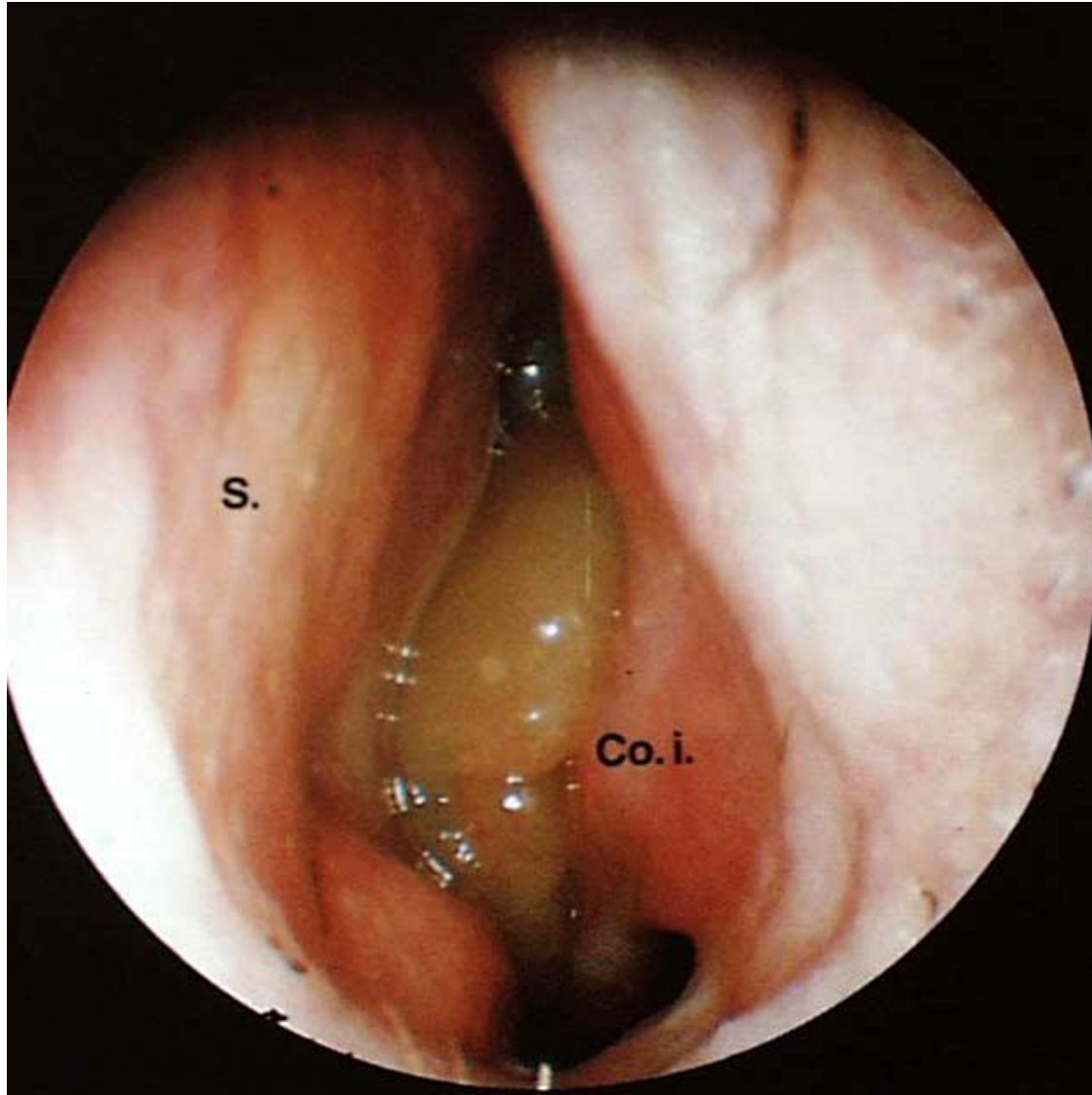
Acute rhinosinusitis



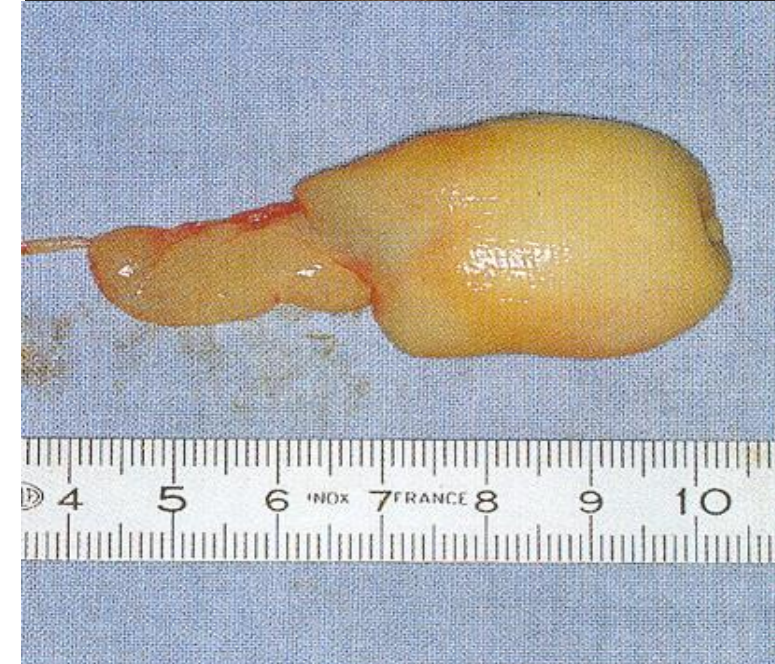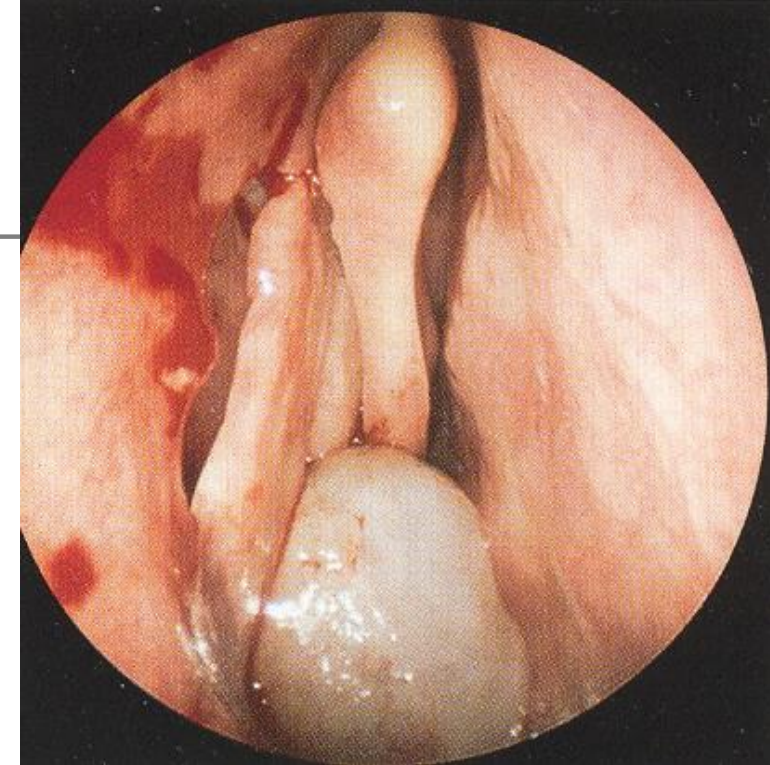
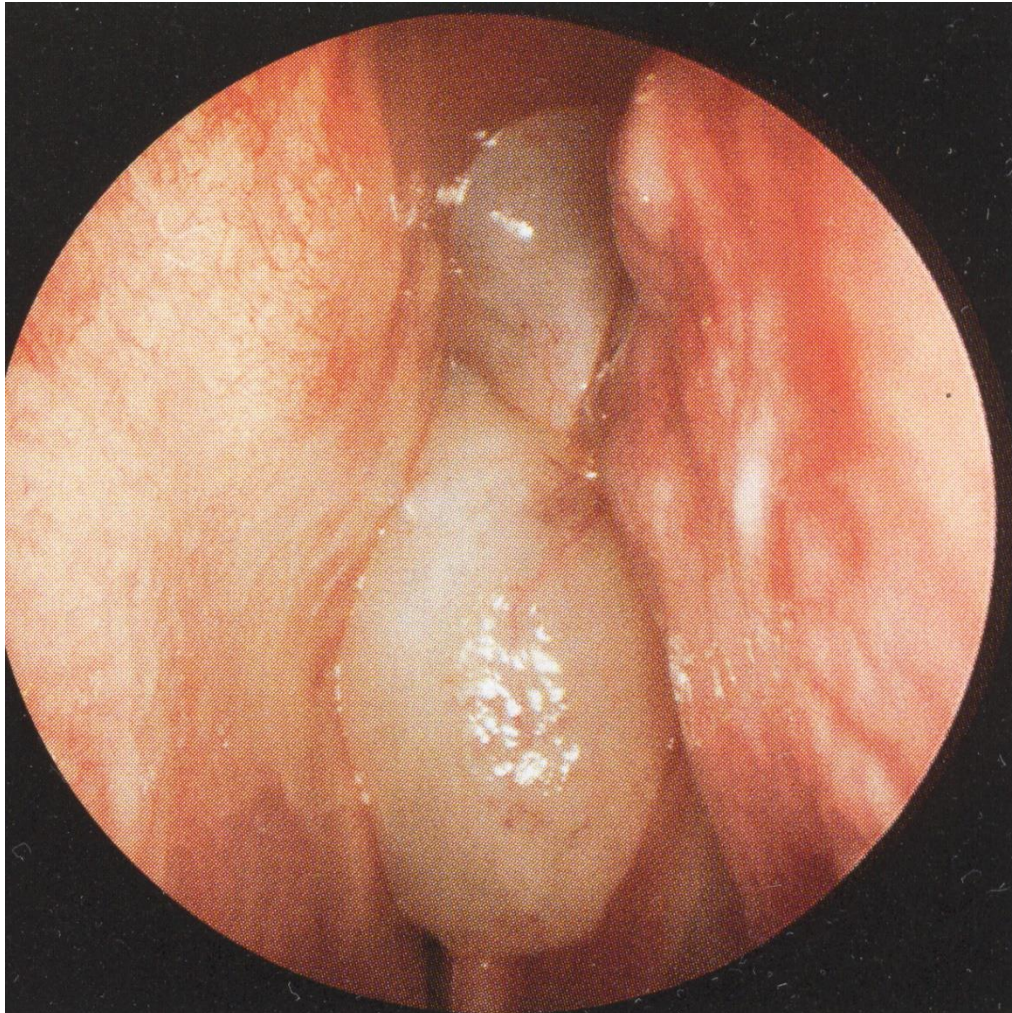
Mycotic sinusitis



Nasal polyps

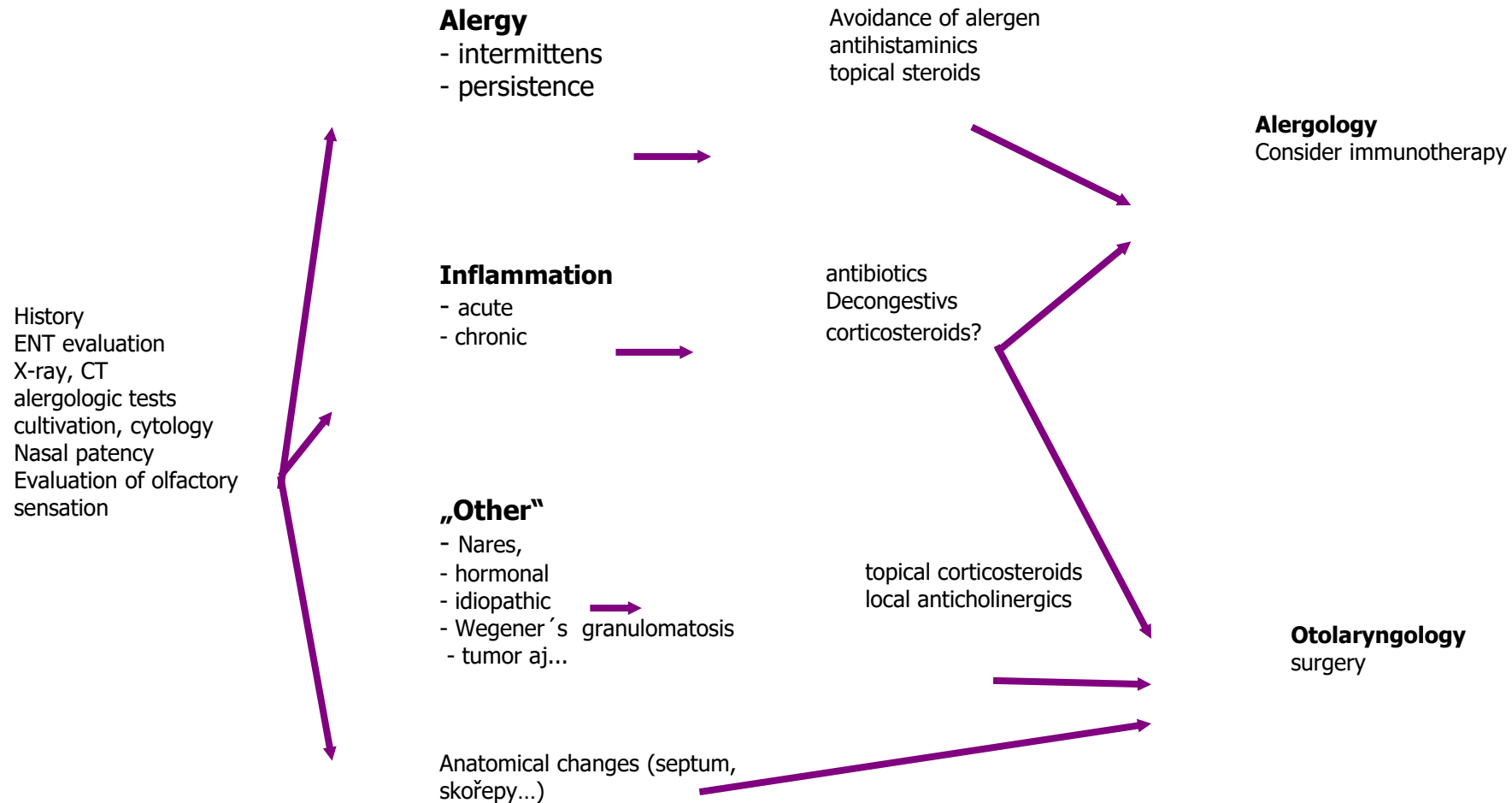


Antrochoanal polyp





Therapy of rhinitis





Therapy of chronic rhinosinusitis

- Medikamentous, conservative
- Surgery
 - „classical“ rhino-surgery
 - Functional endonasal sinus surgery (FESS)



„Classical“ rhino-surgery

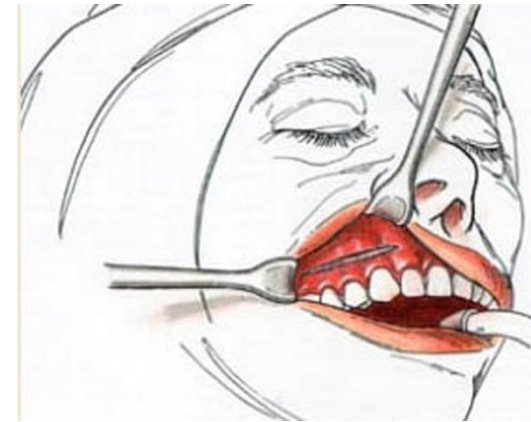
- Approach through healthy tissue
- All mucosa membrane is removed
- Mostly non-physiologic communication into the nose

Maxillar sinus – sec. **Caldwell-Luc**

Ethmoidal labyrinth – sec. **Moure**

Frontal sinus – sec. **Jansen-Ritter**

Caldwell-Luc

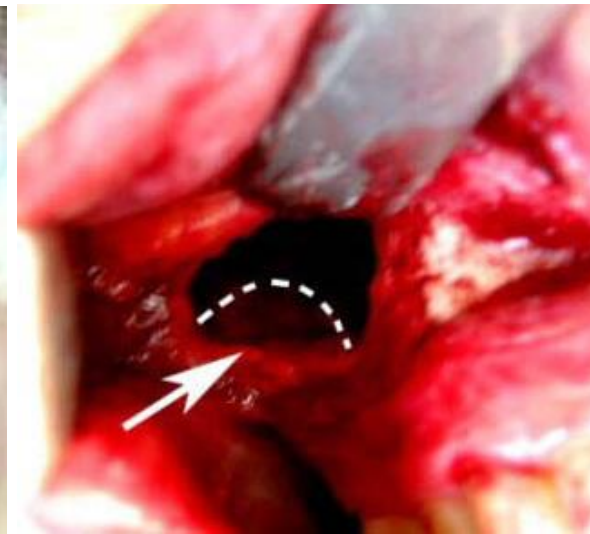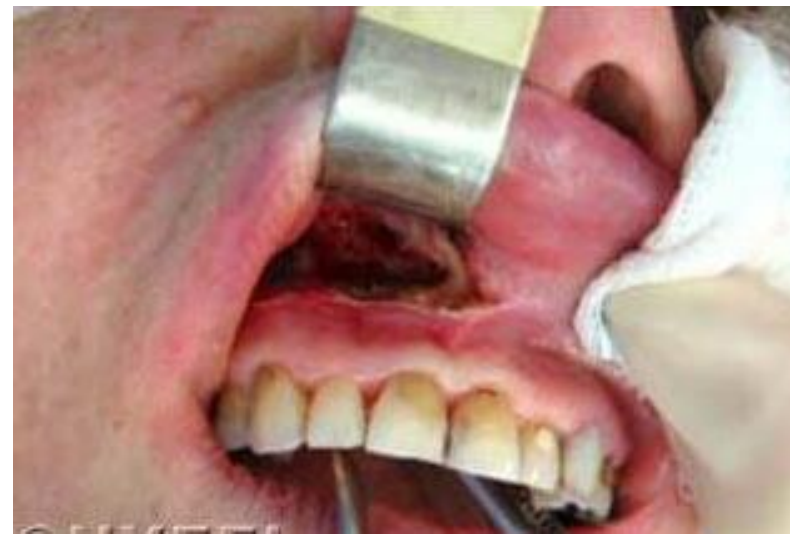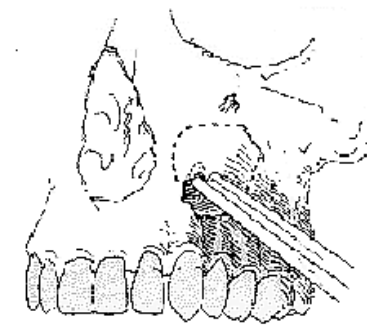
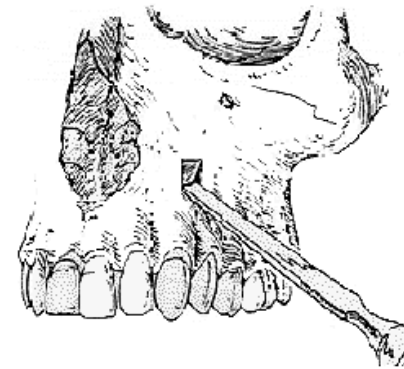


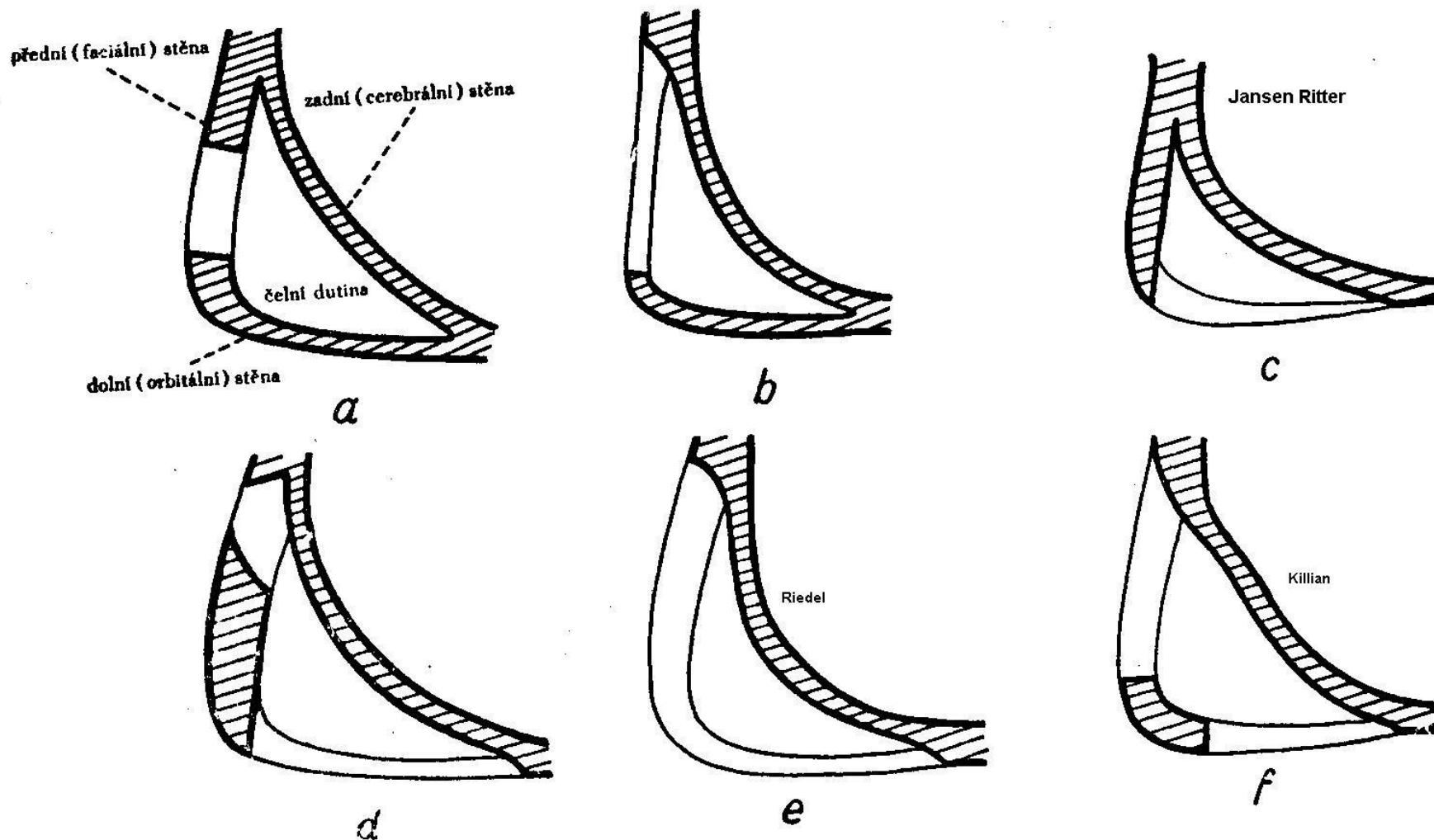
George Walter Caldwell
1866-1946

Henri Luc 1855-1925

1889

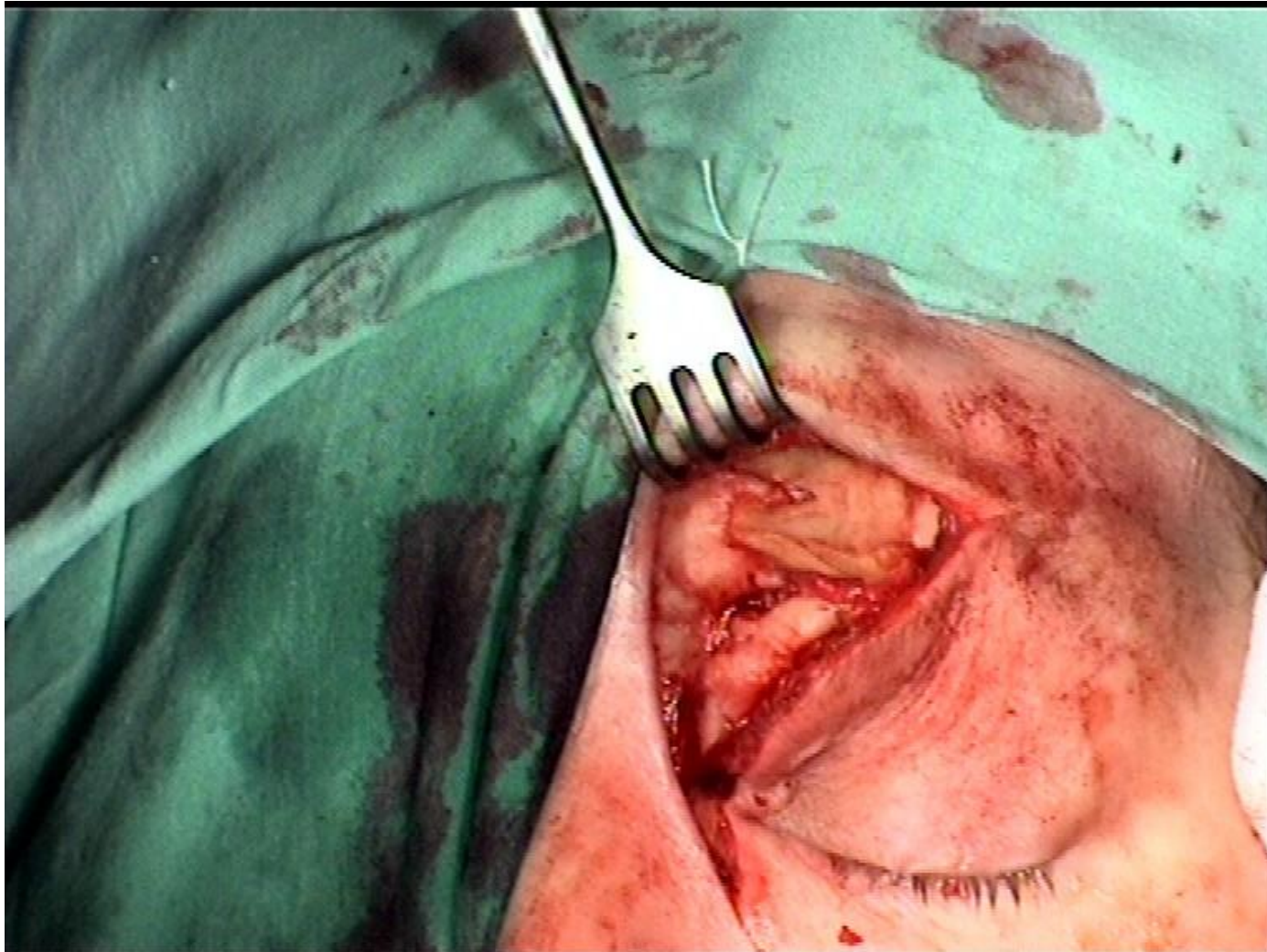
1893



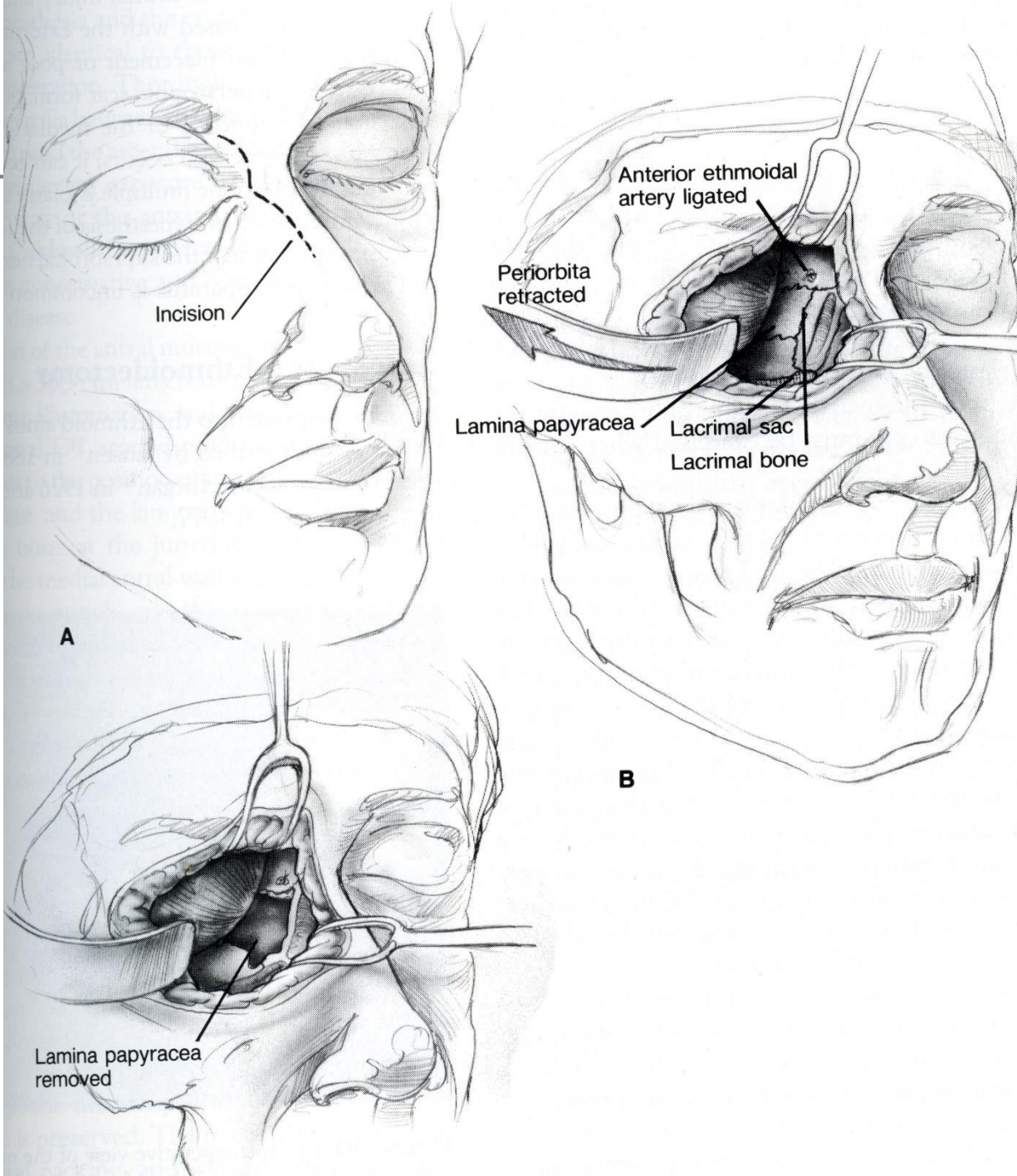


Různé typy operací čelních dutin (podle Denkera-Kahlera) II. str. 787

a) Ogston-Luc - b) Kuhnt - c) Jansen-Ritter při nízké čelní dutině
d) Jansen-Ritter při vysoké čelní dutině - e) Riedel - f) Killian



external ethmoid-ectomy





„classical“ rhino-surgery - indication

- Repeated FESS lege artis failed
- some atypical forms of sinusitis - mycotic sinusitis (aspergilom)
- Inflammatory complications of sinusitis
- tumors of paranasal sinuses
- Some injuries
- Immunocompromised persons, congenital diseases



Classic rhinosurgery

Objections against

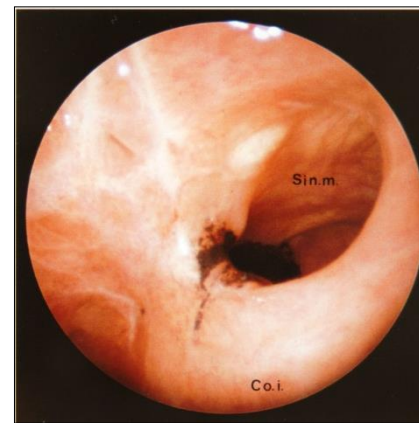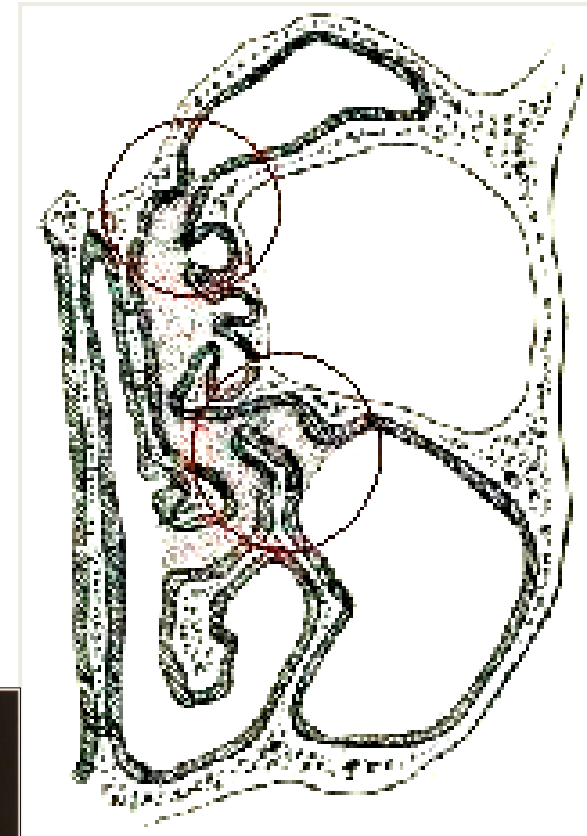
- Too high radicality
- many iatrogenic complications (swelling, pain, innervation disorder)



Functional endonasal sinus surgery (FESS)

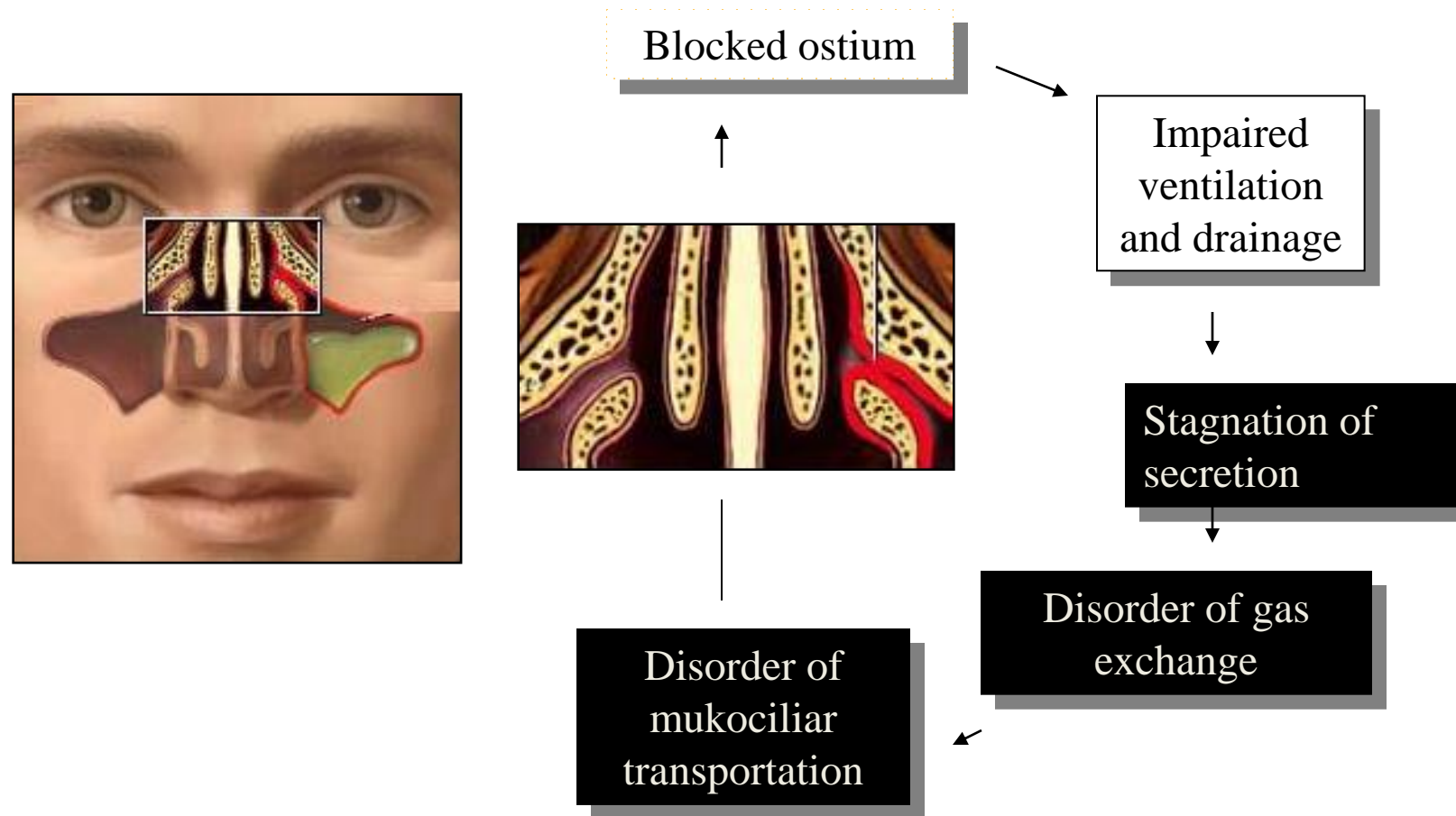
Basic considerations

- Pathologically changed mucosa is able to restitution and should be preserved as more as possible
- For restitution it is necessary to create ventilation and drainage
- Epicentrum of rhinogenic sinusitis is in ethmoidal labyrinth



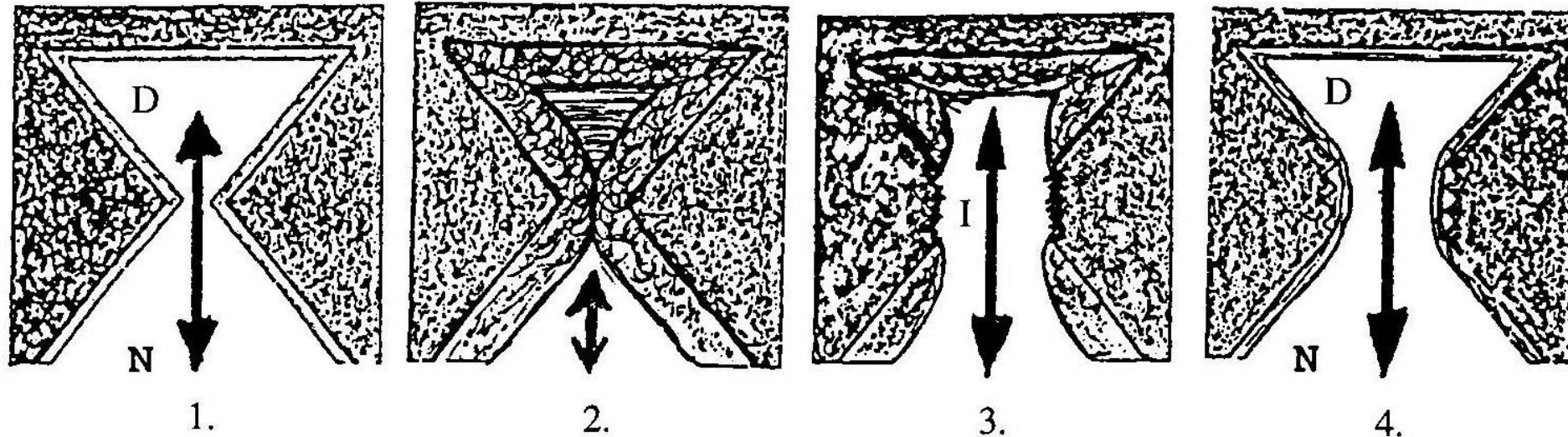


Pathogenesis of chronic rhinosinusitis – „circulus vitiosus“





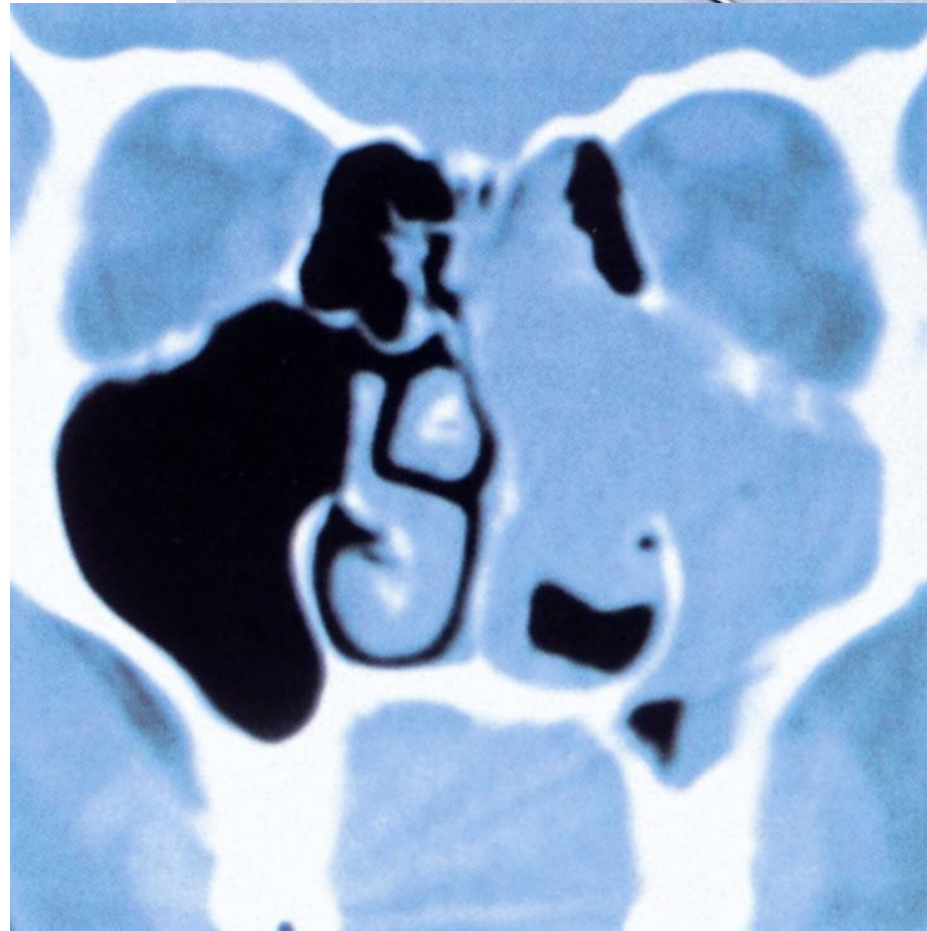
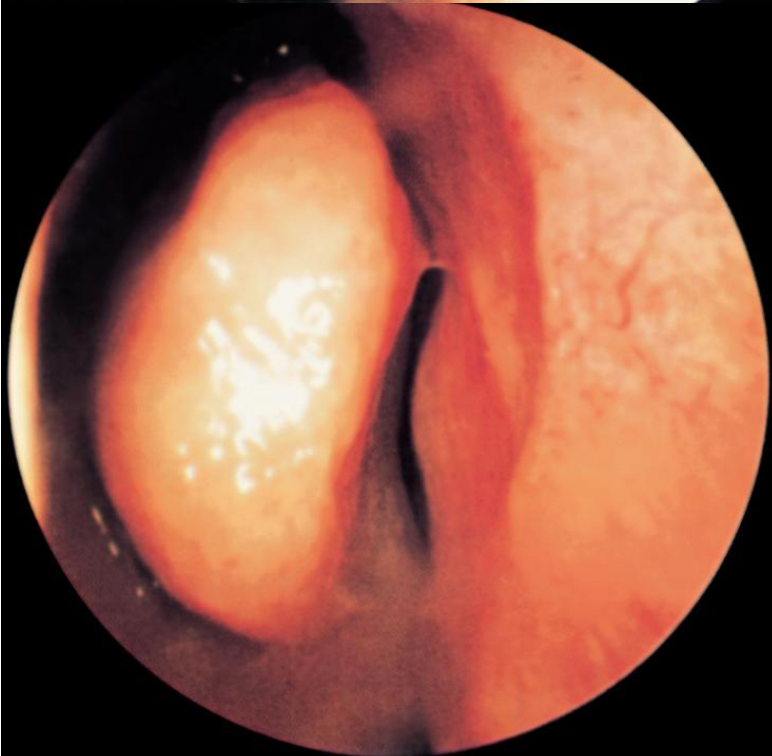
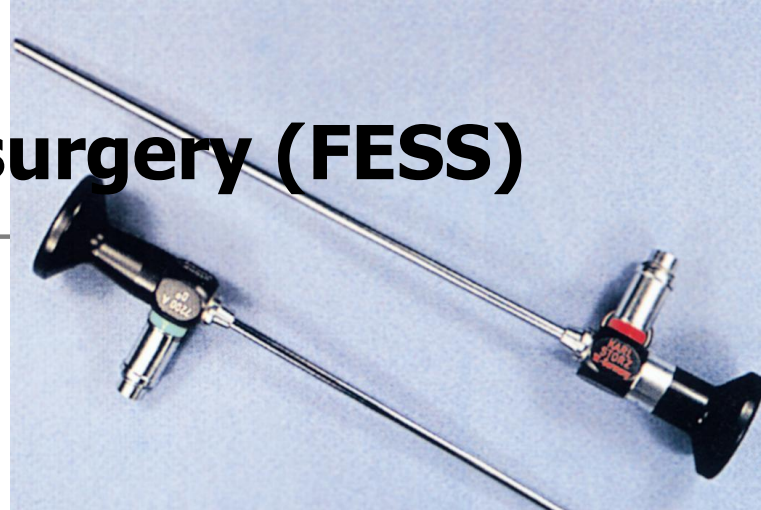
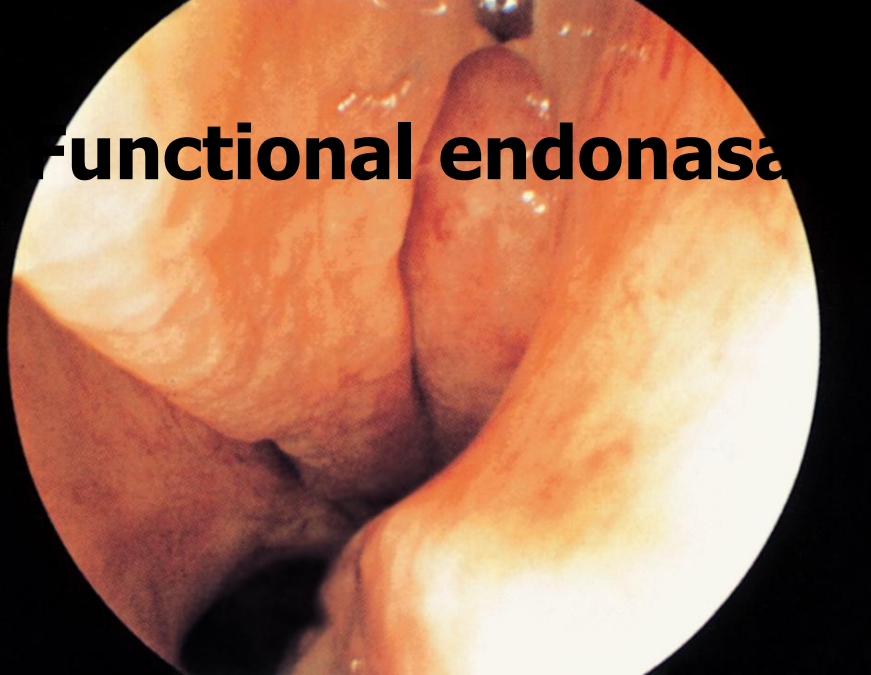
„Ostium Surgery“ (Isthmus chirurgie)

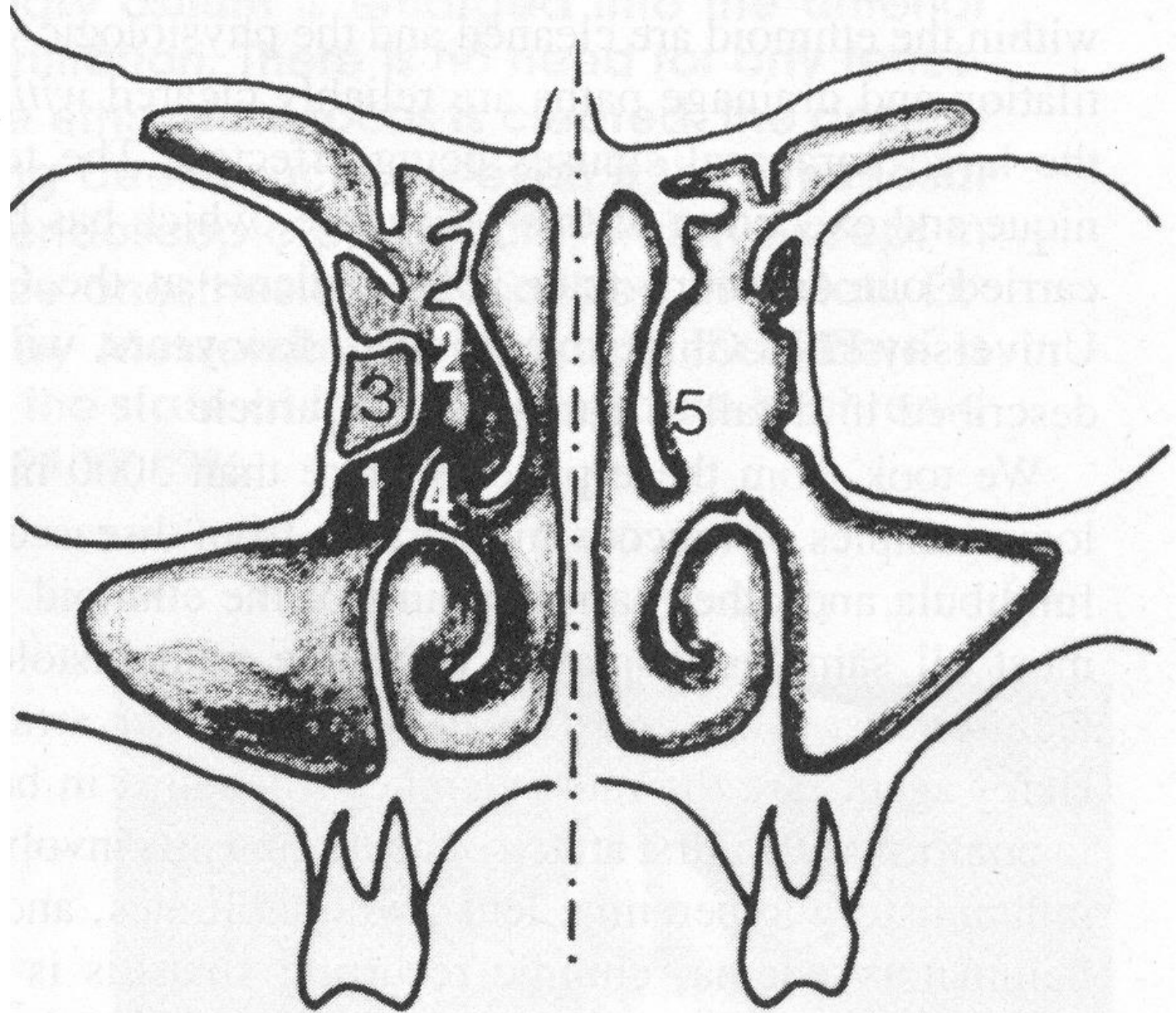


D paranas. sinus connected with nasal cavity N.

1. – normal situation
2. – closed ostium
3. – widened ostium
4. – healed ostium with renewed communication D-N.

Functional endonasal sinus surgery (FESS)





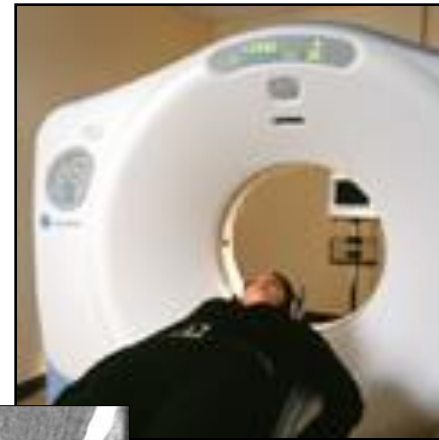
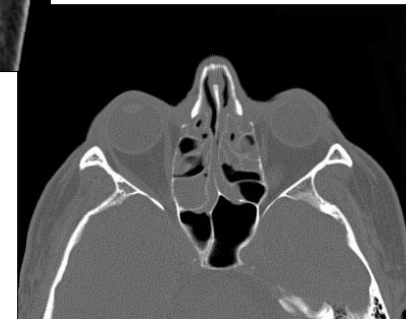
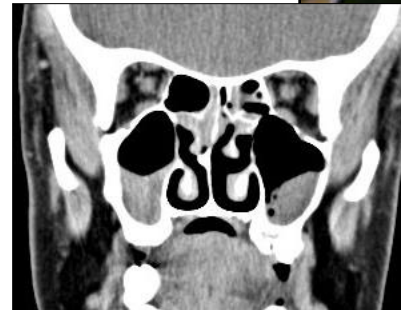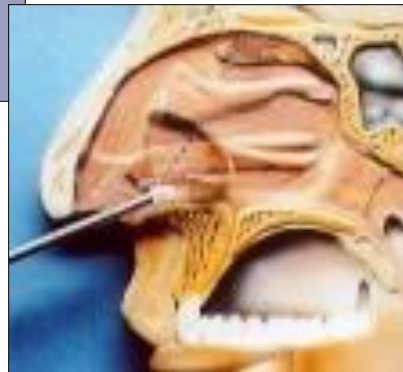Indications, limits of FESS

- Only some surgeries are **treating the cause** – some chronic infectious inflamm., cysts and various structural changes disabling ventilation (deviatio of nasal septum, hyperpneumatized middle nasal concha et al.)
- Nasalization and enabling conservative treatment - **symptomatic** surgery as a part of **complex treatment**

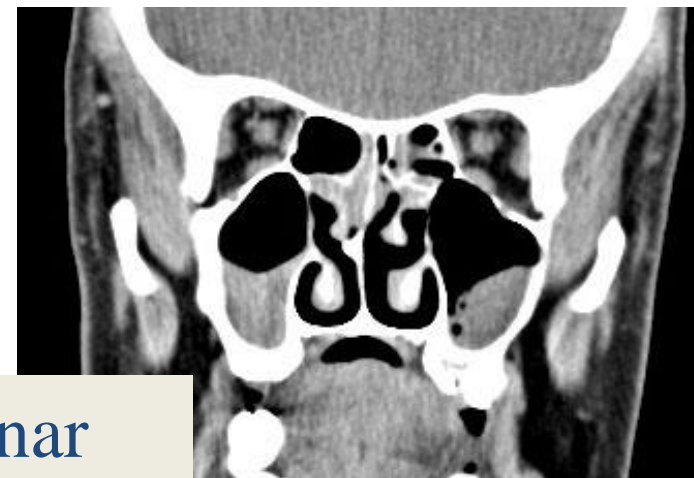
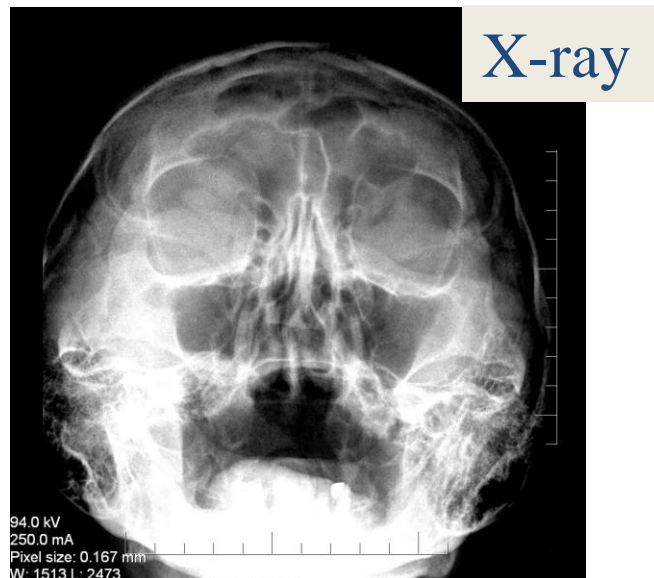
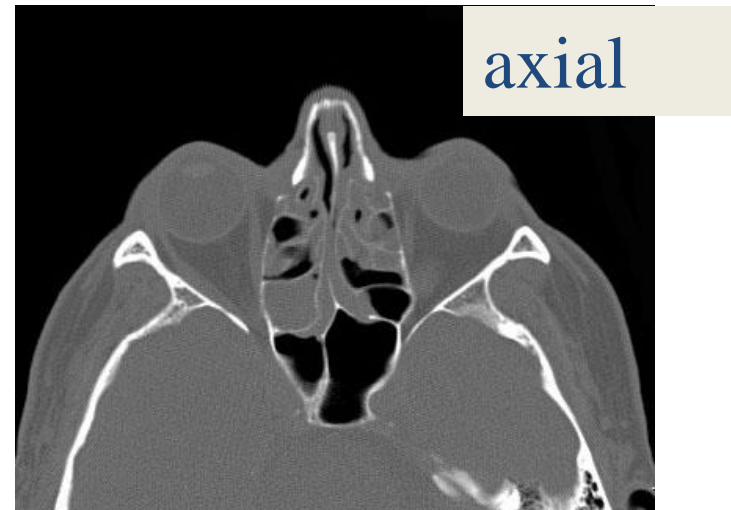Indication of FESS

- History of disease
- Imaginating methods (CT)
- Rhinoadoskopy



CT of paranasal sinuses

- Localization and extent of pathological changes – type and extent of surgery
- Guidelines for surgeon – relationship to orbit and endocranium



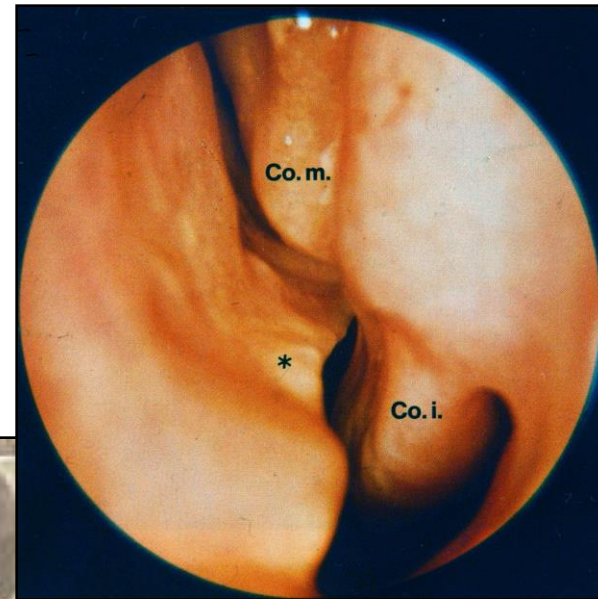
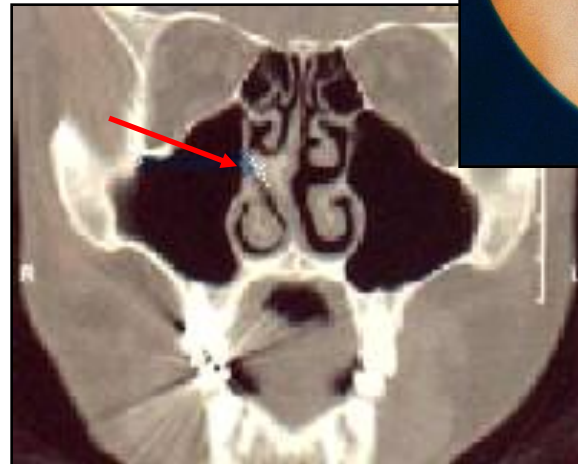

Surgery

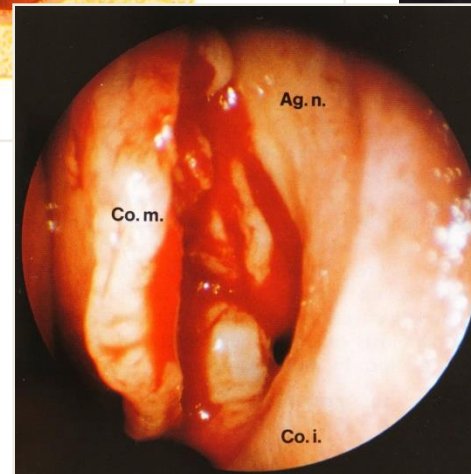
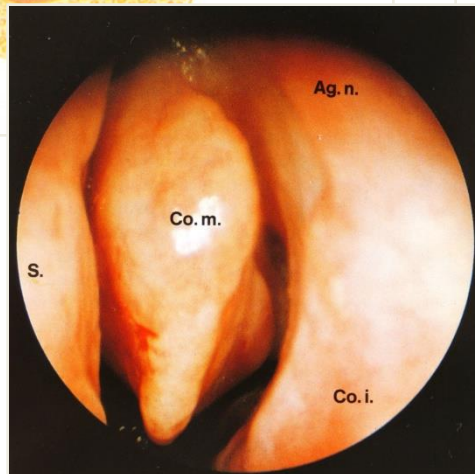
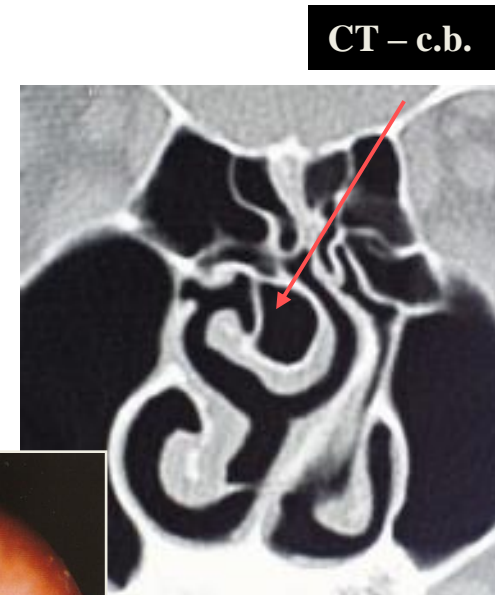
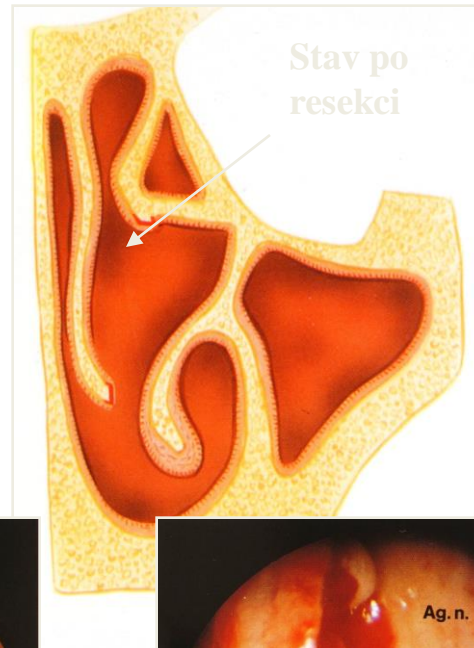
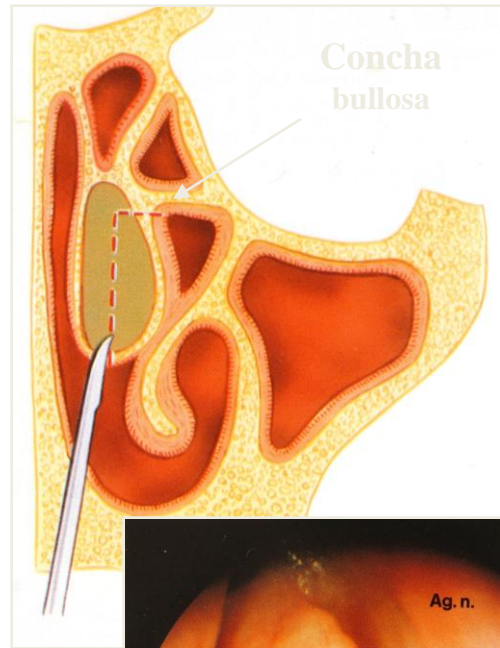
- Structural changes in nasal cavity (deviace přepážky nosní, concha bullosa)
- One sinus (supraturbinal antrostomy, sphenoidotomy, frontal sinotomy, ethmoidektomy)
- Pansinus surgery („Wigand complet“)

Surgery of nasal septum

endoscopic resection (cristae,
spins)

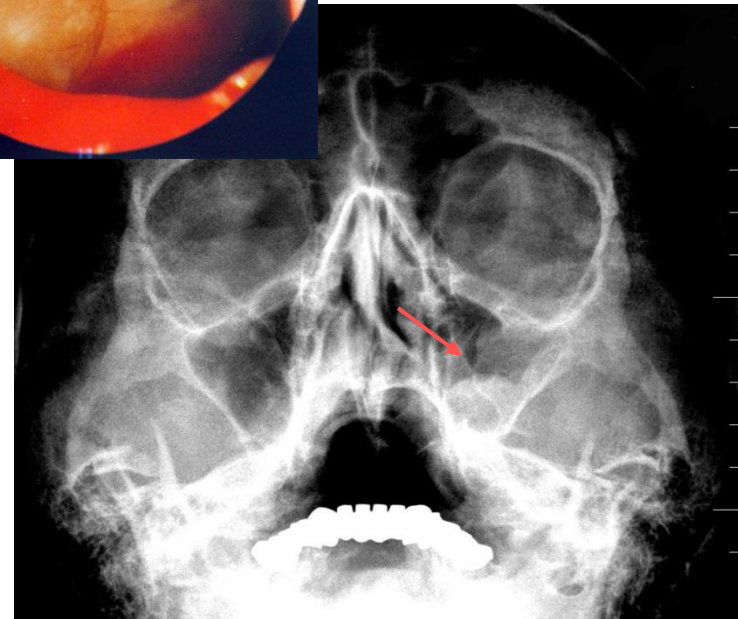
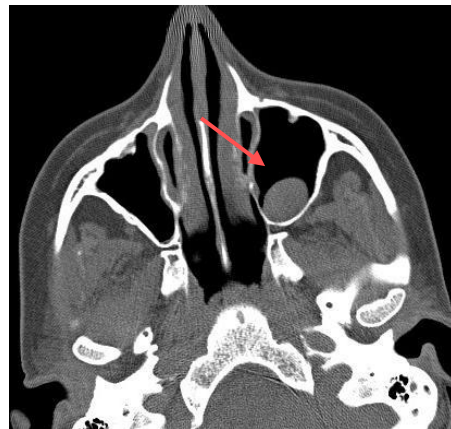
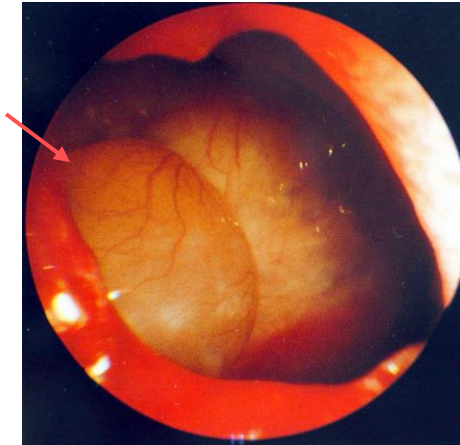
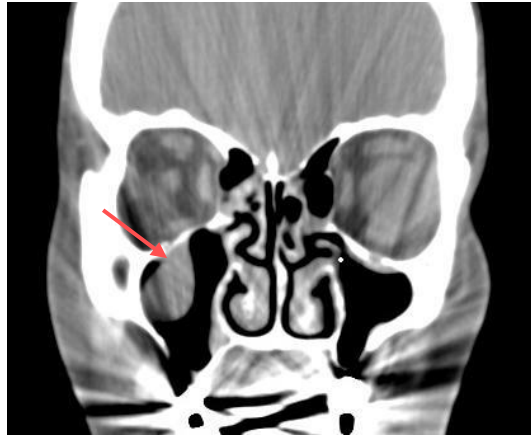


Concha bullosa resection



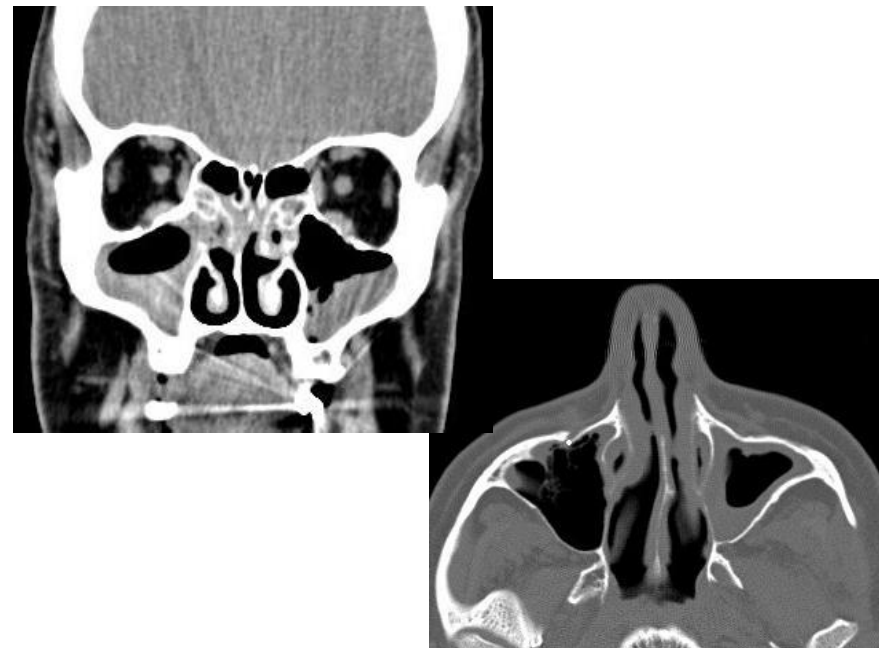
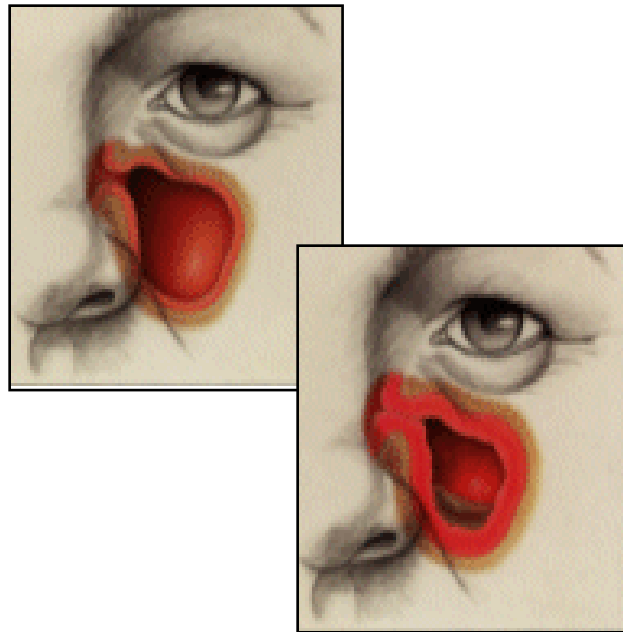
Maxillary sinoskopy

Mucosal cyst in antrum



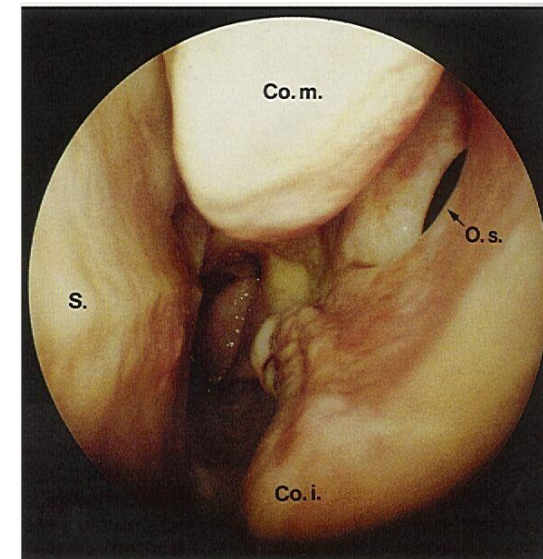
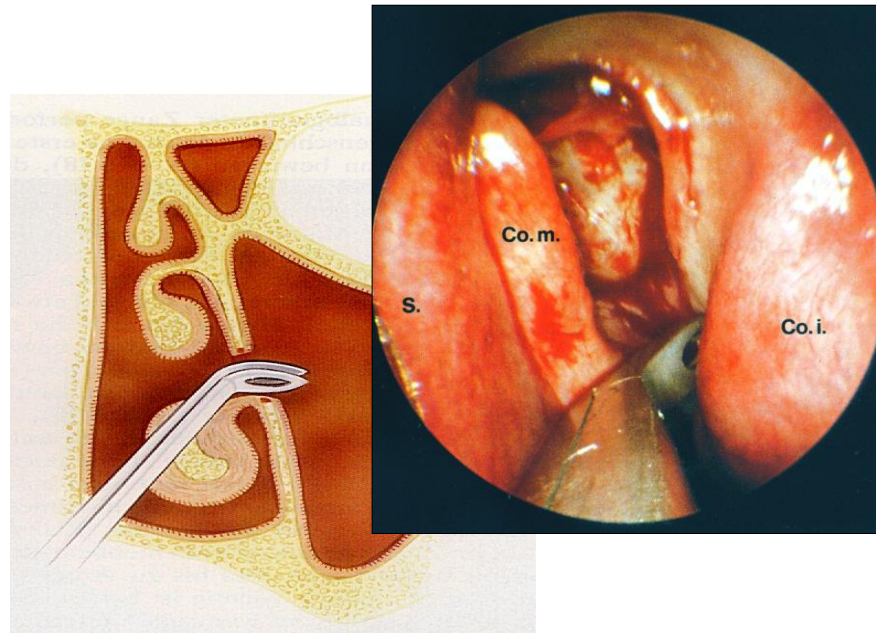
Supraturbinal antrostomy

Indication - chronic inflamm.chaneges of maxillary sinus caused by blocked ostio-meatal-unit



Supraturbinal antrostomy

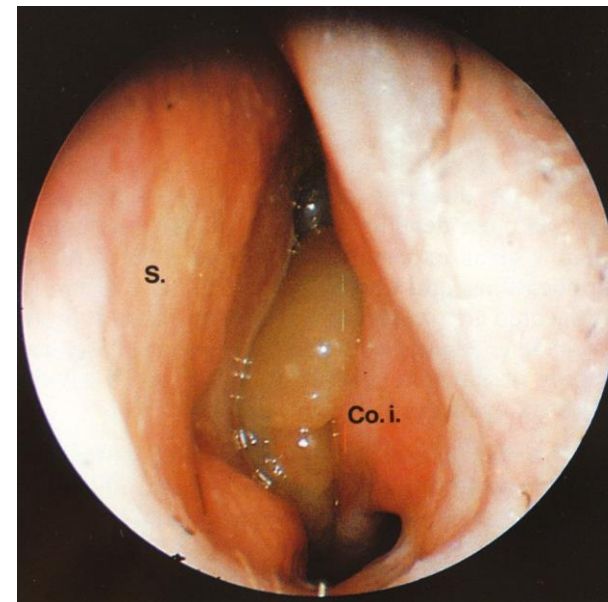
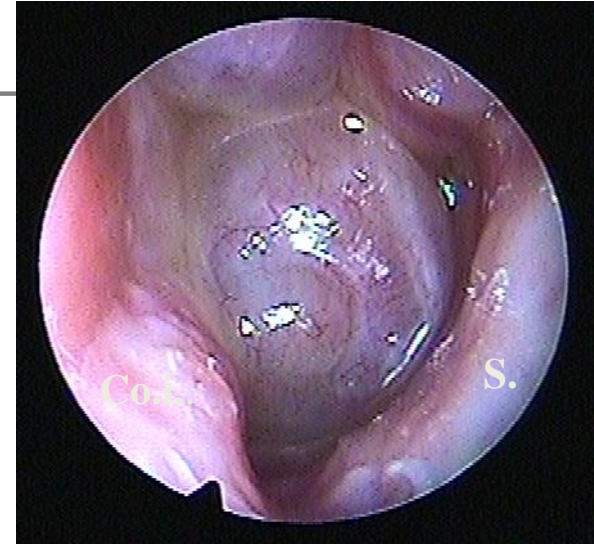- renewal of communication between nose and maxillary sinus
- usually part of extent surgery



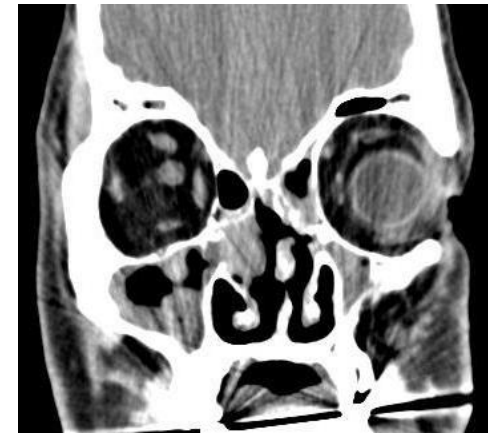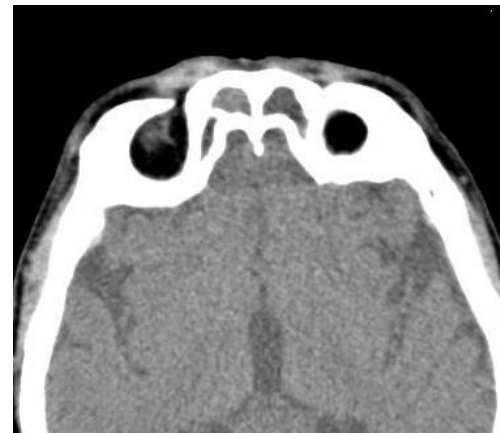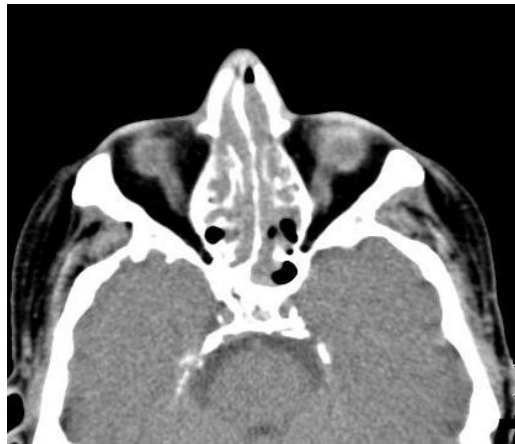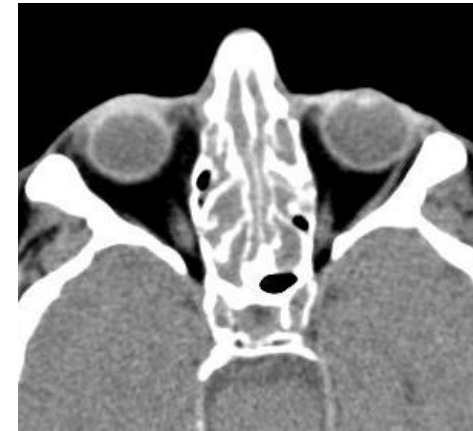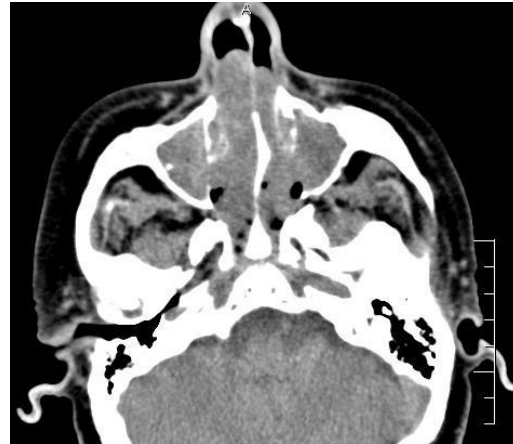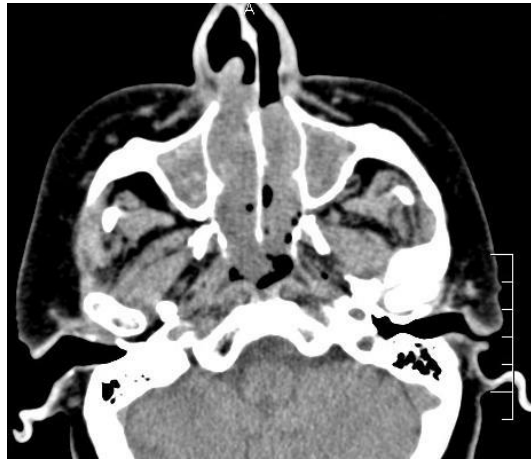„Pansinus surgery“

Indication : chronic inflammations
with polyposis

Aim : nasalisation of big paranas.
sinuses

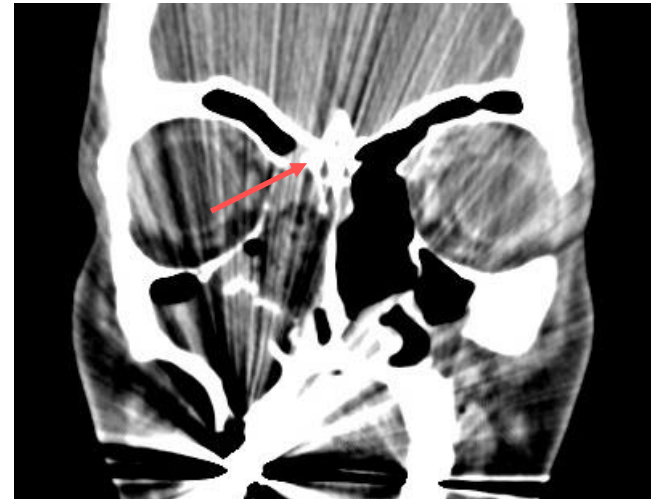
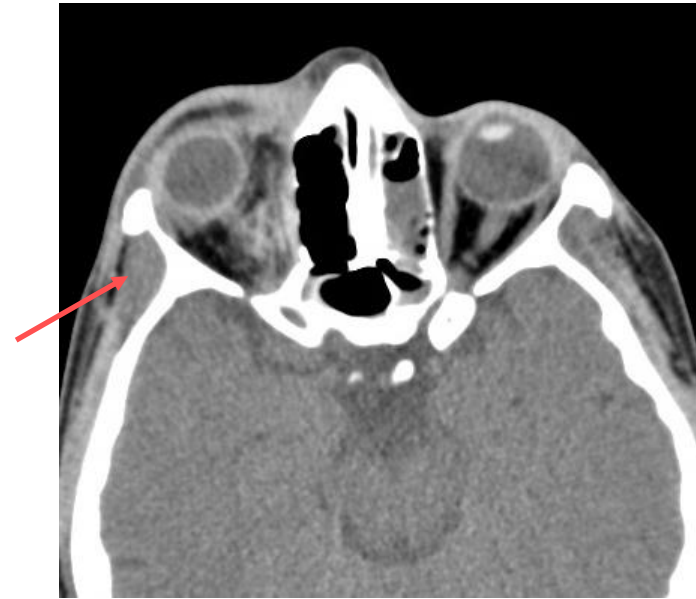
Pansinus surgery - CT



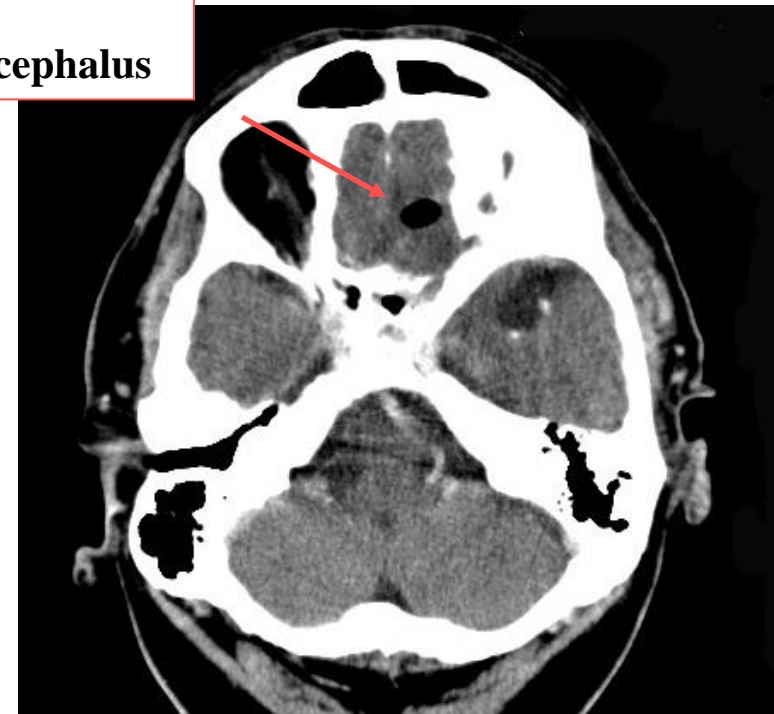
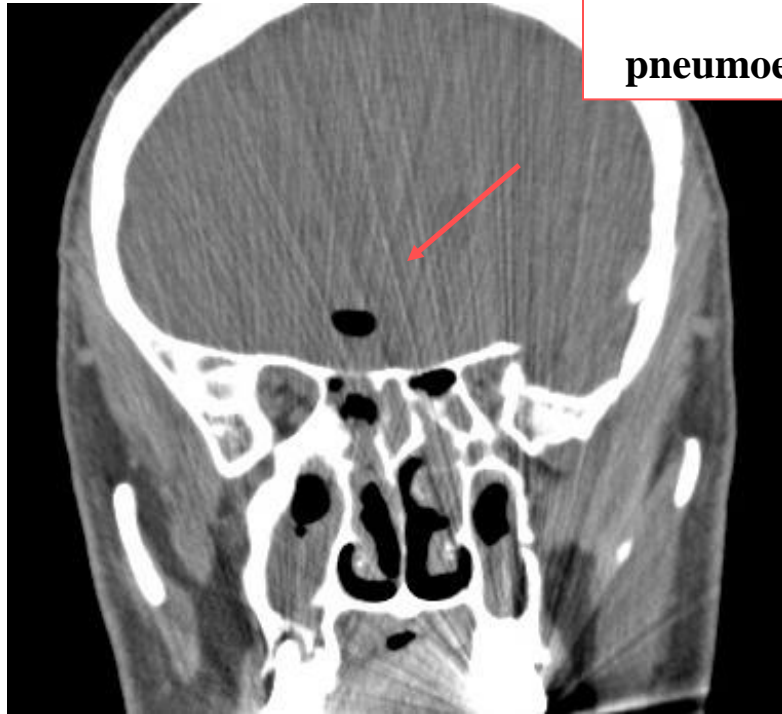
Complications

- „Small“
 - bleeding
 - hematoma, emphysema of eye lids
 - headache
- „Big“
 - retrobulb. hematoma
 - meningitis
 - liquorea
 - Bleeding from ACI
 - death



Complications II

Liquorea
+
pneumoencephalus



CAS – computer assisted surgery

Navigation system (Medtronic, Scopis – magnetic navigation)

