

FAKULTNÍ  
NEMOCNICE  
U SV. ANNY  
V BRNĚ



MUNI  
MED

# Oral cavity and Pharynx

## *KOCHHK FNUSA*

Klinika otorinolaryngologie a chirurgie hlavy a krku

Fakultní nemocnice u sv. Anny a LF MU v Brně

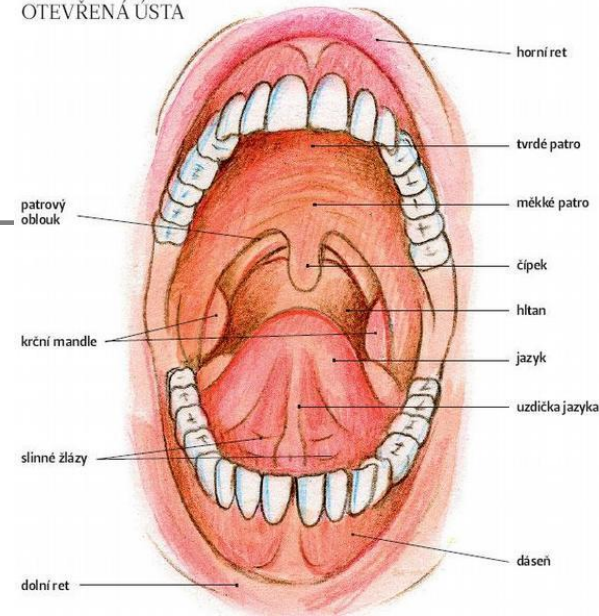
Přednosta: Doc. MUDr. Gál Břetislav, Ph.D.

Pekařská 53, Brno , 656 91

# Anatomy - oral cavity

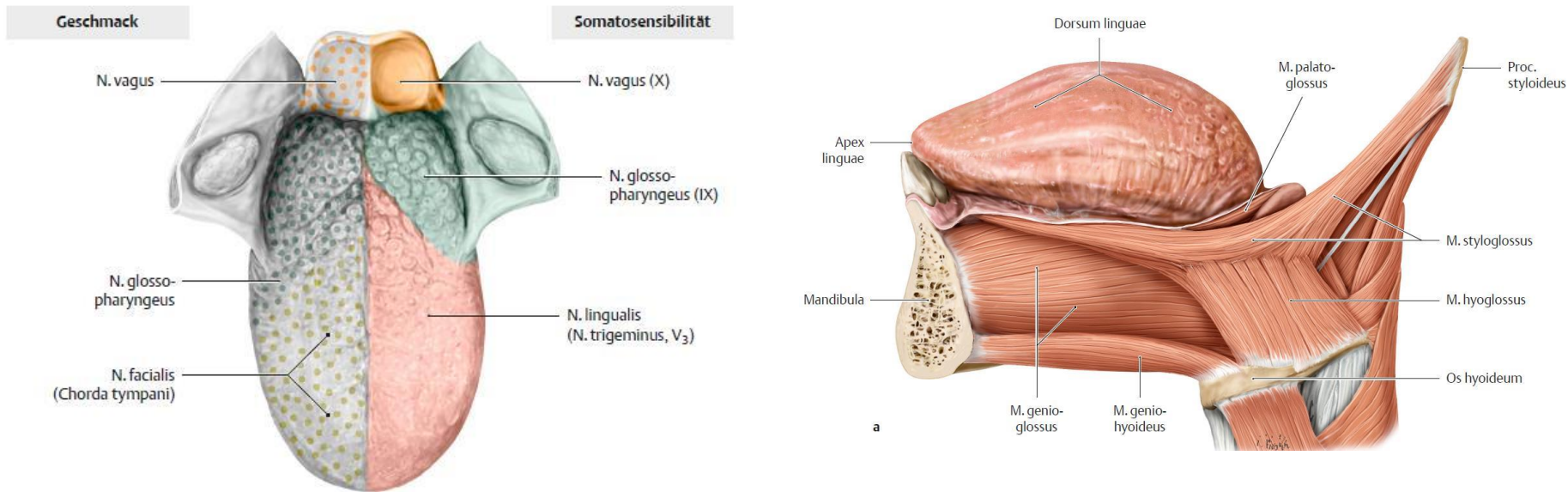
- **Lips** (m.orbicularis oris)
- **Cheek** (m.buccinator, d.Stenoni)
- **Processus alveolaris maxillae et mandibulae, teeth** (adult 32, child 20)
- **Hard palate**
- **Base of the oral cavity** (m.geniohyoideus, m.myohyoideus) – gl.sublingualis, ductus Warthoni (gl.submandibularis)

OTEVŘENÁ ÚSTA



# Anatomy - oral cavity

**Tongue** – intraglossal and extraglossal („deep“) muscles (m.styloglossus, m.palatoglossus, m.genioglossus, m.hyoglossus)



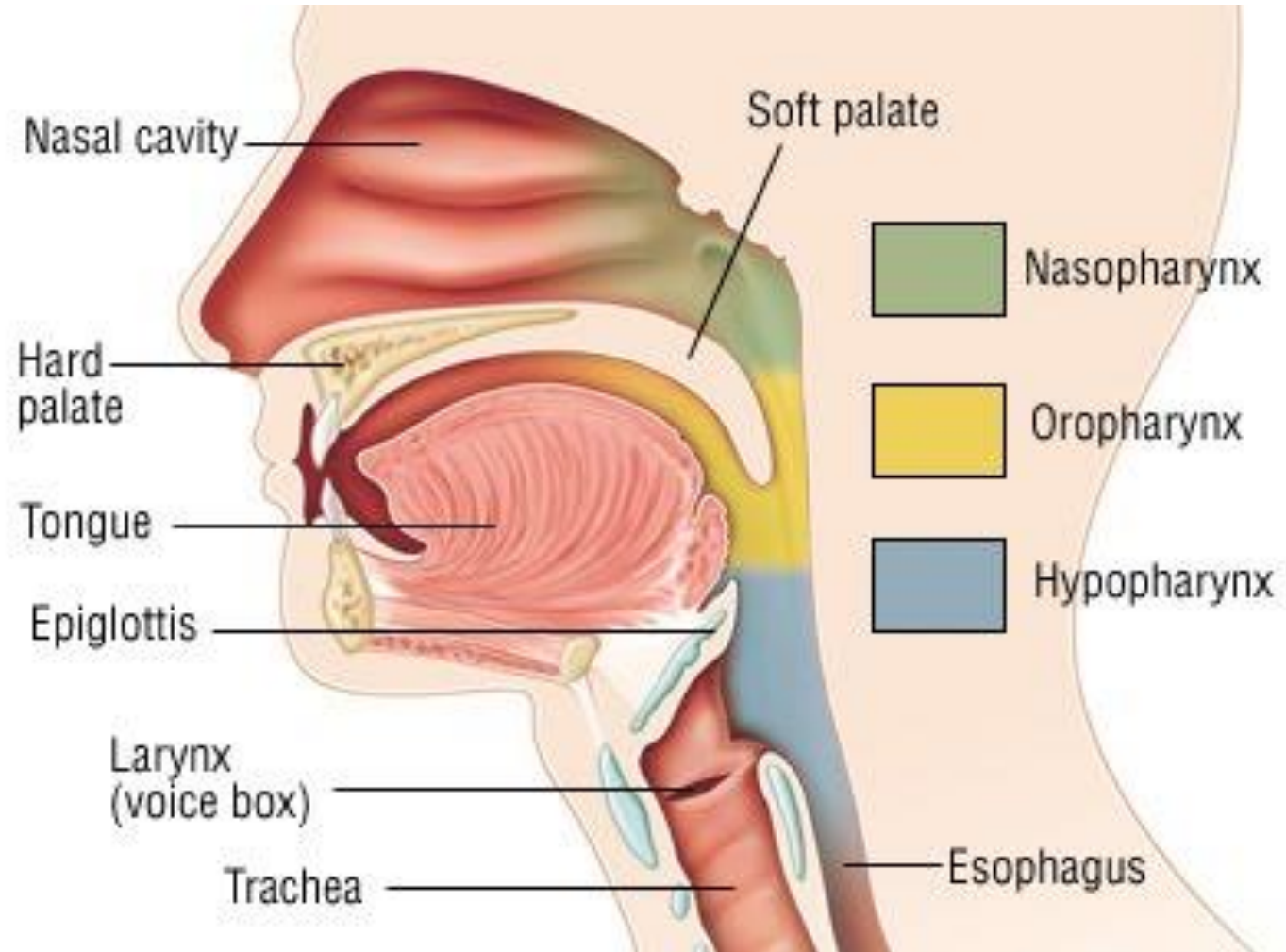
**masticatory muscles** (m.masseter, m.pterygoideus lateralis et medialis, m.temporalis) – innervation n. V.

# Anatomy - pharynx

Muscular-  
fibrous tube, -  
from skull base  
to C6  
(cricopharyngeal  
sphincter)

**Pars nasalis  
(epipharynx)**

**Pars oralis  
(mesopharynx)**

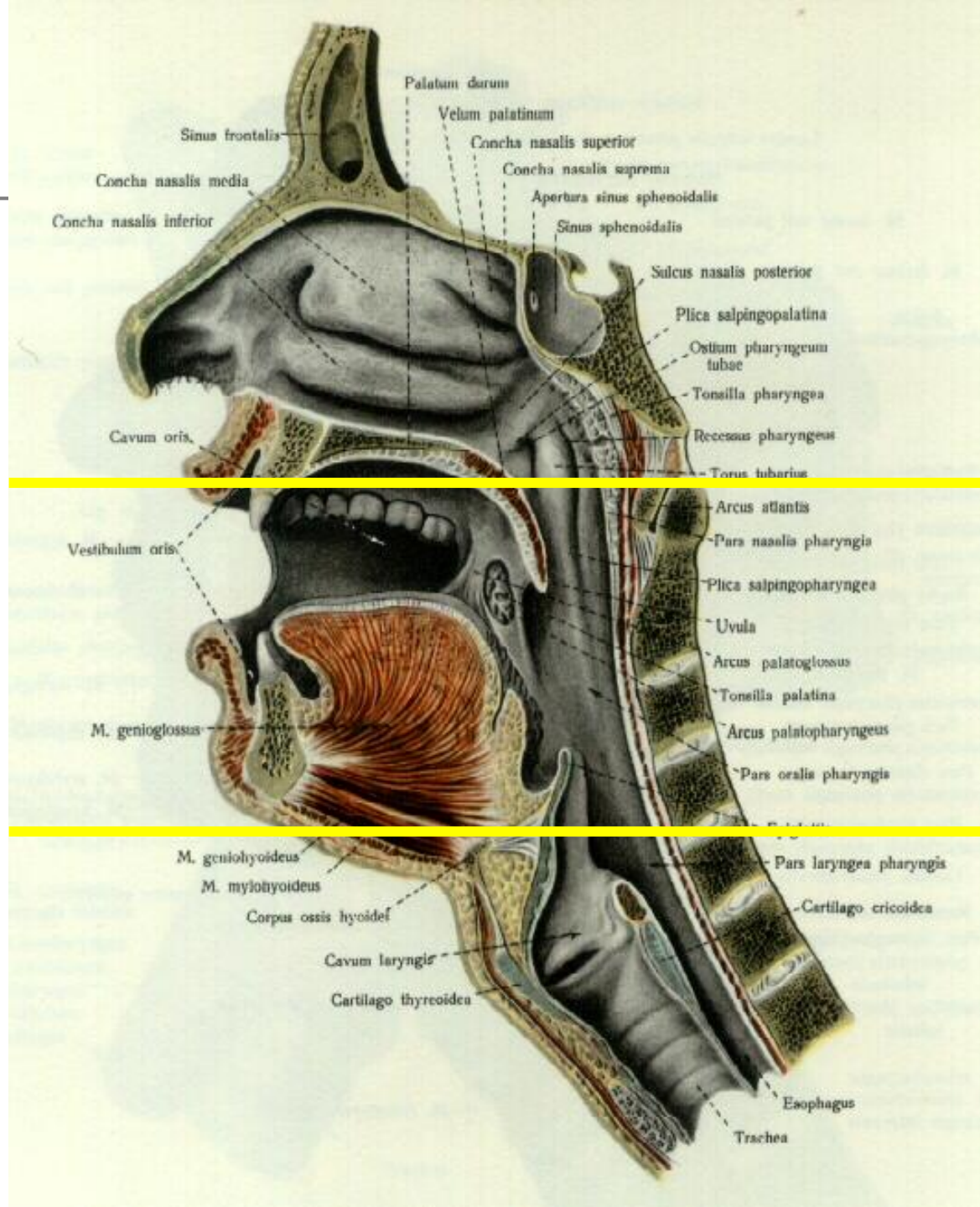


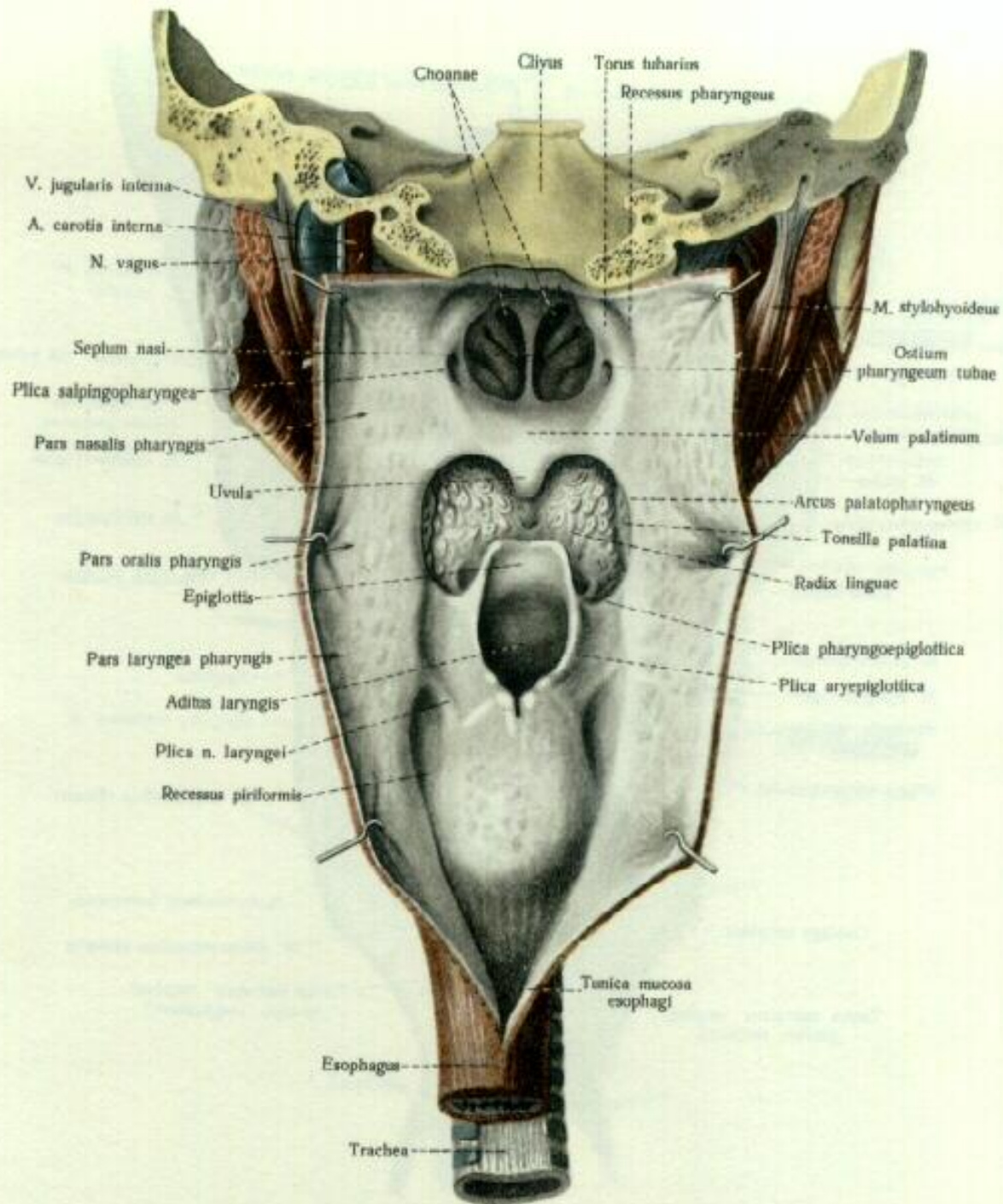


## Epipharynx

## Oropharynx

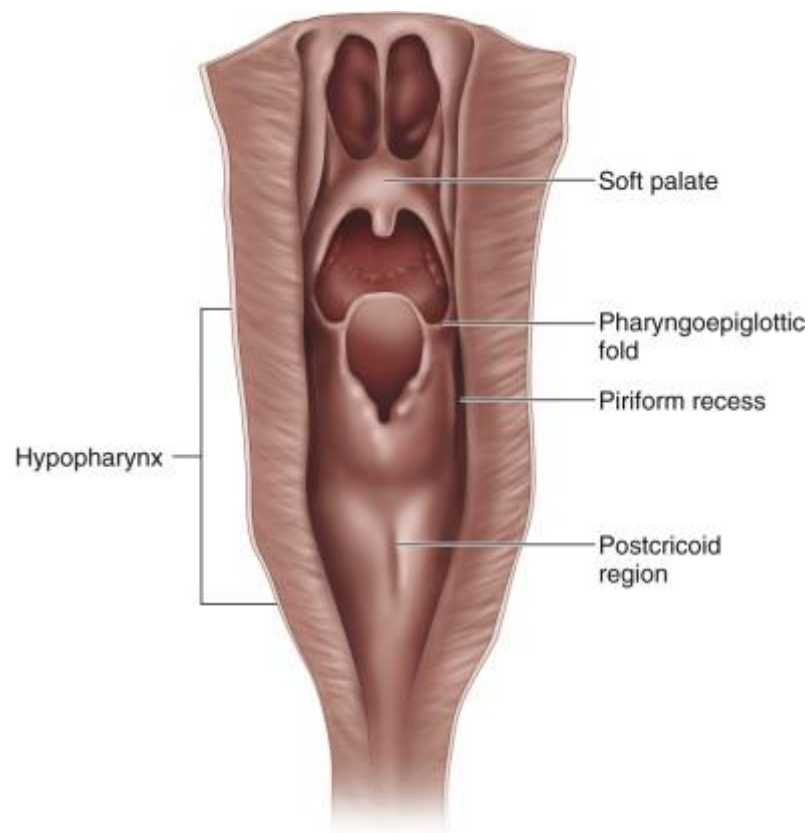
## Hypopharynx





# Pars laryngea (hypofarynx)

- from superior edge of hyoid bone horního (vallecula glossoepiglottica) to inferior edge of cricoid cartilage (C6)
- piriform recess – bordered medially by aryepiglottic fold, laterally internal space of thyroid cartilage, posteriorly posterior wall of hypopharynx
- anteriorly - postcricoid region





# Waldayer's lymphoepithelial ring (system of the Pharynx)

---

Lies at the opening of the upper aerodigestive tracts.  
Consists of tonsils and lymphatic subepithelial tissue.

Tonsila:

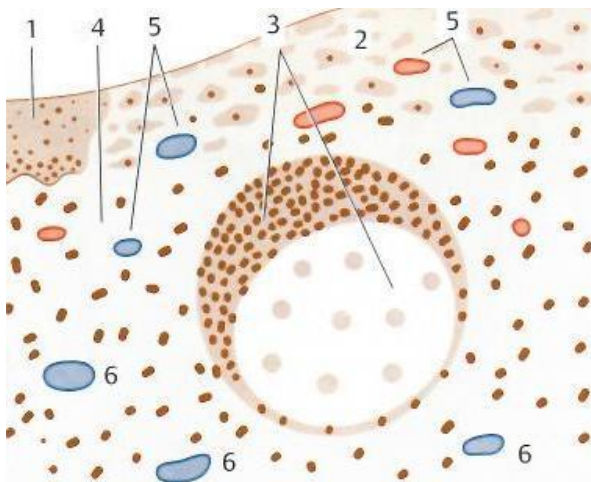
- pharyngea (epipharynx)
- Tubariae (epipharyngeal opening of tuba Eustachii)
- Palatinae
- Lingualis (tongue)
- Lymphatic tissue on lateral pharyngeal walls
- Lymphatic tissue on posterior pharyngeal walls
- Lymphatic tissue in introitus laryngis



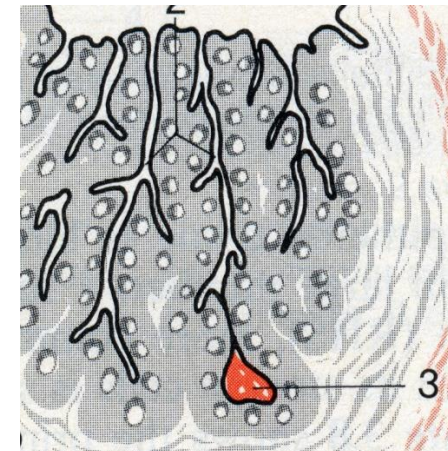
# Immune-specific function of Waldeyer's Ring

Lymphoepithelial tissue, reticulohistiocytic system lymphoepithelial organ - tonsils

- The tonsils ensure controlled and protected contact of the organism with environment, immunologic surveillance
- The tonsils produce lymphocytes
- The tonsils expose B- and T-lymphocytes to current antigens
- The tonsils produce specific antibodies after the production of the appropriate plasma cells.
- All types of immunoglobulins occur in tonsillar tissue.



1. Continuous squamous epithelium
2. Reticular epithelium
3. Secondary nodes
4. Basic lymphoid tissue
- 5.,6. Arterioles and venules





# Main symptoms indicating disease of the mouth and pharynx I:

---

## **Pain on eating, chewing, or swallowing**

Frequent cause: inflammations, tumors, foreign bodies

## **Dysphagia**

Inflammations (glossitis, abscess, angioneurotic edema, edema of introitus laryngis)

Neurogenic etiology (disorder of n. vagus a glossopharyngeus, amyotrophic lateral sclerosis, bulbar and pseudobulbar paralysis, sclerosis multiplex, diabetic and alcoholic neuropathy)

Mechanical obstruction (foreign body, diverticulosis, stricture, tumor)

Miscelanea (epithelitis post actinotherapiam, xerostomy, fractures of mandibula and maxilla, disorder of chewing muscles)

## **Burning of the tongue**

toxic stomatitis, various diseases of GIT, xerostomia, syndrome Plummer-Vinson, Diabetes mellitus, food allergy, mucoviscidosis, psychogenic glossodynia



## Main symptoms indicating disease of the mouth and pharynx II: - superficialis laesions of the tongue

---

**Red tongue** (anemia, scarlett fever, hepatic cirrhosis, hypertension, allergy, Sjögren´s syndroma)

**Gray smooth tongue** (st.p. radiotherapiam, vitamin A deficiency, lichen planus)

**Black hairy tongue** (antibiotics, mycosis)

**Fissured tongue** (lingua plicata, Melkersson-Rosenthal syndrome)

**Coated tongue** (mycosis, non-specific inflammation, reduced food intake, fever, malhygiene of oral cavity)

**Brownish plaques** (uremy in renal insufficiency)



## Presence of blood in saliva, sputum

Bleeding in paradentosis, injury, foreign bodies, varices in base of the tongue, tumors.

Differential diagnosis: epistaxis, hemoptysis (coughing of blood from lower airways, hematemesis (bleeding from swallowing ways)

## Foetor ex cavo oris (Oral Fetor)

teeth, gingiva- caries dentium, paradontosis, stomatitis, exulcerated tumors

Pharynx - inflammation (acute, chronic, specific), foreign bodies, tumors

Airway – atrophic rhinitis, ozaena, purulent rhinosinusitis, bronchiectasis

Digestive tract – esophageal diverticulum, disorder of stomach etc.

Metabolic cause- diabetes mellitus (acetone), renal insufficiency (urine), liver coma (sweet aromatic smell)



## **Trismus**

Inflammation of the teeth or mandible, temporomandibular joint, oropharynx (peritonsillar abscess) injury, muscle spasm from neurologic origin, tumors of oropharynx and around the temporomandibular joint, congenital ankylosis of temporomandibular joint

## **Disorder of salivary secretion**

xerostomia - dehydration, st.p.RT, Sjögren's syndrome, sialoadenosis, sialorrhoea - psychogenic factors, gravidity; ...

## **Disorder of speech**

dysarthria - bulbar and pseudobulbar palsy, ...etc.



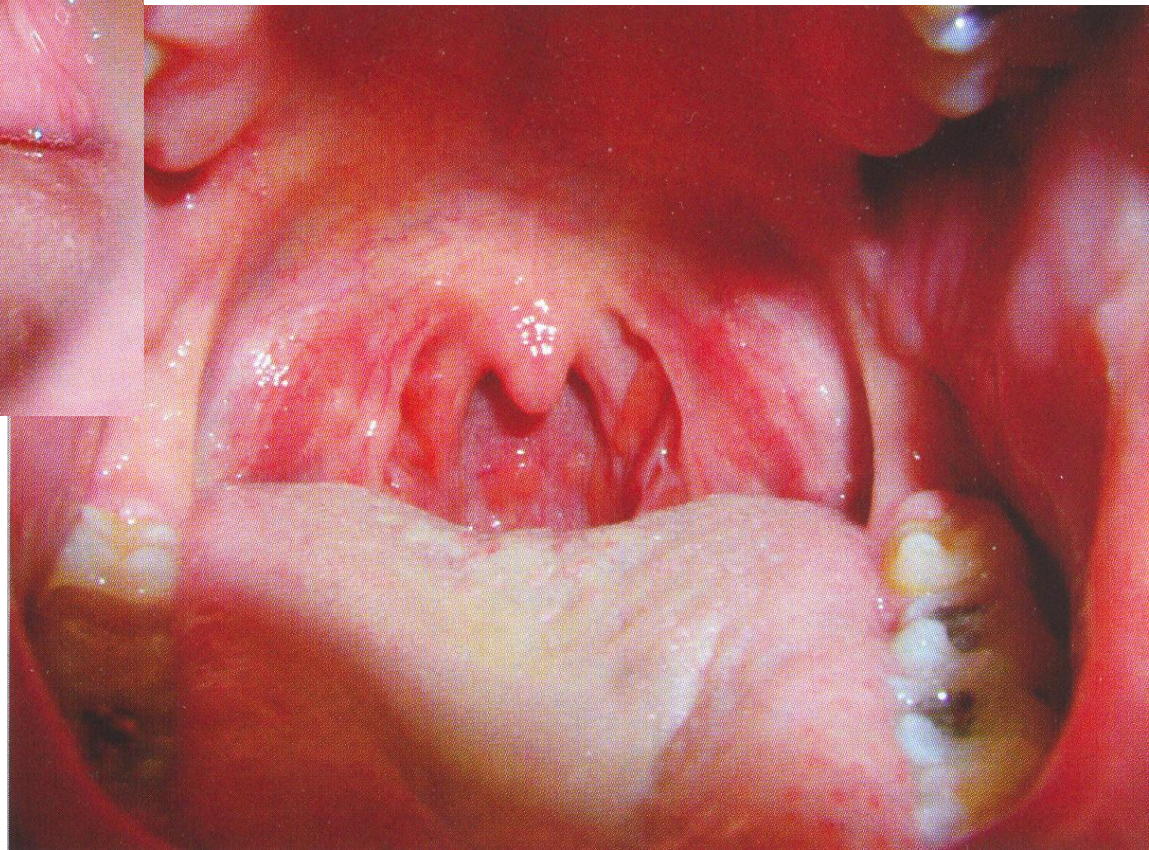
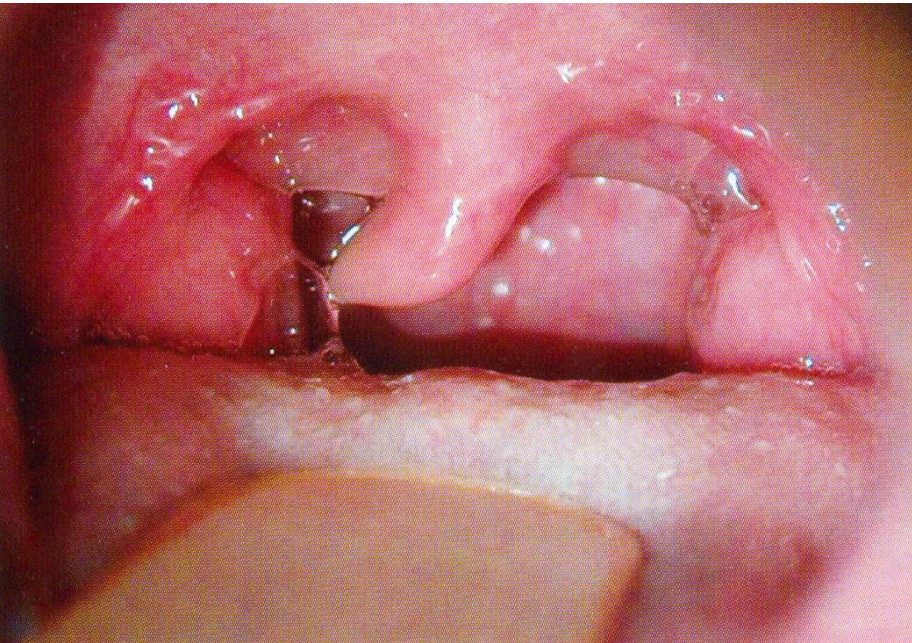
# Methods of investigation

---

- **Inspection - indirect, direct endoscopy**
- **Palpation**
- **Investigation of innervation**
  - ✓ **tongue** motoric innervation (n. hypoglossus – lying tongue - the tip to the sound side, tongue out – to the disease side)
  - ✓ **Sensitive**
  - ✓ **Sensorics (anterior 2/3 n. V., posterior 1/3 n. IX), elektrogustometry**

# Oropharynx- normal finding

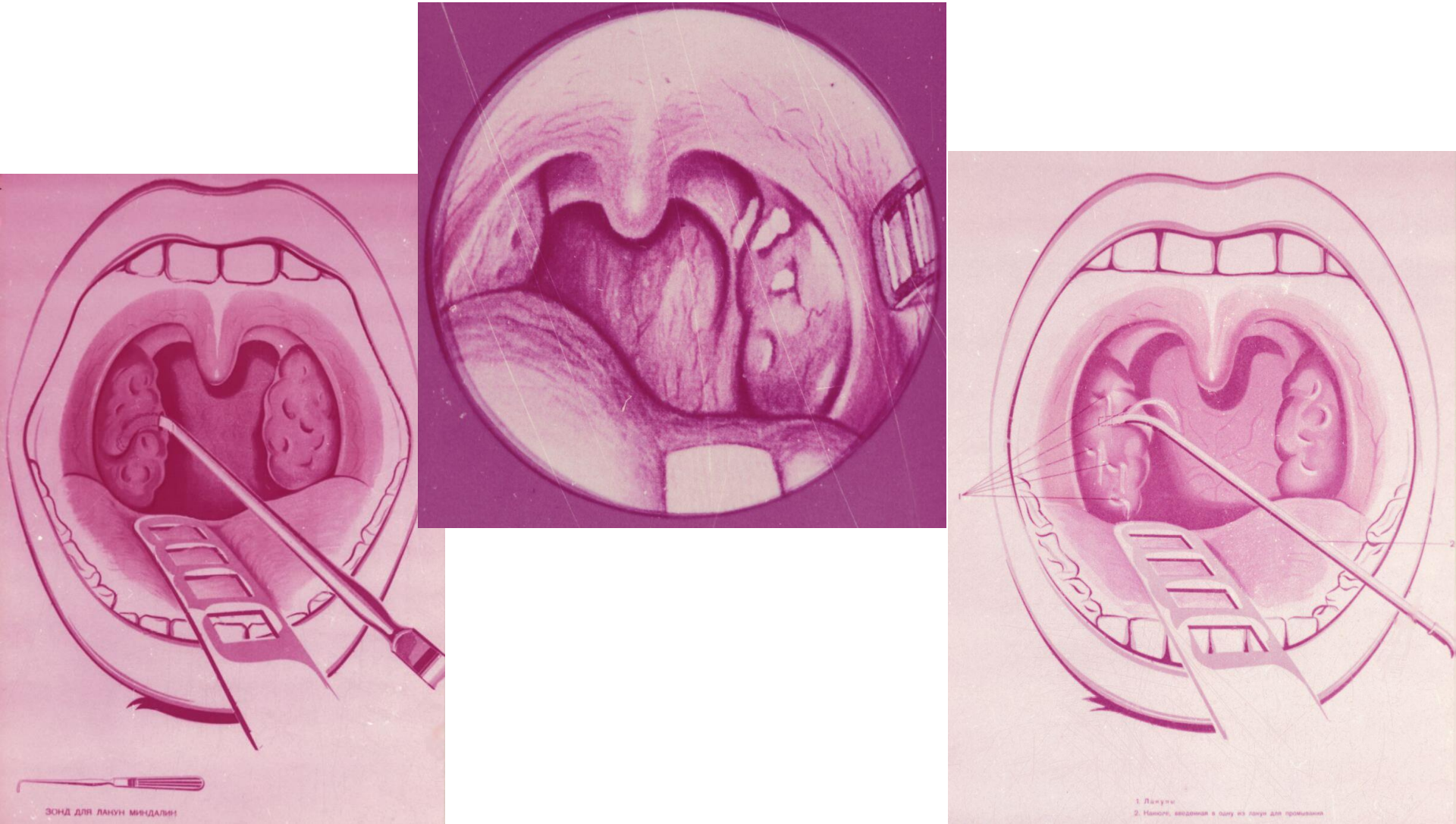
---





# Tonsillar pin

**the crypts usually contain cell debris, bacteria, lymphocytes - that smell extremely foul when released and can cause bad breath.**



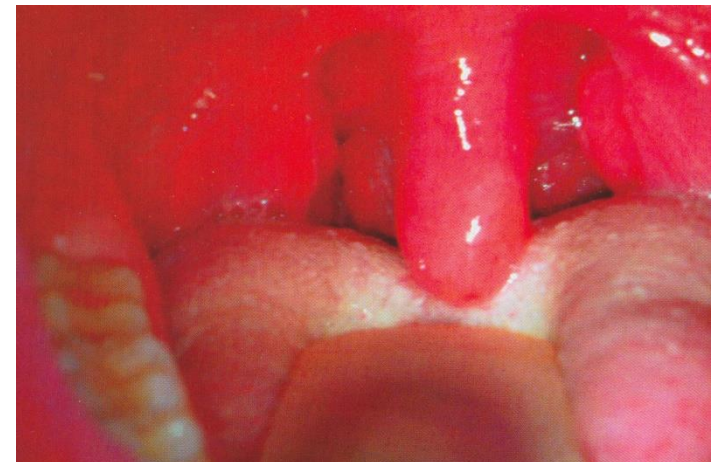


# Inflammation of pharynx

- division according to site of disorder
- **Tonsillitis** inflammation of lymphoepithelial tissue of pharynx.
- **Pharyngitis** inflammation of mucose membrane of pharynx.
- **Tonsillo-pharyngitis** inflammation of mucose membrane of pharynx and also lymphoepithelial tissue.

## According to course

- acute
- chronic





# Types of tonsillitis according to various criterion

---

- Anatomic (site)
- Microbiologic
- Pathogenetic
- Pathology- anatomy



# Site of disorder – acute tonsillitis

---

- angina palatina
- angina retronasalis
- angina pharyngis lateralis
- angina lingualis



# Microbiology

---

- **bacterial infection** : Streptococcus pyogenes **90%** of bacterial origin, Haemophilus influenzae, Staphylococcus aureus, Mycoplasma pneumoniae
- **viral** – adenoviruses, parainfluenza, enterovirus, coxsackie, etc.
- **fungal** – rarely in immunocompromised patients (immunosuppression, HIV, tumors)





## Acute tonsillitis

- suppurative
- symptomatic – local symptom of general disease with bacteriemia or viremia

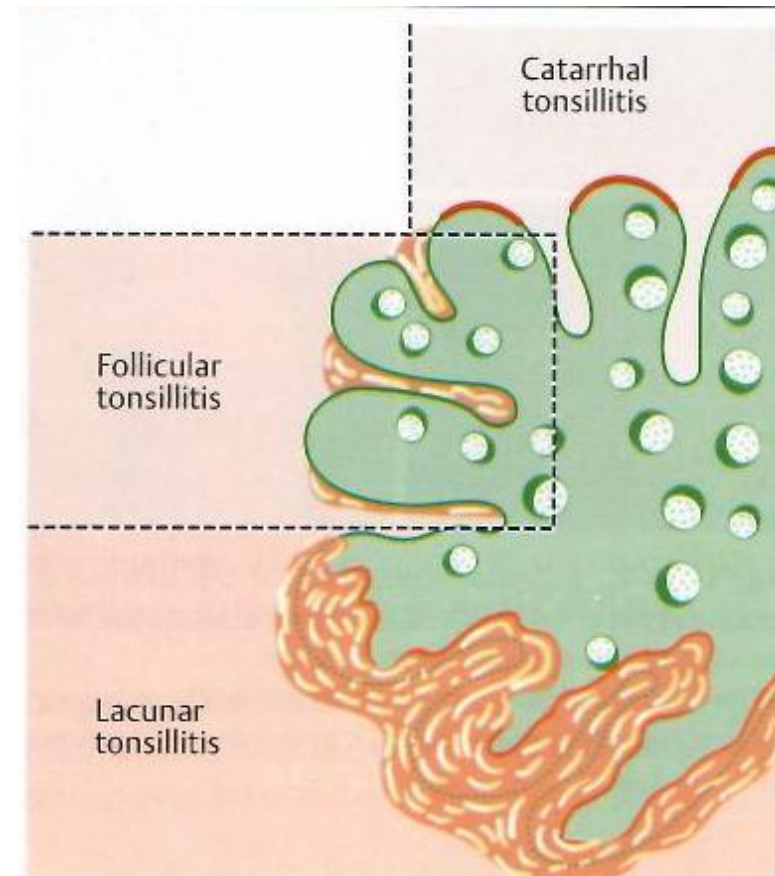
## Secondary tonsillitis

- in immunodeficiency (agranulocytosis, leukemia etc.)

## Acute tonsillitis

According the grades of severity and pathomorphology

- catarrhal
- follicular
- lacunar
- vesiculous
- pseudomembranous
- phlegmonous and gangrenous



Secondary nodes



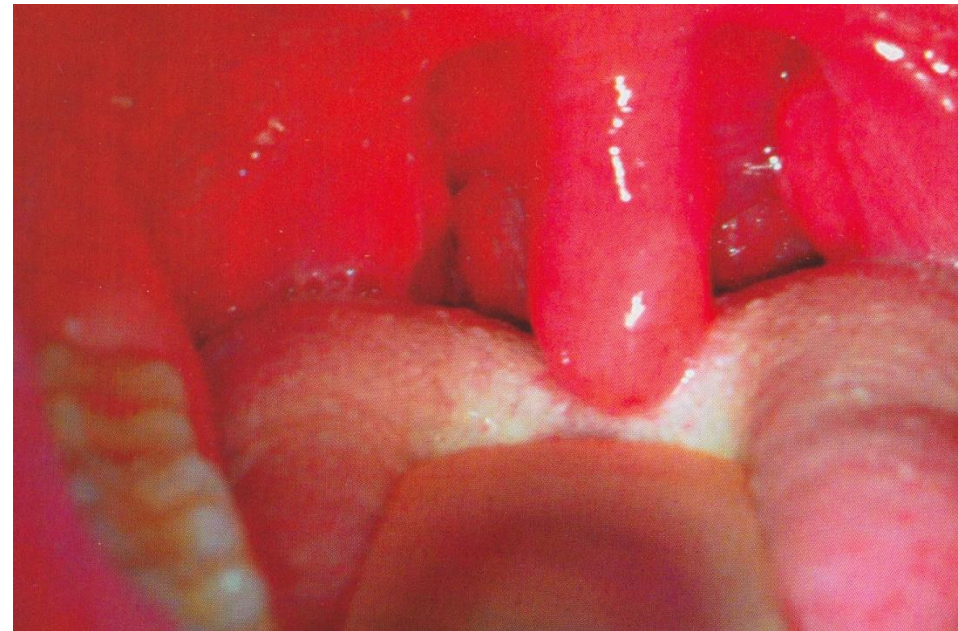Fibrin / granulocytes



## Tonsillitis ac. catarrhal

Bilateral odynophagy

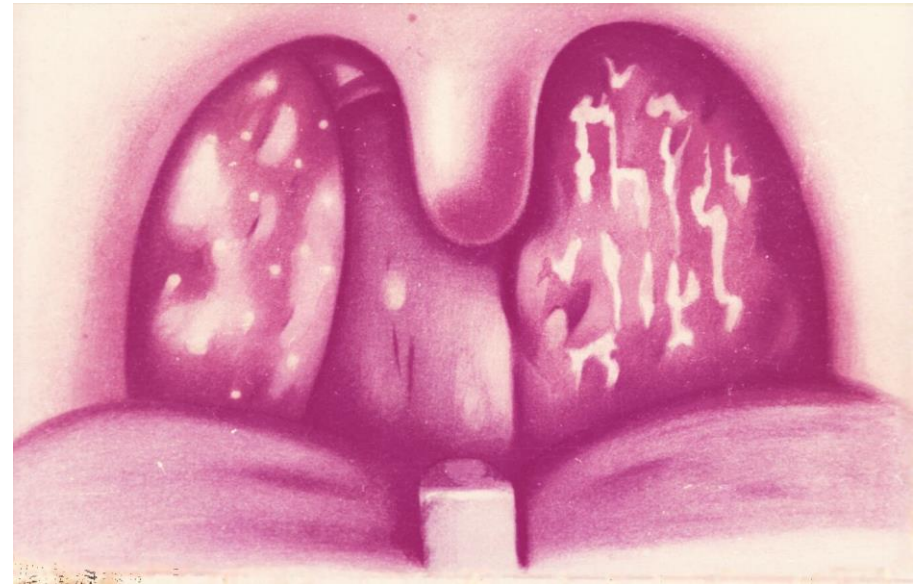
redness, swelling of  
tonsills, febris



# Tonsillitis ac. follicular

Bilateral odynophagia,  
increasing in  
swallowing, irradiated  
into ears

Micro-abscessus in  
follicles visible  
through mucosa  
membrane on the  
tonsillar surface

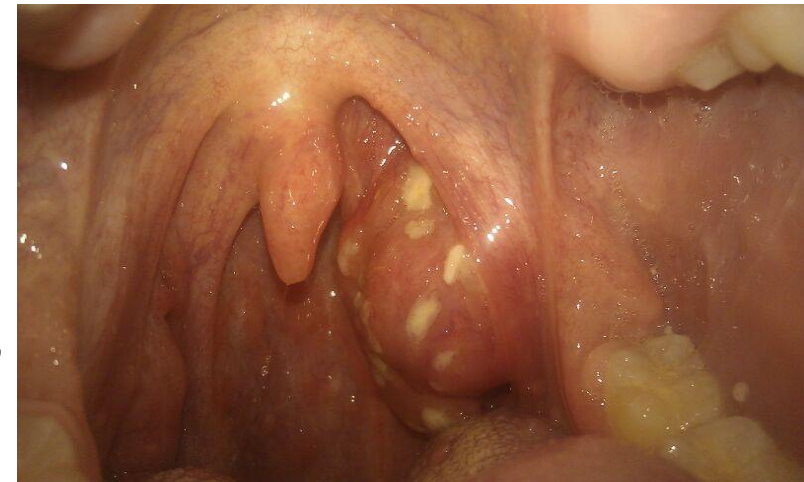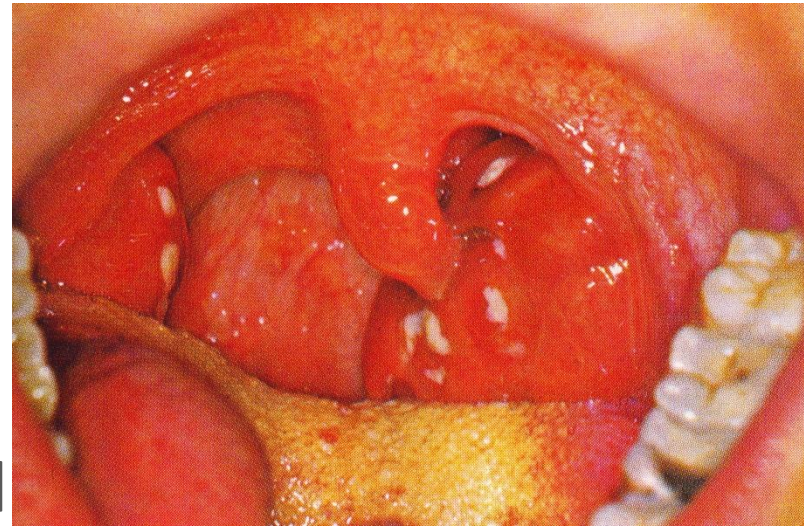




## Tonsillitis ac. lacunar

Bilateral odynophagia,  
increasing in swallowing,  
irradiated into ears

infiltrated, reddened, enlarged  
tonsils with plaques in  
opening of tonsillar crypts,  
sometime confluent  
(*angina confluens*), not  
spreading to tonsillar pillars,  
fever

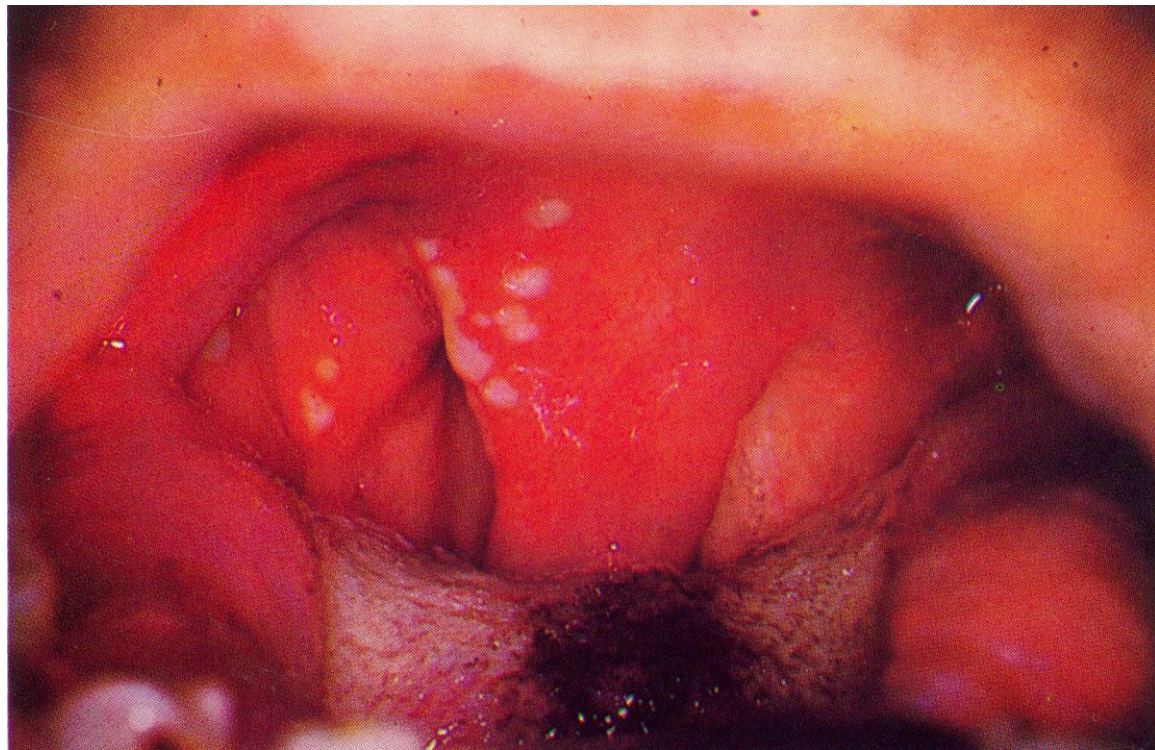


# Herpangina (angina vesiculosa) - Coxsackie virus

---

Marked generalized symptoms, such as high fever, headache, pains in the neck, loss of appetite, stomatitis, vomiting

Vesicles form initially, particularly on the anterior faucial pillar, than small flat ulceration covered in milky white plaques,





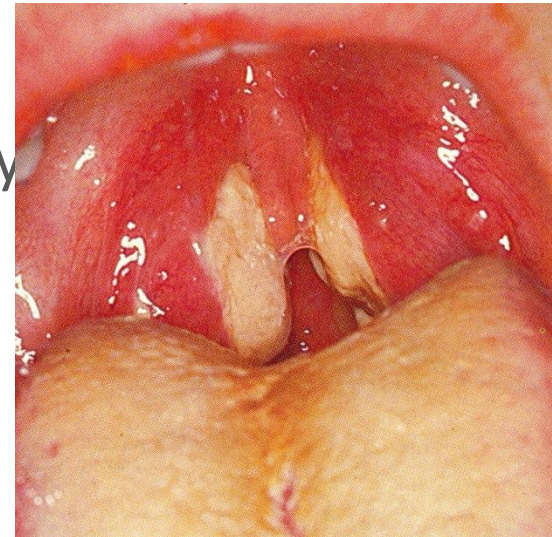
# Pseudomembranous tonsillitis (mononucleosis infectiosa)

Epstein-Barr virus's

Bilateral odynophagia, headache

fever 38-39, marked lymphadenopathy, tonsil is swollen, covered with a fibrinous exudate or membrane, hepatosplenomegaly, marked feeling of being unwell, leukocytosis, mononuclear cells and atypical lymphocytes

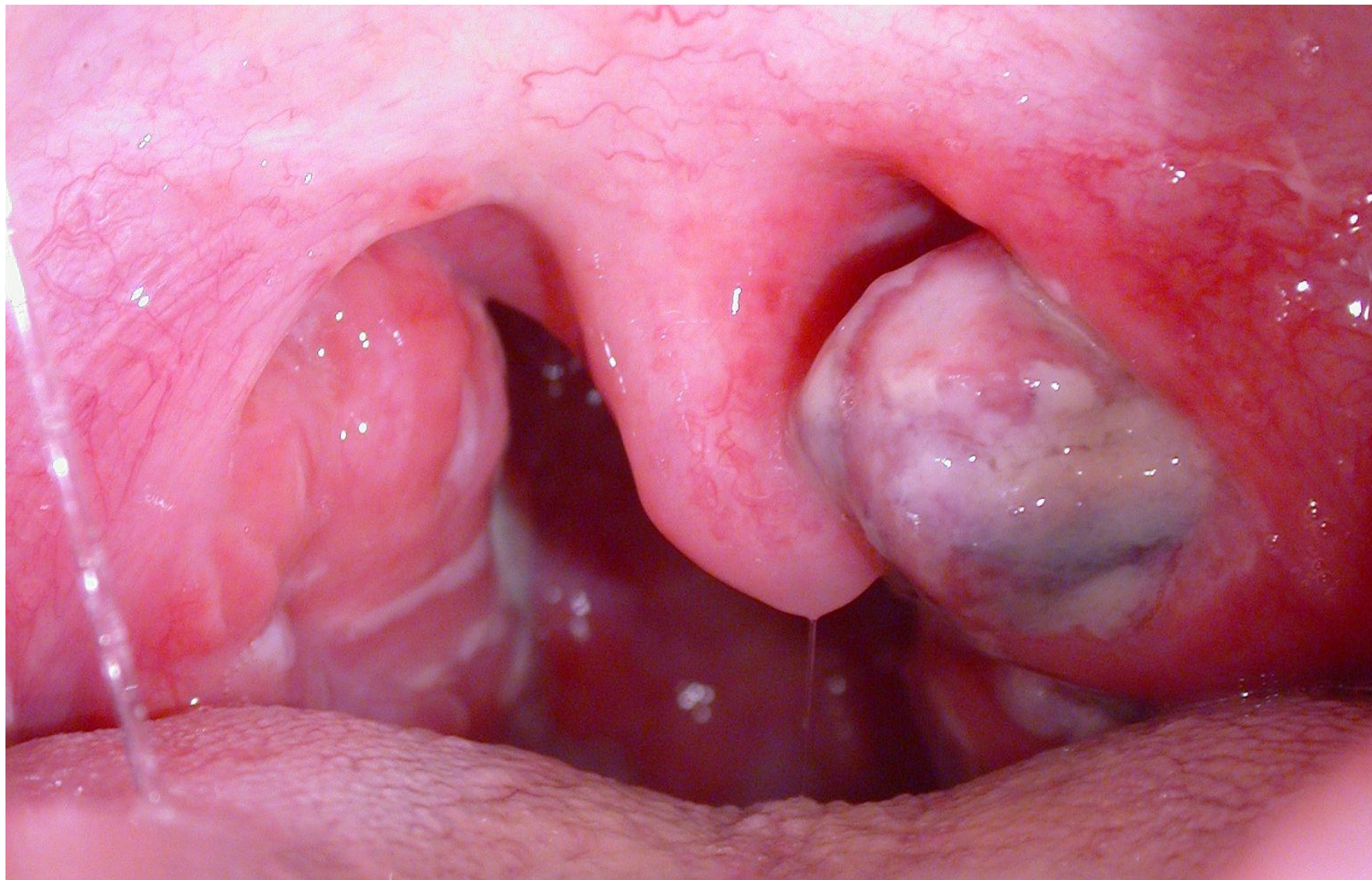Higher transaminases (ALT, AST), positive antibody against EB virus and positive Paul-Bunnell reaction.





# Pseudomembranous tonsillitis

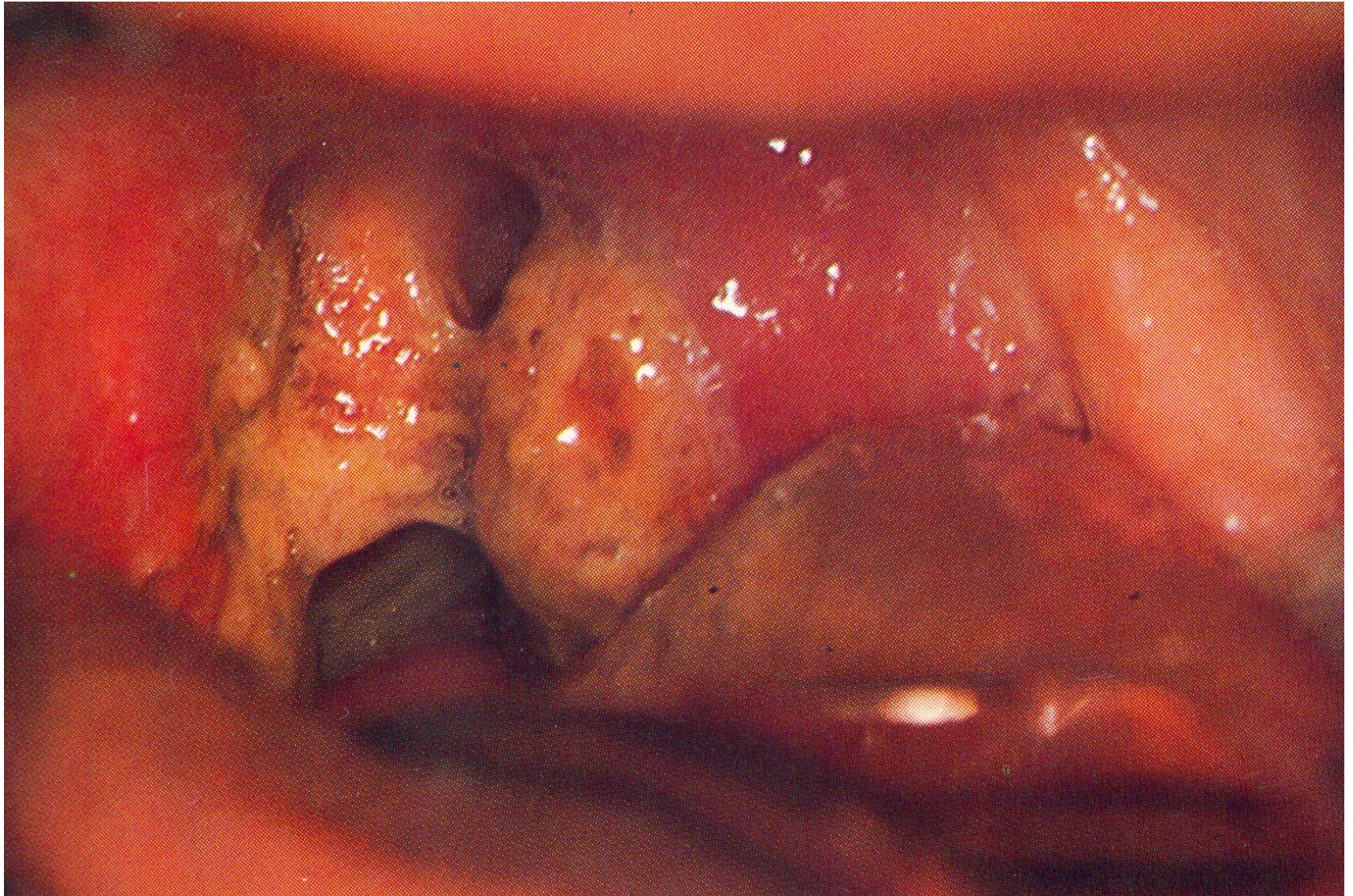
---





# Pseudomembranous tonsillitis

---







# Tonsillitis ac. retronasal

---

Pain experienced in depth behind the nose, blocked nose, running nose

Closed mumbling, hearing disorder (bad function of Eustachian tube), pus in posterior wall of oropharynx



# Tonsillitis ac. of the tongue

---

odynophagy increasing with movement of tongue  
in laryngeal mirror- the finding as in tonsillitis ac.  
lacunaris

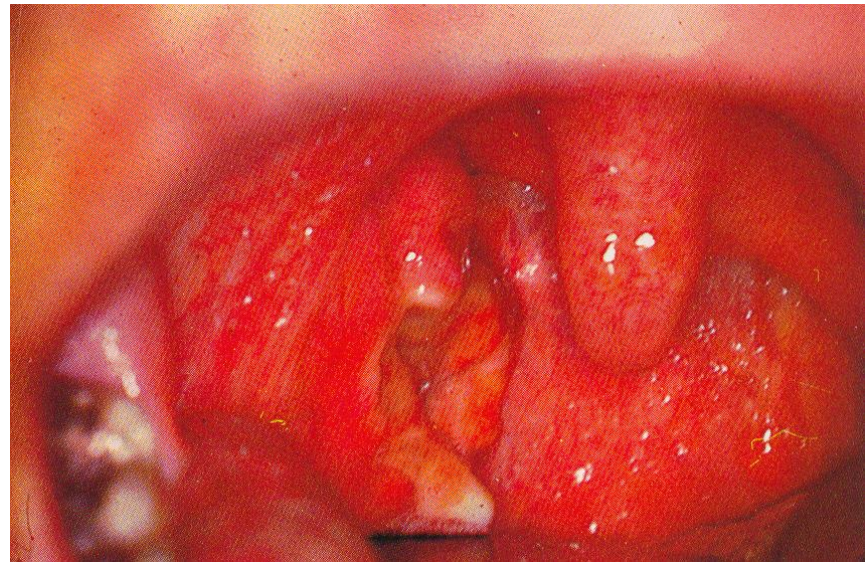


# Plaut-Vincent angina (ulceromembranous pharyngitis)

feeling of foreign body, scratching, no general symptoms

in superior pole of one tonsil  
ulceration with fibrin  
coatings, halitosis (foetor  
ex ore), bad teeth.

Bacteriology: *Bacillus  
fusiformis* and *Spirocheta  
buccalis*,



# Syphilis, Lues

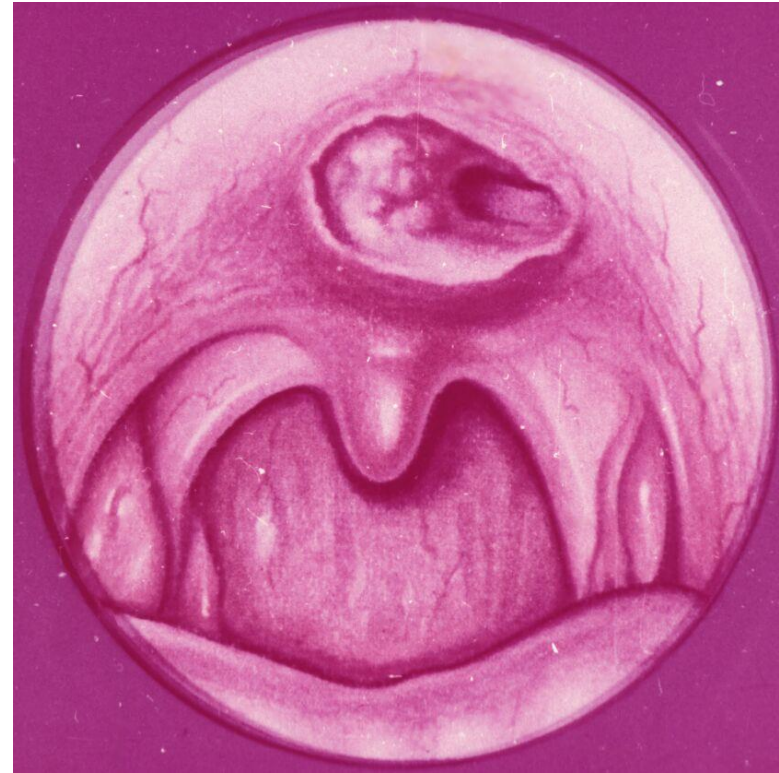---

*primary ulcer* gray coated

*syphilitic angina* mucous plaques or hazy, smoke-colored mucosal lesions

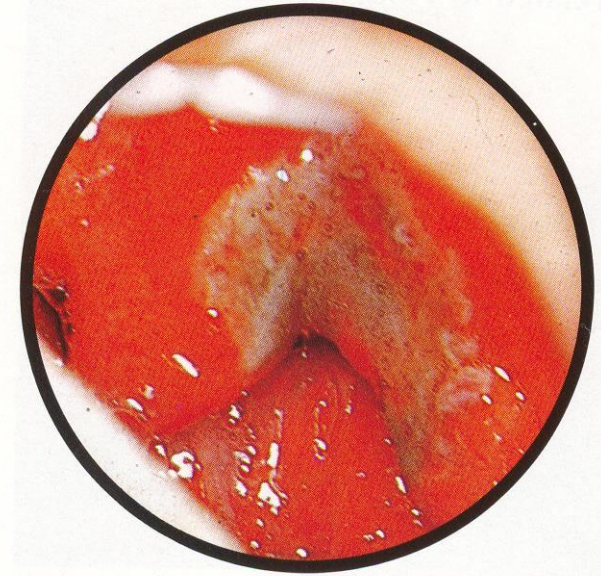*gummose stage* swelling with ulceration

typical bacteriology, serology and histology evaluation

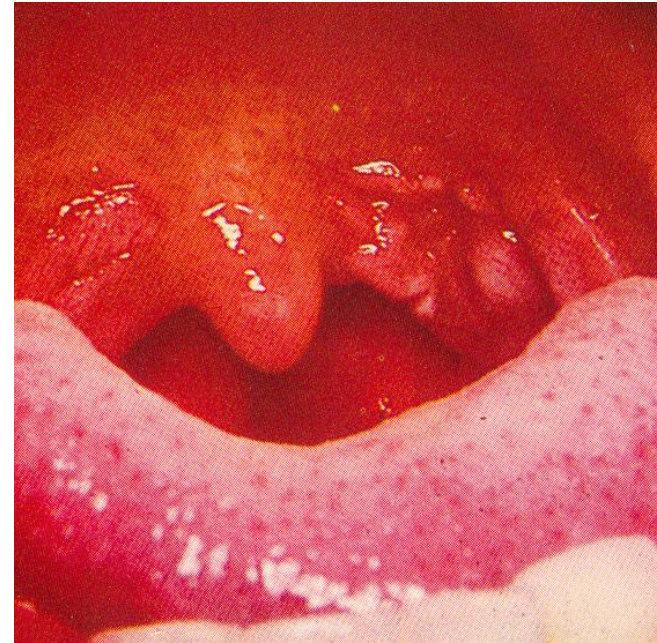



*primary ulcer* on soft palate in 21 old male



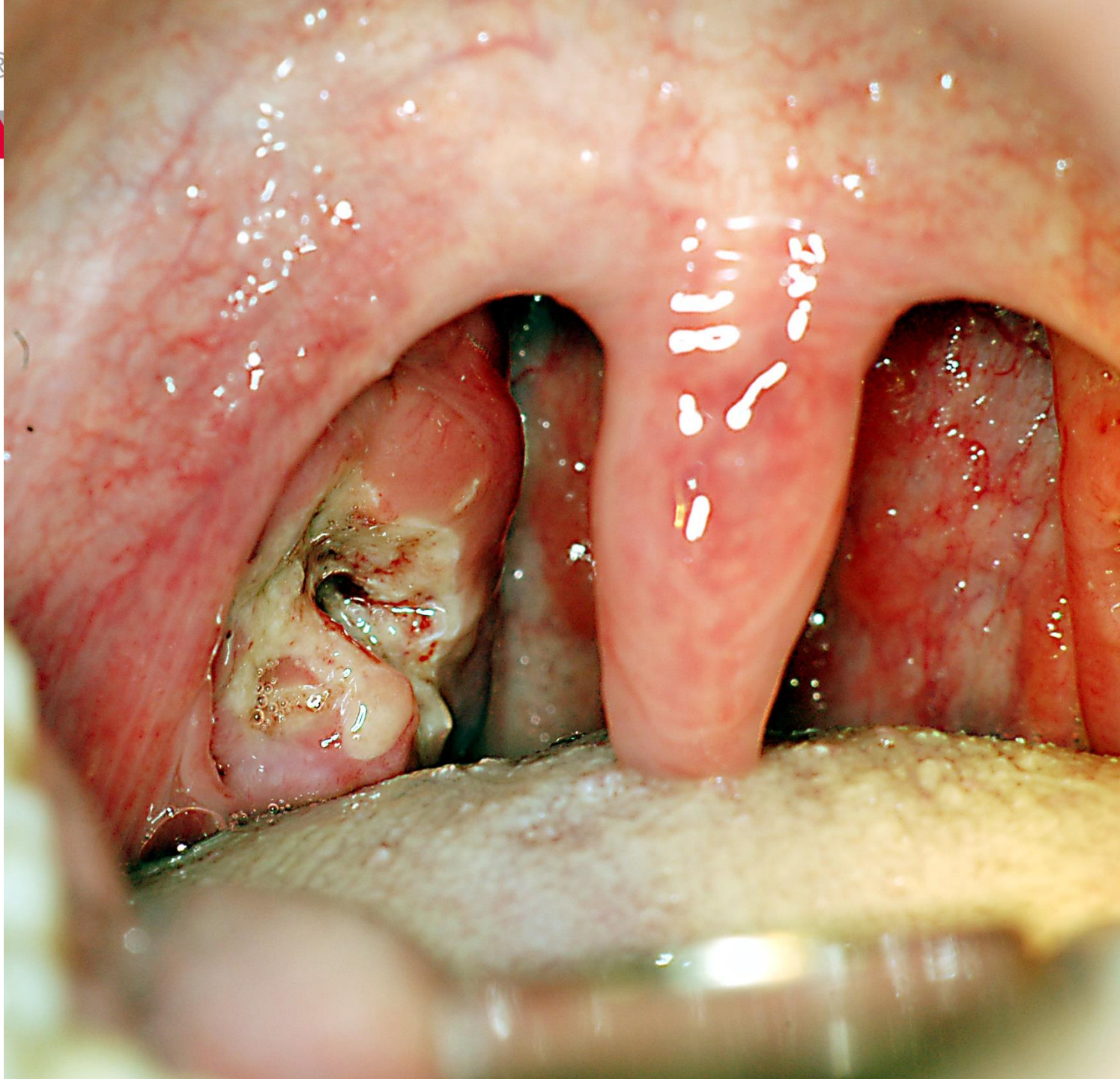*syphilitic angina* mucous plaques



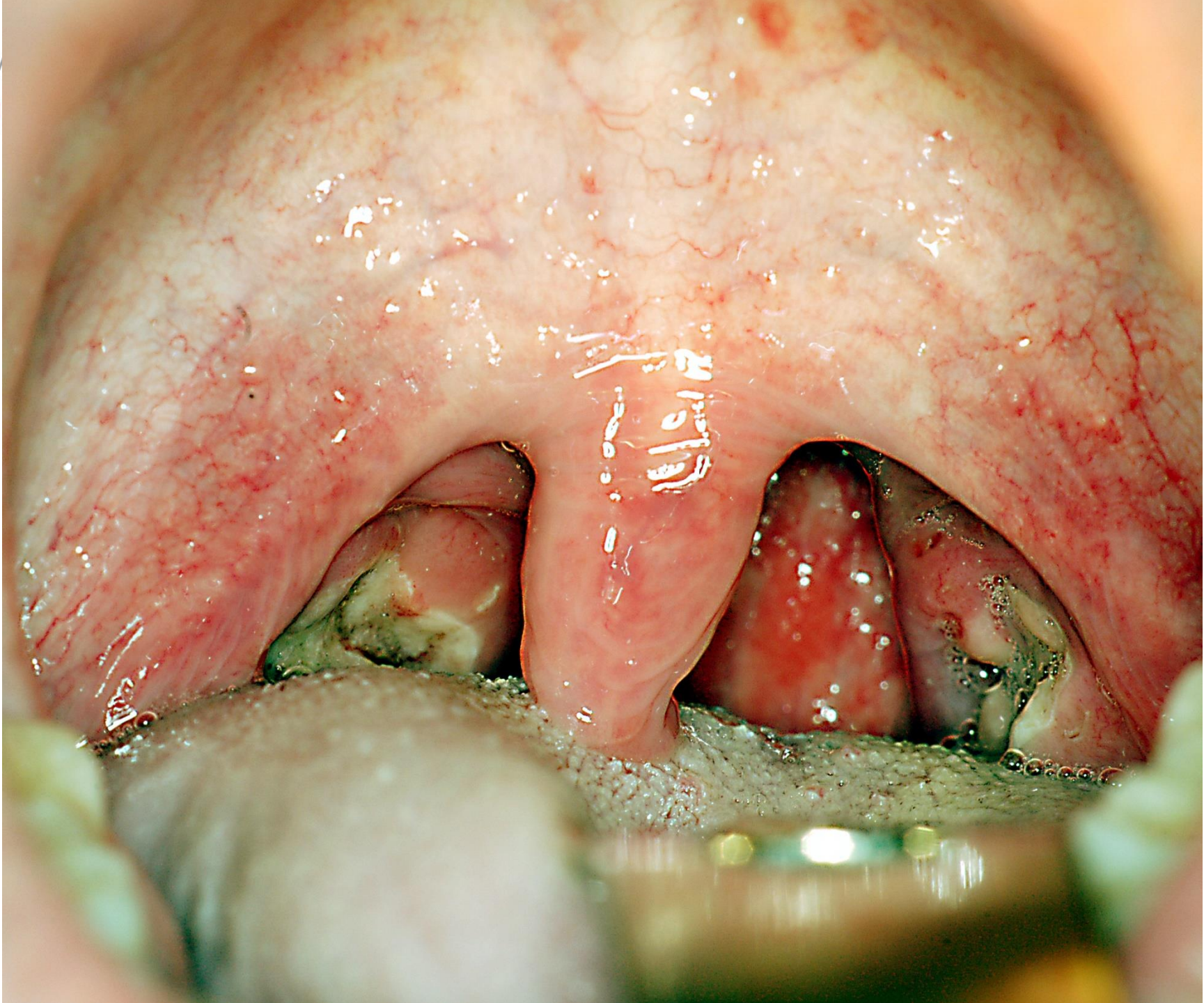

**Syphilis II.  
st.  
oropharynx  
male  
29 let**

**cook in public  
catering**







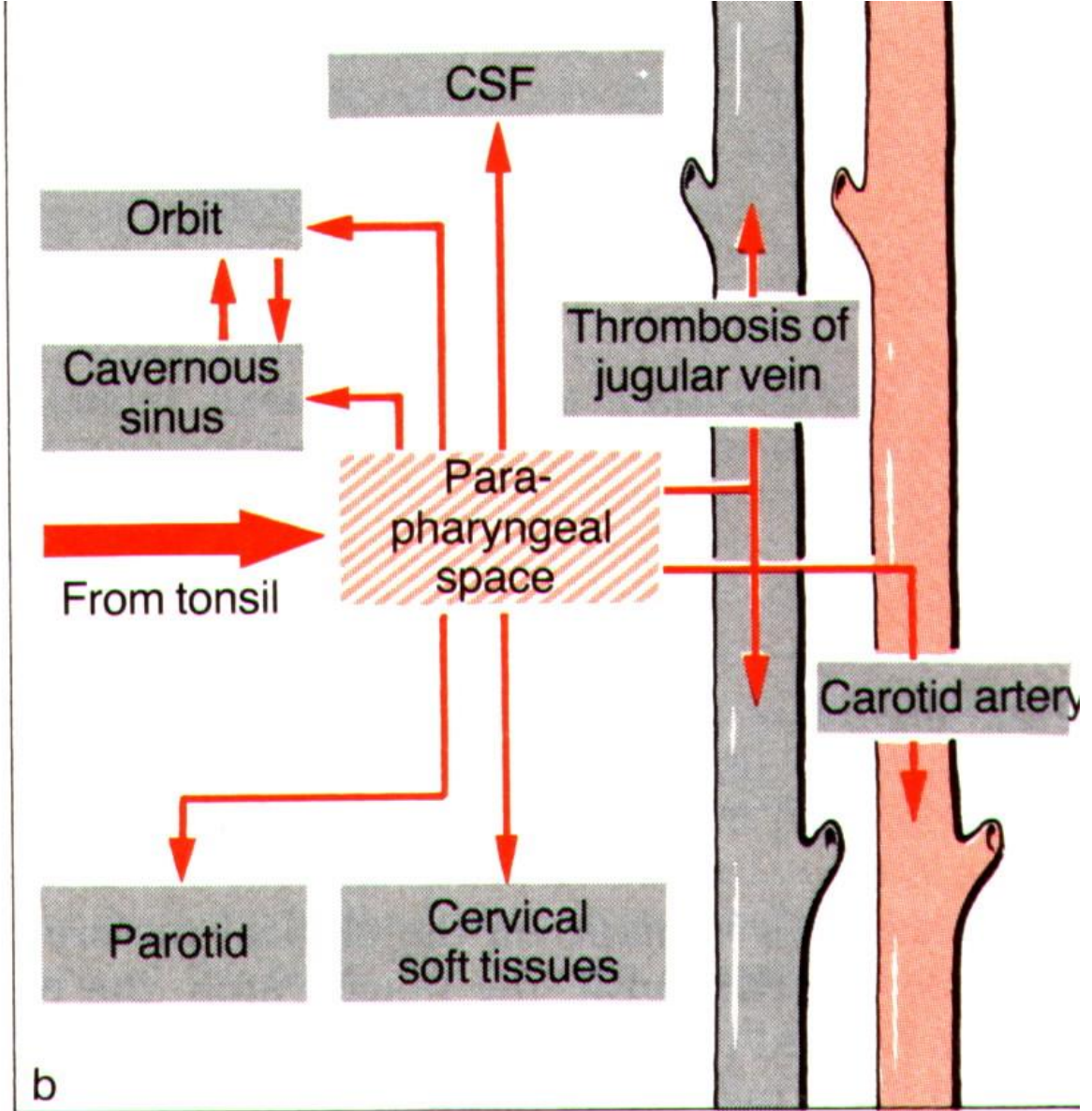
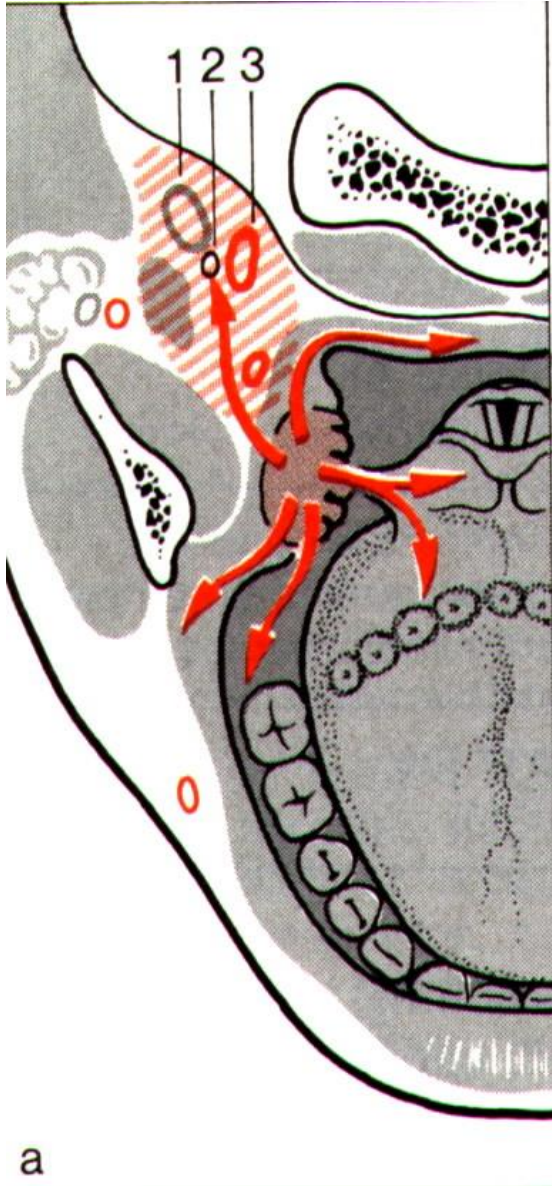


# Serious complications of inflammatory disease of tonsils

- „Internal“
  - febris rheumatica, sterile consequences of streptococcal infection, autoimmunity
  - Sepsis tonsillogenes (angina septica, sepsis post anginam, trombophlebitis v. jug. int.)
- „Surgical“
  - Abscessus et phlegmona peritonsillaris
  - Abscessus et phlegmona parapharyngealis
  - „Deep inflammation of neck soft tissues“, Phlegmona colli



# Complications during and after tonsillitis





# Phlegmona et abscessus peritonsillaris

---

**Localization:** supratonsillar, retrotonsillar, infratonsillar, lateral

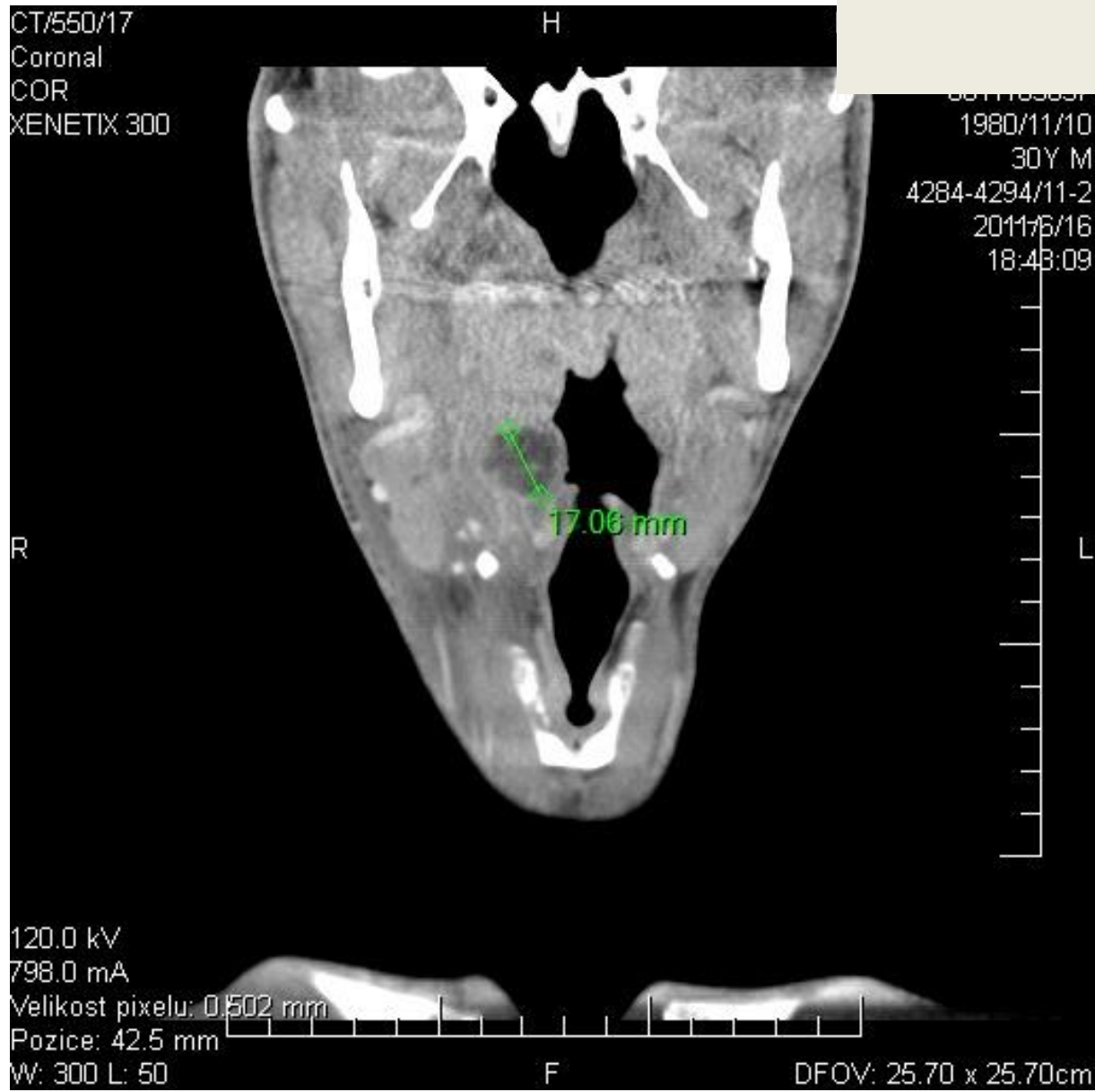
**Symptoms:**

- Increasing difficulty in swallowing occurs after a symptom free interval of a few days after tonsillitis
- Fever not too high
- Severe pain on diseased side, spreading to the ear, patient refuses to eat,

**Differential diagnosis:** tonsilogenic sepsis, dentitio diffitilis tertii molaris inferioris

**Treatment:** abscess drainage - puncture, incision, dilatation, antibiotics

# Abscessus infratonsillaris





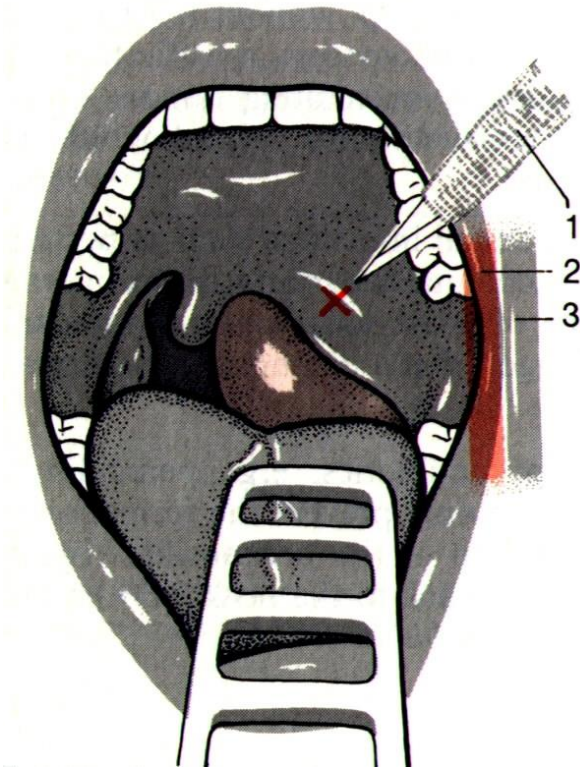
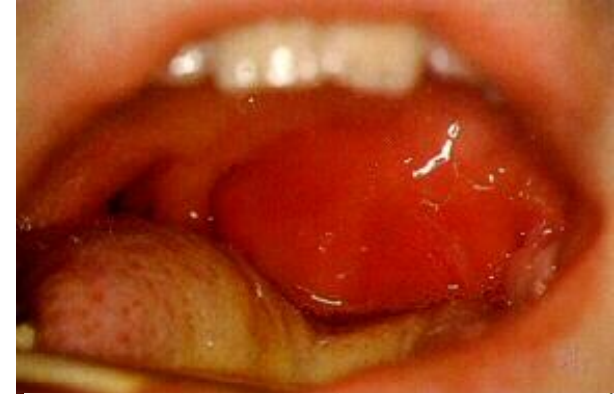
# Peritonsillar phlegmona and abscess

Clinical picture of swelling, redness and protrusion of the tonsil, faucial pillar, the palate and the uvula, marked tenderness of the tonsillar area, trismus

Typical side for incision:

**X midpoint between the uvula and the last molar**

- 2) Arteria carotis interna
- 3) Vena jugularis int.

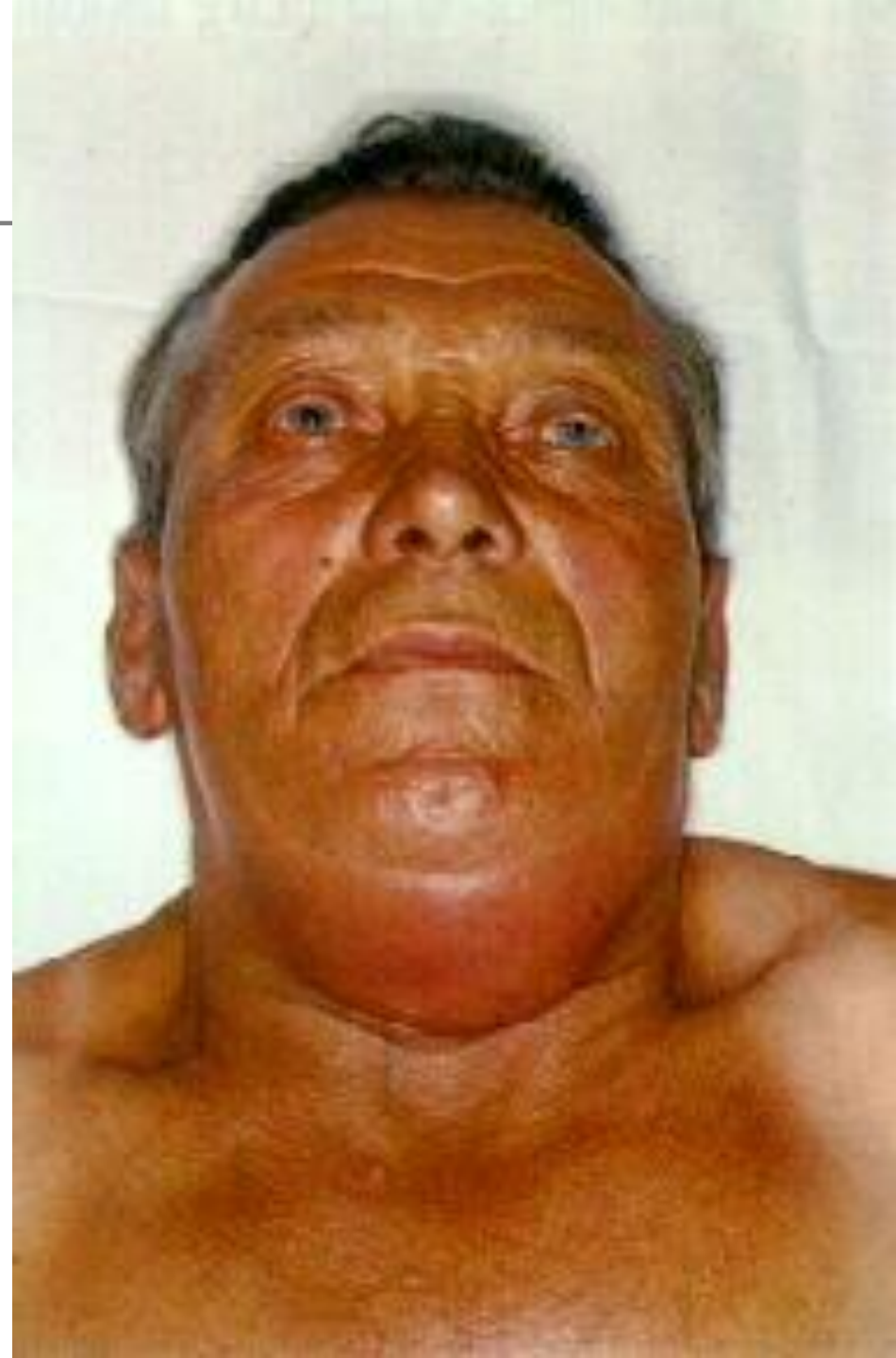

# Phlegmon base of the oral cavity

## „Angina Ludowici“

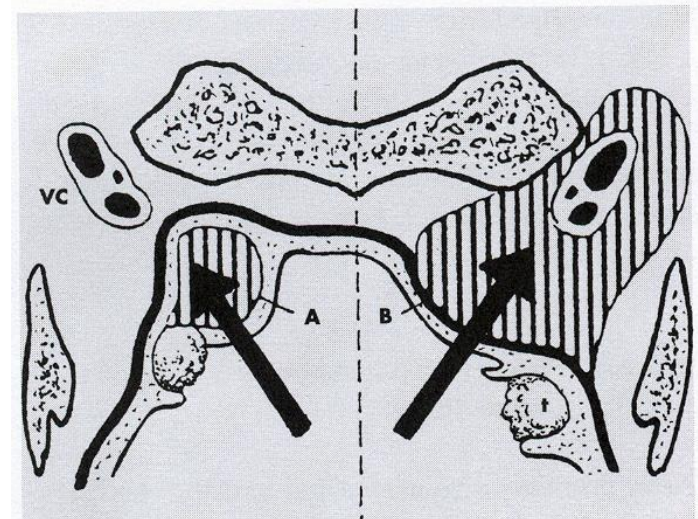
tongue pain, odynophagy,  
fever with shivering fit,  
symptoms of sepsis

elevation of base of oral cavity,  
tongue not moving, infiltration  
in submandibular region



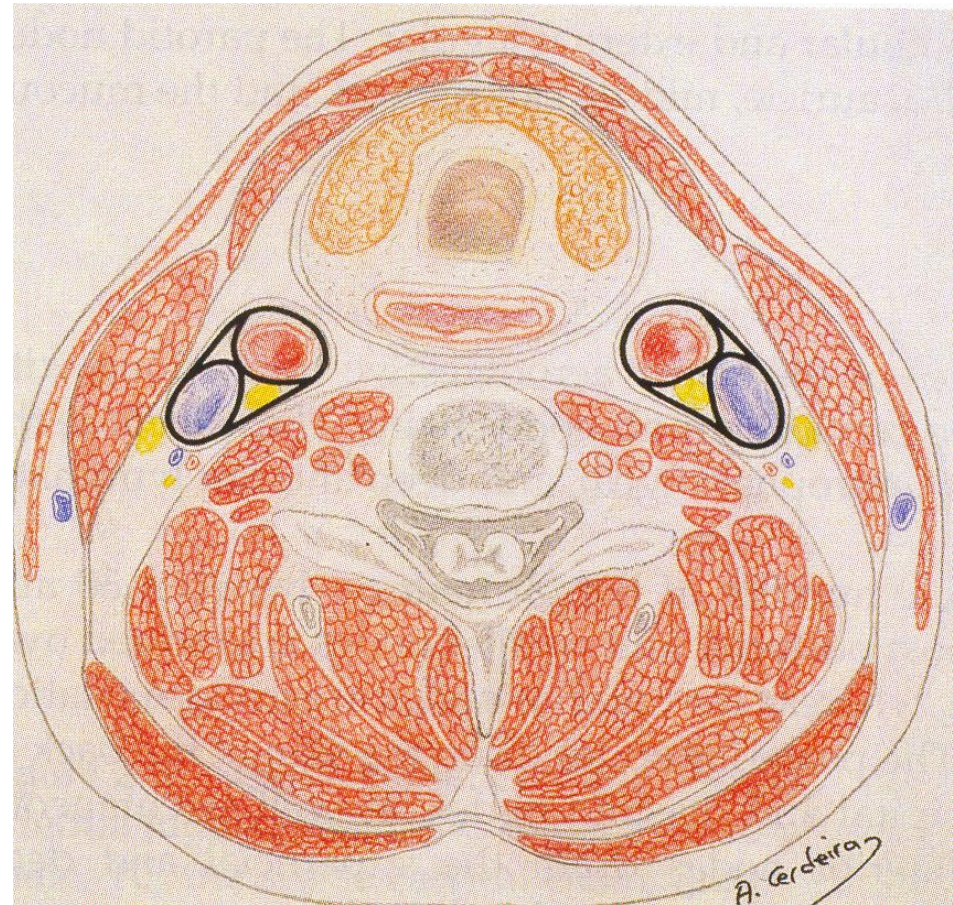
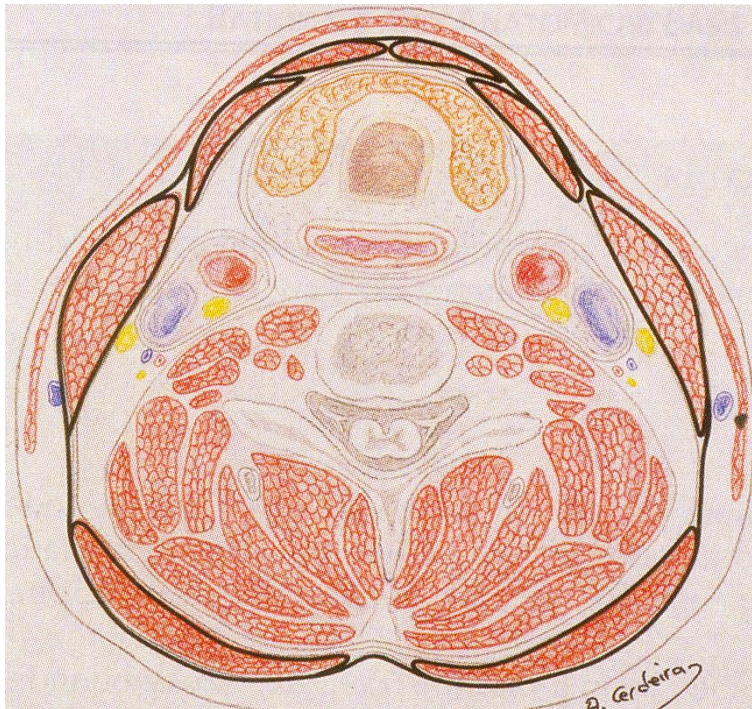
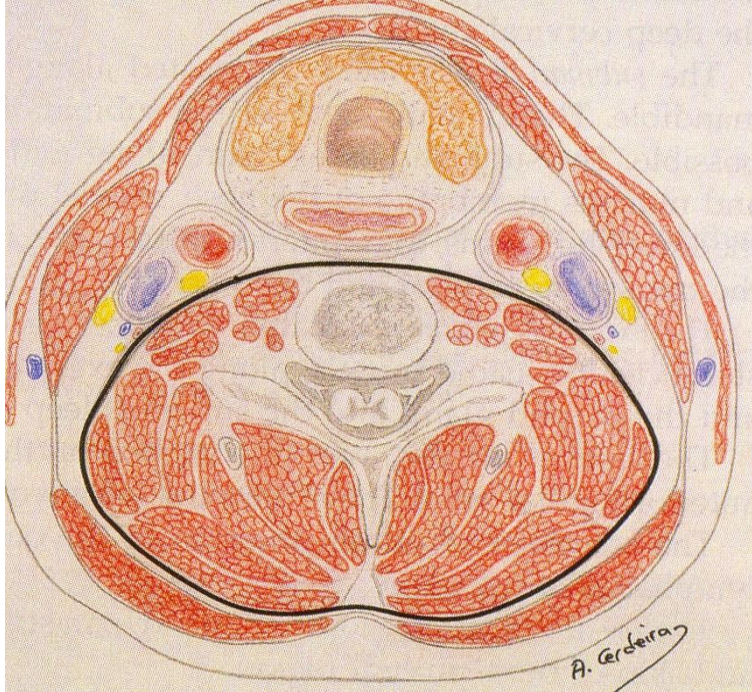
# Phlegmon and abscess parapharyngeal

- Spreading infection from tonsils into the parapharyngeal space, borderline – the wall of pharynx
- **Symptoms:** Fever, pain, trismus, torticollis, swelling of external neck, swallowing of hypopharynx
- **Risk** of infection spreading into the mediastinum
- **Treatment:** incision, drainage of infection focuses, antibiotics – broad spectrum in sufficient dosage, external approach

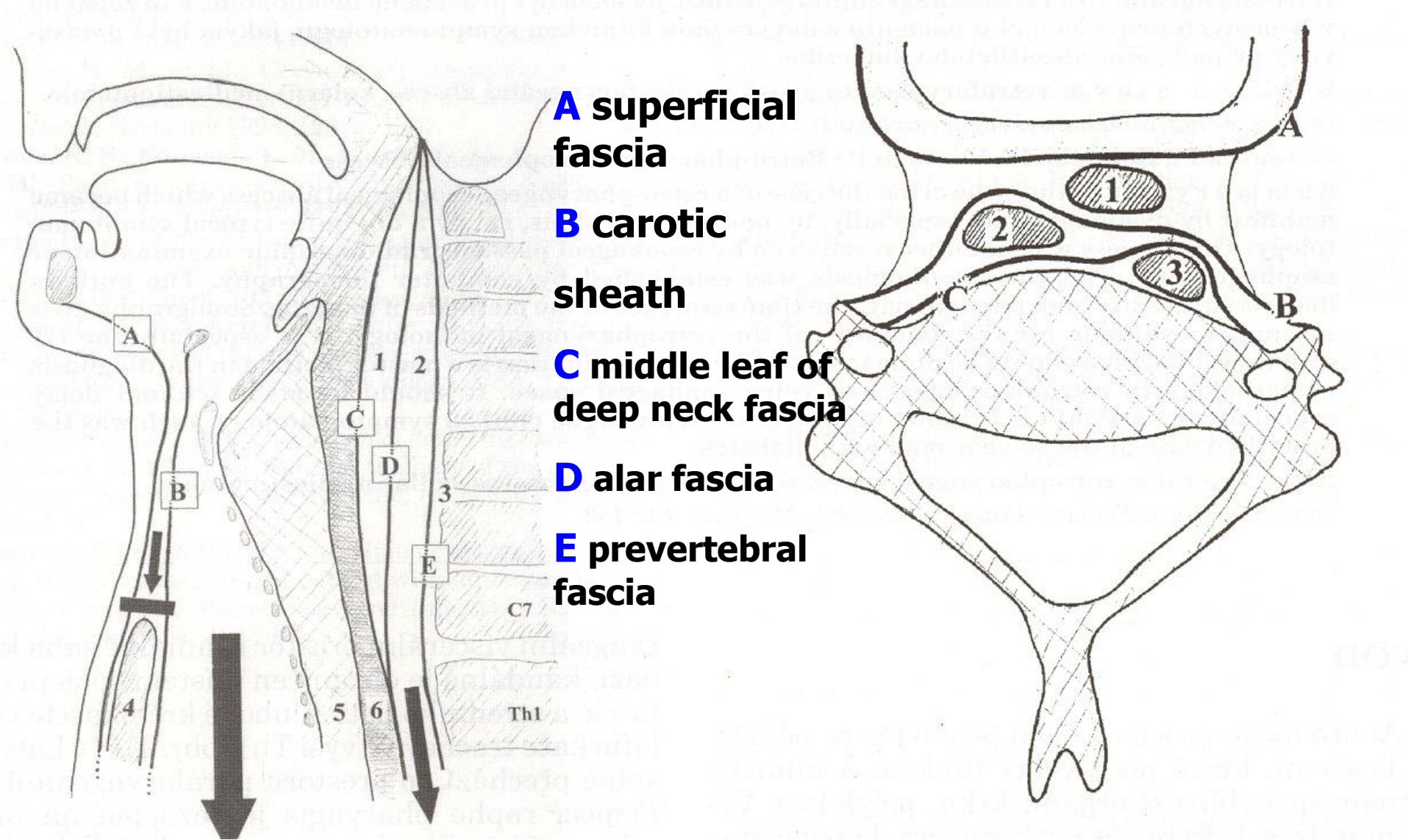




# Carotid sheath between deep and superficial cervical fascia



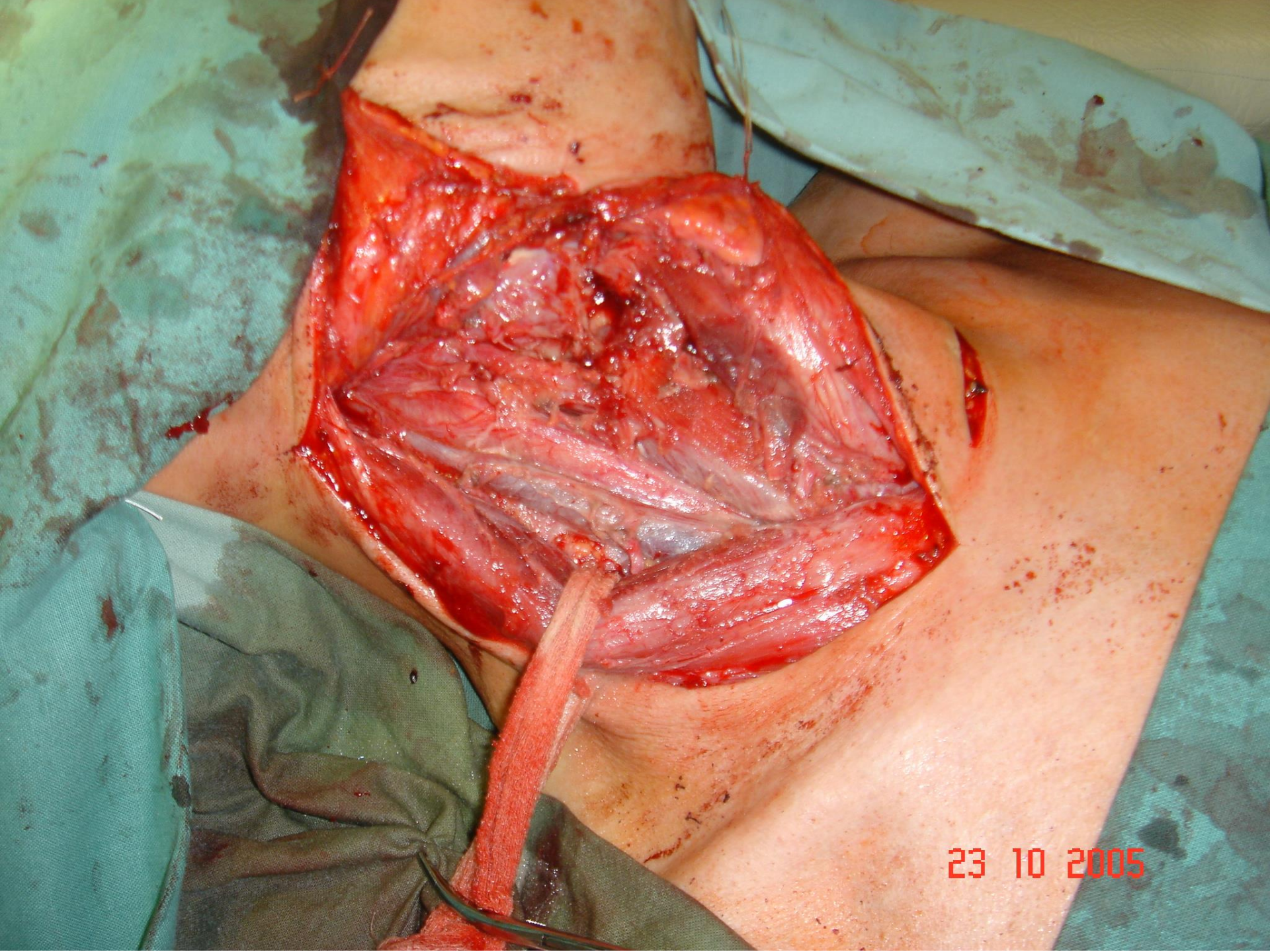






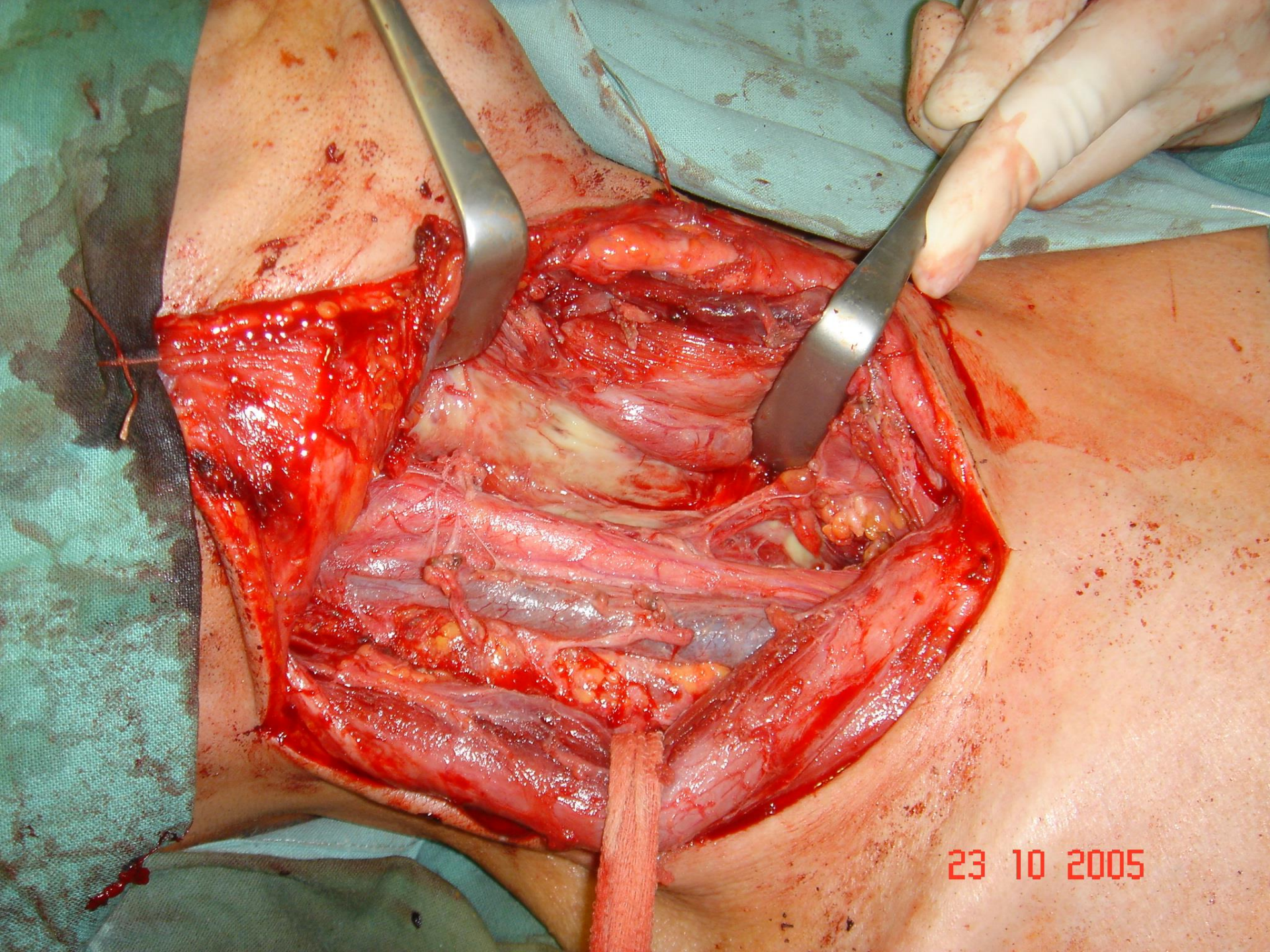
- Source: odontogeneses origin, infection of paratonsillar and retromolar region, injury of oral cavity base, pharynx or cervical esophagus.
- Visceral spaces of the neck have no distal boundary with mediastinum.
- **Clinical picture** – fever, usually septic, dysphagia, pain in the neck, back (intrascapular), retrosternal pain
- Inflammatory infiltration of the neck without boundary, fluctuation, special palpation feeling; by spread into the mediastinum – dysphagia and even dyspnoe
- **Treatment** – surgical opening of space surrounding great neck vessels, collateral mediastinotomy, treatment of primary source, general treatment aimed against sepsis, thrombosis, kidney failure etc.
- Bad prognosis, high mortality





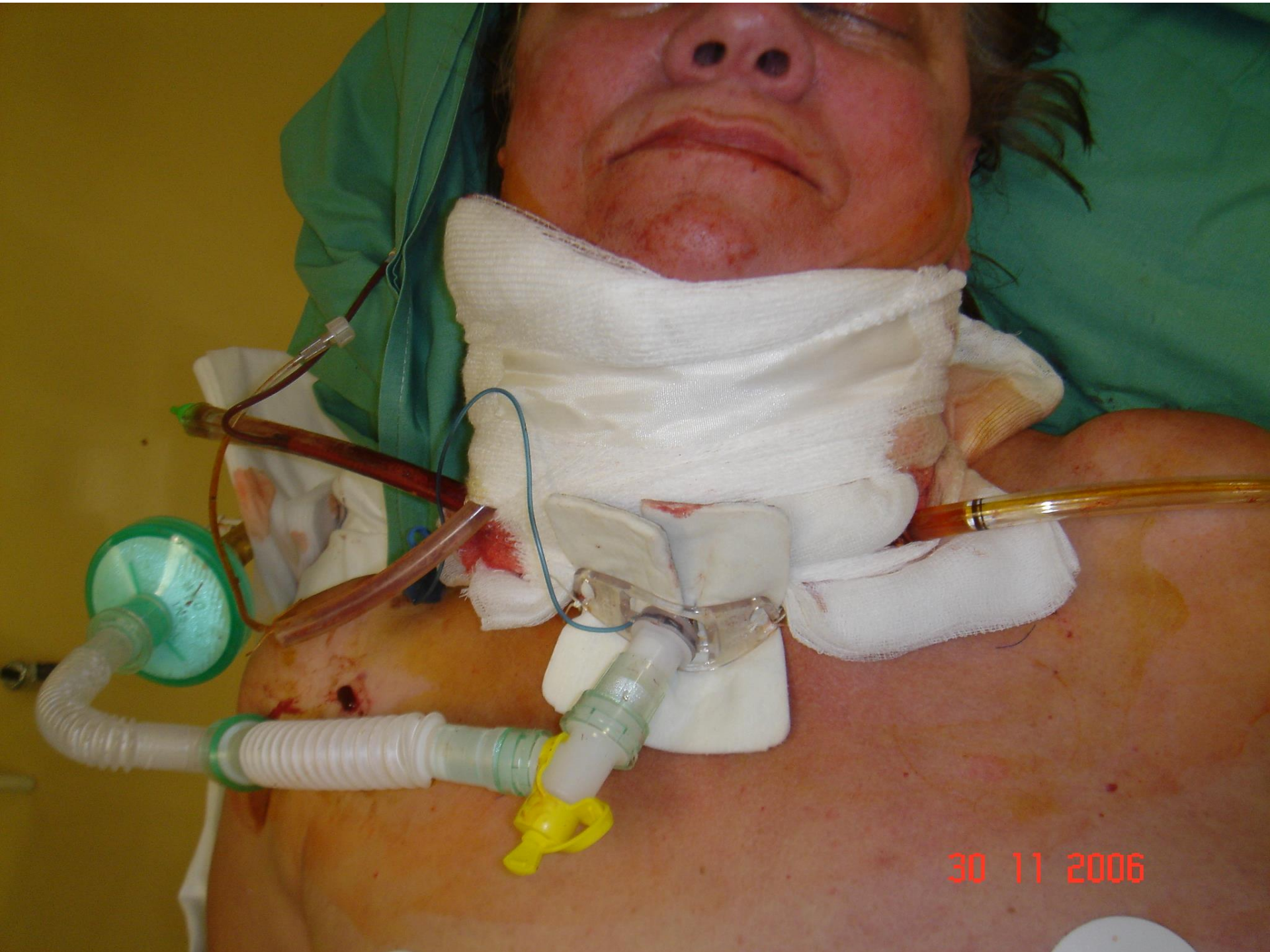23 10 2005





23 10 2005

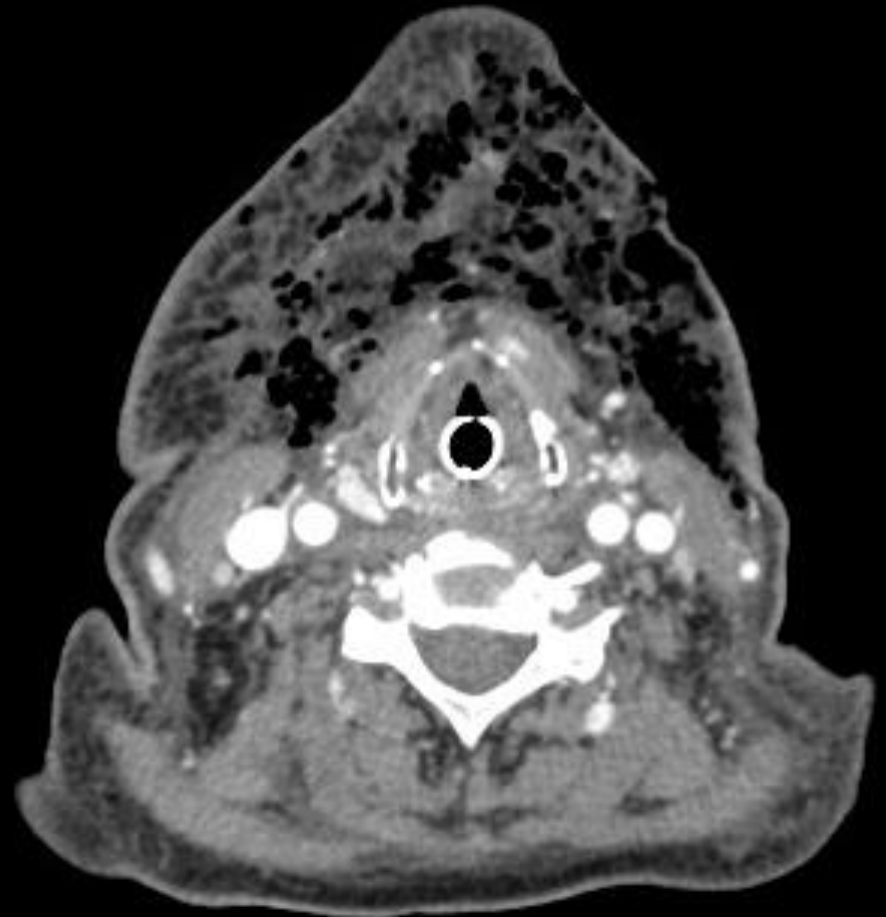
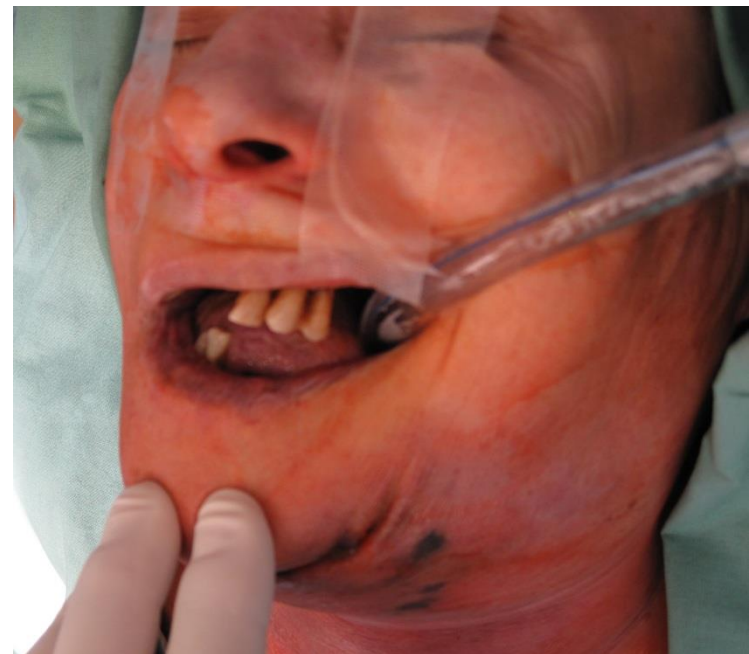
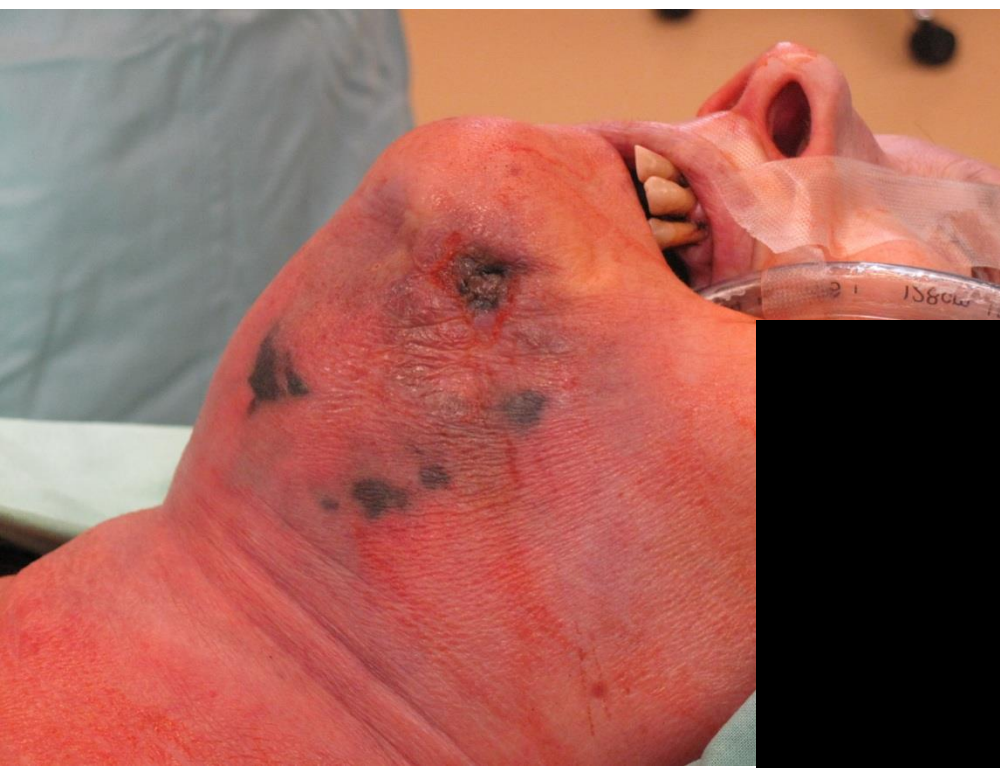


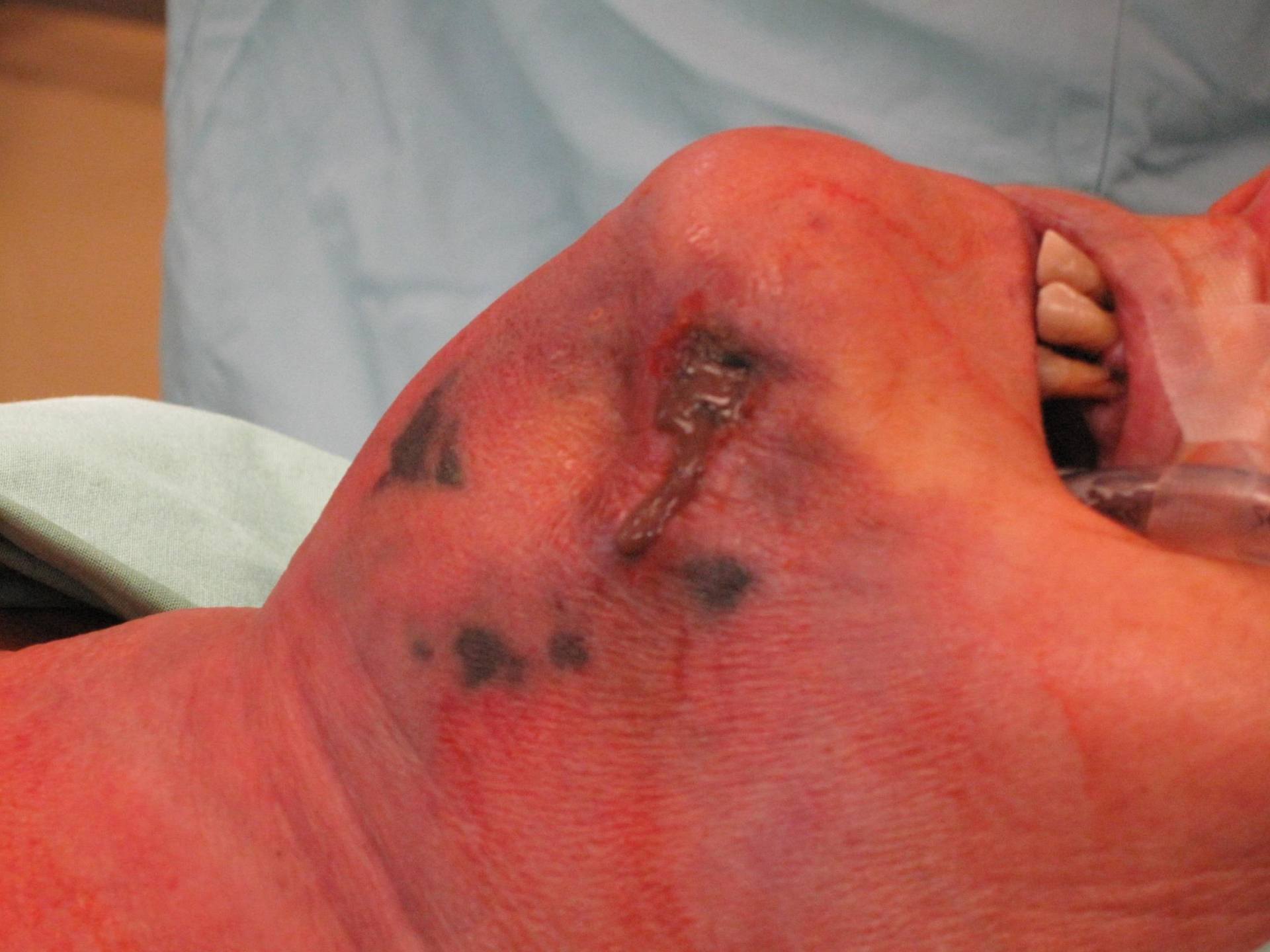30 11 2006



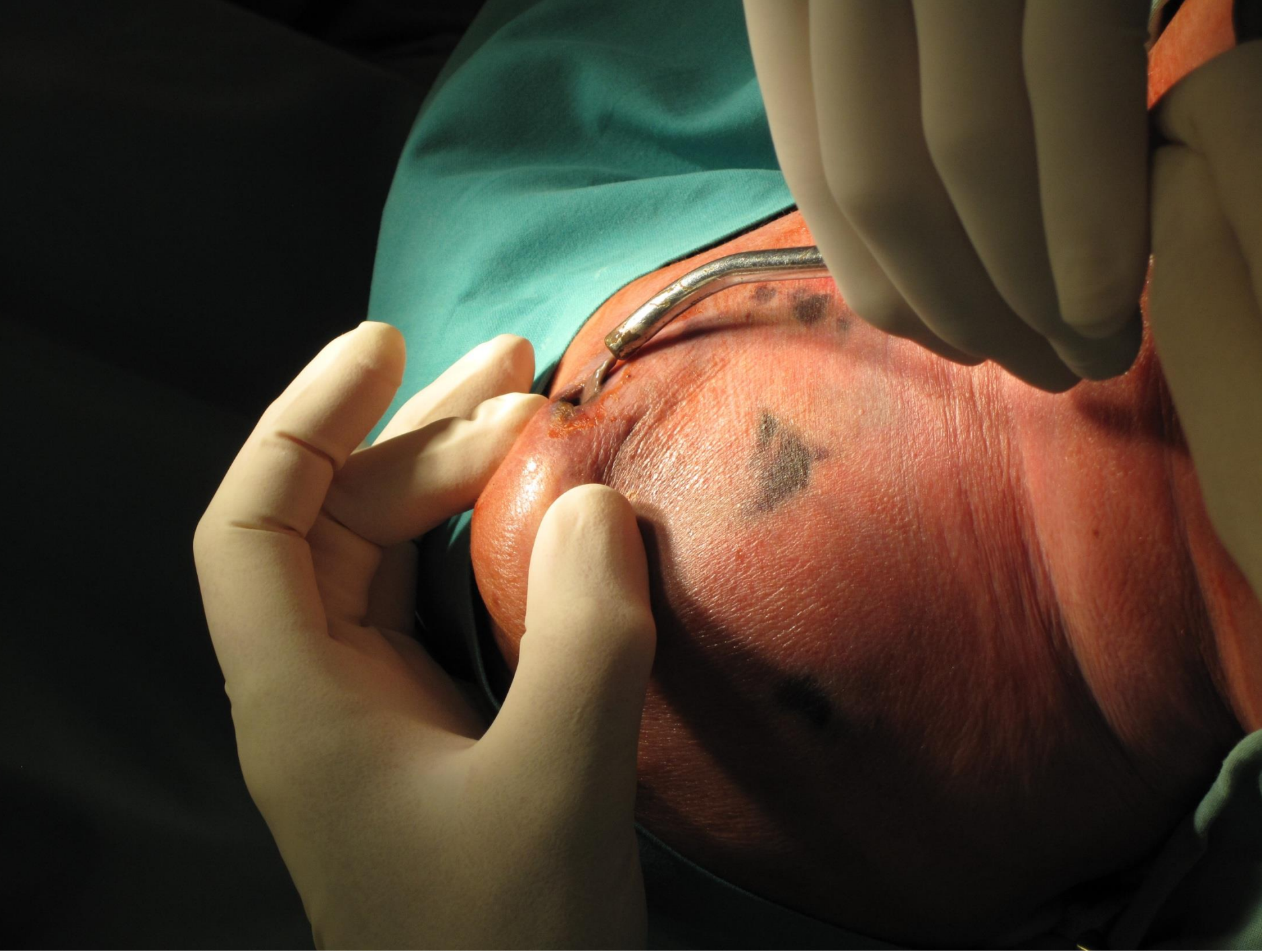**Fasciitis necrotisans,  
60 year female**



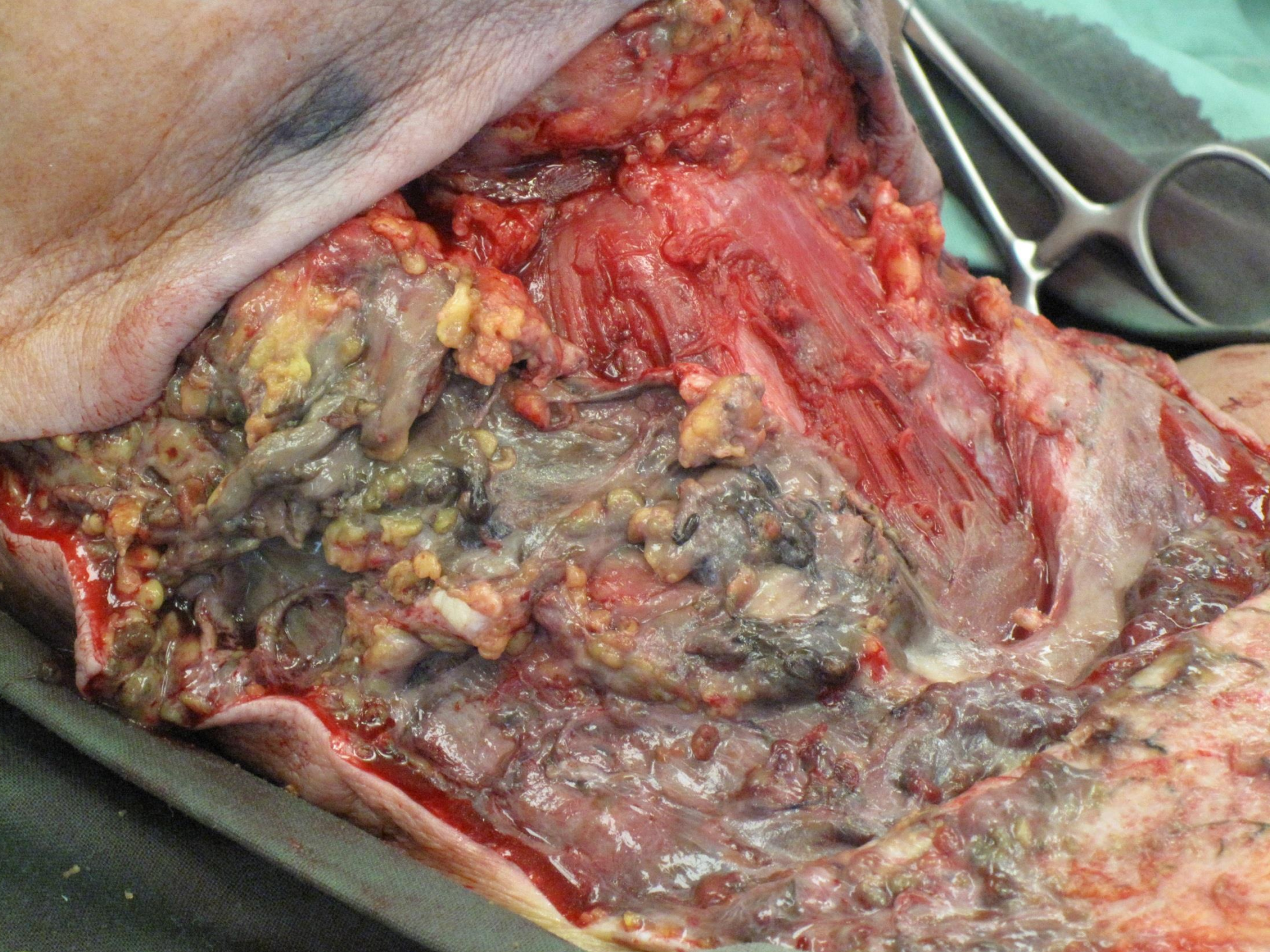



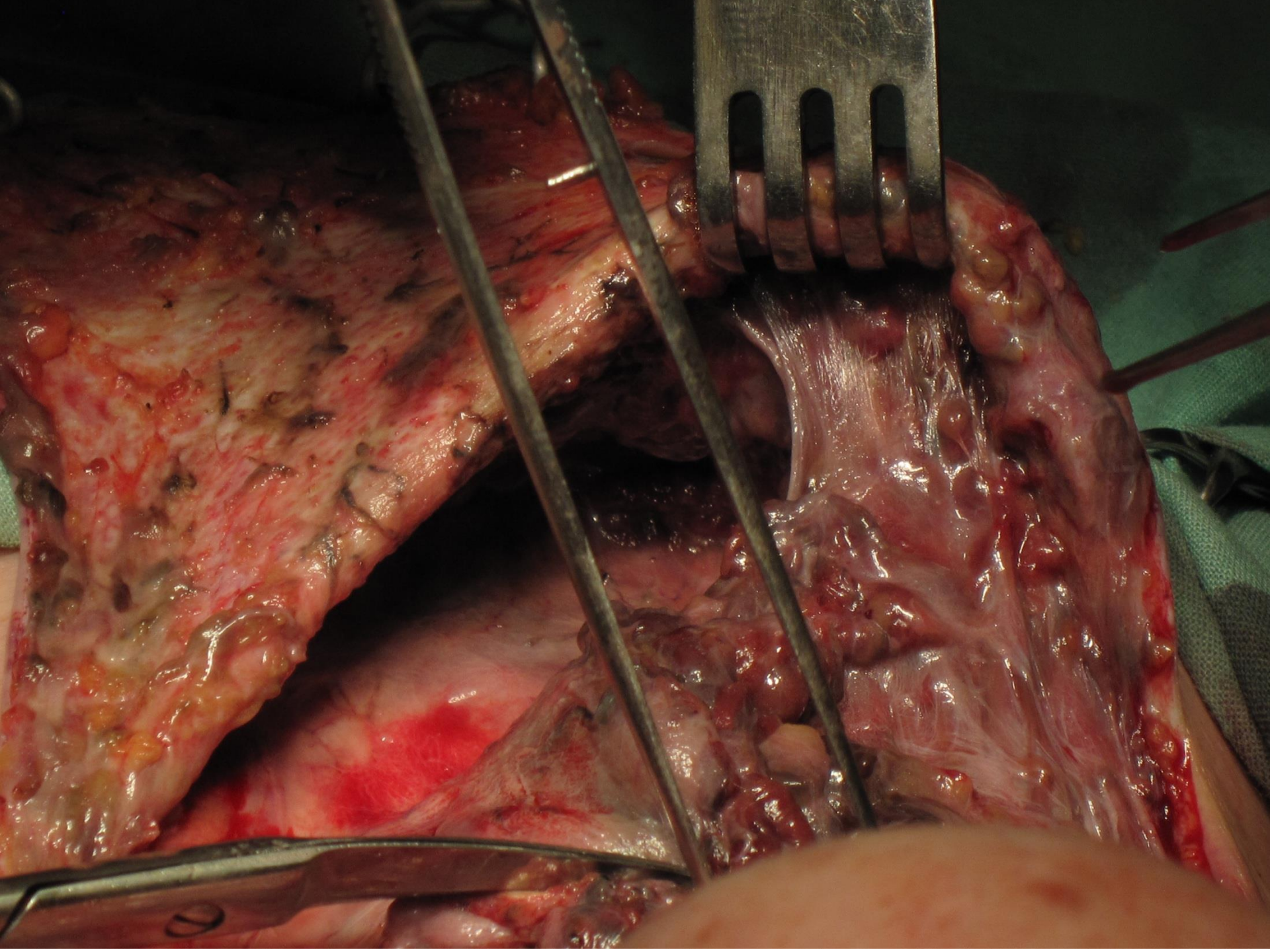




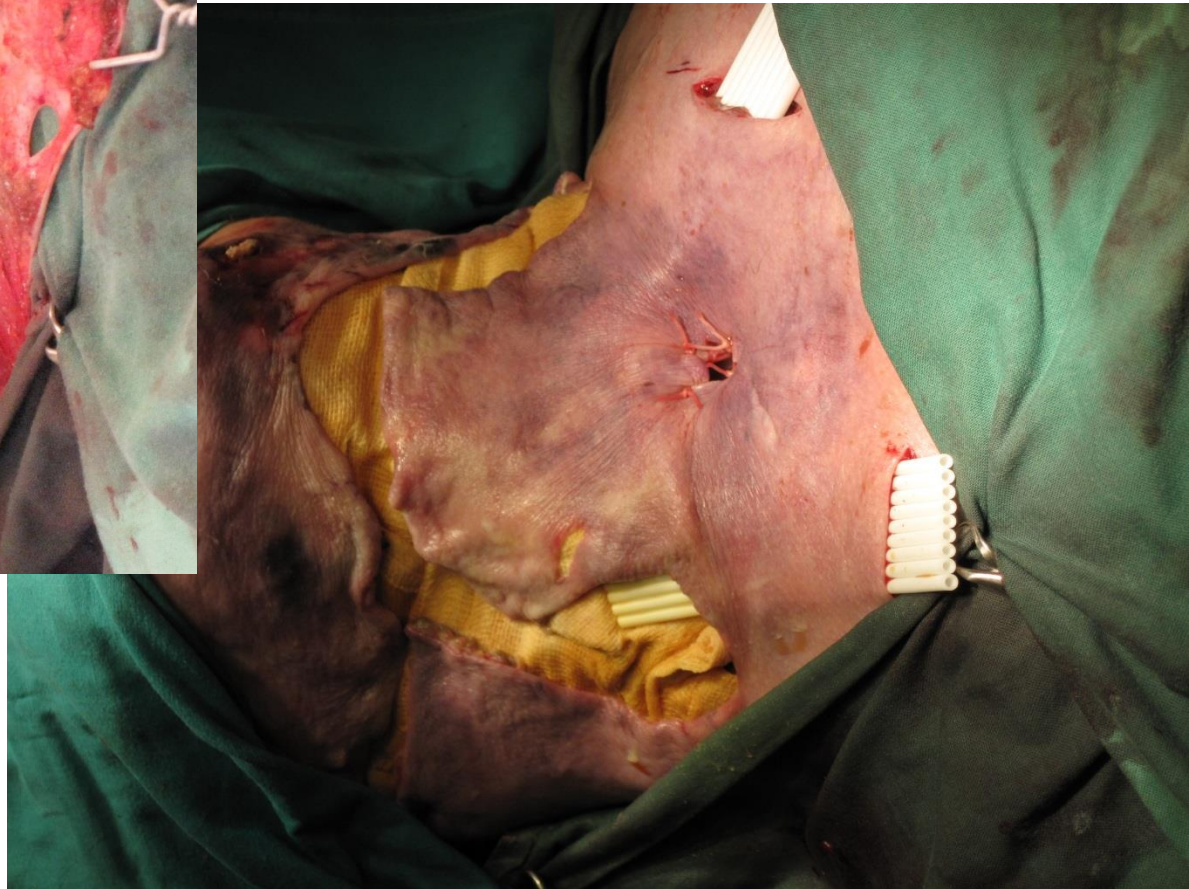
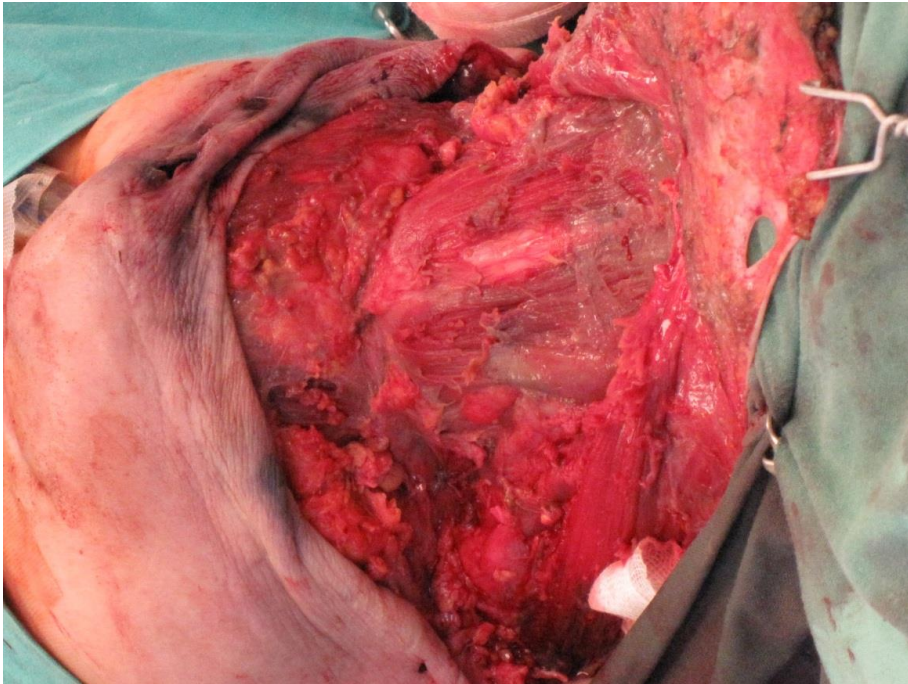










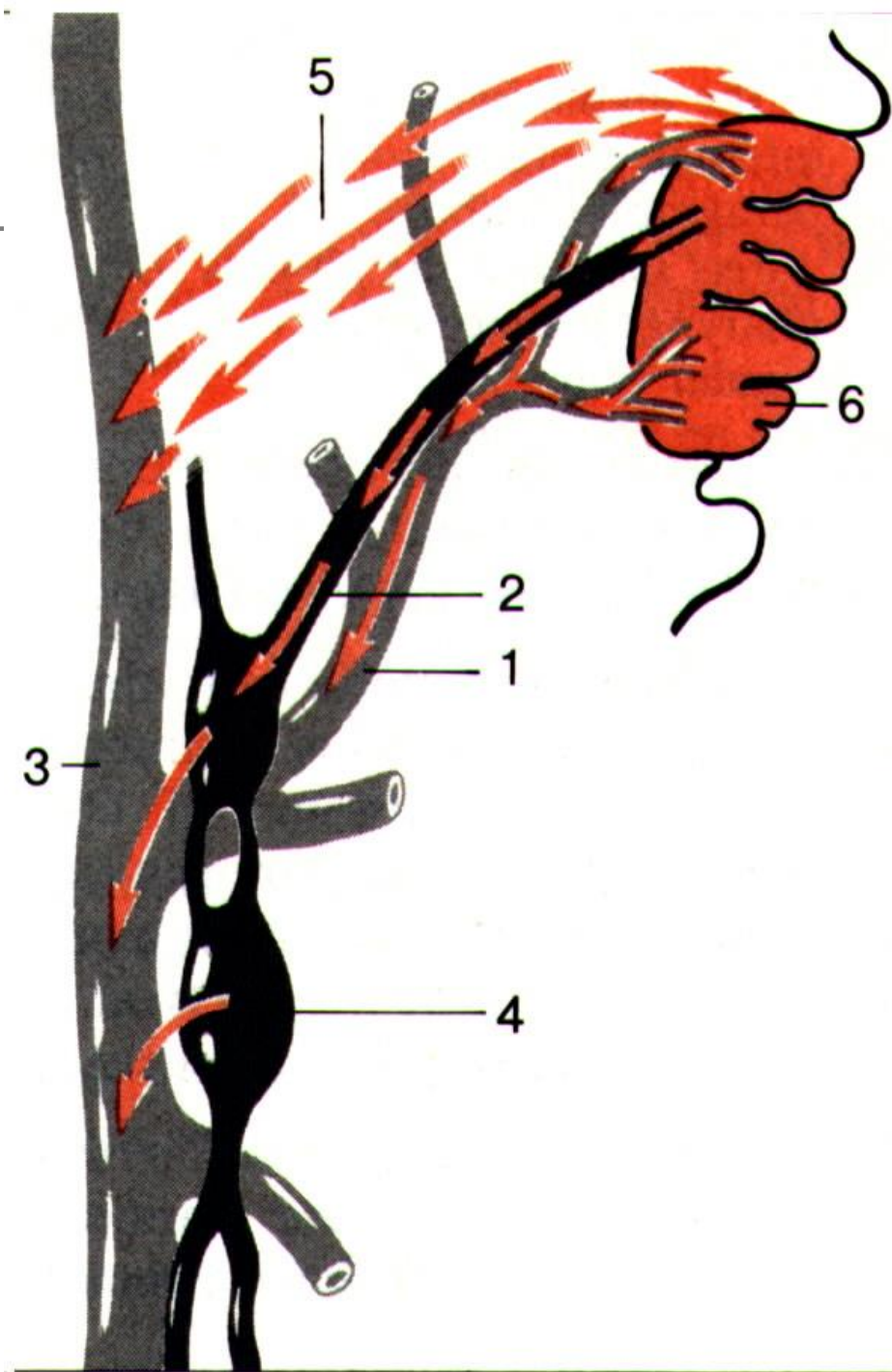


60y female, caries teeth, submandibular fistula and phlegmon of soft tissues of neck and anterior mediastinum, death as consequence of sepsis next day after surgery.



## Genesis of tonsillogenic complications (sepsis)

- 1) Extension through **veins**
- 2) Extension through **lymph vessels**
- 3) Internal jugular vein
- 4) Regional lymph nodes around the VII
- 5) Extension in continuity via the **cervical soft tissue**



# Sepsis tonsillogenes

---

**Angina septica** – thrombophlebitis of small veins occurring during tonsillitis – spreading into internal jugular vein. Symptoms: fever, shivering fit, palpation pain before anterior edge of sternocleidomastoid muscle. Possibility of spreading into the intracranial space.

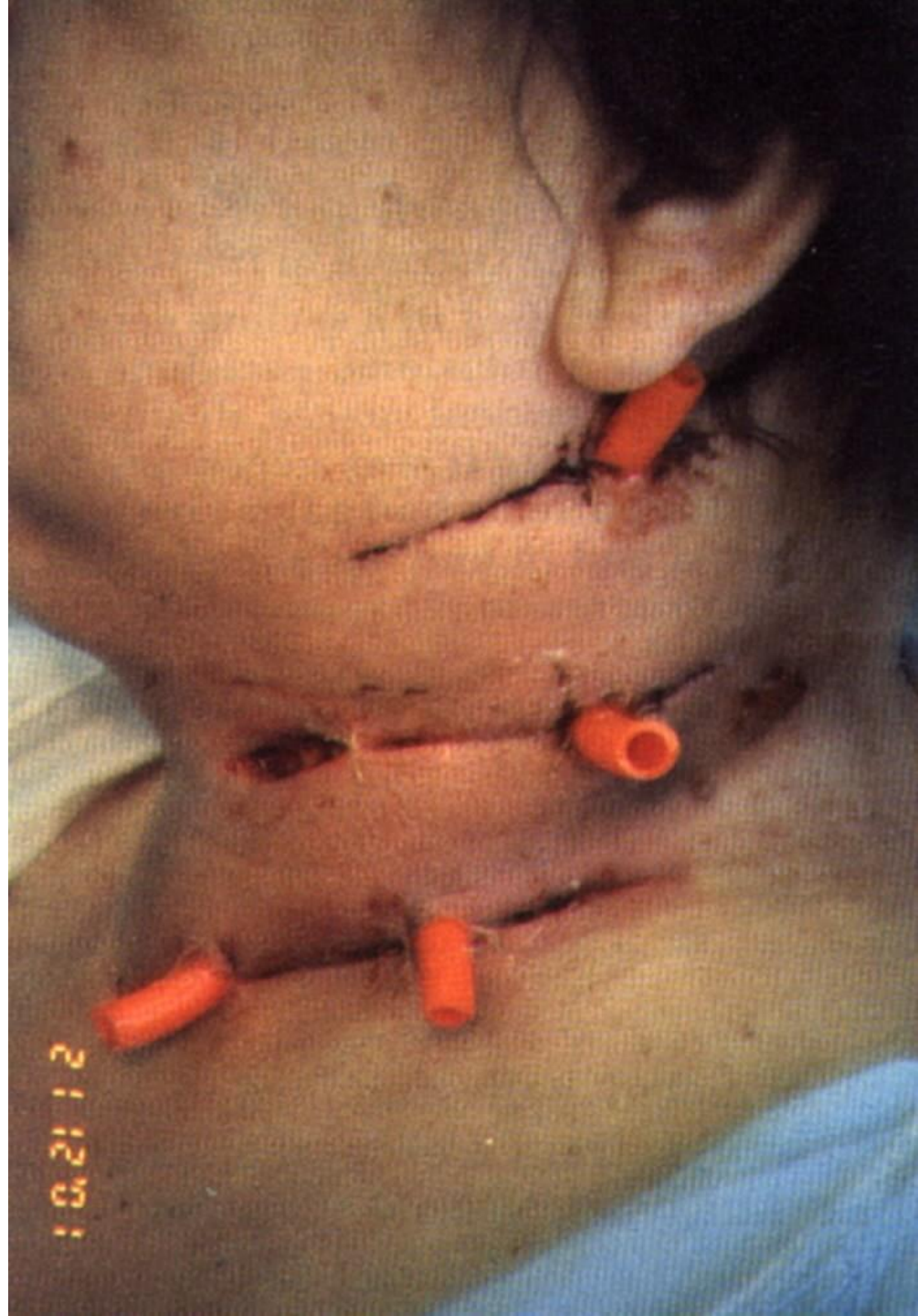
**Sepsis post anginam** – symptoms free interval of a few days after tonsillitis, normal finding on tonsils; Lymphatic way: lymph node – periadnitis -periphlebitis-trombophlebitis VJI

**Thrombophlebitis v. jug. int.** – treatment :surgery, removal of inflam. focus, suture of VJI and resection in extension of thrombosis, antibiotics

## Fasciitis necrotisans

inflammation of soft  
tissues of the neck with  
fast spreading in fascial  
compartments without  
borders, with necrosis

Incision, drainage







# Chronic pharyngitis

---

- Frequent disease in adult population
- Part of chronic inflammation of breathing pathways
- **Etiology** – chronic inflammation , long lasting nasal blockage, breathing through mouth, fume and dust, extreme temperatures, spicy food, hard alcohol, smoking, GERD – gastro-esophageal-reflux-disease

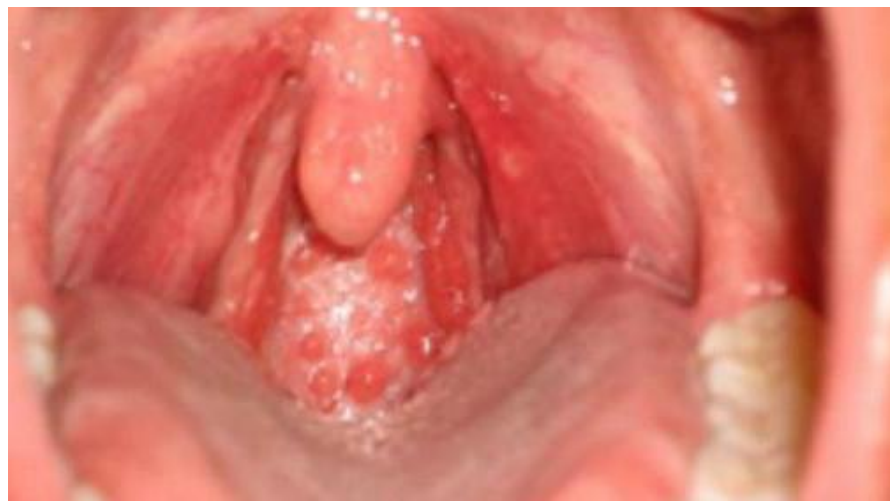**Hyperplastic**

**Atrophic**

# Chronic hyperplastic pharyngitis

---

- **symptoms:** strange sensation in the pharynx with compulsive throat-clearing and swallowing, little better after intake of food
- **Objective finding:** the mucosa of posterior pharyngeal wall is thickened and granular, prominent solitary follicles, venous telangiectasis and secretion
- **Therapy:** reduction of hyperplastic mucosal areas with 2-4% silver nitrate, removal of focuses in breathing ways

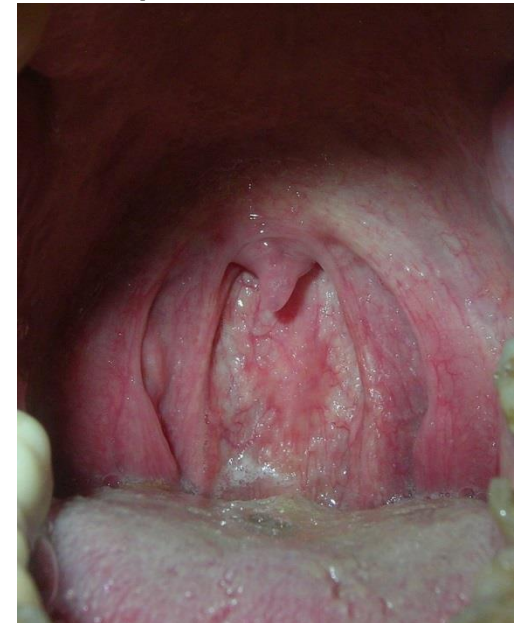

# Chronic atrophic faryngitis

---

- **Etiology:** pobyt v suchém prostředí nebo v prostředí extrémně vlhkém, často u diabetiků a po tonzilektomii
- **Symptoms:** feeling of foreign body, burning sensation and dryness feeling;
- **Objective:** posterior pharyngeal wall is dry and glazed, often with dry crusts of secretion. The mucosa is smooth, pink
- **Therapy:** moisturizing the pharyngeal mucosa with steam inhalation, saline solution, „vincentka“, a change of climate, air humidity, seaside stay

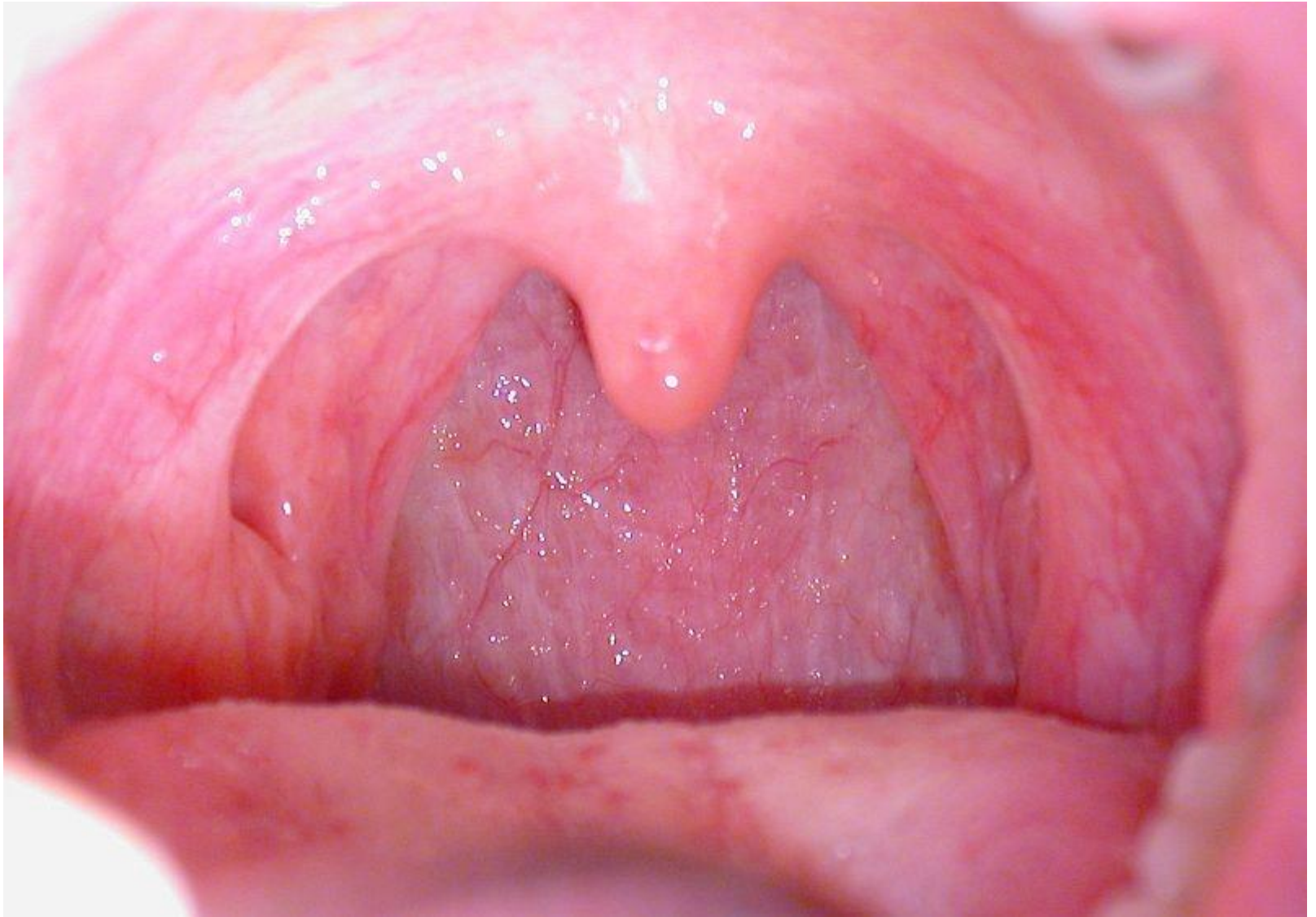
Nicotin, alcohol mentol, chamomile, sage  
must be avoided,





# Chronic atrophic pharyngitis

---





# Chronic tonsillitis

---

- Focal inflammation in tonsillar tissue
- Very frequent disease in adult population
- **Etiology:** mixed bacterial infection in tonsillar crypts - Streptococcus  $\beta$ -hemolyticus gr. A, less B,C,G, gold staphylococcus)
- **Symptoms:** strange feeling in pharynx, feeling of foreign body, foetor ex ore, higher level of ASLO, sometimes subfebrilie. After exercising fevers, pain in muscles... repeated use of antibiotics

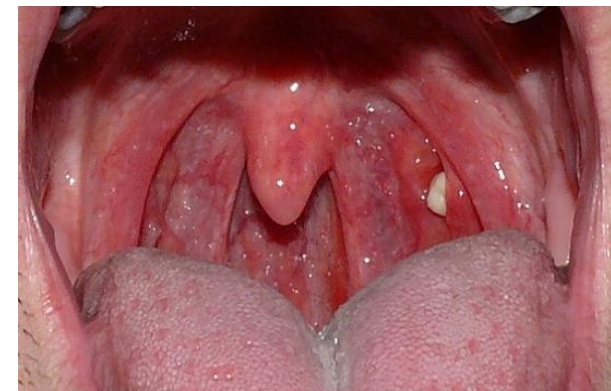
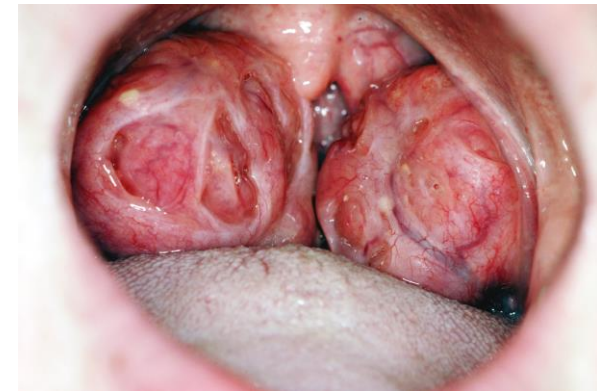
# Chronic tonsillitis

**Objectively:** hypertrophic / atrophic tonsils;  
tonsils are fixed to their base, tonsillar  
surface is fissured or scarred, watery pus and  
grayish-yellow material can be pressed out  
of the openings of the crypts

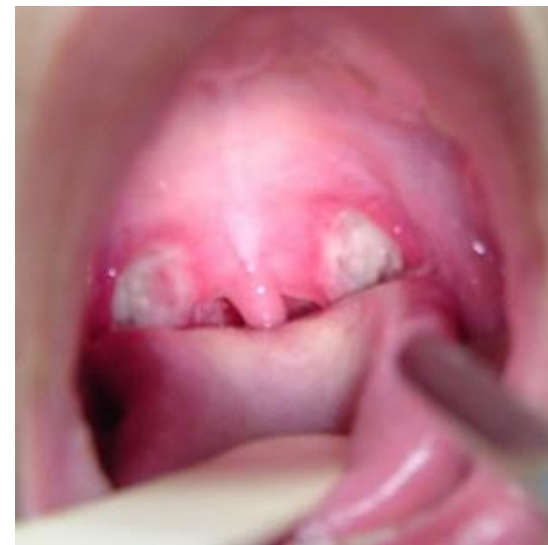## Therapy:

- Conservative – antibiotics  
(uncertain effect – bad spreading into  
crypts)  
local antiseptics, autovaccines,  
immunostimulants
- Surgery : tonsillectomy



# Tonsillectomy - indication

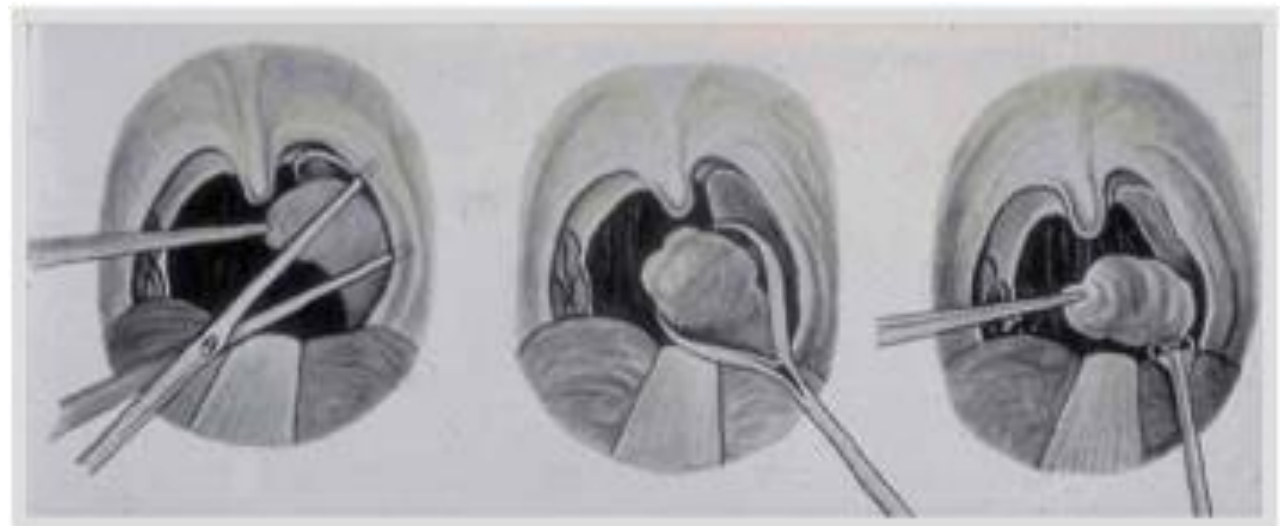
- Recurrent tonsillitis according to Pittsburgh protocol (7/y in 1st y, 5/y in 2 x, 3/y in 3 y)
- Chronic tonsillitis
- Tonsillar hypertrophy with sleep apnea syndrome
- Peritonsillar (or parapharyngeal) abscess
- Suspicion on tumor
- Tonsillogenic septicemia, Angina septica
- Focal infection – „metatonsilar troubles“ (pain in joints, trouble in cardiology, urology)
- Branchial cleft fistulas (2nd branchial arch)
- Processus styloideus elongatus with dysphagia
- Part of plastic treatment of palate cleft



# Principples of tonsillectomy

---

- Performed under intubation anesthesia,
- introduced McIvor gag
- „cold“ vs. „hot“ technics
- Infiltration of tonsillar pillars, combination of blunt and sharp dissection
- Bleeding – bipolar electrocoagulation,



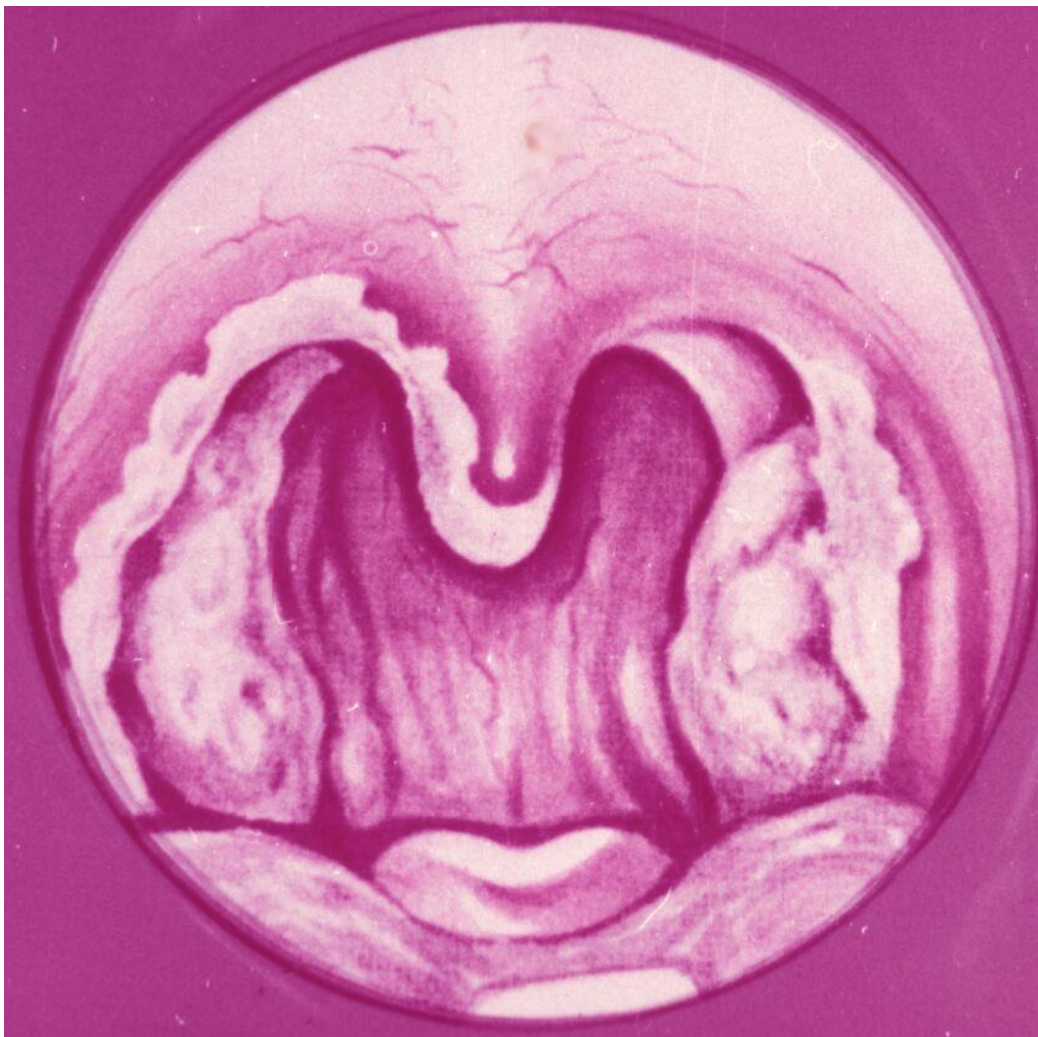

Tonsils are removed only partly

- **Laser**
- coblation technique
- Radiofrequency surgery
- simple tonsillar hypertrophy in children (with clinical symptoms – breathing, swallowing etc.),
- sleep apnea syndrome in children

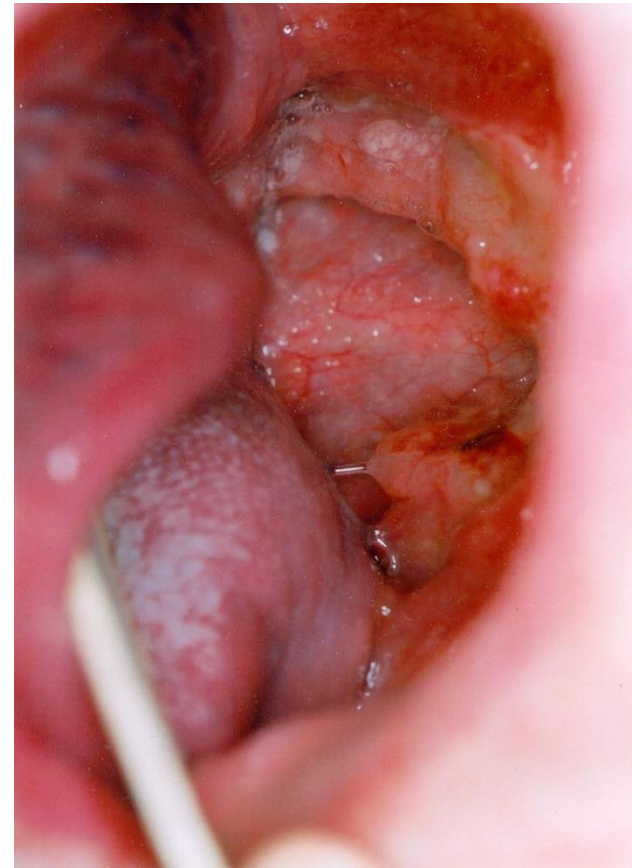
# Diphtery

---



## tumors of oropharynx

history – long lasting: pain, feeling of foreign body, bleeding, halitosis  
asymmetric changes in isthmus faucium,  
ulceration, hyperkeratosis,  
bleeding, tough tonsil, exofytic growth – histology !







# Foreign bodies

---

onside pain, feeling of foreign body

History- sudden onset during eating, finding of foreign body.



# Evaluation of epipharynx

---

- **Posterior indirect rhinoscopy**
- **Direct epipharyngoscopy**
- **Rtg, CT**
- **(Palpation)**

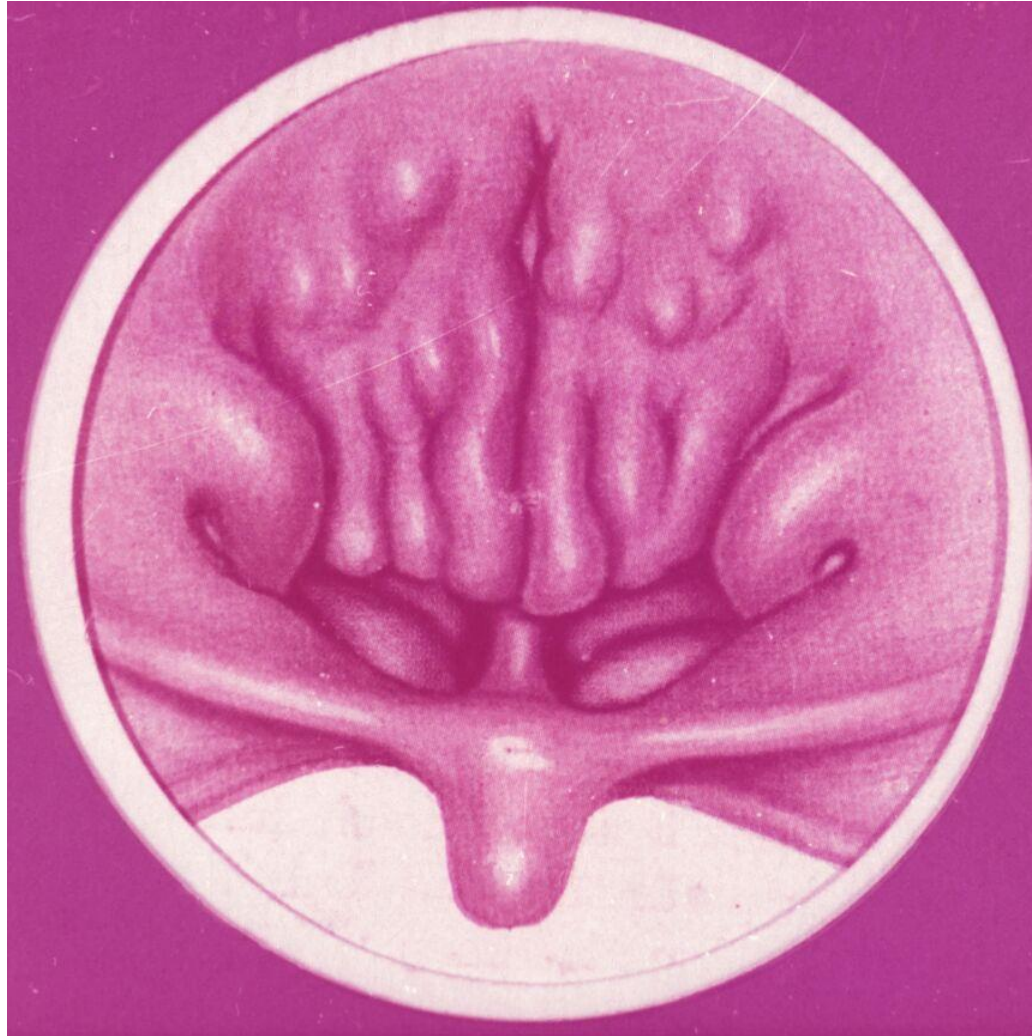


- Epipharyngoscopy
- Politzeration
- Catheterization - murmur
  - **Normal** dry, filled
  - In **stenosis** – discontinuous, abrupt
  - In **liquid** in middle ear cavity– moist phenomenon's
  - In **perforation** of ear drum – high, whistle
- Tubometry – even in perforated ear drum (Valsalva, Toynbee),



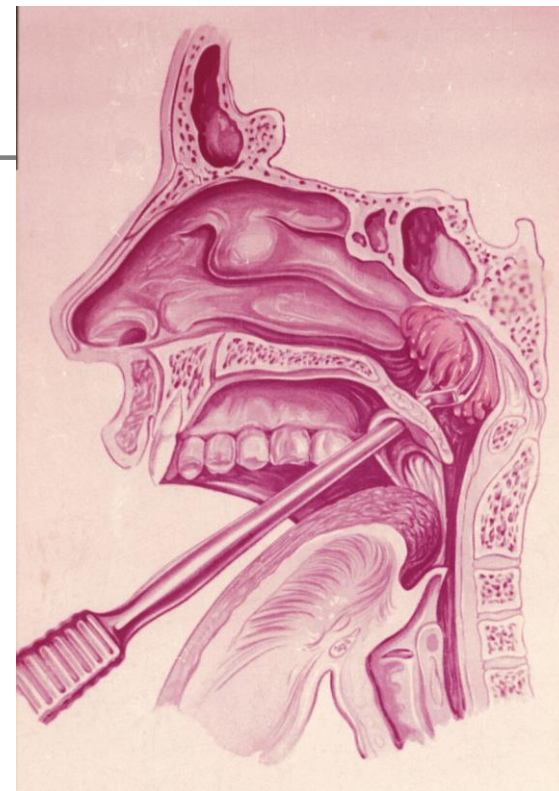
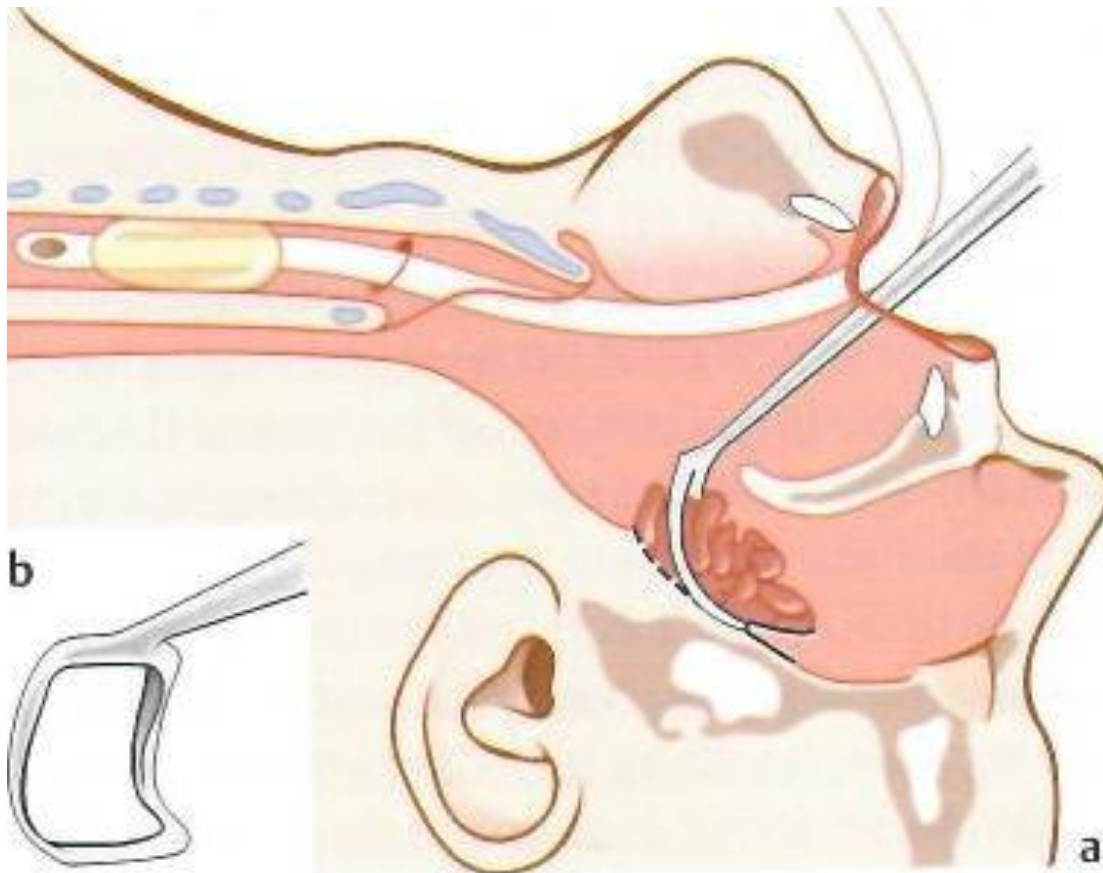
# Vegetationes adenoideae (tonsilla pharyngea)

---



# Adenoidectomy

under general anesthesia

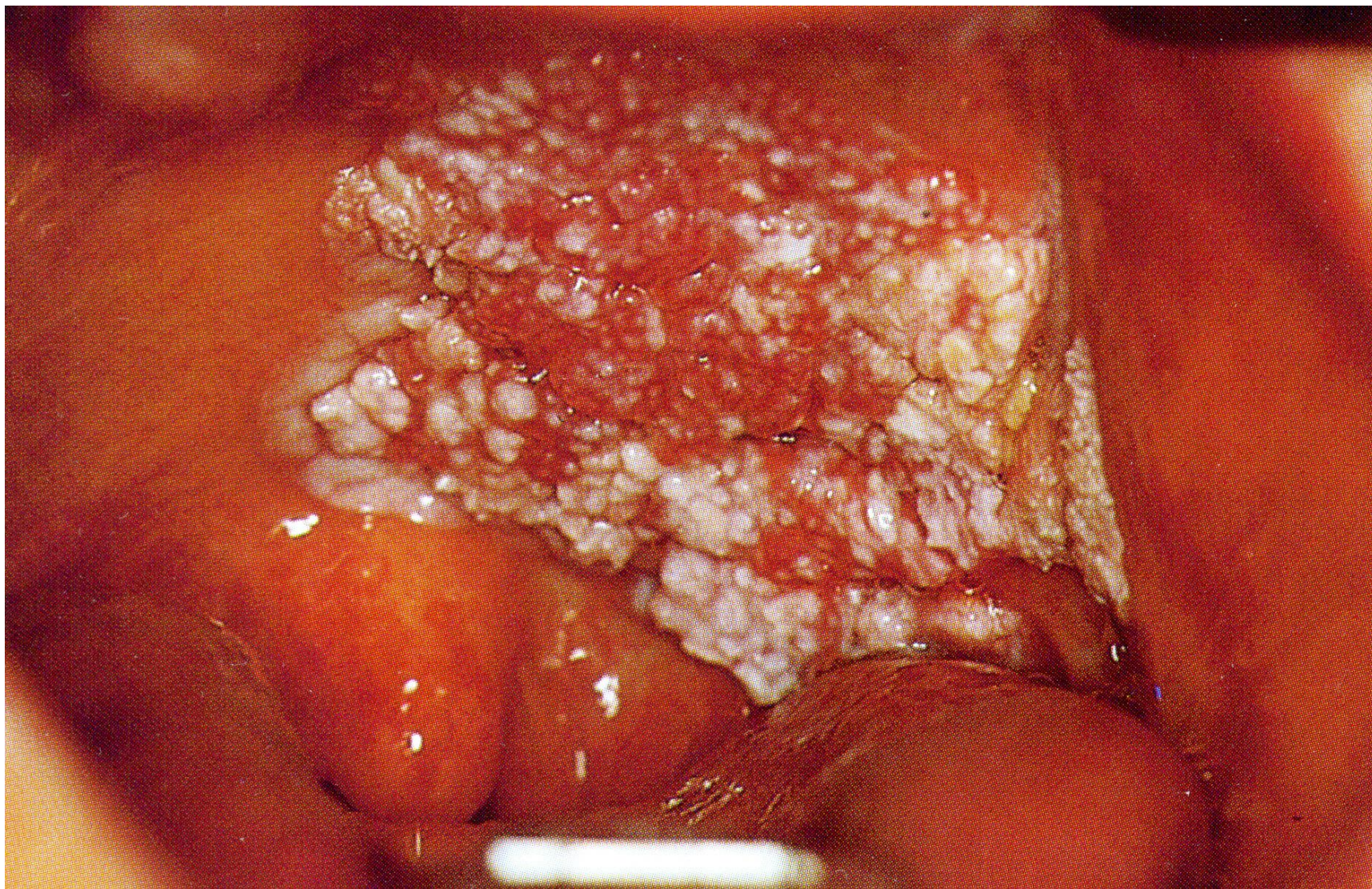


under local anesthesia



# soft palate carcinoma

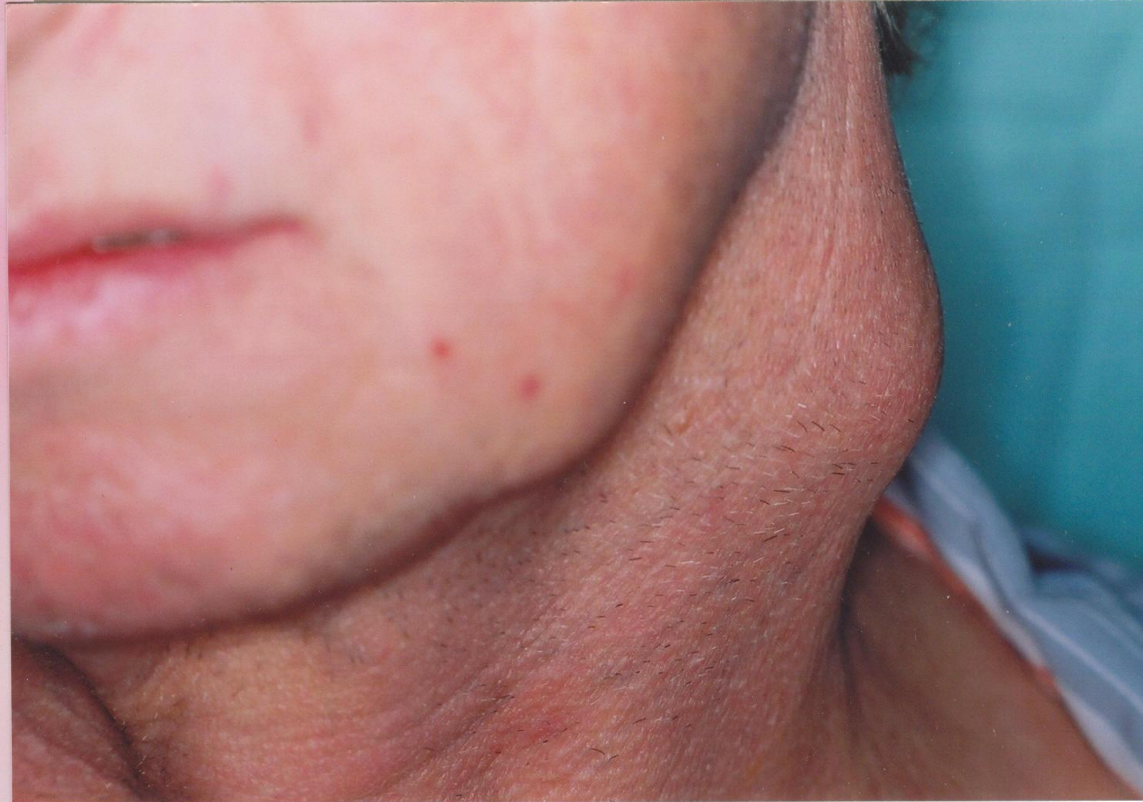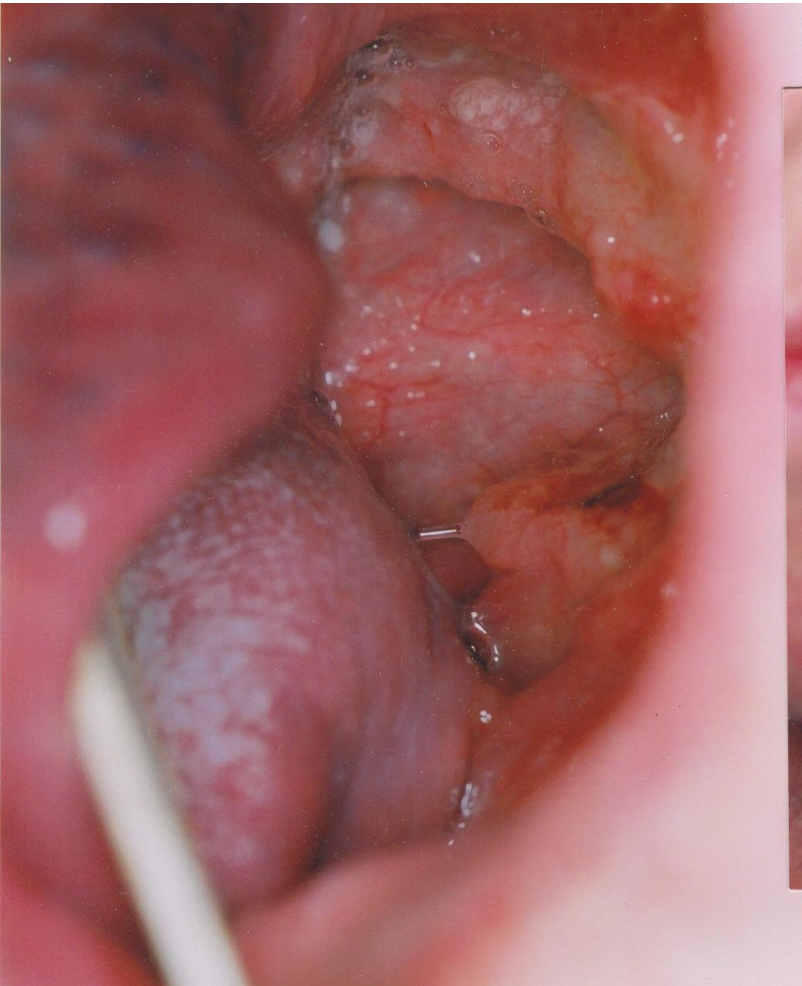
---





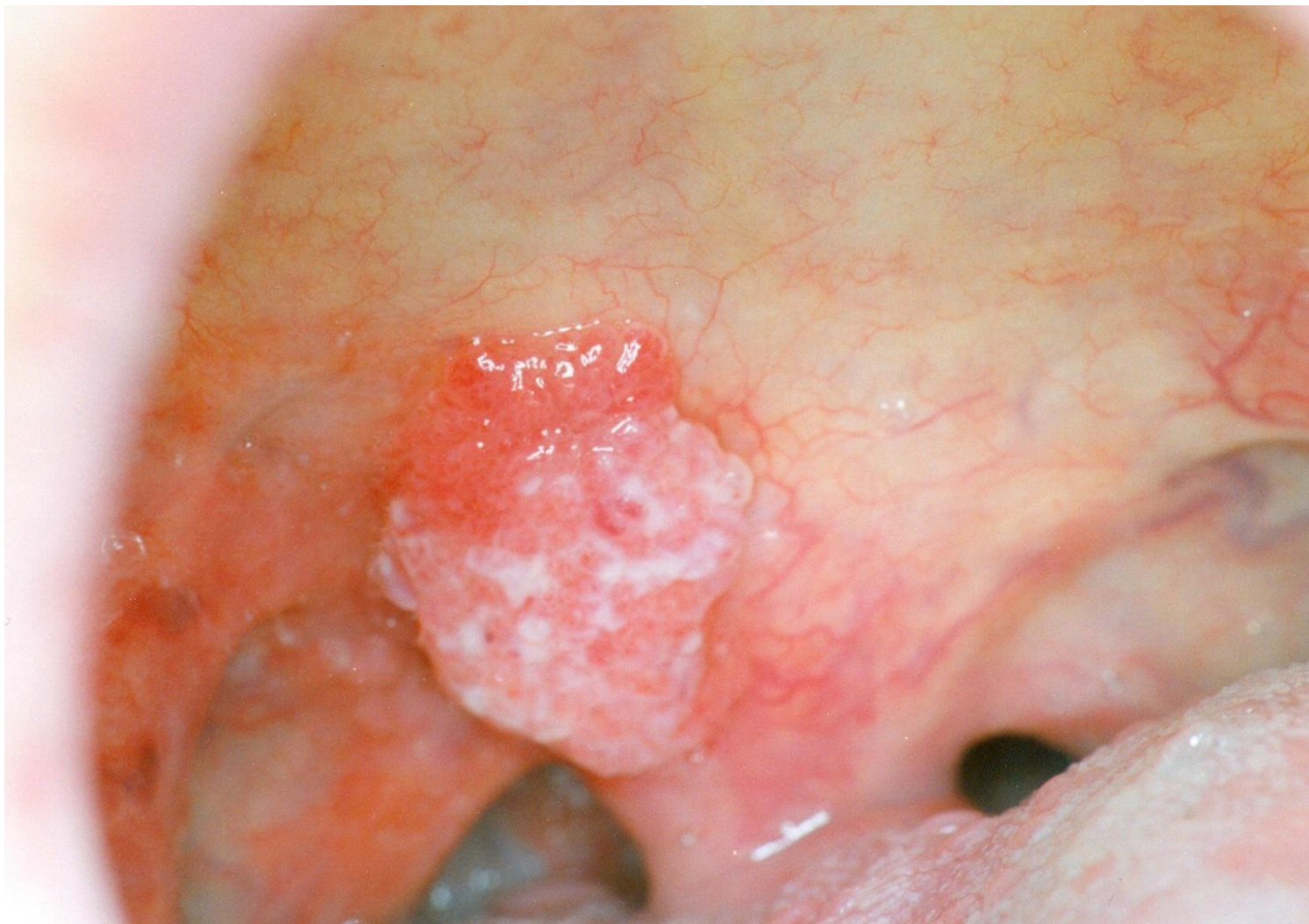# oropharyngeal cancer with metastasis on the neck

---



# oropharyngeal cancer – soft palate

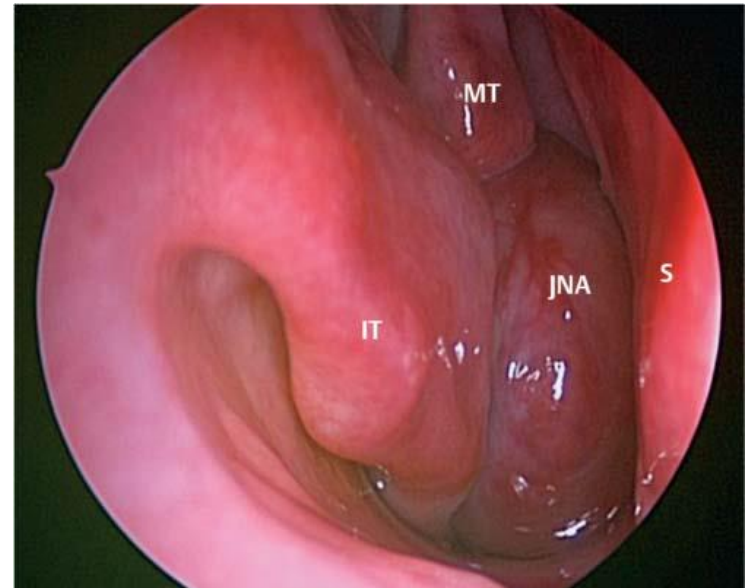
---





# Benign tumors of epipharynx – juvenil angiofibroma

- Frequent benign tumor of epipharynx, usually arises from the pterygomaxillary fissure (foramen sphenopalatinum), spreading into epipharynx, or nasal cavity, paranasal sinuses, orbit and base of the skull.
- Highly vascularized tumor, locally destructive, recurrent
- Occurs exclusively in males 15-25 let
- **Vessels** –  
ACE (a.maxillaris, a.pharyngica asc.)  
ACI (a.opthalmica, sin.cavernosus)



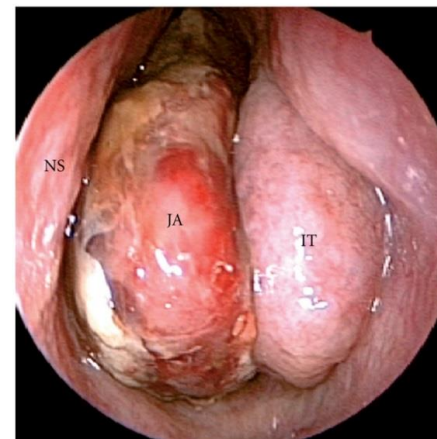


# Nasopharyngeal angiofibroma

**Etiology** not sufficiently known

A) hormonal - adolescent male

B) other – disturbances in embryonal development



**Classification according to** Chandler

I) limited to nasopharynx

II) spreading into nasal or sphenoidal cavity

III) spreading into maxillary and ethmoidal cavities, fossa pterygopalatina or infratemporalis, into orbit or face

IV) intracranial spreading



# Nasopharyngeal angiofibroma

---

**Symptoms:** recurrent epistaxis, one sided or both sided nasal obstruction, nasal discharge, rhinosinusitis, rhinolalia, hearing disorder, headache, in advanced stage: diplopia, eye bulb protrusion, liquorhea, loss of smell, deformities of face, palate

## Diagnosis

- rhinoendoscopy red-yellow soft, bleeding tissue on contact
- Zobrazovací metody CT with contrast medium+angiography, NMR with contrast medium+angiography, DSA
- Biopsy contraindicated for strong bleeding



## Surgery

- Trans nasal endoscopic technique (small tumors)
- External approaches – medial maxillectomy from lateral rhinotomy, transpalatinal, transantral, neurosurg. approaches
- Preoperative embolization of the feeding vessels – within 48 hours before surgery (risk of CMP)

**Actinotherapy - success rate 80 %**

**chemotherapy intraarterial** – only advance, or palliative

Recurrences in 20-50% - uncomplete removal





# Nasopharyngeal cancer

---

- South-east asia; in European rare
- WHO classification:
  - I. Spinocelular cancer with keratinization
  - II. Small differentiated Spinocelular cancer without keratinization
  - III. Not-differentiated cancer
- **Type I** – local spread into base of the skull, less frequently regional or distant metastasis, low chemo and radiosensitivity
- **Type II a III** (lymphoepithelioma, nasopharyngeal type cancer)
  - usually both large regional metastasis and distant metastasis, good chemo-radiosensitivity, is thought to be due to the Epstein-Barr virus



# Nasopharyngeal cancer

---

## Symptoms

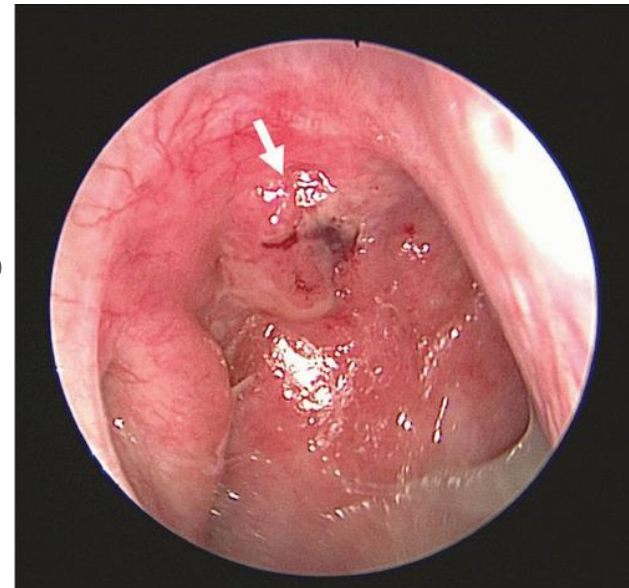
- 1st symptom frequently – enlarged, not painful bilateral neck lymph nodes
- **Ear** - Eustachian tube dysfunction from obstruction-  
conductive hearing loss, tinnitus, middle ear effusion
- **Nasal** obstruction, bloodstained purulent nasal discharge
- **Neurology** typical for advanced tumors (n.VI, n.V – diplopia, disorder of face sensitivity, n.IX-XI), Trotterova trias: palate paresis, neuralgia n V., conductive hearing loss

## Diagnosis

- rhinoepipharyngoscopy
- Biopsy
- CT (bone destruction) a MR (intracranial spread)

# Nasopharyngeal cancer

- Radiotherapy
- Advanced primary tumor - Radiotherapy + chemotherapy (neoadjuvant, concomitant)
- Surgery only in case persisting neck metastases after non surgical treatment – neck dissection
- Lymphoepithelioma  
(Schmincke-Regaud) 5y survival rate 40 %  
other malignant tumors in this region 20 %







# Evaluation of salivary glands

---

- Inspection
- Palpation
- Ultrasound
- Sialography, CT, NMR
- FNB = fine needle biopsy
- Endoscopy of drainage system

# Sialography

