

Endodontic treatment – from access to the working length



RCT – root canal treatment

- Irreversible pulpitis
- Necrosis
- Gangraena
- Periodontitis



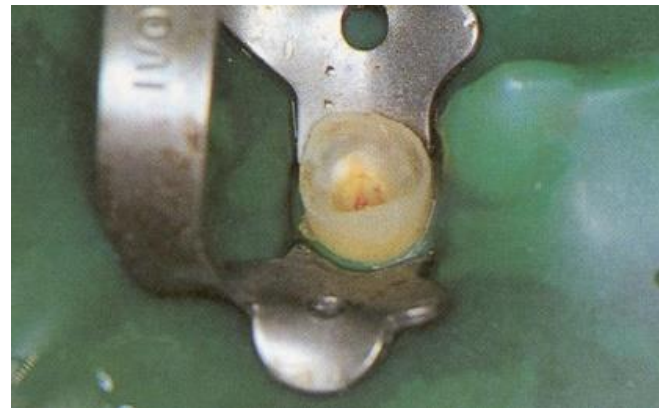Phases of the endodontic treatment

- **Investigation, diagnostic radiogram, consideration (local, regional, systemic factors)**
- **Preendodontic treatment**



Preendodontic treatment

- **Removal of old fillings, carious dentin, temporary restoration - contours of treated tooth.**
- **Gingivectomy or elongation of clinical crown if necessary.**

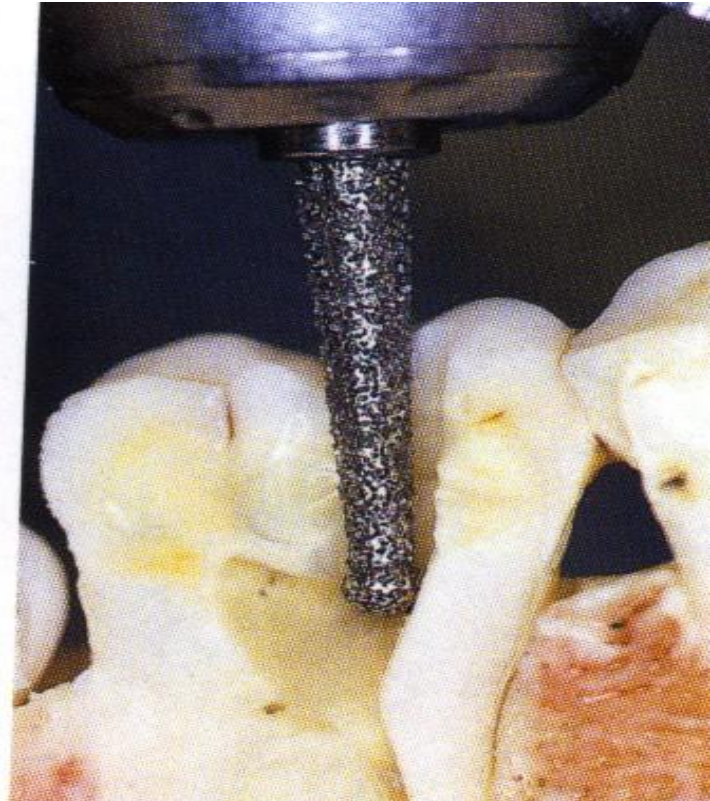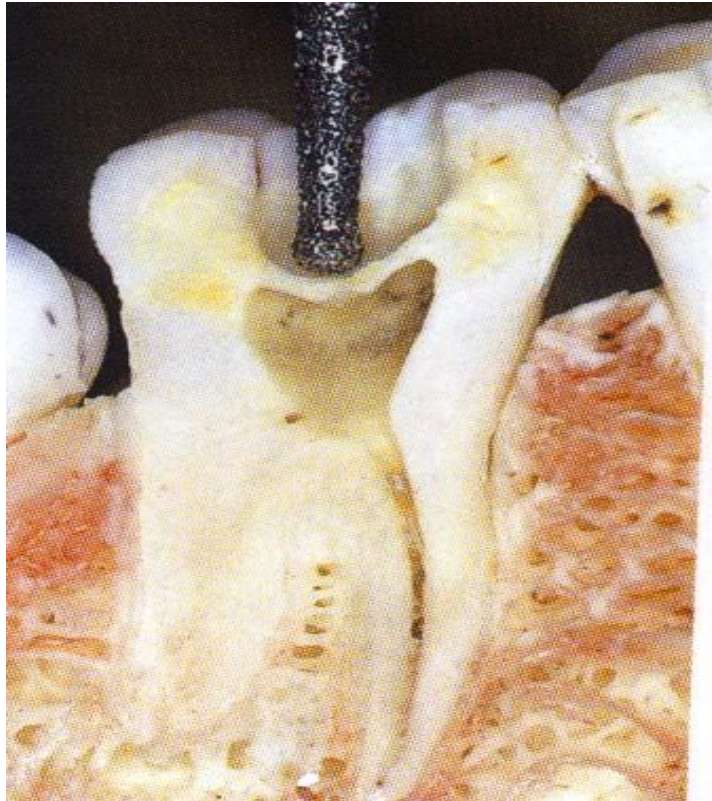


- **Dry operating field – rubber dam**

See presentation Dry operation field



Access



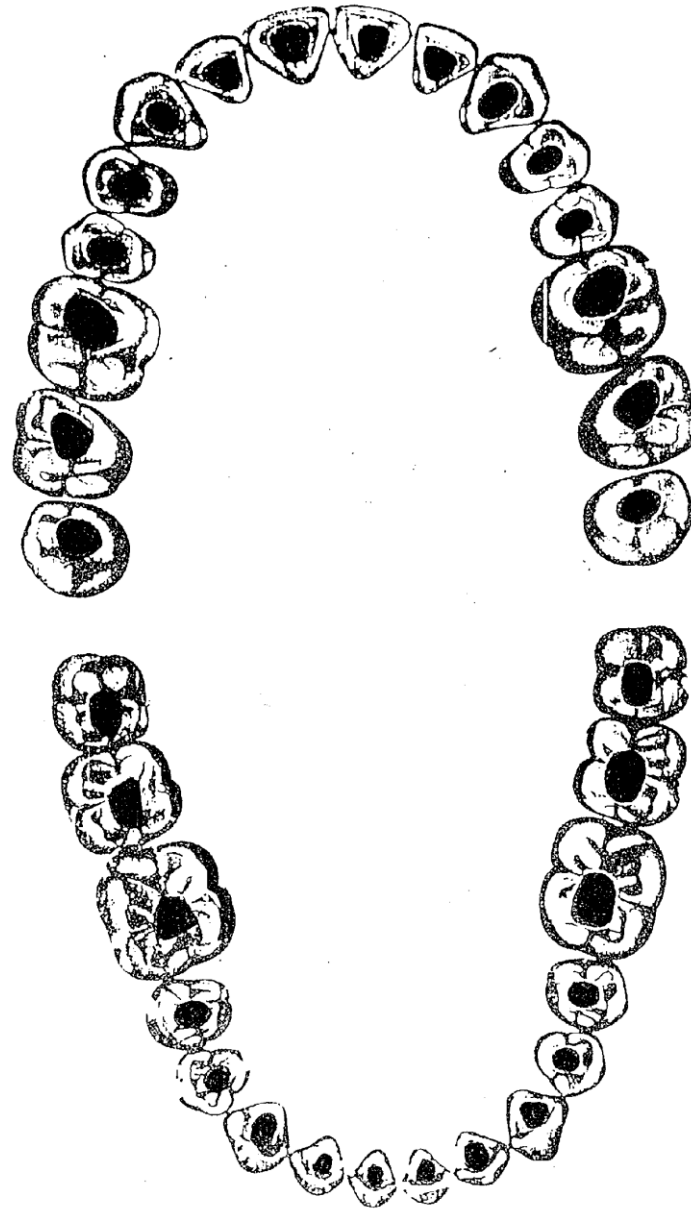
Phases of the endodontic treatment

- **Opening of root canals**
- **Initial flaring and removal of content of root canal**
- **WL (working length)**
- **Root canal shaping and cleaning (irrigation)**
- **Recapitulation**
- **Drying**
- **Filling**
- **Radiogram**
- **Postendodontic treatment**

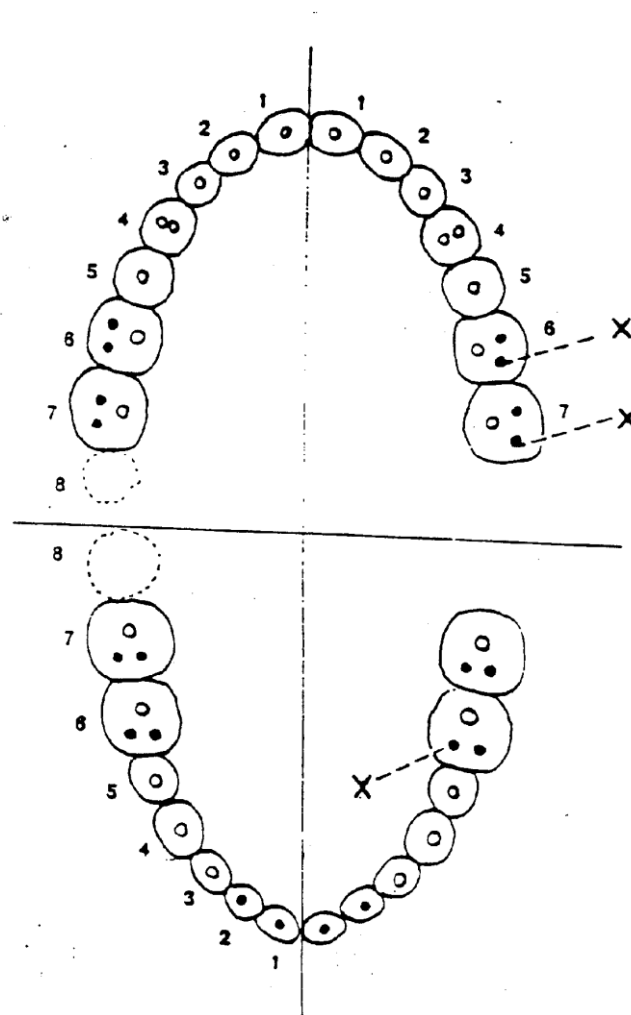


Shapes of endo cavities

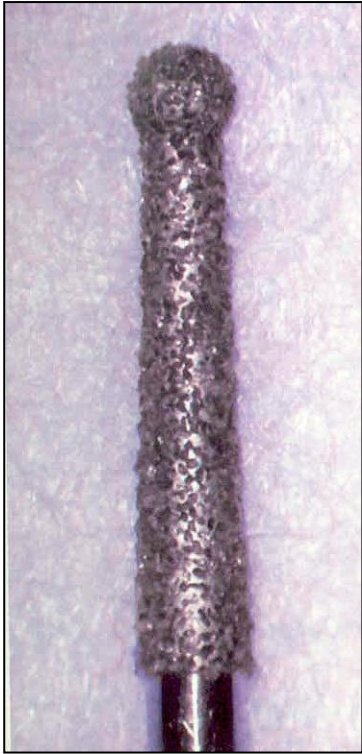
See special material on is



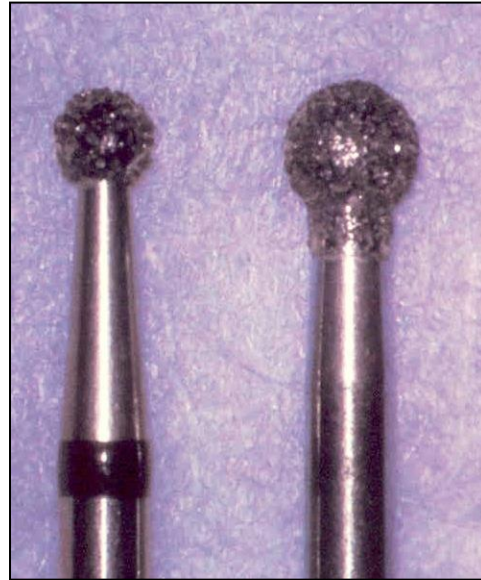
Number of root canals
First upper molar – 4 root canals



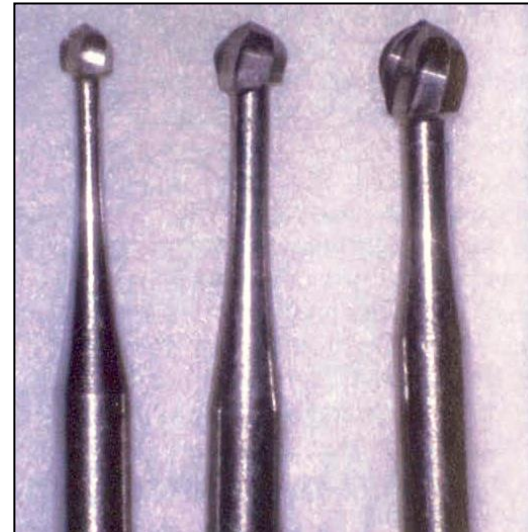
Instruments



Dia trepan



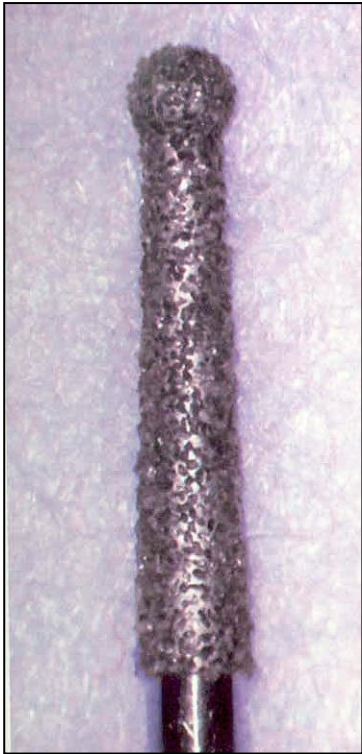
Dia balls



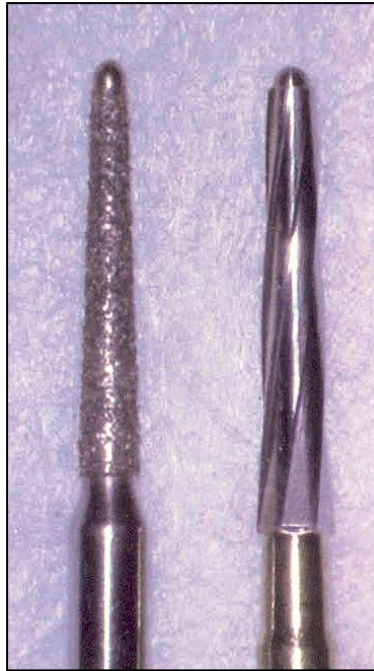Ball burs



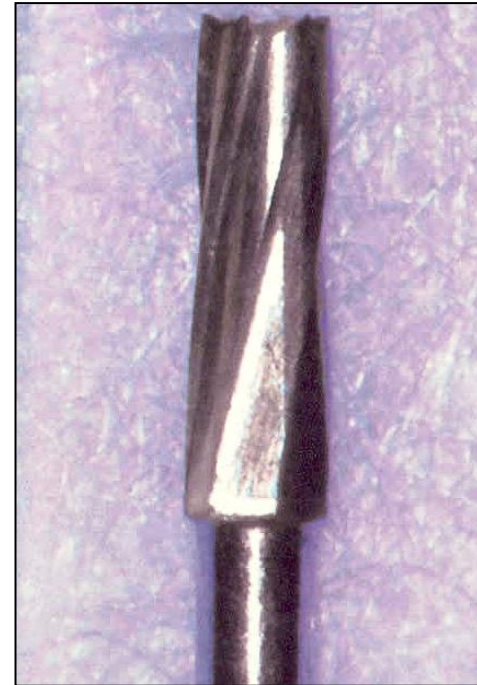Preparation of the endodontic cavity



Dia trepan



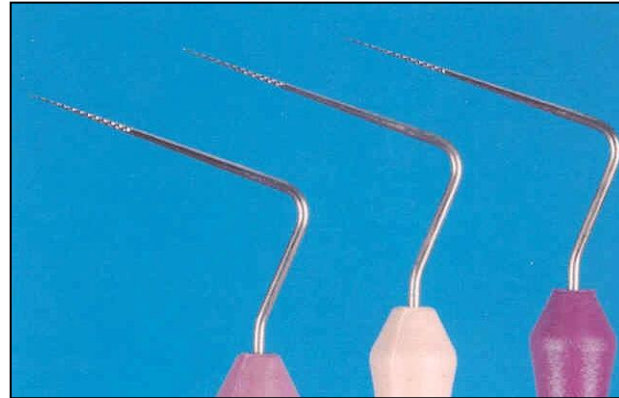

Safe ended tips
Batt's instruments



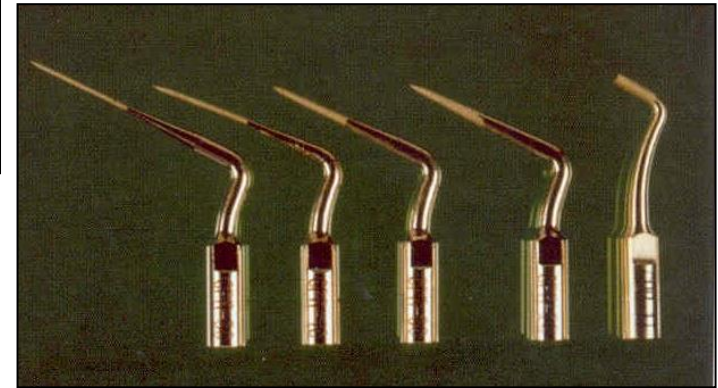
Fissure bur



Find of root canals



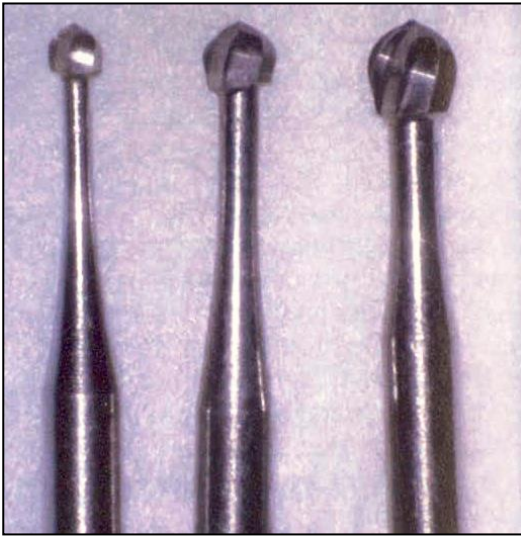Endodontic probes, microopeners



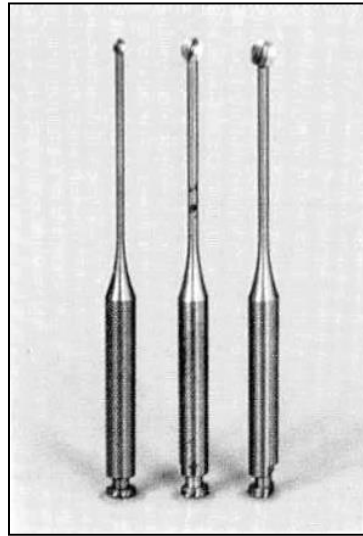
Ultrasound tips



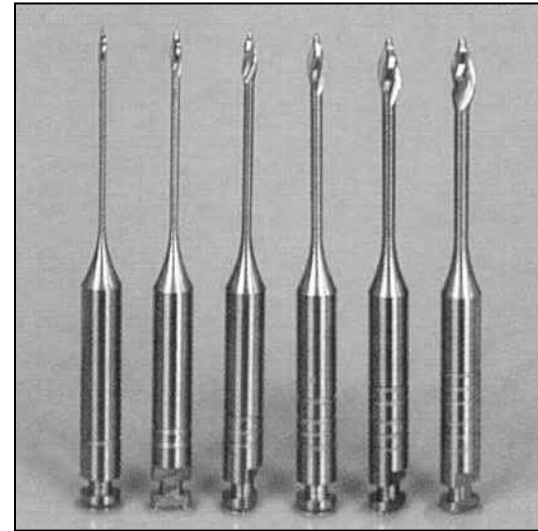
Opening of root canals



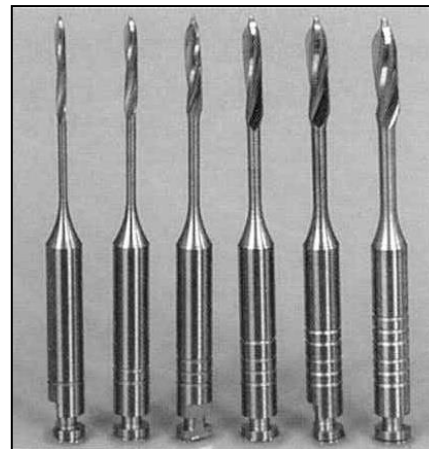
Ball burs



Miller's
burs



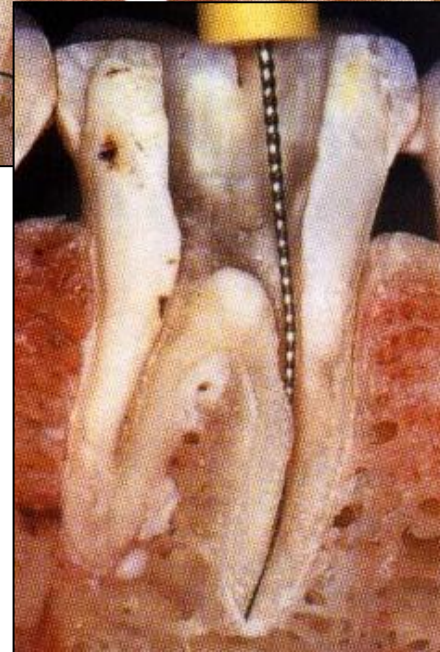
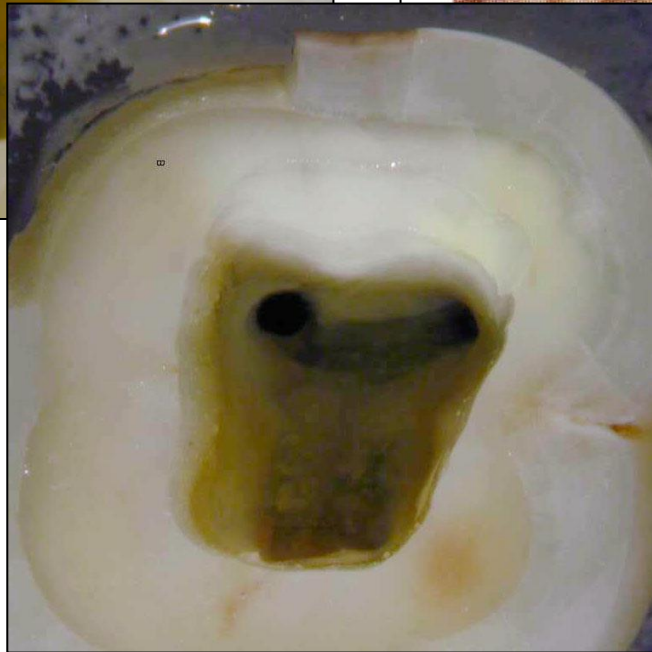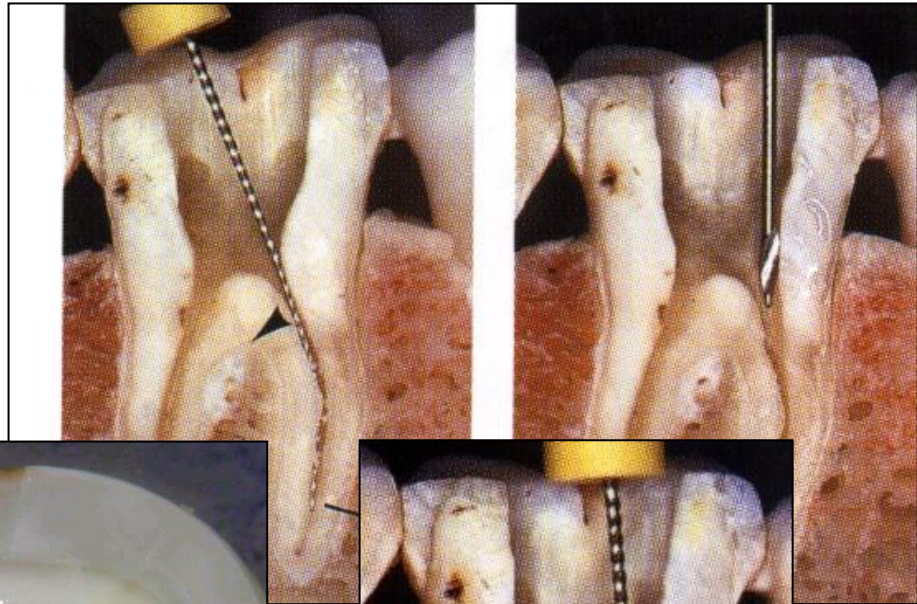
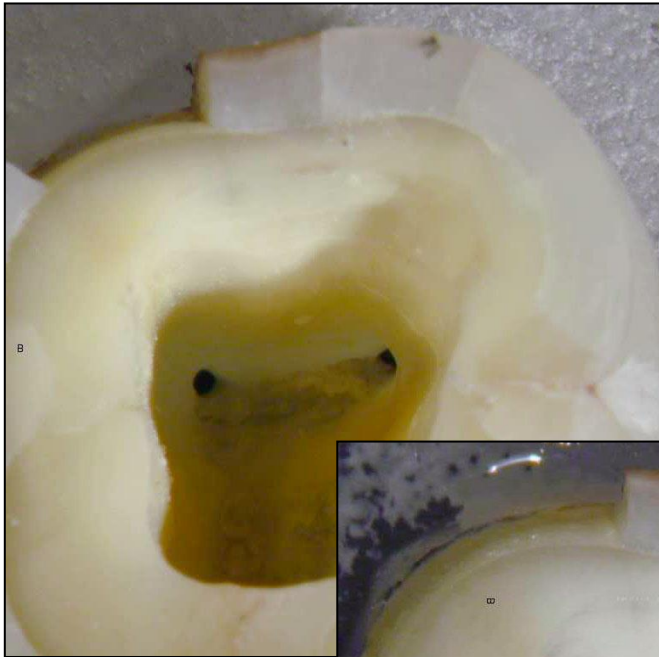
Gates Glidden's burs

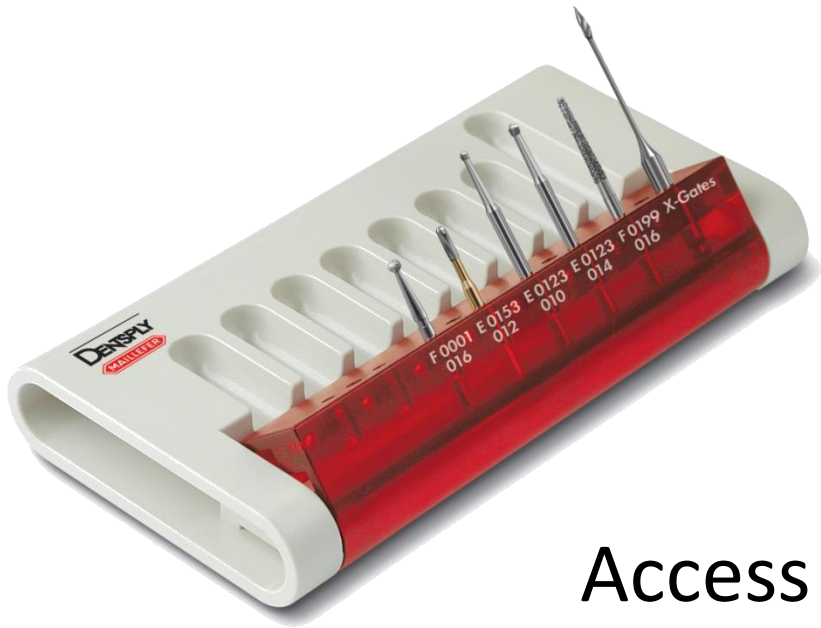

Peeso – Largo

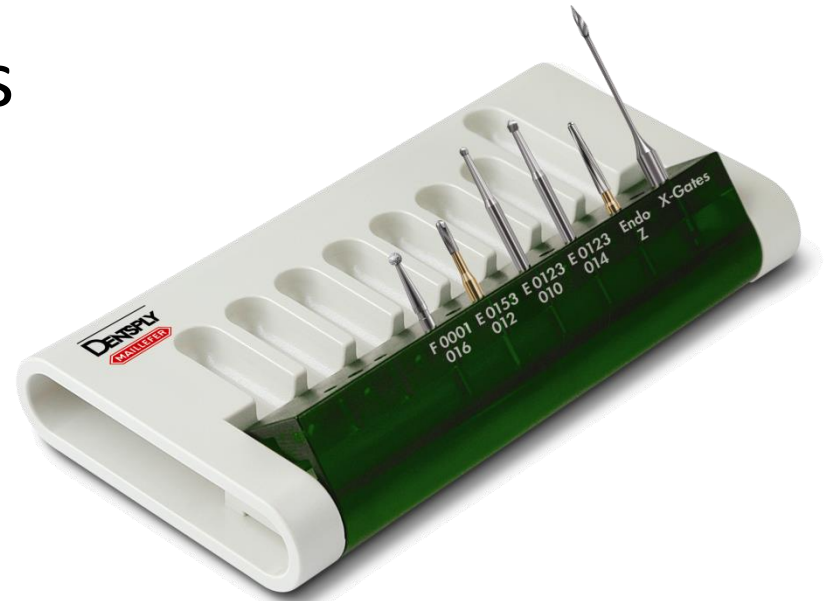

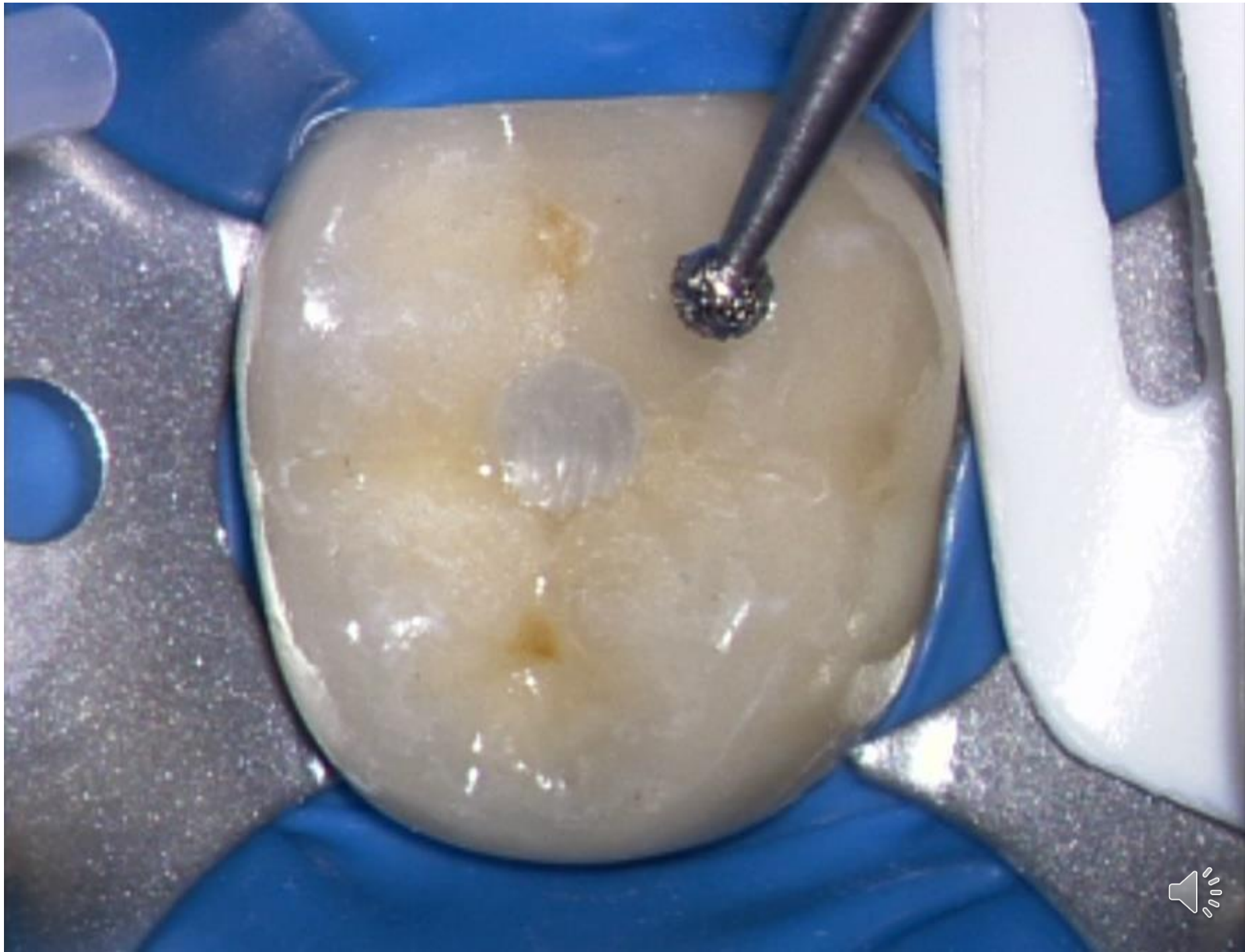Finding of the root canal orifice

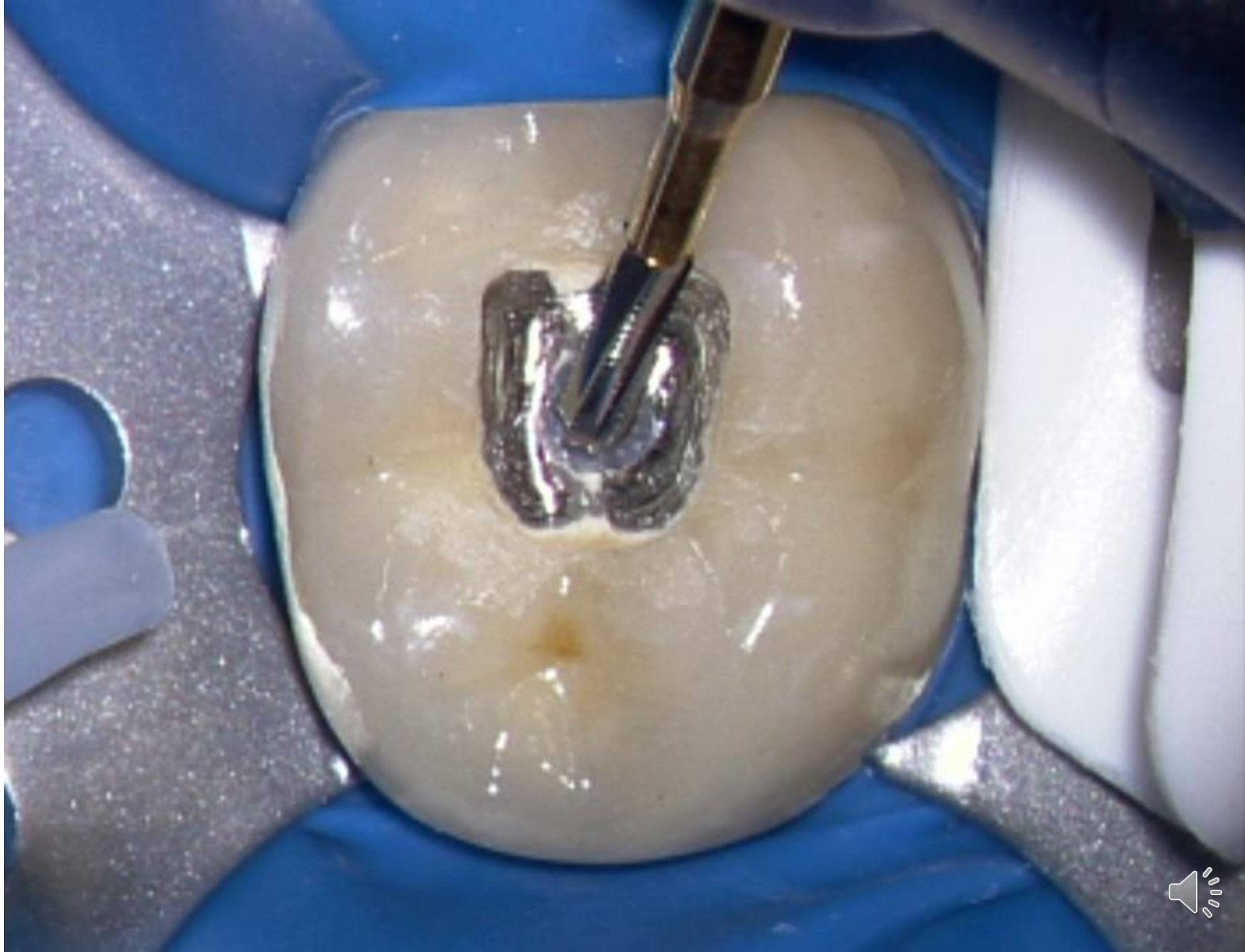


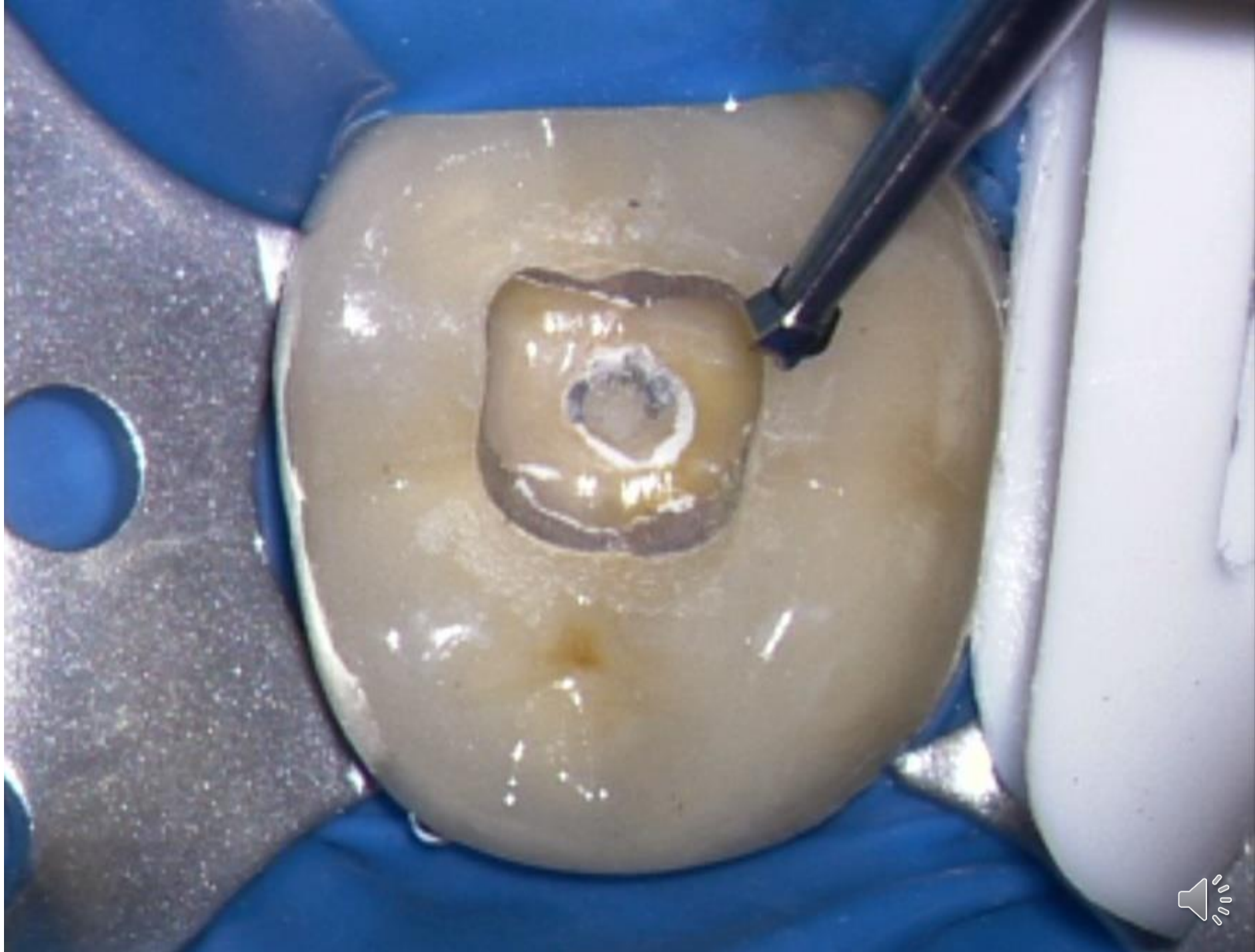
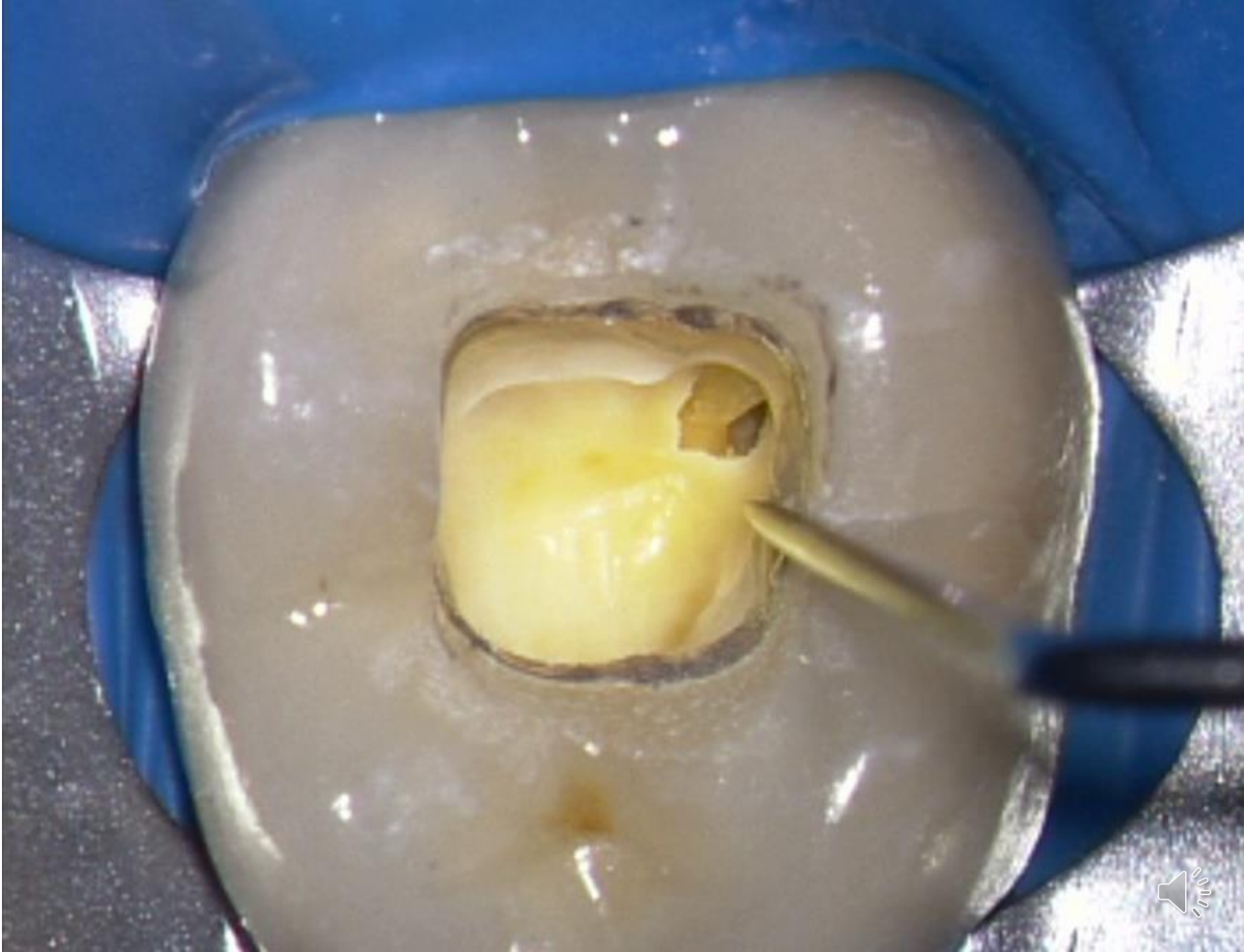Access kits

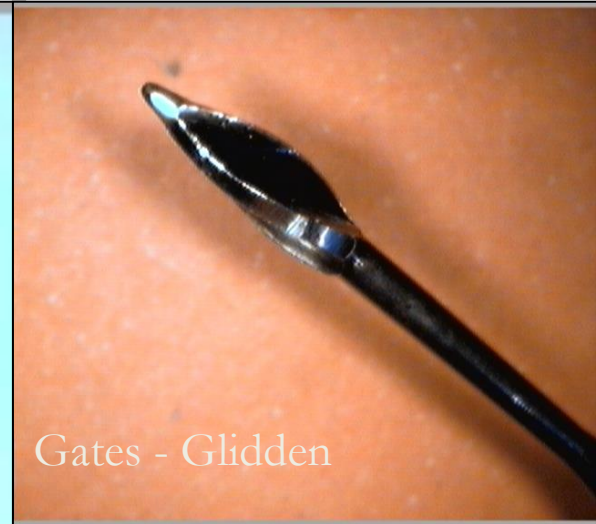
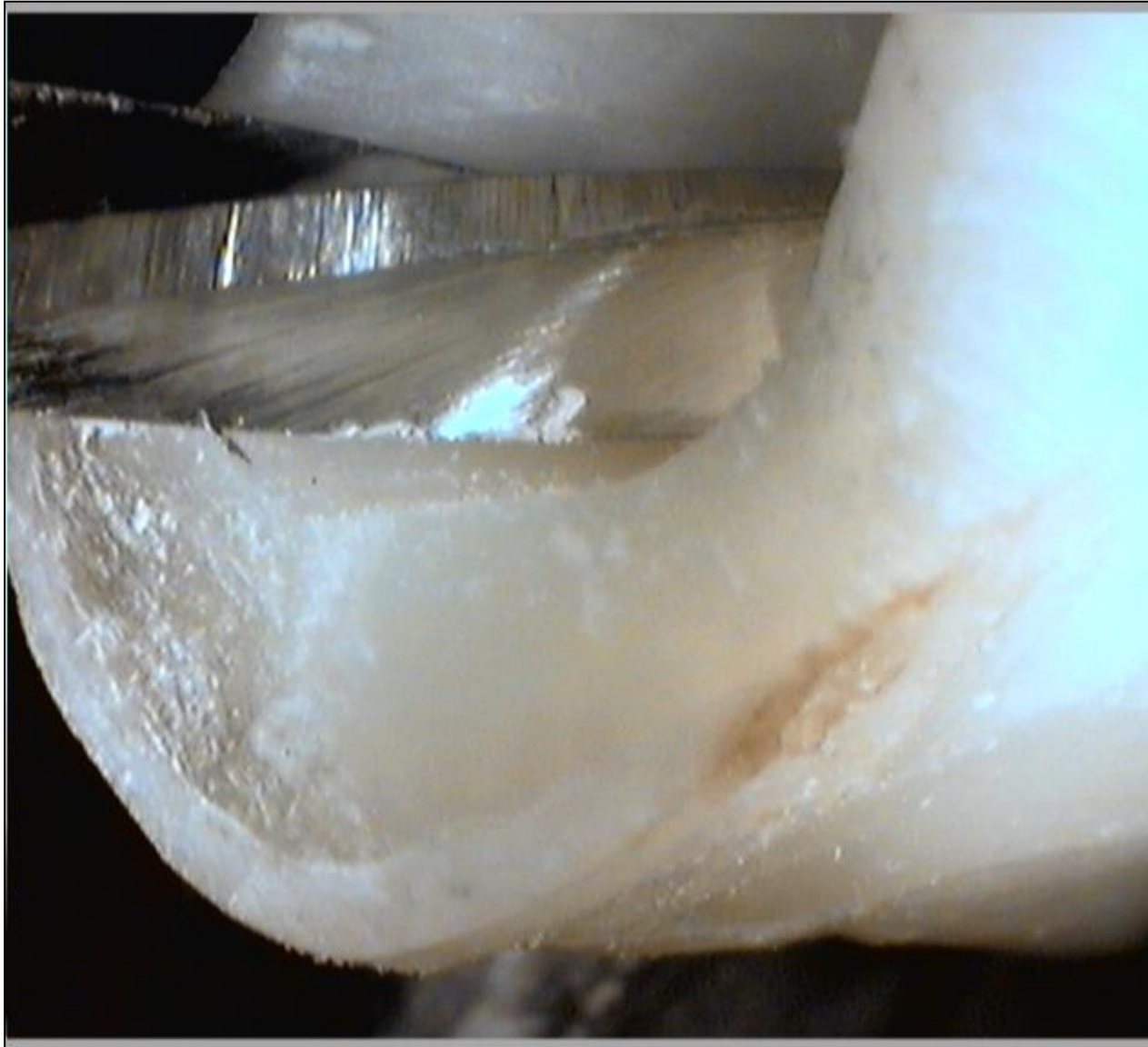








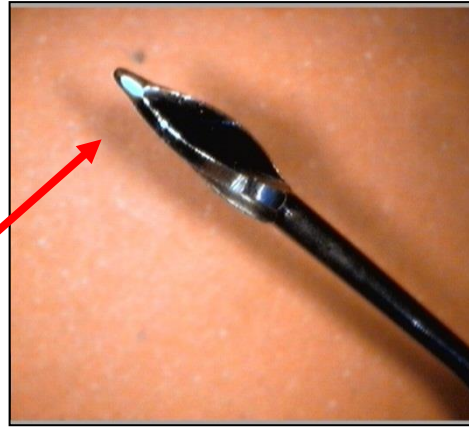


Gates - Glidden

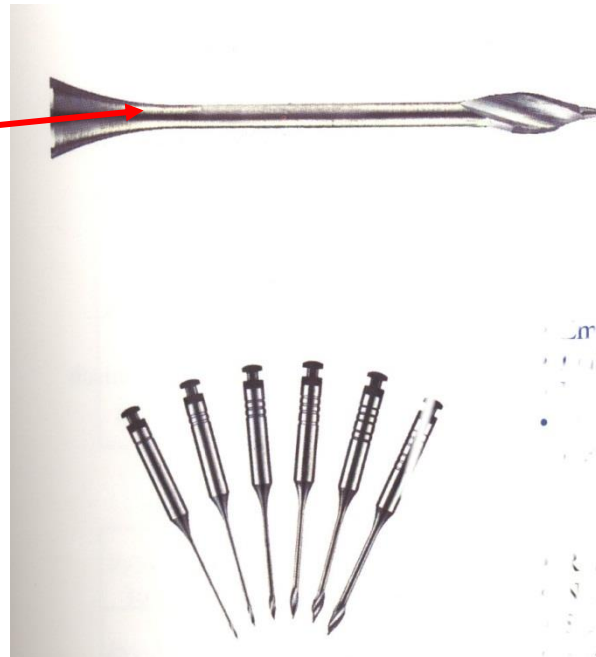


Peeso-Largo

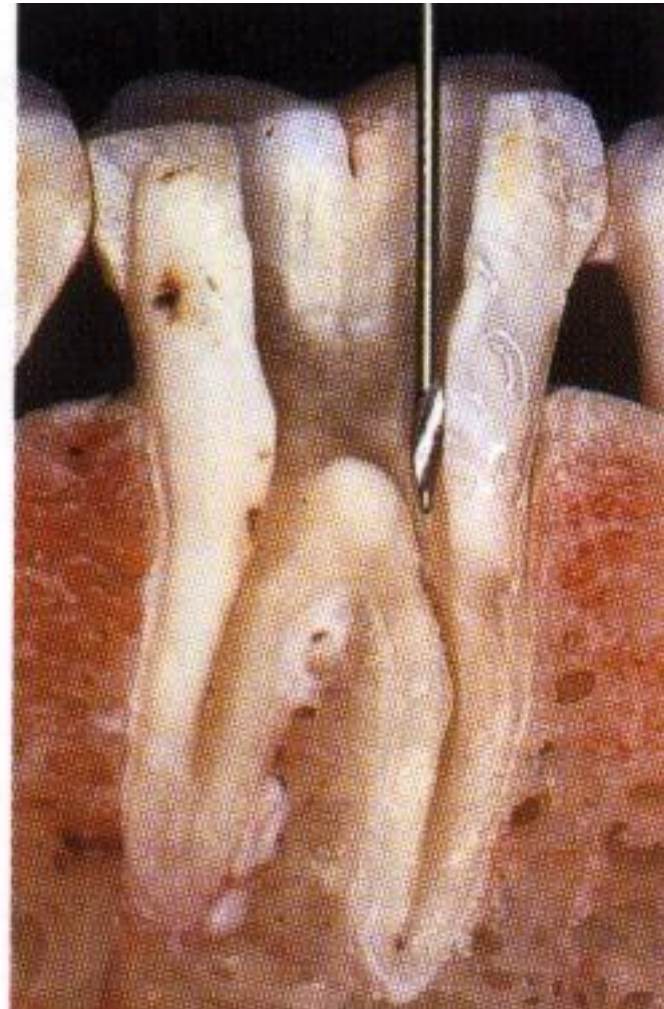
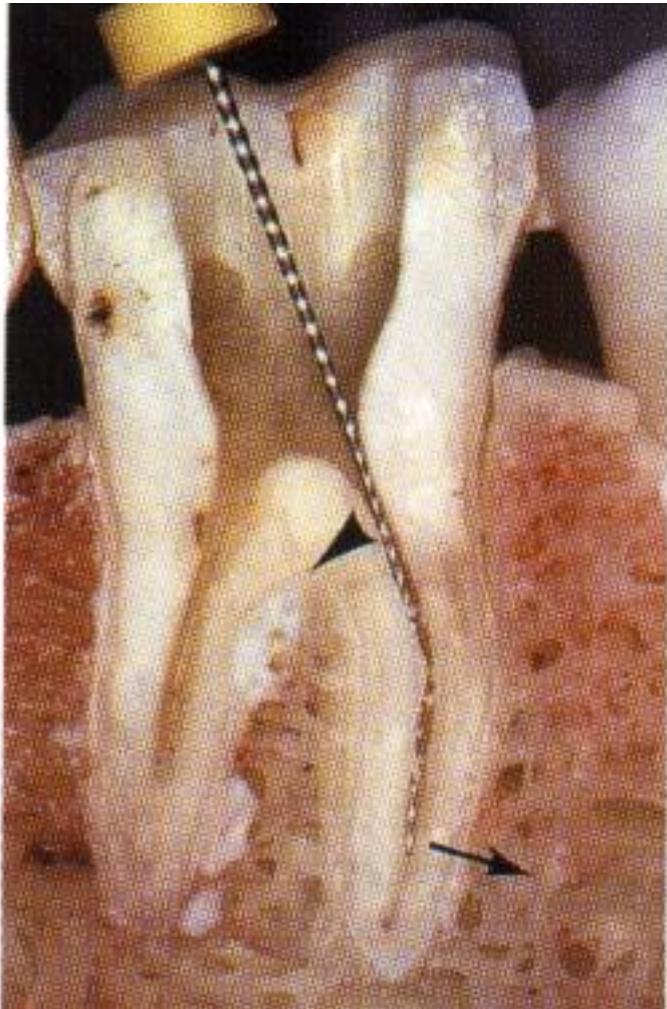




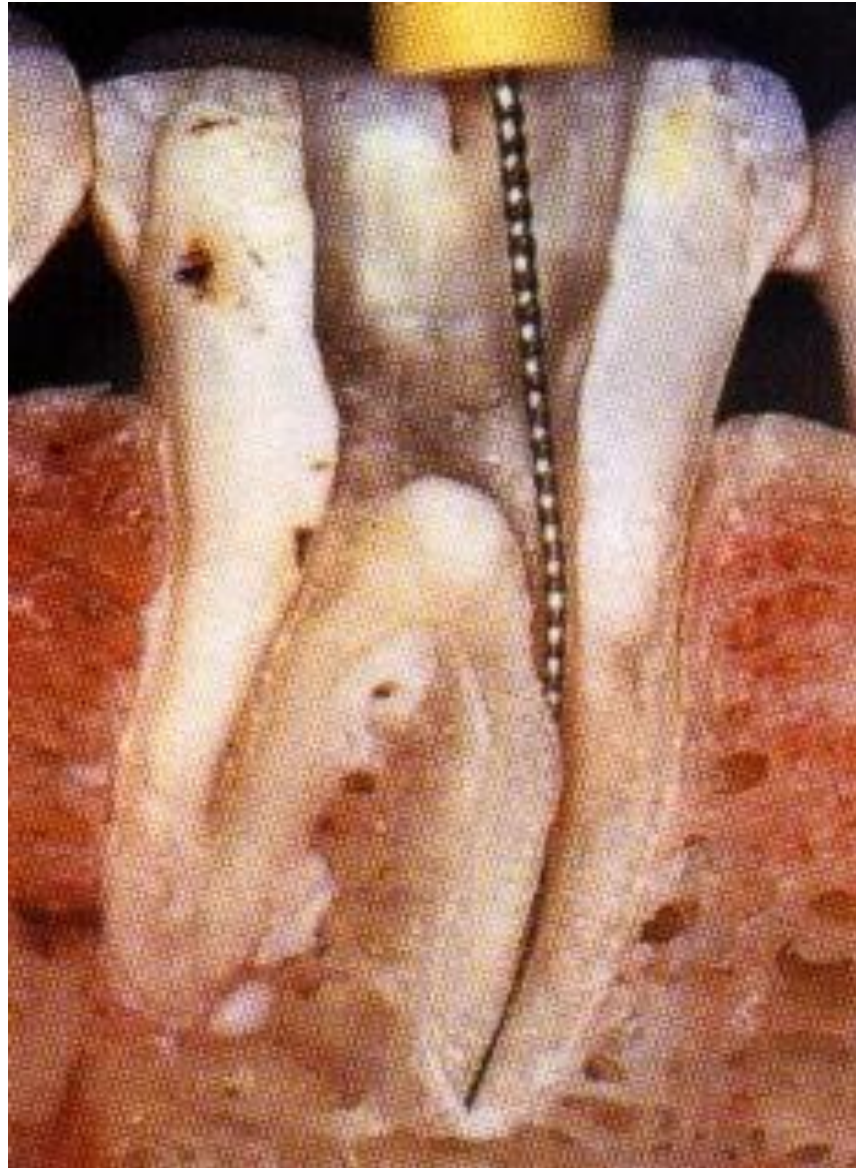
Gates – Glidden:
Tupá, neaktivní vodící špička
Naprogramované místo
zlomu



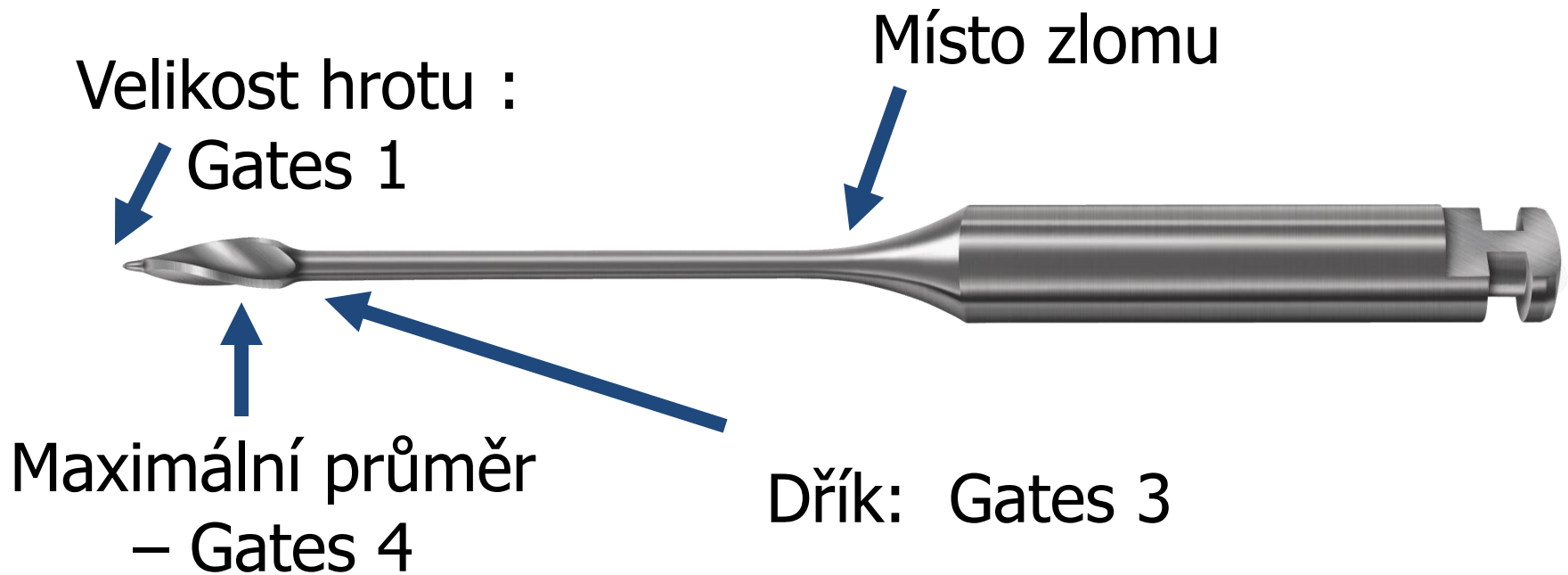
Opening of root canal orificies

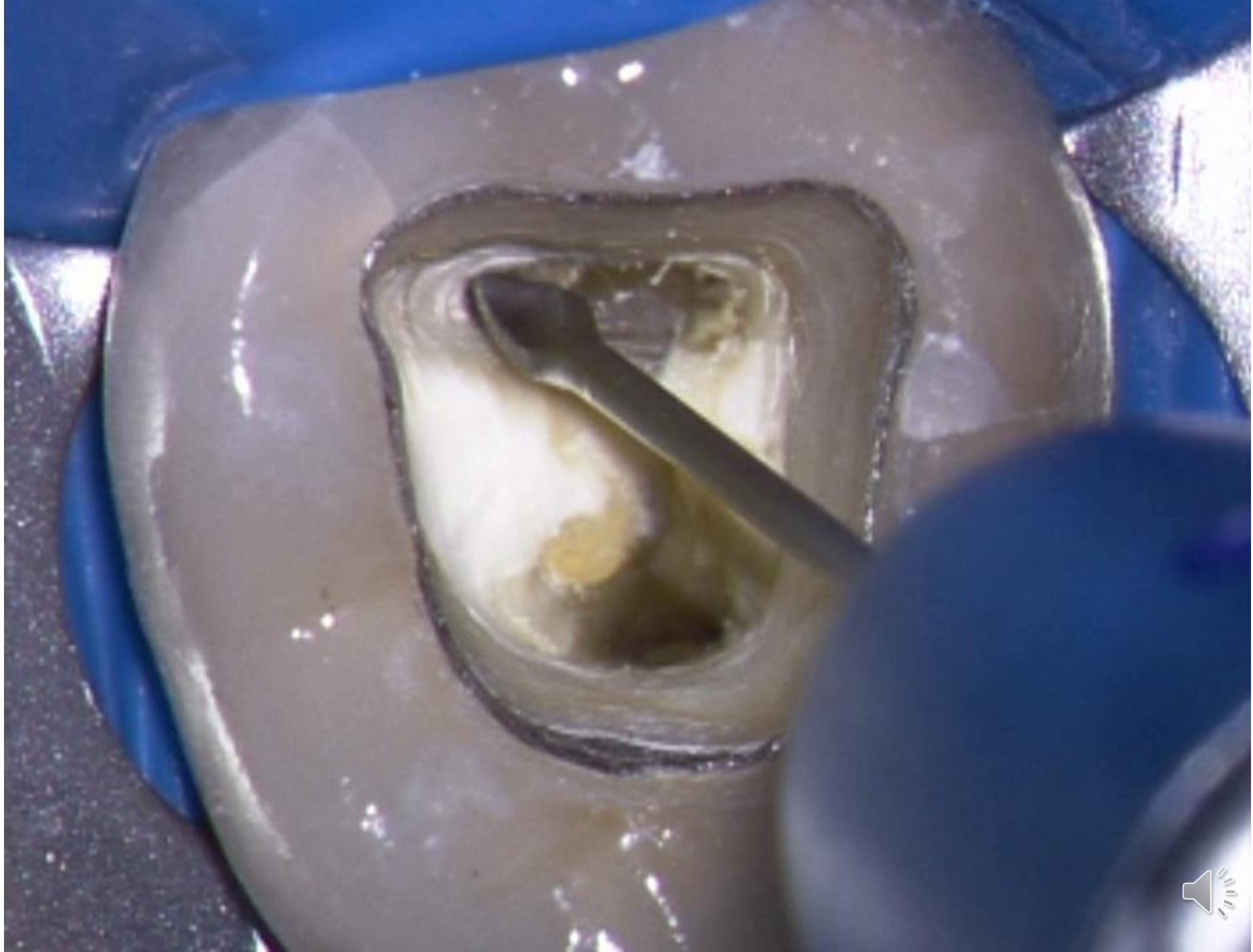

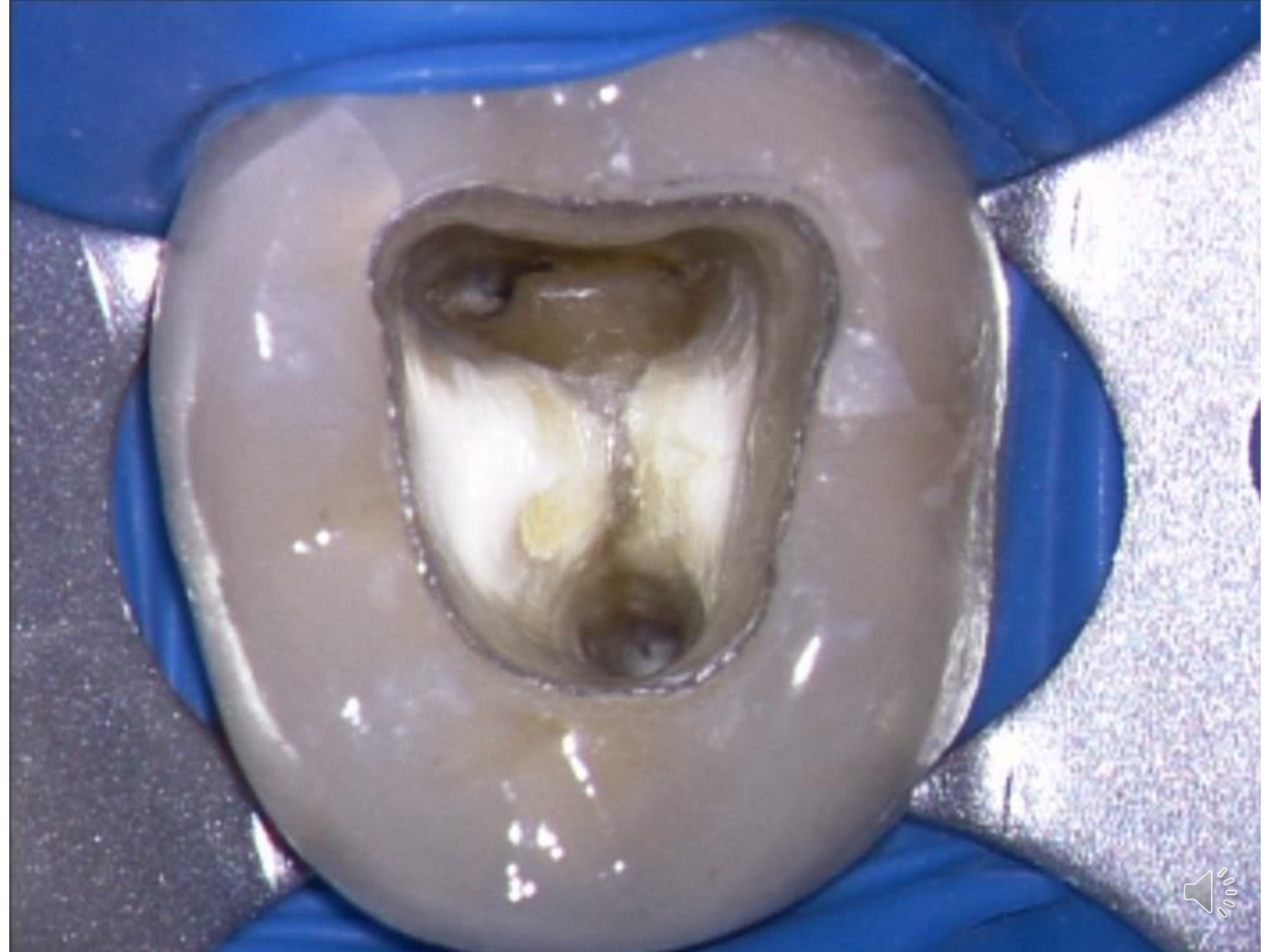After opening of the access and shaping of the root canal orifice



X-GATES








Rozšíření vstupu do kořenových kanálků

Ni-Ti nástroje

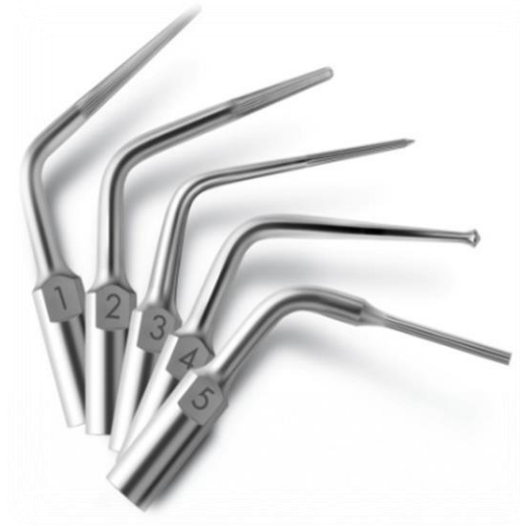S velkou kónicitou (kónusem)

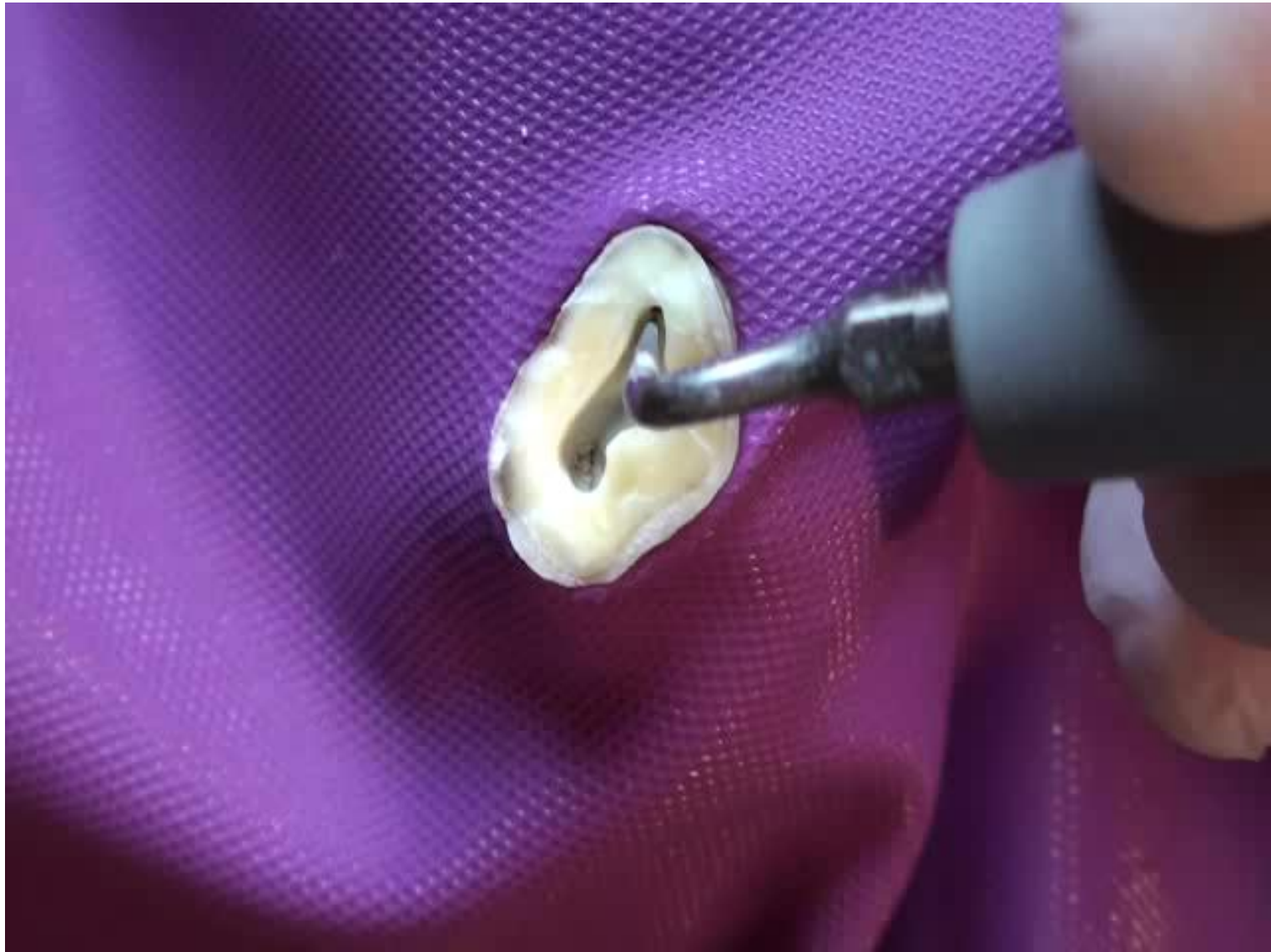Např.: ProFile O.S., ProTaper SX, IntroFile aj.



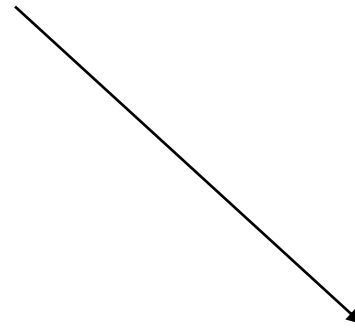
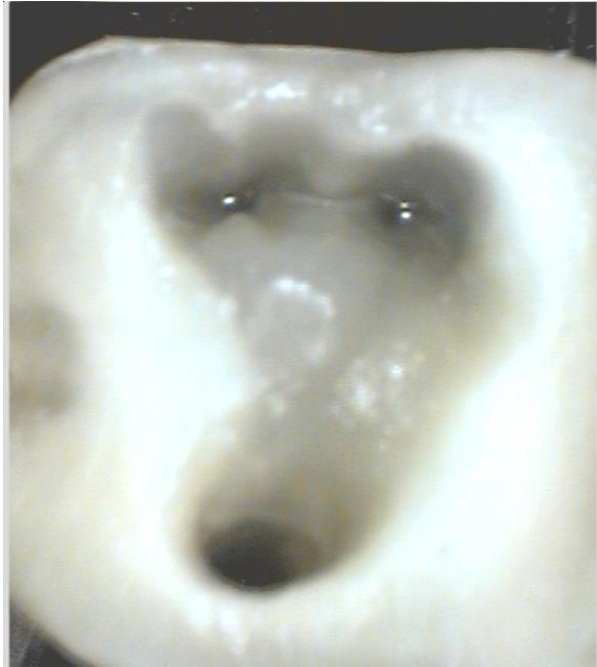Ultrasound

Less invasive – better overview





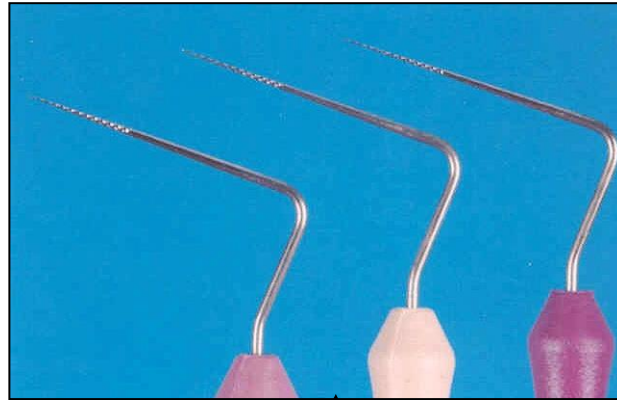




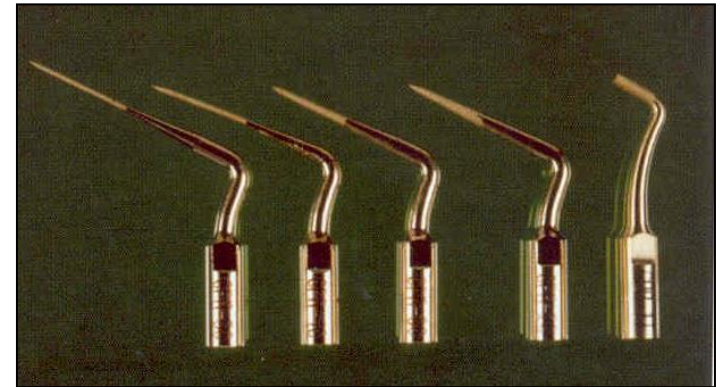
The pulp chamber correctly open



Finding and opening of rot canal orifices



← Endodontic probes
Microopeners

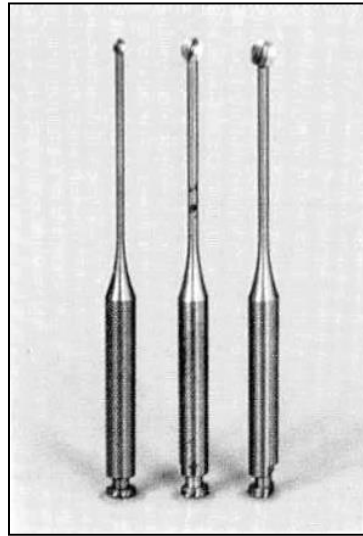


Ultrasound tips

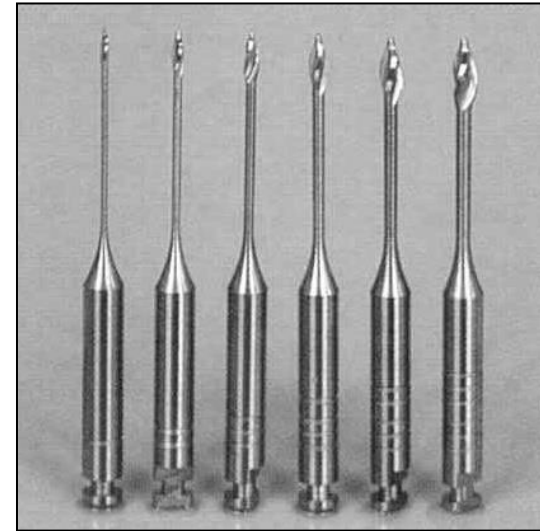
Finding and opening of root canal orifices



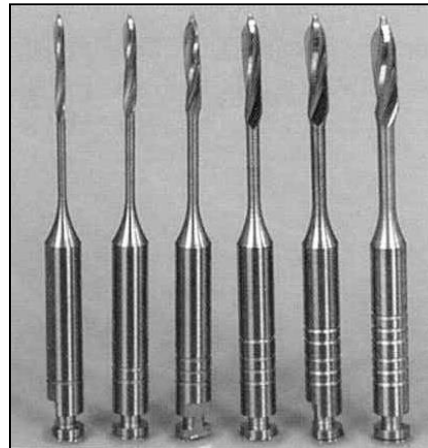
Rounded burs - balls



Miller's burs

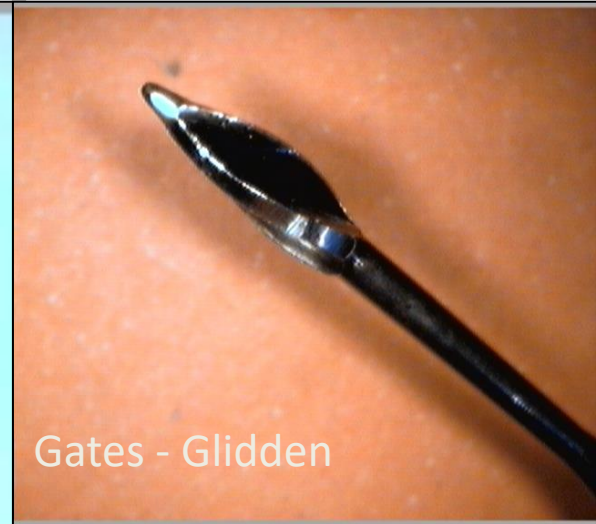
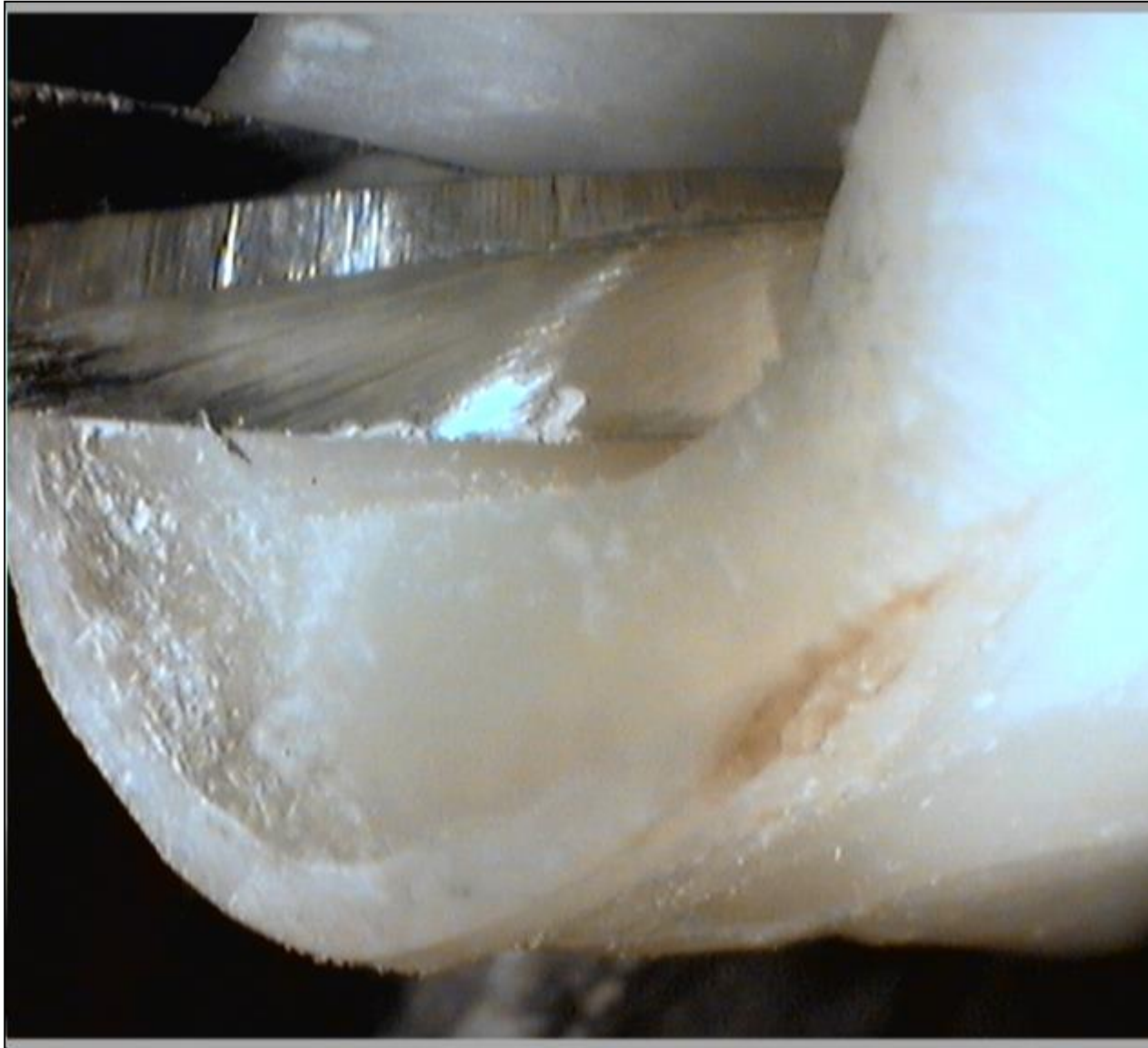
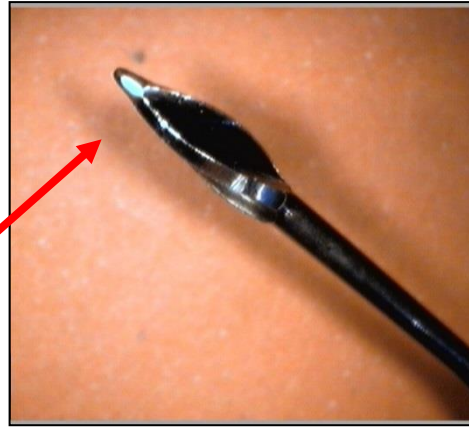
Gates Glidden's burs




Peeso ₃₃Largo







Gates – Glidden:
Blunt, non active tip

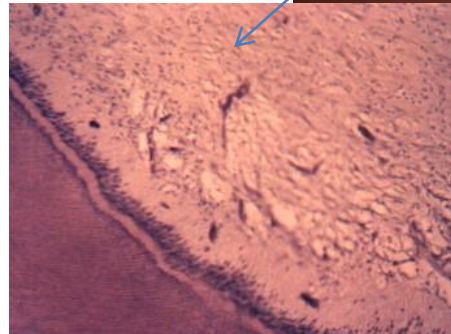
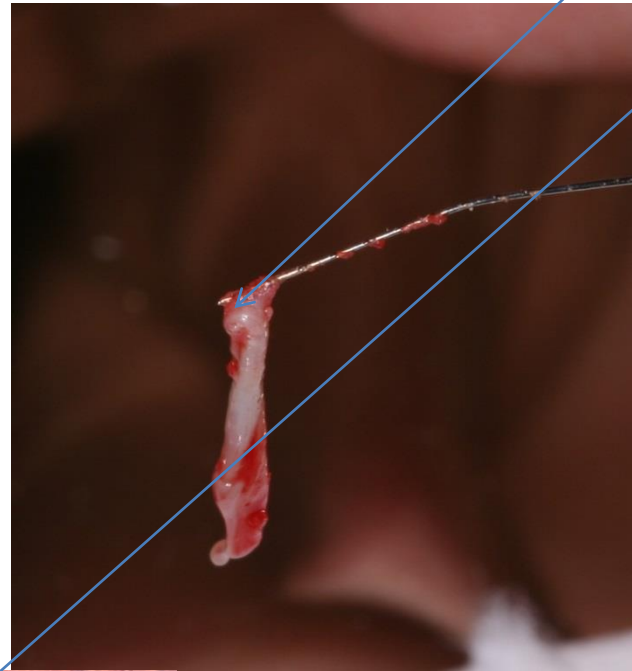


Programm point of breakage



Pulpextractor

Dental pulp



Soft wire
Prickles like harpune
Insertion
Rotation
Exstirpation



Initial flaring – glide path

- **Learn the morphology of root canals**
- **Minimize the risk of fractures**



Hand instruments

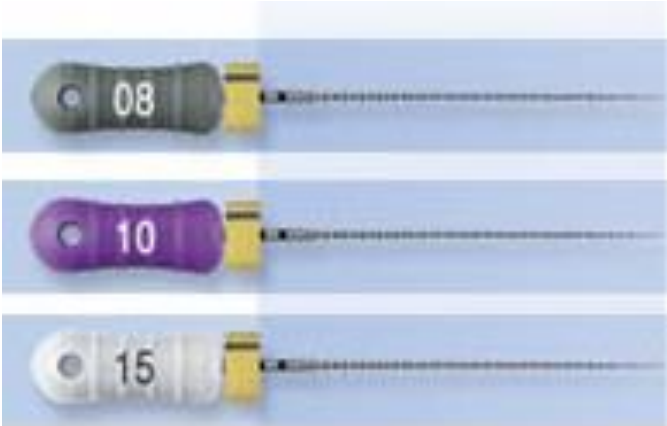C- file, C-pilot, ProFinder File etc.

Instruments should be precurved

Manual preflaring



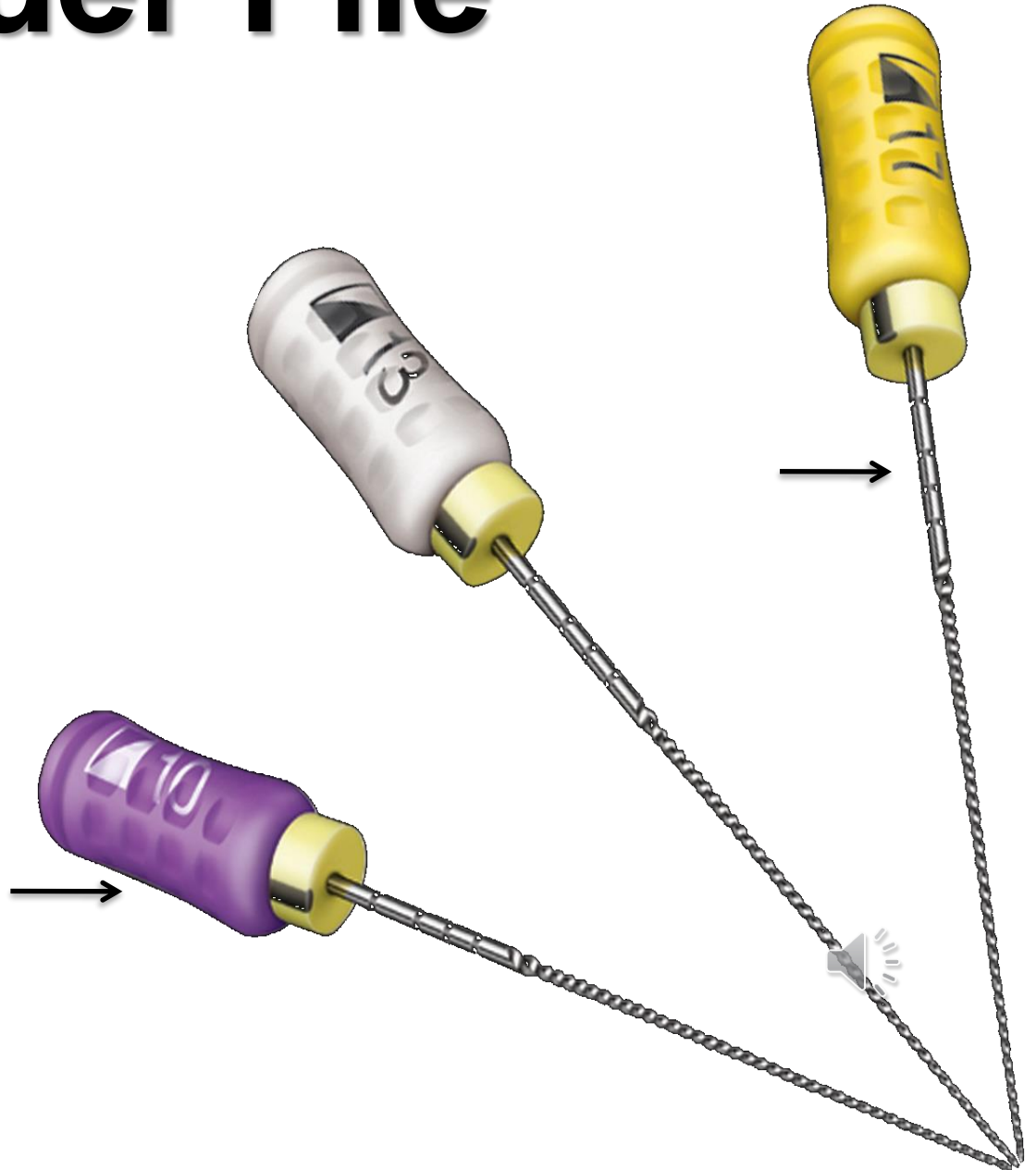
C- File



ProFinder File

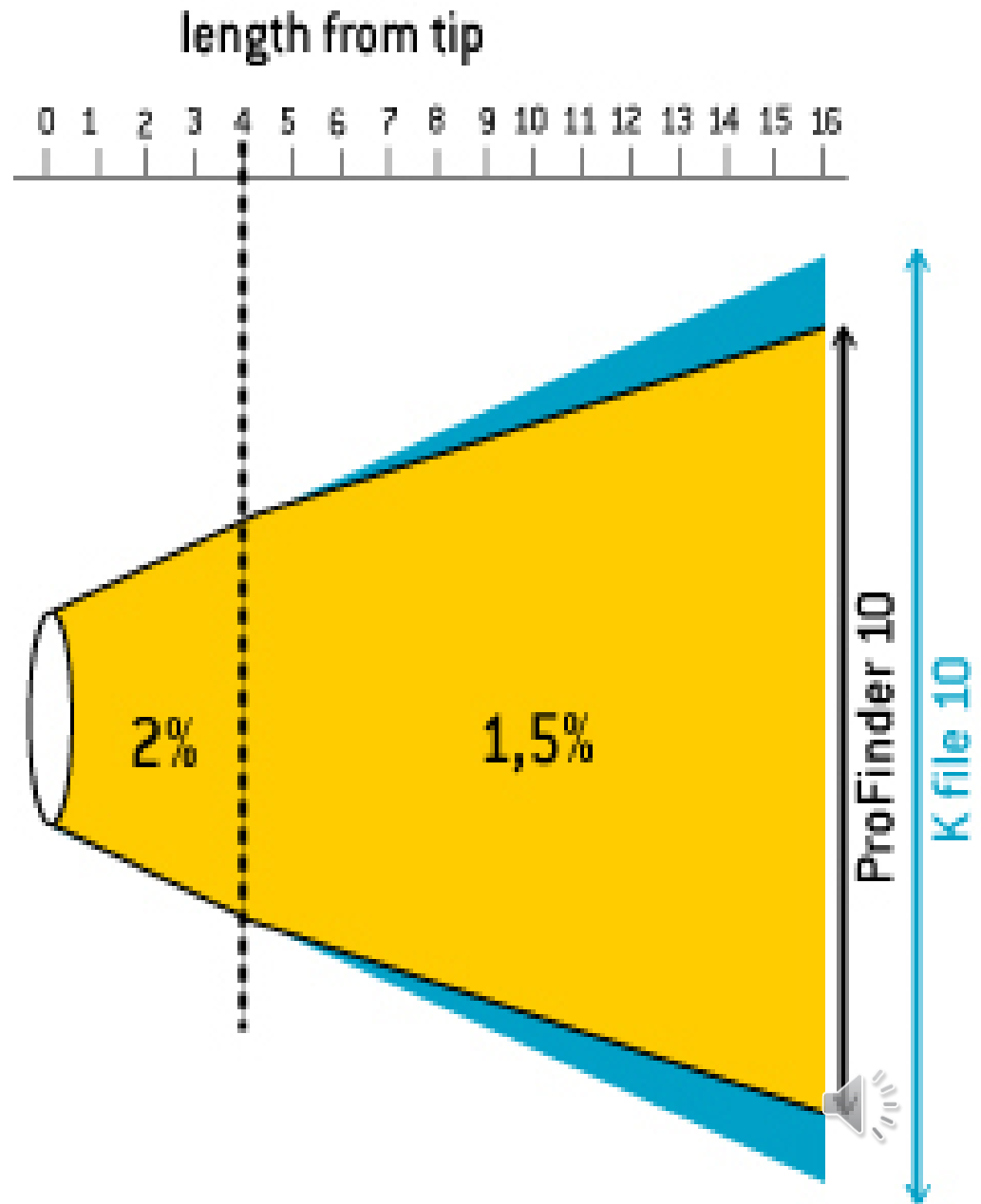
Regressive taper

Silicone grip,
regressive taper



ProFinder File

Regressive taper



Canal shaping

- Reamers (penetration)
- Files (shaping)

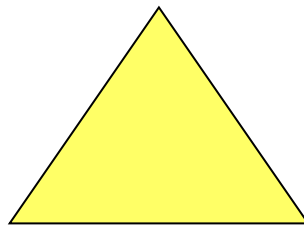


Reamer


K -reamer

Triangl or square wire spun

Symbol



Reamer

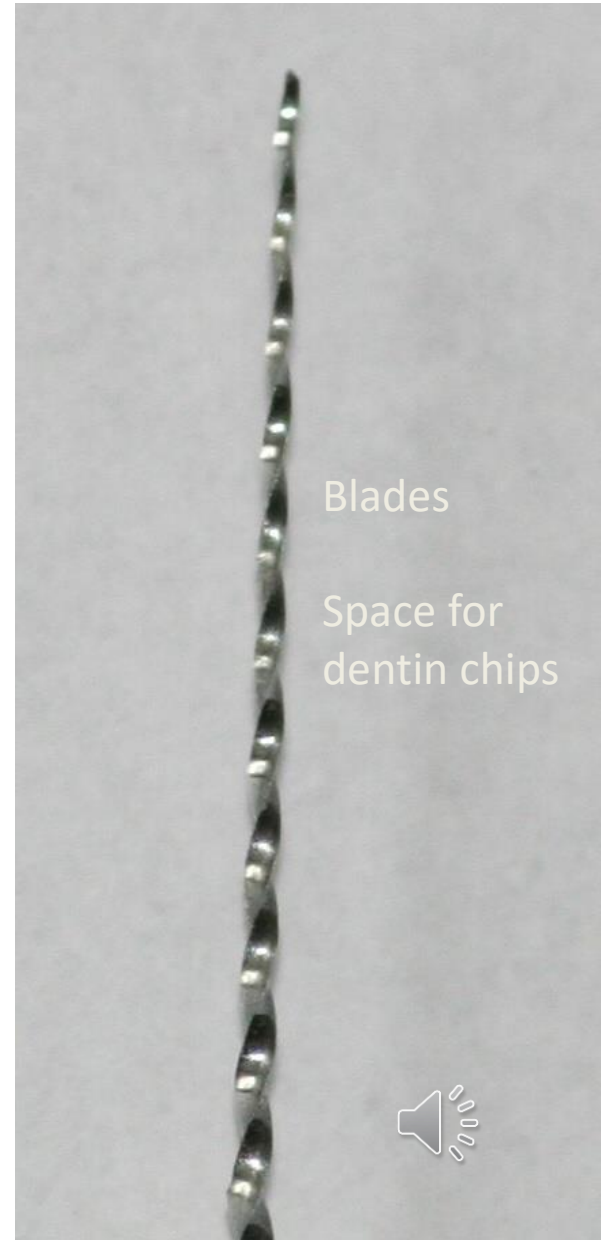


Bladed part

Shank

Stopper

Grip



Blades

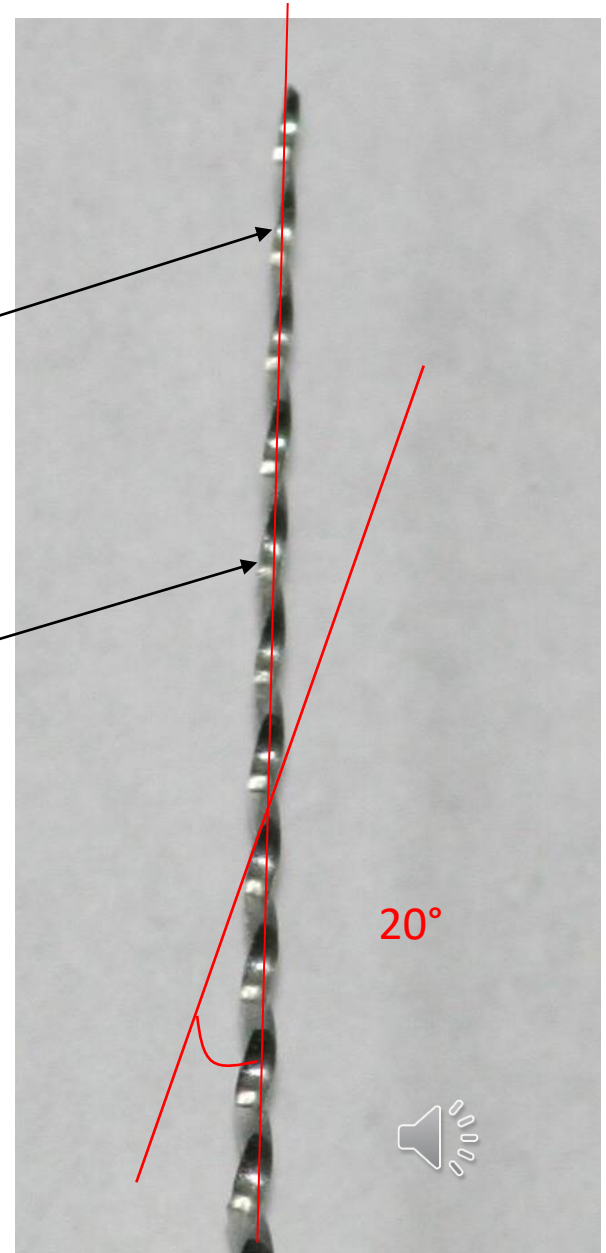
Space for
dentin chips

Reamer

Blades

Space for dentin chips

Rotation – reaming action - penetration



Reamer

Rotation (clockwise) – penetration

**Application of plastic material
(counterclockwise)**



Files


- 1. K-file**
- 2. K-flexofile, flexicut, flex-R**
- 3. K-flex**
- 4. H-file, S-file**



K file

Wire triangle or square

Symbol is always square




K-file

Filing


Also rotation

45° – 90°




K-flexofile, flexicut, flex-R

- Triangle wire always



Flexibility




K- flexofile a flex – R file: non cutting tip and first blades are blunt

Like K-file



K- flex



Rhombus


Two blades in action

Enough space for dentin chips

Flexibility, efficacy





K-file and reamer: the difference



H-file

= Hedstroem file

Ring





H- file

No rotation!!

Pull motion only!!

Risk of breakage in small sizes



ISO

- Diameter of the tip
- Length of the cutting part
- Taper



ISO standard

06

08

10

15

20

25

30

35

40

45

50

55

60

70

80

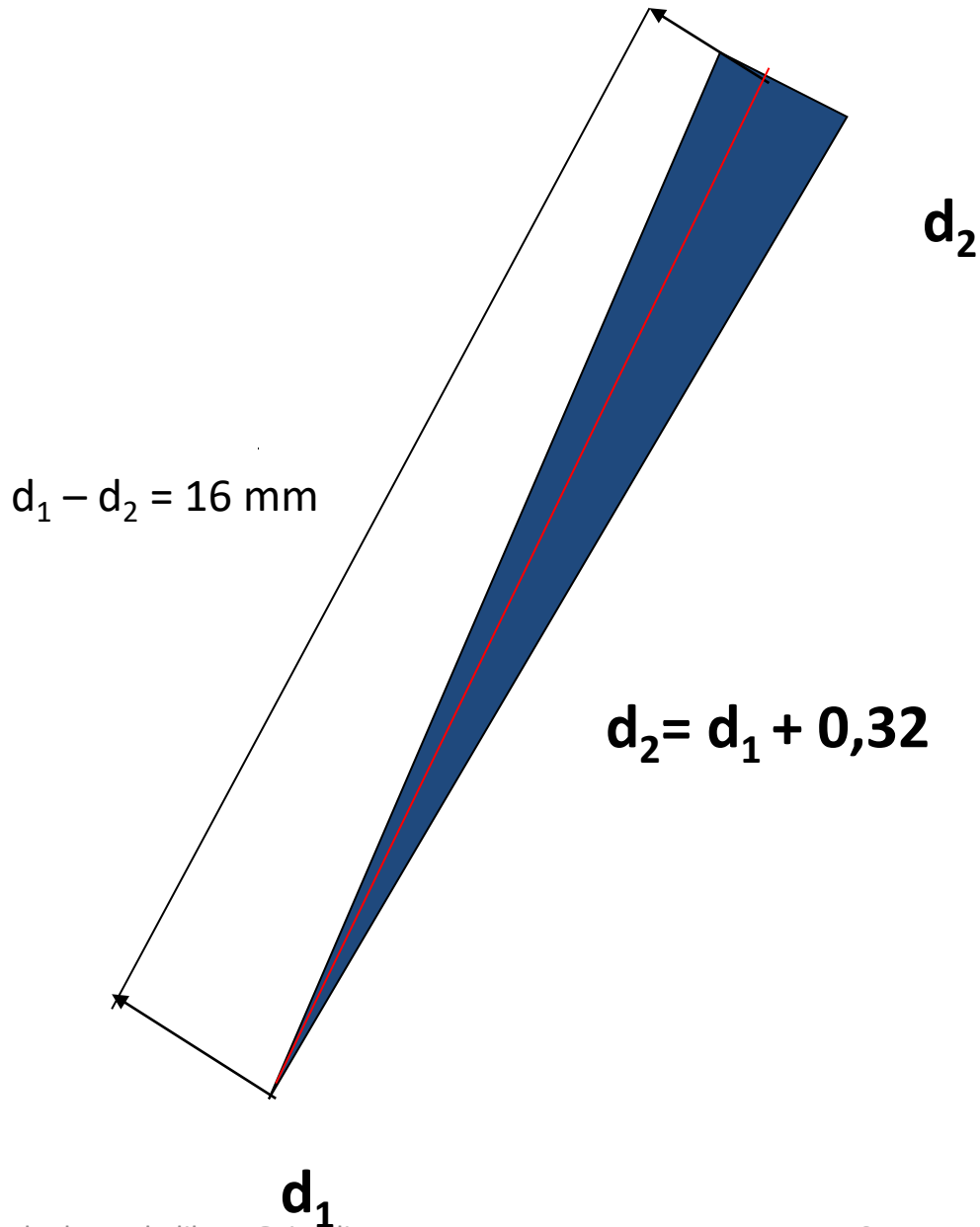
Size – diameter at the tip



Stainless steel



Taper 2%



d_2

$$d_2 = d_1 + 0,32$$

d_1



0,02 mm na 1mm

- **Niti alloy**

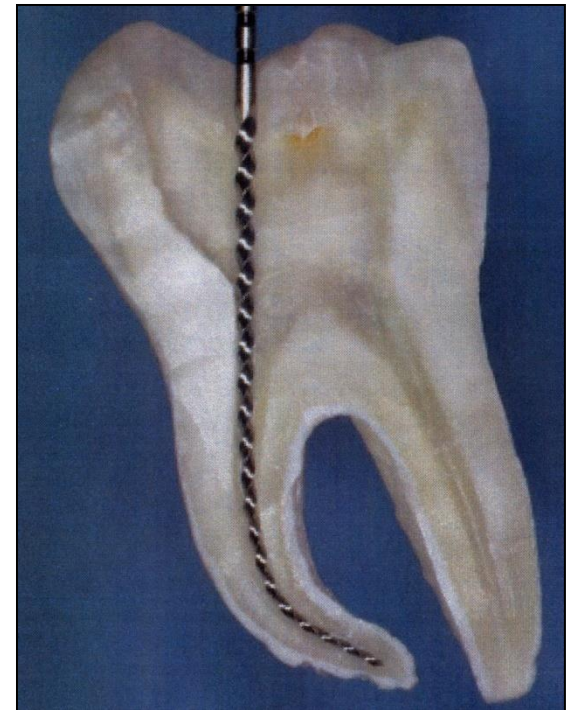
56 % nickel, 44% titanium,

60% nickel, 40 % titanium


flexibility

memory effect

Cutting efficacy?



Taper 4%



d_1

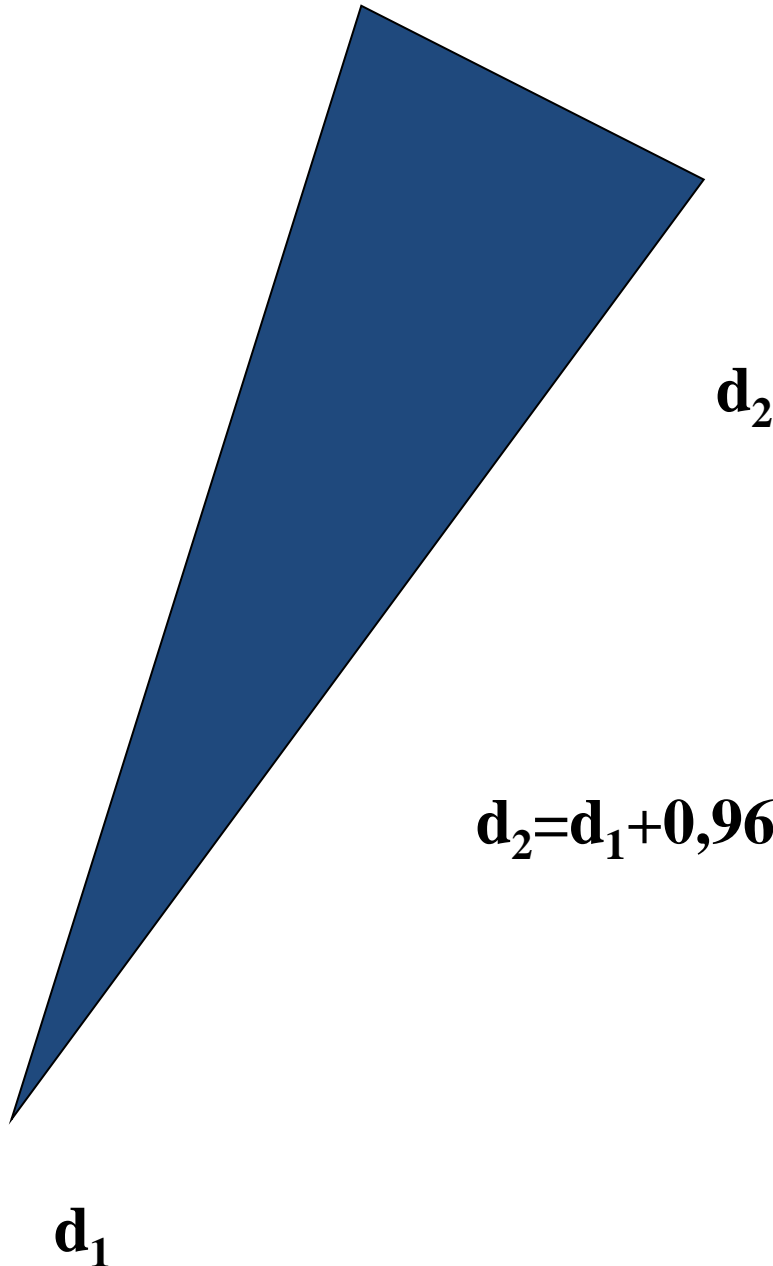
d_2

$d_2 + 0,64$

0,04mm na 1 mm



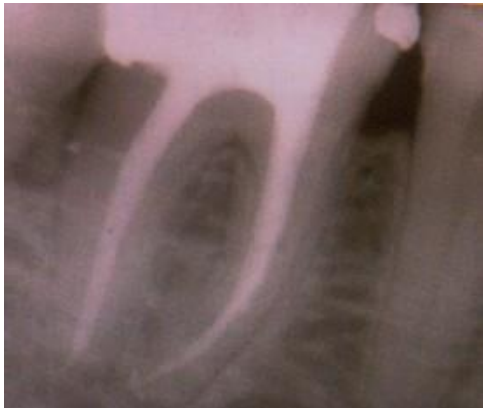Taper 6%



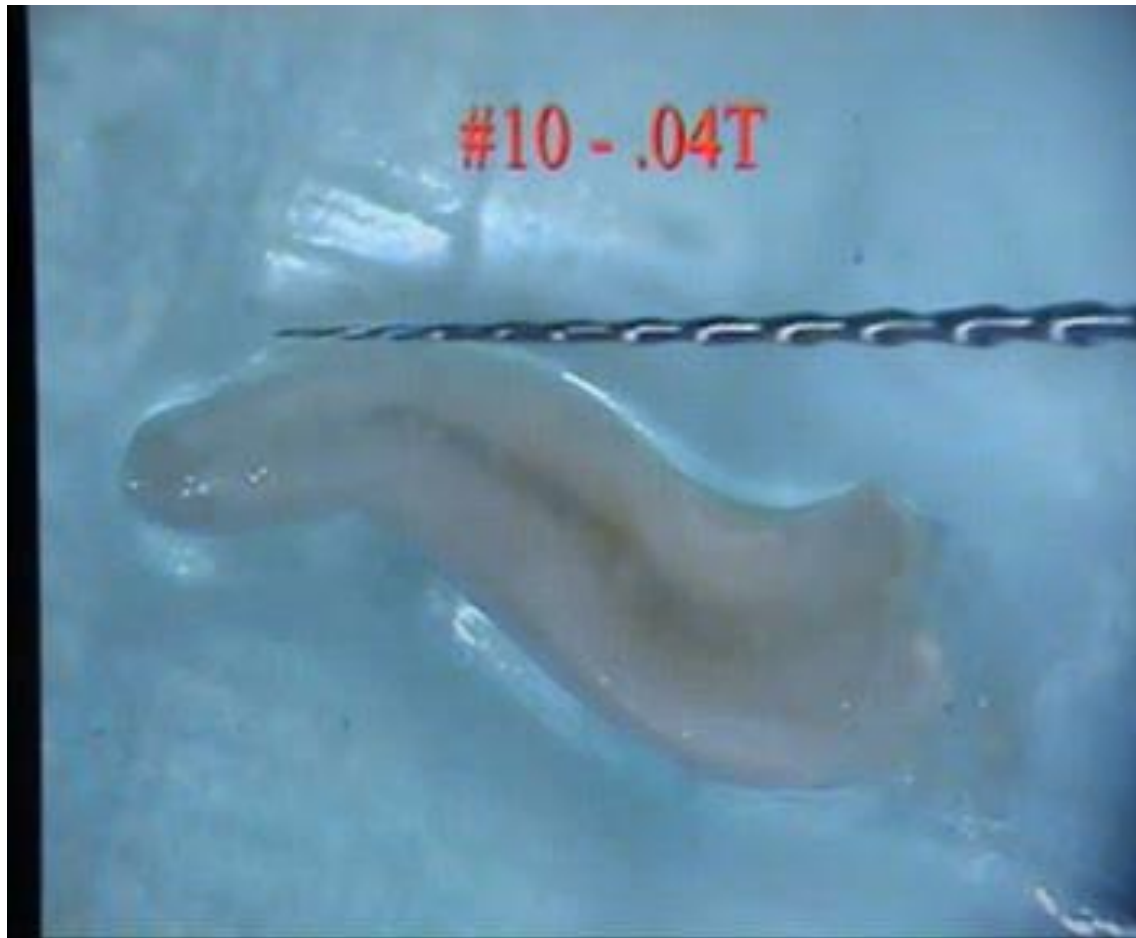$$d_2 = d_1 + 0,96$$

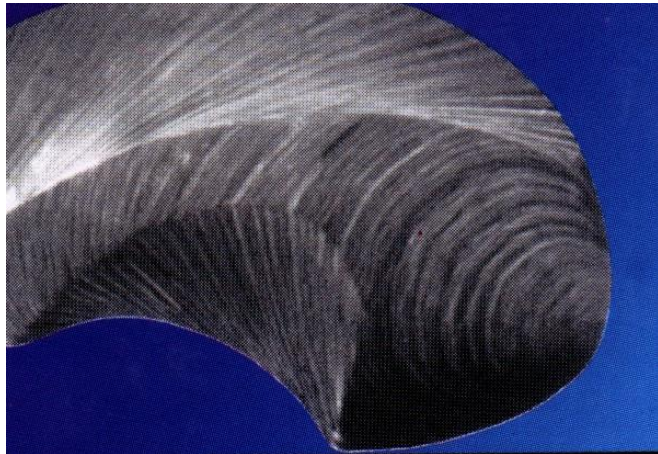


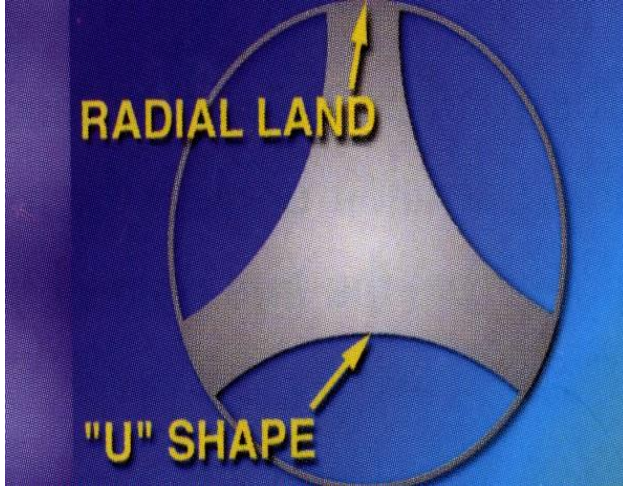


0,06mm na 1 mm



Vysoce kvalitní NiTi slitina

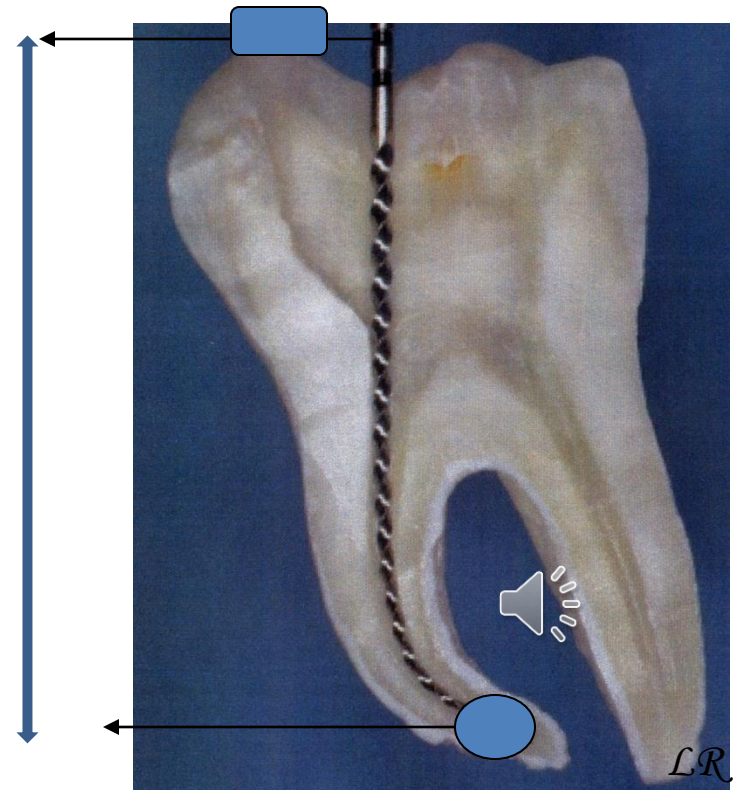






Working length

- Distance between the referential point and apical constriction
- Radiographically
- Apexlocators
- Combination



Why apical constriction

- Small apical communication
- Minimal risk of damage of periodontium
- Prevention of overfilling
- Prevention of extrusion of infection
- Good decontamination
- Good condition for root canal filling



Radiogram

X-ray with inserted root canal instrument

Safe length: average length of teeth reduced for
2 – 3mm

Tooth with clinical crown



Safe length

Average length of the tooth less 2 mm

- Maxilla:

I1 20

I2 18

C22-24

P20

M 18 mkk, 20 P



Safe length

Average length of the tooth less 2 mm

- Mandible

I 18

C20 -22

P18

M18



Procedure

- Instrument ISO 15 inserted into the root canal, stop at the referential point
- Estimation of location of apical constriction (1 – 1,5 mm distance from x-ray apex.


If difference in the radiogram more than 2 mm - repeat

If 2 mm or less – add to the safe length



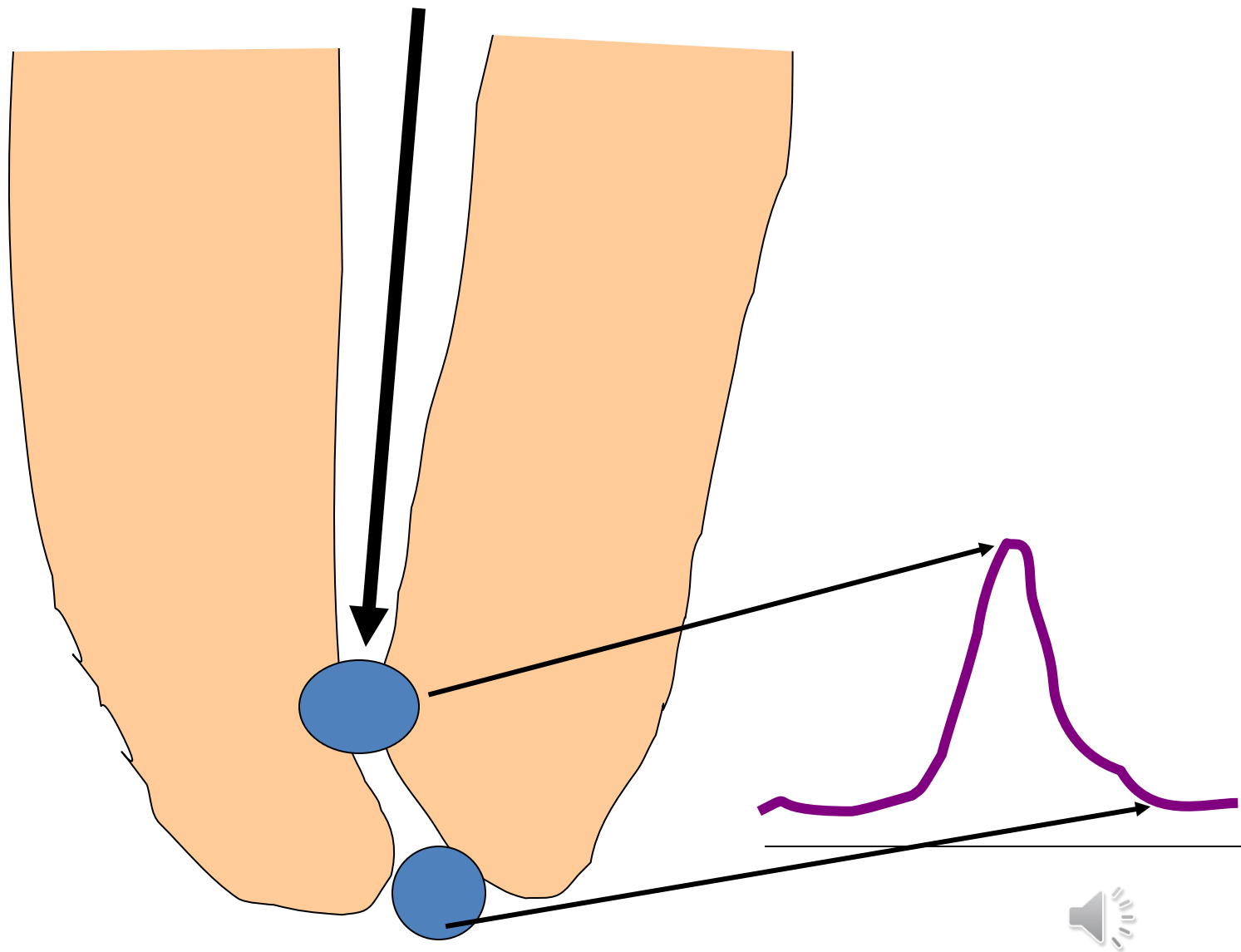
Endometry, odontometry

- Endometry

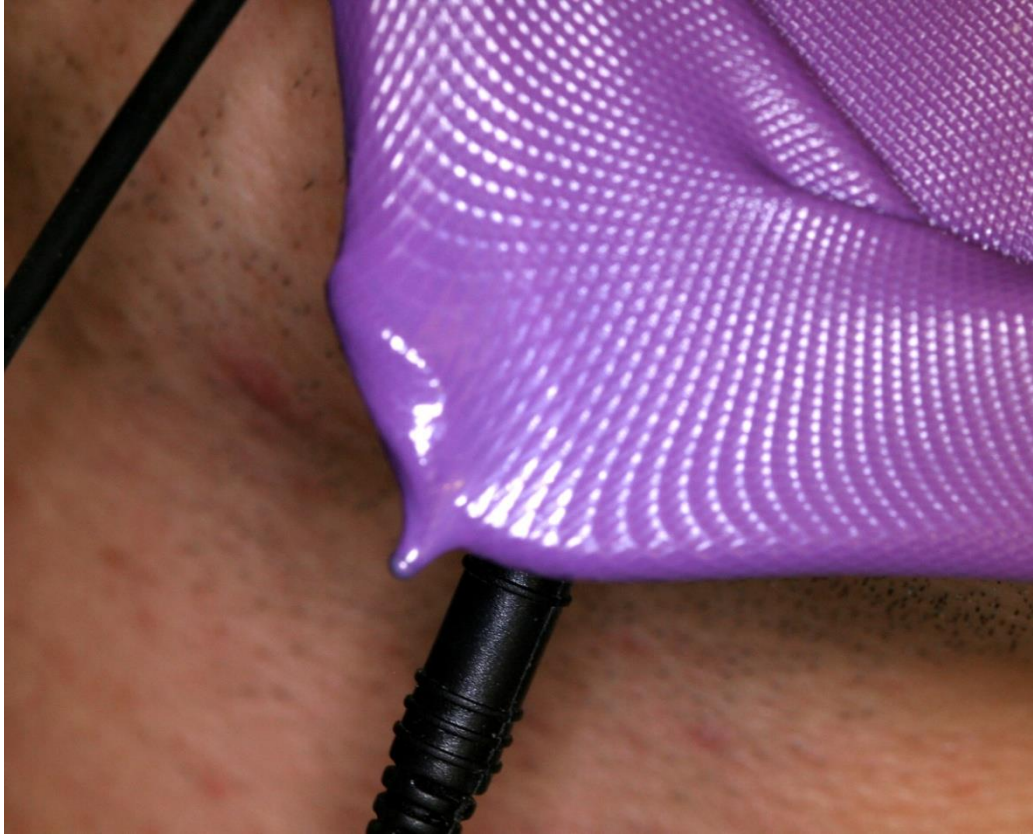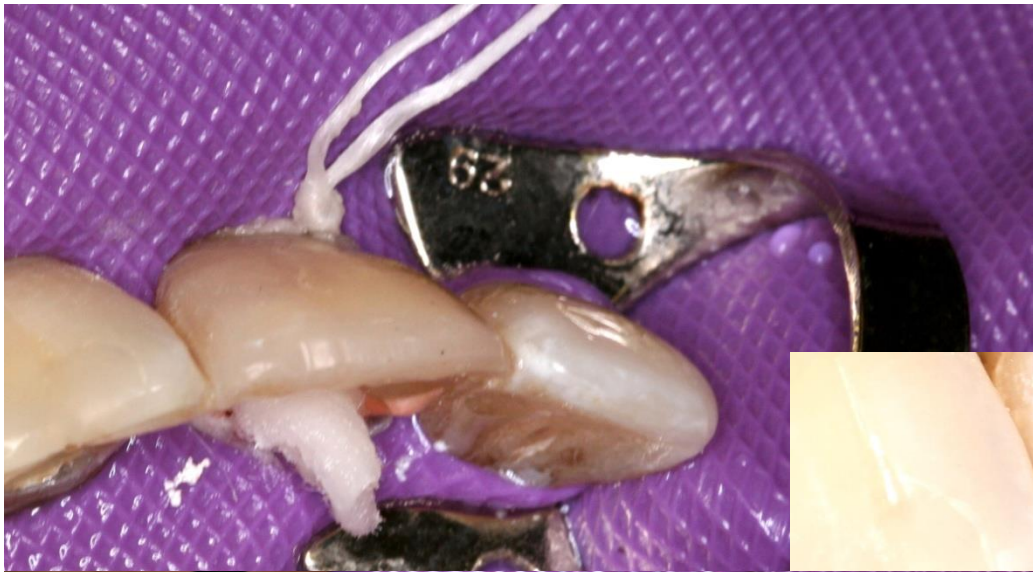


edevices based on measurement of electrical resistance

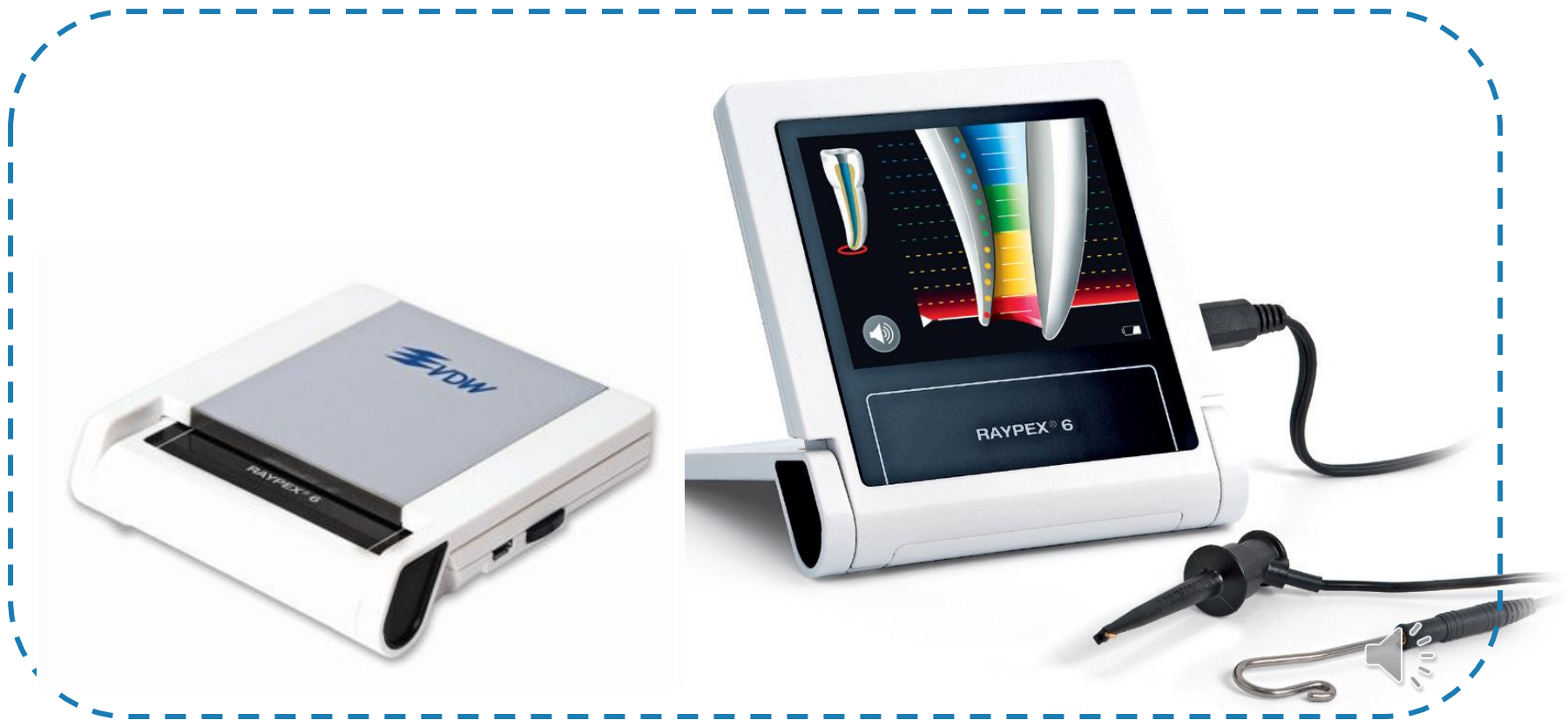



LR




RAYPEX® 6



RAYPEX® 6





Canal shaping and cleaning

- Basic rules
 - Elimination of infection
 - Enlargement till the apical constriction – simplify the shape
 - 6% taper of the root canal at the end of the shaping
 - Gangraena – clean chips



Canal cleaning

❑ Elimination of infection

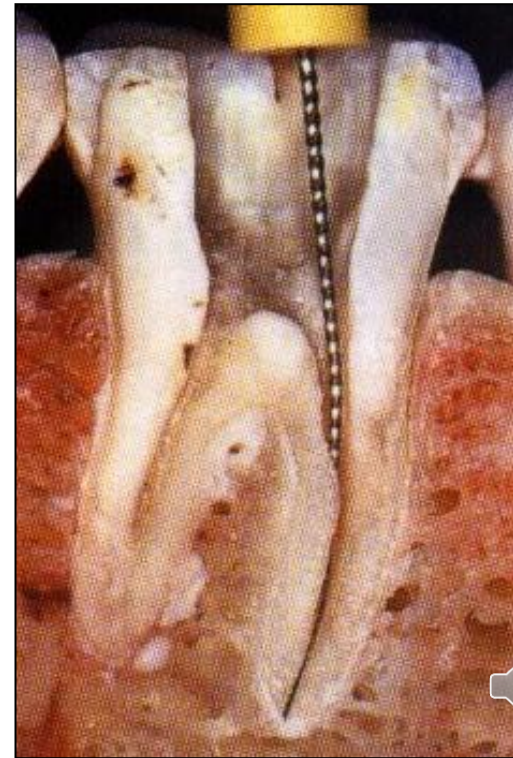
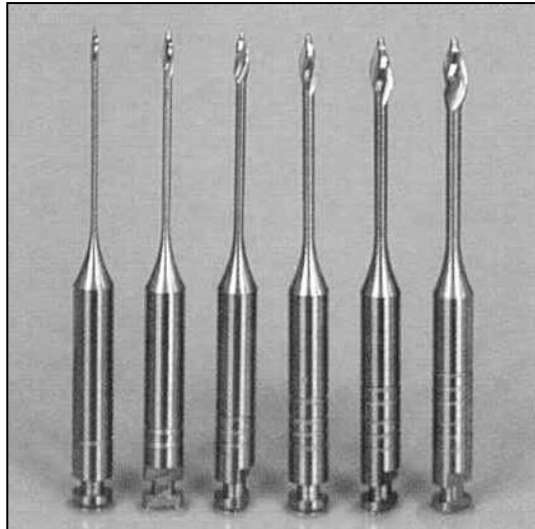
Mechanically – instrumentation, irrigation

Chemically – irrigation, temporary root canal filling

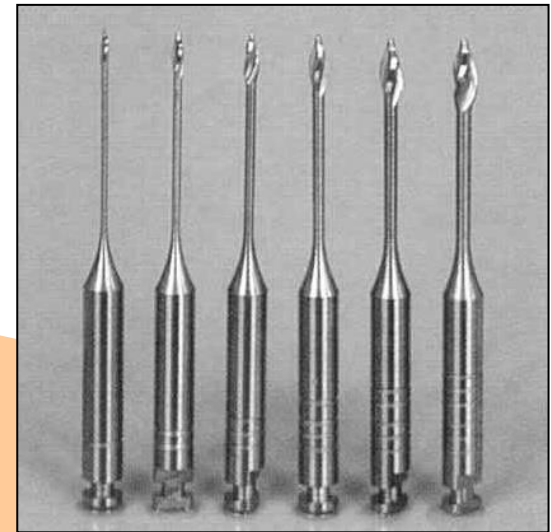
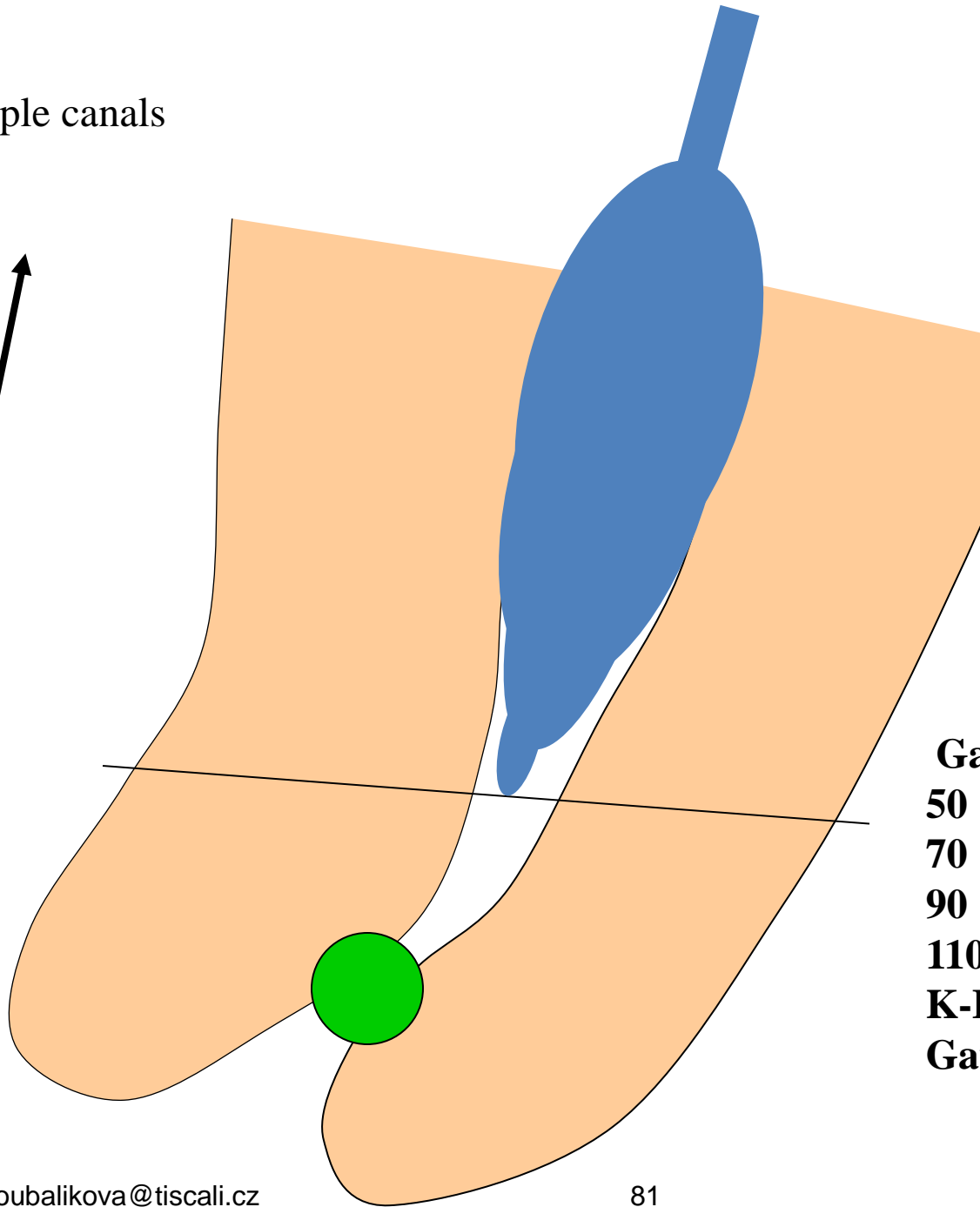



Canal shaping

Coronal flaring (Weine 1982, Peřinka 2003)



Simple canals



Gates Glidden

50

70

90

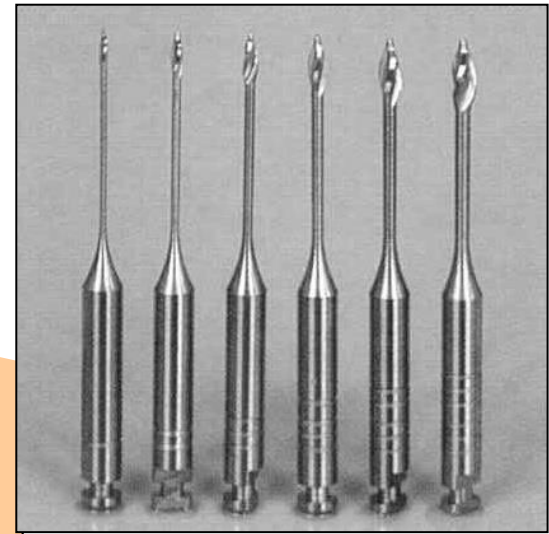
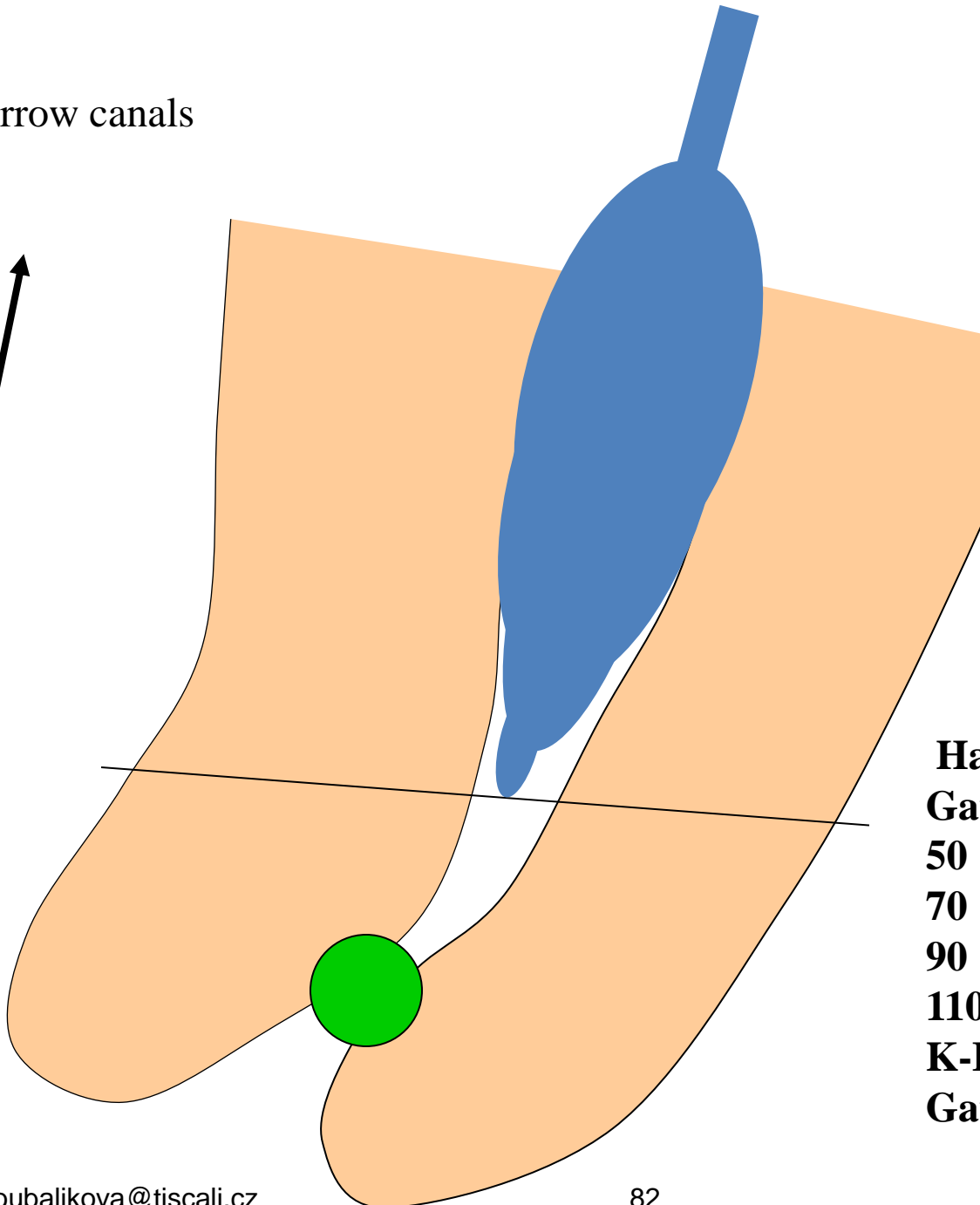

110

K-File 15

Gates Glidden 50



Narrow canals



Hand instruments till 50

Gates Glidden

50

70


90

110

K-File 15

Gates Glidden 50





NiTi systém
– decreasing size
speed 250 - 300 rpm




Importance

- Protection against fracture
- Better cleaning of coronal part (effective transport of debris)
- Effective irrigation
- Better conditions for measurement of working length
- Better conditions for apical preparation
- Less risk of complication



Shaping technique

- Rotation



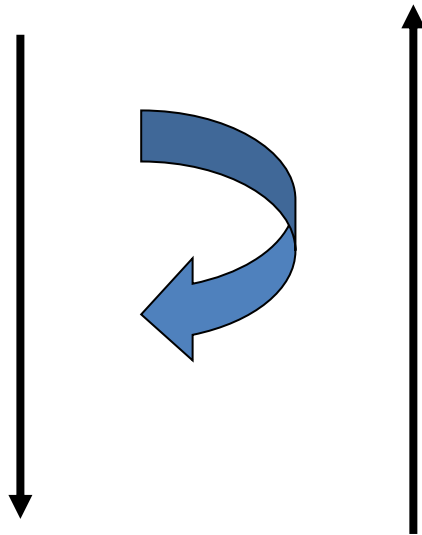
K – reamer

K- file



Shaping technique

- Rotace 45° tlak and pull motion



K – reamer

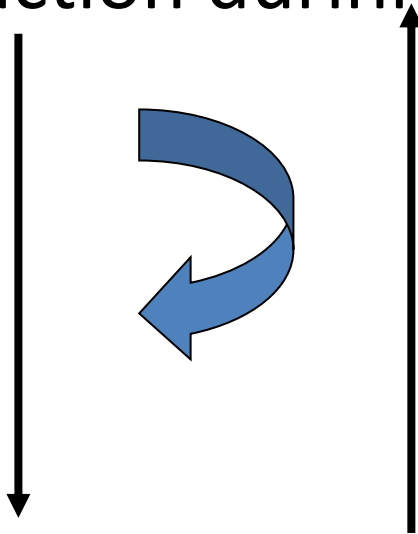
K- file

Risk of ledging
Zip, elbow effect
Via falsa - perforation



Shaping technique

- Filing - push and pull motion. The file is in action during the pull motion



H- file

S- file

K – file

Risk of periapical infection

Risk of plug



Balanced force technique – 1st step

- Insertion of the instrument one ISO size bigger than apical size of the root canal until the instrument comes to the contact with the root canal wall. Rotation 90 – 180° Very slight pressure – the instrument is reaches the WL.



Balanced force technique – 2nd step step

- Rotation of the instrument counterclockwise 180 -270°, pressure forward. Dentin chips are broken.



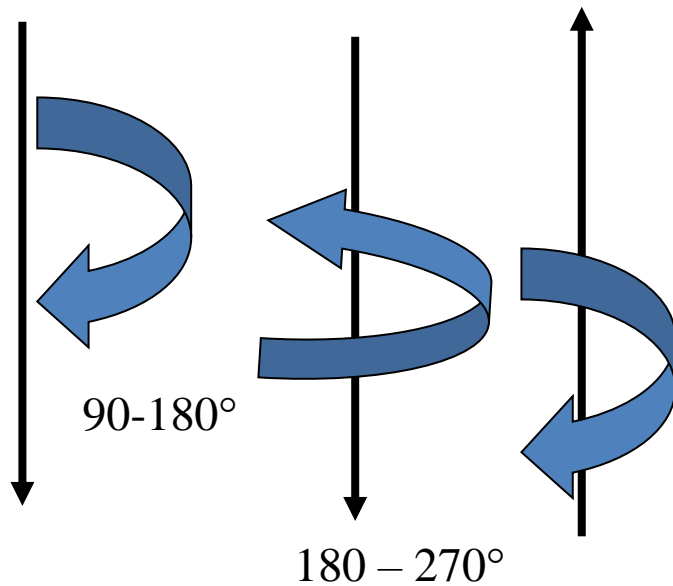
Balanced force technique – 3rd step

- The instrumentid is being pulled out and is rotating clockwise – the debris is being removed.



Shaping technique

- Balanced force



K- flex- O- file

K – flex- R - file



Methods of shaping

Combination of various technique

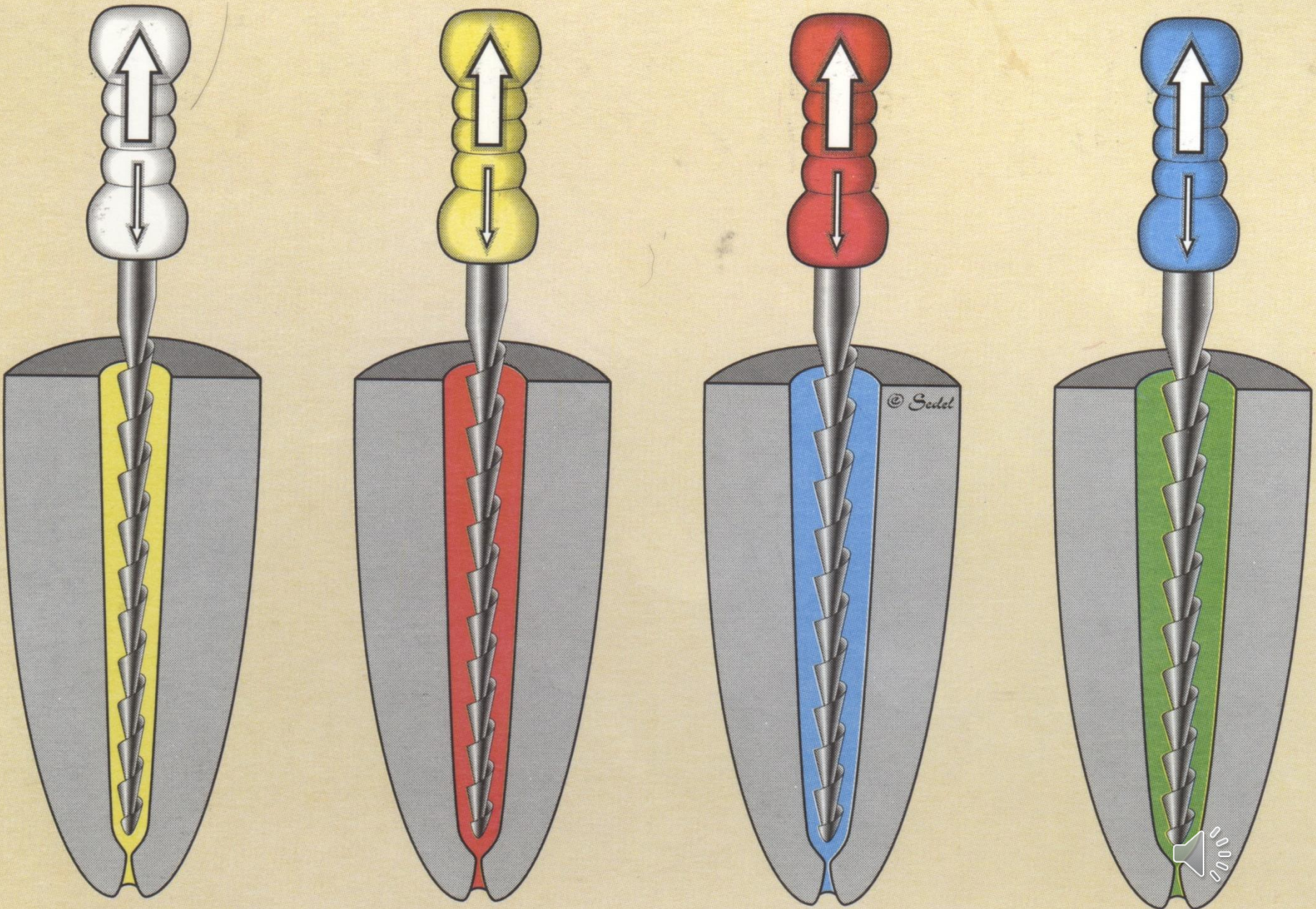


Methods of shaping

Circumferential filing

Filing around the root canal – circumferentially.
The shape of the root canal is kept.





Methods of shaping

- Step back

H-file

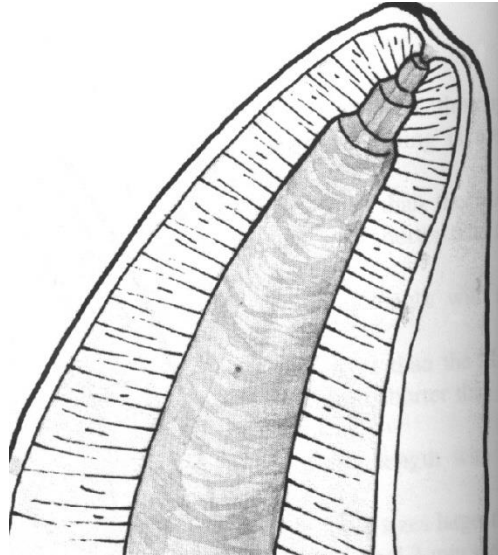
K-file

Apical stop

K-flexofile

Prevention of the ledge

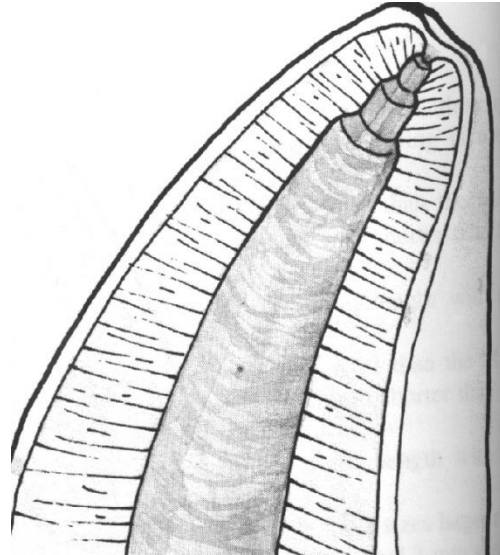




2% taper of the root canal instrument
6% taper of the root canal

30	Apex	0,30 mm
35	1 mm	0,35 mm
40	2 mm	0,40 mm
45	3 mm	0,45 mm





Initial flaring

Establishment of WL

Shaping till the WL, the last instrument MAF

Shortening of next instruments (2-3 instruments)

Final flaring with the MAF



Methods of root canal shaping

- Modified double flared with balanced force
 1. *Coronal flaring)*
 2. *Apical preparation balanced force*
 3. *Step back*
 4. *Final flaring (filing)*



Method modified double flared

- I. Opening of root canal
 - Coronal third – coronal flaring
- II. Apical preparation

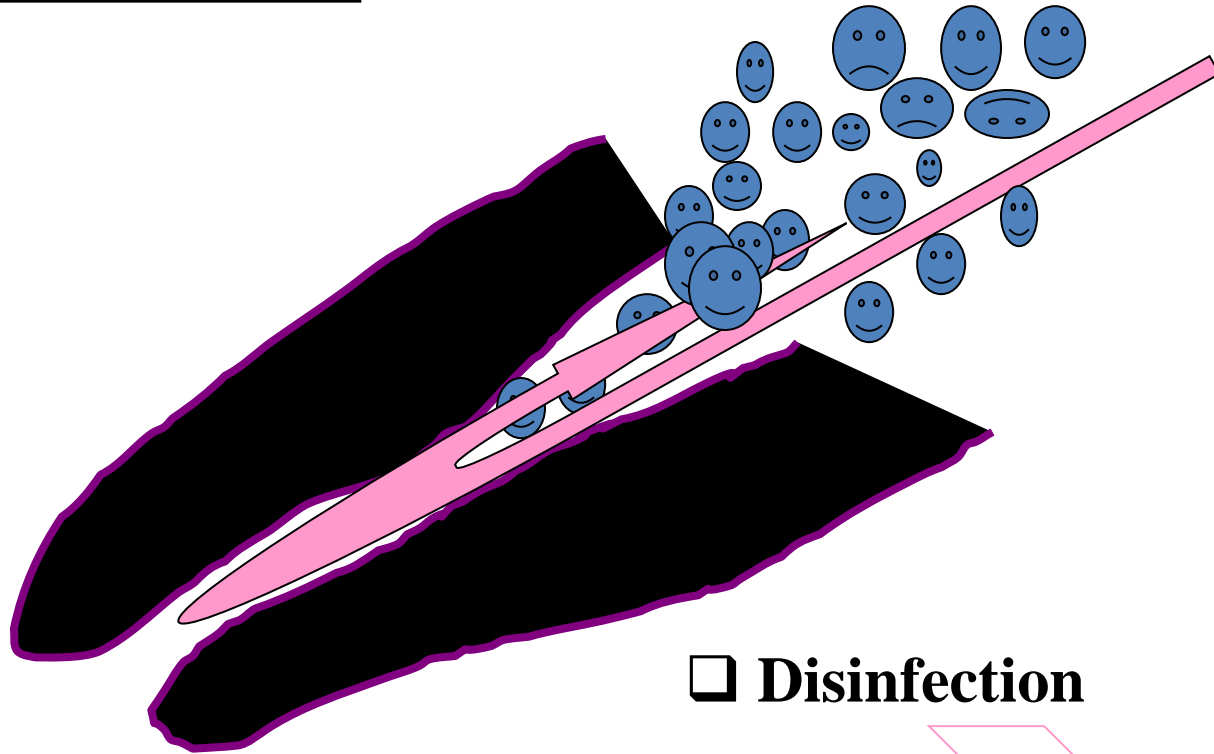
Cathetrization, measurement, shaping till ISO 30 – 35 balanced force. Master file – MAF (till WL)

- III. Step back
- Final flaring (MAF)




Root canal irrigation

Debris removal




Disinfection






ISI LEI 5.0kV X2,000 10 μ m WD 8.1mm



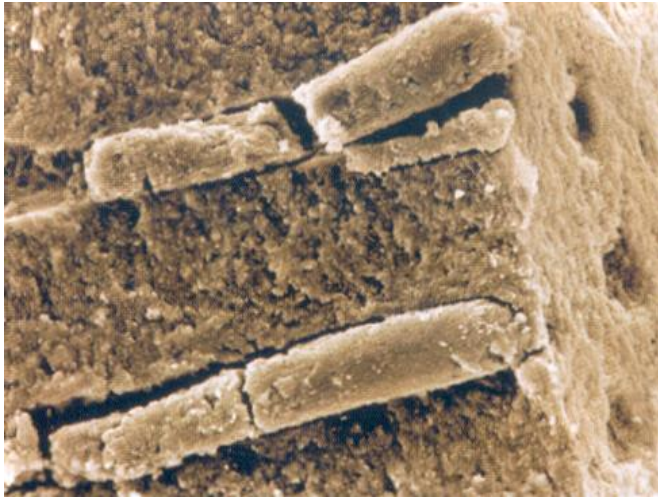





CANTATORE G.

Irrigation Canalaire: avantages
potentialisation et sequence operative

Endo Contact 1999 - 5:13-21



NaOCl



Irrigants

- NaOCl (sodiumhypochlorit)

2 – 6%

- Oxidation and chloration
- Irritation, risk of heamorrhagic necrosis



Irrigants

- Chlorhexidin

0,12% -0,2% (a 2%)

Long term binding to surfaces

Good antimikrobial spectrum

No dissolving effect



Irrigants

- EDTA
17%

No antimicrobial efec

Dissolves smear layer

It is a part of irrigation protocols

It is a components of lubricants tohether with urea peroxide and carbopol



Irrigants

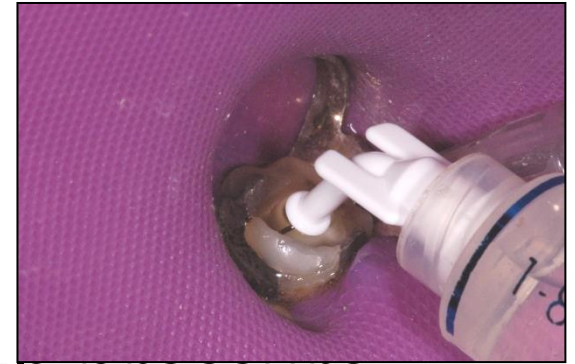- Saline solution

When an inert irrigants is necessary
(surgical treatmen, widely open apex)



Syringe and canula

- Blunt, side perforations, flexible tip
- Screw
- Irrigant must not be applied with pressure
- The liquid is streaming in the root canal



Activation of irrigation

- Increasing of effectivity

Vibration

Increasing of temperature

Decomposition of sodiumhypochlorite



Activation

- Hydrodynamic
- Sonic
- Ultrasonic
- Laser



Activation

- Sodium hypochlorite (3x 20s)
- EDTA (1 min)
- Activation of other irrigants without any effect



Protocol of irrigation

- Hand instrumentation - NaOCl
- Power driven instrumentation – NaOCl.
- Recapitulation – NaOCl
- Final protocol – EDTA + NaOCl + activation
- Amount of irrigants – 10ml/root canal, velocity 1ml/min
- *Never combine sodium hypochlorite and chlorhexidim*

