


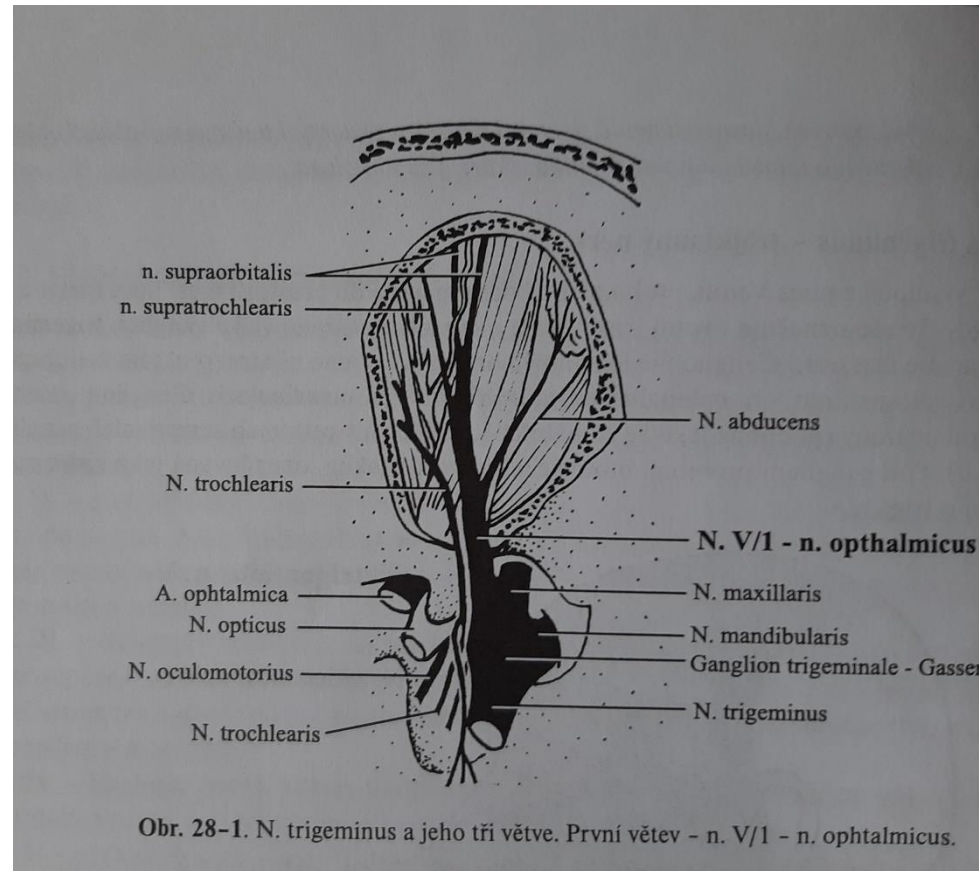
Nerves supply the orofacial region, pain



N. supply the orofacial region

- I. Nn. olfactorii
- II. N. opticus
- III. N. oculomotorius
- IV. N. trochlearis
- V. **N. trigeminus**
- VI. N. abducens
- VII. **N. facialis**
- VIII. N. vestibulocochlearis
- IX. N. glossopharyngeus
- X. N. vagus
- XI. N. accessorius
- XII. N. hypoglossus

Nervus trigeminus

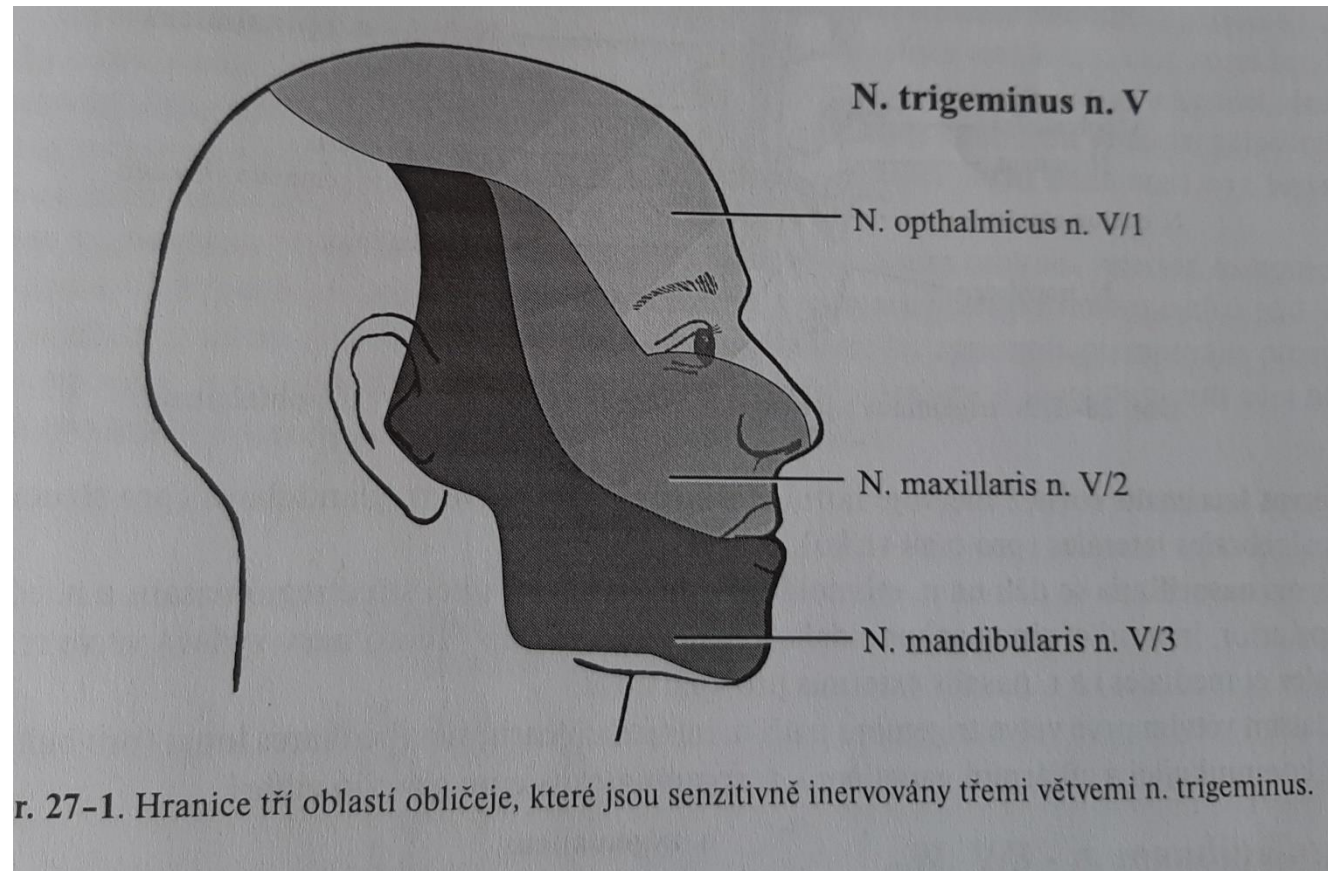


N. Trigeminus – three main branches

- N. ophtalmicus
- N. maxillaris
- N. mandibularis

- Sensitiv and motoric part

Nervus trigeminus zones of the supply



N. ophthalmicus

- Goes through fisura orbitalis superior into the orbita.
- It supplies: skin of: the forehead, the upper lid, the vertex, back of the nose as well as a part of the nasal mucosa.

N. maxillaris

- Goes through f.rotundum into fossa pterygopalatina from where its branches continue.
- Zones: skin of the temple, lateral part of the nose, lower lid, upper lip, teeth in maxila, oral and nasal mucosa including maxillary sinus. Also part of dura mater (the middle part).

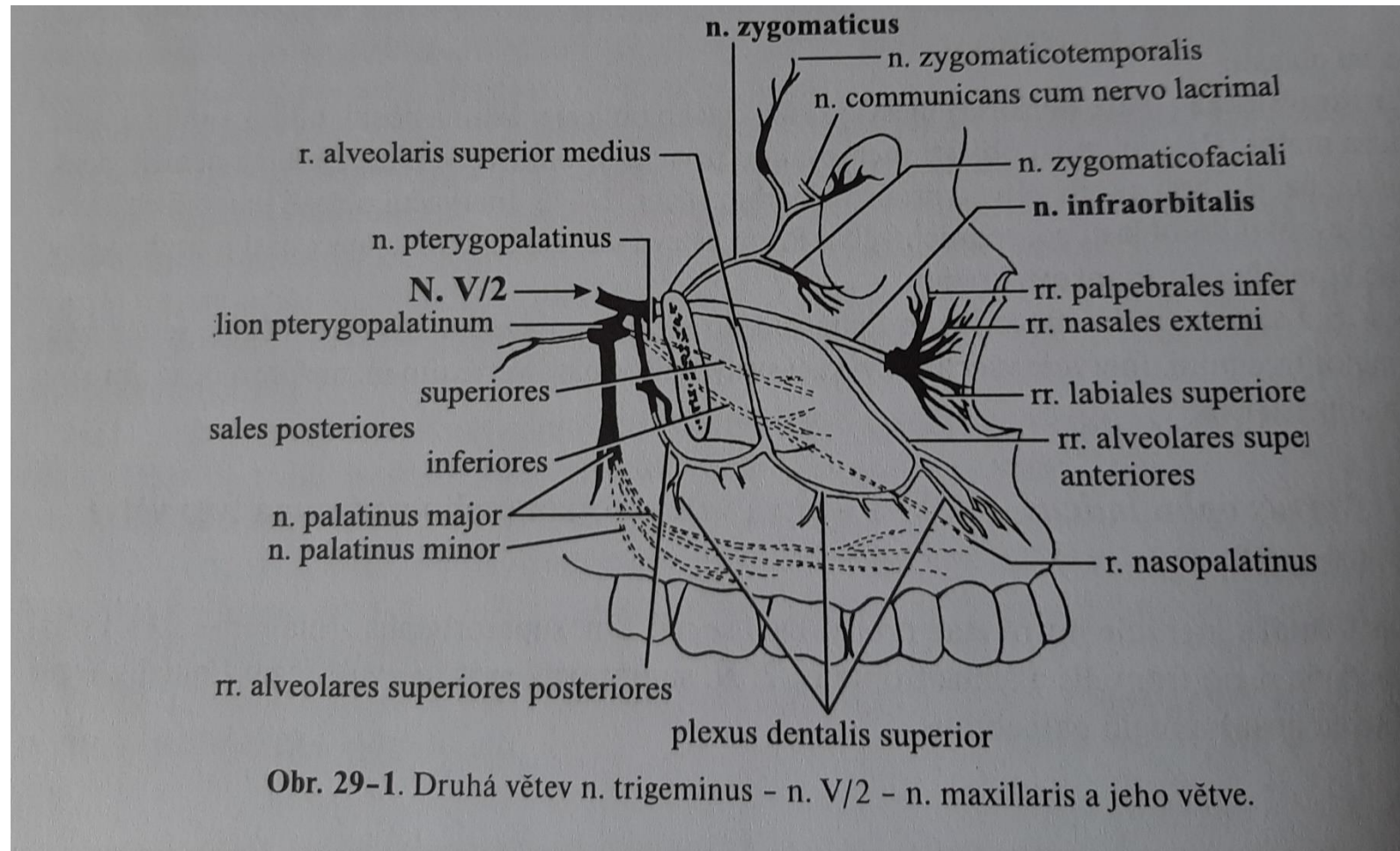
N. maxillaris branches

- 1. R.meningeus
- Nervi pterygopalatini (rr. Nasaes)
- N palatinus major a nn palatini minores
- N. infraorbitalis –rr.alveolares superiores posteriores

N. Infraorbitalis branches

- R. alveolaris superior medius - plexus dentalis superior
- Rr. alveolares superiores anteriores
- Rr. nasales interni
- Rr. cutanei

N. maxillaris and its branches



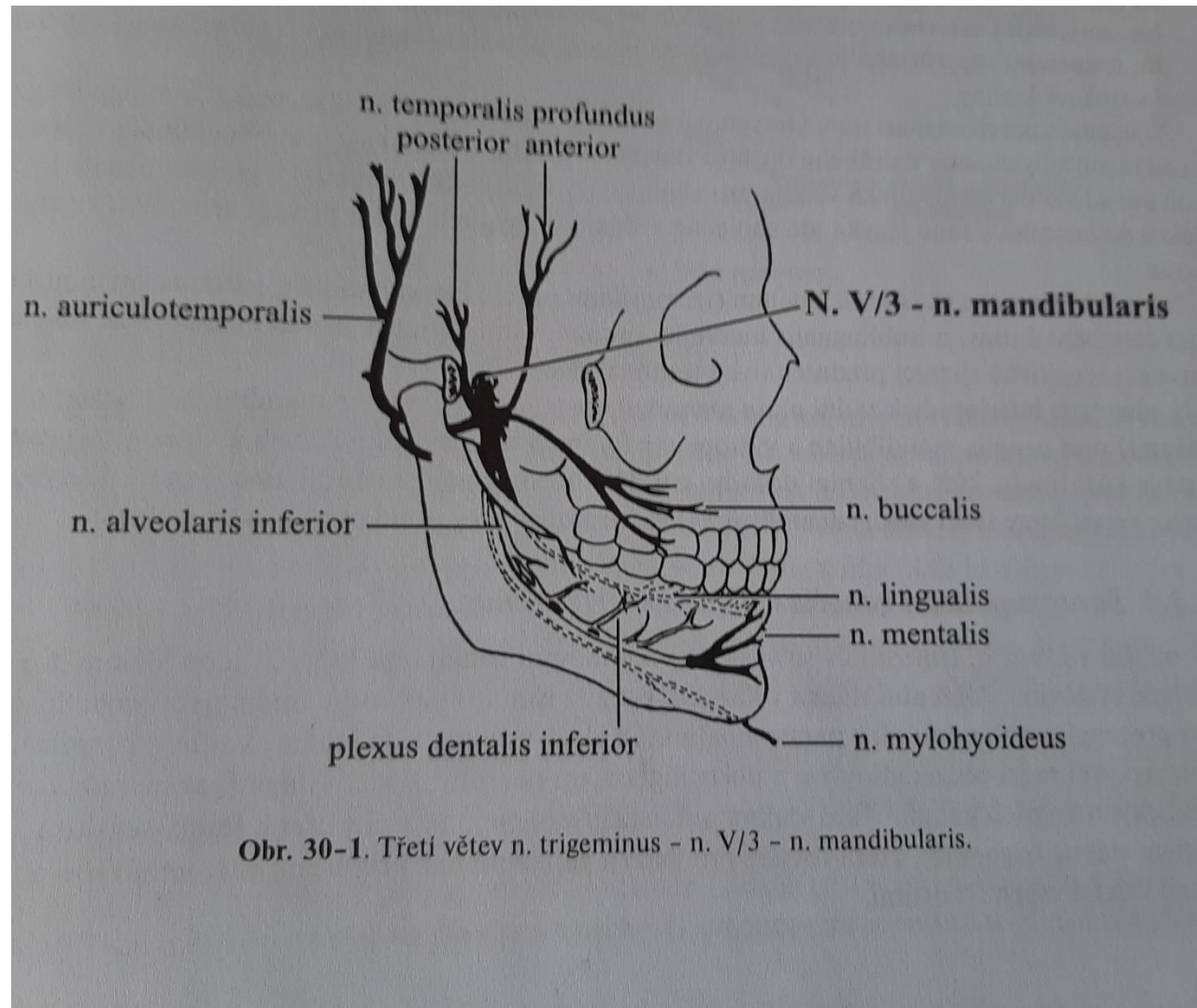
N.Mandibularis - branches

- N. mylohyoideus
- N. buccalis (it supplies skin of the cheek, goes through m. buccinator but this muscle is supplied by n. facialis). N. buccalis can be also a branch of the n. infraorbitalis.
- N. auriculotemporalis
- R. communicans cum ganglio otico, rr.comunicantes cum nervi faciali,rr.parotidei, rr. articulares,n.meatus acustici interni aj.

N. mandibularis - branches

- N. lingualis: many branches, it terminates as rr. linguales supplying the lingual mucosa in the anterior part.
- N. alveolaris inferior: goes into foramen mandibulae and continues in canalis mandibulae till the foramen mentale, from where the terminal branches go to the skin of the lip. Branches:
 - N. mylohyoideus
 - Plexus dentalis inferior
 - N. mentalis

N. mandibularis – zones of supply



Vegetative ganglia next to the n. trigeminus

- G. ciliare – orbita
- G. pterygopalatinum - fossa pterygopalatina
- G. oticum – next to f.ovale
- G. submandibulare – next to n. linguialis

Afferent branches: radix sympathica, radix parasymphathica, radix sensitiva.

Efferent branches mixed.

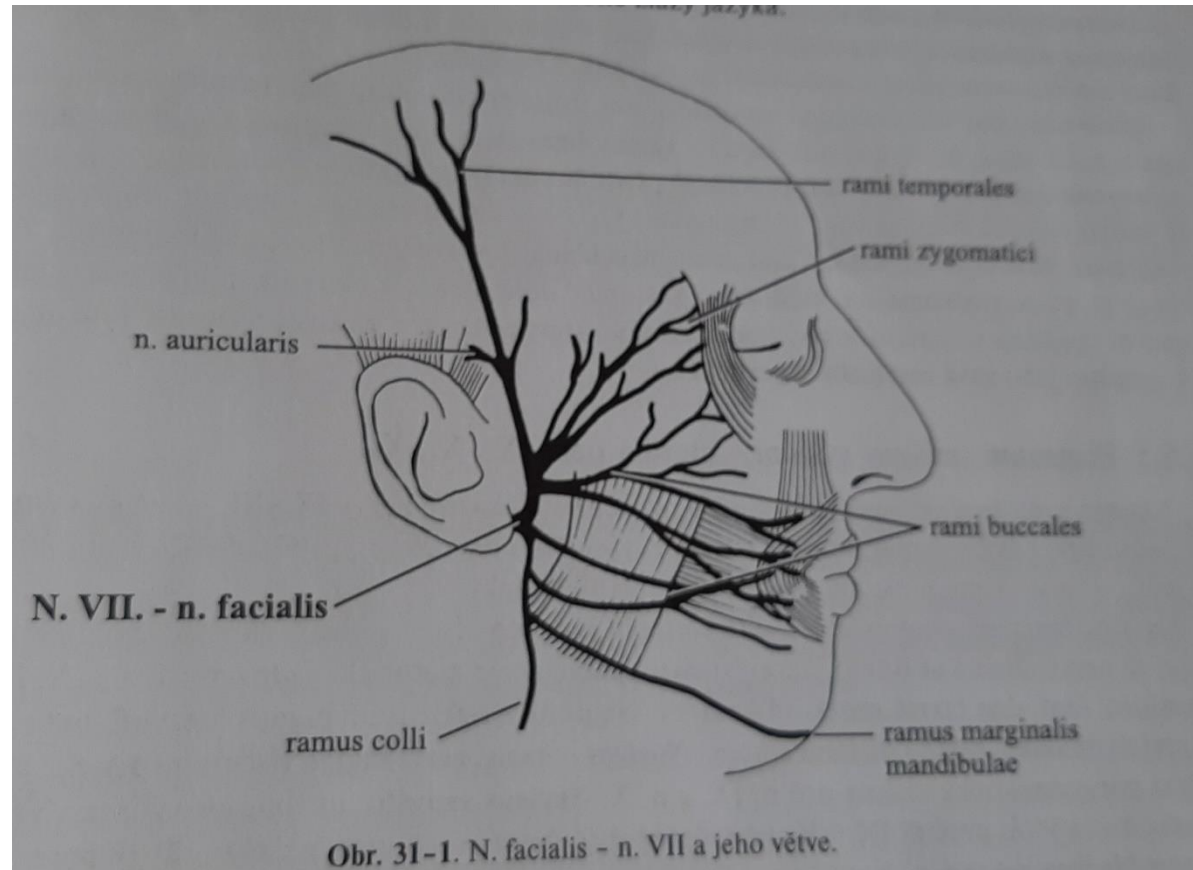
N. facialis – branches

- N. petrosus major-parasympatic fibres for ganglion pterygopalatinum
- R. communicans cum plexu tympanico
- N. stapedius
- Chorda tympani: connection with n. lingualis (parasympatic and sensoric fibres)
- Nervus auricularis posterior, r- digastricus, r. stylohyoideus

N. facialis-branches

- Plexus parotideus – supply of mimic muscles, r- colli m. platysma.

N. facialis



N. glossopharyngeus

- Supplies the posterior third of the tongue and pharynx.

Pain

- Unpleasant, troublesome up to intolerable feeling
- Subjective and individual
- Chain of physiological reactions and psychological manifestations
- The stimulus affects receptors or nerves, information is led to the central nerve system and transformed into subjective experience and final reactions

Receptors of pain

- Receptors are free nerve endings

No adaptation, feeling is so long as the duration of the stimulus is.

Stimuli

– Physical

Mechanical, thermal (cold, hot), electrical

Each feeling is transformed on the pain if the intensity exceed certain limit.

Changes of the intracranial pressure (vasodilatation), contraction of the nuchal or scalp muscles belong also to the physical stimuli.

Stimuli

– Chemical

- pH changes (decrease of pH – pain, around 5,8 intolerable)

- ions (potassium)

- Chemicals: acids, bases, hypotonic or hypertonic liquids,

Extrinsic factors: acid, bases, hypotonic or hypertonic liquids, also stinging plants, insect poison : changes of metabolism in cells -

pain

Stimuli

- Intrinsic factors

Internal origin: hydrochlorid acid (stomach), acetylcholin, histamin, serotonin, KCl, lactic acid.

Inflammation - pain

- Reaction of cells and blood vessels on damage (irradiation, burning, mechanical, chemical factors, infection or allergy)

Participation of histamin, serotonin, plasmakinin and others inflammatory mediators

Ischemia

- Disorders of metabolism – reduction of the supply of oxygen and nutrients, obstruction of elimination of catabolites.

Table 3-2. Classification and function of fibers in peripheral nerves

Fiber	Diameter (μm)	Conduction velocity (speed of impulse, m/sec)	Function
A-alpha (α)	6 to 20	15 to 80 (myelinated)	Afferent fibers for touch, pressure, proprioception, vibration (mechanoreceptors)
A-beta (β)	5 to 12	30 to 70	
A-gamma (γ)			
A-delta (δ)	1 to 5	2 to 30 (myelinated)	Afferent fibers for pain and temperature
B	1 to 3	3 to 15 (myelinated)	Visceral afferent fibers; preganglionic visceral efferent fibers
C	0.4 to 1.0	0.4 to 2 (nonmyelinated)	Afferent fibers for pain and temperature; postganglionic visceral efferent fibers



Table 3-3. Pain fibers in the pulp (nociceptive/algogenic)

	A-delta (δ) fibers	C fibers
Diameter (μm)	2 to 5 Measurement of parent fiber, which includes myelin sheath; smaller terminal processes (telodendrites) emerge from parent fiber.	0.3 to 1.2 Remain this diameter throughout their length
Conduction velocity (m/sec)—speed of electrical impulse or action potential traveling along nerve	5 to 30 As many as eight smaller terminals (telodendrites) feed into one larger myelinated parent fiber to produce greater velocity because of increased diameter.	0.4 to 2
Myelinated	Yes—parent axons located in cell-rich and central zones No—myelination lost by terminal branches of parent axon in dentinoblastic and subdentinoblastic zones	No Jelly roll spirals of Schwann cell membranes are absent. Fibers are enveloped by Schwann cells but not with myelin.
Location of terminals	Superficial—terminals in dentin tubules in dentinoblastic and subdentinoblastic zones (pulp-dentin border zones)	Probably near blood vessels throughout pulp; small C fibers difficult to differentiate from other cell processes.
Pain characteristics	Sharp, pricking and unpleasant but bearable (fast and momentary)	Throbbing, aching, and less bearable; lingering and extremely unpleasant sensation
Stimulation threshold	Relatively low—doesn't take much to initiate (fire) an impulse; can be stimulated without injury to tissue	High stimulation threshold to stimulate these fibers; stimulus may have to be so intense that tissue is damaged; from a pathologic standpoint, pain is associated with inflammatory process (exudative lesion and tissue damage).



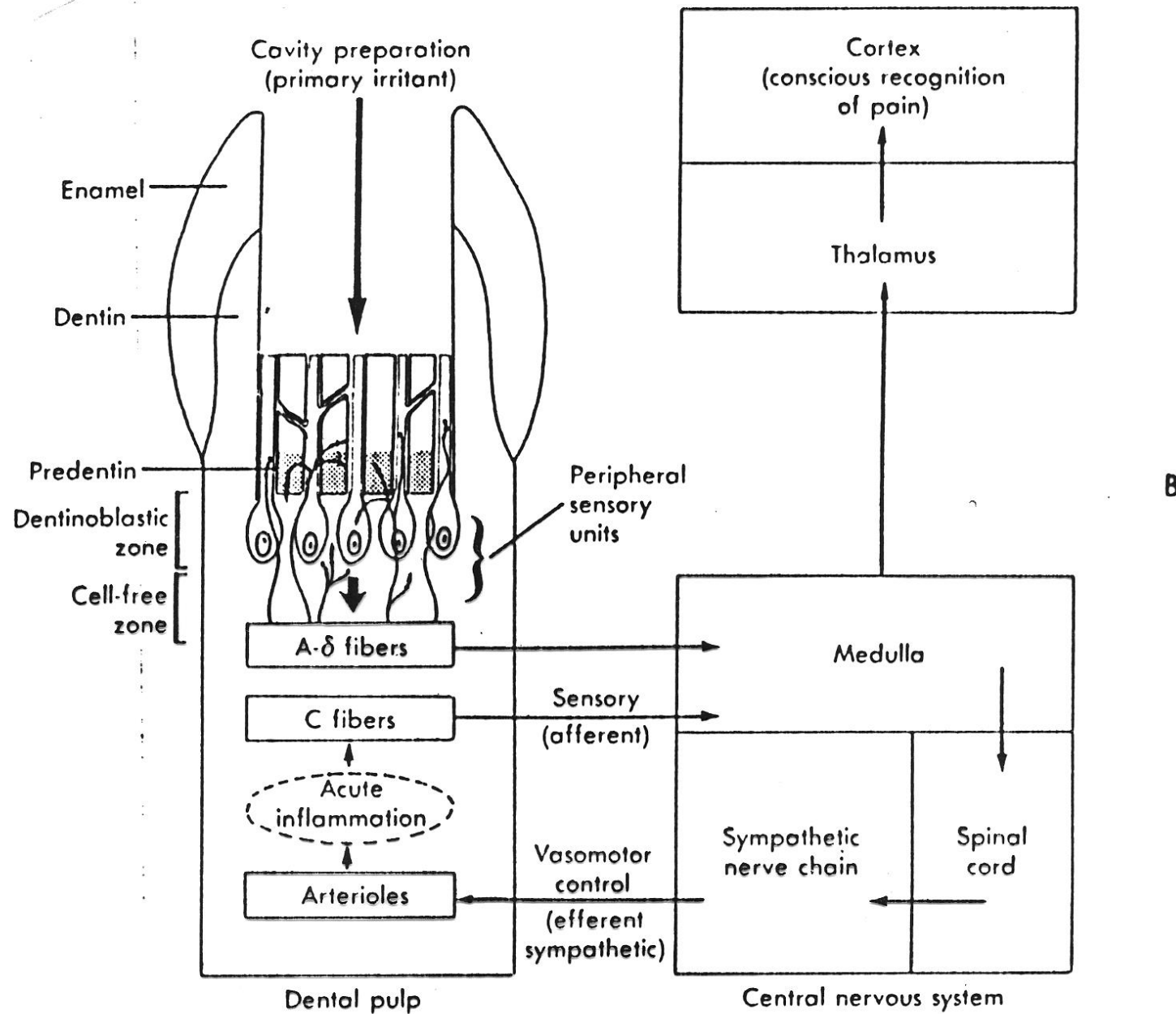


Fig. 3-20, cont'd. B, Afferent-efferent pathway for sensory and vasomotor impulses as a result of severe dentinal stimulation.



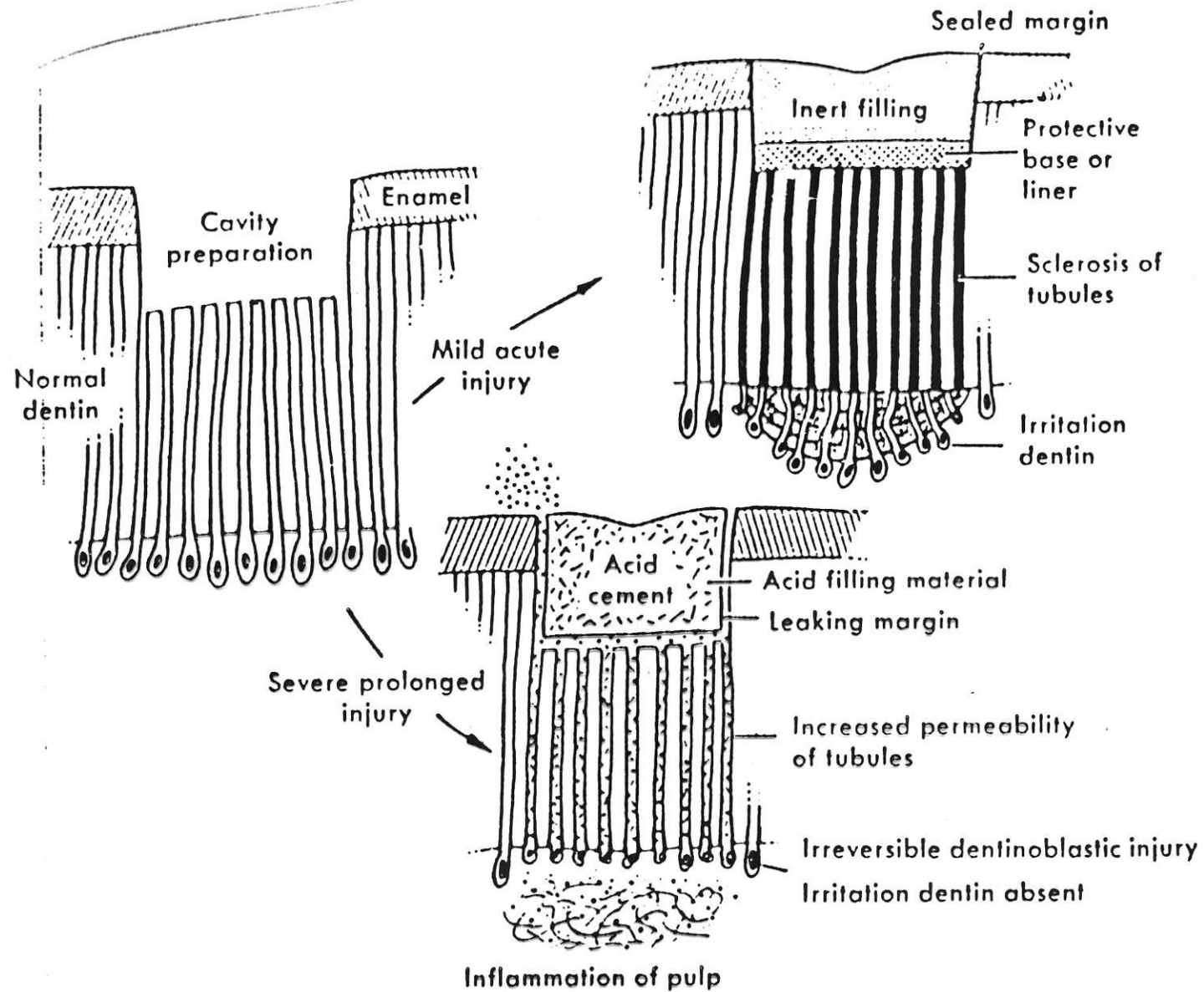


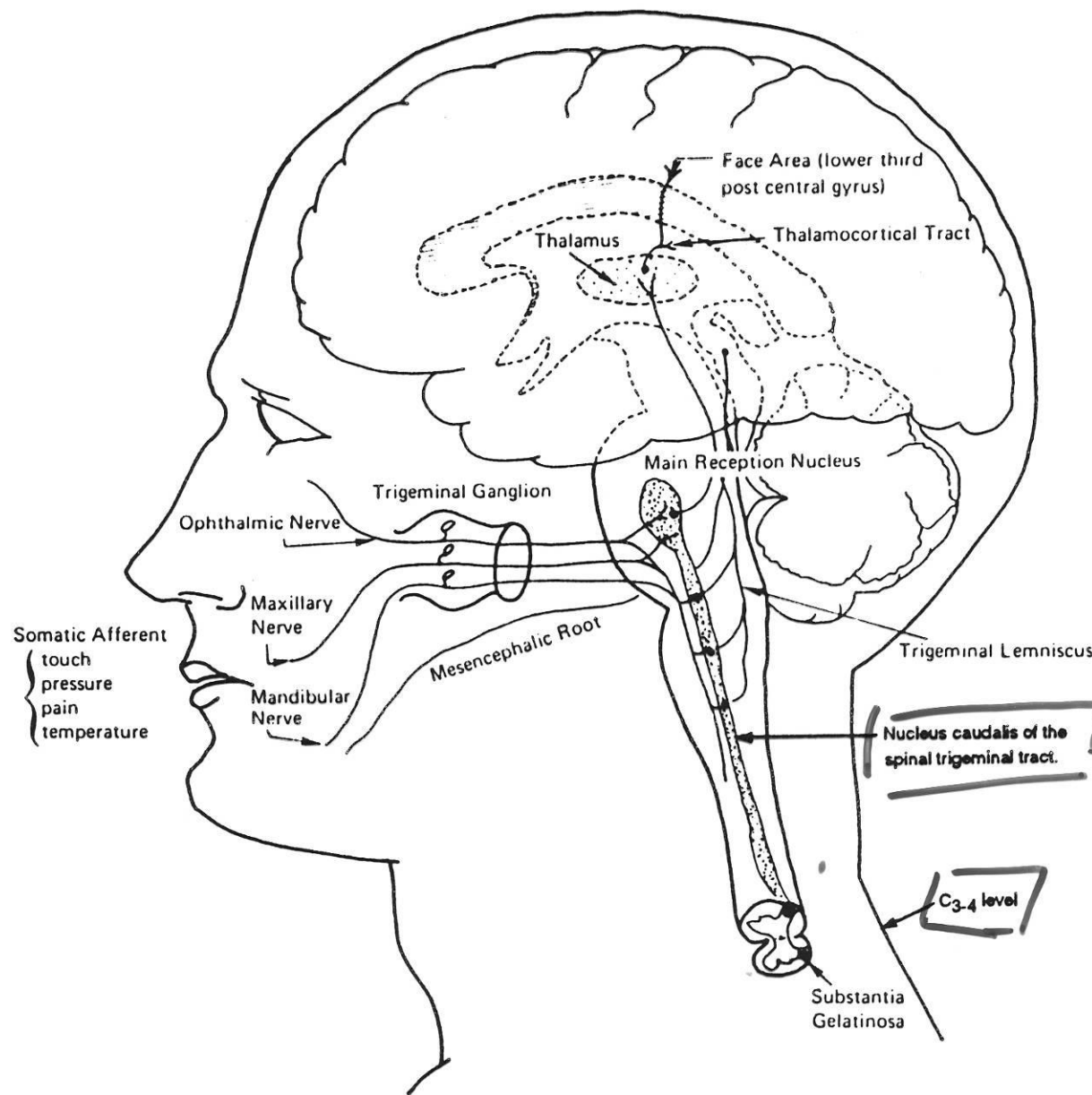
Fig. 3-34. Reaction of pulp-dentinal complex to mild and severe injury. Following cavity preparation and insertion of an inert filling, mild acute injury produces tubular sclerosis and irritation dentin. However, severe prolonged injury causes irreversible dentinoblastic injury, which in turn initiates pulpal inflammation. (From Massler, M: Dent Clin North Am, March 1965.)



Table 3-10. Referred pulpal pain

<u>Site of pain referral</u>	<u>Tooth pulp initiating pain</u>
<u>Frontal (forehead) region</u>	Maxillary incisors
<u>Nasolabial area</u>	Maxillary canines Maxillary premolars
Maxillary region above maxillary molars	Maxillary second premolars Maxillary first molars
<u>Temporal region</u>	Maxillary second premolars
Mandibular area below mandibular molars	Maxillary second and third molars
<u>Ear</u>	Mandibular molars Maxillary second and third molars (occasionally)
Mental region of mandible	Mandibular incisors, canines, and premolars
Angle of mandible	Mandibular first and second molars
Midramal region	Mandibular second premolars
<u>Superior laryngeal area</u>	Mandibular third molars
Maxillary premolars	Maxillary canines
Maxillary molars	Maxillary canines Mandibular premolars
Mandibular premolars	Maxillary canines Maxillary premolars
Mandibular first premolar	Mandibular first and second molars





Primary afferent nociceptive fibers of the trigeminal nerve (cranial nerve V) synapse in the nucleus caudalis of the spinal trigeminal tract. The nucleus caudalis descends as low as C3–4 in the spinal cord. Many nociceptors from deep cervical structures synapse on the same second-order pain transmission neurons as the trigeminal nerve. This may explain why cervical pain disorders are often perceived as facial pain or headache.



Local Pathosis of Extracranial Structures

Structures	Diseases
Tooth pulp, periradicular structures	Inflammation
Periodontium, gingiva, mucosa	Infection
Salivary glands	Degeneration
Tongue	Neoplasm
Ears, nose, throat, sinuses	Obstruction
Eyes	



Psychology of pain and its importance for the human body.

- For the subjective feeling the status of the central nerve system is important.
- Painful stimuli cause defensive reflexes
- Indicator of location of the pathological process.

Pain in the orofacial region

– Dental origin

Pulpitis

Periodontitis

Periodontal disease

Post extraction complications

Pain in the orofacial region

– Extradental origin

Oral mucous membrane disease

Sinusitis

Otitis media

Neurologic diseases (neuralgia, migraena)

Ophthalmological diseases

Systemic diseases

Pain of dental origin

- Endodontics I., II.
- Periodontology

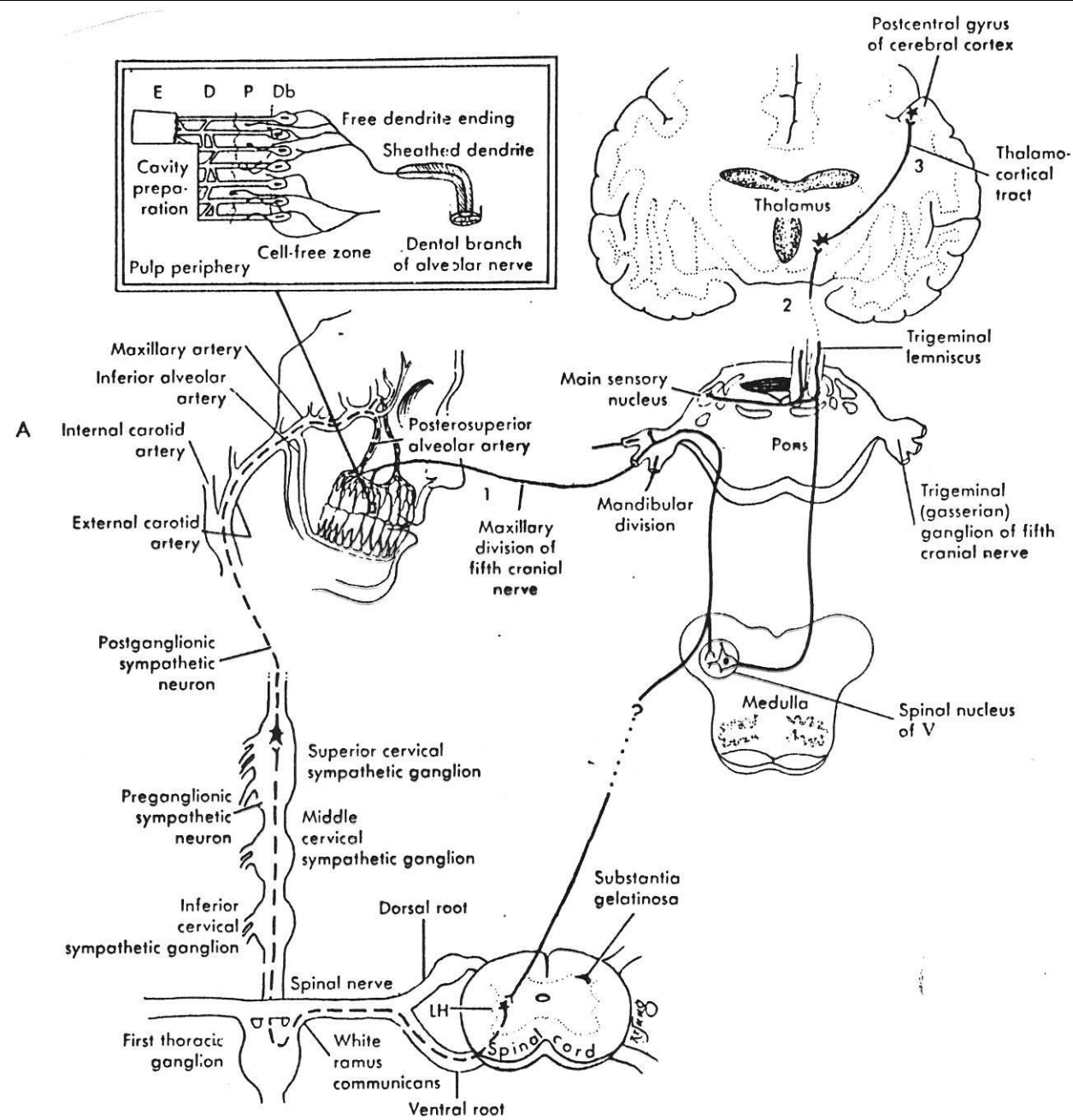


Fig. 3-20. A, Afferent-efferent pathway for sensory and vasomotor impulses. *E*, Enamel; *D*, dentin; *P*, predentin; *Db*, dentinoblast; *LH*, lateral horn (upper thoracic region); ----, efferent nerves; —, afferent nerves; 1, 2, 3, sensory neuron sequence.

- **The neurogenic factor** - activation of neural response by environmental irritants (mechanical, chemical, microbial)
- may cause
 - immediate and transient pain perception - result of nerve fibers irritation
 - vasodilatation - persists = increase in capillary permeability, fluid exudation, leucocytes infiltration= beginning of the exudative phase
 - increased intrapulpal pressure = result of the increased blood volume (hyperemia) and tissue exudate
 - secondary (spontaneous) pain response (C fibers)
- The pain persists - the presence of necrotic tissue

- **The tissue injury factor** - is due to release of mediators by the injured odontoblasts
- chemical substances
- the same effect as the nerve factor
- prolonged vasodilatation, fluid exudation, leucocytes infiltration, increase of intrapulpal volume and pressure, pain

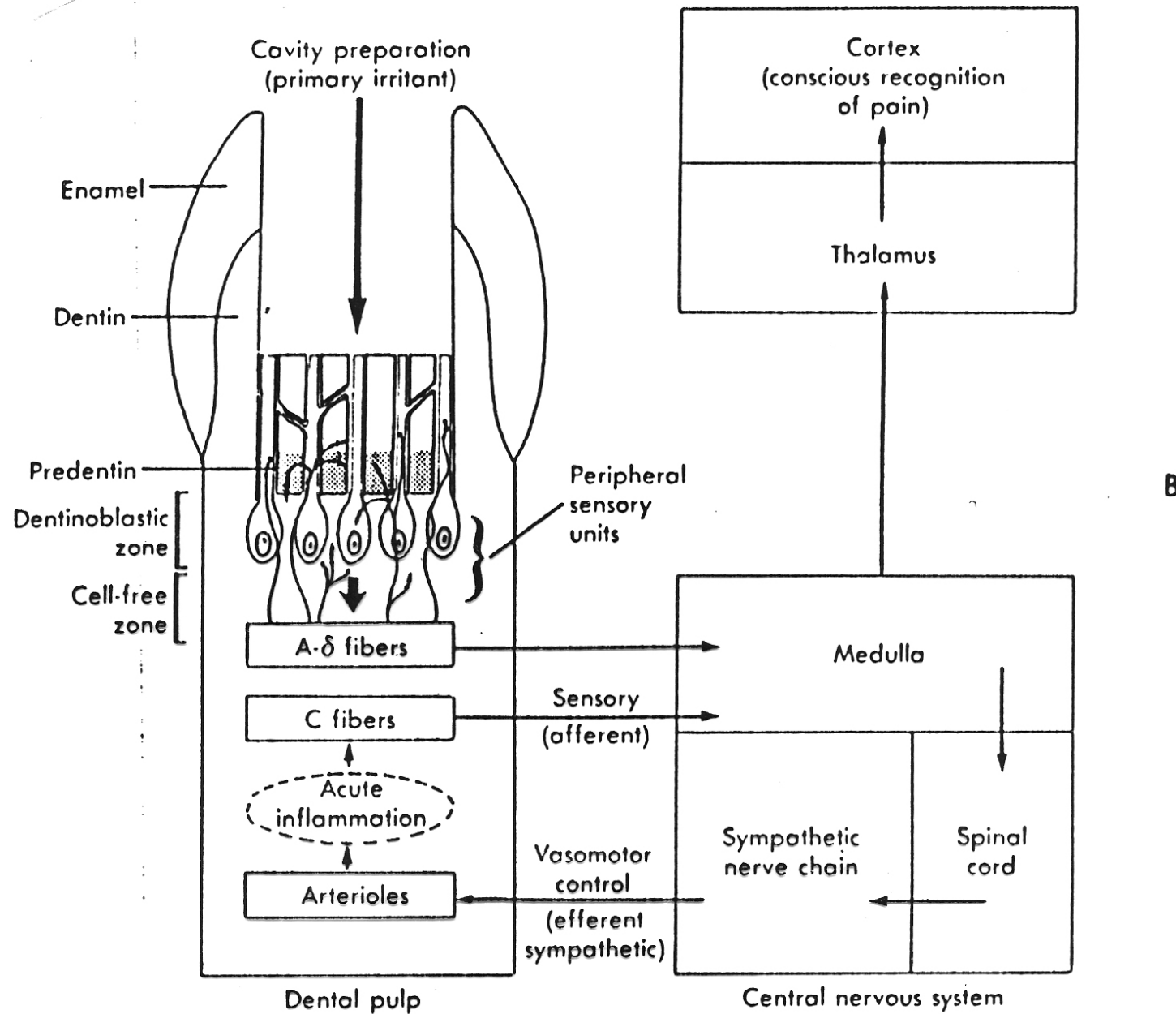


Fig. 3-20, cont'd. B, Afferent-efferent pathway for sensory and vasomotor impulses as a result of severe dentinal stimulation.



Reversible pulpitis - Hyperemia

- Capillary bed - enlargement, vasodilatation, elevated capillary pressure, increased vascular permeability, potentially reversible response

Irreversible pulpitis

Acute - hyperactivity of exudative forces
polymorphonuclear leucocytes, later macrophage

Chronic - proliferative phase
granulomatous tissue
pain is usually absent
lymphocytes, plasma cells, macrophages
limited number of PMNS

- **Duration and severity**
- acute
- chronic
- subacute

- **Presence/absence of pain**
- painful
- non painful

- Irreversible
 - painful pulpitis
- acute pulpitis
- subacute pulpitis
 - nonpainful pulpitis
- chronic ulcerative pulpitis (due to caries)
- chronic pulpitis (no caries)
- chronic hyperplastic pulpitis (pulp polyp)

Periodontitis

Painful pulpoperiapical pathoses

(acute apical periodontitis)

Inflammatory response - to pulpal irritants

exogenous forces become hyperactive

great increase in intraperiapical pressure

algogenic mediators released by the injured cells



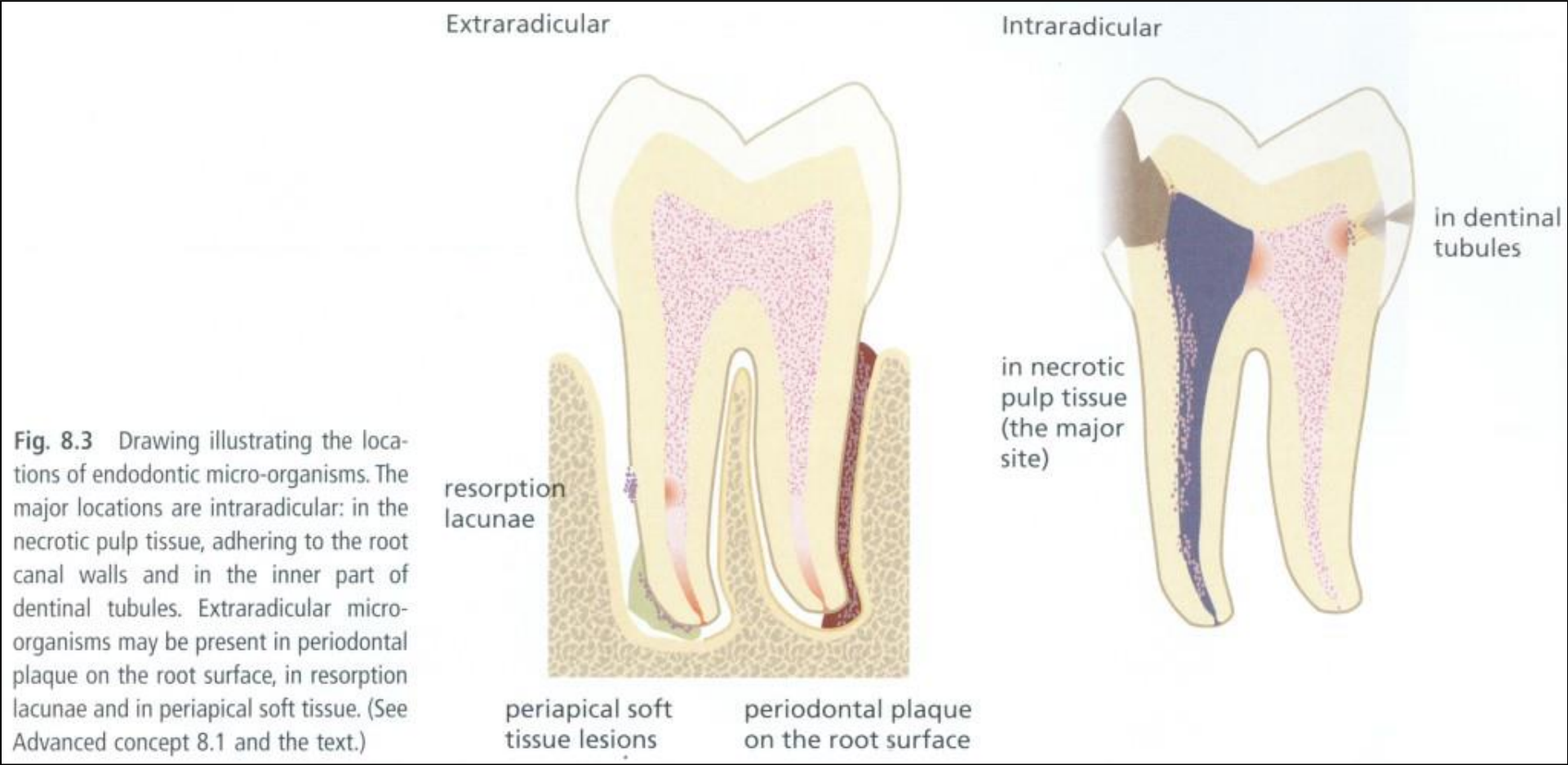


Fig. 8.3 Drawing illustrating the locations of endodontic micro-organisms. The major locations are intraradicular: in the necrotic pulp tissue, adhering to the root canal walls and in the inner part of dentinal tubules. Extraradicular micro-organisms may be present in periodontal plaque on the root surface, in resorption lacunae and in periapical soft tissue. (See Advanced concept 8.1 and the text.)



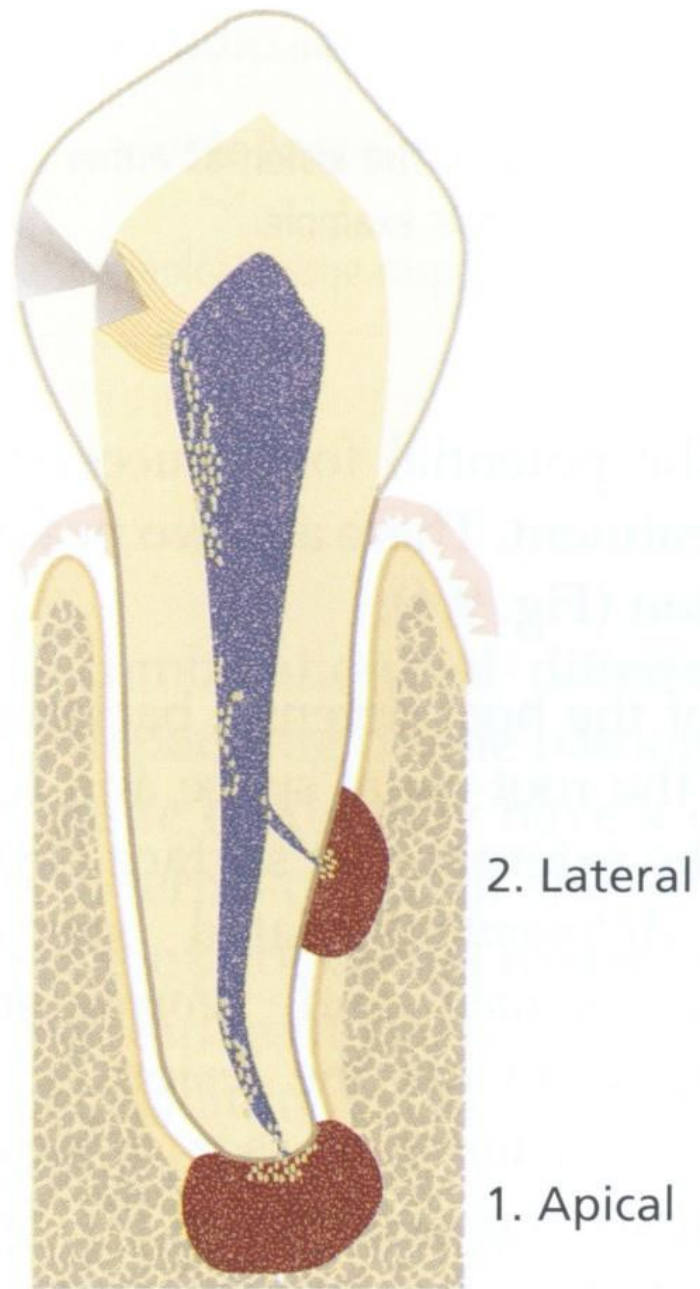


Fig. 9.1 Potential locations of endodontic lesions in the periodontium.

Acute apical periodontitis

mild symptomatic (exudative) response
contaminants from the pulp, vasodilatation, fluid exudation,
white cells infiltration
periodontal phase - abscess in the periodontal space
endosseal phase - localized osteitis
periosteal phase - severely symptomatic
pain - throbbing character, radiating
submucous phase - periosteal inflammation - relief

Acute periapical abscess

Advanced exudative, severely symptomatic
steadily increasing amount of inflammatory exudate, leucocytic
infiltration

suppuration

Etiology

infection

injury (acute, chronic)

chemical irritation (dressings)

Recrudescence abscess (phoenix abscess)

previously - chronic (granulomatous lesions)

contaminated (infected)

decrease in immunity

Symptoms: acute symptoms + periapical radiolucency

Subacute periapical abscess

chronic periapical abscess cycle

drainage through the stoma = the sinus tract (fistula)

parulis (gumboil) on the mucosa = swelling (gingiva, oral mucosa)

Acute periodontitis - symptoms

1. Phase (periodont)	hyperemia in the apical periodontium increase in pressure - elevates slightly the tooth nerve endings are stimulated slight pressure - mild pain
2. phase (enosseal)	as the process advances - the tooth becomes increasingly tender, lymph nodes sensitive, alteration of the patient, starts pus formation, pain more intense and steady soft vestibular tissue - painful to palpation, patient may be febrile

Acute periodontitis - symptoms

3. phase (periost)	the most intense pain - throbbing, steady radiating - pus penetrates the outer plate of the bone - raises the periosteum swelling in the apical region great mobility face asymmetry, swelling the symptoms greater in horizontal position patient - febrile
4. phase (submucous)	periosteum and mucosa - ruptured RELIEF pain subsides - but swelling fluctuation great asymmetry

Periodontal pain

- Apical

- Marginal

Pain of marginal periodontal origin

- Papillitis, gingivitis
(finding on interdental papilla)
- Acute inflammation in the periodontal pocket
(*the tooth is vital, BOP positive, suppuration, subgingival treatment is effective*)
- Abscess in periodontal pocket

Location, percussion in perpendicular direction, the tooth is vital

Dentitio difficilis

- Finding in the retromolar area
- X- ray finding

Aerodontalgia (barodontoalgia)

- Change of intrapulpal pressure (flight or diving)
- Pressure or expansion of air bubbles- irritation of nerve endings

Teeth that have been treated previously, chronic inflammation...

Referred pain -synalgia

- N. trigeminus many anastomoses, connection with sympathetic and parasympathicus and other nerves.

Dental irritation can have responses in remote tissues and organs and vice versa



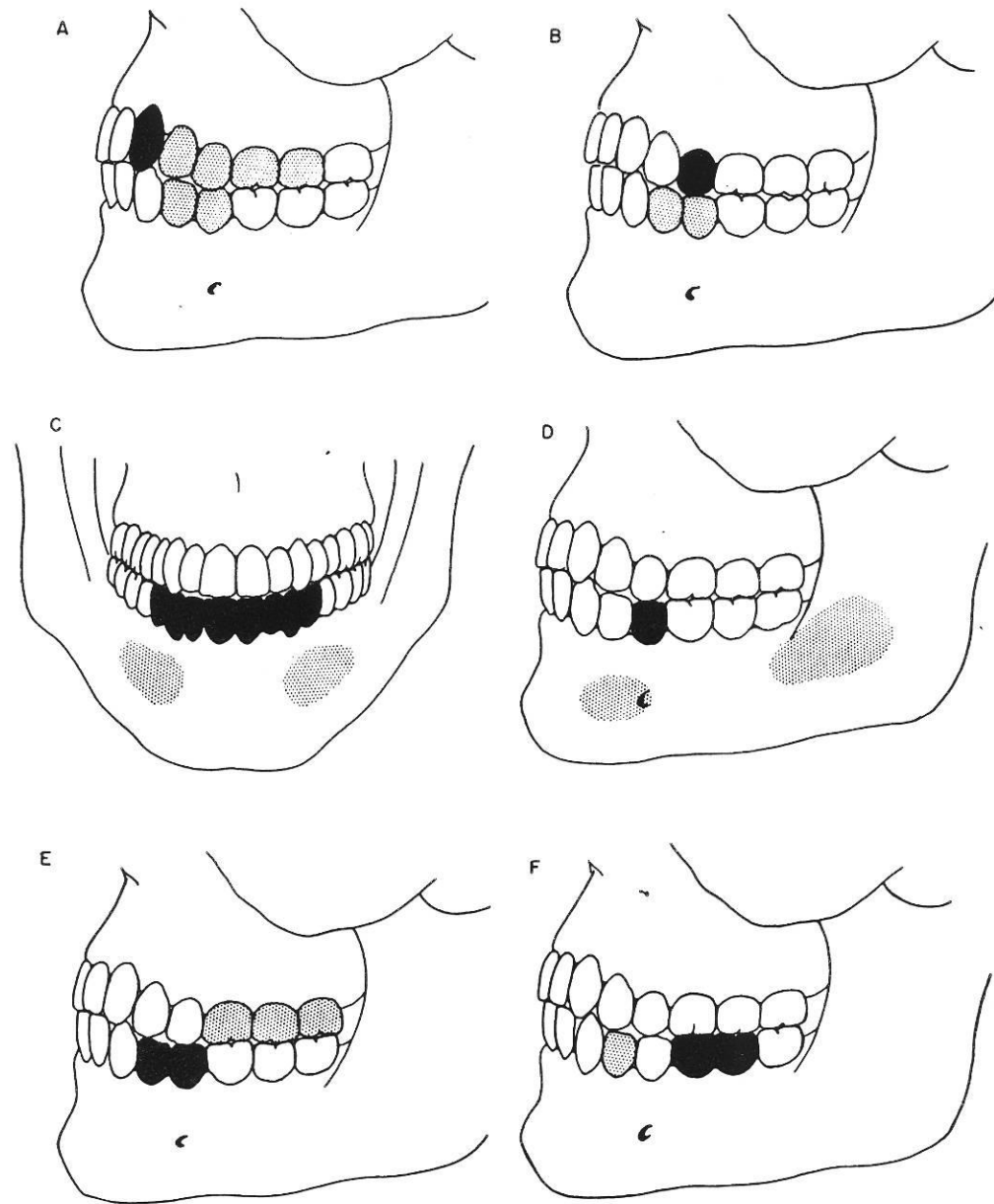
Synalgia dentodental

- The pain is localised into the other tooth. Always on the same side.
- Horizontal
- Ascendent
- Descendent

The referred tooth can be more painful, the patient is not able to describe the symptoms exactly. Careful investigation, x-ray.

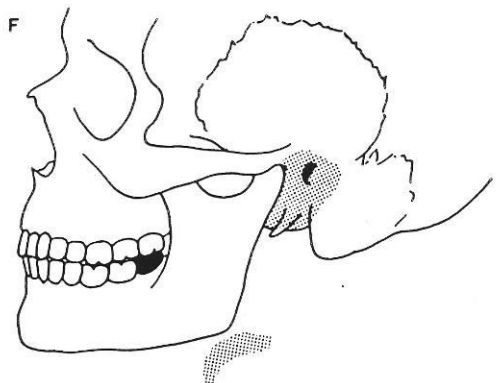
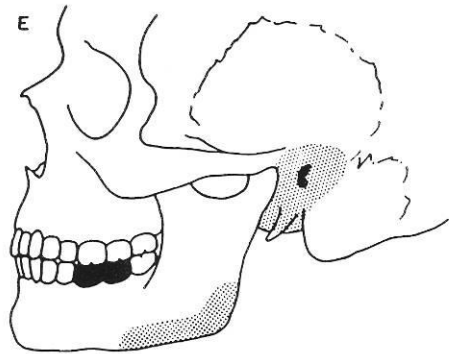
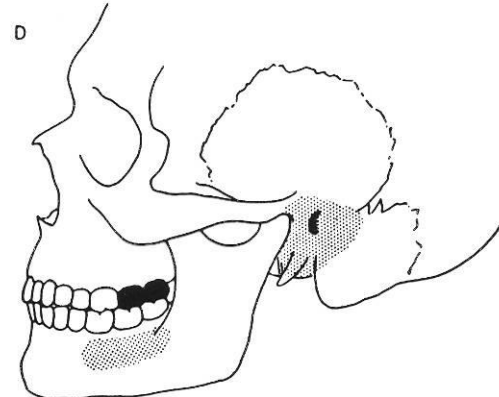
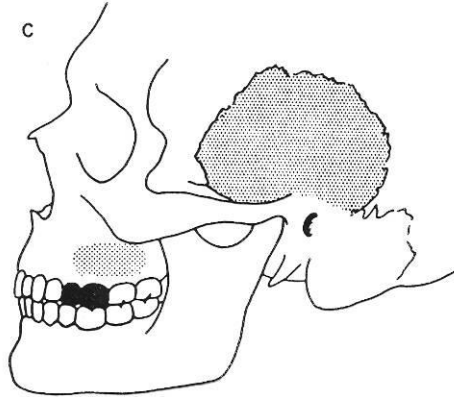
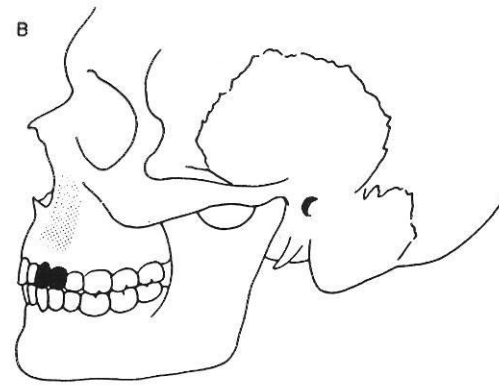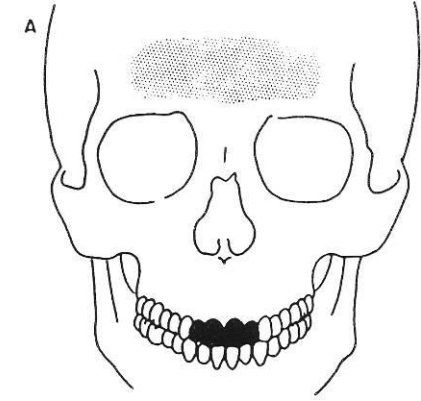
Synalgia dentocutaneous

- Hyperaesthesia of the cutaneous areas (see slides above)



Referred pain pathways from teeth involved with pulpalgia to other teeth as well as to immediate area. **Black** signifies tooth with pulpalgia; **stippled** areas, site of referred pain. **A**, Maxillary canine may refer to maxillary first or second premolars and/or first or second molars; also to mandibular first or second premolars. **B**, Maxillary premolars may refer pain to mandibular premolars. Reverse is also true. **C**, Mandibular incisors, canine, and first premolar may refer pain into mental area. **D**, Mandibular second premolar may refer pain into mental and midramus area. **E**, Mandibular first or second premolars may also refer pain into maxillary molars. **F**, Mandibular molars may refer pain forward to mandibular premolars. (Adapted with permission from Glick, D.H.: Oral Surg., 15:613, May, 1962.)





Pain referred from pulpalgia to structures remote from involved tooth. **Black** indicates teeth involved in pulpalgia; **stippled** areas, remote areas of referred pain. **A**, Maxillary incisors may refer pain to frontal area. **B**, Maxillary canine and first premolar may refer pain into nasolabial area and into orbit. **C**, Maxillary second premolar and first molar may refer pain to maxilla and back to temporal region. **D**, Maxillary second and third molars may refer pain to mandibular molar area and occasionally into ear. **E**, Mandibular first and second molars may commonly refer pain to ear and to angle of mandible. **F**, Mandibular third molar may refer pain to ear and occasionally to superior laryngeal area. (Adapted with permission from Glick, D.H.: Oral surg., 15:613, May, 1962.)



Synalgia dento-mucousal

– Various fields of mucousa

Synlagie dentonasal (maxillary incisors)

Synalgia dento - ocular and dento - auricular

- Ocular – maxillary canine, first premolar

- Auricular – maxillary molars

Pain of extradental origin:

Sinusitis maxillaris

The pain is similar to pulpitis and periodontitis. Unilateral. The posterior maxillary teeth are painful on percussion

Rhinitis can be present

Pain of extradental origin

Ophtalmologic diseases _ iritis, iridocyclitis, glaucom :

Maxillary canine or first premolar.

Pain of extradental origin

- Onemocnění vzdálených orgánů
 - *Malign tumors of oesophagus and lungs*
 - *Angina pectoris*
 - *Gastroenteritis*
 - *Meningitis and cerebral tumors*

Pain of extradental origin

- Systemic diseases

- Acute leucaemia and other oncologic diseases

- Diabetes

Referred Pain from Remote Pathologic Sites

Structures	Diseases
Heart	Angina pectoris, myocardial infarction
Thyroid	Inflammation
Carotid artery	Inflammation, other obscure causation
Cervical spine	Inflammation, trauma, dysfunction
Muscles	Myofascial trigger points



Neuralgia n. trigemini

- Pain can occur before the typical attack of neuralgia

- Primary:

Sharp short pain, vegetative (lacrimation, reddening of the skin) and motoric symptoms (defense movement)

Trigger zone

The teeth are usually intact

The pain is very short

Usually women (age from 50)

Vasomotoric changes around g.semilunare

Neuralgia n. trigemini

Secondary:

The pain is longer, irradiation, no trigger zone, no vegetative and motoric symptoms, finding on the teeth (caries, filling, crown..)

Oral membrane mucous diseases

– Herpes zoster

Irradiation of the pain along the nerv branche, vesicles.

Oral mucous membrane diseases

- Stomatodynia a glossodynia

Postextraction complications

- Alveolitis sicca

- History, empty socket

- Alveolitis purulenta

History, swelling redness, suppuration

- Nerve injury after extraction: hyperaesthesia or hypoaesthesia.

History.

Migraena - hedeache

- Unilateral. Duration hours, pulsation, nauzea, vomitus, aura, women, history.
- Aura 20% - one or more hours before ghe attack (ophtalmologic symptoms, skin sensitivity, paraesthesia)

Migraena start up factors

- **Hormonal: Menses, pregnancy, climax**
- **Food** – chocolate, alcohol, spice
- **Stress, lack of sleep**
- **Change of environment – sudden changes of atmospheric pressures, climate**

Acute pulpitis x migraena

Character of the pain, finding on the third maxillary molars.

Thank you!

lroubal@med.muni.cz