

Diseases of the
temporomandibular joints, facial
pain and neuromuscular diseases.

Markéta Hermanová

Components of temporomandibular joint (TMJ)

- **Mandibular condyle** (3 zones distinguished in the articular surface during development)
 - Articular zone
 - Proliferative or cellular zone
 - Hypertrophic zone
- **Articular fossa of the temporal bone**
- **Articular disc** (fibrocartilage)
 - Anterior band (pterygoid muscle attached to medial part)
 - Intermediate zone
 - Posterior band
 - Retrodiscal tissues

Developmental disorder

- **Hypoplasia or underdevelopment of the condyle**
 - Congenital
 - Acquired (trauma, radiation, infection)
- **Hyperplasia of the mandibular condyle** (unknown etiology)
- **Aplasia of the condyle**
 - Unilateral
 - Bilateral

Inflammatory disorders

■ Traumatic arthritis or haemarthrosis

(intracondylar fractures, dislocation, hyperextension sprains – resolution, scar formation, ankylosis)

■ Infective arthritis (*Staphylococcus aureus*)

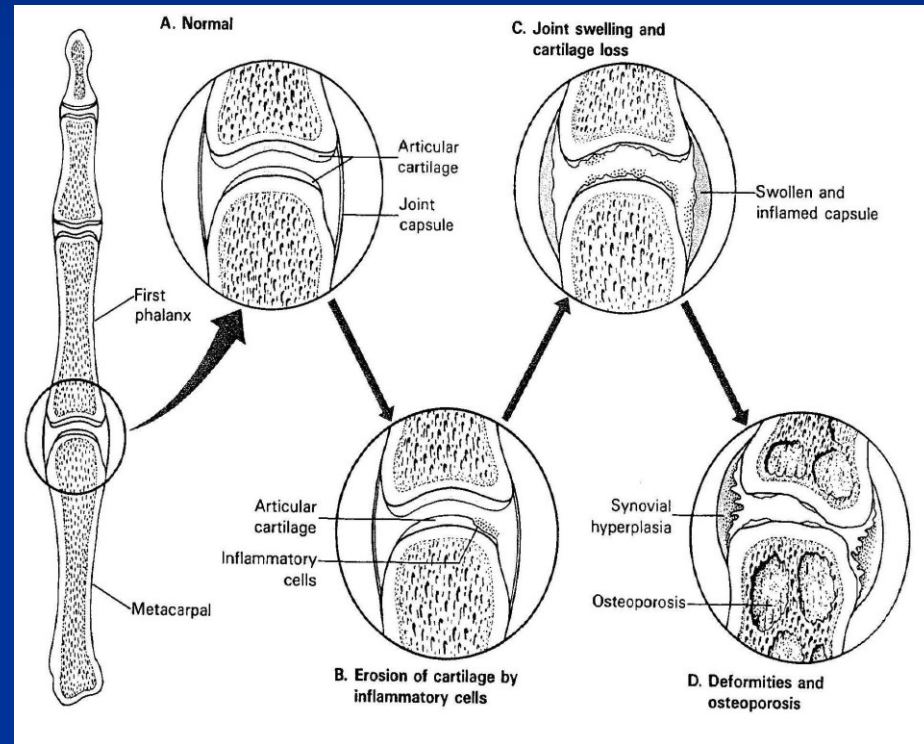
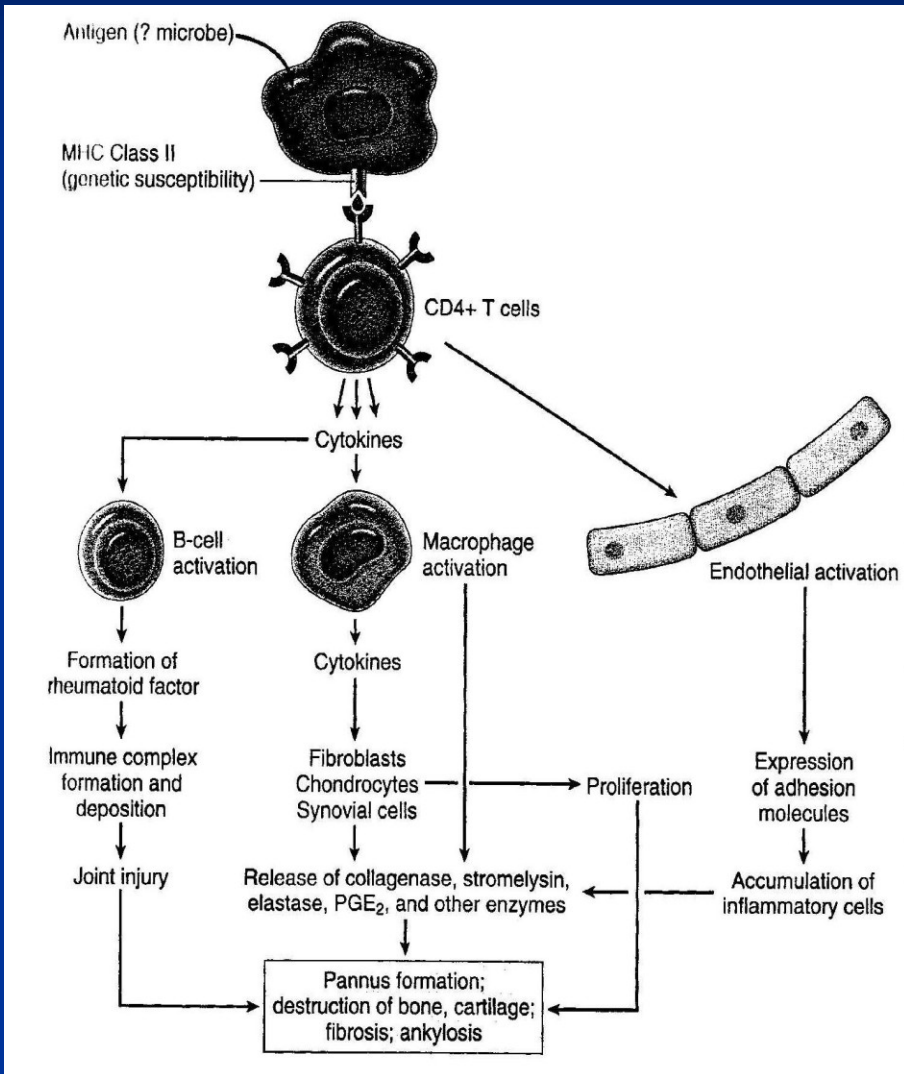
- Direct spread (middle ear, form surrounding cellulitis)
- Haematogenous spread (distant focus)
- Facial trauma
- Involvement of TMJ in wide spread of gonococcal or viral arthritis

Clinically pain, trismus, deviation on opening, signs of acute infection.

■ Rheumatoid arthritis (RA)

- Non organ specific autoimmune disease with articular and diverse extra-articular manifestation
- F>M; usually smaller joints affected; ofted ass. with Sjögren sy
- 20-70 % at some time TMJ involvement
- Limitation of opening, stiffness, crepitus, pain, tenderness
- Lymphoplasmocellular synovitis→proliferation of synovial tissue→formation of vascular pannus→erosion and resorption of adjacent bone→fibrous a nd complete ankylosis
- Rheumatoid factor: IgM-class autoantibody against chemical groups on IgG (in 85 % patients)

Immune reaction and morphology of RA



Osteoarthrosis (osteoarthritis)

- Degenerative rather than inflammatory disease
- Increasing incidence after 50 years
- Degenerative changes, denudation, and eburnation of condyle
- Limitation of opening, crepitus, pain, deviation on opening
- Related to untreated myofascial pain-dysfunction sy, loss of molar support
- Fibrillation, fragmentation and loss of the articular surface; denudation of the underlying bone, reactive changes in the exposed subarticular bone; osteophytes; perforation of articular disc
- Radiography: loss on the articular surface of the condyle, flattening and reduction in the total bony size of the condyle, reduction of the joint space, osteophytes, their fractures-loose bodies

Myofascial pain-dysfunction syndrome

- Masticatory muscle spasm
- Symptoms: pain ass. with joint or its musculature, clicking of the joint, limitation of jaw movement
- Tenderness of masticatory muscles
- F>M
- ass. with unilateral tooth loss, dental irregularities, emotional stress (bruxism, nocturnal tooth grinding habits)

Disc displacement

- Abnormal positional relationship between articular disc, head of the condyle, and the articular fossa of the temporal bone
- 25-65 % of elderly patients
- Prevalent in myofascial pain-dysfunction sy and in osteoarthritis
- Initially adaptive, later remodelling of the disc (shape, proportions, fibrosis, hyalinisation in retrodiscal tissue, haemorrhage, myxomatous changes, cartilage formation, perforation of the posterior attachment,.....)

Loose bodies

- Radiopaque bodies lying in the joint space
- Discomfort, crepitus, limitation of opening
- Causes: intracapsular fractures, fractured osteophytes, synovial osteochondromatosis (multiple nodules of metaplastic cartilage – unknown etiology)

Age changes in the jaws and TMJ

- Osteoporosis
- Atrophy of alveolar bone, loss of teeth
- Osteoarthritis
- Disc displacement

Neoplasms

- Extremely rare
- Benign chondromas and osteomas
- Malignant sarcomas (bone, soft and synovial tissues)

Trismus – limitation of movement in the temporomandibular joints - causes

■ Intra-articular

- Traumatic arthritis
- Infective arthritis
- Rheumatoid arthritis
- Dislocation
- Intracapsular fracture
- Fibrous or bone ankylosis following trauma or infection

■ Extra-articular

- Adjacent infection, inflammation or abscess (e.g. mumps, pericoronitis, submasseteric abscess,...)
- Extracapsular fractures (mandible, zygoma,...)
- Overgrowth (neoplasia) of the coronoid process
- Fibrosis from burns or irradiation
- Haematoma/fibrosis of medial pterygoid (e.g. after inferior dental block)
- Myofascial pain-dysfunction syndrome
- Tetanus
- Tetany
- Drug-associated dyskinesia and psychotic disturbances

Bell's palsy (idiopathic 7th nerve paralysis: idiopathic facial paralysis)

■ Triggering events:

- Acute otitis media
- Atmospheric pressure change (diving, flying)
- Exposure to cold
- Ischemia of the nerve near the stylomastoid foramen
- Local and systemic infection (viral (herpetic), bacterial, fungal)
- Melkersson-Rosenthal sy (cheilitis granulomatos, facial paralysis and fissured tongue)
- Multiple sclerosis
- Pregnancy (3rd trimester, early eclampsia)
- Lyme disease
- sarcoidosis

Other facial and cervical neuralgias

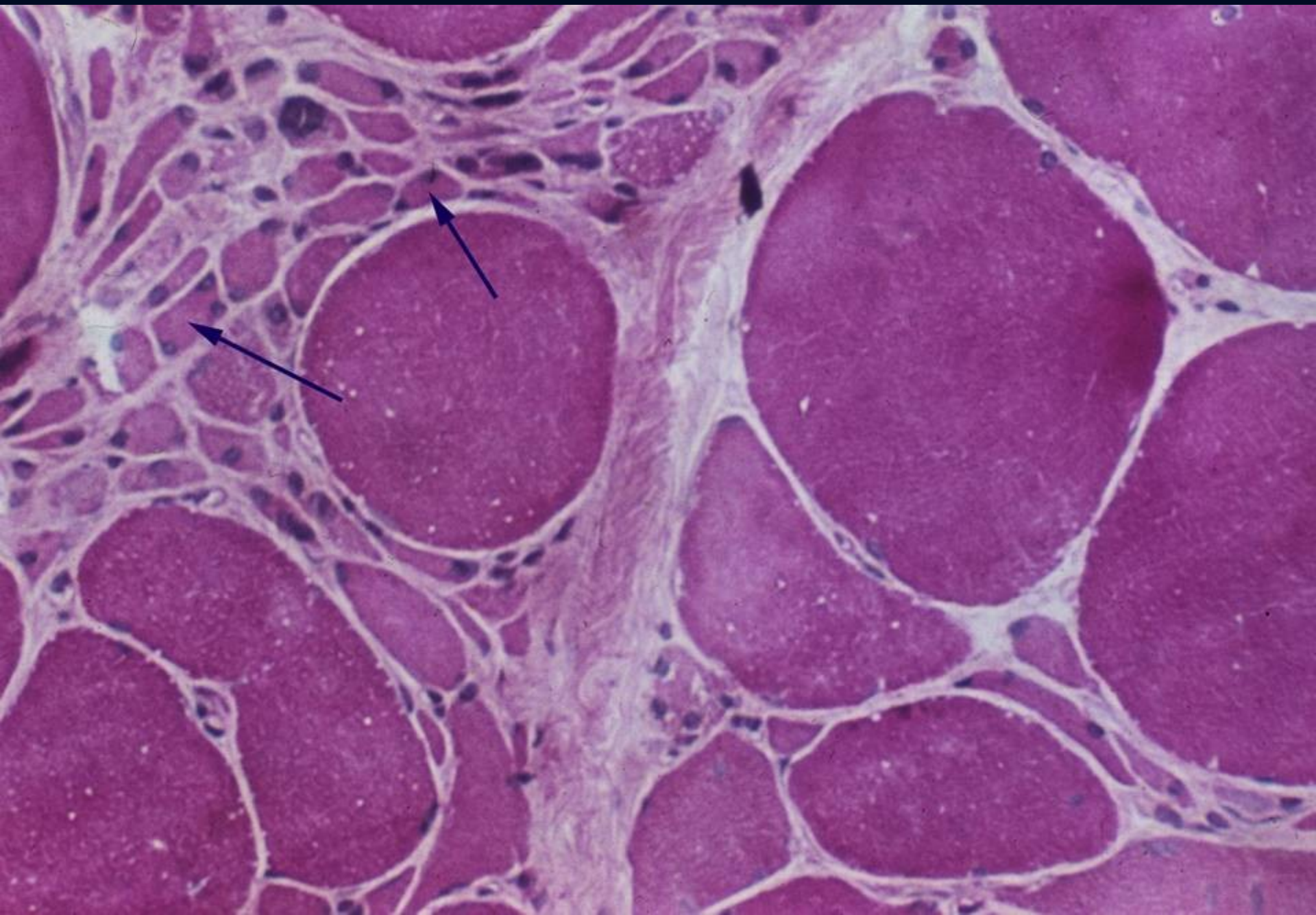
- Trigeminal neuralgia: the extreme, paroxysmal and lancinating pain, usually initiated by light touch to a trigger point
- Glossopharyngeal neuralgia
- Migrainous neuralgia
- Occipital neuralgia
- Paratrigeminal neuralgia
- Postherpetic facial neuralgia
- Tympanic plexus neuralgia
- Sphenopalatine ganglion neuralgia
- Superior laryngeal neuralgia
- Neuralgia induced cavitation necrosis (3rd molar)

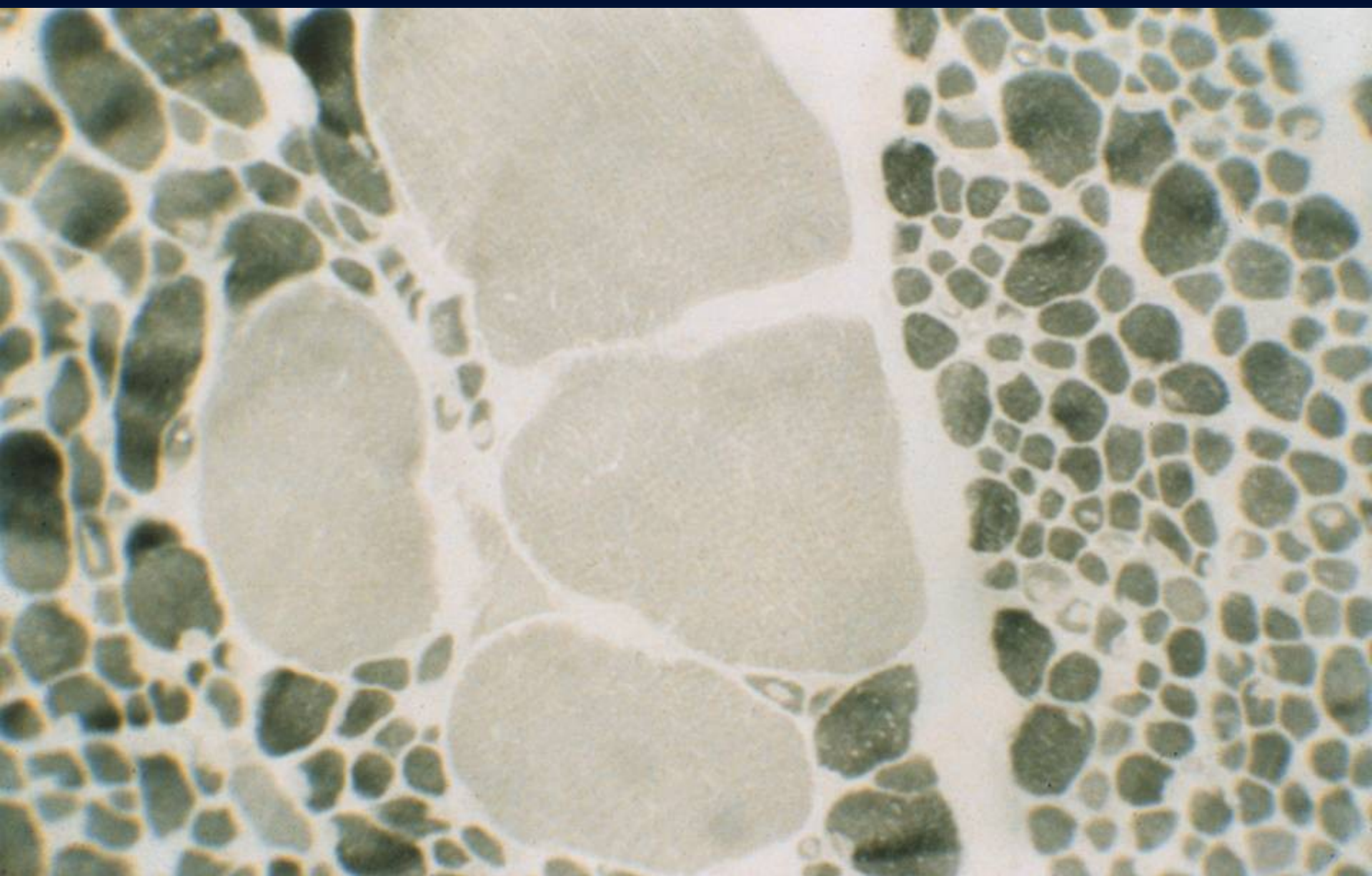
Motor neuron disease – progressive degeneration and death of the motor neurons

- Dysphagia
- Fasciculation (small, synchronous, subcutaneous muscle contraction)
- Bulbar paralysis

Spinal muscular atrophy

- AR
- SMN1 (survival motor neuron gene) – 95% SMA
- 1/6000-10000
- 2-3% carriers
- 2nd most common after cystic fibrosis (mucoviscidosis)





Amyotrophic lateral sclerosis

- **90 % sporadic ALS**
- M:F – 1,7:1
- older people, survival 3-4 years, first symptoms in 56-63 years, upper extremities preferentially affected, bulbar symptomatology
- **10 % hereditary ALS** (4th decade, juvenile forms, F:M – 1:1)

Myasthenia gravis

- Autoimmune disease
- Antibodies against AChR
- Abnormal progressive fatigability of skeletal muscle
- Ass. with thymoma or thymus hyperplasia
- Clinical symptoms:
 - An inability to focus the eyes (extraocular muscular paresis)
 - Drooping eyelids (ptosis)
 - Double vision (diplopia)
 - Difficulty in chewing
 - Difficulty of swallowing (dysphagia)
 - Slurring of words (dysarthria)

