

Preclinical dentistry II. 3

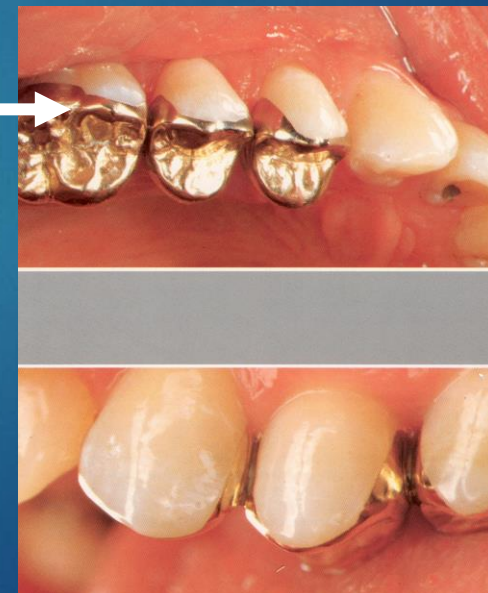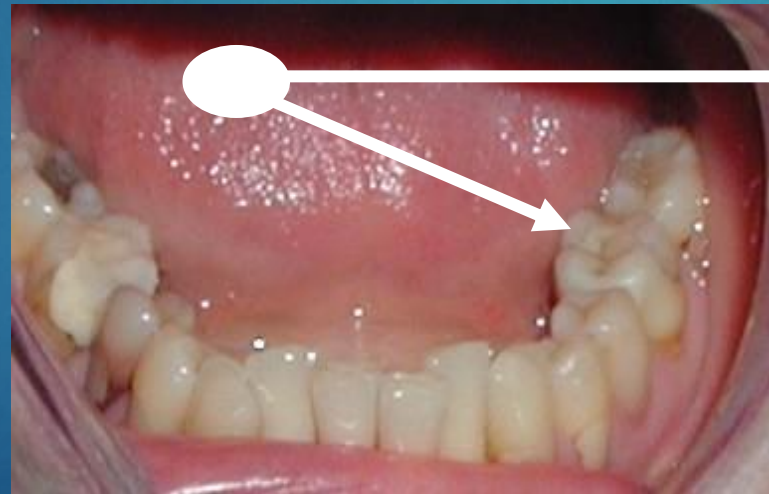INLAYS AND ONLAYS



Indirect
reconstructions
inlays and onlays

Inlay

Rigid filling made out of oral cavity. Insertion using luting material



Inlays made of metal alloys

Indications

Large defects that is not possible to restore using amalgam or composite materials

Out of aesthetic zone

Golden alloys

Inlays made of metal alloys contraindications

High caries risk

Small and shallow cavities

Aesthetic zone

Metal inlay

Fabrication

- Direct method – *seldom, for large central cavities only*
- Indirect method

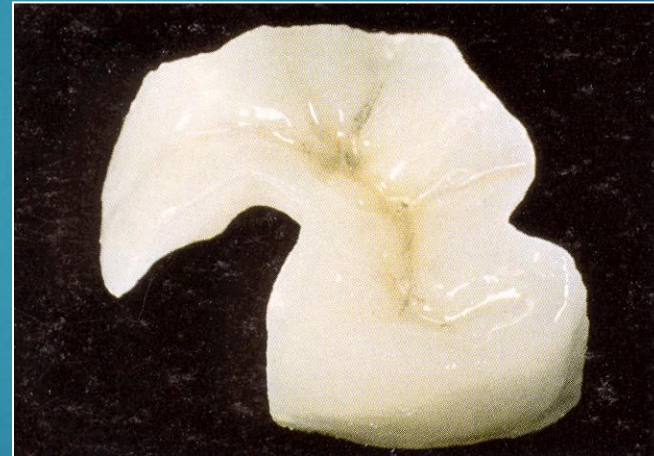Contempoprary trends

**Demands on aesthetic solution are
increasing also in posterior area**

Non metallic restorations

Composite

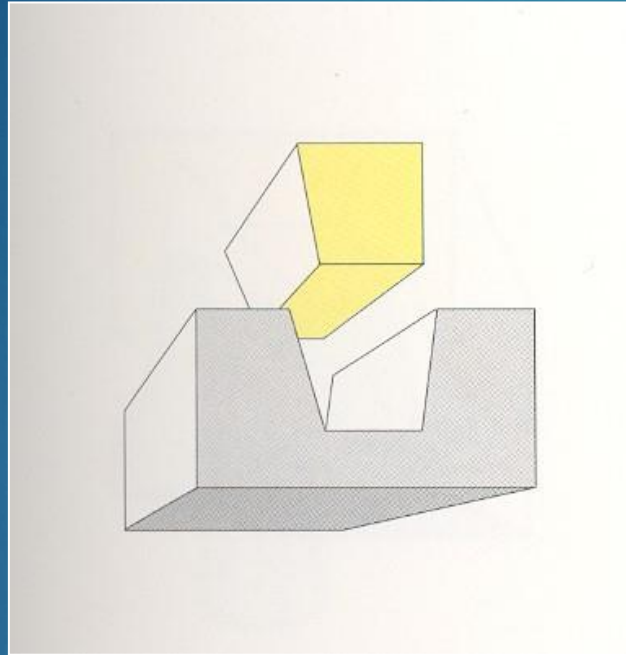
Ceramics





Indications

Large defects that are not possible to be restored using amalgam or composite materials

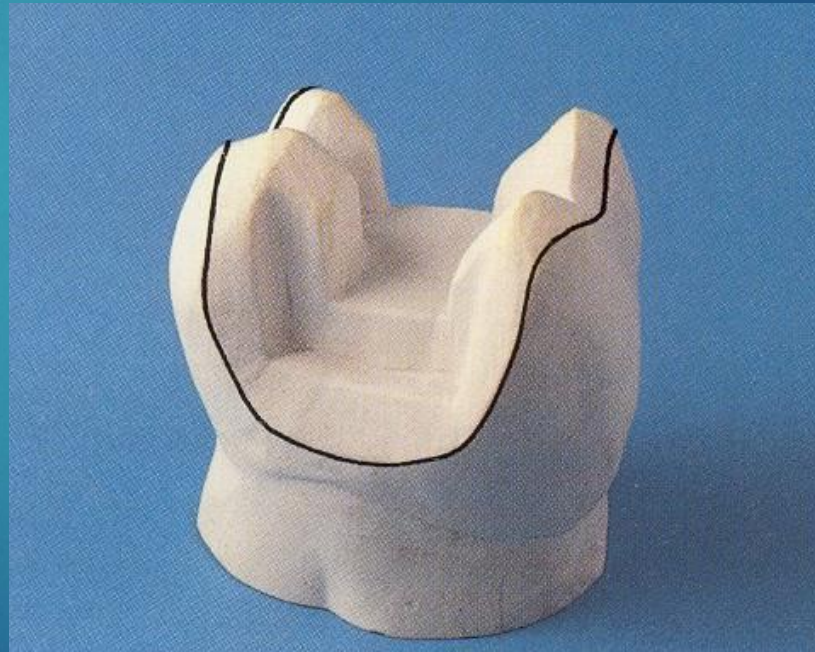
Inlay



Onlay

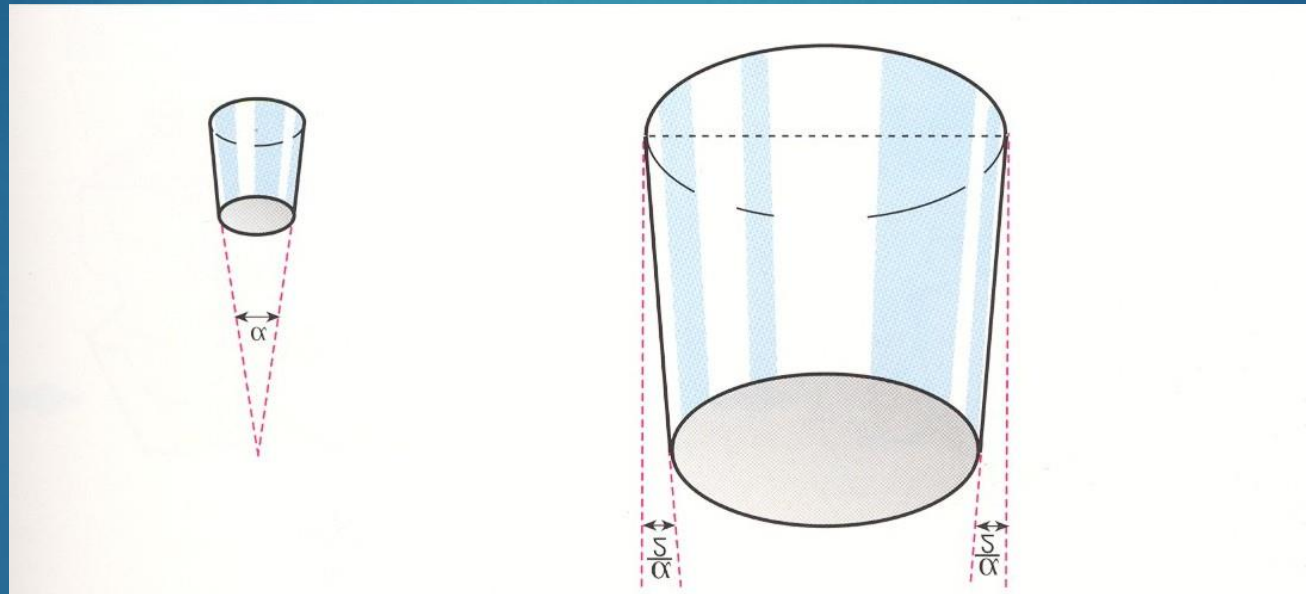


Overlay

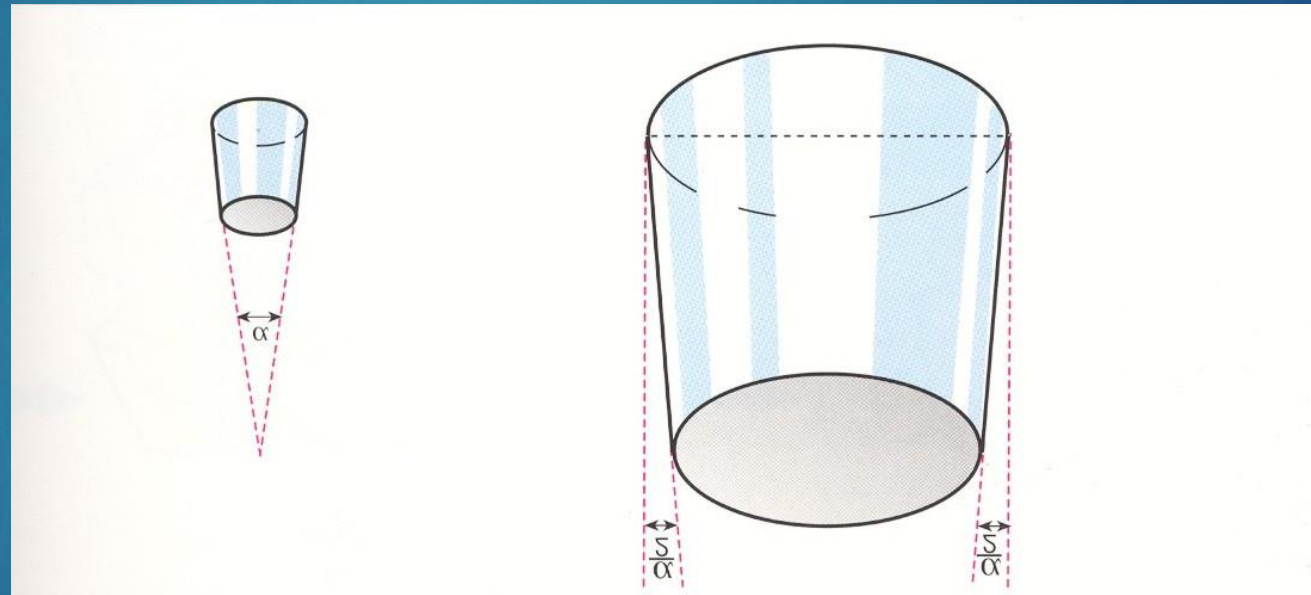


Retention

Ability to face up to occlusal forces



Geometry of preparation





Angle of divergency

Optimum 6° – 20°

Area of retention

Area of the contact of both surfaces (tooth and restoration)

- *Surface friction*
- *Luting material*

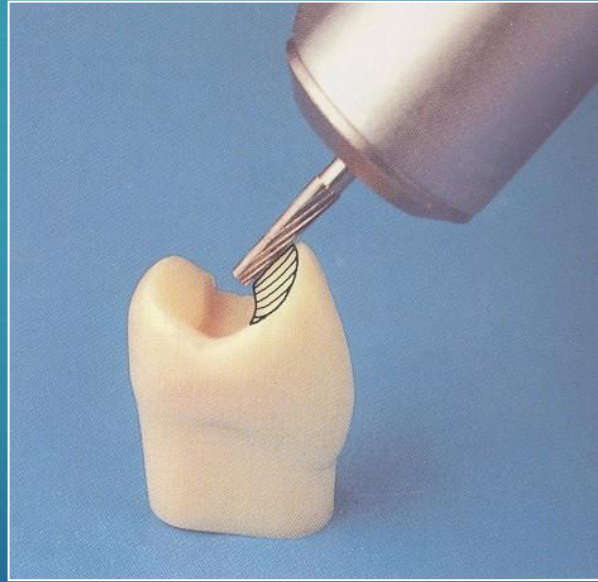
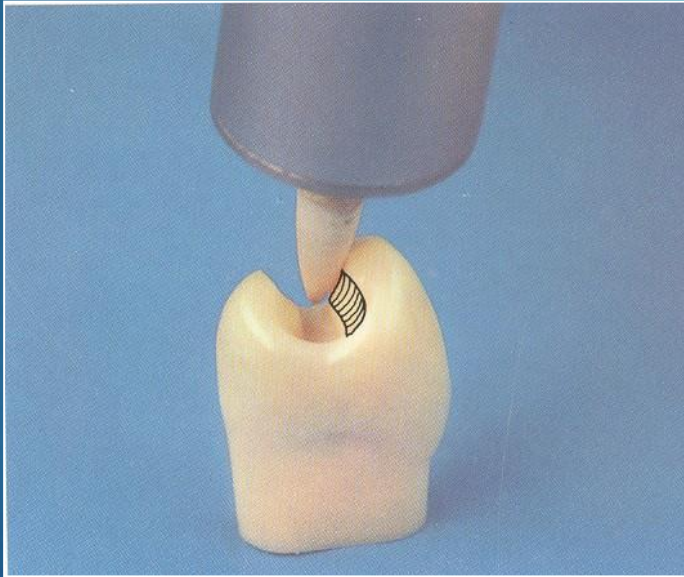
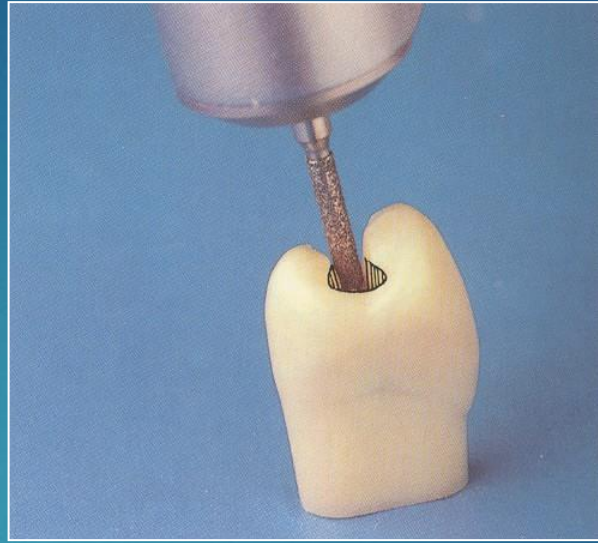
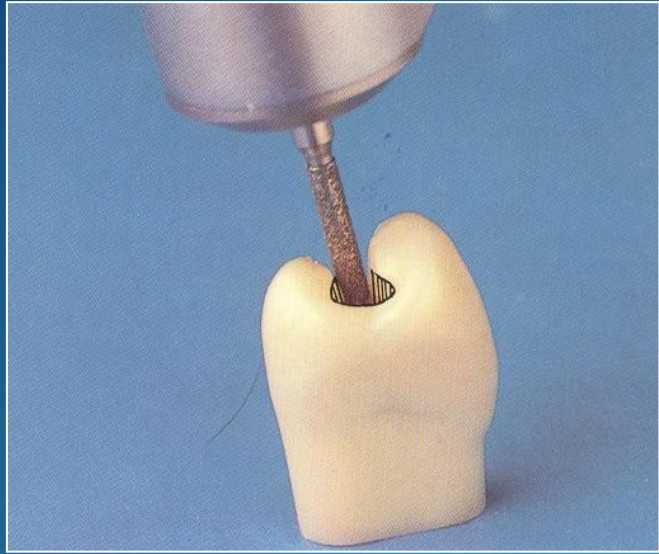
Importance of the luting material

Metallic inlays

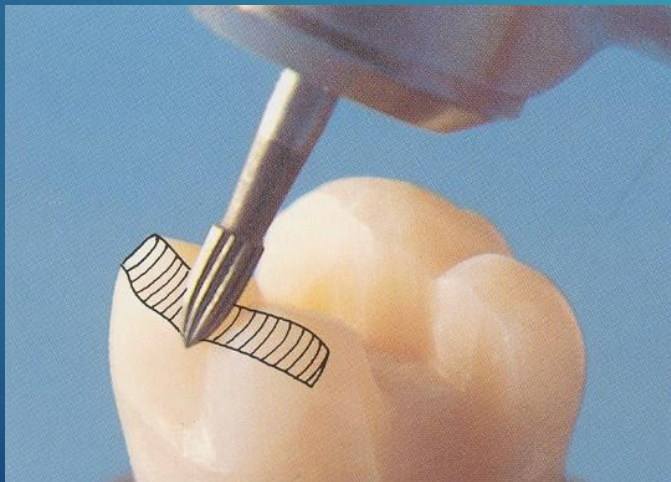
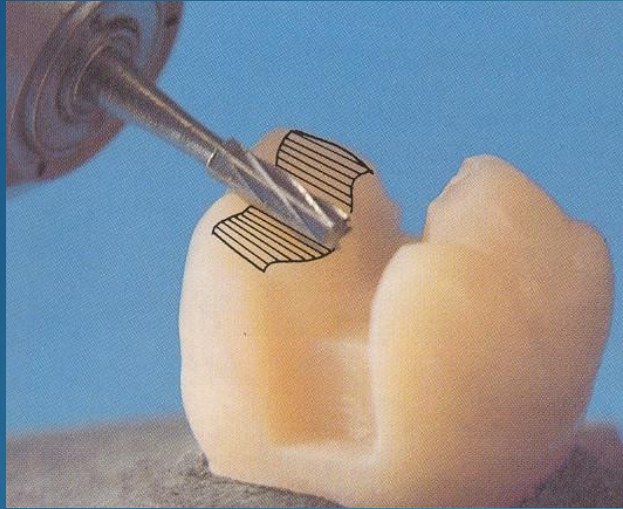
Zinc oxide phosphate cement

Preparation

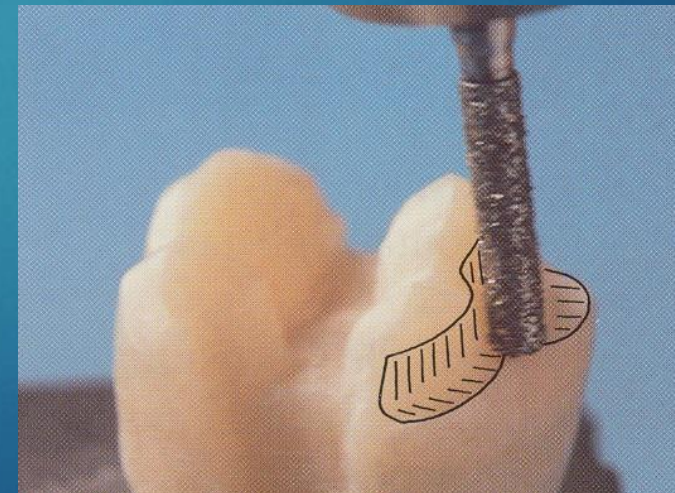
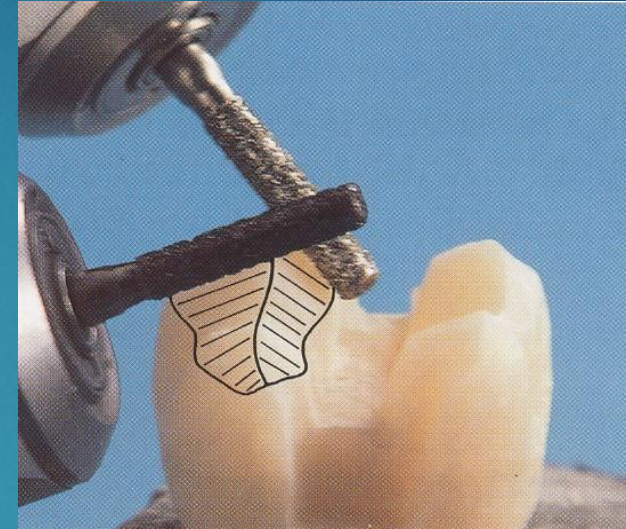
- ▶ Standard diamond – blue:
Cavosurface margin
- ▶ Fine diamond – red or special hard metal bur
Finishing of the preparation



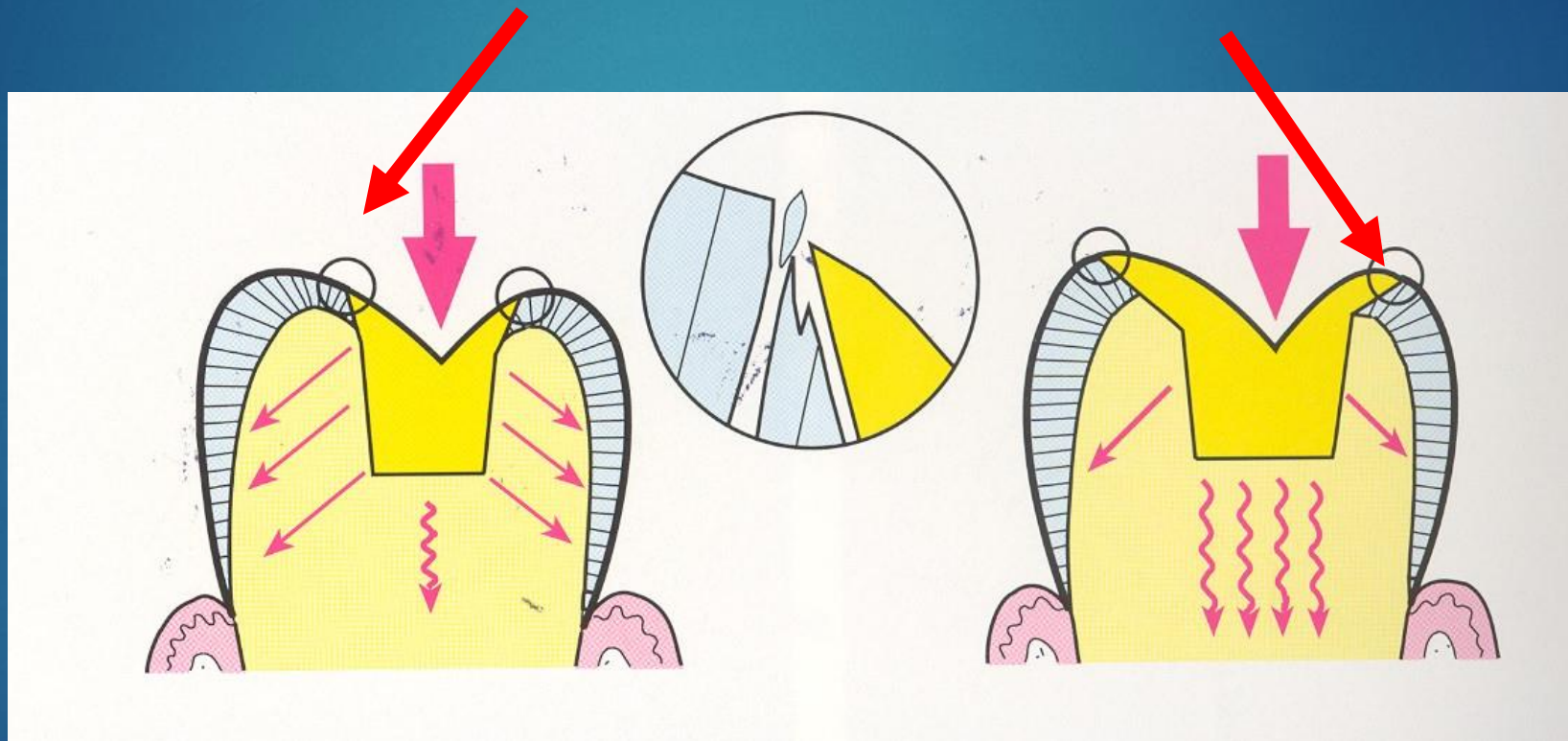
Overlay



Schůdková korunka



Enamel must be beveled – only in outer half



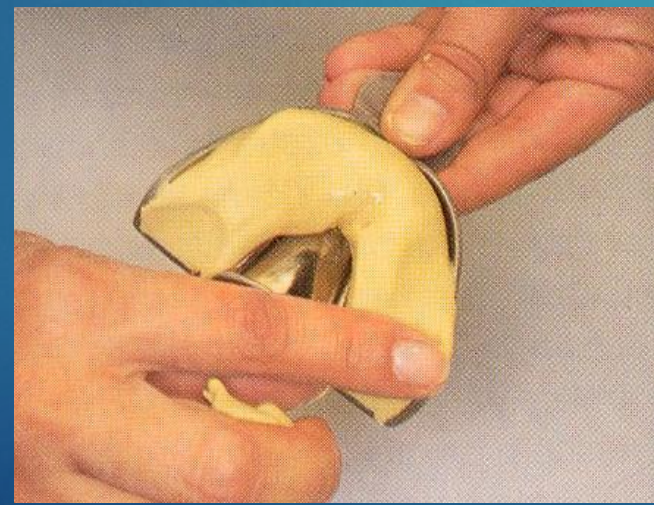
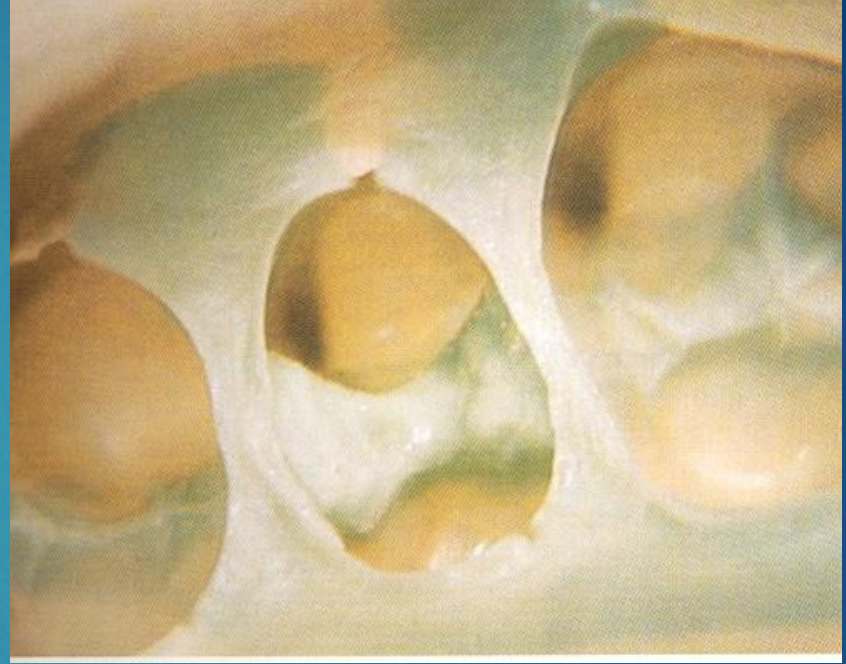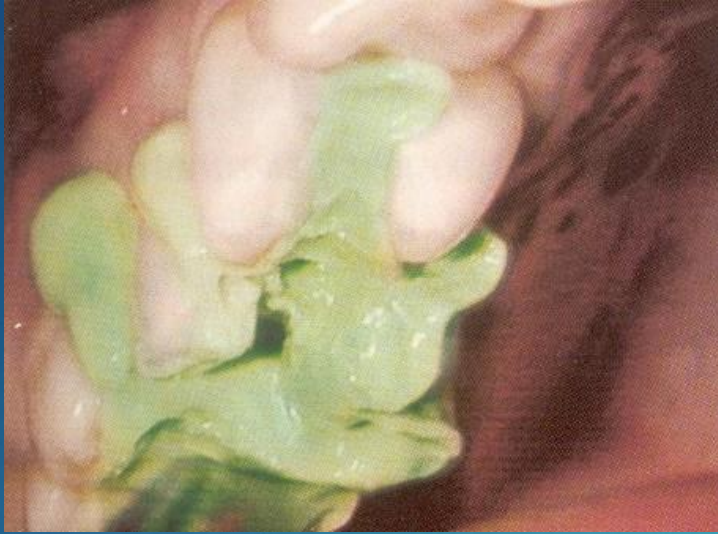Cavity for inlay II. class

- ▶ Divergent walls in occlusal cavity as well as in proximal box
- ▶ Extension for prevention
- ▶ Enamel is beveled also in occlusal part of the cavity

Impression technique elastomers

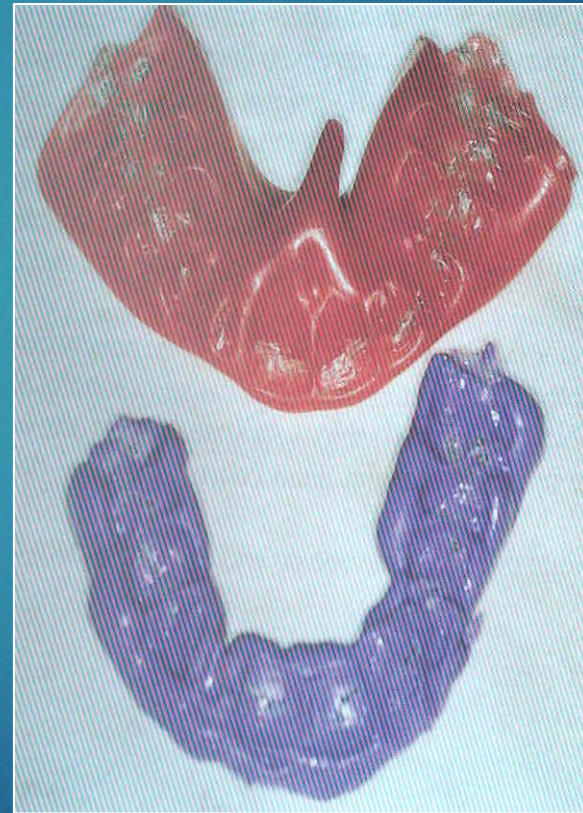- ▶ Dual viscosity technique

One phase

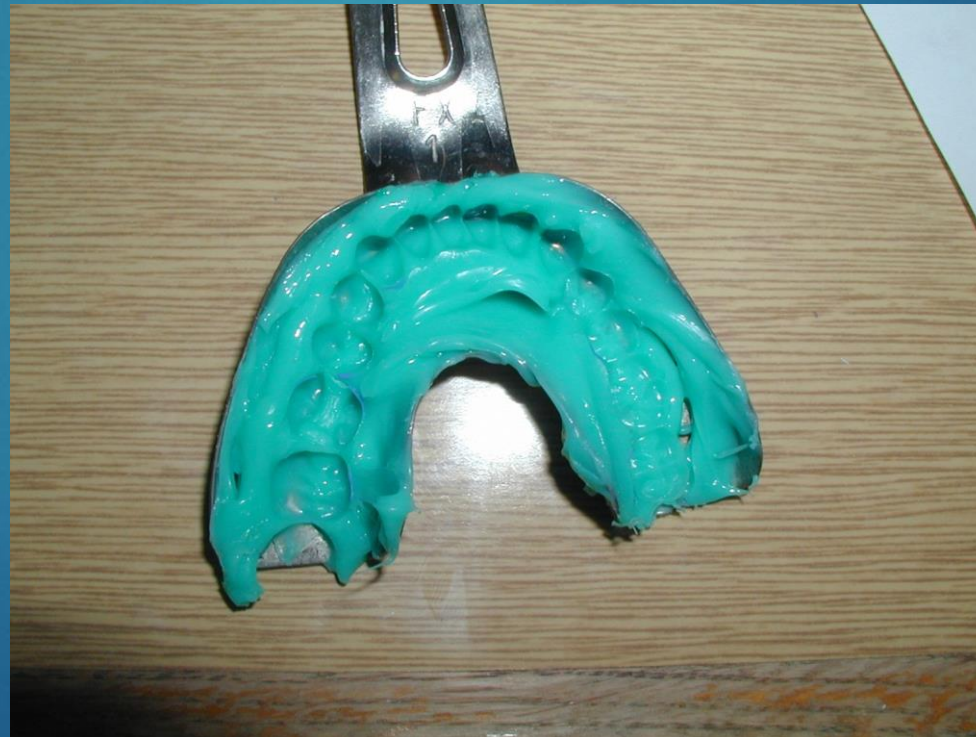

Registration of intermaxillary relationships

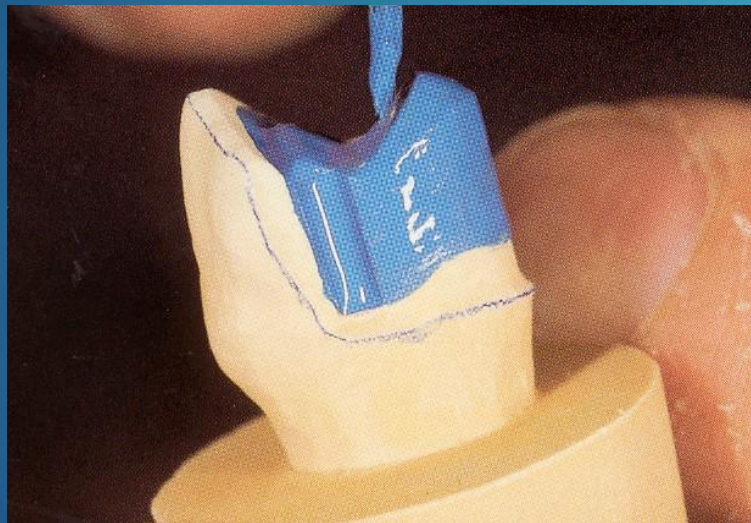
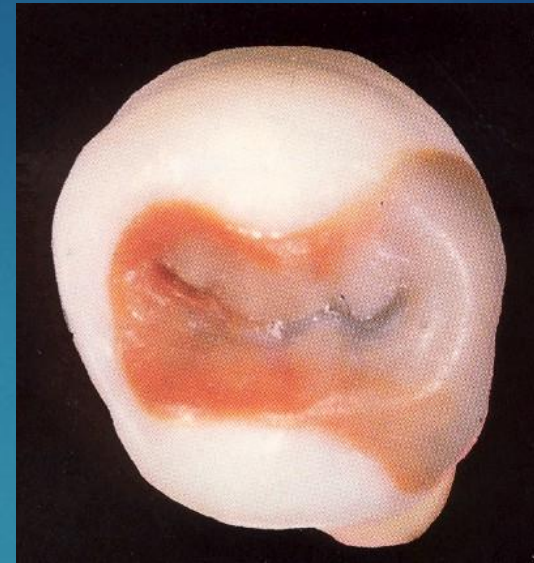
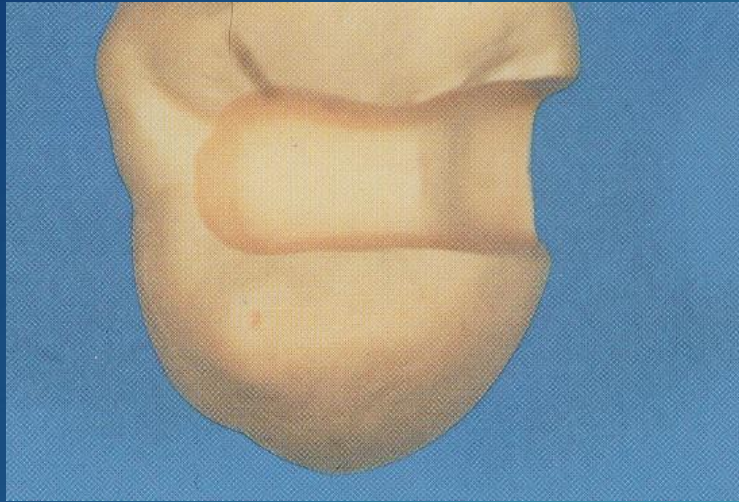
Wax registration

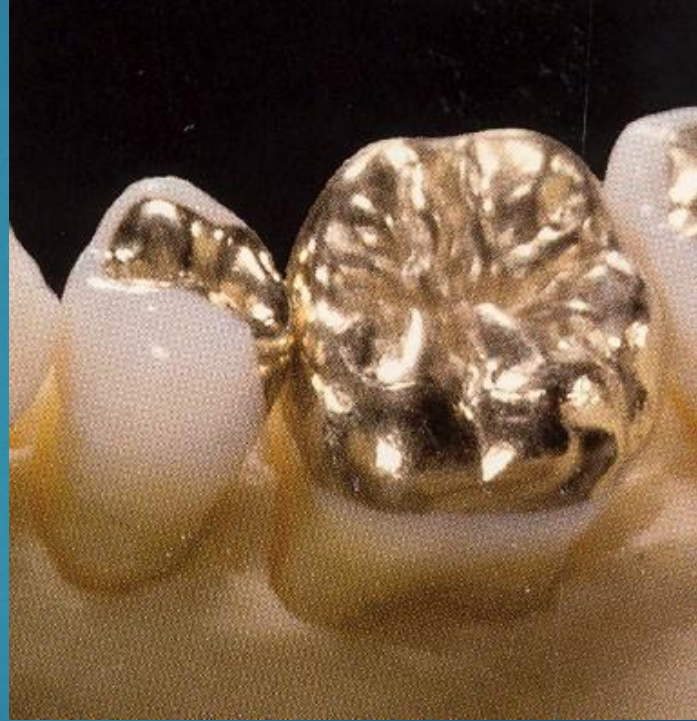
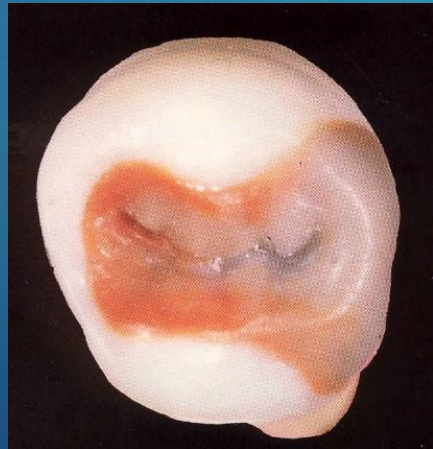
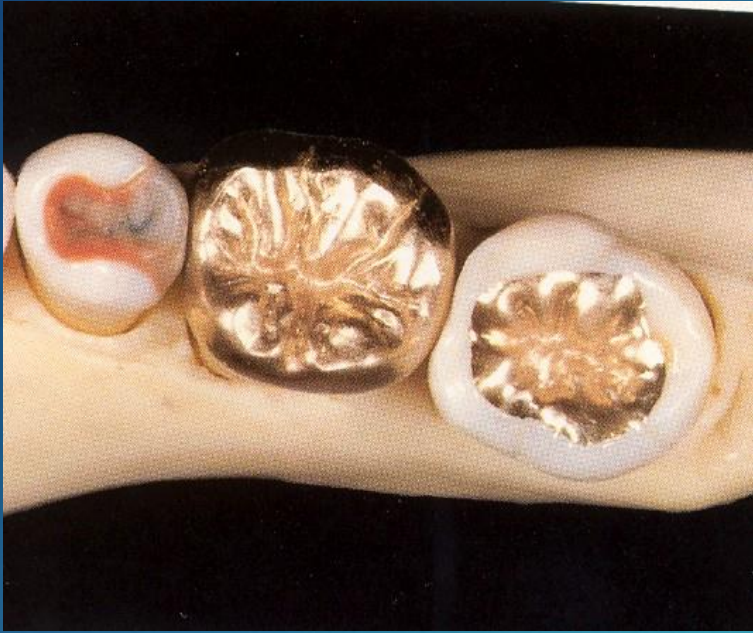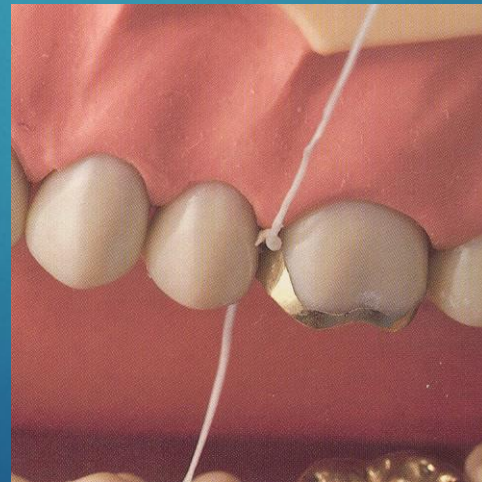
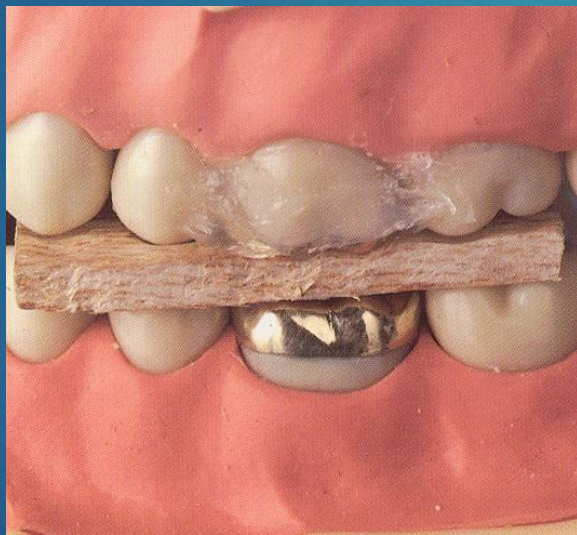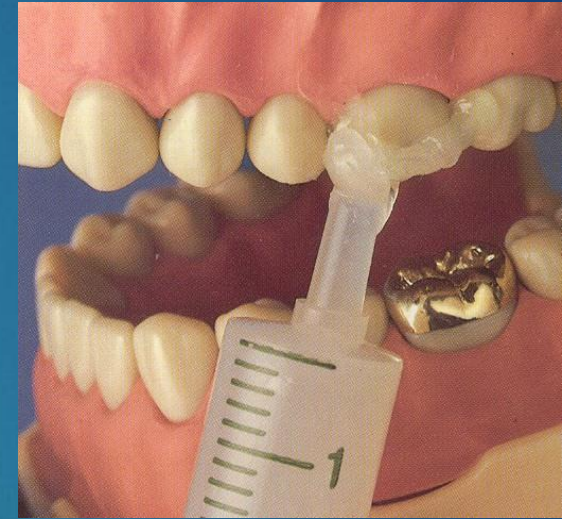
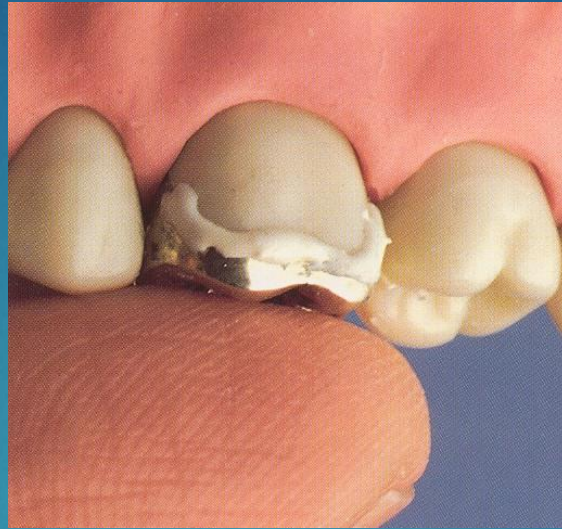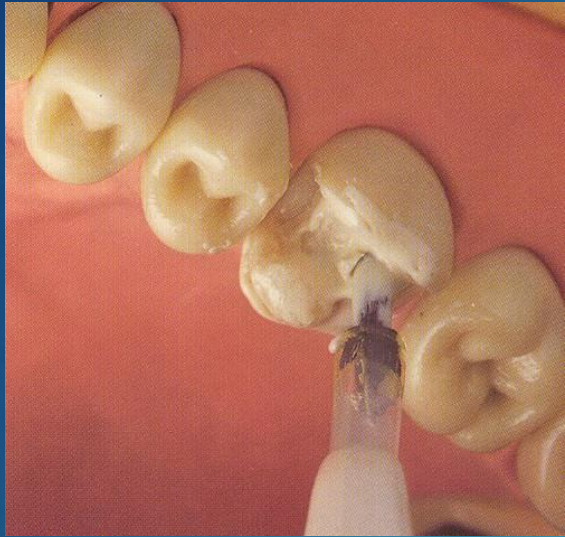
Antagonal impression alginate



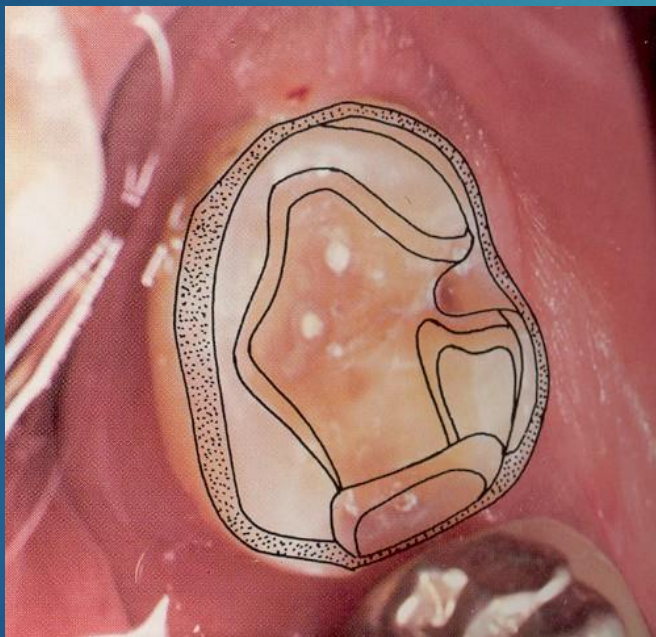
Fabrication



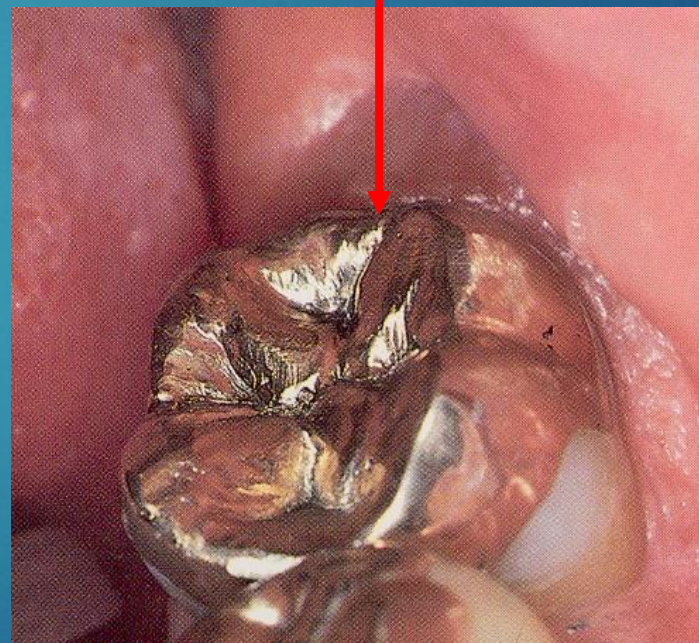




Preparation



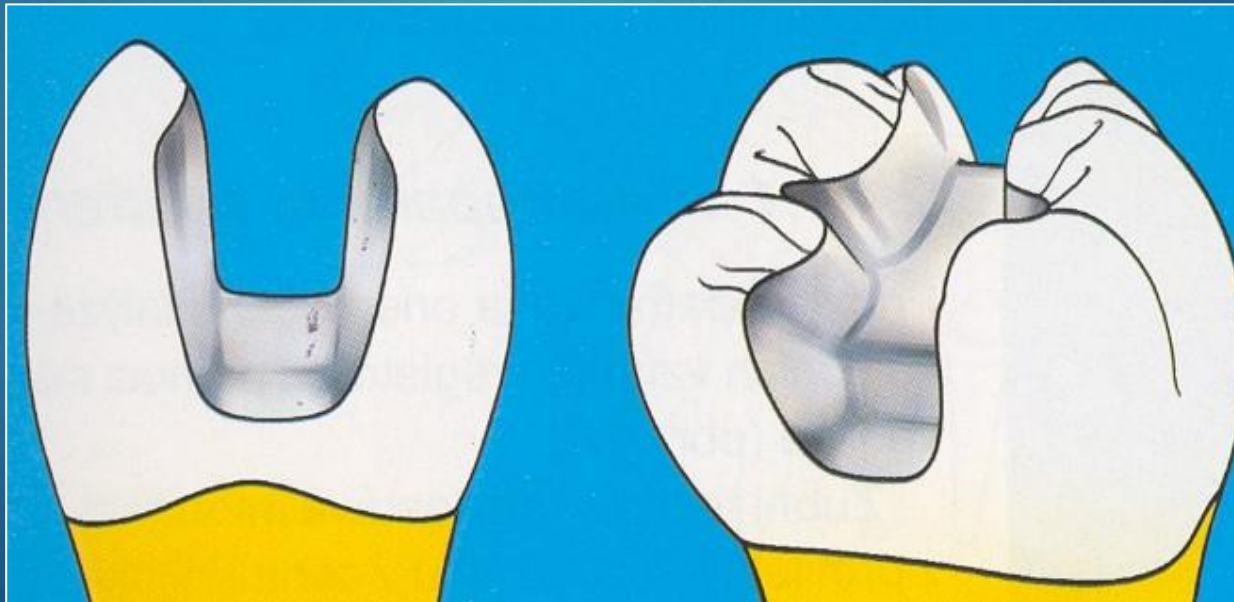
Restoration



Composite and ceramic inlays and onlays

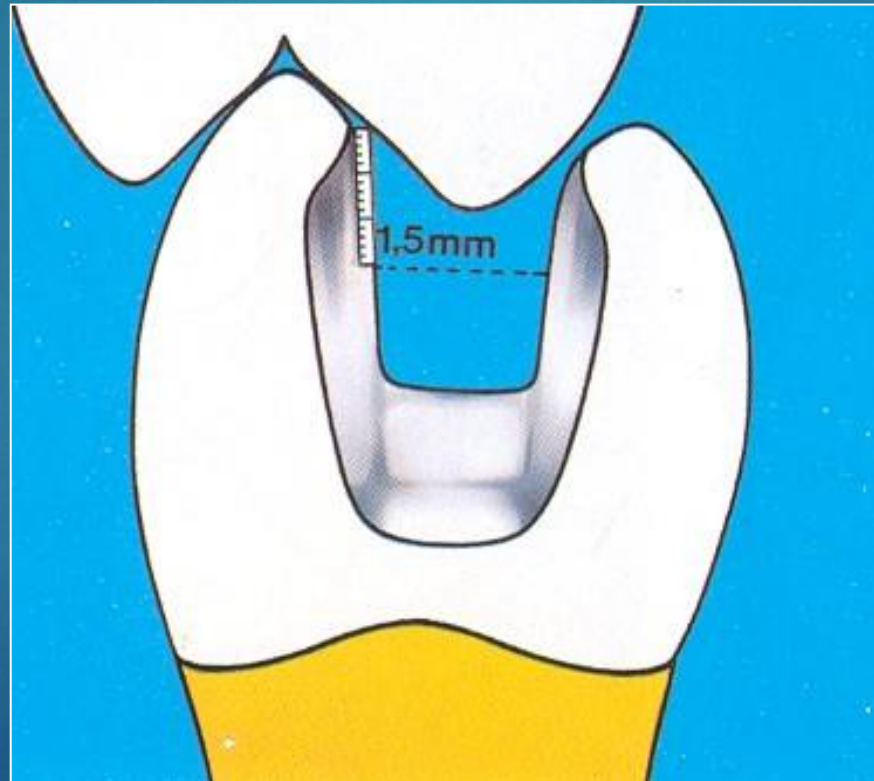
Preparation

Cavity without any undercuts with smooth borders. Divergency appr. 6°



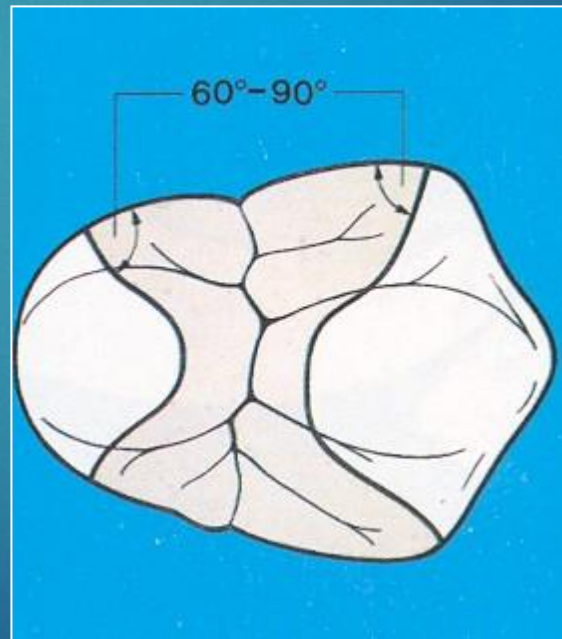
Preparation

Thickness of the material 1,5mm - 2 mm



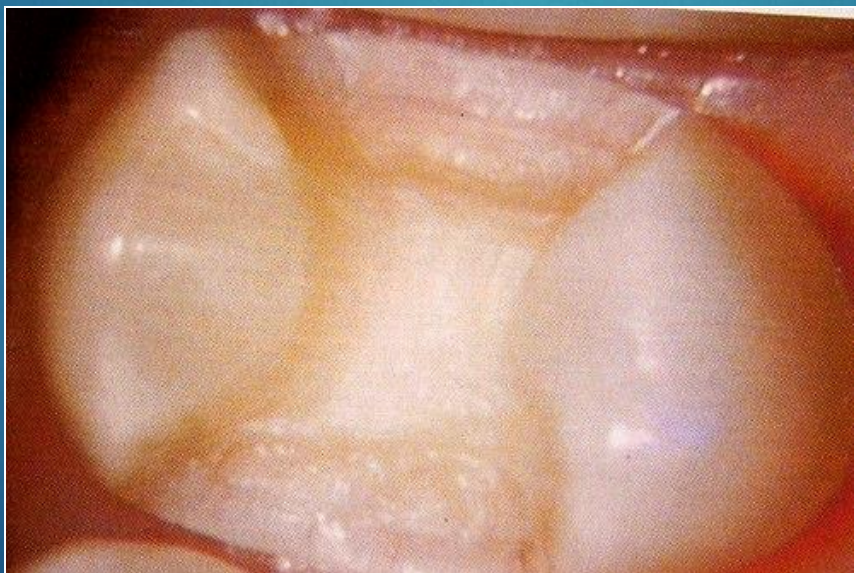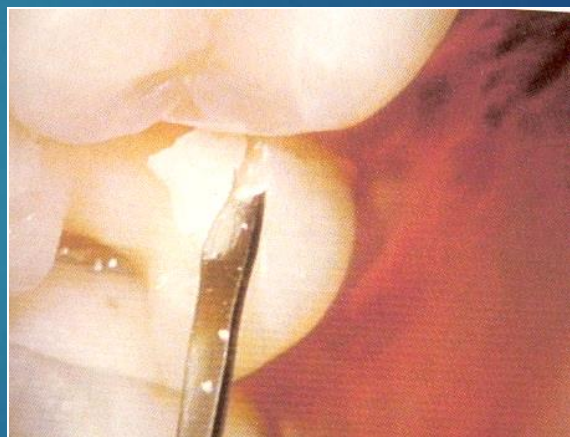
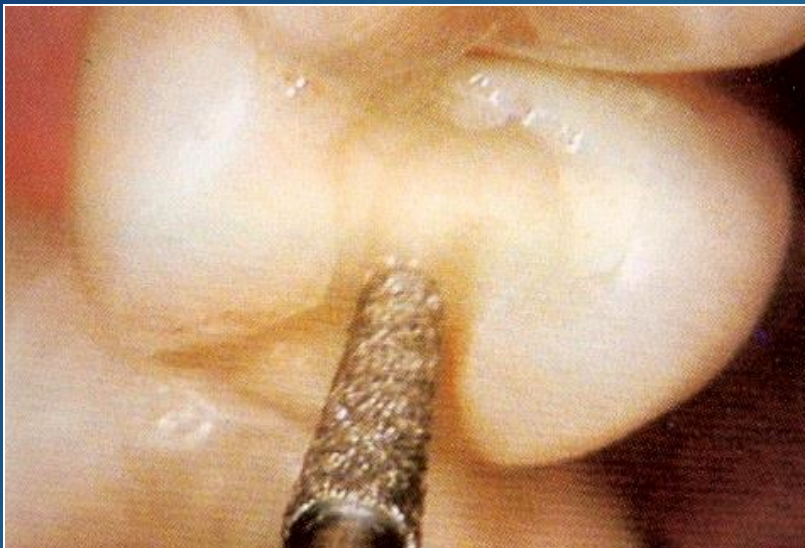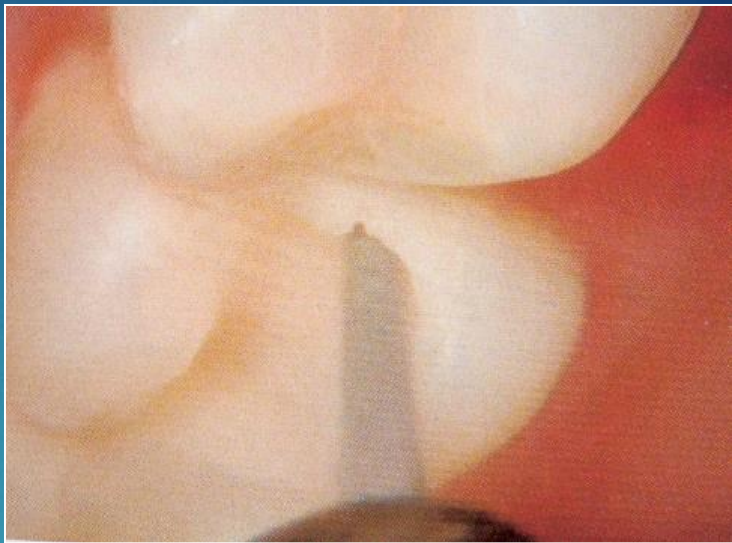
Preparation

- ▶ Cavo surface angle, smooth borders, slight bevel in proximal box only, not on occlusal surface






lenka.roubali
kova@tiscali
.cz



Before impression

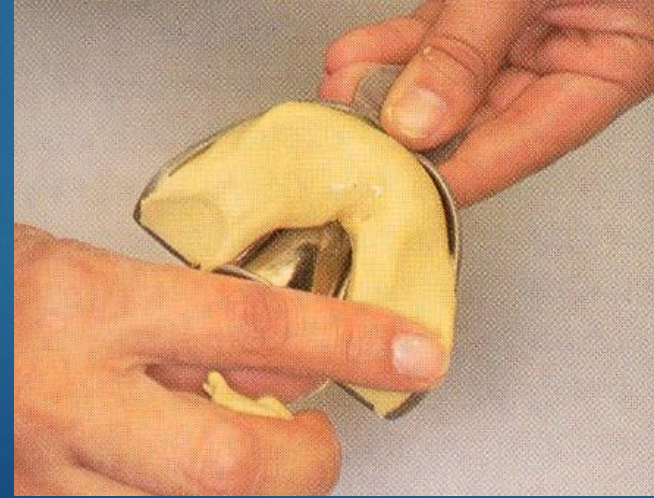
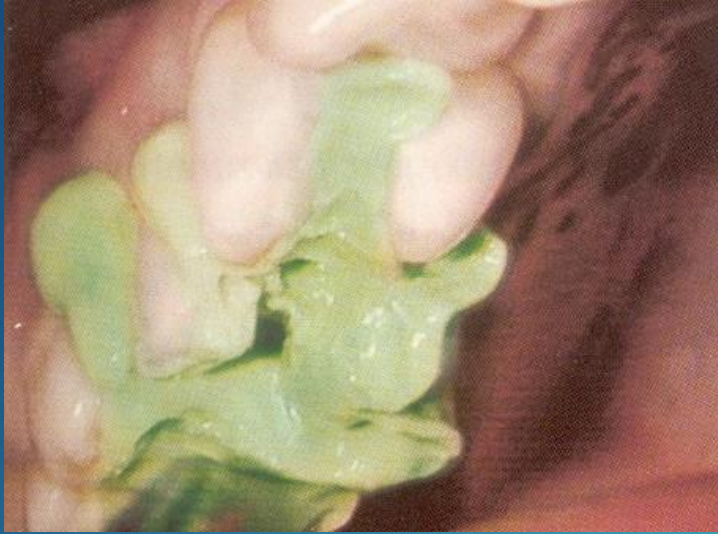


lenka.roubali
kova@tiscali
.cz

Closure of dentine tubules – adhesive treatment and flowable on the walls

Impression Elastomers

One phase



Registration of intermaxillary relationships

Wax registration



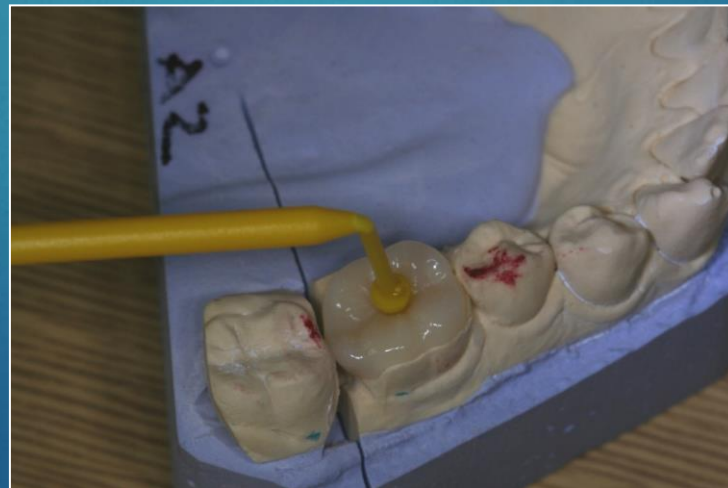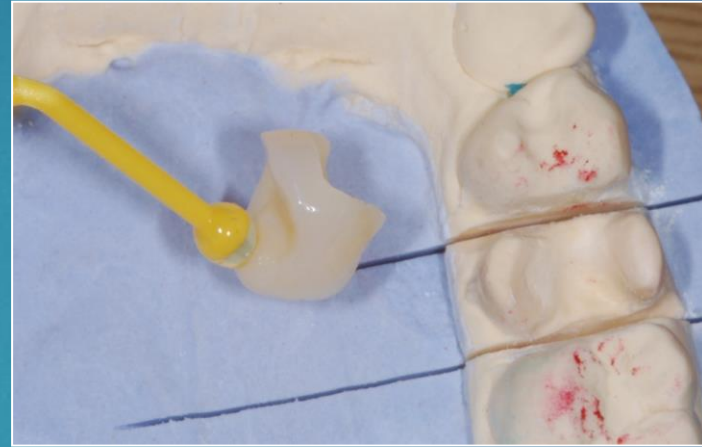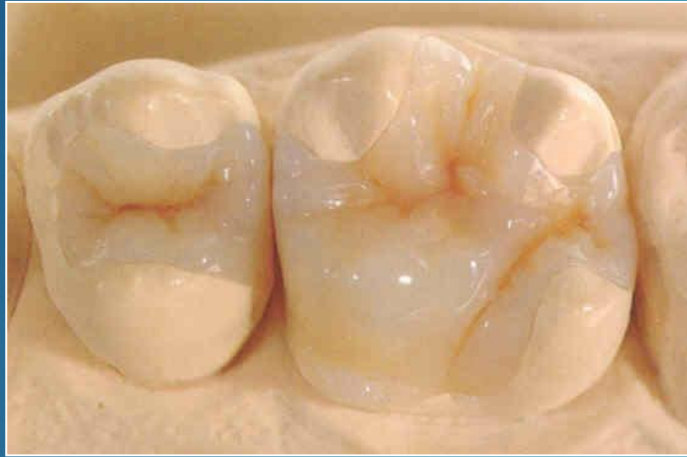Antagonal impression alginate



Registration of intermaxillary relations

Wax

Fabrication – various procedures



Cementation of ceramic and composite inlays

- ▶ Adhesive cementation
 - Special composite materials with lower viscosity dual curing
 - Micromechanical retention

Adhesive cementation

Hard tissues – adhesive procedures: acid etching, bonding, priming)

Restoration – sandblasting or special etching, bonding.



lenka.roubali
kova@tiscali
.cz

