

Klinická anatomie kloubů

aneb

jejich slabá místa

Martin Repko

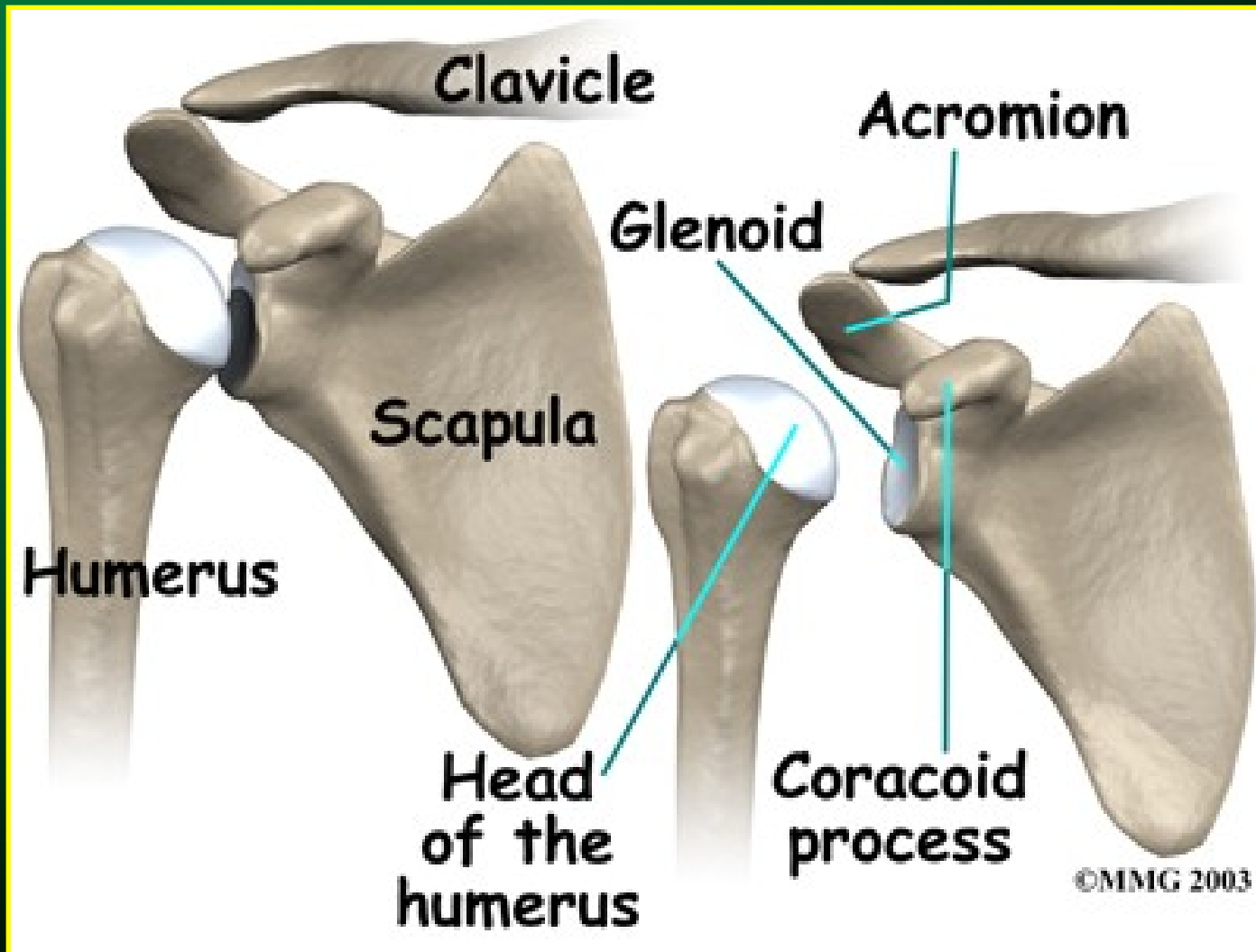
Andrea Šprláková-Puková

Snímky použity z archivu RDK FNB

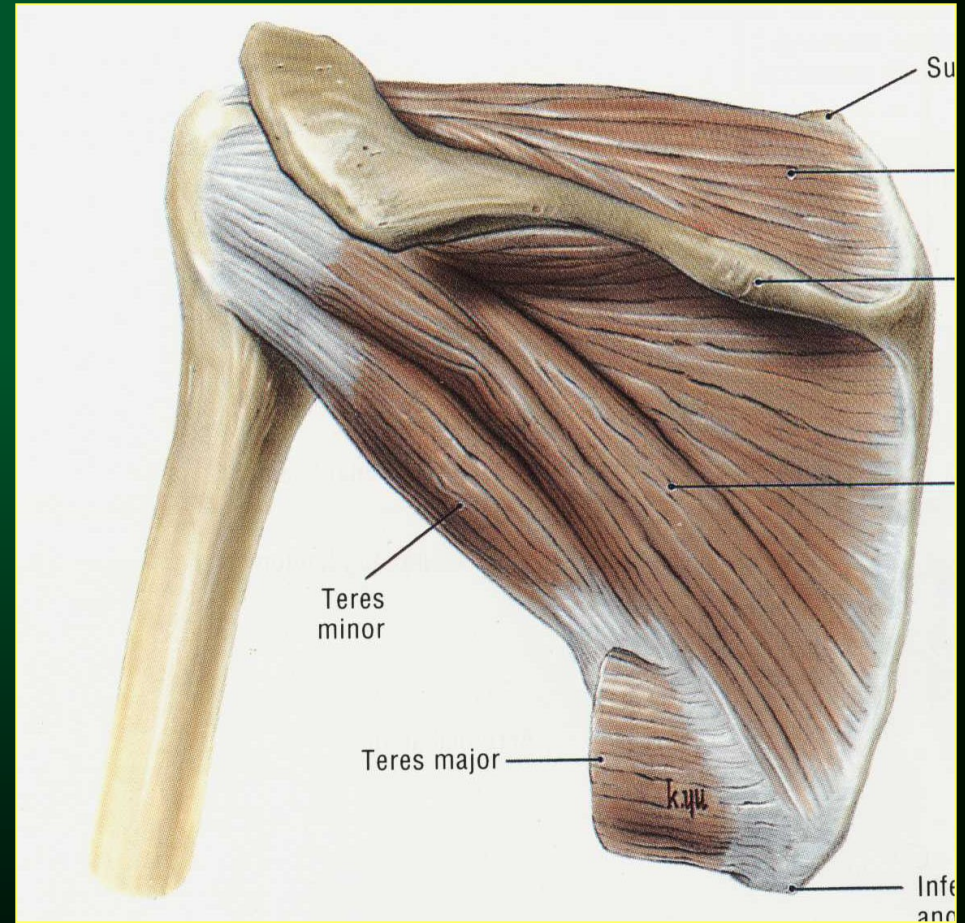
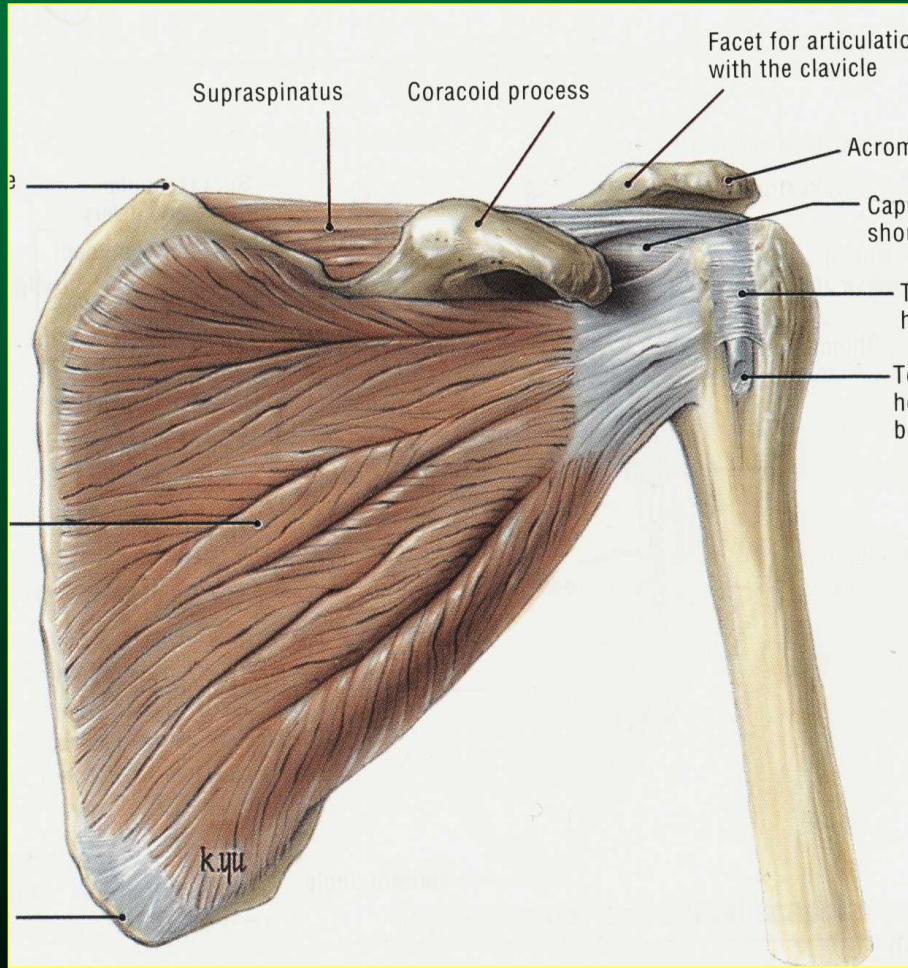
schémata z výukových materiálů MMG 2001-03

RAMENO

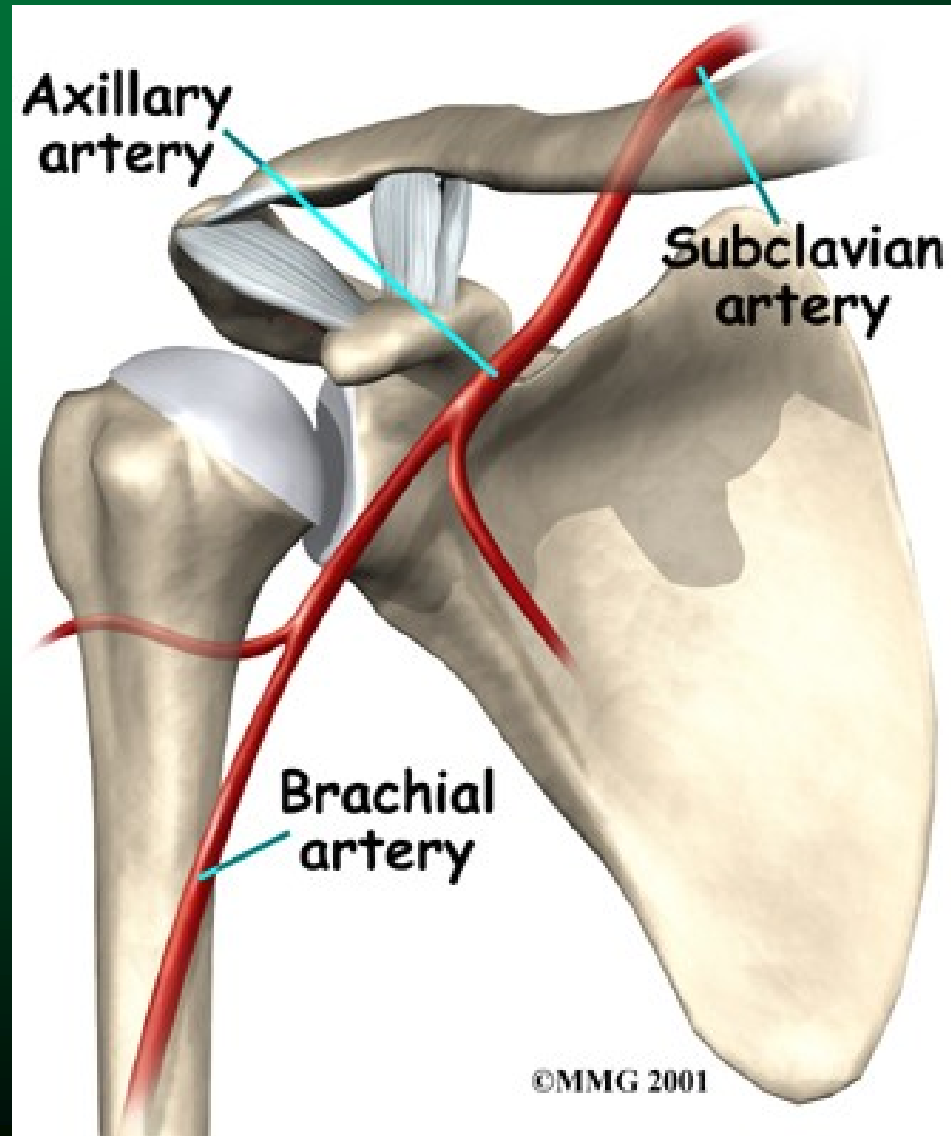
Anatomie - kosti



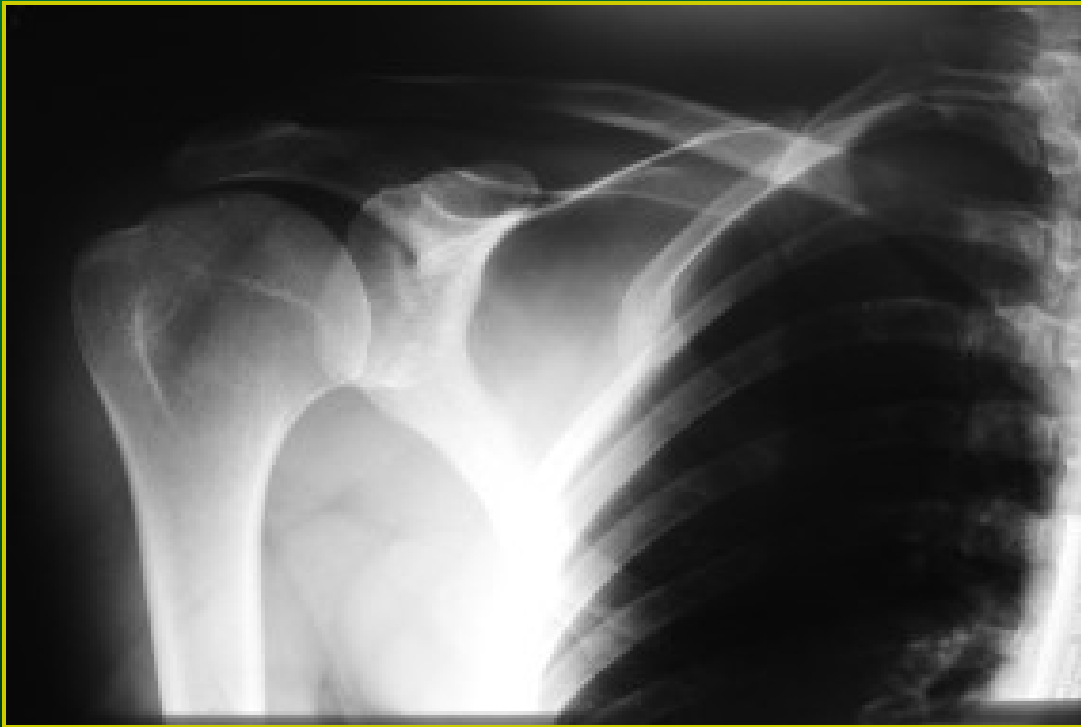
Anatomie svaly



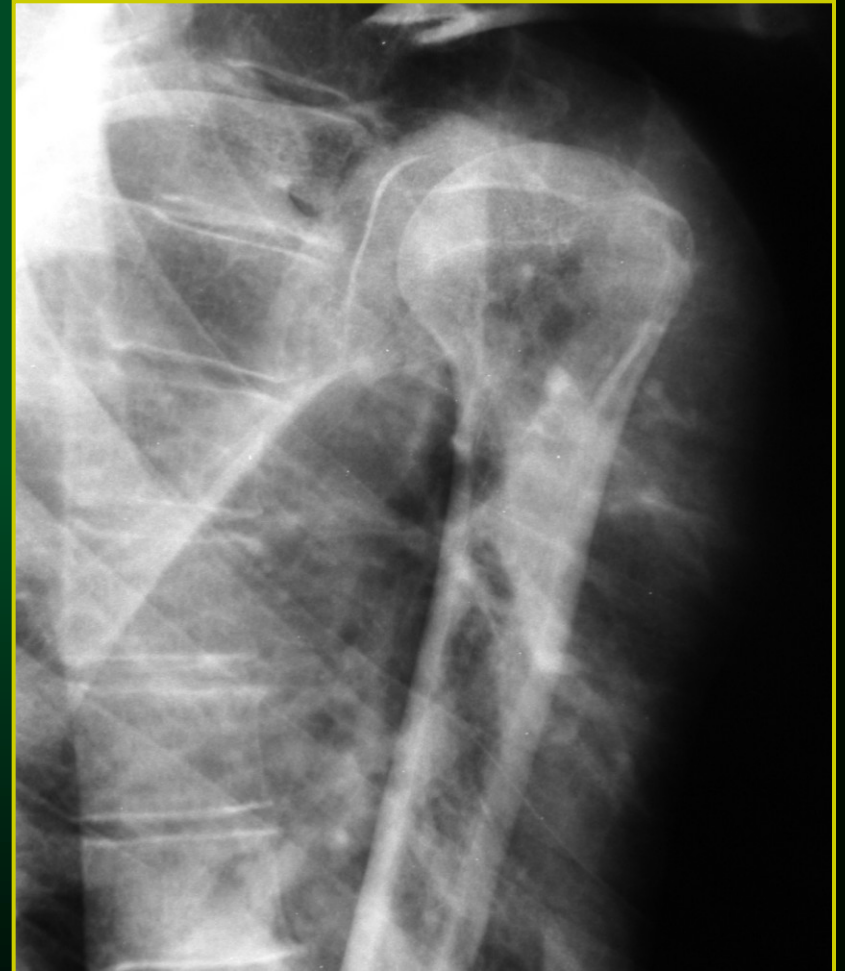
Anatomie - cévy



AP snímek



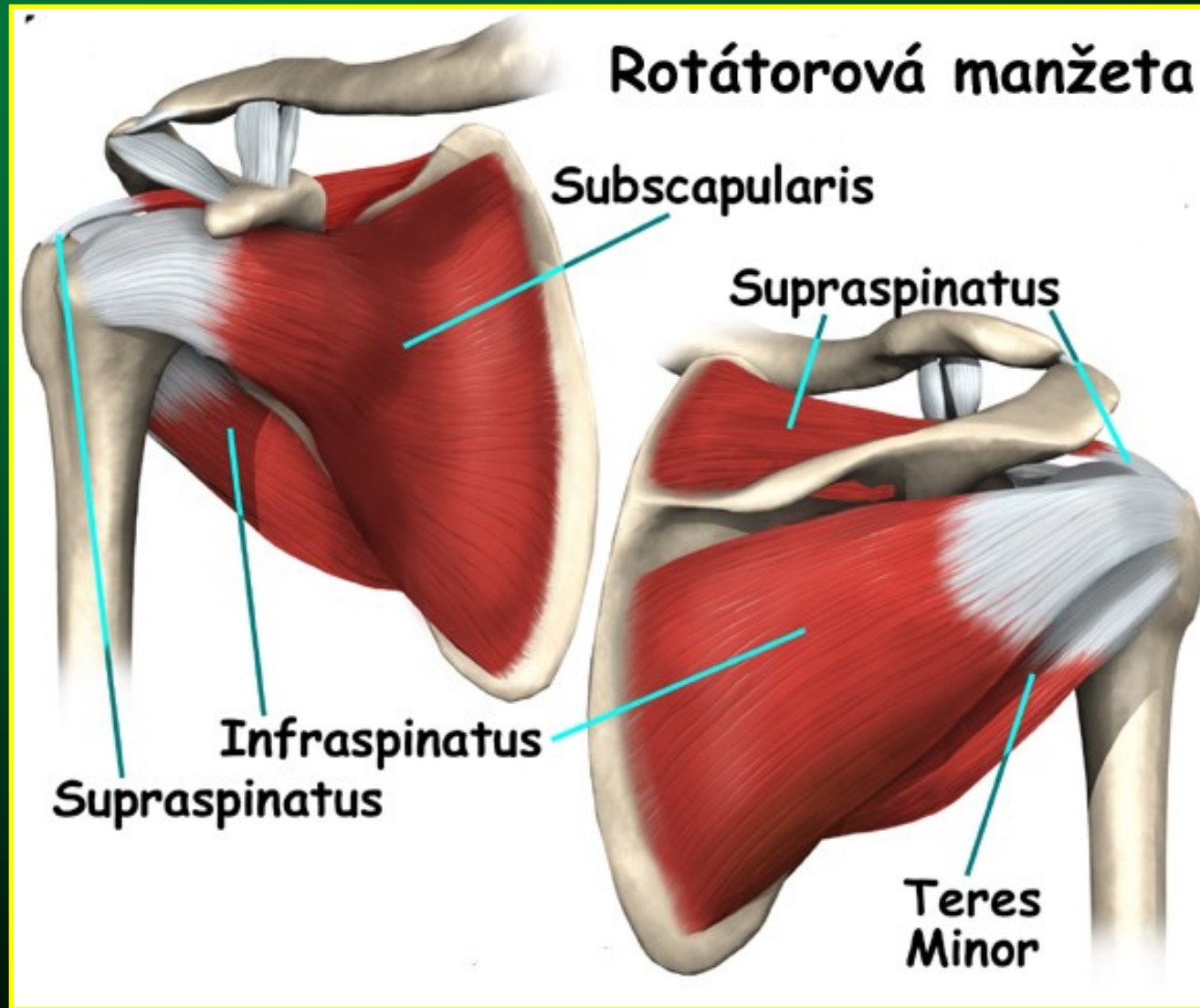
Transtorakální pr.



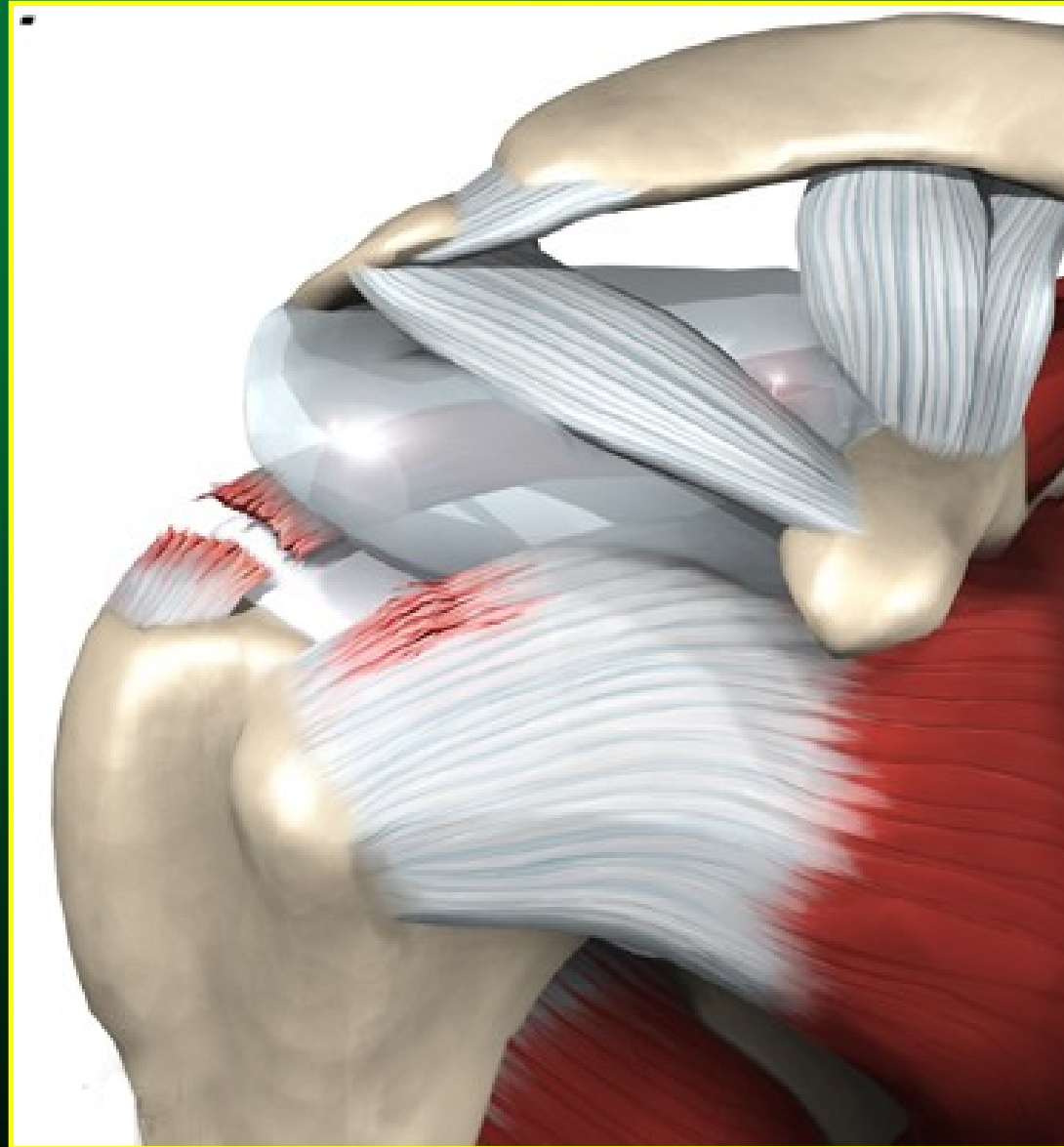Nejčastější postižení ramene

- impingement syndrom
 - postižení rotátorové manžety
- akromioklavikulární poranění
- luxace ramene
- artróza ramenního kloubu

Rotátorová manžeta

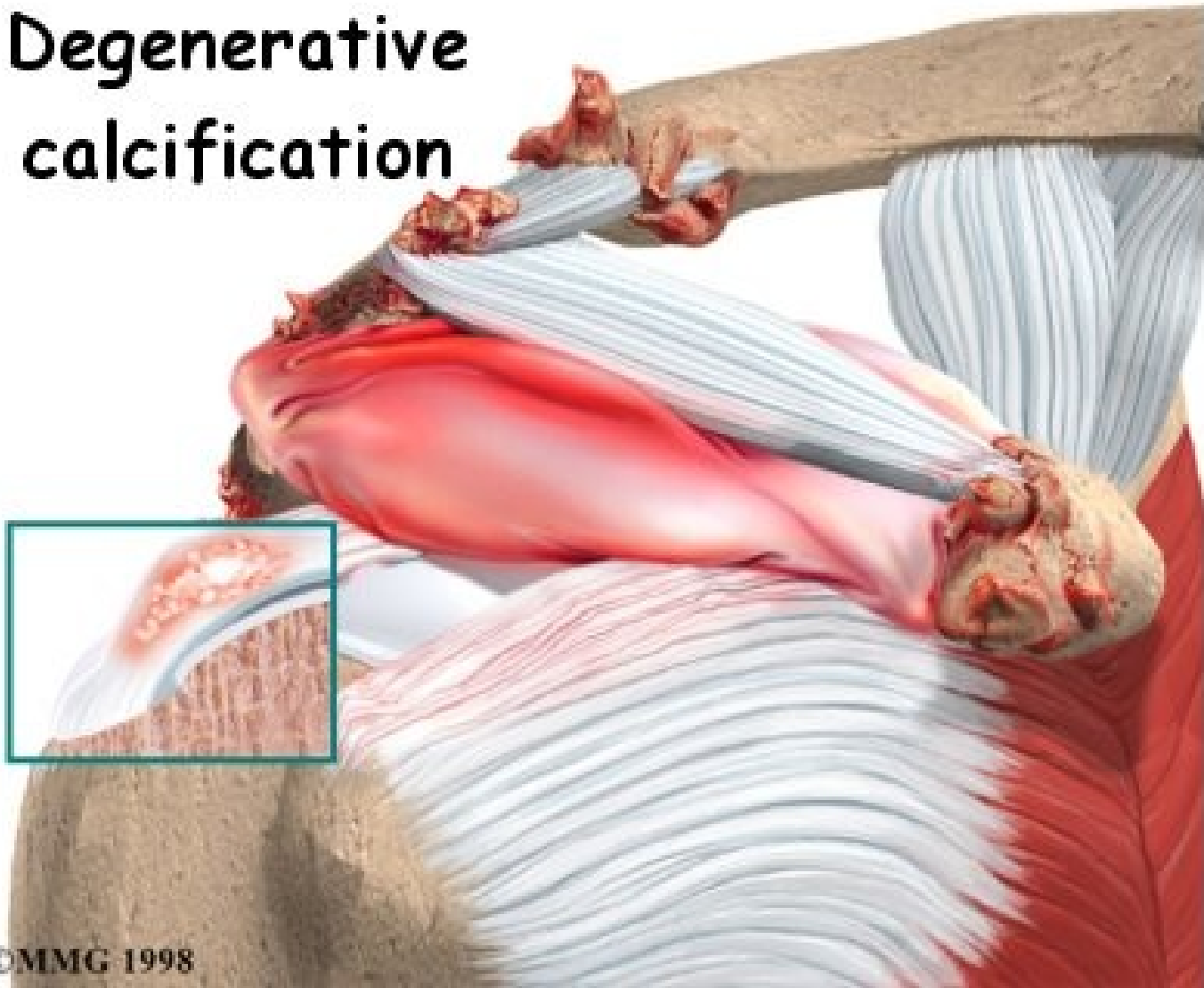


Ruptura rotátorové manžety

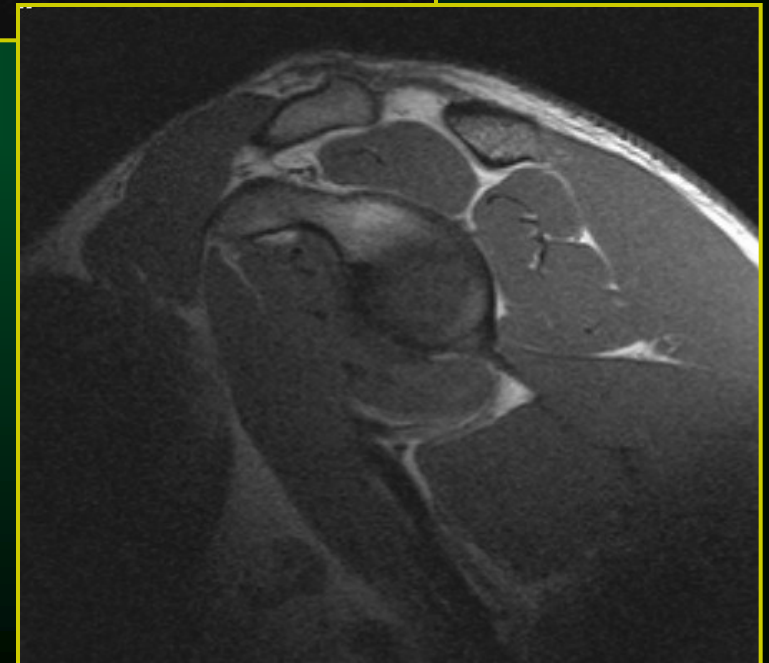
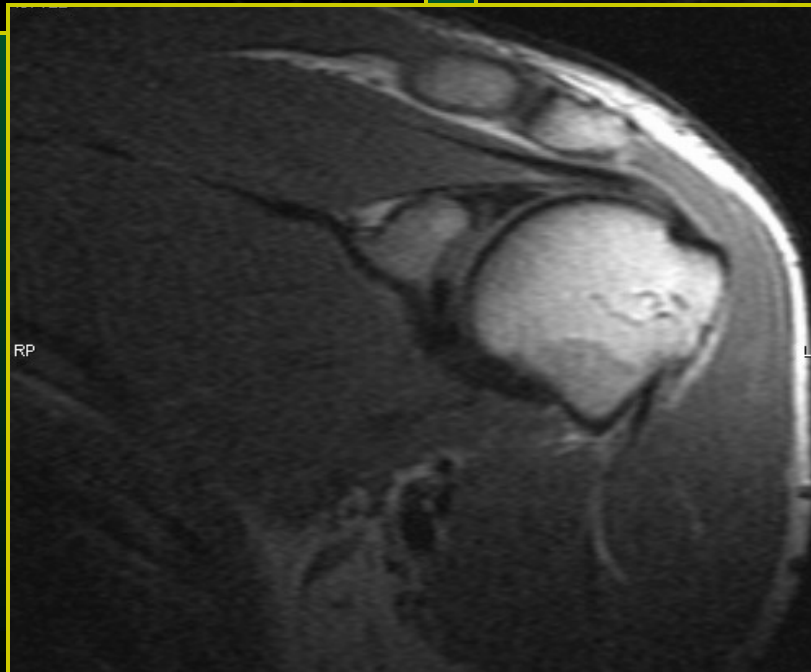
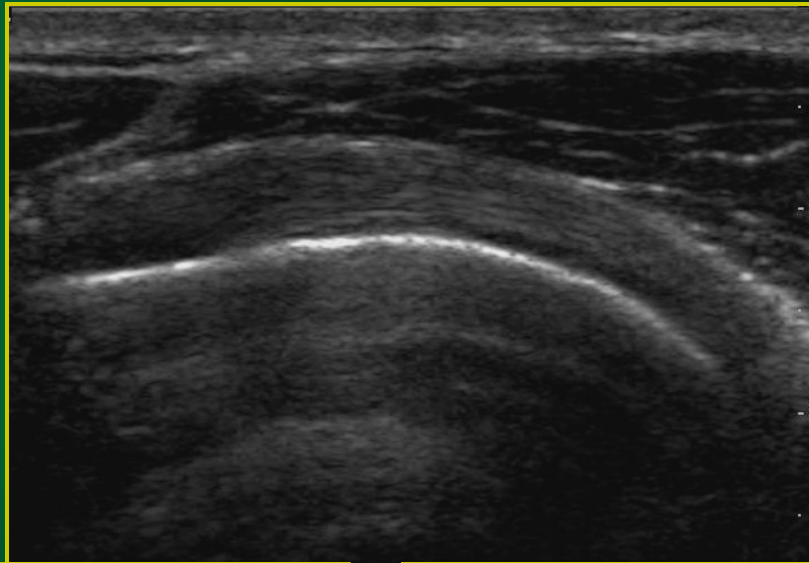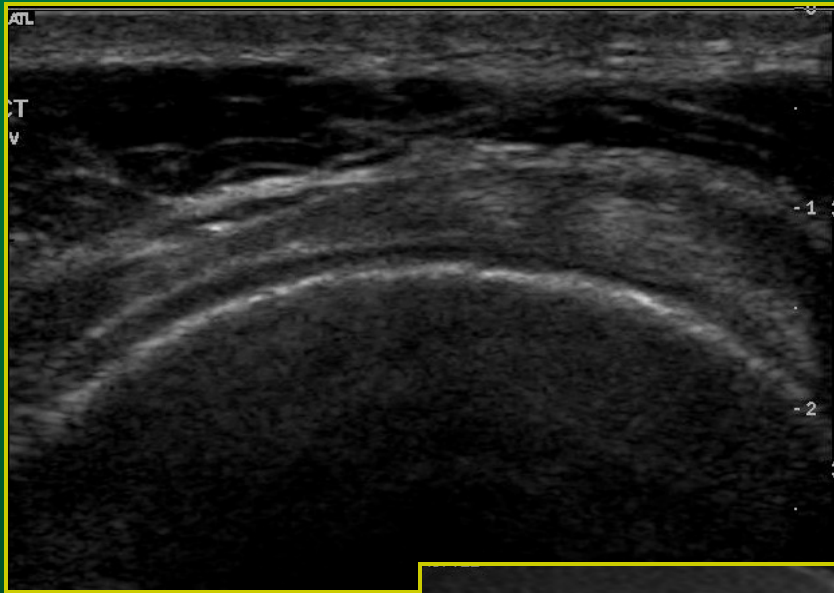


Ruptura rotátorové manžety

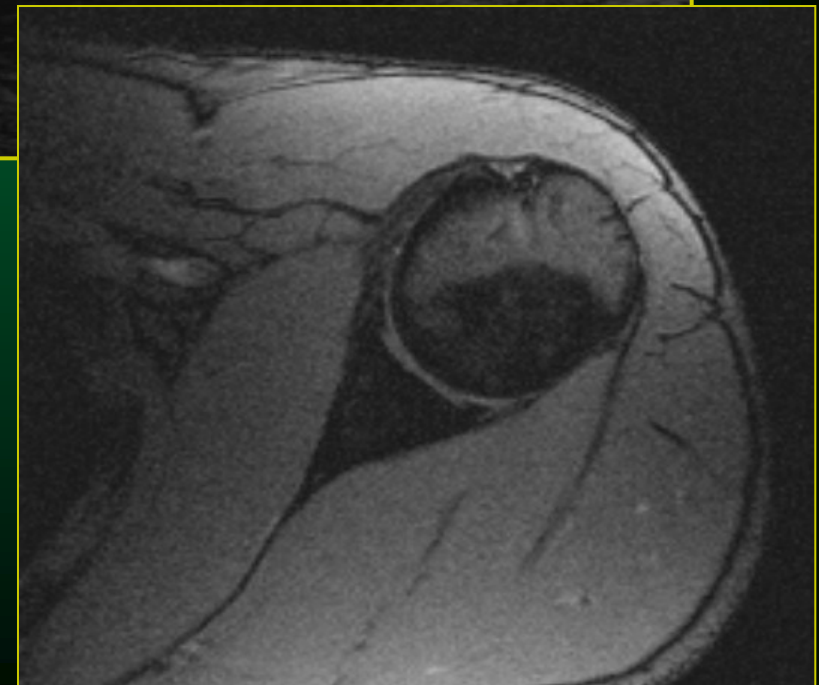
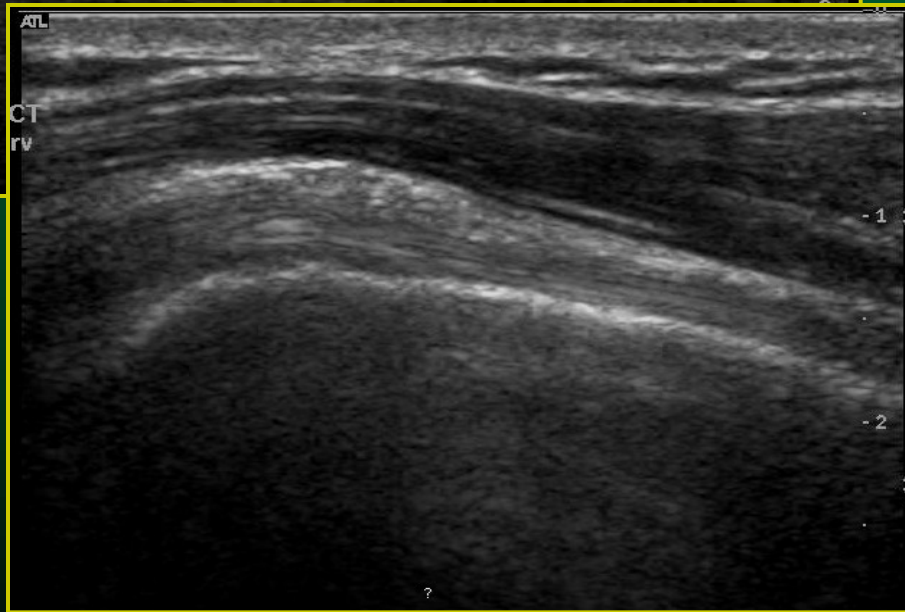
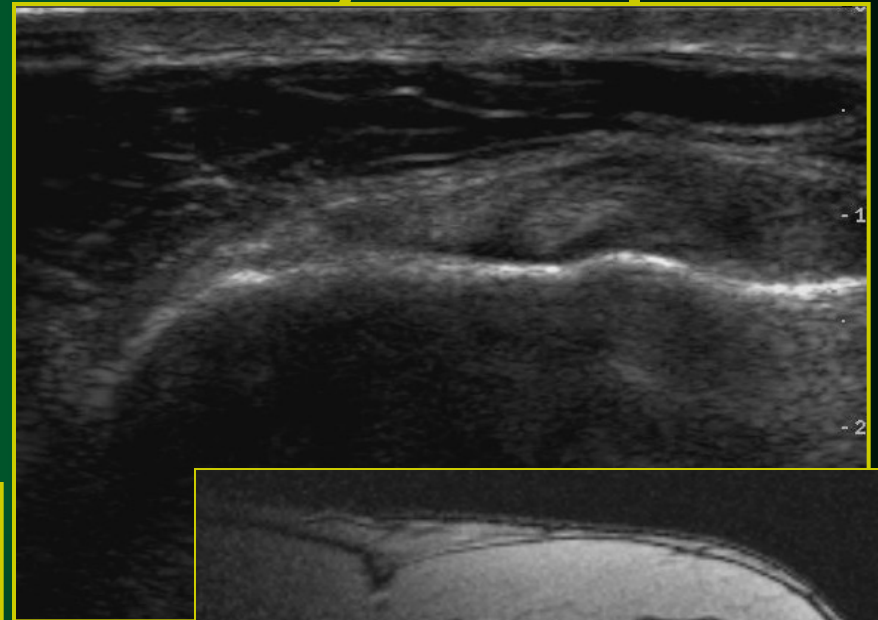
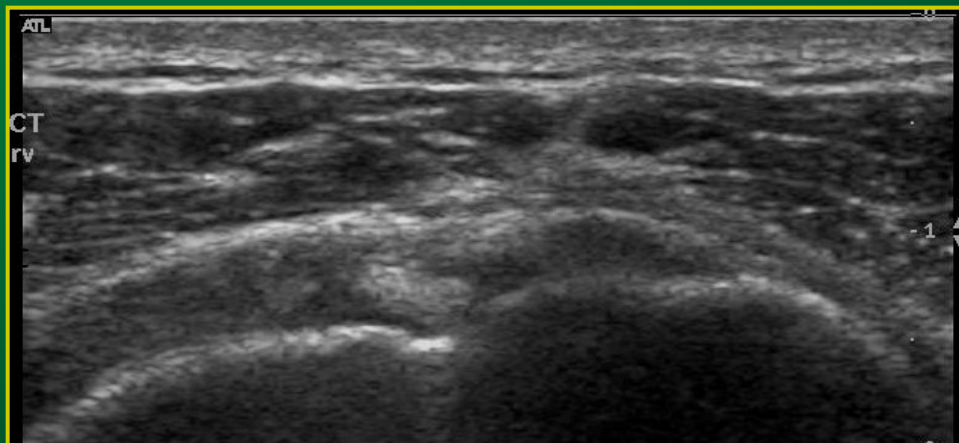
Degenerative
calcification



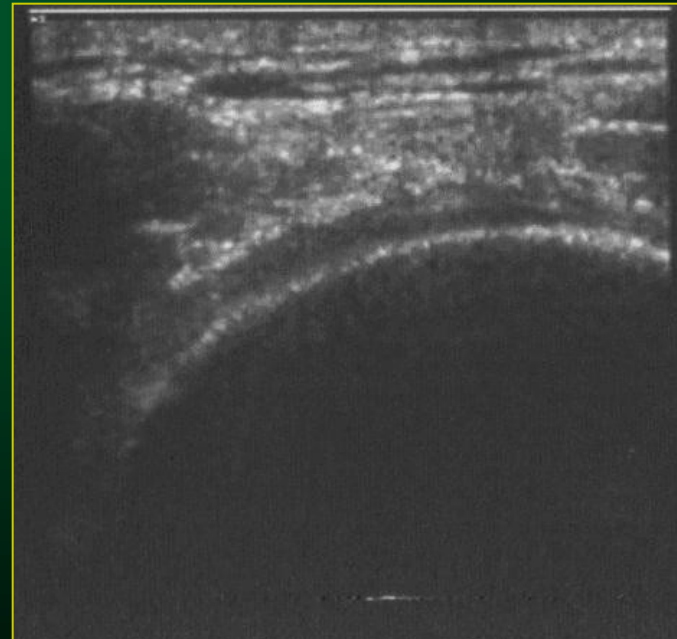
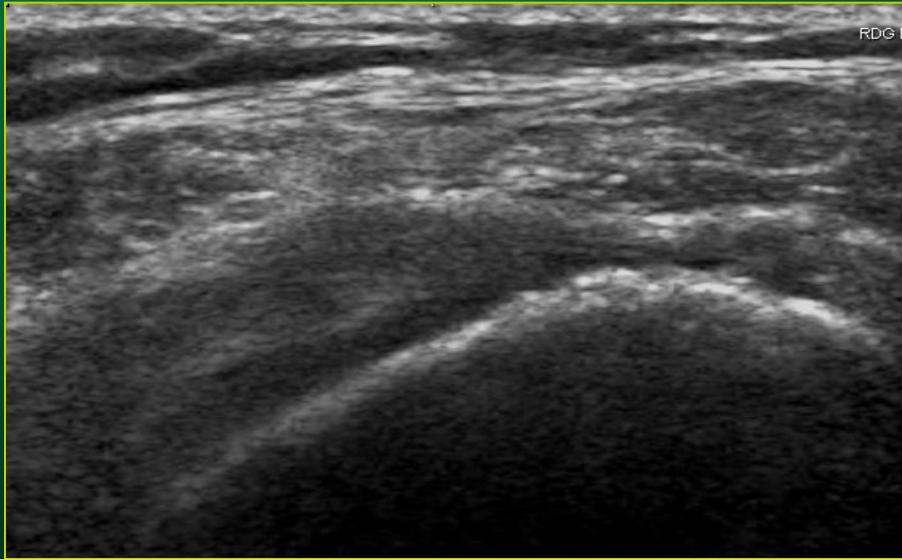
Manžeta rotátorů – UZ a MR obraz



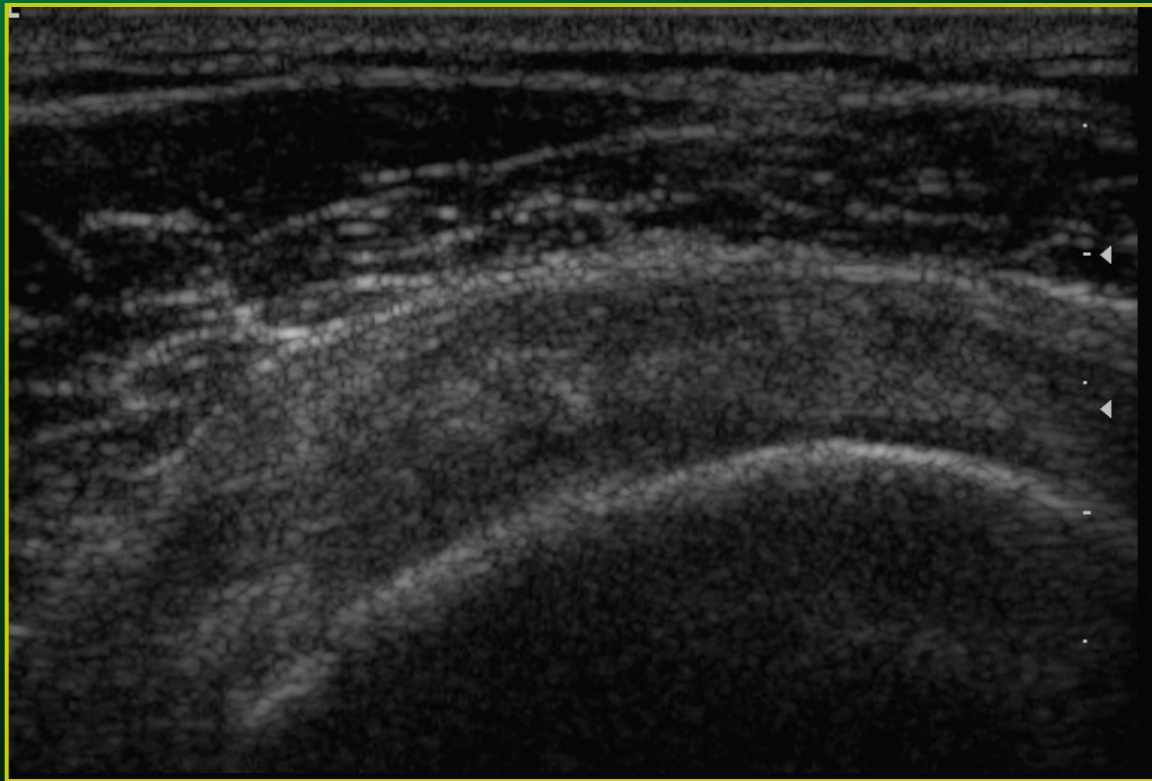
Šlacha dlouhé hlavy bicepsu



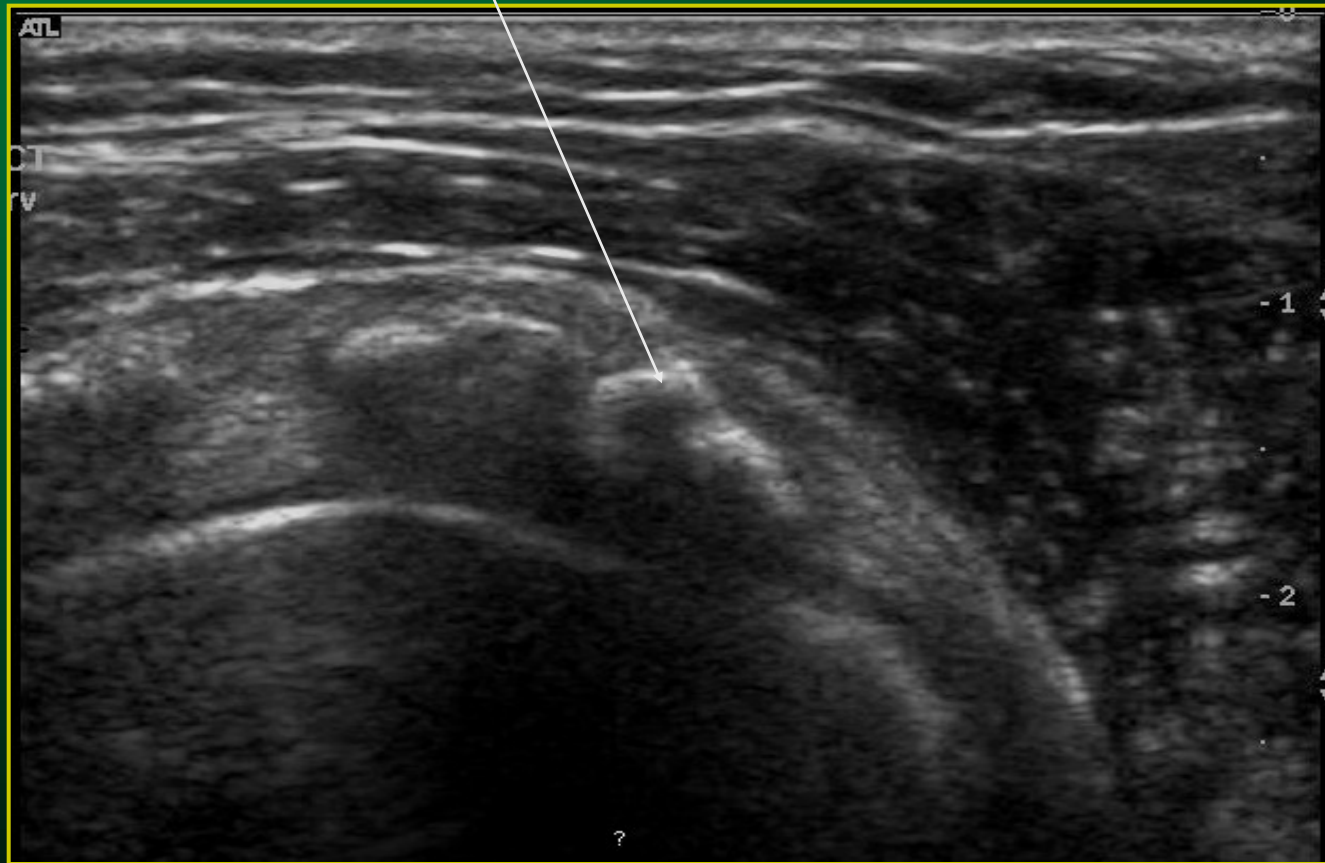Ruptura manžety rotátorů – UZ obraz



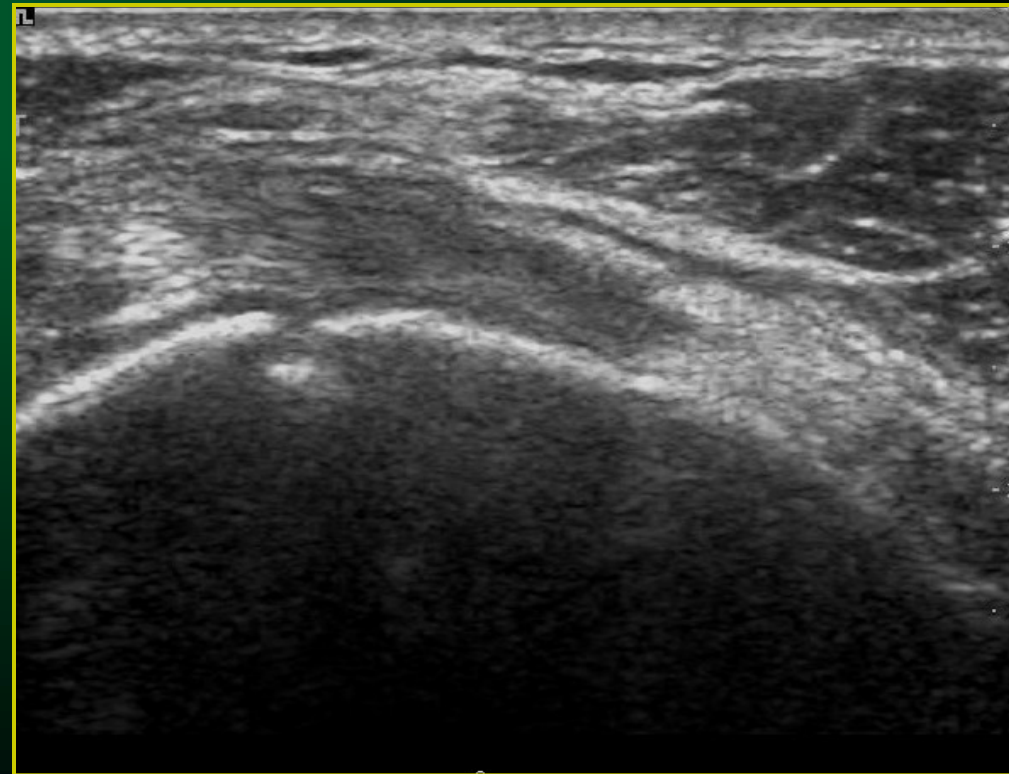
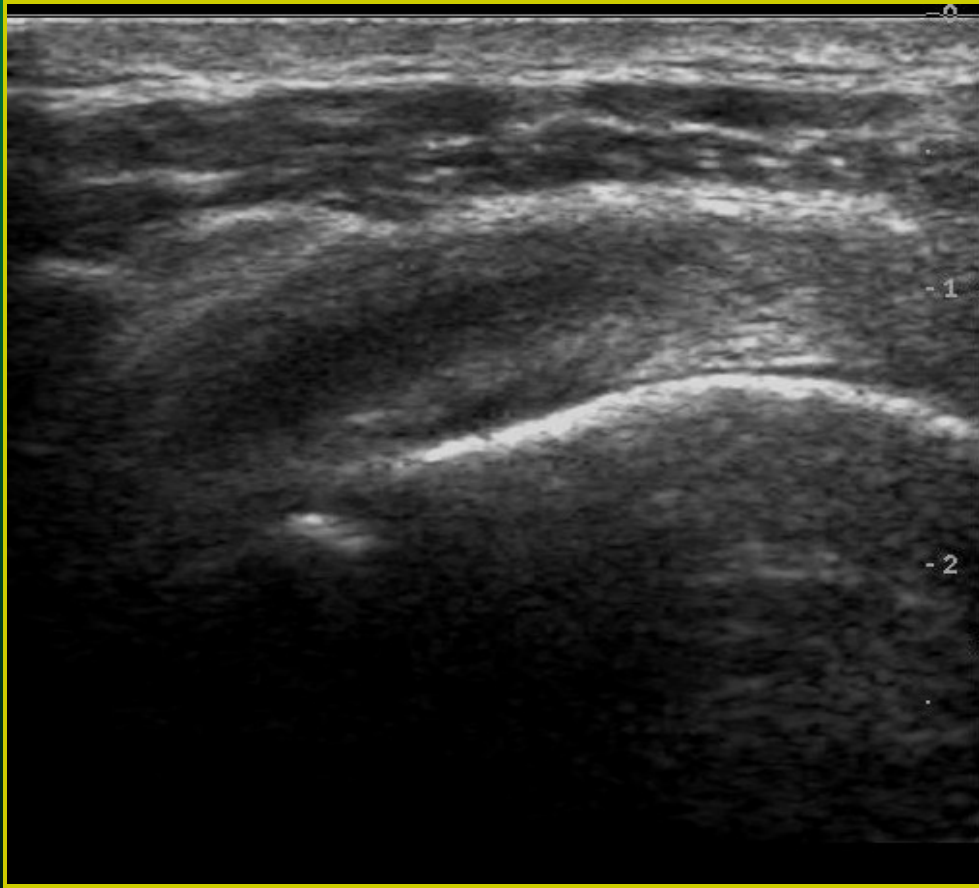Impingement syndrom – UZ obraz



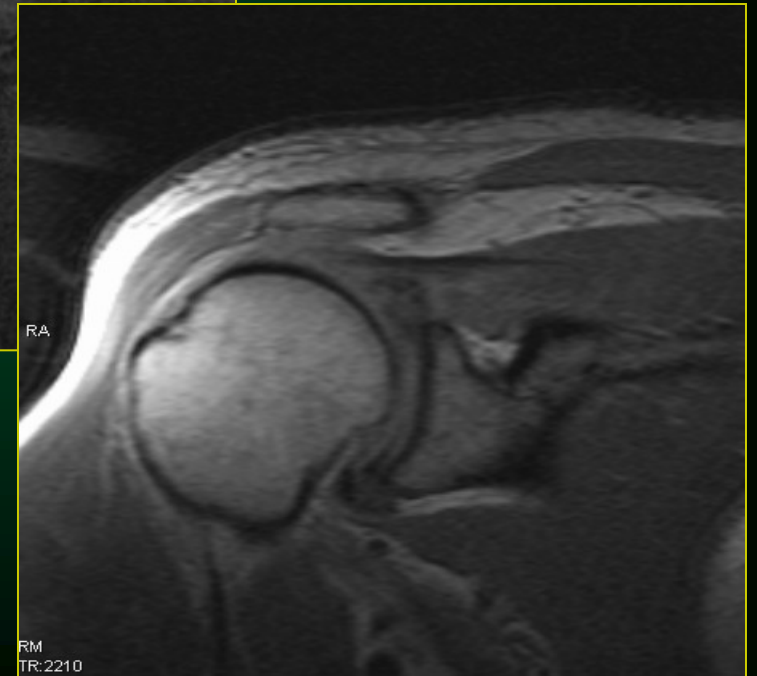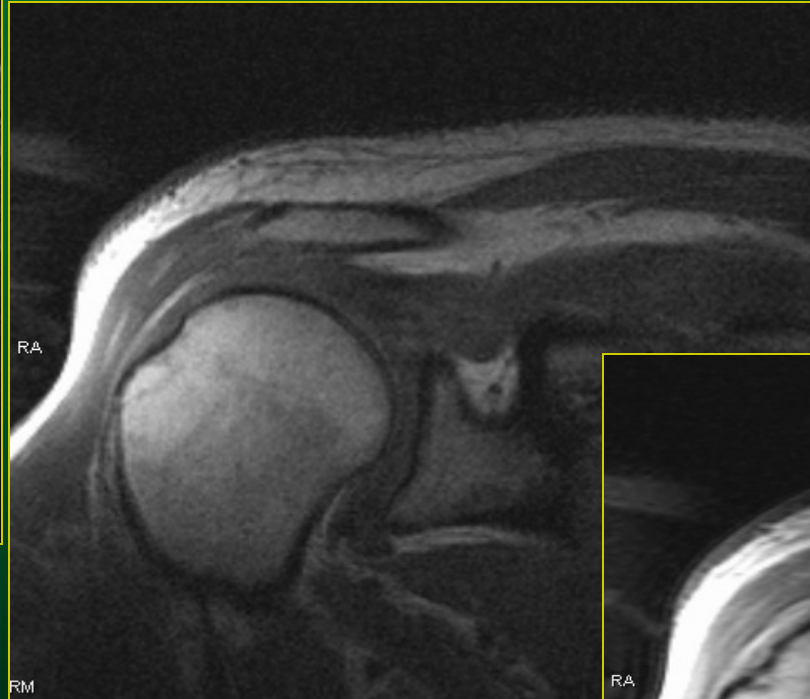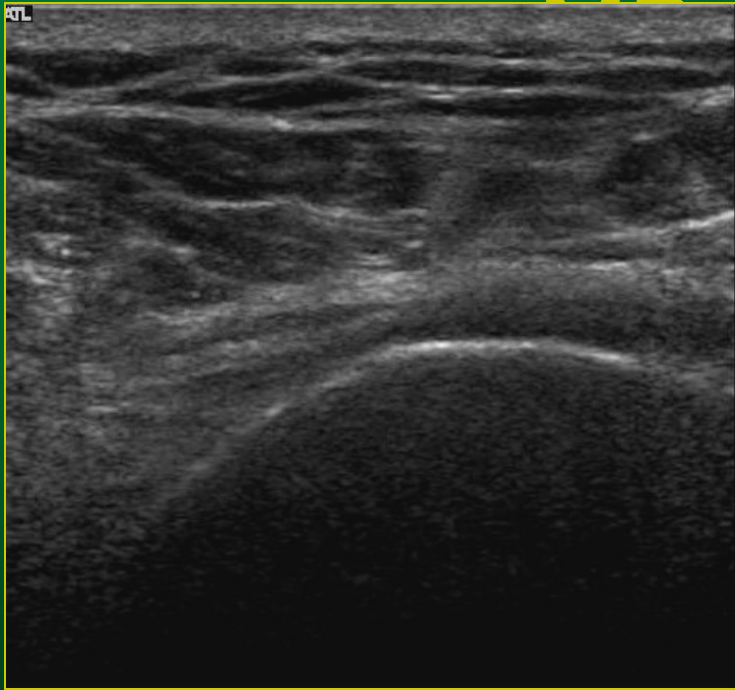
Kalcifikace - UZ obraz



Manžeta rotátorů, hlavice humeru

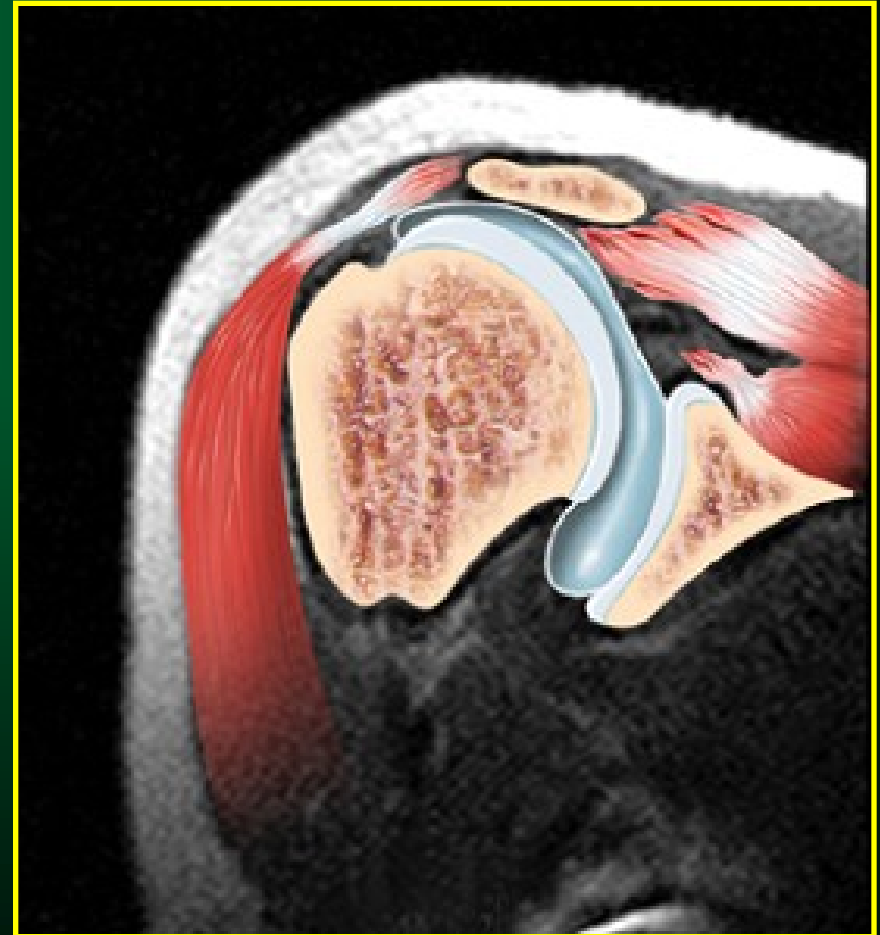
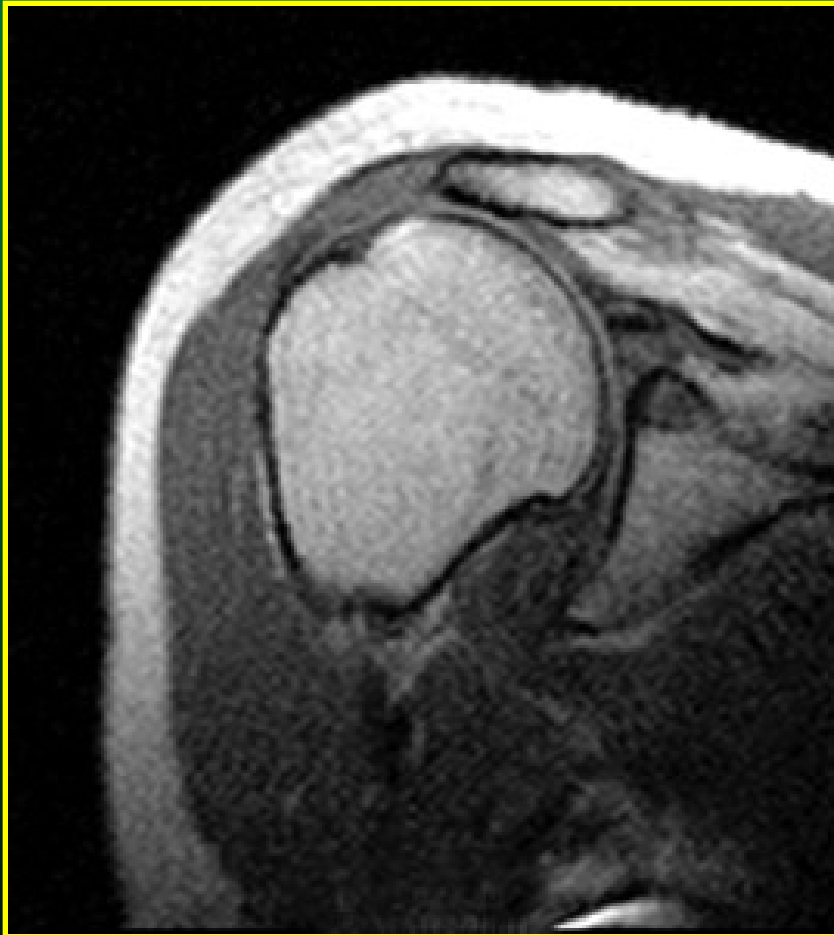


Ruptura manžety rotátorů – UZ obraz

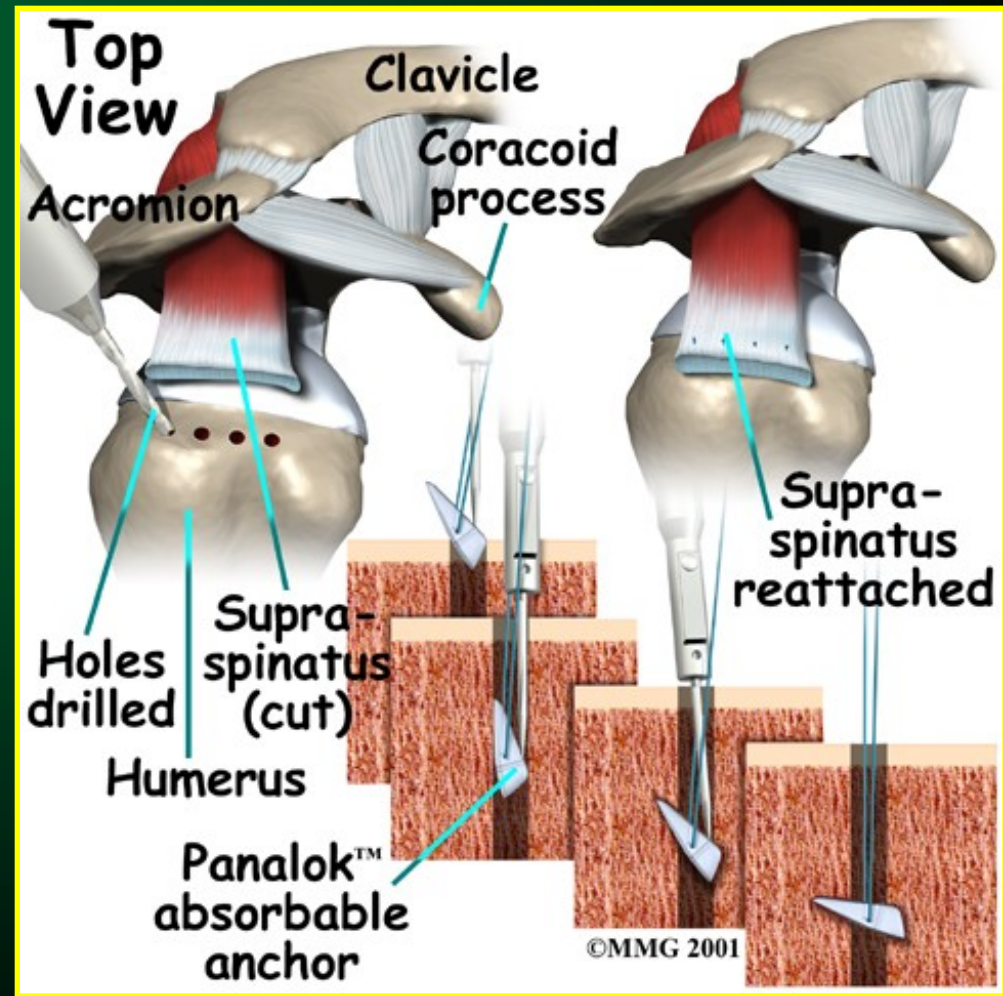
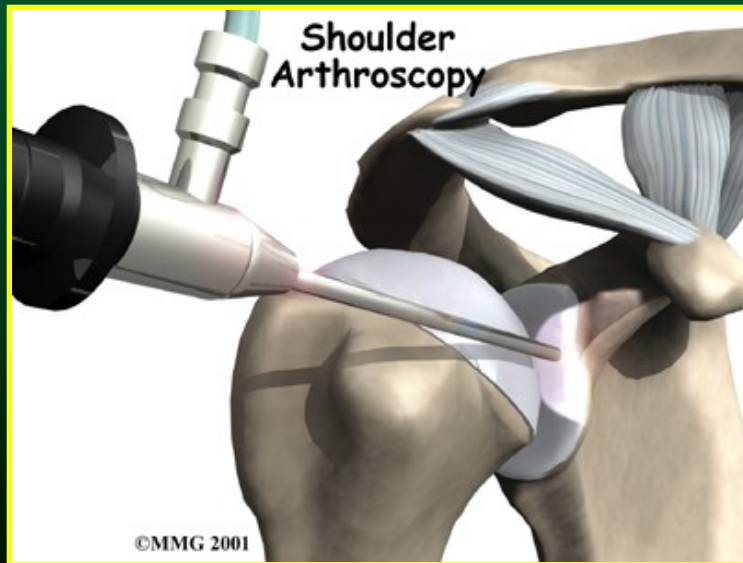
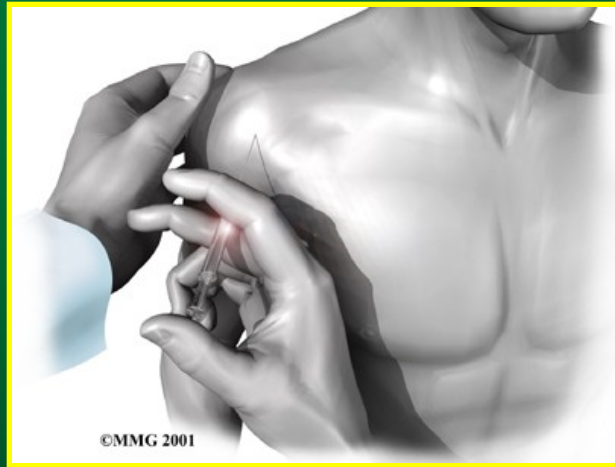

MR diagnostika

ruptury rotátorové manžety

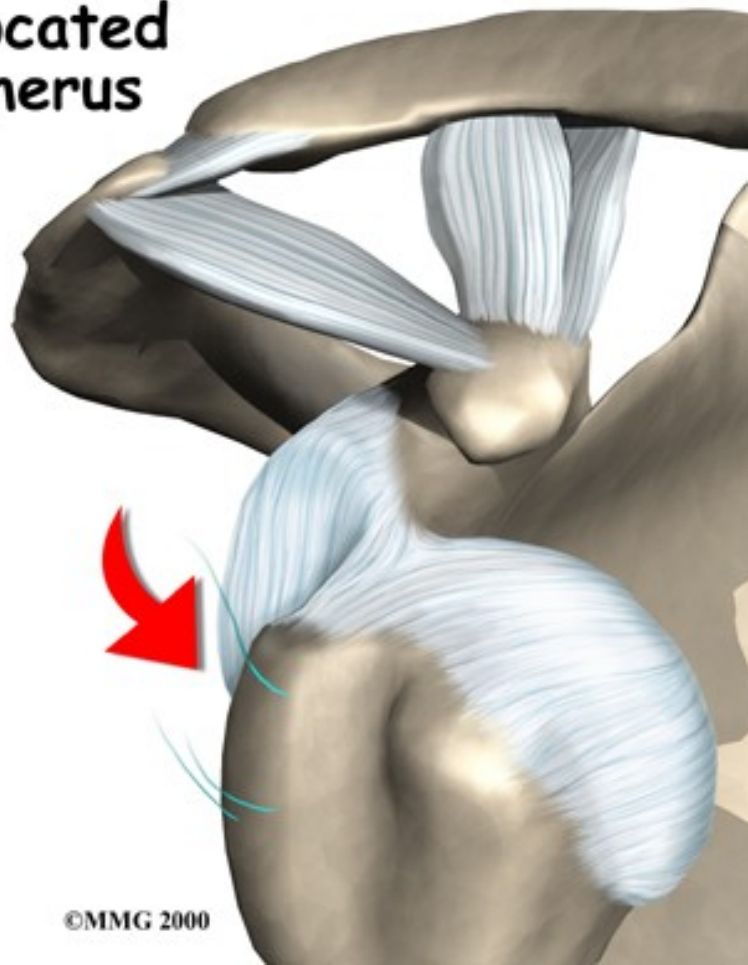


Léčba ruptury rotátorové manžety

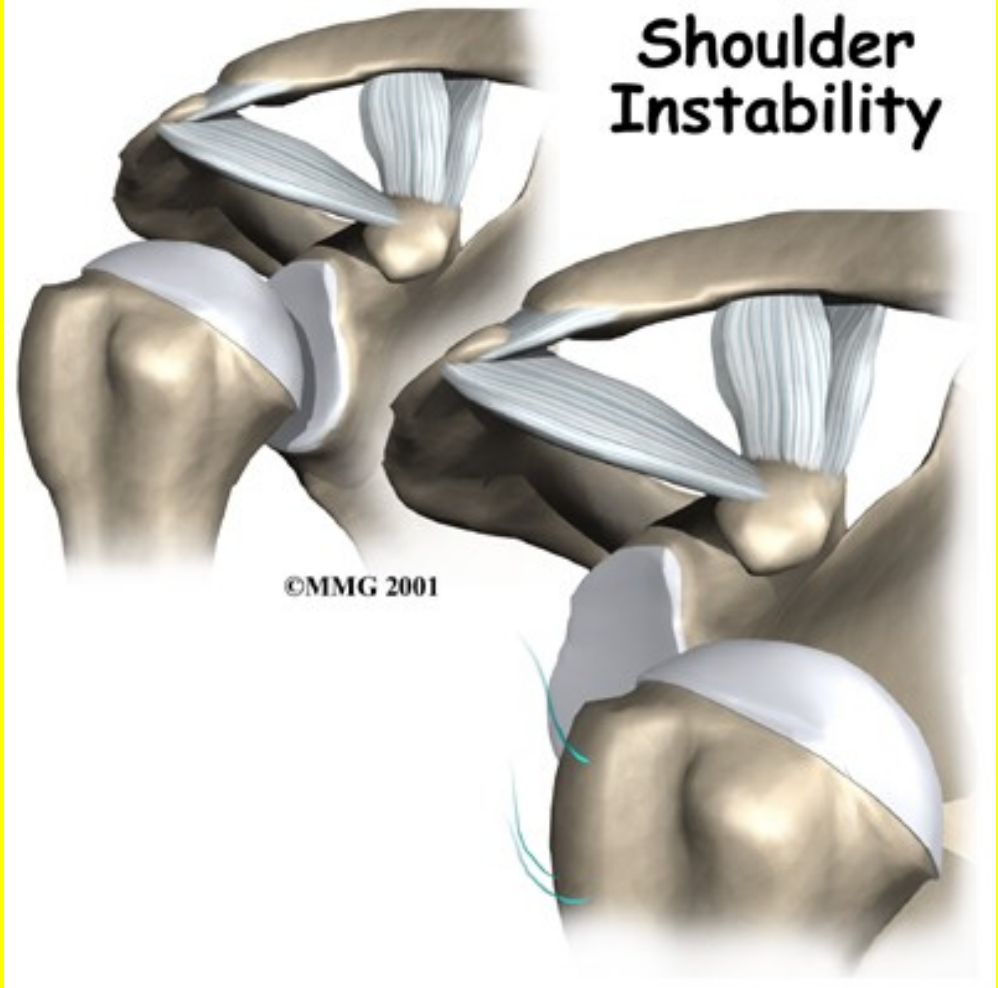


Luxace ramene

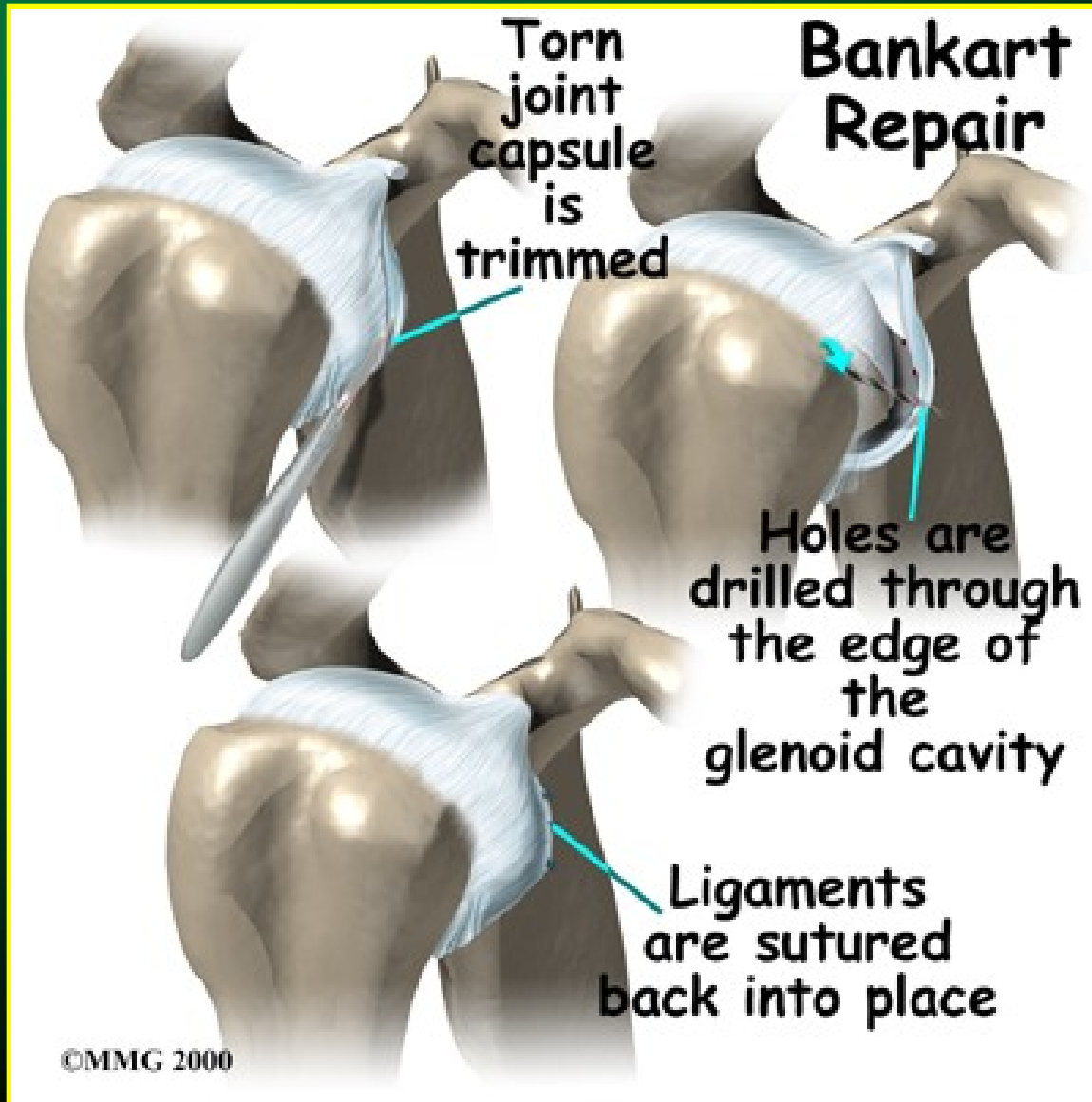
Dislocated
Humerus



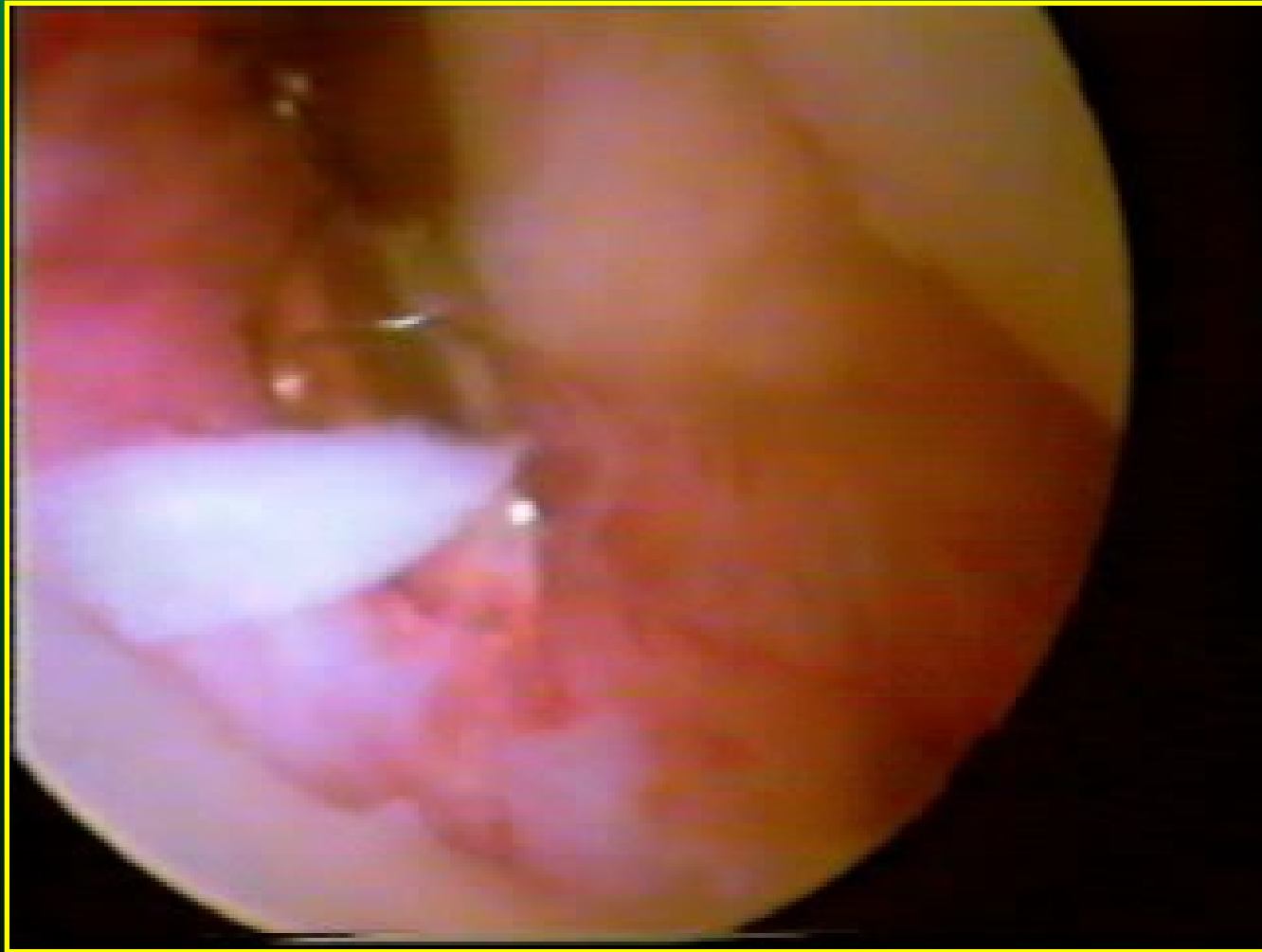
Shoulder
Instability



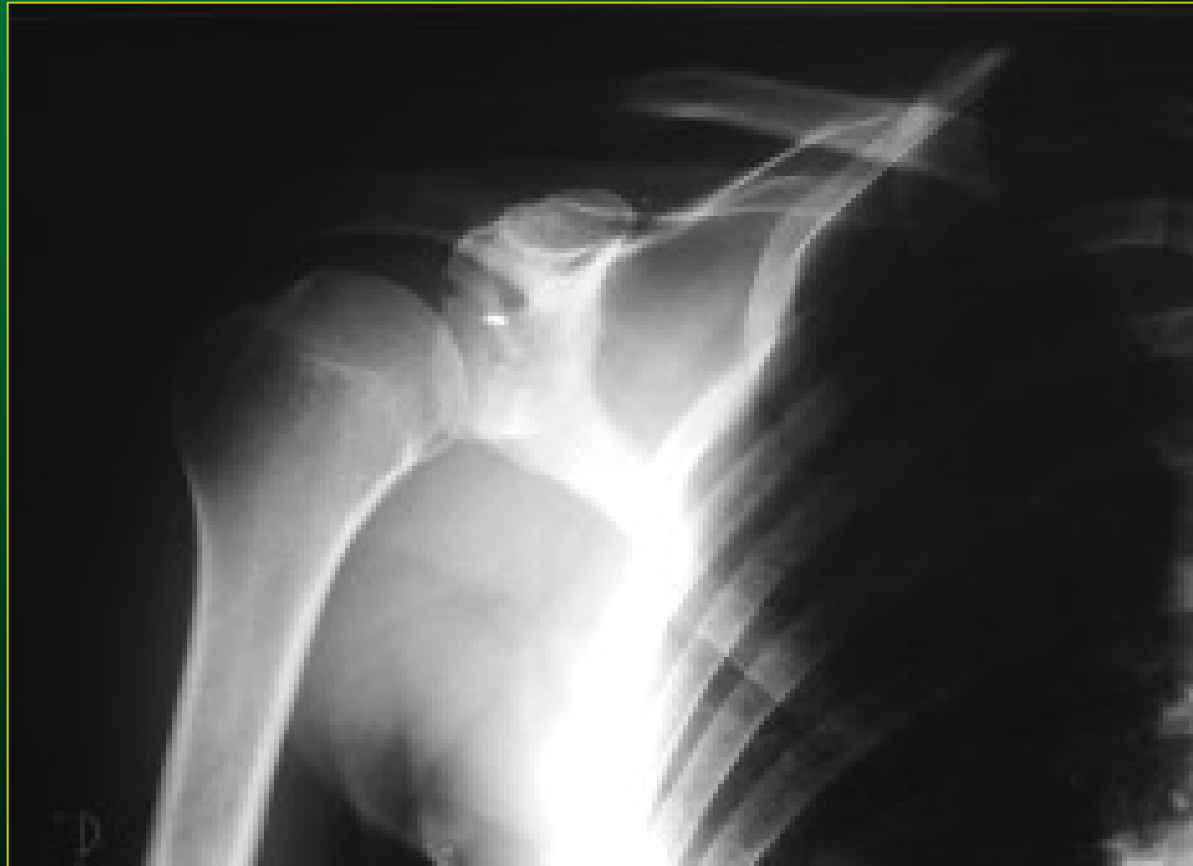Luxace ramene



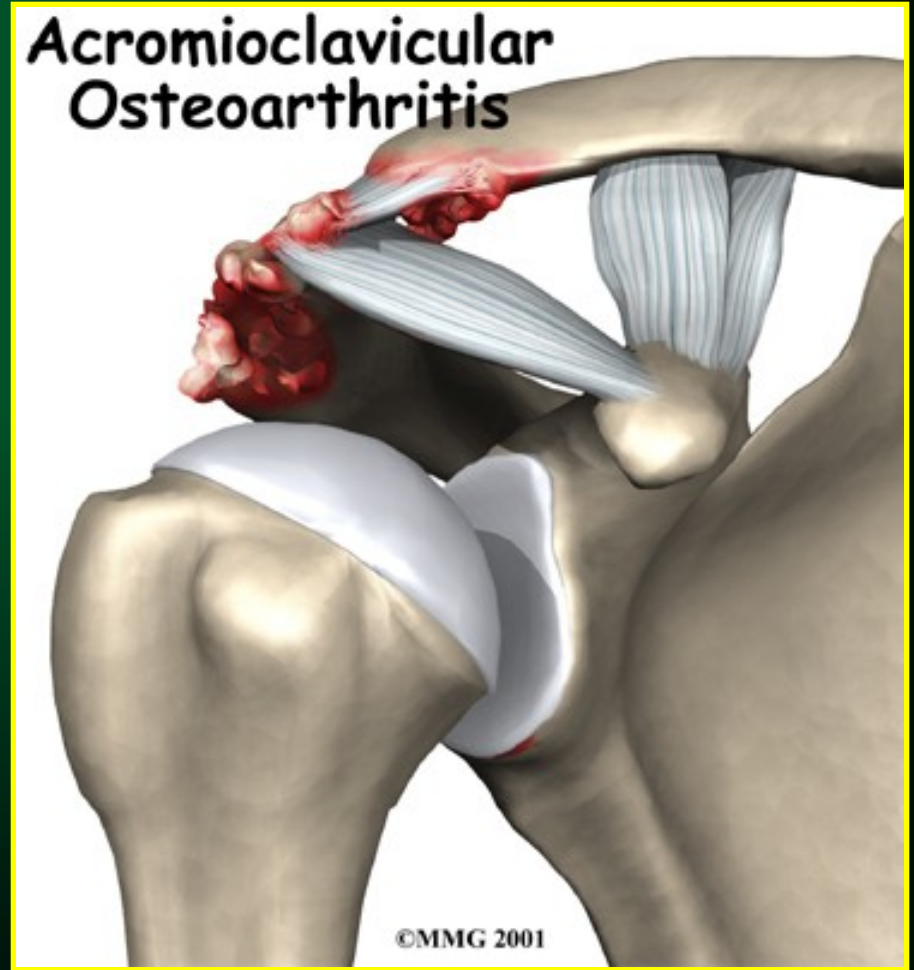
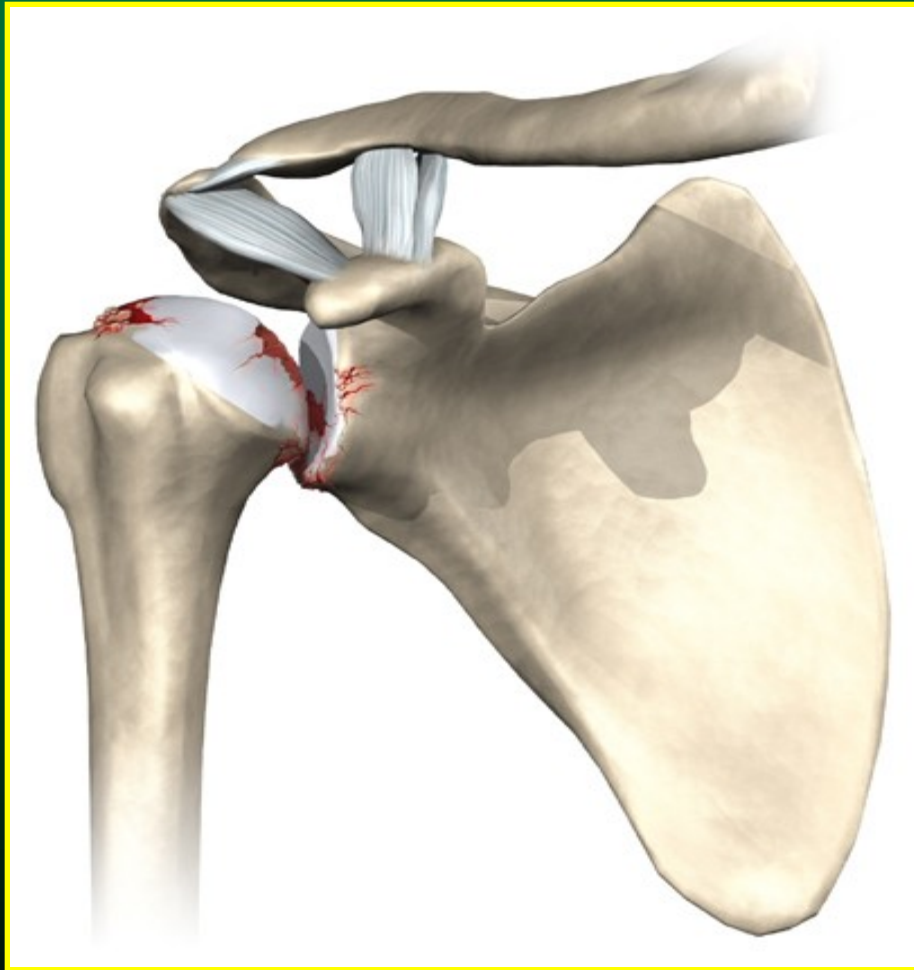
Luxace ramene: artroskopická stabilizace dle Bankarta



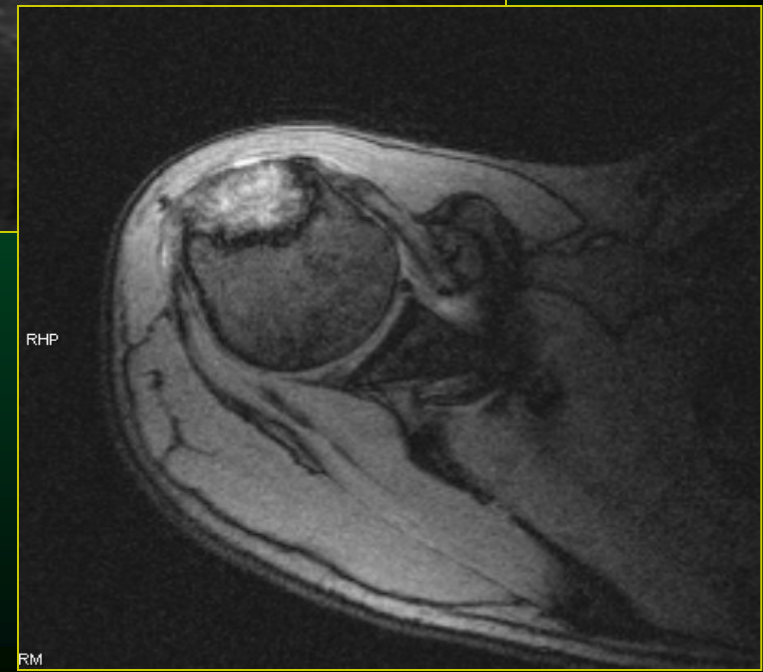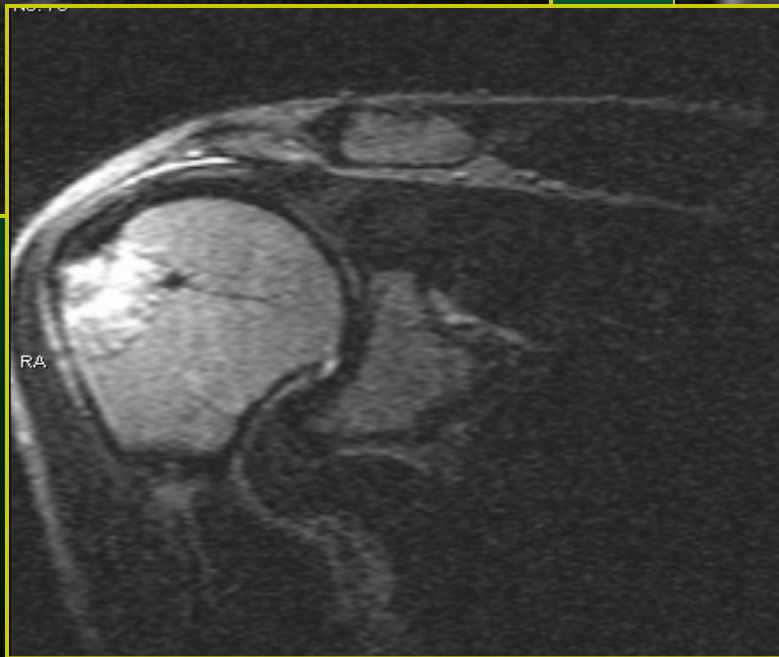
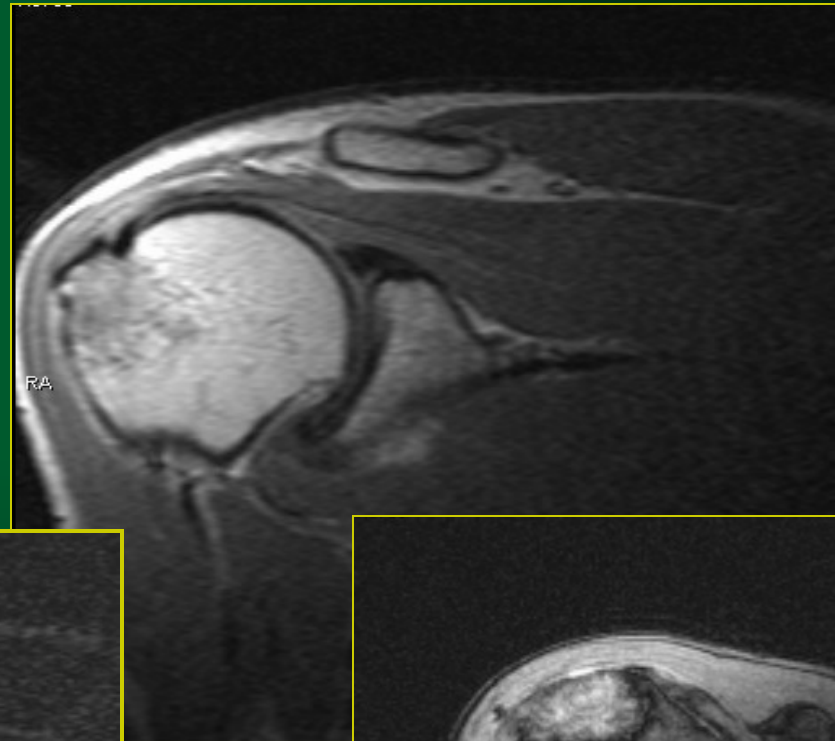
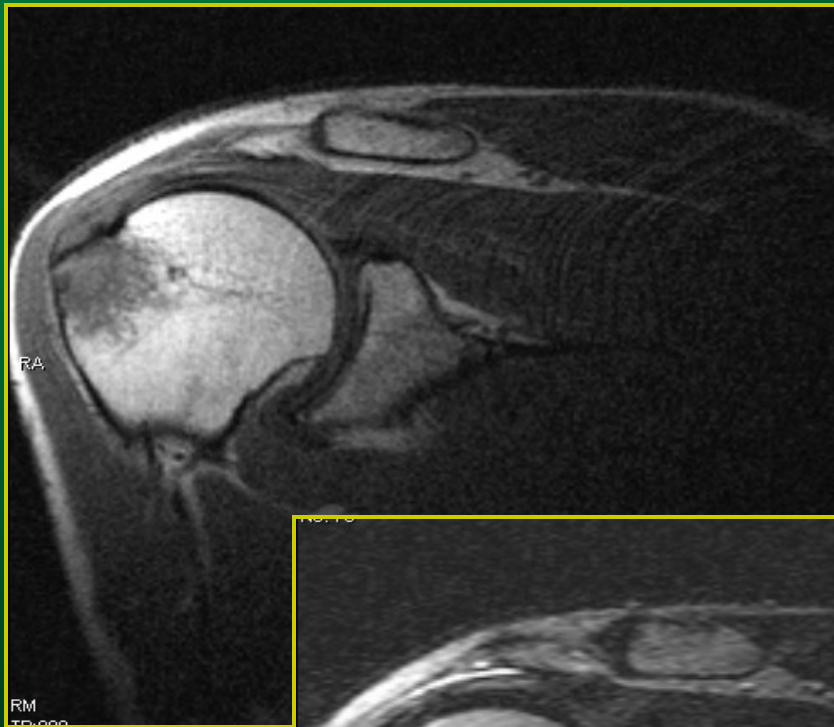
Pooperační změny



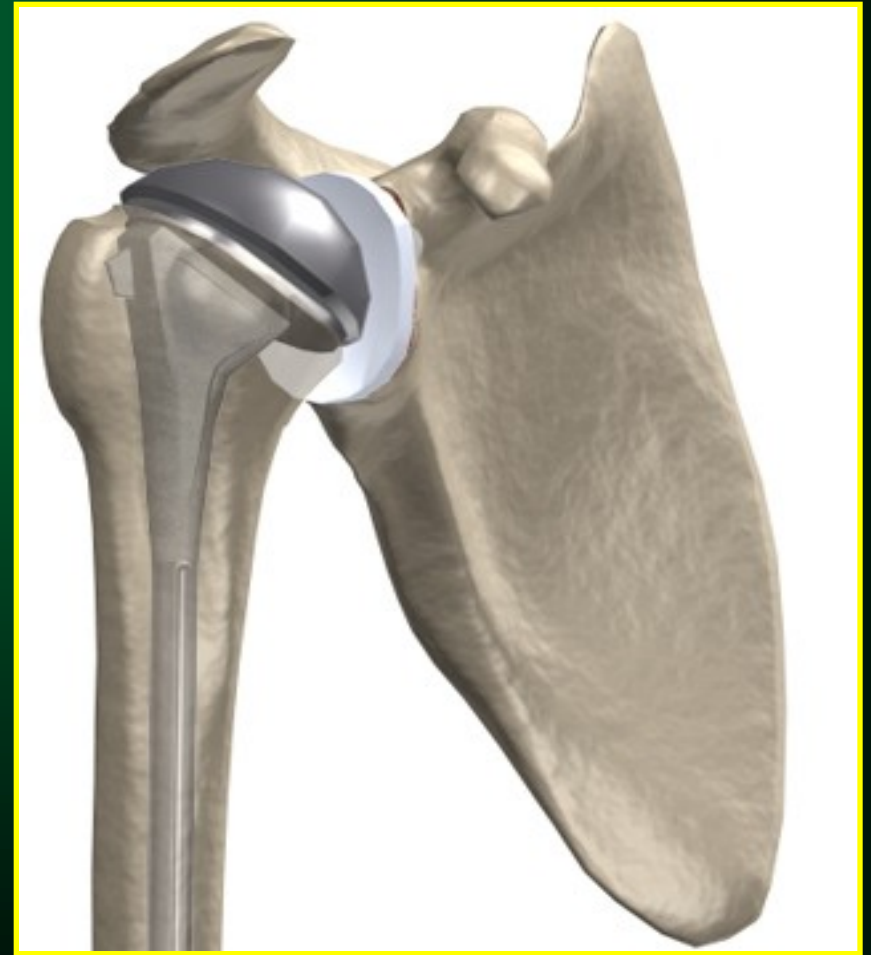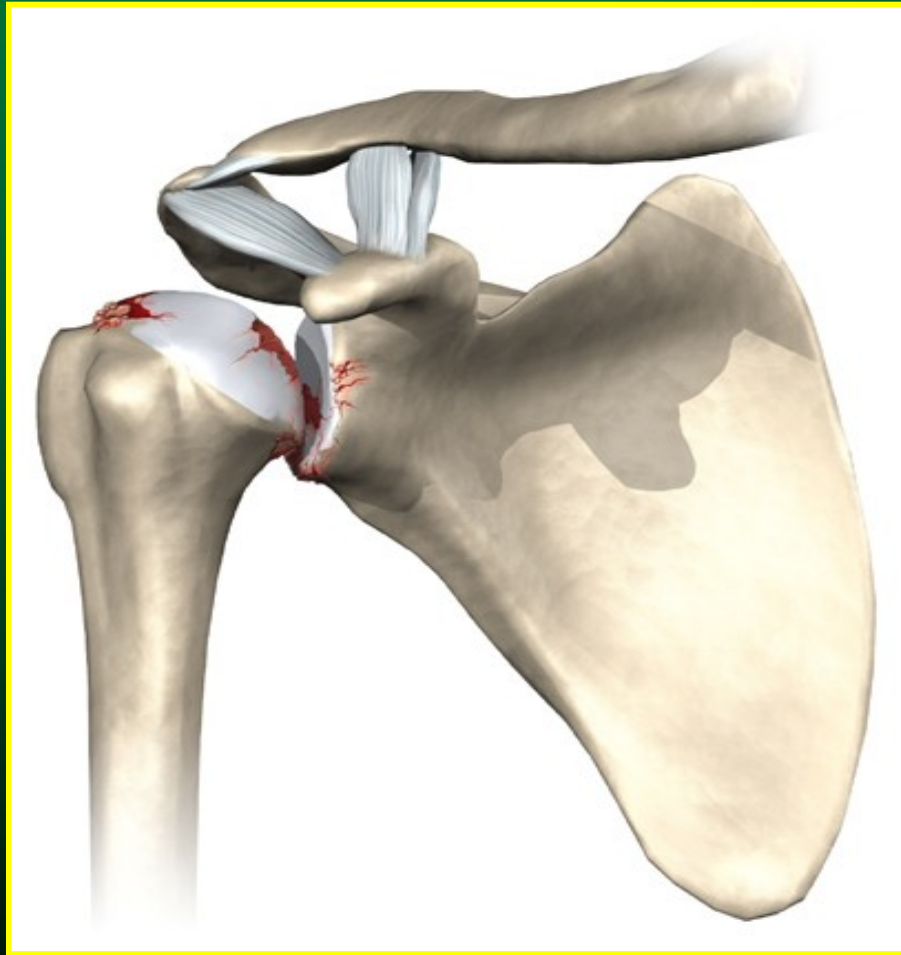
Omartróza



Aseptická nekróza

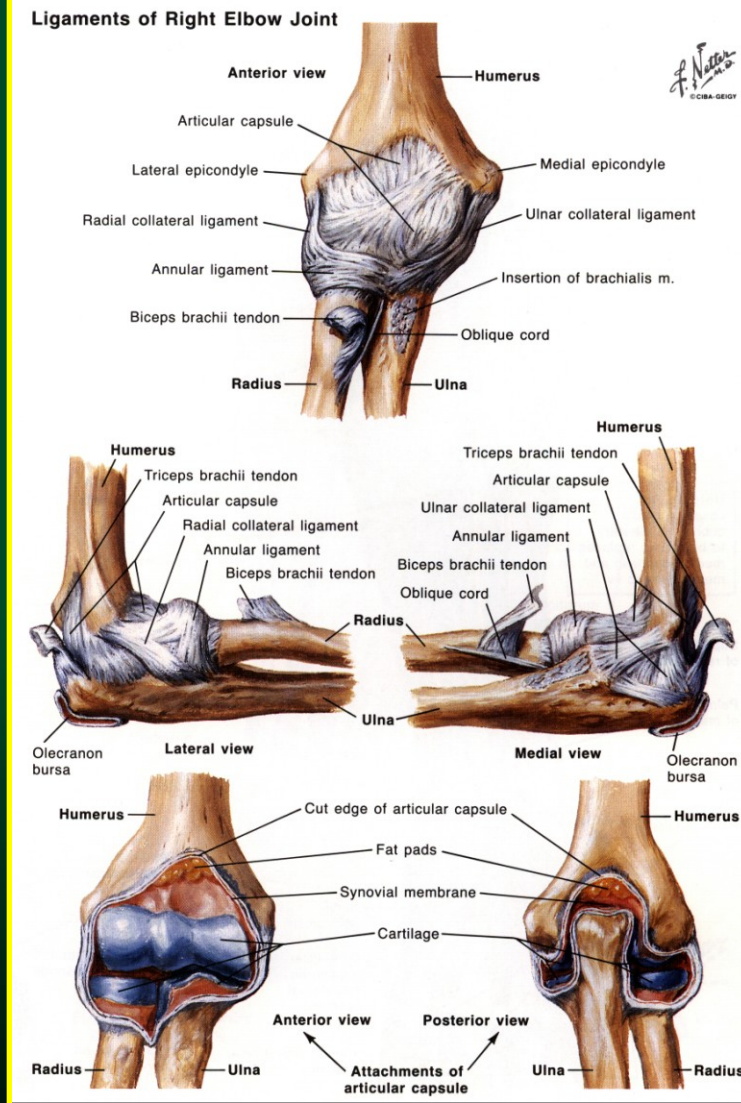
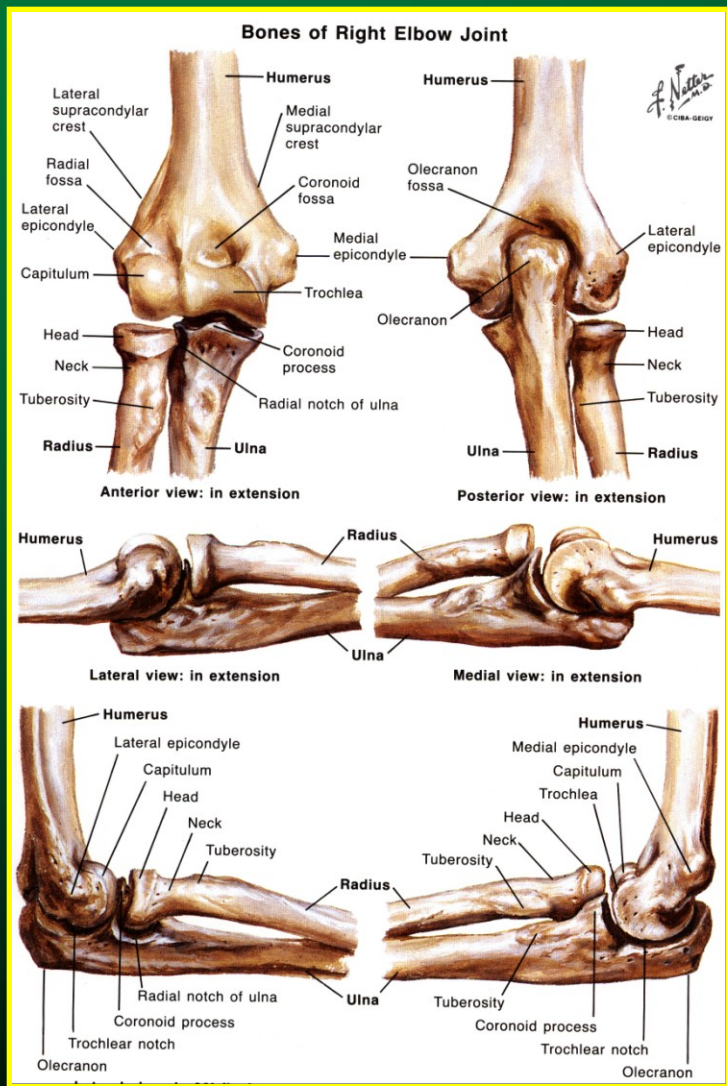


Omartróza



LOKET

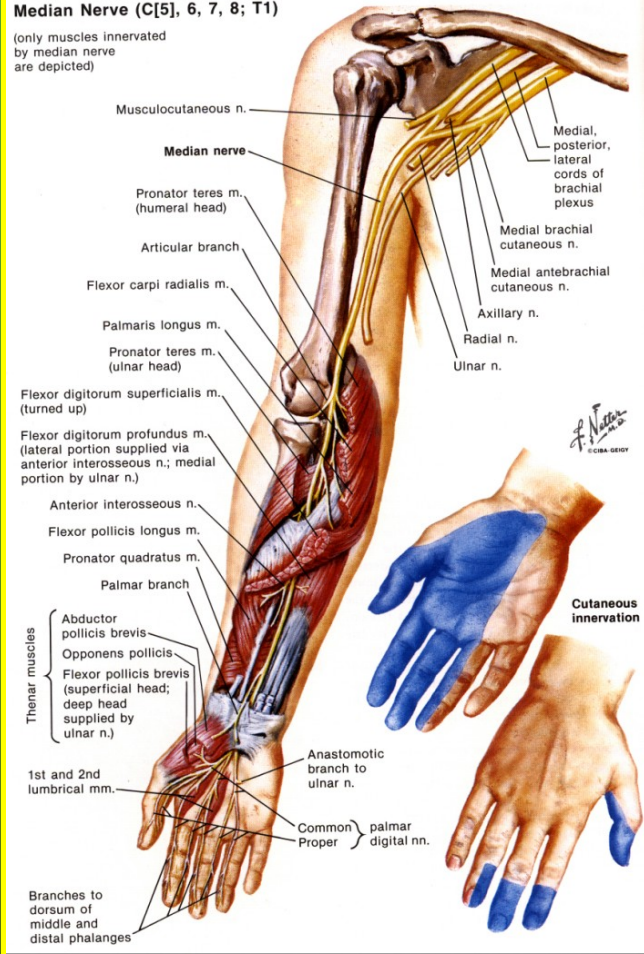
Anatomie lokte



Anatomie lokte

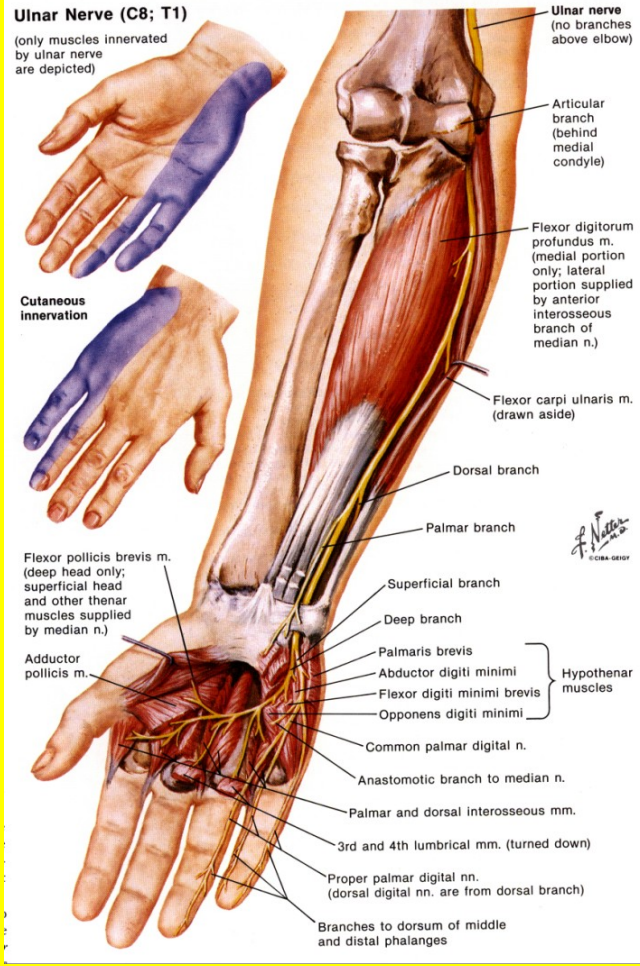
Median Nerve (C[5], 6, 7, 8; T1)

(only muscles innervated by median nerve are depicted)

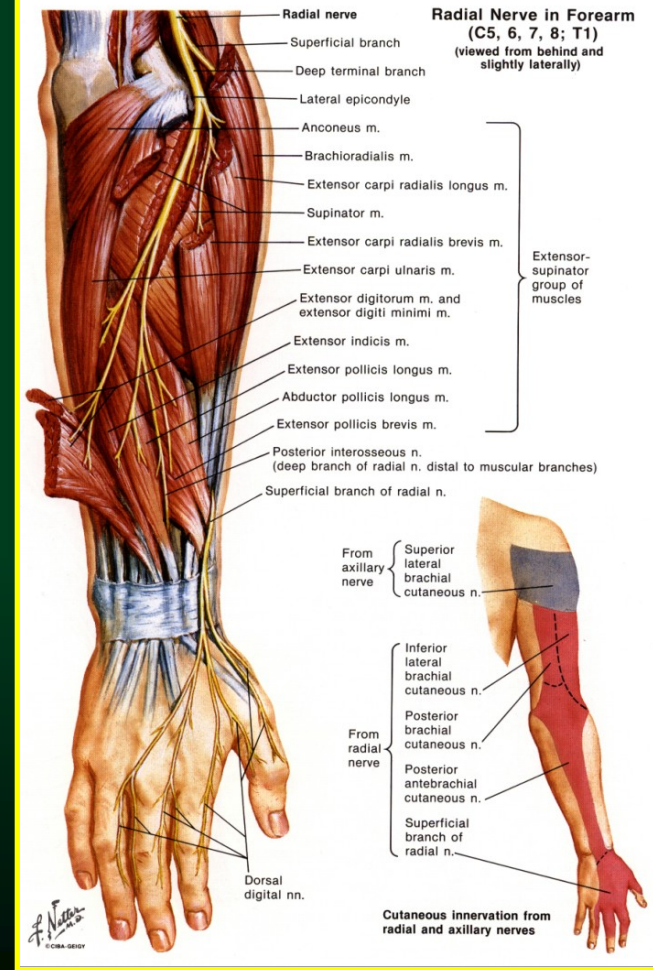


Ulnar Nerve (C8; T1)

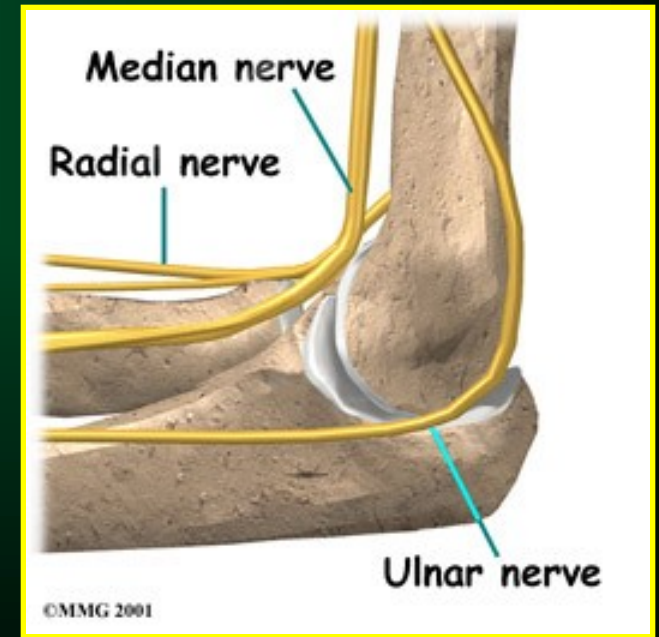
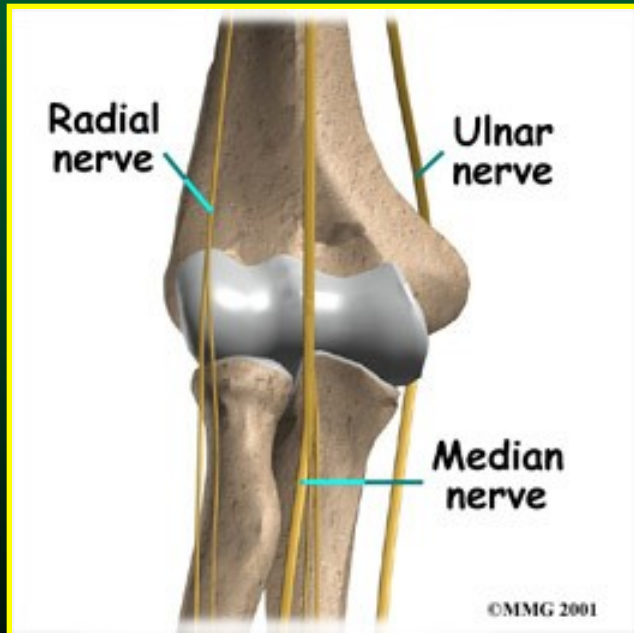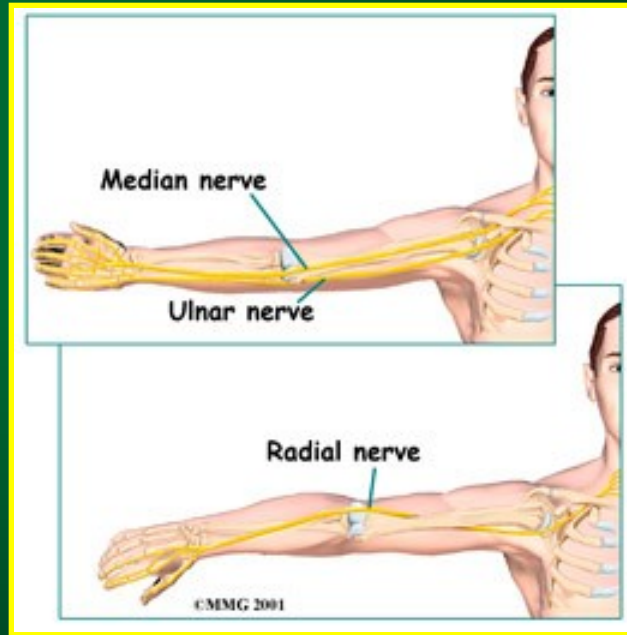
(only muscles innervated by ulnar nerve are depicted)



Radial Nerve in Forearm (C5, 6, 7, 8; T1) (viewed from behind and slightly laterally)



Anatomie lokte



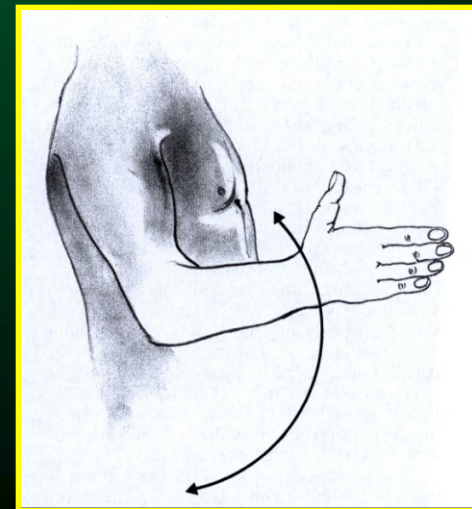
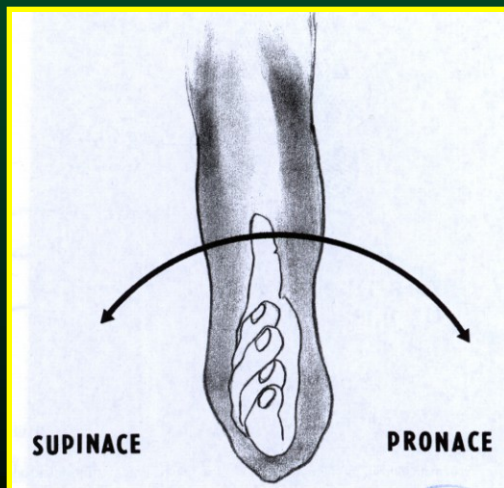
Pohyb v lokti = dvouosý pohyb

- pronace + supinace

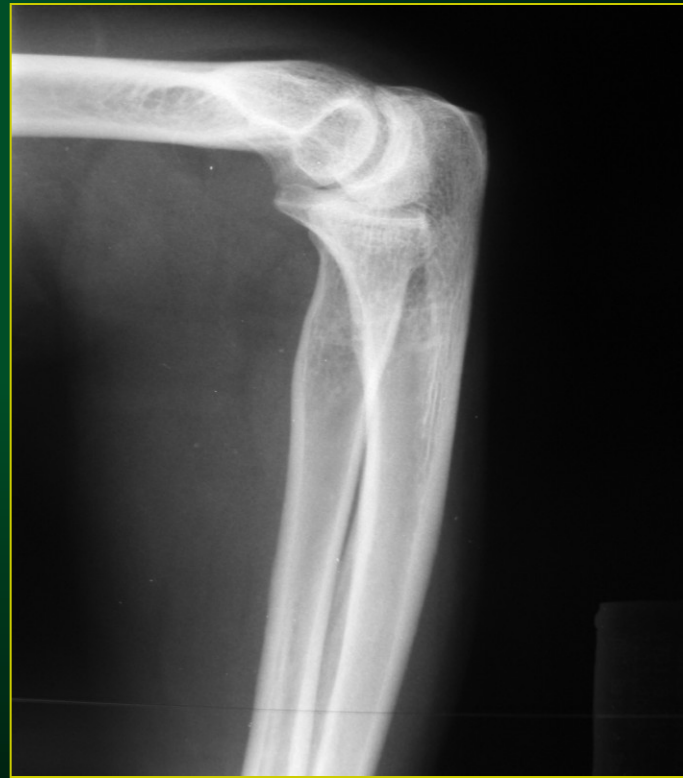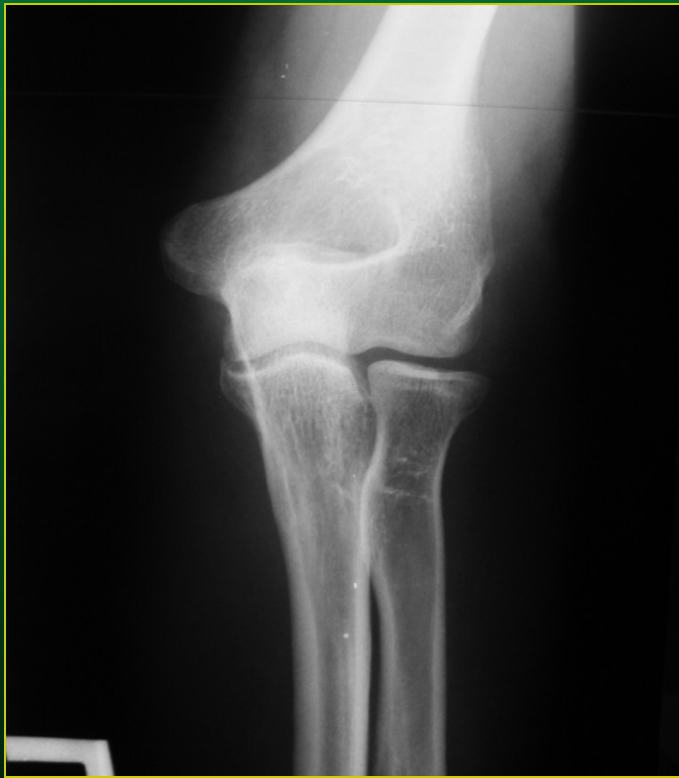radiohumerální + prox. radioulnární skloubení

- flexe + extenze

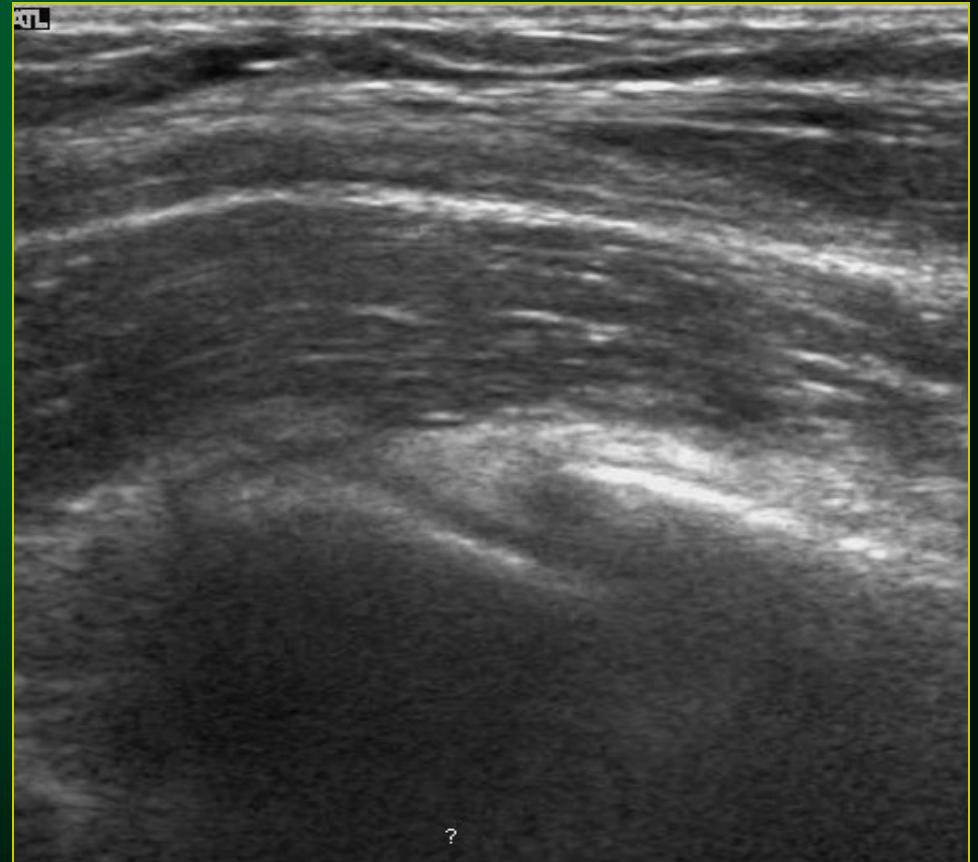
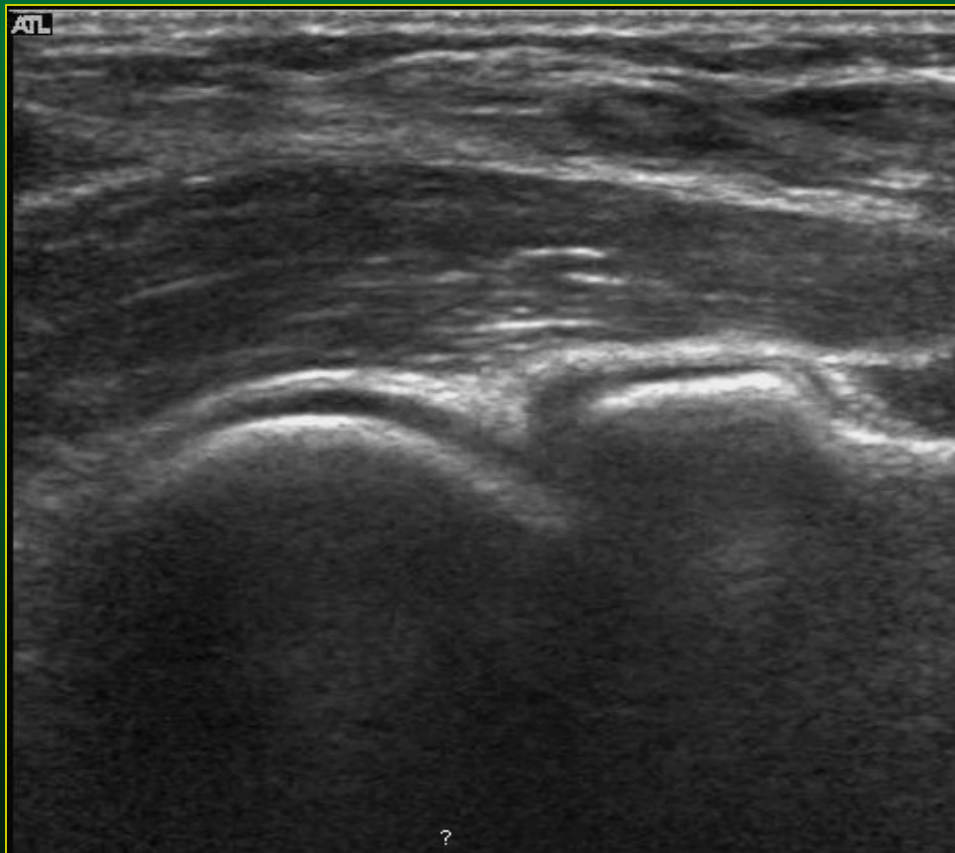
ulnohumerální skloubení



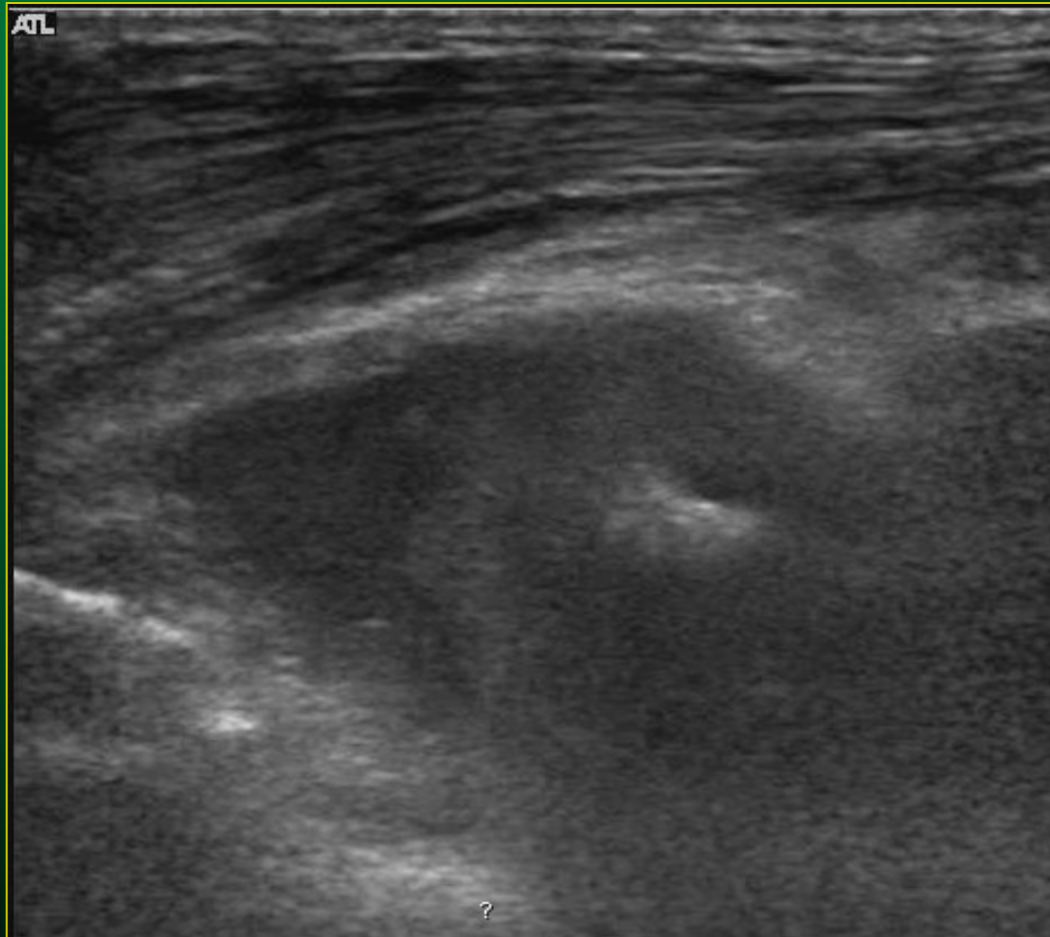
RTG snímky loketního kloubu



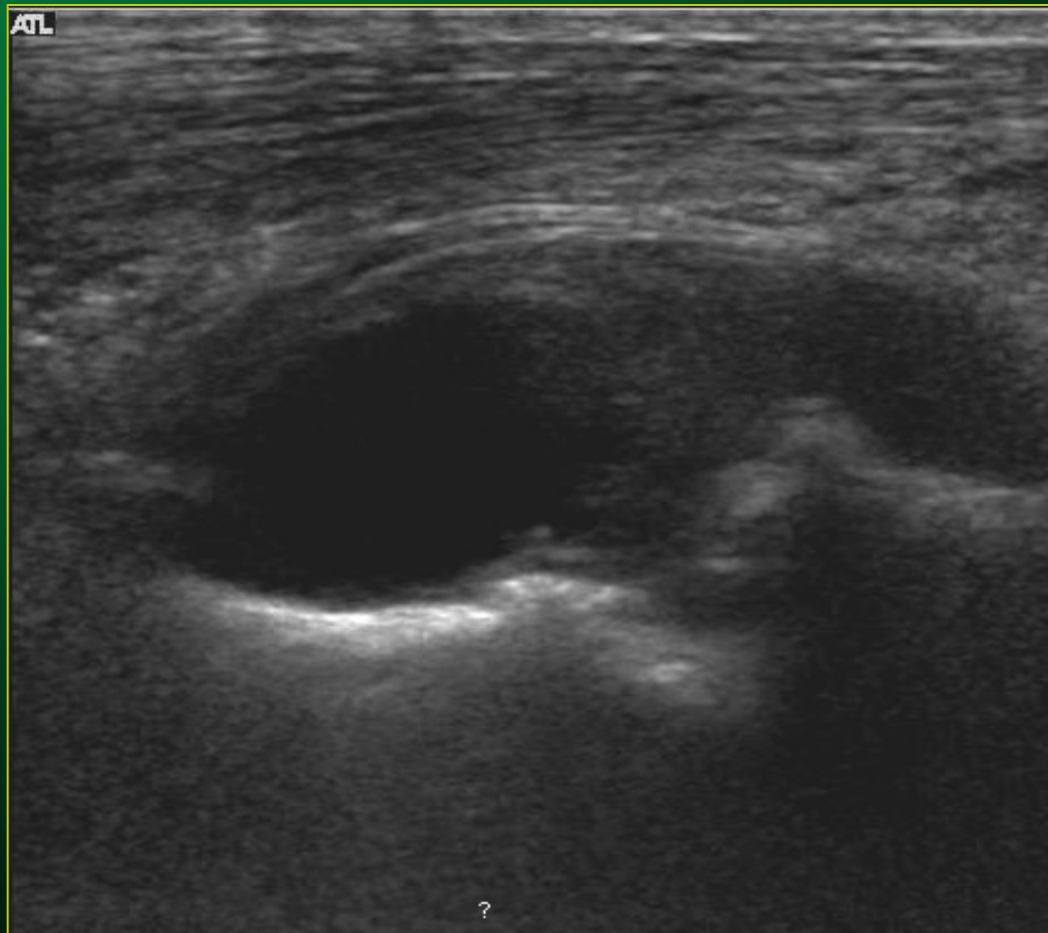
Loket – normální UZ obraz



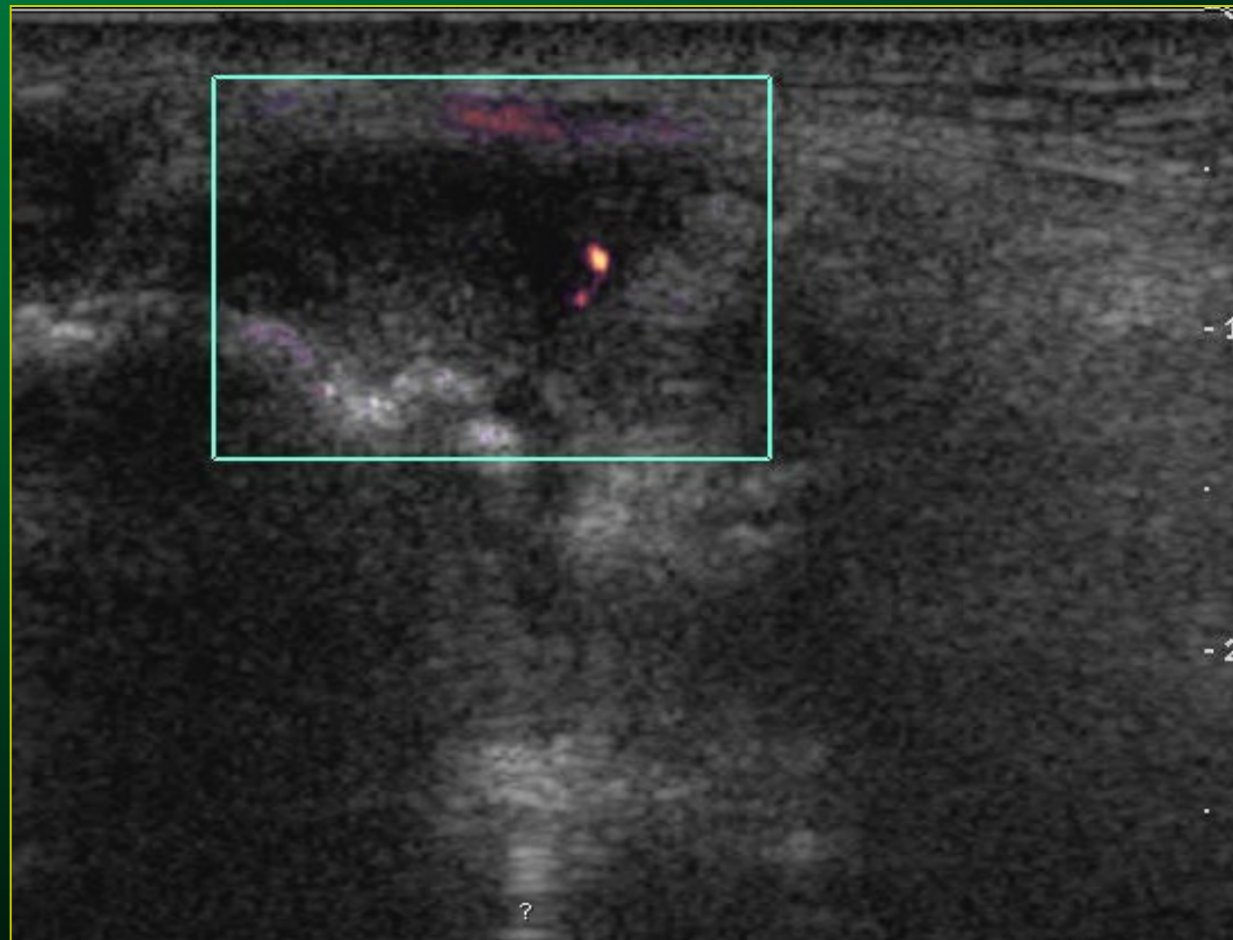
Loket -výpotek při zánětlivých změnách



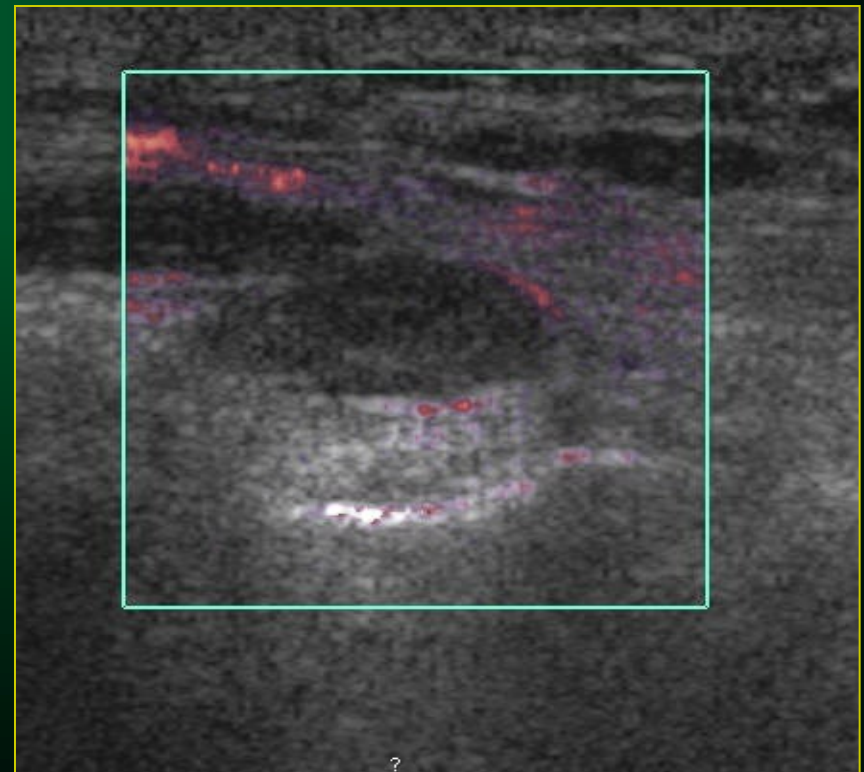
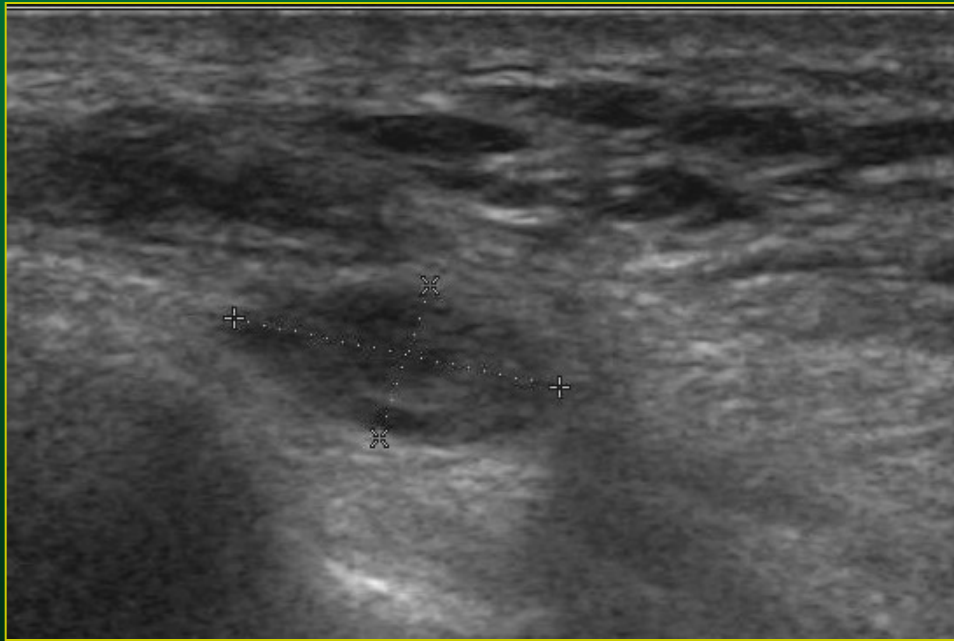Loket – výpotek, přihrocení kl.ploch



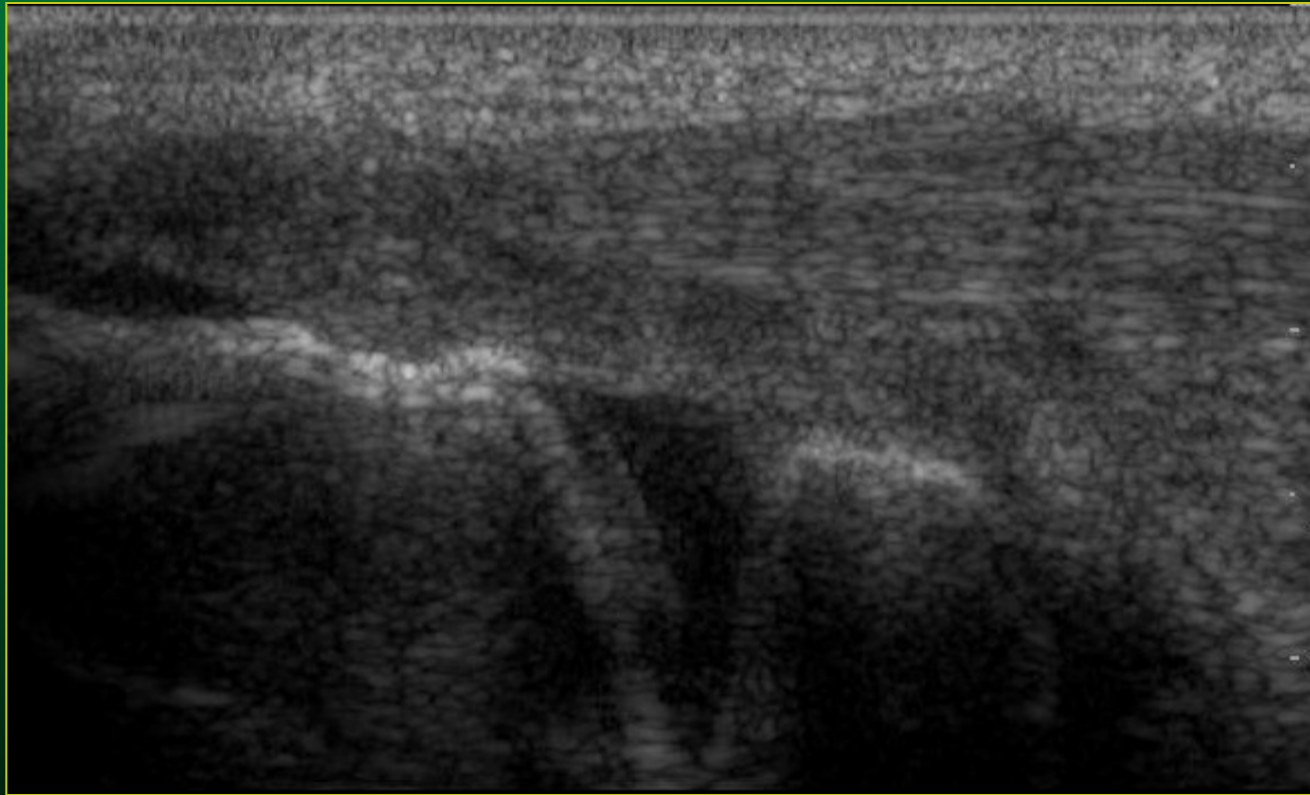
Loket – zánětlivé změny



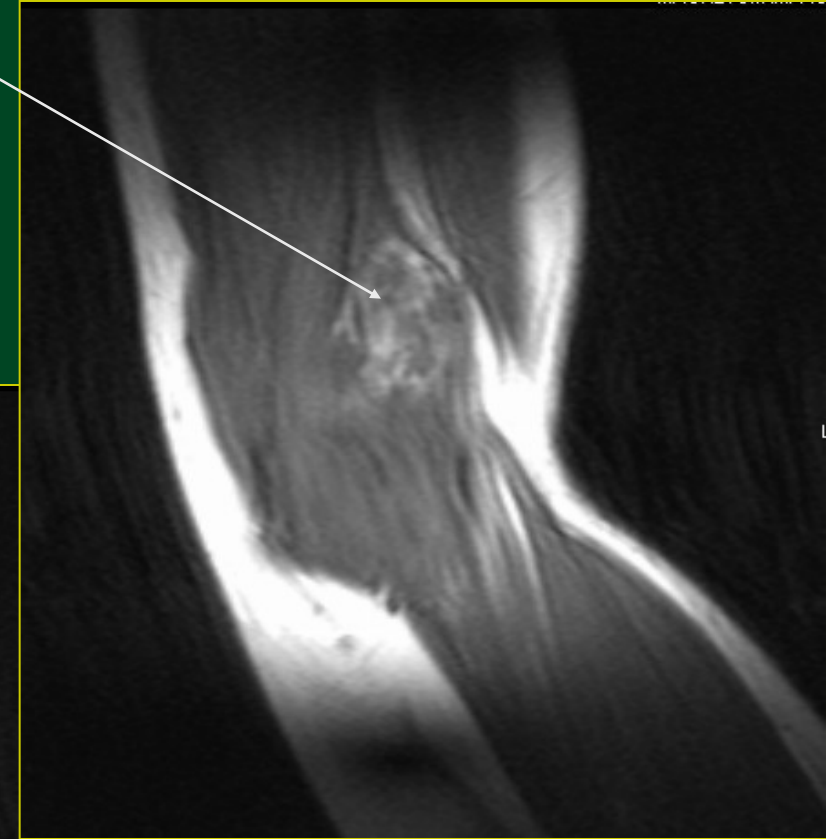
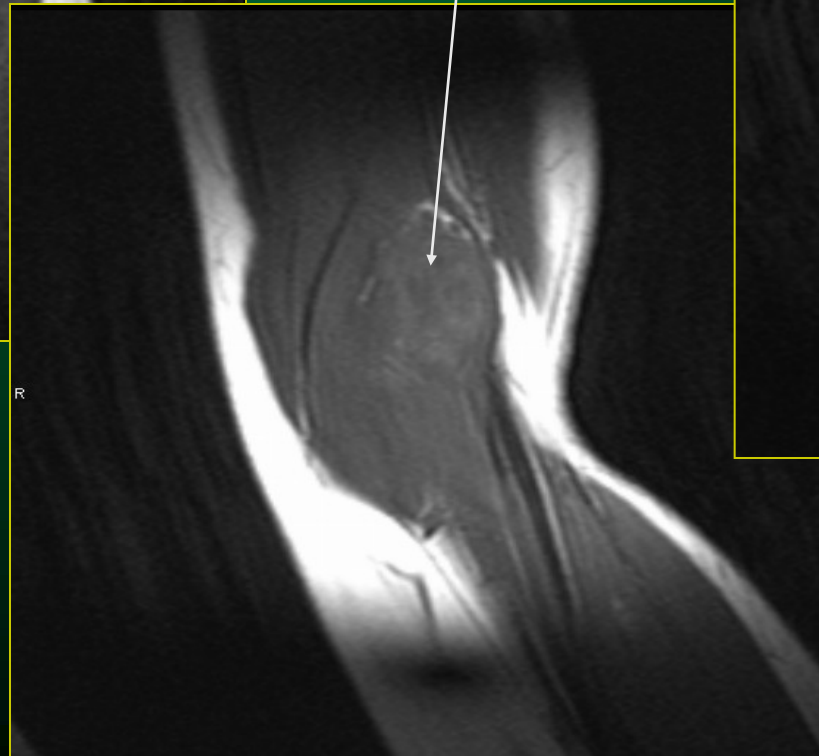
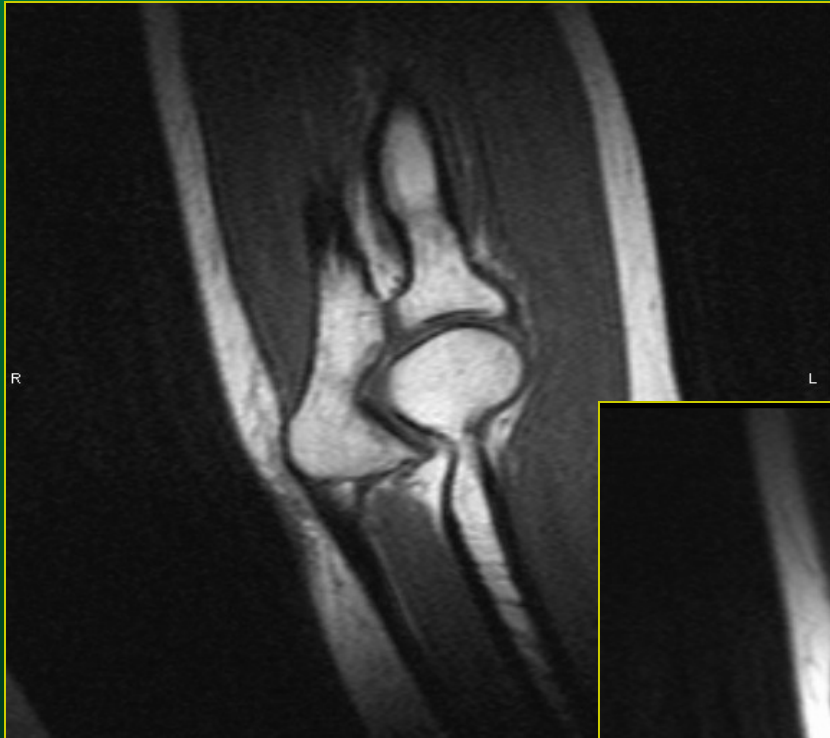Neurofibrom n.ulnaris



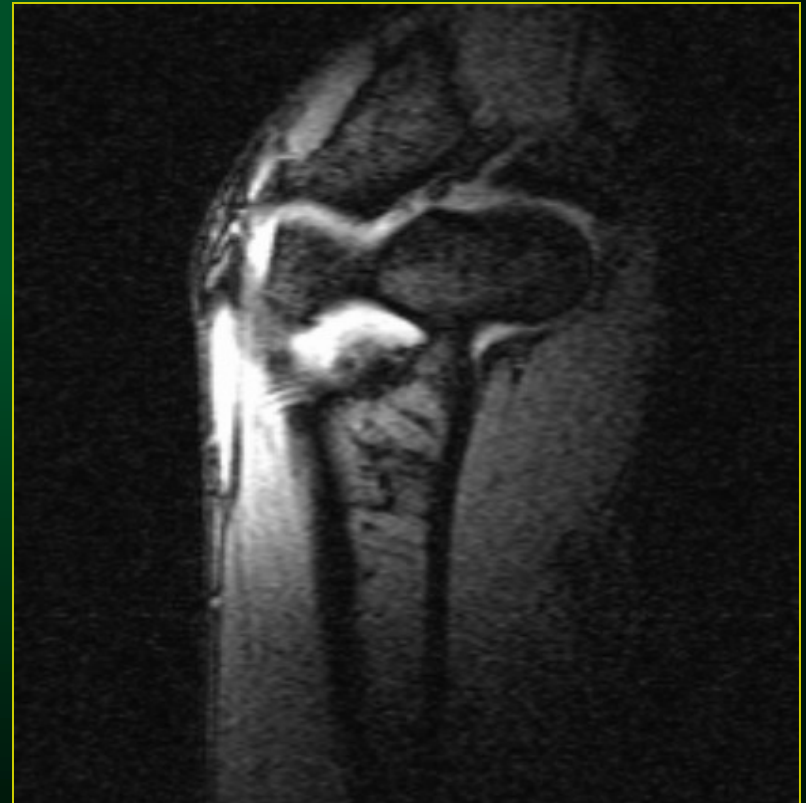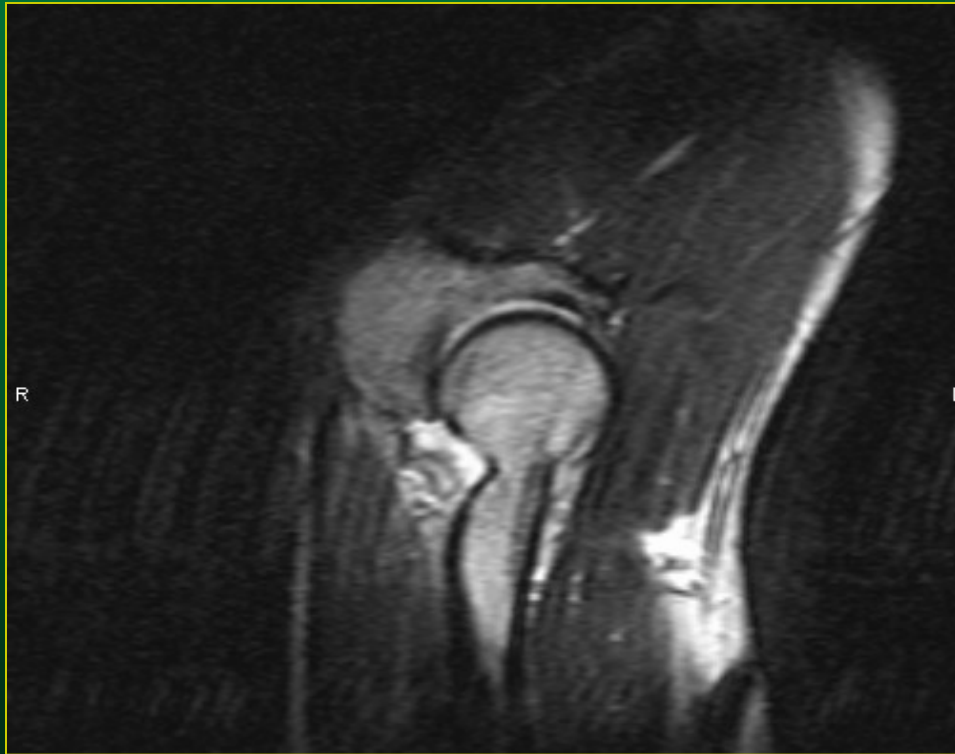
Loket - výpotek



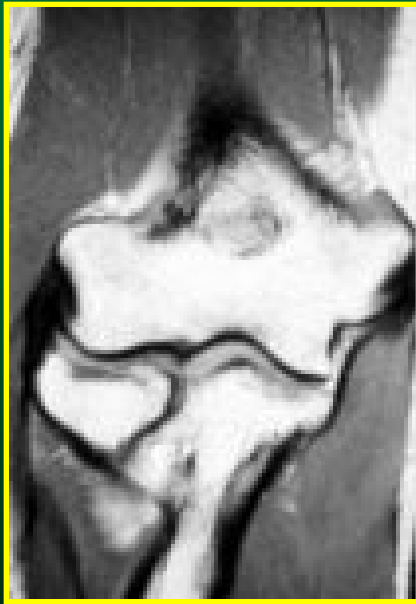Loket – hemangiom MR obraz



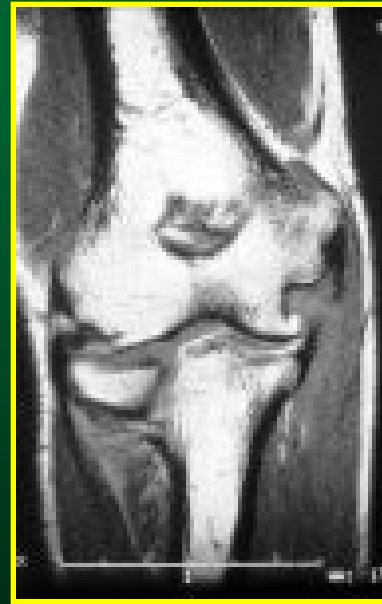Loket – výpotek MR obraz



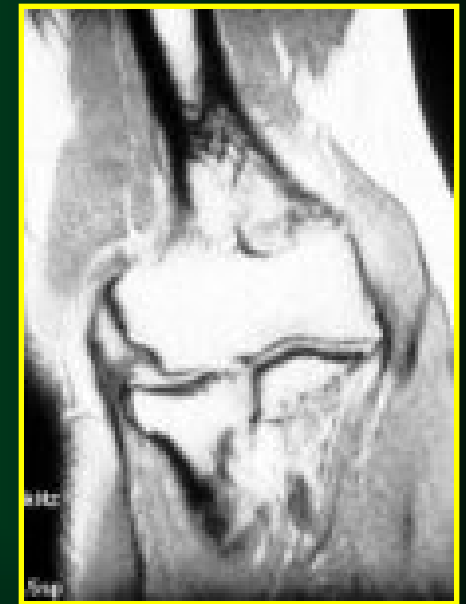Vyšetření magnetickou rezonancí (MRI)



normální nález



odlomení
ulnárního
epikondylu



radiální
epikondylitida

Stabilita lokte

- ◆ kongruence kloubních ploch
- ◆ statické stabilizátory (vazy)
- ◆ dynamické stabilizátory (svaly)

Nejčastější onemocnění lokte

- ◆ Vrozené vady
- ◆ Osové deformity
- ◆ Aseptické nekrózy
- ◆ Epikondylitidy - úponové potíže
- ◆ Úžinové syndromy
- ◆ Záněty
- ◆ Artróza

Vrozené vady lokte

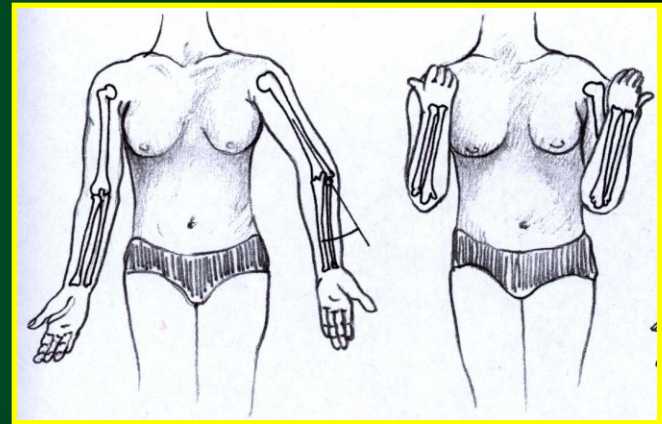
- ◆ Vrozená luxace (lokte, hlavičky radia)
- ◆ Vrozený zkrat
- ◆ Vrozený pakloub (radia, ulny)

Fyziologická valgozita:
u mužů do 10°
u žen do 20°

Osové deformity lokte

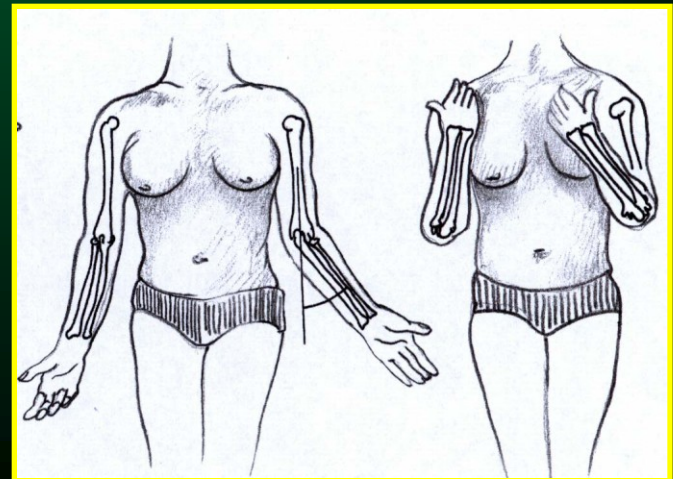
◆ Cubitus varus

- po suprakondylických zlomeninách u dětí
- funkčně závažné při více jak 15°



◆ Cubitus valgus

- po zlomeninách s luxací
- riziko pozdní parézy n.ulnaris

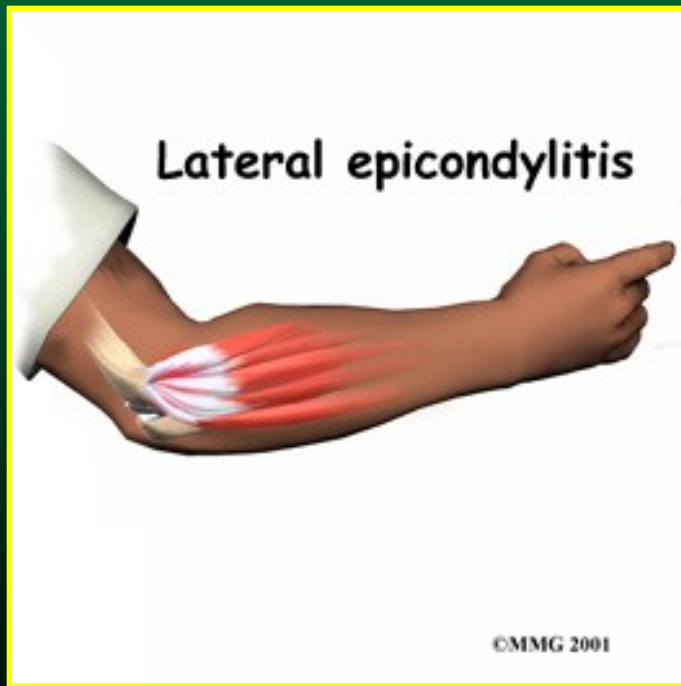


Aseptické nekrózy lokte

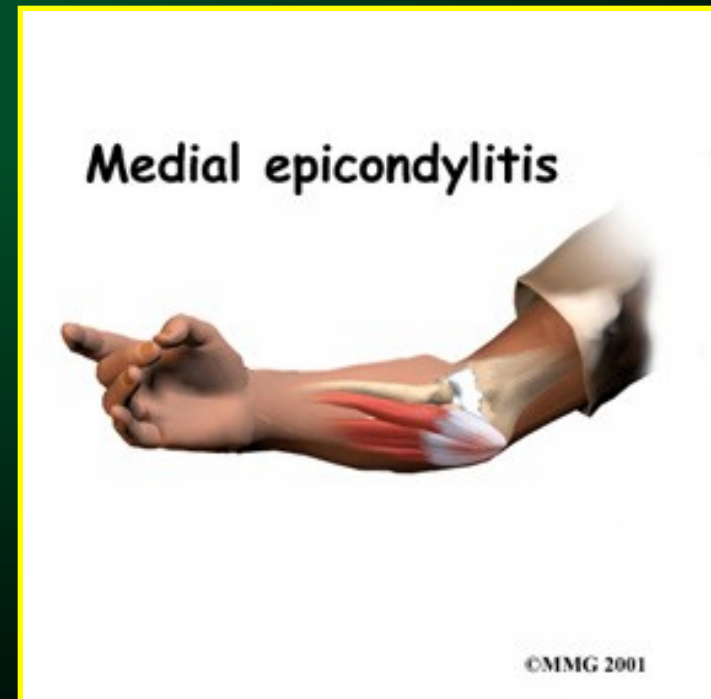
- ◆ Hlavičky humeru - m.Panner (vrhačský loket)
- ◆ Trochley humeru - m.Hegemann I
- ◆ Hlavičky radia - m.Hegemann II

Entezopatie lokte

Radiální
tenisový loket



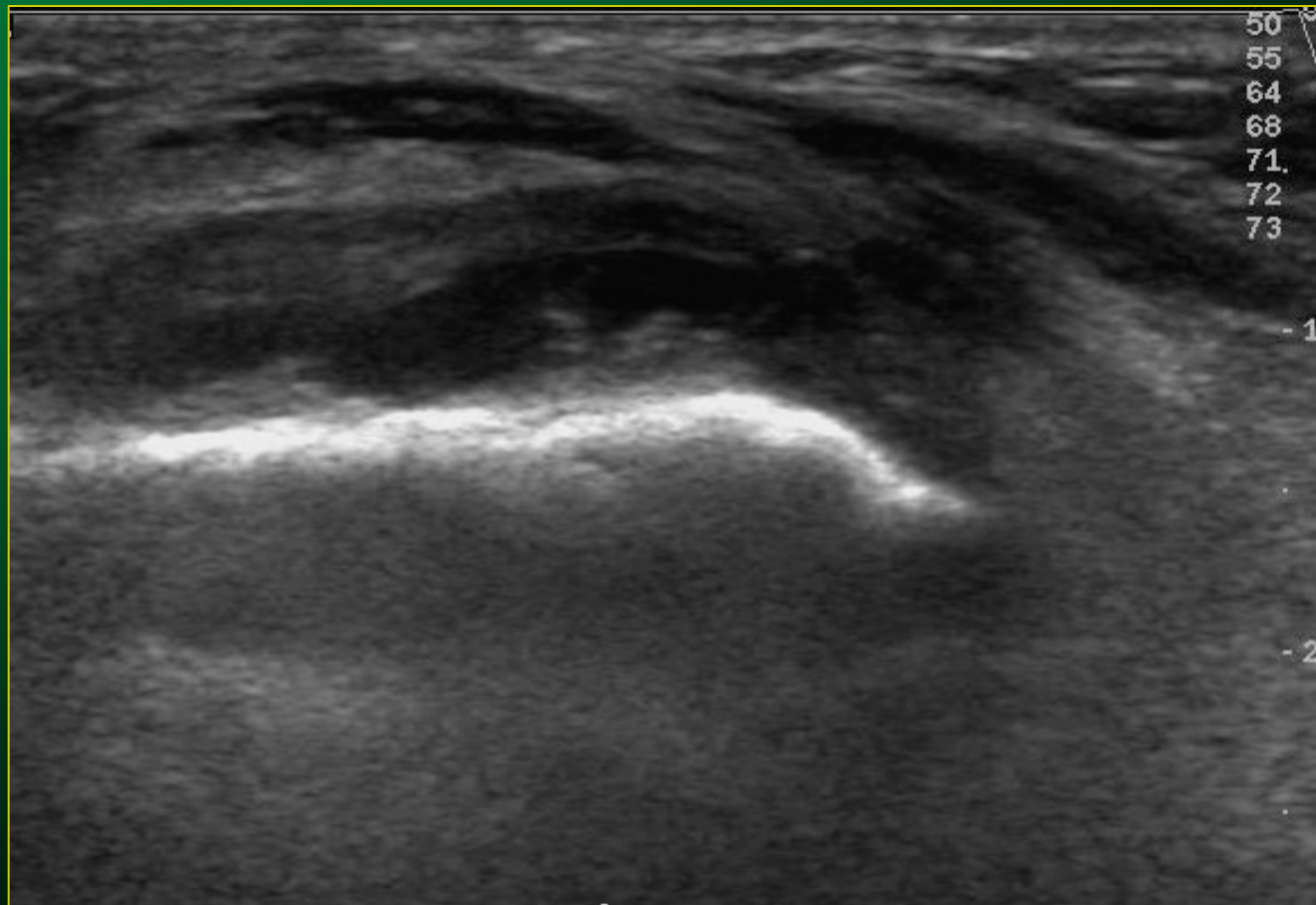
Ulnární
oštěpařský, golfový loket



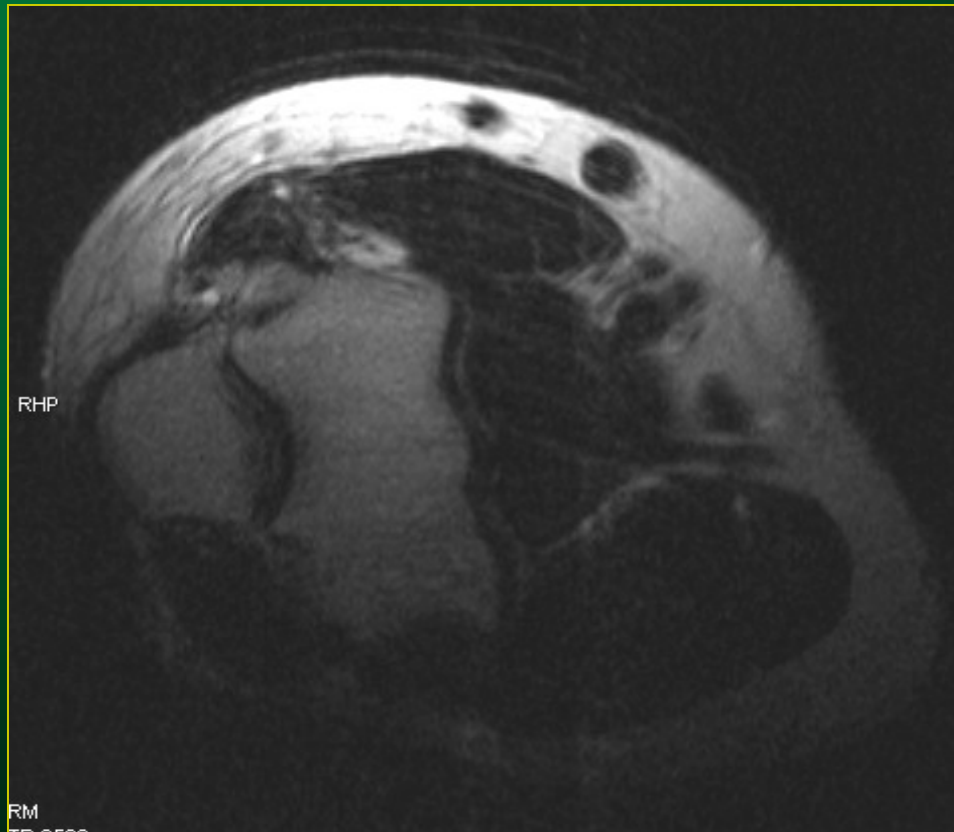
Epicondylitis RADIALIS humeri

- ◆ postižení EXTENZORŮ předloktí
- ◆ max.zatížení při: -PRONACI předloktí
 -EXTENZI zápěstí
- ◆ sport (tenis, házená, odbíjená,...)
- ◆ iradiace bolesti
 do dorza zápěstí

Loket – epikondylitis UZ obraz



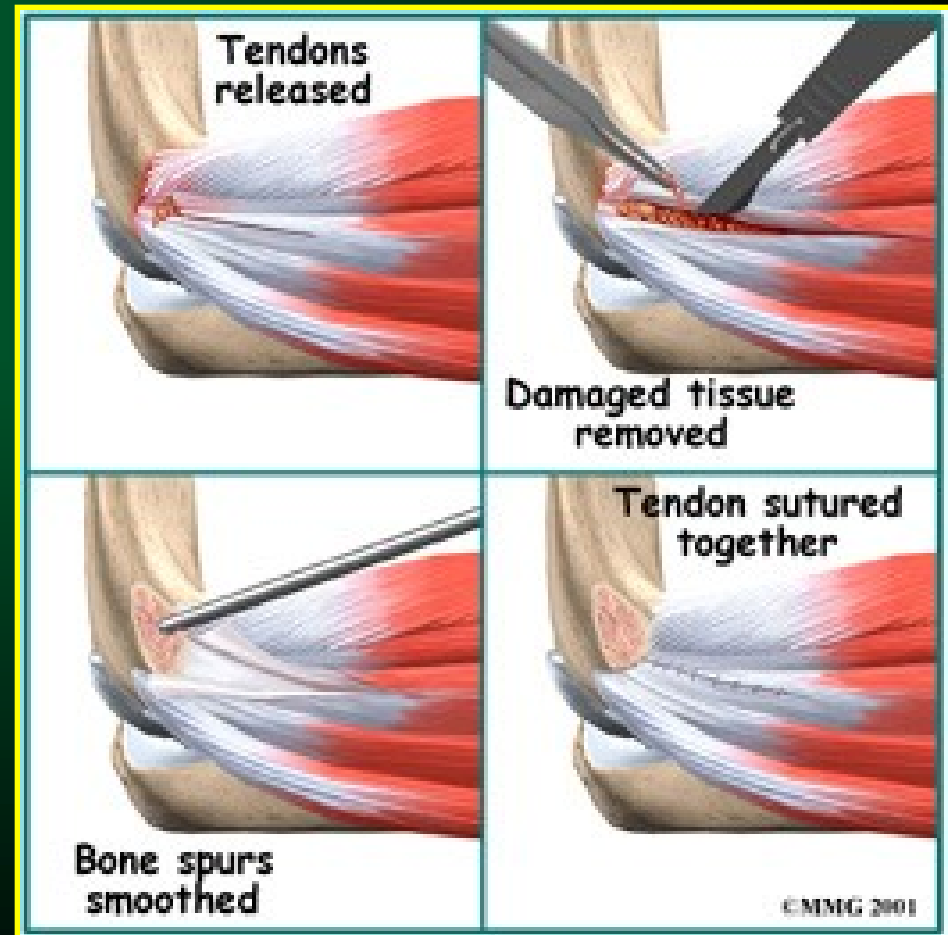
Epikondylitis MR obraz



Operační léčba radiální epikondylitidy

dle Boyd-McLeoda

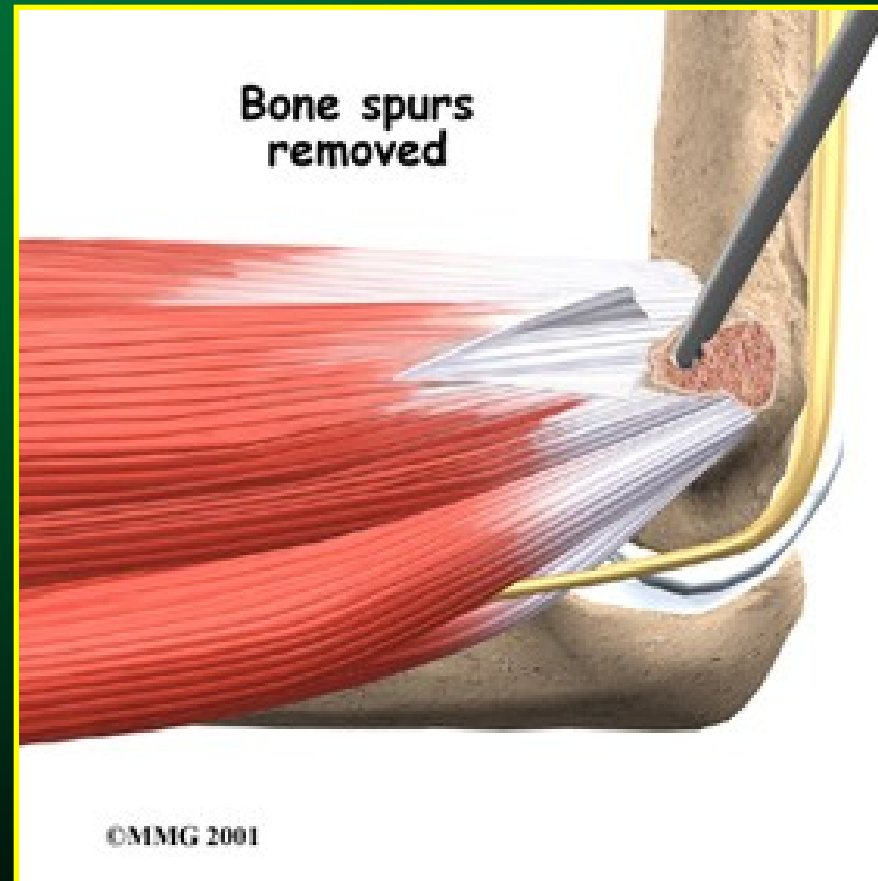
- denervace + revize RH kloubu
- distalizace úponu extenzorů



Epicondylitis ULNARIS humeri

- ◆ postižení FLEXORŮ předloktí
- ◆ max.zatížení při:
 - SUPINACI předloktí
 - FLEXI předloktí
- ◆ sport (oštěp,golf,odbižená,...)

Operační léčba ulnární epikondylitidy



Úžinové syndromy - kompresní neuropatie

- ◆ N.medianus - pronátorový syndrom
- ◆ N.ulnaris - syndrom kubitálního tunelu
- ◆ N.radialis - supinátorový syndrom

Úžinové syndromy

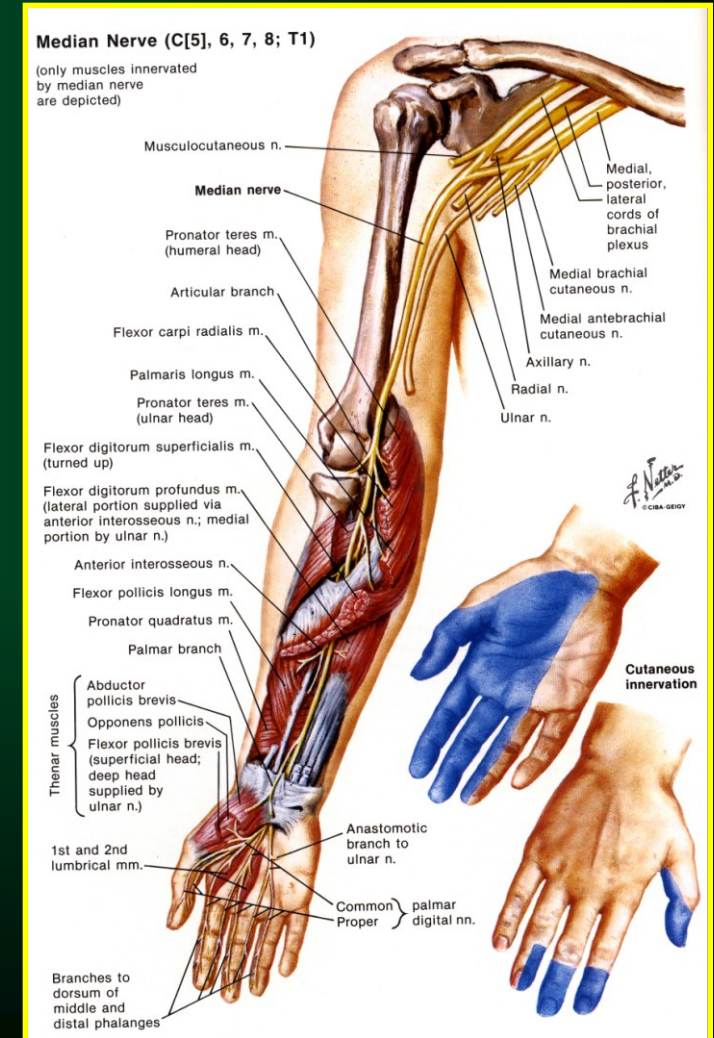
◆ N.MEDIANUS - pronátorový syndrom

◆ Komprese průchodem přes:

m.pronator teres
m.fle dig.superfic.

◆ Postižení:

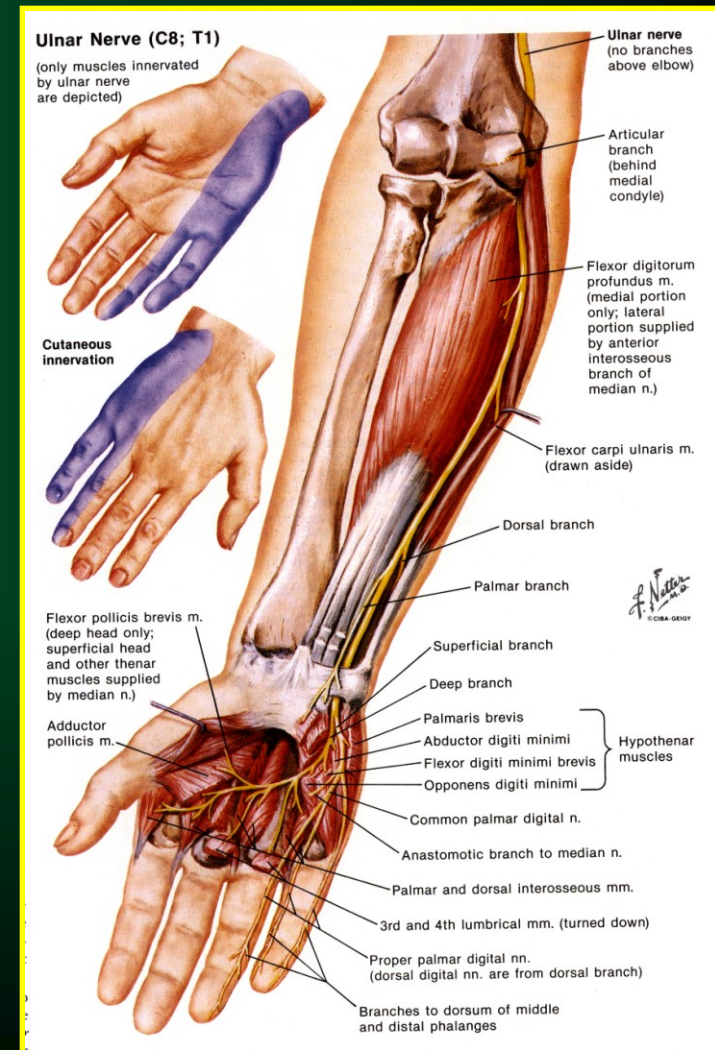
- oslabení úchopu palce (flexe)
- parestezie volární část předloktí
- paretsezie volární část I.-III.prstu



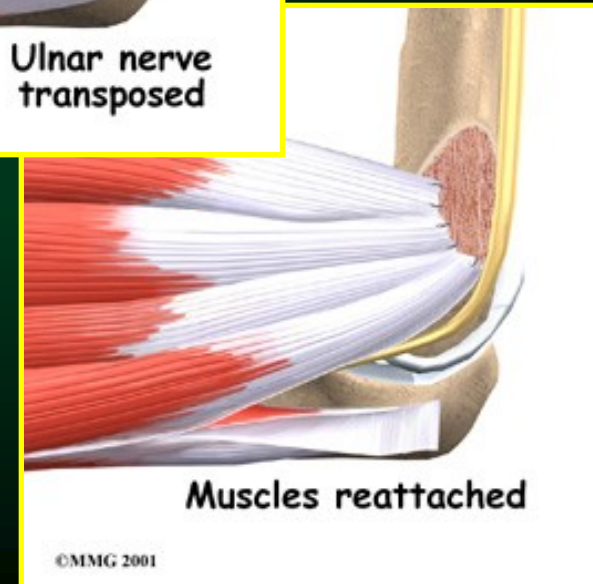
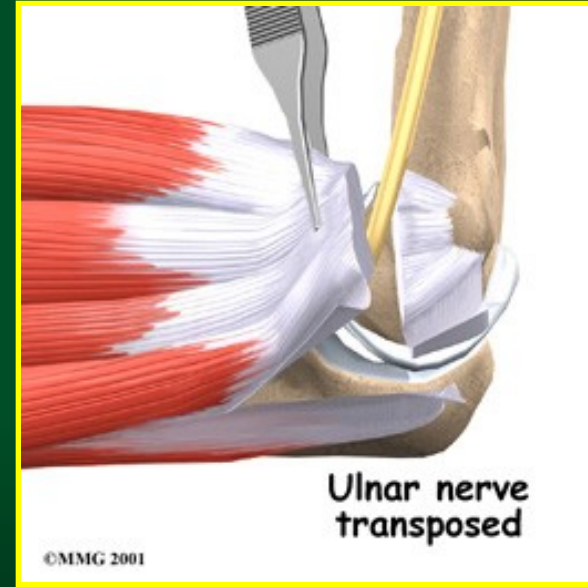
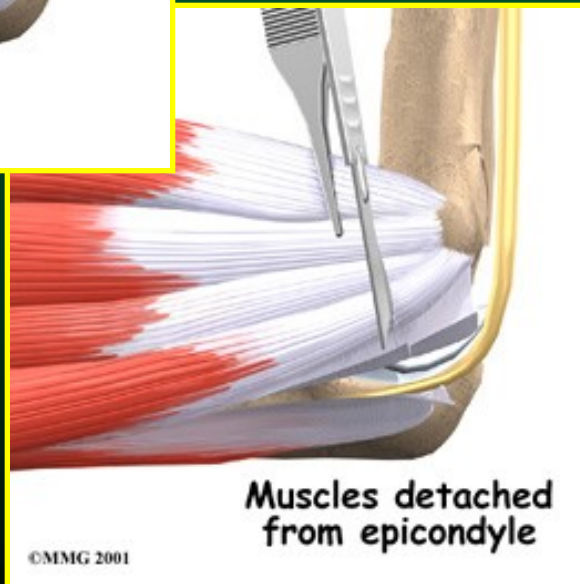
Úžinové syndromy

◆ N.ULNARIS - syndrom kubitálního kanálu

- ◆ Komprese v sulcus n. ulnaris
(kanálek překrytý m.fle.carp.uln.)
- ◆ Brusiči skla, telefonistky, hodináři
- ◆ Postižení:
 - bolesti při flexi + ulnární dukci lokte
 - oslabení malíku (ADD+ABD)
 - parestezie ulnární části předloktí
 - parestezie IV.+V.prstu



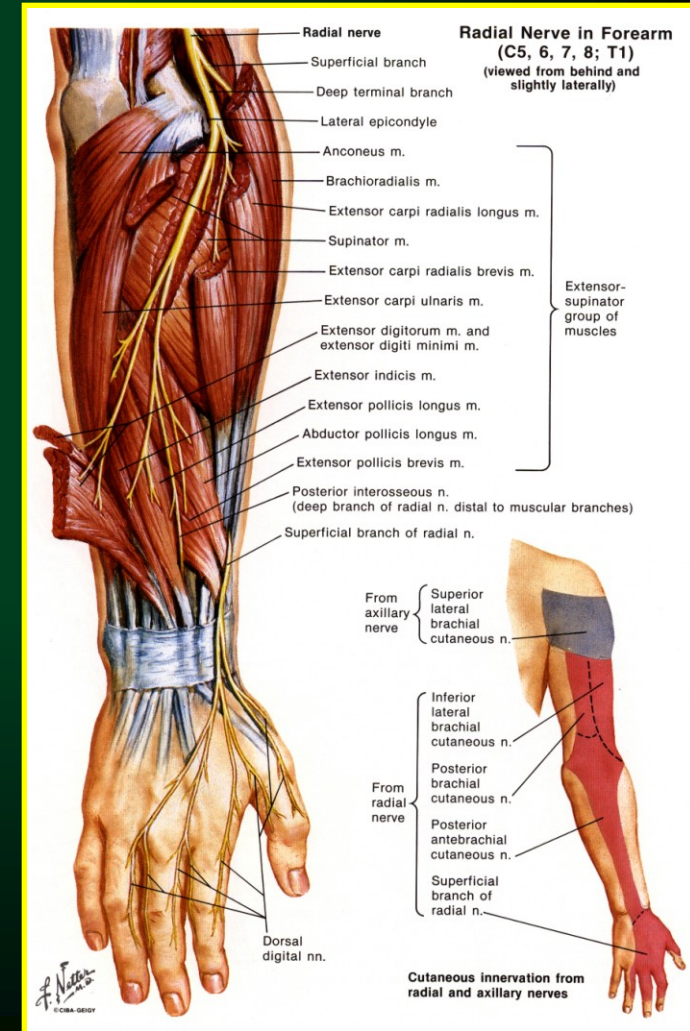
Operační léčba syndromu kubitálního tunelu



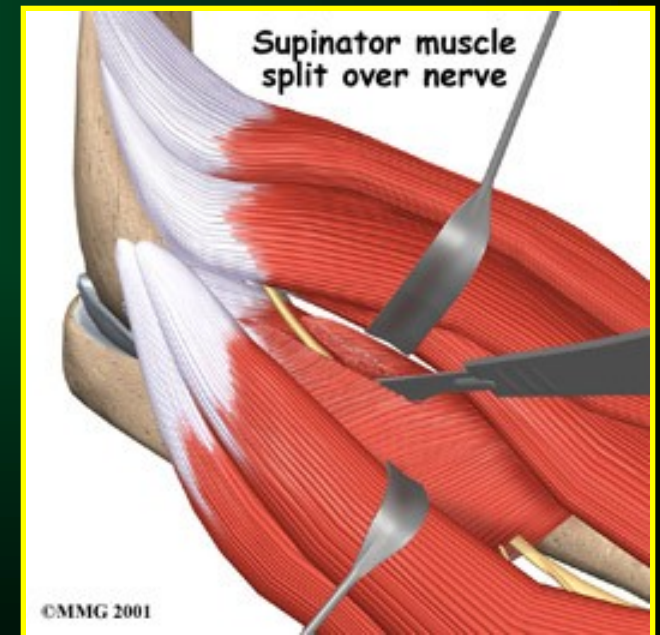
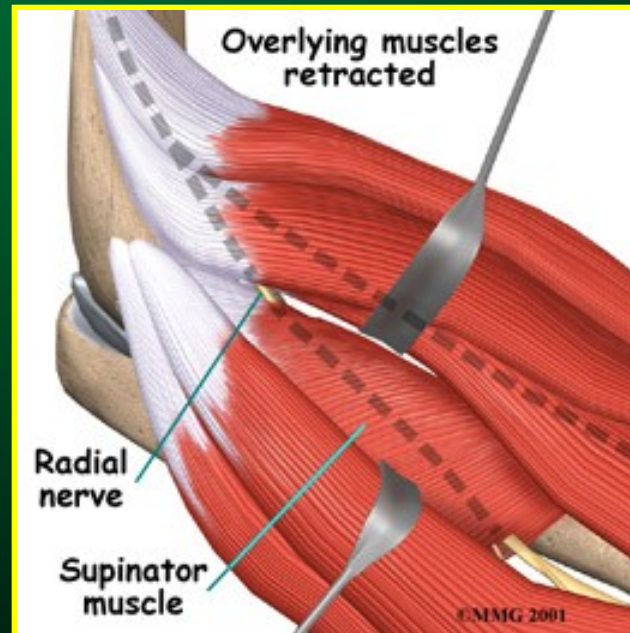
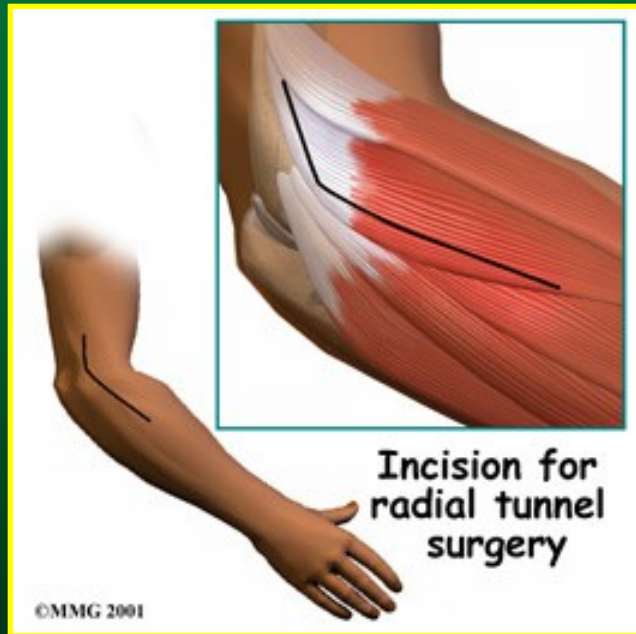Úžinové syndromy

◆ N.RADIALIS - supinátorový syndrom

- ◆ **Komprese ve Frohseho arkádě**
v m. supinator
- ◆ **Napodobuje tenisový loket !**
- ◆ **Potíže:**
 - zhoršení při pronaci
 - a palm. flexi karpu
 - parestezie volární část předloktí
 - hluboká větev - paréza EXT prstů
 - povrch. větev - písářská křeč
 - (cheiralgia parestetica)



Operační léčba supinátorového syndromu



Úžinové syndromy

- ◆ Diagnostika - emg vyšetření
- ◆ Terapie - chirurgická dekomprese

Záněty lokte

- ◆ Revmatoidní artritida
- ◆ Septická artritida
- ◆ Bursitis olecrani (studentský loket)

Artróza lokte

◆ Primární

- metabolické poruchy chondrocytů

- synovialitis

- subchondrální cysty

- nestabilita + osteofyty

◆ Sekundární

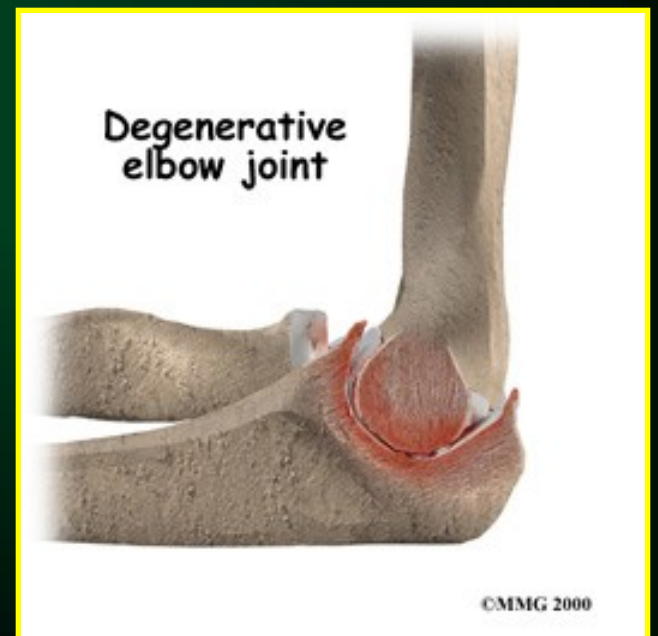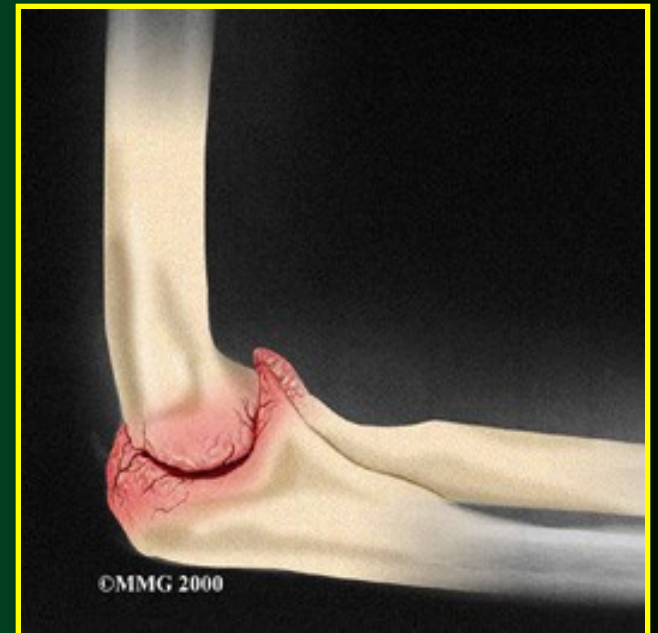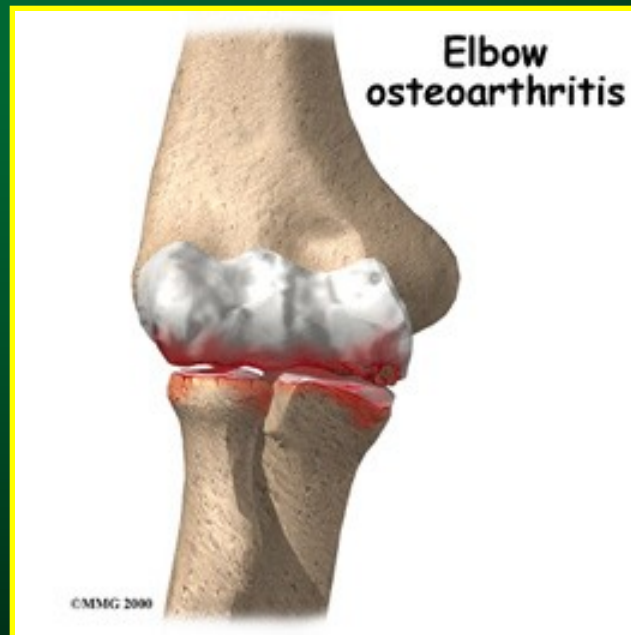
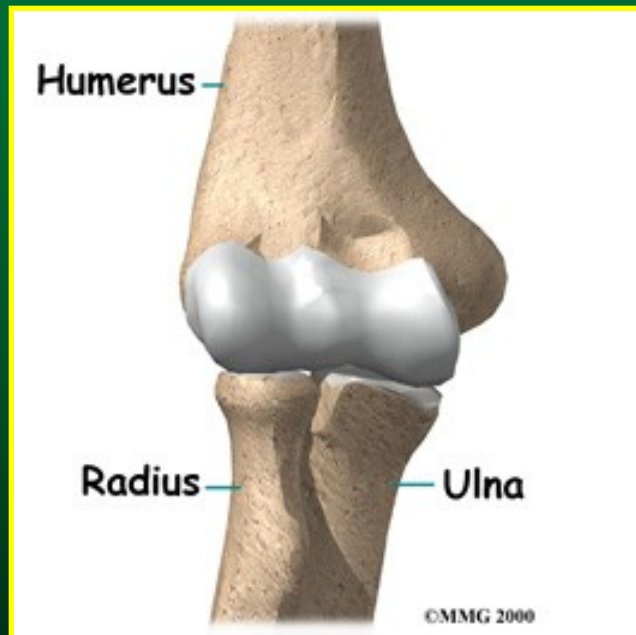
- traumata

- záněty

- metabolická onemocnění

- aseptické kostní nekrózy

Artróza lokte



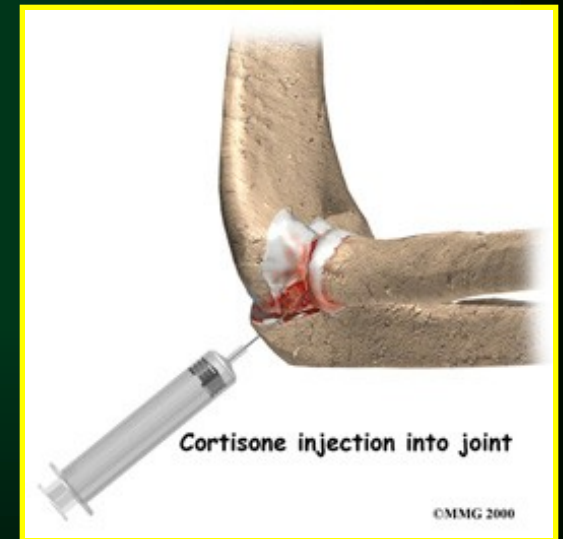
Terapie artrózy lokte

◆ Konzervativní

- medikamenty (NSAID, chondroprotektiva)
- intraartikulární injekce (kortikoidy-depomedrol)
- rehabilitace - k zachování pohybu (IF, UZ, vodoléčba, LTV)

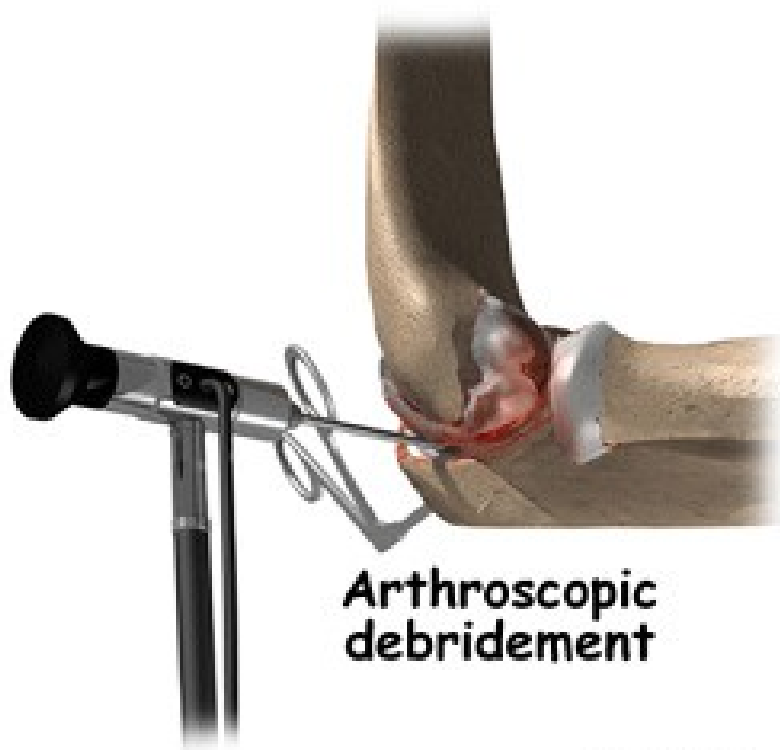
◆ Chirurgická

- artroskopie (debridement)
- artrodézy
- endoprotézy



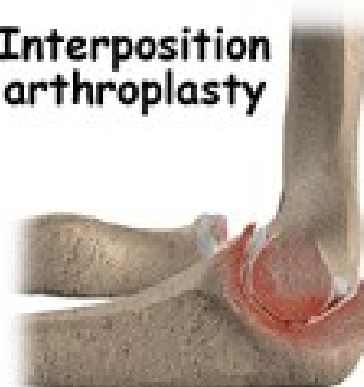
Artróza lokte

operační terapeutické možnosti

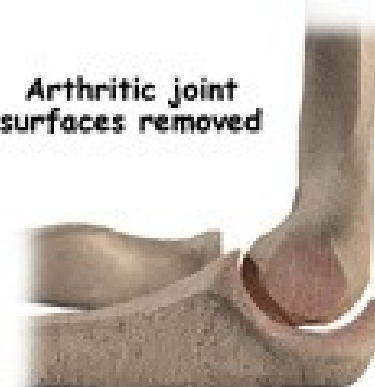

©MMMG 2000

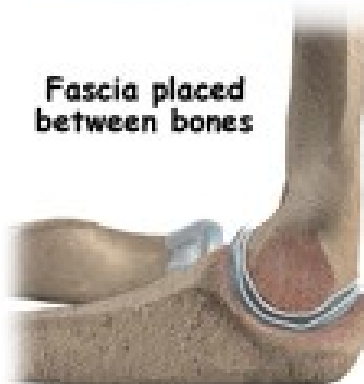Interposition
arthroplasty



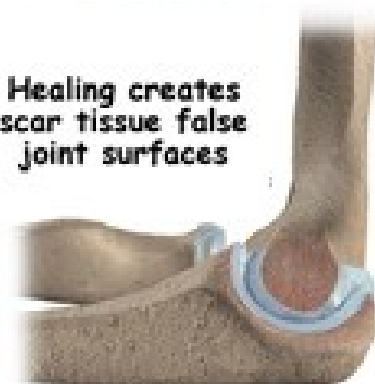Arthritic joint
surfaces removed



Fascia placed
between bones

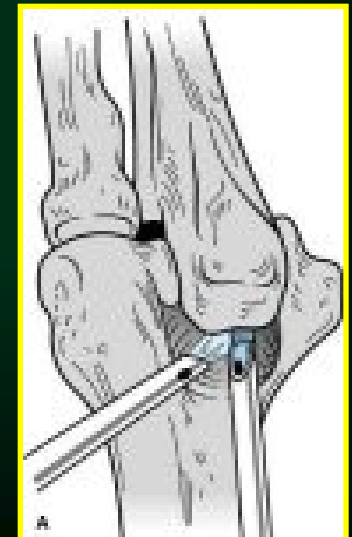
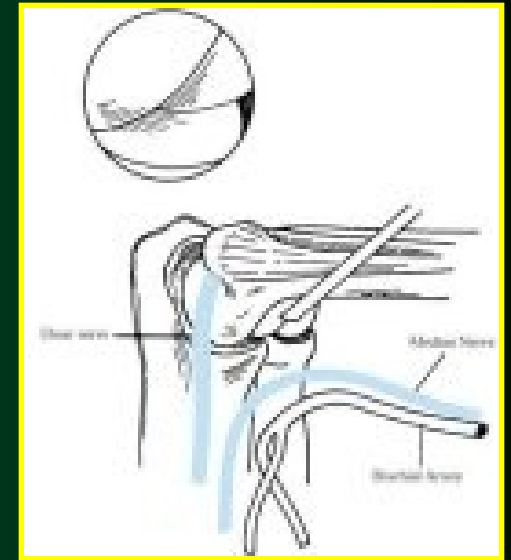
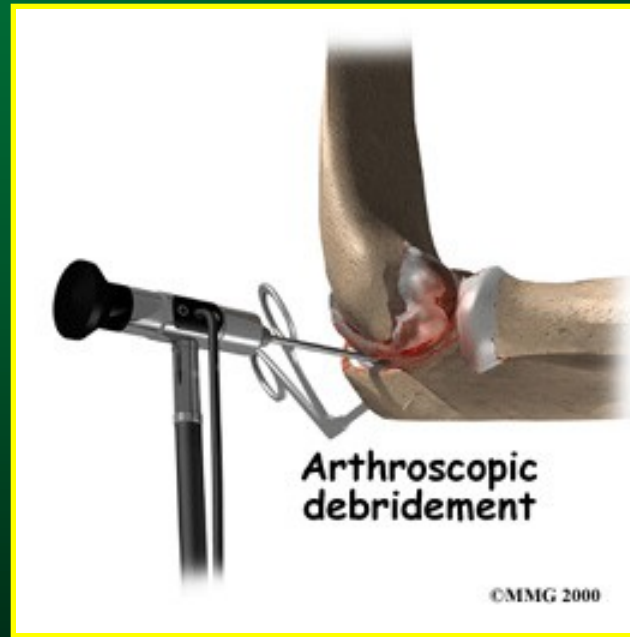
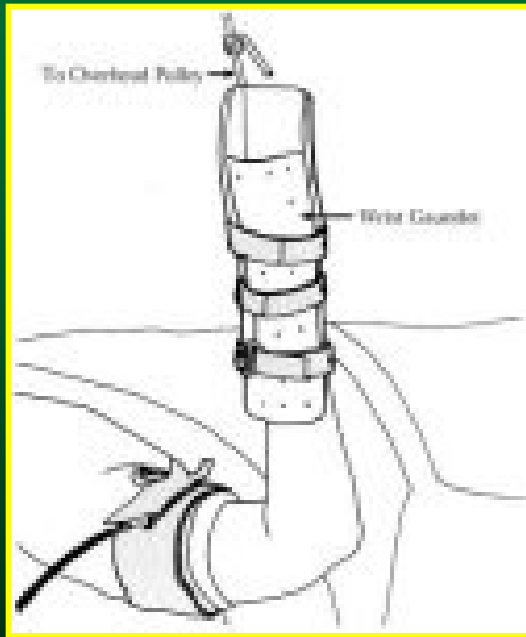


Healing creates
scar tissue false
joint surfaces

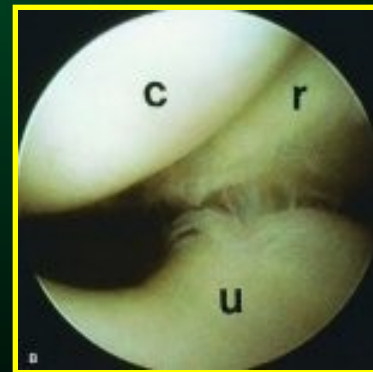
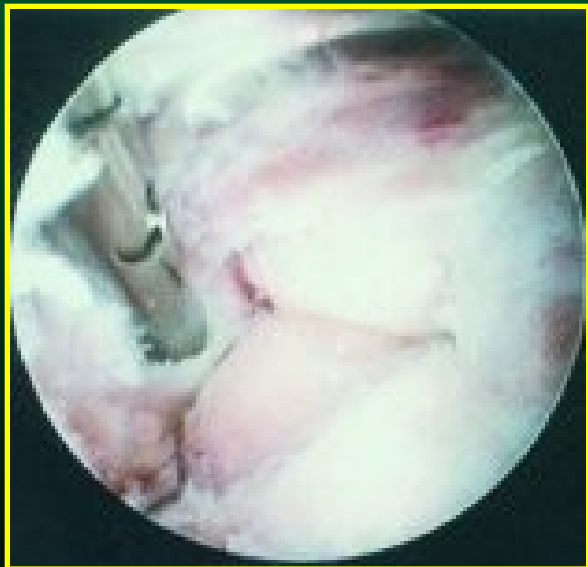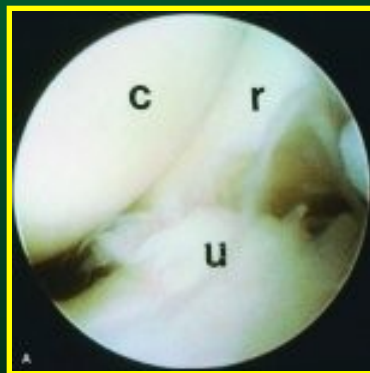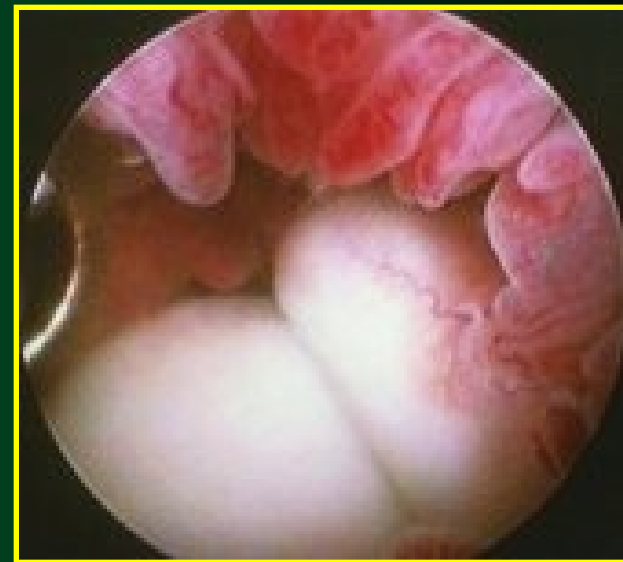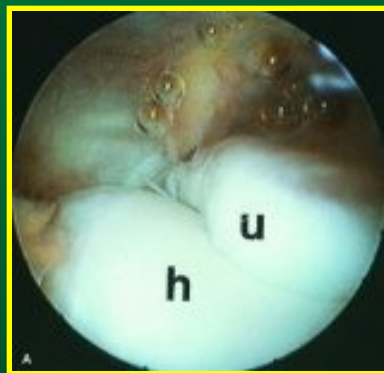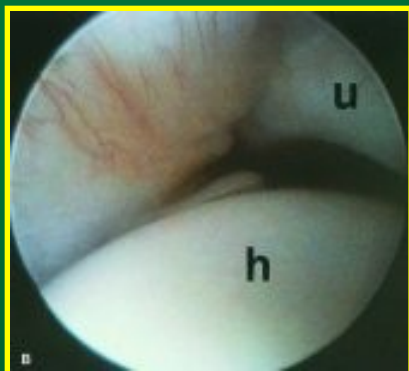


©MMMG 2000

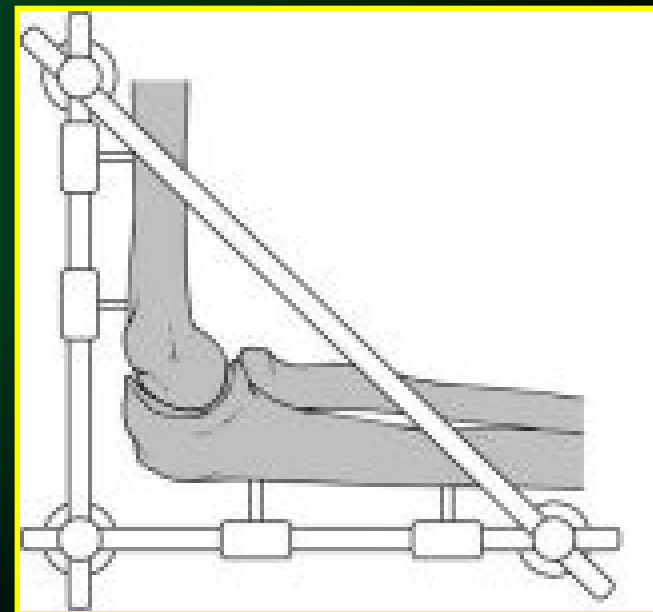
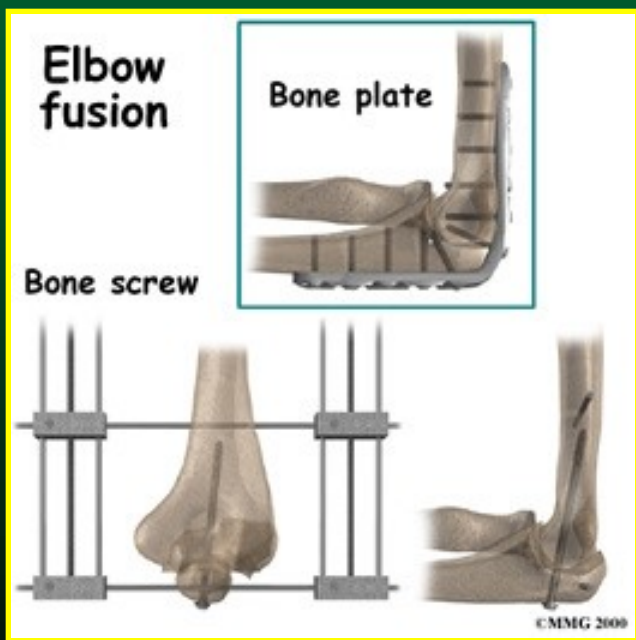
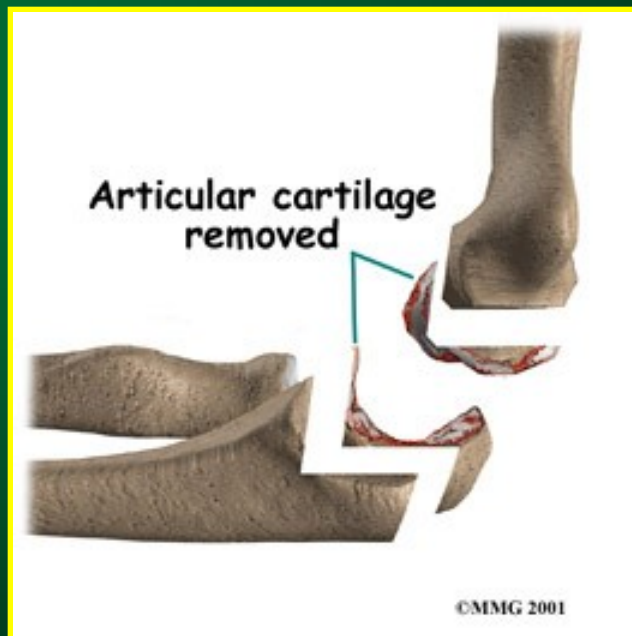
Artrioskopie lokte



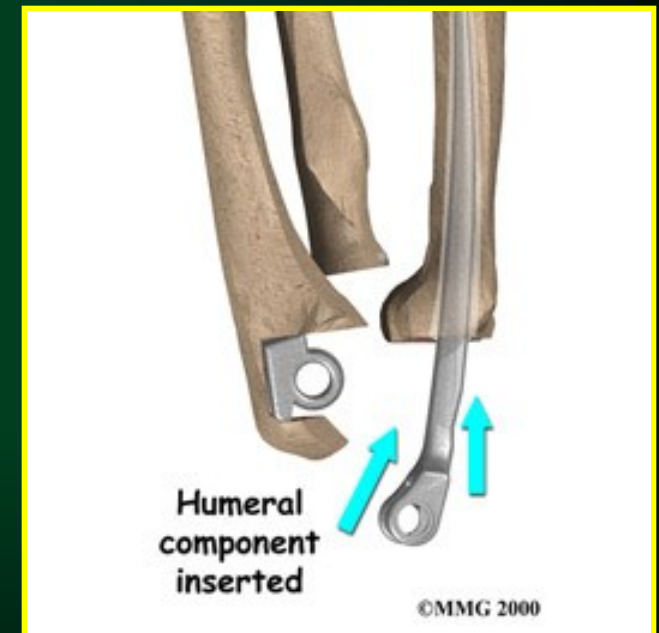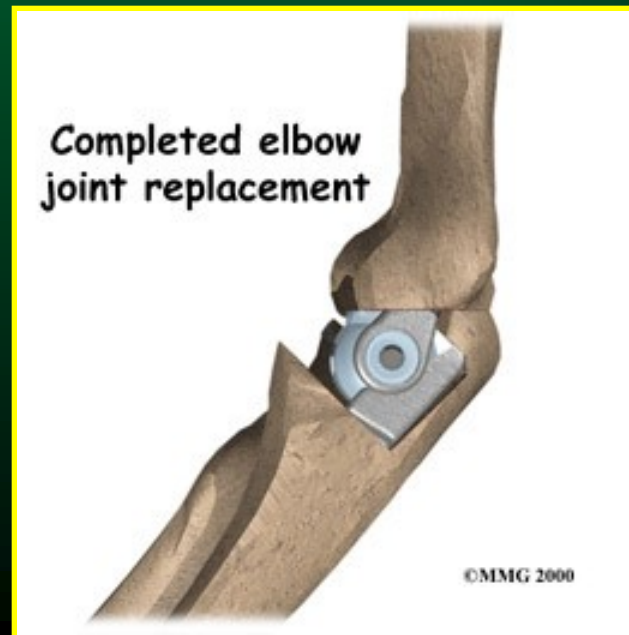
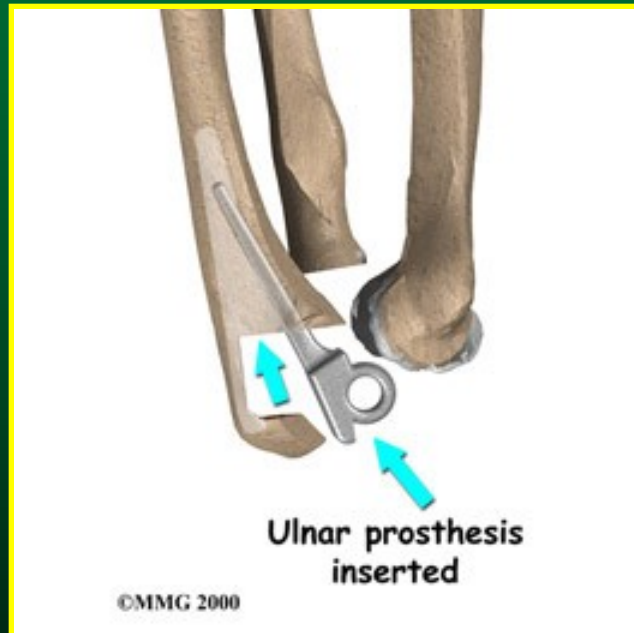
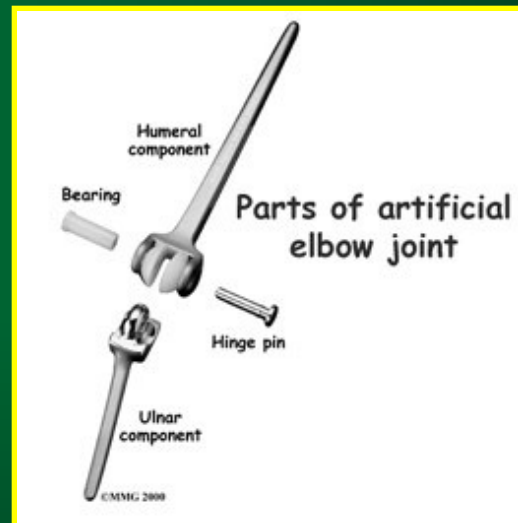
Artrioskopie lokte



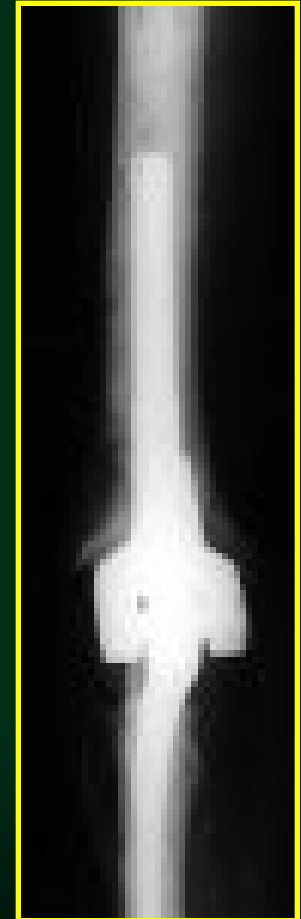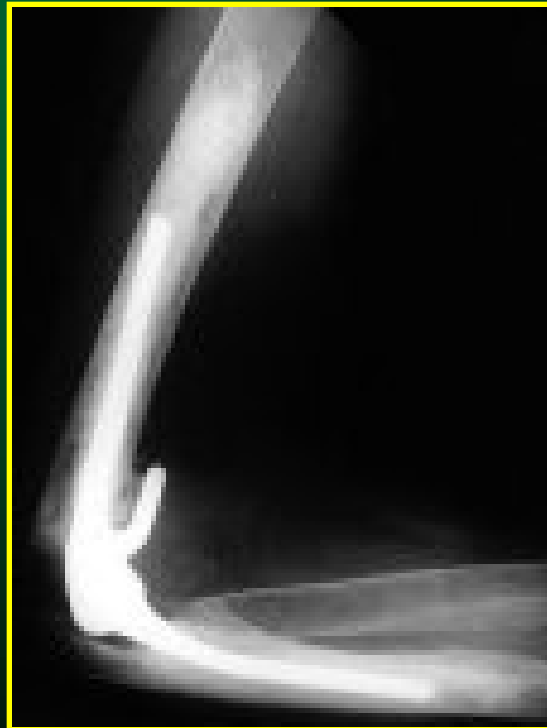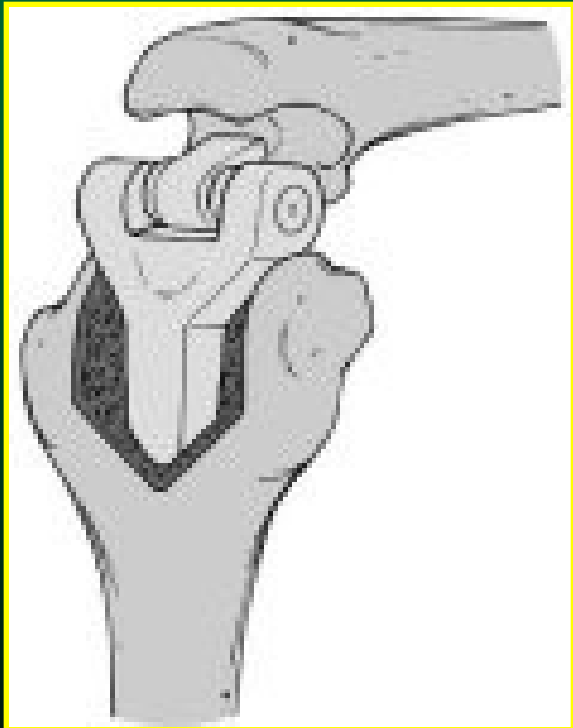
Artrodéza lokte



Totální endoprotéza lokte

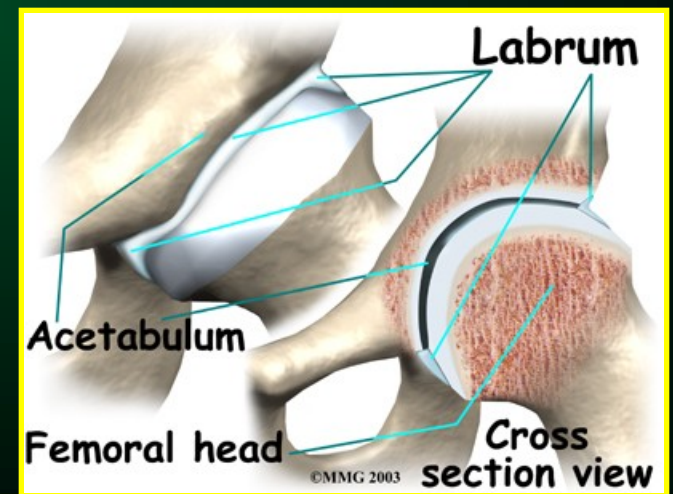
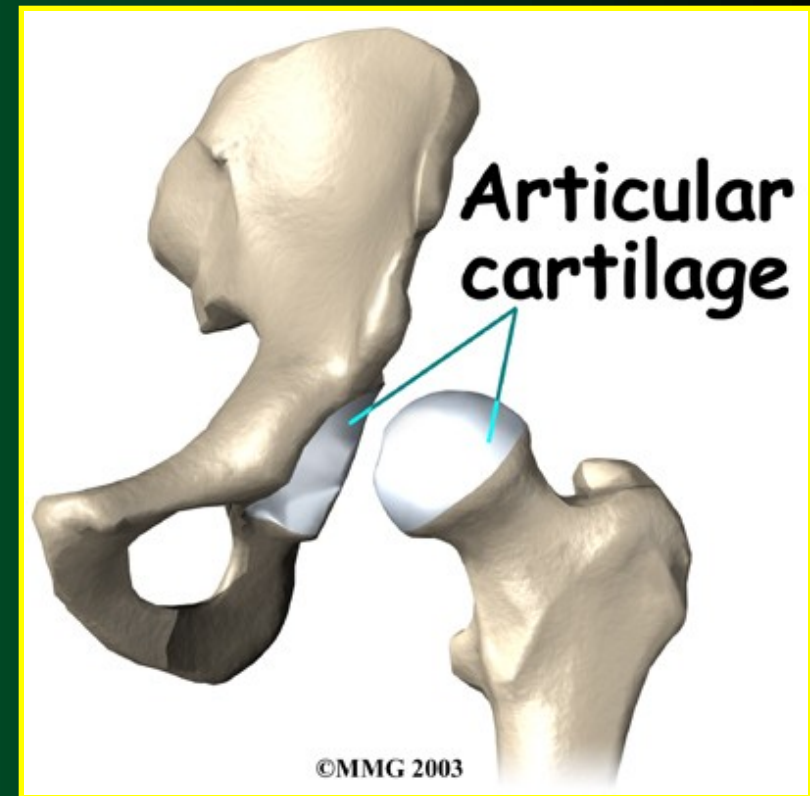
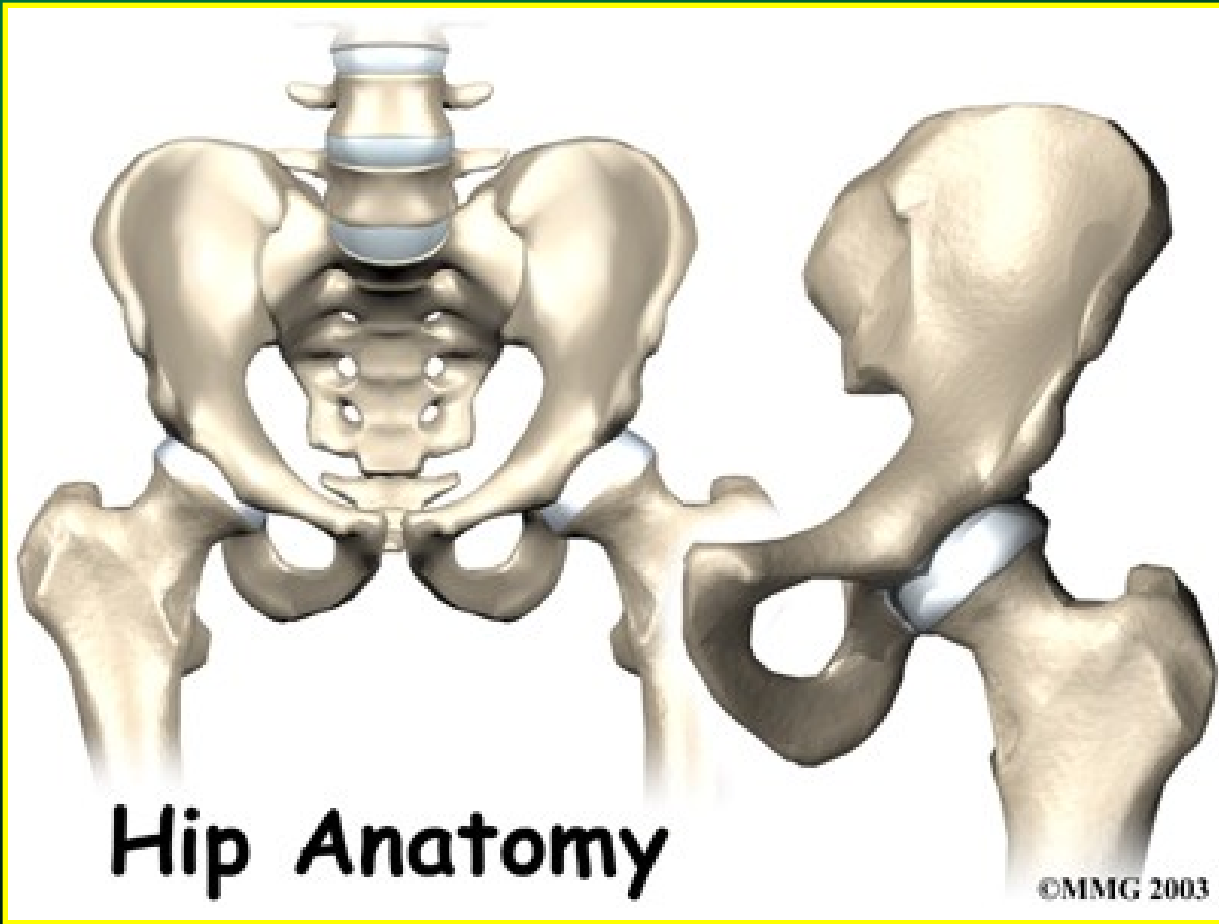


Totální endoprotéza lokte

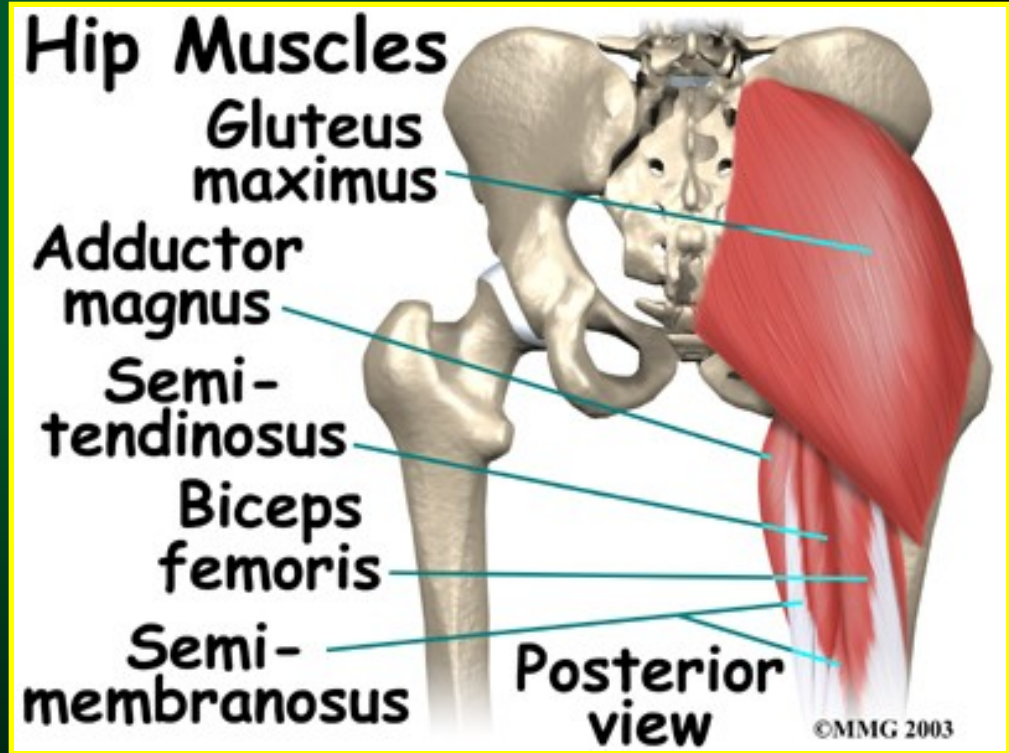
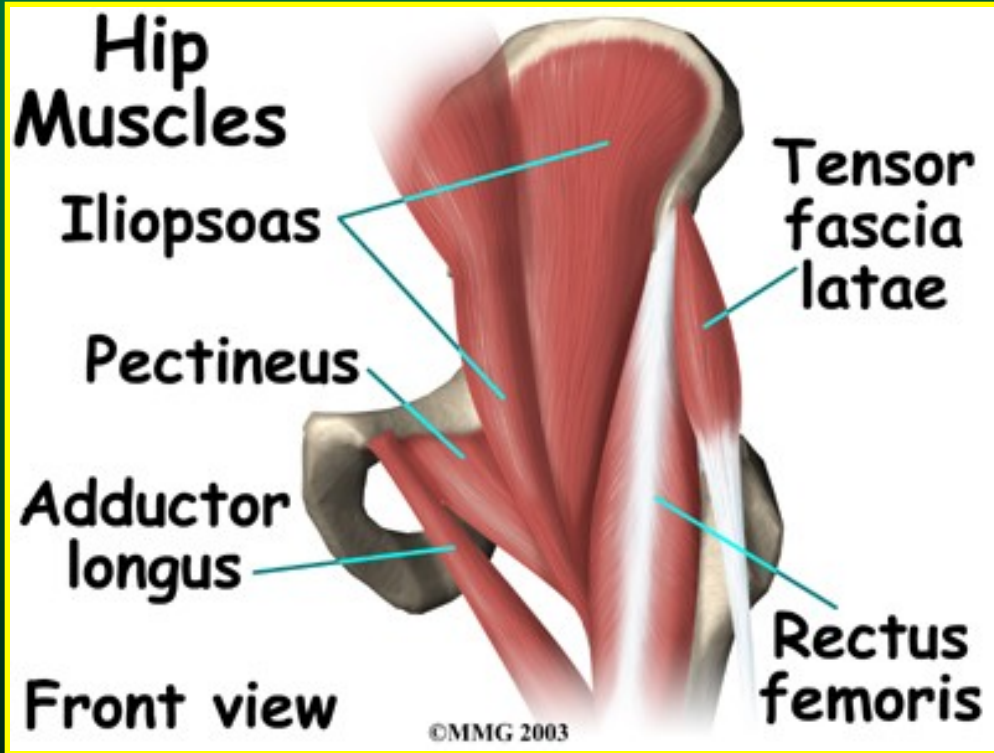


KYČEL

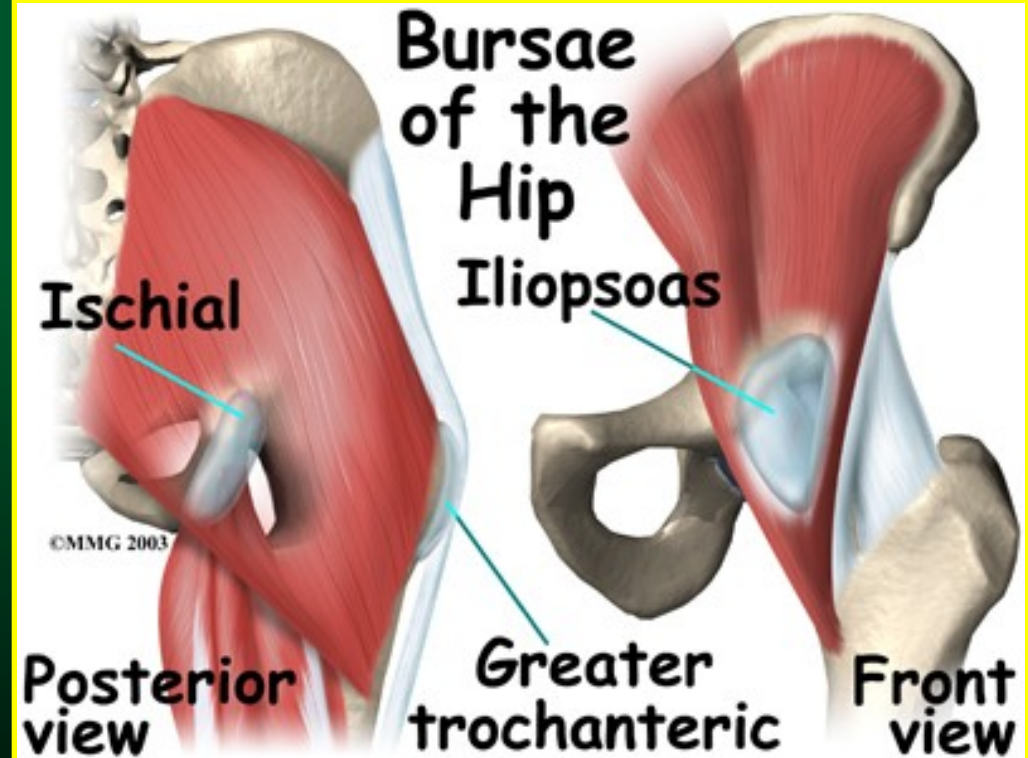
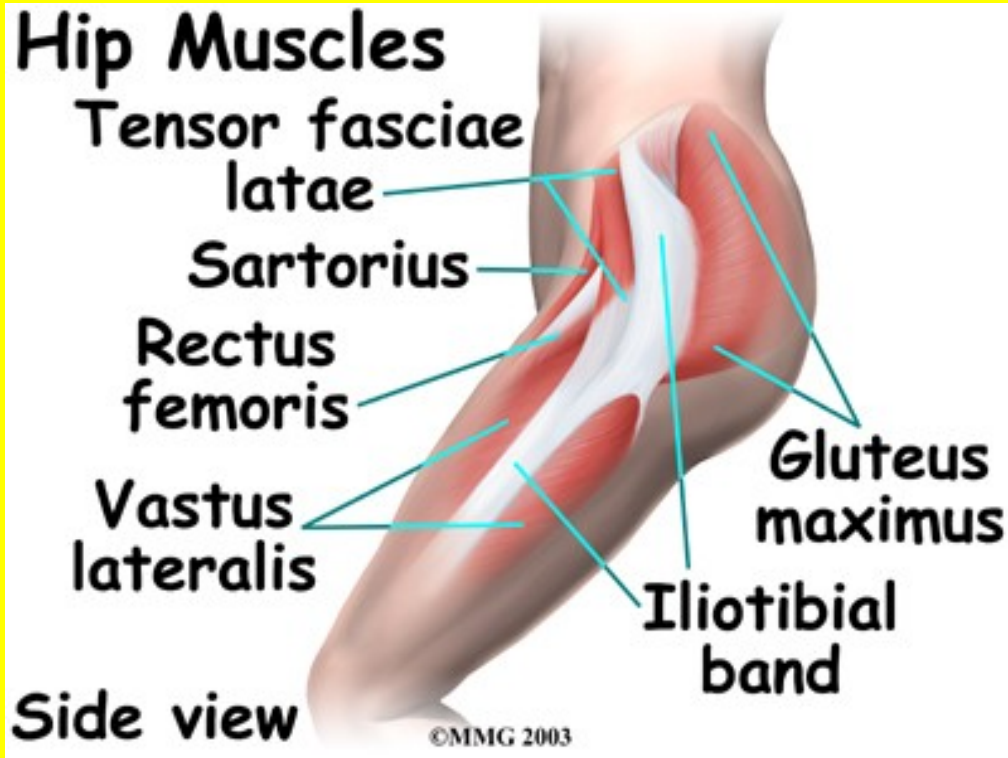
Anatomie



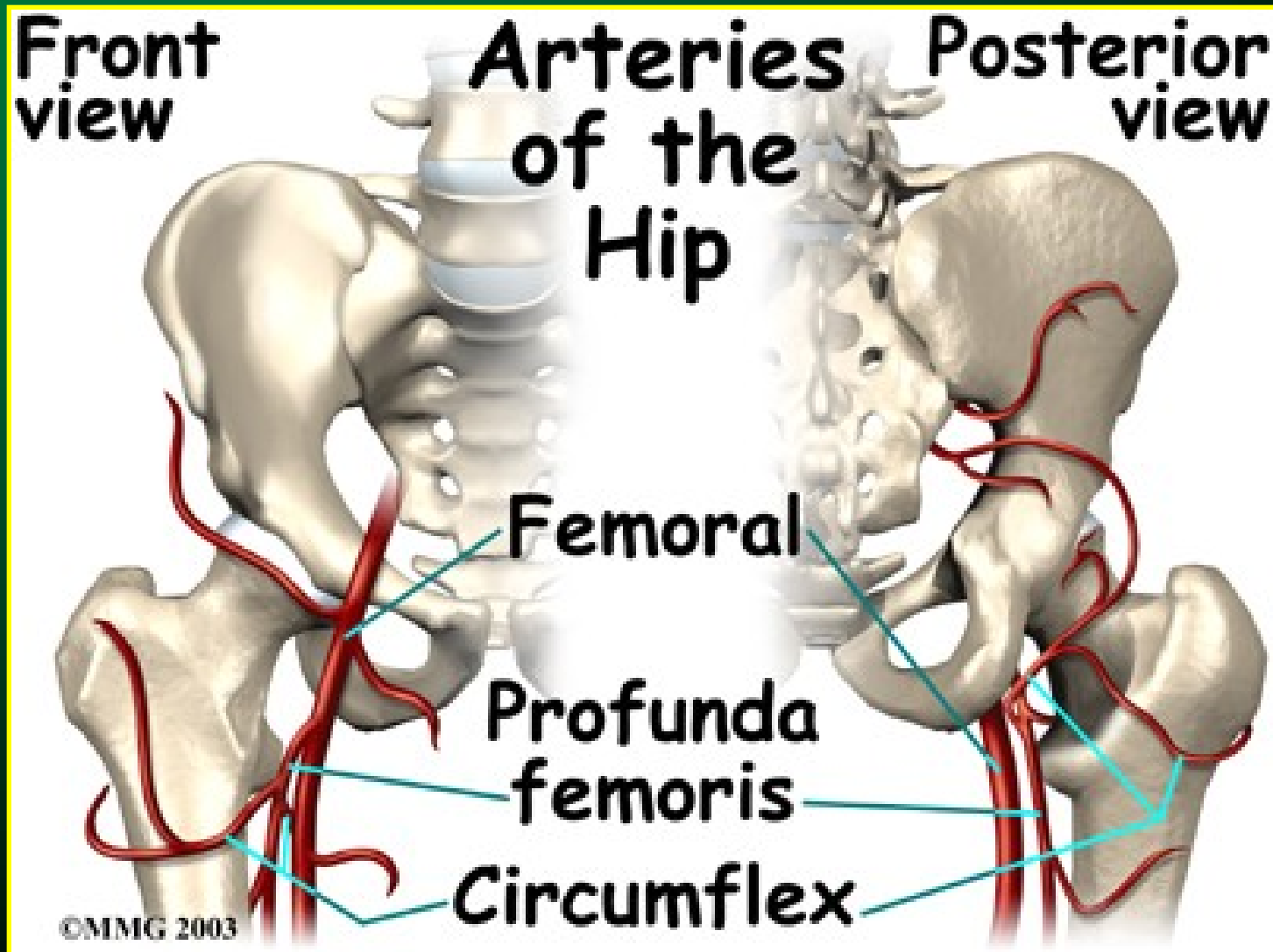
Anatomie



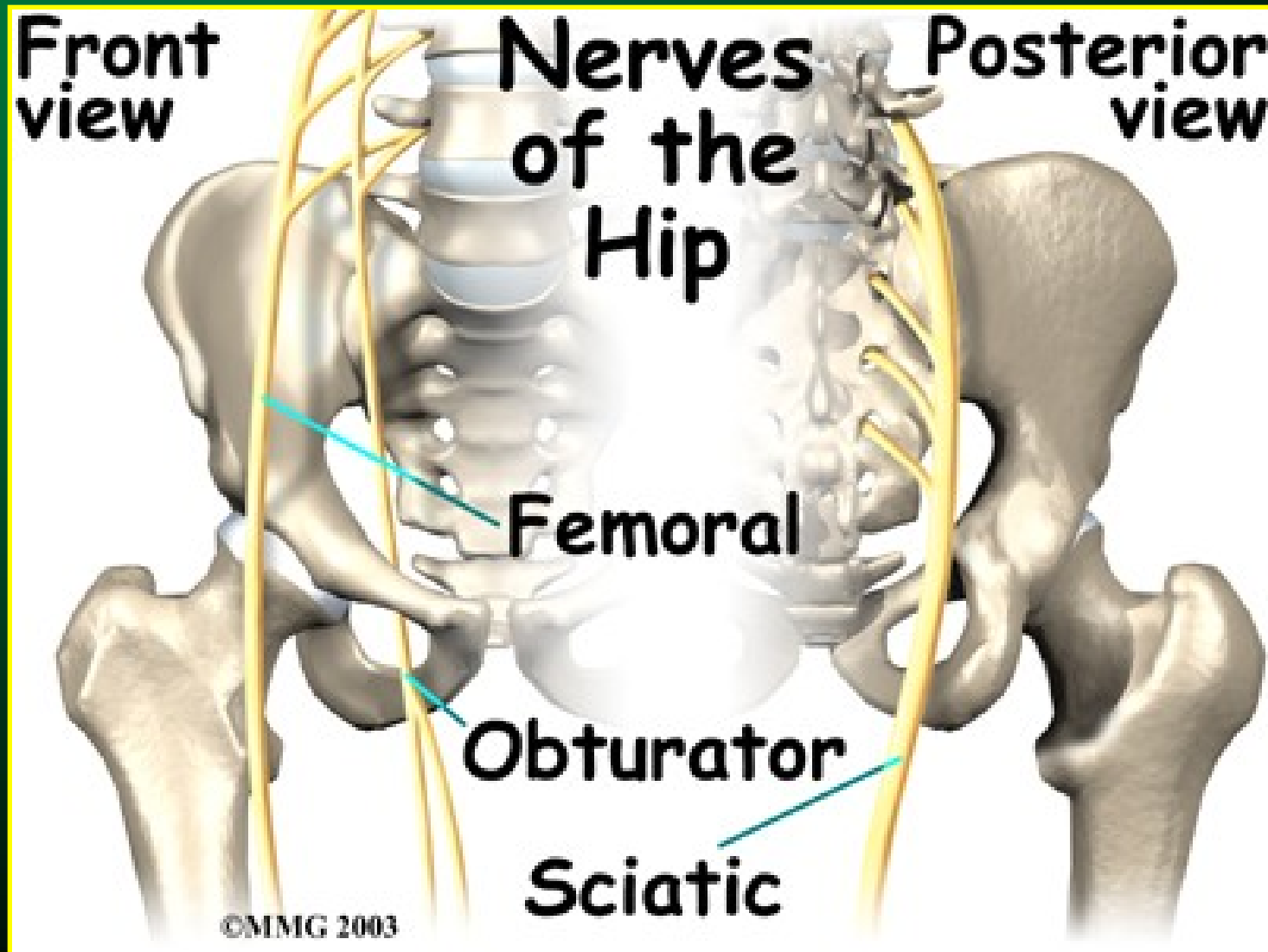
Anatomie



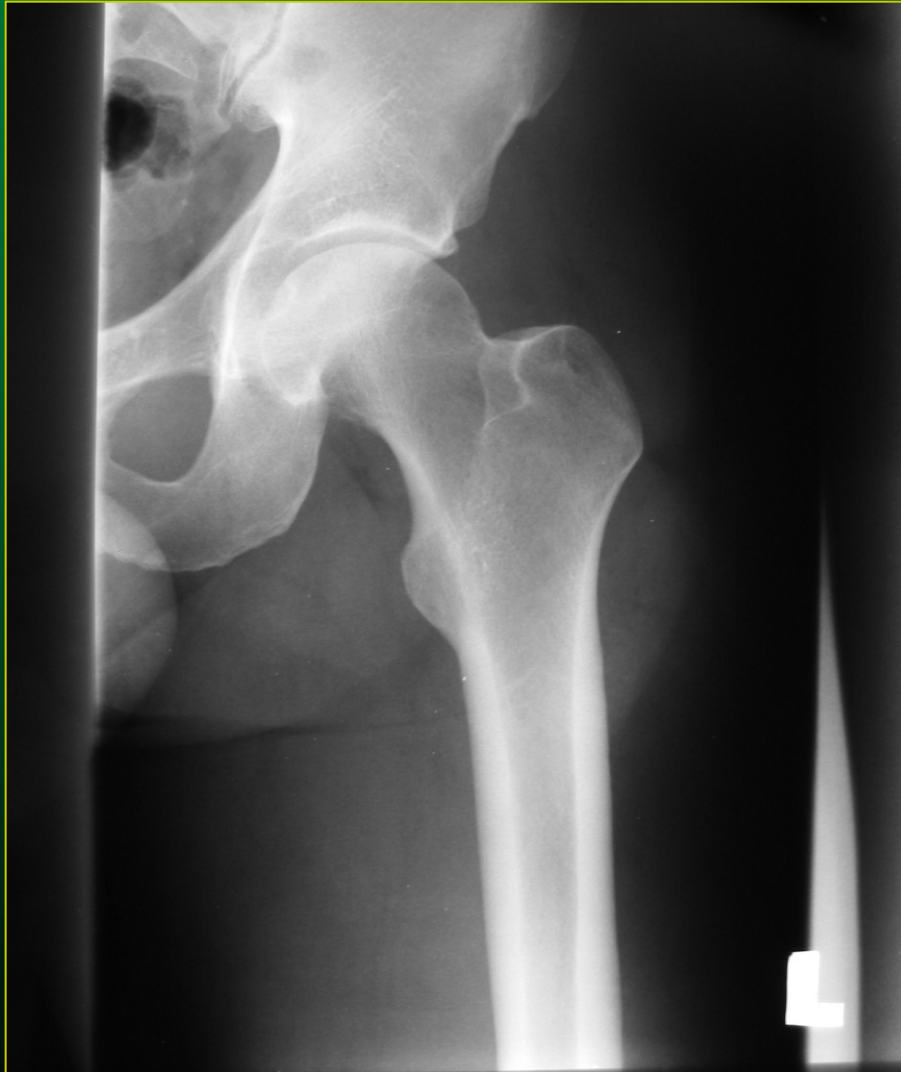Anatomie



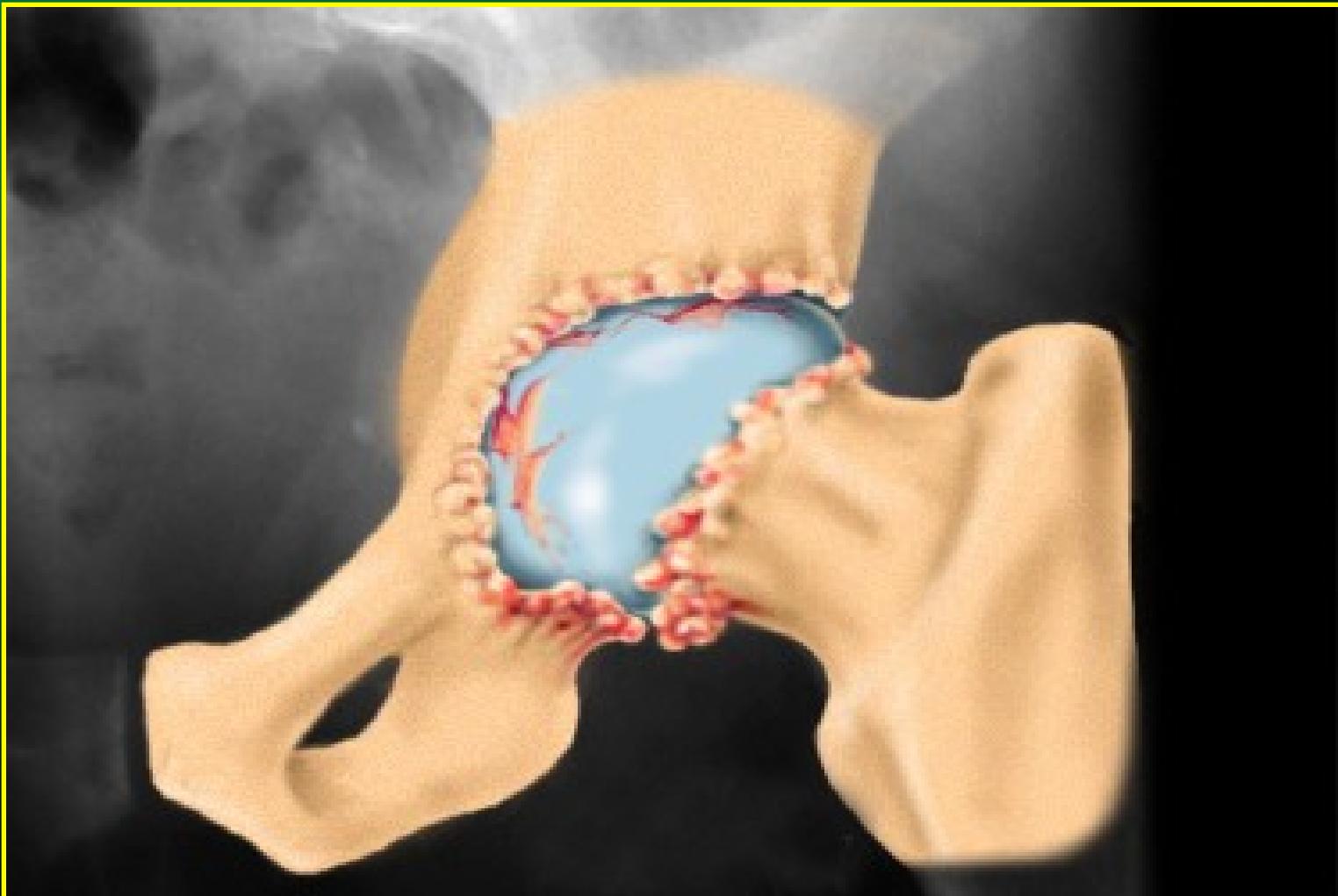
Anatomie



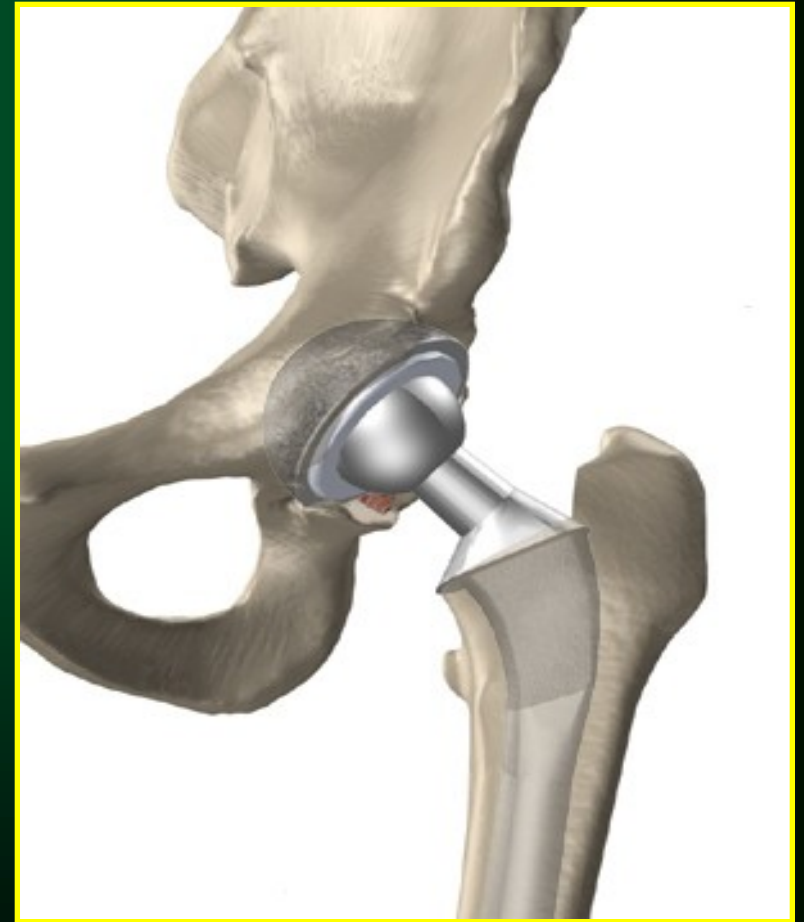
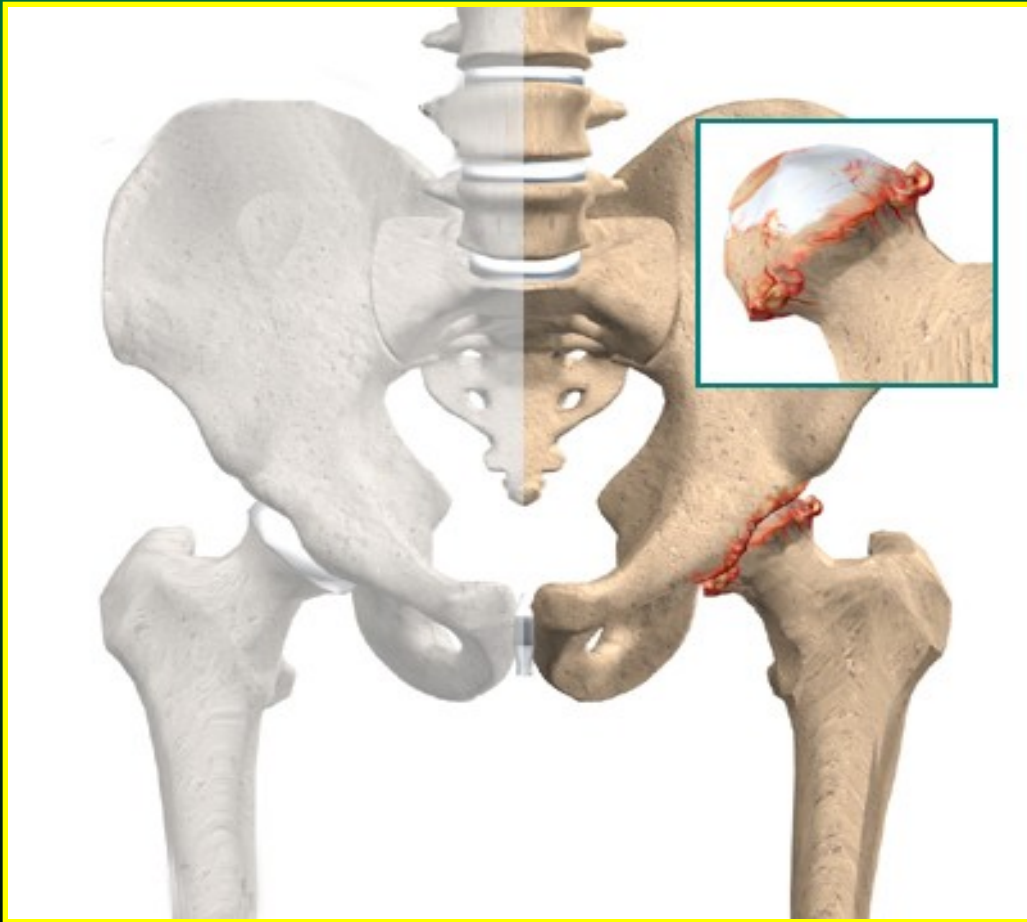
RTG snímek kyčelního kloubu



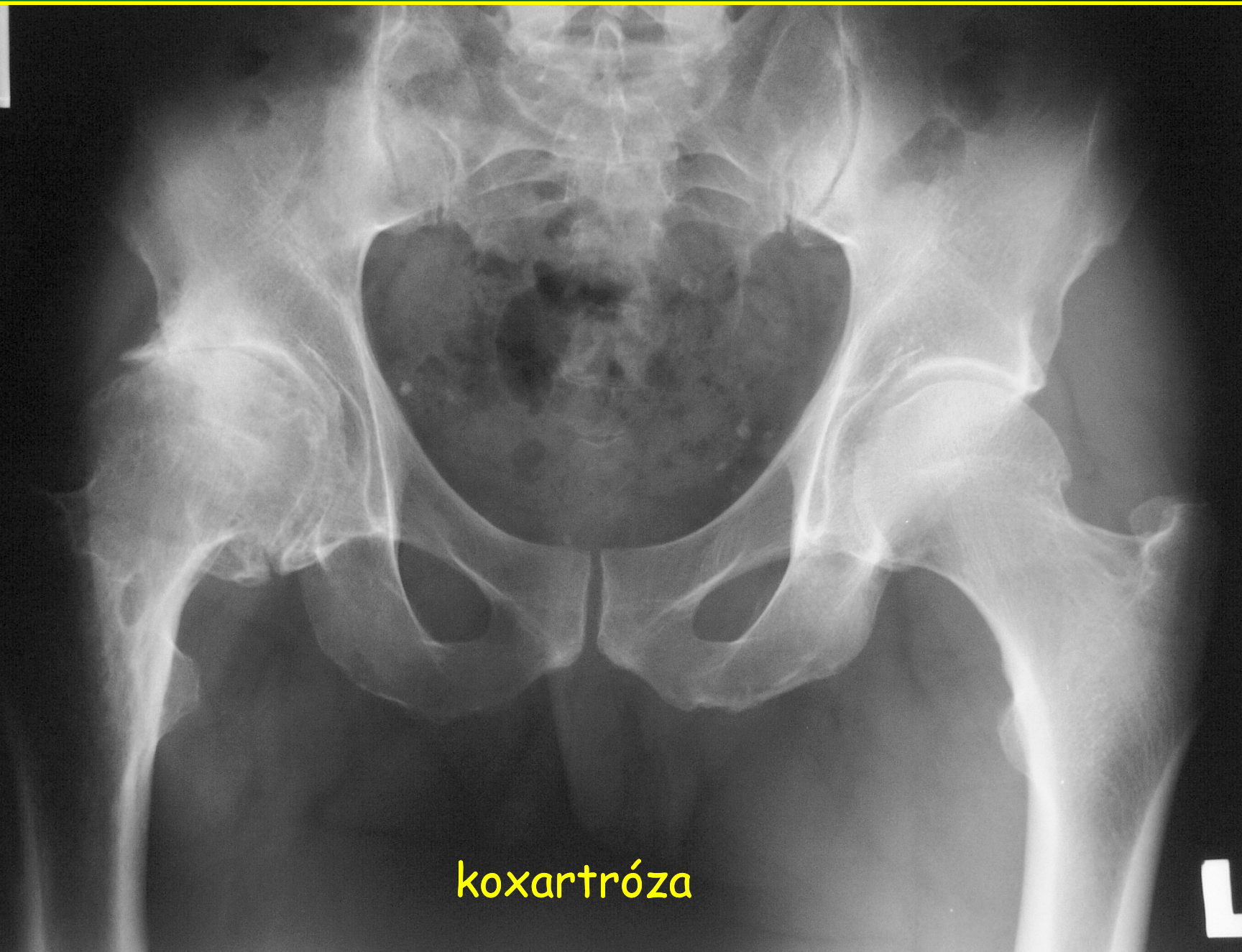
Koxartróza



Koxartróza



Posluszny
510207/16
15.11.09



koxartróza

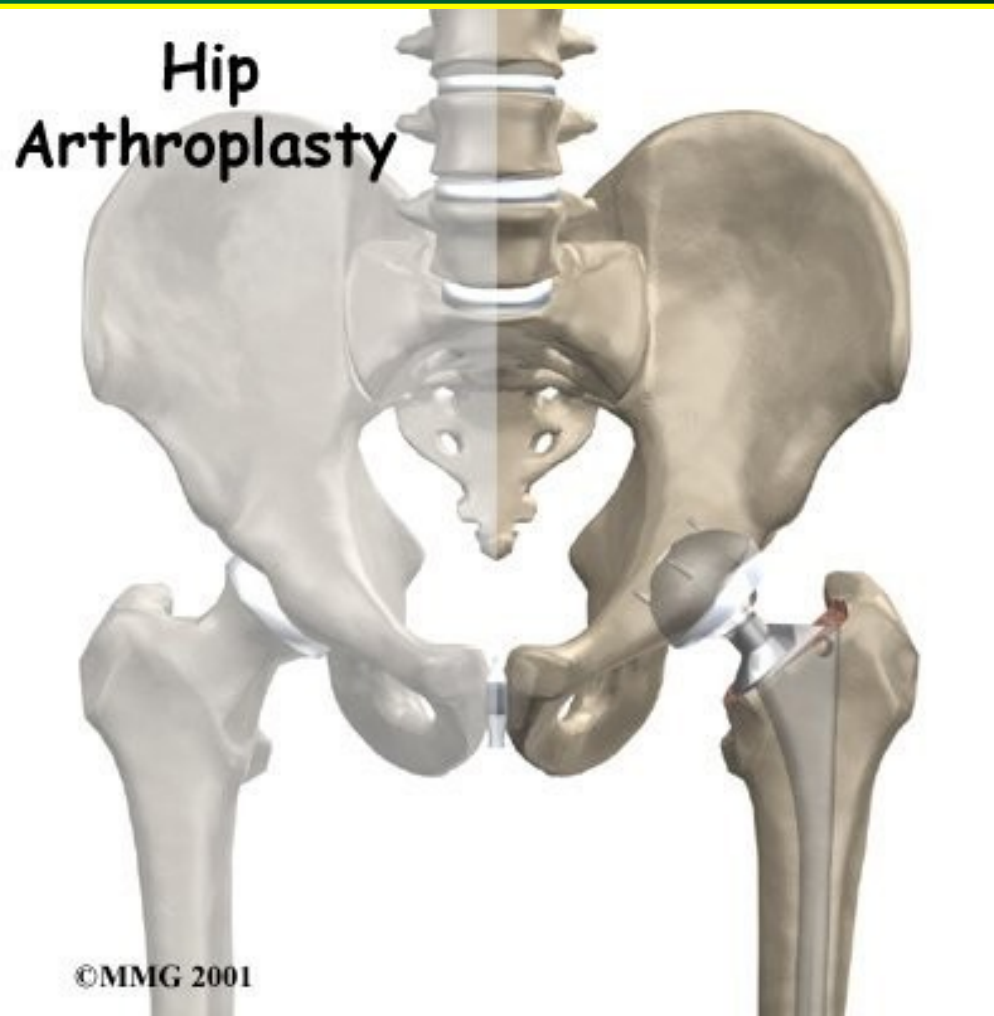
Acetabular
components



©MMG 2002

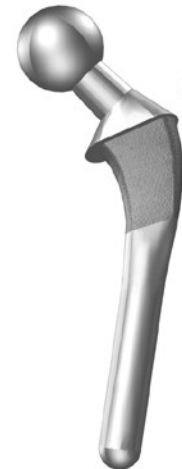TEP

totální endoprotéza



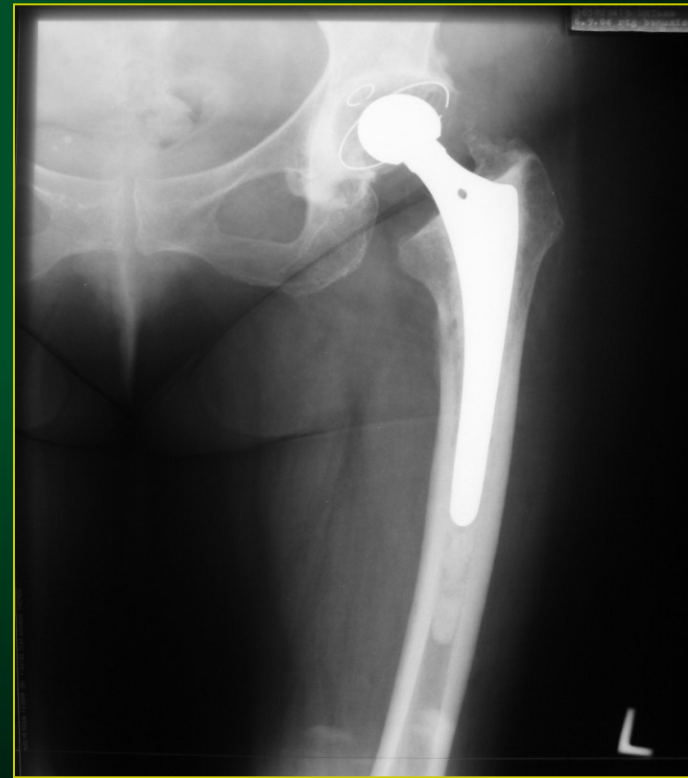
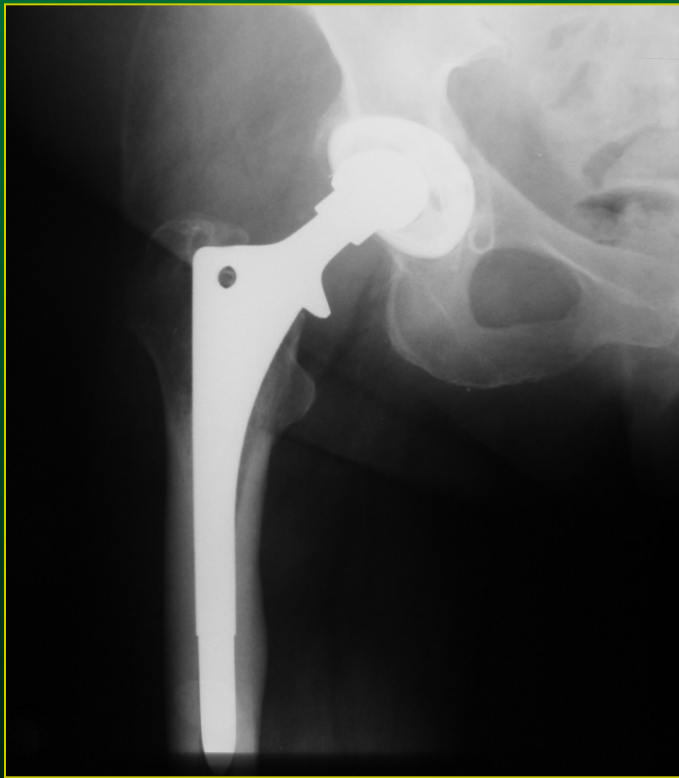
©MMG 2001

Femoral
components

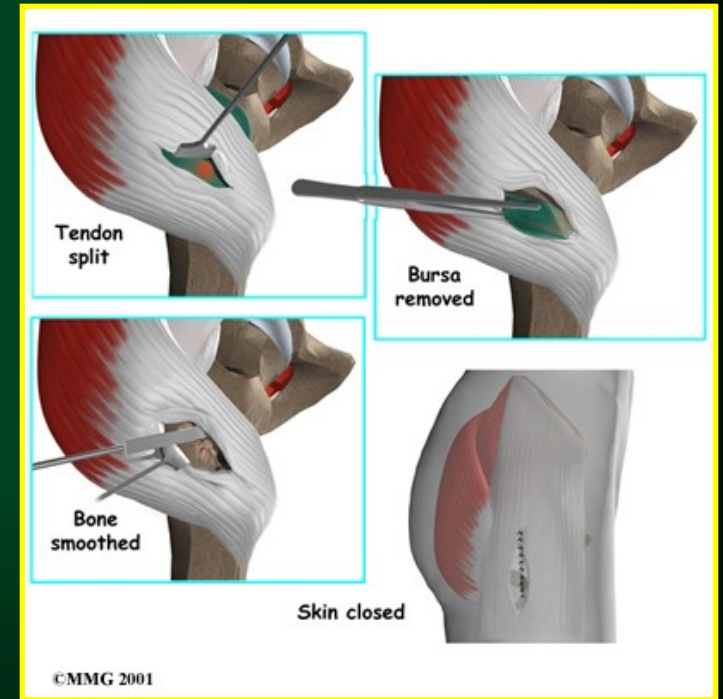
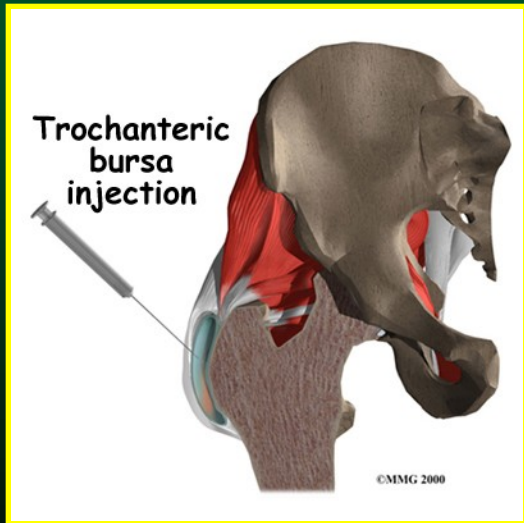
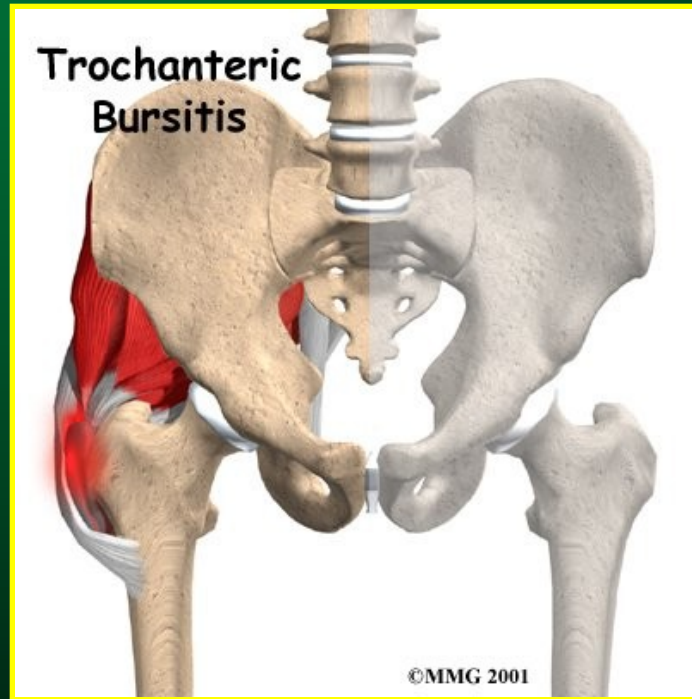
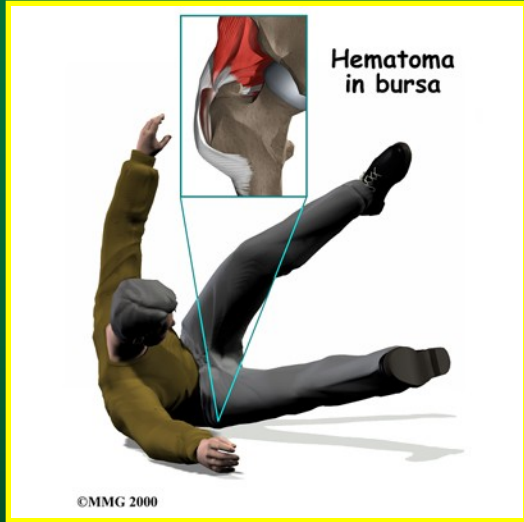


©MMG 2002

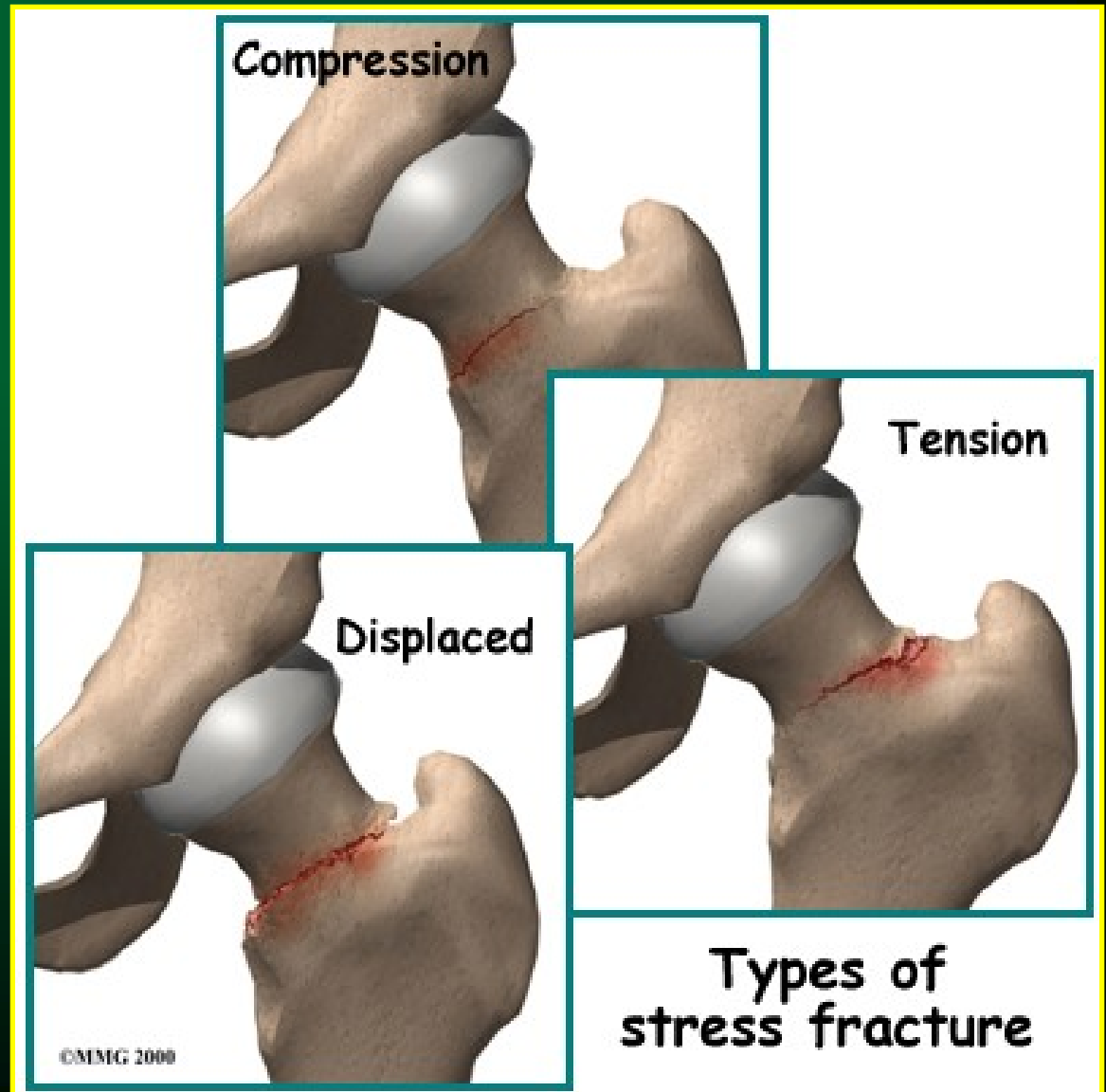
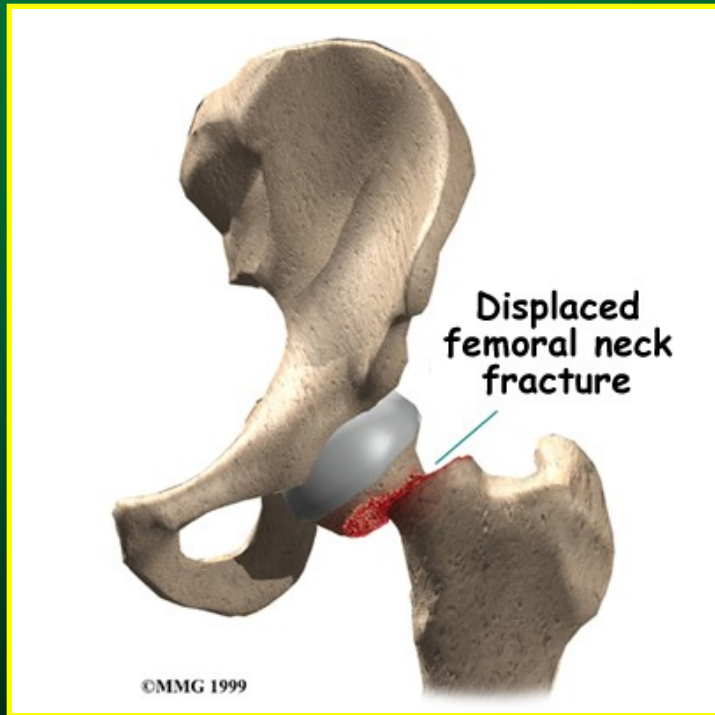
RTG snímky, TEP



Trochanterická bursitida

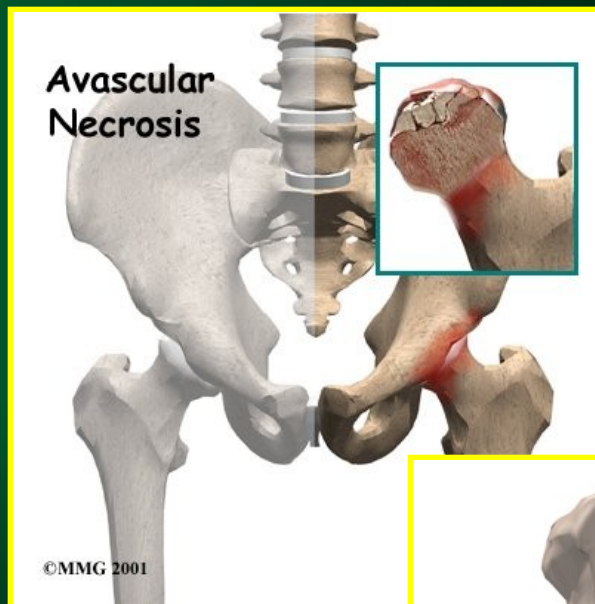
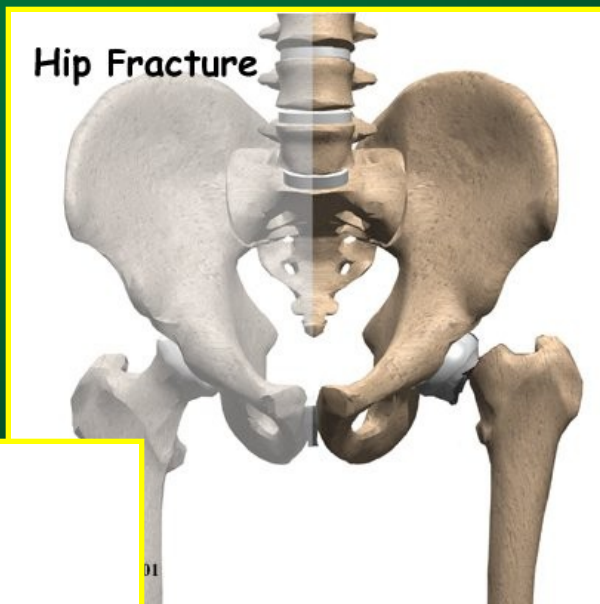


Fraktury krčku femoru

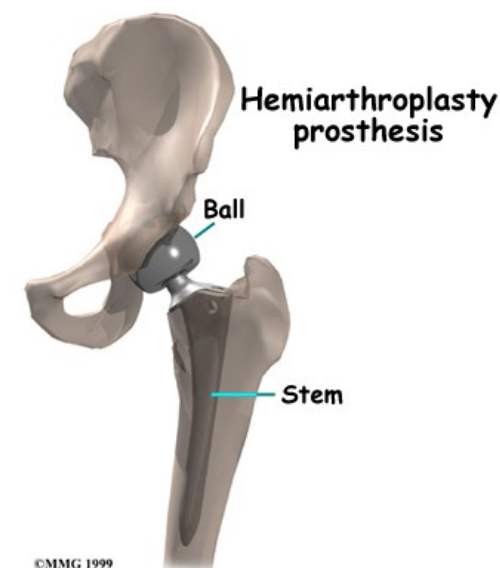
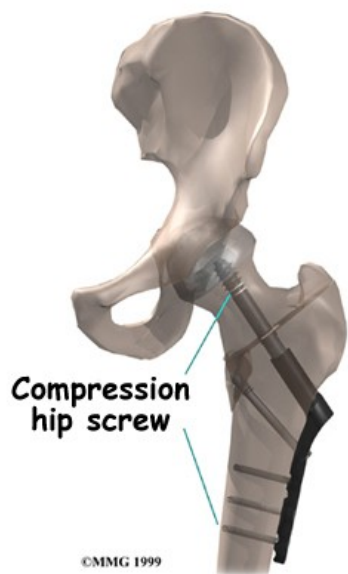


Operační léčba zlomenin krčku femoru

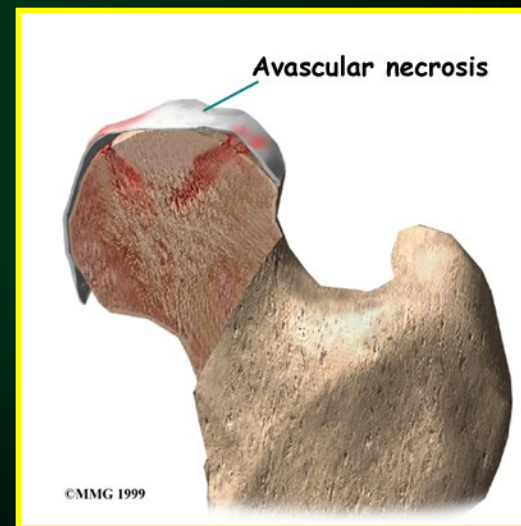
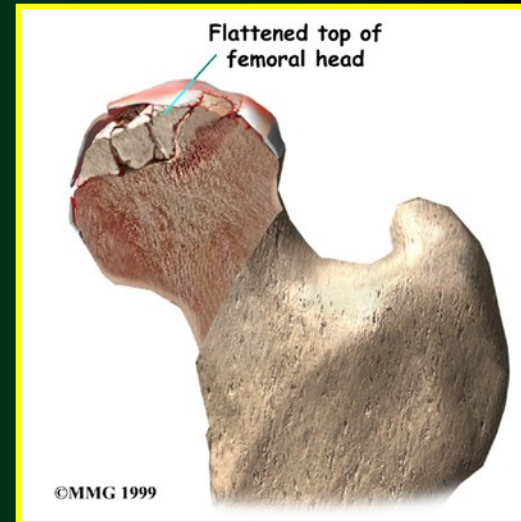
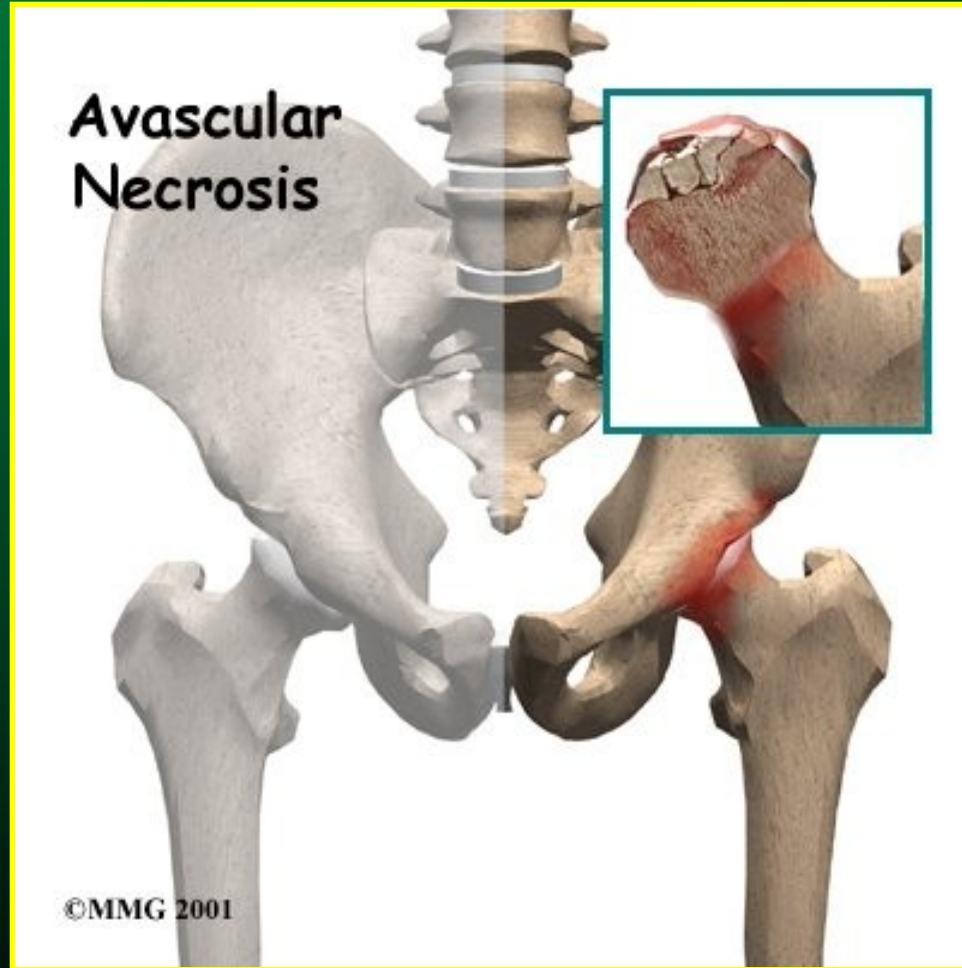
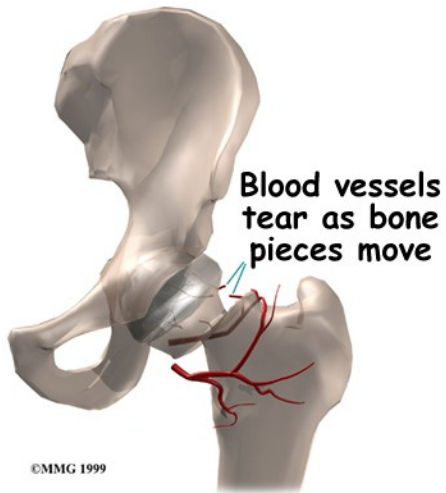
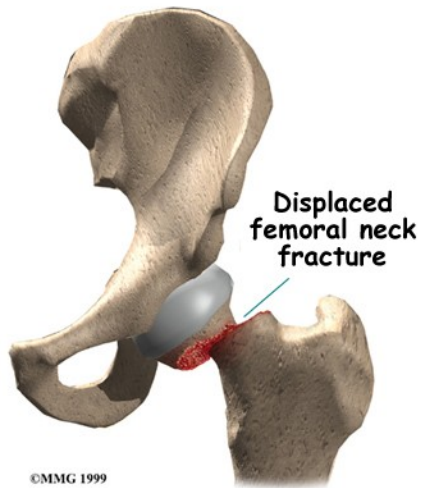
osteosyntéza



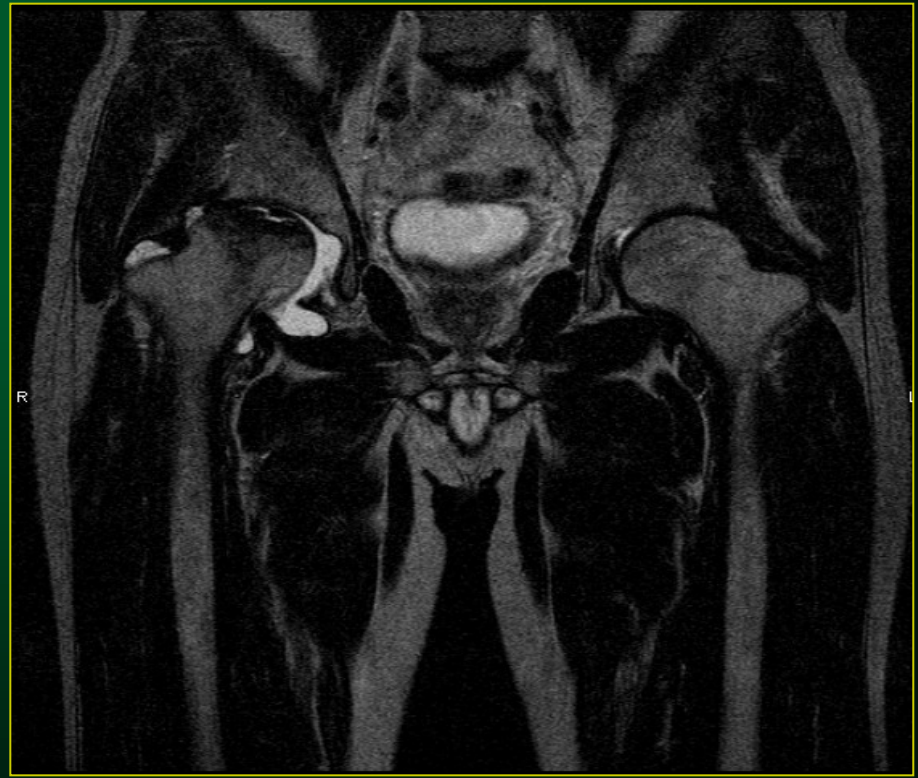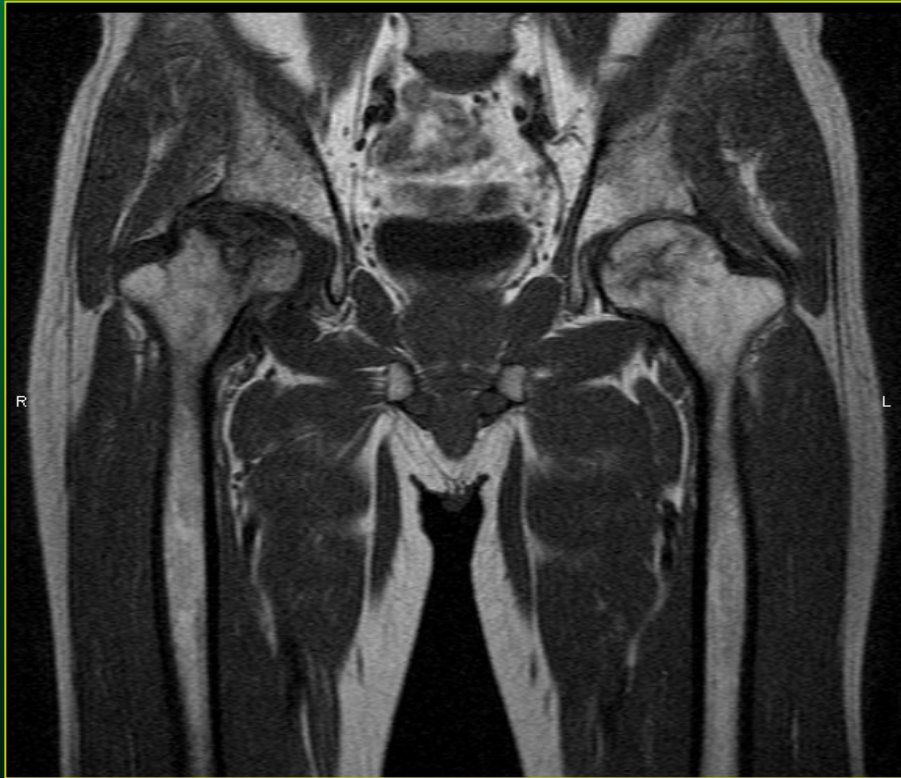CKP/TEP



Fraktury krčku femoru

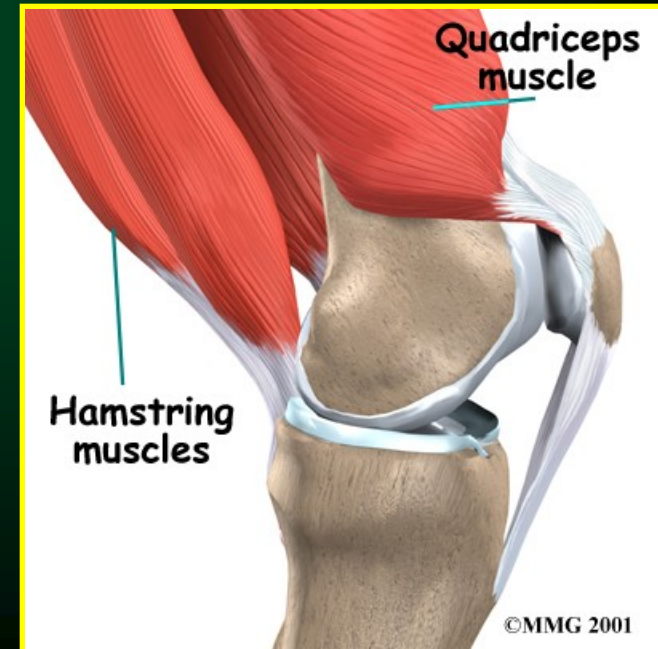
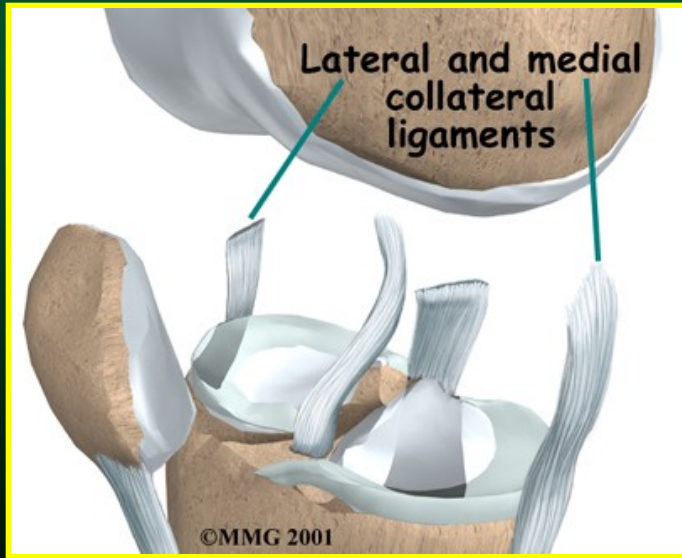
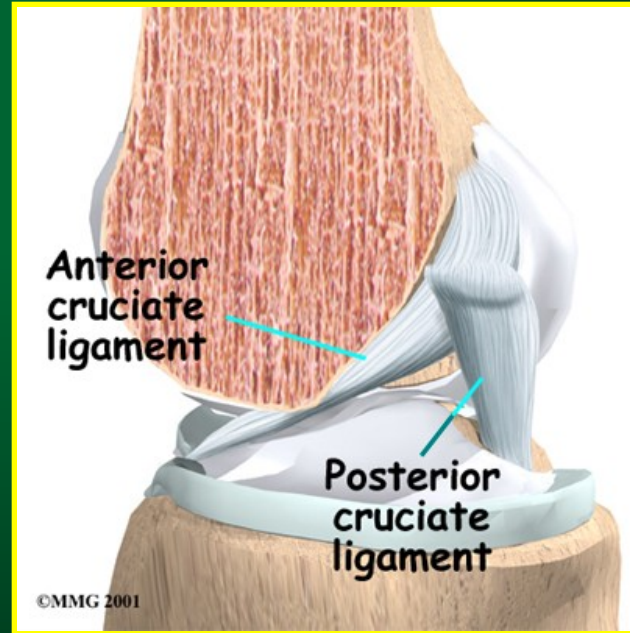
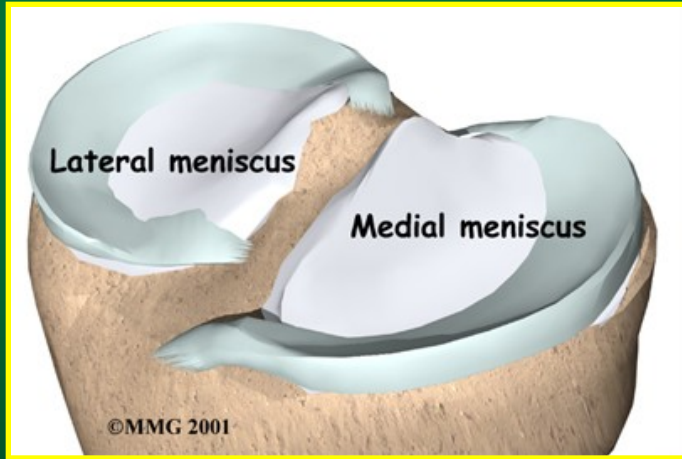


Aseptická nekróza MR obraz

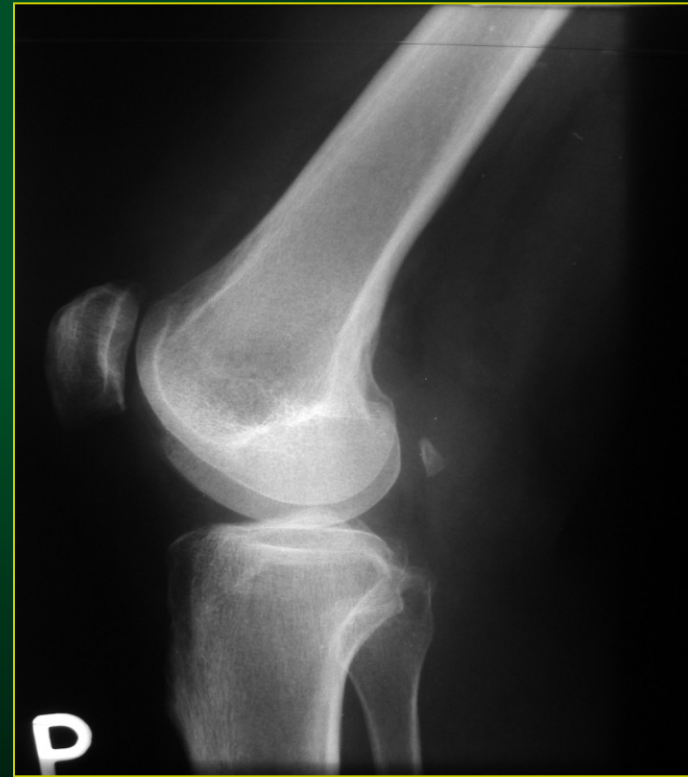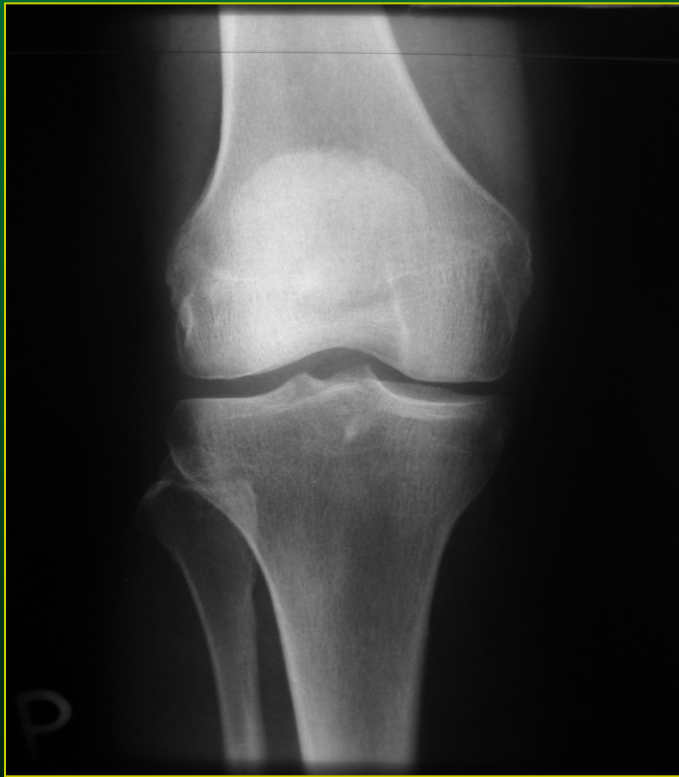


KOLENO

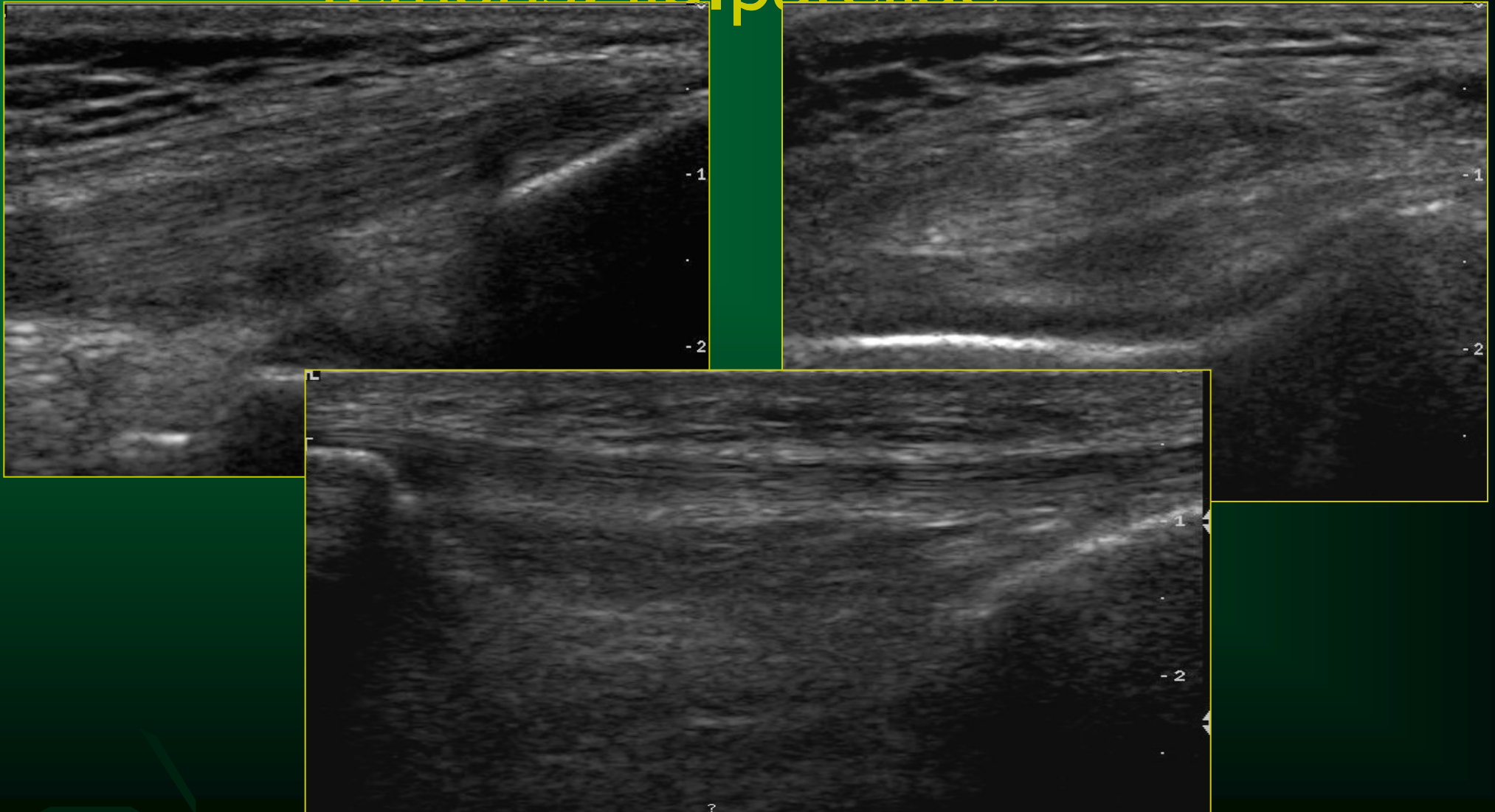
Anatomie kolene



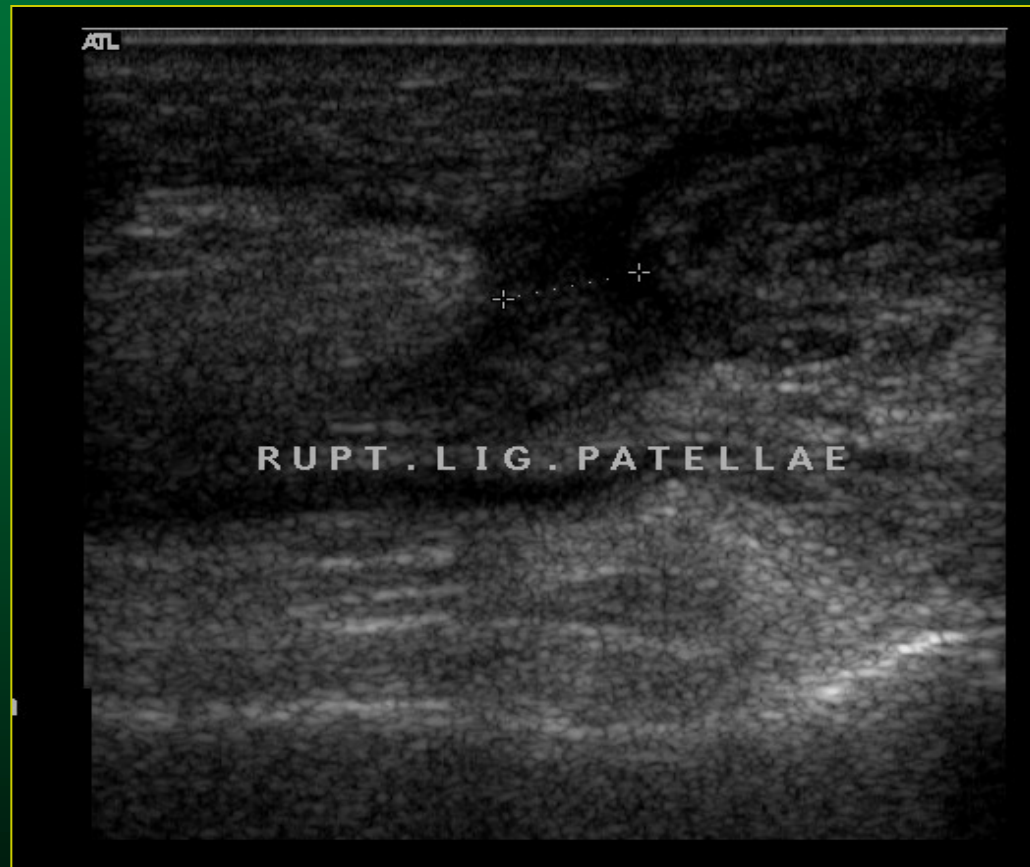RTG snímek – AP a bočná pr.



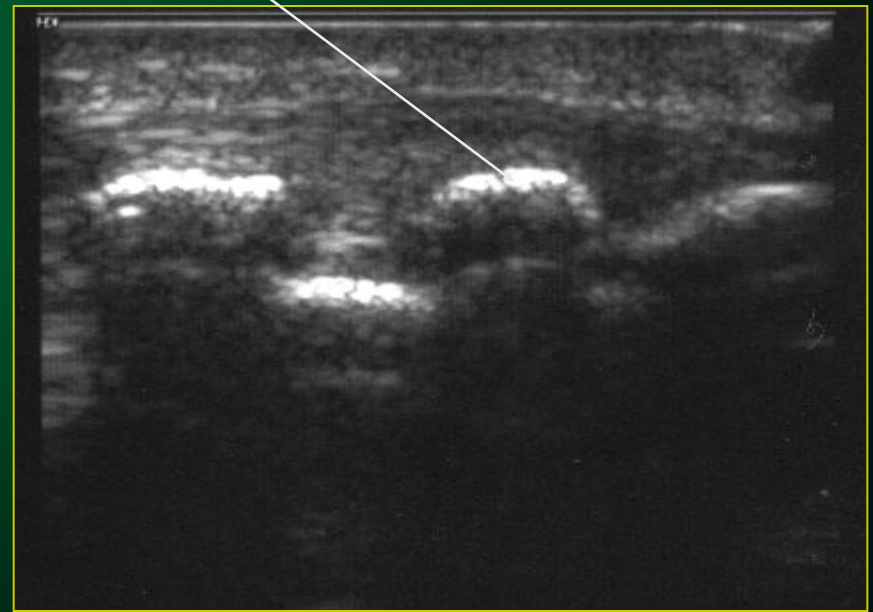
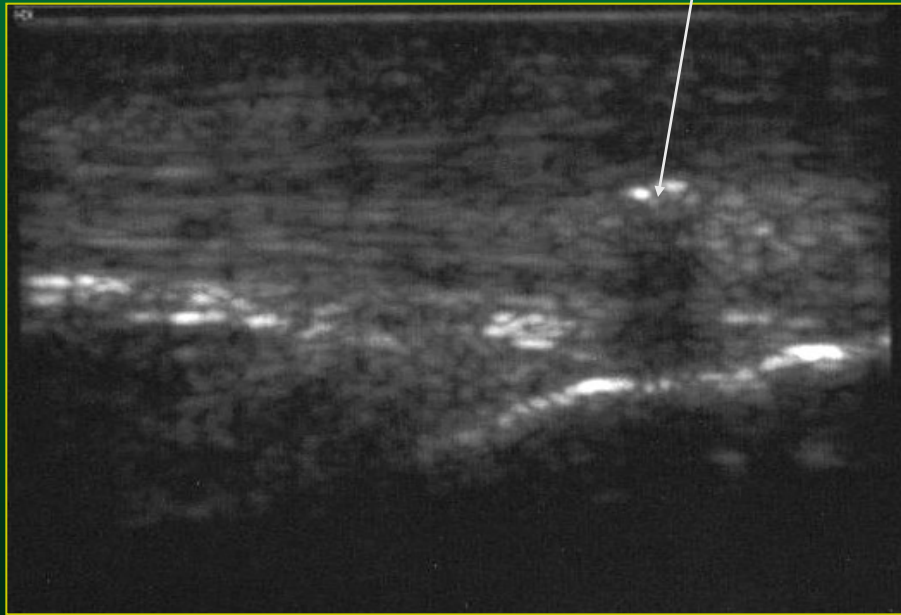Úponová šlacha m.quadriceps femoris, lig.patellae



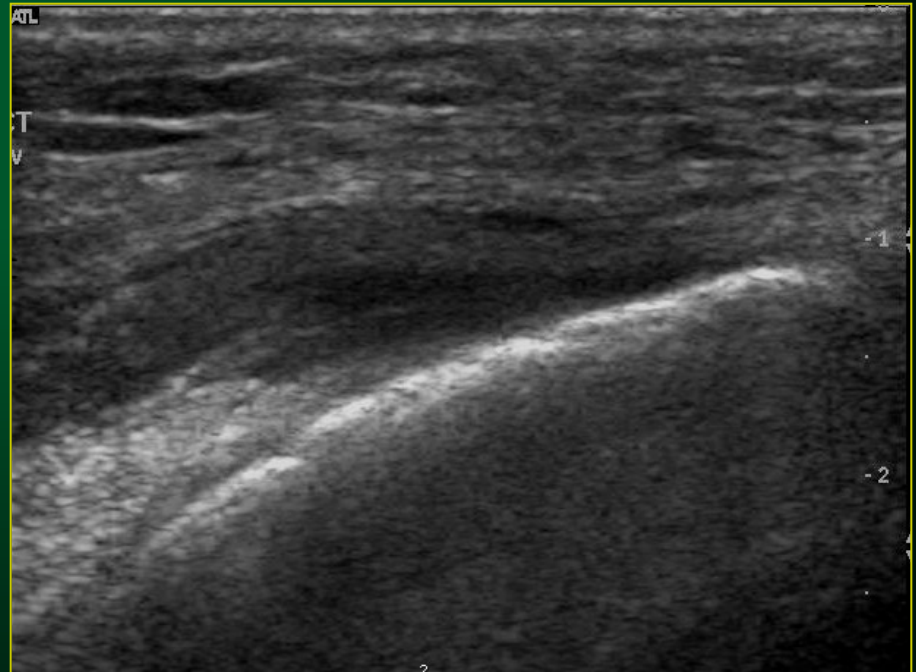
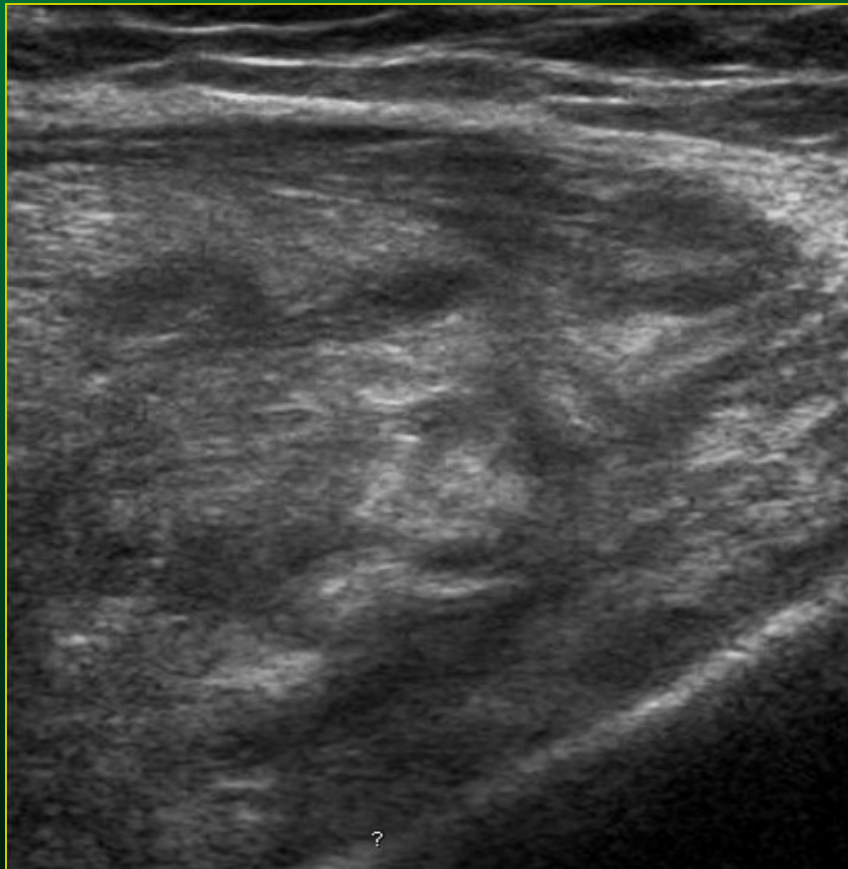
Ruptura lig. patellae – UZ obraz



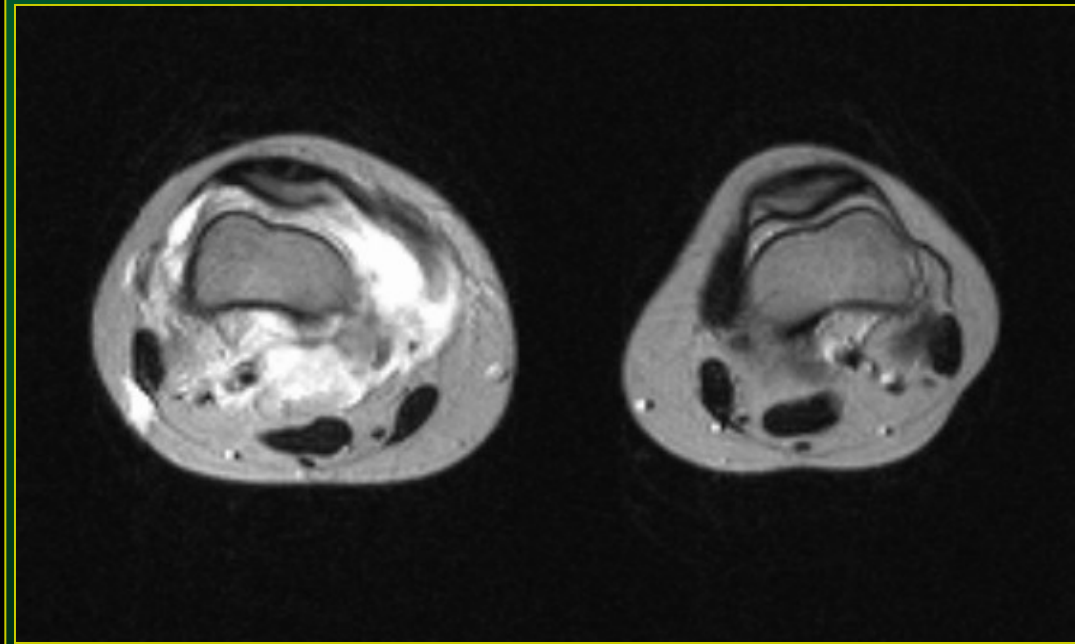
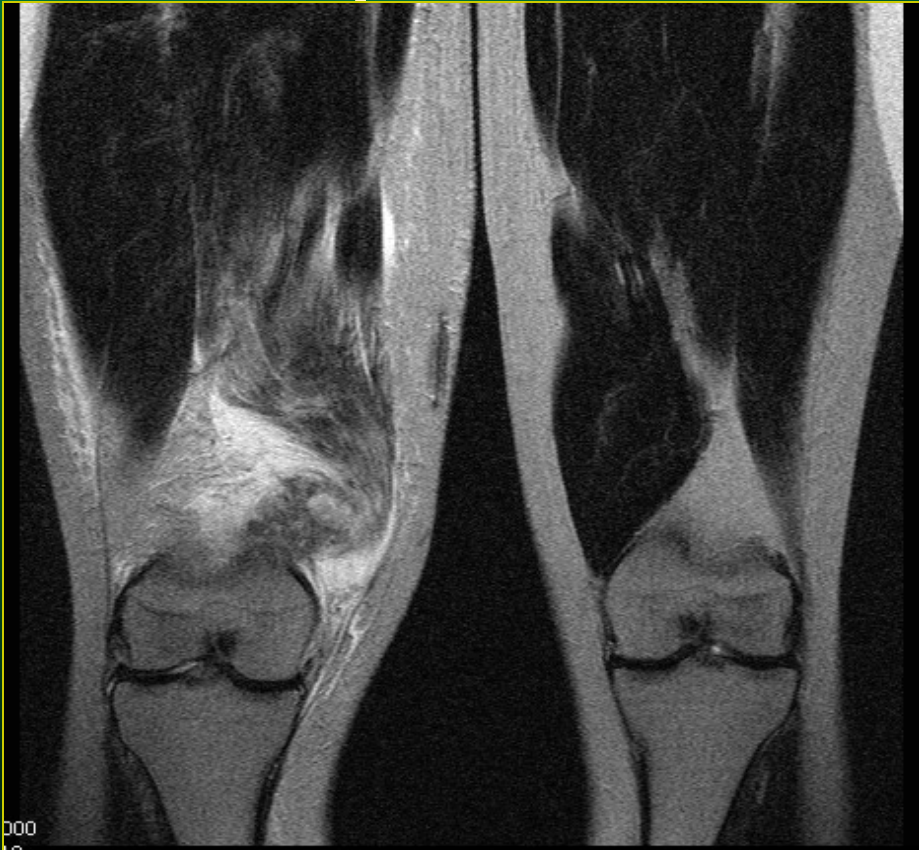Kalcifikace lig. patellae - UZ obraz



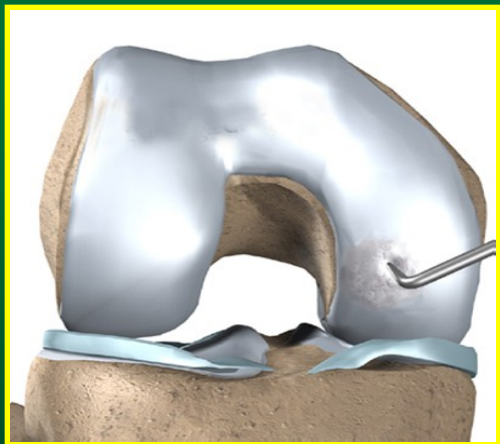
Svalová ruptura UZ obraz



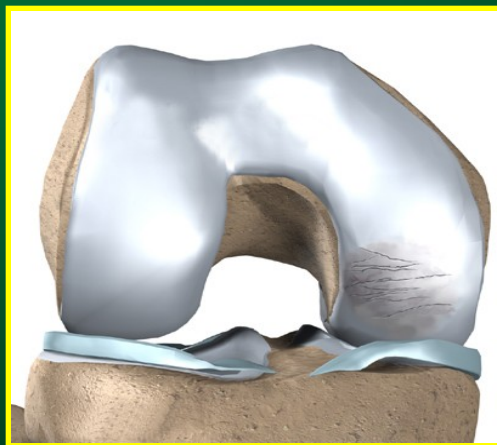
Svalová ruptura MR obraz, prokrvácení, T2 v.o.



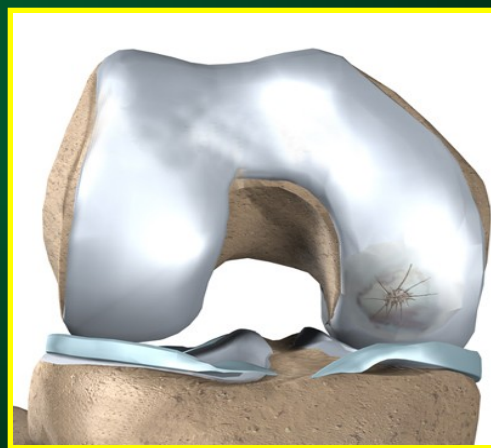
Postižení chrupavky= primární postižení při artróze



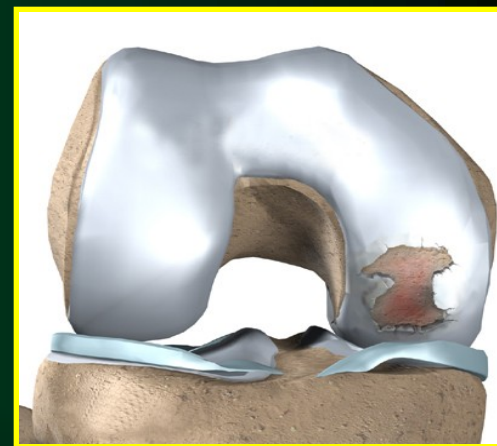
I. stupeň



II. stupeň

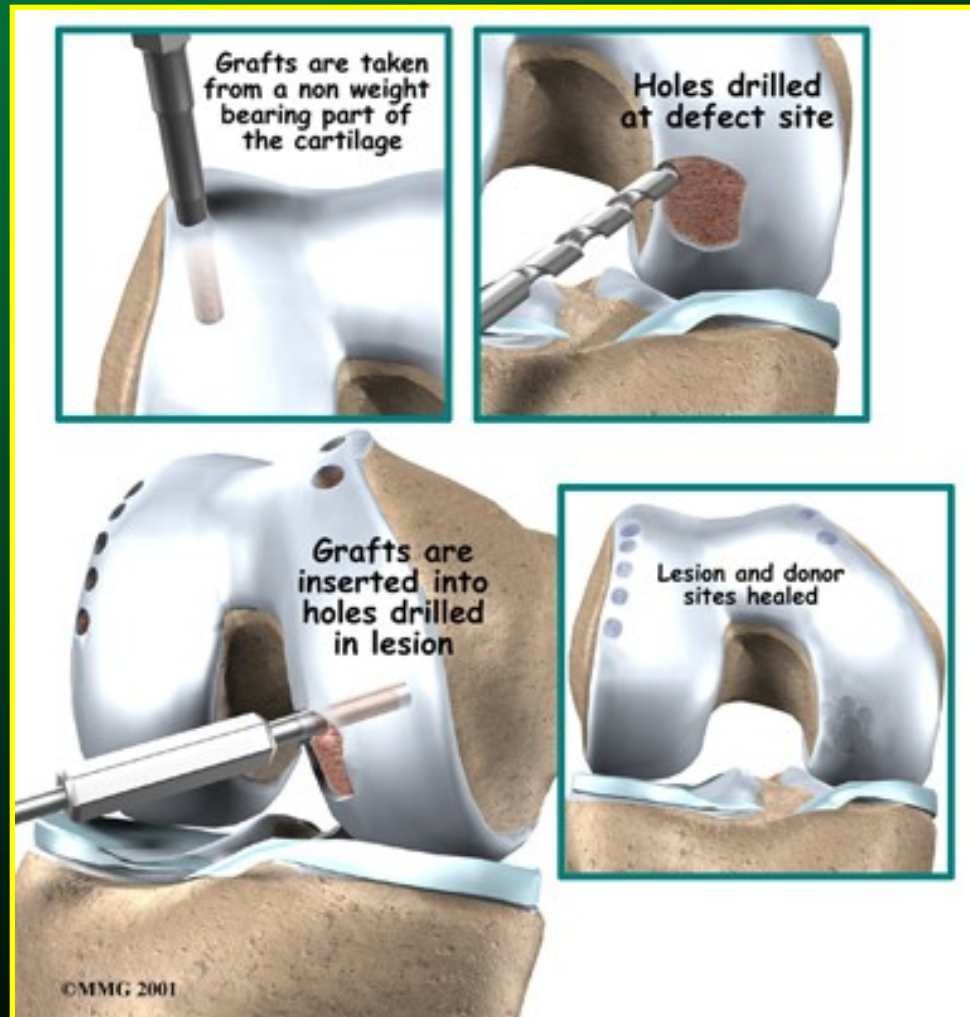


III. stupeň

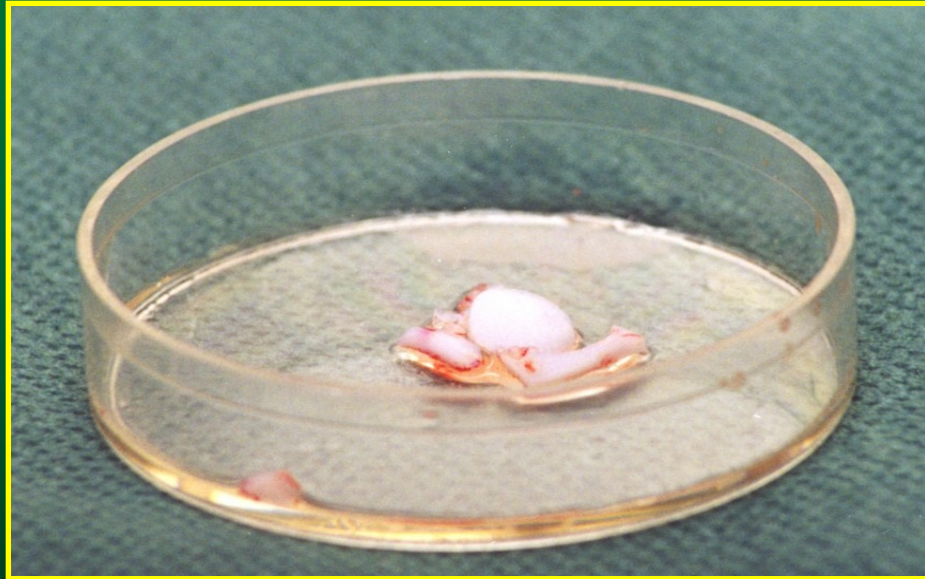


IV. stupeň

Léčba chrupavčitých lézí osteochondrografty



Postup kultivace chondrocytů




odebraná chrupavka

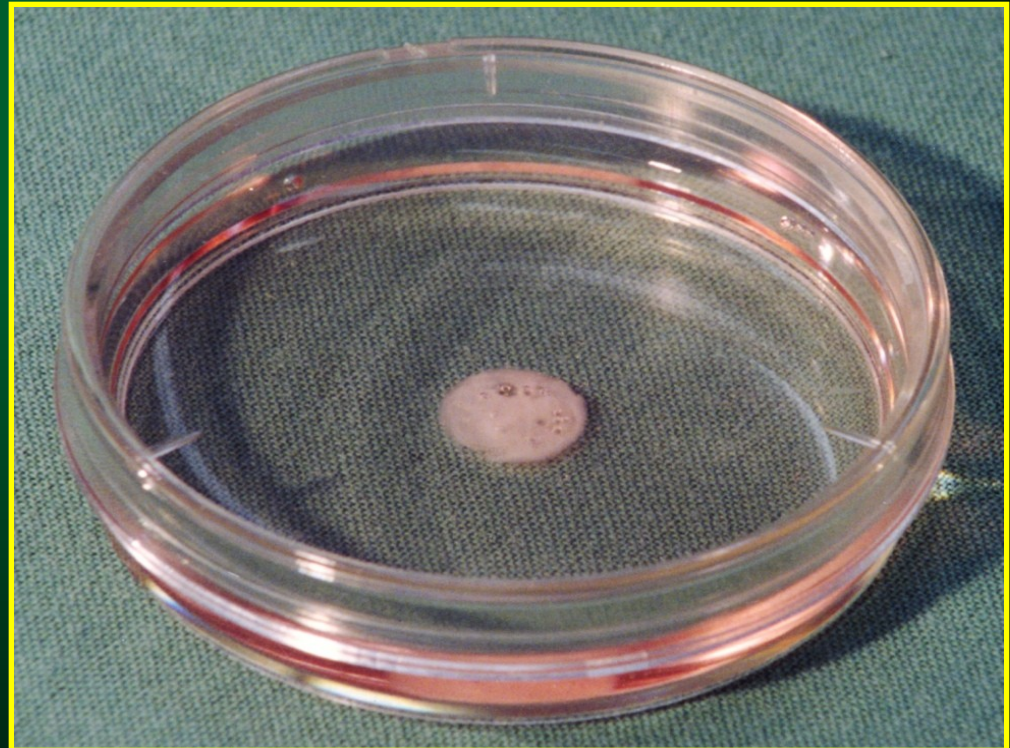


fragmentace materiálu

Postup kultivace chondrocytů




odstředěné buňky

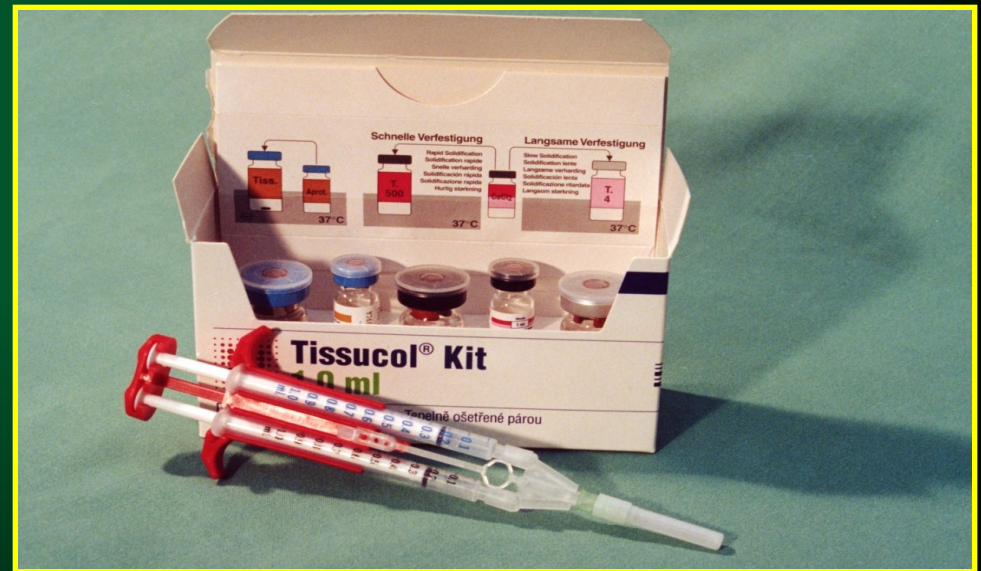

kultivace chondrocytů

Postup kultivace chondrocytů



odlitek implantátu



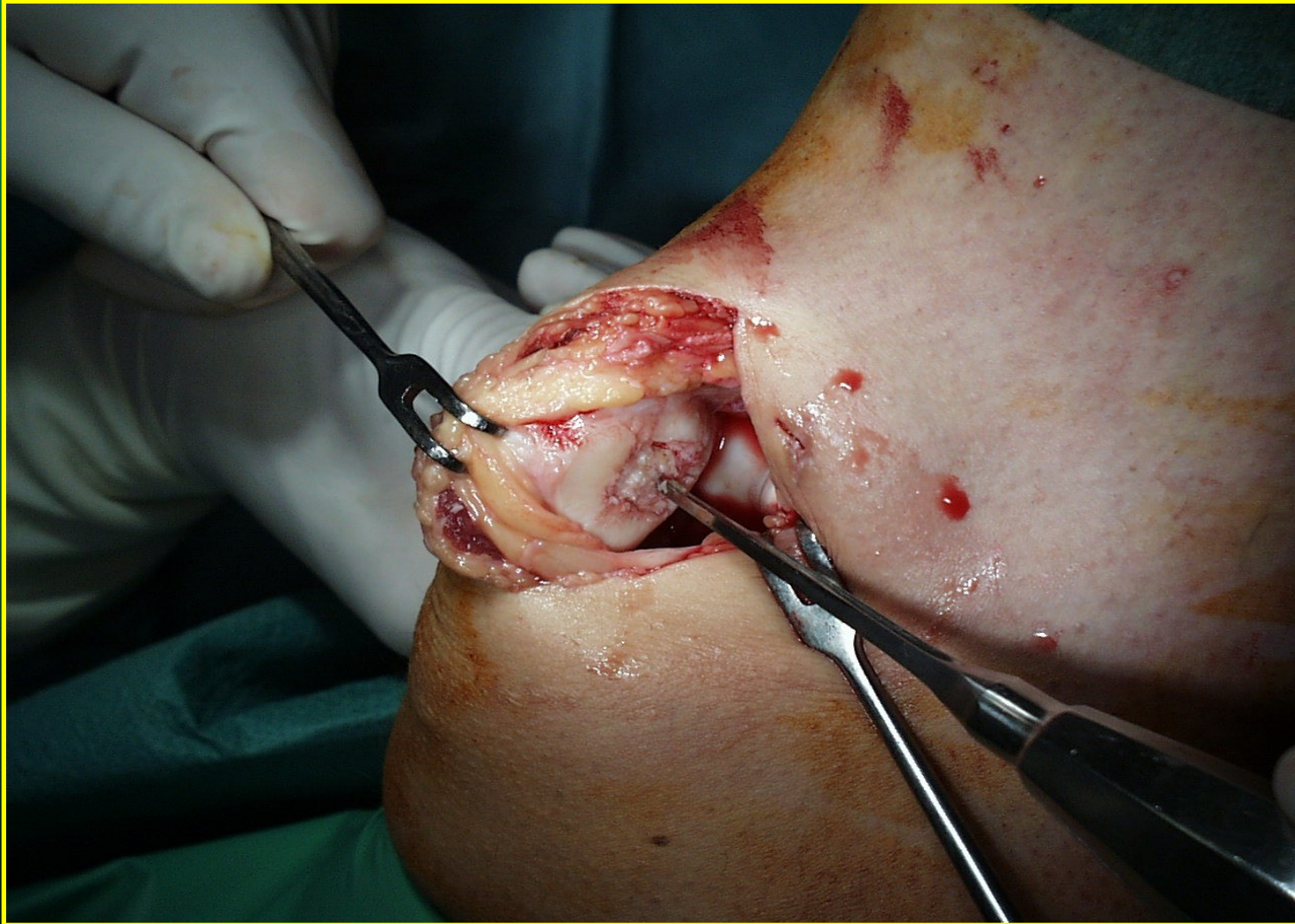
tkáňové lepidlo Tissucol

Postup kultivace chondrocytů

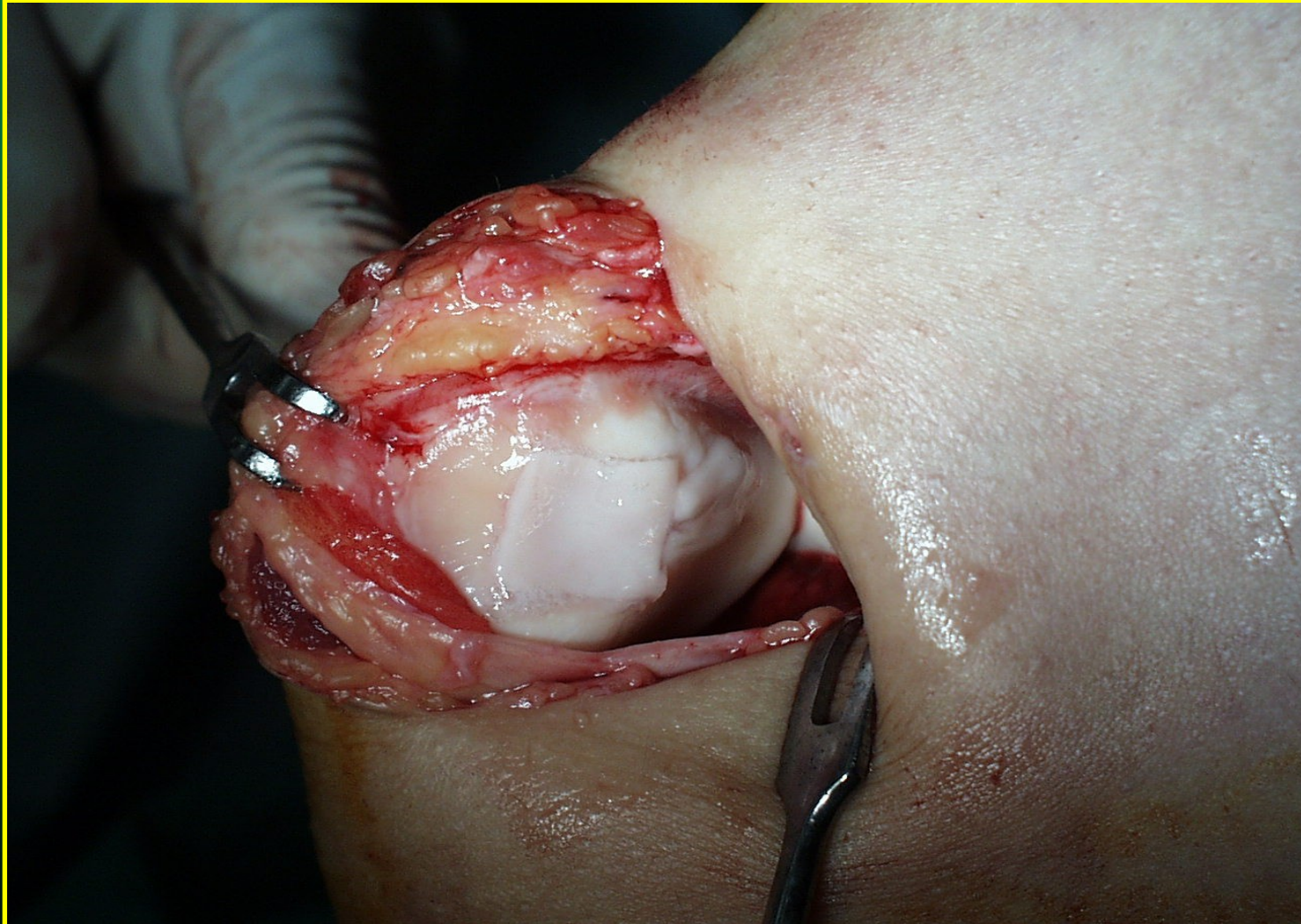

definitivní podoba transplantátu

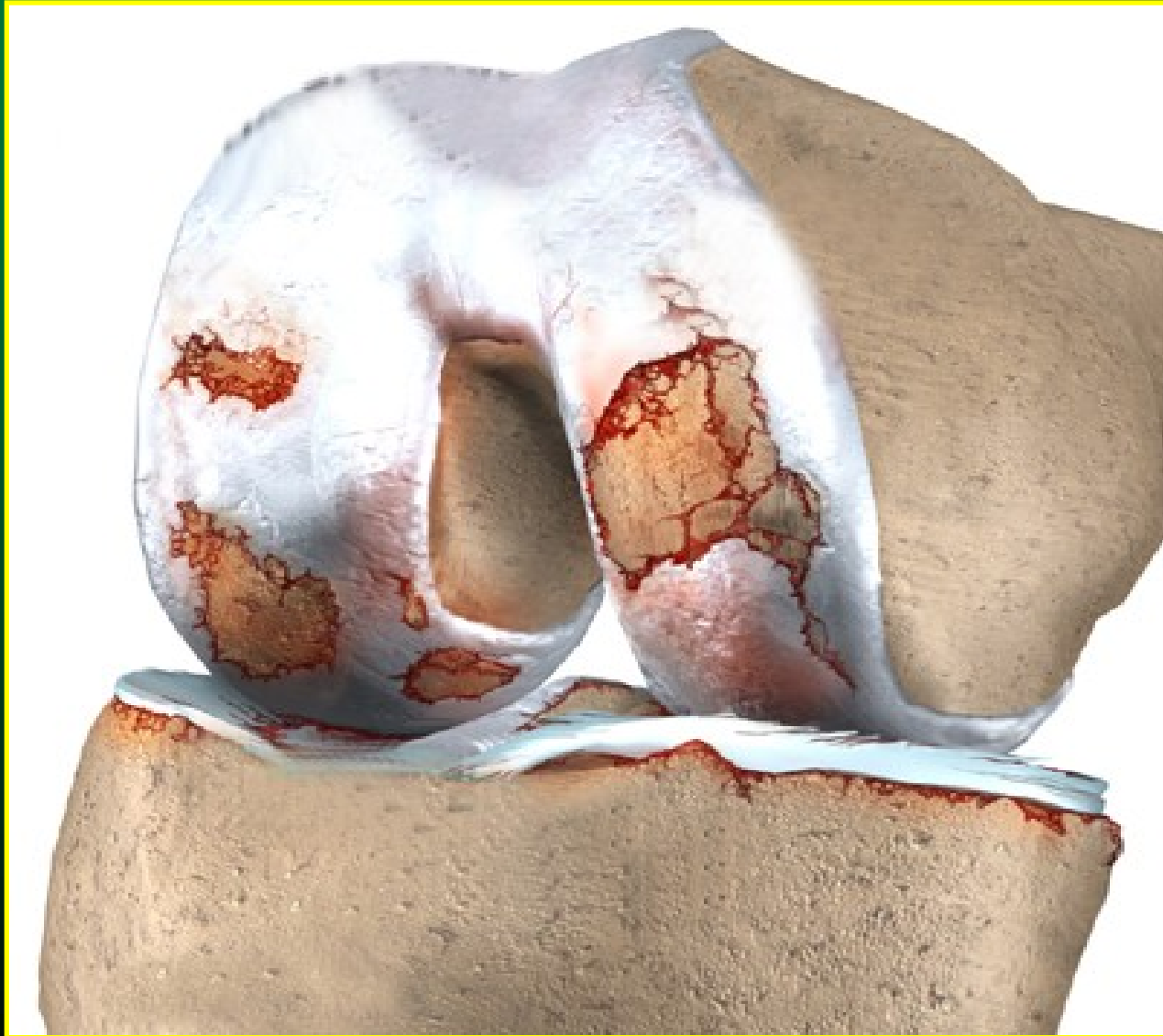Defekt chrupavky pately - předoperačně



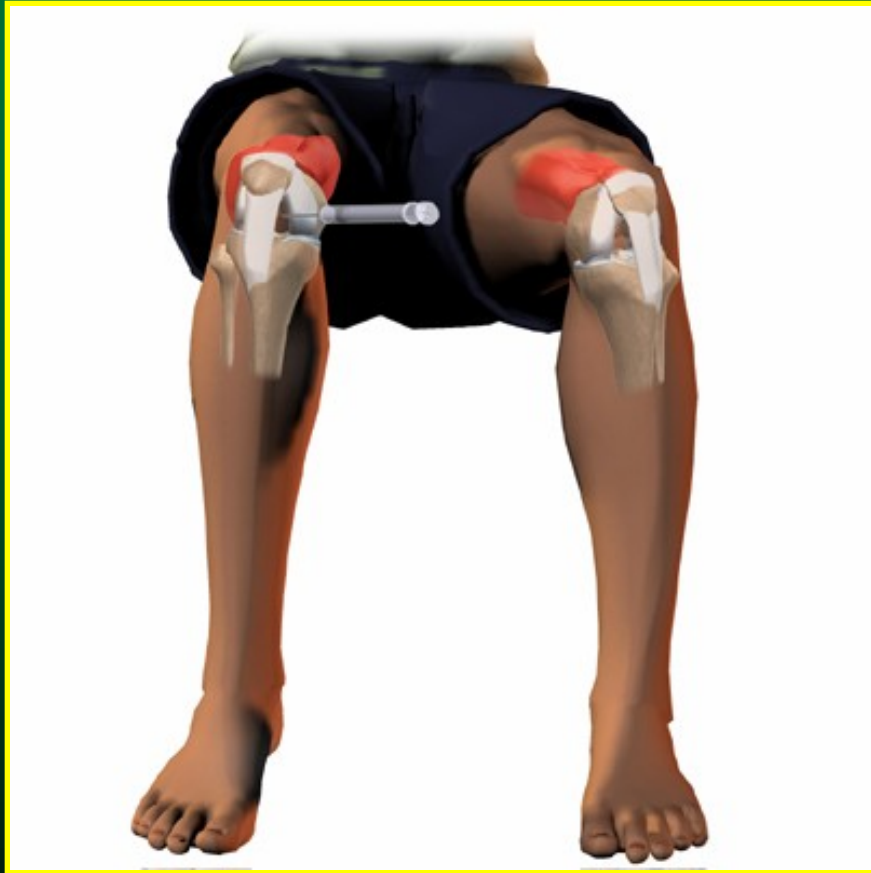Defekt chrupavky pately - pooperačně



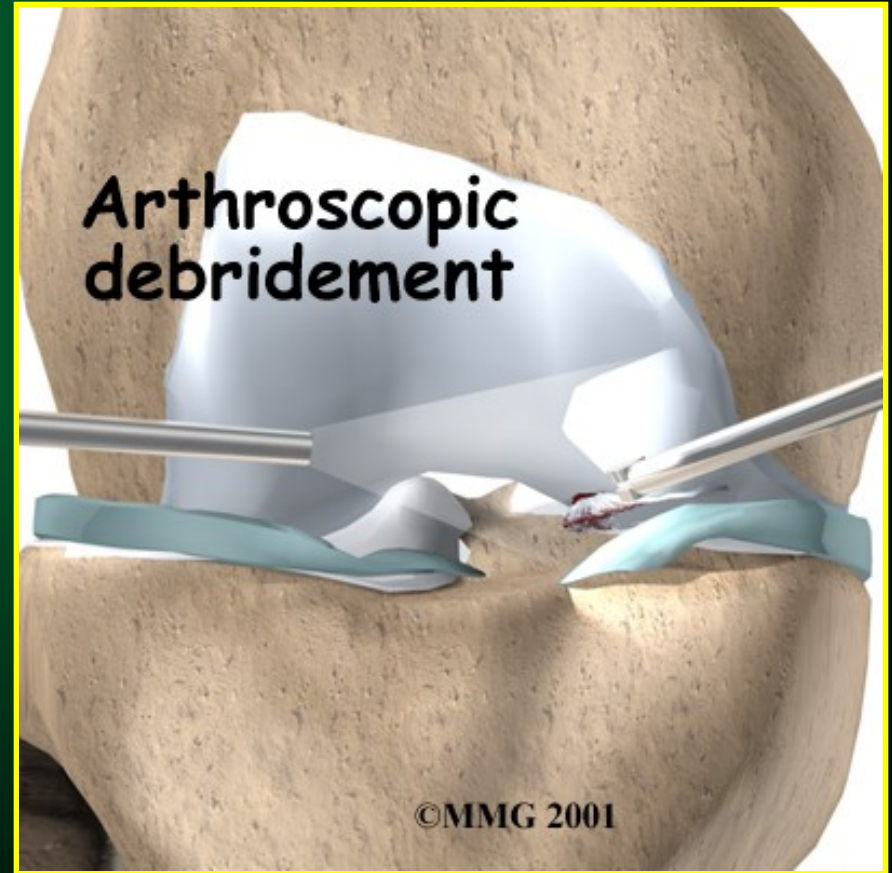Gonarthróza



Léčba gonartrózy



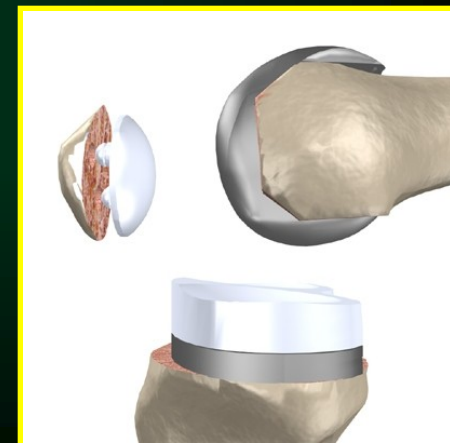

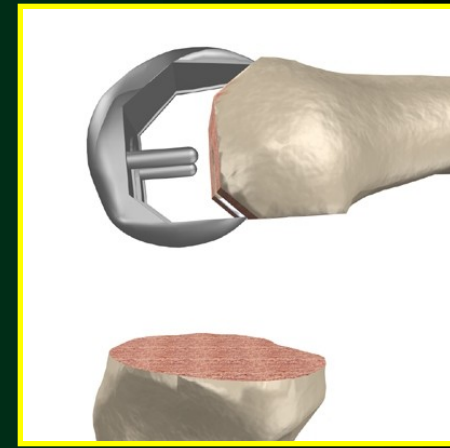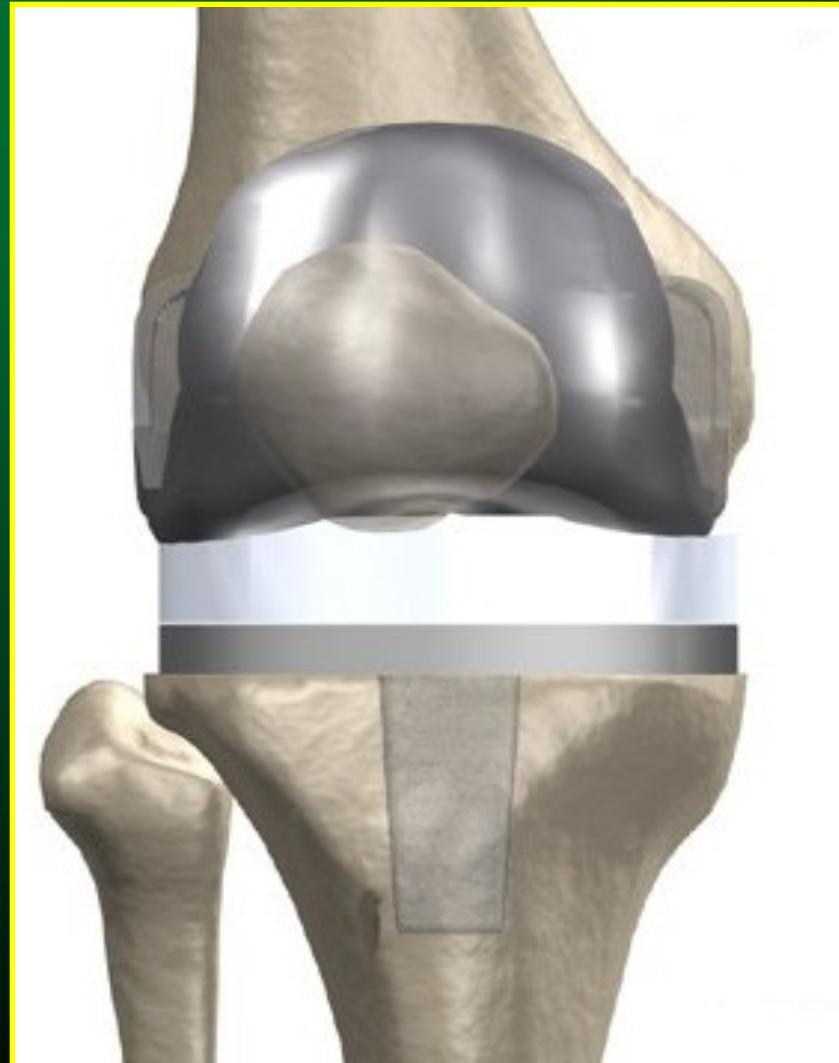
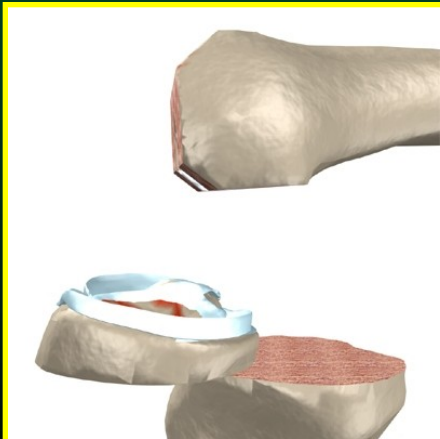
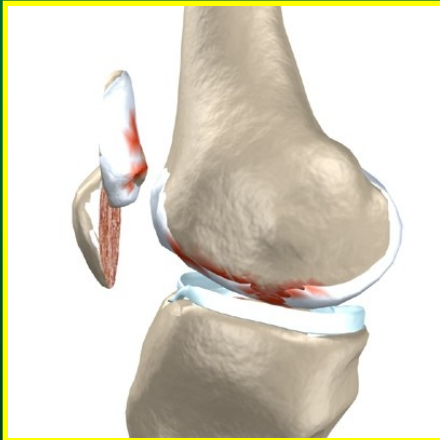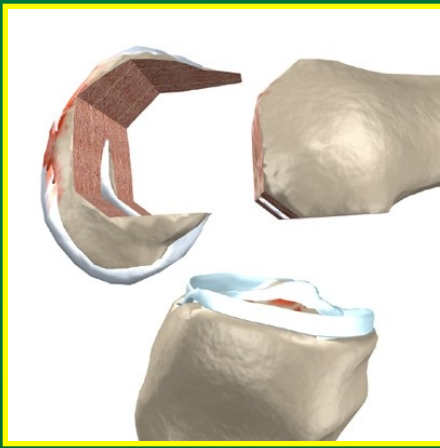
instilace kortikoidů

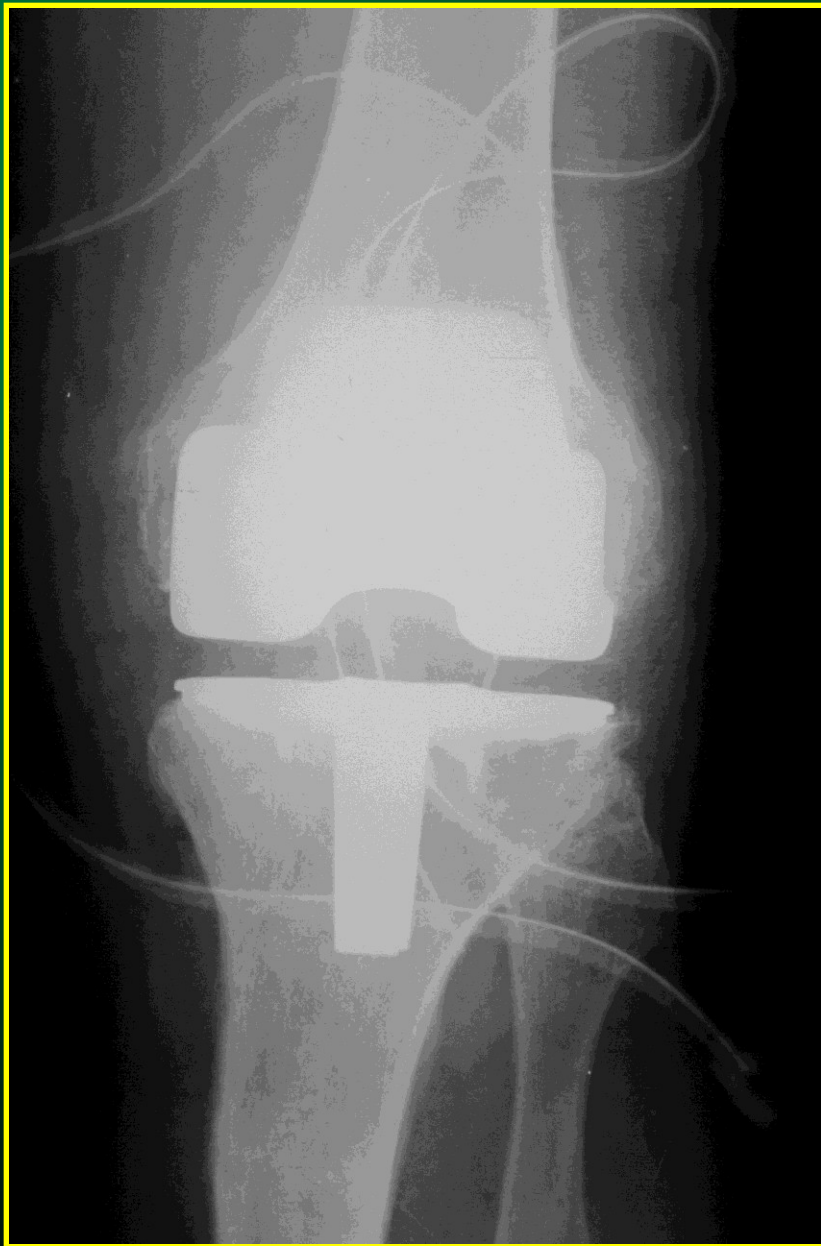

artroskopické debridement

TEP

totální endoprotéza

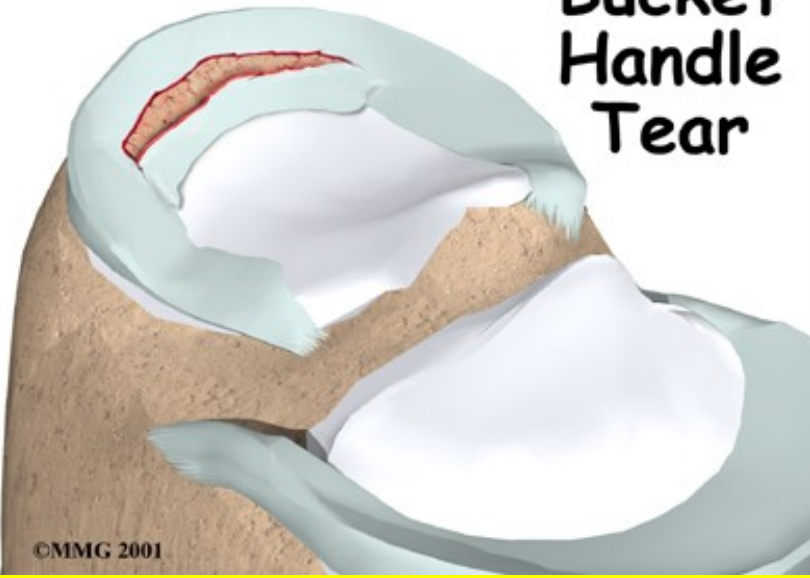



TEP kolene -
RTG snímek
časně po
operaci

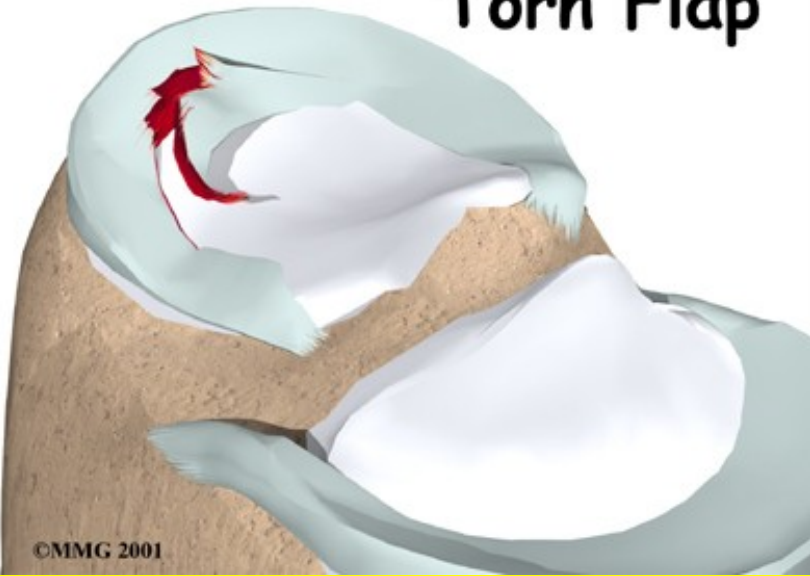
Poranění menisků

Bucket
Handle
Tear



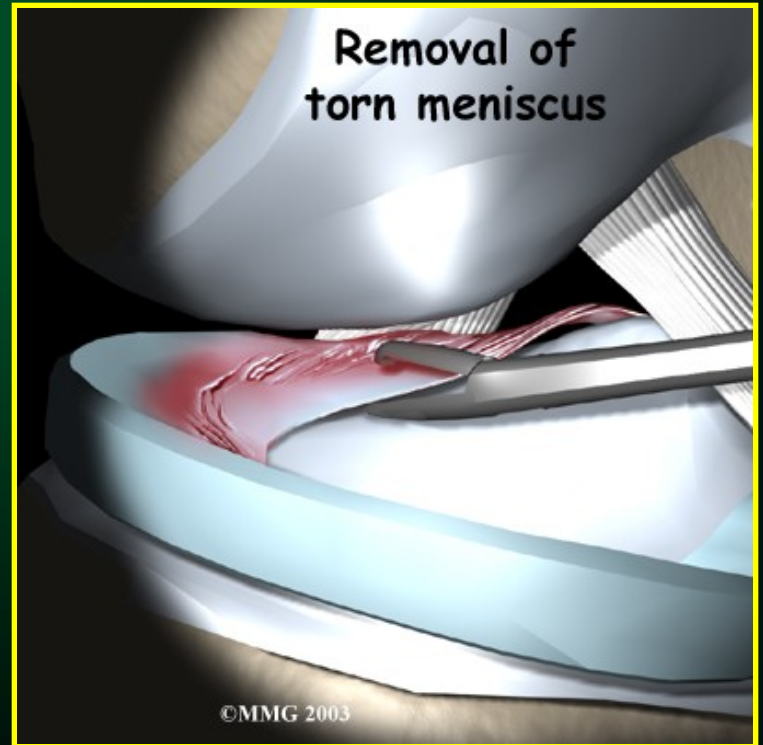
©MMG 2001

Torn Flap



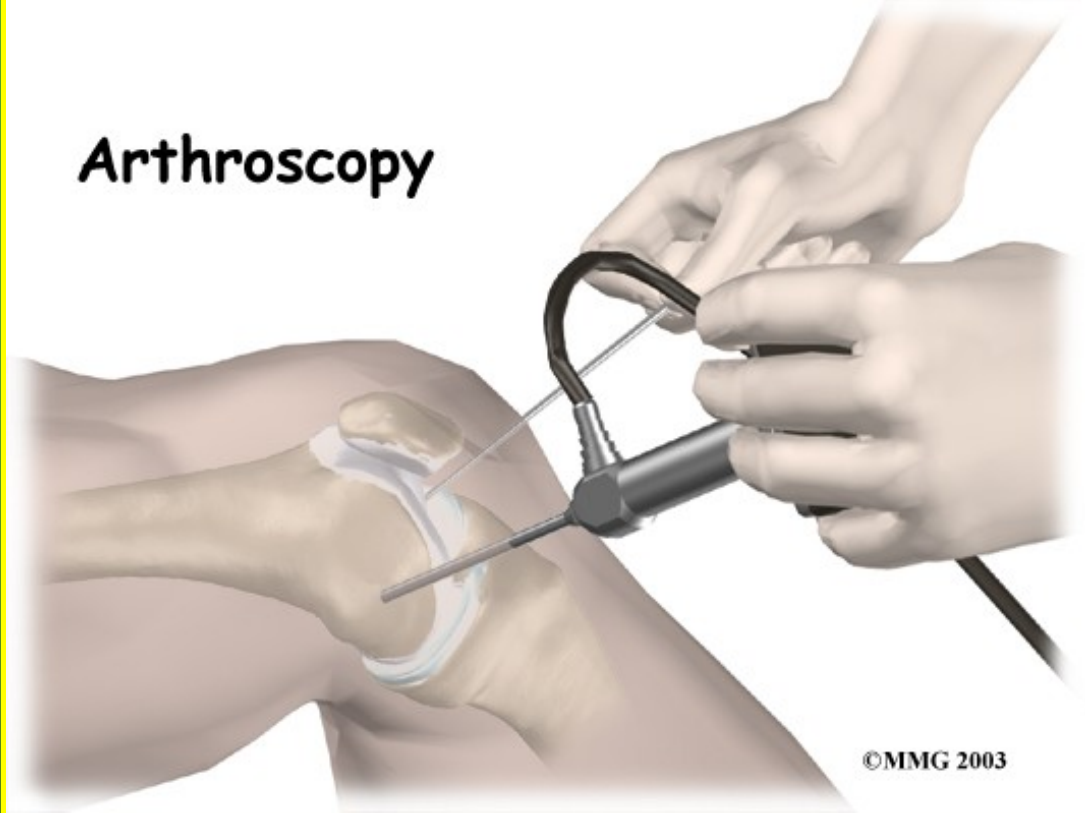
©MMG 2001

Removal of
torn meniscus



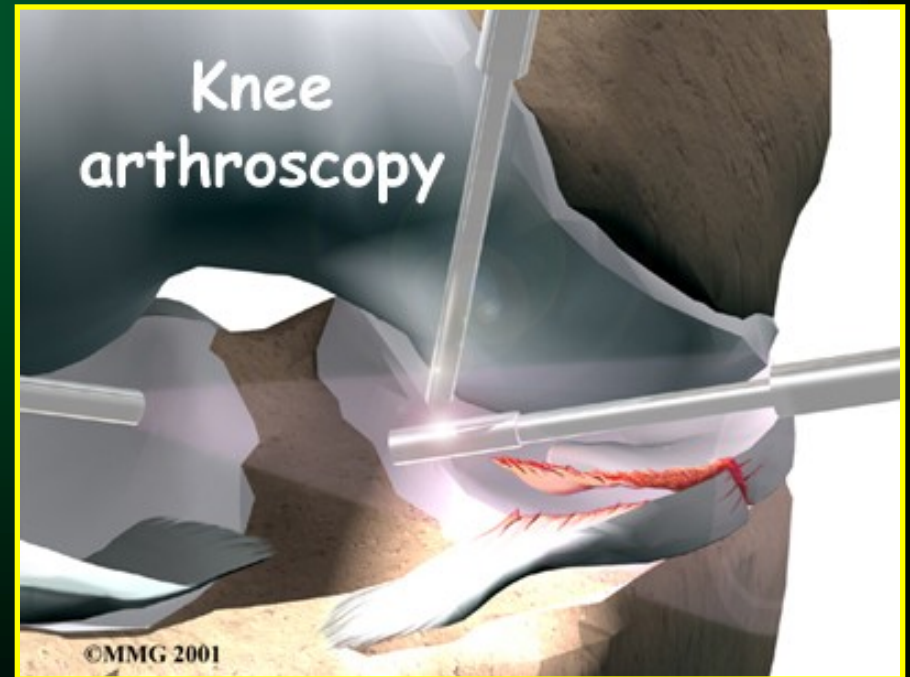©MMG 2003

Arthroscopy



©MMG 2003

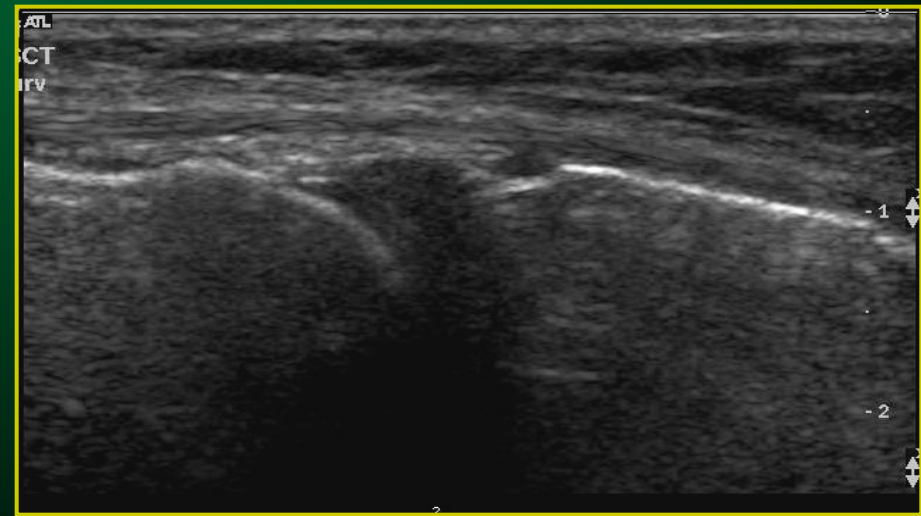
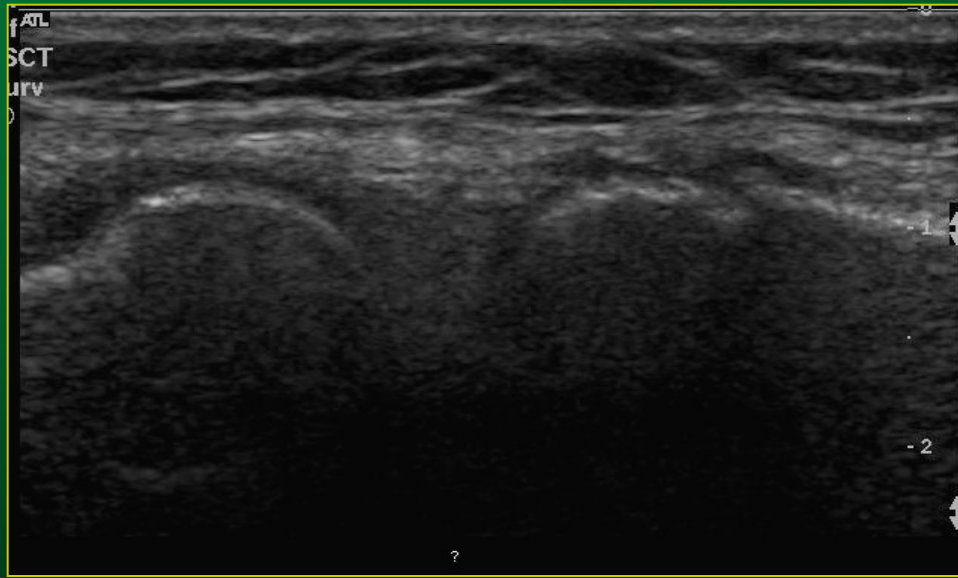
Artrioskopie



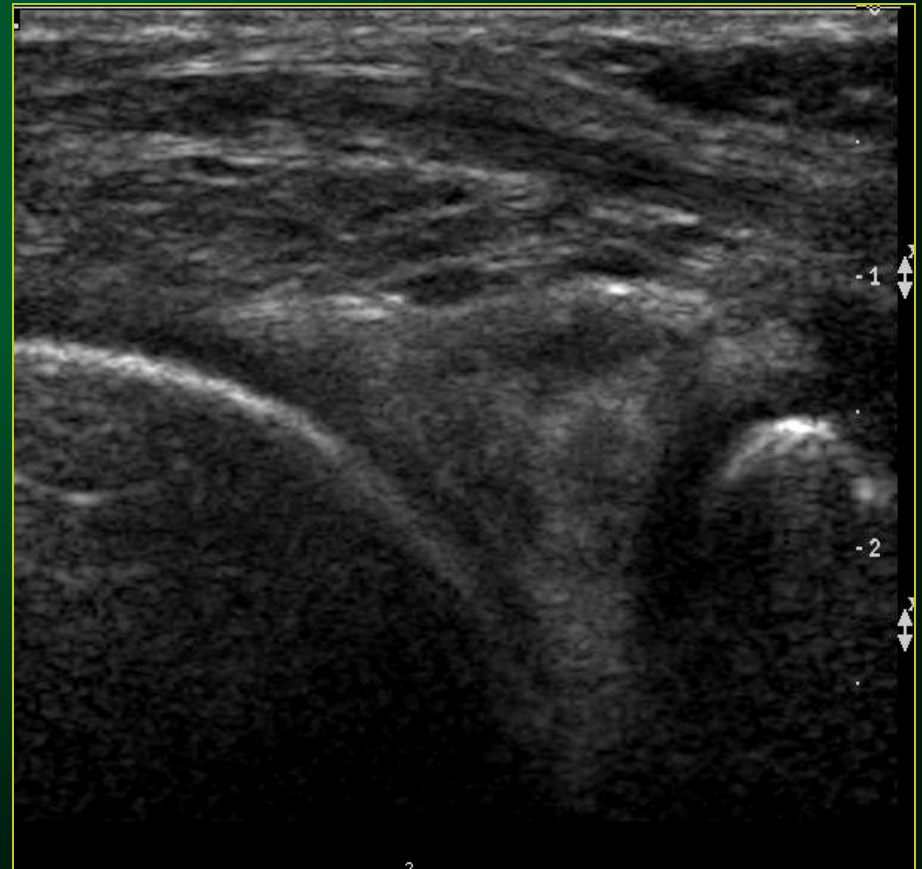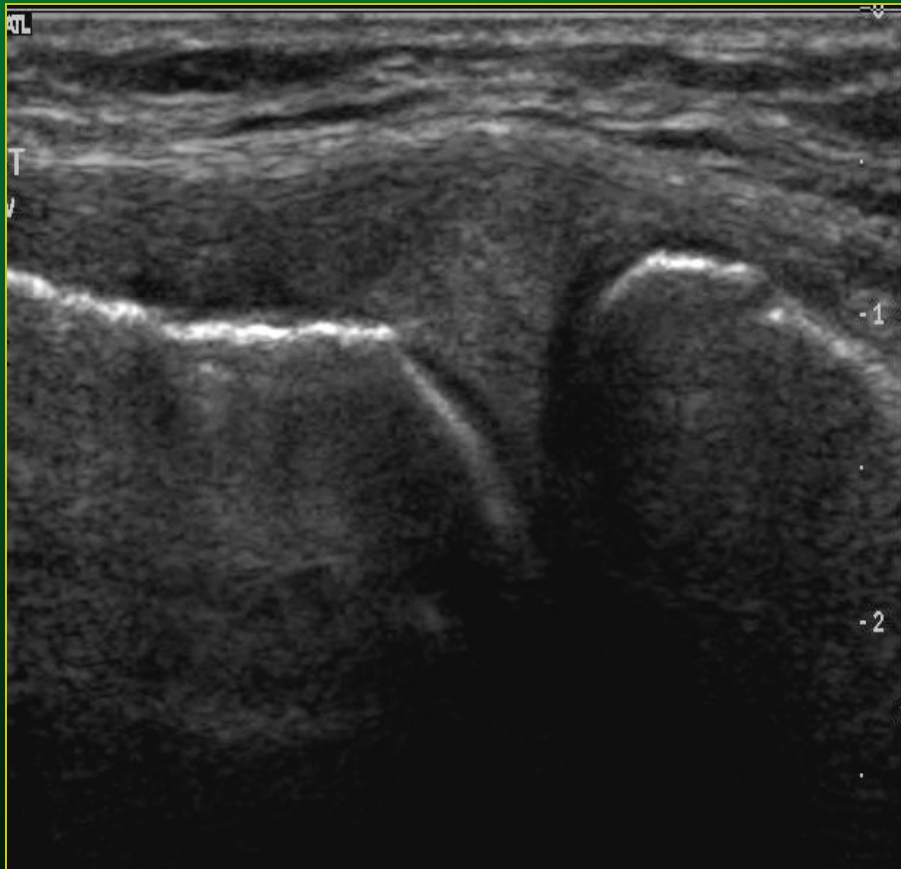Knee arthroscopy

©MMG 2001

Meniskus – UZ obraz

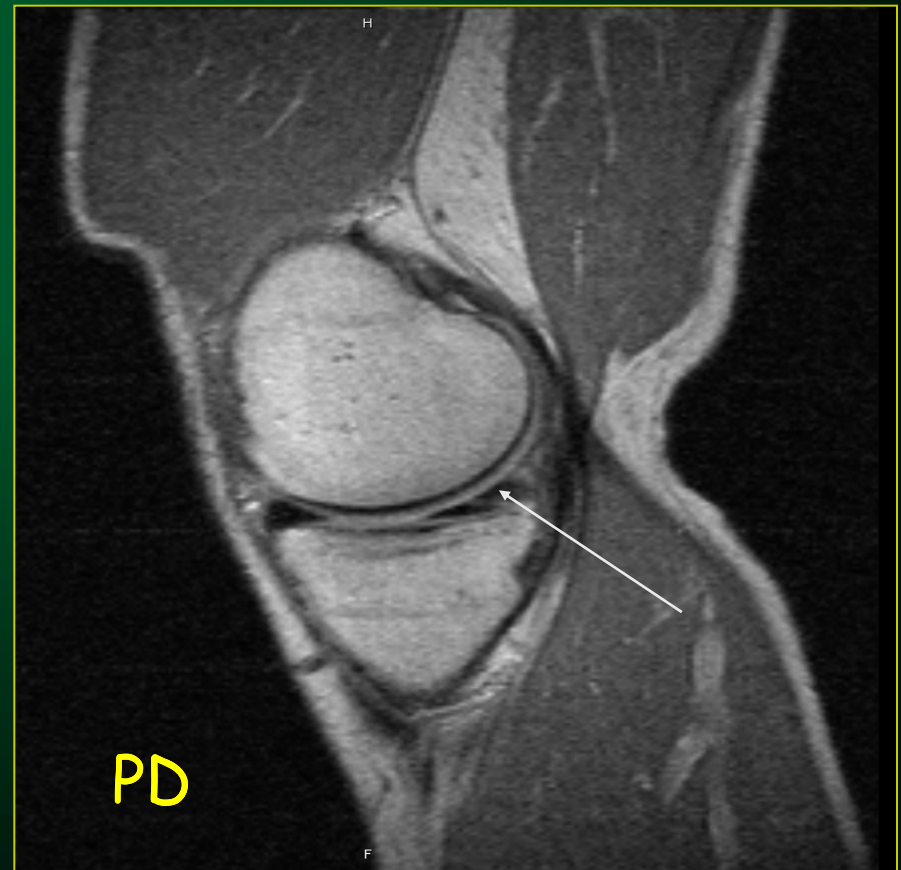
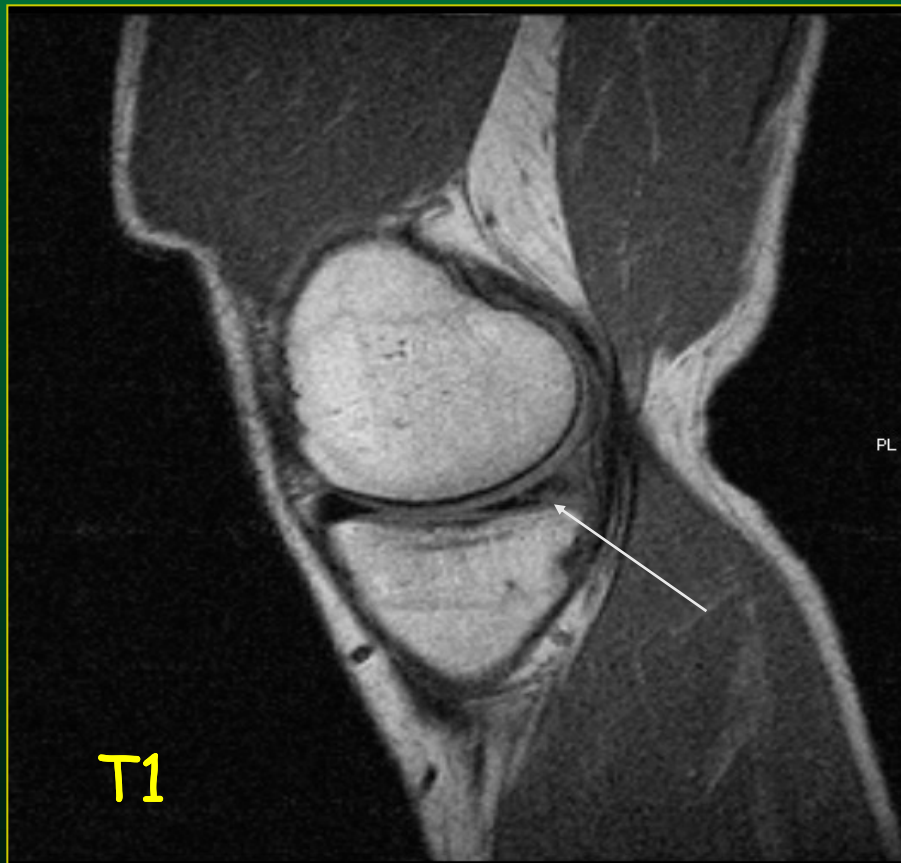


Ruptura menisku UZ obraz

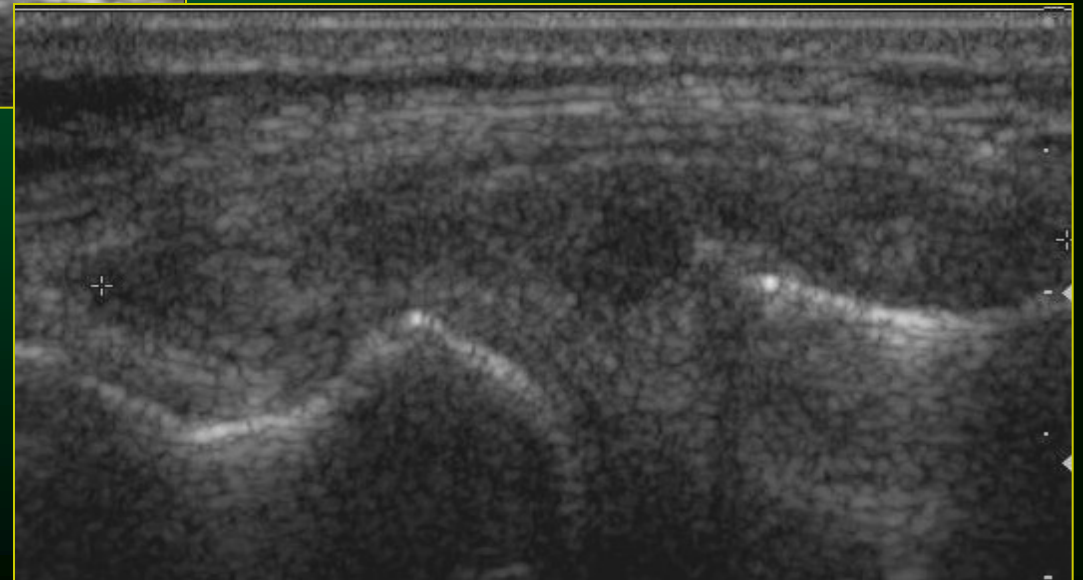
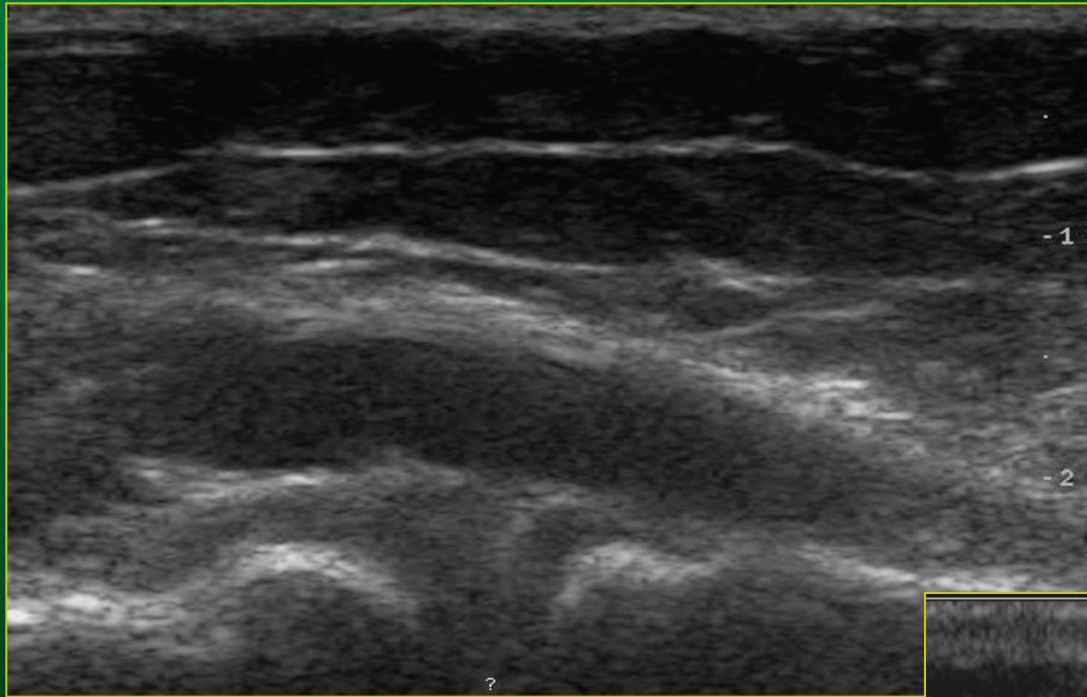


Ruptura mediálného menisku

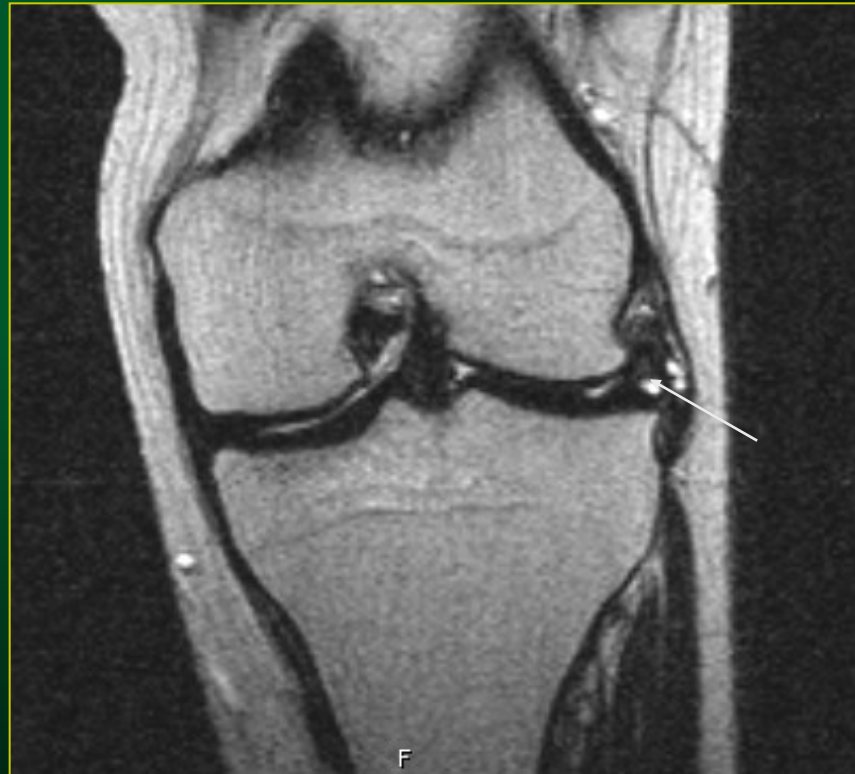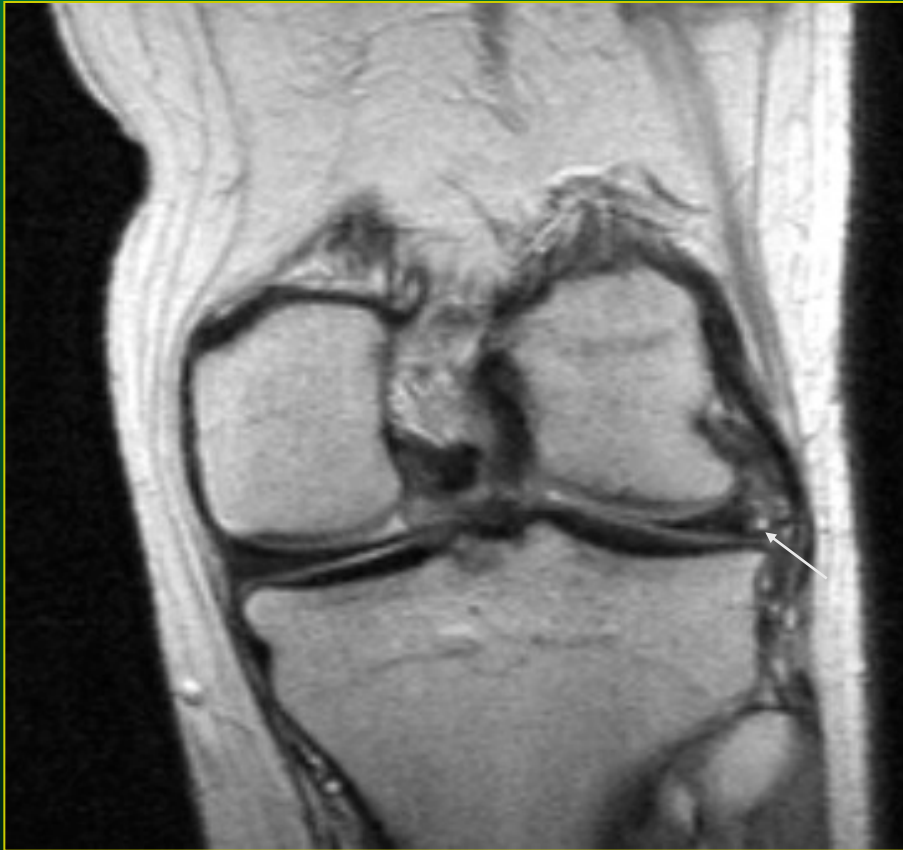MR obraz



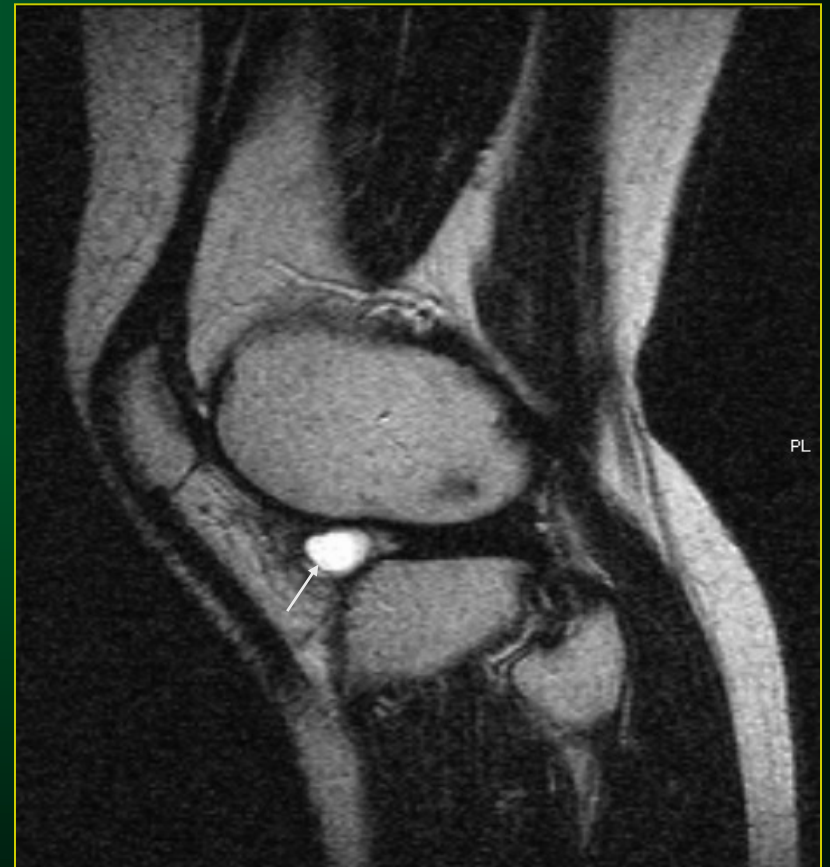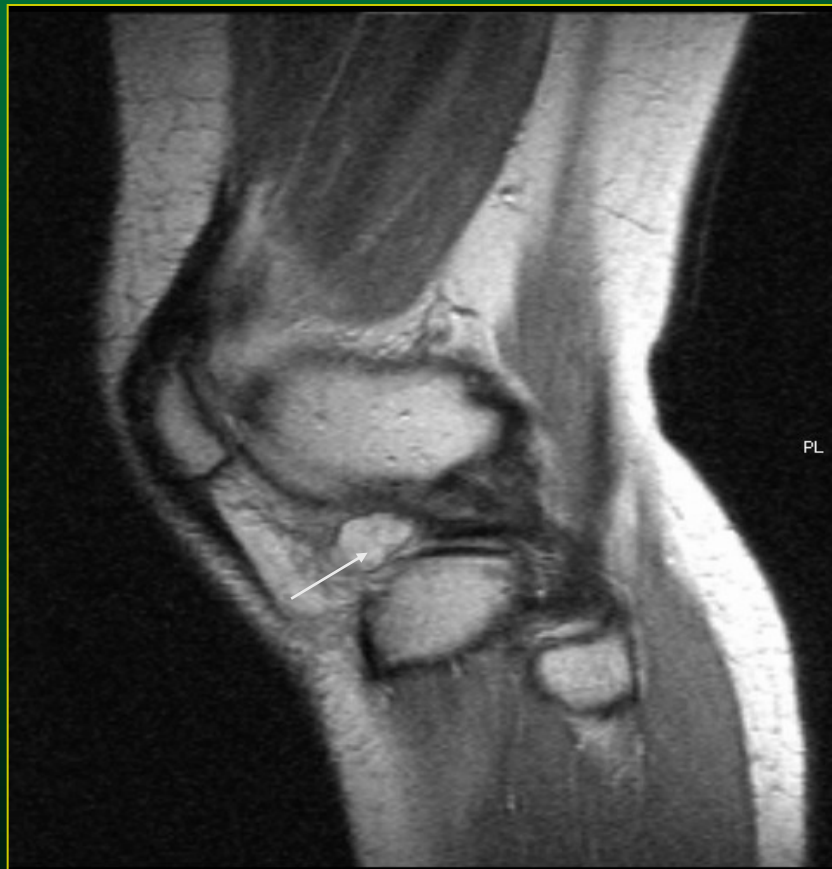Cysta, ganglion –UZ obraz



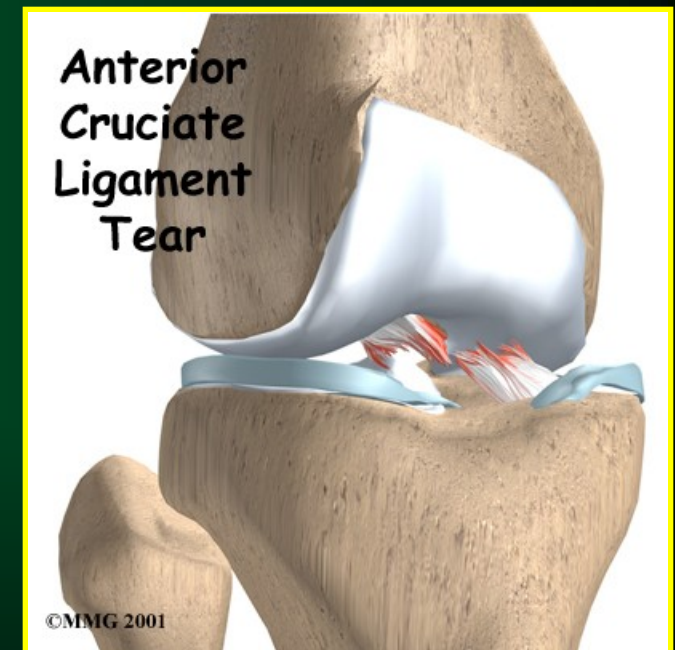
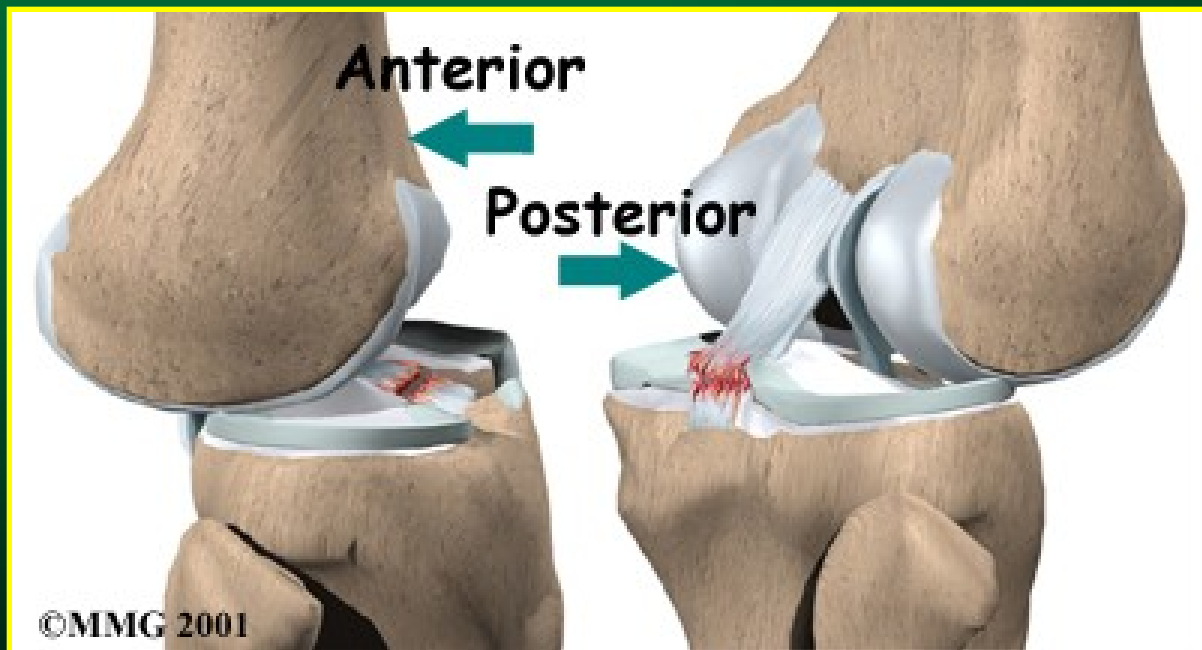
Ganglion laterálního menisku



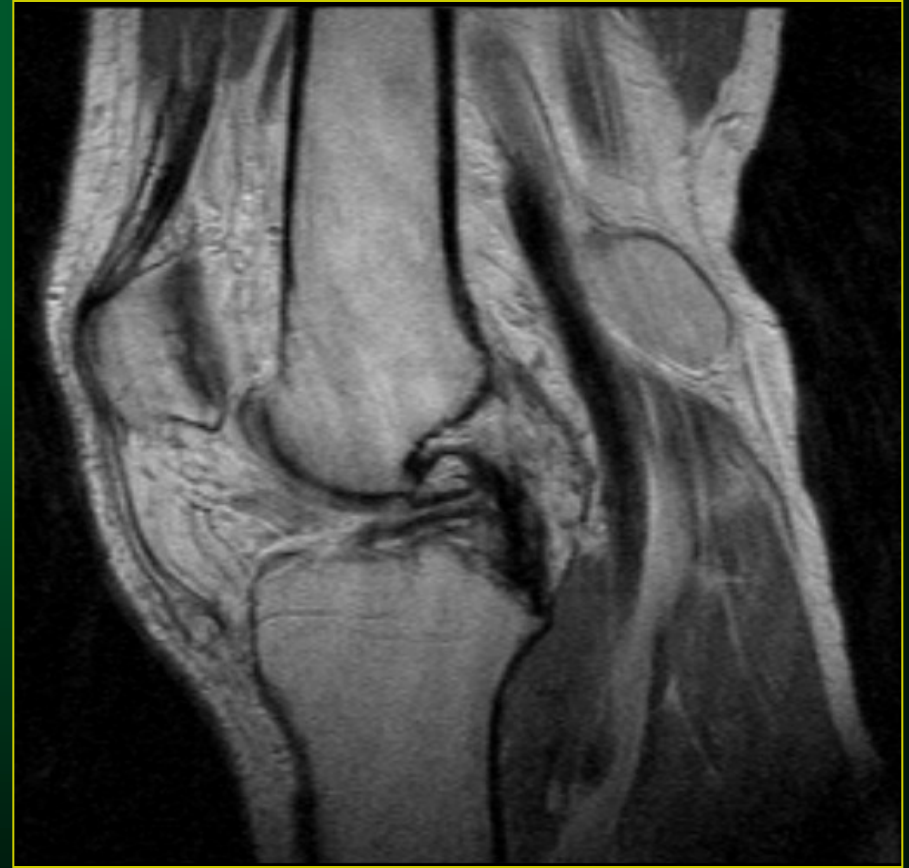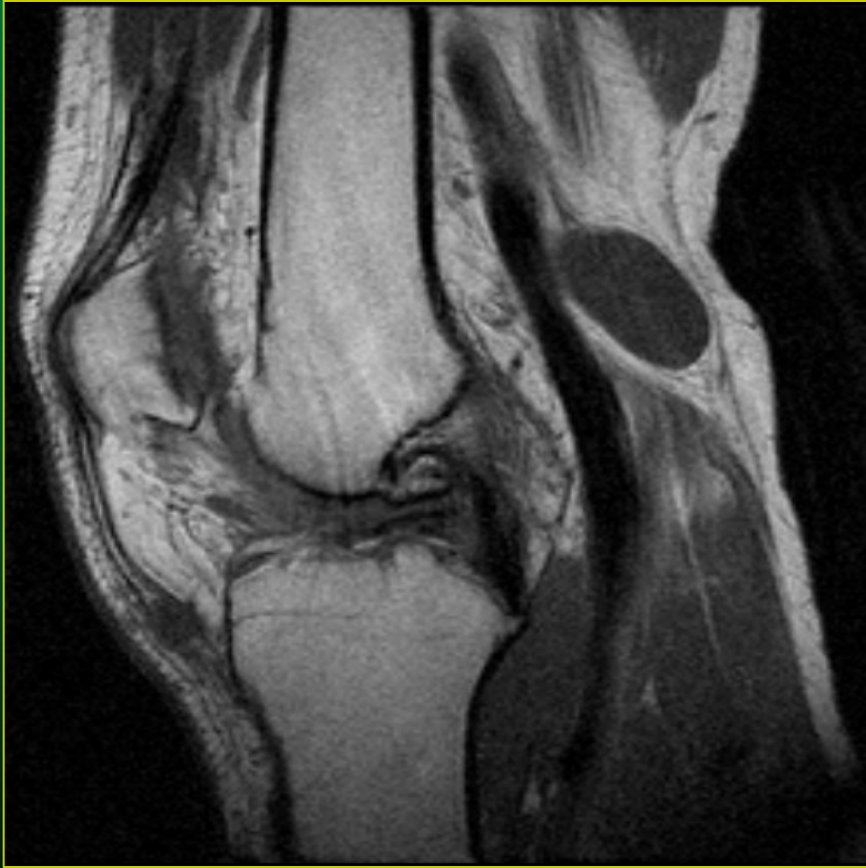Ganglion laterálního menisku



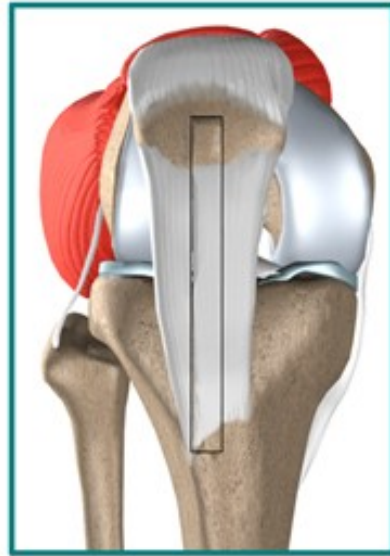
Poranění zkřížených vazů



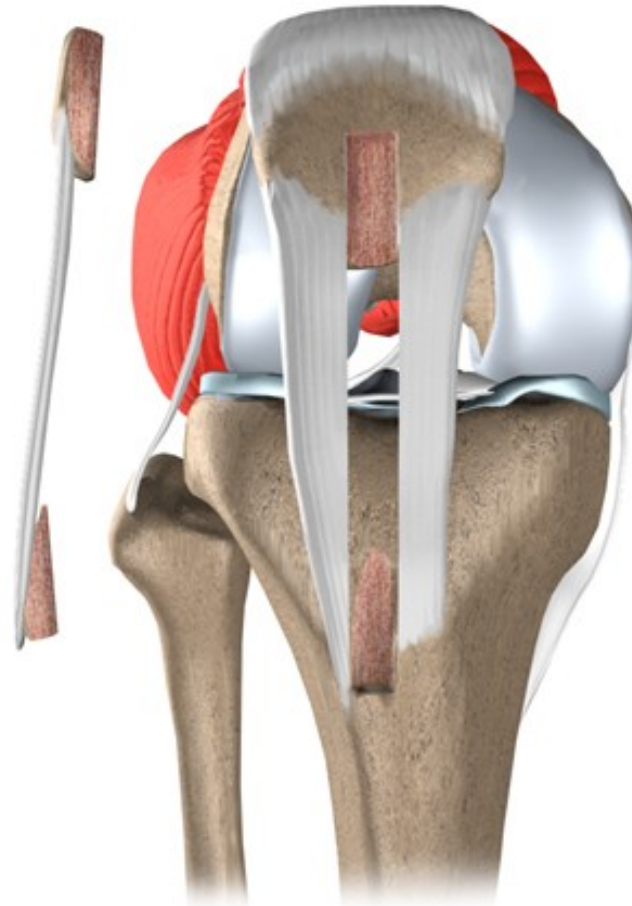
Ruptura LCA



Plastika předního zkříženého vazu dle Brücnera

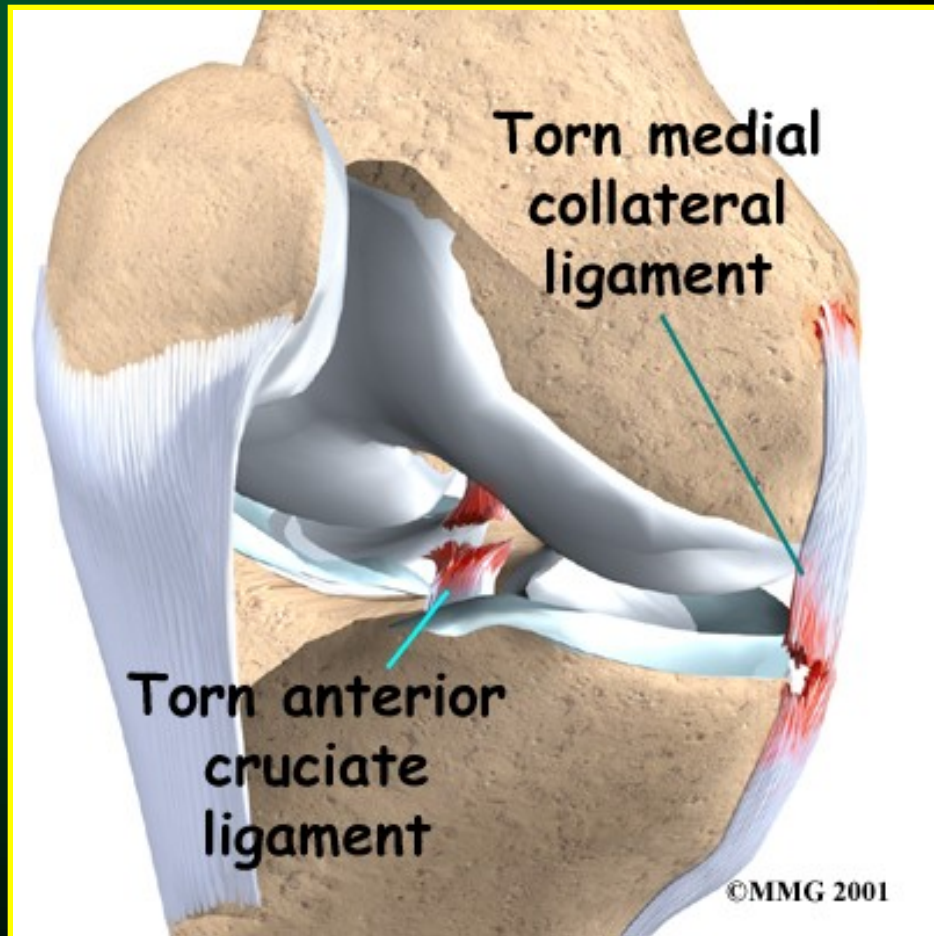
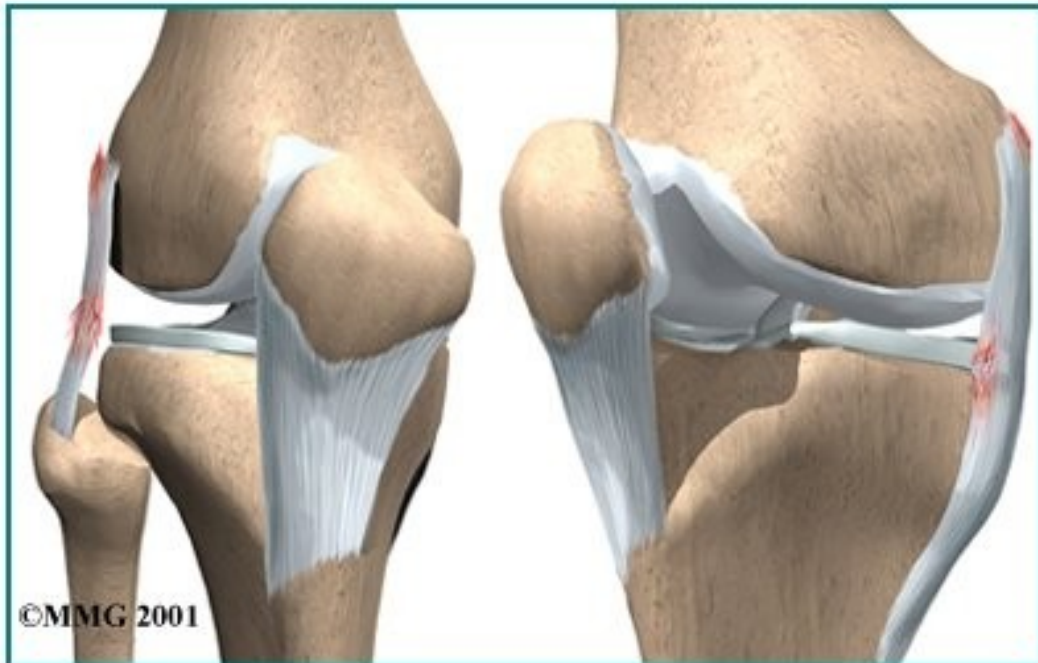

Middle third of patellar ligament cut and removed

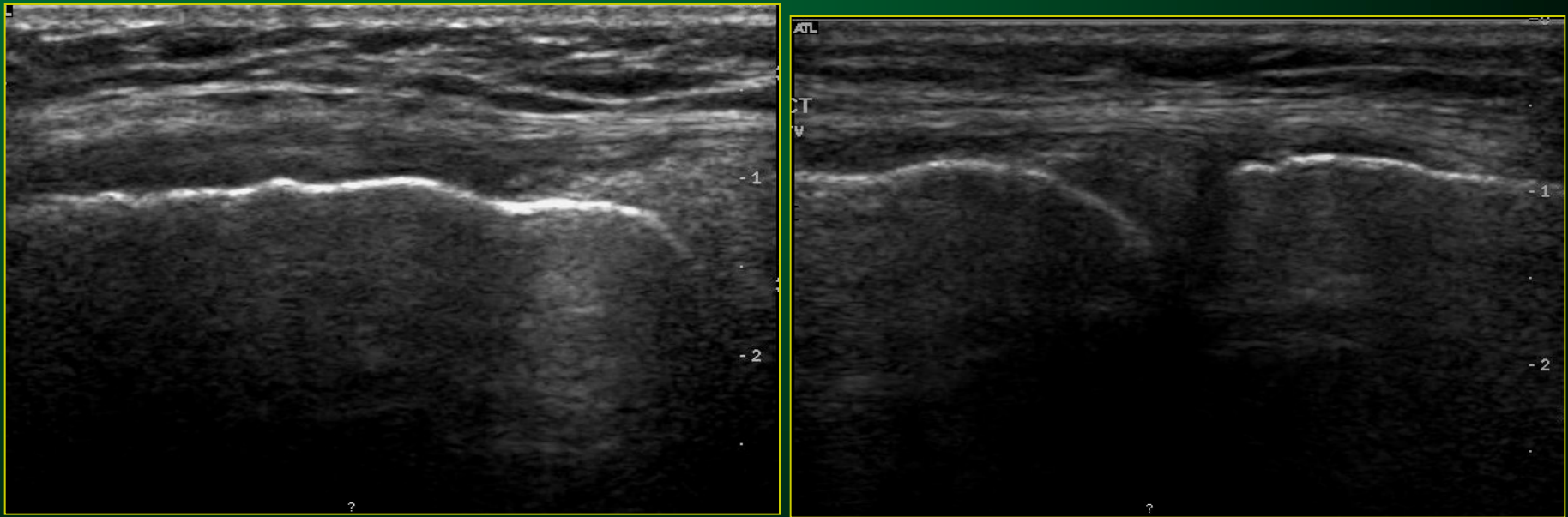


Poranění postranních vazů

Collateral Ligament Injuries



Kolaterální vaz



Ruptura med. kolaterálního vazu

