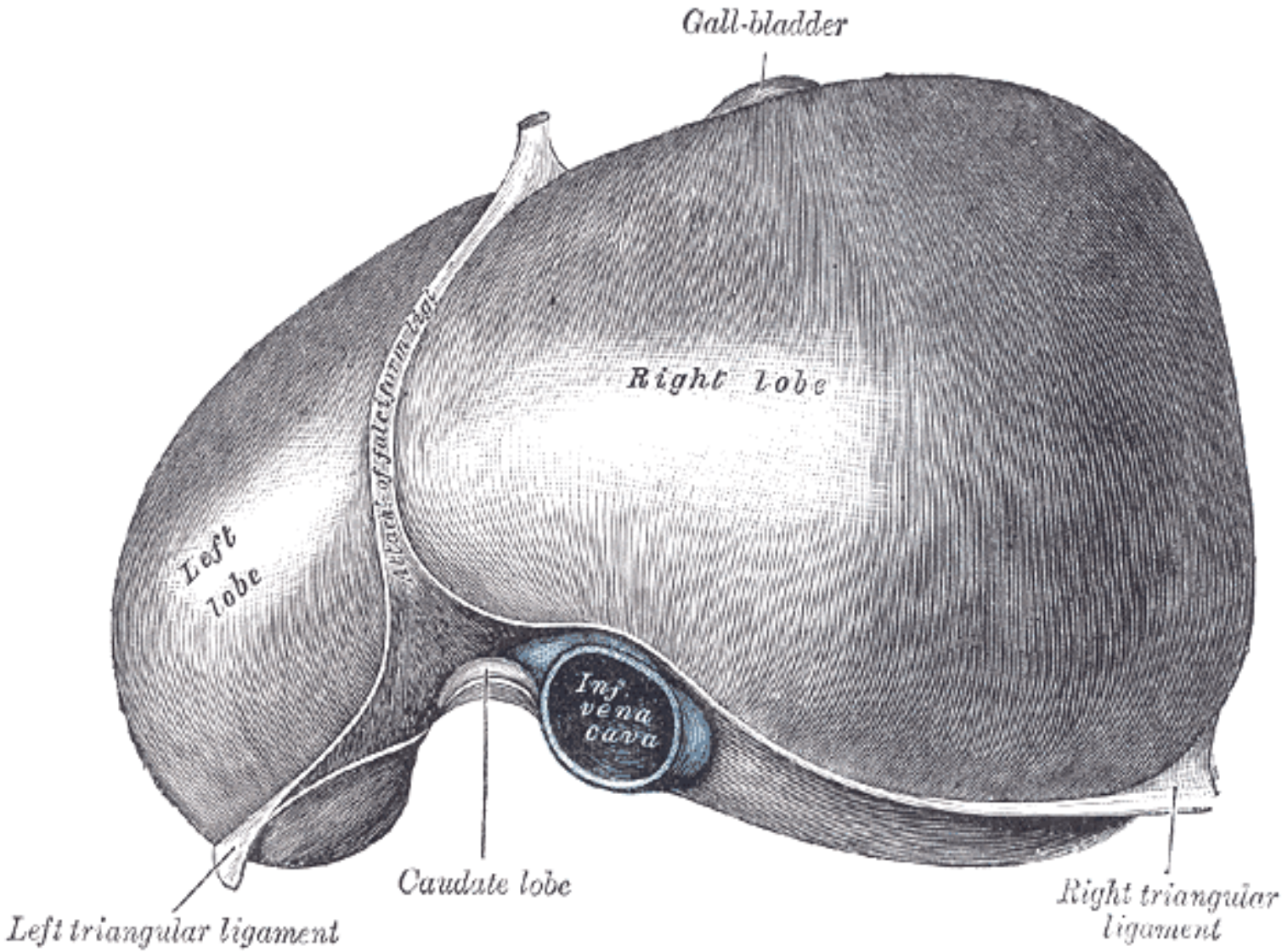
Gall-bladder
Right lobe
Left lobe
Inf. vena cava
Caudate lobe
Left triangular ligament
Right triangular ligament

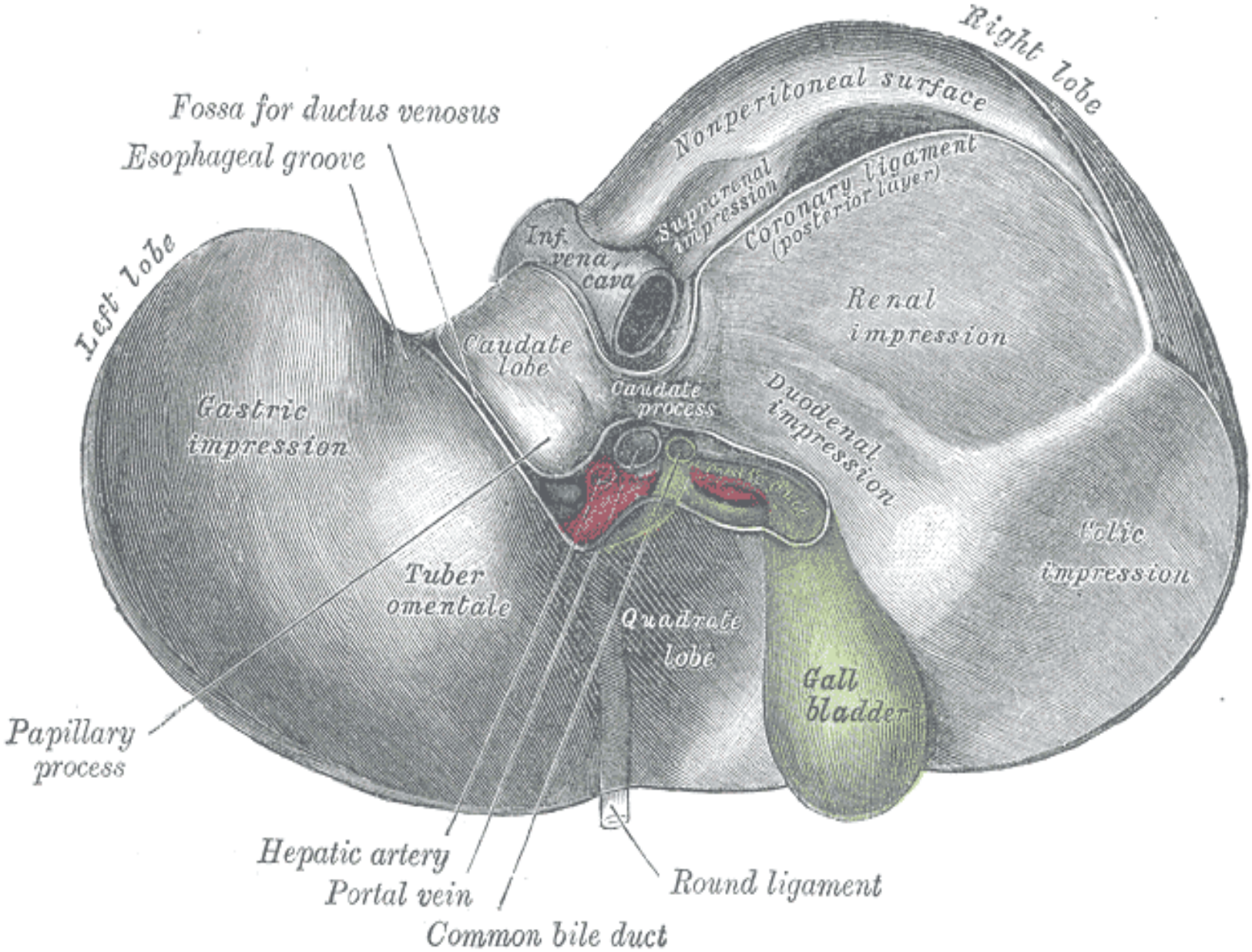
Right lobe
Nonperitoneal surface
Fossa for ductus venosus
Esophageal groove
Left lobe
Inf. vena cava
Suprarenal impression
Coronary ligament (posterior layer)
Renal impression
Caudate lobe
Caudate process
Duodenal impression
Gastric impression
Colic impression
Tuber omentale
Quadrate lobe
Gall bladder
Papillary process
Hepatic artery
Portal vein
Common bile duct
Round ligament

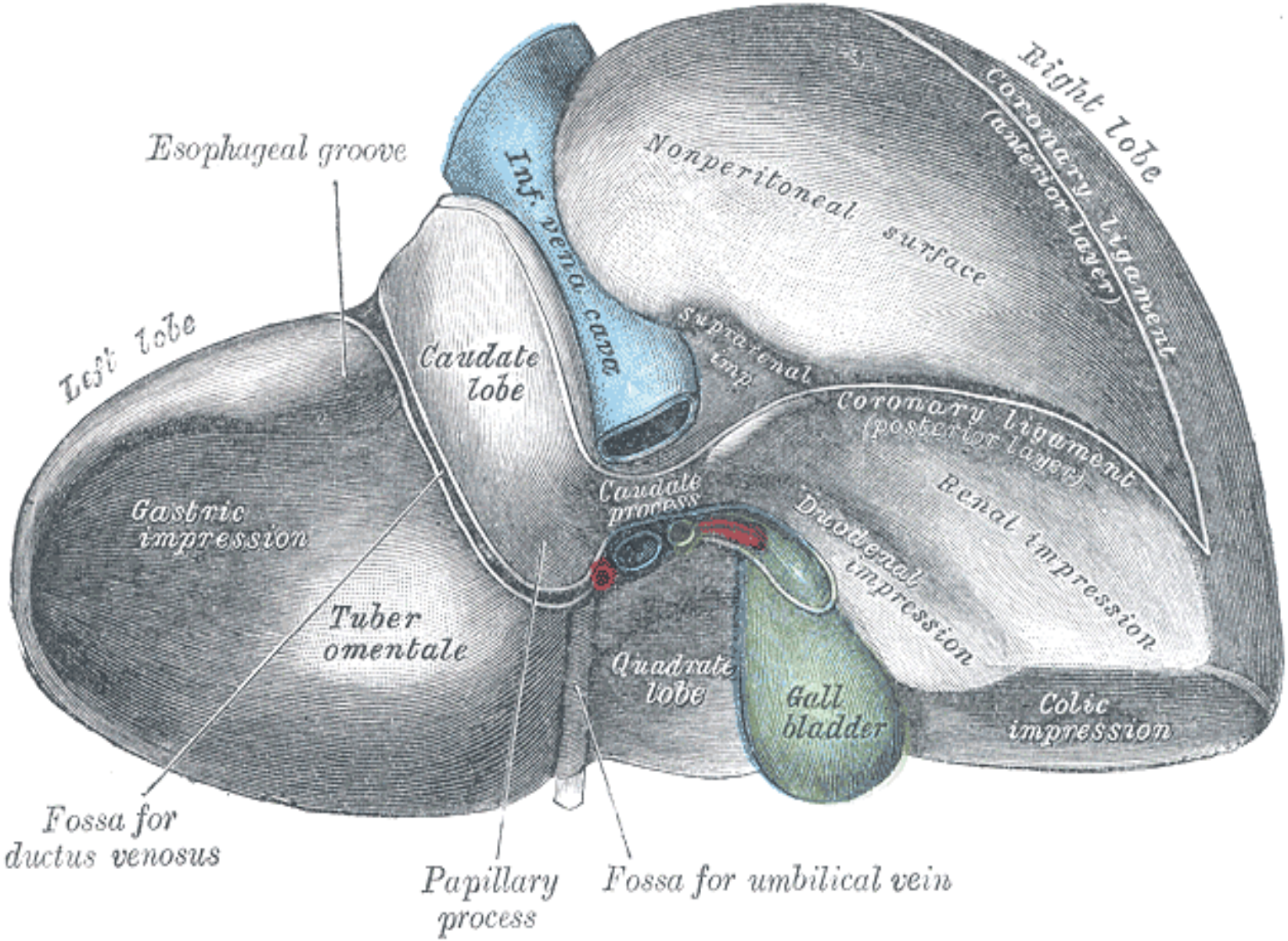
Right lobe
Coronary ligament (anterior layer)
Nonperitoneal surface
Inf. vena cava
Esophageal groove
Left lobe
Caudate lobe
Suprarenal imp.
Coronary ligament (posterior layer)
Caudate process
Renal impression
Duodenal impression
Gastric impression
Tuber omentale
Quadrate lobe
Gall bladder
Colic impression
Fossa for ductus venosus
Papillary process
Fossa for umbilical vein

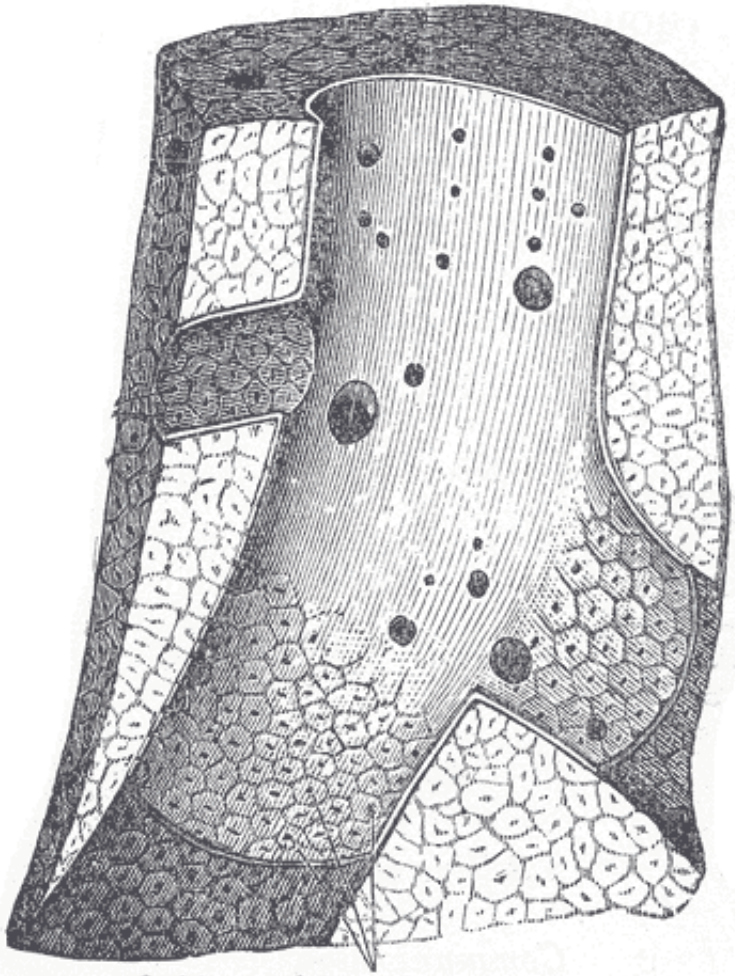

Orifices of intralobular veins

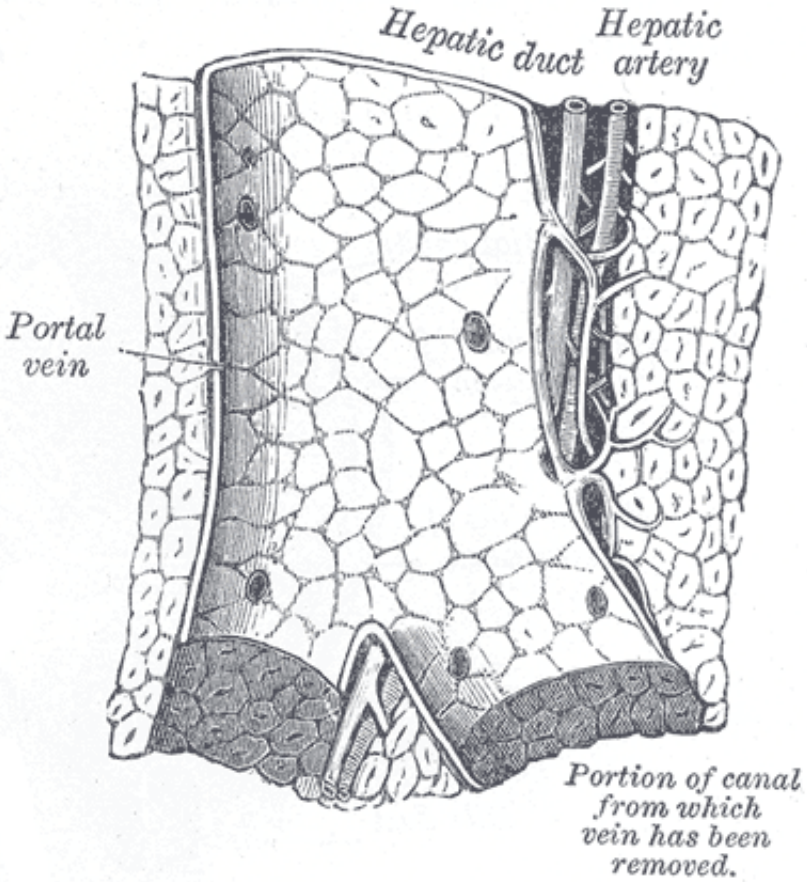

1089, 1090

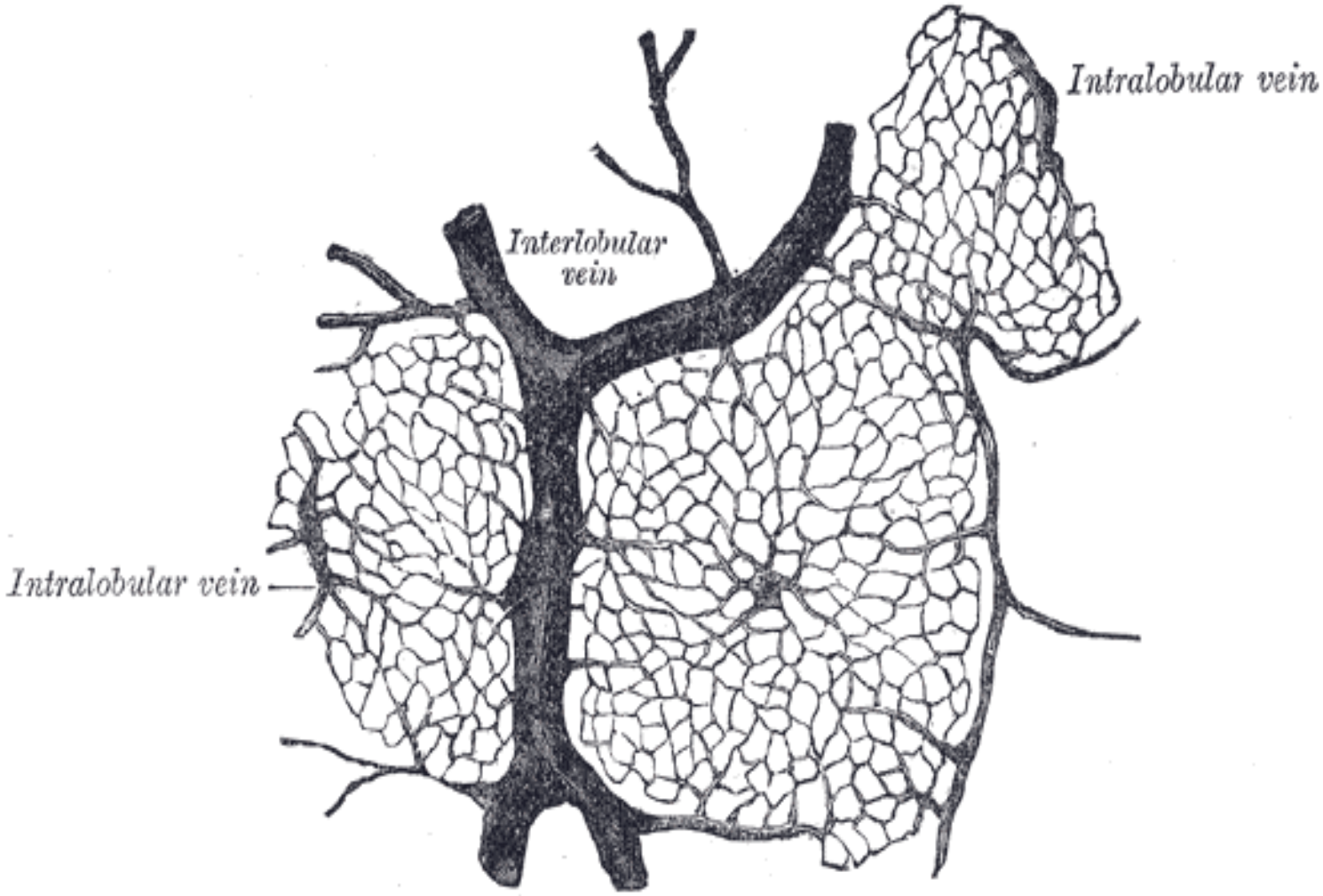

1091

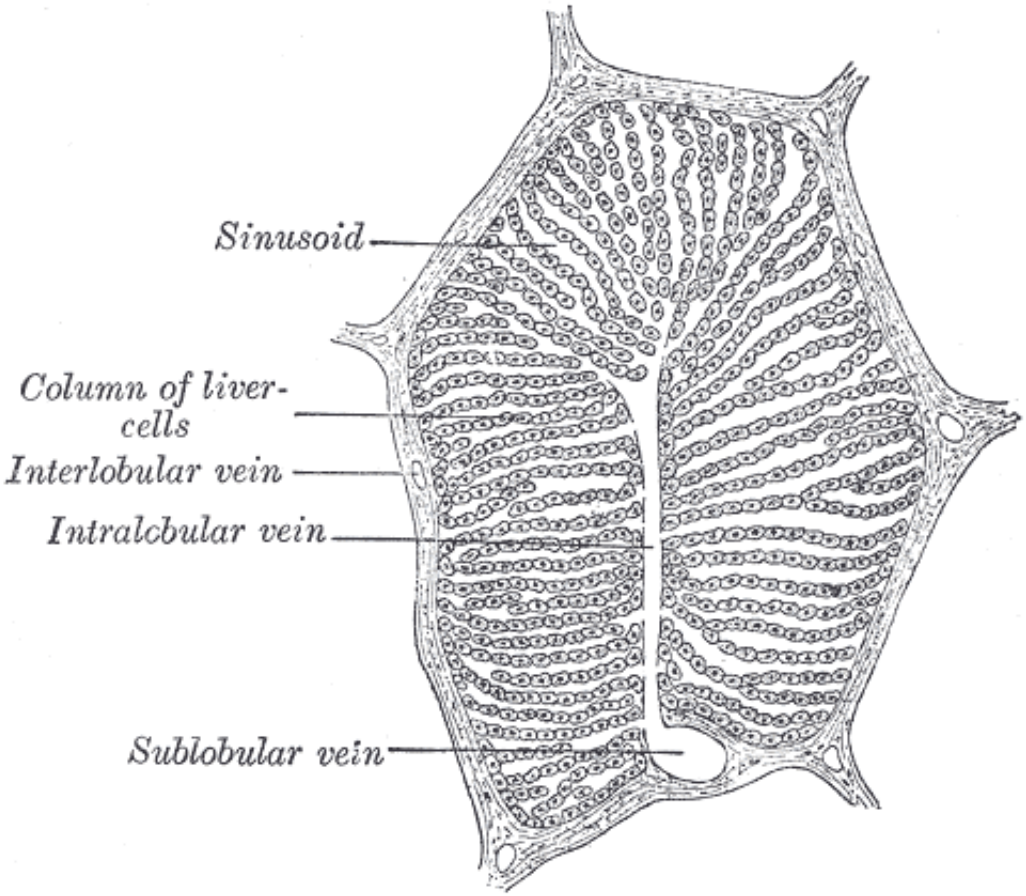
Sinusoid
Column of liver-cells
Interlobular vein
Intralobular vein
Sublobular vein

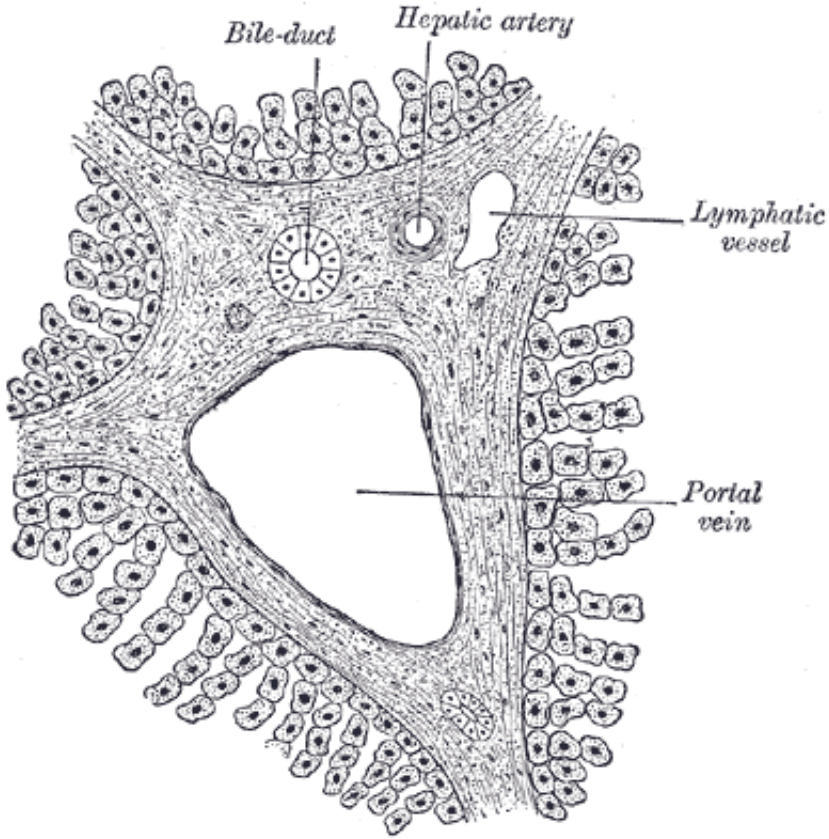
Bile-duct
Hepatic artery
Lymphatic vessel
Portal vein

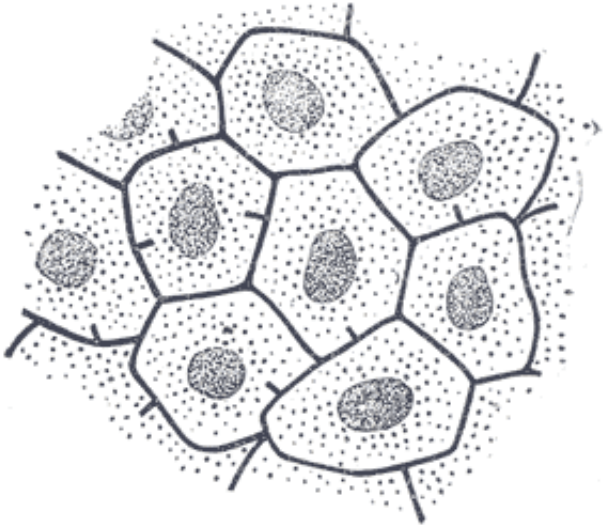

1092 - 4

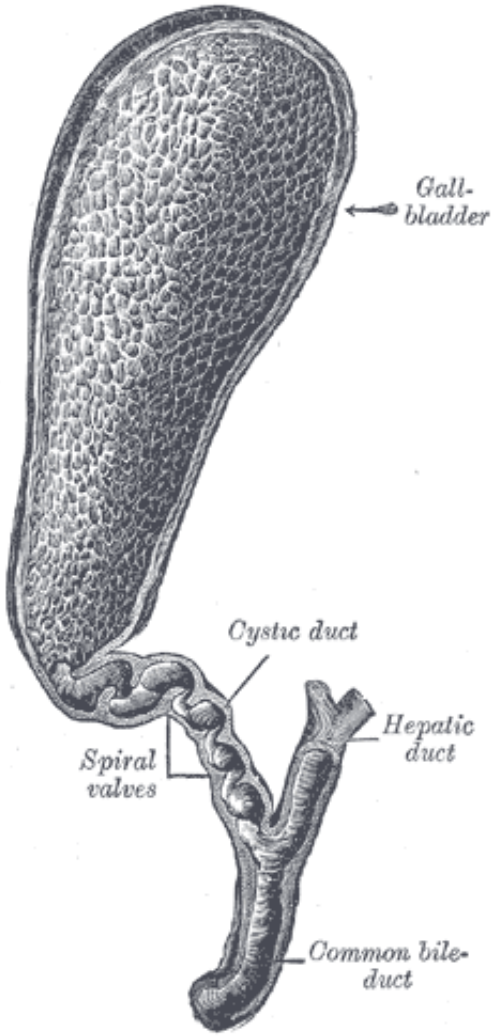
Gall-
bladder
Cystic duct
Hepatic
duct
Spiral
valves
Common bile-
duct

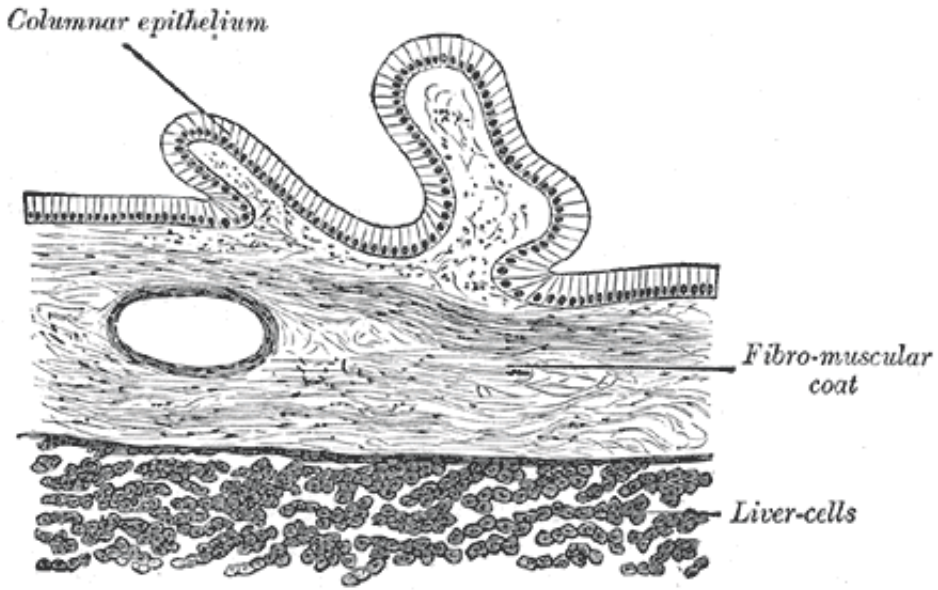
Columnar epithelium
Fibro-muscular
coat
Liver-cells

1096, 7

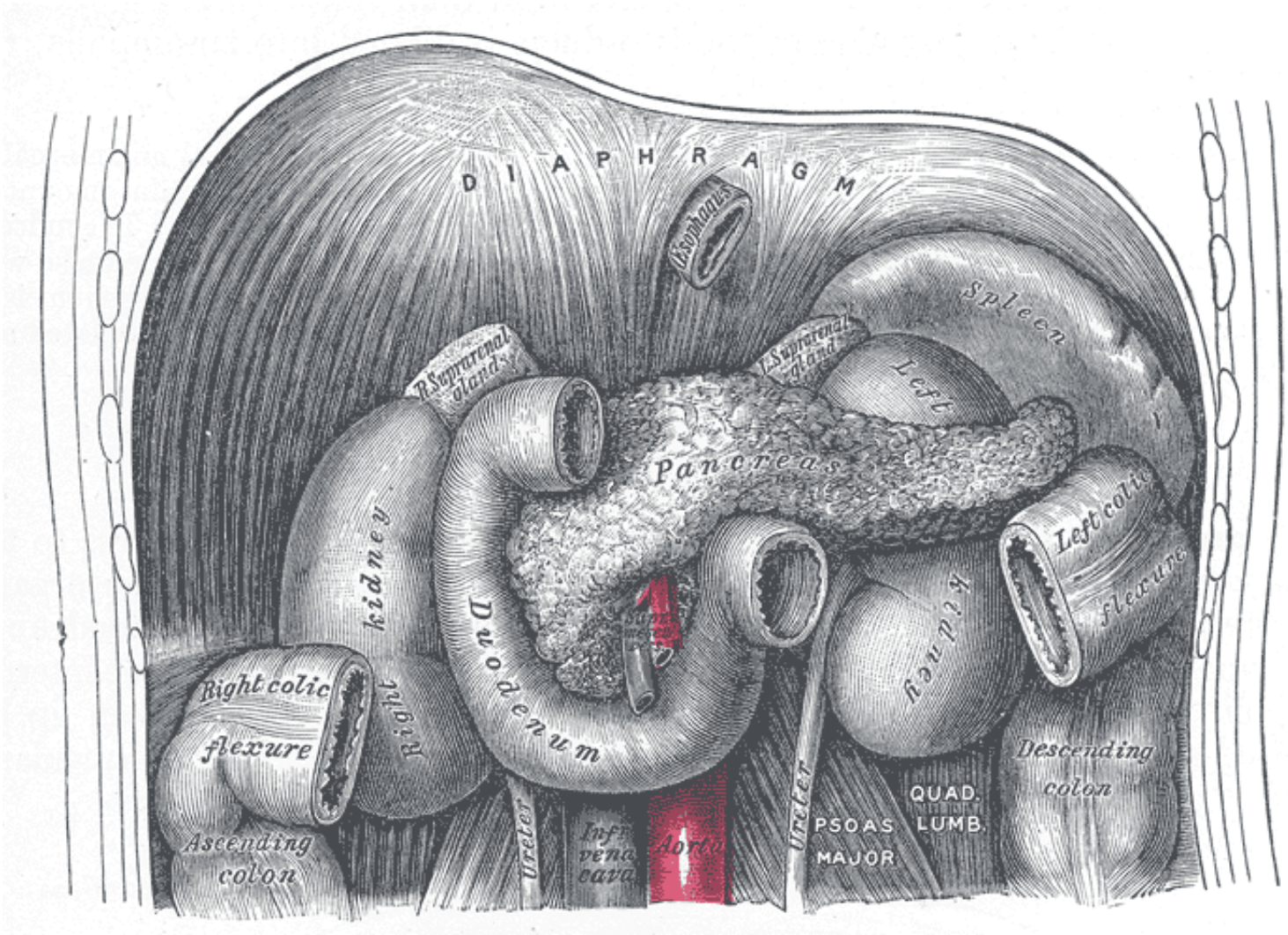
DIAPHRAGM
Oesophagus
Spleen
R. Suprarenal gland
L. Suprarenal gland
Left
Pancreas
Left colic
flexure
Kidney
Duodenum
Kidney
Right colic
flexure
Right
Descending colon
QUAD. LUMB.
PSOAS MAJOR
Ureter
Ureter
Inf. vena cava
Aorta
Ascending colon

1098

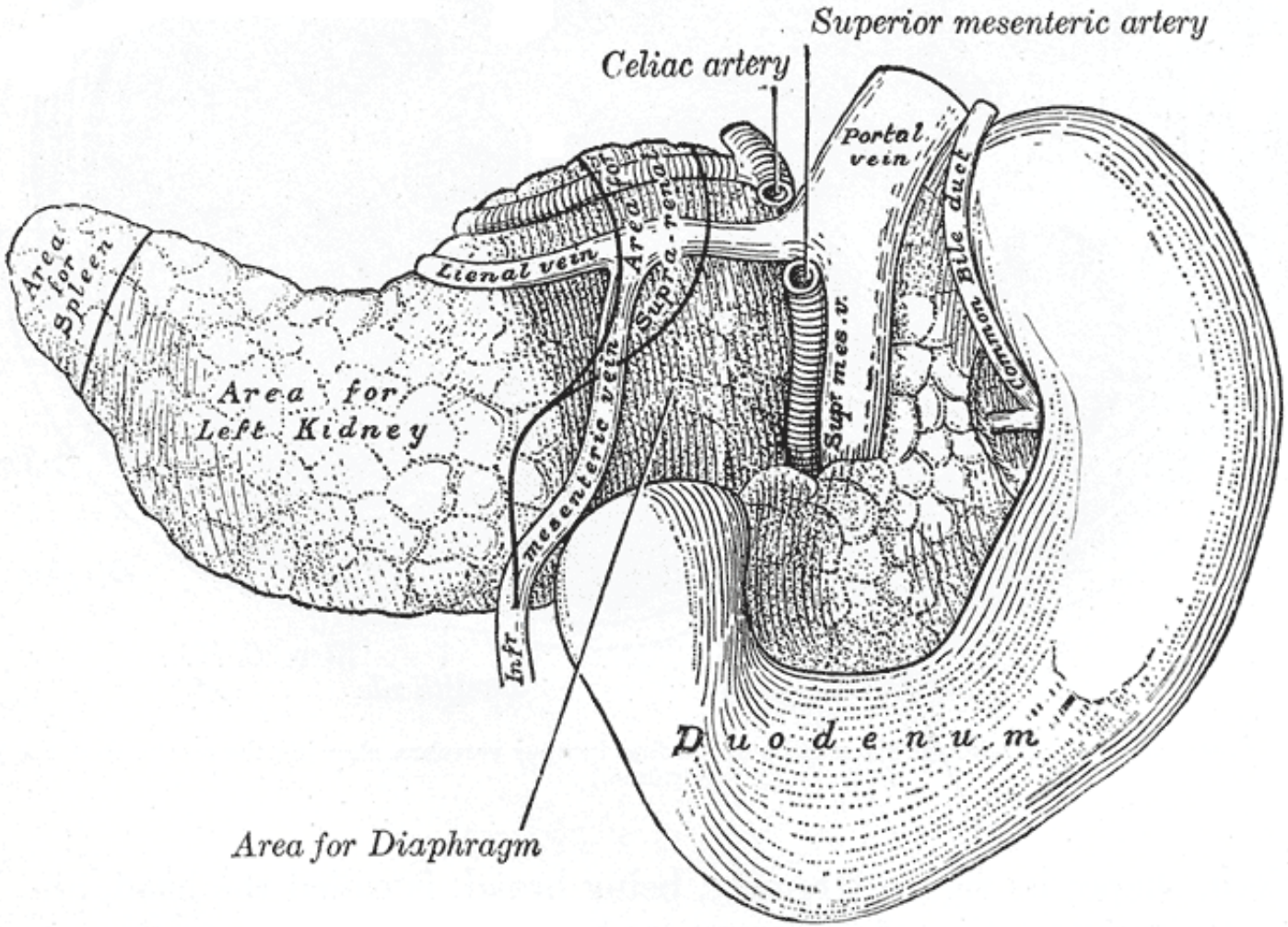
Superior mesenteric artery
Celiac artery
Portal vein
Area for Spleen
Lienal vein
Area for Supra-renal
Bile duct
Common
Area for Left Kidney
Supr. mes. v.
Infr. mesenteric vein
Duodenum
Area for Diaphragm

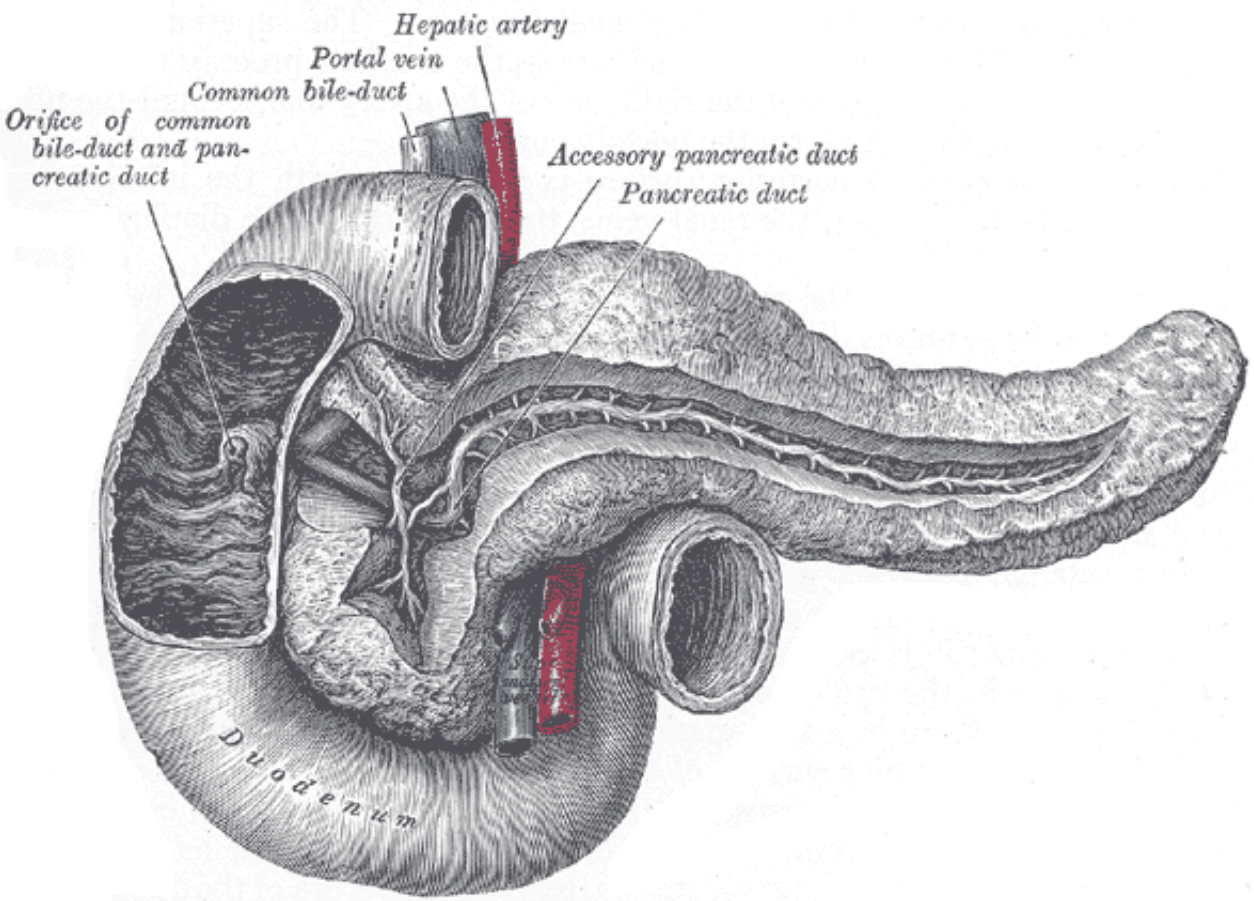
Hepatic artery
Portal vein
Common bile-duct
Orifice of common bile-duct and pancreatic duct
Accessory pancreatic duct
Pancreatic duct
Duodenum

1000

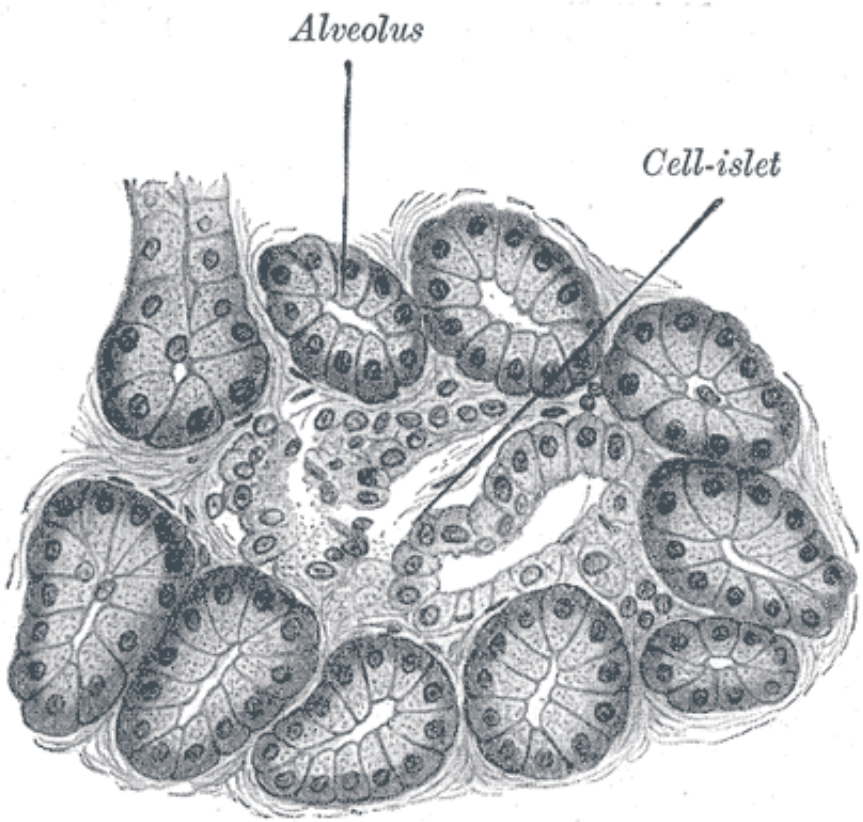

1105