

**Institute for Microbiology, Medical Faculty of Masaryk University
and St. Anna Faculty Hospital in Brno**

Miroslav Votava, Vladana Woznicová

**Agents of infections with
skin manifestations**

Infections with skin symptoms

1. **primary skin infections**
2. **secondary infections of already diseased skin**
3. **skin symptoms of systemic infections**

Etiology:

- **bacterial**
- **viral**
- **fungus**
- **parasitic**

Bacterial skin infections

Primary acute bacterial skin infections – la

acne vulgaris –

***Propionibacterium
acnes***

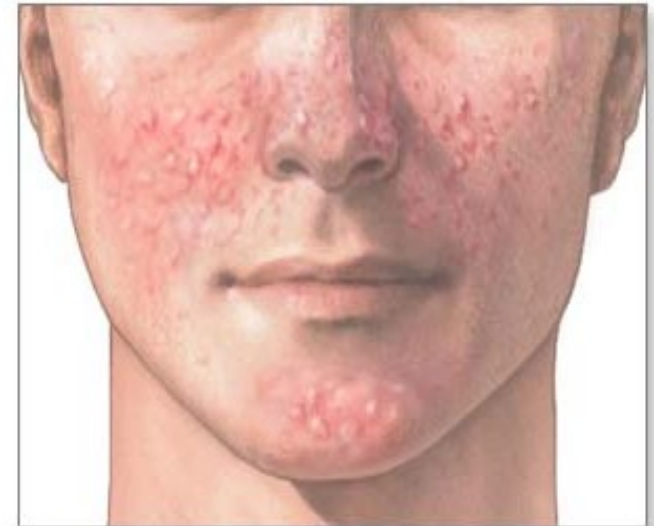
carbunculus nuchae –

Staphylococcus aureus

ecthyma gangraenosum –

Pseudom. aeruginosa

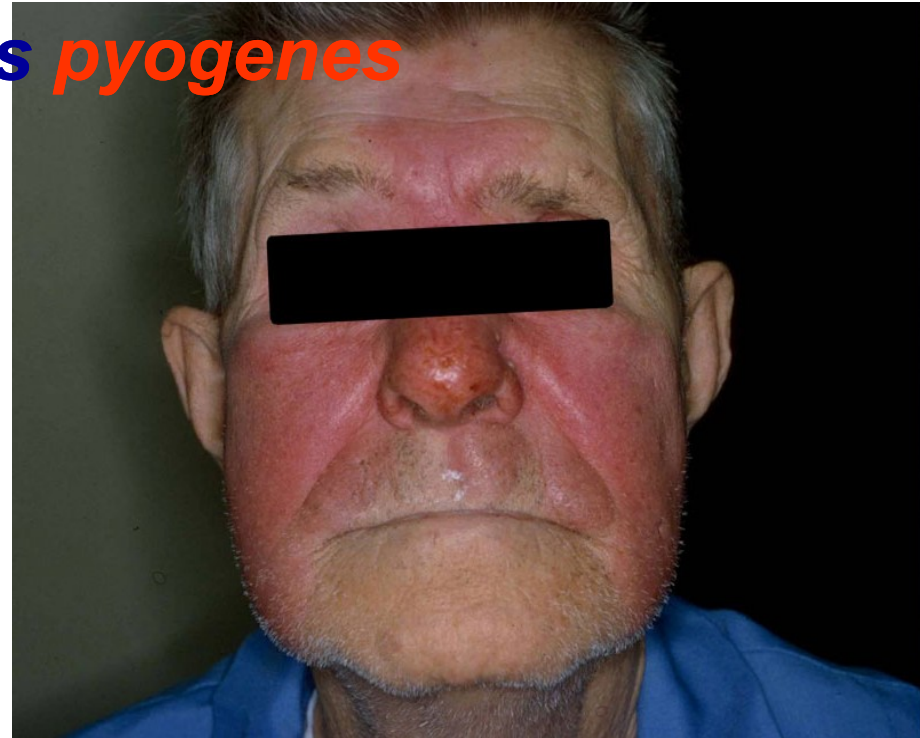
Adult facial acne



Primary acute bacterial skin infections – Ib

erysipelas – *Streptococcus pyogenes*

- local redness, heat, swelling, and a highly characteristic raised, indurated border, **no localized purulence**
- the **legs and face** are the most frequently affected sites
- on the face is a **butterfly distribution** involving the cheeks and the bridge of the nose

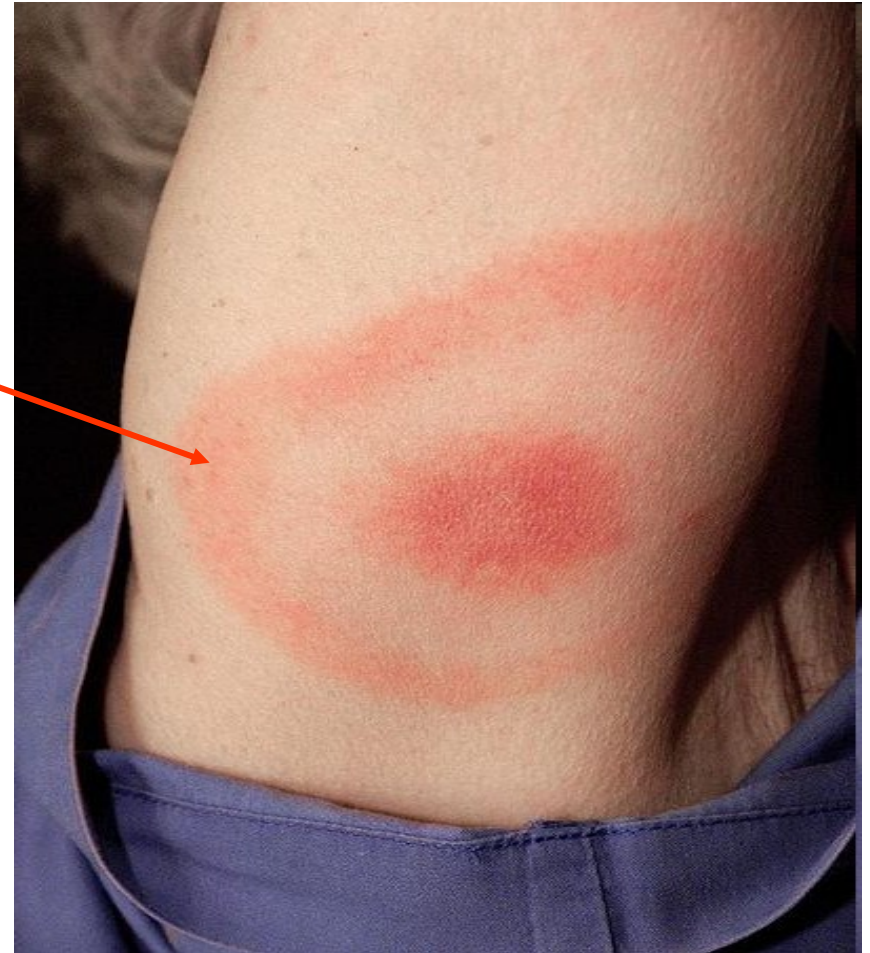

erysipeloid – *Erysipelothrix rhusiopathiae*

Primary acute bacterial skin infections – Ic

erythema migrans –
Borrelia burgdorferi

erythrasma –
*Corynebacterium
minutissimum*



Primary acute bacterial skin infections – Ila

folliculitis

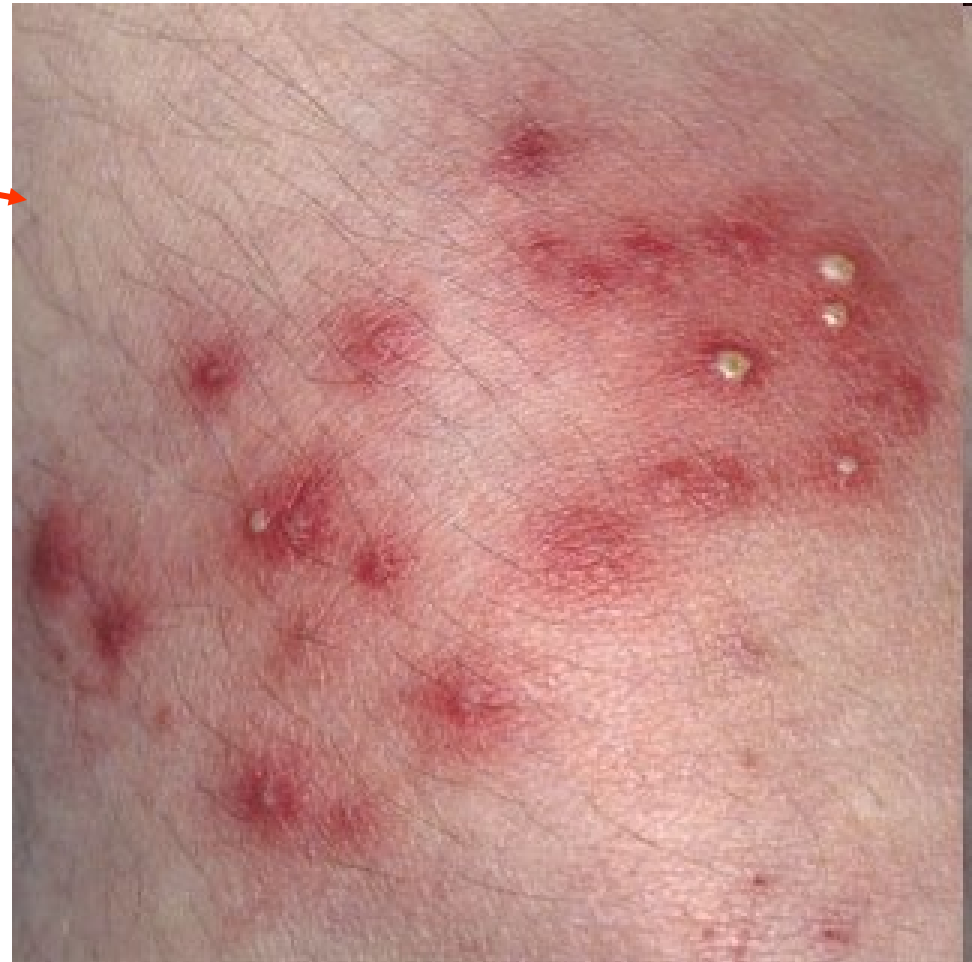- *Staph. aureus*,
- P. aeruginosa*

furunculosis (boil)

- *Staph. aureus*

hidradenitis suppurativa

- *Staph. aureus*



Primary acute bacterial skin infections – IIb

hordeolum (stye)

– *Staph. aureus*

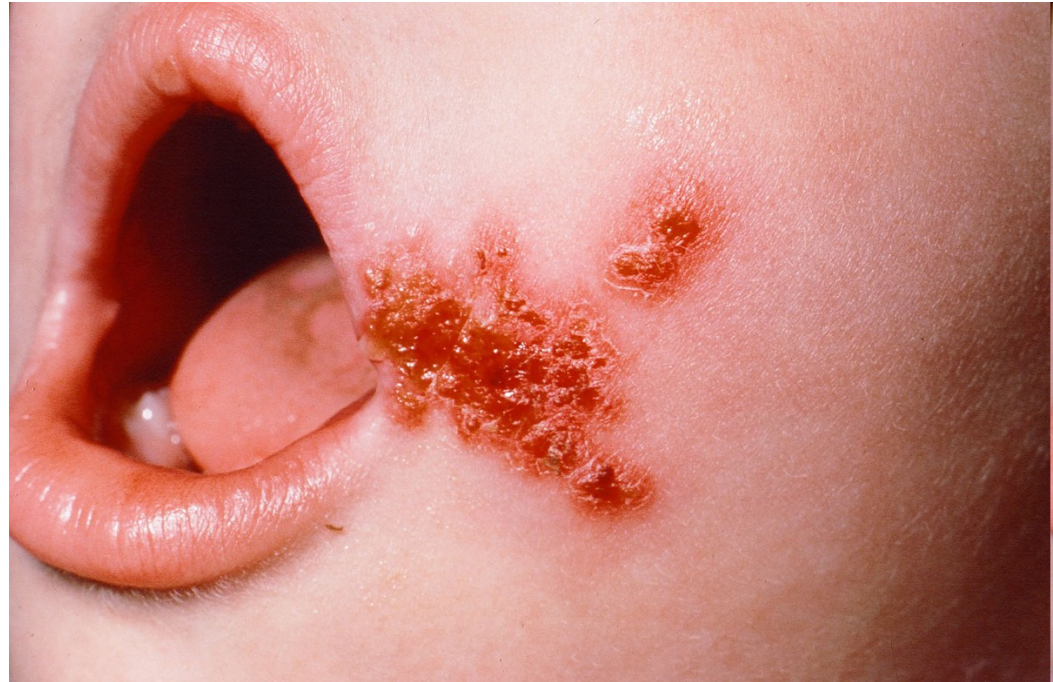Impetigo →

– *Staph. aureus*,

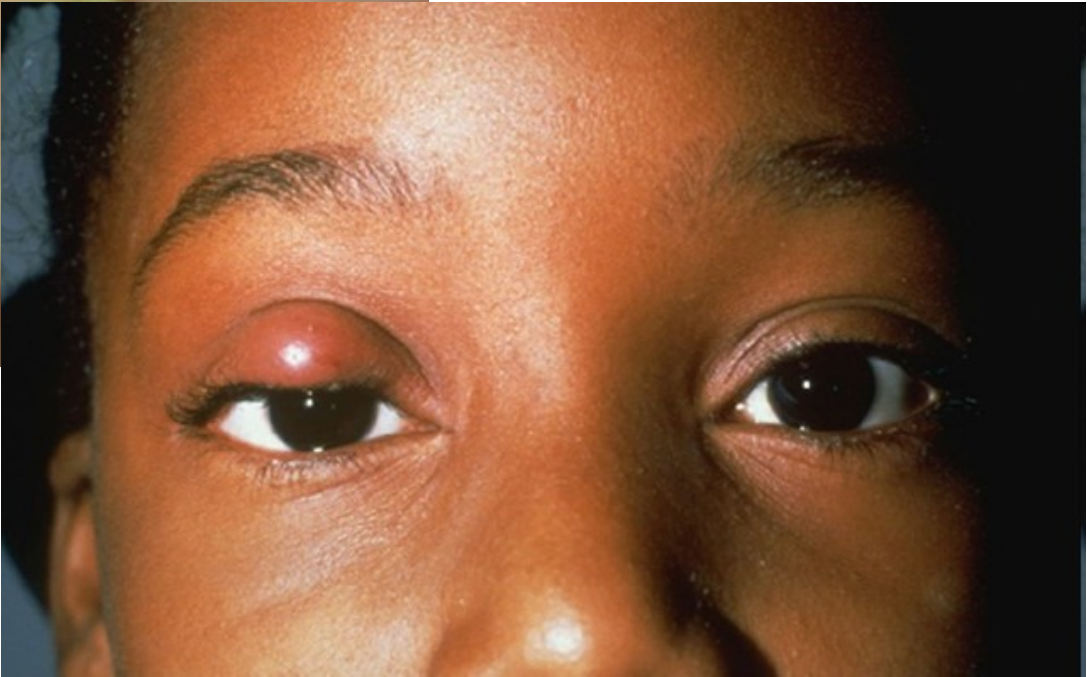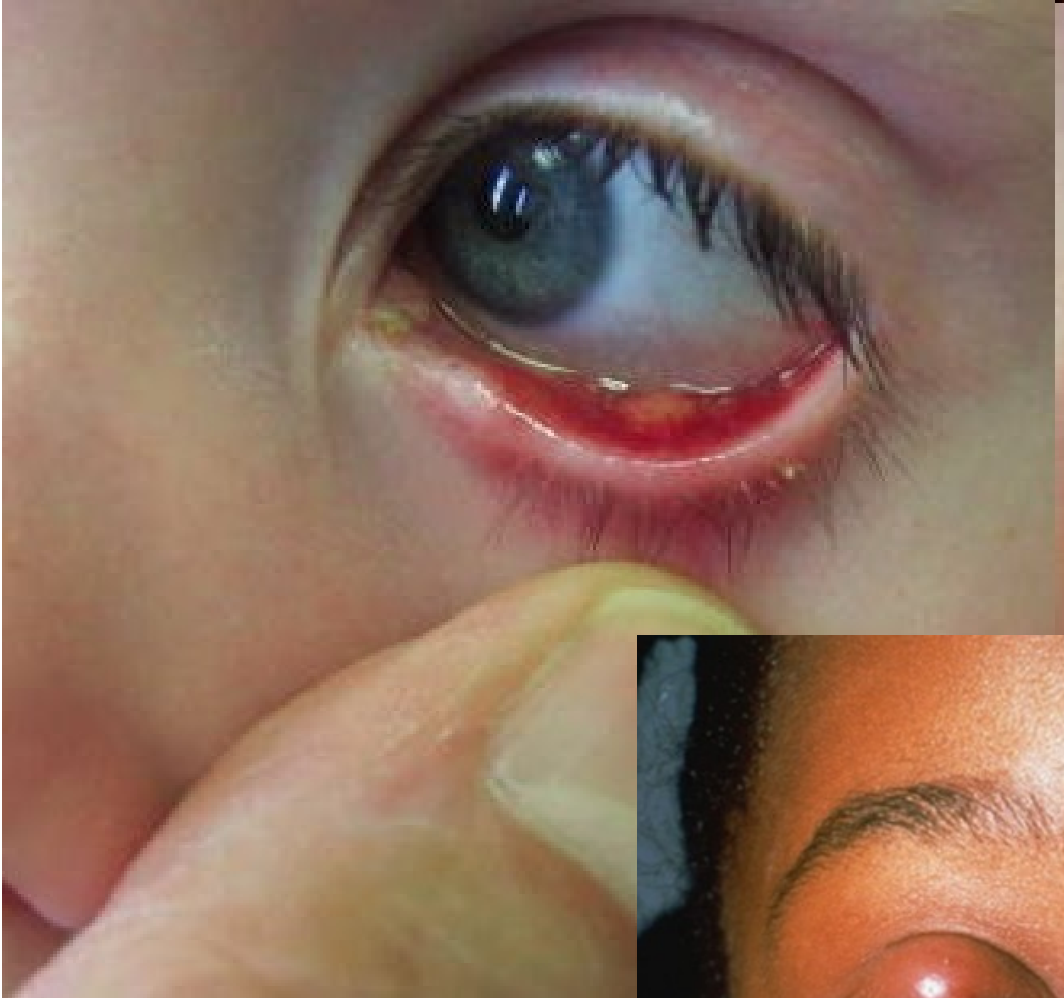- *Str. pyogenes*

lymphangoitis

– *Strept. pyogenes*



Stye



Primary acute bacterial skin infections – IIC

panaritium

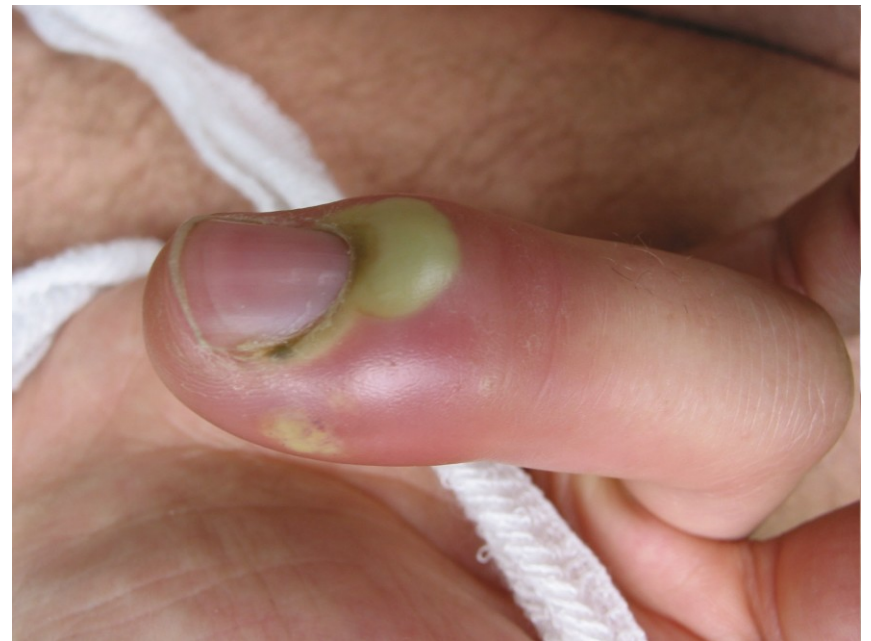Staphylococcus aureus

paronychium

Staphylococcus aureus

sycosis barbae

Staphylococcus aureus



Primary chronic bacterial skin infections

actinomycosis - *Actinomyces israelii*

chronic subcutaneous abscesses -

A. israelii, Nocardia asteroides, Rhodococcus equi

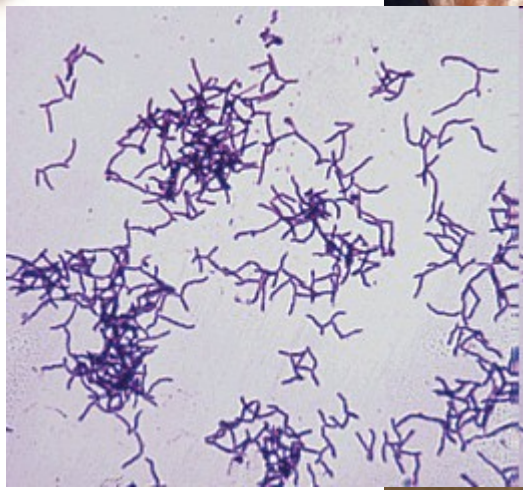
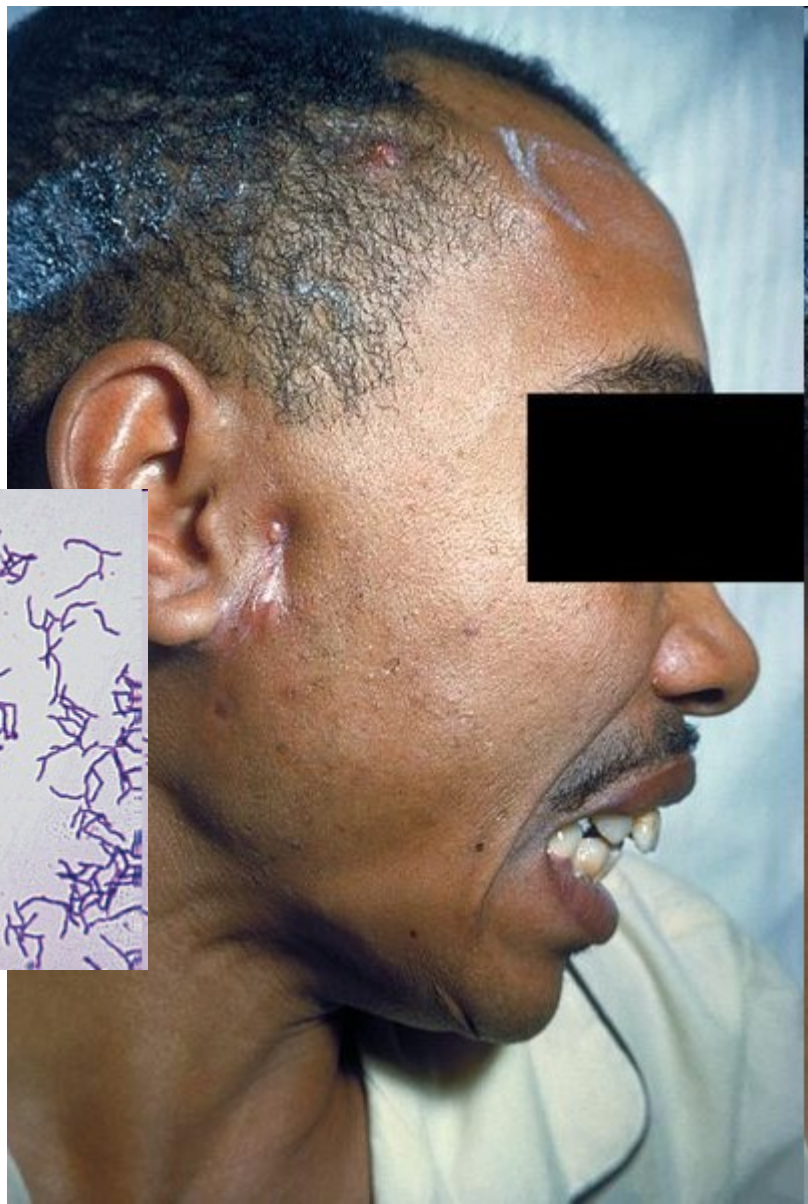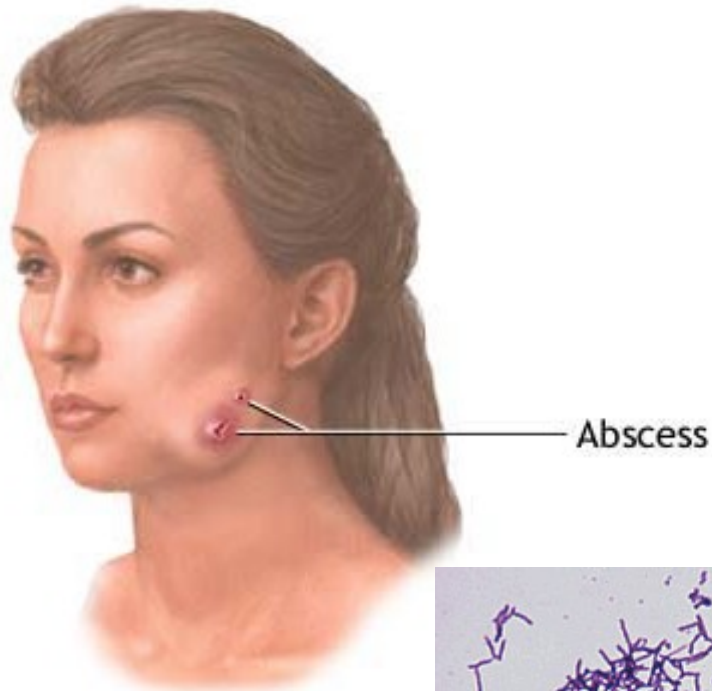
skin granulomas -

Mycobacterium marinum, M. haemophilum, M. chelonae

leprosy - *Mycobacterium leprae*

lupus vulgaris - *Mycobacterium tuberculosis*

scrophuloderma - *M. tuberculosis, M. bovis*



actinomycosis – *Actinomyces israelii*

Secondary infections of skin lesions

decubitus (bedsore), trophic ulcer –
neighbouring and endogenous flora
(staphylococci, streptococci, enterococci,
enteric bacteria, pseudomonads and other
Gram-negative non-fermenting rods,
anaerobes, yeasts)

infected atheroma – *S. aureus*, *P. acnes*

infected intertrigo (raw) – *S. aureus*, *P. acnes*

sec. infected dermatomycoses – *S. pyogenes*

infected wounds – *discussed in previous lecture*

Skin symptoms of systemic bacterial infections

roseola (rash in typhoid fever) – *Salmonella Typhi*

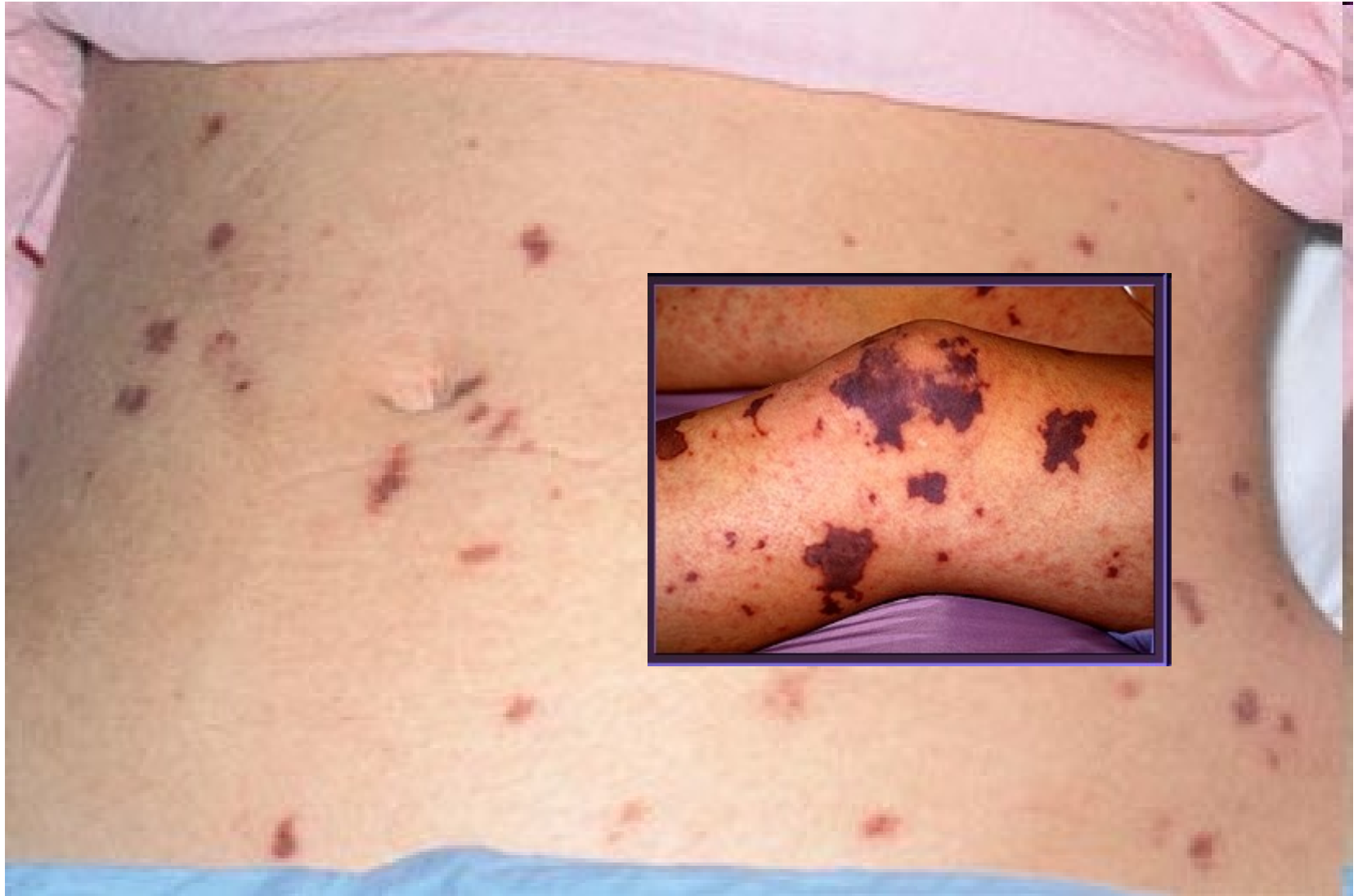disseminated gonorrhoea – *Neisseria gonorrhoeae*

infective endocarditis – to be dealt with by sepsis

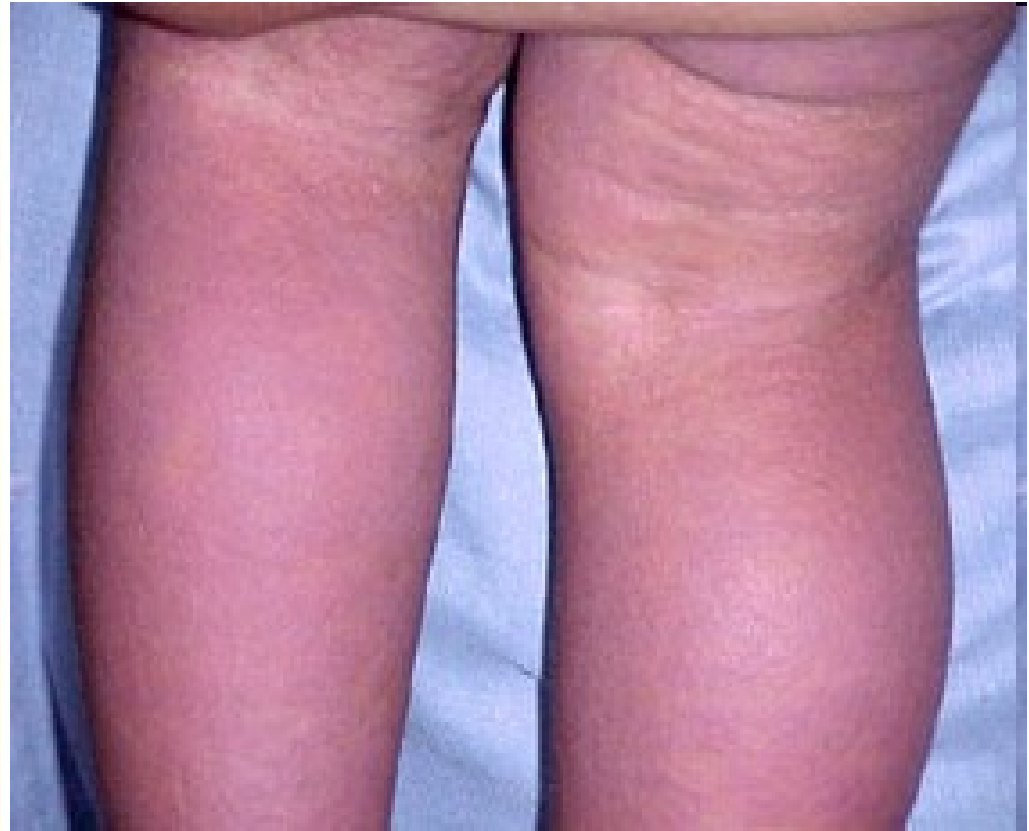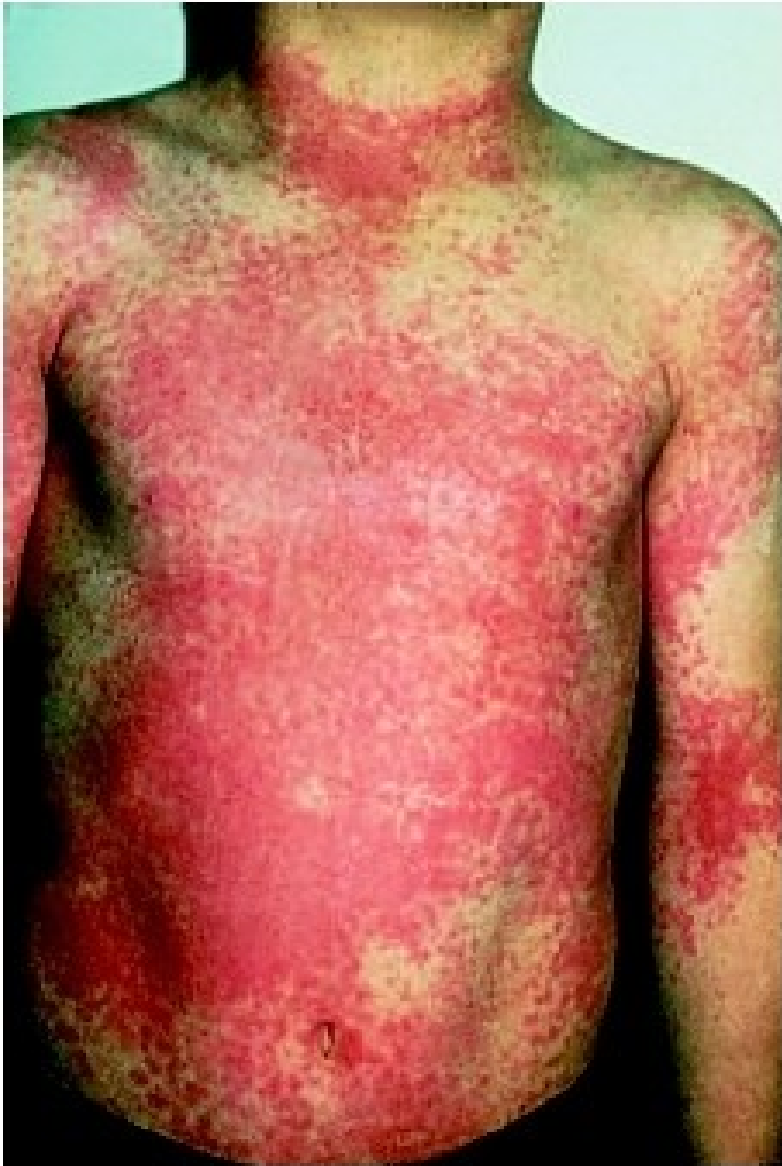scarlatina (scarlet fever) – *Streptococcus pyogenes*

SSSS (staphylococcal scalded skin syndrome) –
Staphylococcus aureus

syphilis – *Treponema pallidum*



Rash - meningococemia – *Neisseria meningitidis*



scarlatina (scarlet fever) – *Streptococcus pyogenes*

Fungal infections

Etiology of skin fungal infections

Etiology differs in...

- **superficial mycoses**, like **pityriasis versicolor** – *Malassezia furfur* (syn. *Pityrosporum ovale*)
- **mucocutaneous mycoses** – *Candida albicans* and other species of candidae
- **cutaneous mycoses** – typical dermatophytes
- **subcutaneous mycoses**
- **opportunistic skin mycoses** in immunodeficient

Etiology of cutaneous mycoses

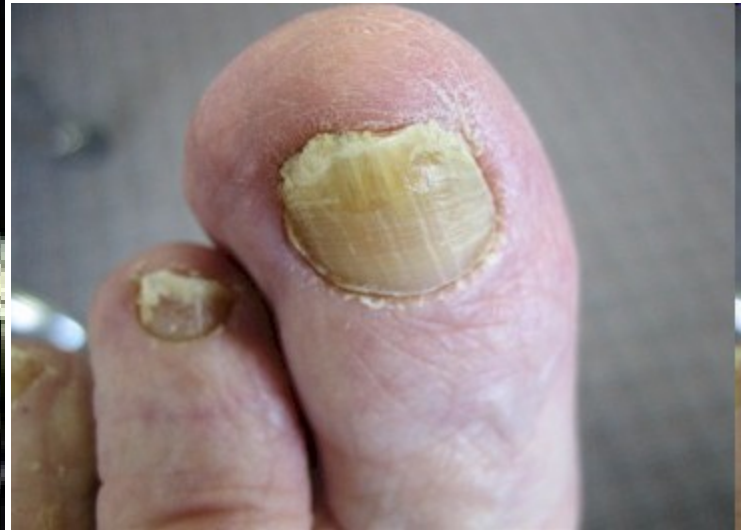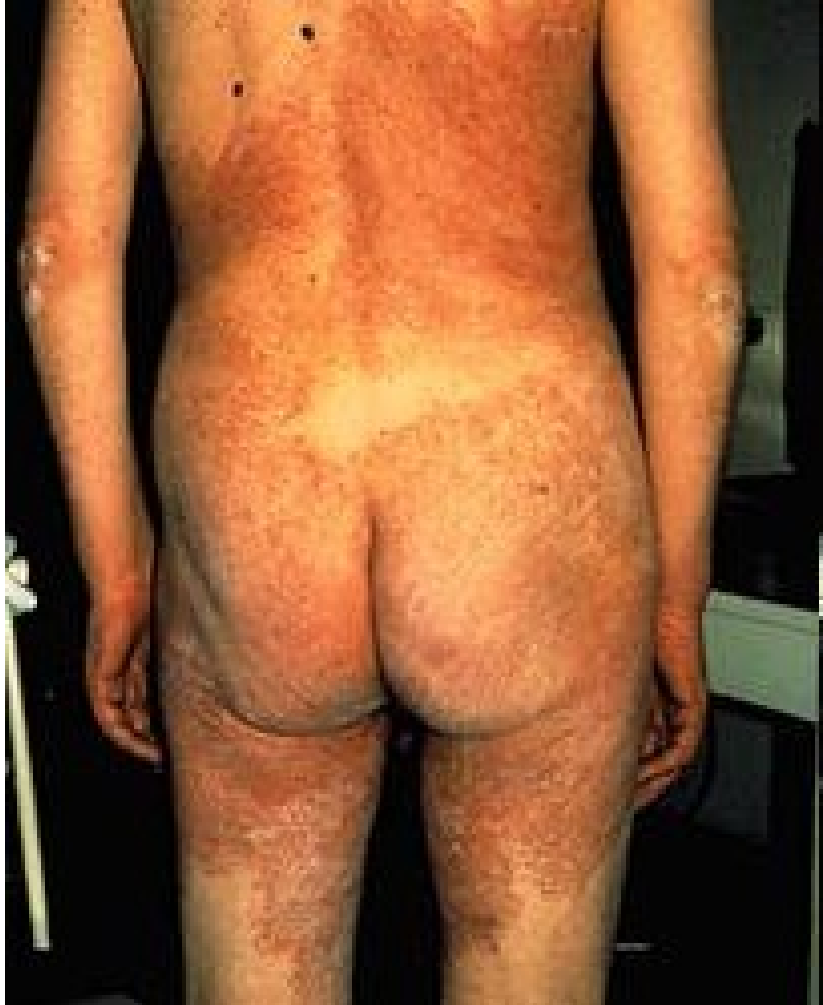tinea pedis – *Trichophyton rubrum*, *Trich. mentagrophytes* var. *interdigitale*, *Epidermophyton floccosum*

onychomycosis – *T. rubrum*, *E. floccosum*

tinea corporis – *T. rubrum*, *Microsporum canis*, *M. gypseum*, *T. mentagrophytes* var. *mentagrophytes*, *E. floccosum*

tinea capitis, type **ectothrix** – *M. gypseum*, *M. canis*, *M. audouinii*, *T. mentagrophytes* var. *mentagrophytes*, *T. verrucosum* type **endothrix** – *T. tonsurans*

favus – *Trichophyton schoenleinii*



cutaneous mycoses

Etiology of subcutaneous mycoses

- pheohyphomycosis** (lesions with pigmented hyphae) –
genera *Alternaria*, *Aureobasidium*, *Cladosporium*,
Culvularia, *Exophiala*, *Phaeoannelomyces*, *Phoma*,
Wangiella & others
- chromoblastomycosis** (wartlike nodules with sclerotic bodies)
– *Cladophialophora*, *Fonsecaea*, *Phialophora*
- mycetoma eumycoticum** (swollen lesion with draining tracts
containing small grains) – *Acremonium*, *Exophiala*,
Madurella, *Pseudoallescheria* (= *Scedosporium*)
- sporotrichosis** (dimorphic fungus) – *Sporothrix schenckii*

Etiology of opportune skin mycoses in immunodeficitates

Fusarium solani, *Fusarium oxysporum*,
Fusarium verticillioides

Pseudoallescheria boydii (= teleomorf,
sexual phase of anamorf *Scedosporium*
apiospermum)

Penicillium marneffe (systemic infection
with skin manifestations)

Scopulariopsis brevicaulis

Viral infections

Skin symptoms in viral diseases – I

Macular (spotted) exanthem:

morbilli – morbilli virus, *Morbillivirus* genus

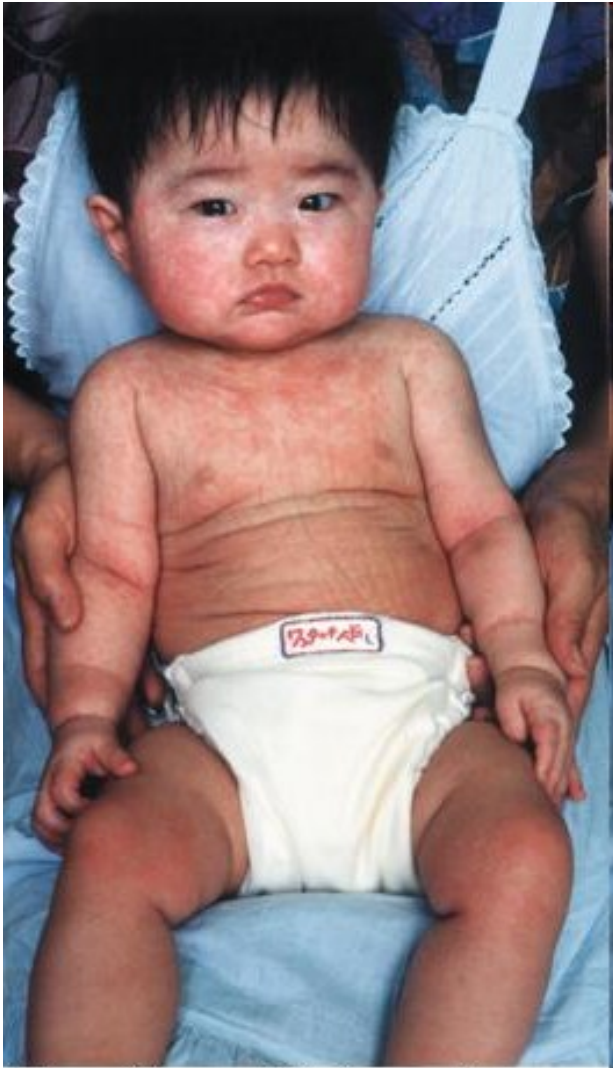rubella – rubella virus, *Rubivirus* genus

erythema infectiosum (the fifth disease) –
parvovirus B19, *Erythrovirus* genus

exanthema subitum (roseola infantum, the sixth
disease) – HHV 6, *Roseolovirus* genus

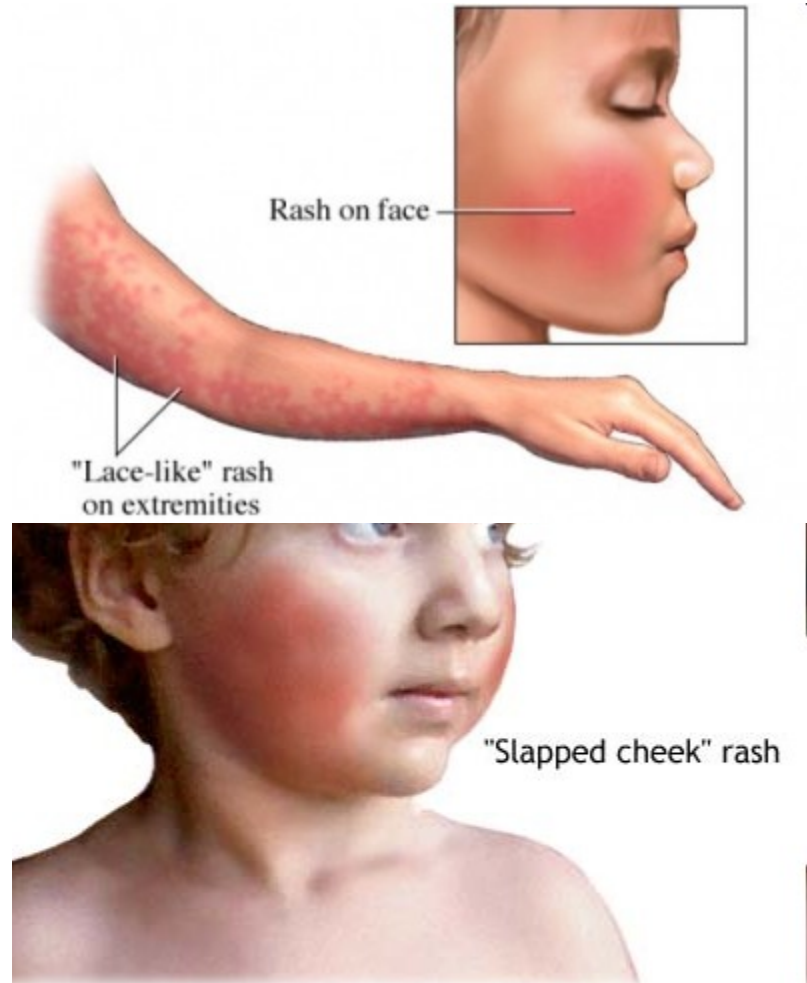
Umbiliform papulae:

molluscum contagiosum – molluscum
contagiosum virus, *Molluscipoxvirus* genus



Medscape © <http://www.medscape.com>

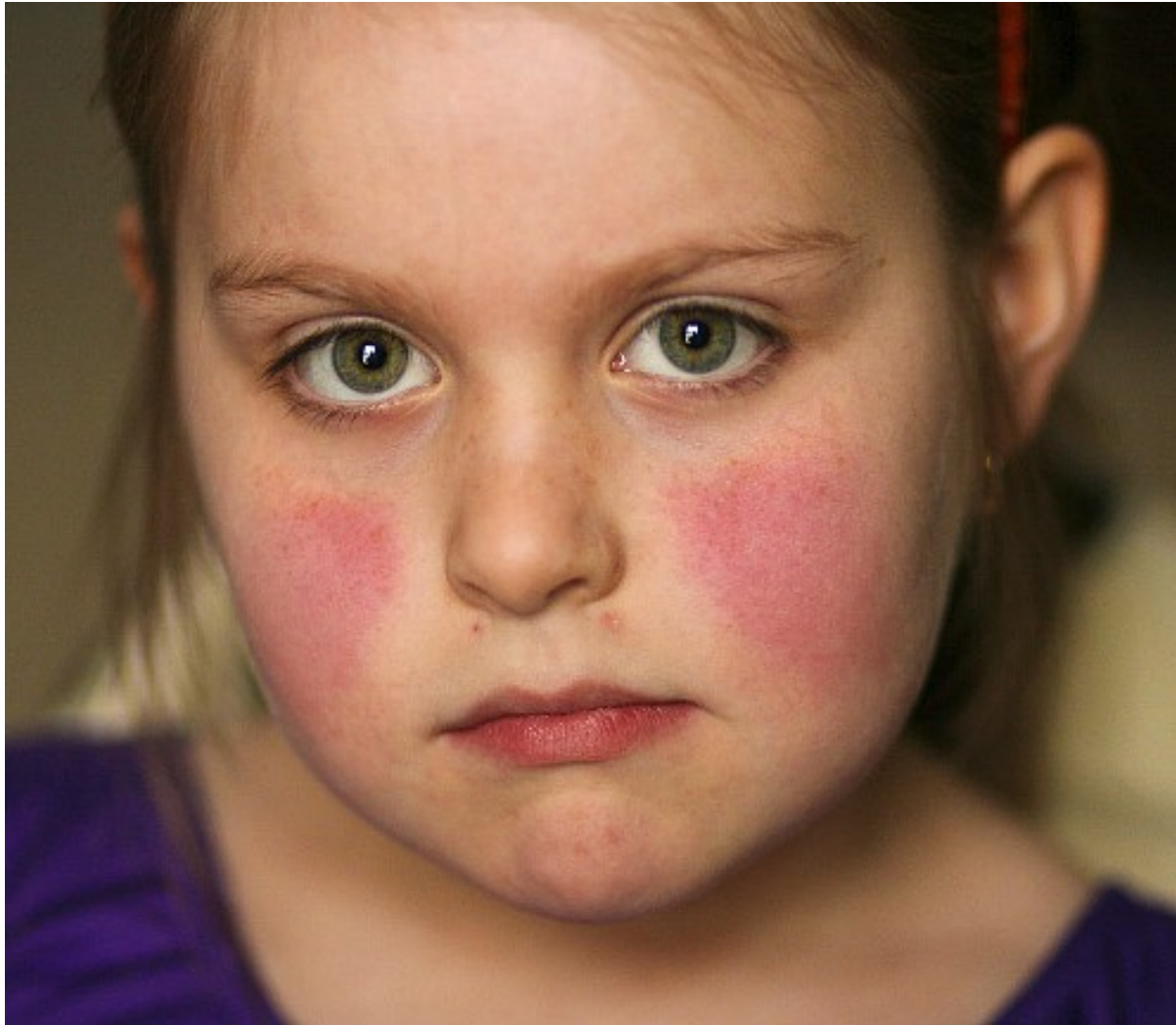Sixth Disease/ Exanthem subitum,
Roseola infantum, "Sudden
Rash", rose rash of infants,
3-day fever



ADAM.

Fifth Disease/Erythema
infectiosum - Erythrovirus
(Parvovirus) B19

Fifth Disease/Erythema infectiosum



<http://img405.imageshack.us>

Skin symptoms in viral diseases – II

Vesicles:

herpes simplex (cold sore) – HSV 1, *Simplexvirus* genus

herpes genitalis – HSV 2, *Simplexvirus* genus

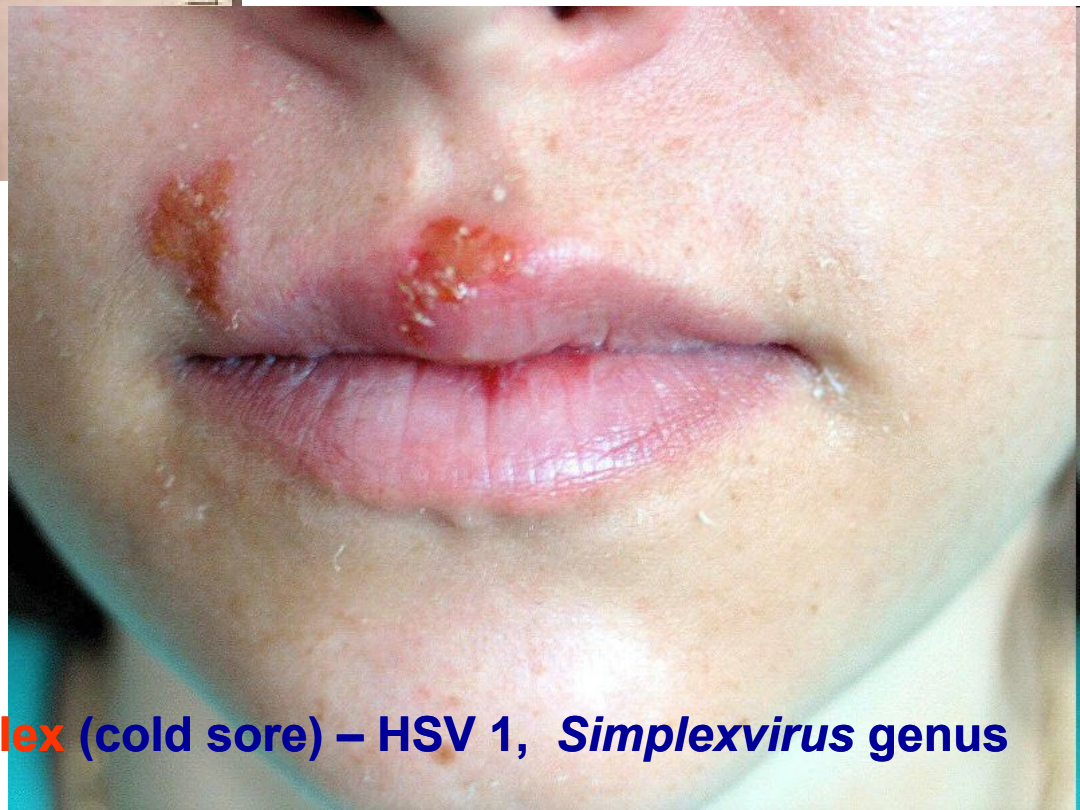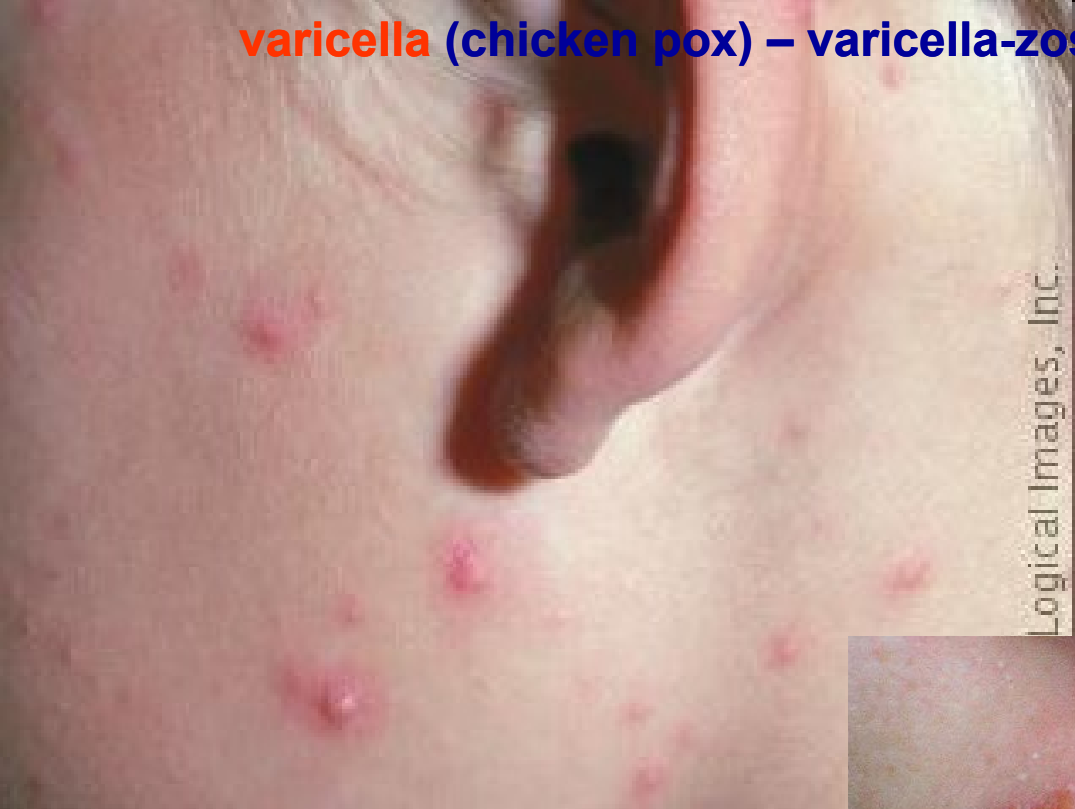varicella (chicken pox) – varicella-zoster virus, VZV, *Varicellovirus* genus

herpes zoster (shingles) – varicella-zoster virus, VZV, *Varicellovirus* genus

variola vera (smallpox) – variola virus, *Orthopoxvirus* genus

(continued)

varicella (chicken pox) – varicella-zoster virus, VZV, *Varicellovirus* genus



herpes simplex (cold sore) – HSV 1, *Simplexvirus* genus

Skin symptoms in viral diseases – III

Vesicles – cont.:

vaccinia – vaccinia virus, *Orthopoxvirus* genus

cowpox and monkey pox – cowpox virus and monkey pox virus, *Orthopoxvirus* genus

tubera mulgentium (milkers' nodules) – milker's nodule virus, *Parapoxvirus* genus

aphthae epizooticae (foot and mouth disease) – foot-and-mouth disease virus, *Aphthovirus* genus

hand, foot and mouth disease – coxsackievirus A16, *Enterovirus* genus

Skin symptoms in viral diseases – IV

Petechiae:

Hemorrhagic fevers –

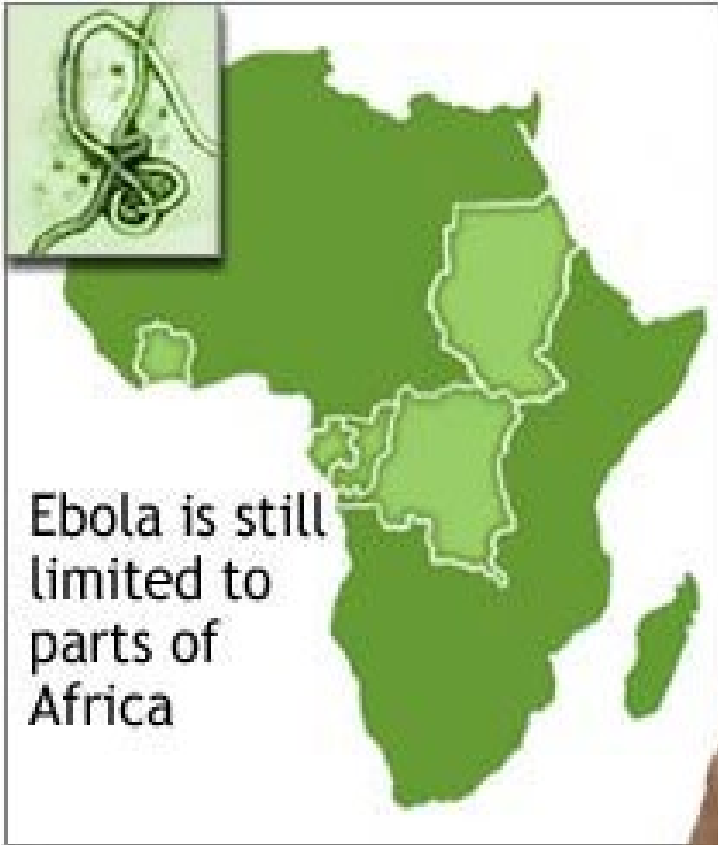Ebola fever, Ebola virus, *Ebolavirus* genus

Marburg disease, Marburg virus, *Marburgvirus* genus

Lassa fever, Lassa virus, *Arenavirus* genus

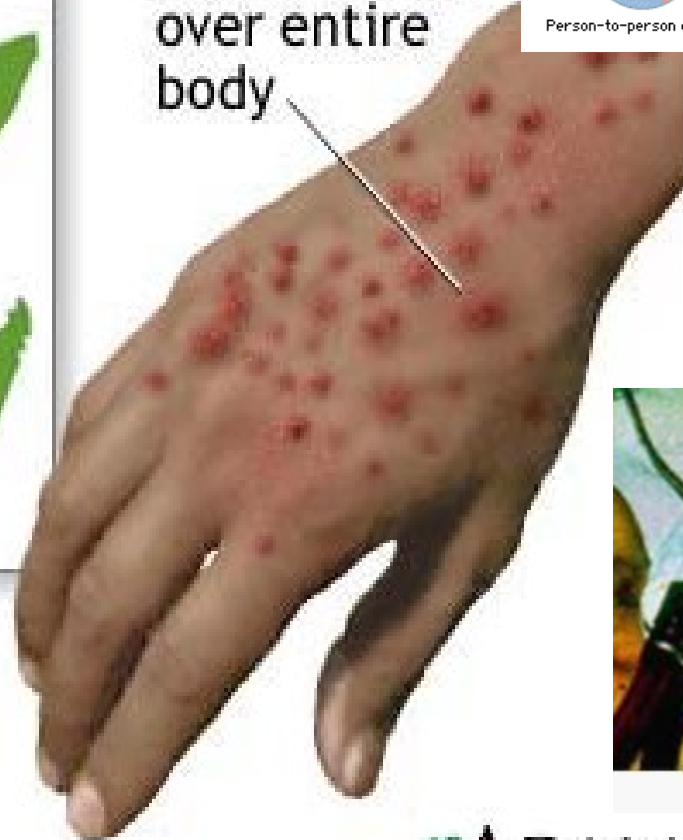Generalized congenital cytomegalic disease –

cytomegalovirus, CMV, *Cytomegalovirus* genus

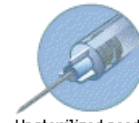

Ebola is still limited to parts of Africa

A hemorrhagic rash appears over entire body



Modes of Infection



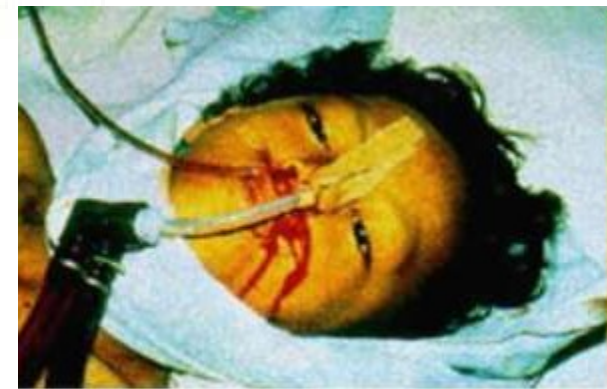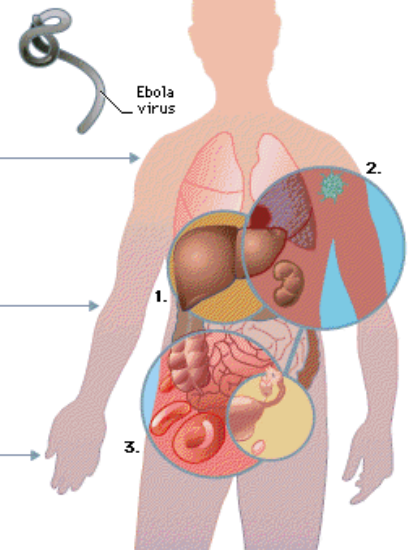
Unsterilized needles



Hospital contagion



Person-to-person contact



Ebola Patient (Intensive Care)

Parasitic infections

Skin symptoms in parasitoses – I

Domestic parasitoses:

scabies – itch mite, *Sarcoptes scabiei*

pediculosis capitis – head louse, *Pediculus capitis*

pediculosis corporis – body louse, *Pediculus humanus* (syn. *Pediculus corporis*)

pediculosis pubis (phthiriasis) – pubic (crab) louse, *Phthirus pubis*

Skin symptoms in parasitoses – II

Infestation by native ectoparasites:

cimicosis, urticaria cimicosa – bites by bedbug
Cimex lectularius

pulicosis – bites by human flea *Pulex irritans*,
dog flea *Ctenocephalides canis*,
cat flea *Ctenocephalides felis*,
chicken flea *Ceratophyllus gallinae*

trombiculosis, trombidiosis – bites by larvae
Neotrombicula autumnalis

Skin symptoms in parasitoses – III

Tropical parasitoses:

ulcus humidum (humid ulcer) – *Leishmania major*

ulcus siccum (dry ulcer) – *Leishmania tropica*

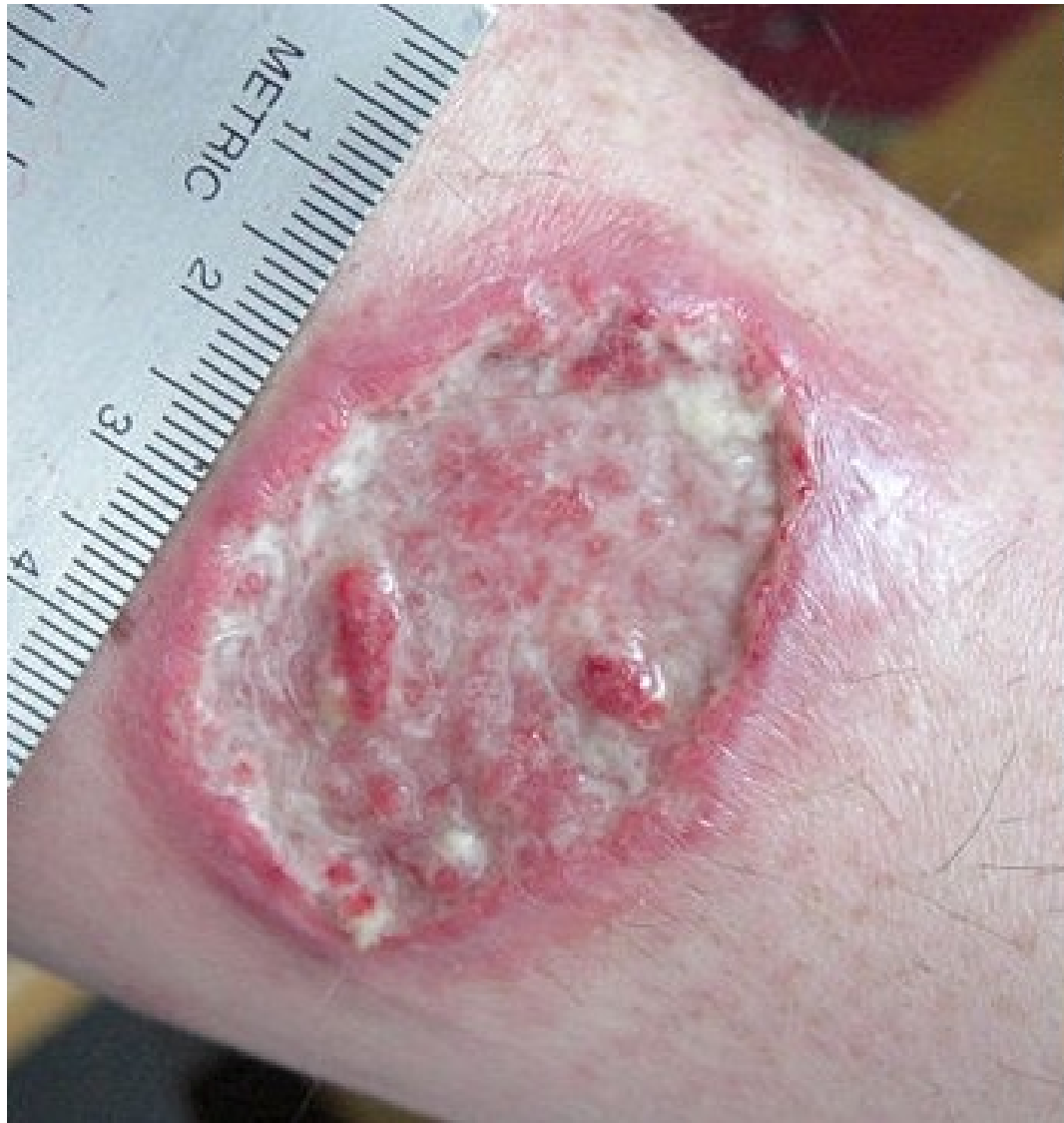espundia – *Leishmania braziliensis*

tungosis – chigoe flea *Tunga penetrans*

dermatitis cercariosa – cercariae of *Schistosoma*,
Bilharziella and *Trichobilharzia* genera

dracunculosis – *Dracunculus medinensis*

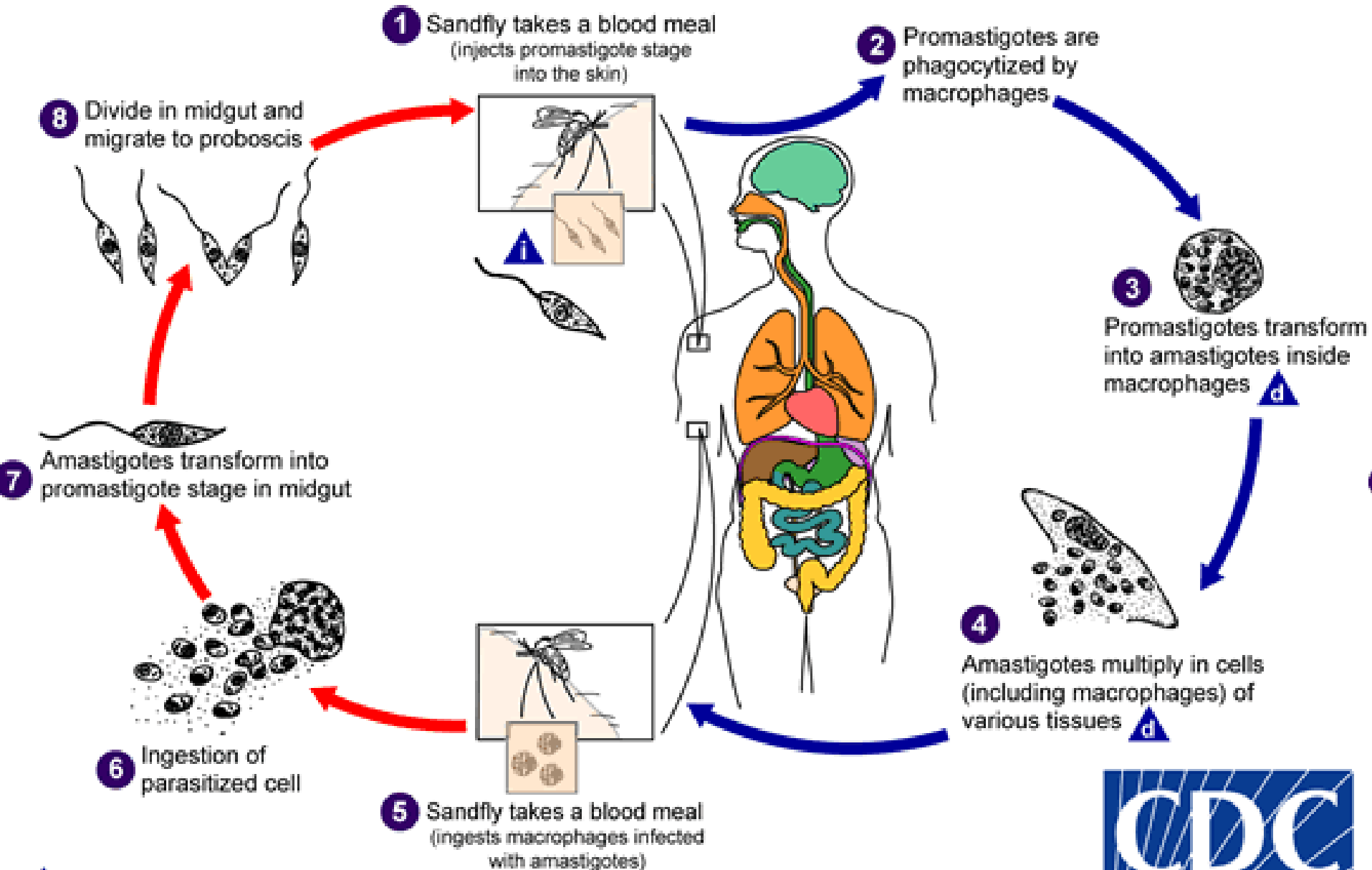
filariosis – filariae *Loa loa* and *Onchocerca volvulus*



Leishmaniasis

Sandfly Stages

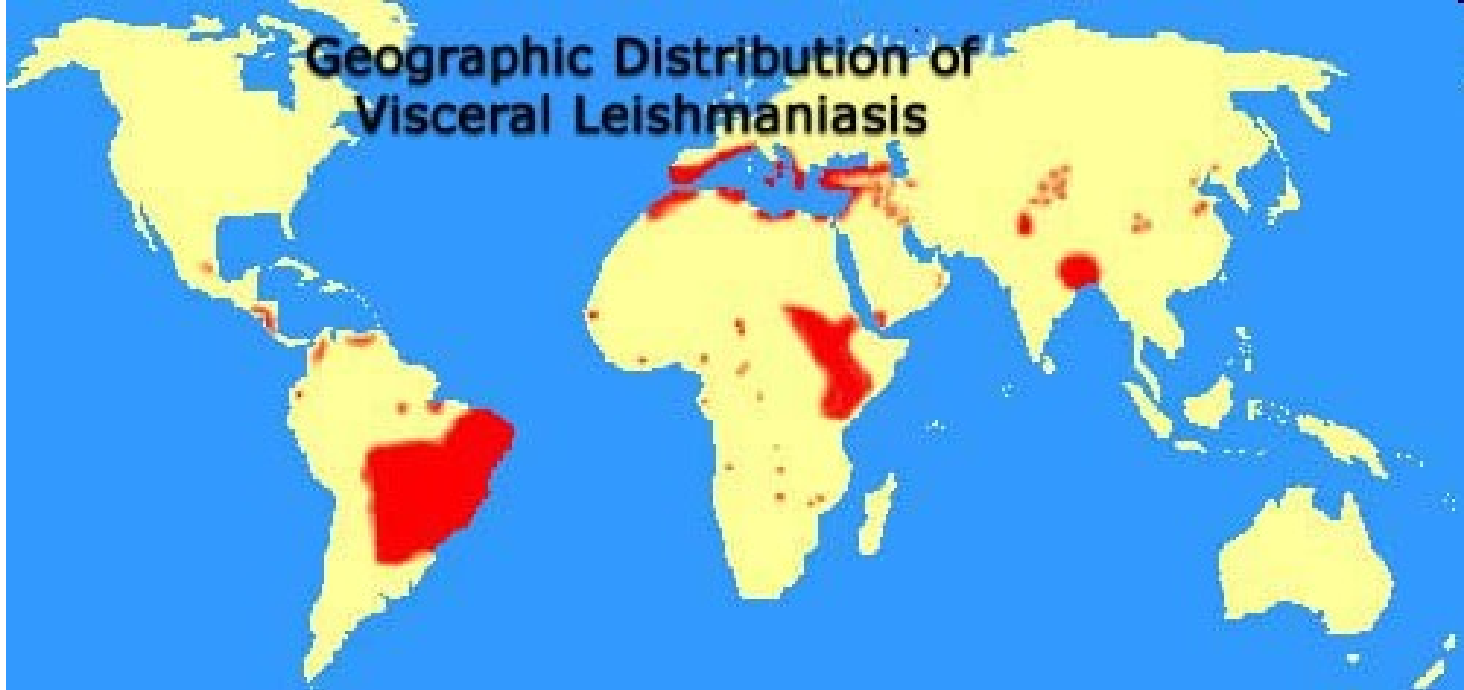Human Stages



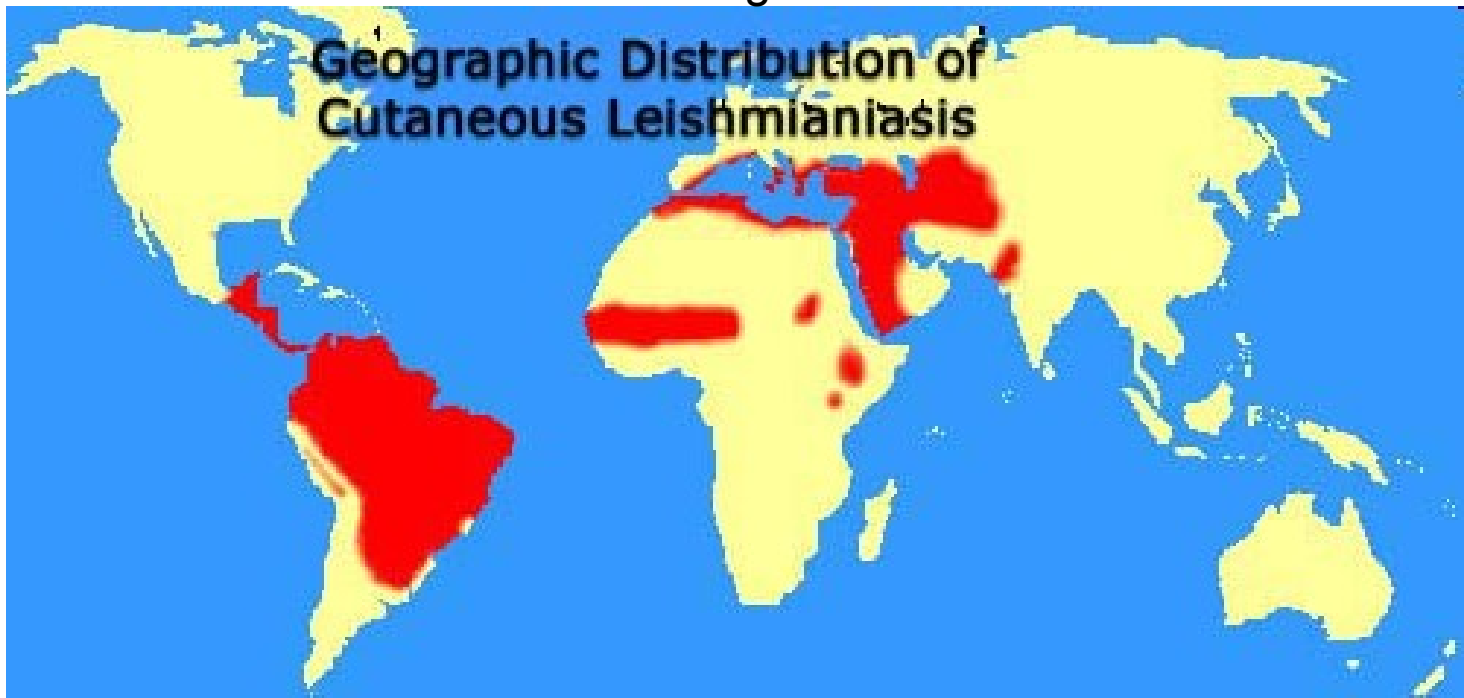
i = Infective Stage

d = Diagnostic Stage





www.vet.uga.edu



Homework 7 – solution

Edvard Munch (1863-1944):
Death in a Room



Homework

8

Please give the name
of the author and of
the painting

