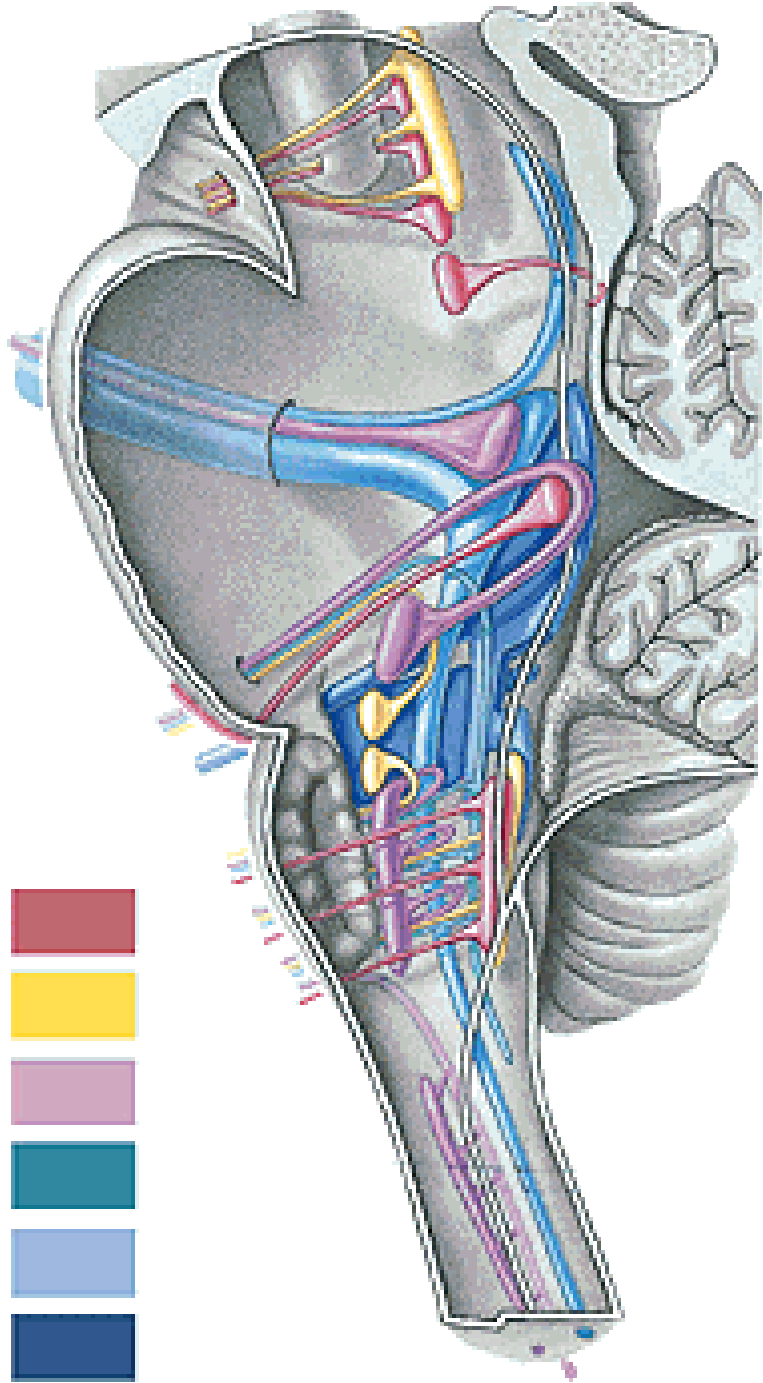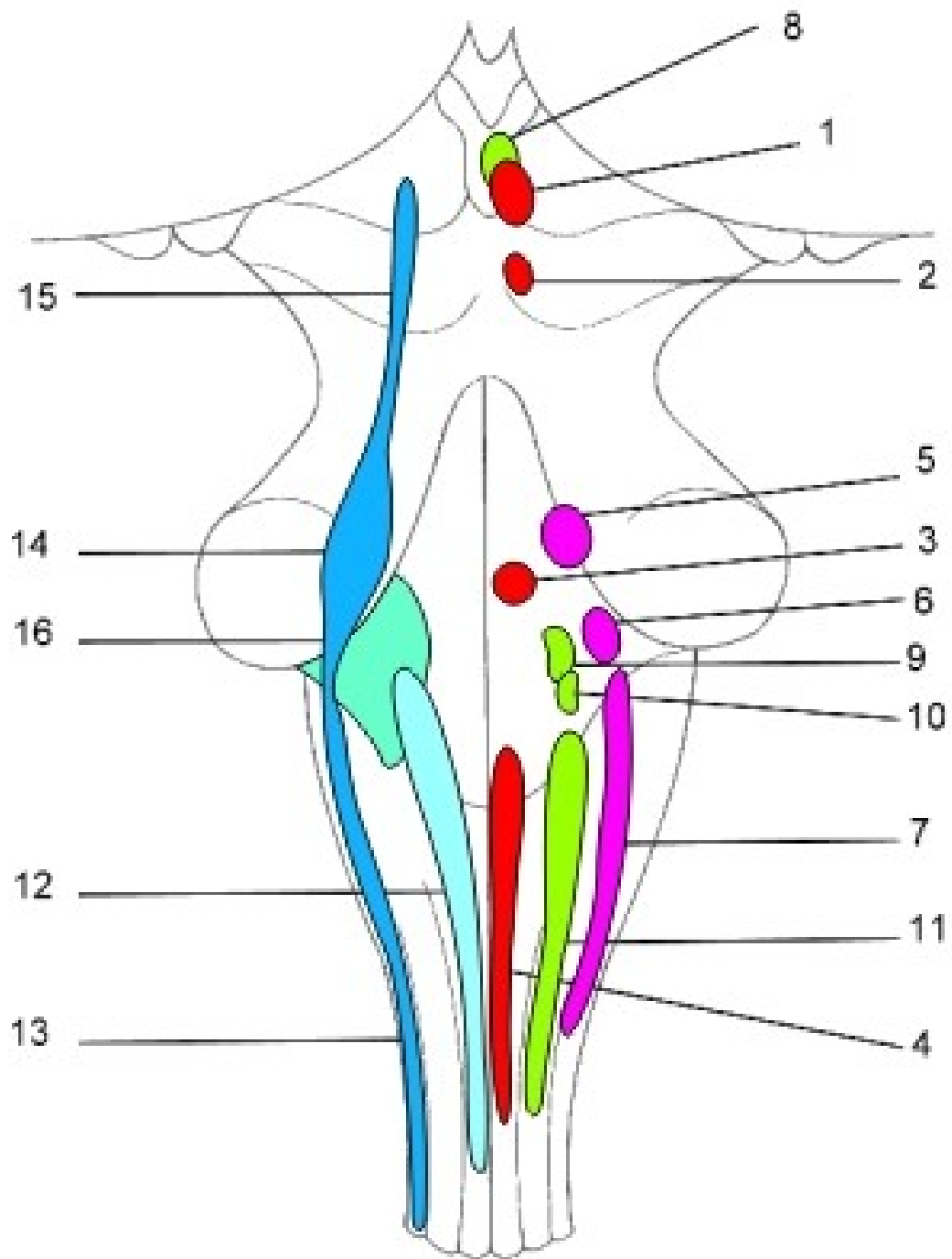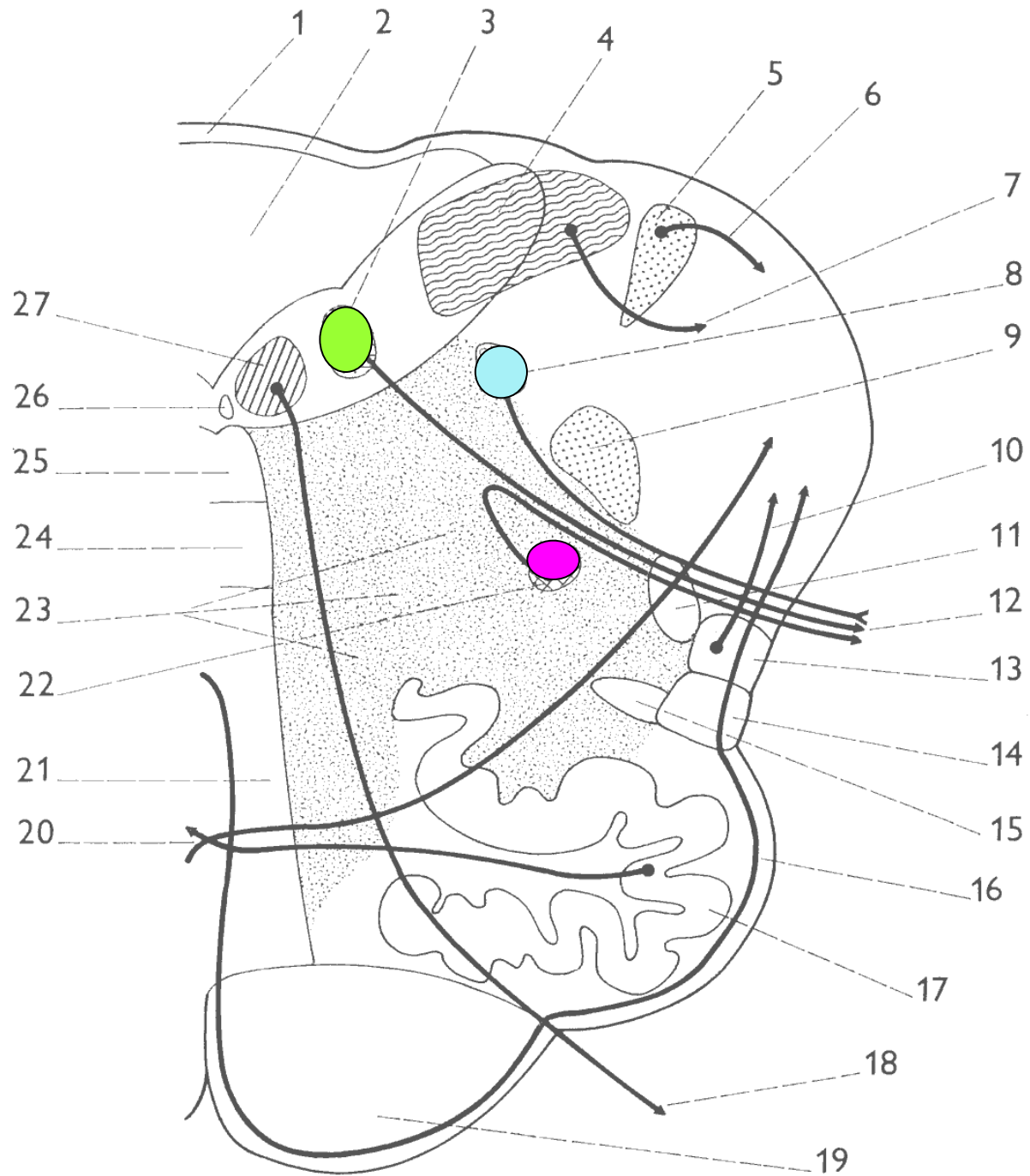
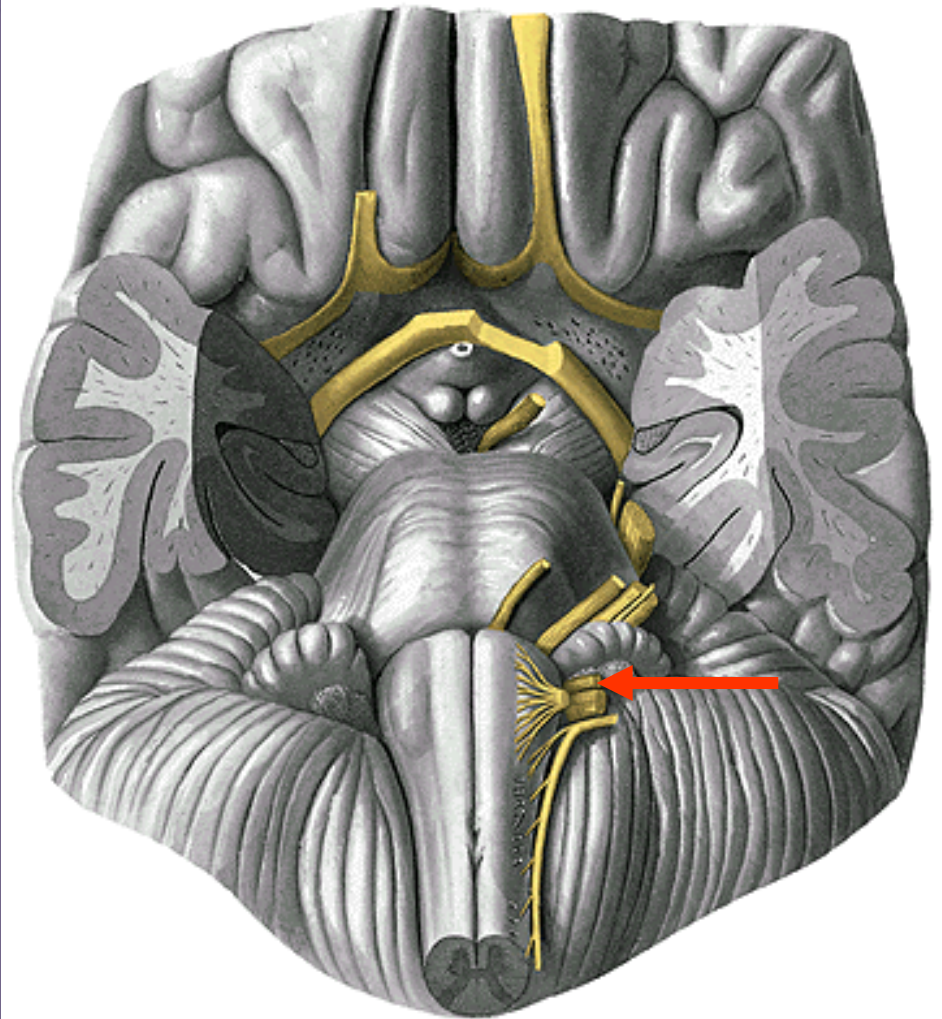
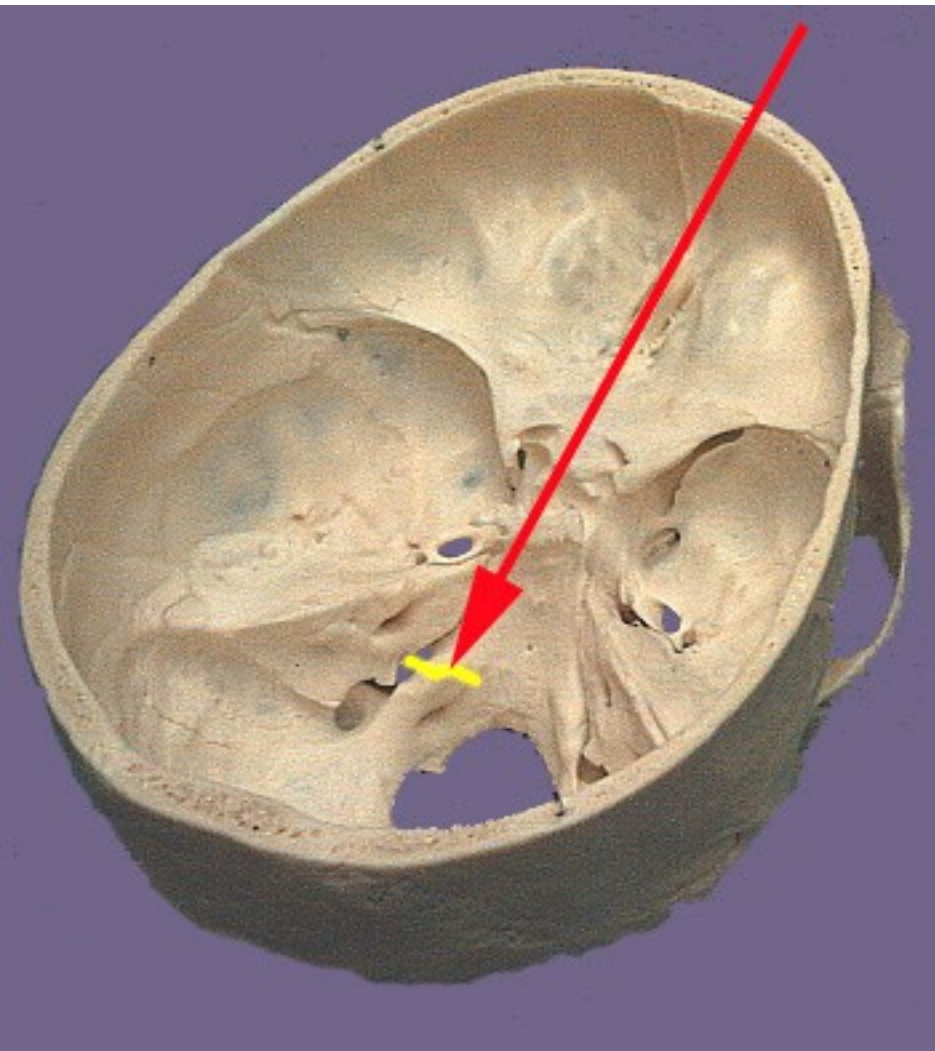


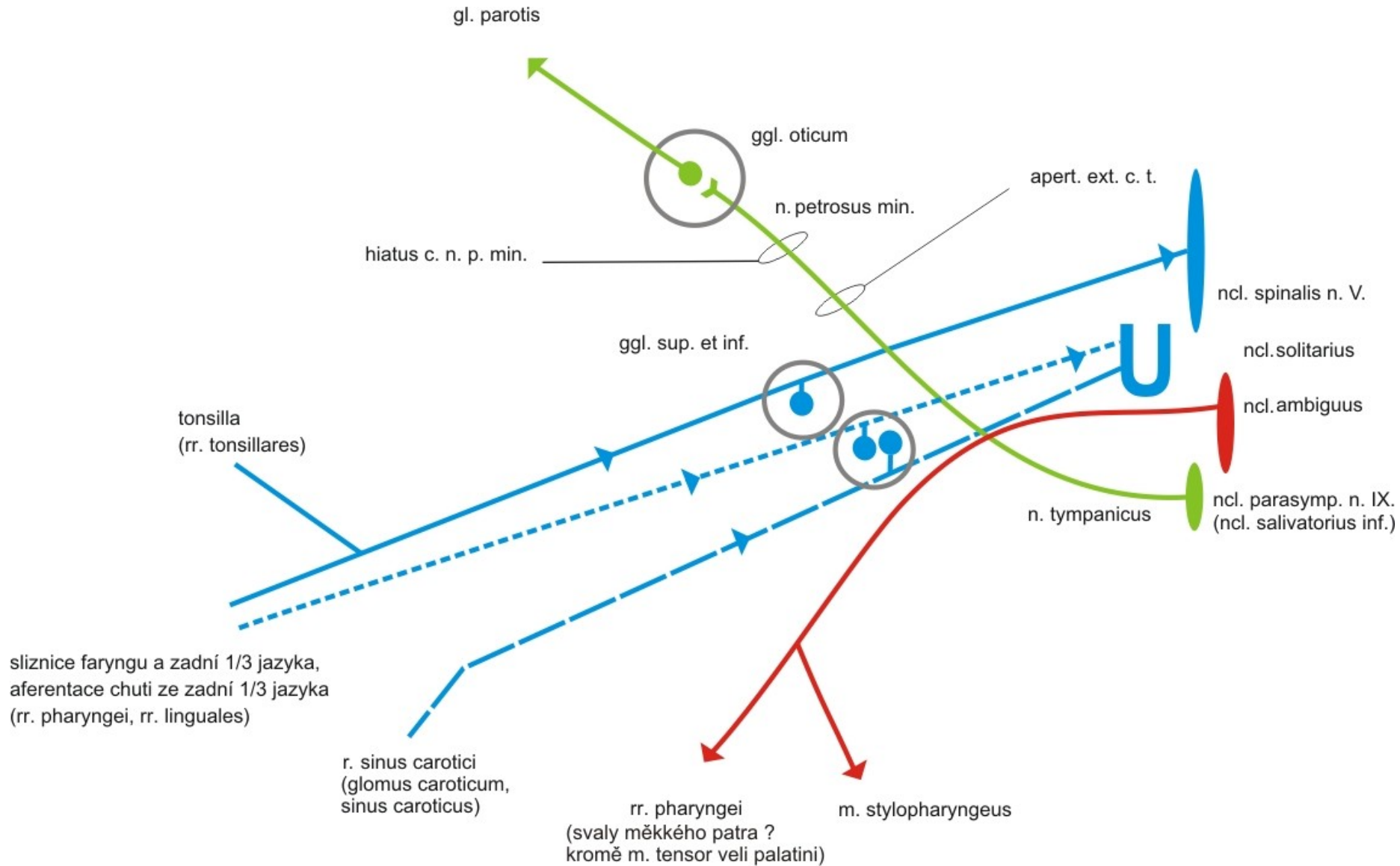
CN IX





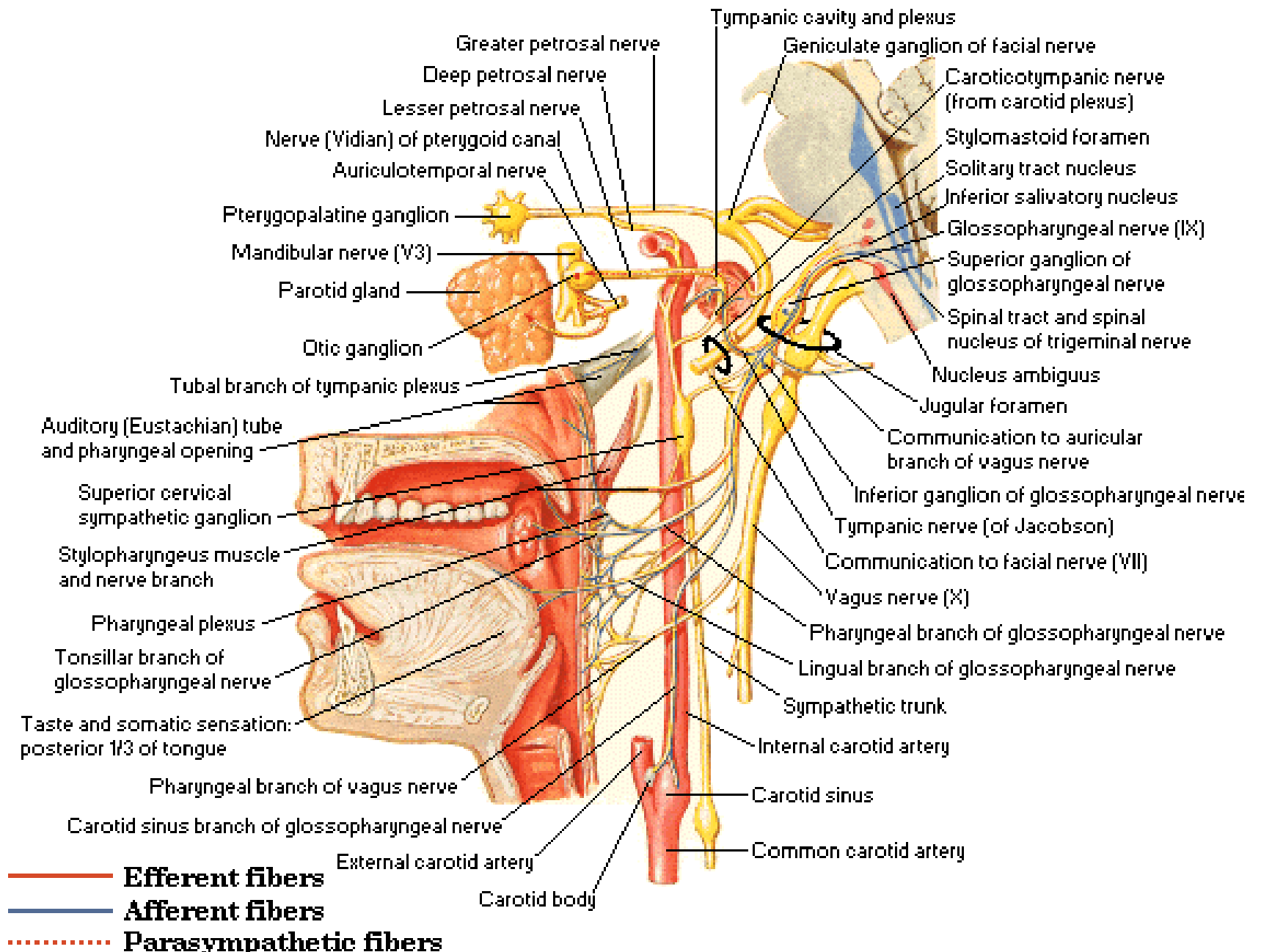
CN IX

n. IX.

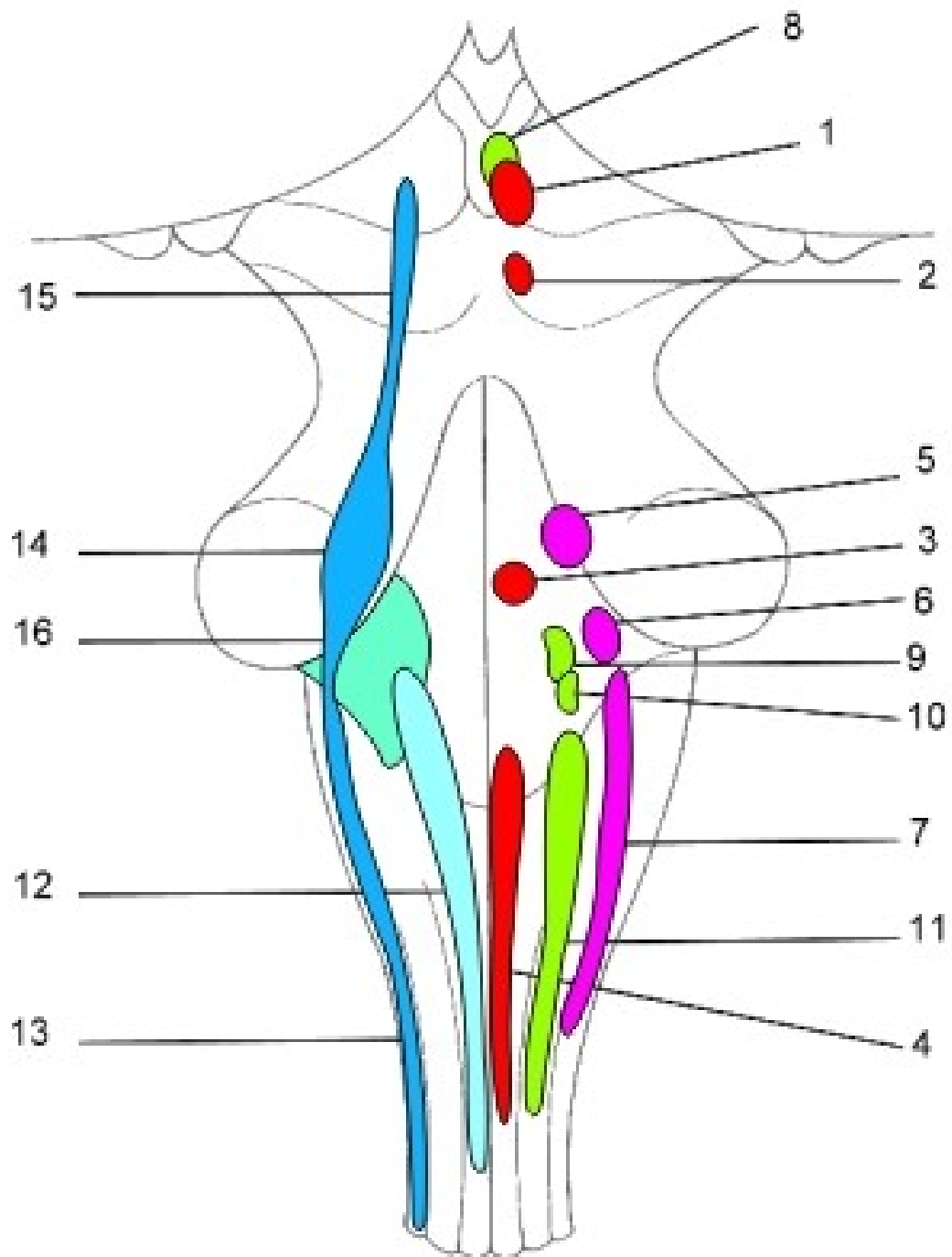


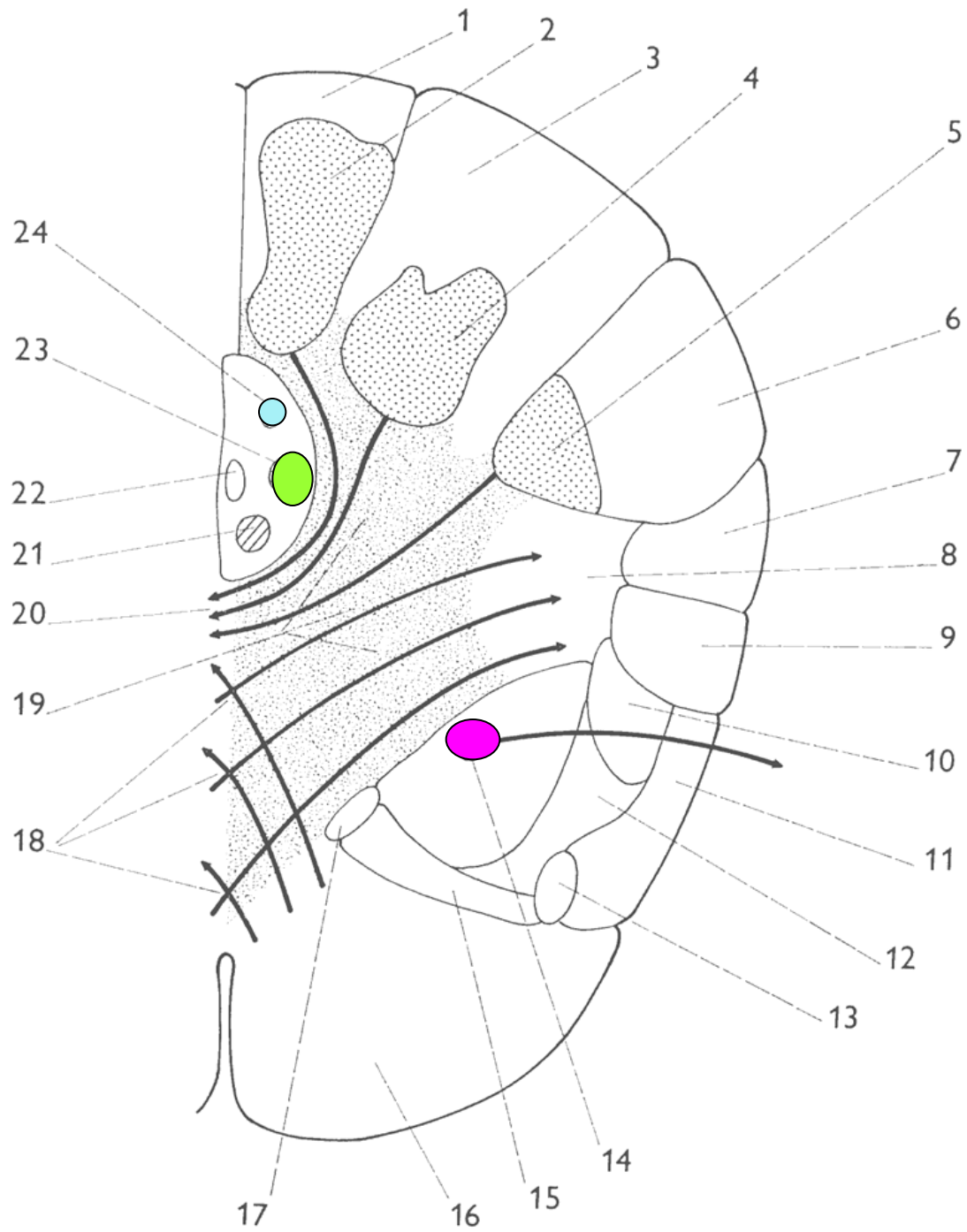
Glossopharyngeal Nerve

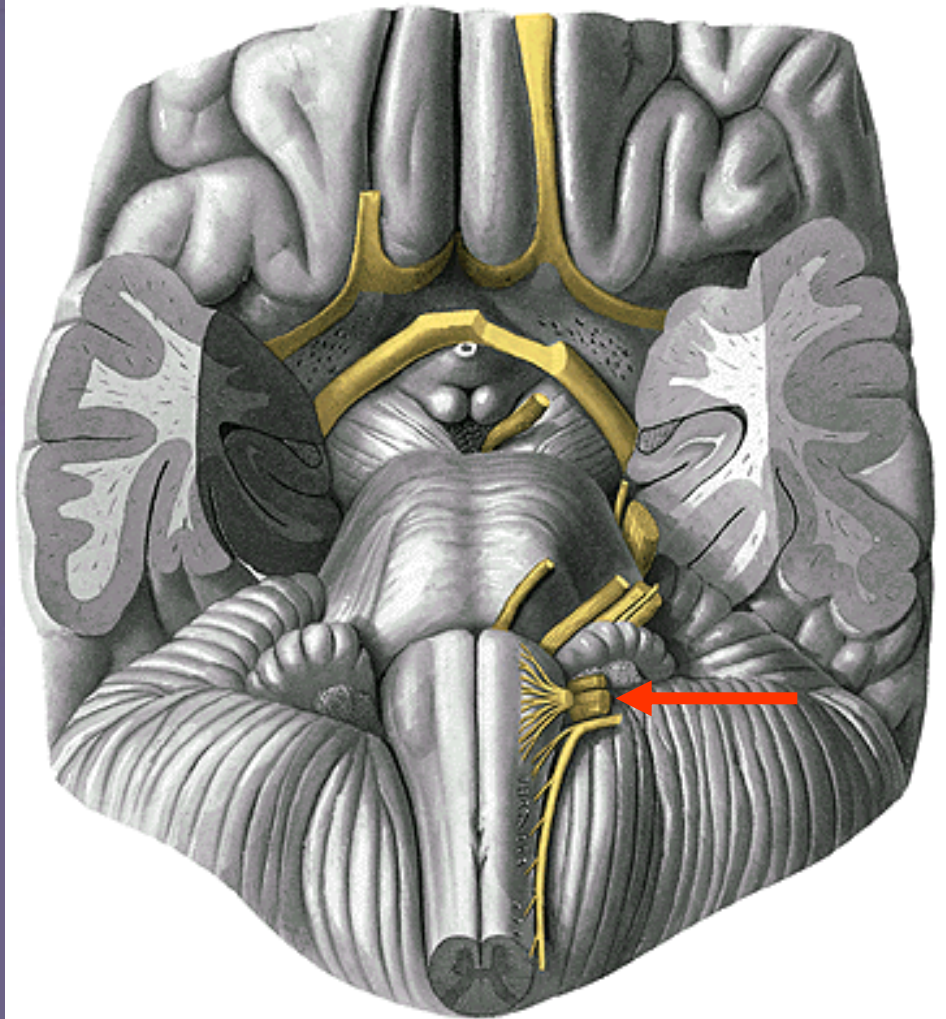
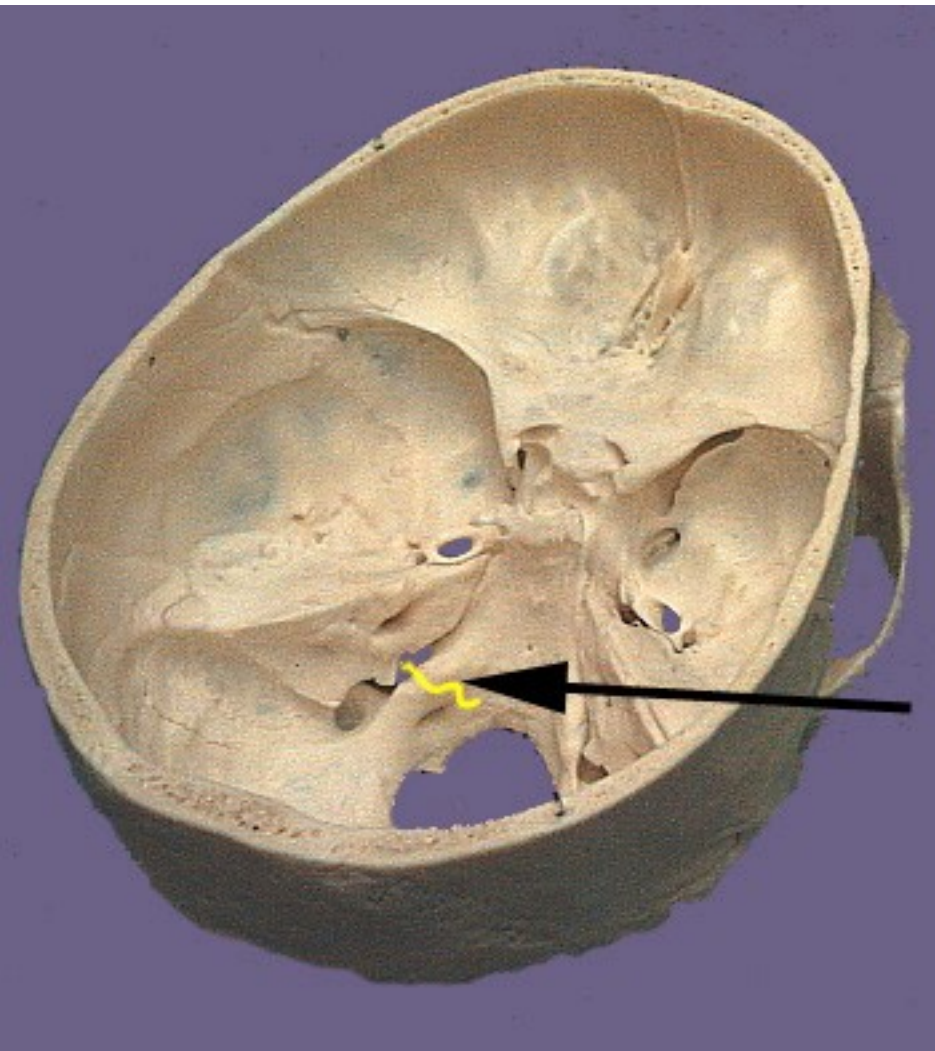
Schema



CN X

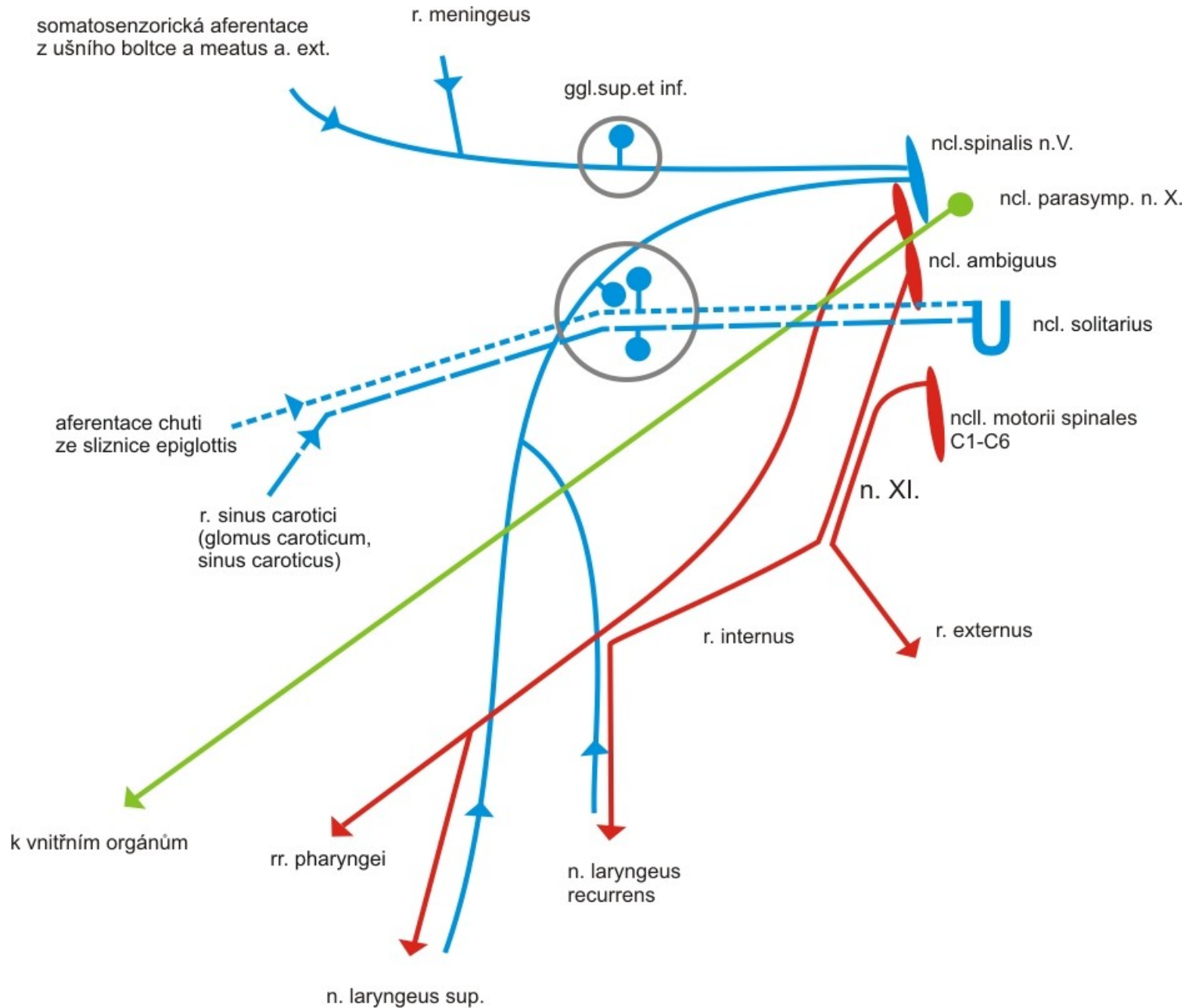


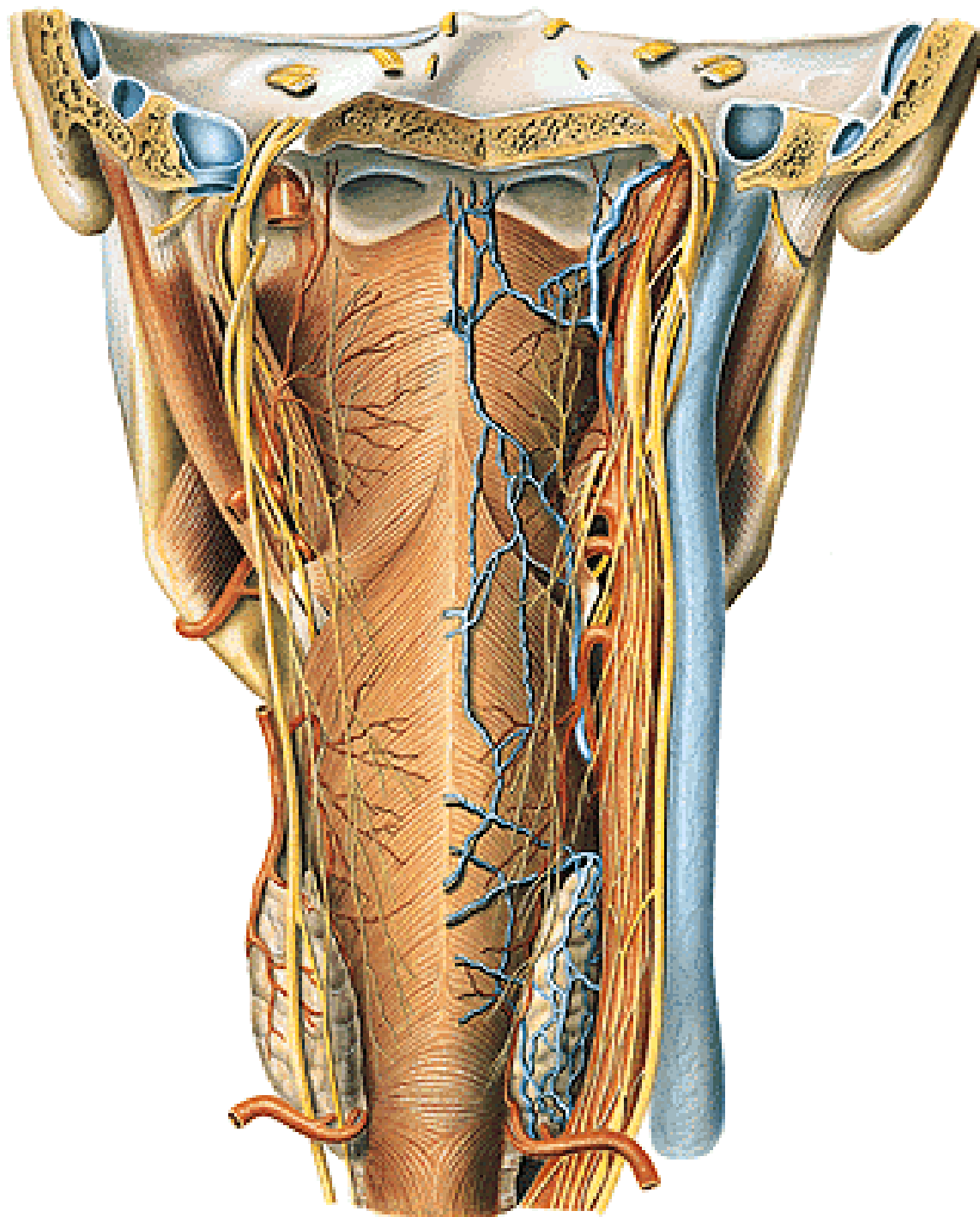


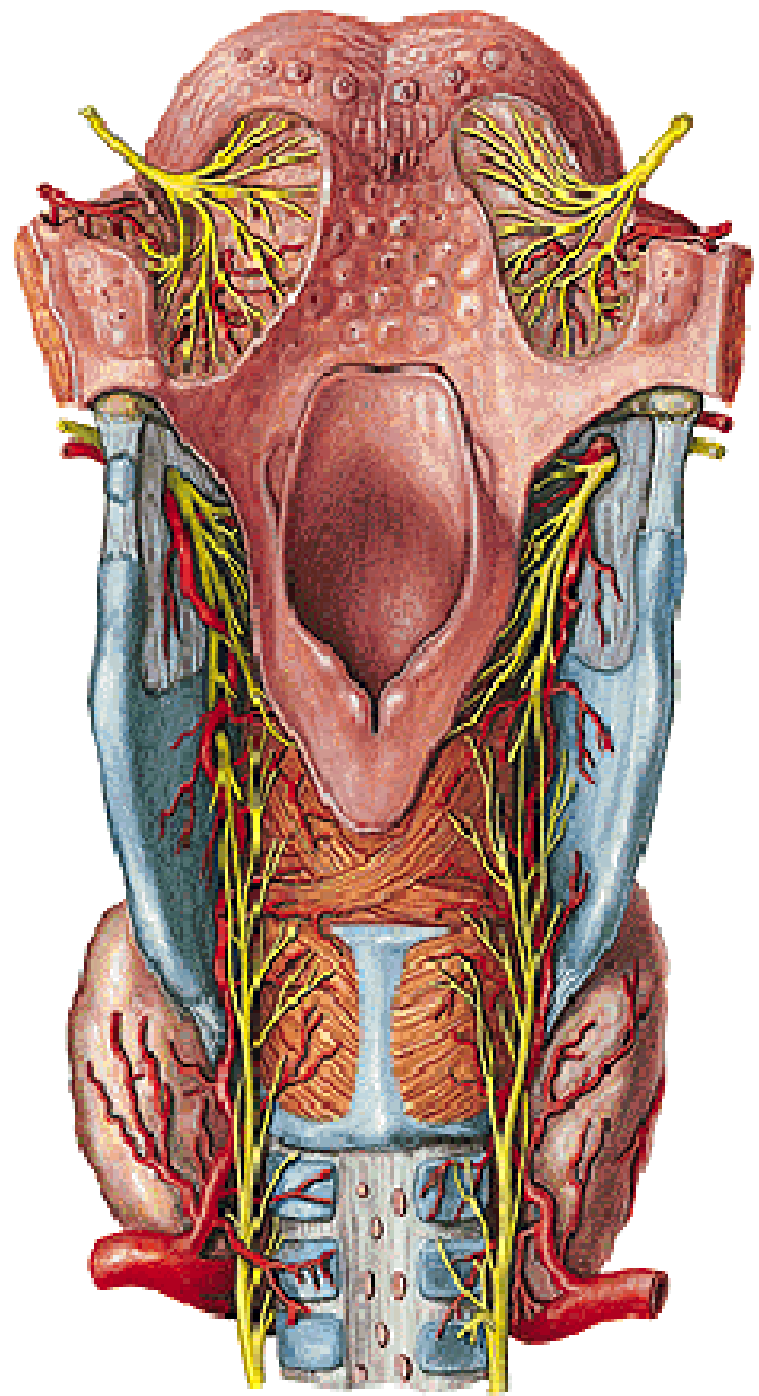
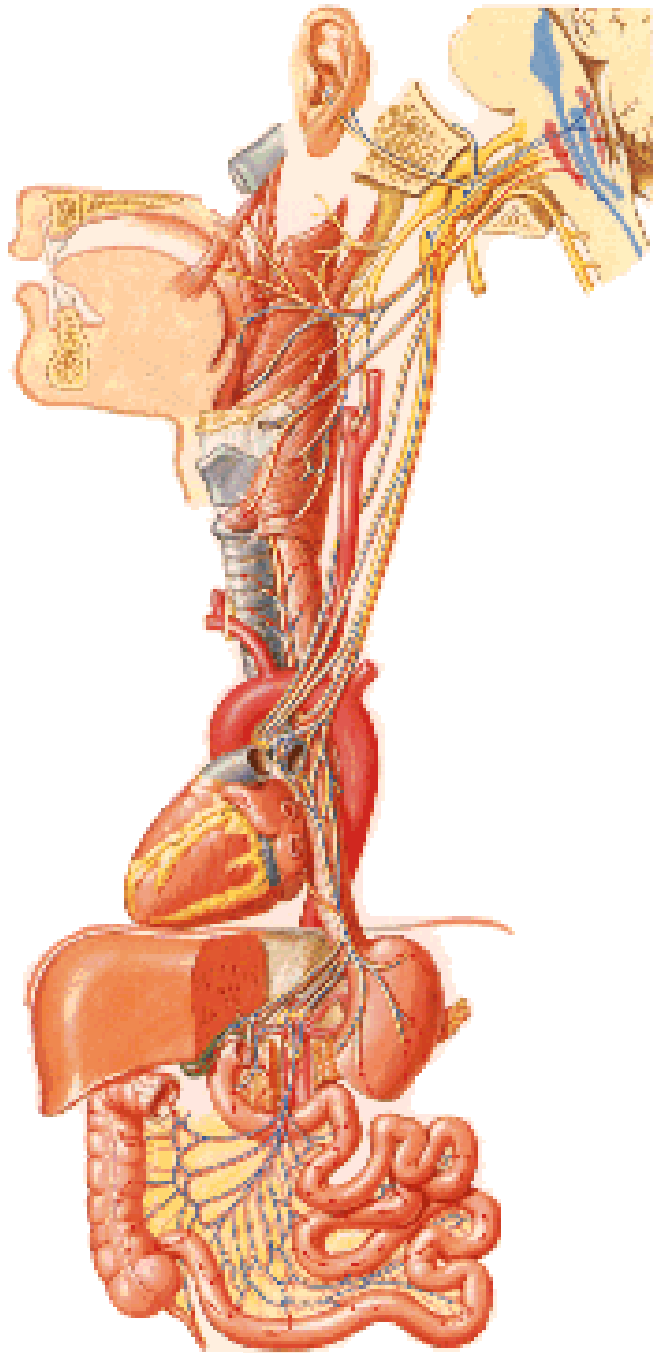


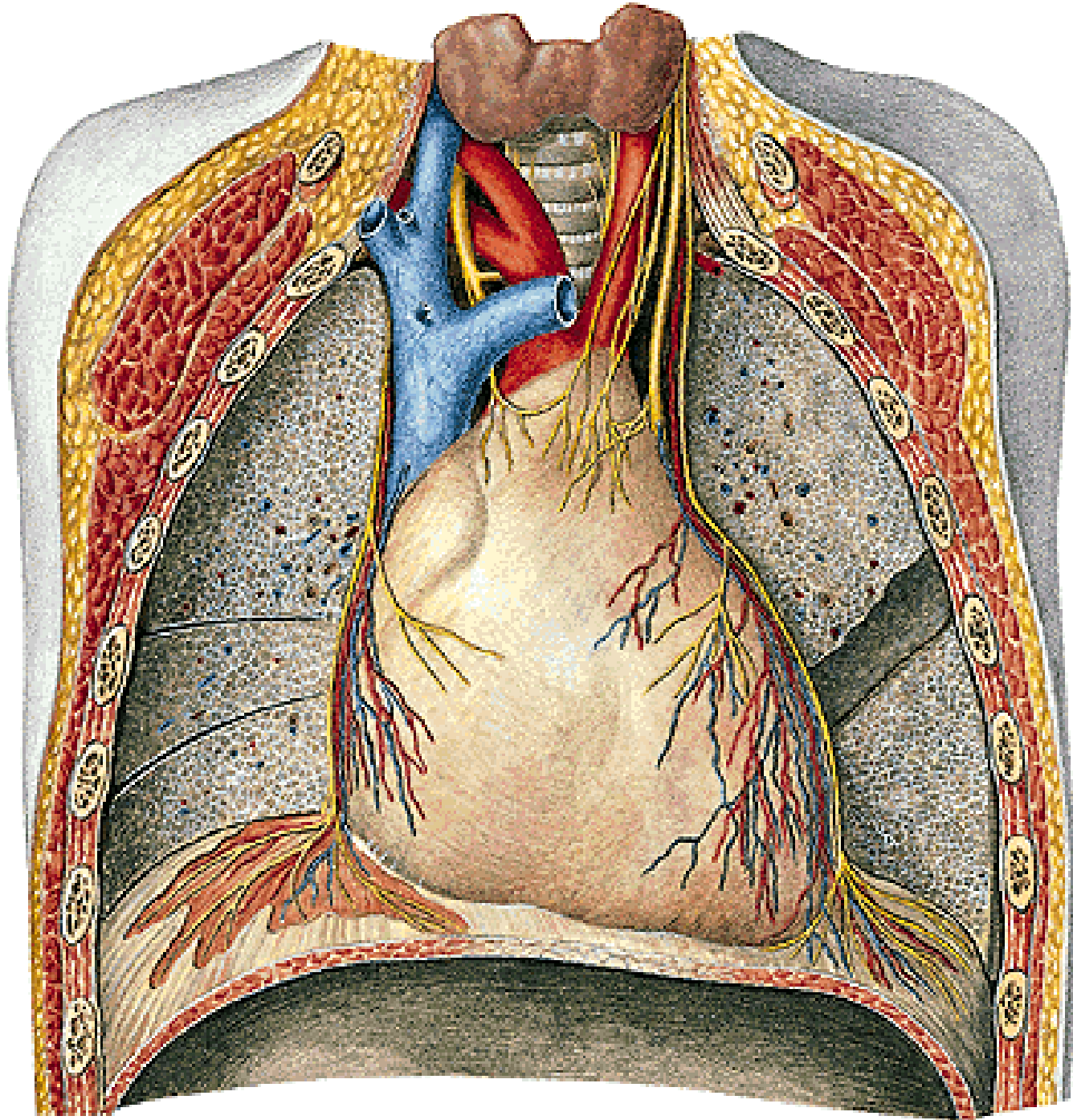
CN X

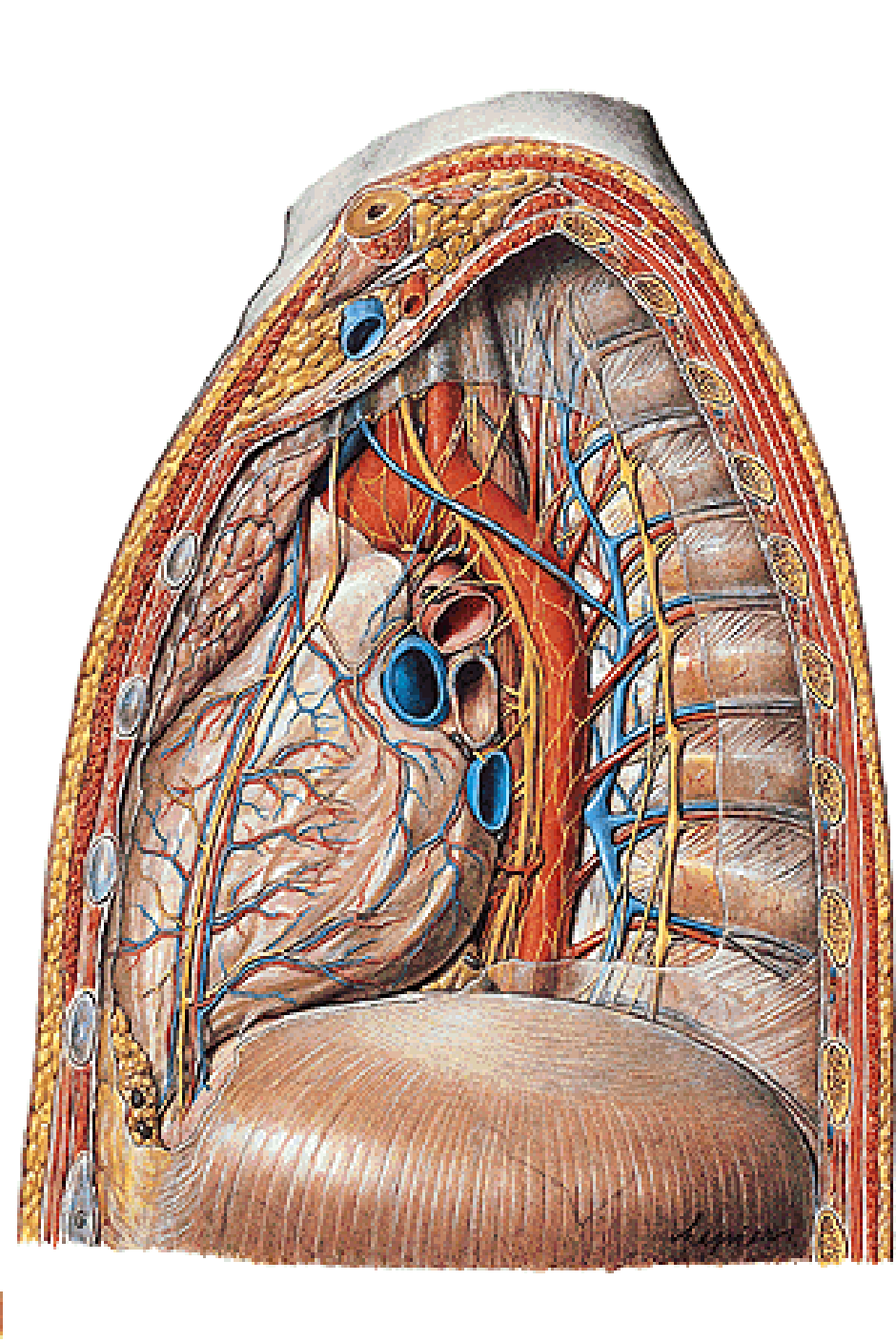
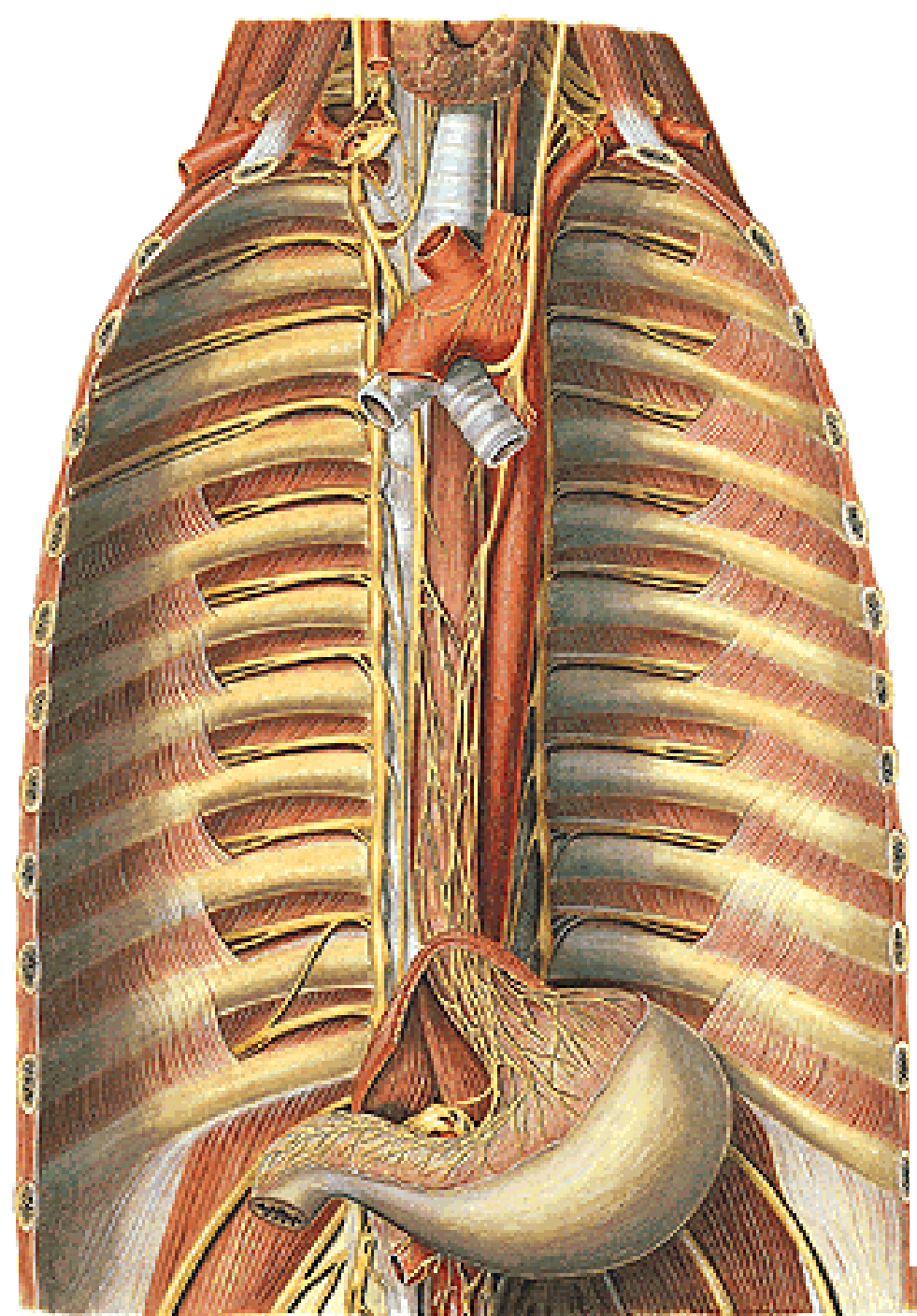
CN X



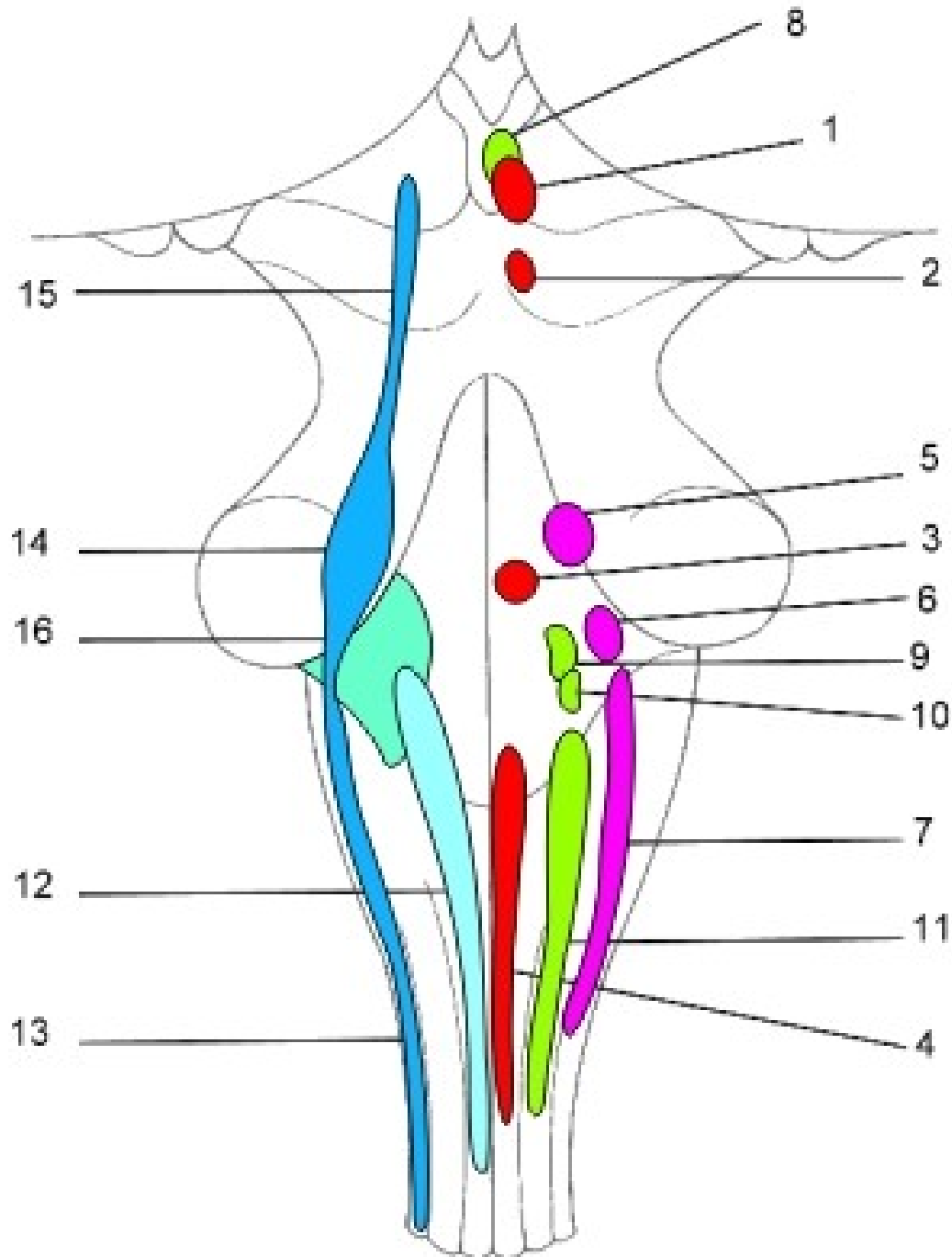


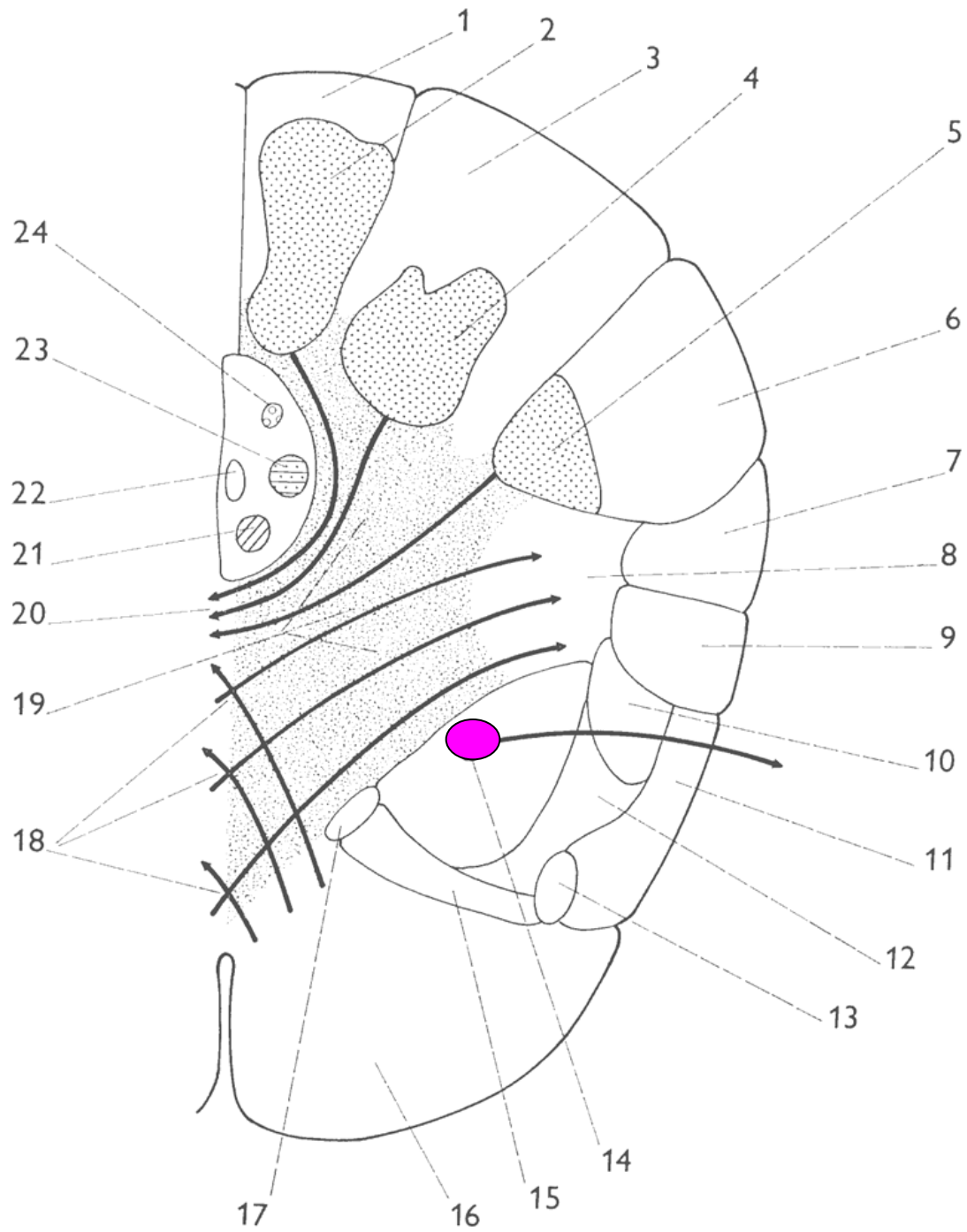




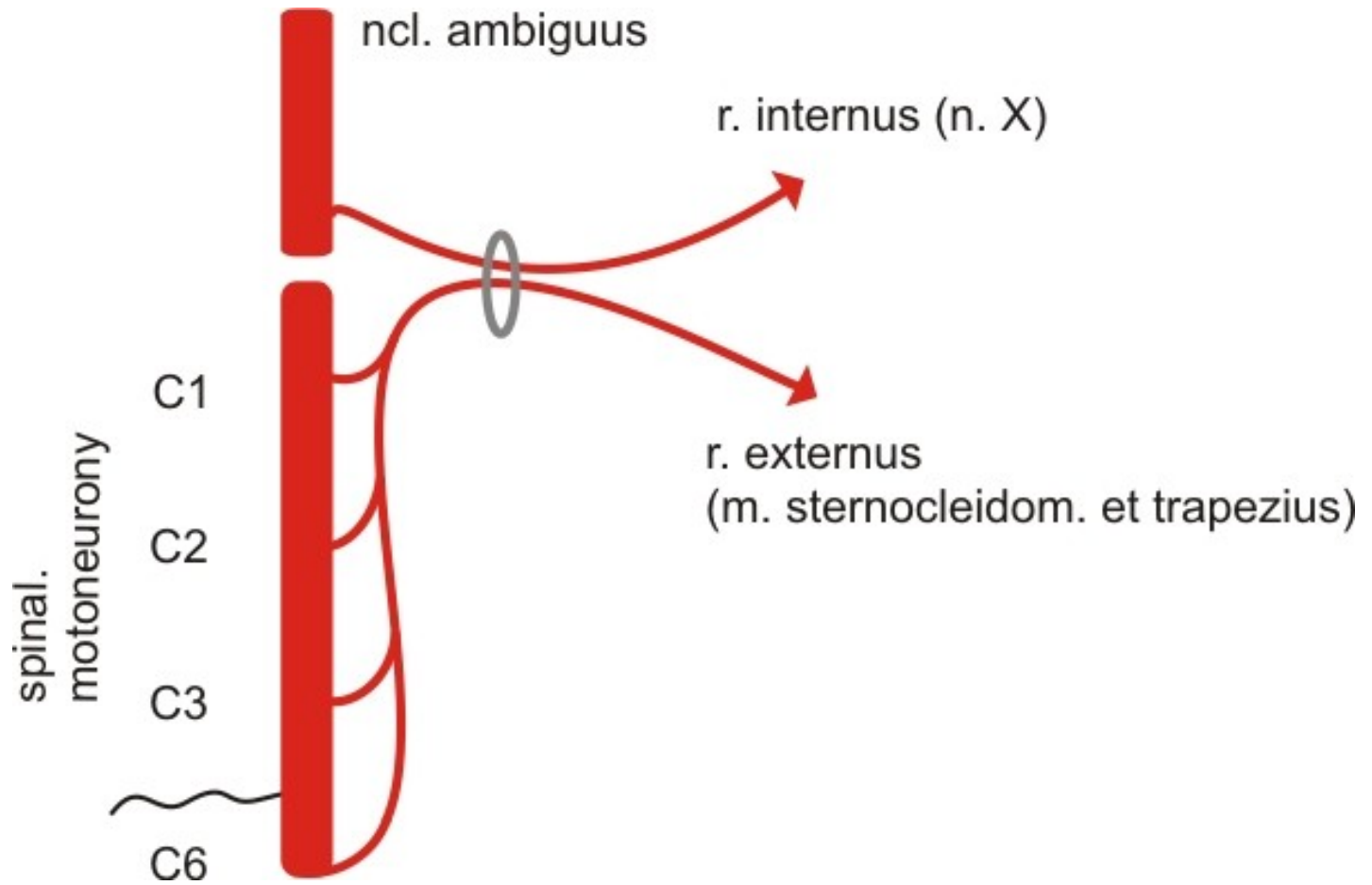


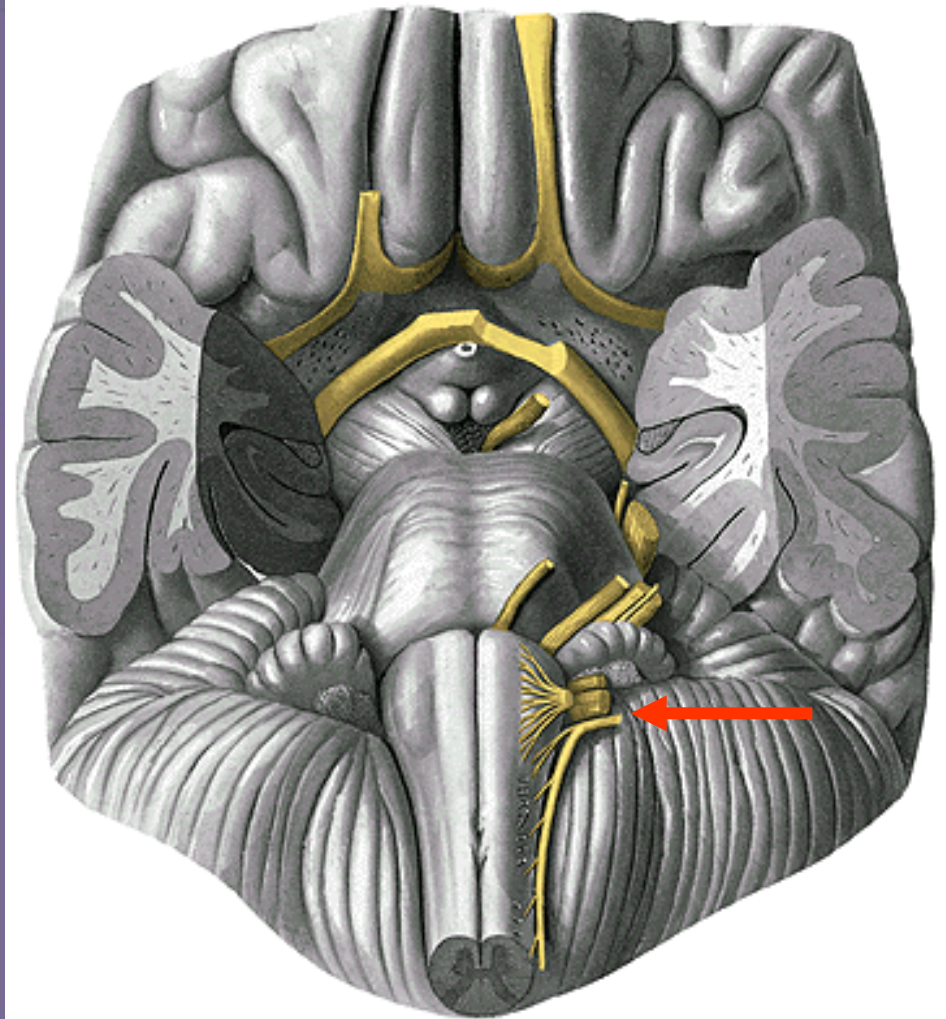
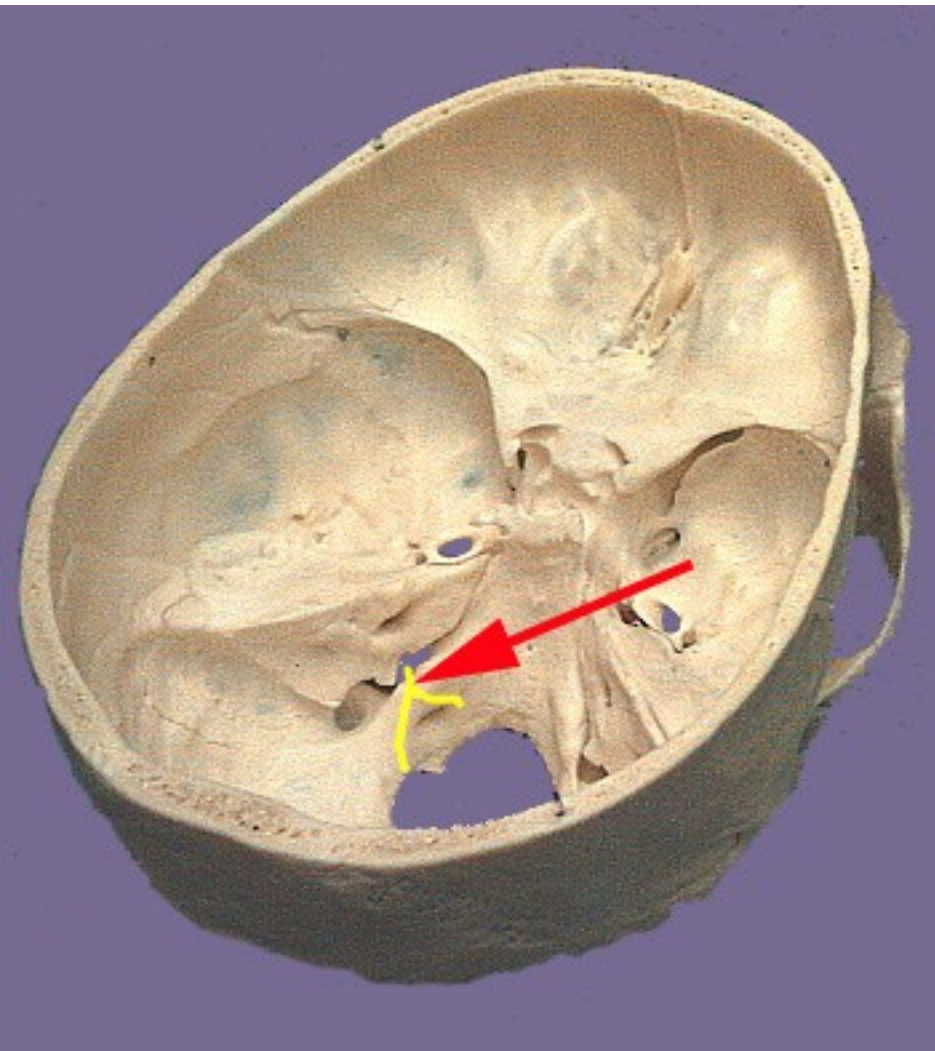
CN XI



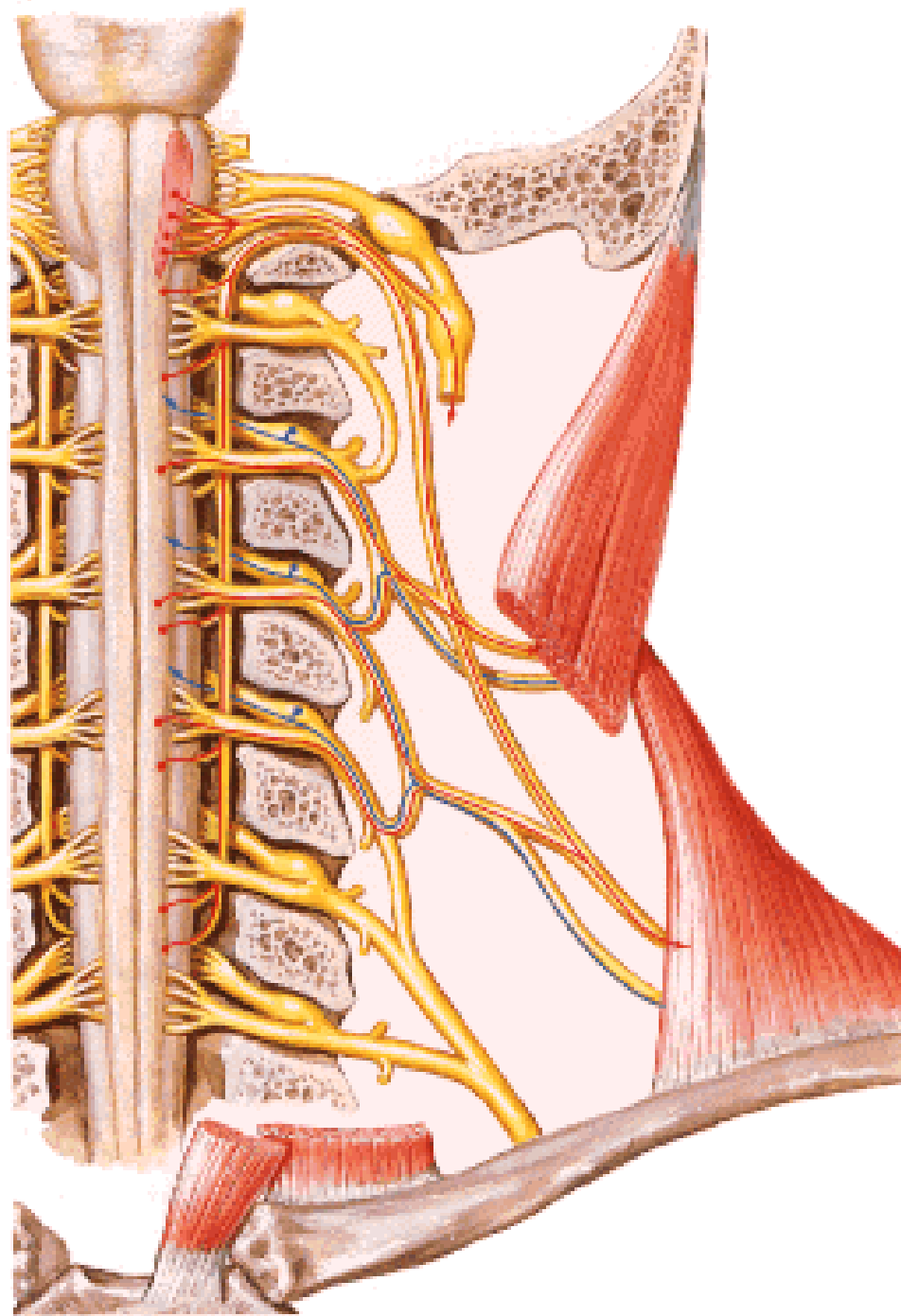


n. XI.

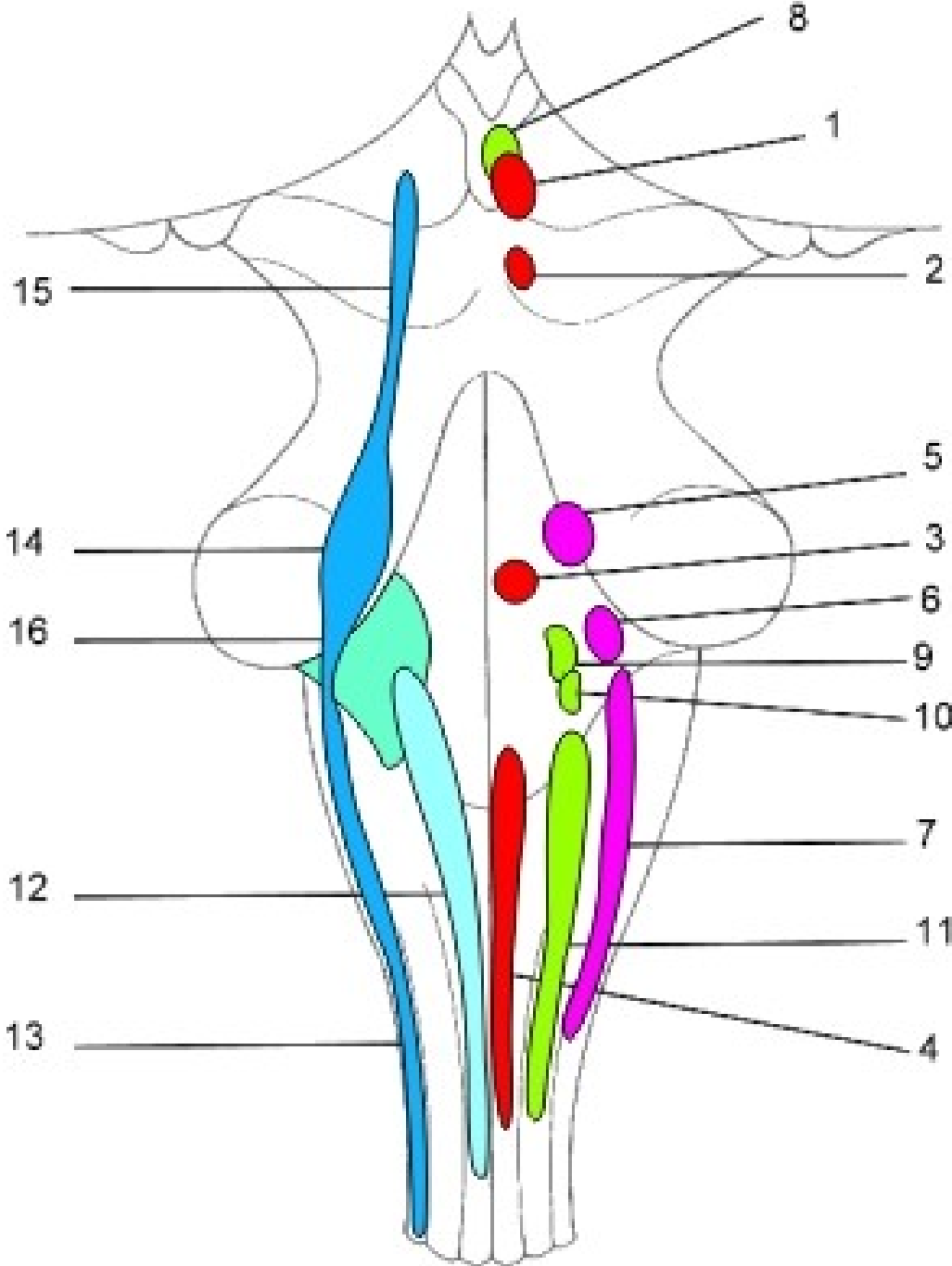


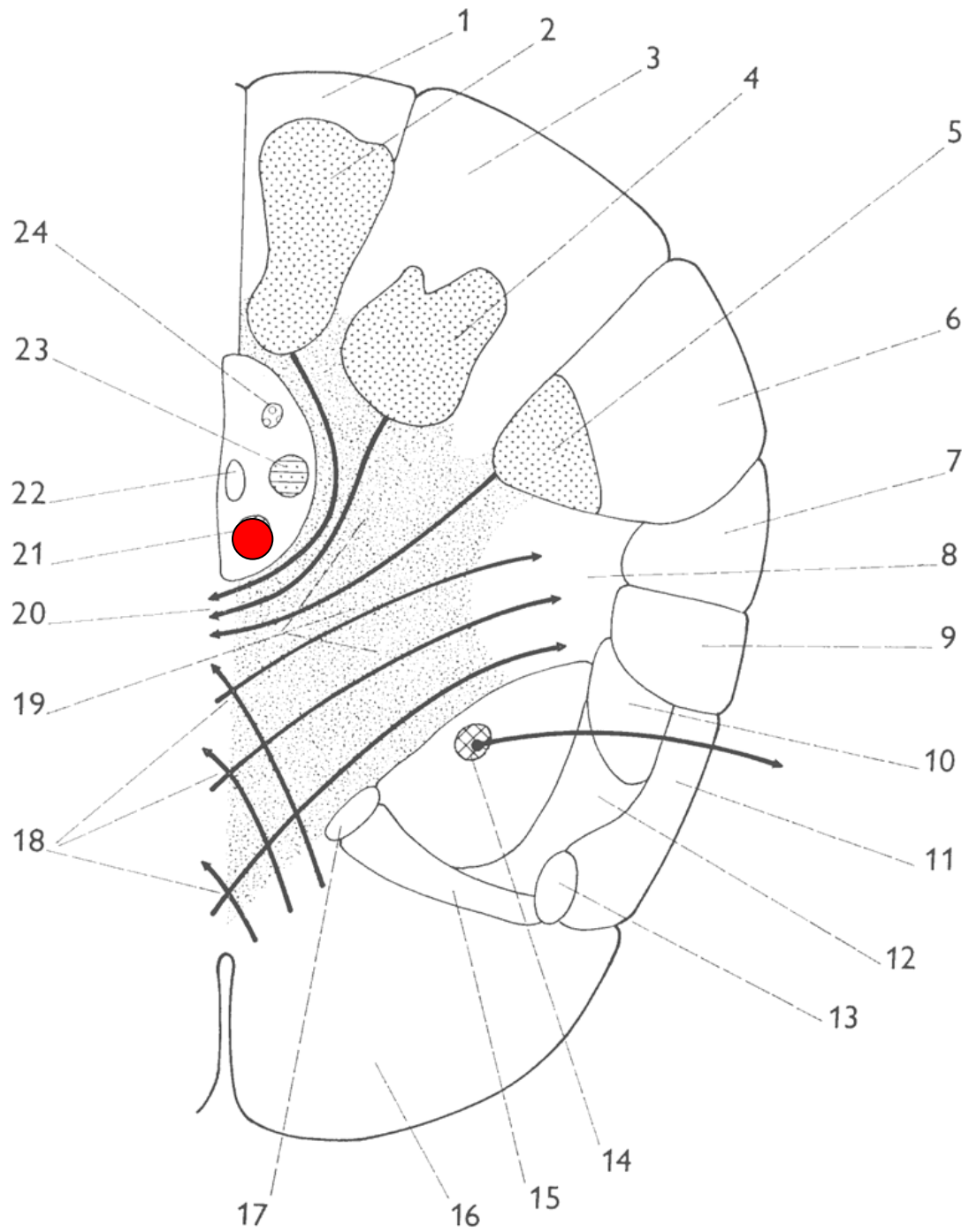


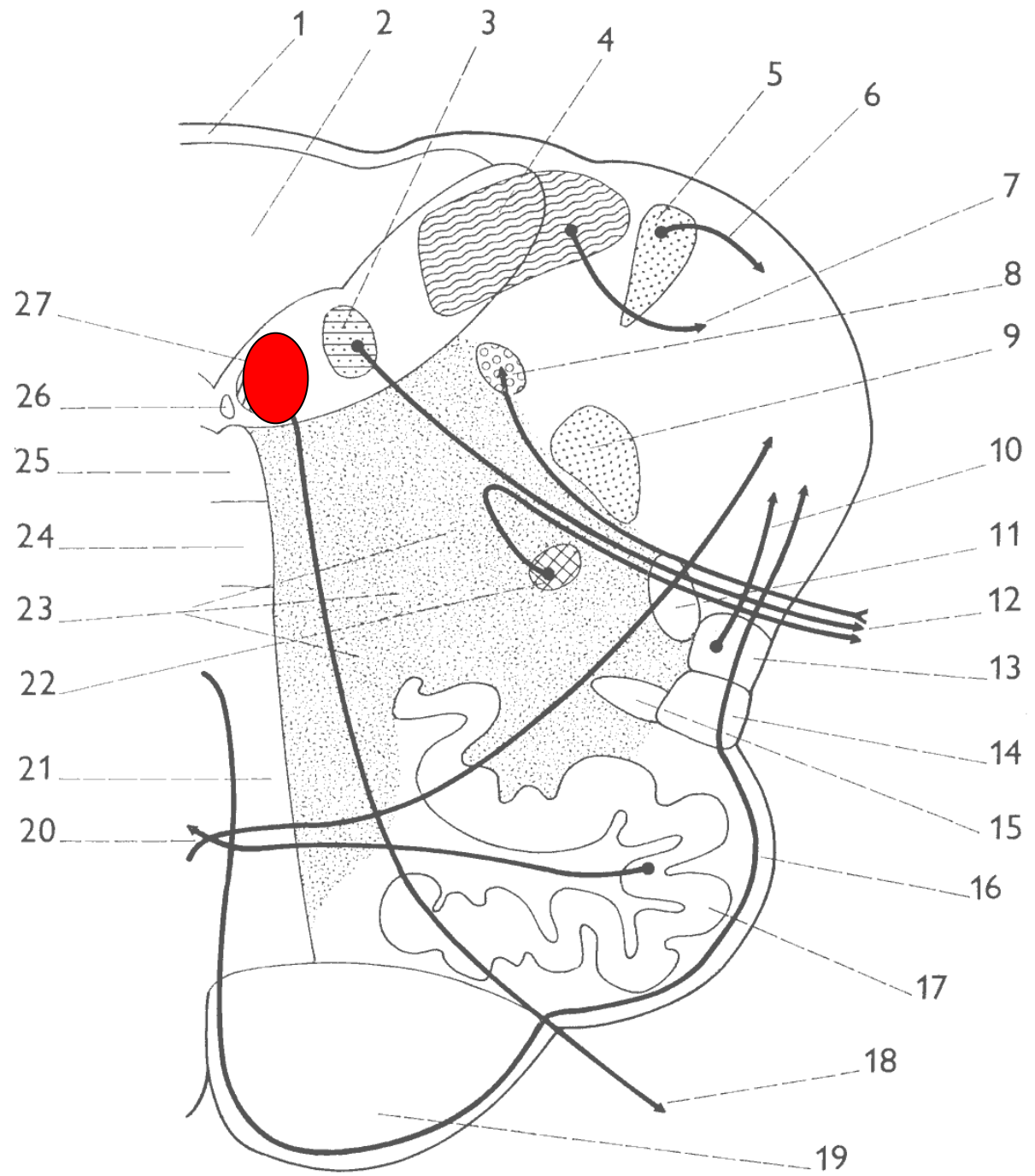
n. XI.

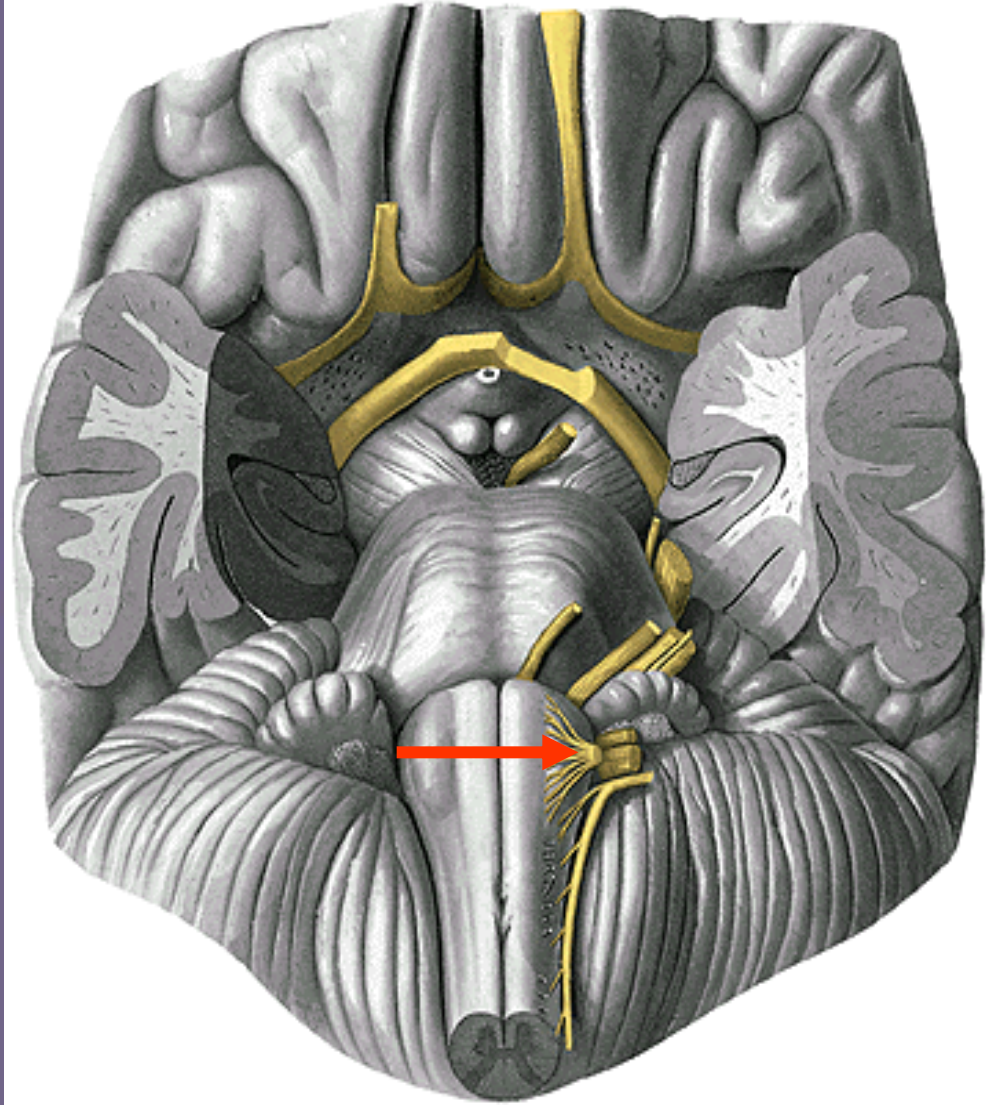
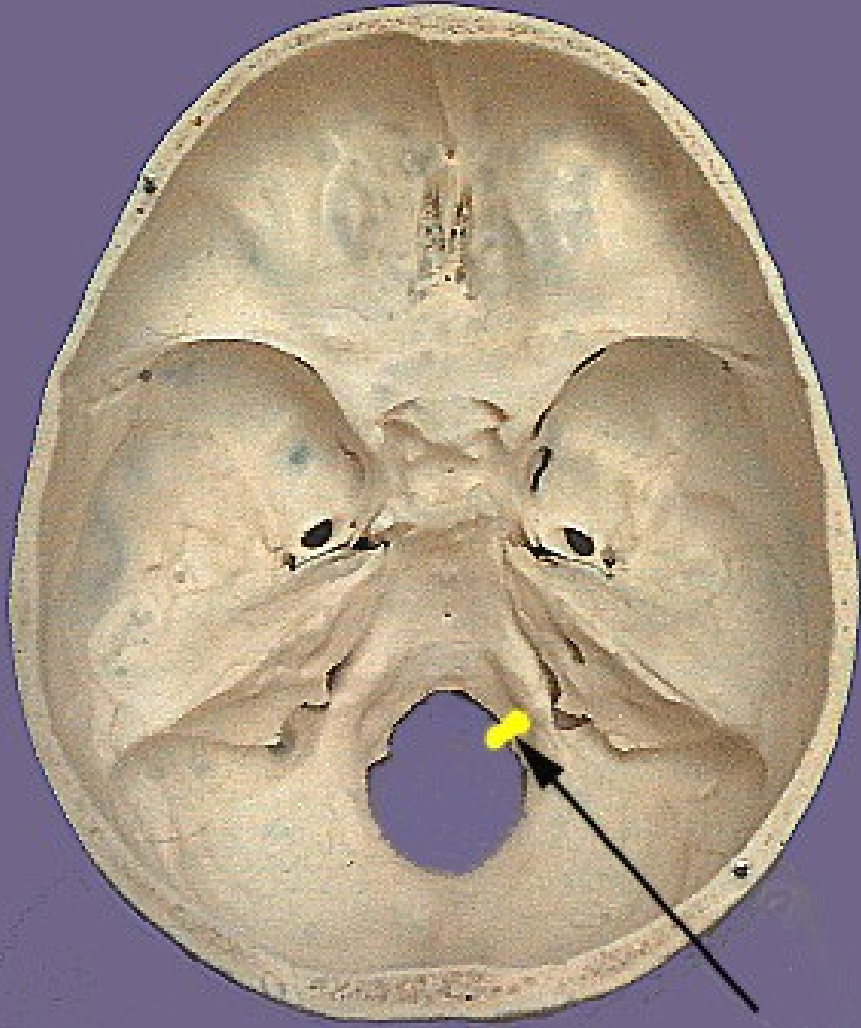


CN XII



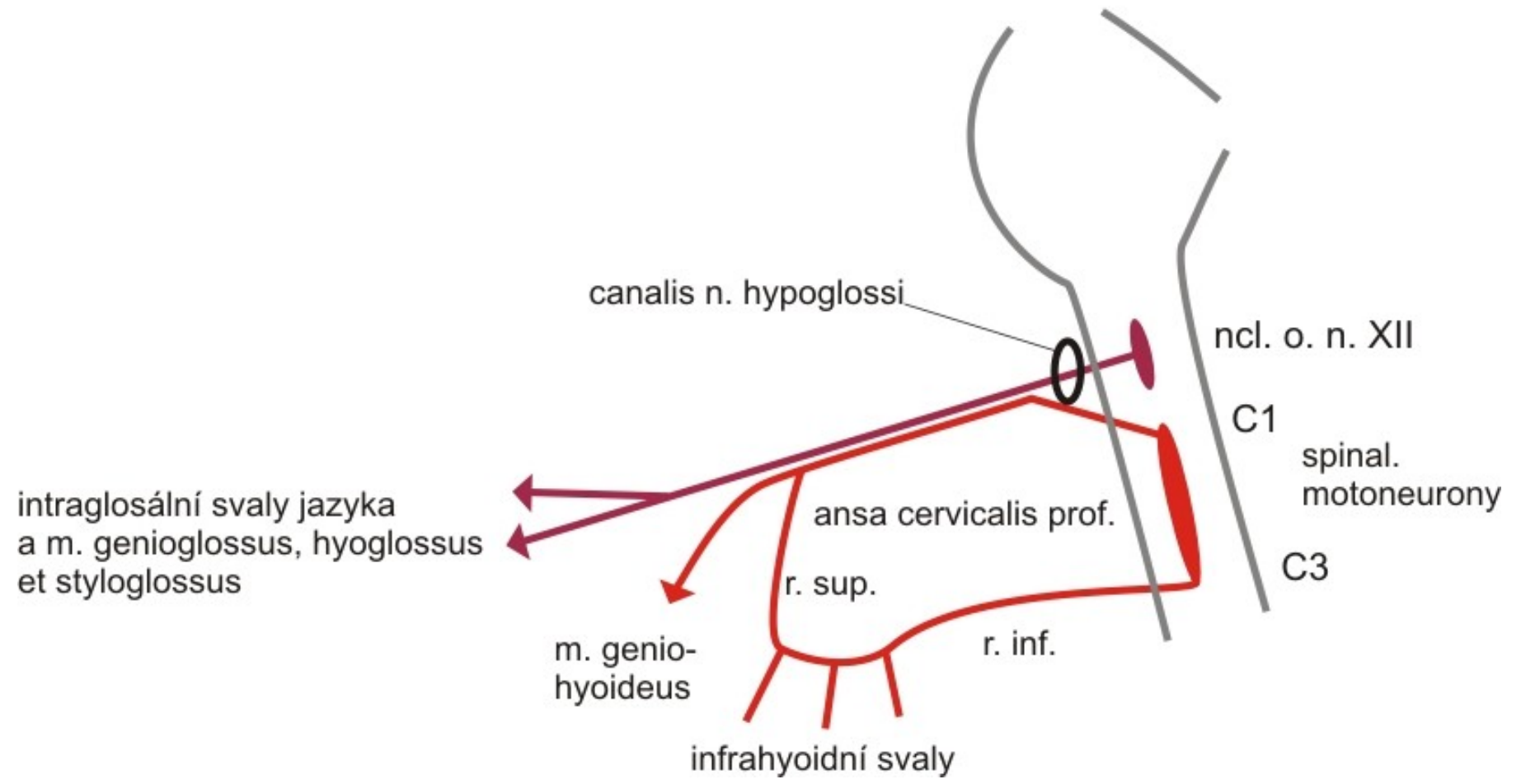


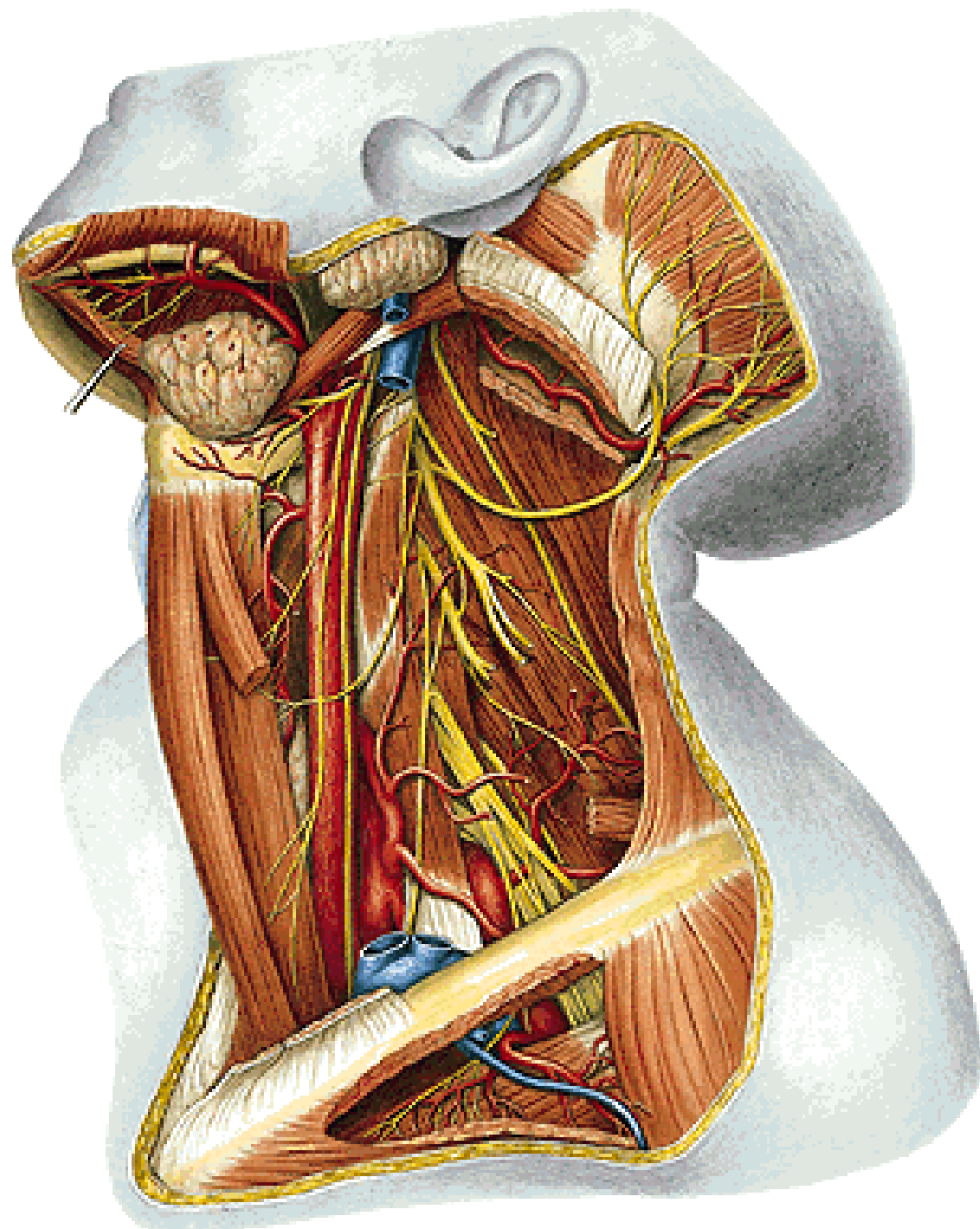


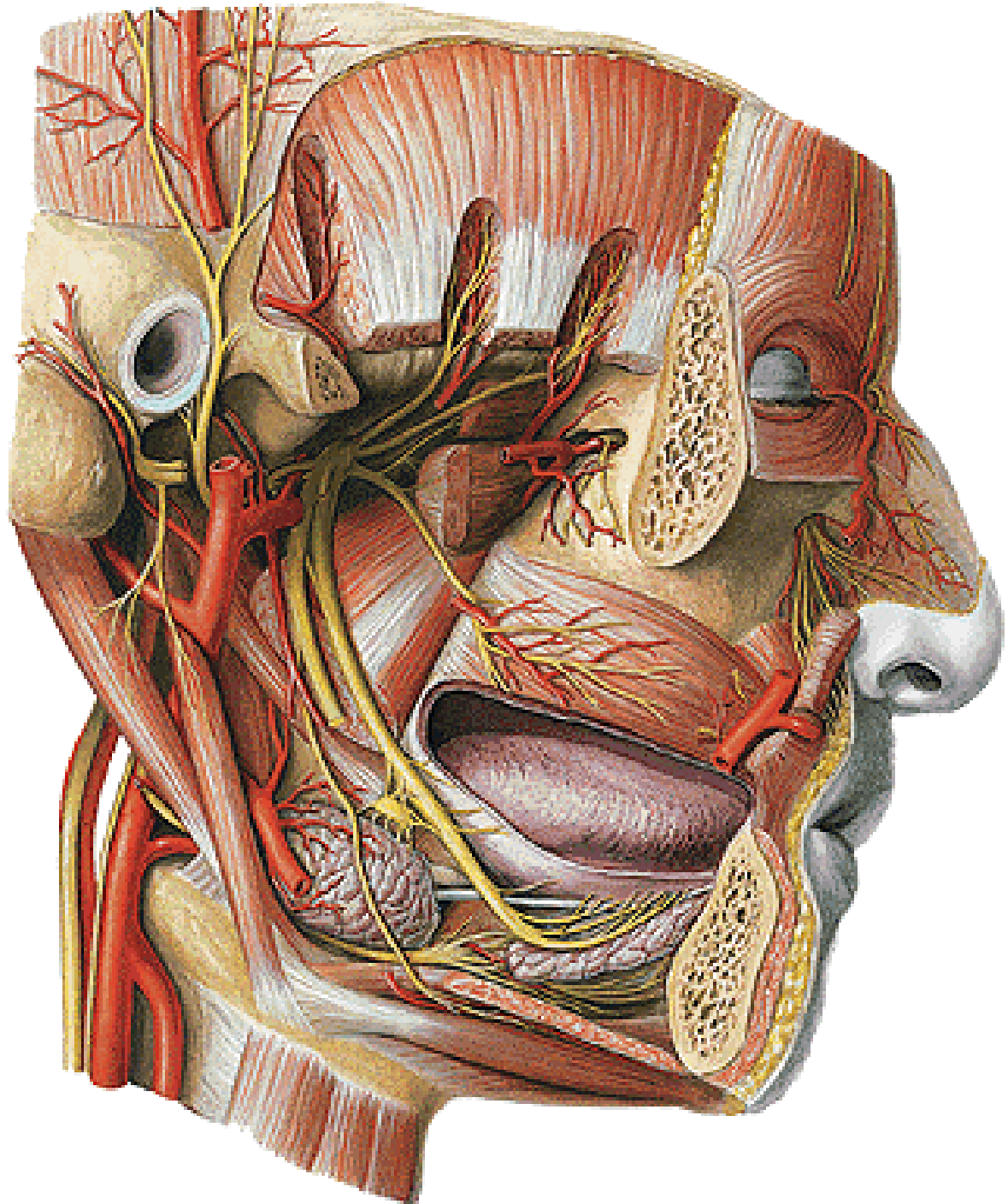


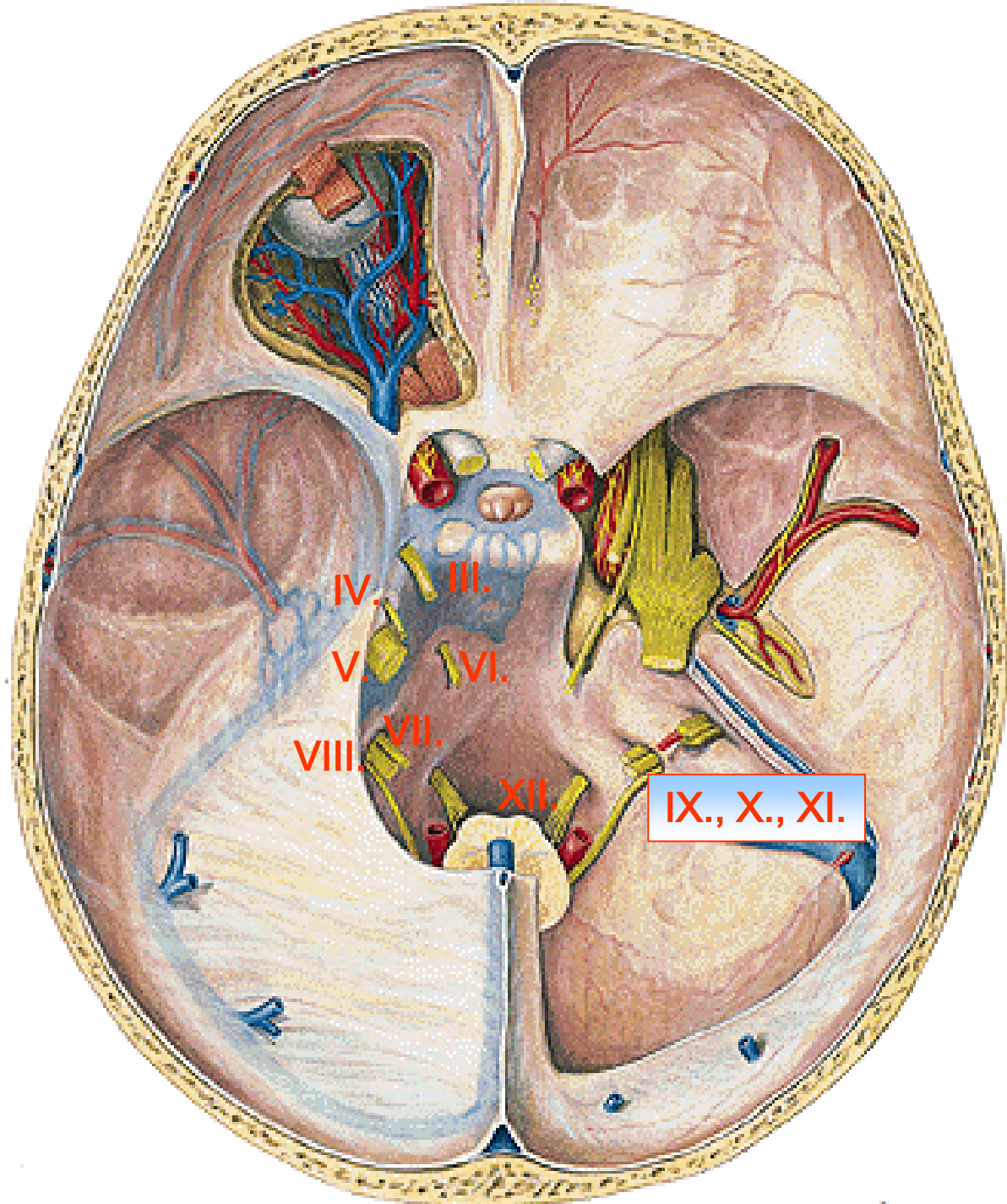
n. XII.

n. XII.









IV.

III.

V.

VI.

VIII

VII.

XII.

IX., X., XI.