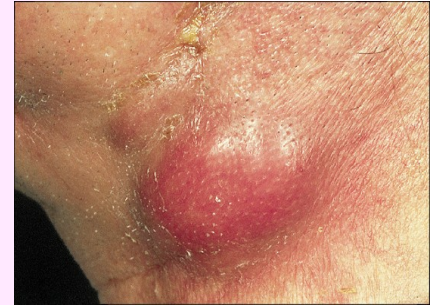

Anaerobic G+ rods to filaments

Rod *Actinomyces* (*A. israelii*, *A. naeslundii*)



Microscopy: G + rods to filaments

Biochemistry: glucosis fermentation

Cultivation: anaerobic, 5-7 day growth

Patogenity: common in the mouth, vagina, endogenous origin

Forms: cervikofacial (neck fistule) inoculation by face trauma for ex. ski stick

abdominal – looks like cancer

thoracic – atypic pneumonia

pelvic – occurs in woman fitted with plastic intra-uterine contraceptive devices

Typical for actinomycosis, „pus“ contain characteristic agglomerate of microbes

Dg.: direct – microscopy and cultivation

Treatment: PNC (doxycyklin, linkomycin)

Disease like this is also caused by Bifidobacterium, Propionibacterium (cause also acne)

Aerobic G+rods to filaments

Nocardia (N. asteroides, N. brasiliensis)

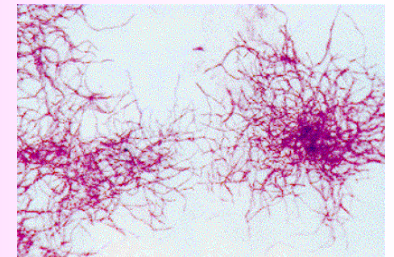
Microscopy: G + rods to filaments, often disintegrate

Cultivation: aerobic actinomycets, velvet white to yellowish colonies, aerobic growth on most nonselective media, (2-3 days, to 14 days)

Patogenity: conditional patogens, lead to pulmonary infection, brain absces, skin form looks like actinomycosis (usually in tropical areas, comes from soil)

Dg.: microscopy and scultivation

Treatment: kotrimoxazol, drenage, tetracyklin



M. tuberculosis

Microscopy: don't use Gramm stain

Ziehl-Neelsenem stain of sputum (heated carbol fuchsin - acid diluted in ethanol, a blue/green counterstain) - pink rods in ZN stain, blue background, called acid-fast bacilli

Fluorescent stain

Cultivation: solid soil (Löwenstein-Jensen) growth 3-6 weeks, yellow, cauliflower colonies, liquid media (Šula) forms semolina like sediment

Patogenesis: grow intracellularly (inside macrophages) and slowly, damage of a tissue is caused by reaction of macroorganism (late immune response no. IV)

Patogenity: cause tuberculosis (TBC)

Primary TBC – lung disease, basillary meningitis, scrofulous lymphadenitis of neck nodes

Postprimary TBC - reactivation when the individual ages or immune status changes, lung disease

TBC signs: cough, blood caughing, temperature, weight loose

M. tuberculosis II.

Treatment: multidrug therapy, initial phase (2 months) - HRZS, HRZE – large numbers are killed, continuation phase (6-8 months) – remainders are killed (HR, HE)

Epidemiology: transmitted by aerosols from an infected individual

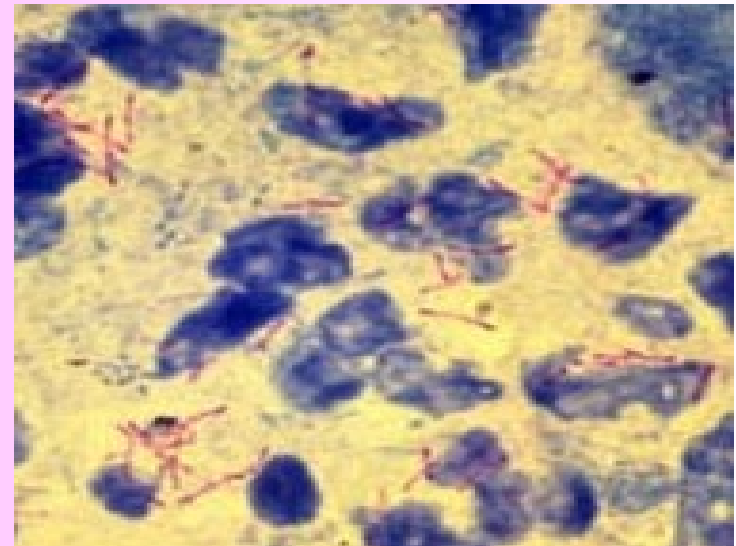
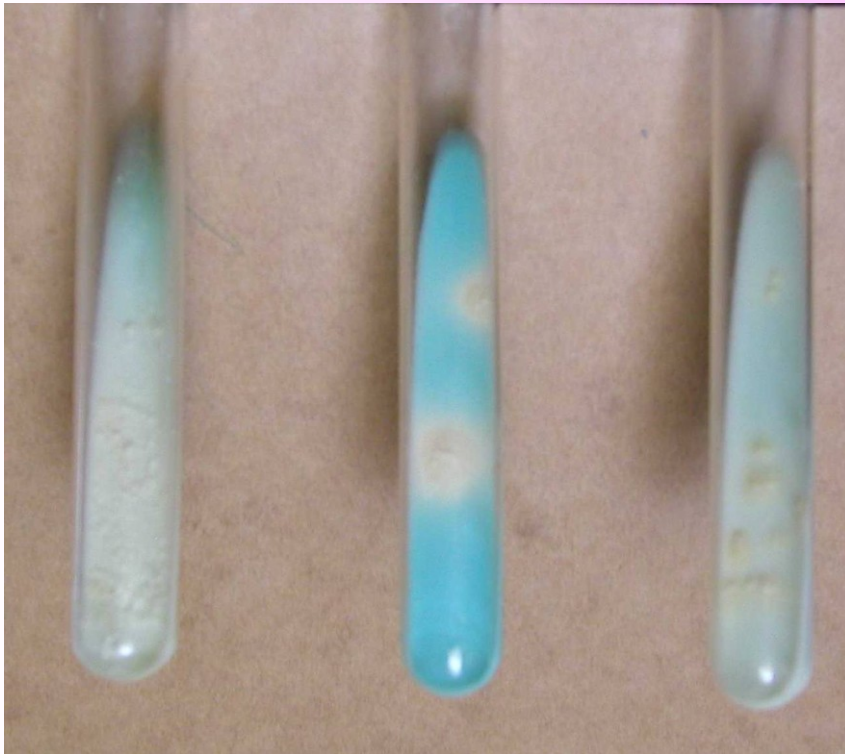
Prevention: vaccination in new-born babies, before next vaccination diagnostic test Mantoux is needed, after 48-72 hours induration occurs, vaccination is made only in tuberculin negative person

Dg.: microscopy, cultivation (L-J, Ogawa – solid media; Šula, Banič – liquid media) – 1,3,6 and 9 weeks.
Demonstration on guinea-pig, detection of metabolic products or PCR

*H – INH, R – rifampicin, Z – pyrazinamid, S – streptomycin, E - etambutol

M. tuberculosis

„cauliflower“ colonies



Ziehl-Neelsenem stain

red rods on blue background

Mycobacteria other than tuberculosis

M. bovis (BCG) - serves as vaccination strain

M. leprae

Will not grow in culture, only on mice, infection of peripheral nerves
tuberculoid – anesthetic plaques on skin

lepromatous – leads to loss of digits on fingers, face damage, blindness

Atypic mycobacteria - are found in water + in soil, cause skin infection,
TBC like disease – lung infections, resistant to many antituberculous –
multidrug therapy is needed

