

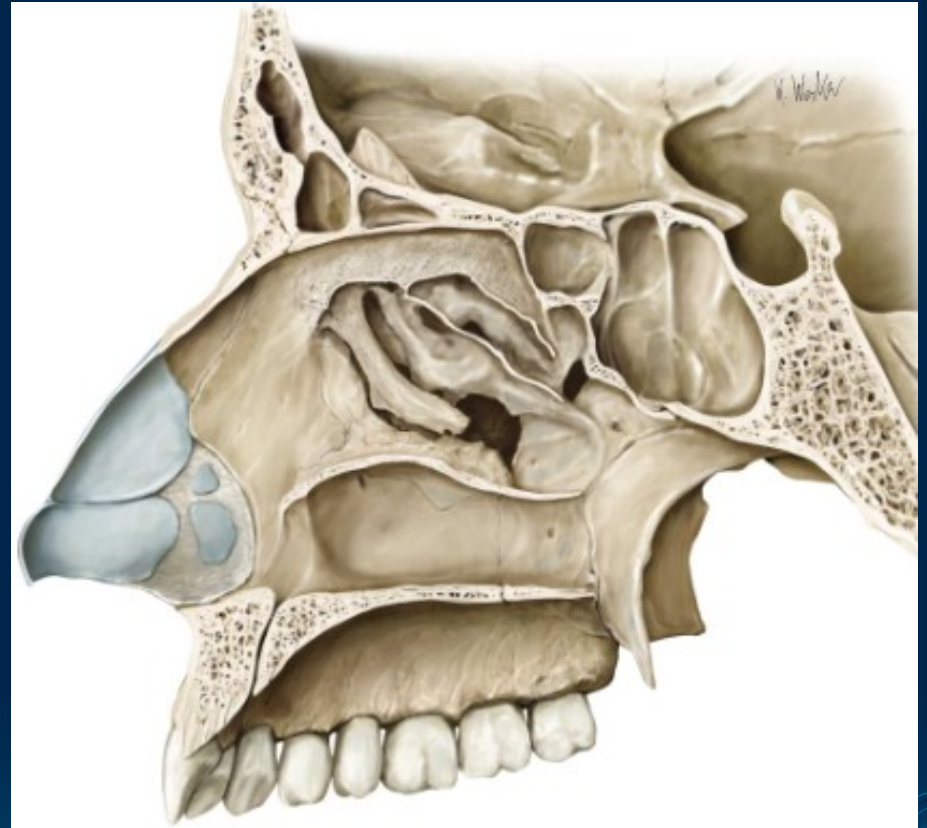
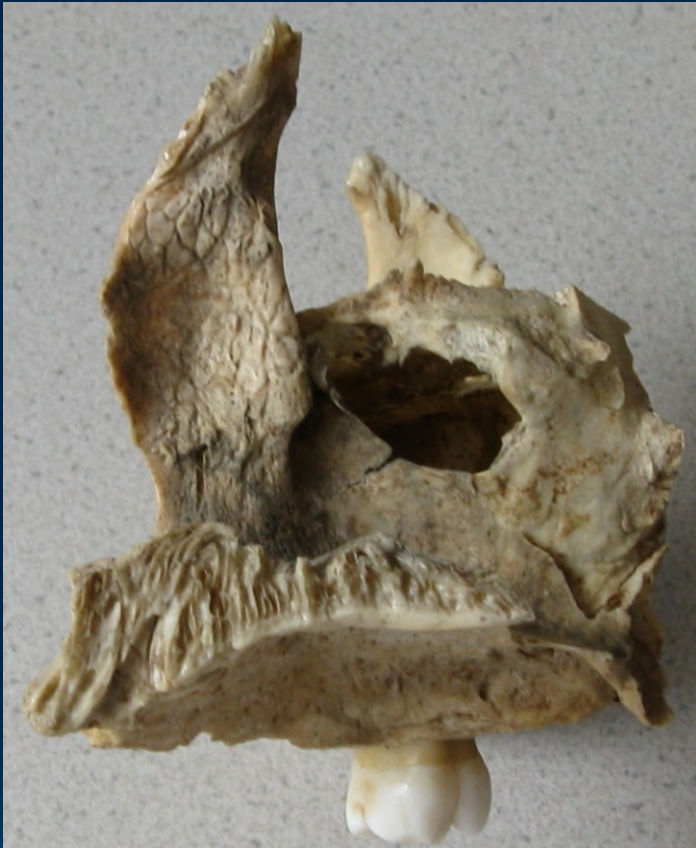MAXILLA

Upper jaw



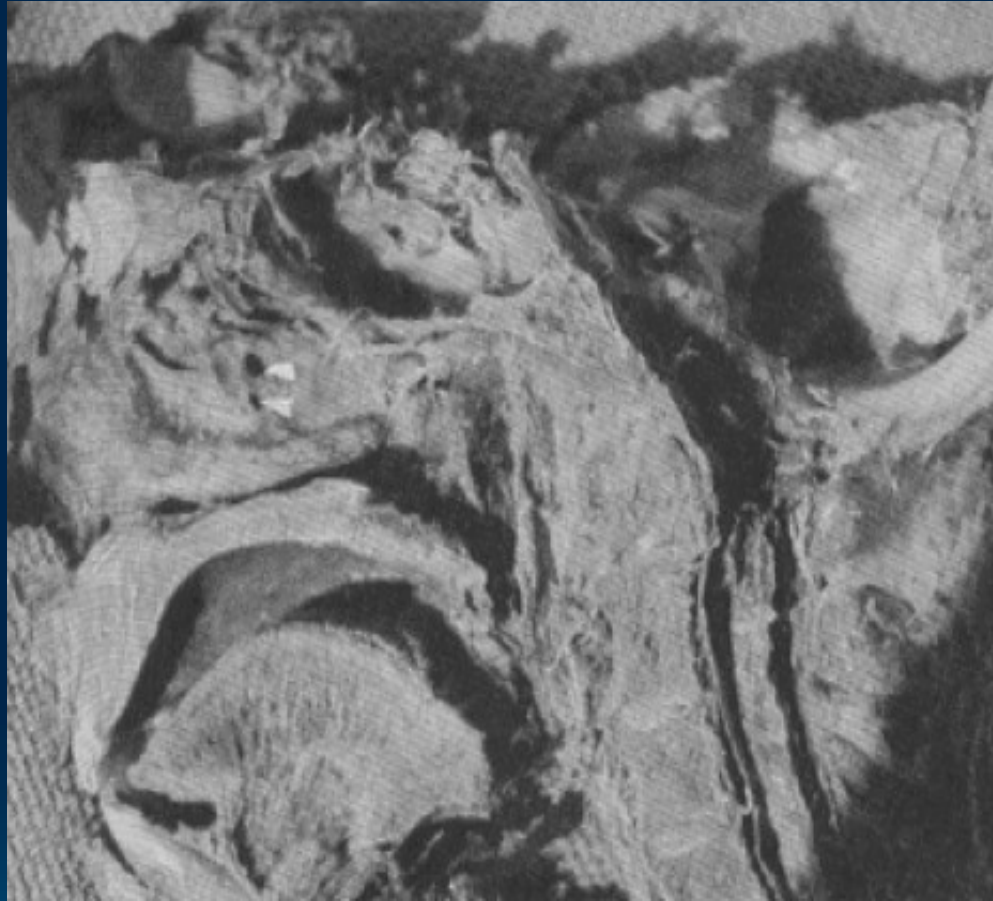- **Anatomy** (repetition), widespread description
- **Clinical notes**
- **Dentoalveolar topography:**
 - transverse asymmetry of alveolus
 - rate of spongy and compact bone
 - the relationship of root to neighbouring struct.
- **Nerve and blood supply** (repetition)

Sinus maxillaris - foramina accessoria



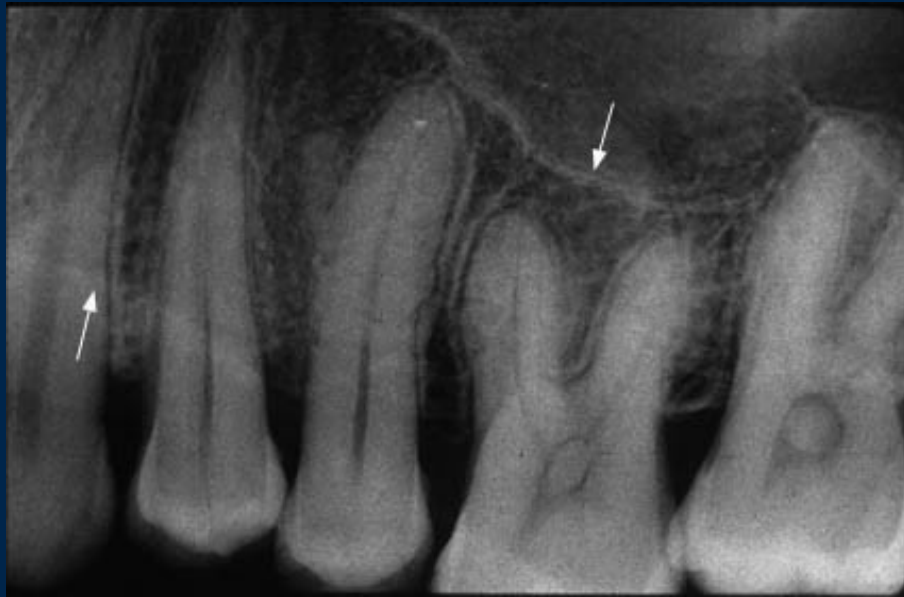Below pr. uncinatus form the medial wall of sinus the collagenous tissue = **fontanella ant. et post.** in which **for. accessoria** may be occure

25-30%



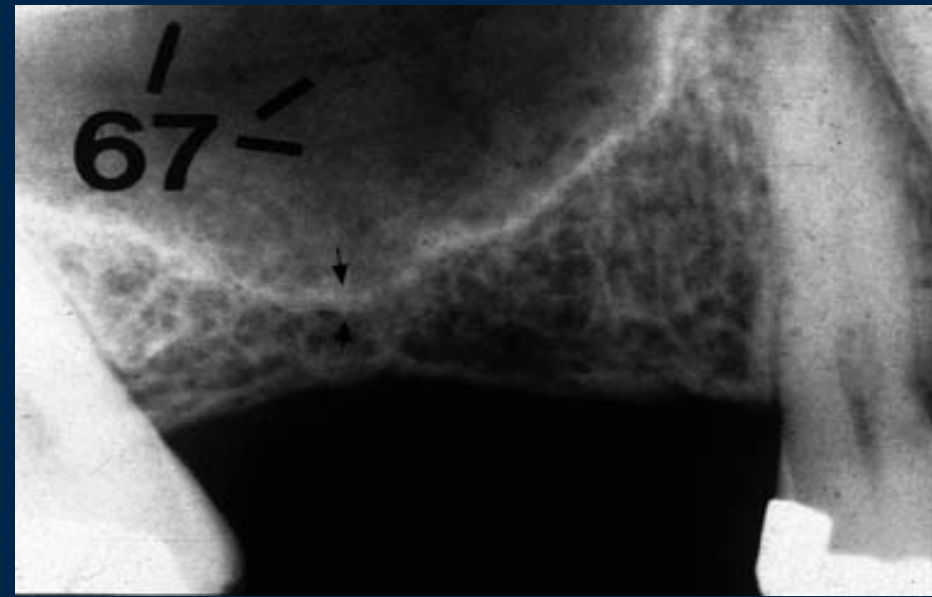
- Solitary or multiple
- Congenital or secondary to disease process

Sinus maxillaris – decrease of floor



The toothed jaw

Variable layer of spongy bone between sinus and roots of teeth



The edentulous jaw

CAVE!
By the maxillary sinus lift (augmentation) before installation of implants

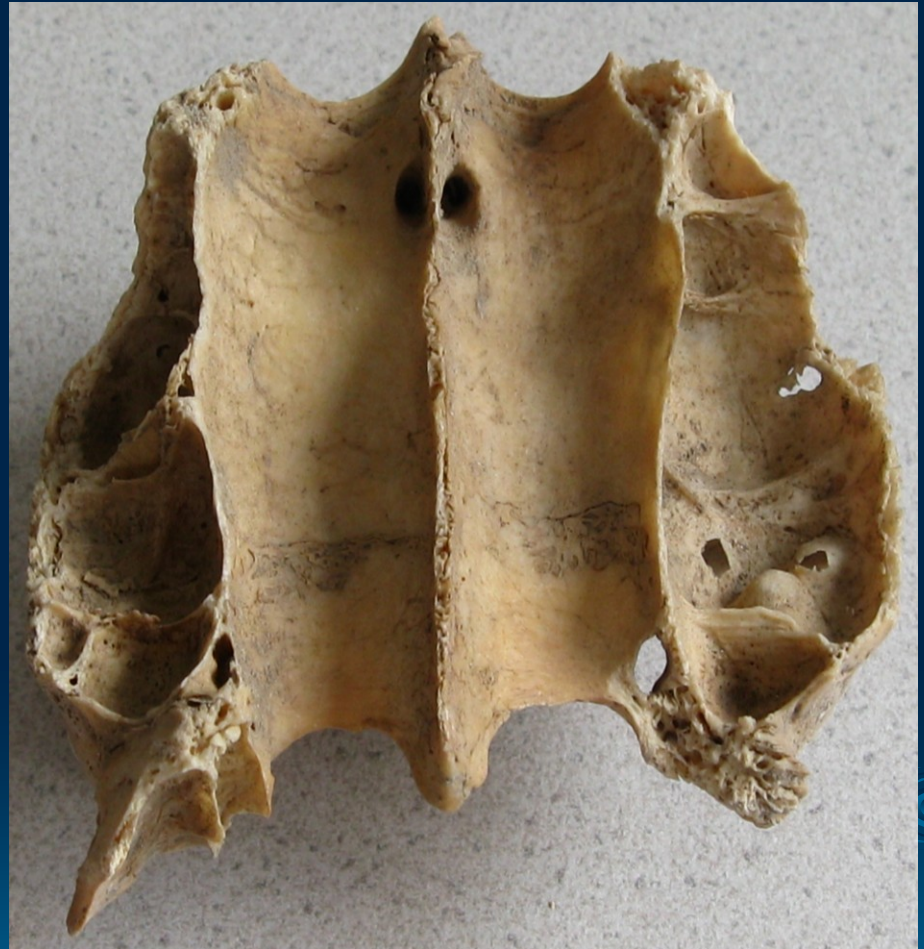Sinus maxillaris - septa

Primary:

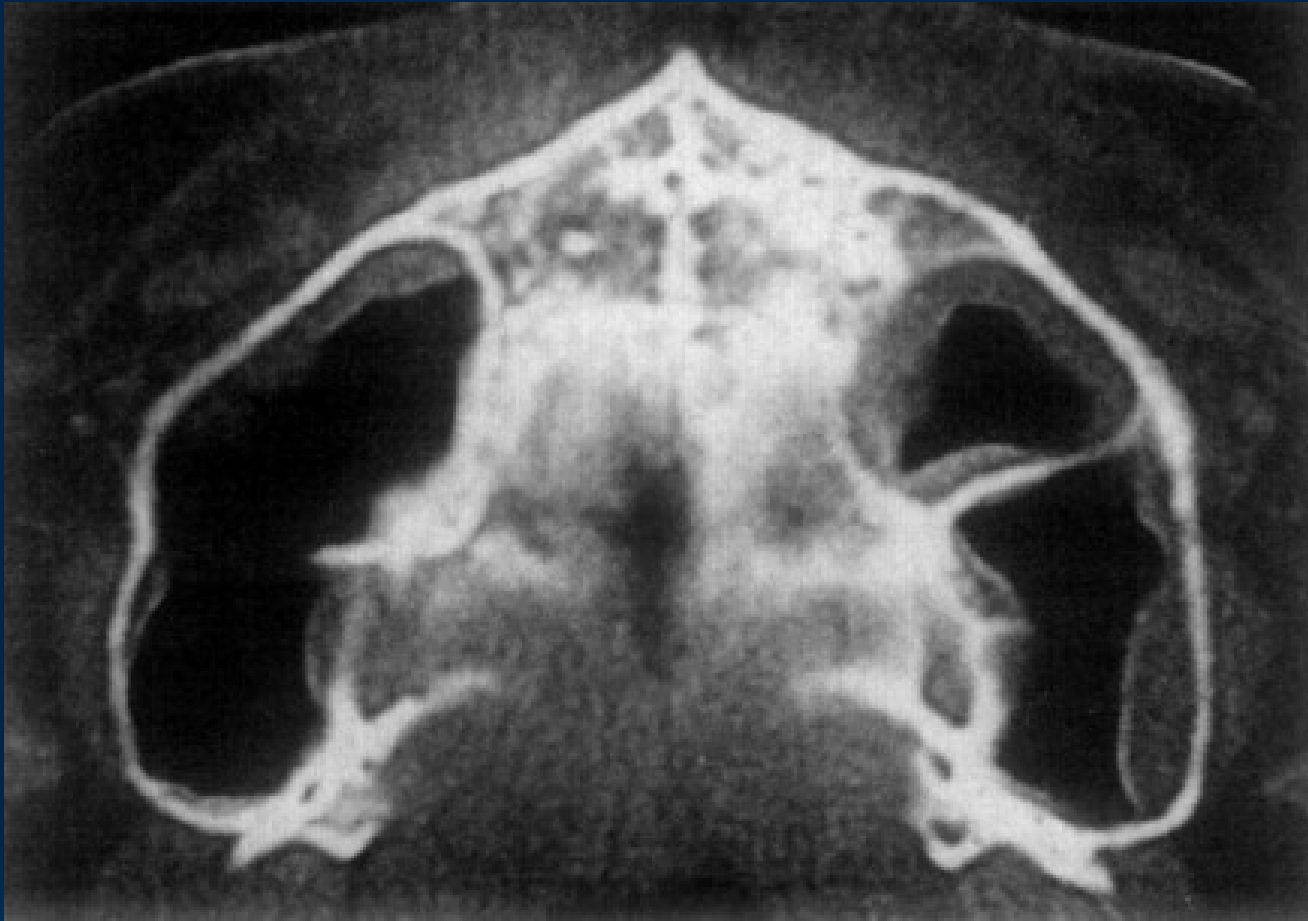
arising from the development of the maxilla

Secondary:

arising from the pneumatization of the sinuss floor following tooth septa



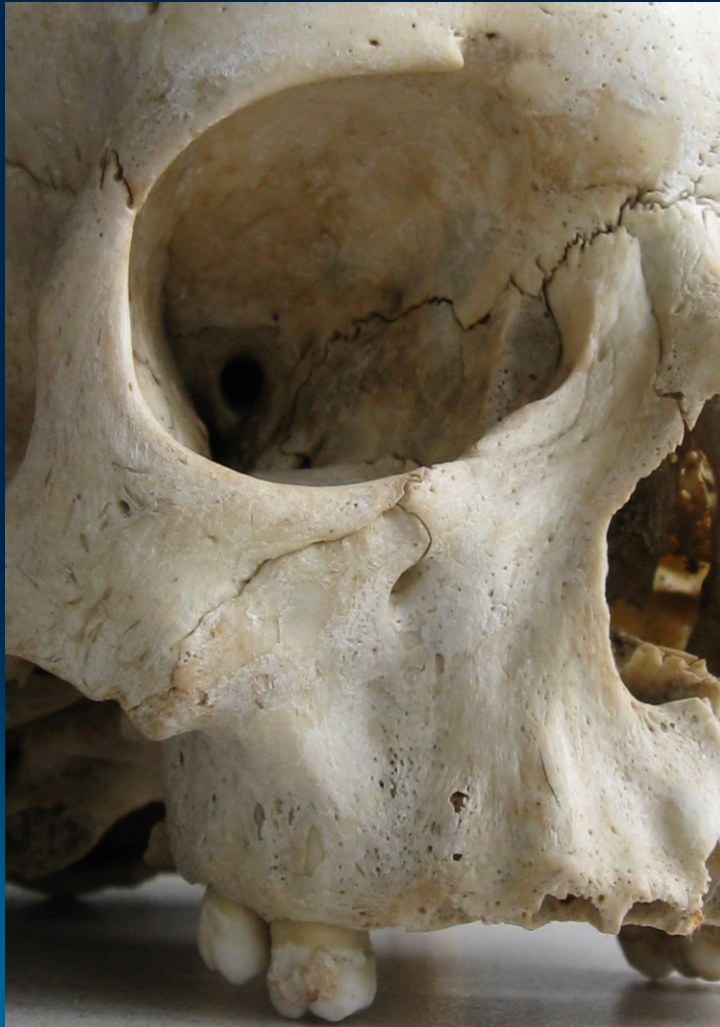25% - 35%



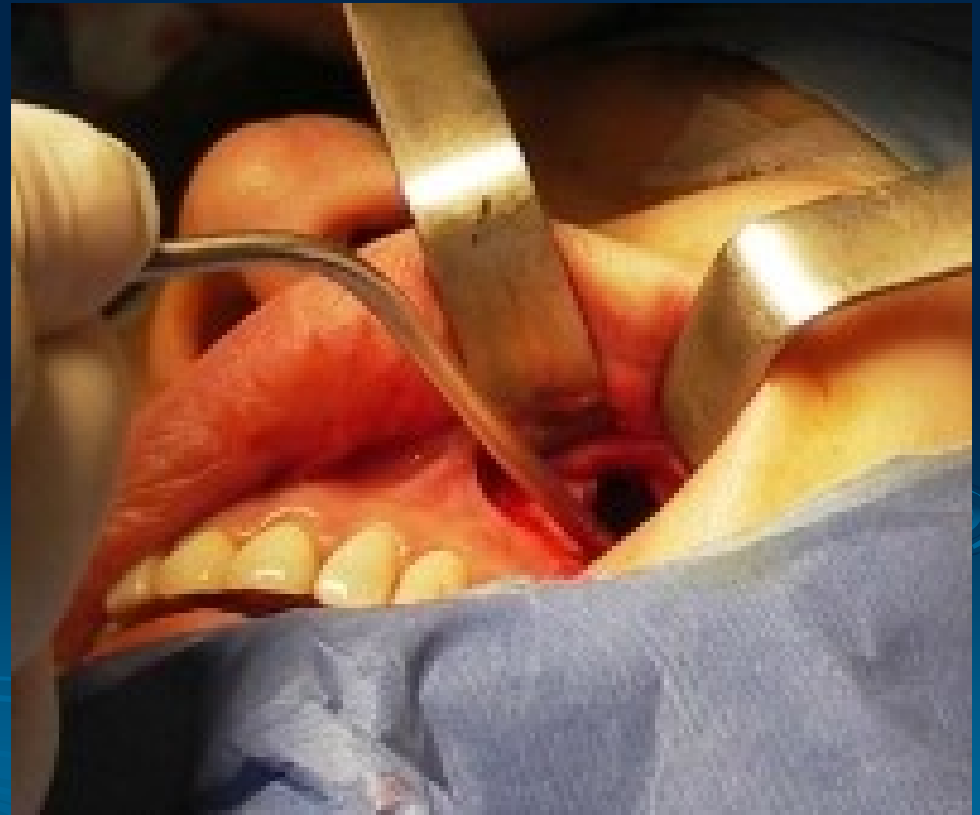CAVE!

- The separately maxillary sinus puncture
- Dental implants

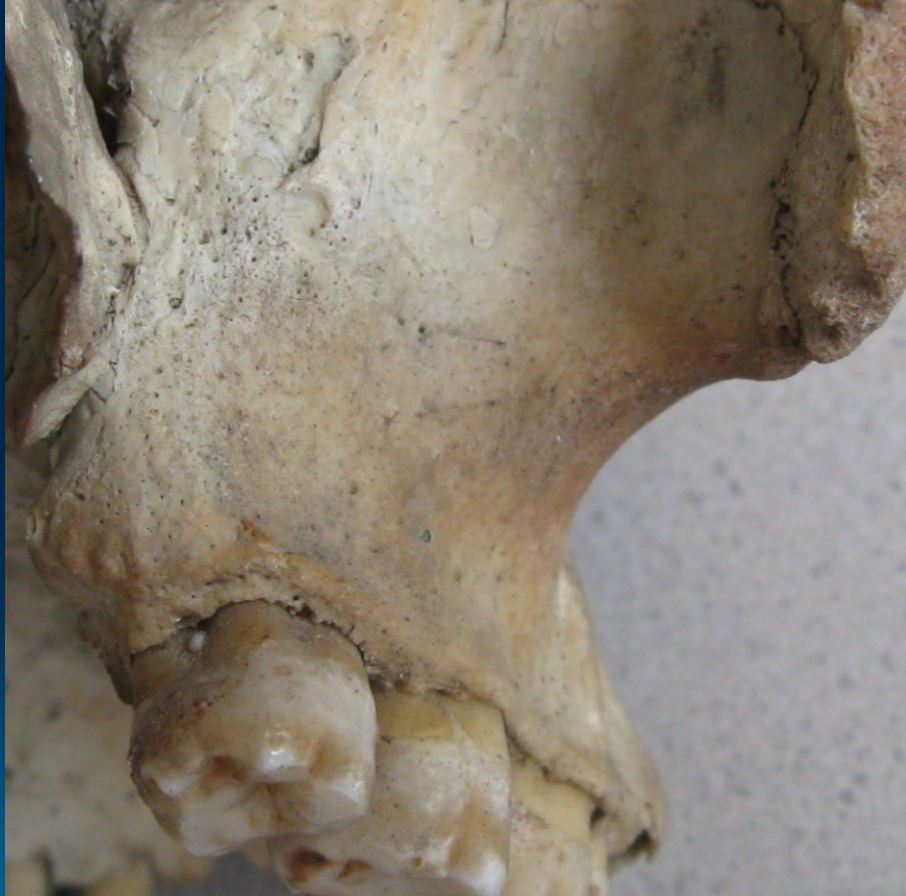Corpus maxillae - facies ant. (fossa canina)



Caldwell-Luc antrostomy



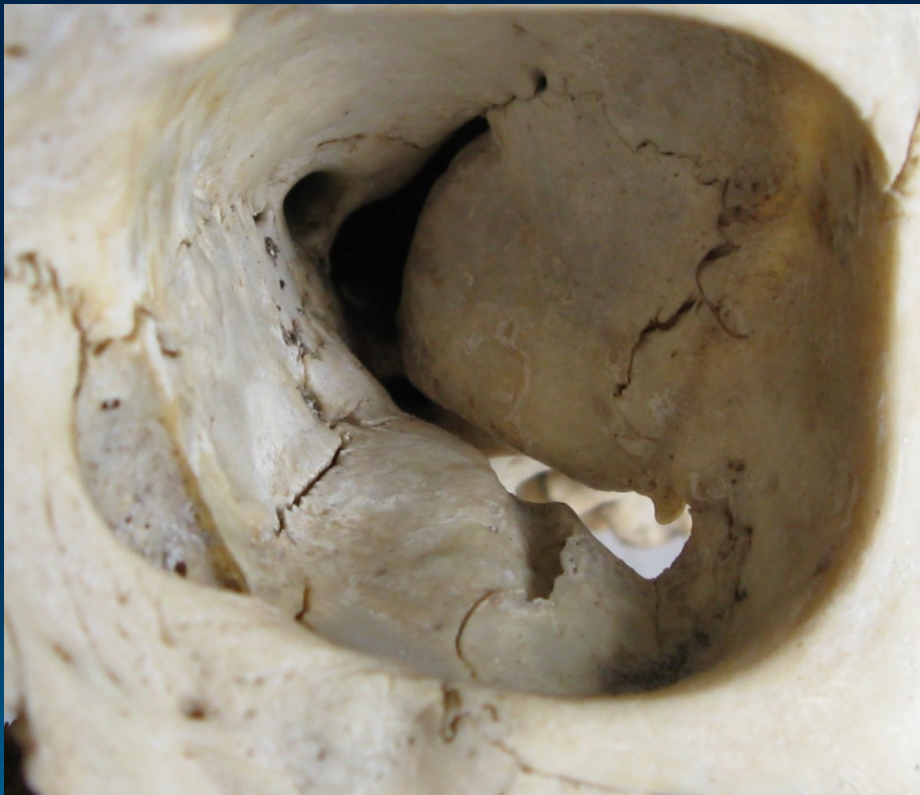Corpus maxillae - facies post. (tuber maxillae)



CAVE!

- Alveolar foramens:
a., v., n. alveolaris sup.
post. - local anesthesia
- Thin bone → during
molar teeth extraction
can occur maxillary
tuberosity fractures

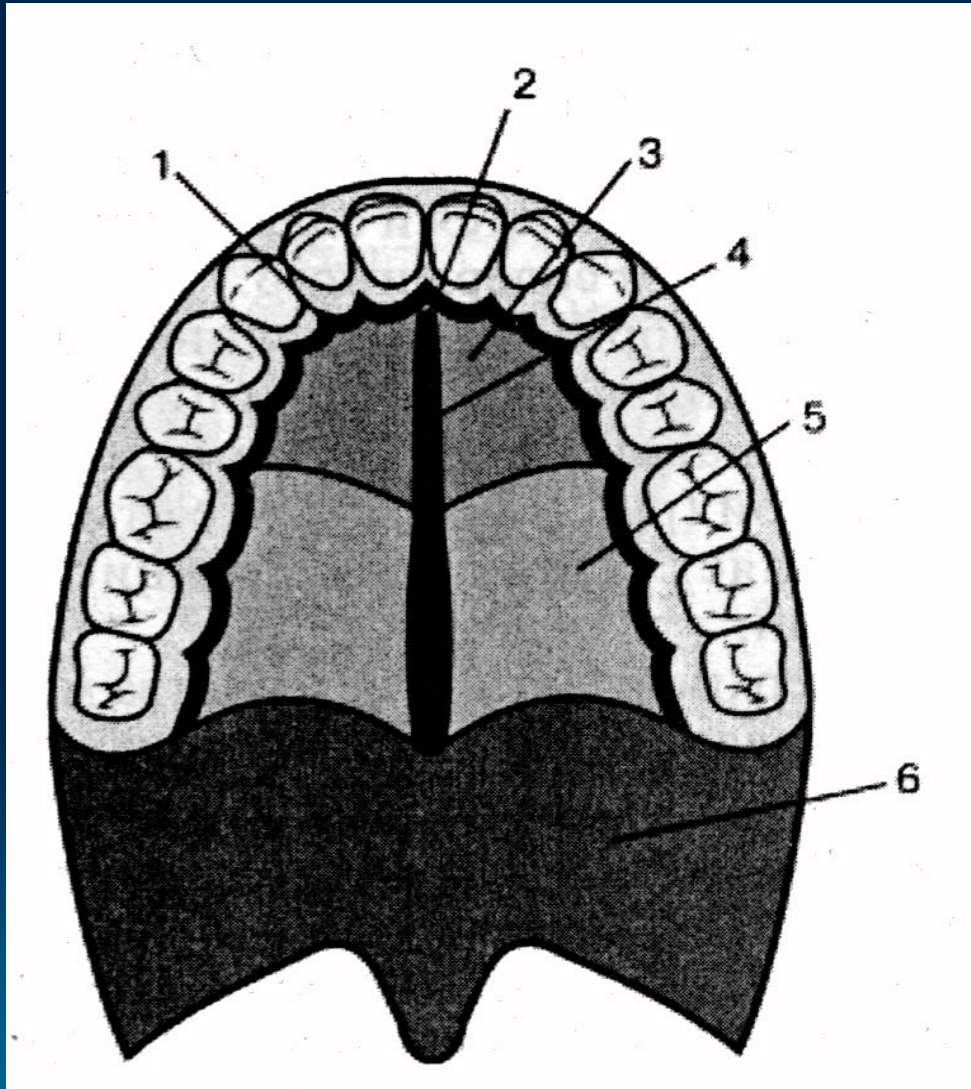
Corpus maxillae - facies orbitalis - canalis infraorbitalis



CAVE !

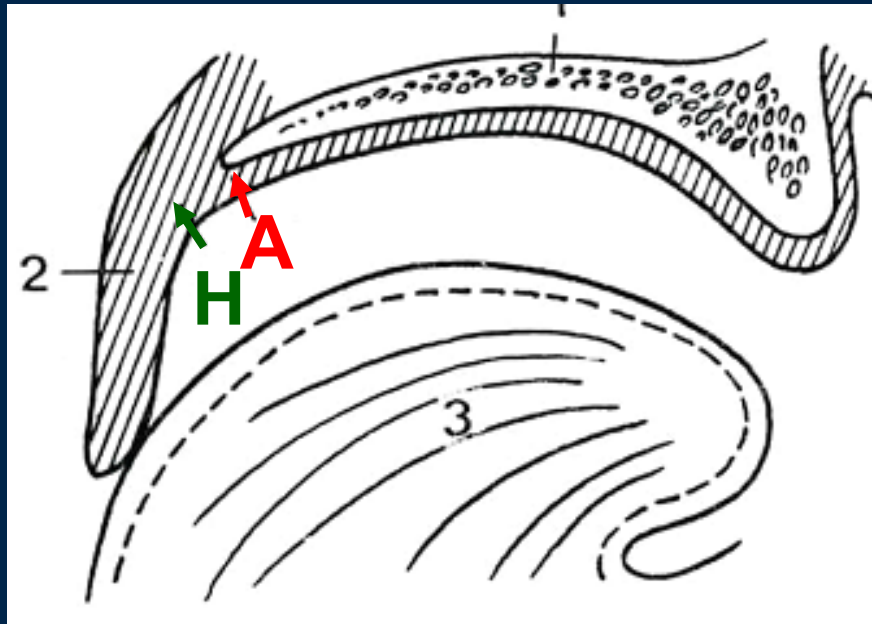
Maxillary sinus disease
can lead to dehiscence
of the orbital floor →
**secondary neuralgia of
trigeminal nerve**

Palatum – zones of mucous membrane



- 1 – the marginal zone
- 2 – the incisive papilla
- 3 – the adipose zone
- 4 – the zone of the palatine seam,
mucoperiosteum
- 5 – the glandular zone
- 6 – the soft palate

Palatum: A and H line



A line

localized on the line between hard and soft palate

H line

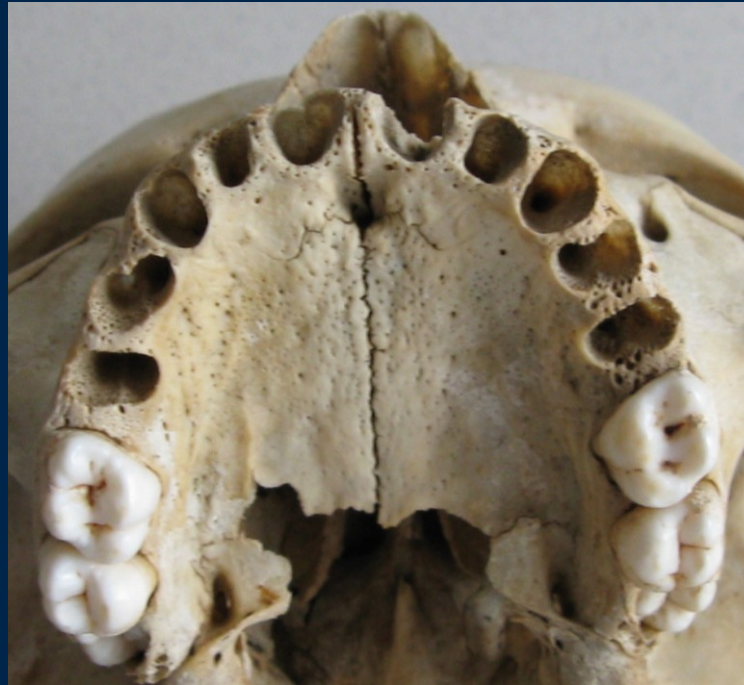line between mobile and immobile parts of the soft palate

Dentoalveolar topography

Important for anesthesia, extraction, injury, implantology, endodontic treatment ...

1. The transverse asymmetry of alveolus
2. The rate of the spongy and the compact bone
3. The relationship the roots the lower jaw to neighbouring structures

1. The transverse asymmetry of alveolus

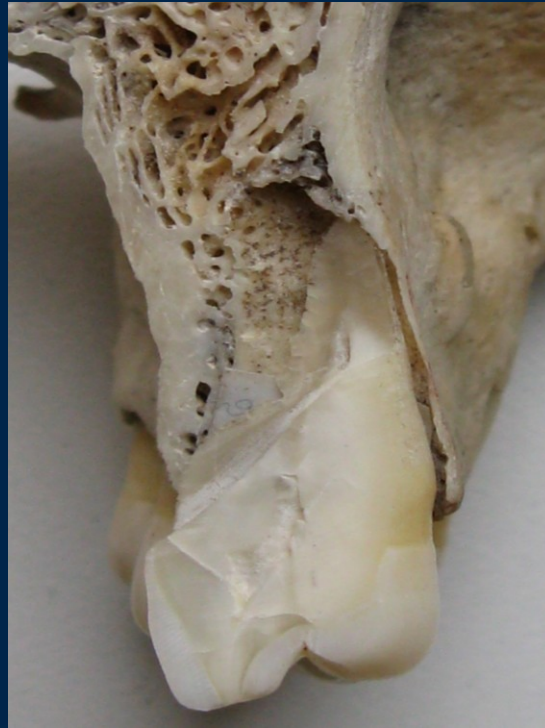

- The dental and skeletal arch are asymmetric !
- Roots of the teeth:
 - 1-5 eccentric směrem vestibulárním
 - 6-7 in alveolar process axis

2. The rate of the spongy and the compact bone

- The layer of **compact bone** is thinner than in the lower jaw
- Roots of the 1-5 are surrounded by the compact bone. Posterior there are **variable layer of retroalveolar spongy bone**. The width of the alveolus depend on the arching palate
- Roots of the molars are surrounded by thin layer of the compact bone (except infrazygomatic crest)

Incisivi, canini, premolars




Compact bone and variable thickness of spongy bone lingually

Molars



Compact bone only

3. The relationship the roots the upper jaw to neighbouring structures

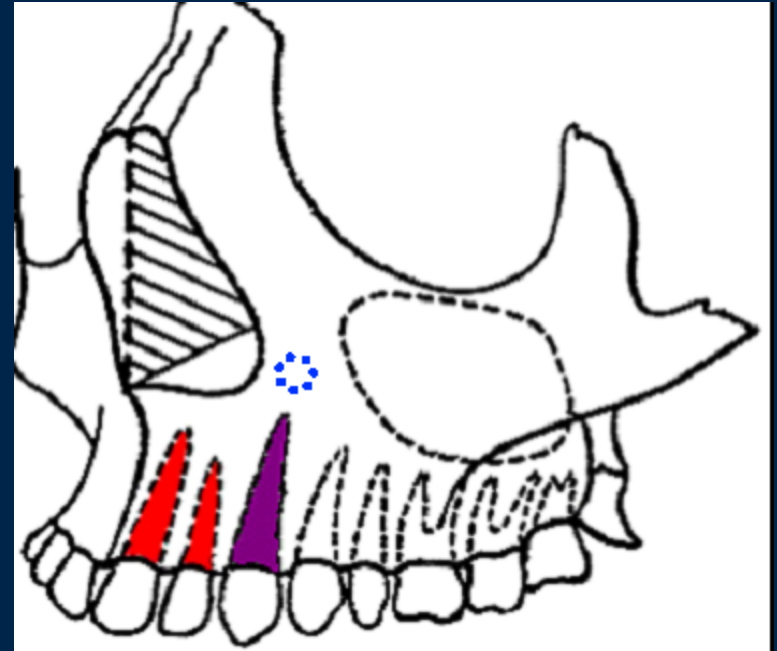
- **Nasal cavity**
 - **Infraorbital foramen**
 - **Maxillary sinus**
- 
- A decorative graphic consisting of several sets of concentric circles in a lighter blue shade, arranged in a pattern that suggests ripples on water. The circles are located in the lower right quadrant of the slide.

Nasal cavity

Infraorbital foramen

- Variable layer of spongy bone between nasal cavity and roots of incisivi

- Root of 3 localized between nasal cavity and sinus maxillaris



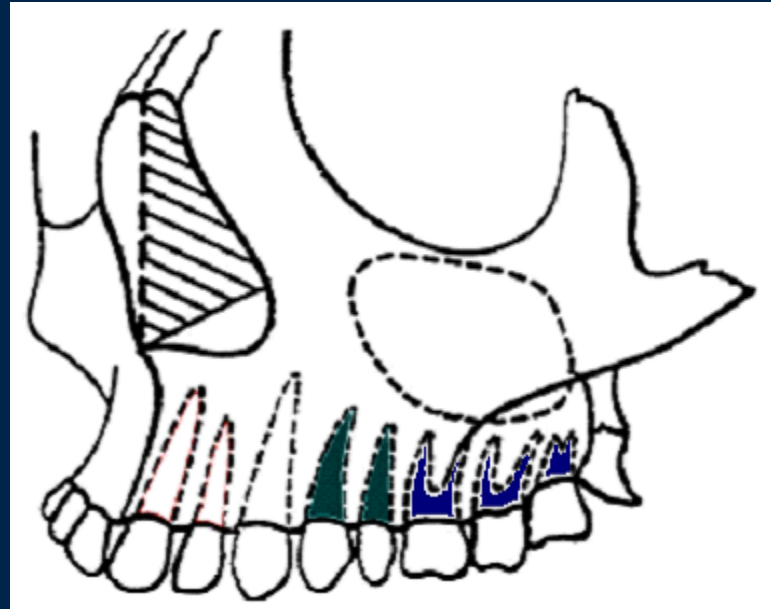
CAVE!

Radices 1,2: periapical inflammatory may led to **abscess of the floor of nasal cavity**

Radix 3: relation to a.,v., n. infraorbitalis and - possible **trombophebitis of cavernous sinus**

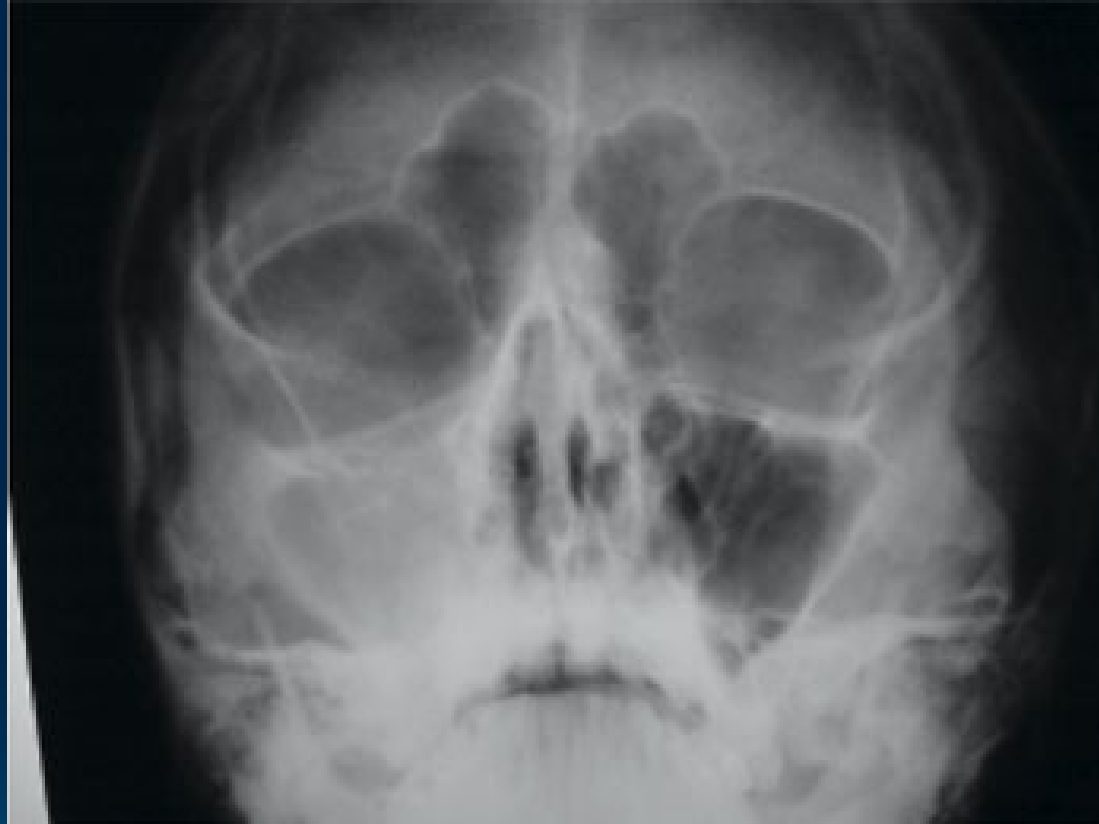Maxillary sinus

Variable layer of spongy bone between maxillary sinus and roots of posterior teeth



CAVE!

- Periapical inflammation developing at the root apices of maxillary molars and premolars are very close to the floor of the maxillary sinus - **sinusitis** or **empyema**
- Potential **oro-antral communication** by the extraction

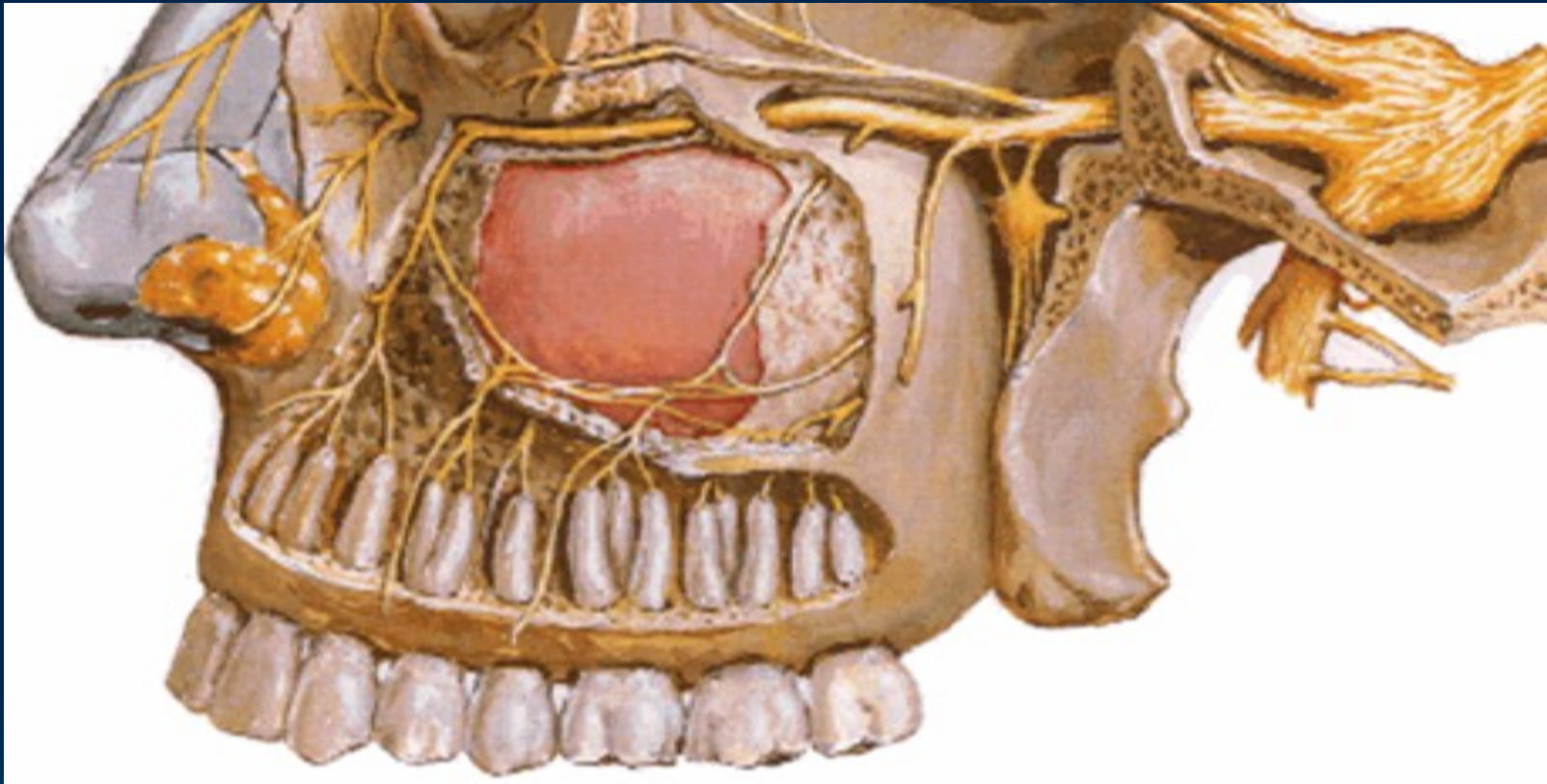


Inflammation in sinus maxillaris

Nerve and blood supply



Trigeminal nerve



Maxillary nerve - infraorbital nerve

ant. sup. alv. nerve

middle sup. alv. nerve

post. sup. alv. nerve

Maxillary artery

Post. sup. alveolar a.

Infraorbital a.

ant. sup. alveolar a.

