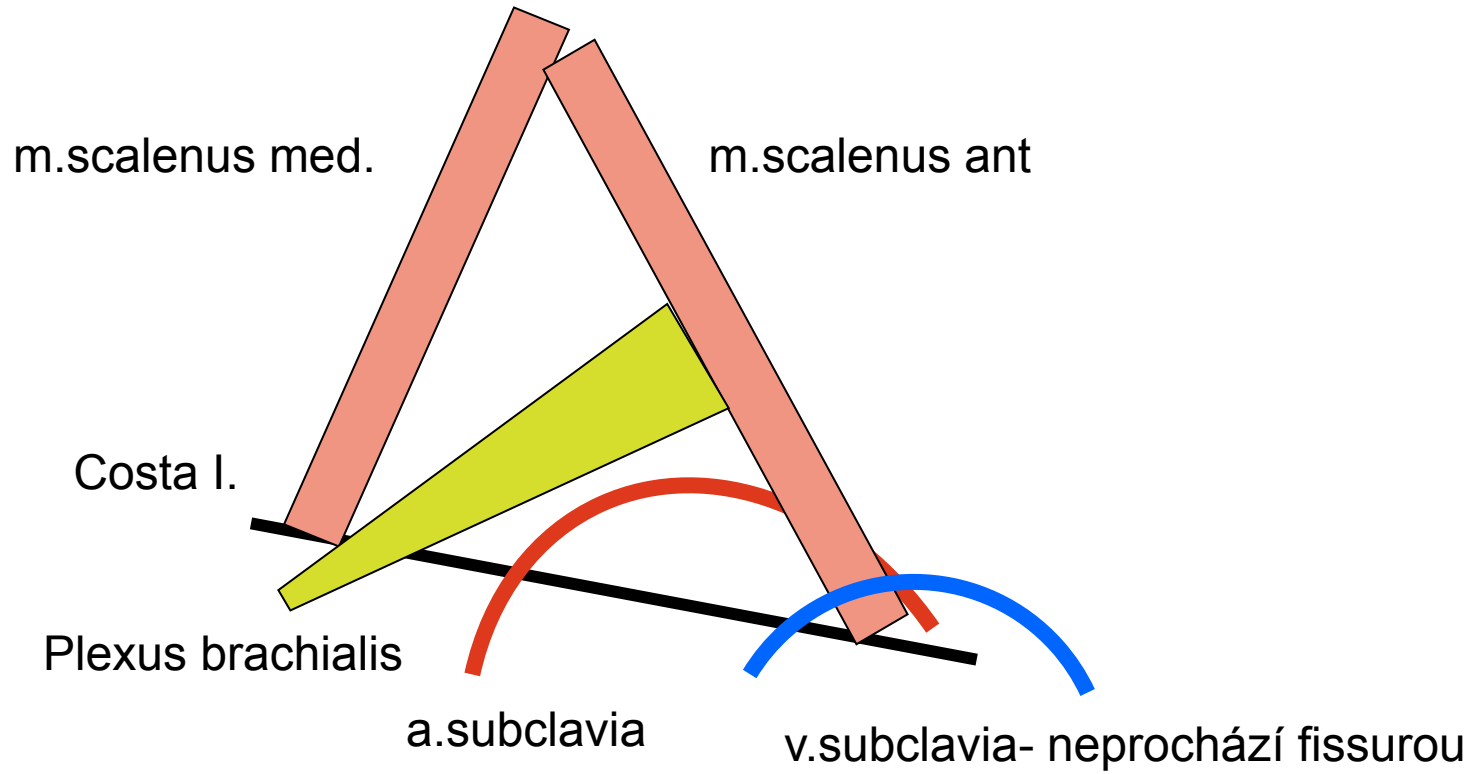


Doporučená topografická schémata

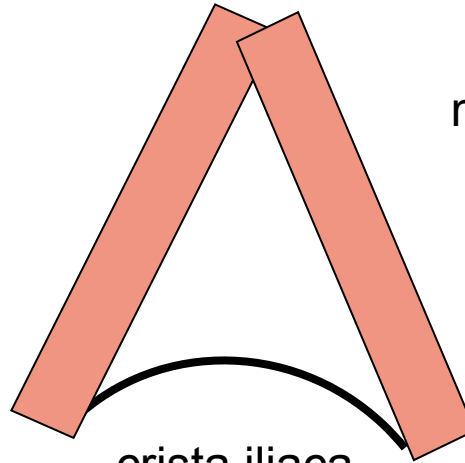
Fissura scalenorum



Trigonum lumbale- Petiti

m.latissimus dorsi

m.obliquus externus



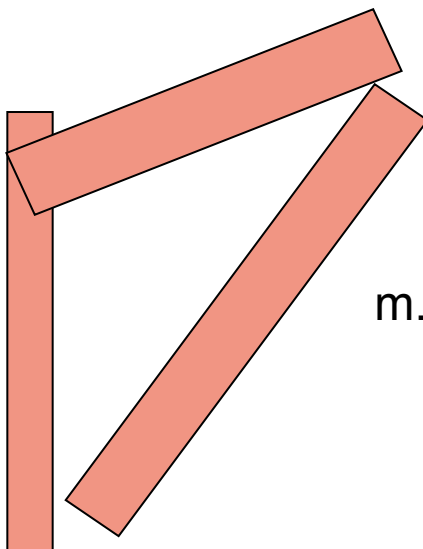
crista iliaca

Trigonum Grynfelti

m.erector spinae

m.serratus posterior infer.

m.obliquus internus



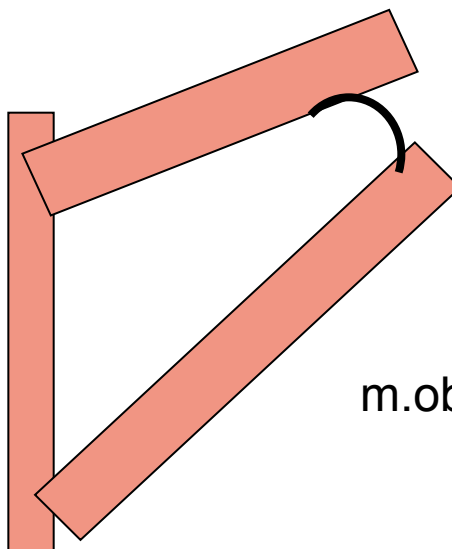
Tetragon Krausei

m.erector spinae

m.serratus posterior infer.

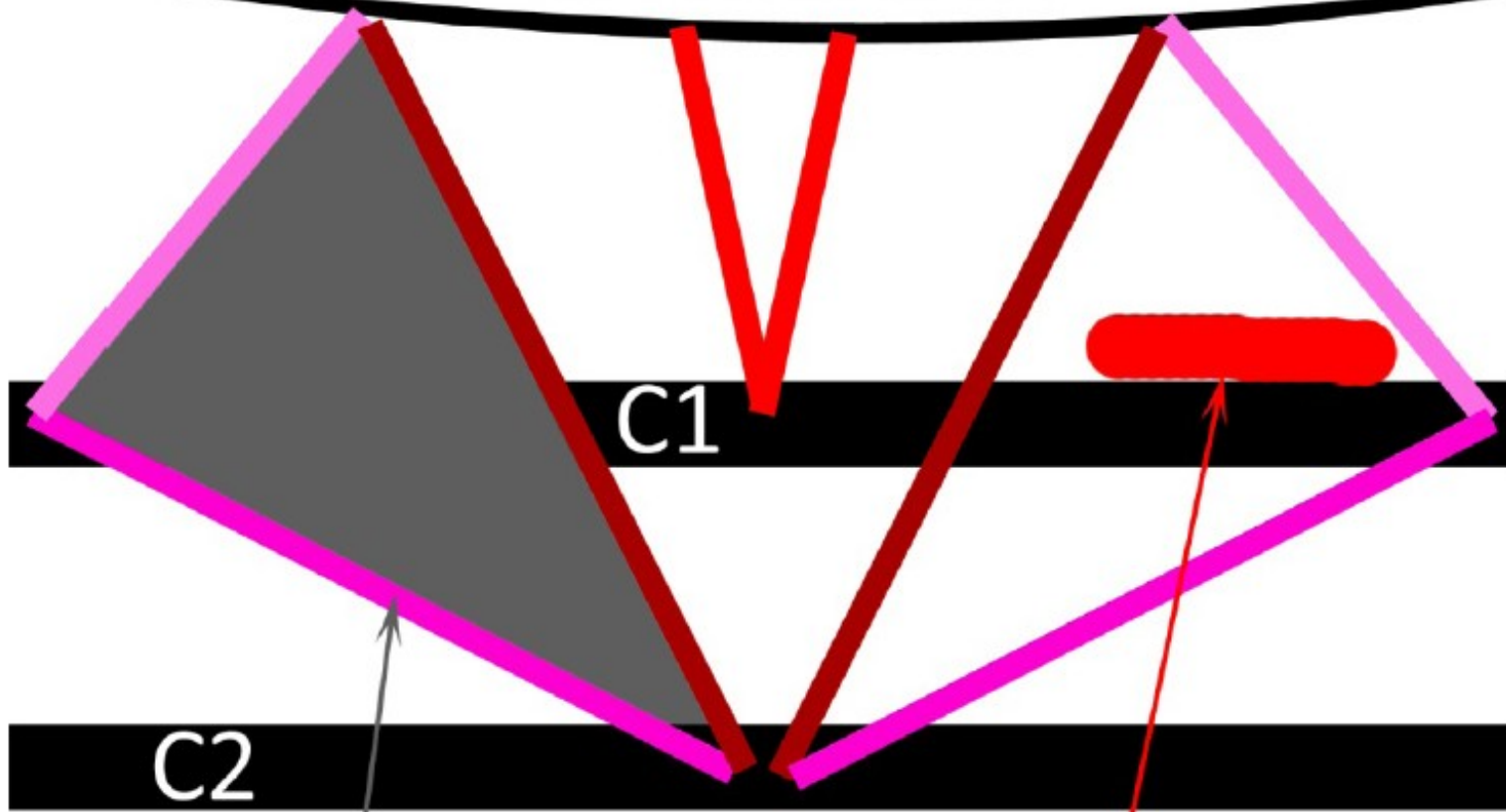
costa I.

m.obliquus internus



Trigonum suboccipitale

Linea nuchae inferior



C1

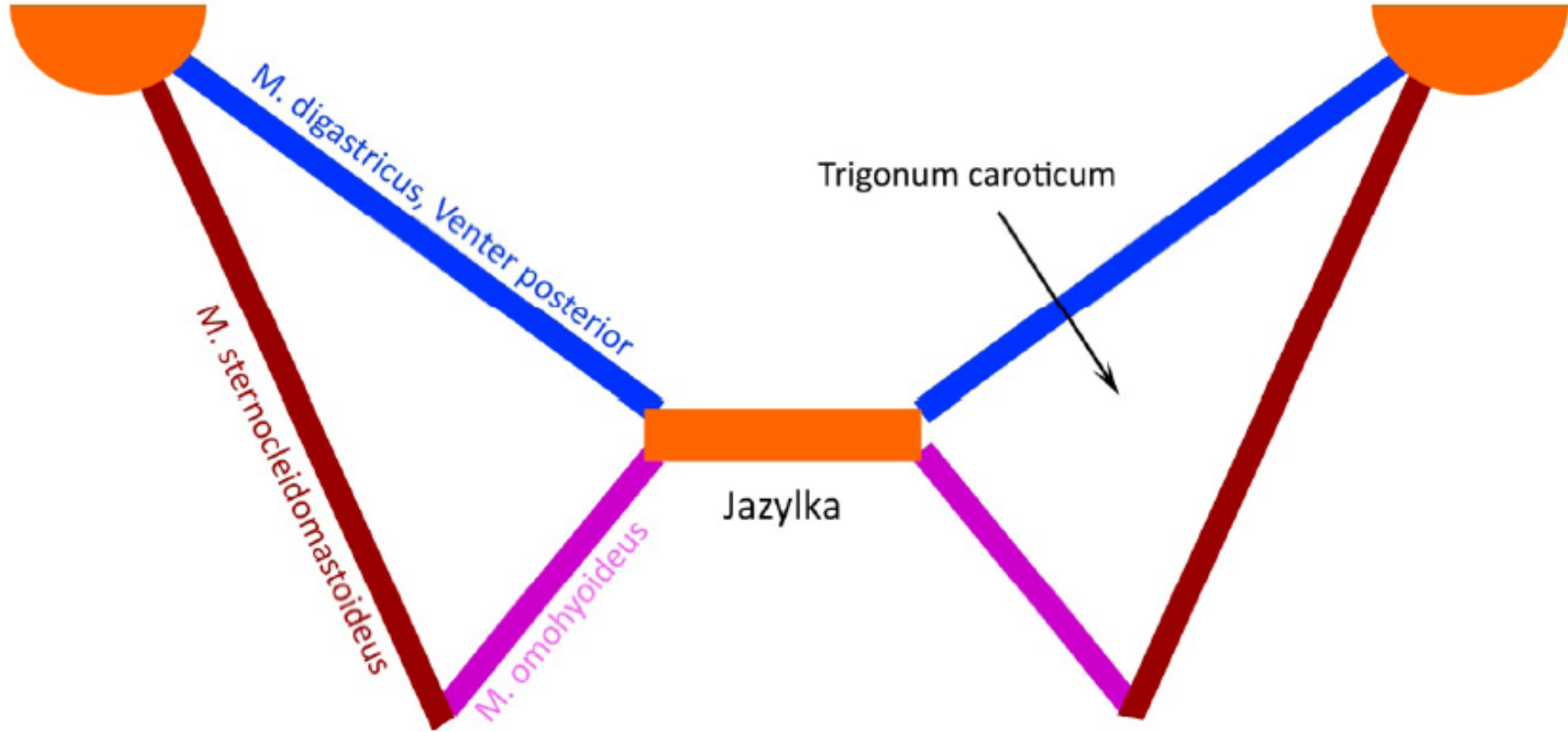
C2

Trigonum suboccipitale

Arteria vertebralis

Trigonum caroticum

processus mastoideus



Trojúhelníky na krku

