

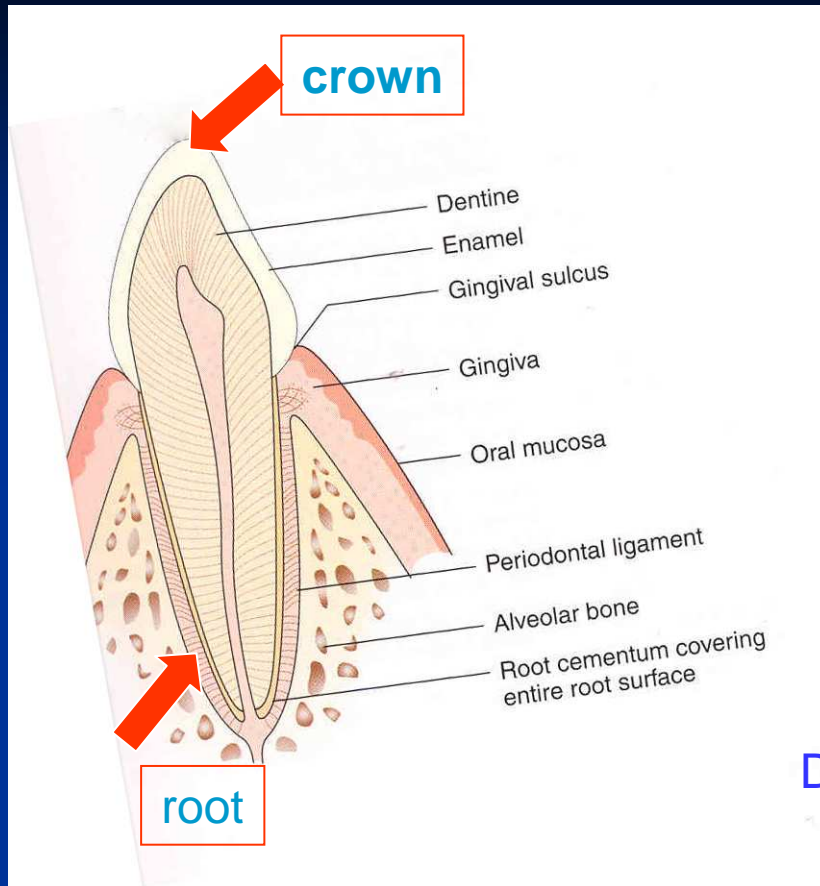
Periodontology

Periodontology

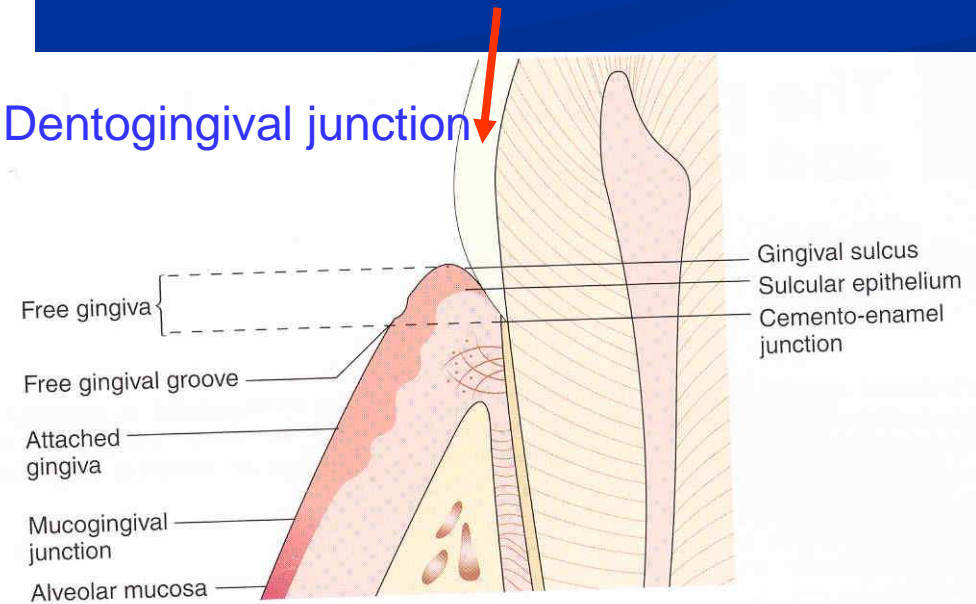
- Periodontal tissues (supportive tissues)
 - alveolar bone
 - cementum
 - periodontal ligament
 - gingiva

Morphology

Supportive tissues



Dentogingival junction



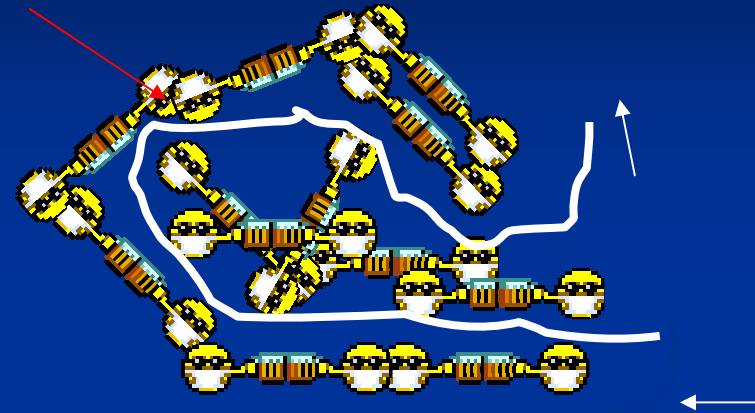

Periodontal diseases

- Inflammation at most!!!!
- The most important ethiological factor?

 **Dental plaque!!!!** 
BIOFILM

Dental plaque = biofilm

■ Community



■ Primitive circulation

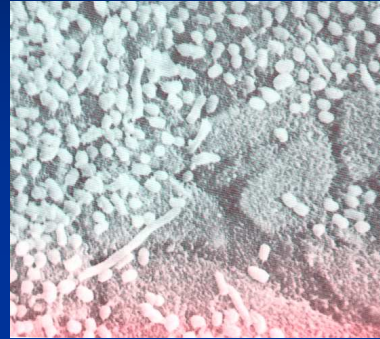


More species
Higher metabolic activity
Higher resistance
(*S. sobrinus* CHX 300x, AF 75x)

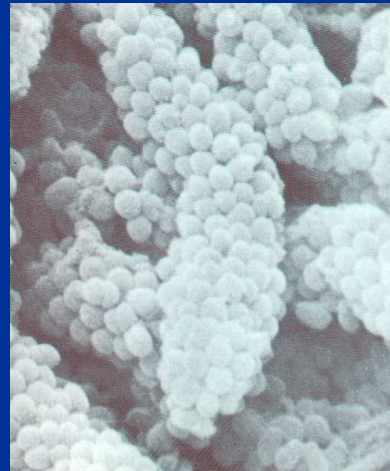
} better conditions to survive
higher virulence

Biofilm

- Adherence

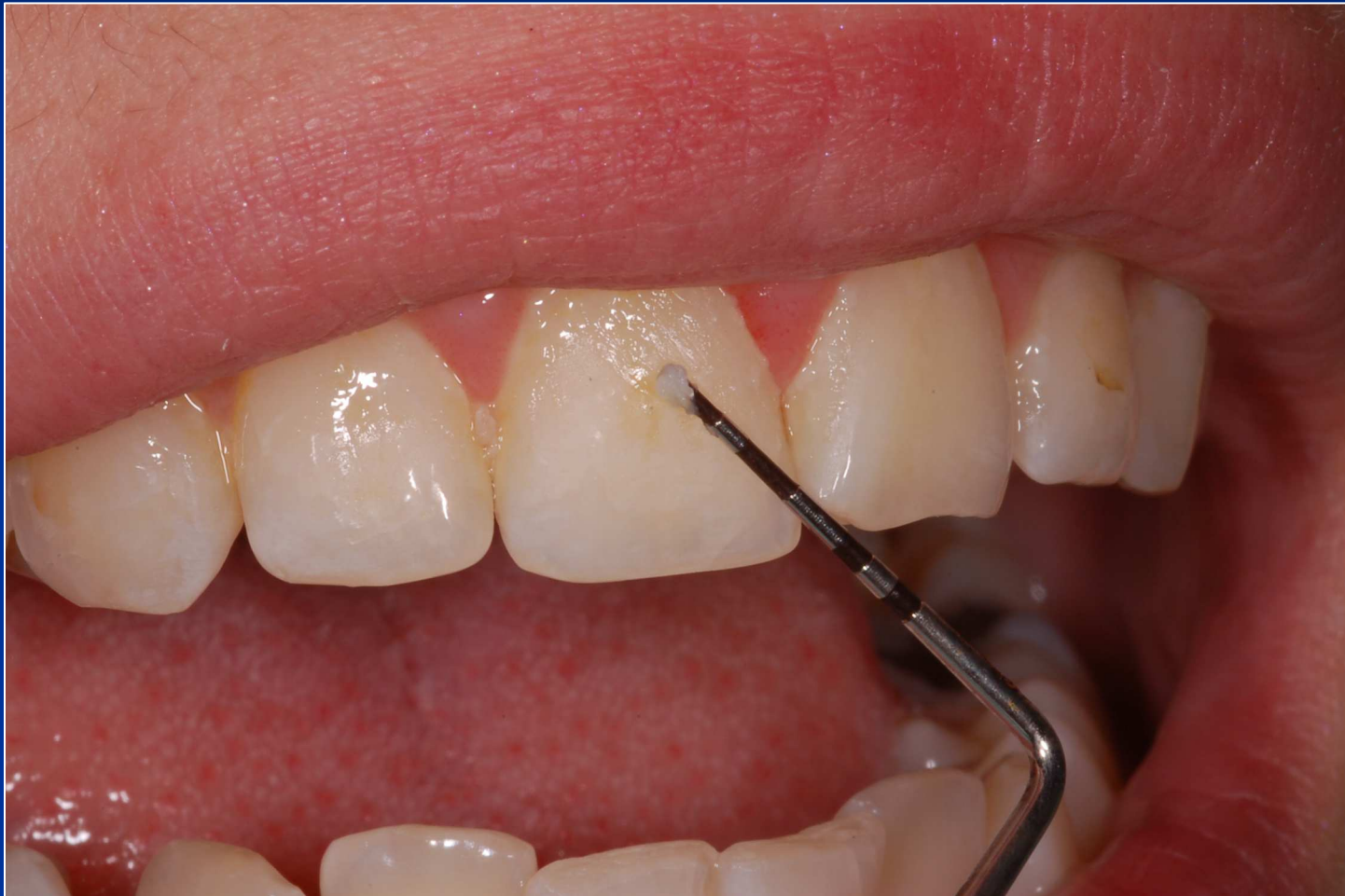

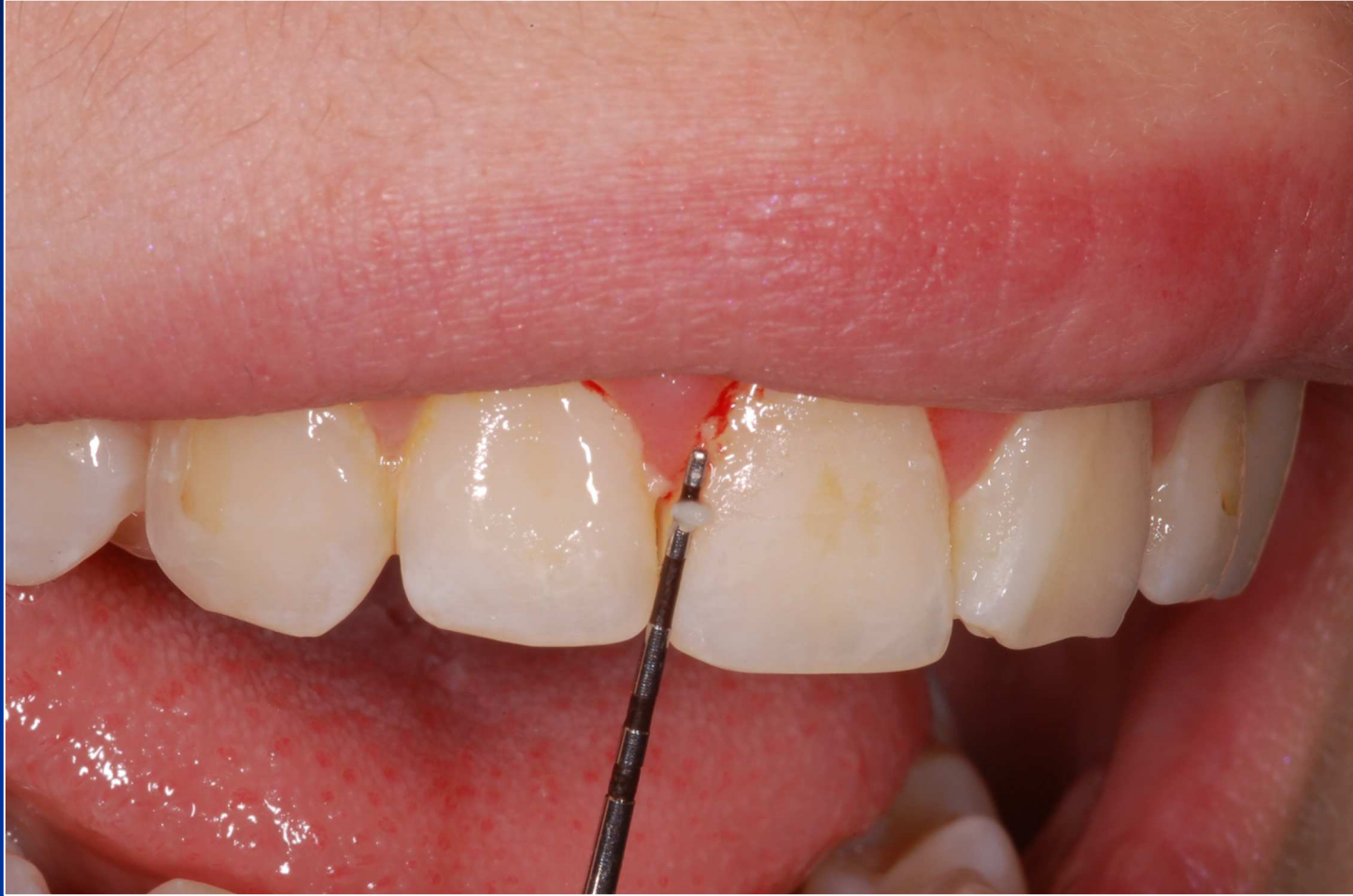- Colonisation



- Maturation

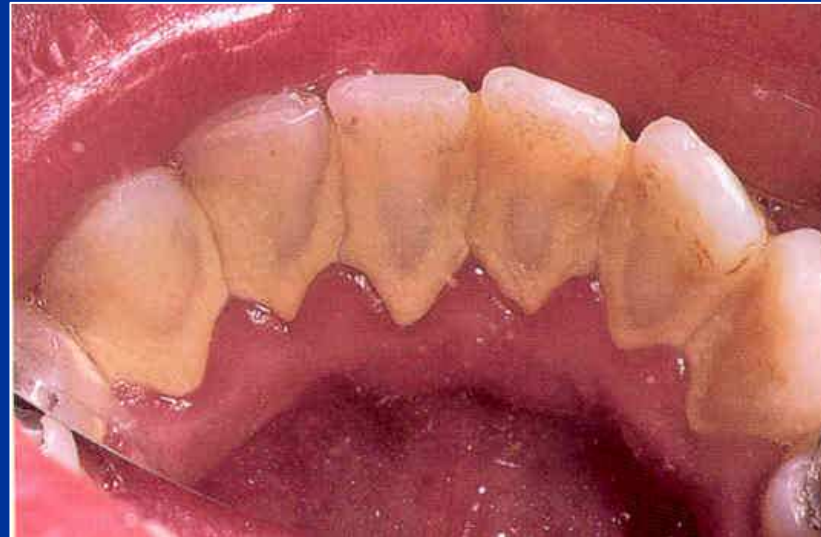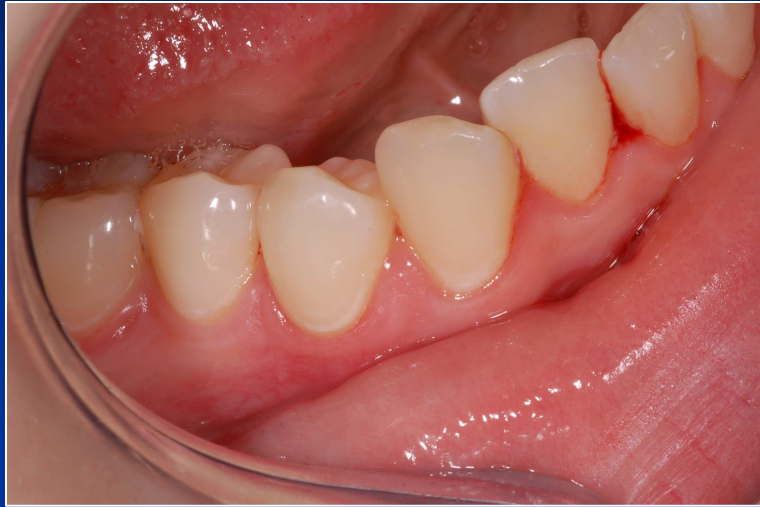Can it be recognised and removed easily?





Other aetiological factors

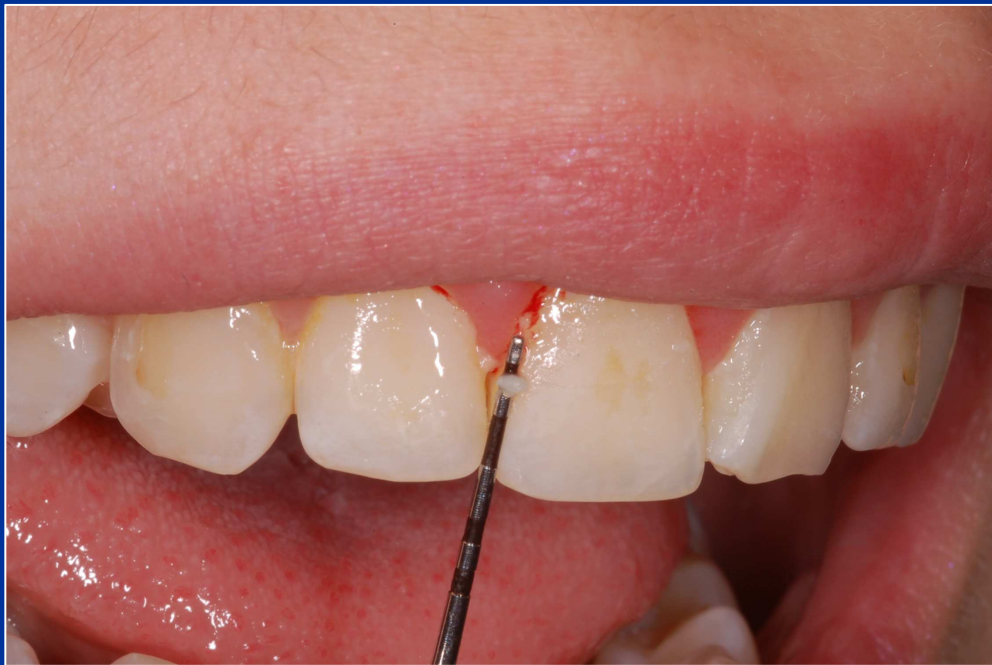- Calcified deposit on teeth, plaque on the surface
- Overhangs, crowns, dentures
- Genetic factors – gen polymorphism



Parodontopathies

Gingivitis

■ Plaque associated gingivitis



Chronic form

Erythema

No pain

Easy bleeding

Plaque on the tooth

Acute form

Erythema

Pain

Easy bleeding

Plaque on the
tooth

Acute necrotising gingivitis - ANUG

- Necrotizing ulcerative gingivitis

Aetiology

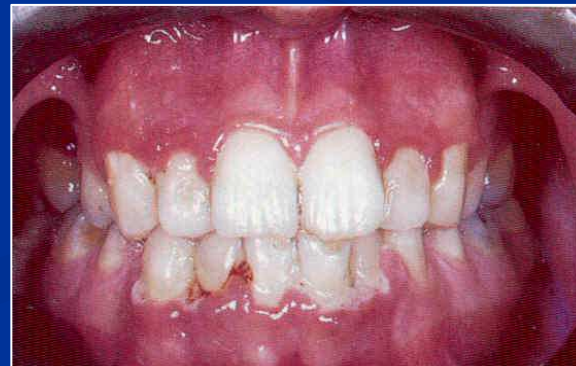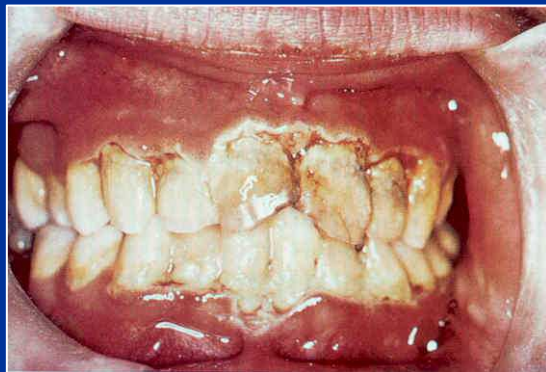Special microbes - anaerobes

The clinical picture

- Gingival inflammation and destruction



Severe pain, bleeding gums, halitosis



Diferential diagnosis

- Herpetic gingivostomatitis
 - Young people
 - Prodroms
 - Pyrexia
 - Lymphadenopathy
 - Lesions more widespread and diffuse

Diferential diagnosis

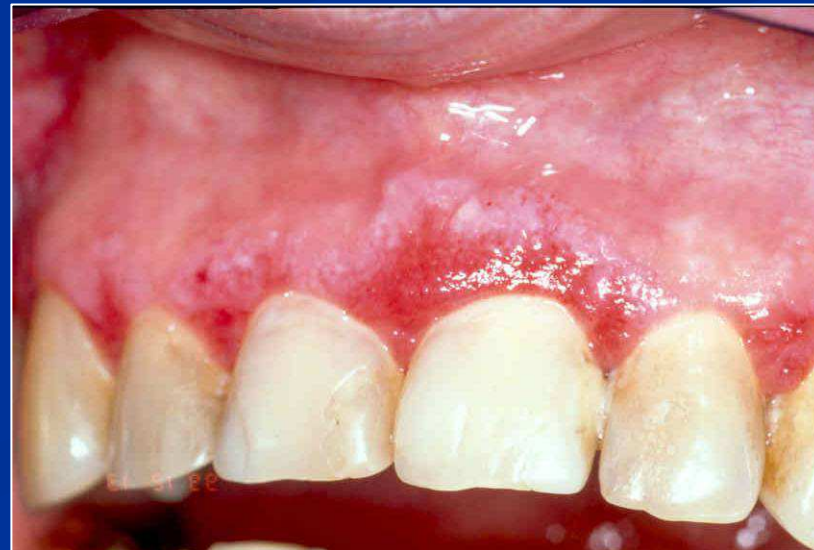- If ANUG does not tend to recover in 10 days – check the blood picture!



Atrophic or desquamative gingivitis

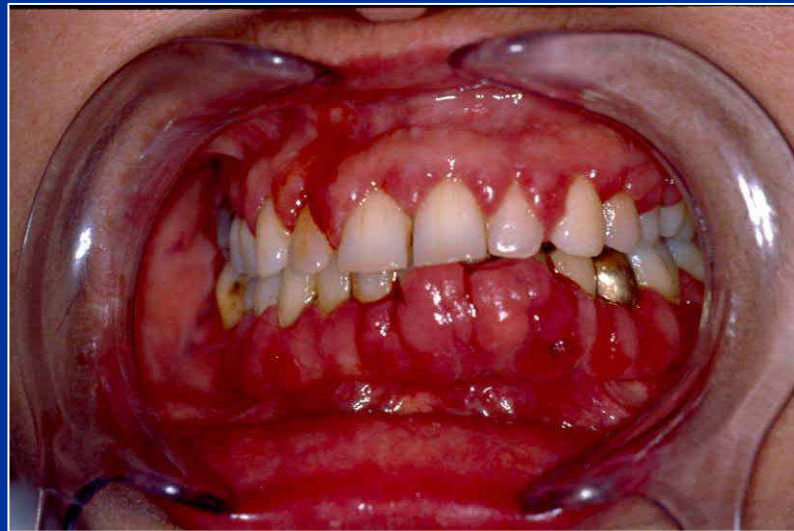
symptoms

- Erythema on free gingiva – loss of the epithelium
- Variety of symptoms: itching, tenderness of eating, burning.



Hyperplastic gingivitis

- High standard of oral hygiene must be achieved!
- Gingivectomy (drugs induced)



Parodontopathies

Periodontitis

- Chronic periodontitis.
- Aggressive periodontitis.
- Periodontitis as a manifestation of systemic disease.
- Necrotizing periodontal diseases.
- Abscesses of the periodontium.
- Periodontitis associated with endodontic lesions.
- Development or acquired deformities and conditions.

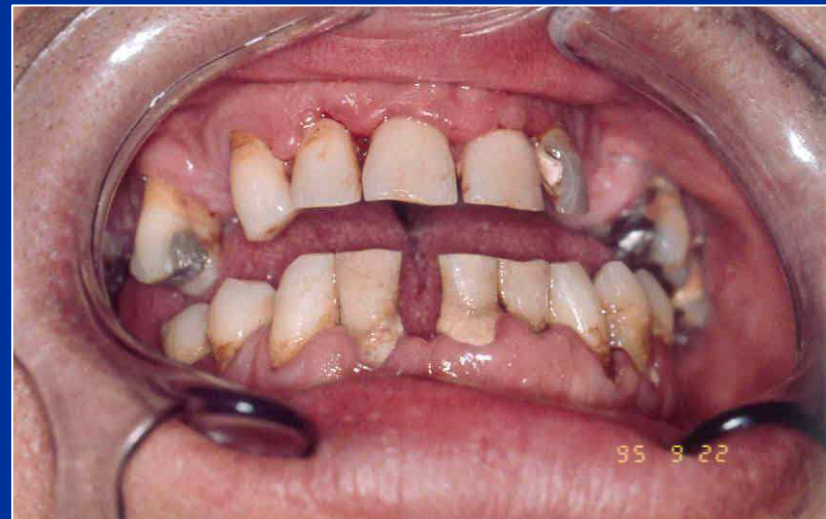Parodontopathies

Periodontitis

- Chronic periodontitis.
- Aggressive periodontitis.
- Periodontitis as a manifestation of systemic disease.
- Necrotizing periodontal diseases.
- Abscesses of the periodontium.
- Periodontitis associated with endodontic lesions.
- Development or acquired deformities and conditions.

Periodontitis

- Gingivitis
- Pocketing
- Loss of alveolar bone
- Drifting and mobility
- Furcation exposures
- Recession

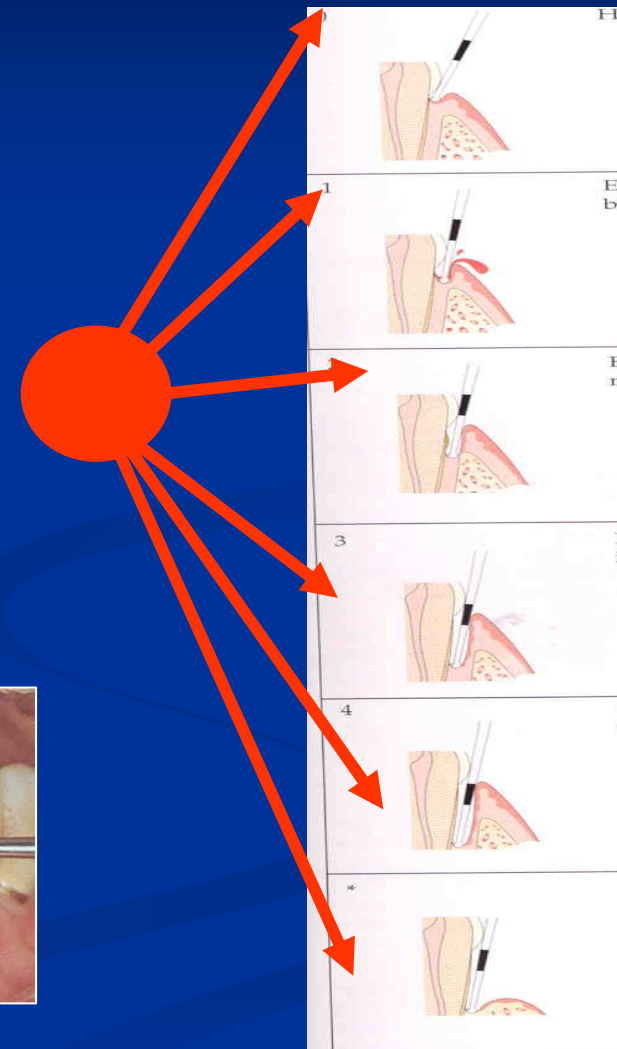
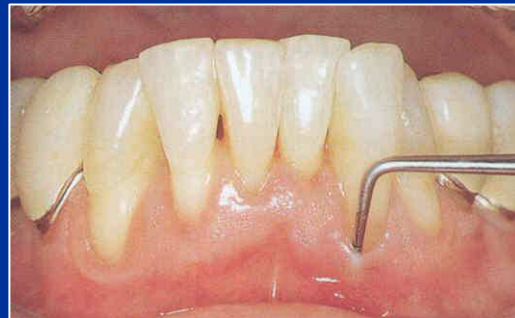

Periodontitis

- Gingivitis
- Pocketing
- Loss of alveolar bone
- Drifting and mobility
- Furcation exposures
- Recession

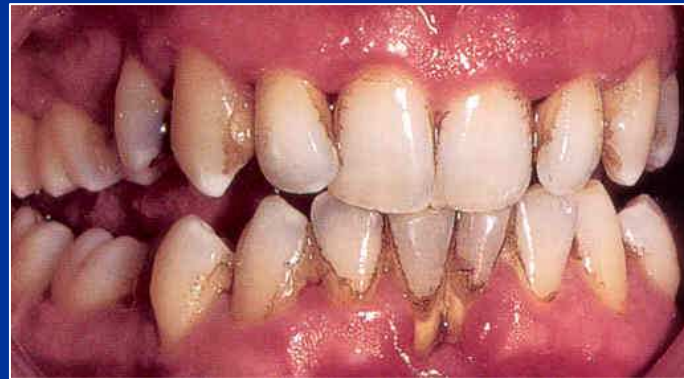Periodontitis

- Gingivitis
- Pocketing
- Loss of alveolar bone
- Drifting and mobility
- Furcation exposures
- Recession



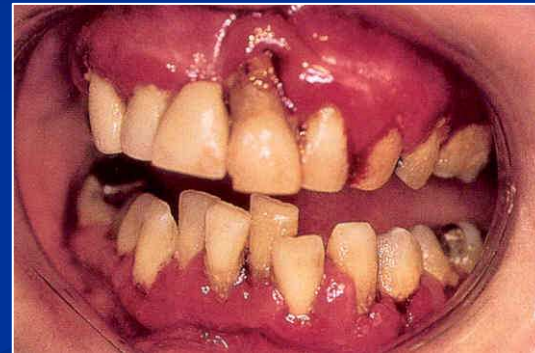Periodontitis

- Gingivitis
- Pocketing
- Loss of alveolar bone
- Drifting and mobility
- Furcation exposures
- Recession



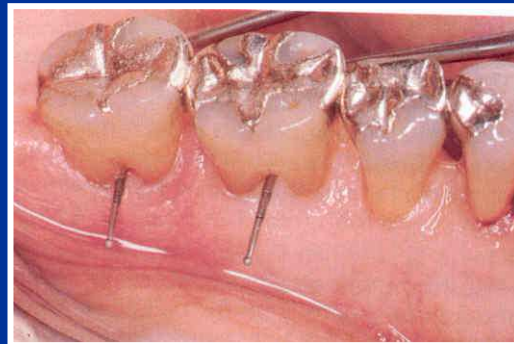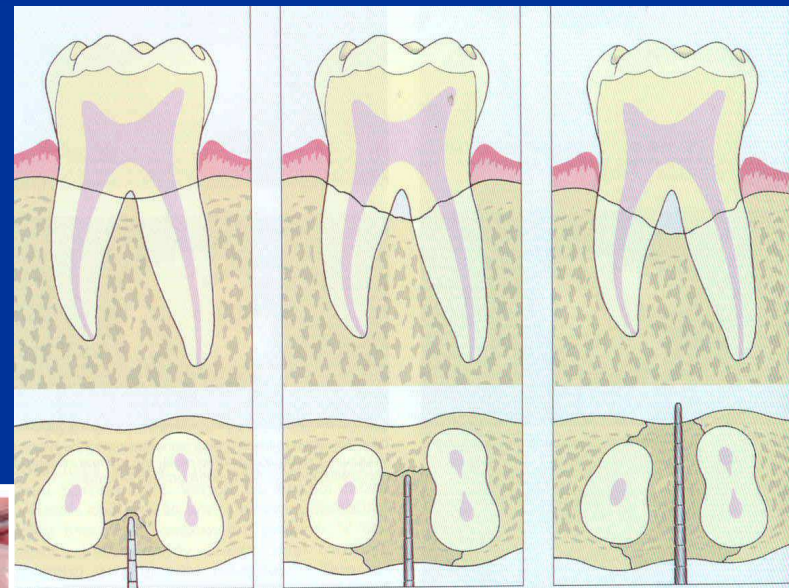

Periodontitis

- Gingivitis
- Pocketing
- Loss of alveolar bone
- Drifting and mobility
- Furcation exposures
- Recession



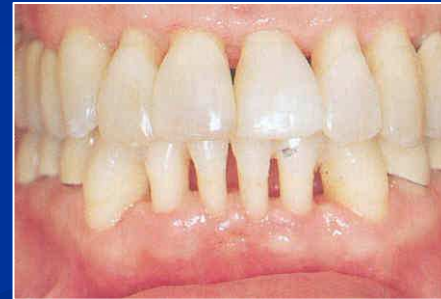Periodontitis

- Gingivitis
- Pocketing
- Loss of alveolar bone
- Drifting and mobility
- Furcation exposures
- Recession



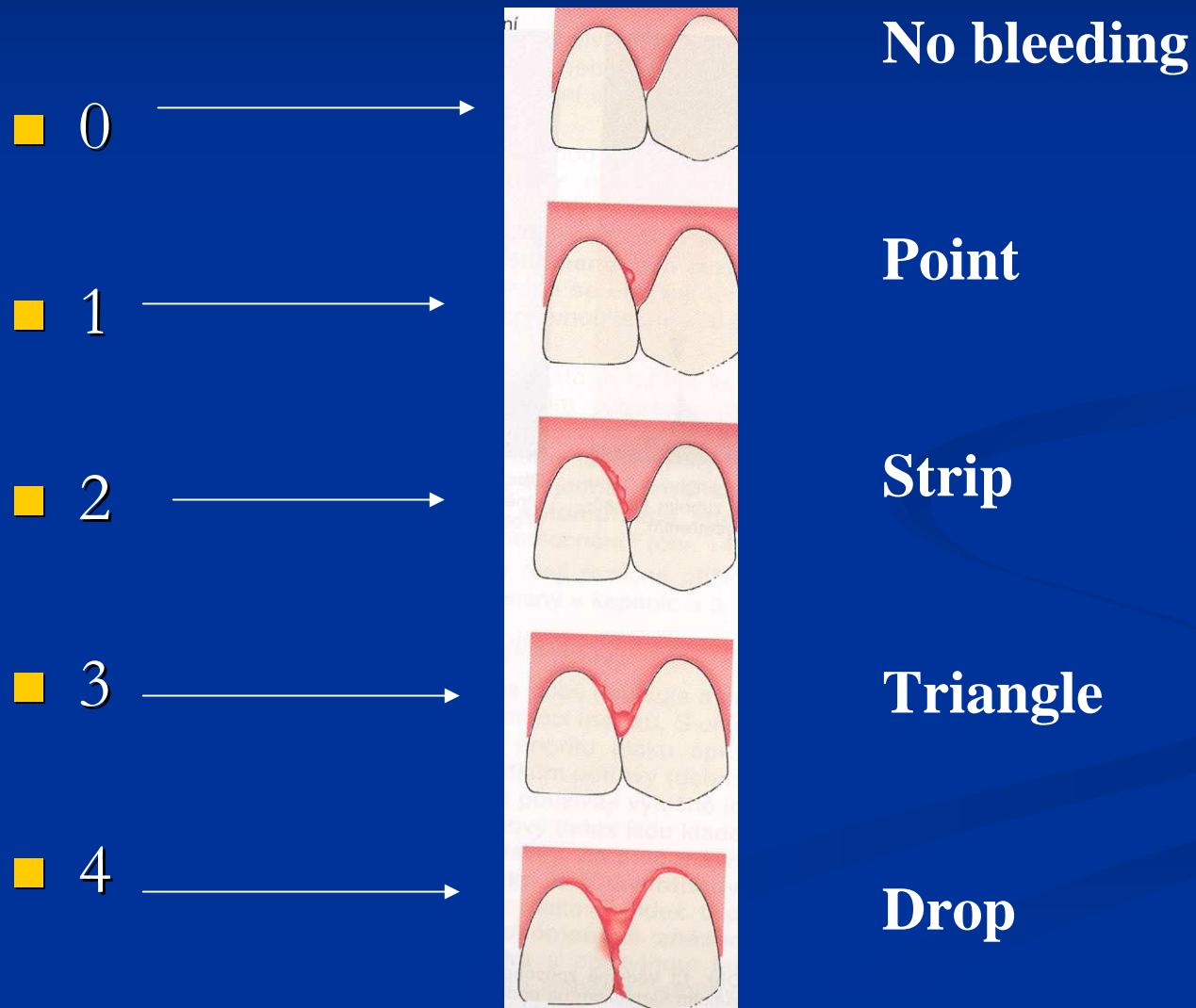
Periodontitis

- Gingivitis
- Pocketing
- Loss of alveolar bone
- Drifting and mobility
- Furcation exposures
- Recession



Indexes

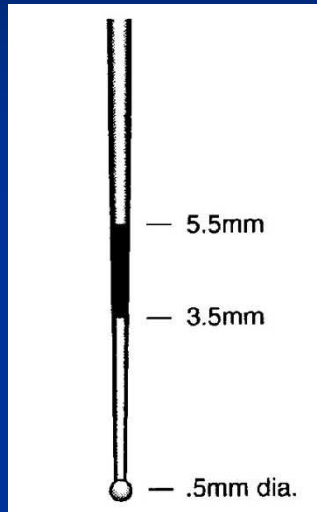
PBI – papilla bleeding index



CPITN

(Community periodontal
index of treatment needs)

WHO probe



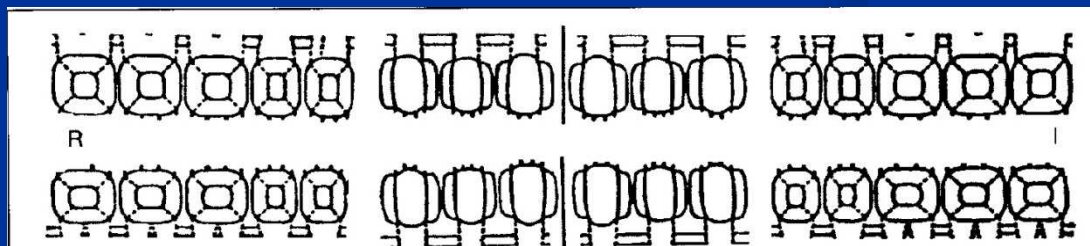
0 – no changes

1 – bleeding (oral hygiene)

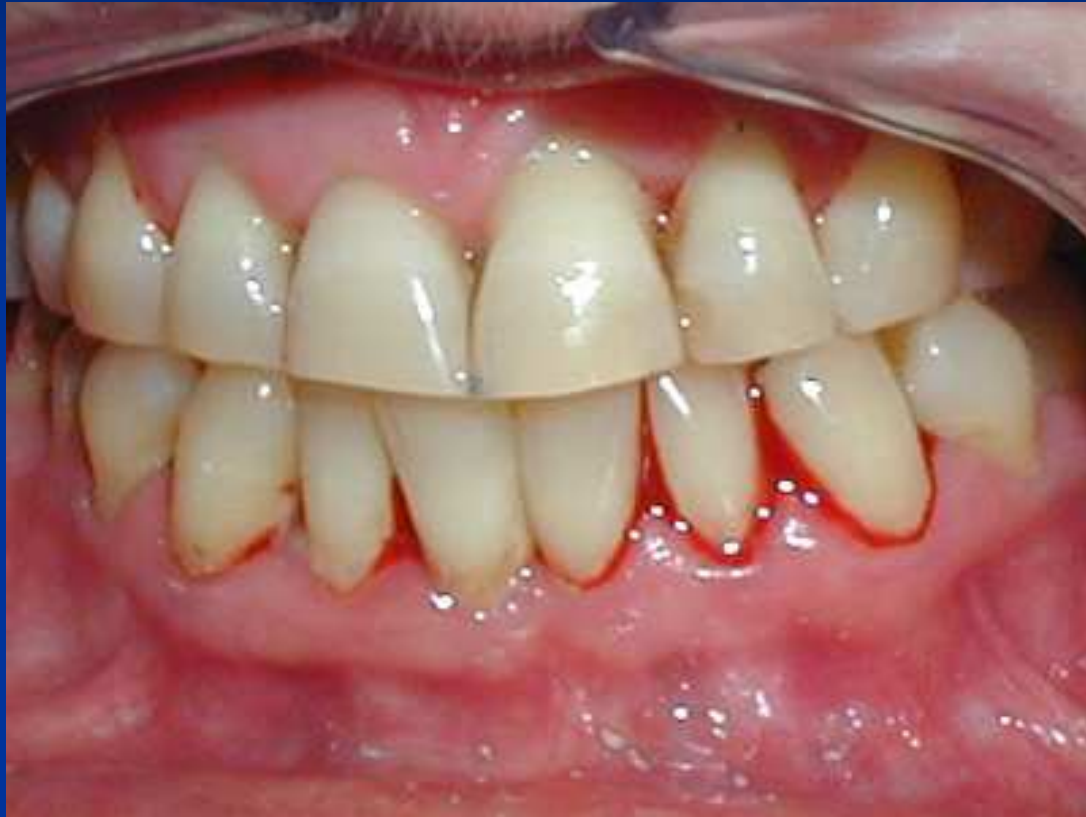2- dental calculus (removal of dental calculus, oral hygiene)

3 –periodontal pocket 3,5 – 5,5 mm (subgingival treatment)

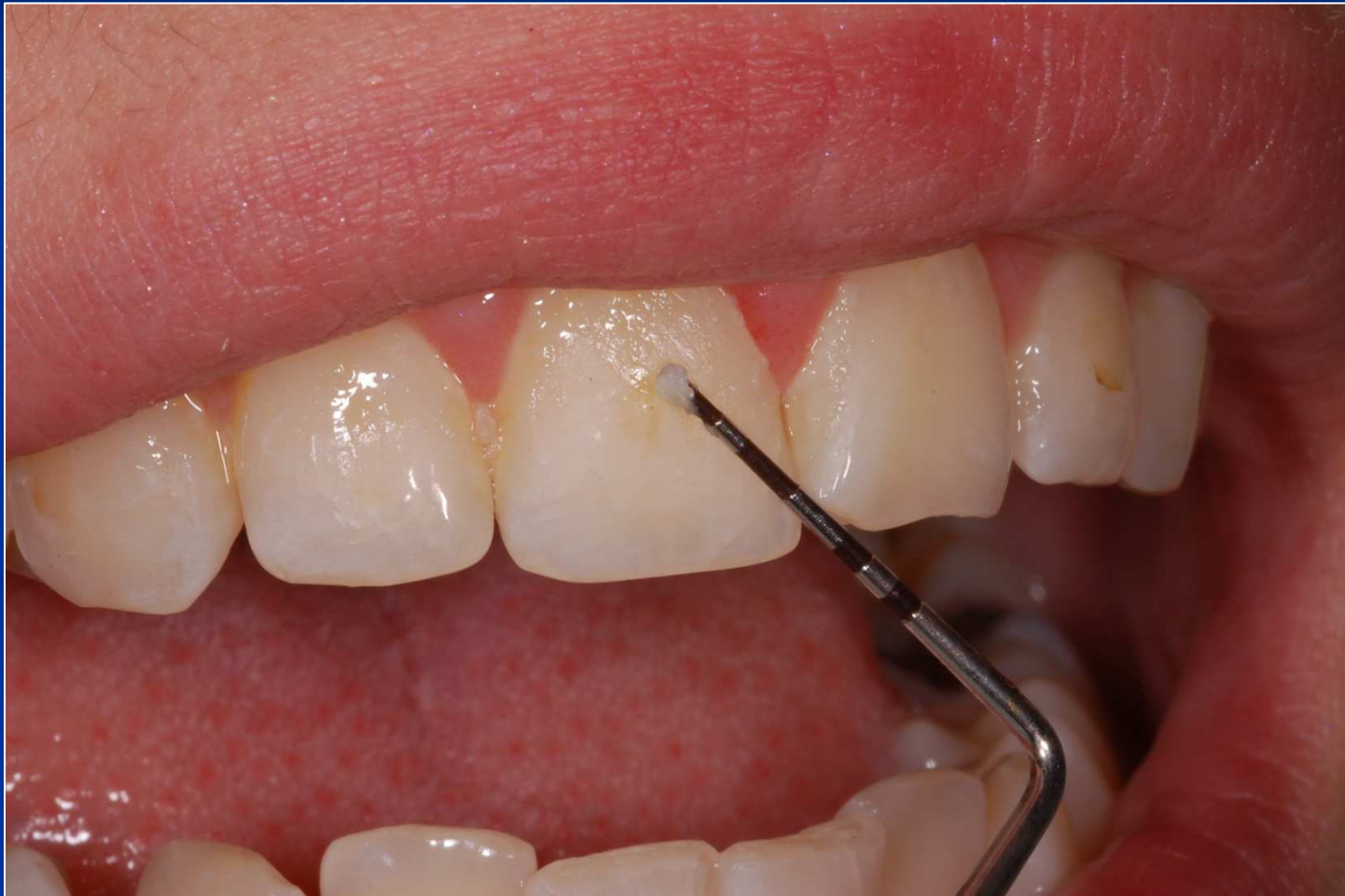4 – periodontal pocket more than 6 mm
subgingival treatment, periodontal surgery.



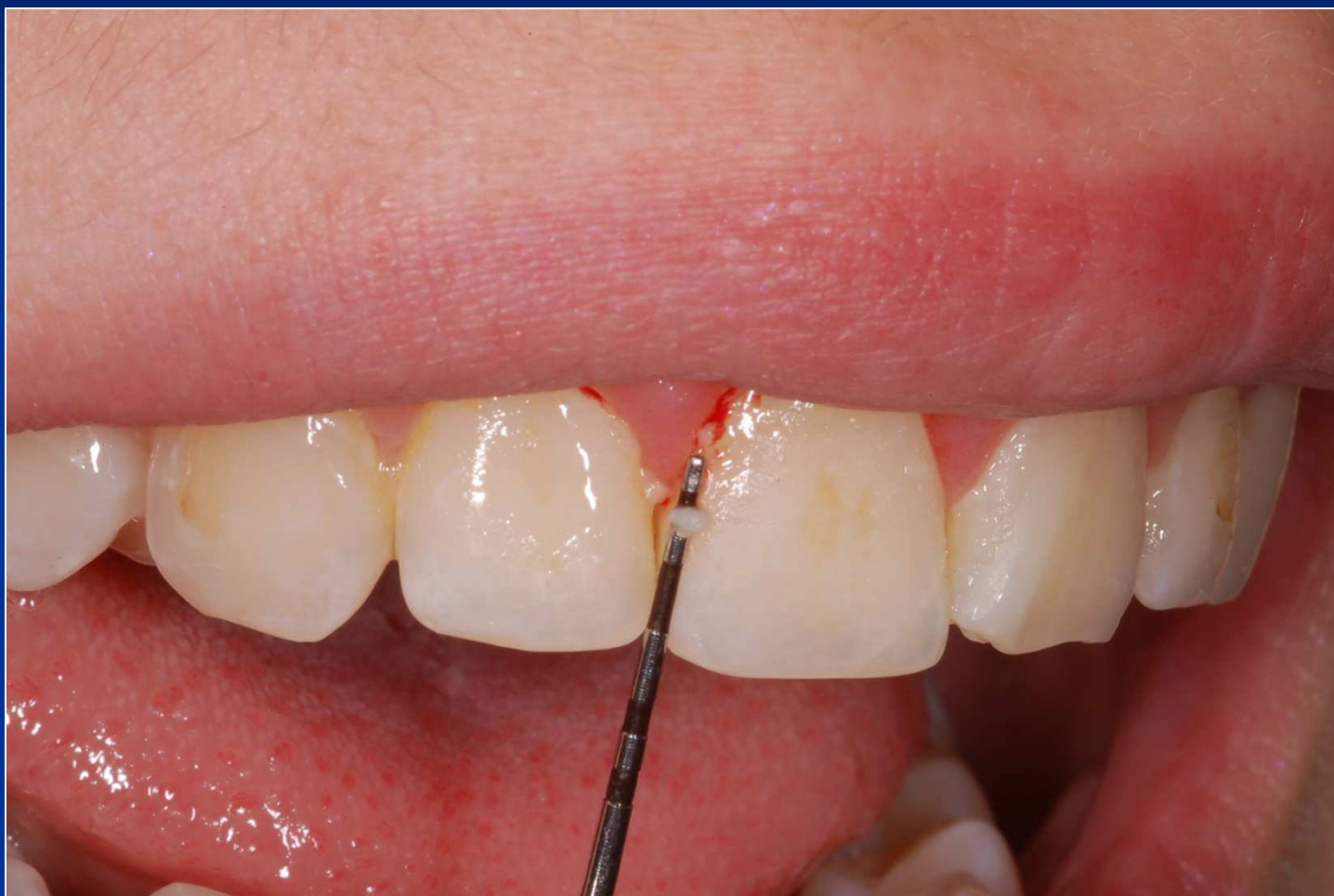17 ←	□	→ 14	13 ←	□	→ 23	24 ←	□	→ 27
47 ←	□	→ 44	43 ←	□	→ 33	34 ←	□	→ 37



Plak



Plakem indukovaný zánět



Měření a výpočet indexu, jeho význam

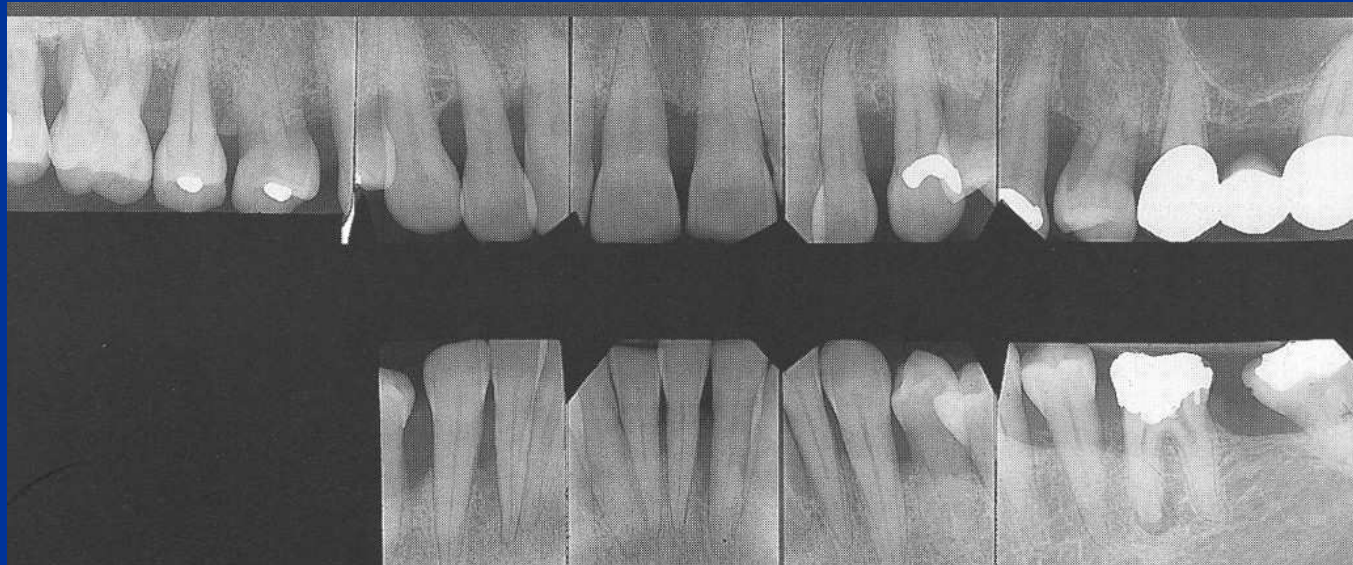
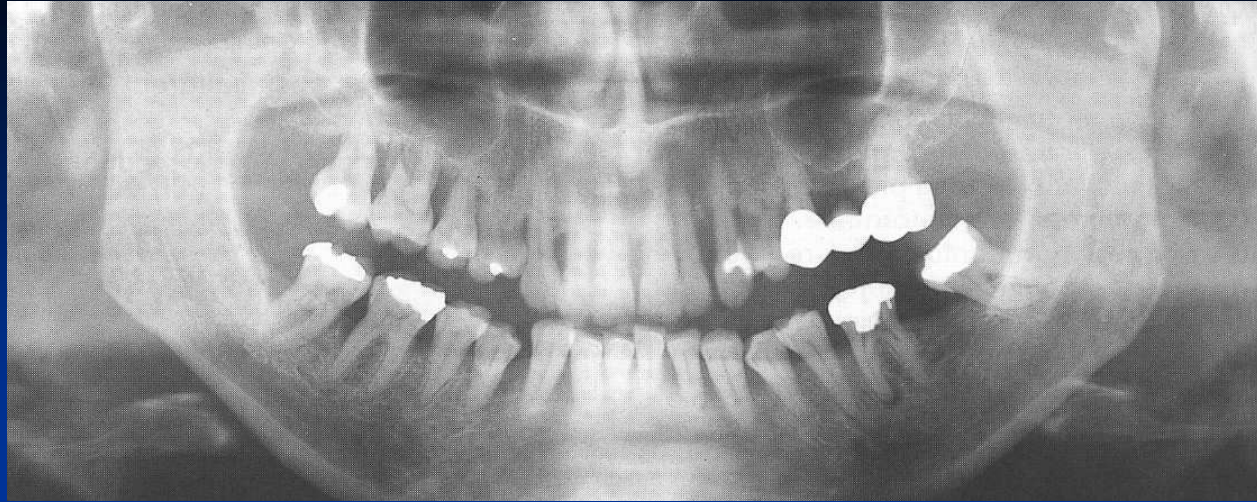
PBI

ORÁLNE		MAXILLA										VESTIBULÁRNE					
1													1				
2													2				
3													3				
4													4				
5													5				
6													6				
7													7				
8													8				
SÚČET													SÚČET				
SEDENIE	R3	R2	R1	5	4	3	2	1	1	2	3	4	5	R1	R2	R3	SEDENIE
SÚČET																	SÚČET
8													8				
7													7				
6													6				
5													5				
4													4				
3													3				
2													2				
1													1				
SÚČET																	SÚČET
VESTIBULÁRNE		MANDIBULA										ORÁLNE					

1	2
3	2
3	1
2	2
1	0
0	2
2	3
12	14
1	1
2	2
0	4
0	3
3	4
2	3
1	0
9	17

$$52:28 = 1,8$$

$$52/28$$



Therapy

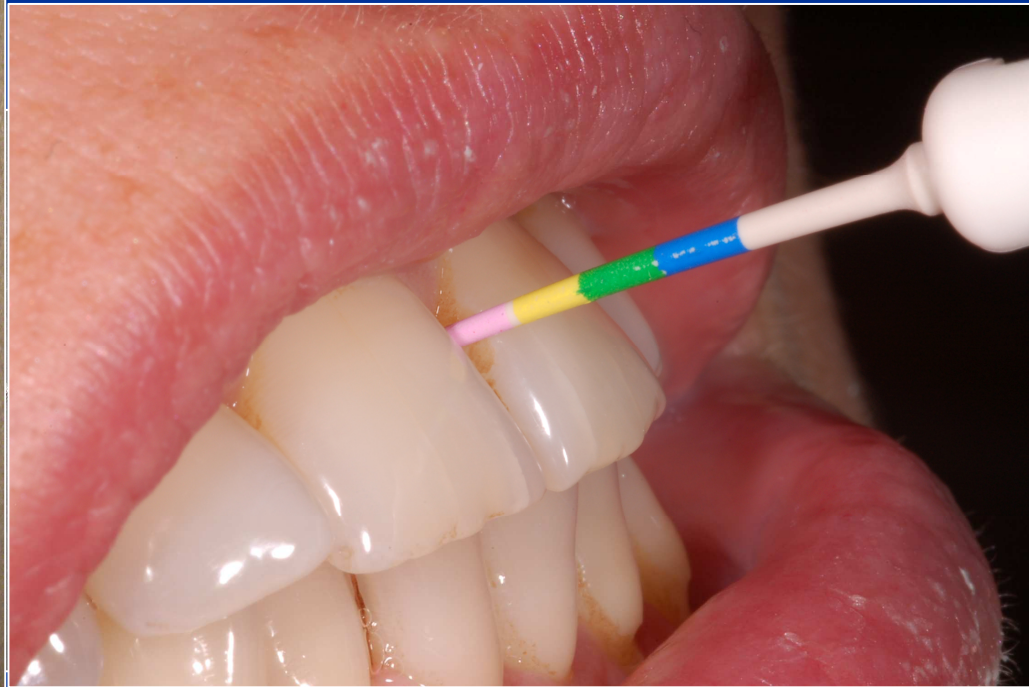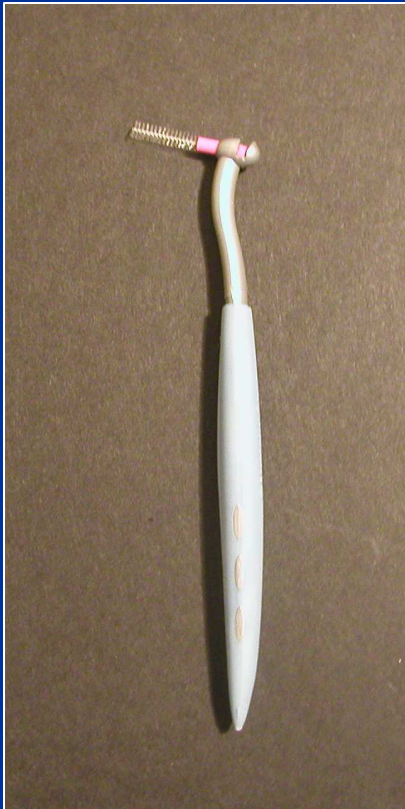- 1. Oral hygiene - professional, home care
INDIVIDUAL



Therapy

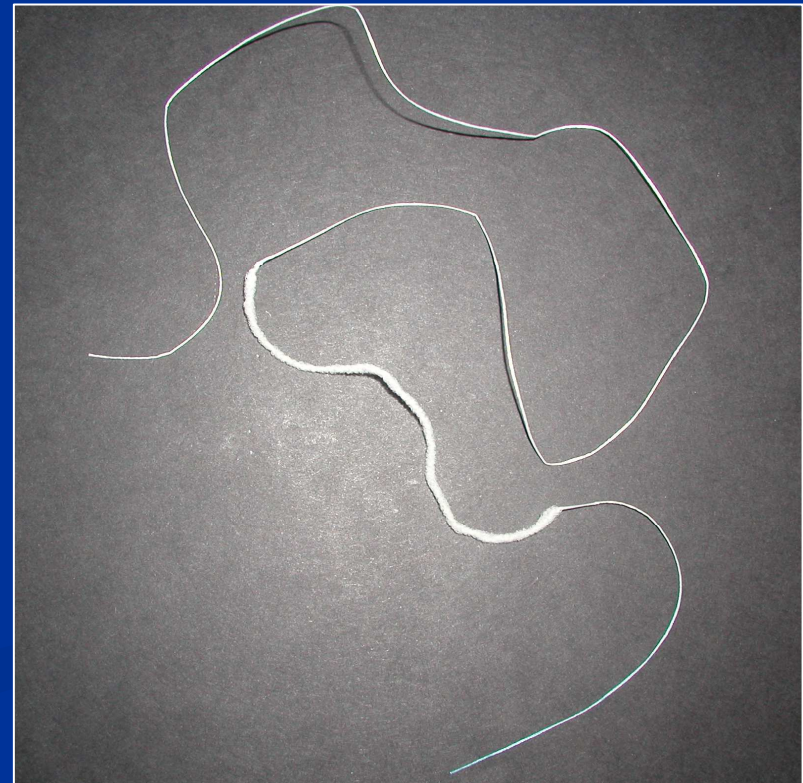

- 1. Oral hygiene - professional, home care

INDIVIDUAL



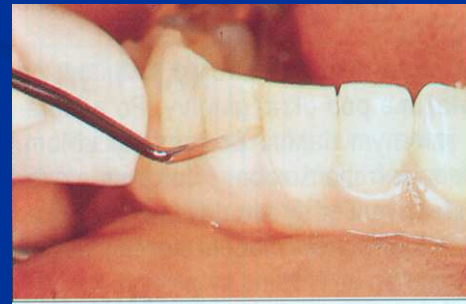
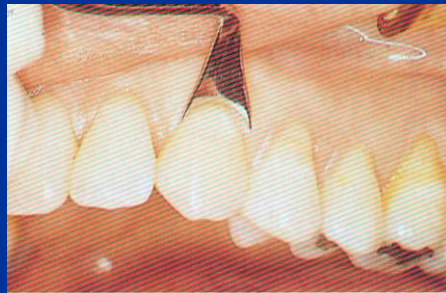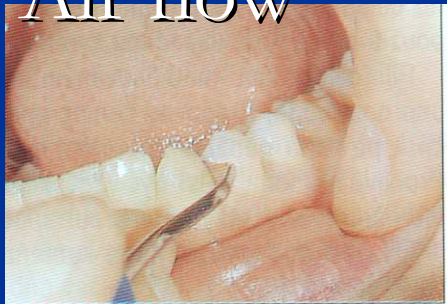
Therapy

- 1. Oral hygiene - professional, home care
INDIVIDUAL



Professional oral hygiene

- Visualisation of dental biofilm
- Calculus removal – scalars (hand instruments)
- Power driven instruments (sonic, ultrasonic)
- Polishing
- Air flow



Scalers

for the supragingival treatment

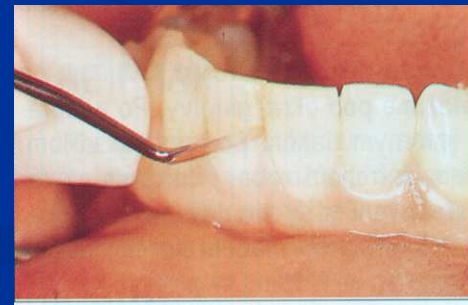
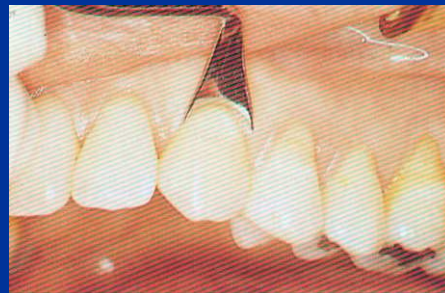
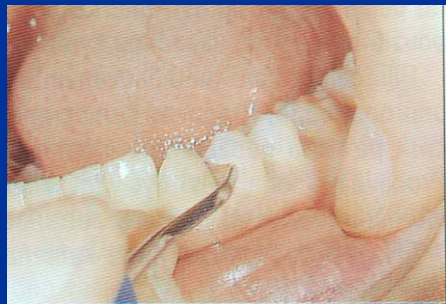
- Sharp pointed instruments

Sickle- scaler

Claw- scaler

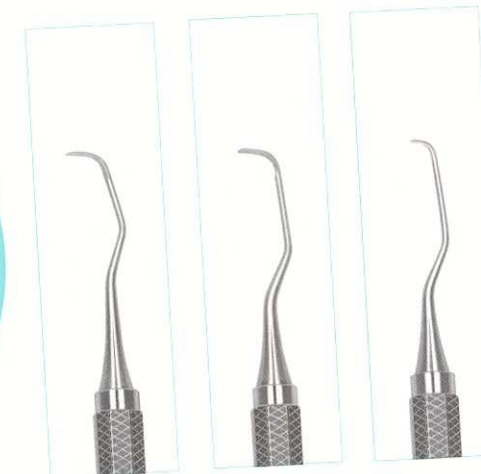
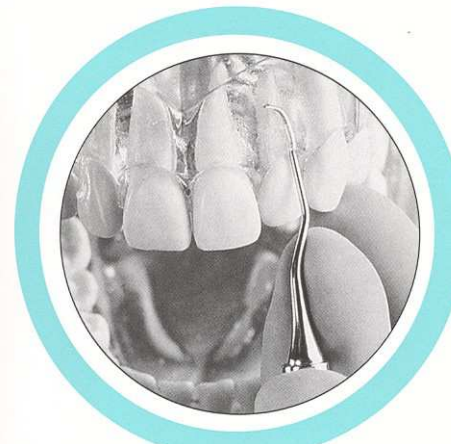
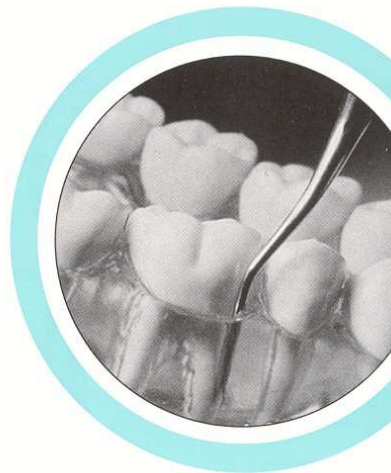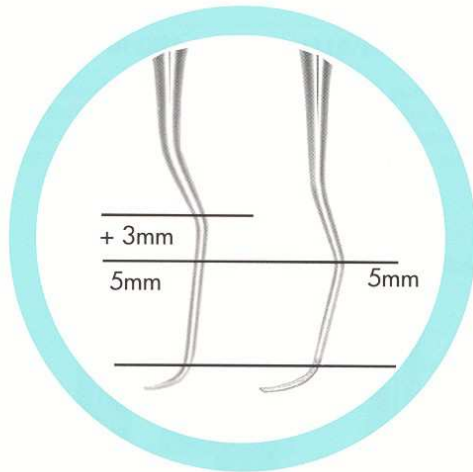
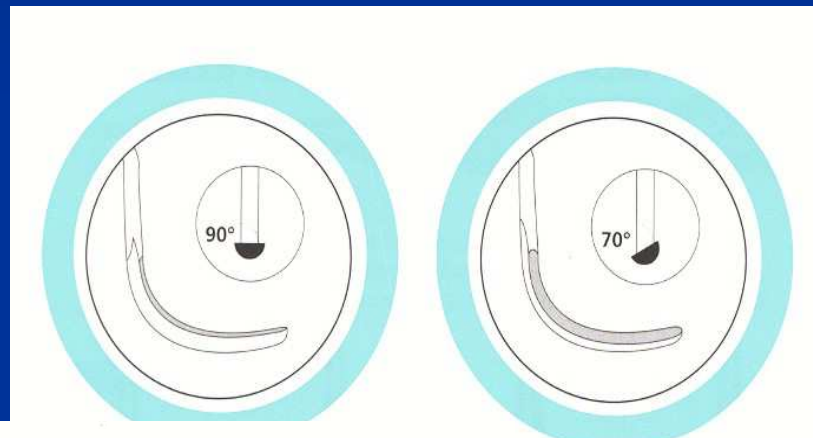
Scraper –scaler

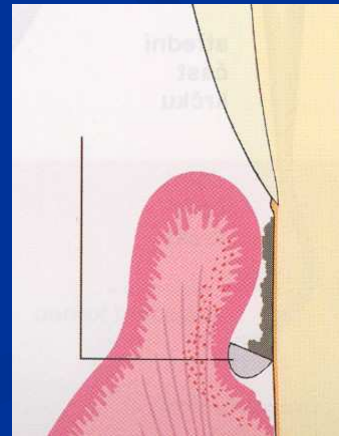
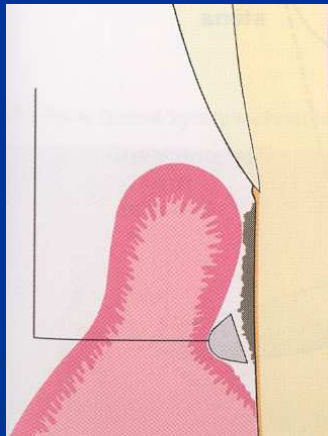
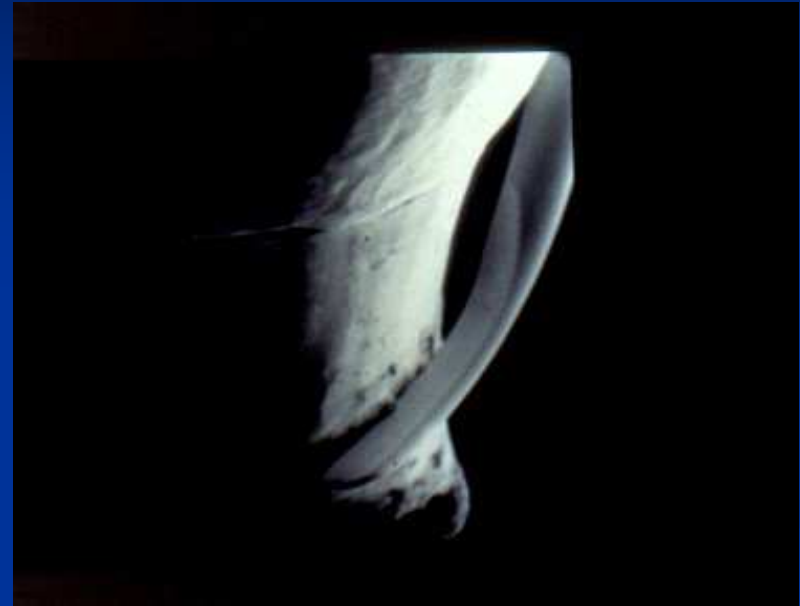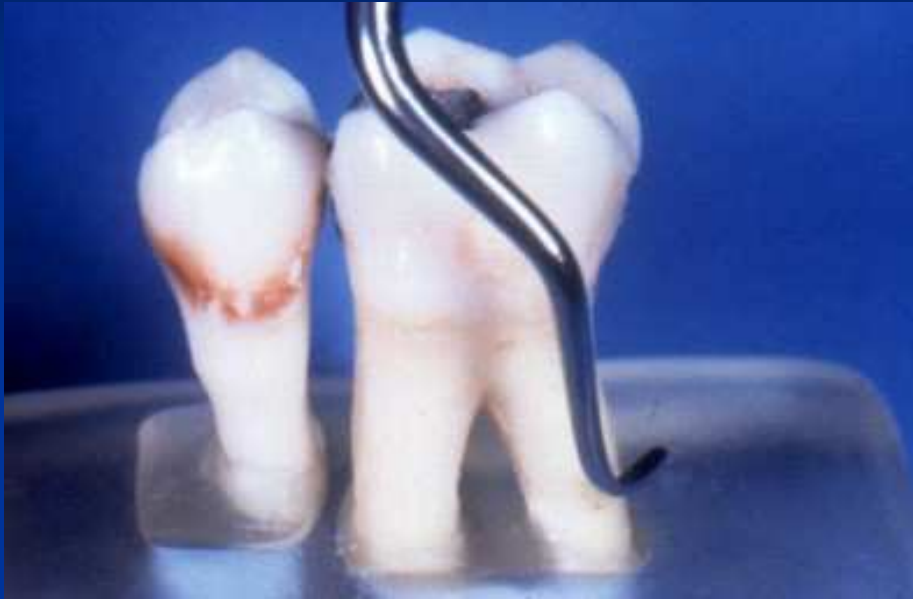Double angle scaler



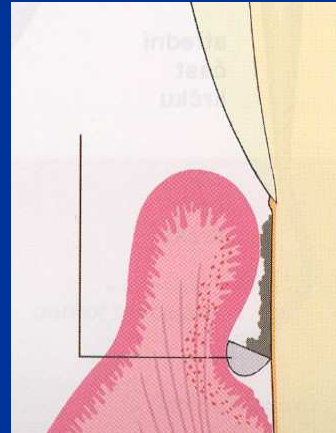
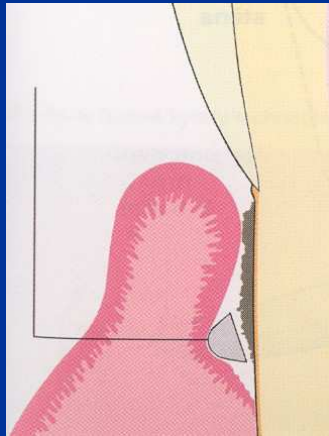
Currettes

Sharp spoons, for subgingival treatment



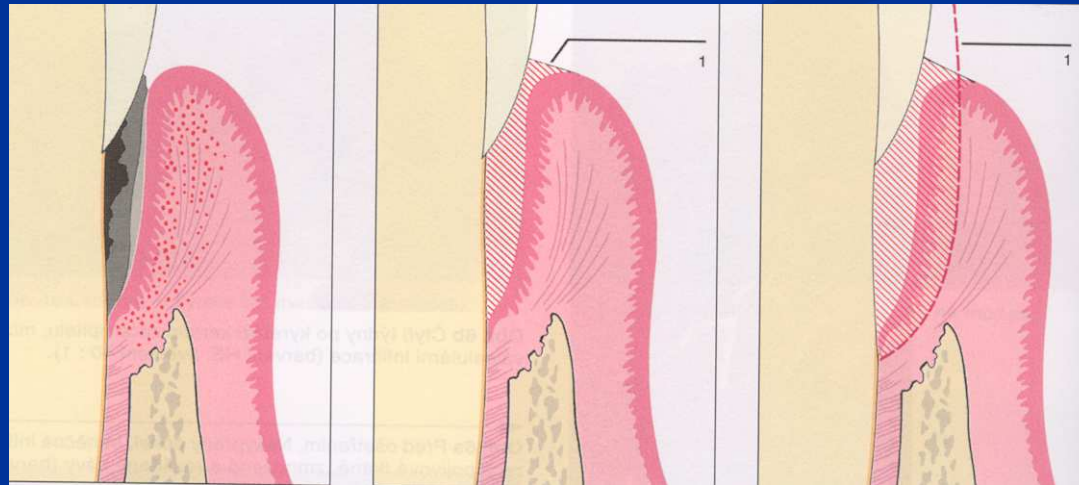



Scaling, root planing



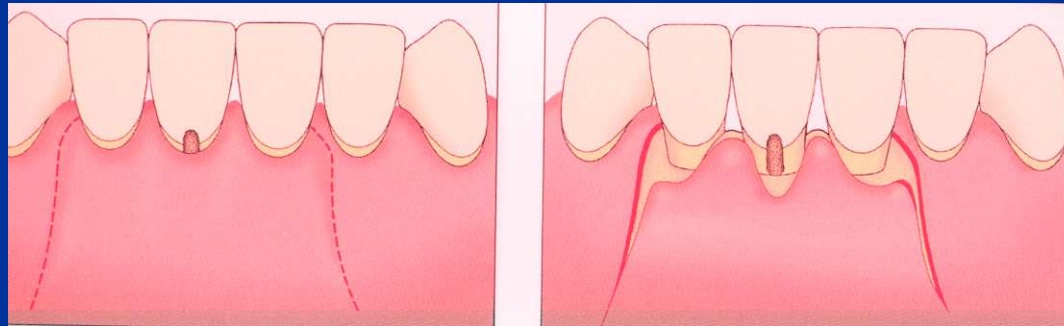
Therapy

- 2. Subgingival treatment – scaling root planing, curettage



Therapy

- 3. Periodontal surgery

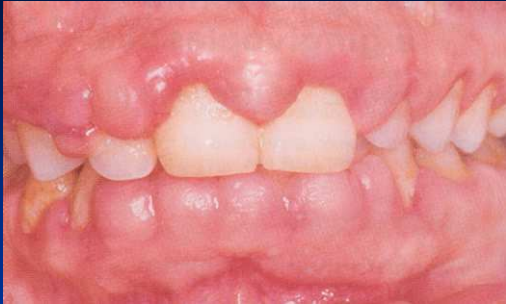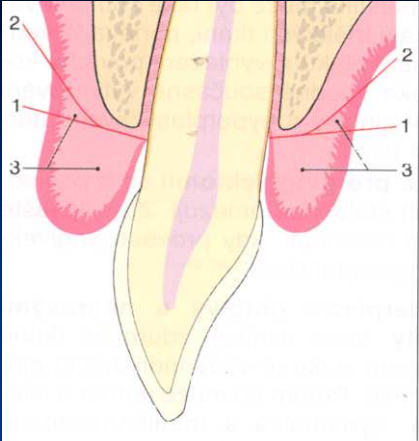


Gingivectomy, gingivoplastic

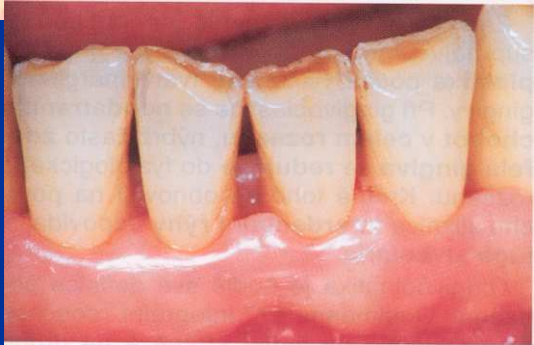
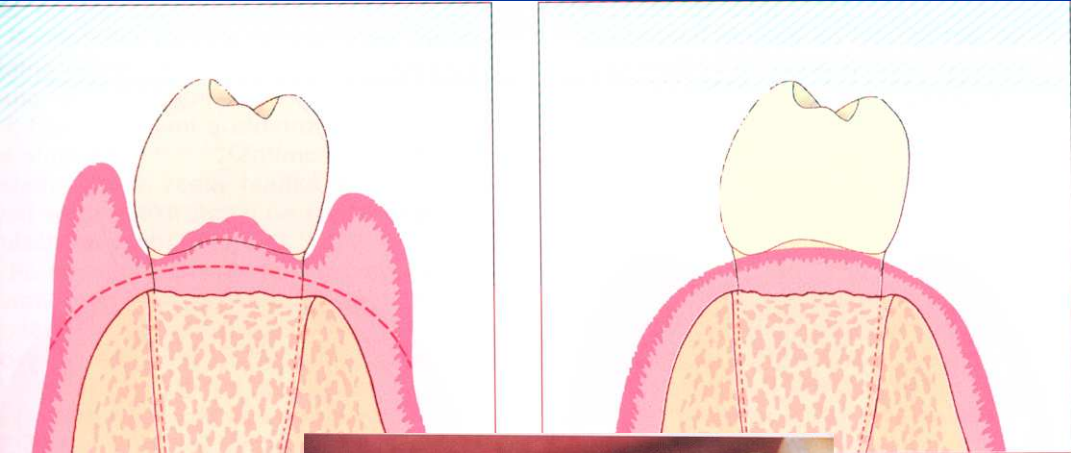
Indications of gingivectomy

- Hyperplasia gingivae (pseudopockets)
- Supraalveolar periodontal pockets with the horizontal bone resorption
- - Bad configuration of the gingival margin or papilla fol. ANUG or extraction.

Gingivectomy

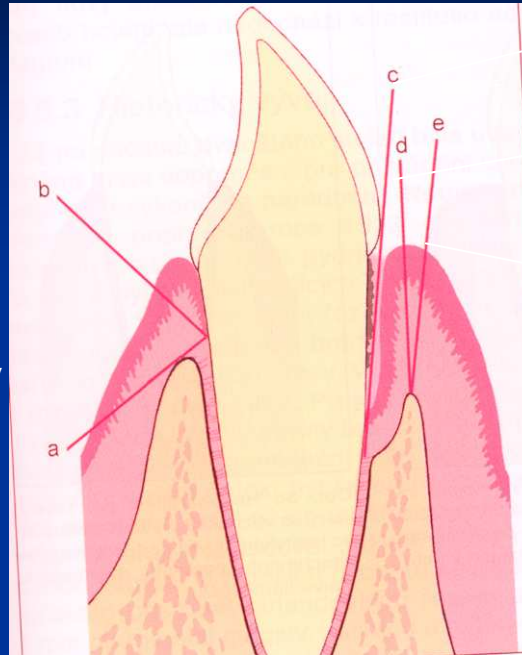


Gingivoplastic



Internal gingivectomy

External gingivectomy



Intrasulcular

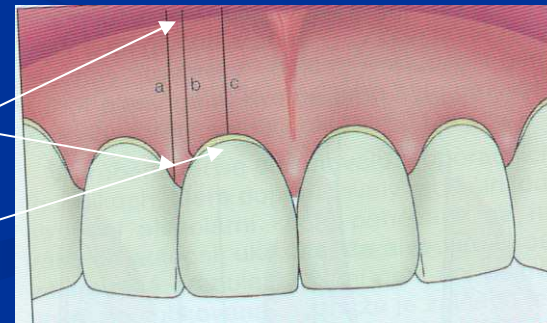
Marginal

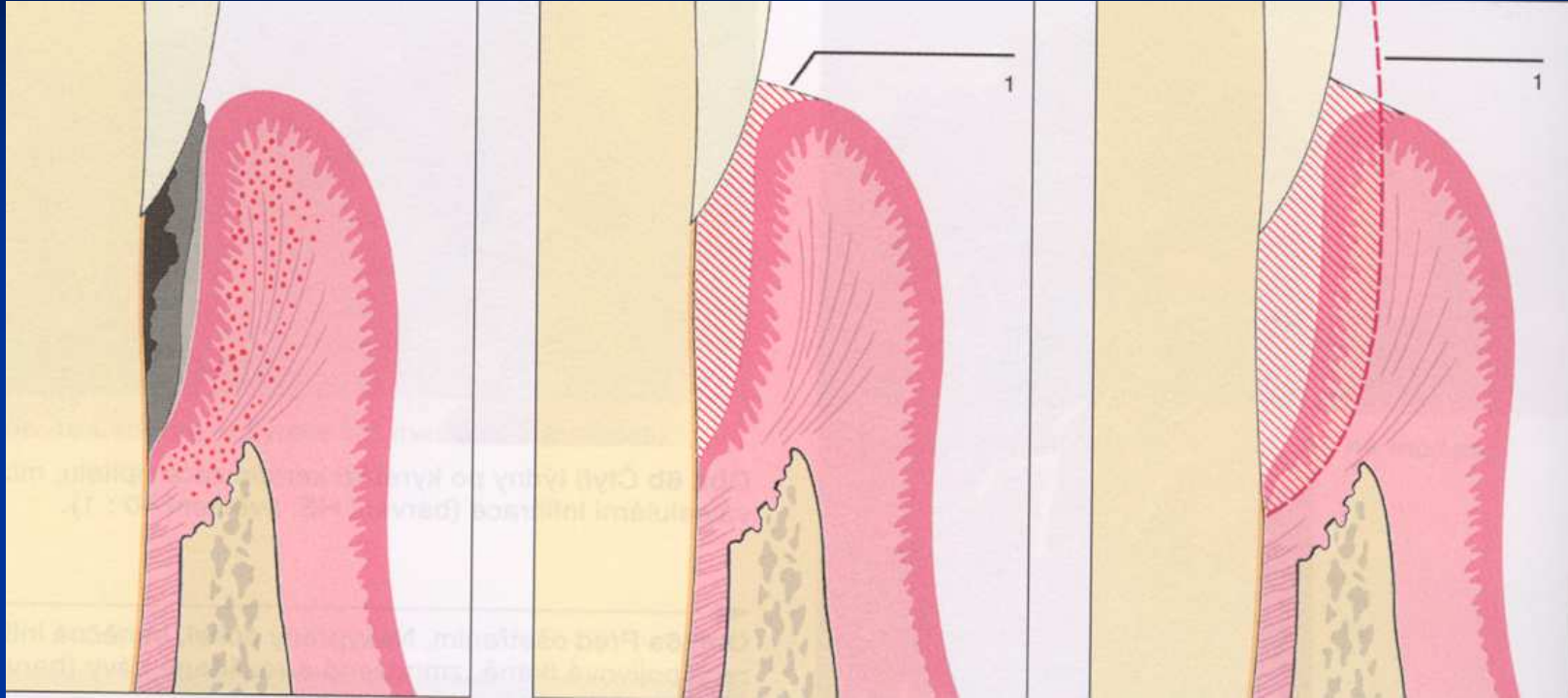
Paramarginal

Papilar

Paramedial

Medial





Closed curettage

Flap operation

Modified Widman flap

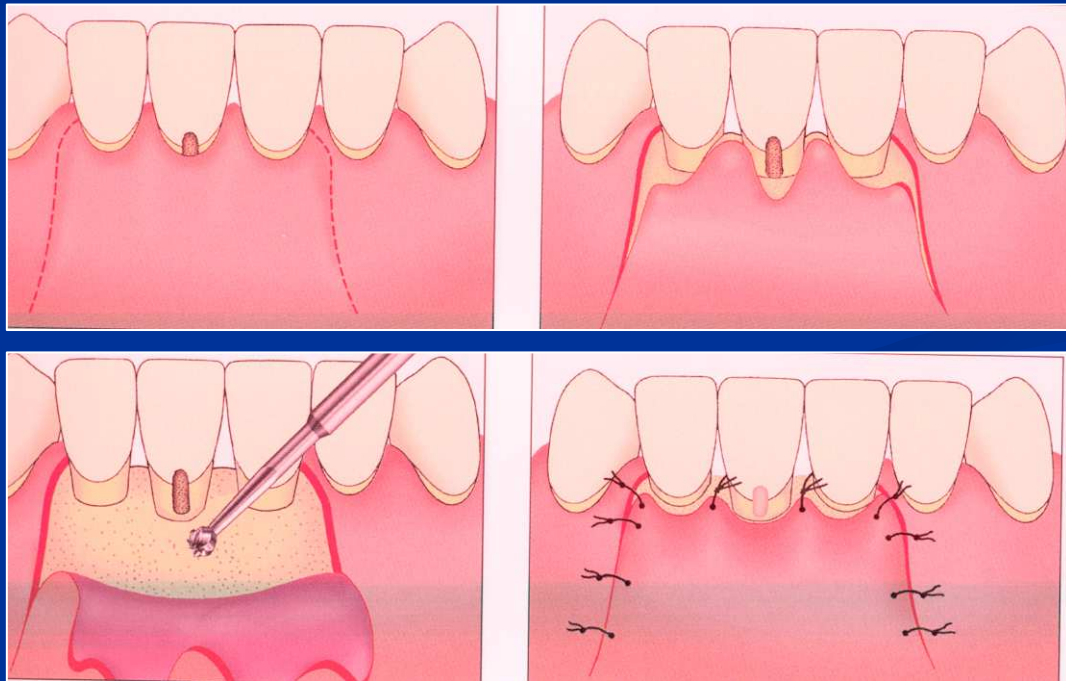
Apical flap, replaced flap

Papilla preservation technique

Wedge excision

Apical flap

Replaced flap



Mucogingival surgery

- Enlargement of attached gingiva
 - Frenulectomy
 - Vestibuloplastic

- Plastic of recessus
 - Lateral flap
 - Bridge flap
 - Mucous or mesenchymal grafts



