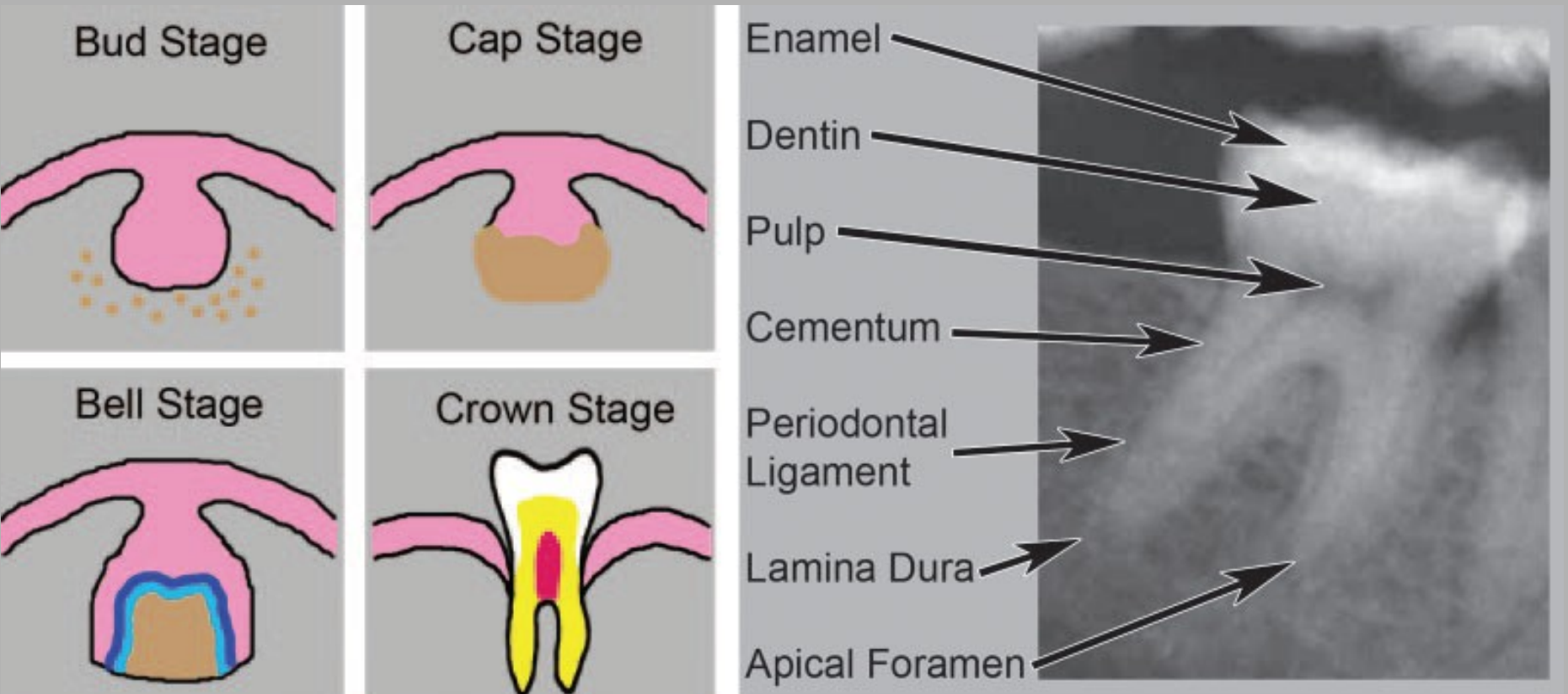


Radiology for stomatologists

Lecture

Odontogenesis and tooth anatomy



a

b

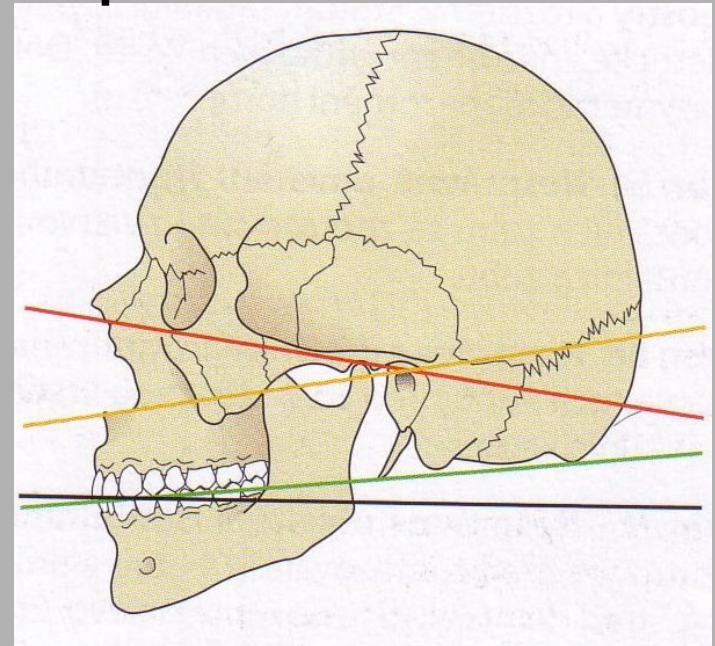
Odontogenesis and tooth anatomy

(a) Drawings illustrate the major stages of tooth development: the bud stage, cap stage, bell stage, and crown stage. Pink oral epithelium, brown dental mesenchyme, dark blue ameloblasts, light blue odontoblasts, yellow dentin, white enamel, red pulp. Although mandibular lesions may originate from cells of early tooth development, they often do not manifest until later in life.

(b) Radiograph demonstrates the anatomy of a mature tooth. Lesions of the mandible typically arise from characteristic locations within and surrounding a tooth.

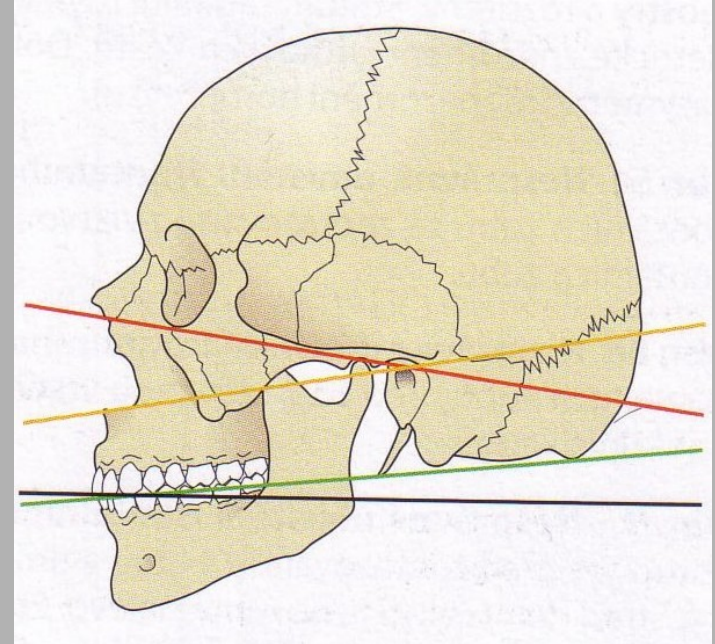
Landmark lines

- **Frankfurt's** horizontal, anthropological basic plane, connects caudal part of orbit to external to auditory meatus.
- **Camper's** plane connects the external auditory meatus to caudal part of nose.



Landmark lines

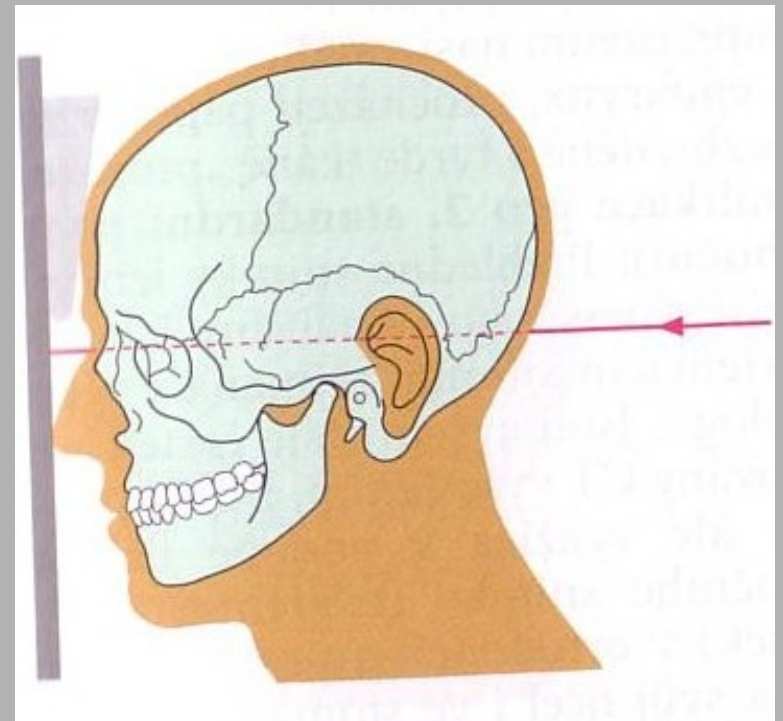
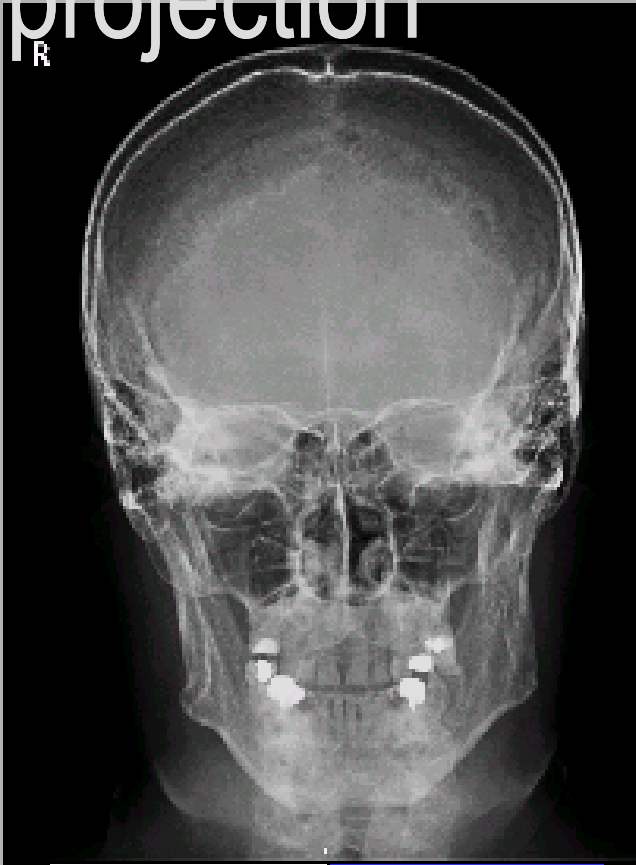- **Occlusal** plane should be horizontally (black line) oriented or slightly inclined down (at small children)



Extraoral skiagrams

- **Panoramatic:**
 - Picture of the cranium
 - Projection of the maxillar sinus
 - TMJ – Temporo-Mandibular Joint
 - Orthopantomograph (OPG)
- **Tomography (CT, MRI)**
 - Film or detector is placed out of the patient mouth.
 - Image of larger surface of mandibula, maxilla, soft tissues and the cranium

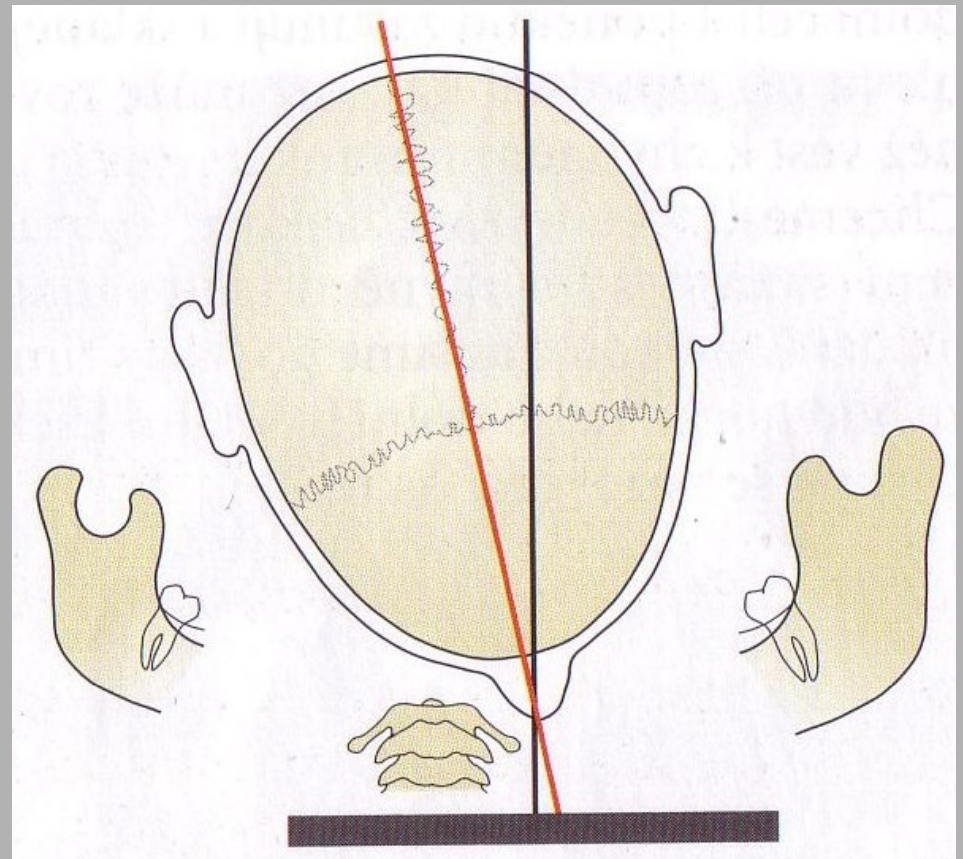
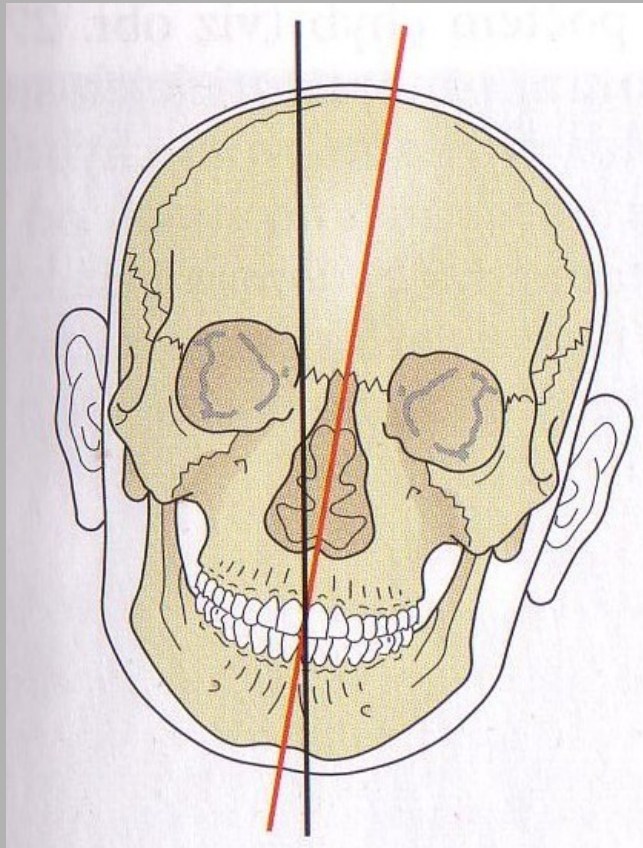
Cranium – dorso-ventral and lateral projection



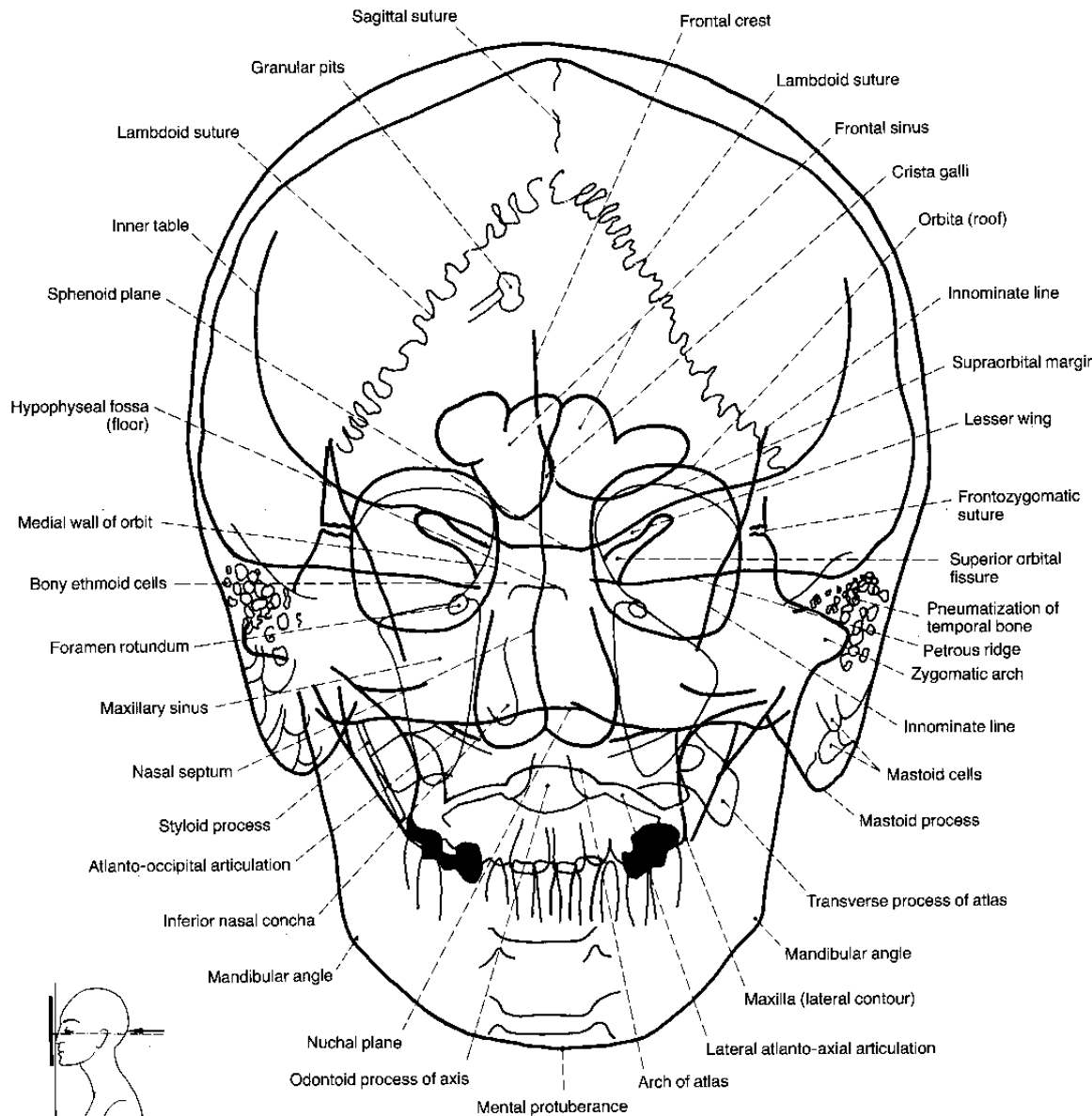
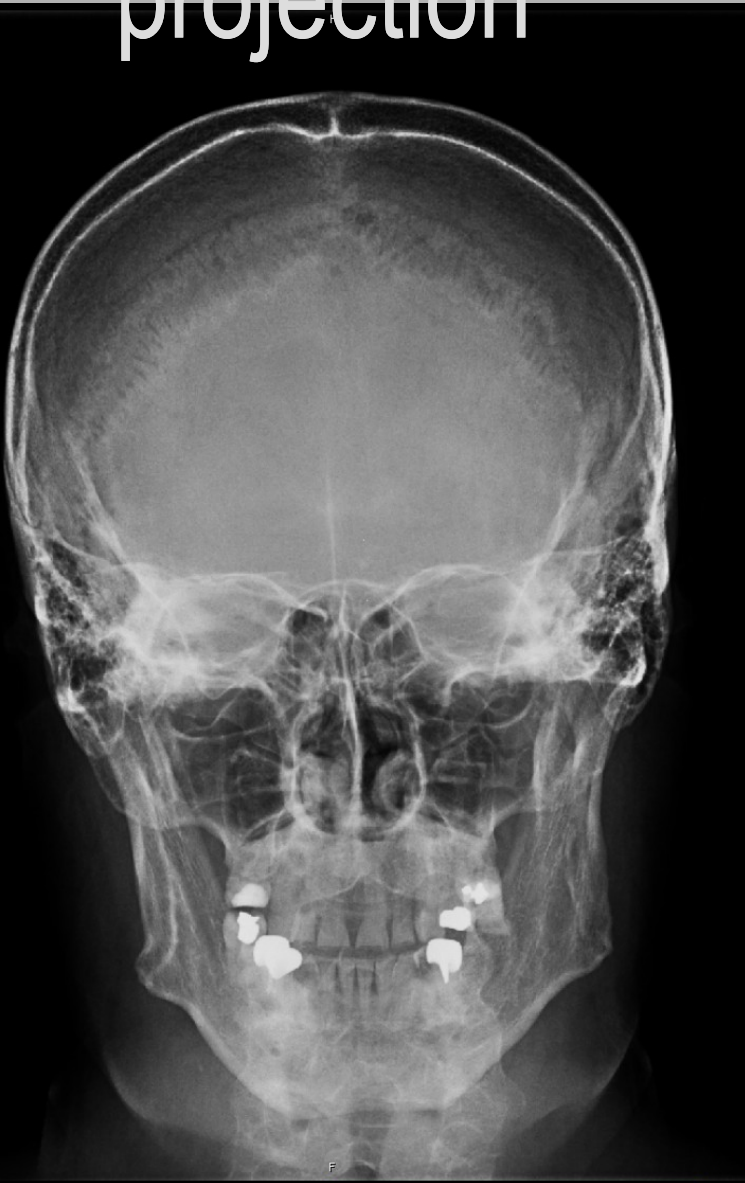- Nose and forehead touch the cassette
- X-ray pass through the protuber. occipitalis perpendicularly to cassette

Cranium – dorso-ventral and lateral projection

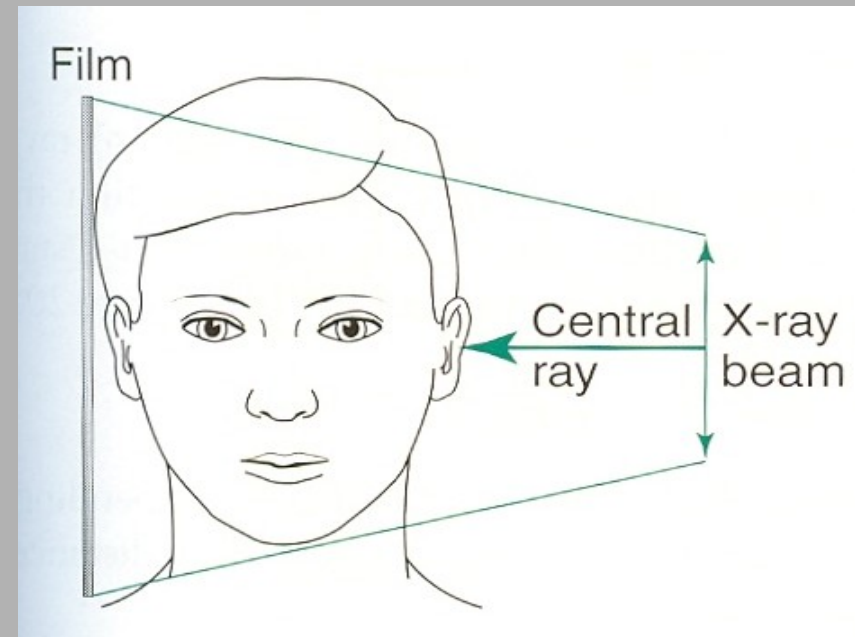
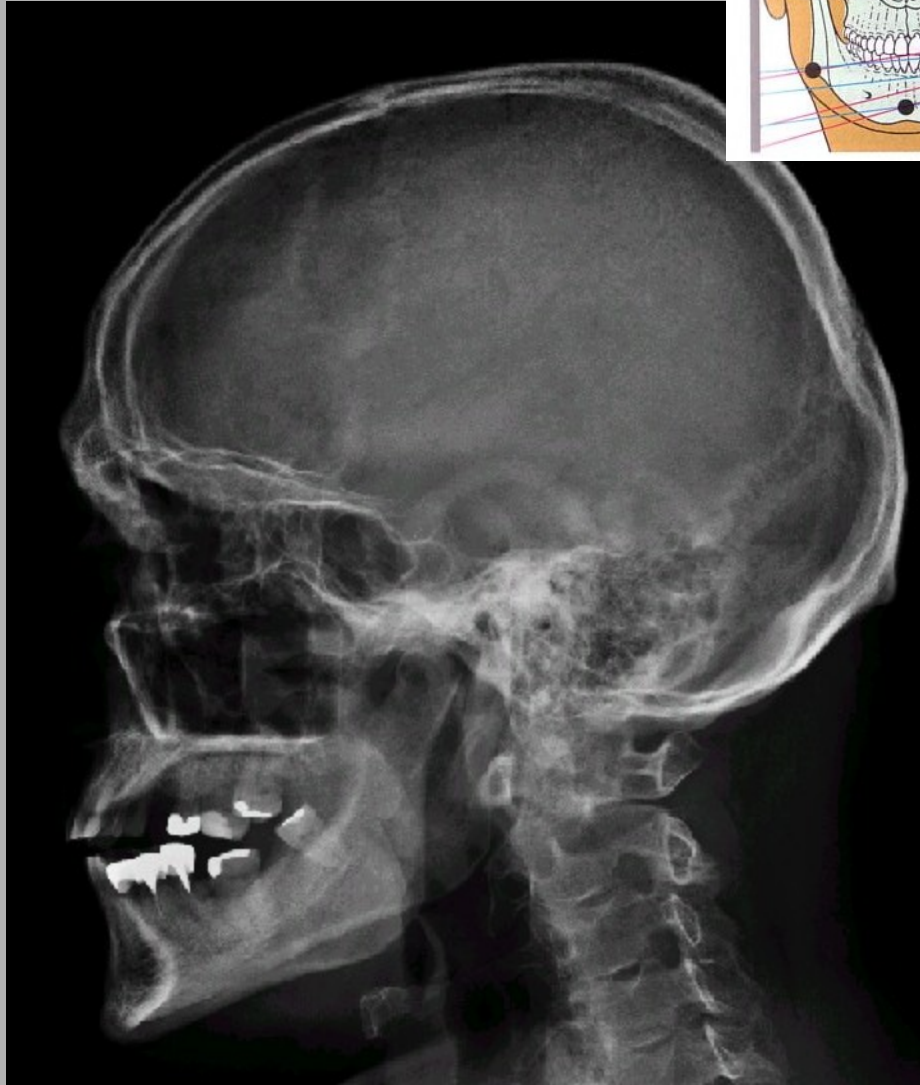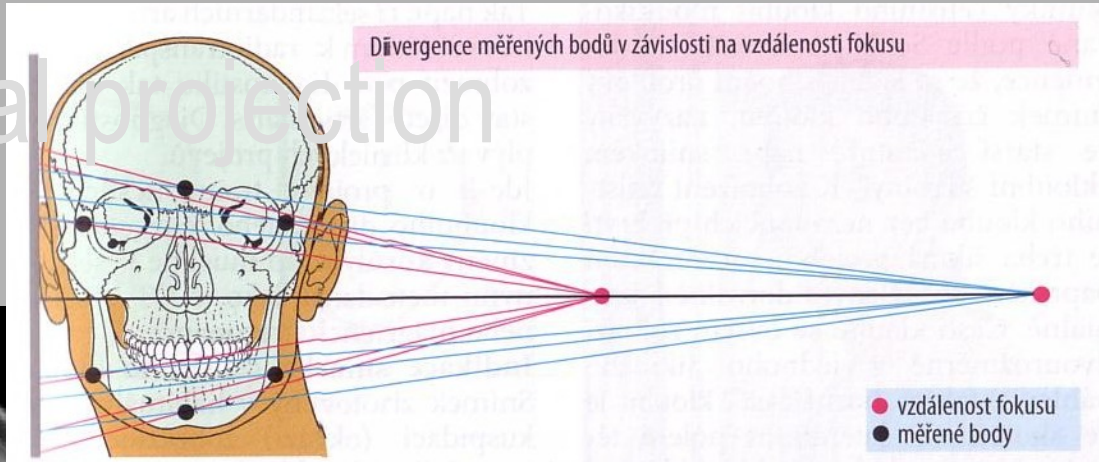
- Centre
- Tilting, etc.



Cranium – dorso-ventral and lateral projection

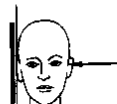
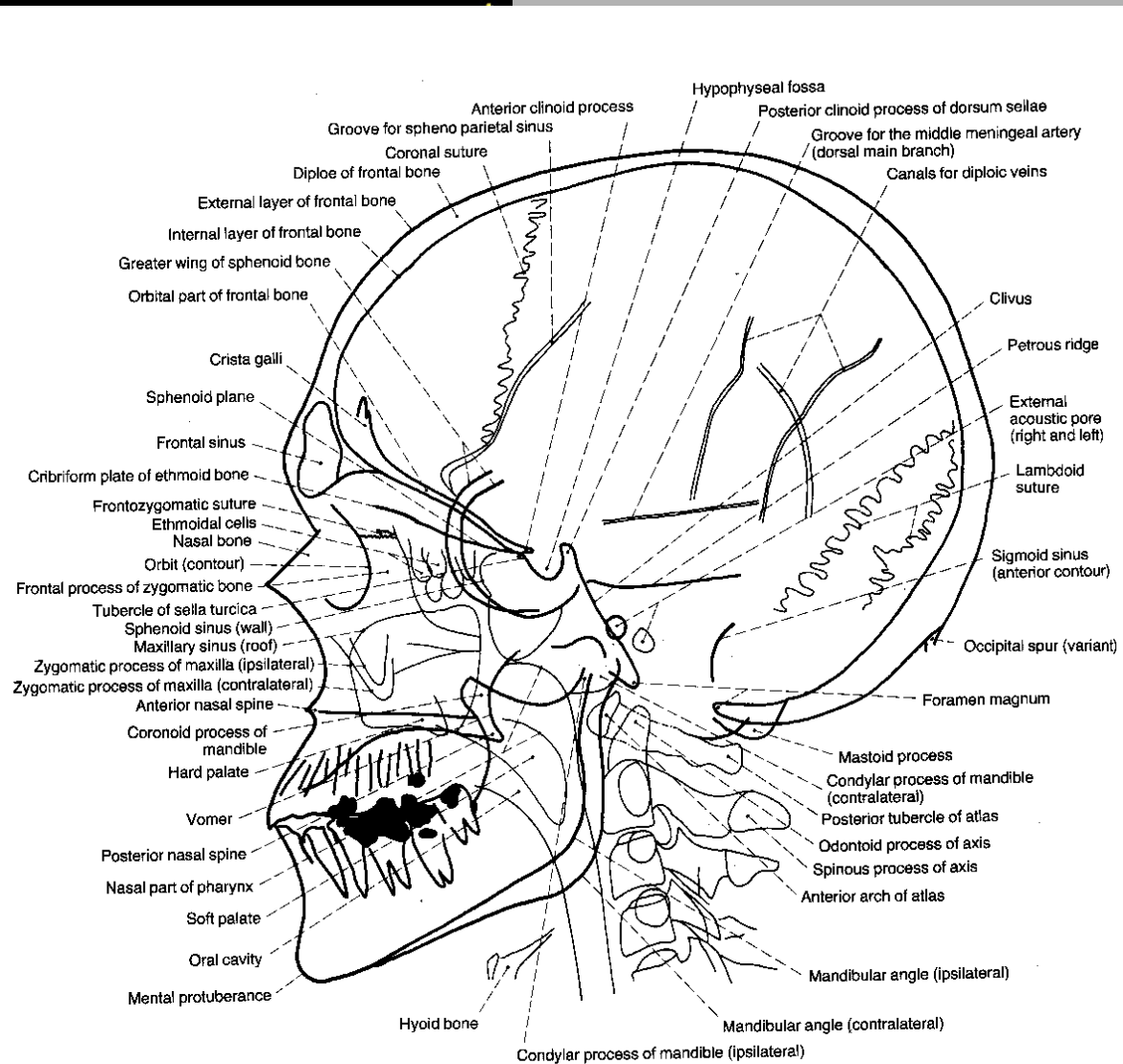
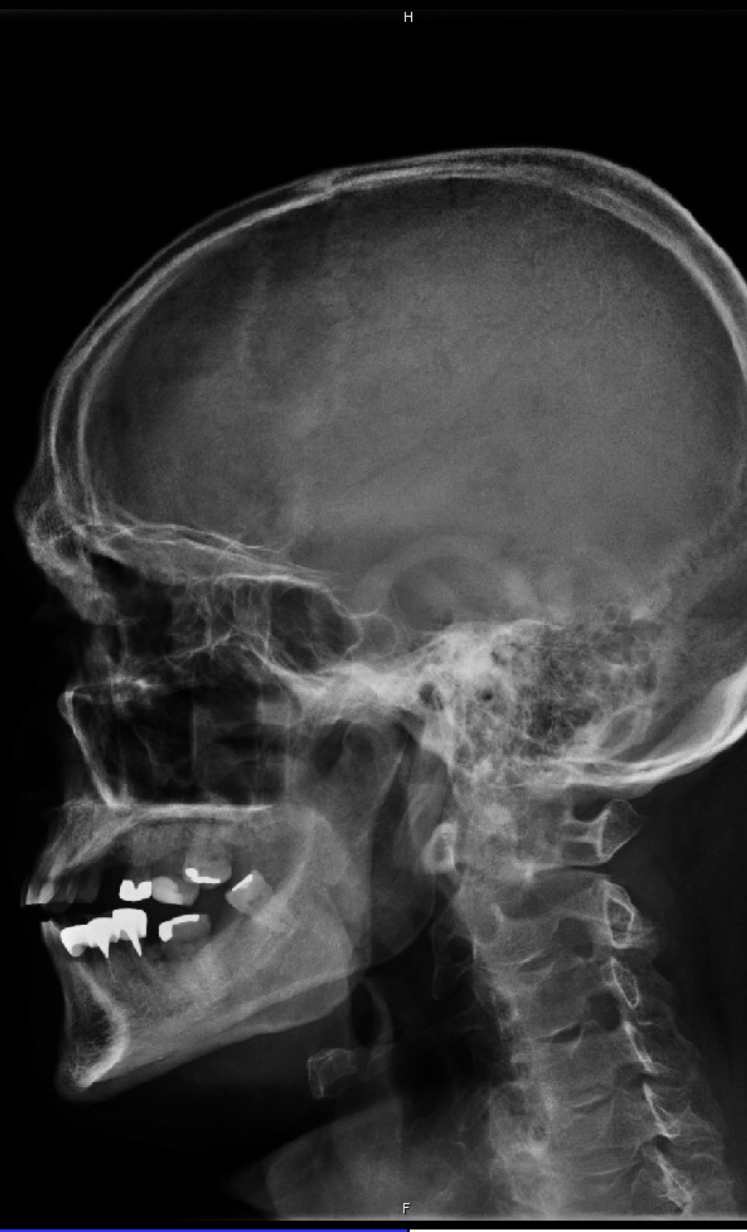

Cranium – lateral projection



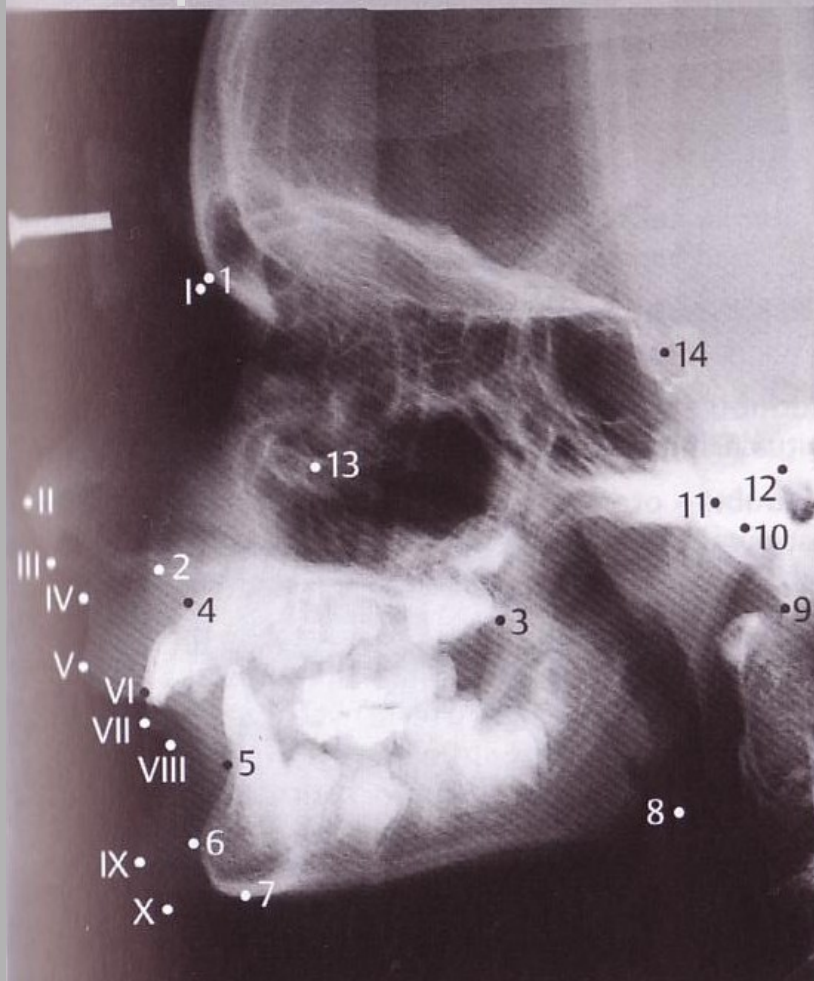
- Central beam goes through the acoustic meatus
- Perpendicular to the cassette

Cranium – lateral projection



Cranium – lateral projection

- splanchnocranium centre



Skeleton Points

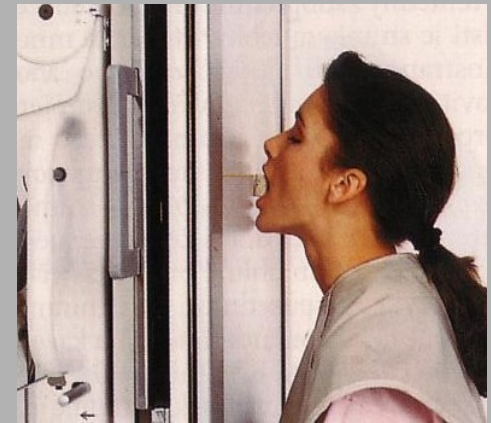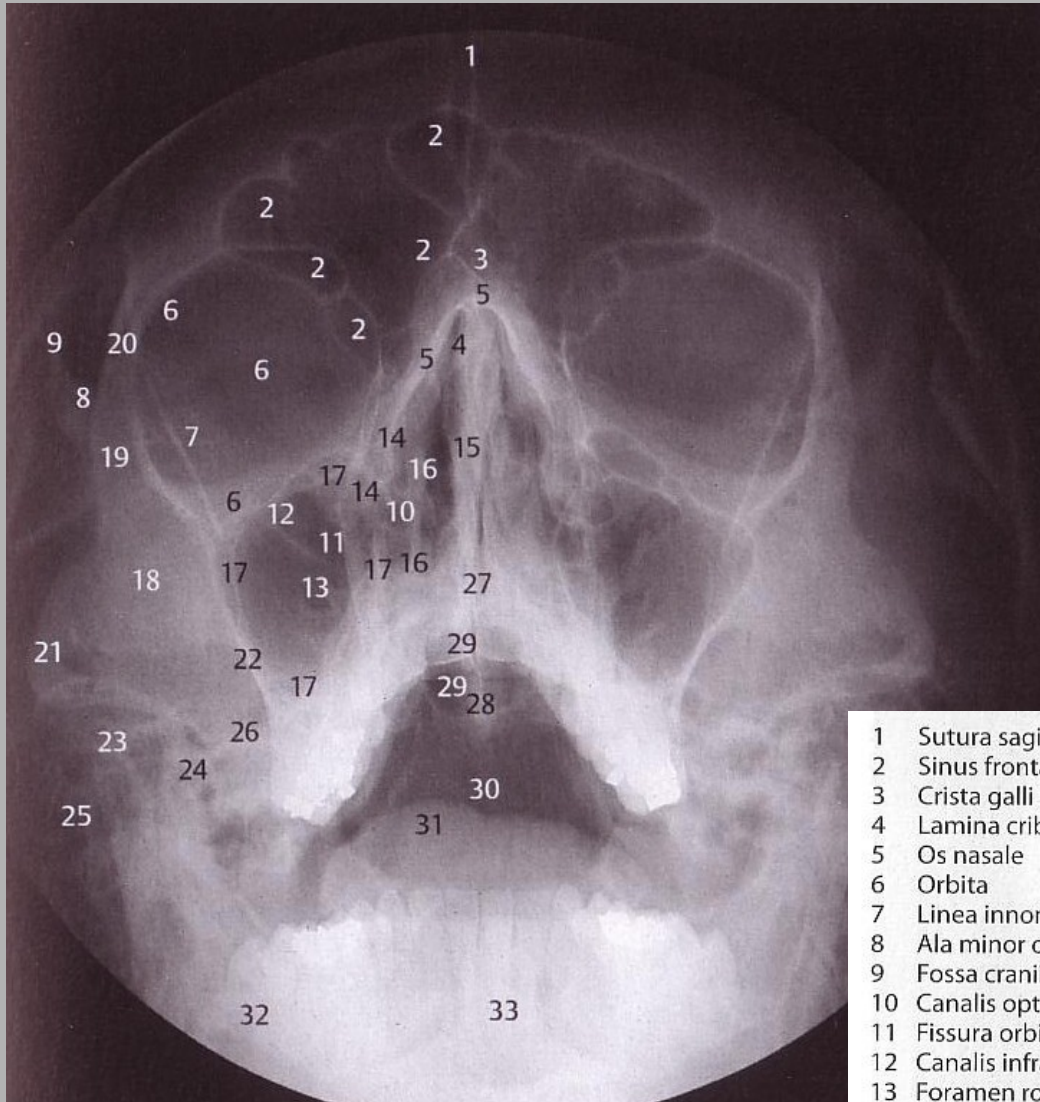
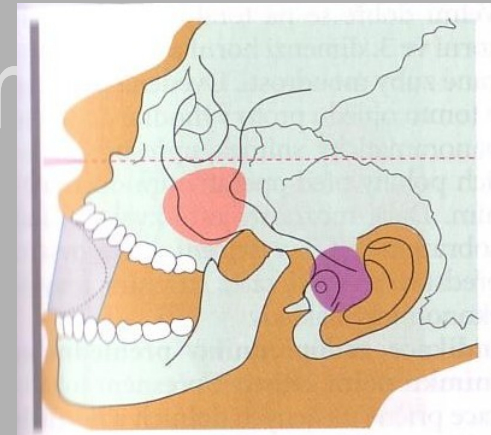
1	Nasion
2	Spina nasalis anterior
3	Spina nasalis posterior
4	Bod A
5	Bod B
6	Pogonion
7	Menton
8	Gonion
9	Basion
10	Articulare
11	Condylion
12	Porion
13	Orbitale

14 sella

Soft Tissue Points

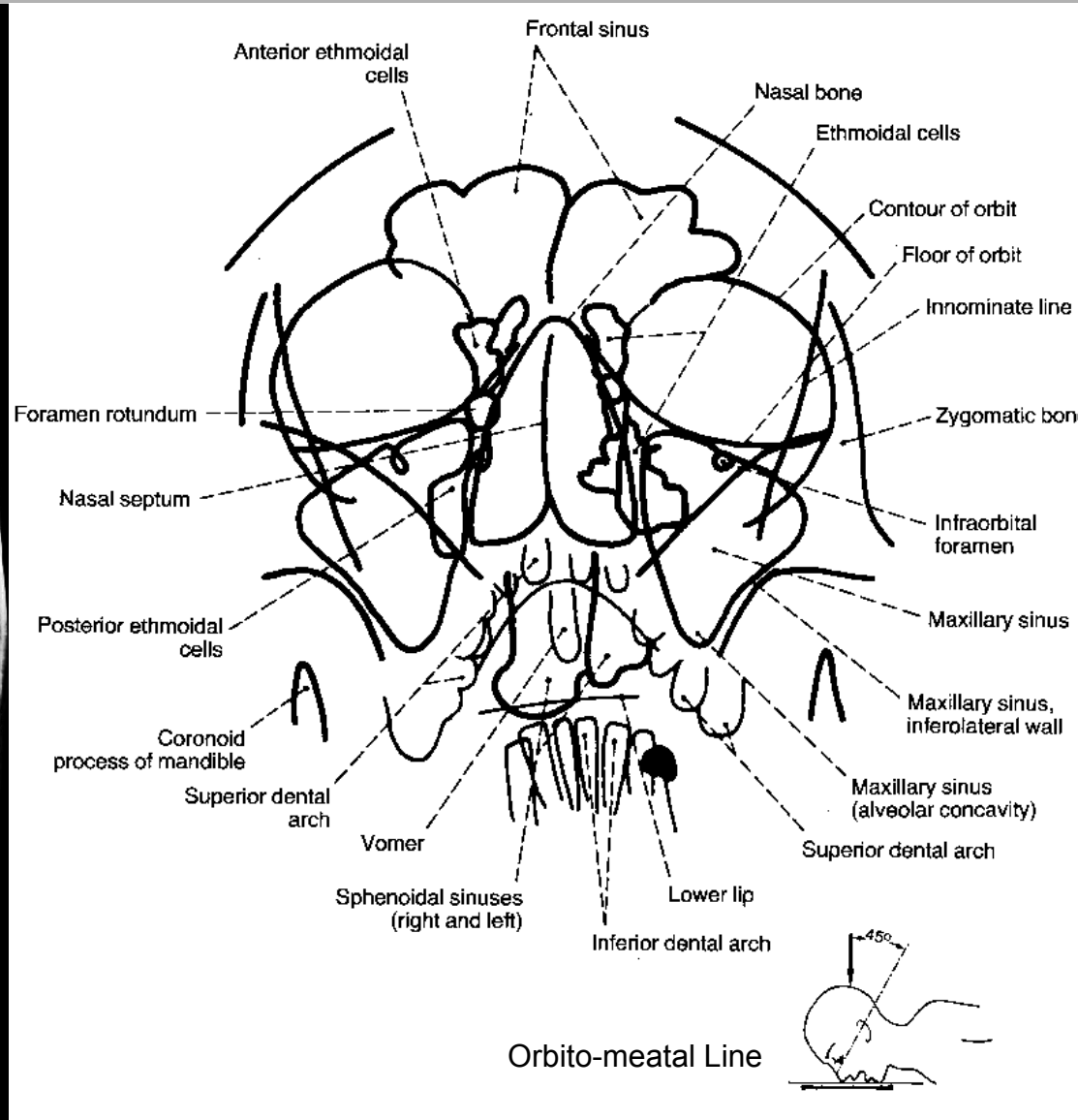
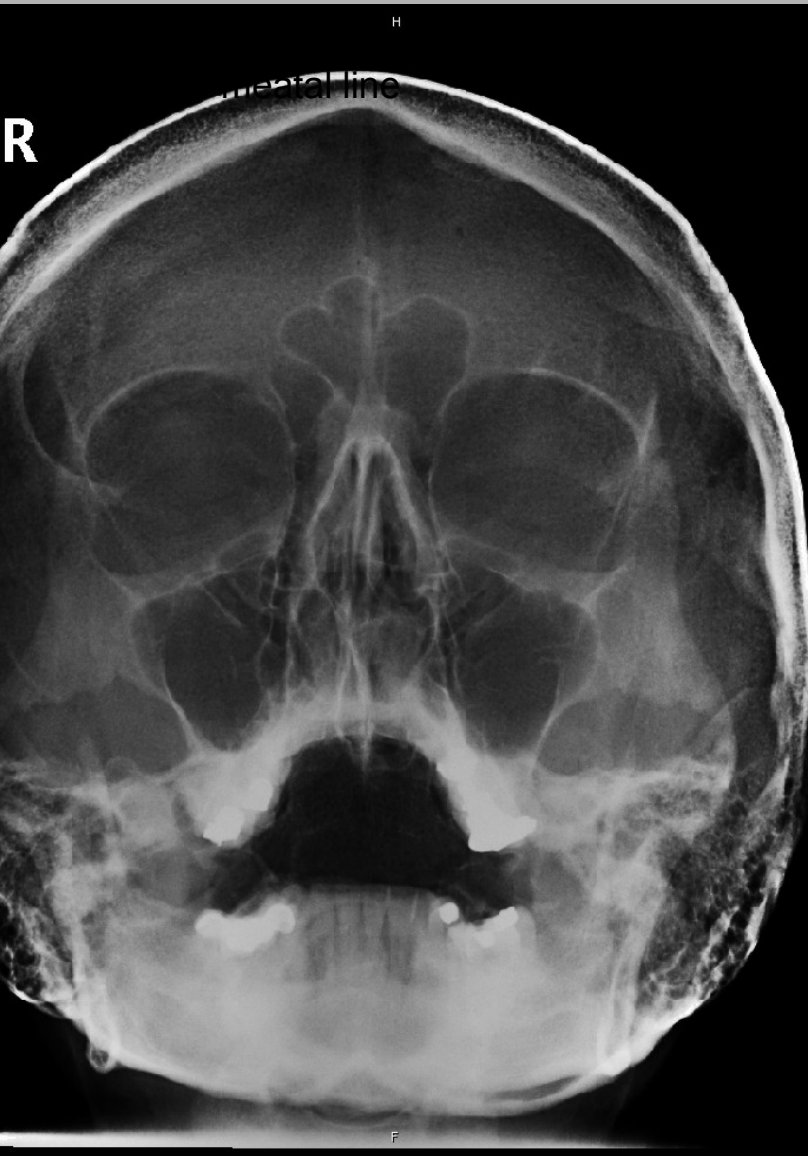I	Kožní nasion
II	Špička nosu
III	Subnasale
IV	Subspinale
V	Labrale superius
VI	Stomion
VII	Labrale inferius
VIII	Submentale
IX	Kožní pogonion
X	Kožní gnathion

Cranium – semiaxial projection

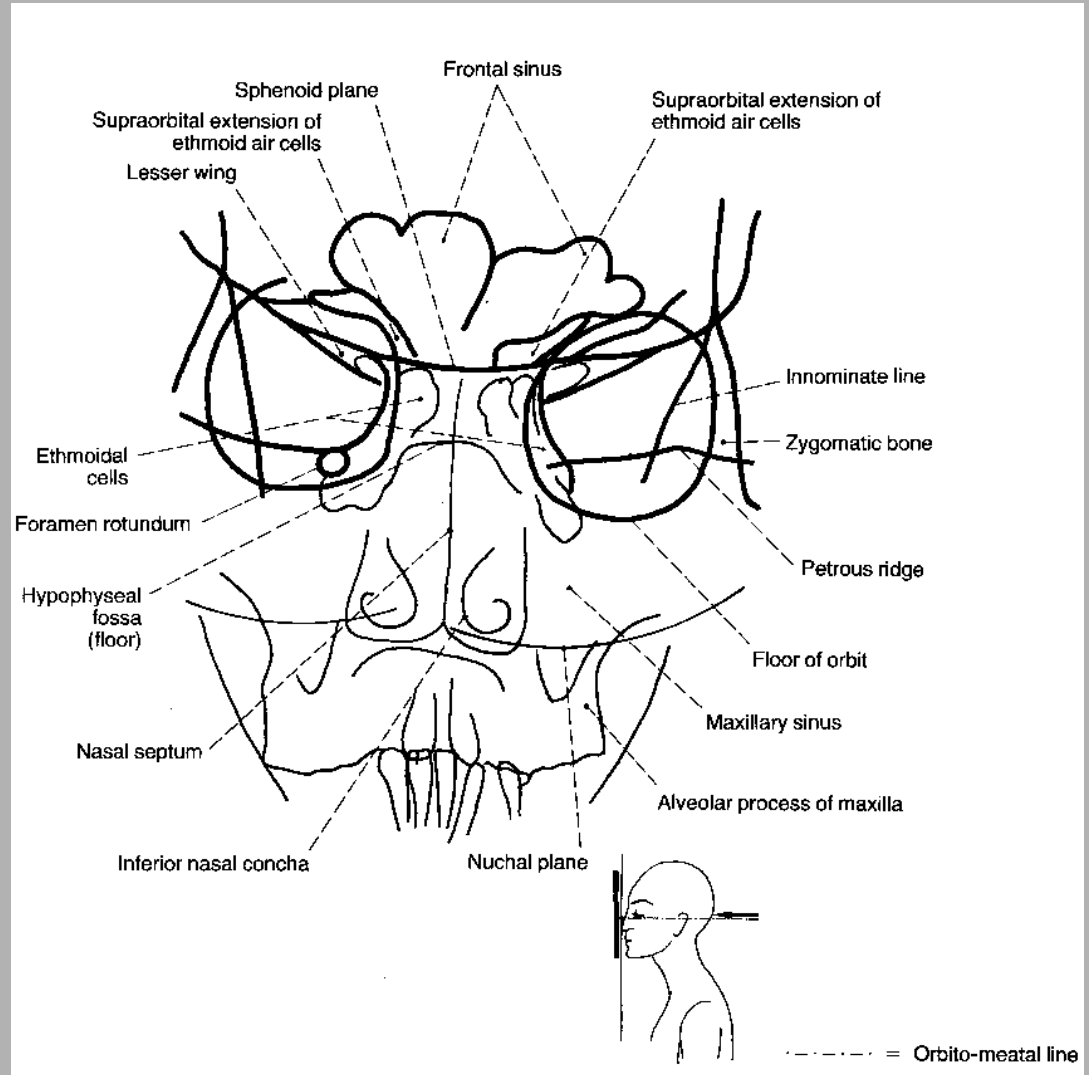
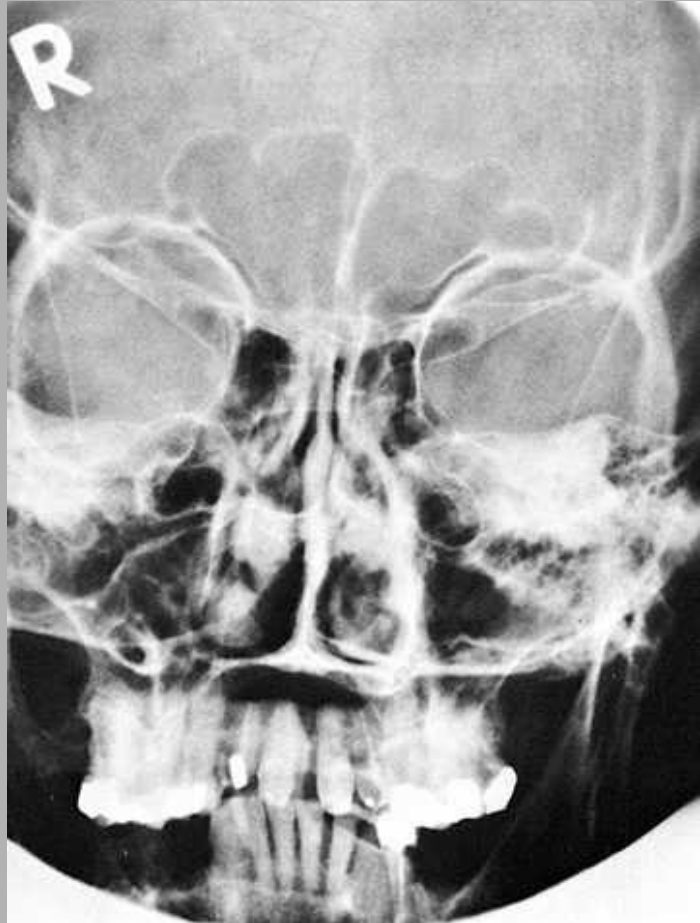

- | | | | |
|----|-----------------------------------|----|---|
| 1 | Sutura sagittalis | 18 | Os zygomaticum |
| 2 | Sinus frontalis se septy | 19 | Processus frontalis ossis zygomatici |
| 3 | Crista galli a falx cerebri | 20 | Sutura zygomaticofrontalis |
| 4 | Lamina cribrosa ossis ethmoidalis | 21 | Arcus zygomaticus |
| 5 | Os nasale | 22 | Crista zygomaticoalveolaris |
| 6 | Orbita | 23 | Processus condylaris mandibulae |
| 7 | Linea innominata (allae majores) | 24 | Processus muscularis (coronoideus) mandibulae |
| 8 | Ala minor ossis sphenoidalis | 25 | Celullae mastoideae |
| 9 | Fossa cranii media (ohraničeni) | 26 | Pars petrosa ossis temporalis |
| 10 | Canalis opticus | 27 | Spina nasalis anterior |
| 11 | Fissura orbitalis superior | 28 | Spina nasalis posterior |
| 12 | Canalis infraorbitalis | 29 | Spina sphenoidalis |
| 13 | Foramen rotundum | 30 | Pars basilaris ossis occipitalis |
| 14 | Labyrinthus ethmoidalis | 31 | Dorsum linguae |
| 15 | Septum nasi osseum | 32 | Massa lateralis atlantis |
| 16 | Conchae nasales | 33 | Dens axis (epistrophei) |
| 17 | Sinus maxillaris | | |

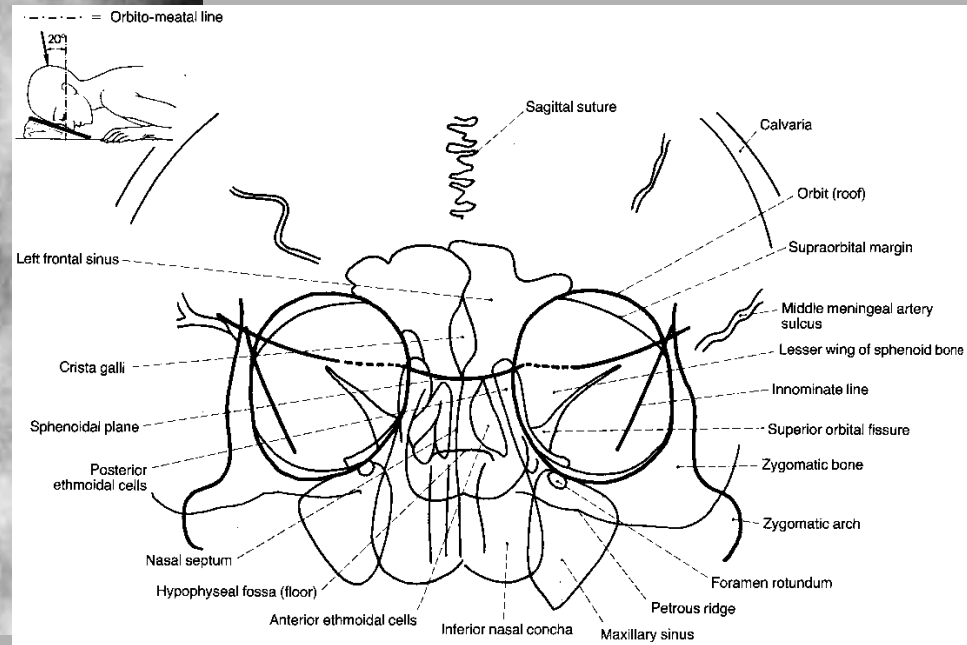
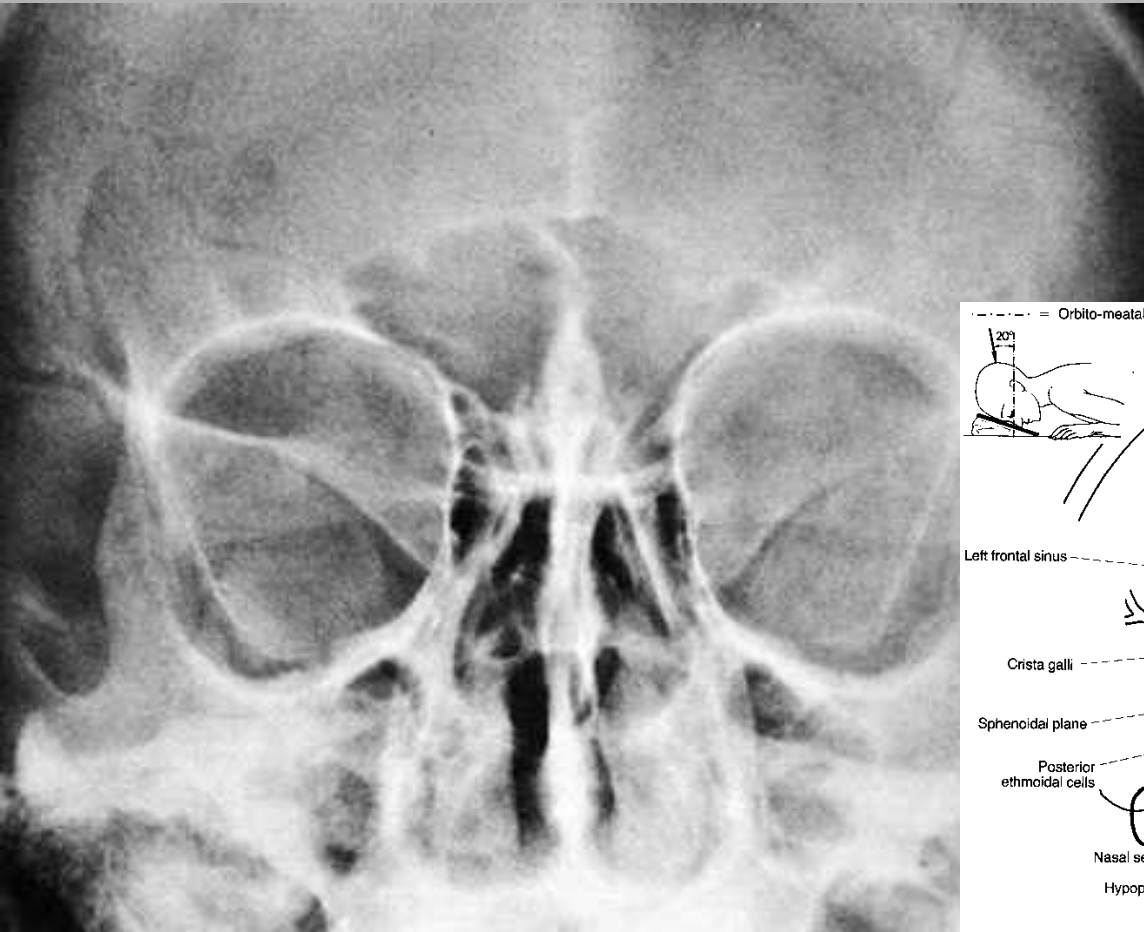
Paranasal sinuses – Water's projection



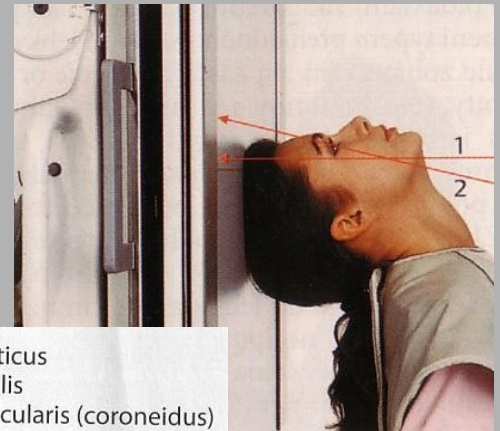
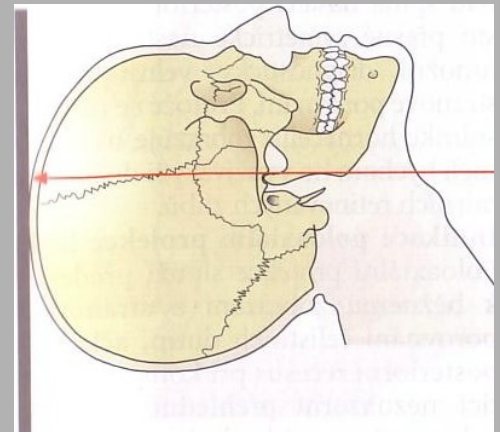
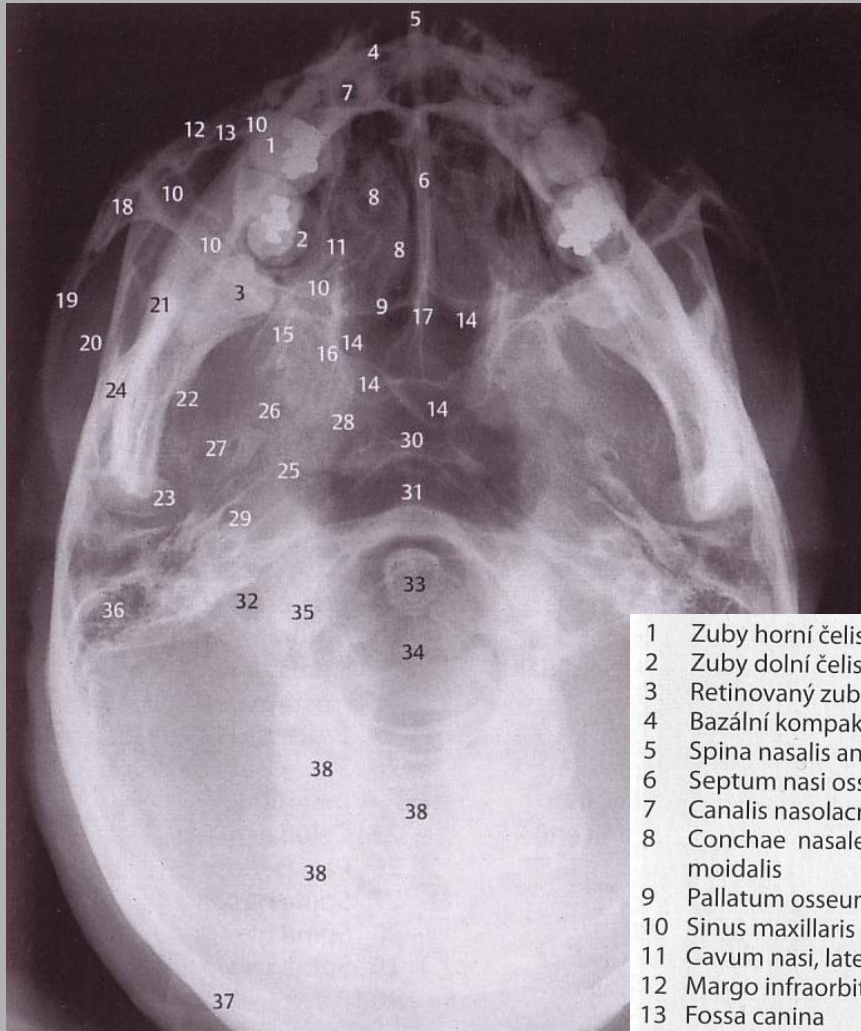
Paranasal sinuses – dorso-ventral projection



Orbits – dorso-ventral projection

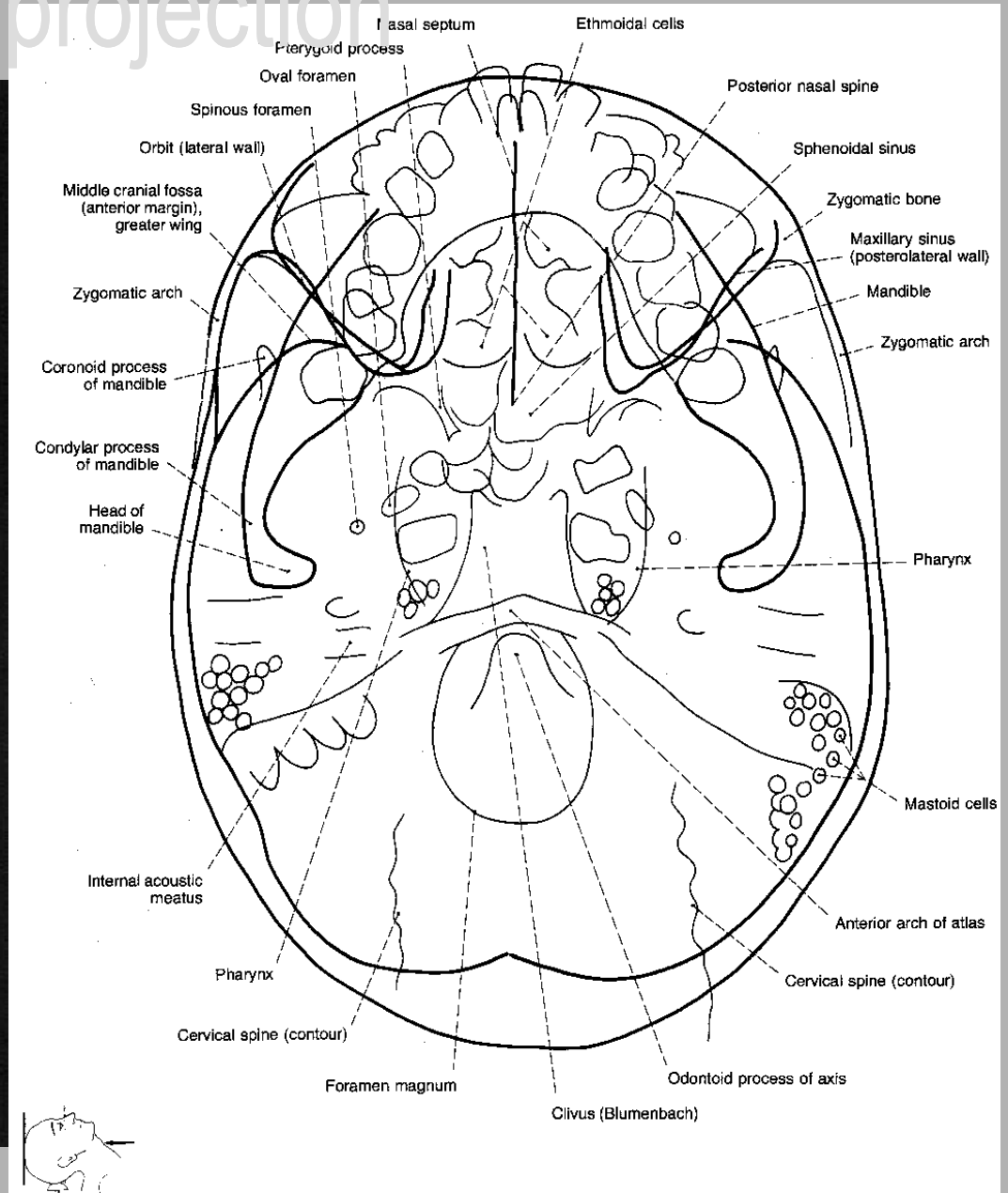
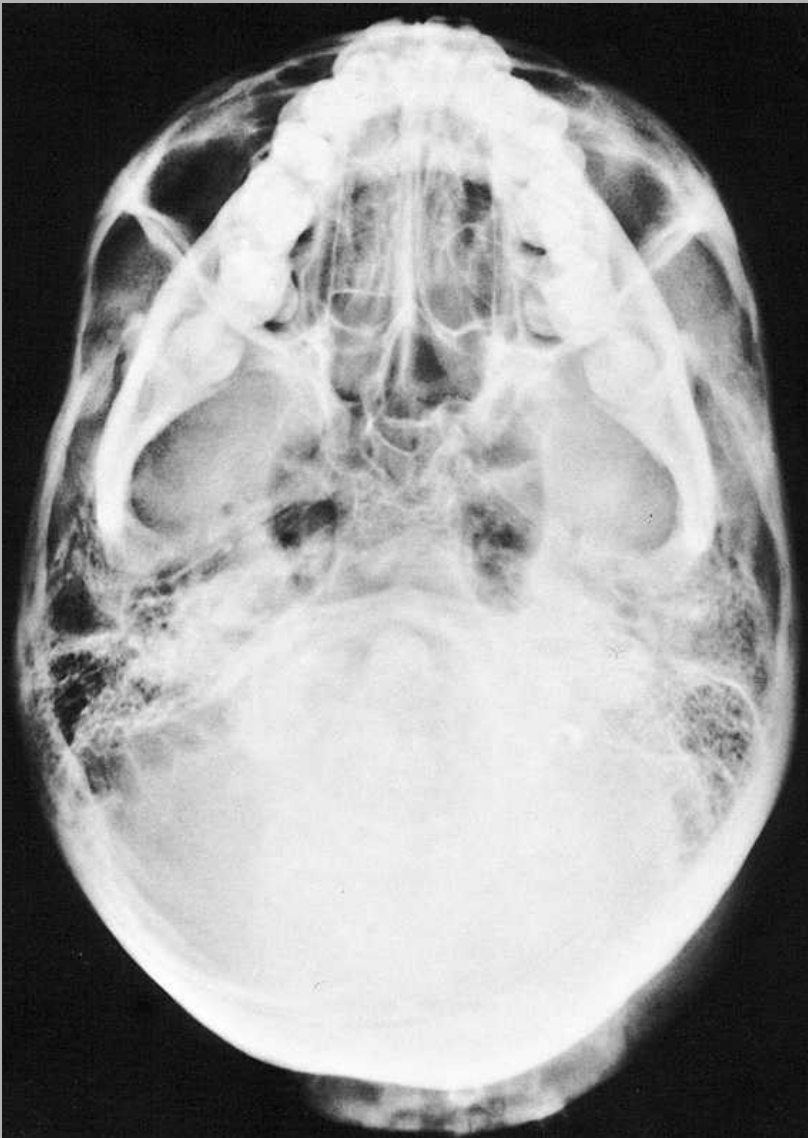

Cranium – axial projection

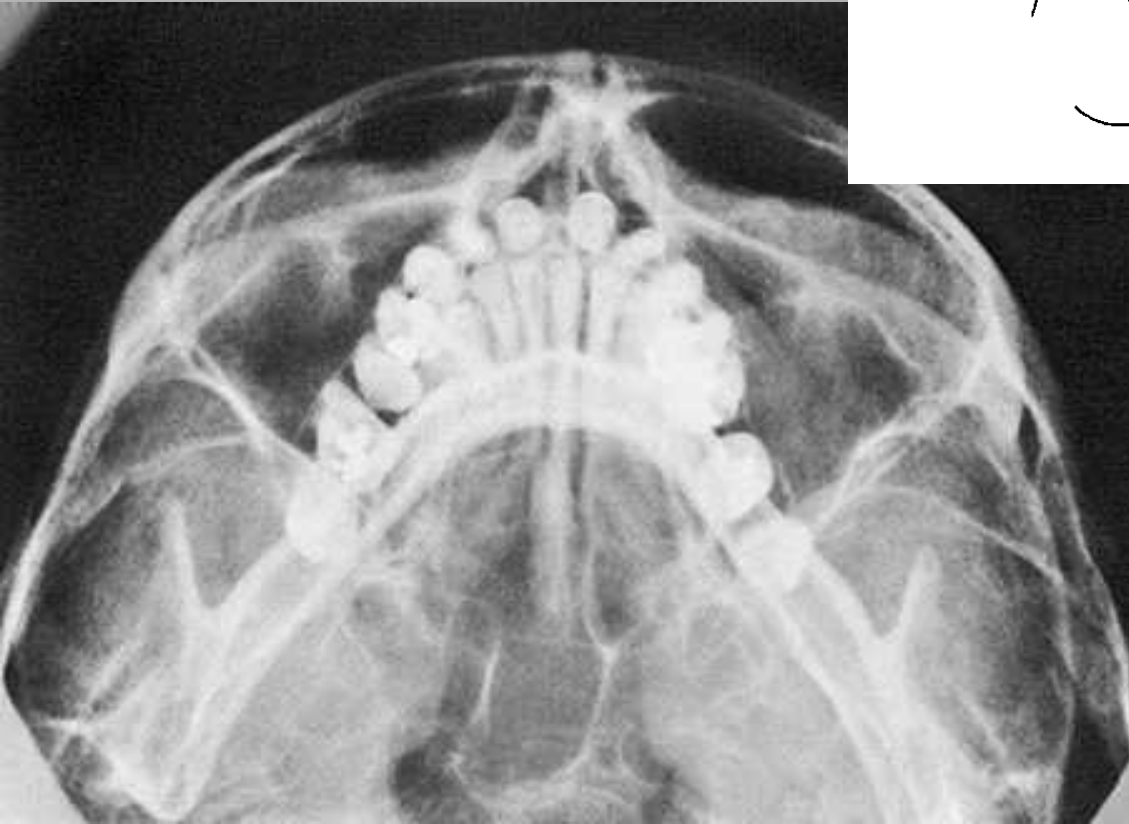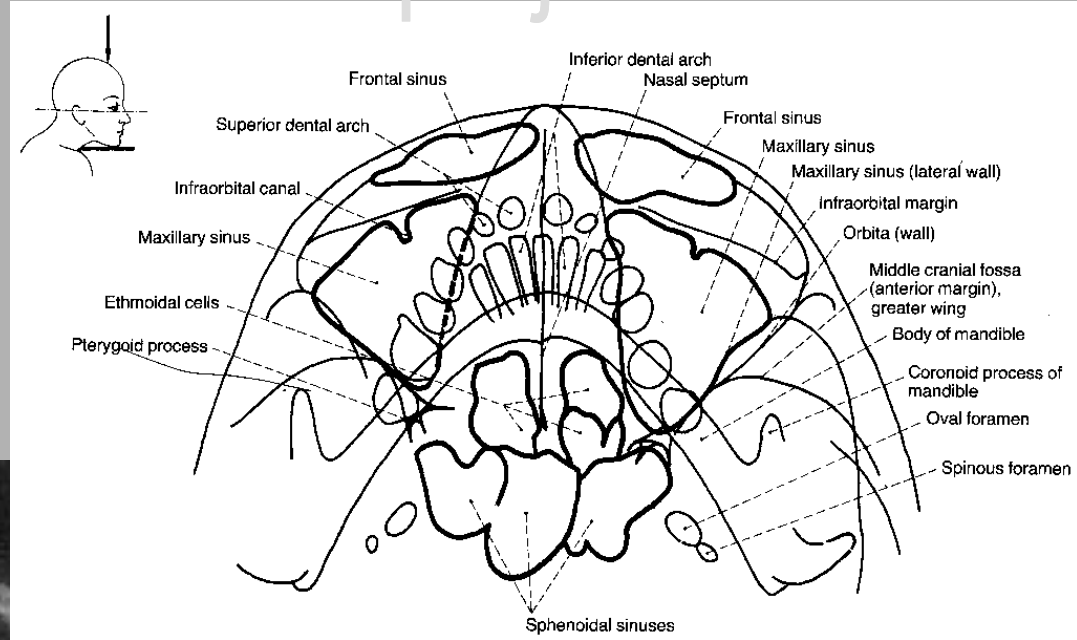


- | | | | |
|----|--|----|--|
| 1 | Zuby horní čelisti | 19 | Arcus zygomaticus |
| 2 | Zuby dolní čelisti | 20 | Fossa temporalis |
| 3 | Retinovaný zub 48 | 21 | Processus muscularis (coroneidus) mandibulae |
| 4 | Bazální kompakta mandibuly | 22 | Lingula |
| 5 | Spina nasalis anterior | 23 | Condylus mandibulae |
| 6 | Septum nasi osseum | 24 | Angulus mandibulae |
| 7 | Canalis nasolacrimalis | 25 | Sutura coronalis |
| 8 | Conchae nasales et labyrinthus ethmoidalis | 26 | Foramen ovale |
| 9 | Pallatum osseum (dorzální hranice) | 27 | Foramen spinosum |
| 10 | Sinus maxillaris (ohraničení) | 28 | Foramen lacerum |
| 11 | Cavum nasi, laterální stěna | 29 | Canalis caroticus |
| 12 | Margo infraorbitalis | 30 | Dorsum sellae |
| 13 | Fossa canina | 31 | Tuberculum anterius atlantis |
| 14 | Sinus sphenoidalis | 32 | Foramen transversarium atlantis |
| 15 | Processus pterygoideus, lamina lateralis | 33 | Dens axis (epistrophei) |
| 16 | Processus pterygoideus, lamina medialis | 34 | Foramen magnum |
| 17 | Spina nasalis posterior | 35 | Condylus occipitalis |
| 18 | Os zygomaticum | 36 | Celullae mastoideae |
| | | 37 | Os occipitale |
| | | 38 | Obratle krční páteře |

Cranium – axial projection



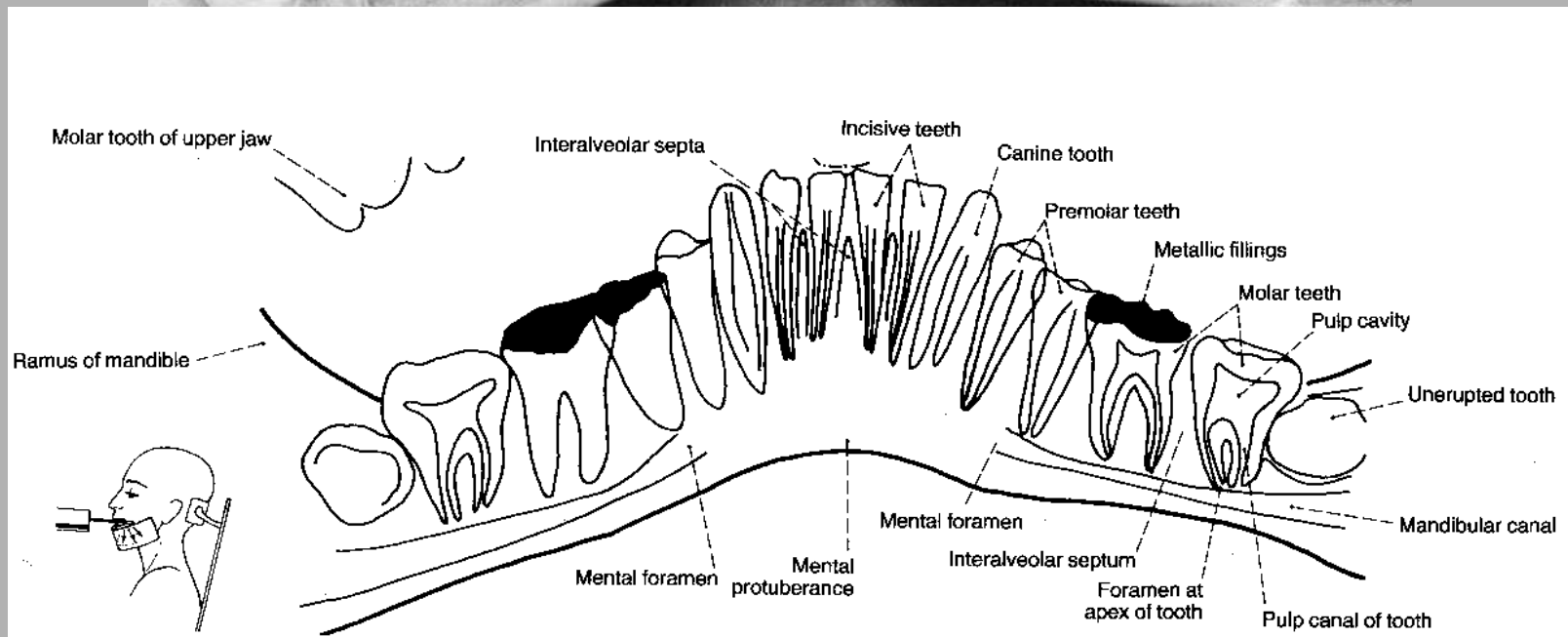
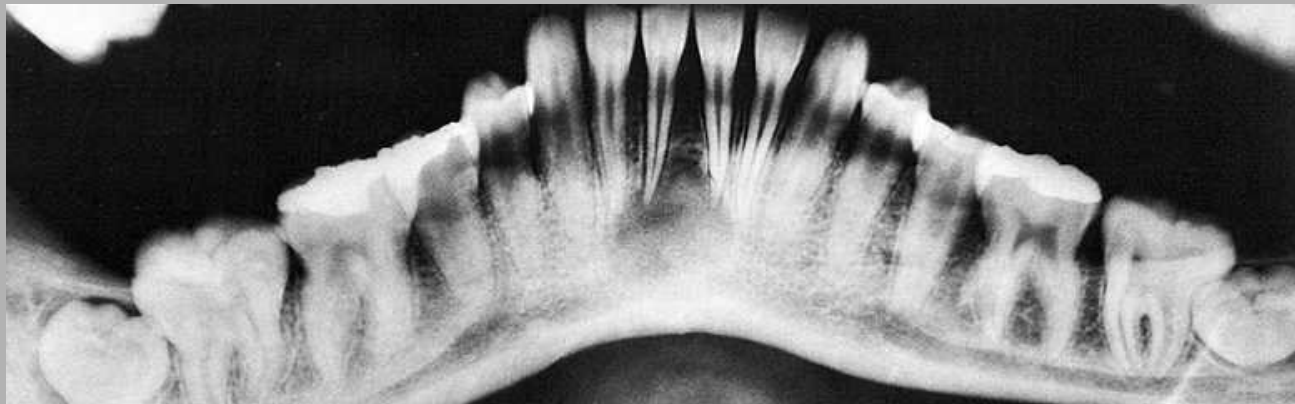Paranasal sinuses – axial projection



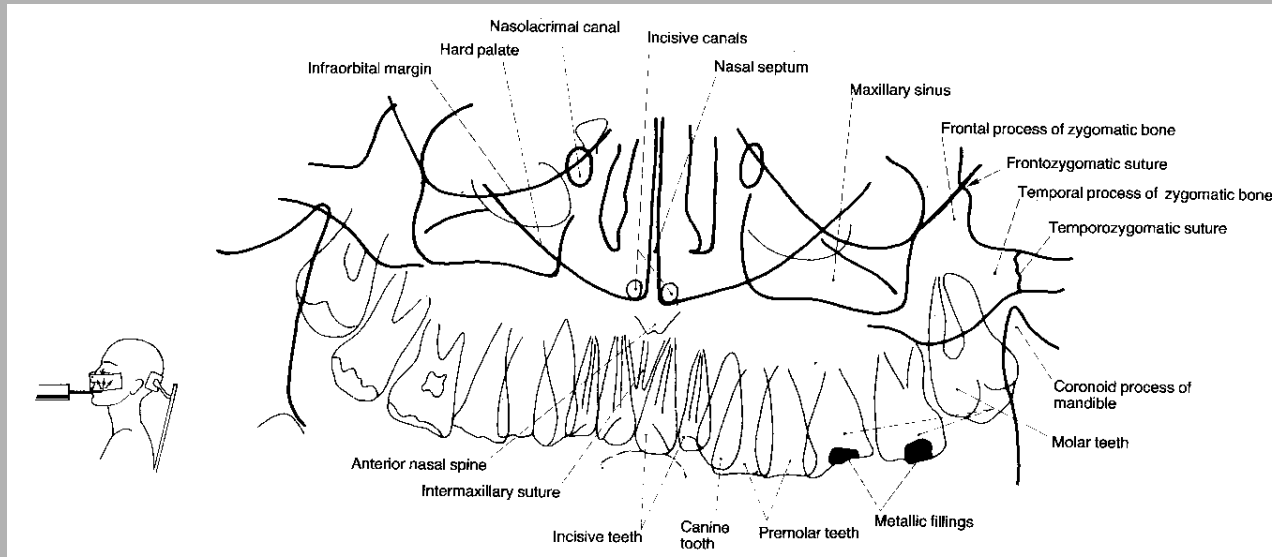
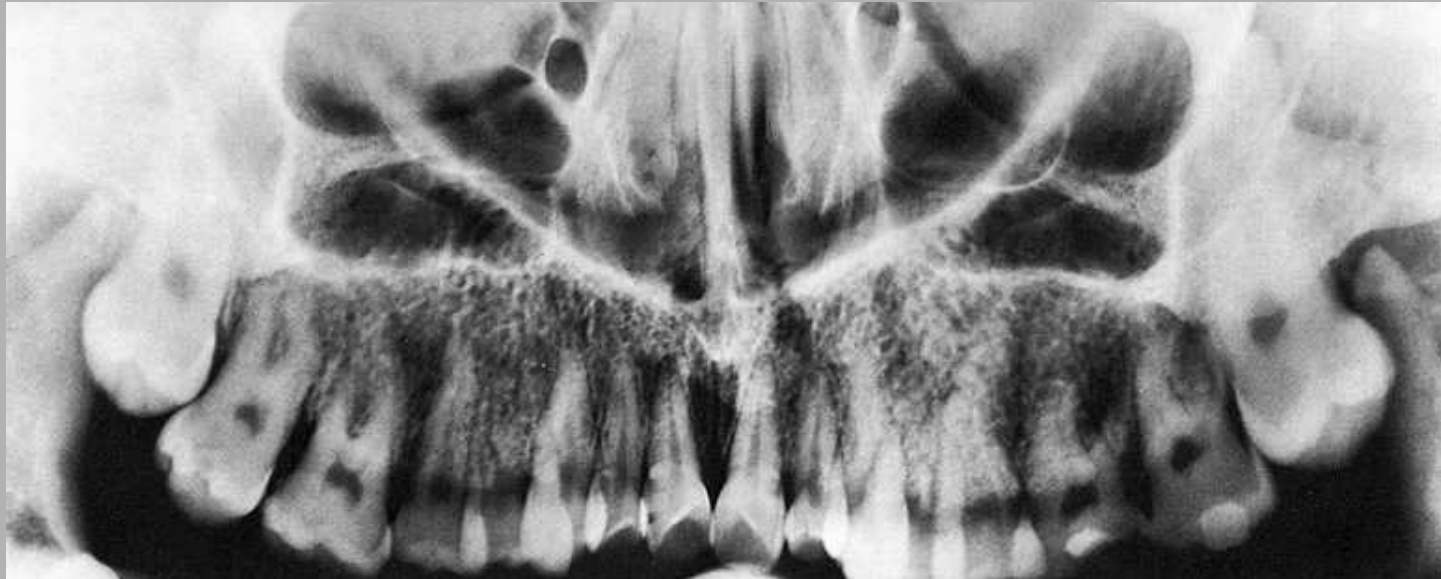
http://rtg.misto.cz/_MAIL_/hlava/08.jpg

Mandible – panoramic projection

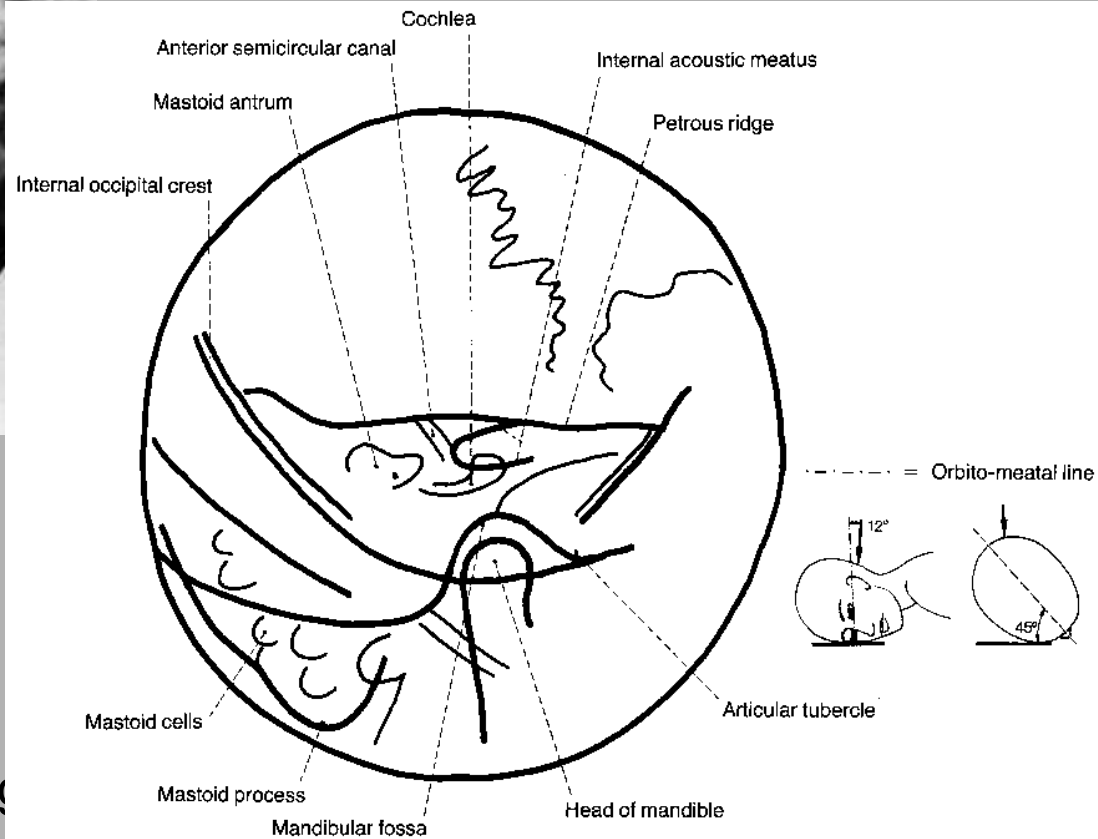
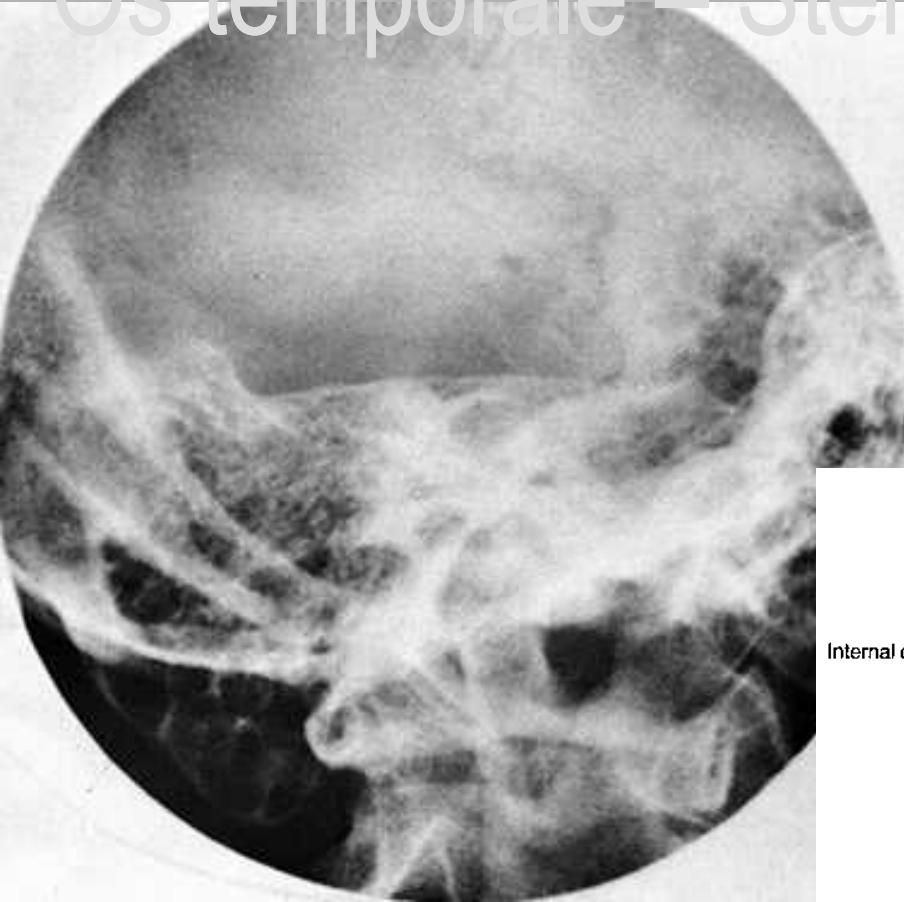- http://rtg.misto.cz/_MAIL_/hlava/15.jpg



Upper jaw – panoramic projection

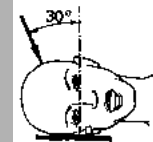
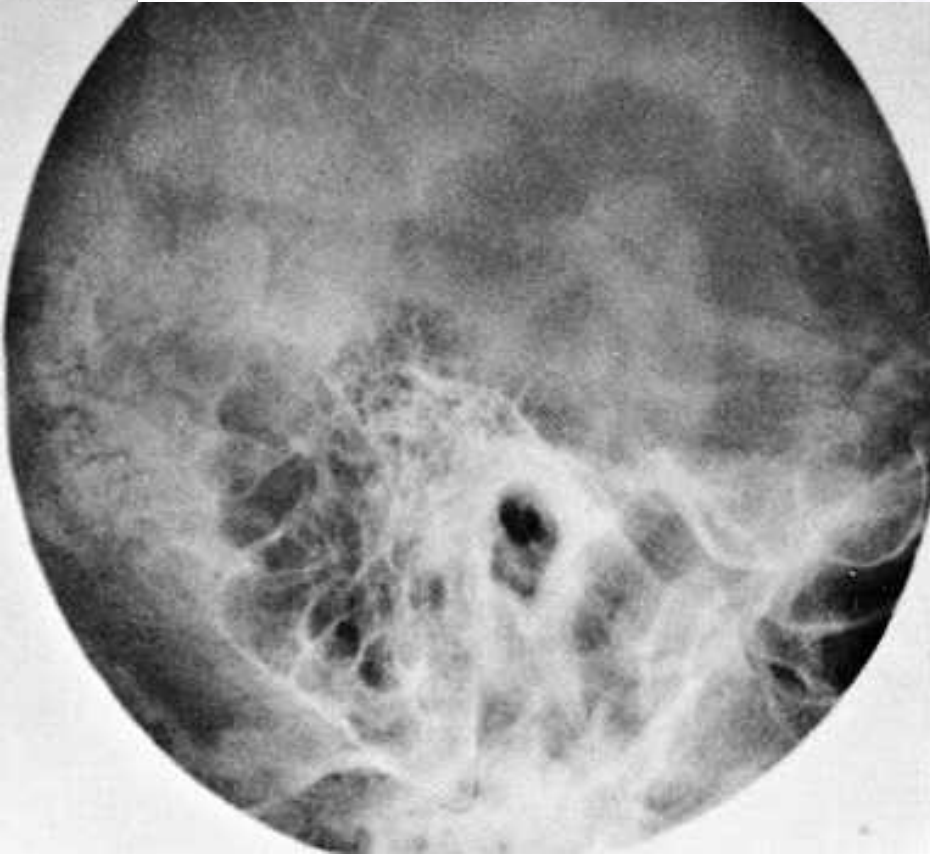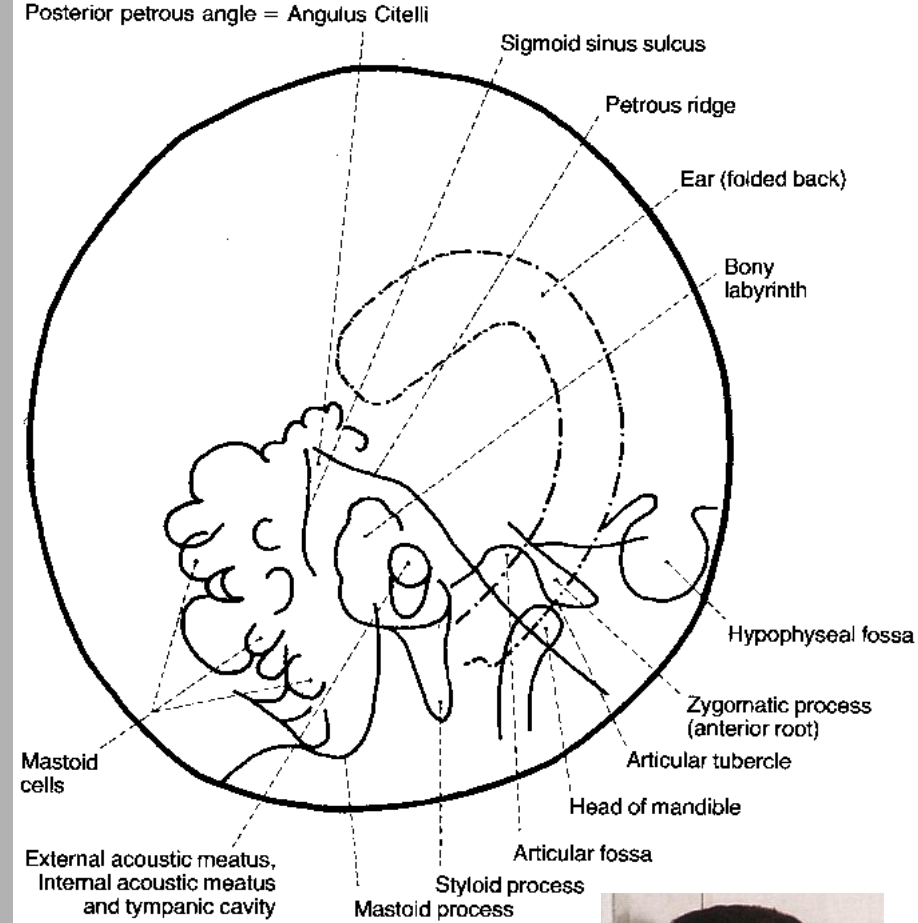
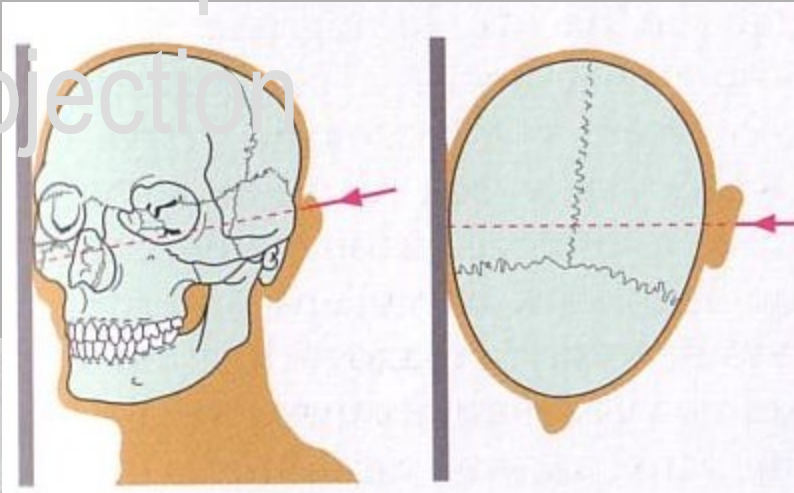


Os temporale – Stenver's – semisagittal pr.



Os temporale – Schüller's – semilateral projection

http://rtg.misto.cz/_MAIL_/hlava/12.jpg

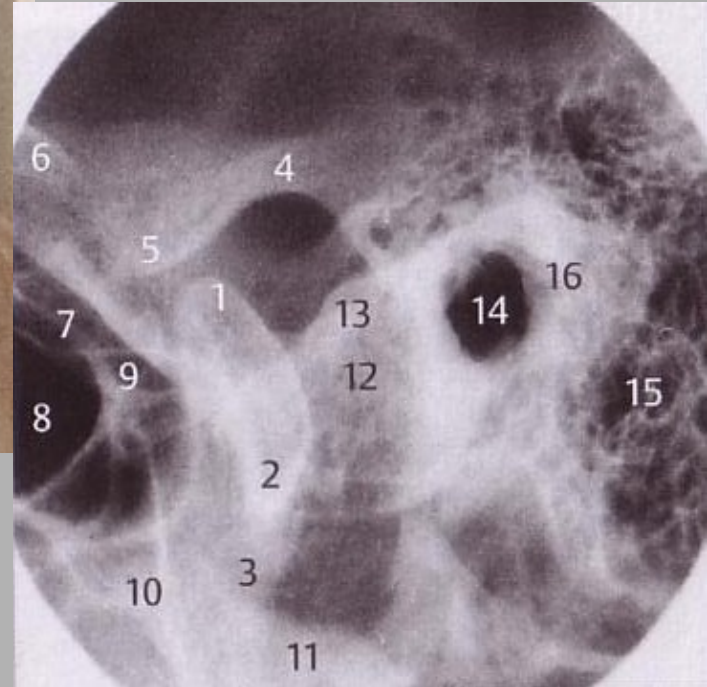
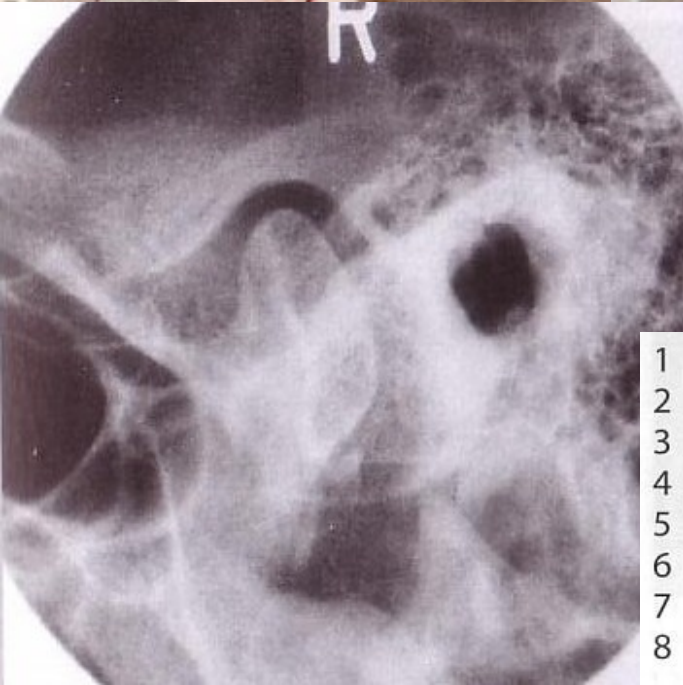


----- = Orbito-meatal line



Os temporale – Schüller's – semilateral

projection

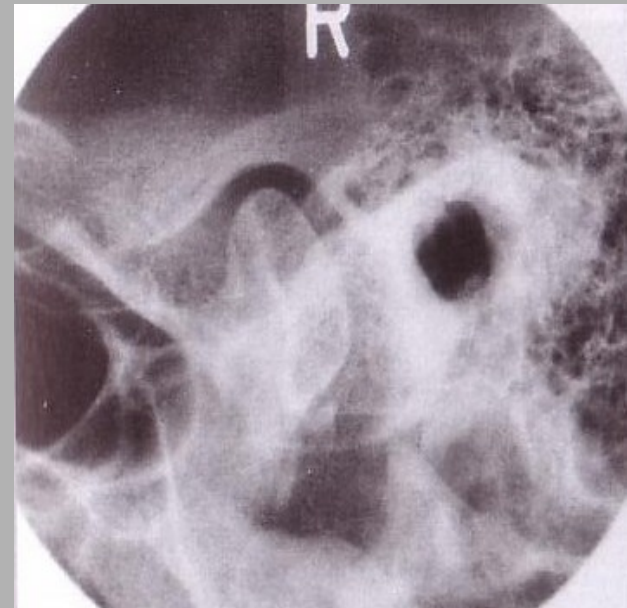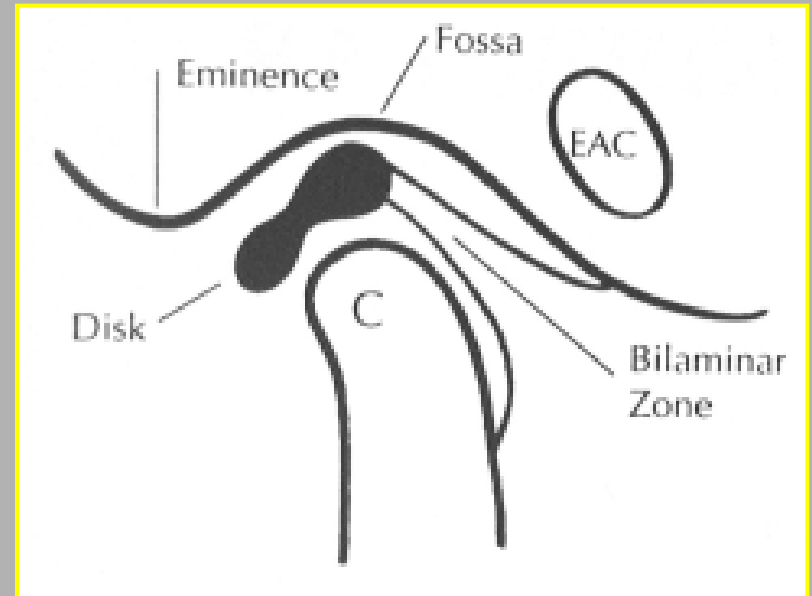


- 1 Kondylus, laterální pól
- 2 Kondylus, mediální pól
- 3 Processus condylaris mandibulae
- 4 Fossa glenoidalis, laterální části
- 5 Eminentia articularis, laterální části
- 6 Arcus zygomaticus
- 7 Sella turcica
- 8 Sinus sphenoidalis

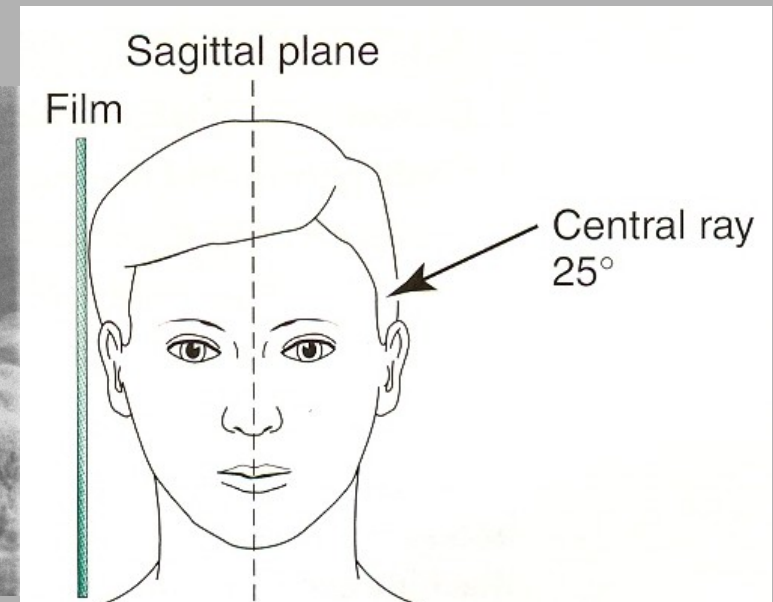
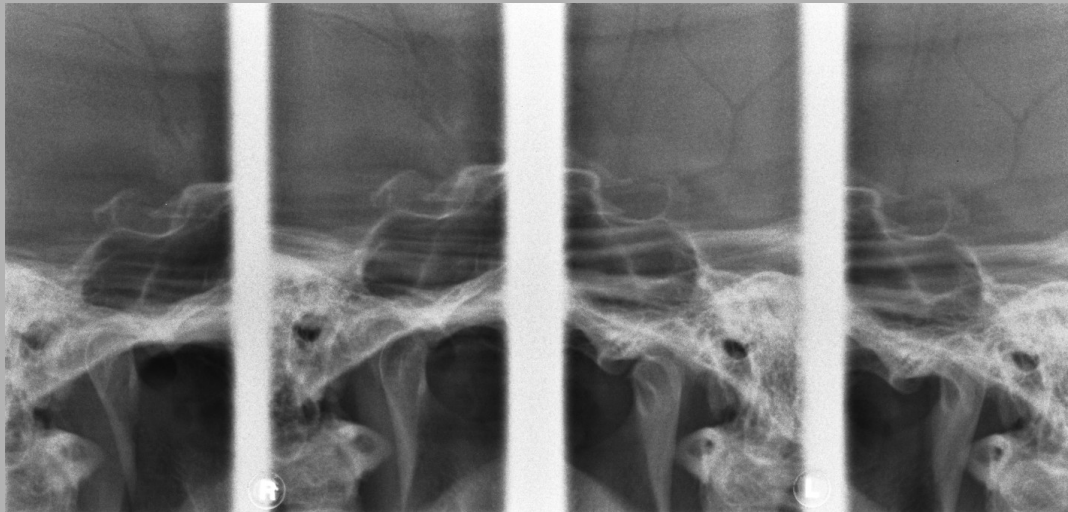
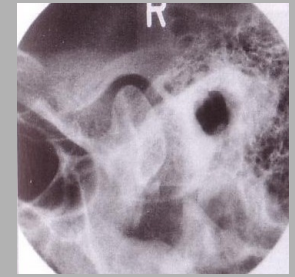
- 9 Processus clinoideus posterior
- 10 Clivus
- 11 Pars petrosa (vzdálenější)
- 12 Pars petrosa (přilehlá)
- 13 Horní hrana pyramidy (přilehlá)
- 14 Porus acusticus externus
- 15 Celullae mastoideae
- 16 Pars tympanica ossis temporalis

Temporomandibular joint (TMJ)

- biconcaval disc,
- correct position protect mandible joint (TMJ)
- Intracapsul. disease = diskopathy
- Diskopathy =
 - disc dislocation
 - ✓ With/ without reposition
 - ✓ adhesion



Temporomandibular joint - TMJ

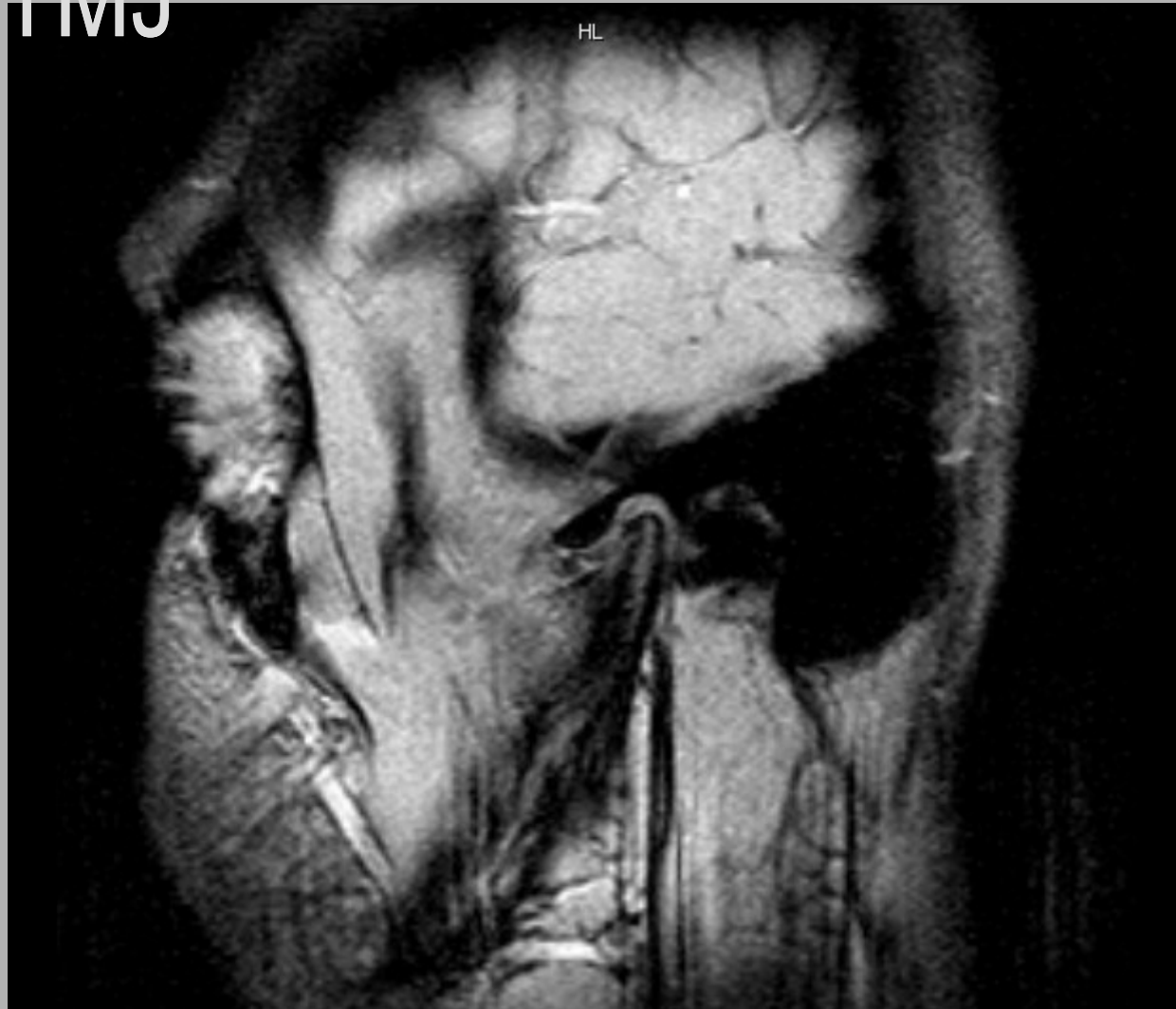


serial radiogram TMJ

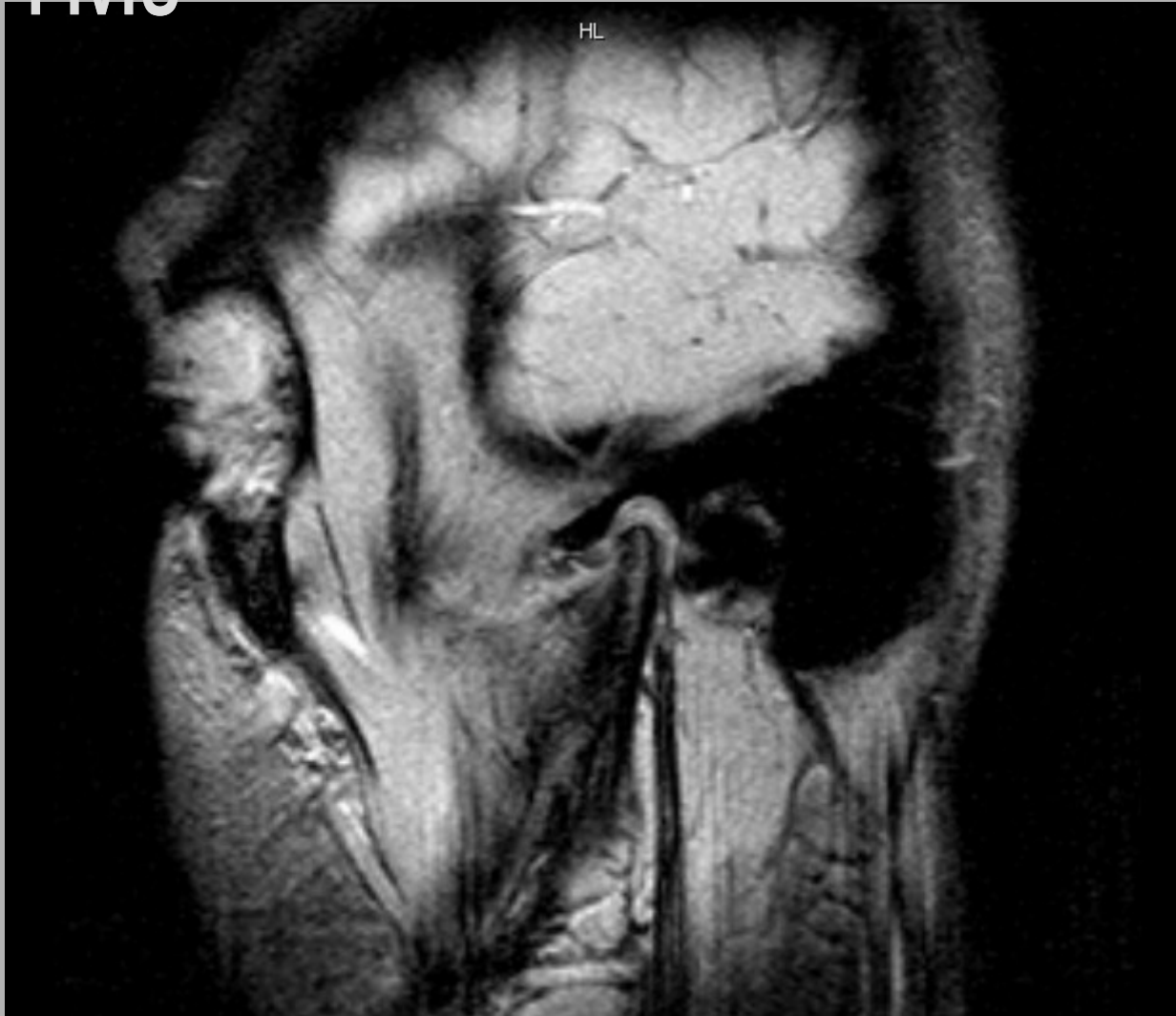
- x-ray beam passes vertical +25° to center of film
- entering 6-7cm over meatus acusticus.

- condyl head
- fossa glenoidalis
- close mouth
- open mouth

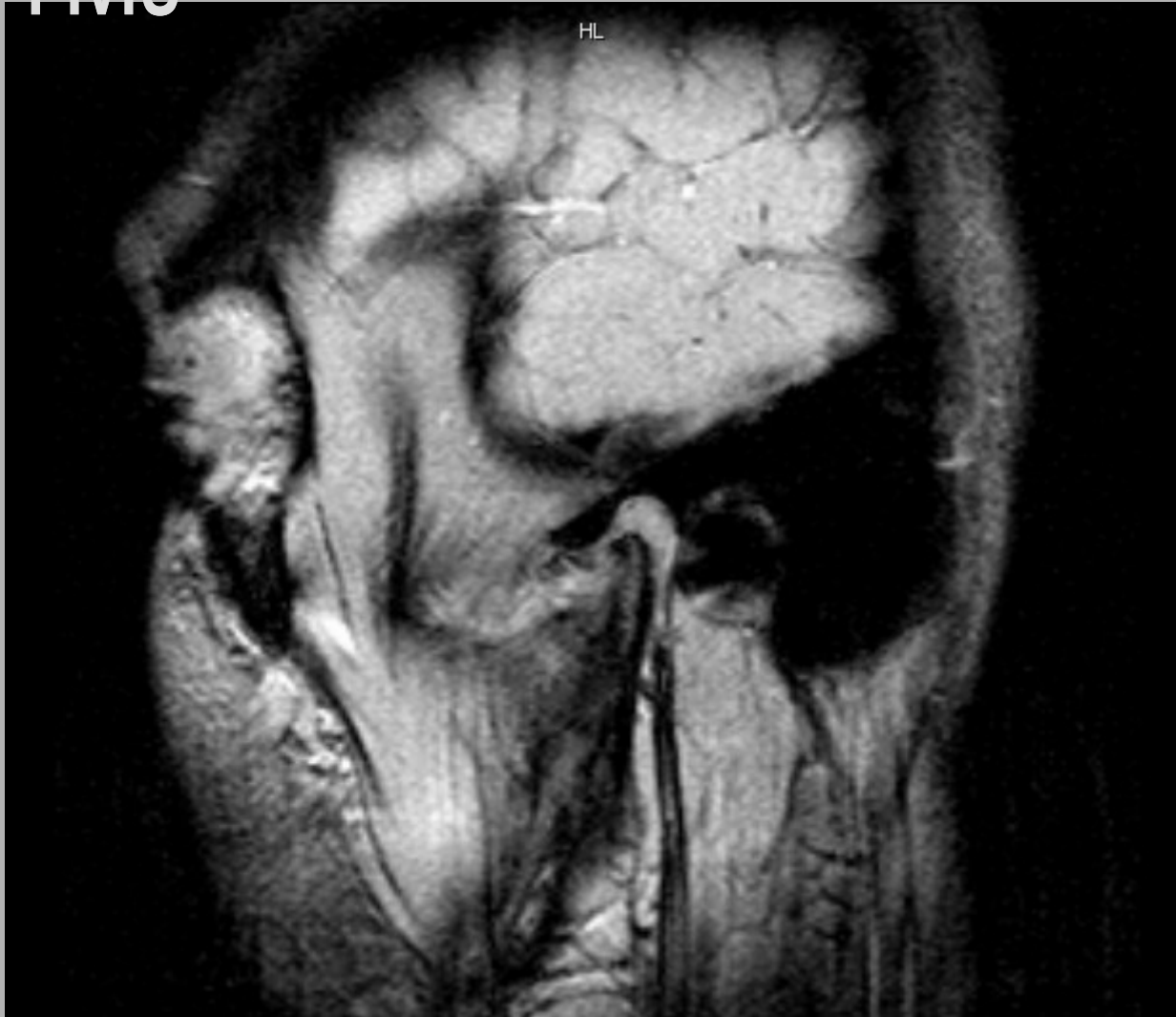
MRI - TMJ



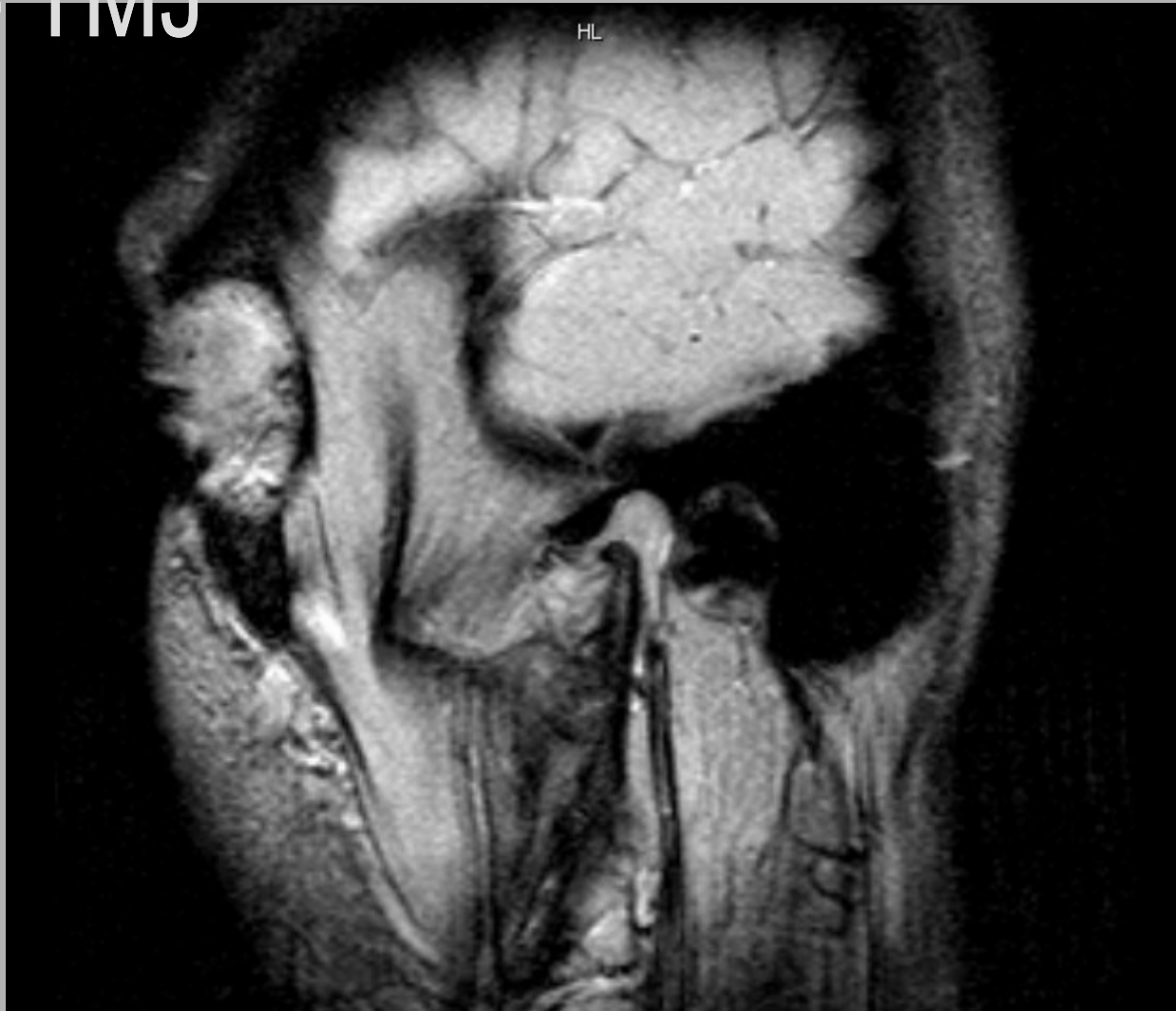MRI - TMJ



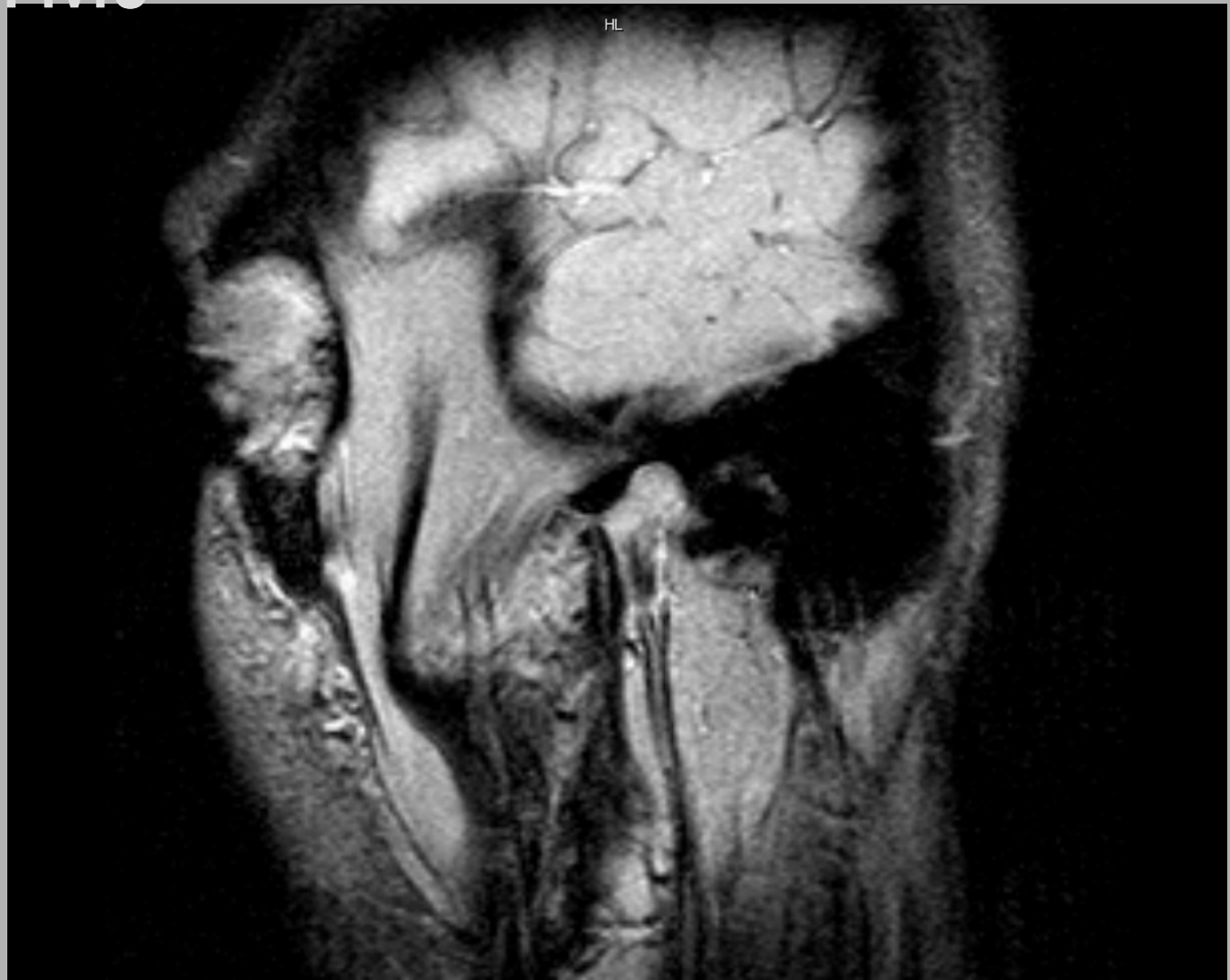
MRI - TMJ



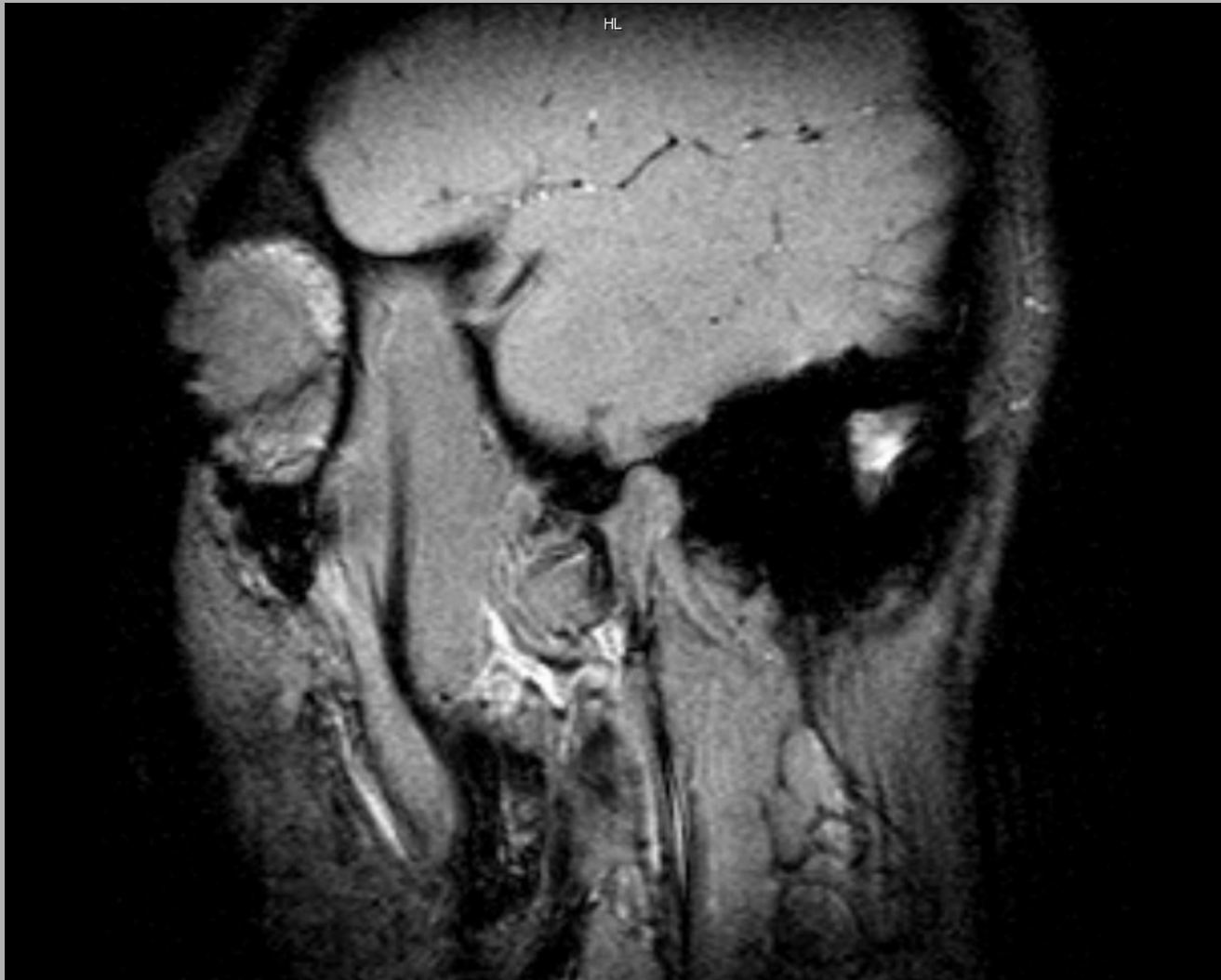
MRI - TMJ



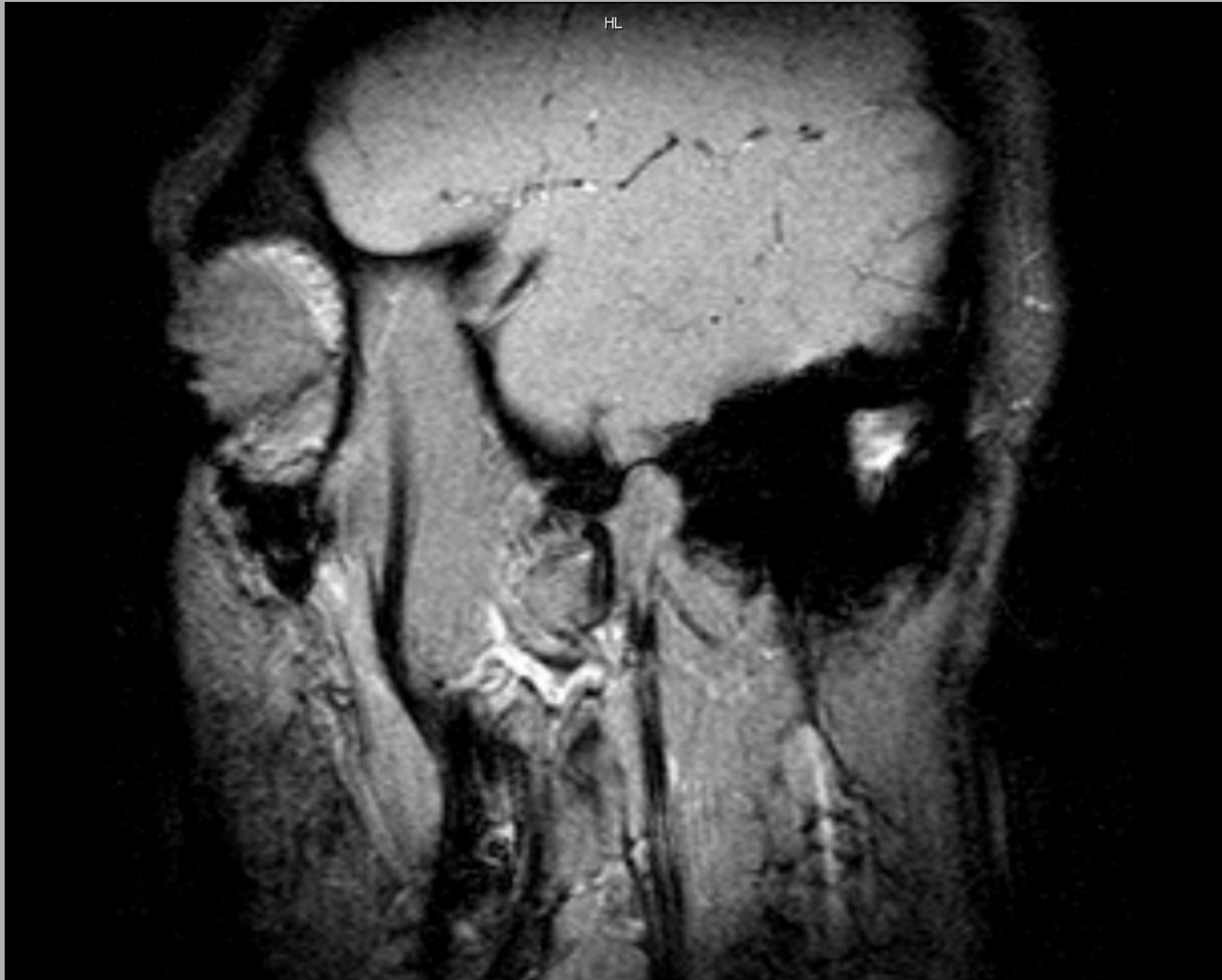
MRI - TMJ



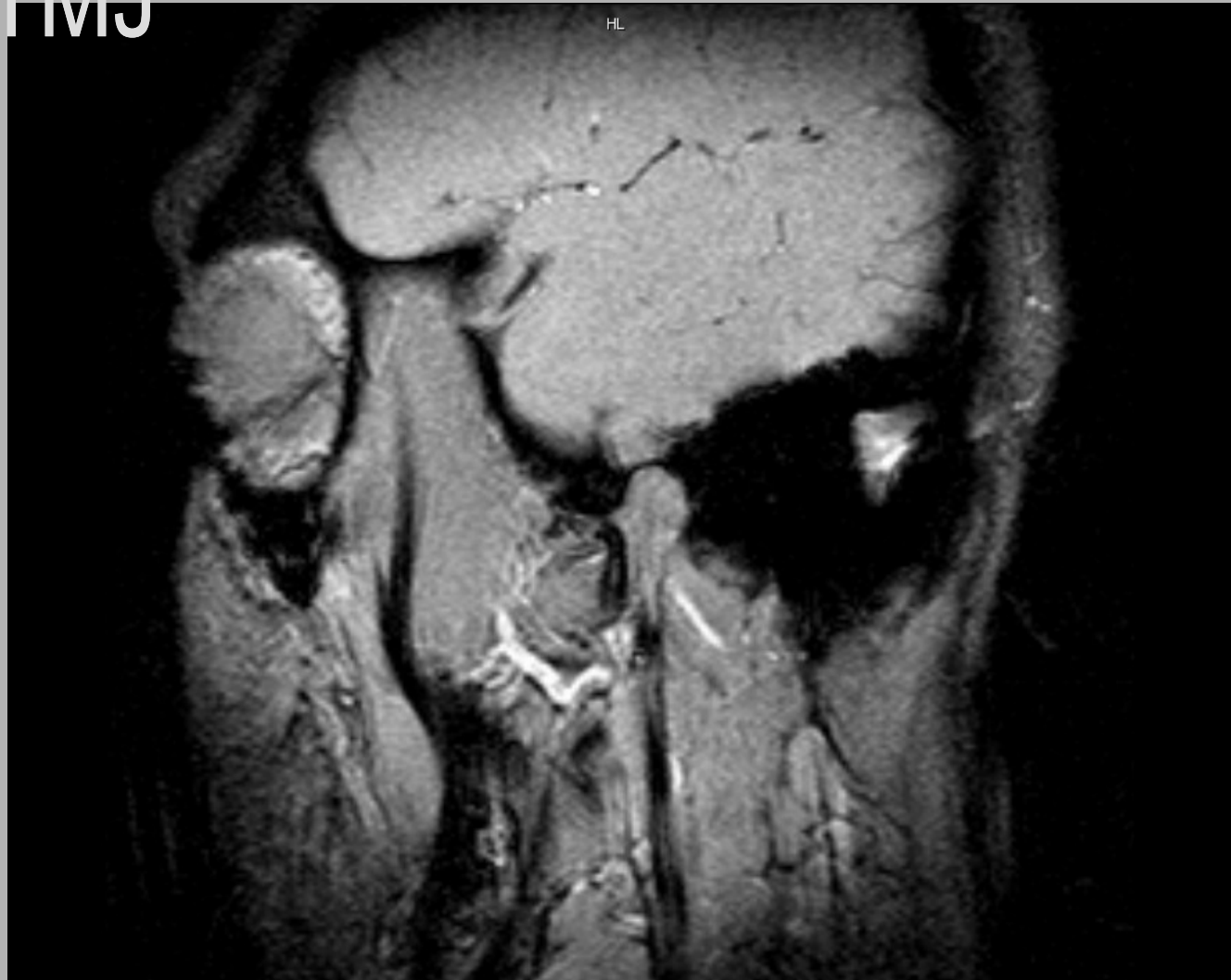
MRI - TMJ



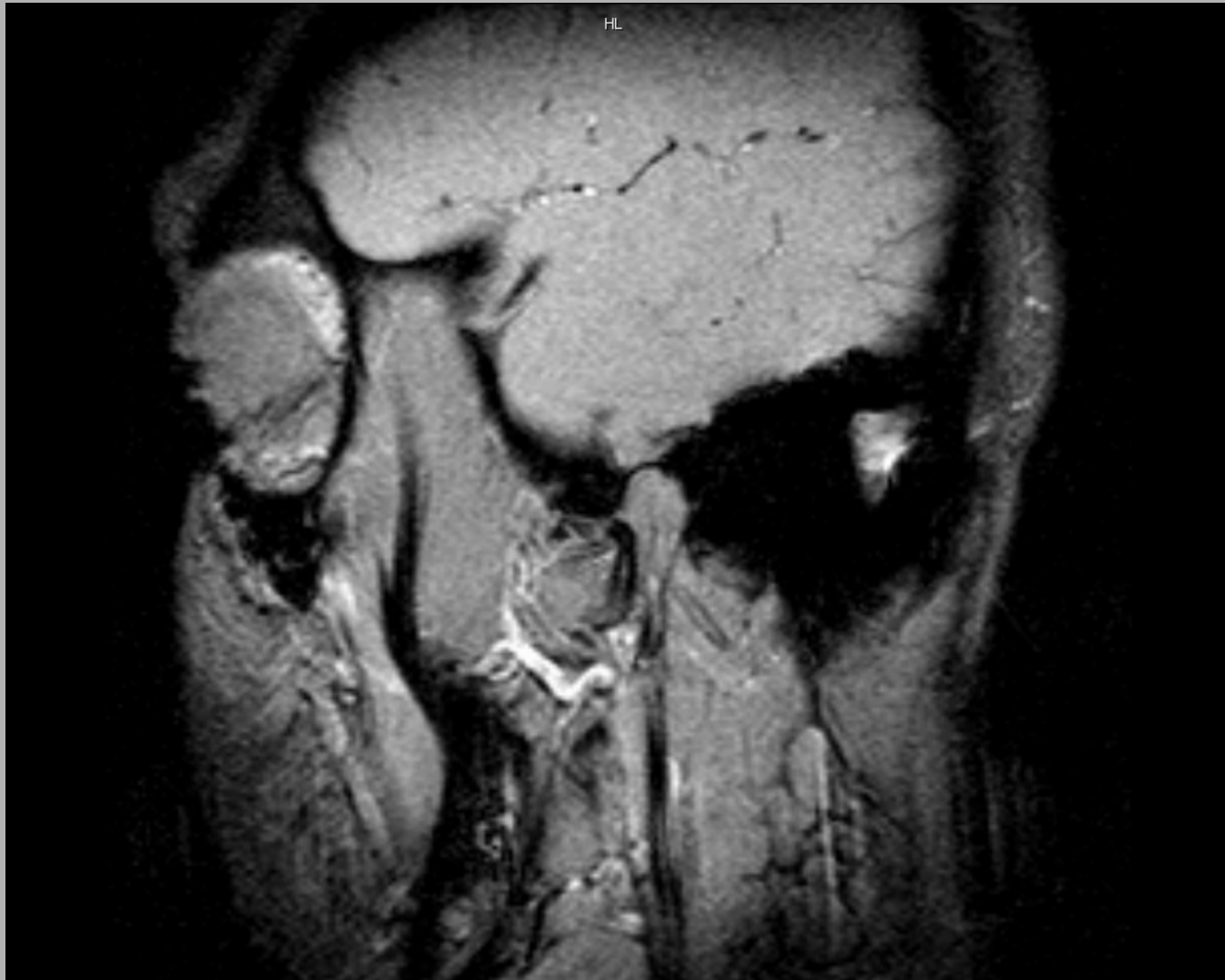
MRI - TMJ



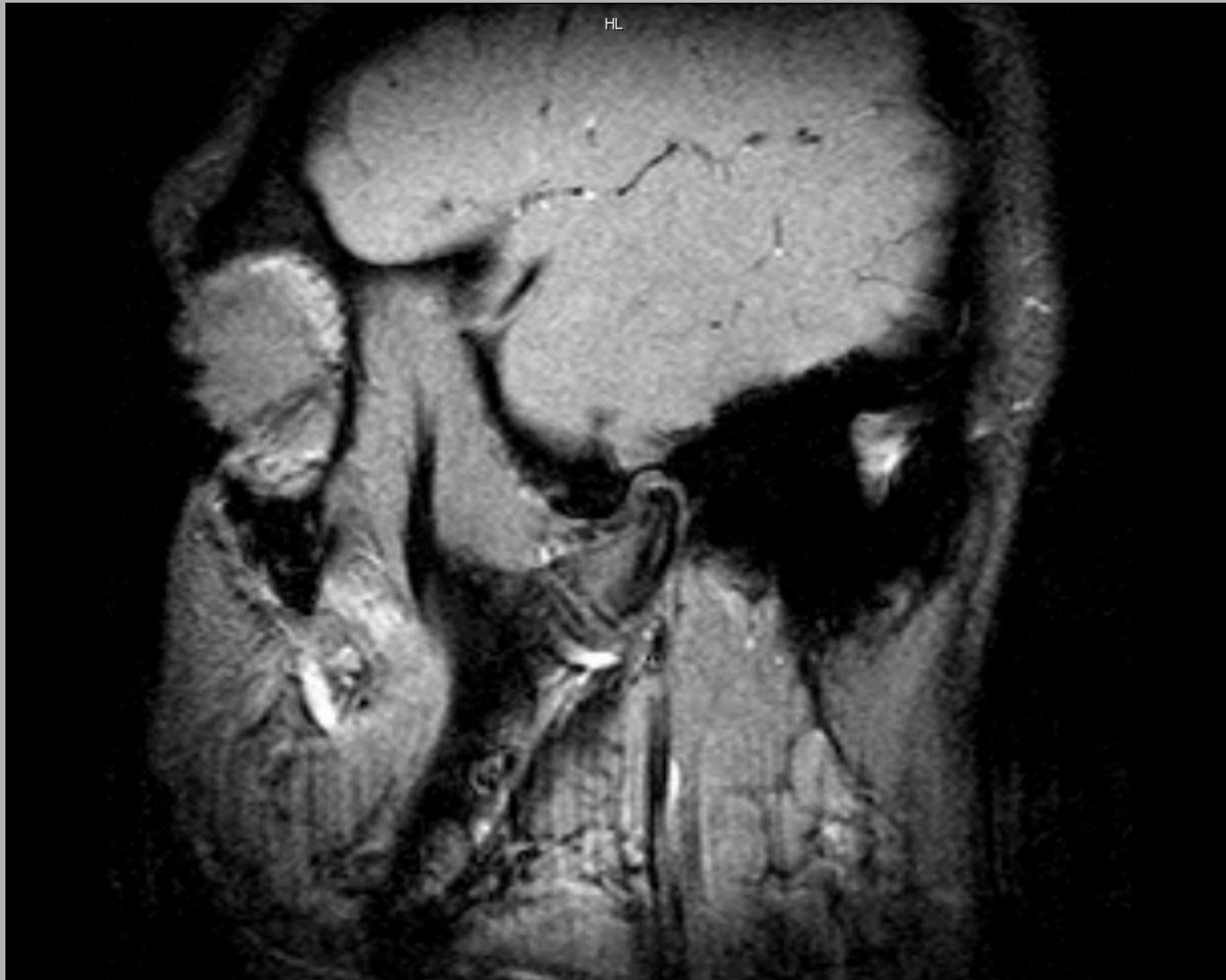
MRI - TMJ



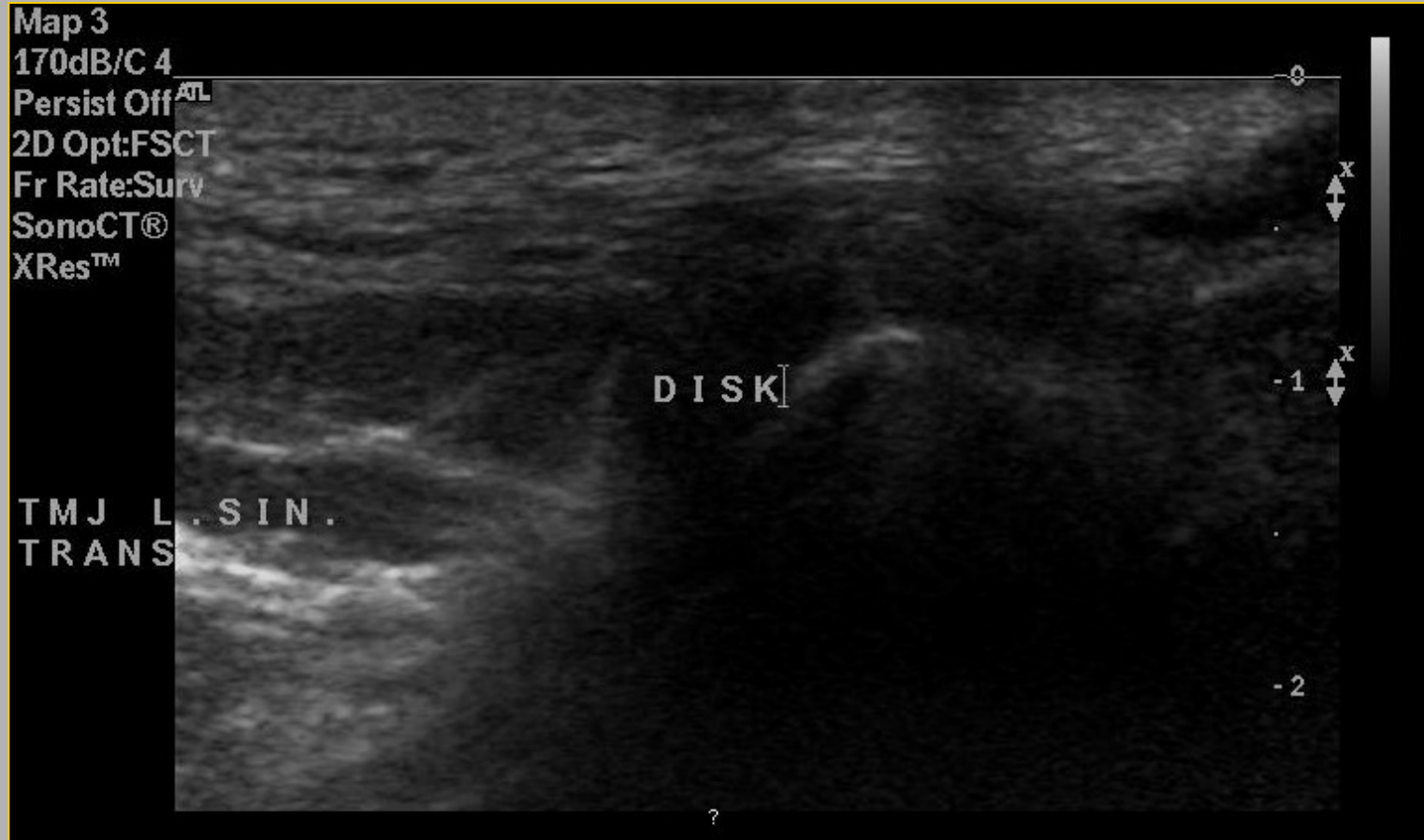MRI - TMJ



MRI - TMJ

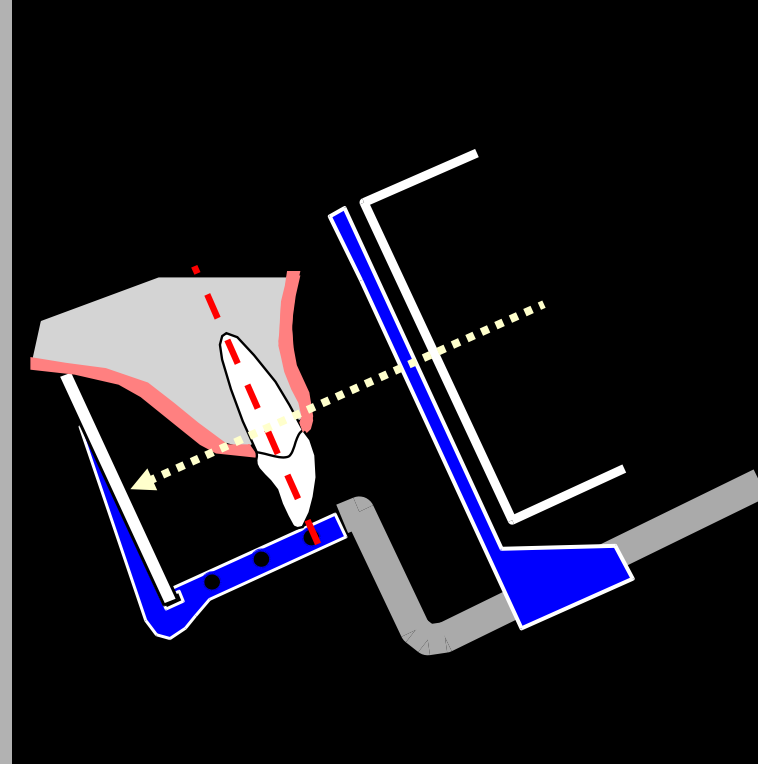
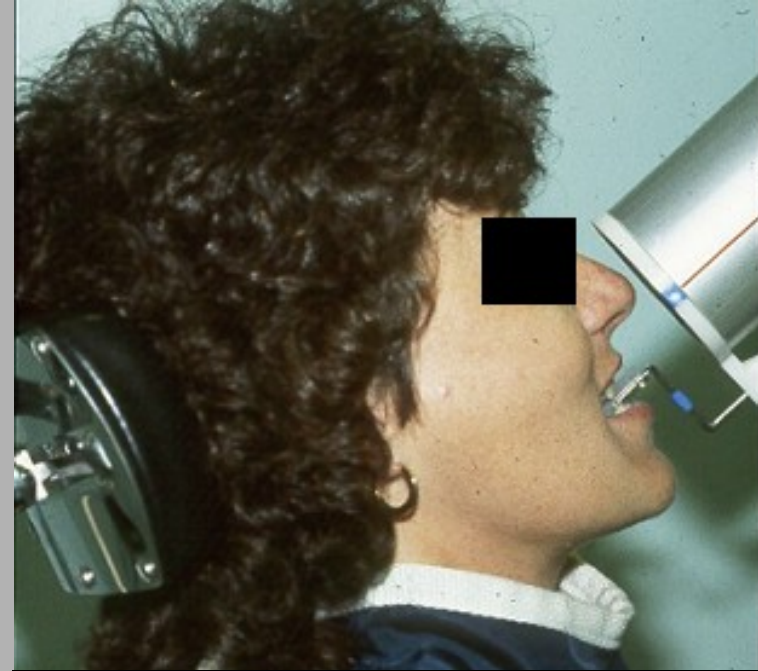

Ultrasound - TMJ



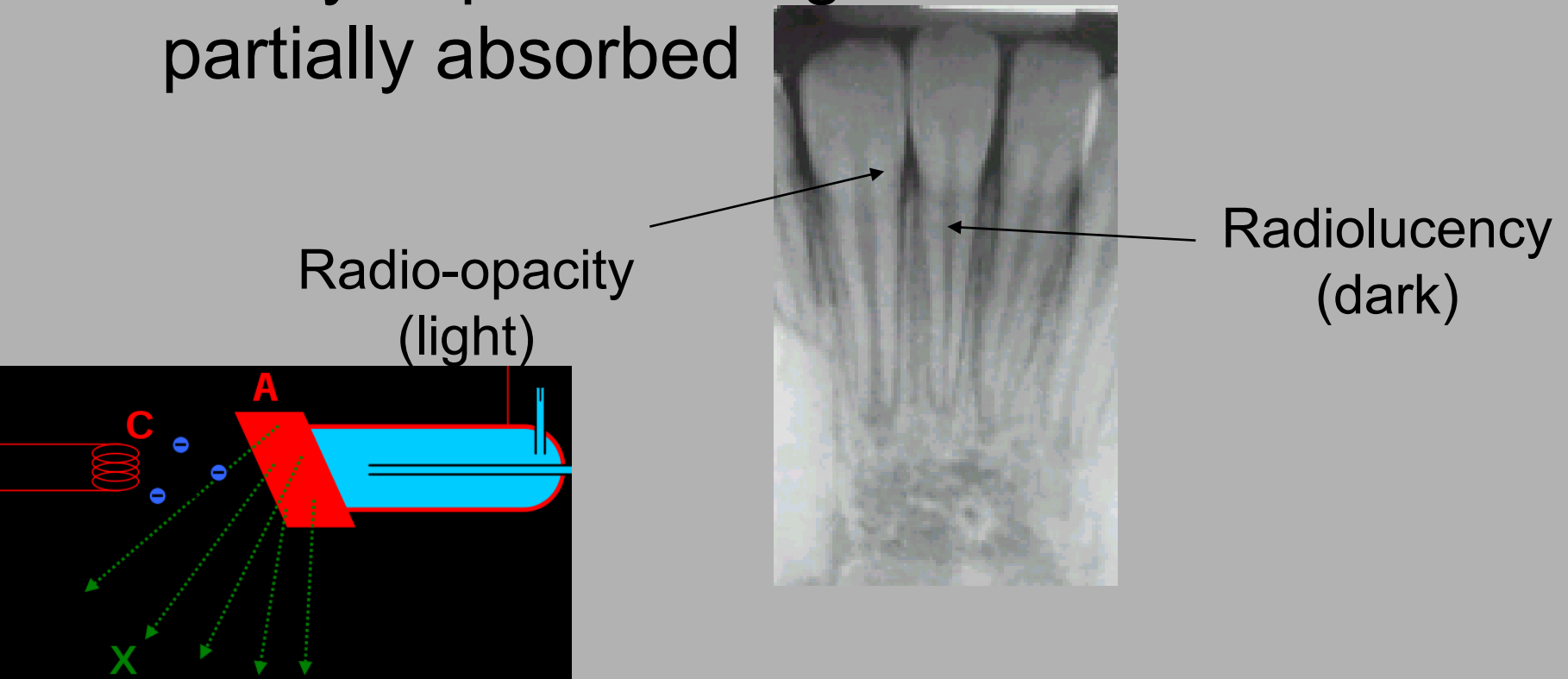
Intraoral X-ray device

- voltage of X-ray tube
 - 50-90 kV
- filtration of primary beam
 - 1,5 mm Al - $U < 70$ kV
 - 2,5 mm Al - $U > 70$ kV
- body tube
 - length of body tube = 10-30 cm




X-ray - attributes

- Electromagnetic radiation of short wavelength produced when high-speed electrons strike a solid target (on anoda)
- Ability to pass through tissues where are partially absorbed





Films for intraoral exposure

- dental films - conventional



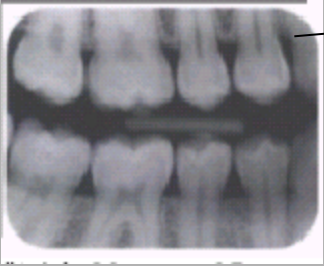Conventional and digital technique

- Digital:
 - CCD (charged coupled device) as a sensor

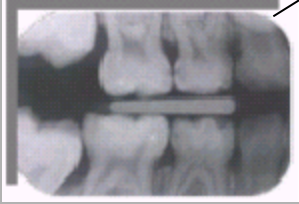

Films for intraoral exposures

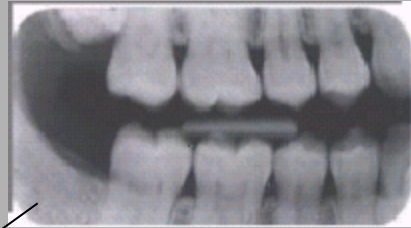
- standard formats



classic 31x41 mm

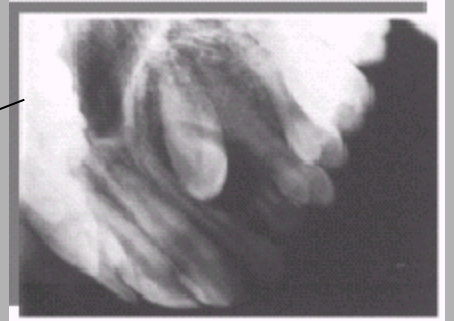


child 22x35 mm




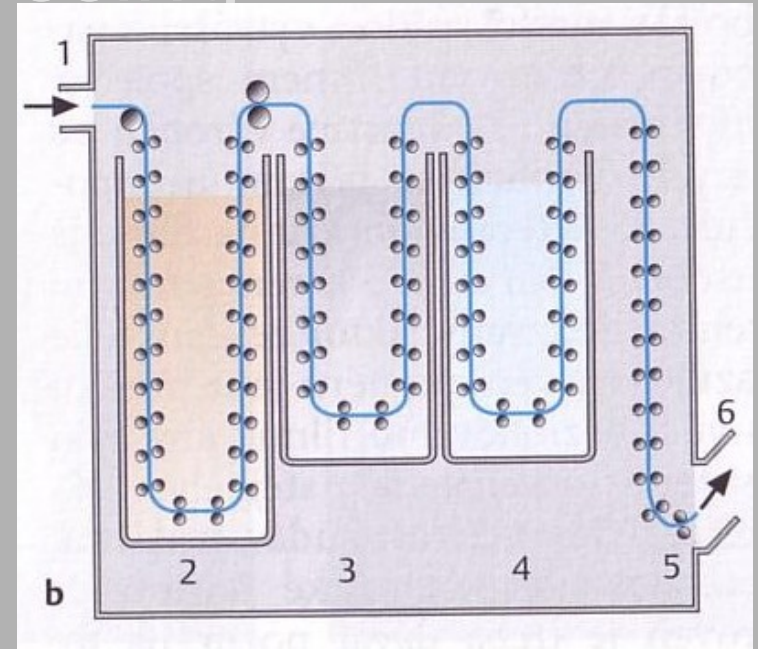
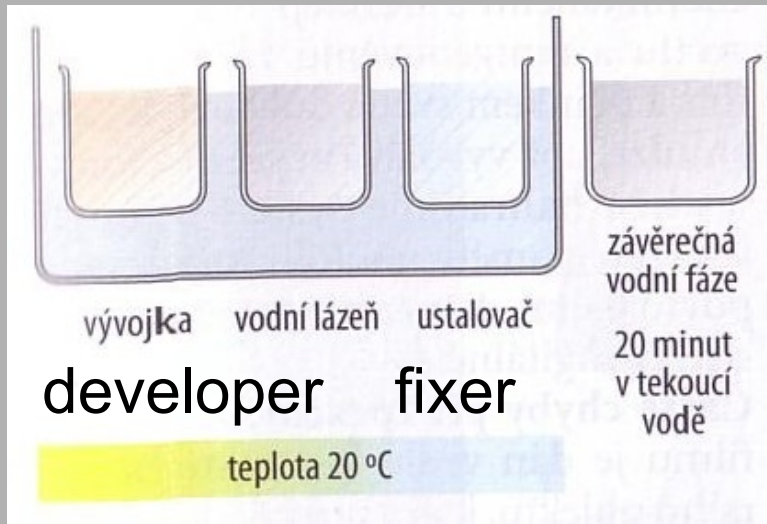
special 27x54 mm

special 57x76mm

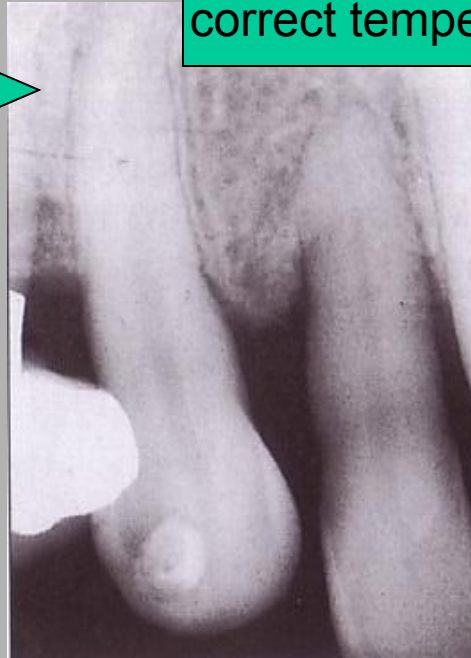
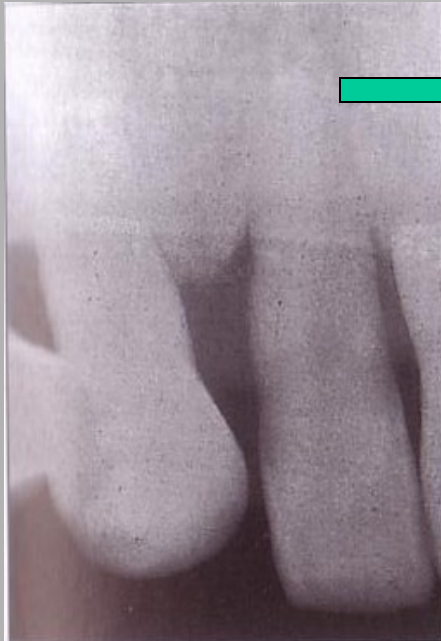


- The film covering is larger than film (over 1 mm)

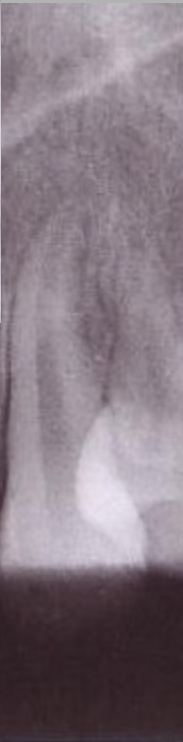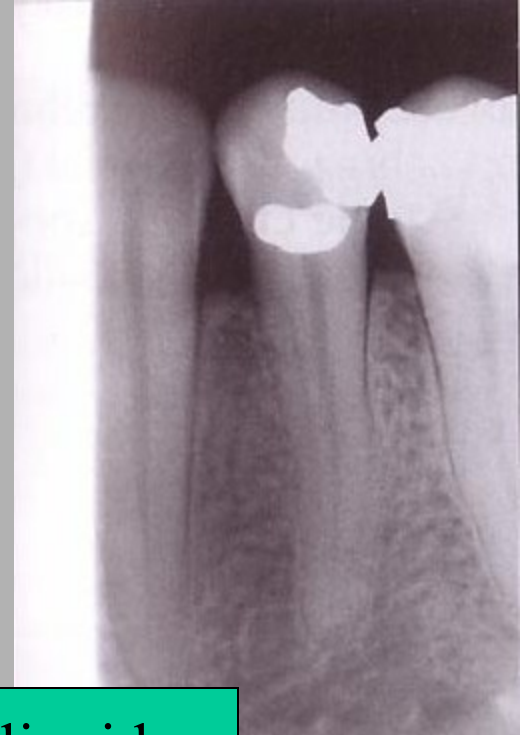Conventional film processing



Conventional film processing - artefacts



correct temperature

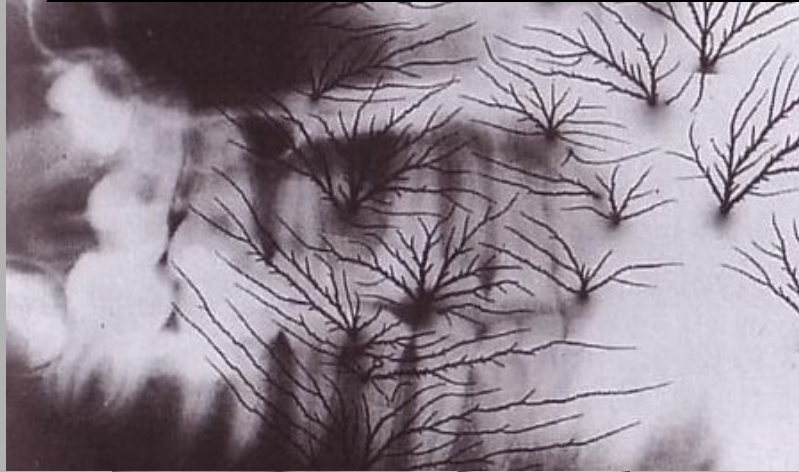

cold chemicals
film is grainy

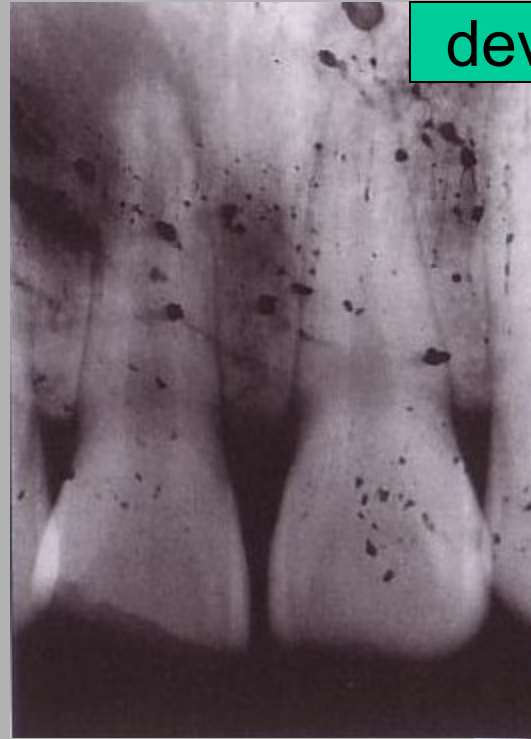little developing liquids

Conventional film processing - artifacts

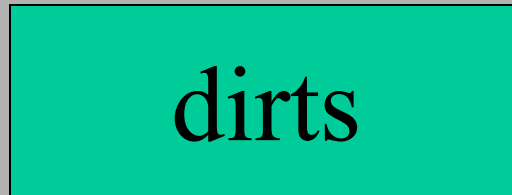Electrostatic energy - too fast taking film out of the cover -



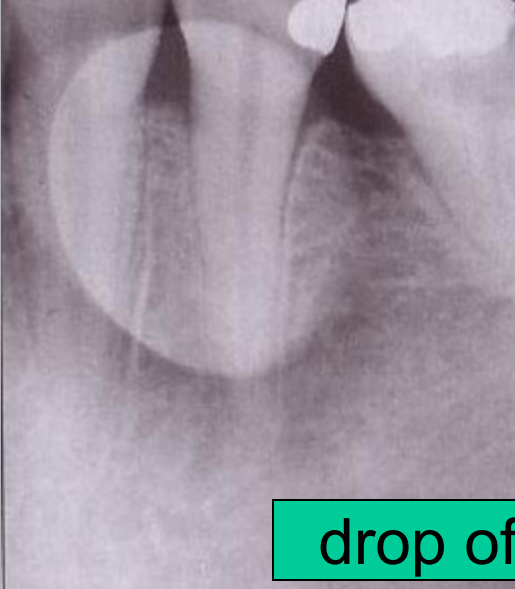developer



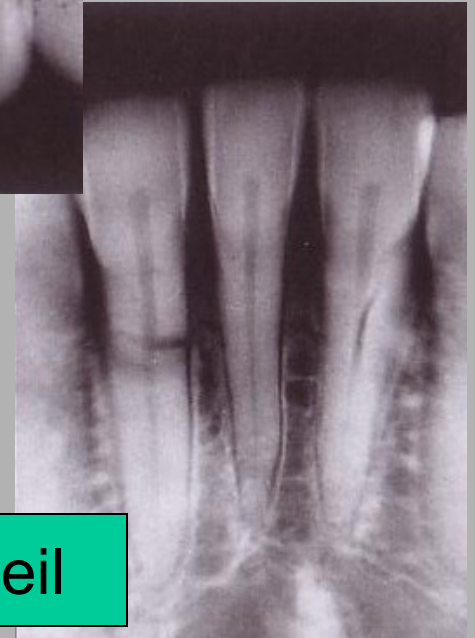
dirts



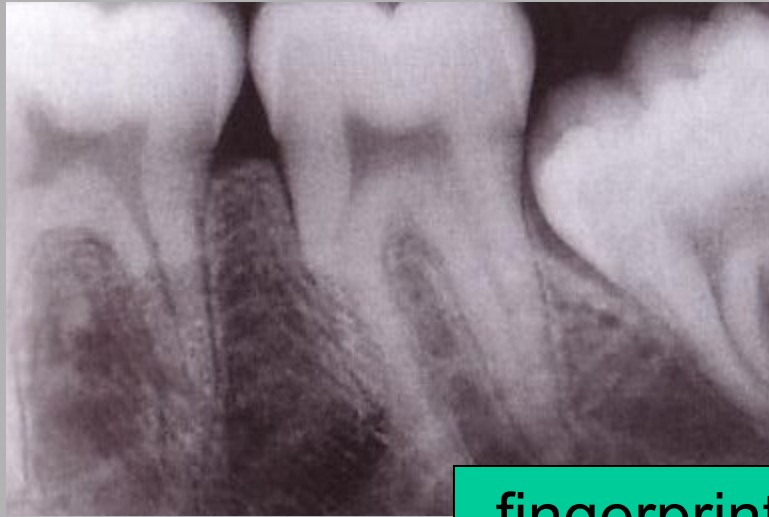drop of water



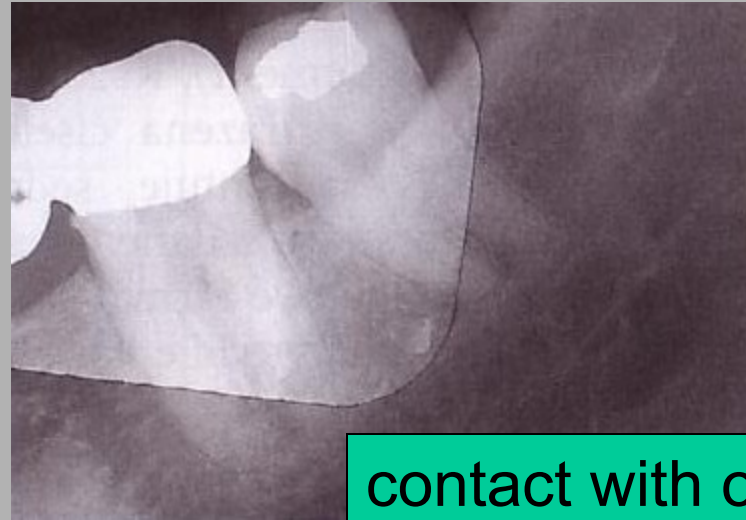
neil



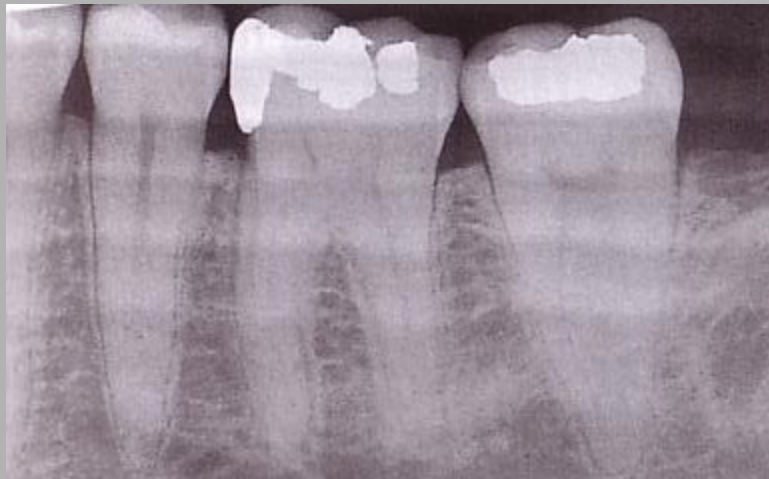Conventional film processing - artefacts



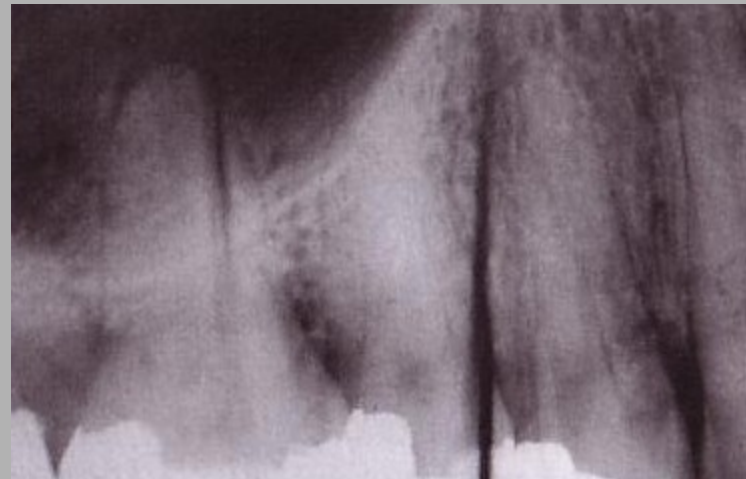fingerprint



contact with other film

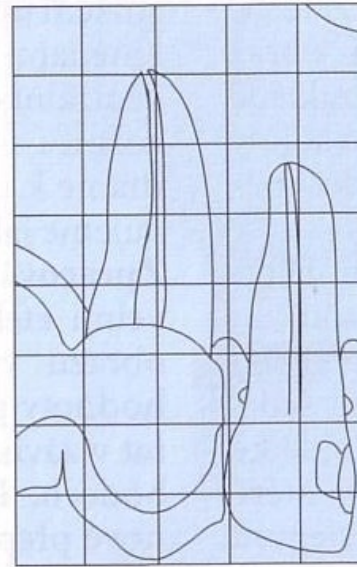
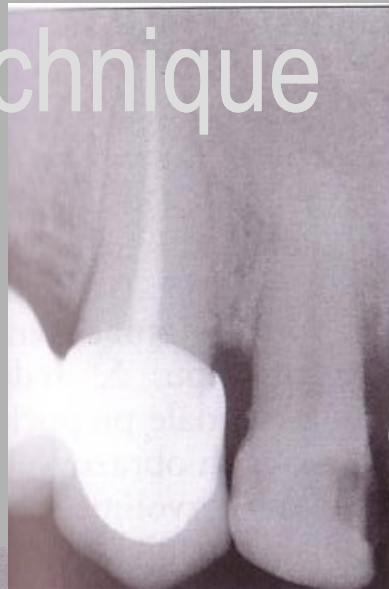


too high temperature during developing

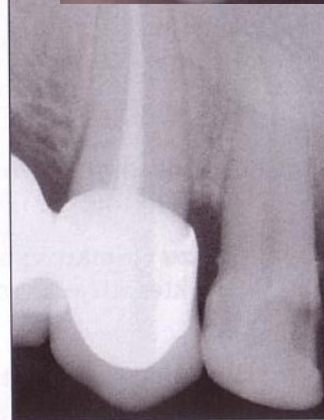
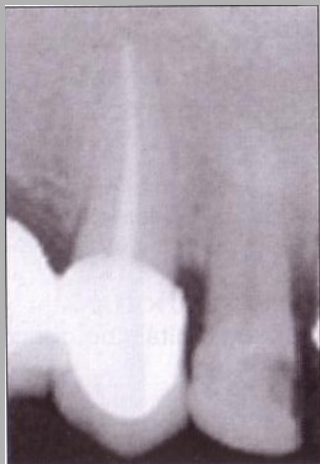

broken emulsion layer up

Digital technique



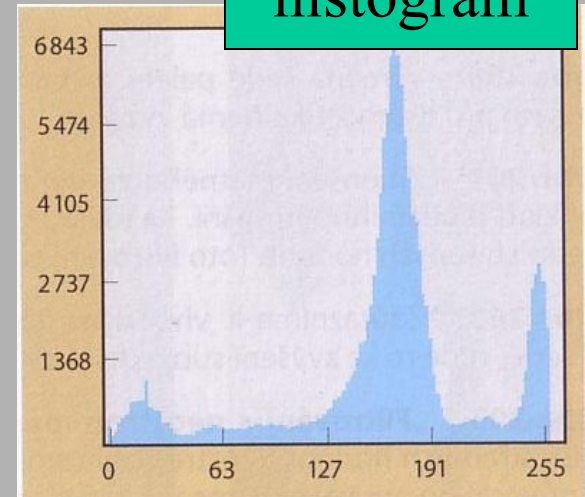
5	5	5	5	4
4	4	4	5	5
4	5	5	5	4
3	4	5	5	5
7	5	4	5	3
7	7	7	5	7
2	5	6	5	0
0	0	0	0	0



256 gray shades

no transitive shades

histogram



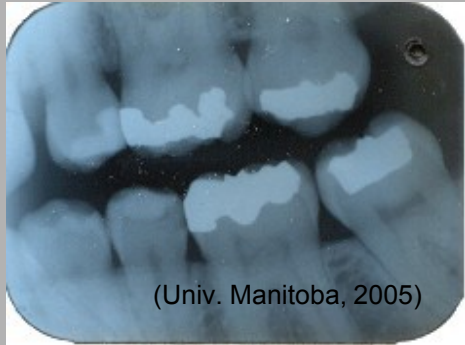Digital technique - advantages

- filmless performance
- friendly inspecting and storage of pictures
- repeated exposure without medium changing
- lower dose?

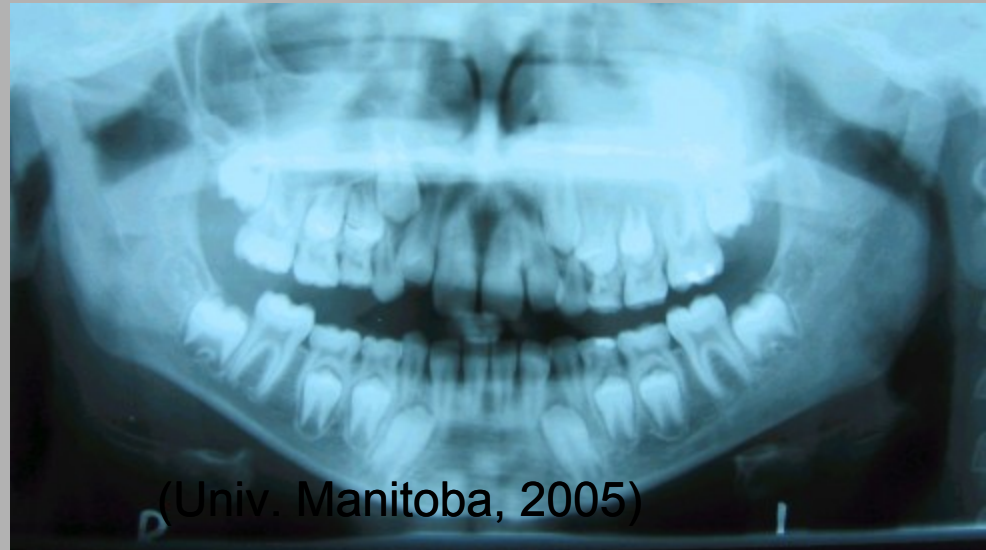Basic types of radiogram

Basic types of radiogram

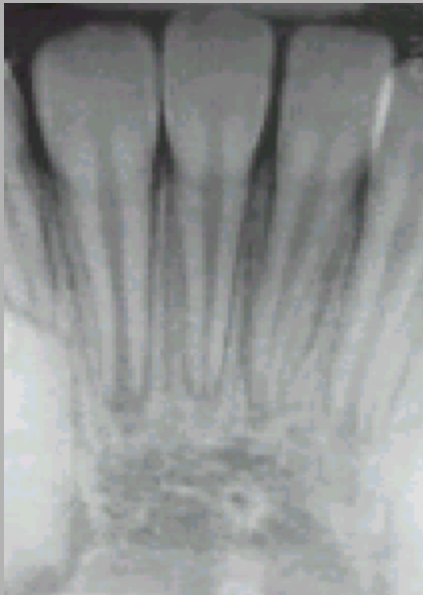
Bitewing



Panoramic - OPG



Periapical



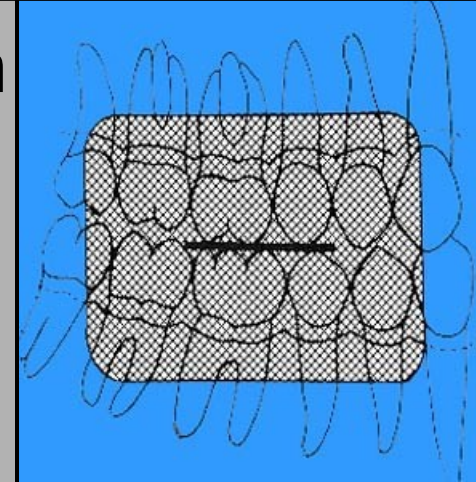
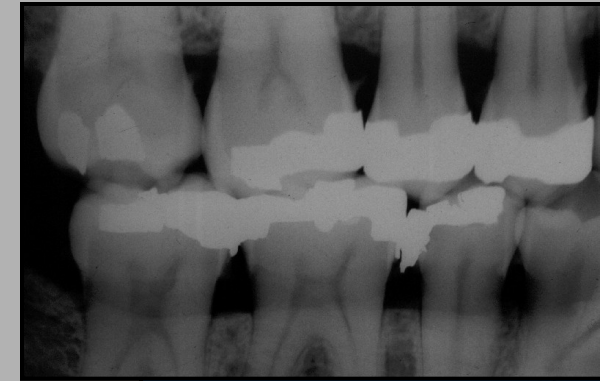
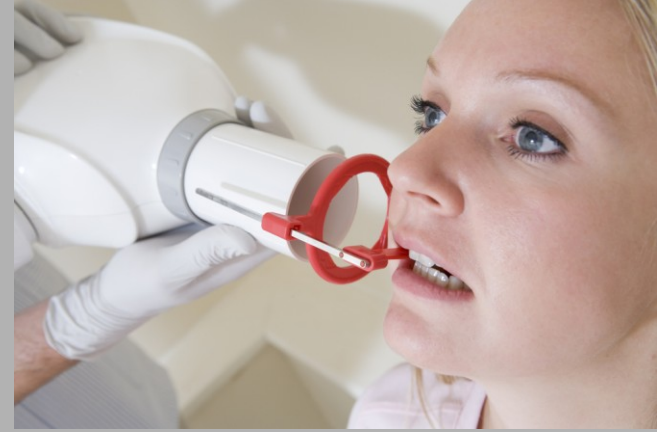Bitewing

Shows crowns of upper and lower teeth simultaneously.

Indications:

- examination of the occlusal line
- examination of:
 - tooth caries
 - tooth loss
 - monitoring pictures, e.g. cured teeth
 - assessment of periodontal status

Usually of posterior teeth but can be anterior teeth.

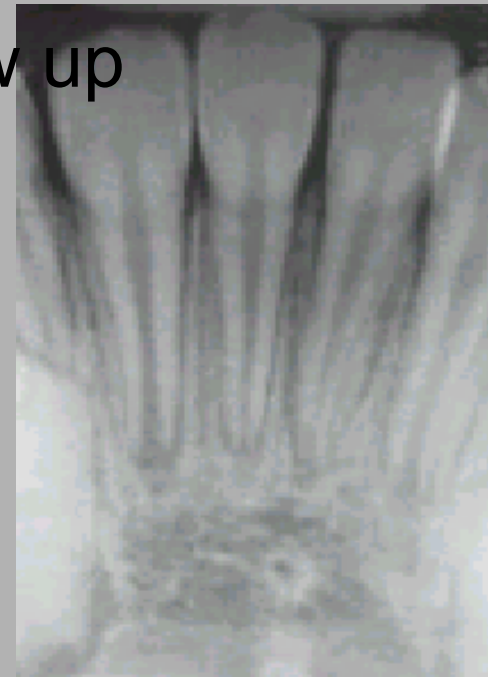

Periapical exposures

Indications:

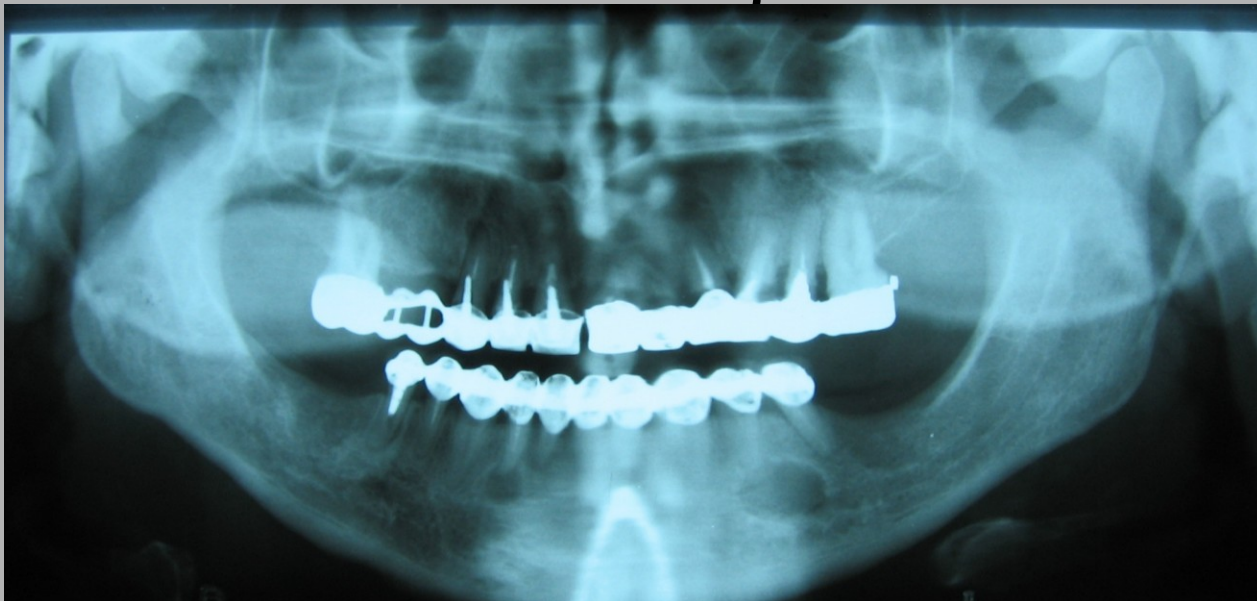
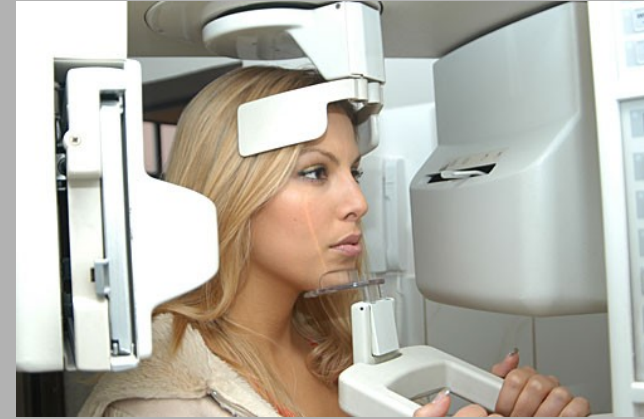- apical infection detection
- trauma – tooth and alveolus
- root assessment
- Orthodontia

diagnostics, plan, therapy, follow up



Ortopanthomography - OPG

- one exposure demonstrates:
- jaws
- teeth
- joints
- alveolar recesses of jaw cavities

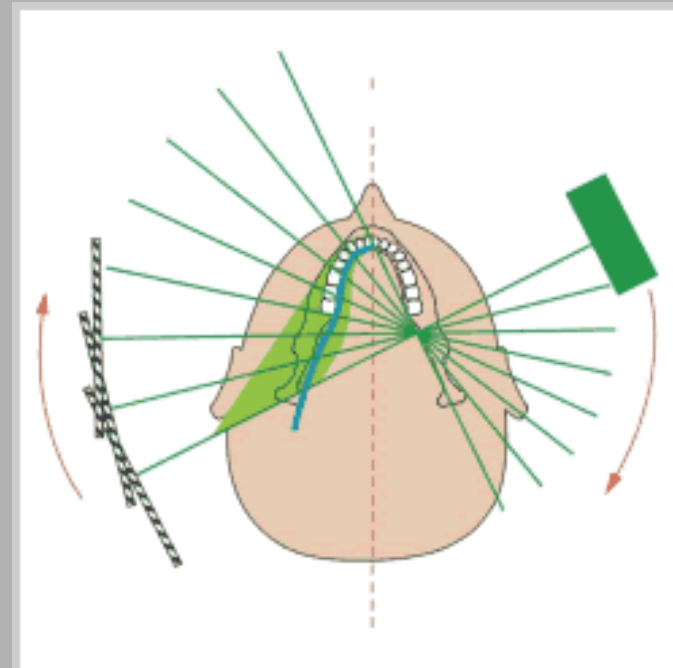
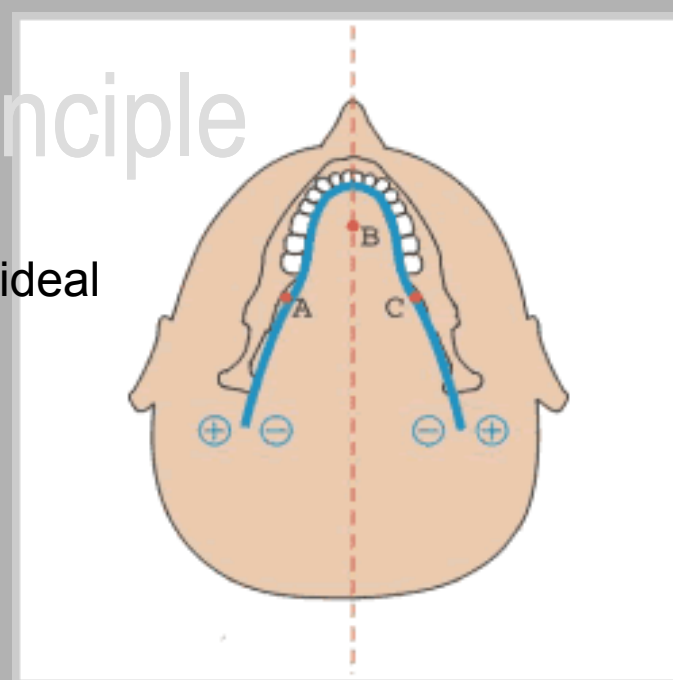


Ortopanthomography - OPG

- comfort
- low radiation dose
- better than intraoral RTG STATUS
(traditional series of teeth)

Ortopanthomography - principle

- X-ray tube goes around the head on the track of ideal teeth occlusion - parabola
- There are 3 rotatory centra very next to the teeth occlusion



Ortopanthomography - assessment

- Wisdom teeth
- TMJ
- Maxilar sinus
- Fractures and other skeleton pathology
- Orthodontia

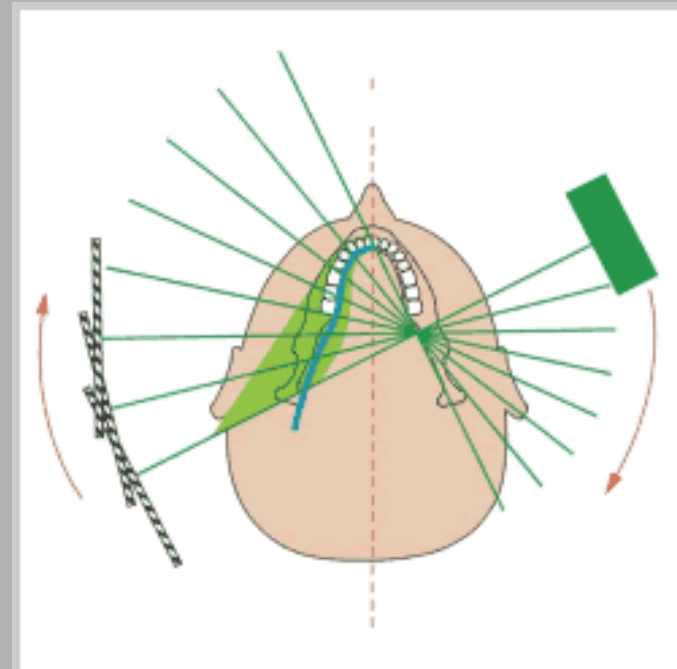
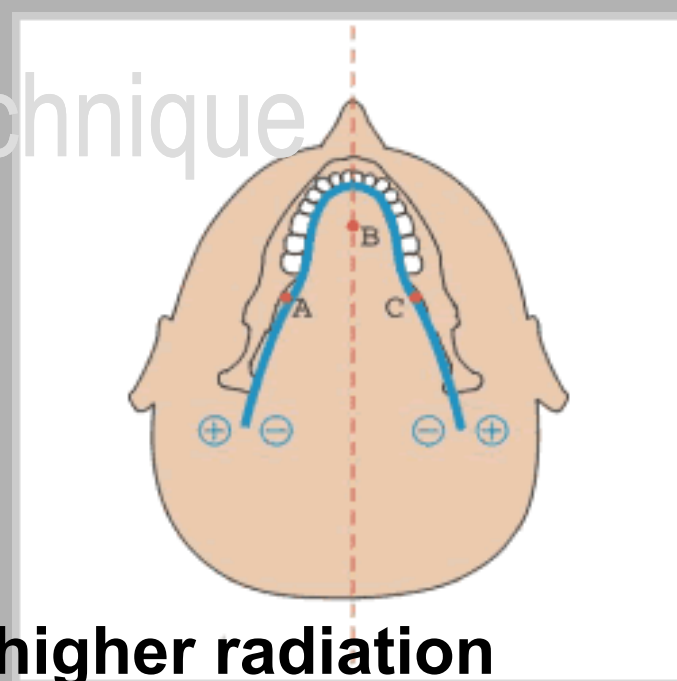
Ortopanthomography - technique

- **leyer thickness**

- ✓ from 9 mm (frontal part)
- ✓ till 20 mm (in the area of TMJ)

– **thinner leyer = less artefacts, higher radiation dose**

- defocus
- zoom
- possibility of mesuring

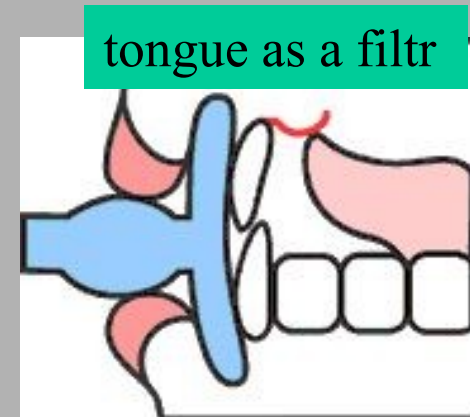
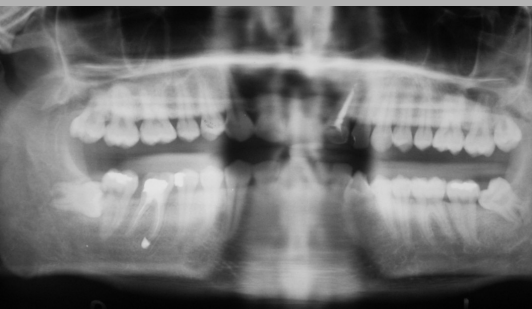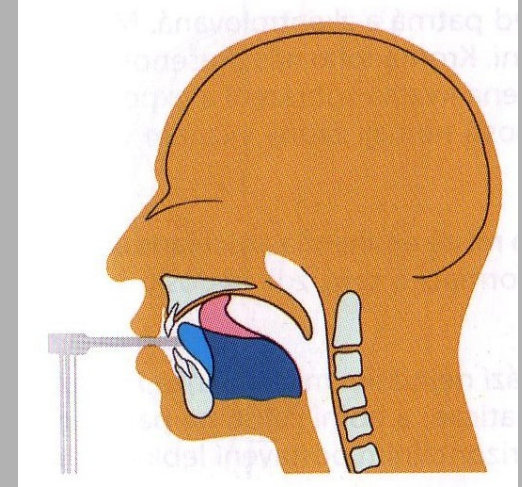


Zonograms

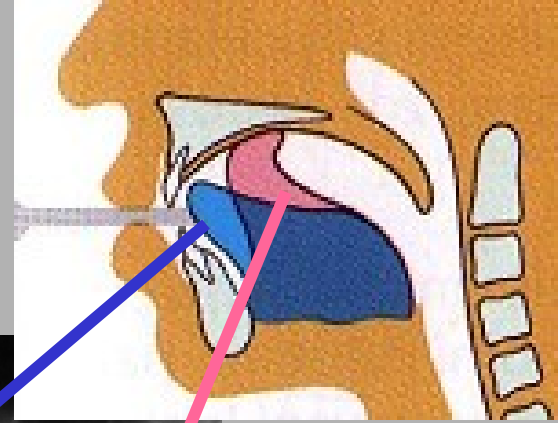
- = panoramic RTG exposures of different layer thickness
- variable layer thickness during exposition
- combination of zoom in (detail) technique
- to better exposure
 - reduction of cervical vertebra summation
 - ✓ reduction of rotating velocity of X-ray tube
 - ✓ increase the exposition parameters in the point of (x-ray) passing

Burn-out effect

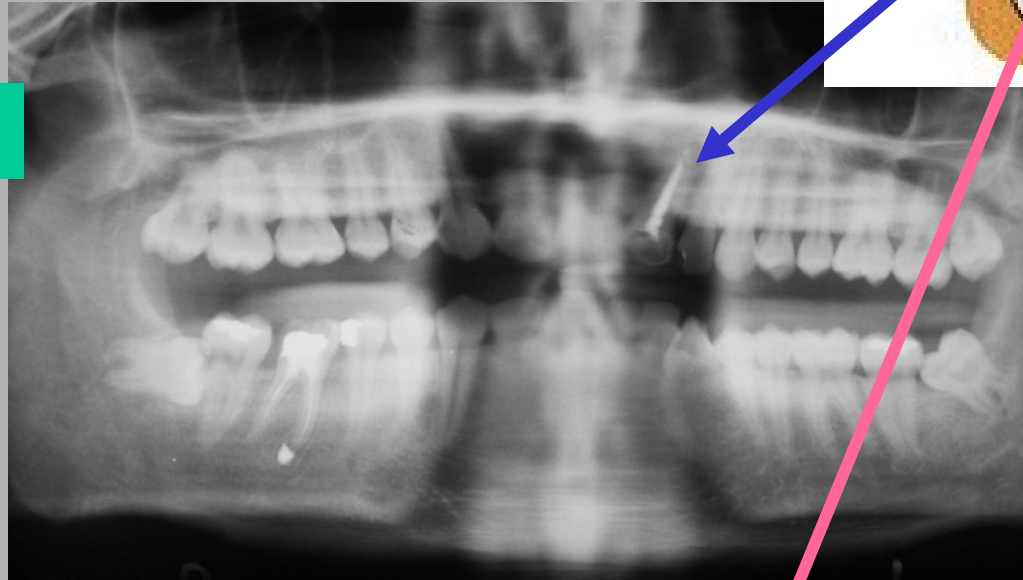
- incorrect tongue position
- x-ray beam is not reduced
- = „overexposition“ of structures
- **negative contrast of air** suppresses:
 - maxillar tooth roots
 - structures of maxilla
 - boundary of nasal and maxillar cavities
- **it is NOT possible to ASSESS**



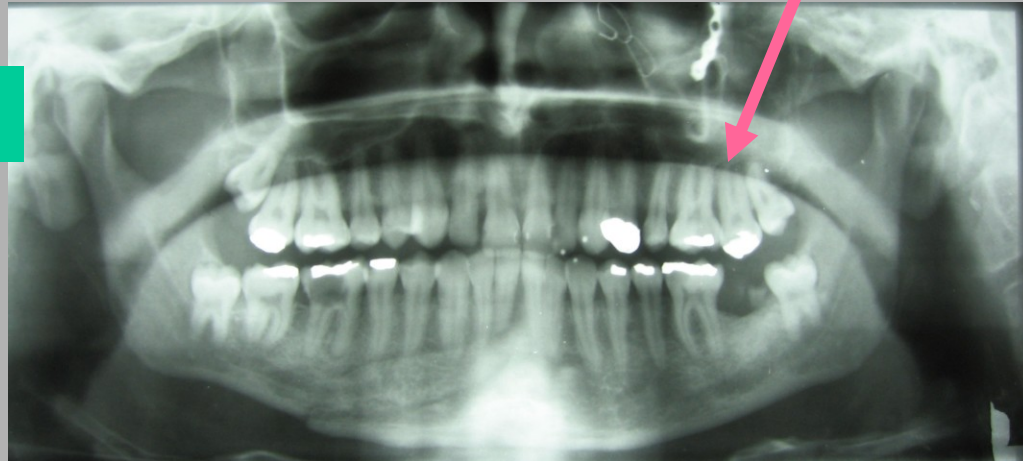
Burn-out effect



overexposed picture



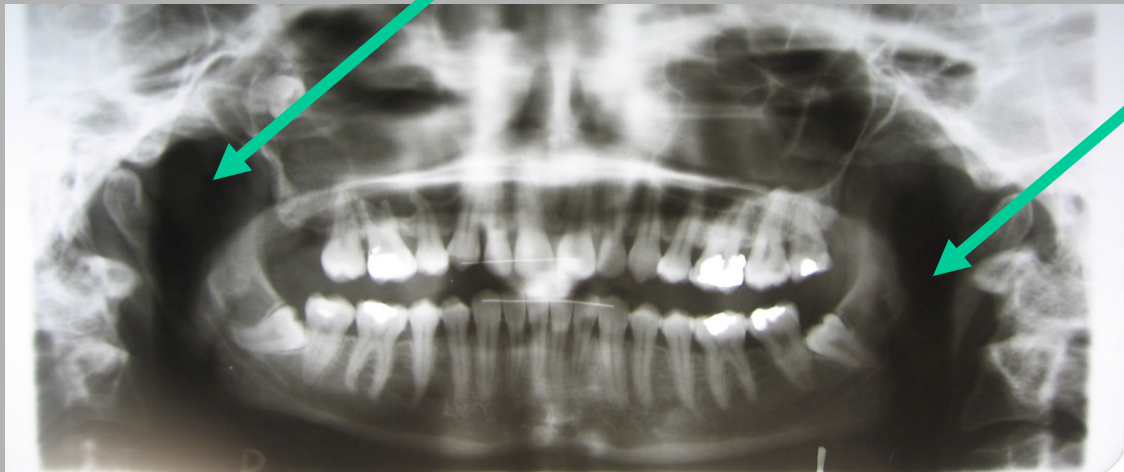
tongue as a filter



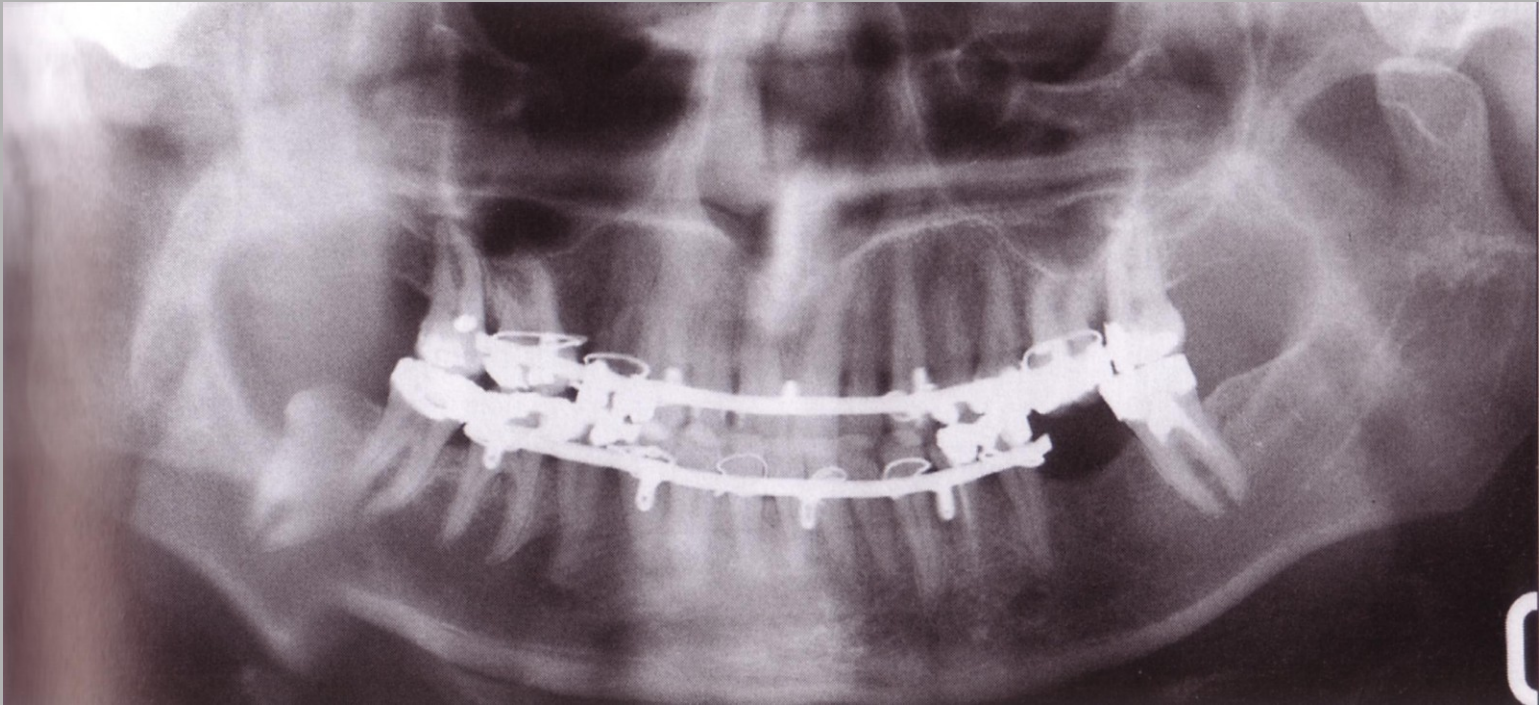
The breathig

„Don't move and breathe calmly during the examination.“

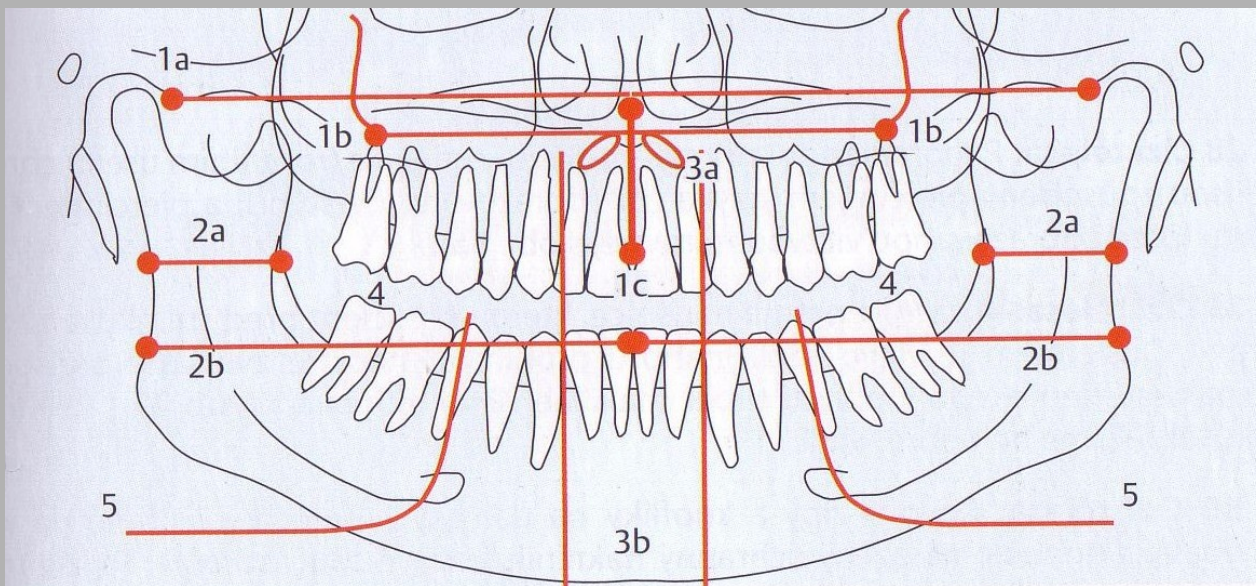
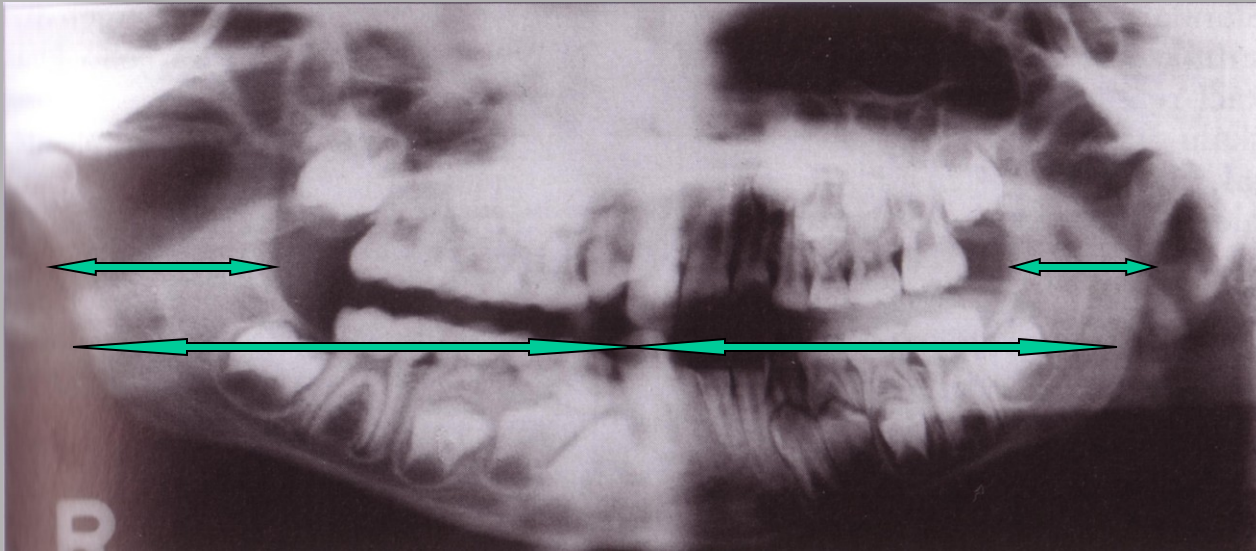
- deep breath and holded breath
- epipharynx is filled up with the air
 - incorrect exposure of lateral part of picture



Movement artefacts

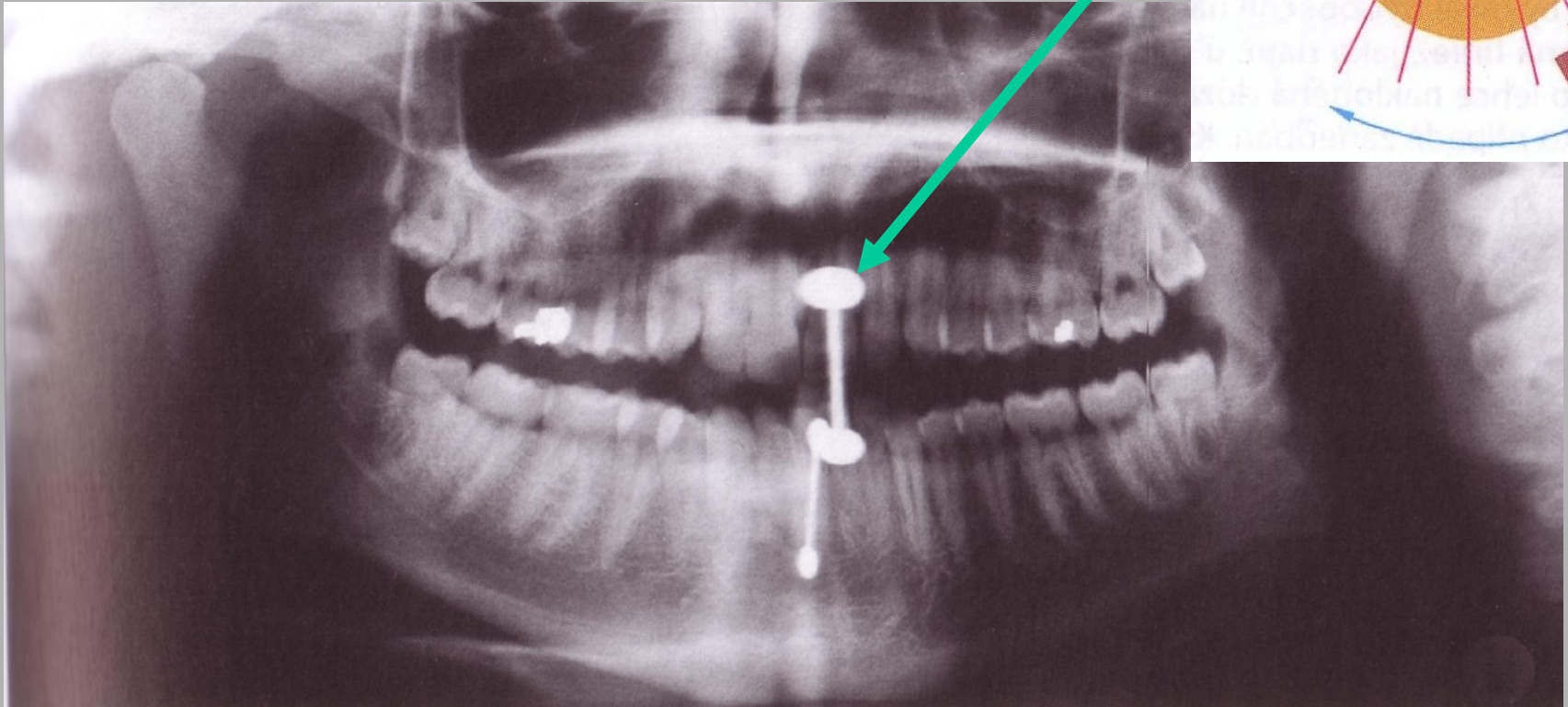
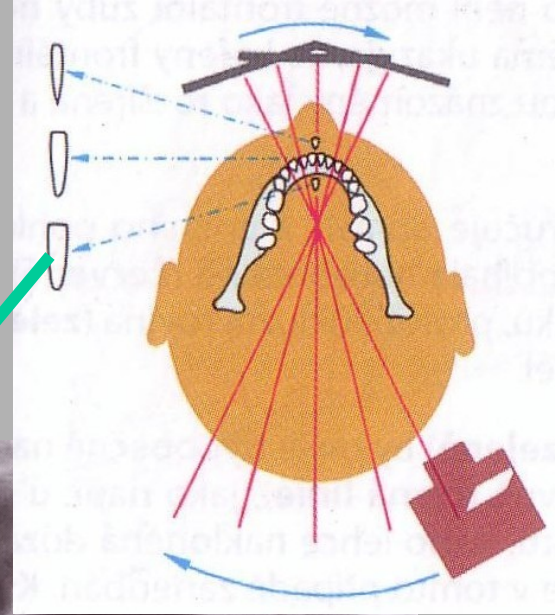


Asymmetry of exposure



Pictured layer

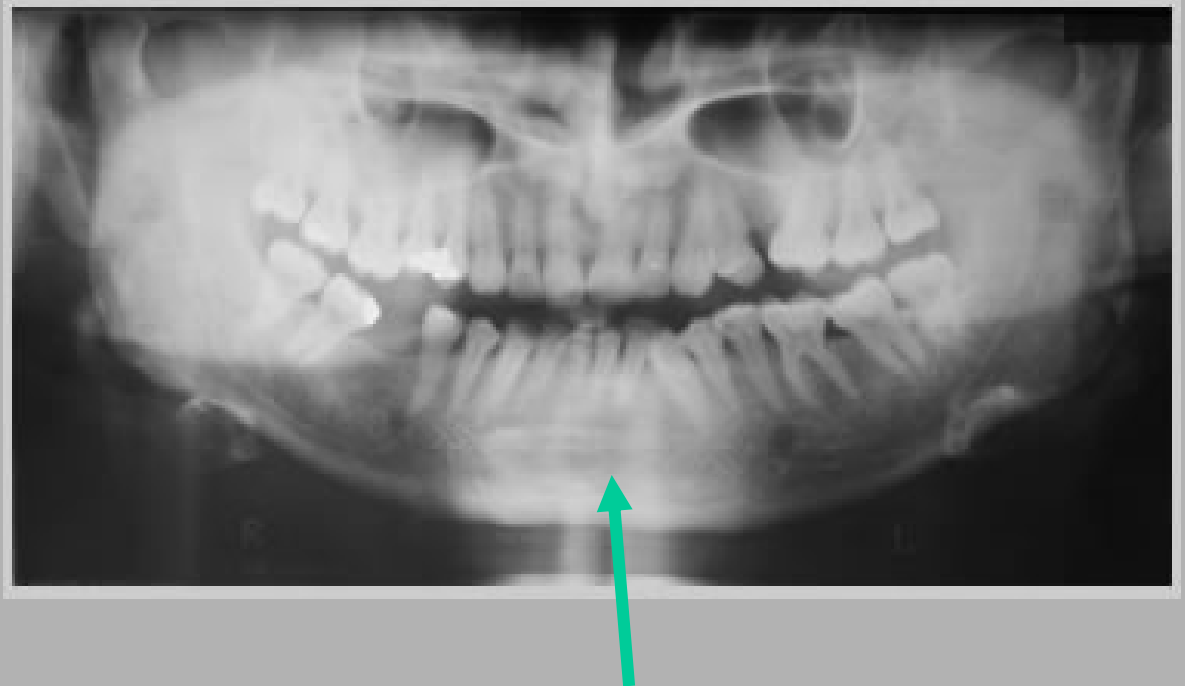
piercing - tongue



piercing - lip

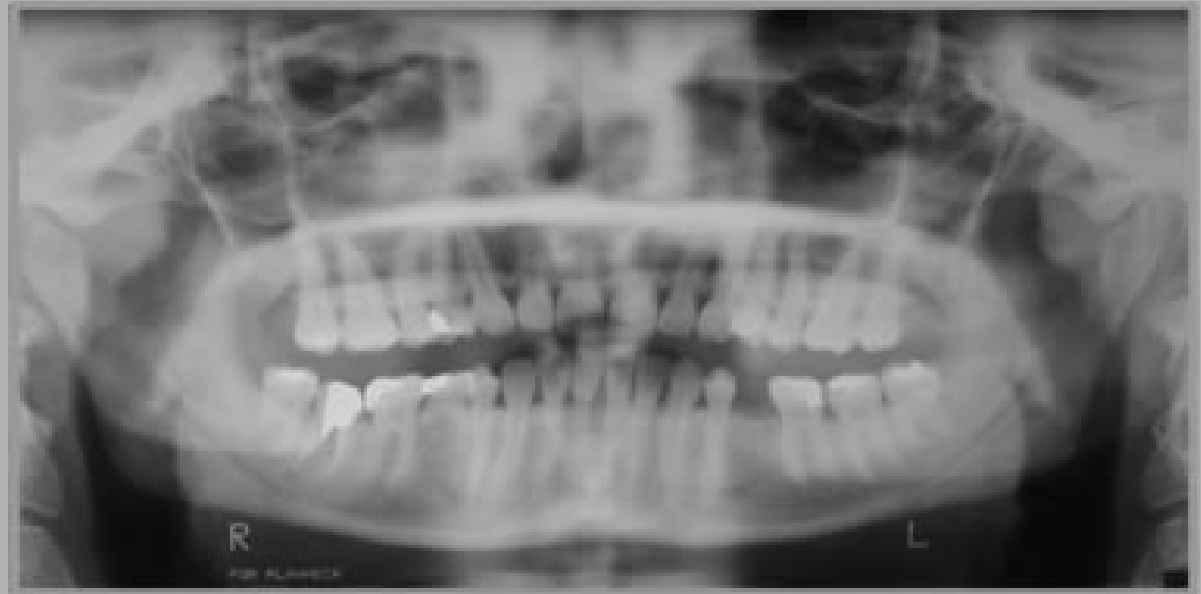Ortopanthomography - mistakes

- The head hang (down)
- the roots of caudal incisors are deviated of the plane
- out of focus



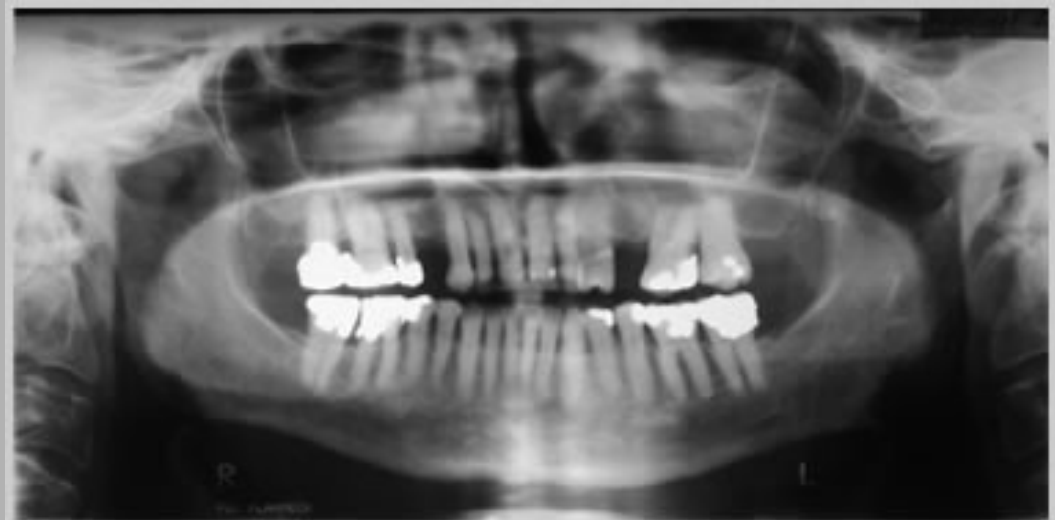Ortopanthomography - mistakes

- Tilting the head back
- the root of cranial incisors are deviated of the plane
- out of focus



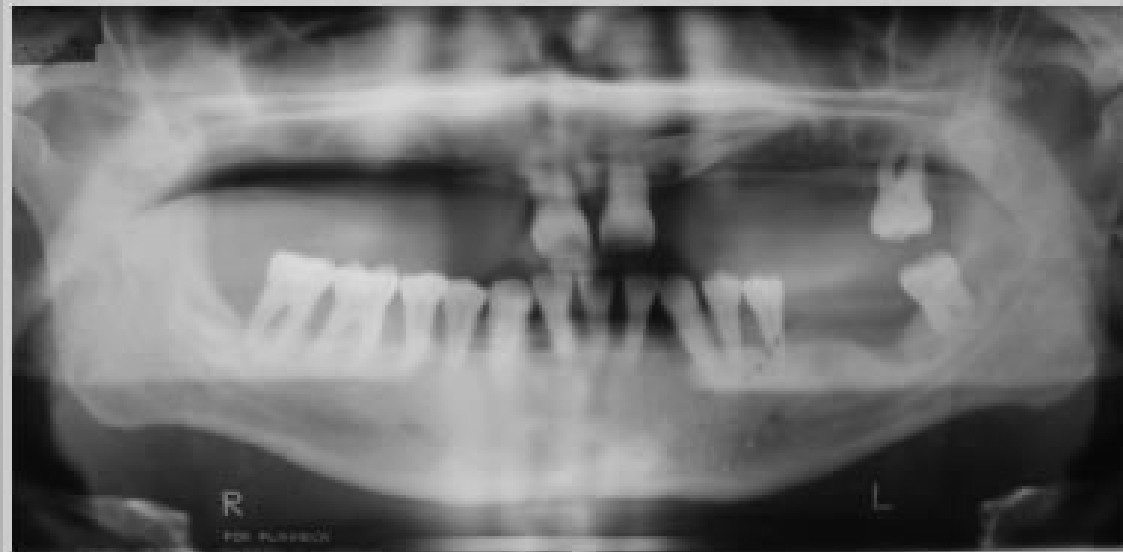Ortopanthomography - mistakes

- The head is too close to the film
- The teeth in both jaws
 - are smaller
 - out of focus
- The cervical vertebrae could summate with mandible arms



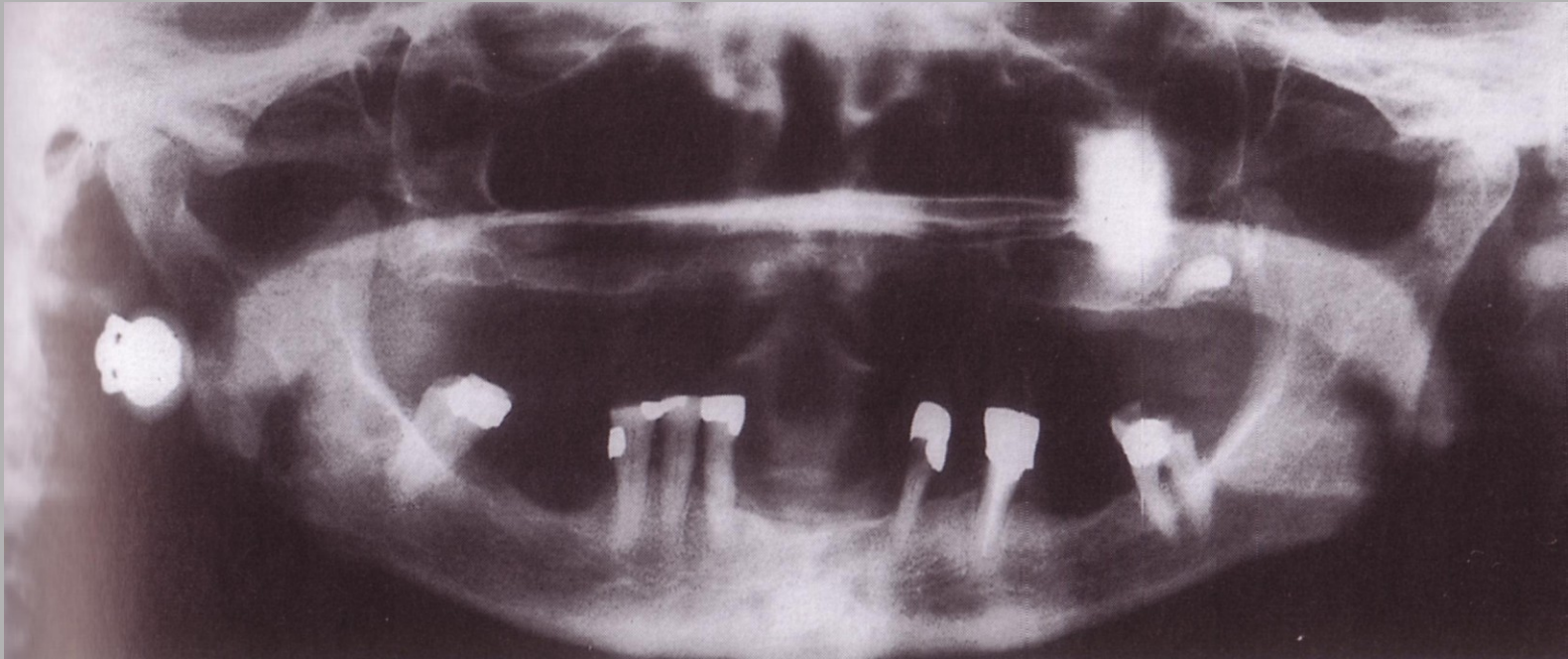
Ortopanthomography - mistakes

- The head is far from the film
- maxillar and manbidular teeth are
 - out of fucus
 - larger
- there are not mandible joints on the picture



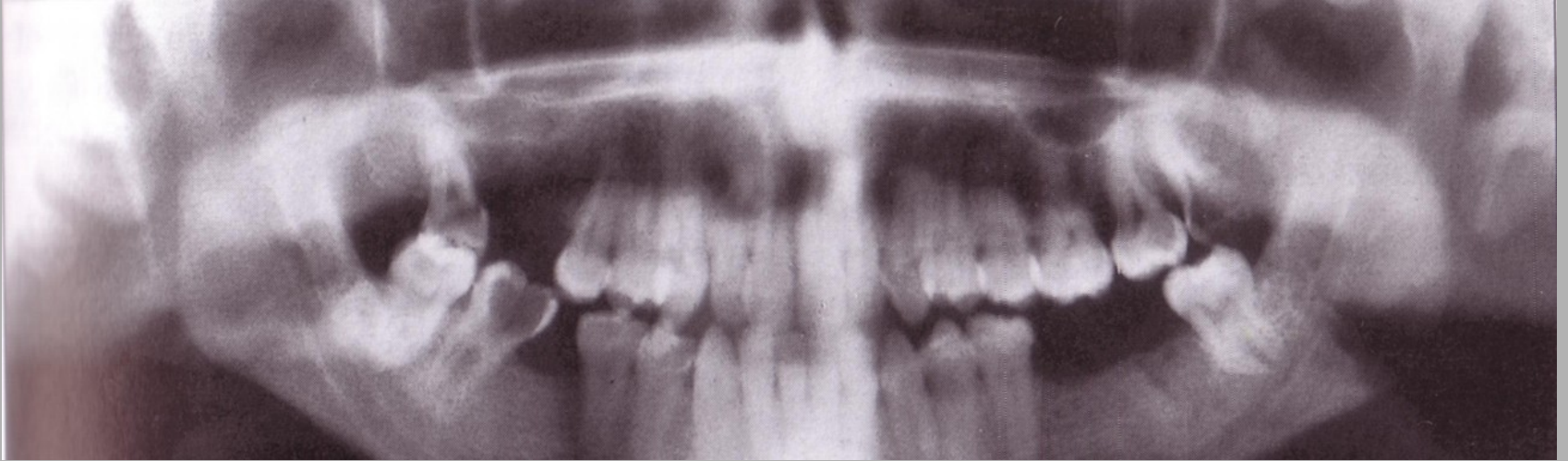Alien body - artefacts

- Ear rign on the right.
- Artefact in the area of the left tuber maxillae.

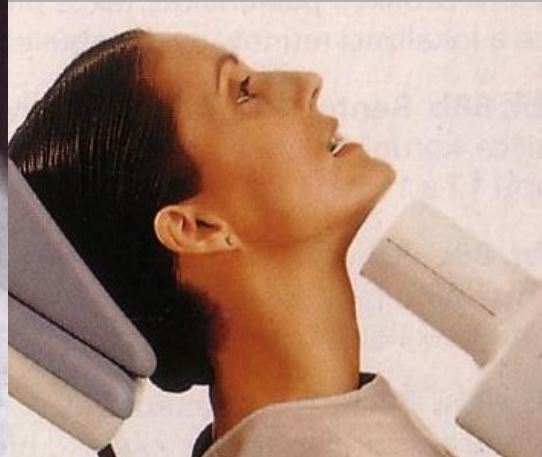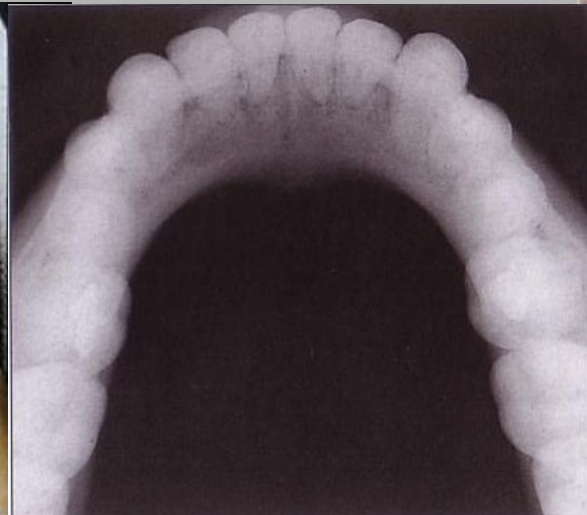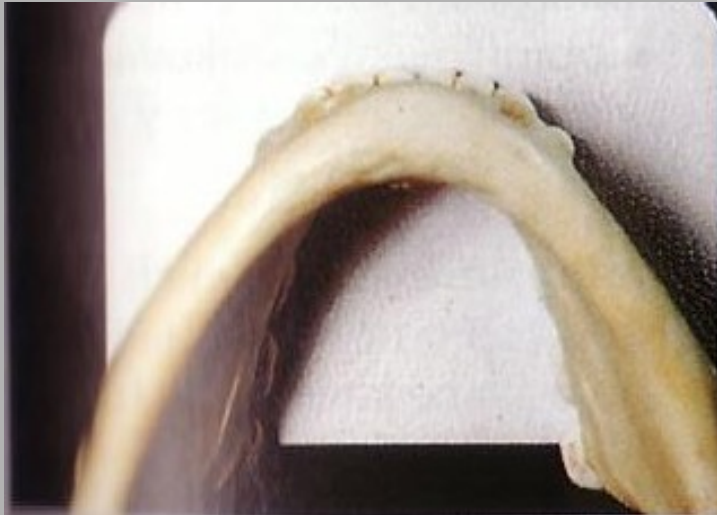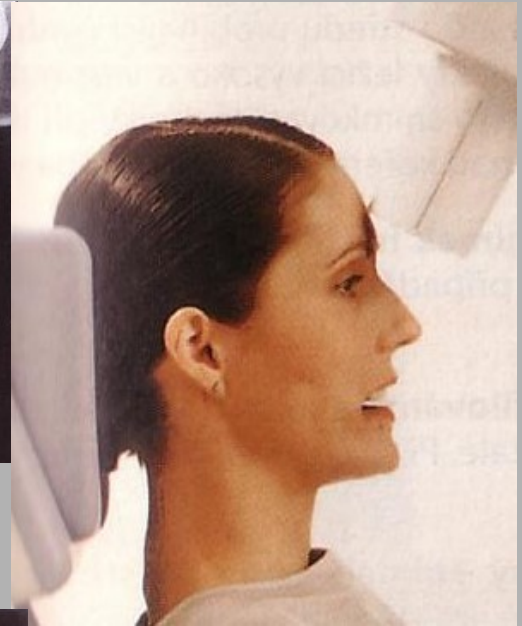
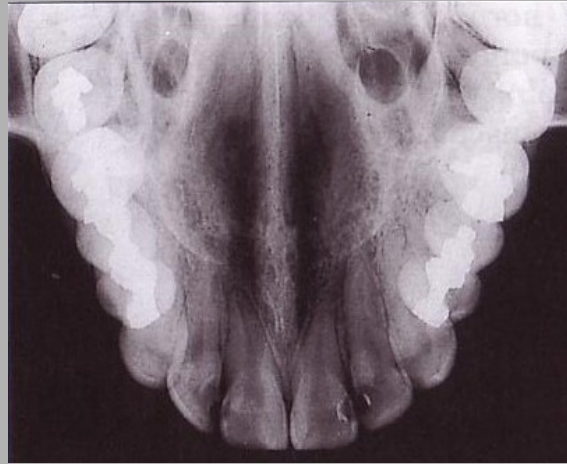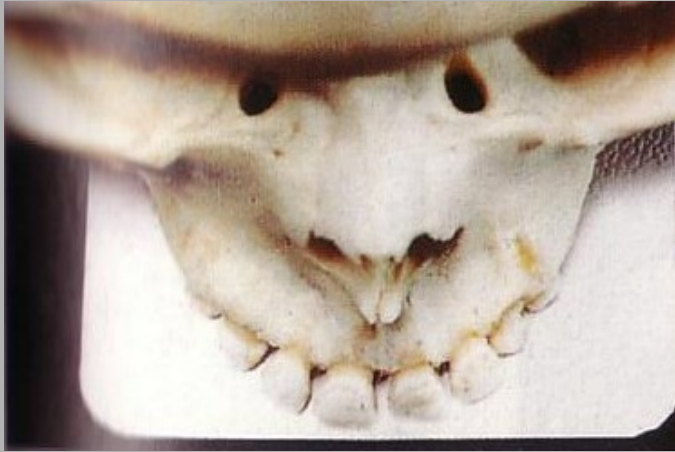


Alien bodies - artefacts

- Metal zips, buttons, glasses, carelessly attached protect collar
- = disturbing artefacts

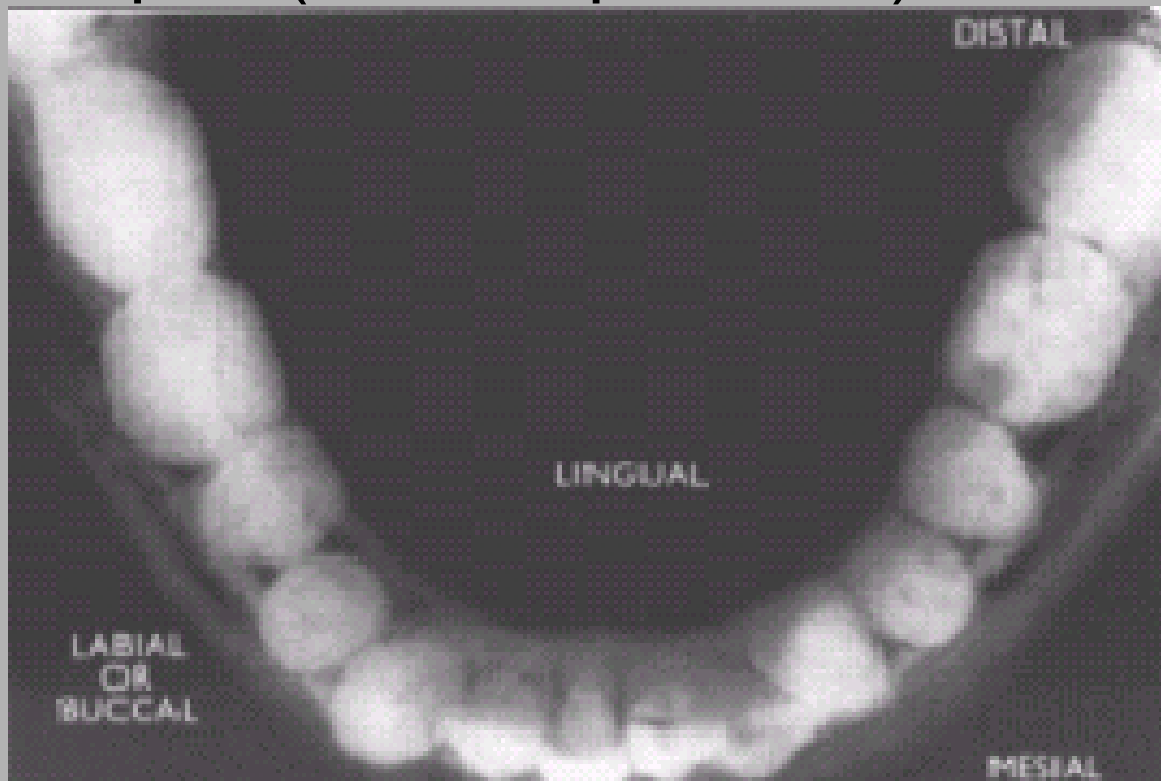

Occlusal exposure of upper and low jaw



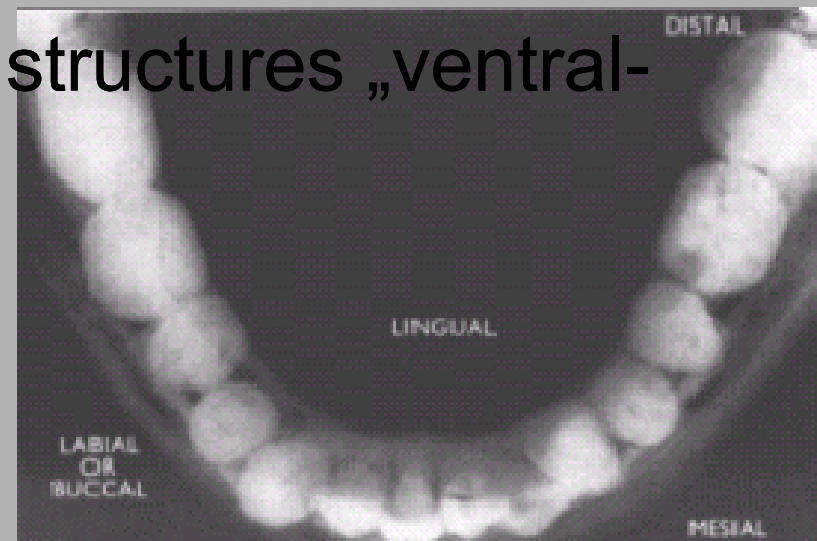
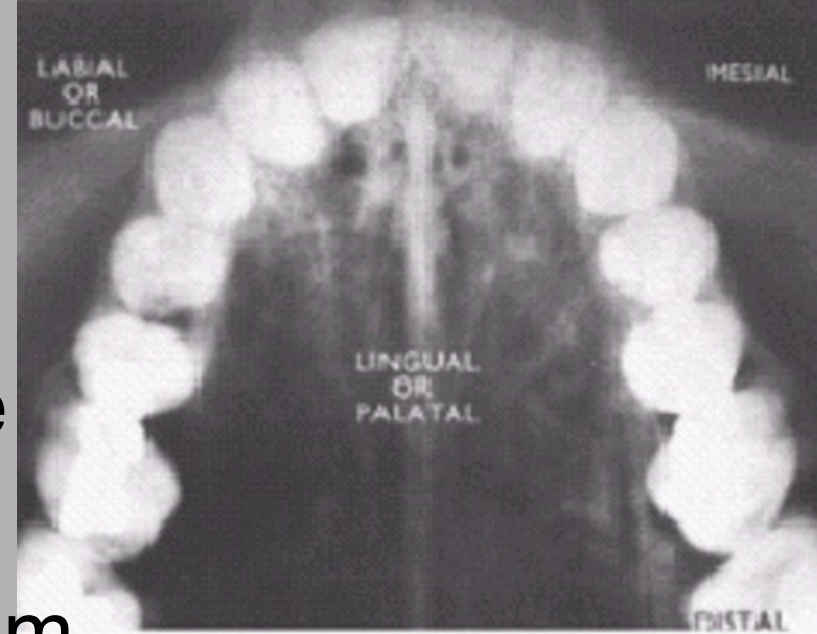
Teeth arch

- Parabole
 - frontal part (curved part of parabole)
 - distal part (arms of parabole)



Topography

- buccal – towards cheek
- lingual – towards tongue
- labial – towards lip
- palatal – towards palatum
- distal
- mesial
 - label the ventral located structures „ventral-medial“

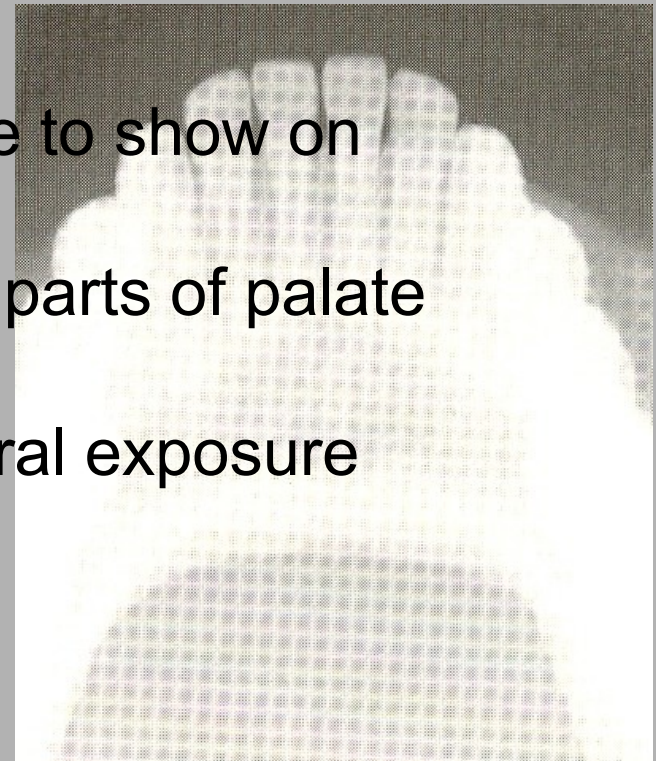
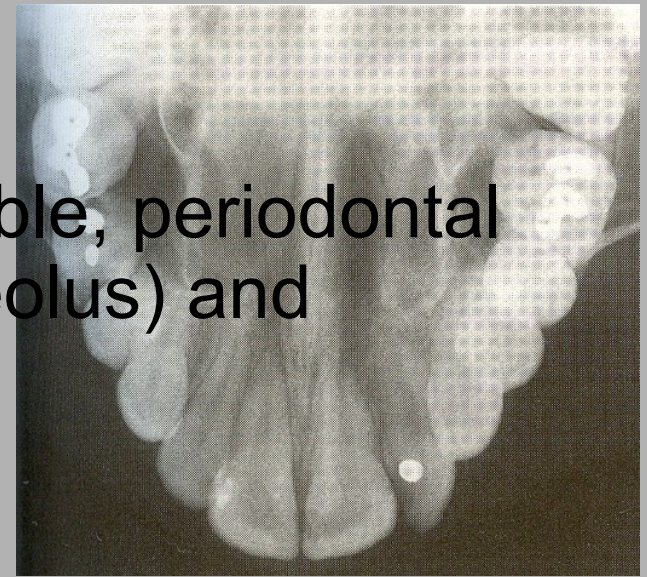


Occlusal exposures

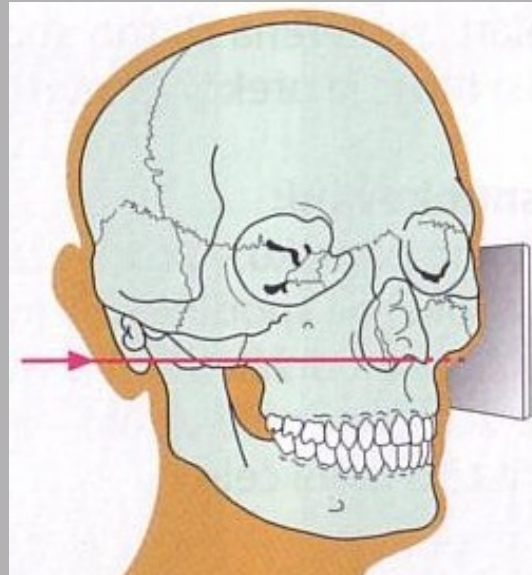
Pictures of maxillary arch, mandible, periodontal ligaments, tooth sockets (alveolus) and adjacent bone

Indications:

- teeth development monitoring
- redundant teeth
- pathology which is not possible to show on intraoral exposures
- contours of buccal and lingual parts of palate skeleton
- no possibility to perform intraoral exposure
 - limitation of mouth opening
 - no cooperation (children)

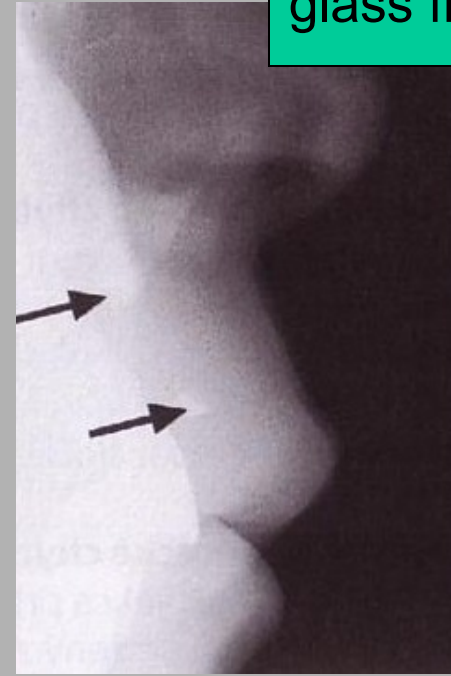


Extraoral lateral exposure of frontal upper frontal part



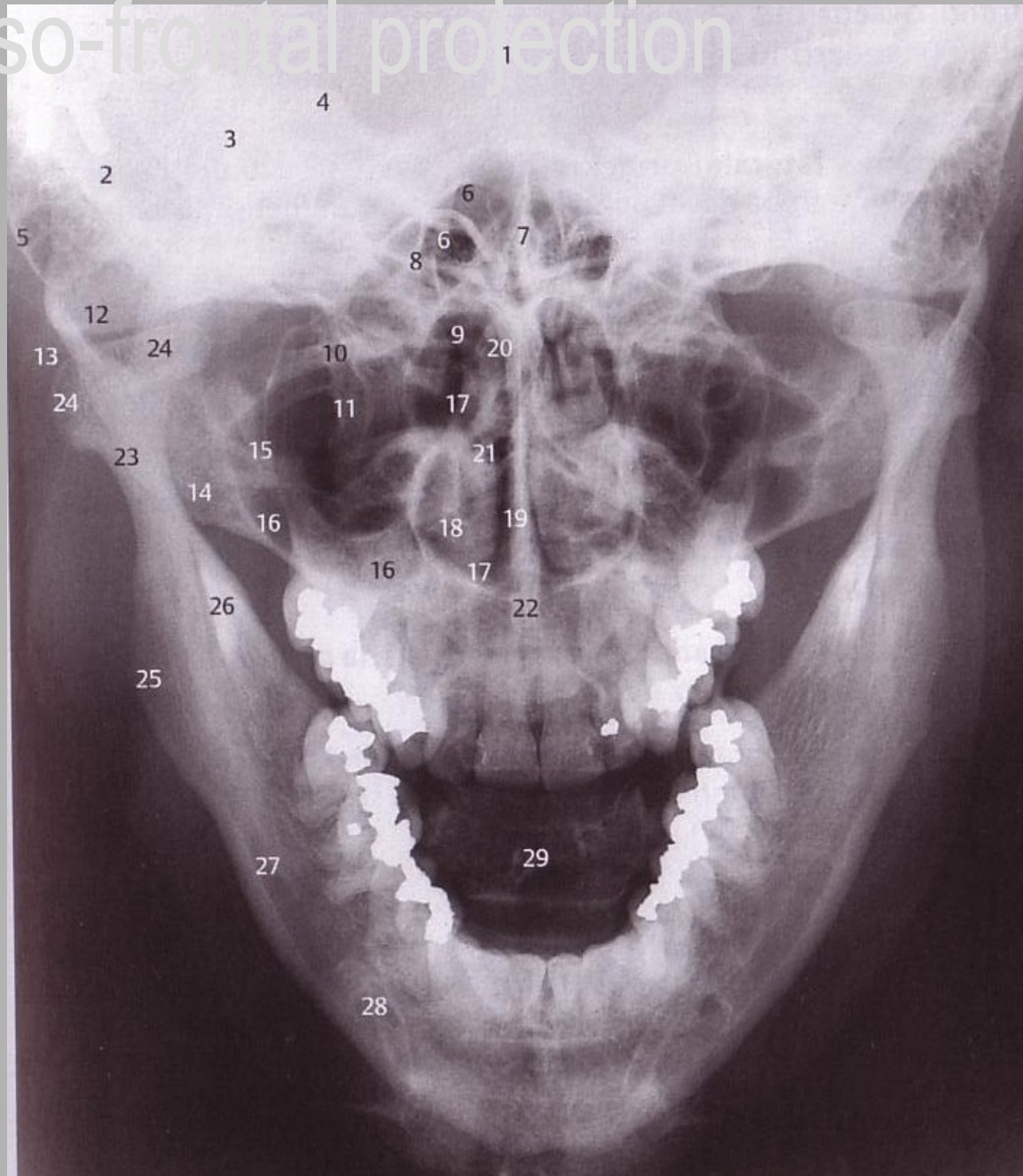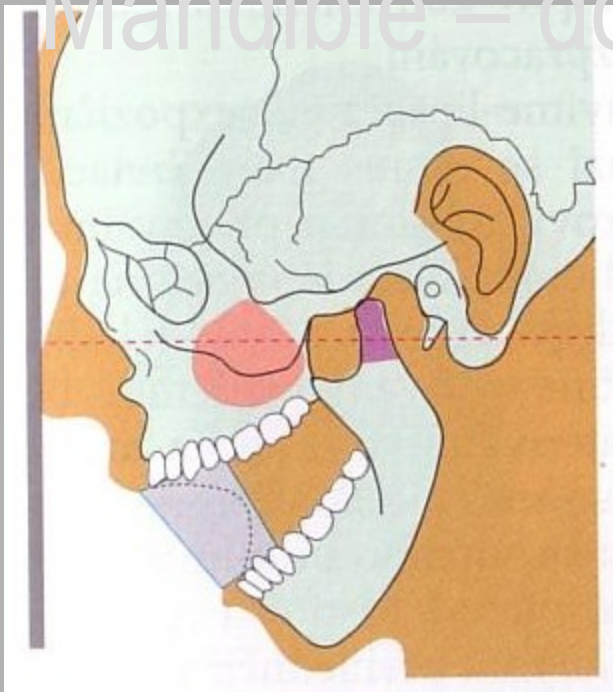
spina nasalis anterior perpendicular to film

glass fragments

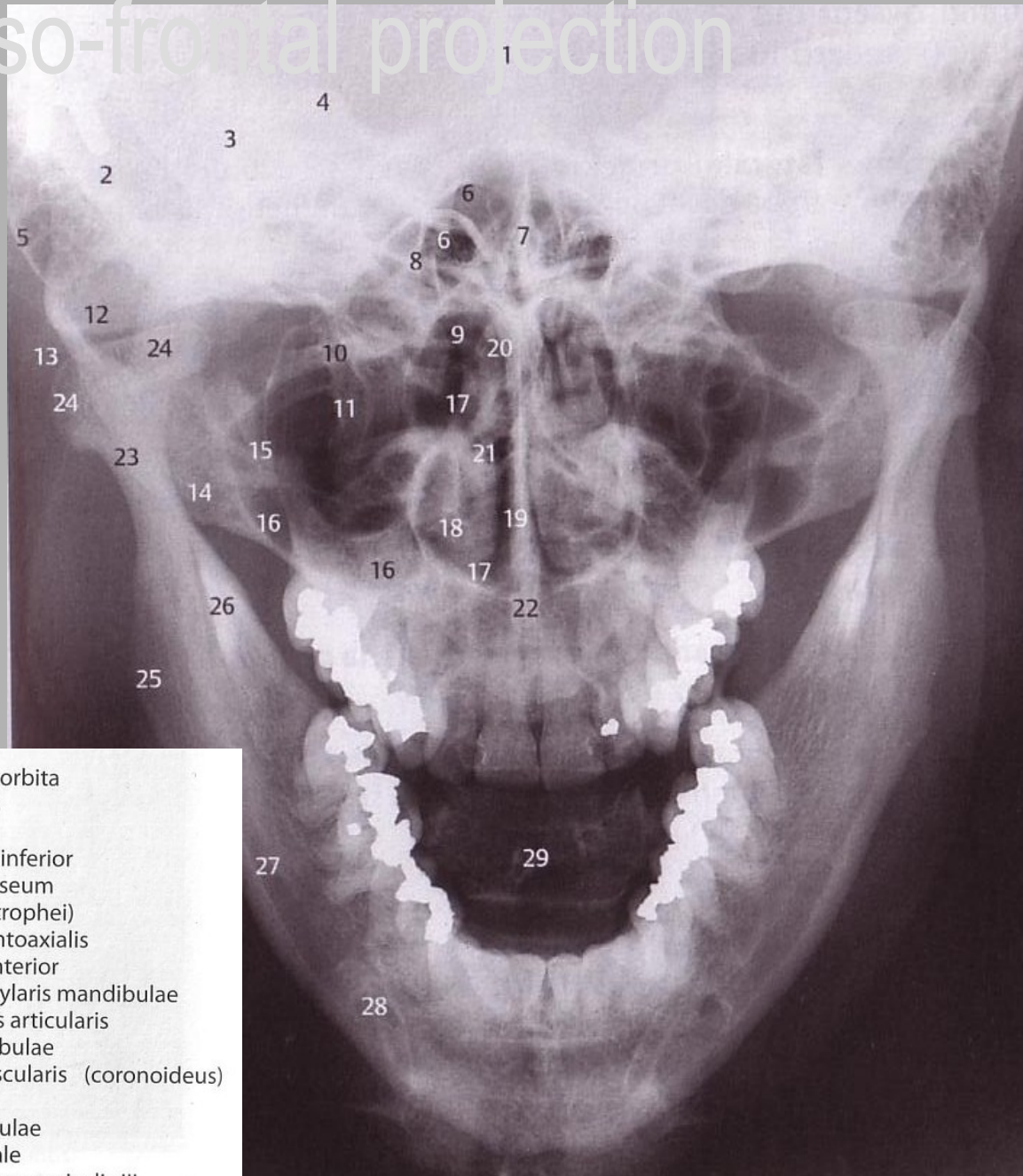
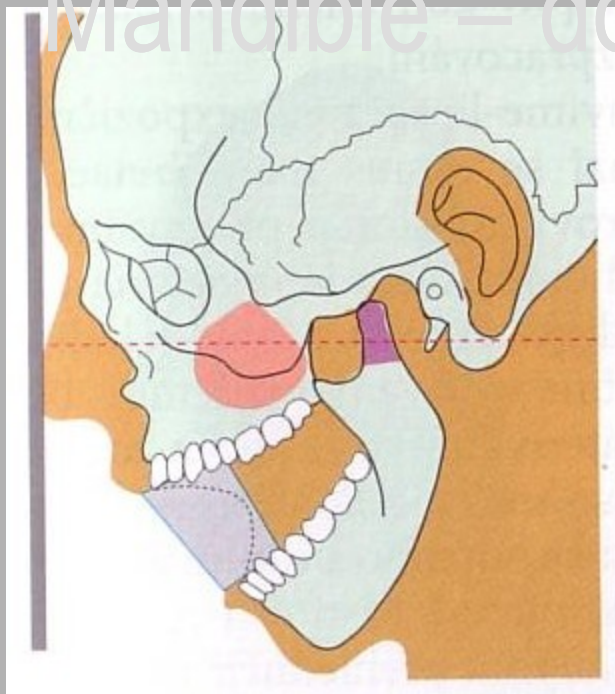


- depiction of nasal bones
- alien particles

Mandible – dorso-frontal projection

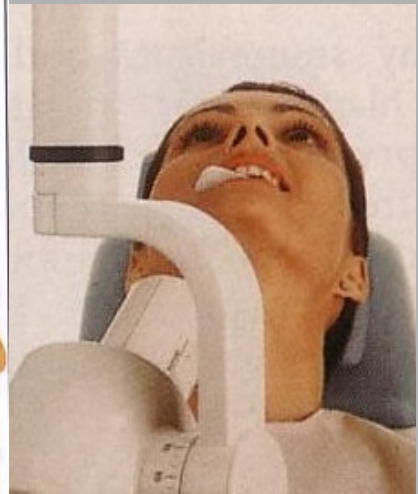
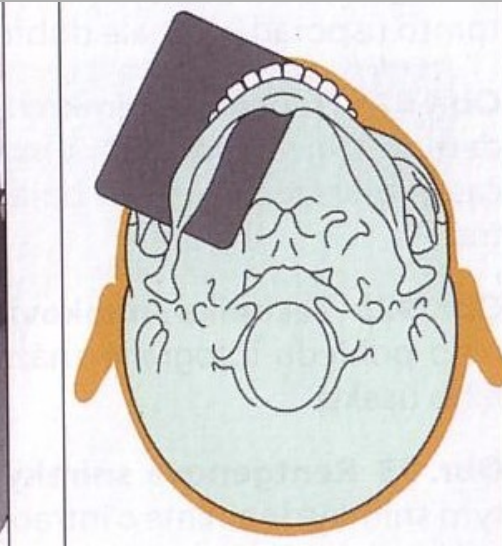
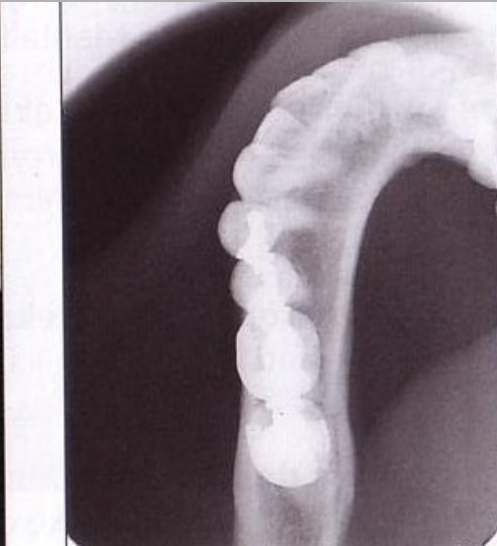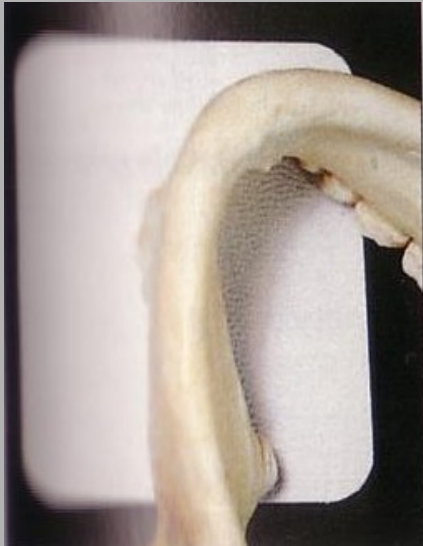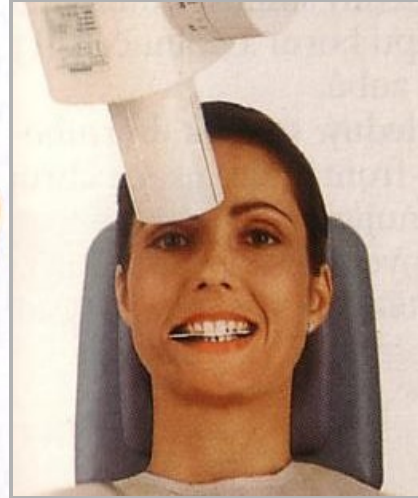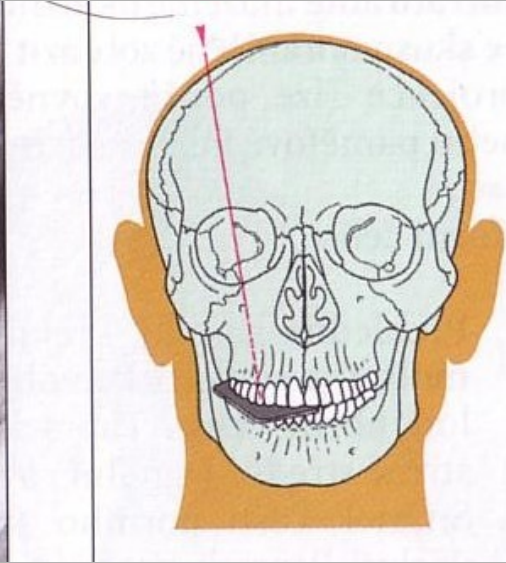
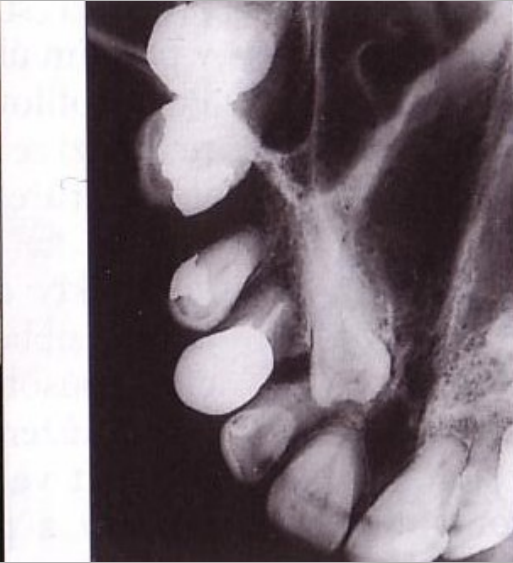
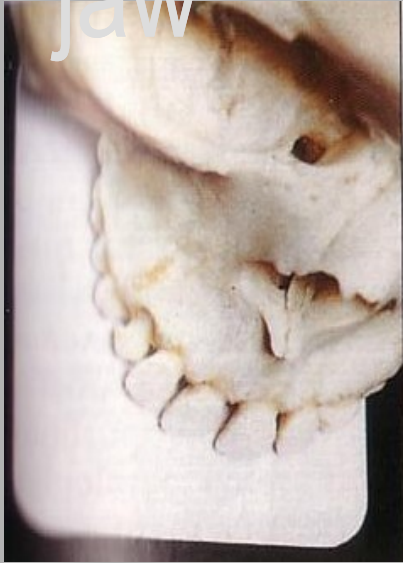


Mandible – dorso-frontal projection

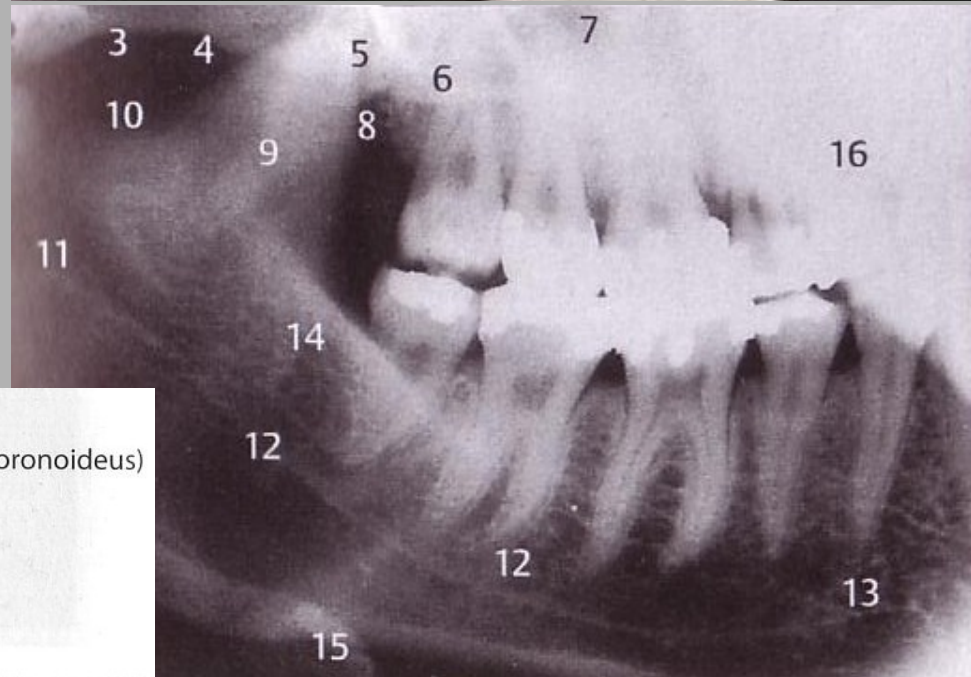
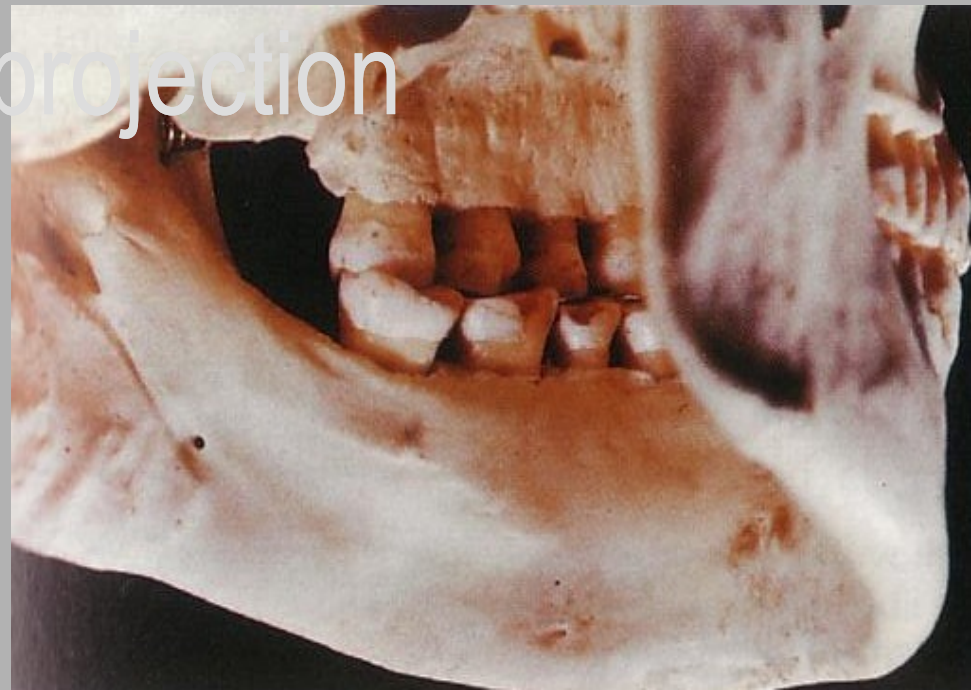

- | | | | |
|----|--|----|---|
| 1 | Crista frontalis | 15 | Margo inferior, orbita |
| 2 | Squama ossis temporalis | 16 | Sinus maxillaris |
| 3 | Pars petrosa ossis temporalis | 17 | Cavum nasi |
| 4 | Eminentia arcuata | 18 | Concha nasalis inferior |
| 5 | Processus mastoideus ossis temporalis | 19 | Septum nasi osseum |
| 6 | Sinus sphenoidalis v superpozici s částí sinus frontalis | 20 | Dens axis (epistrophei) |
| 7 | Crista galli | 21 | Articulatio atlantoaxialis |
| 8 | Planum sphenoidale | 22 | Spina nasalis anterior |
| 9 | Articulatio atlantooccipitalis | 23 | Processus condylaris mandibulae |
| 10 | Processus transversum atlantis | 24 | Kondylus, facies articularis |
| 11 | Processus pterygoideus ossis sphenoidalis | 25 | Angulus mandibulae |
| 12 | Eminentia articularis | 26 | Processus muscularis (coronoideus) mandibulae |
| 13 | Arcus zygomaticus | 27 | Canalis mandibulae |
| 14 | Os zygomaticum | 28 | Foramen mentale |
| | | 29 | Corpus vertebrae cervicalis III |

Semiprofile exposures of upper and low jaw

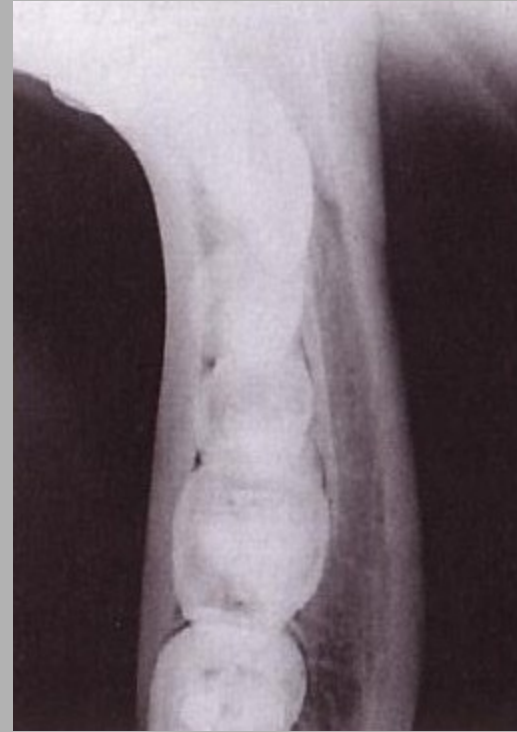
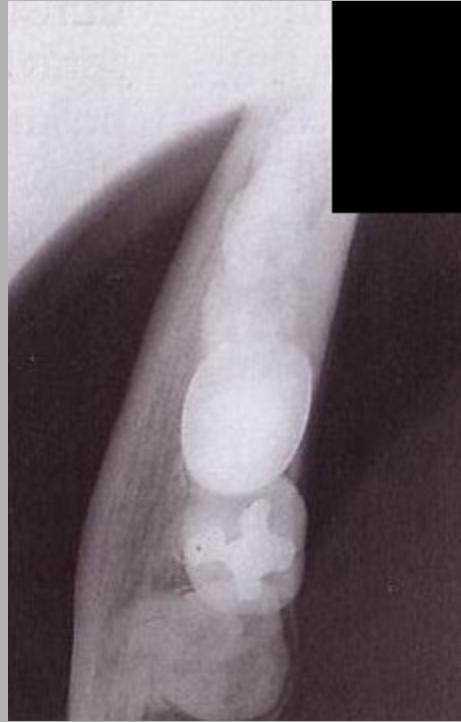
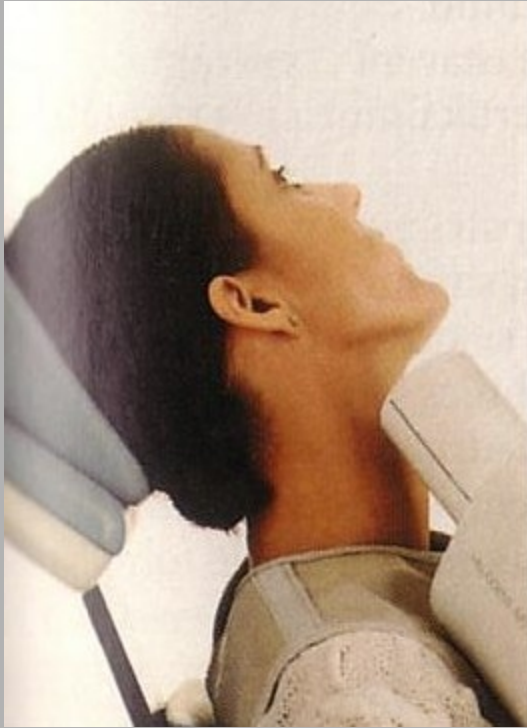Mandible – lateral projection



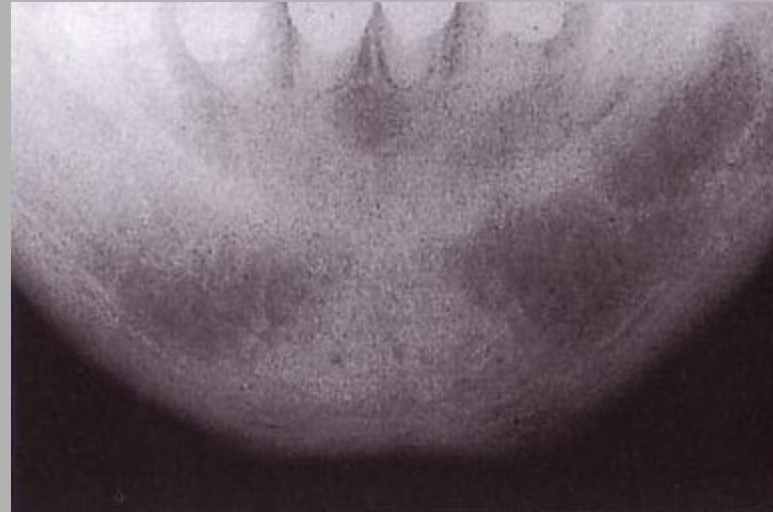
- | | | | |
|---|---|----|------------------------------------|
| 1 | Kondylus | 9 | Processus muscularis (coronoideus) |
| 2 | Eminentia articularis | 10 | Incisura semilunaris |
| 3 | Arcus zygomaticus | 11 | Lingula |
| 4 | Sutura zygomaticoalveolaris | 12 | Canalis mandibulae |
| 5 | Processus pterygoideus ossis sphenoidalis | 13 | Foramen mentale |
| 6 | Os zygomaticum | 14 | Crista temporalis |
| 7 | Sinus maxillaris | 15 | Os hyoideum |
| 8 | Tuber maxillae | 16 | Angulus mandibulae (blíže ohnisku) |

Caudal wisdom tooth



- The head is tilted on healthy side and back
- The x-ray beam passes through the wisdom tooth towards cranio-ventral oriented film cassette which is on the reverse side

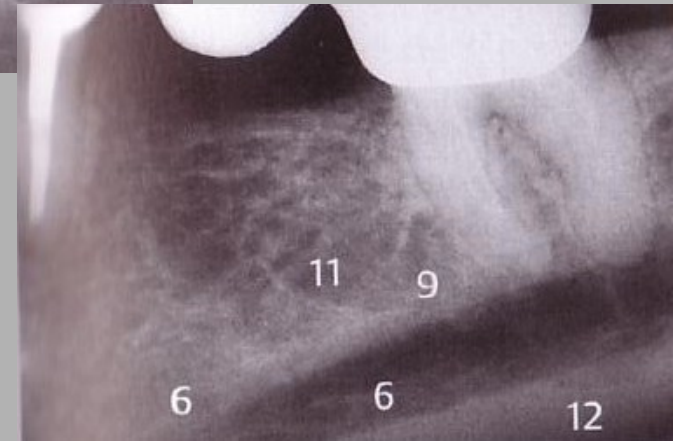
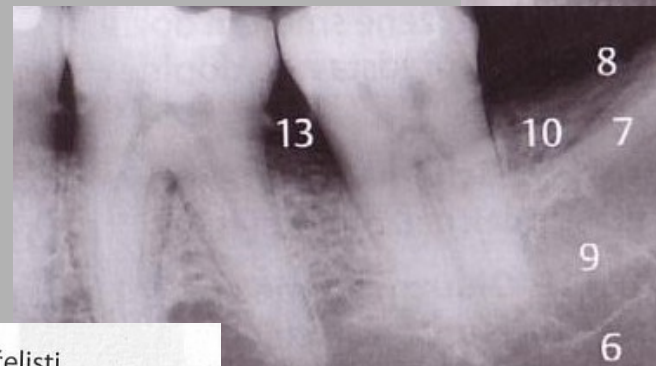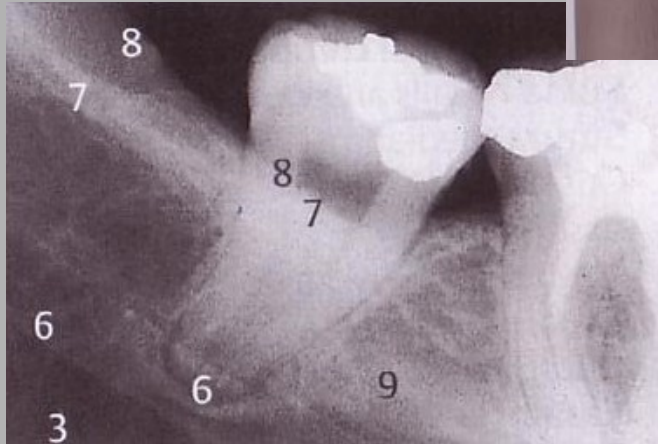
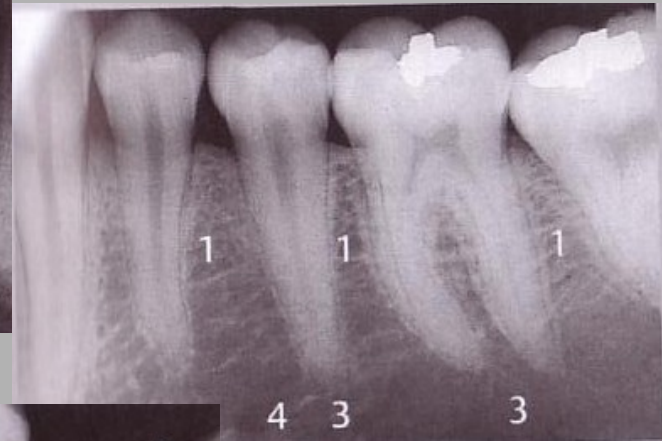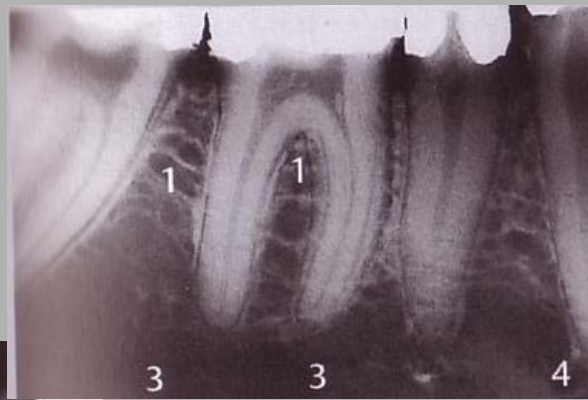
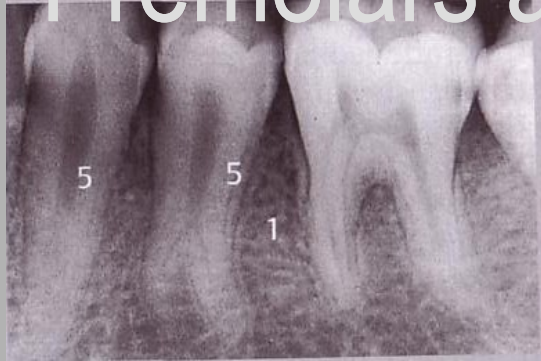
Chin exposure



- horizontal placed film
- imaging toothless chin

Premolars a molars

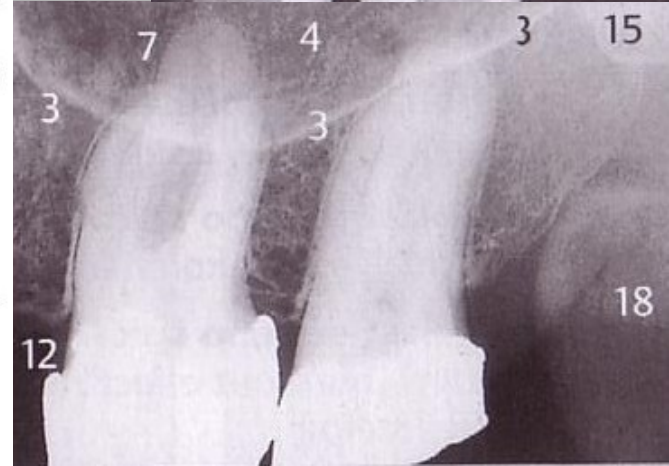
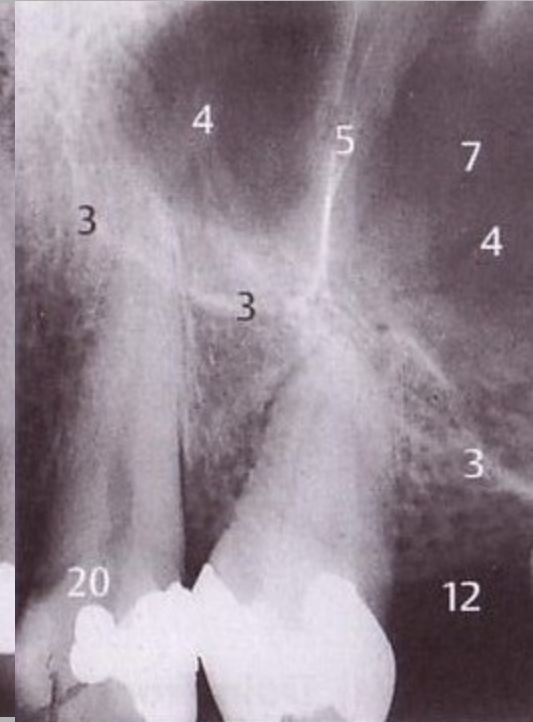
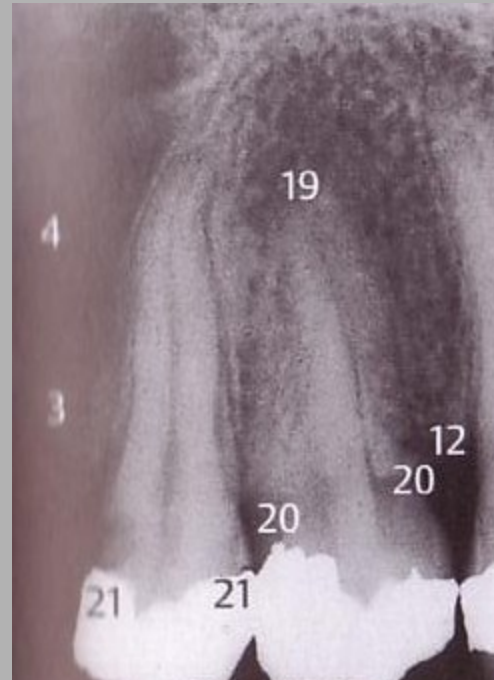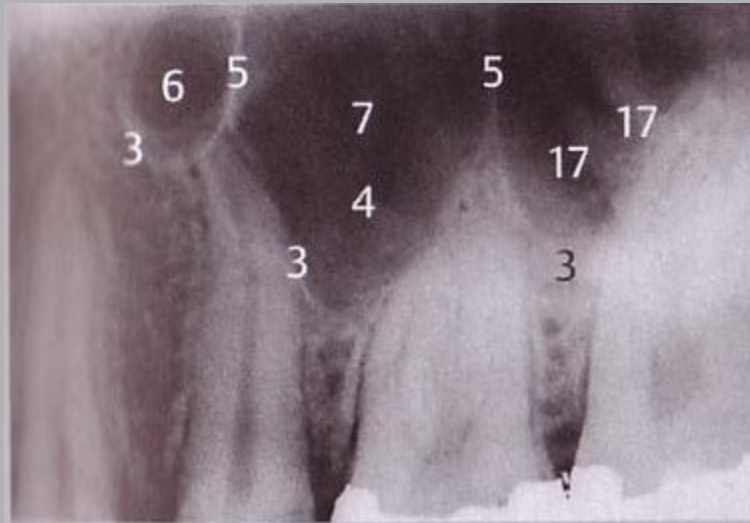Anatomy



- 1 Typická trámčitá struktura alveolárního výběžku dolní čelisti
- 2 Projasnění – subtrakční efekt fovea submandibularis
- 3 Typická trámčina corpus mandibulae
- 4 Foramen mentale
- 5 Taurodontizmus
- 6 Canalis mandibulae
- 7 Linea obliqua interna (pokračování crista temporalis ramus mandibulae)
- 8 Linea obliqua externa (margo anterior ramus mandibulae)
- 9 Linea mylohyoidea
- 10 Trigonum retromolare (crus mediale a crus laterale)
- 11 Ohraničená struktura kosti po extrakci
- 12 Bazální kompakta dolní čelisti
- 13 Aproximální nánosy zubního kamene

Molars, premolars, area of the tuber

Anatomy

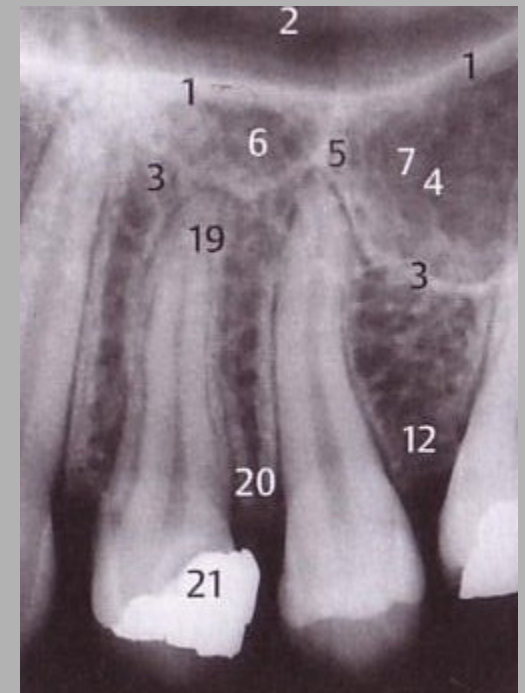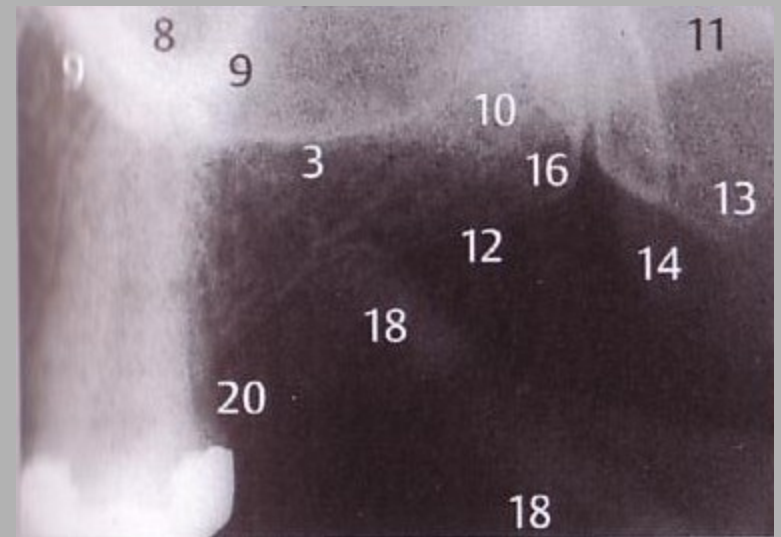
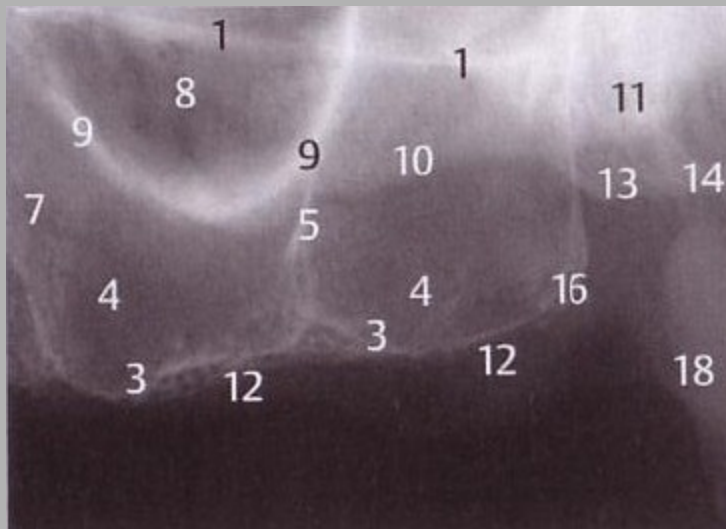


- 1 Laterobazální ohraničení nosní dutiny
- 2 Spodina nosní dutiny
- 3 Laterobazální ohraničení čelistní dutiny
- 4 Spodina (dno) čelistní dutiny
- 5 Septum sinuum
- 6 Anteriorní výběžek čelistní dutiny
- 7 Alveolární výběžek čelistní dutiny
- 8 Recessus zygomaticus čelistní dutiny
- 9 Processus zygomaticus čelistní dutiny
- 10 Corpus ossis zygomatici
- 11 Arcus zygomaticus
- 12 Alveolární hřeben

- 13 Lamina lateralis processus pterygoideus
- 14 Hamulus laminae medialis processus pterygoideus
- 15 Processus pyramidalis ossis palatini
- 16 Tuber maxillae
- 17 Sutura zygomaticomaxillaris
- 18 Processus coronoideus (muscularis)
- 19 Hroty kořenů 1. horního premoláru, delší kořen je palatinální
- 20 „Burn-out effect“
- 21 Sekundární kaz

Molars, premolars, area of the tuber

Anatomy



- 1 Laterobazální ohraničení nosní dutiny
- 2 Spodina nosní dutiny
- 3 Laterobazální ohraničení čelistní dutiny
- 4 Spodina (dno) čelistní dutiny
- 5 Septum sinuum
- 6 Anteriorní výběžek čelistní dutiny
- 7 Alveolární výběžek čelistní dutiny
- 8 Recessus zygomaticus čelistní dutiny
- 9 Processus zygomaticus čelistní dutiny
- 10 Corpus ossis zygomatici
- 11 Arcus zygomaticus
- 12 Alveolární hřeben

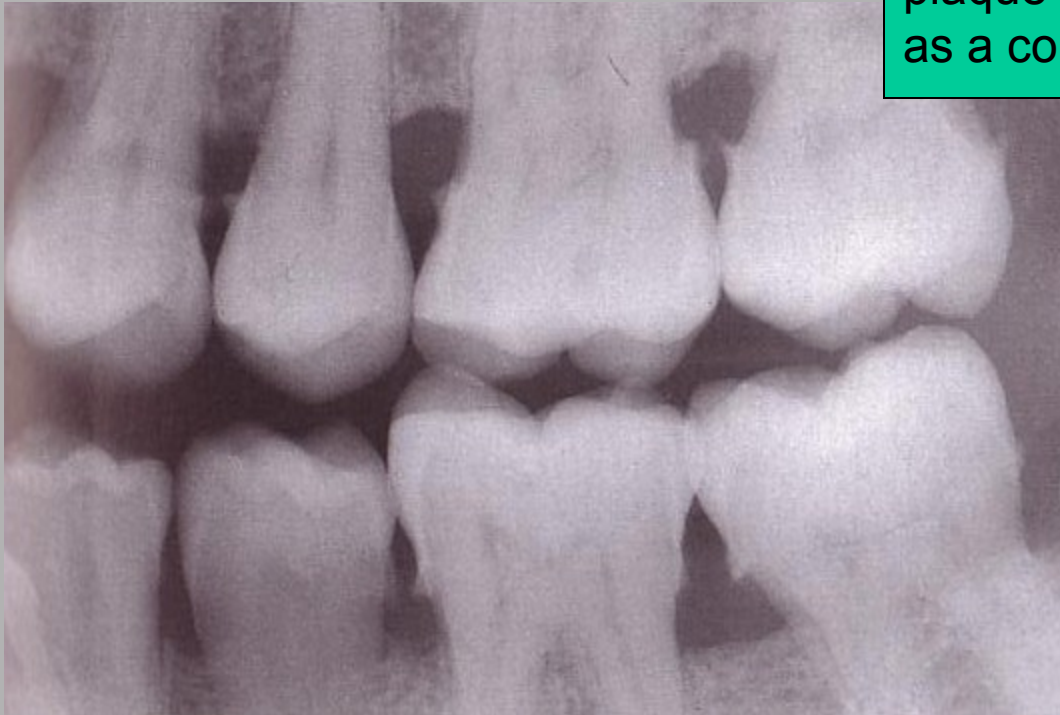- 13 Lamina lateralis processus pterygoideus
- 14 Hamulus laminae medialis processus pterygoideus
- 15 Processus pyramidalis ossis palatini
- 16 Tuber maxillae
- 17 Sutura zygomaticomaxillaris
- 18 Processus coronoideus (muscularis)
- 19 Hroty kořenů 1. horního premoláru, delší kořen je palatinální
- 20 „Burn-out effect“
- 21 Sekundární kaz

Literature

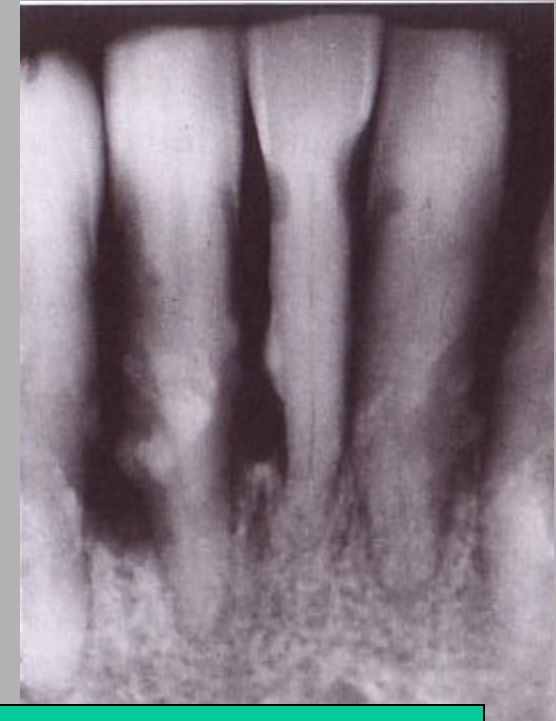
- Pasler F.A., Visser H.: Stomatologická radiologie. Kapesní atlas. 2007. ISBN 978-80-247-1307-6.
- http://rtg.misto.cz/_MAIL_/index.html

Tartar

tartar is composed of mineralized tooth plaque + generalized bone reduction as a consequence of parodont pathology



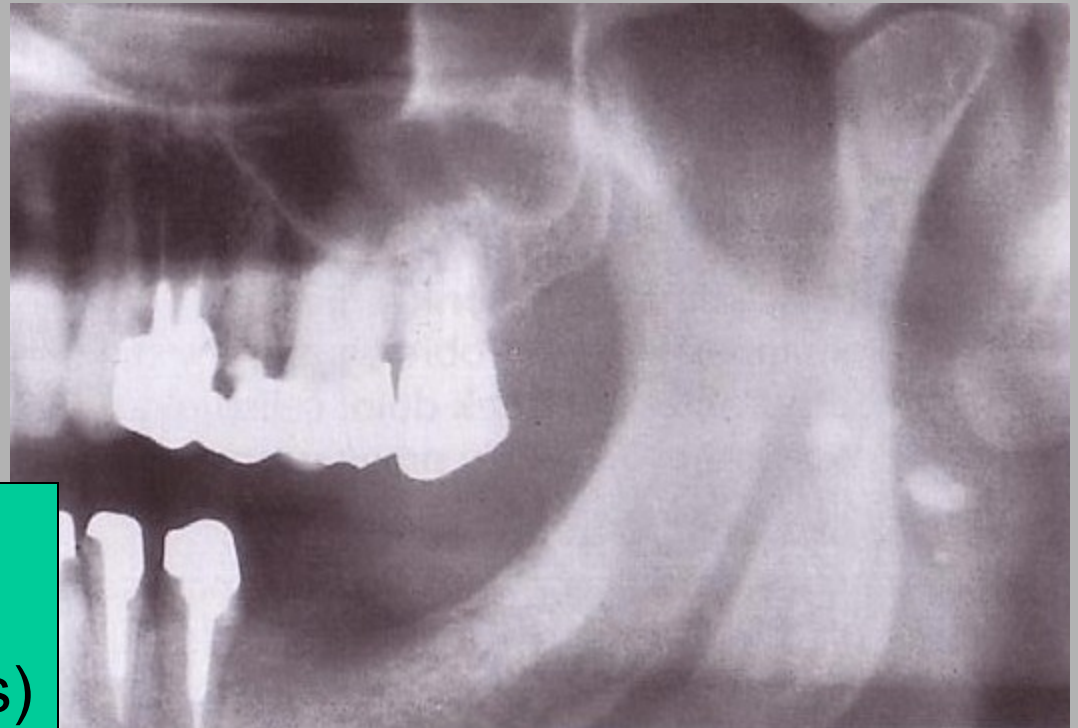
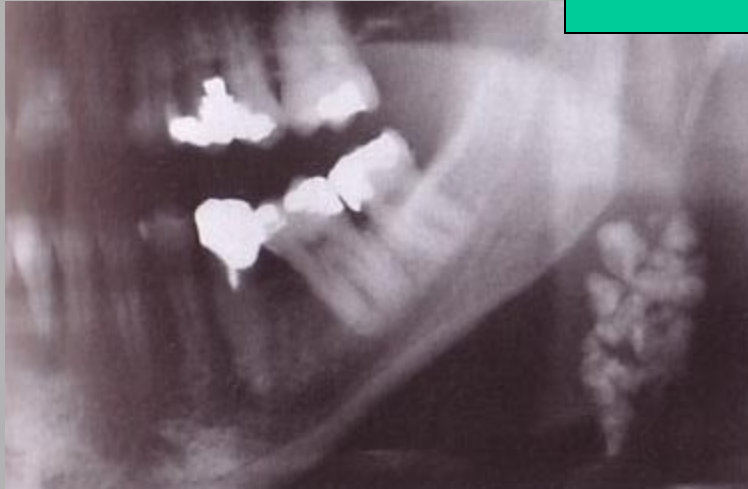- origins in area of outfall of main salivary glands
- calcium phosphate
 - x-ray opacity



parodontitis marg. profunda
sublingual tartar

Concrements

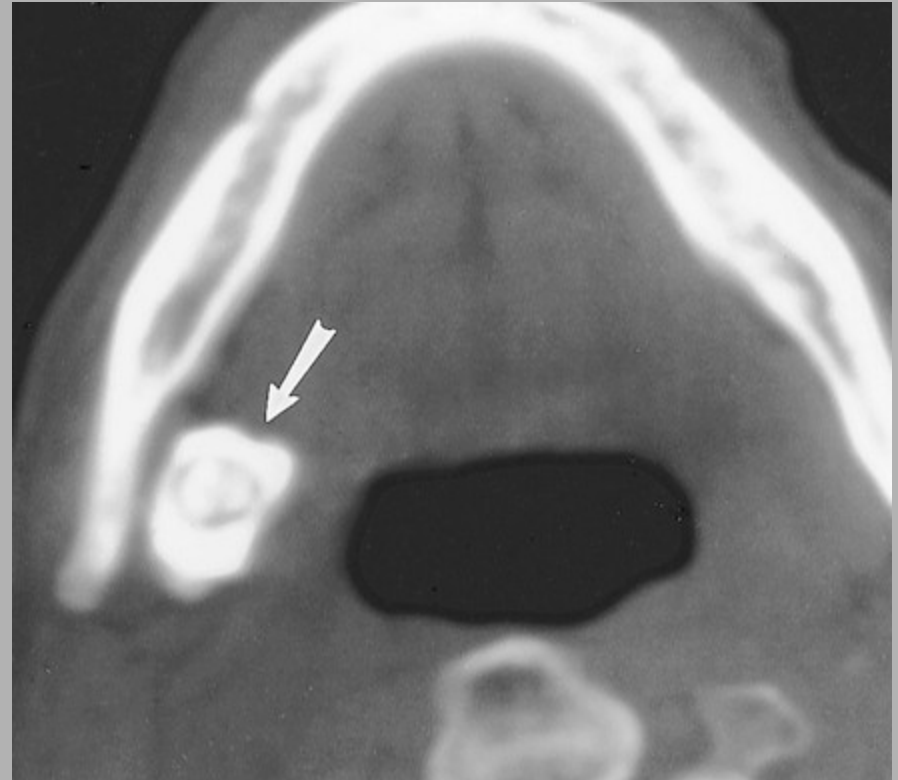calcified cervical lymph. nodes



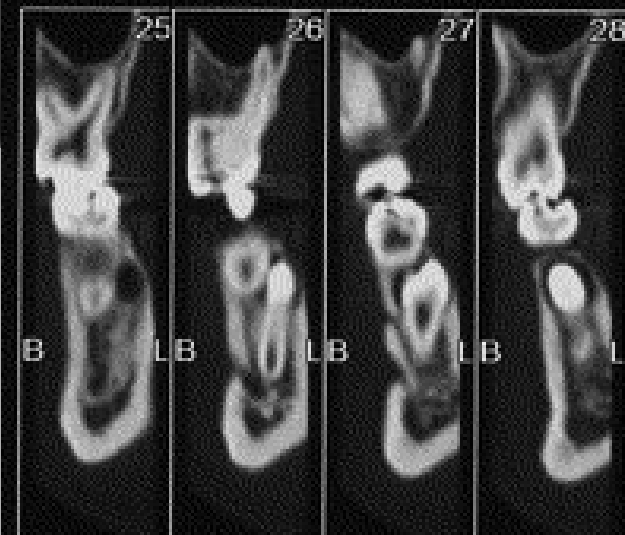
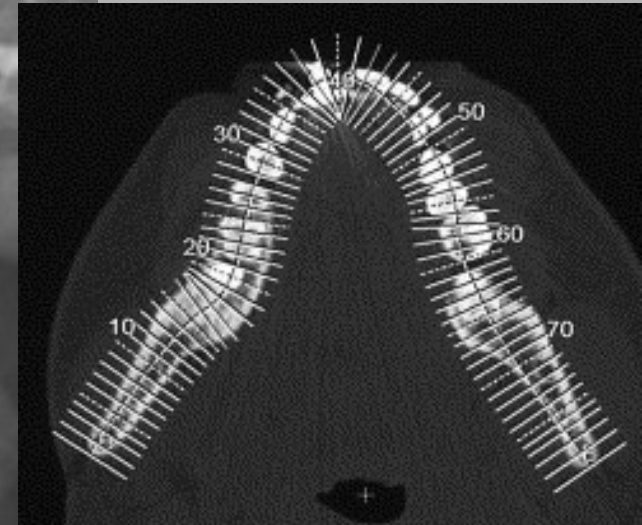
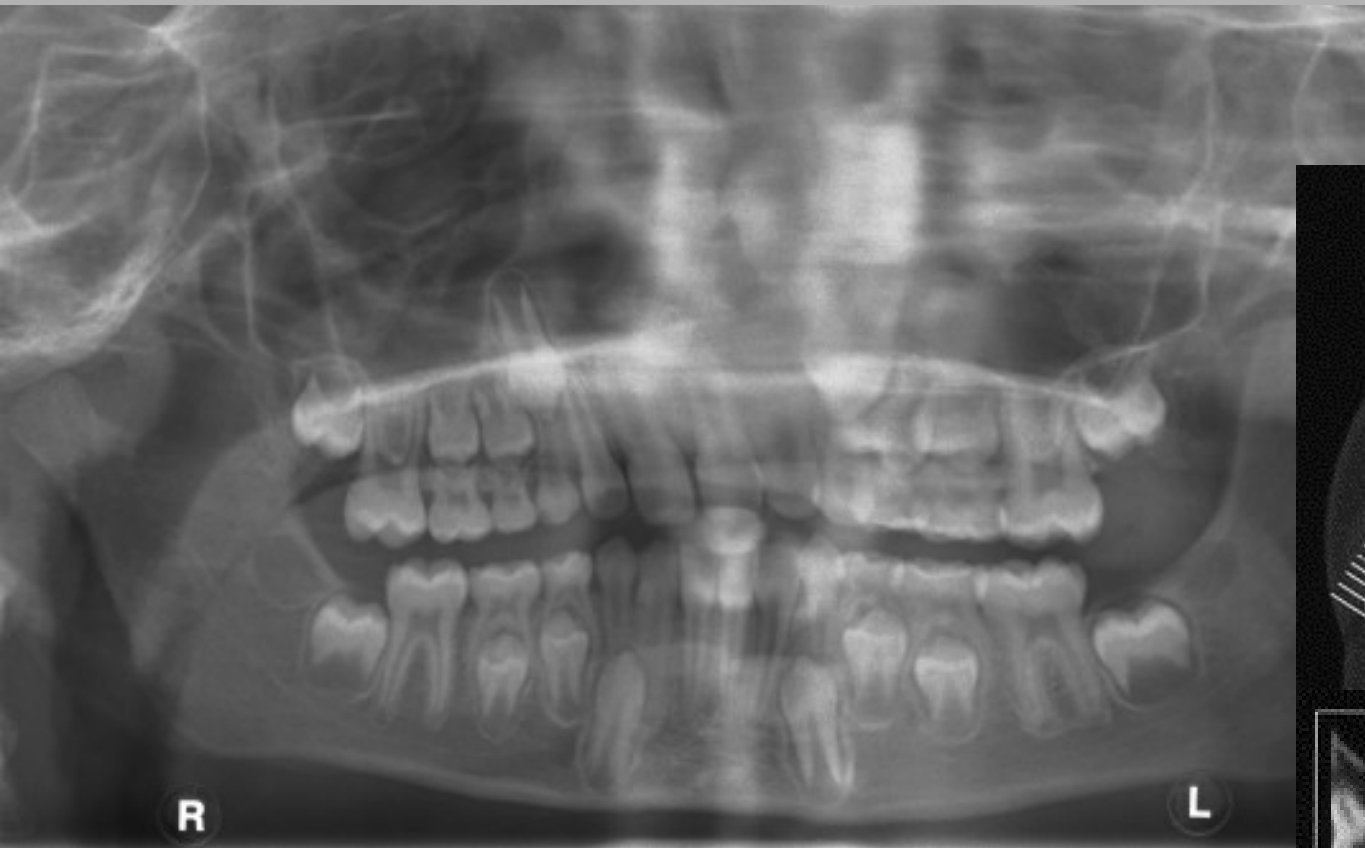calcification of gl. parotis
as a consequence of
parotitis epidemica (mumps)

Glandula parotis calcification

- Transverse CT scan of ductal and glandular calcifications
- Large solitary sialolith (arrow) in the right submandibular duct
- These glandular calcifications (arrows) could easily be mistaken for vessels on this contrast-enhanced CT scan



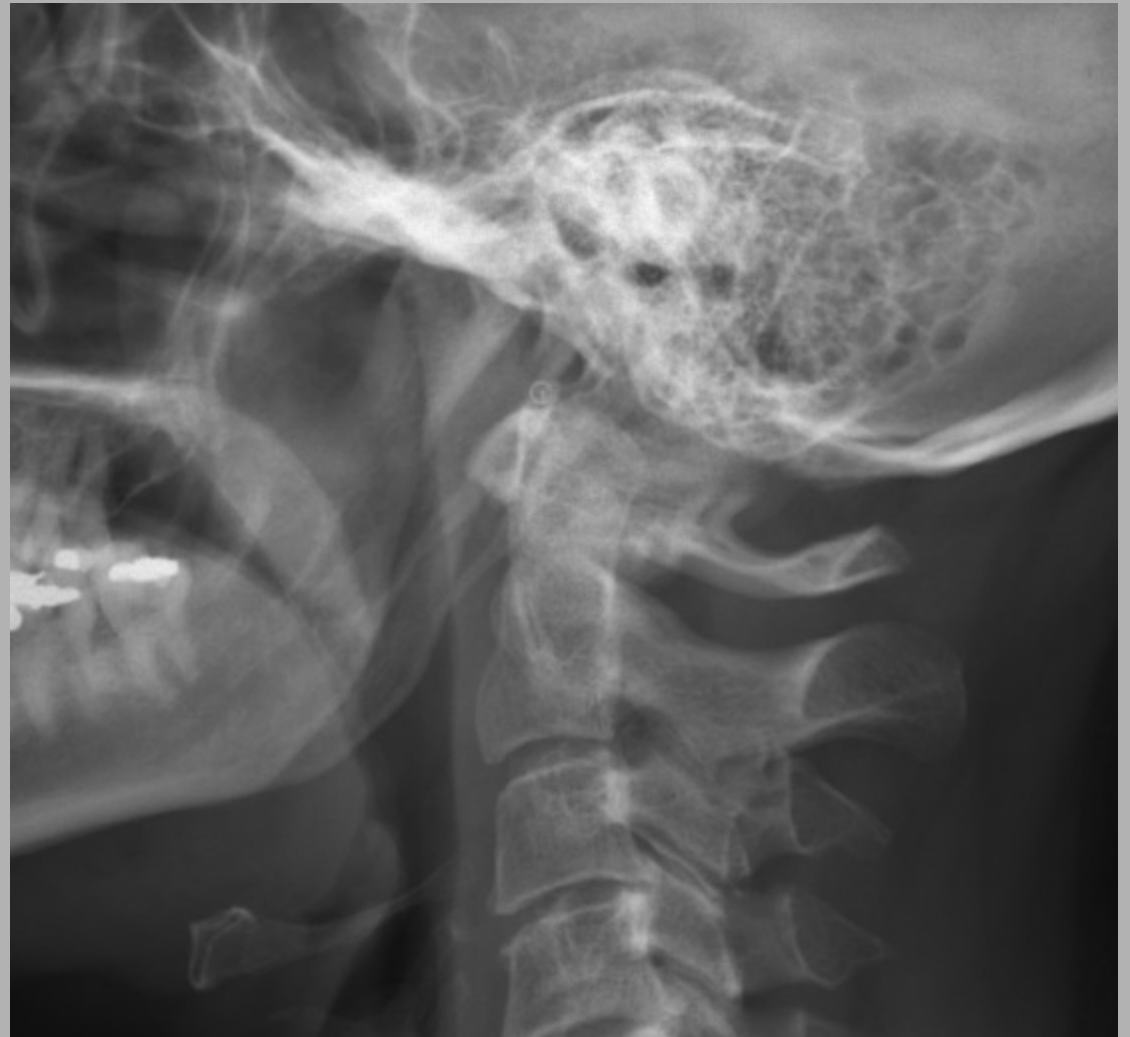Retentio abundant teeth



Processus styloideus

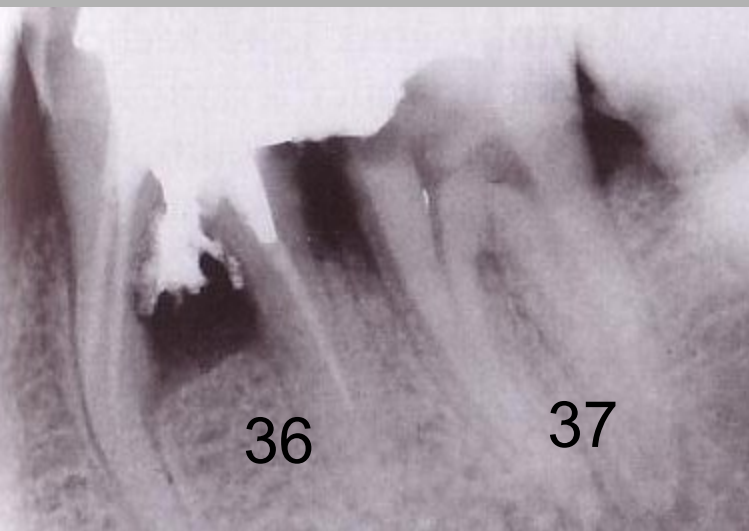
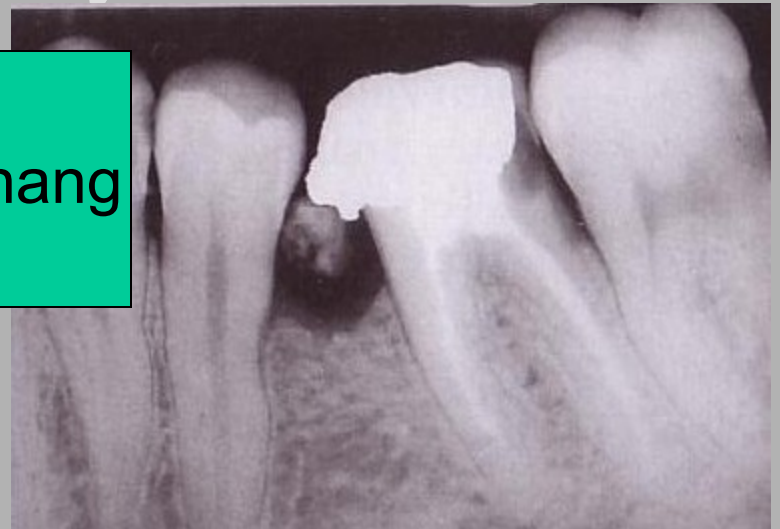pain

long proc. styl.

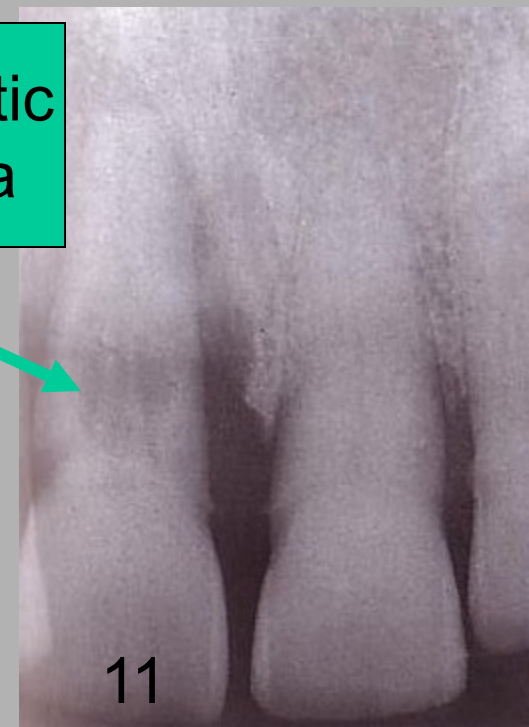


Marginal periodontopathy

bone reduction between 35,37
as a consequence of amalgam overhang
caries 34,37,38



mesial posttraumatic
central granuloma



oversupply of root filling
injury to the desmodont and mesodont of tooth root
etiology: via falsa
= interradicular bone loss

11

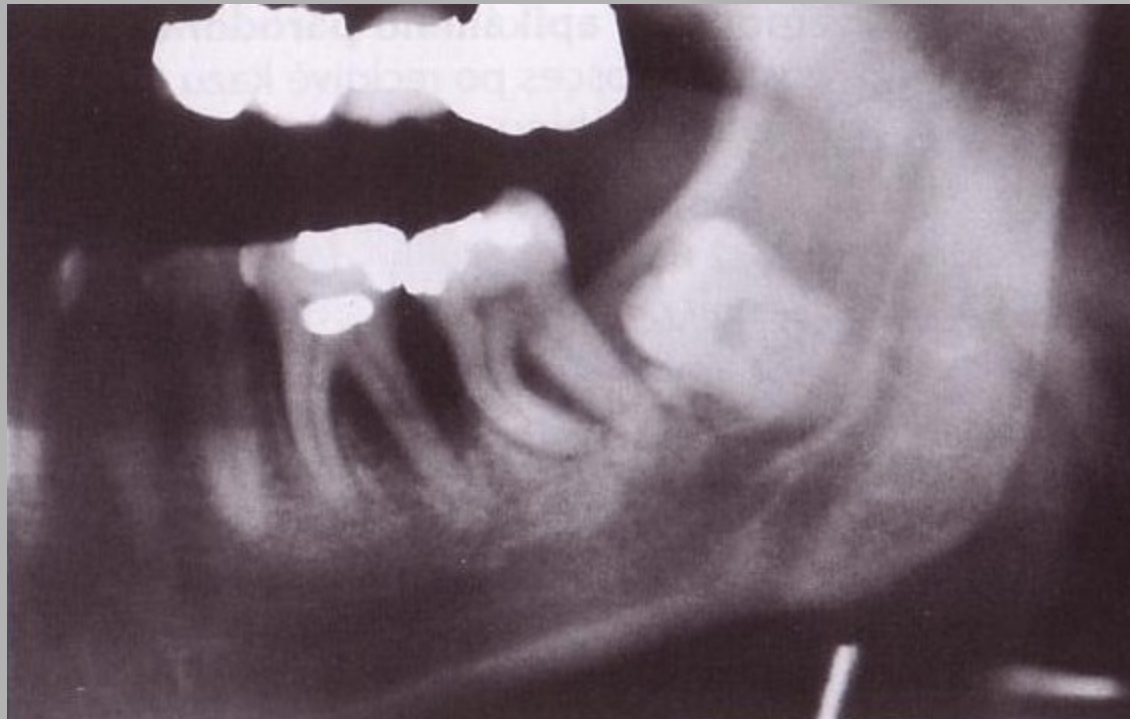Marginal periodontopathy

traumatic occlusion

etiology: fixed bridgework

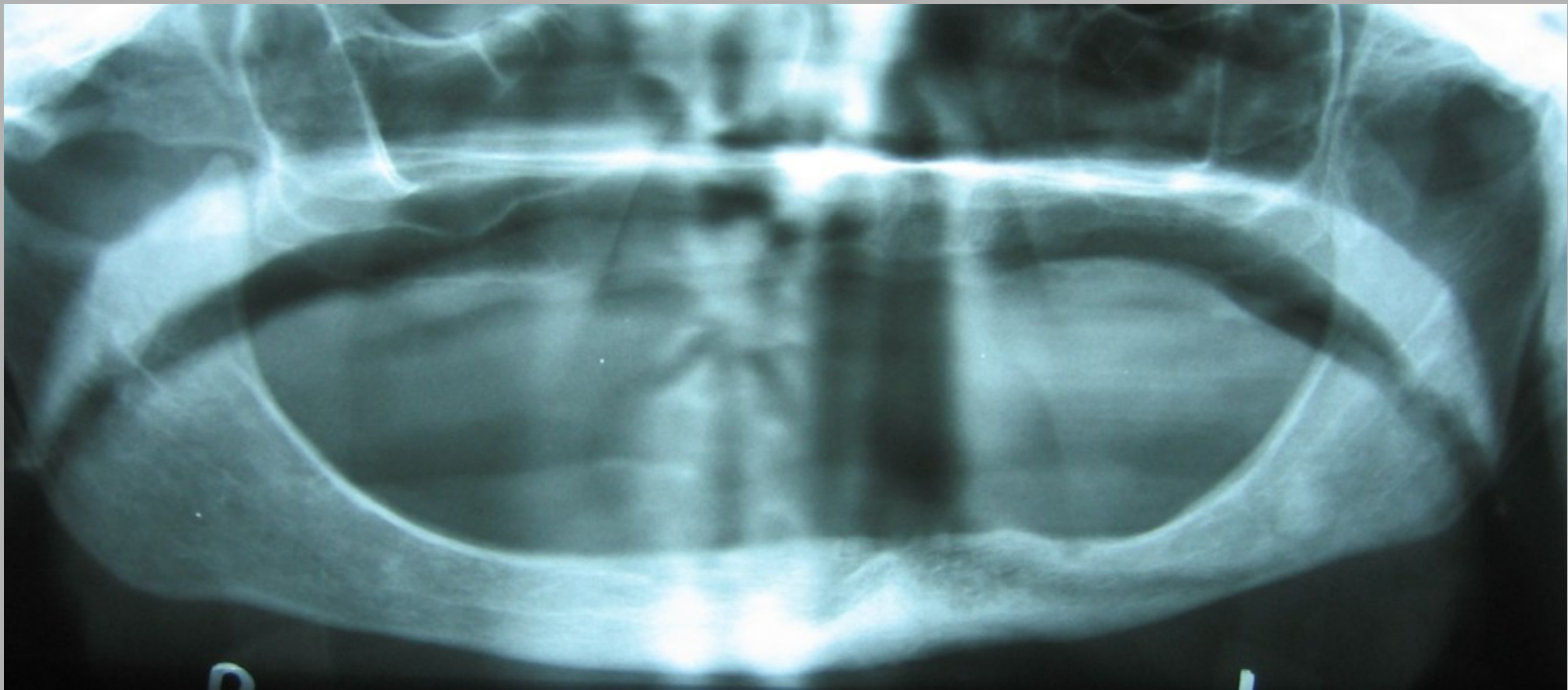
massive bone reduction

sclerotic reactive zone - apically (36,37)

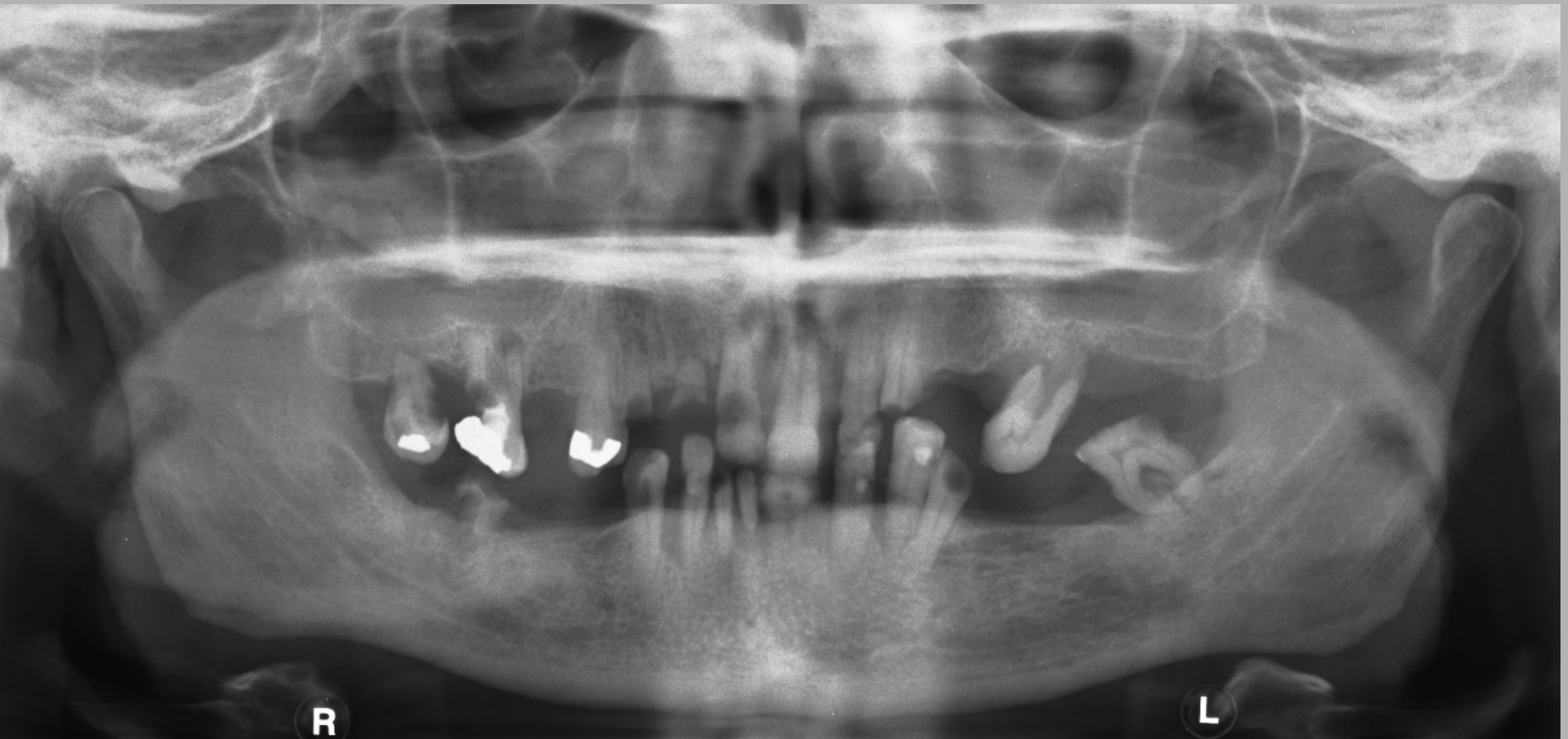

Marginal periodontopathy

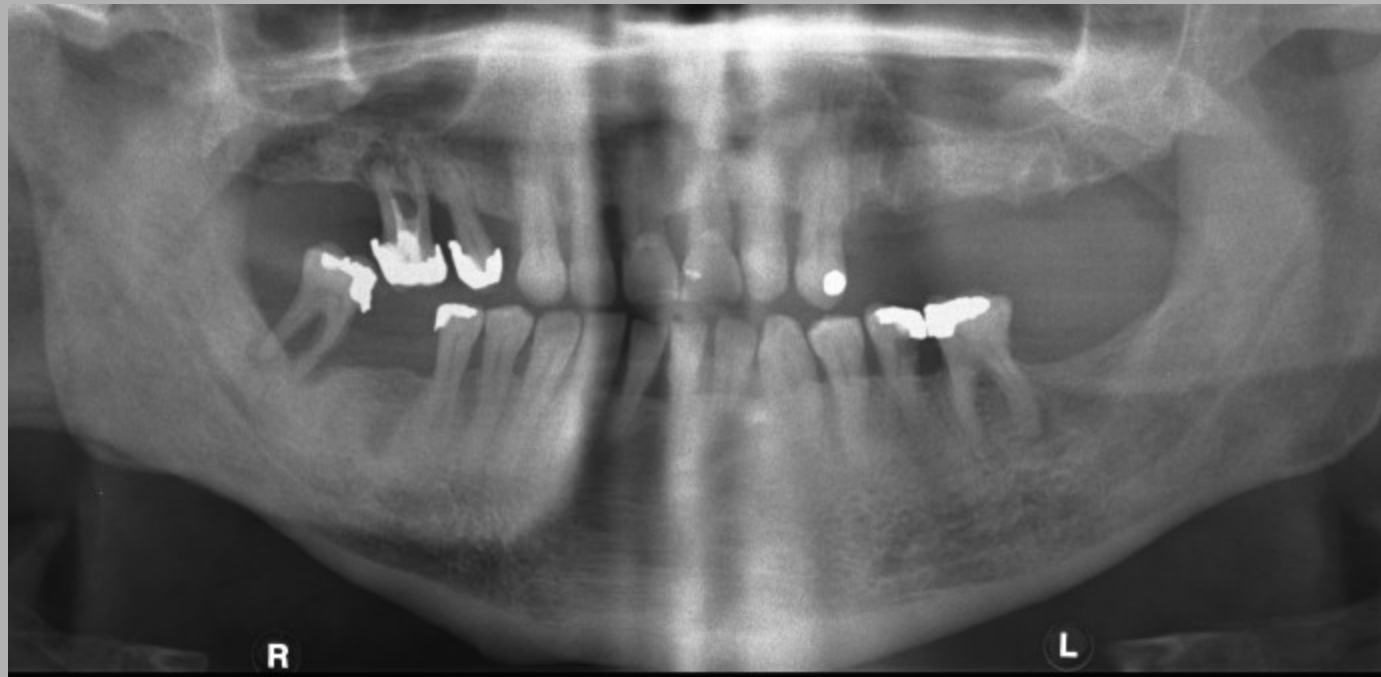alveolar and mandible bone reduction
old age



Chronic. apical periodontitis



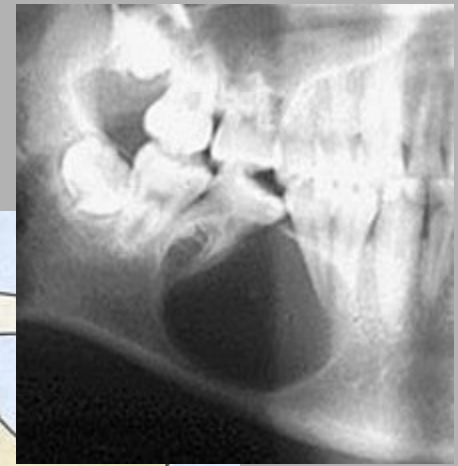
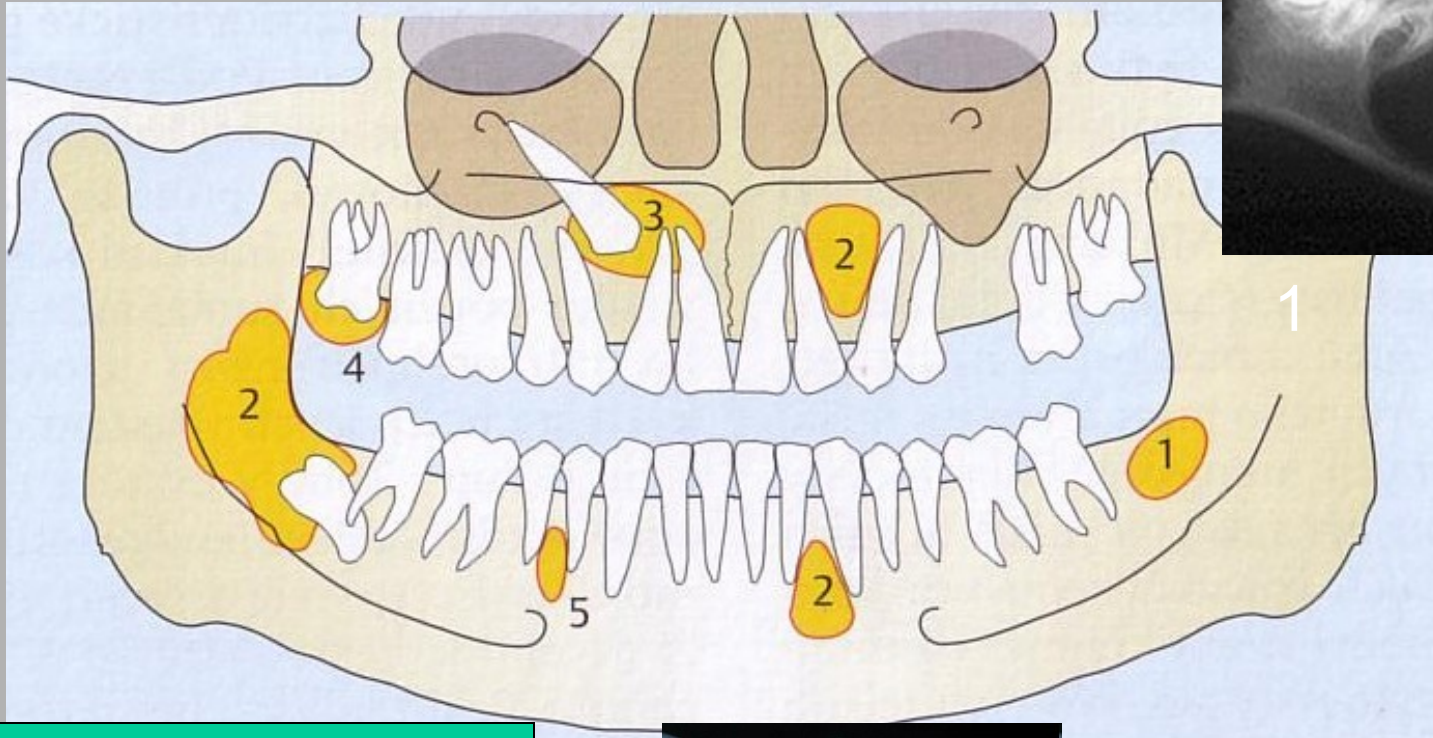
Periodontitis chronica



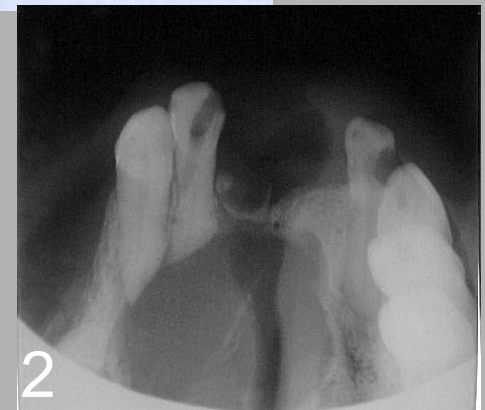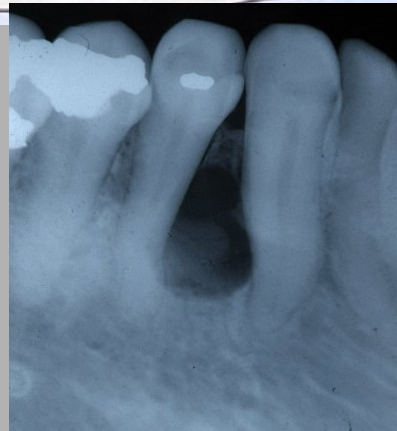
Cysts

- Odontogenic
- Non-odontogenic
- inflammatory

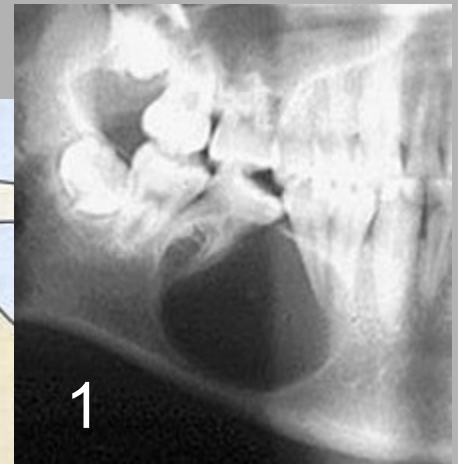
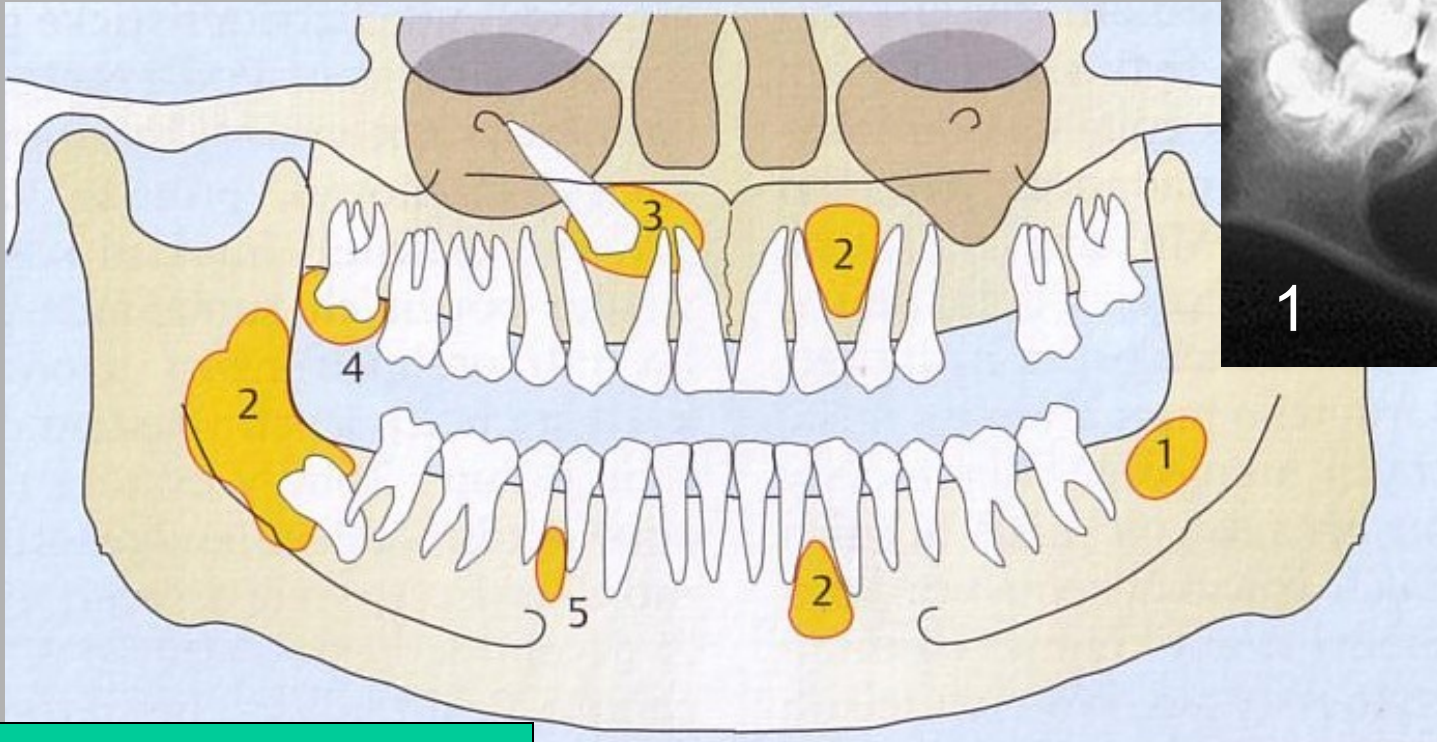
Cysts – odontogenic



1. primordial c.
2. keratocyst
3. folikular c.
4. lateral parodontal c.



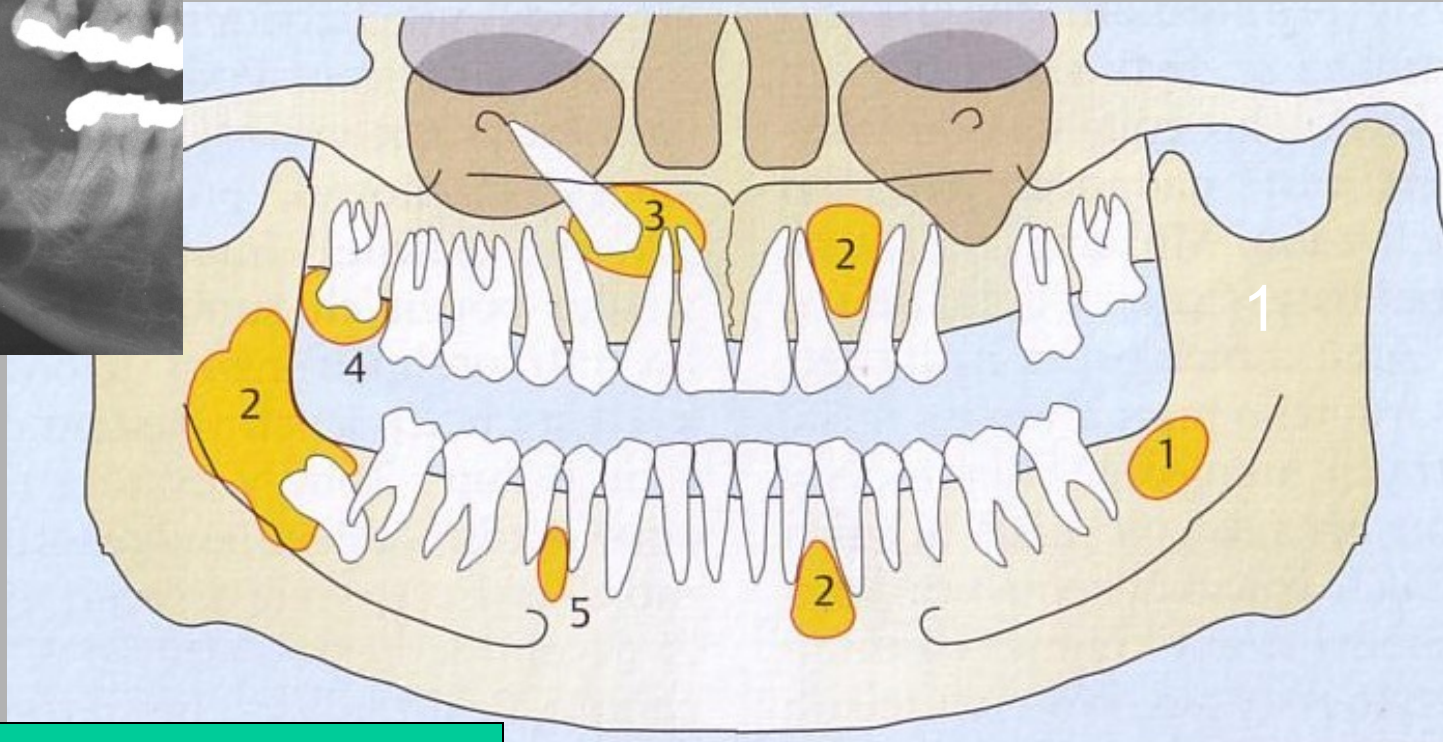
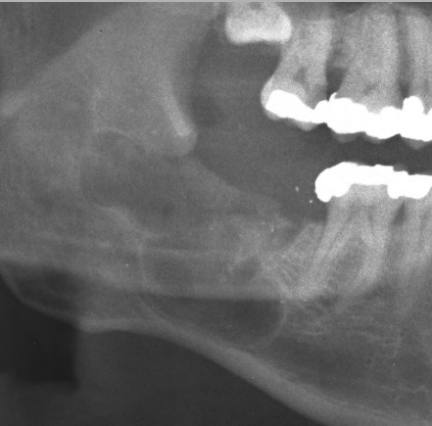
Cysts – odontogenic



1. primordial c.
2. keratocyst
3. follicular c.
4. lateral periodontal c.

A primordial cyst is a developmental odontogenic cyst. It is found in an area where a tooth should have formed but is missing. Primordial cysts most commonly arise in the area of mandibular third molars.

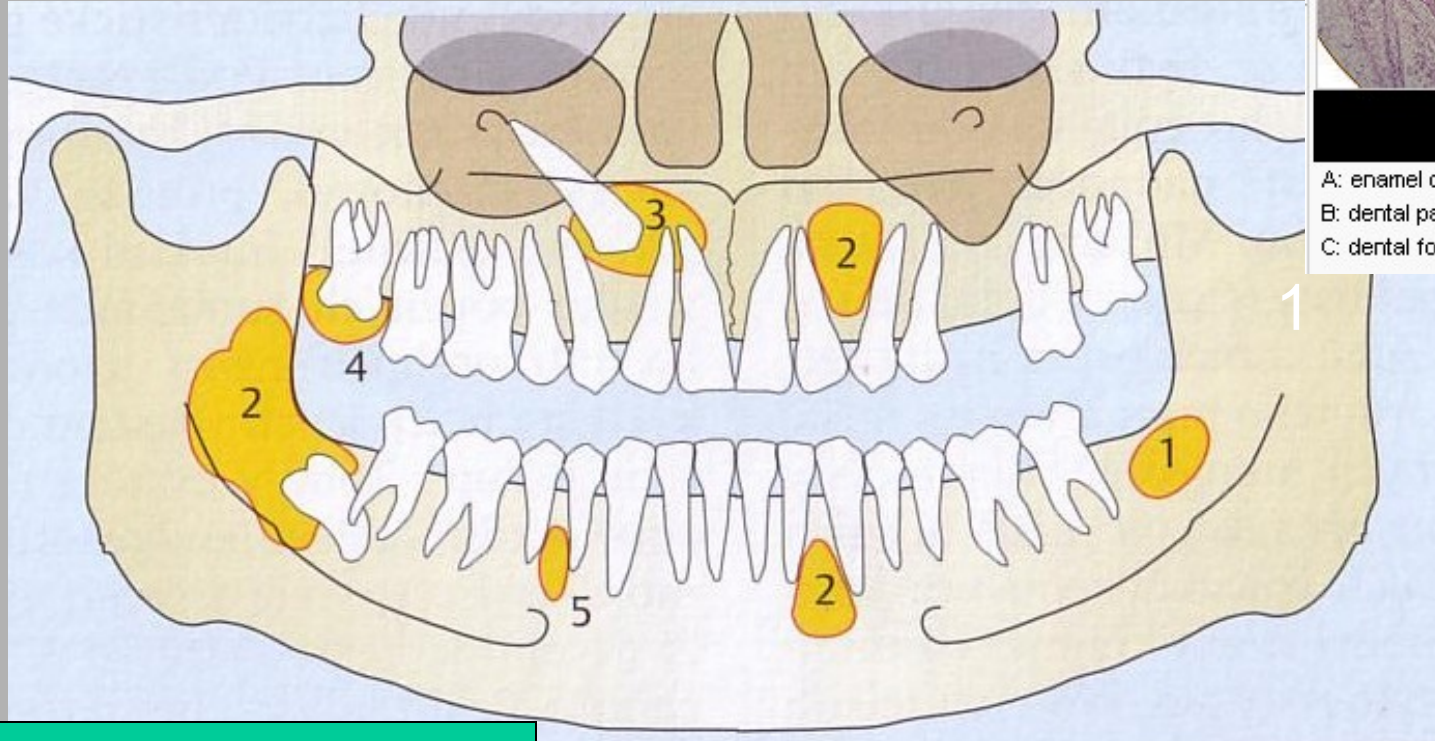
Cysts – odontogenic



1. primordial c.
2. keratocyst
3. follicular c.
4. lateral periodontal c.

Keratocyst is a benign but locally aggressive developmental cystic neoplasm. It most often affects the posterior mandible.

Cysts – odontogenic

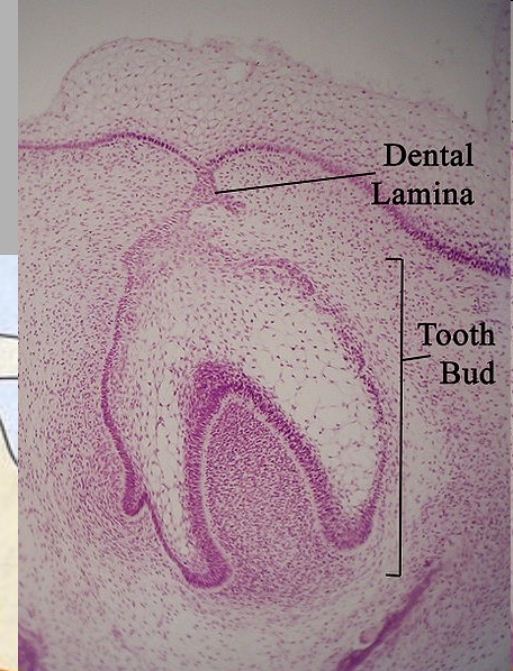
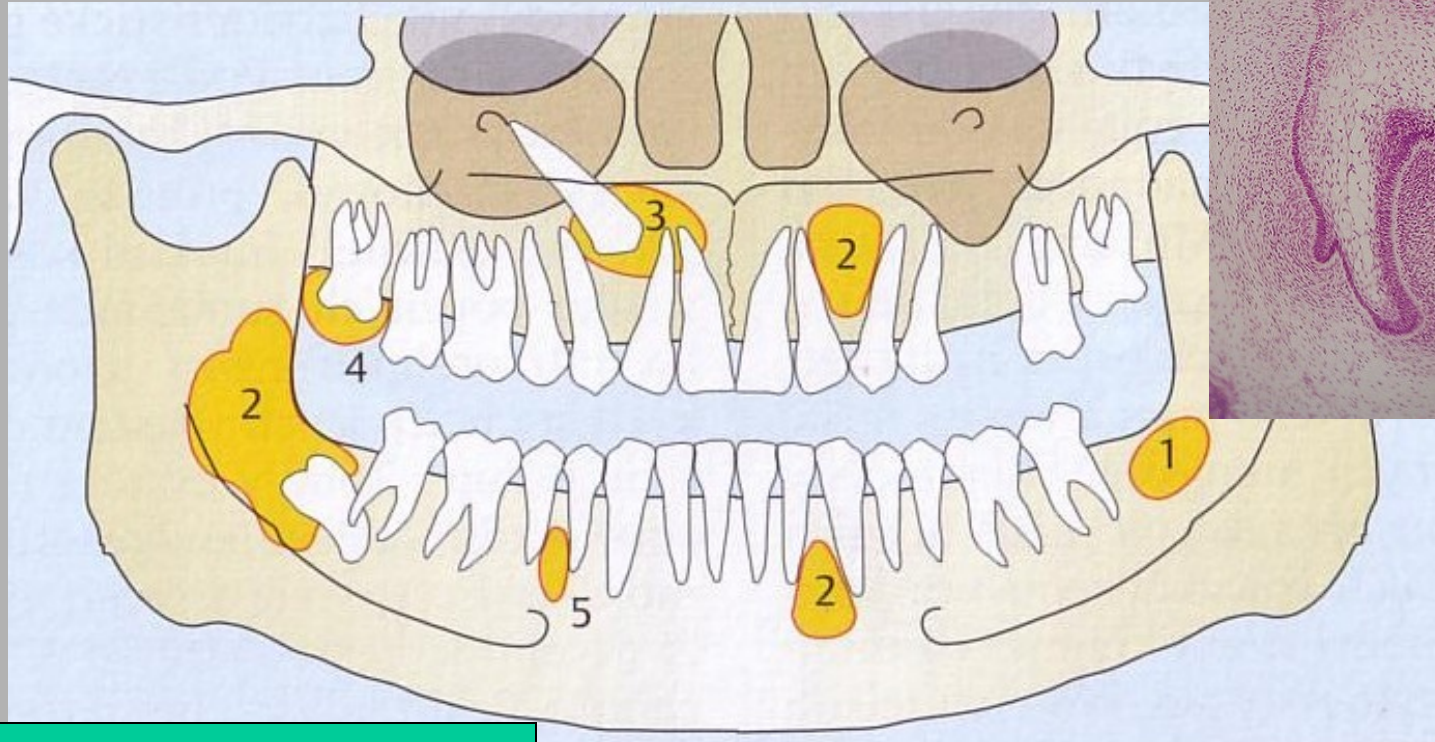


1. primordial c.
2. keratocyst
3. follicular c.
4. lateral periodontal c.

A follicular cyst is a cyst of dental follicle

The **dental follicle** is a sac containing the developing tooth and its odontogenic organ.

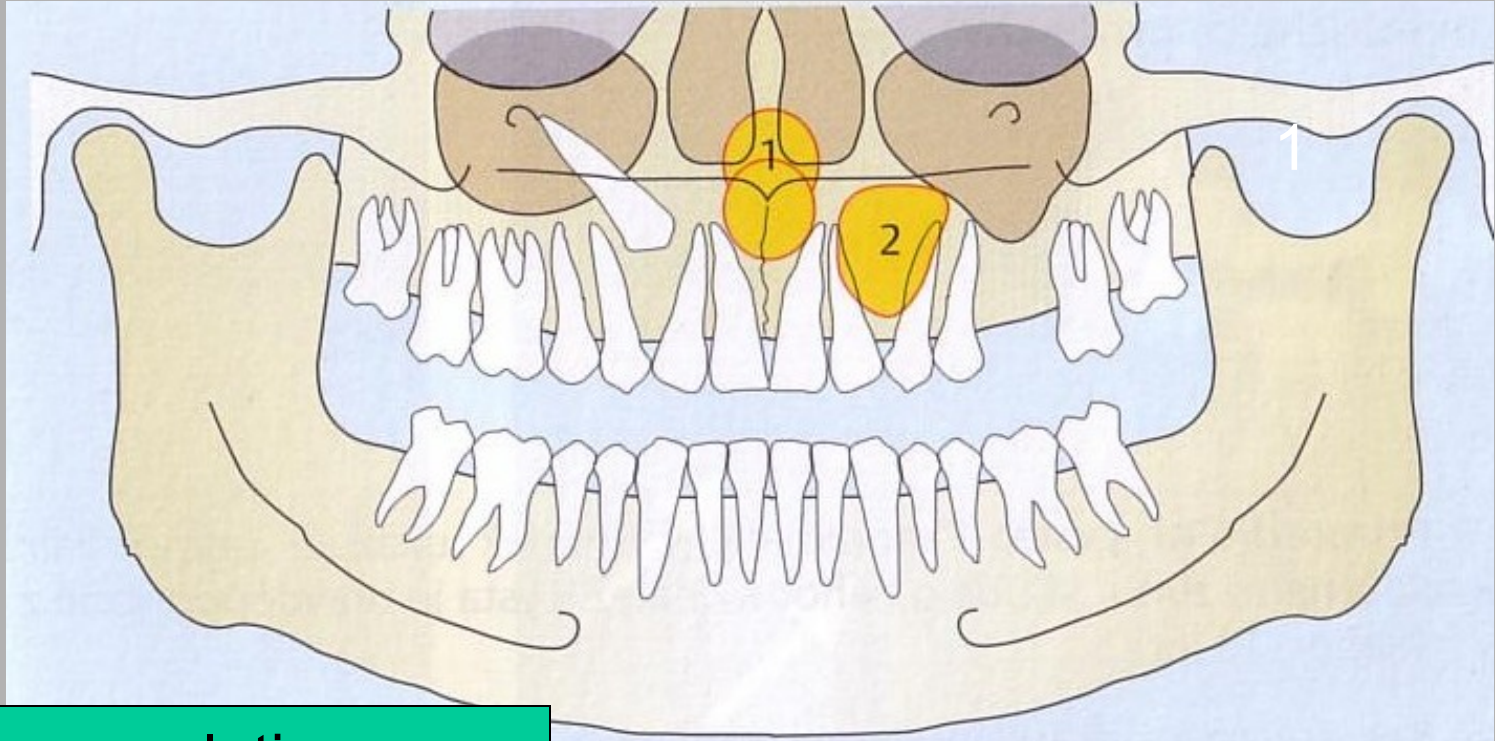
Cysts – odontogenic



1. primordial c.
2. keratocyst
3. folikular c.
4. lateral parodontal c.

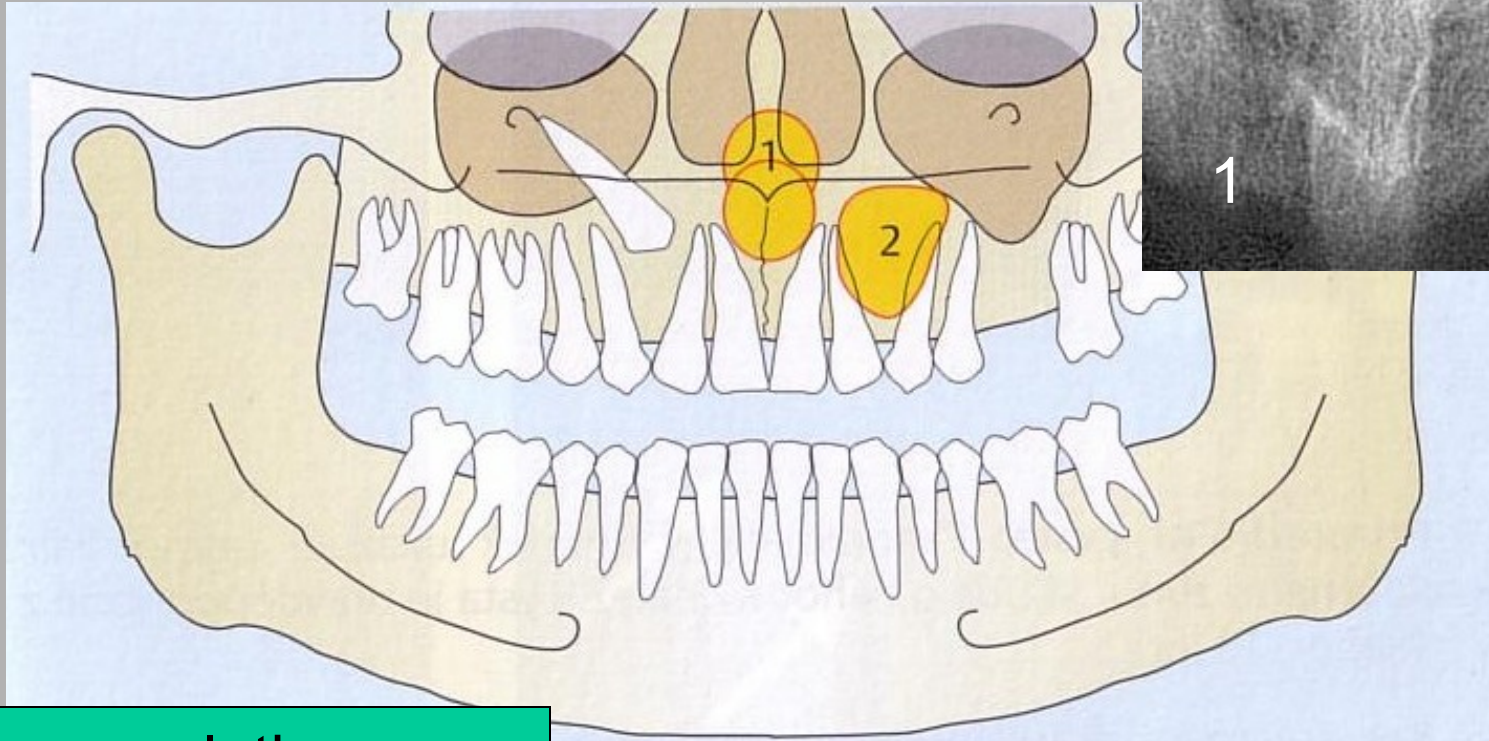
The **lateral periodontal cyst** is a cyst that arises from the rest cells of the dental lamina. It is more common in middle-aged adult males. Usually, there is no pain associated with it, and it usually appears as a unilocular radiolucency (dark area) on the side of a canine or premolar root. Microscopically, the lateral periodontal cyst appears the same as the gingival cyst of the adult.

Cysts – non-odontogenic



1. nasopalatine c.
2. nasolabial c.

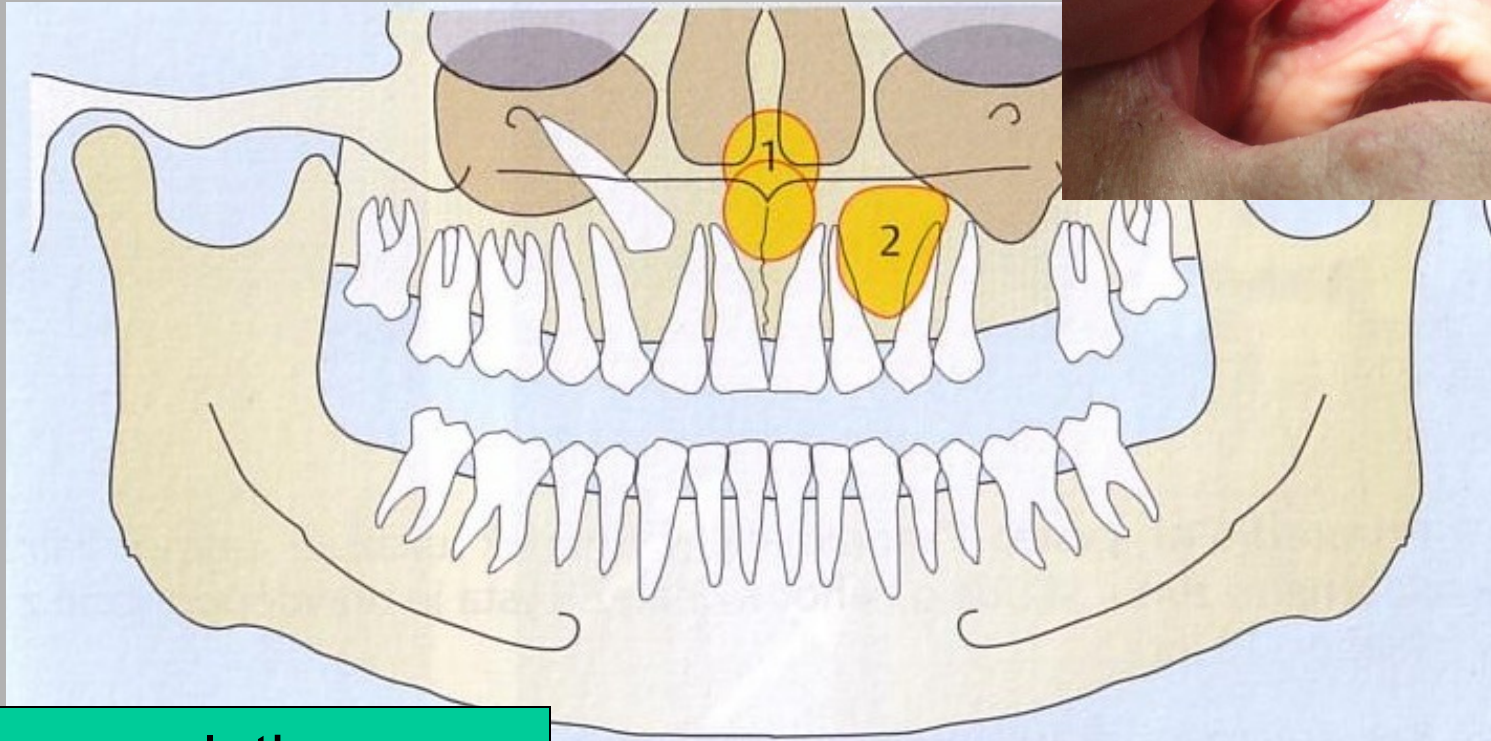
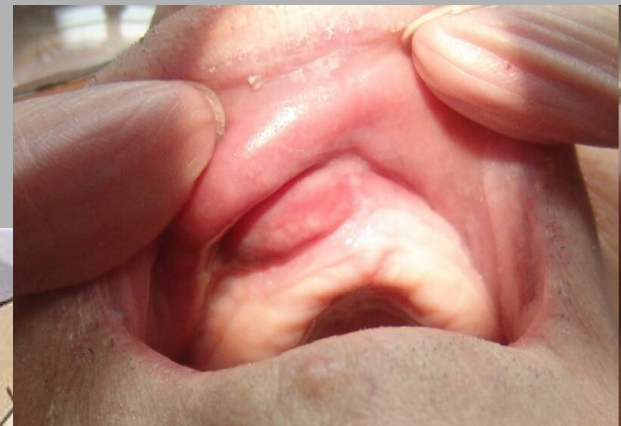Cysts – non-odontogenic



1. nasopalatine c.
2. nasolabial c.

Nasopalatine cyst occurs in the medial part of the palate.

Cysts – non-odontogenic

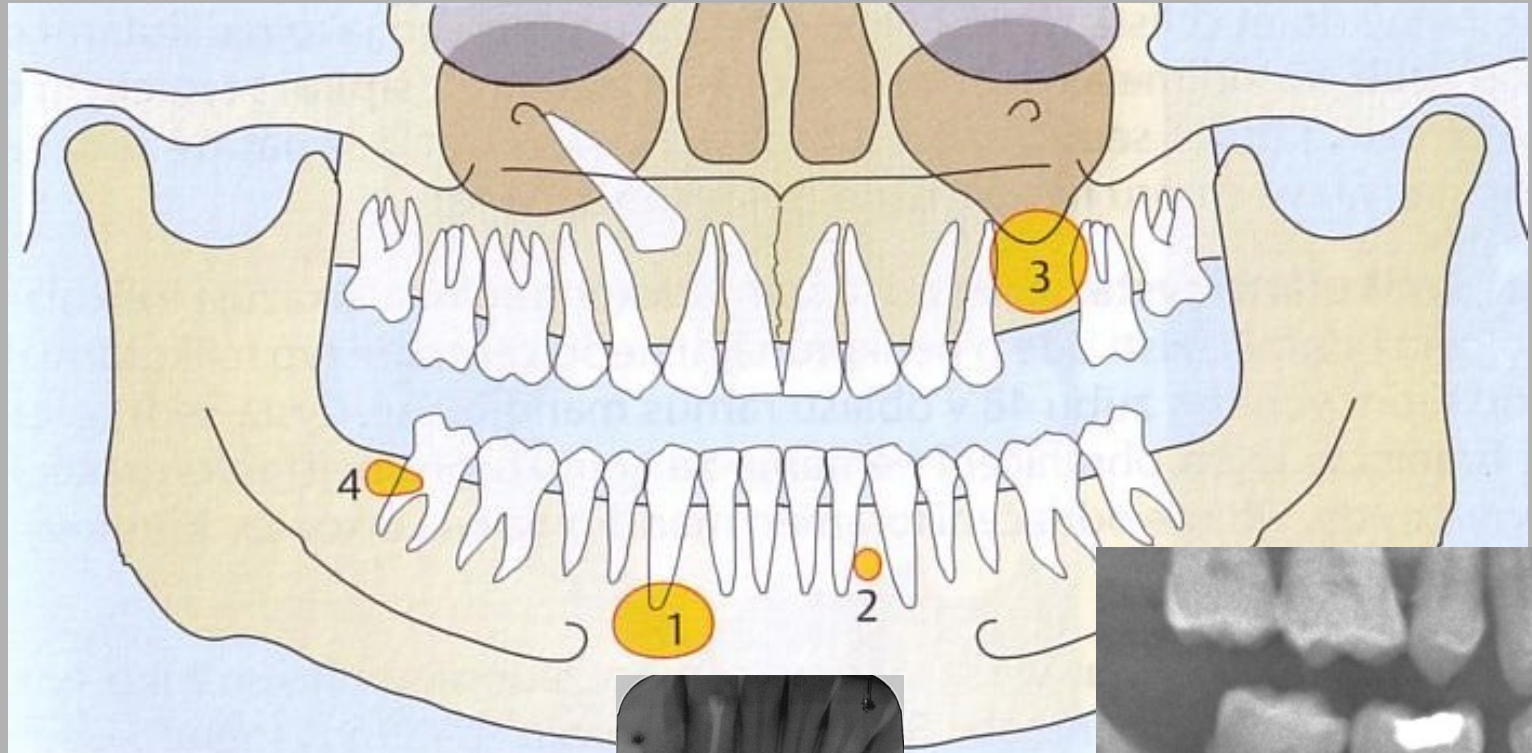


1. nasopalatine c.
2. nasolabial c.

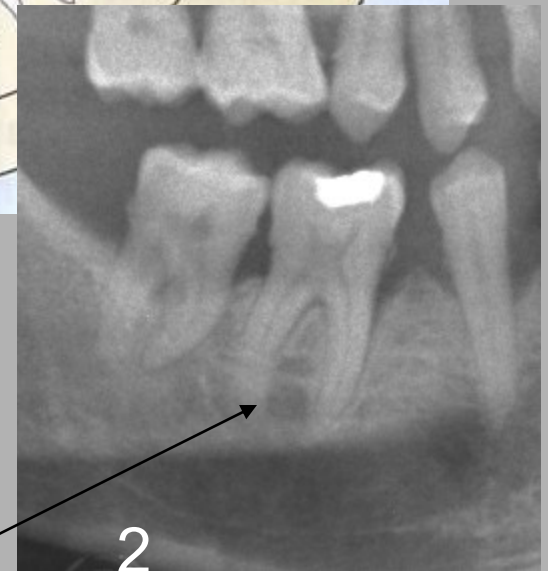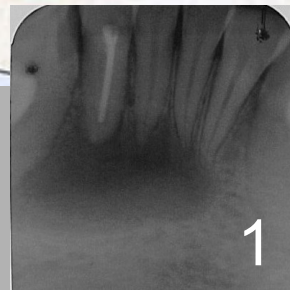Nasolabial cyst is located superficially in the soft tissues of the upper lip.

Unlike most of the other developmental cysts, the nasolabial cyst is an example of an extraosseous cyst.

Cysts - inflammatory

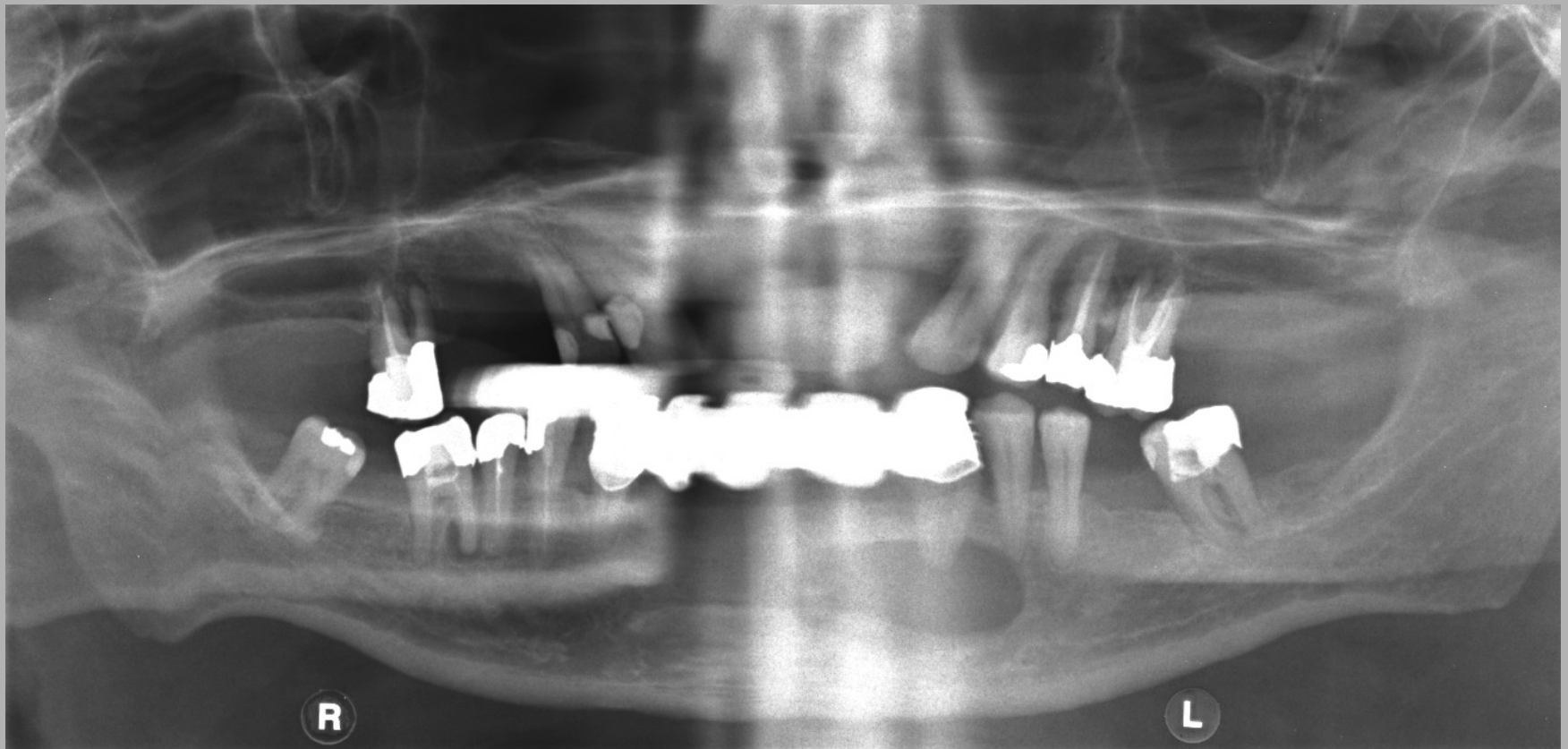


1. apical radicular
2. lateral radicular
3. residual lateral
4. paradontal (Craig's) - wisdom tooth



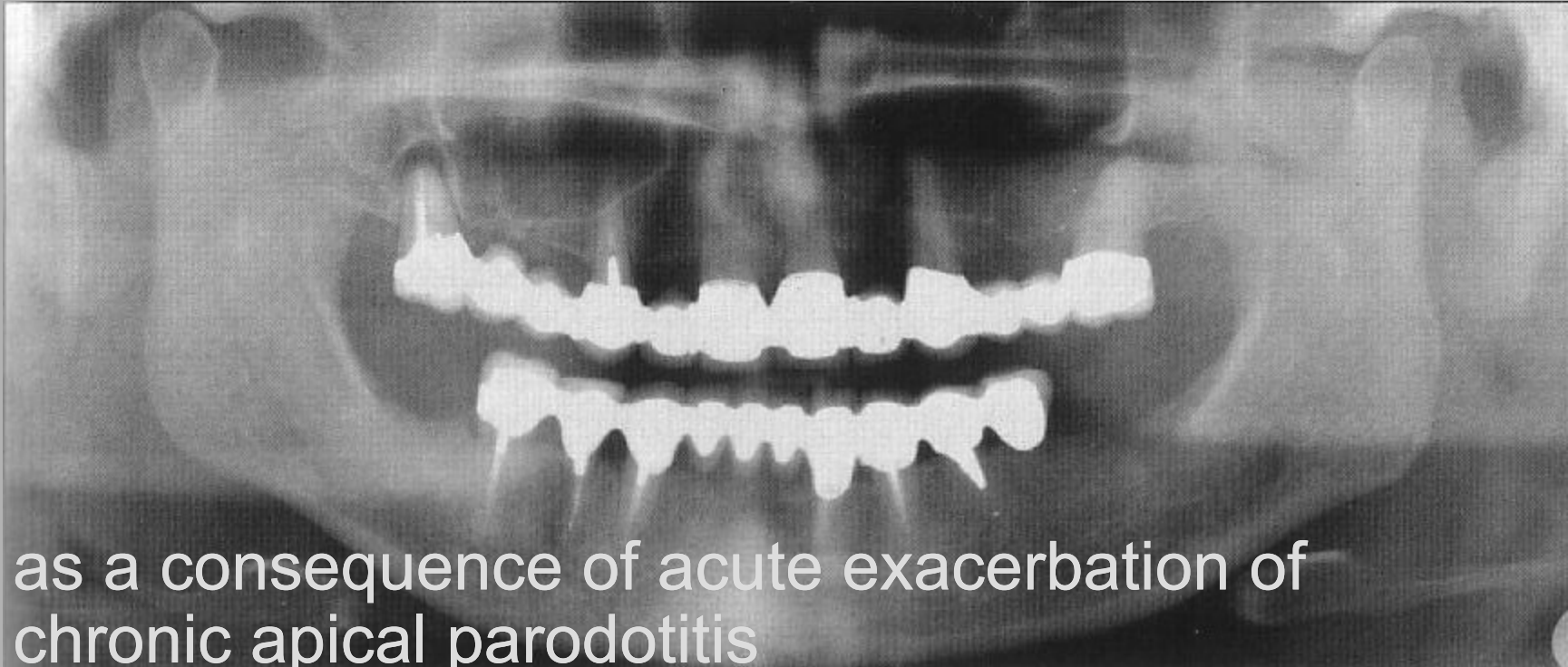
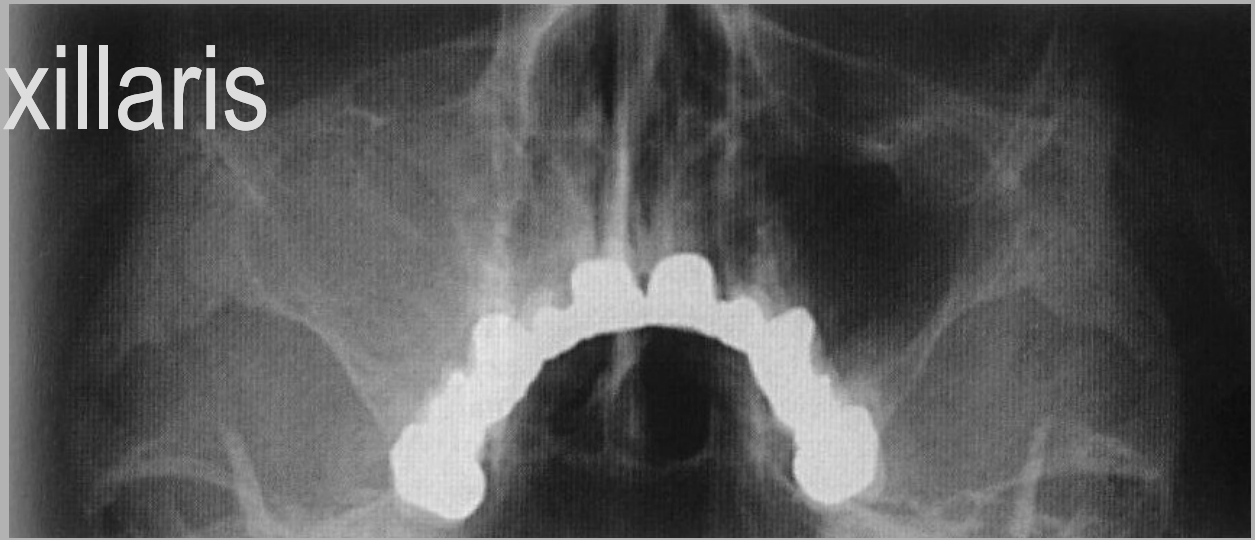
Radicular cyst

- cystis radicularis (234) purulenta
- after intraoral incision excretion of pus and blood.



Sinusitis maxillaris

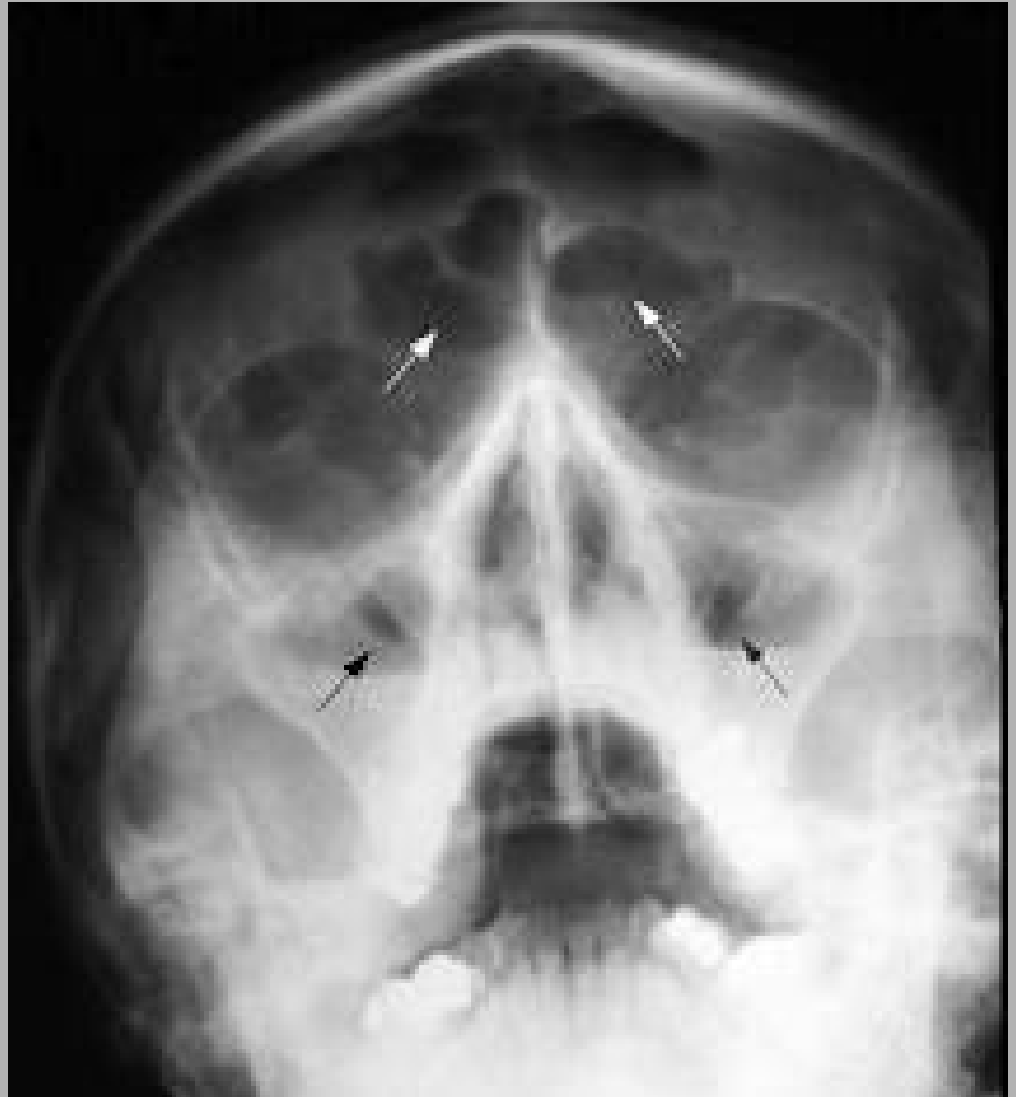female, 57 y



- as a consequence of acute exacerbation of chronic apical parodontitis

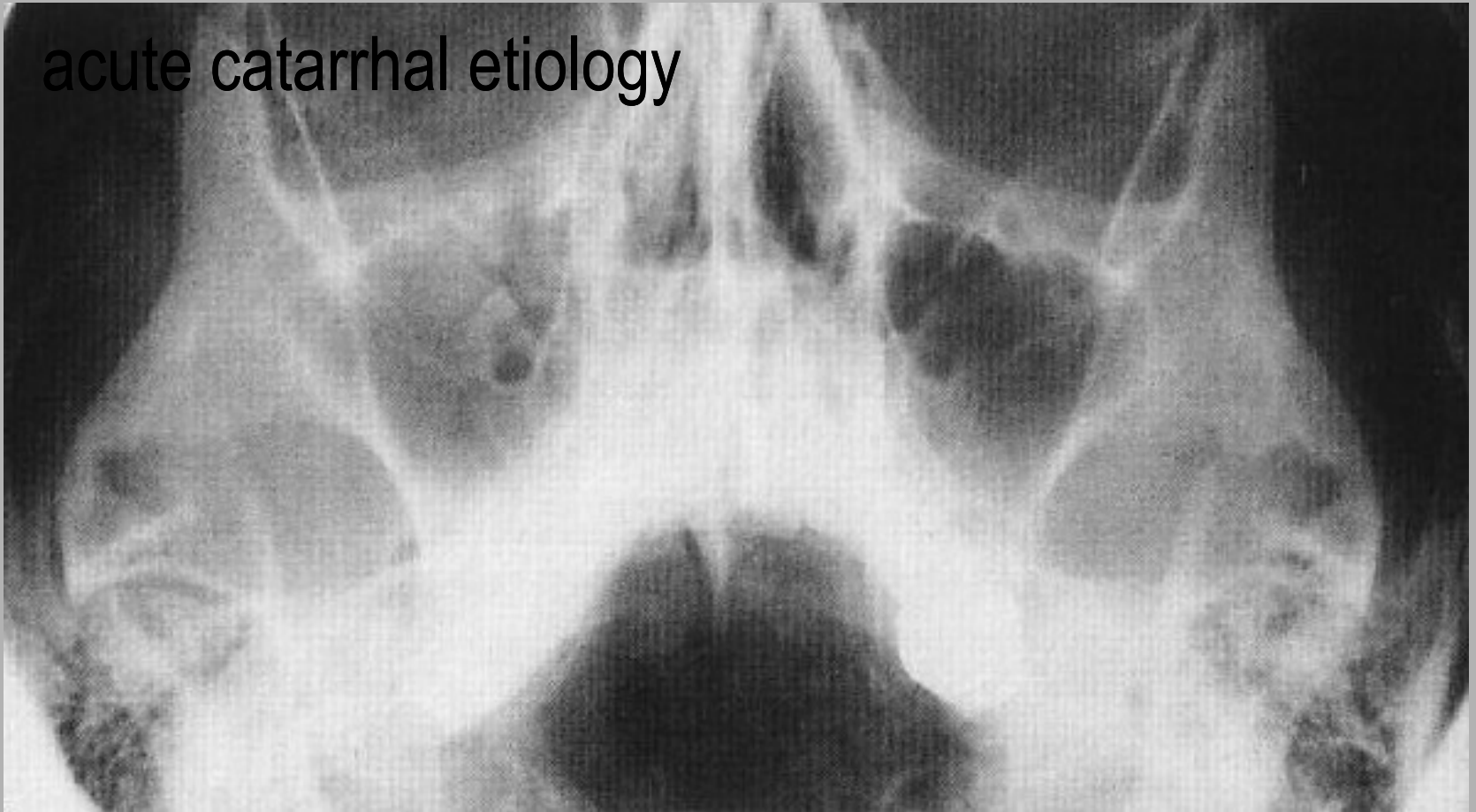
Sinusitis maxillaris

- Liquid surface

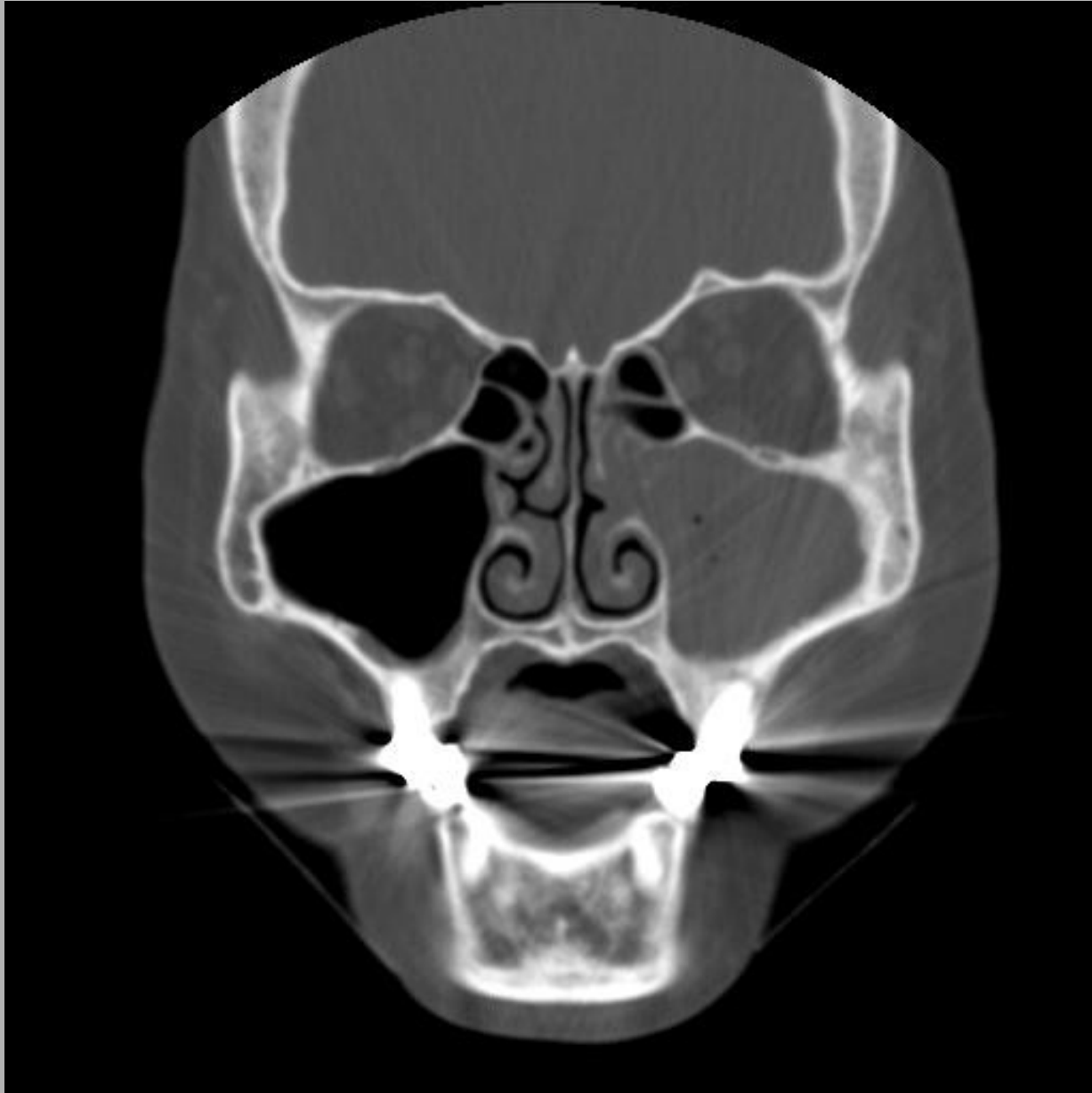

Sinusitis maxillaris - RTG

- woman, 17 y
- acute catarrhal etiology

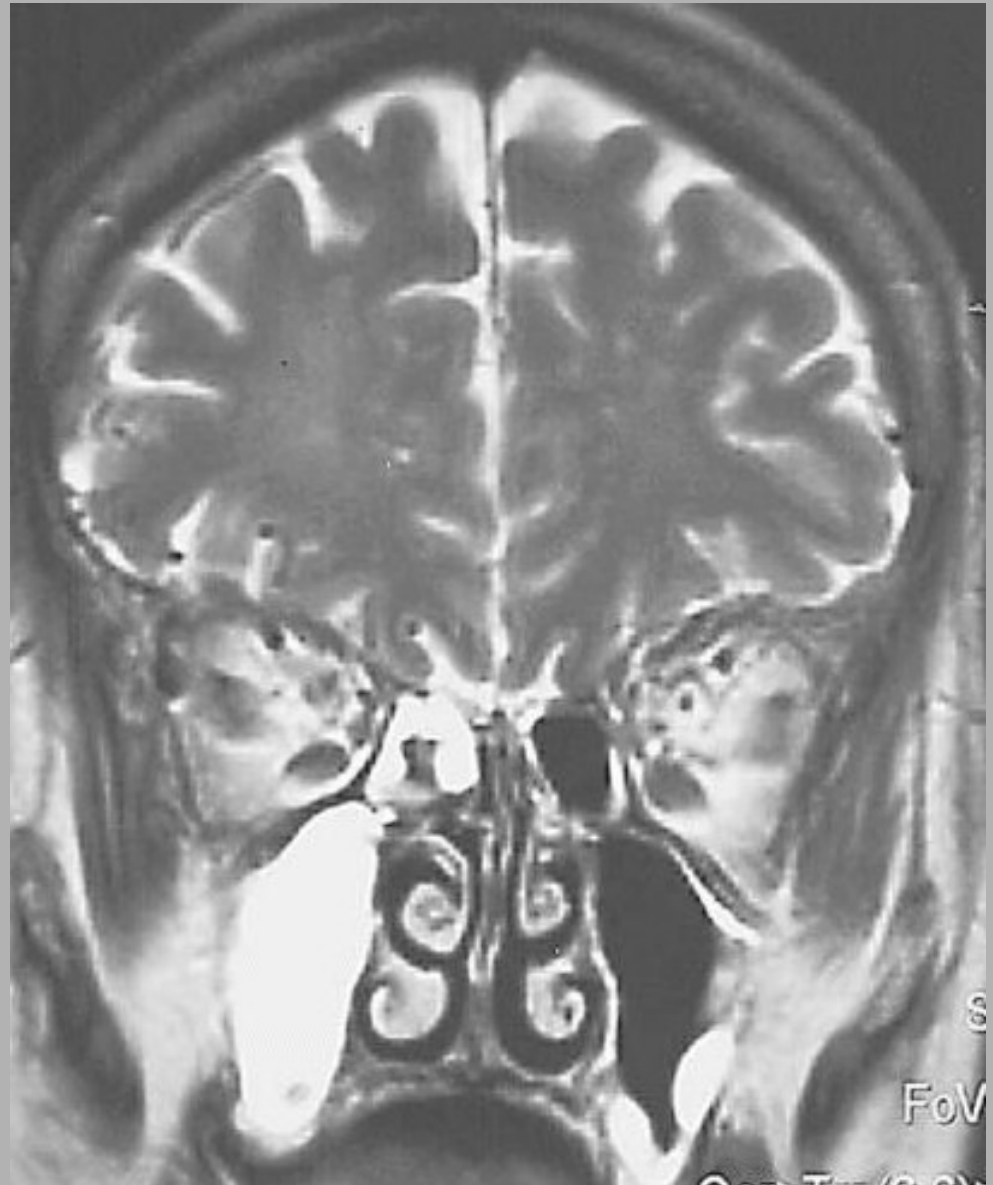

Sinusitis maxillaris - CT



Sinusitis maxillaris - MRI

T2 weighed coronal

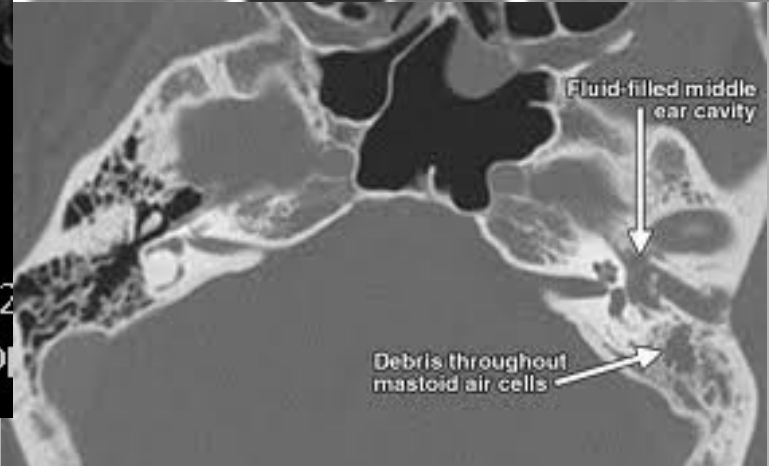
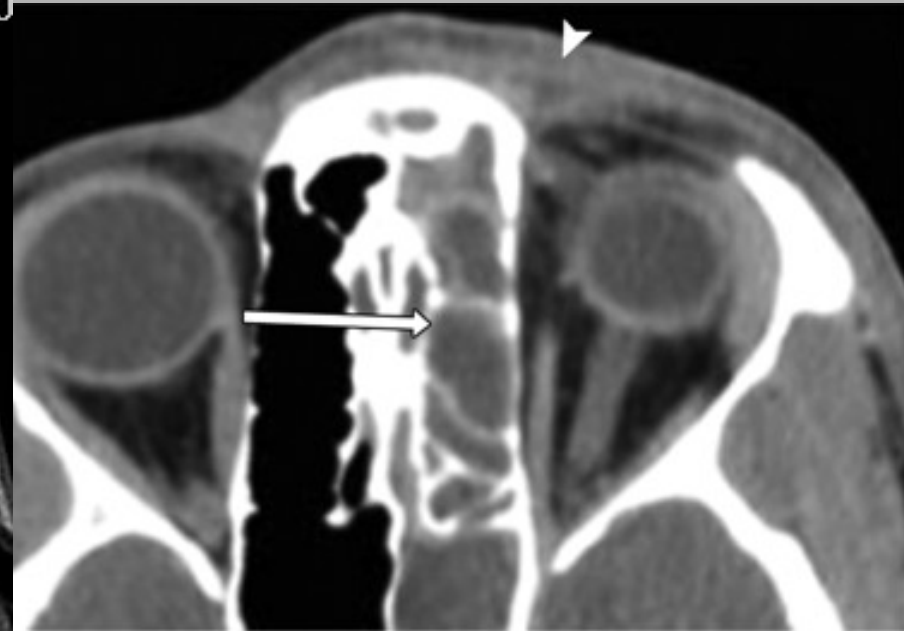
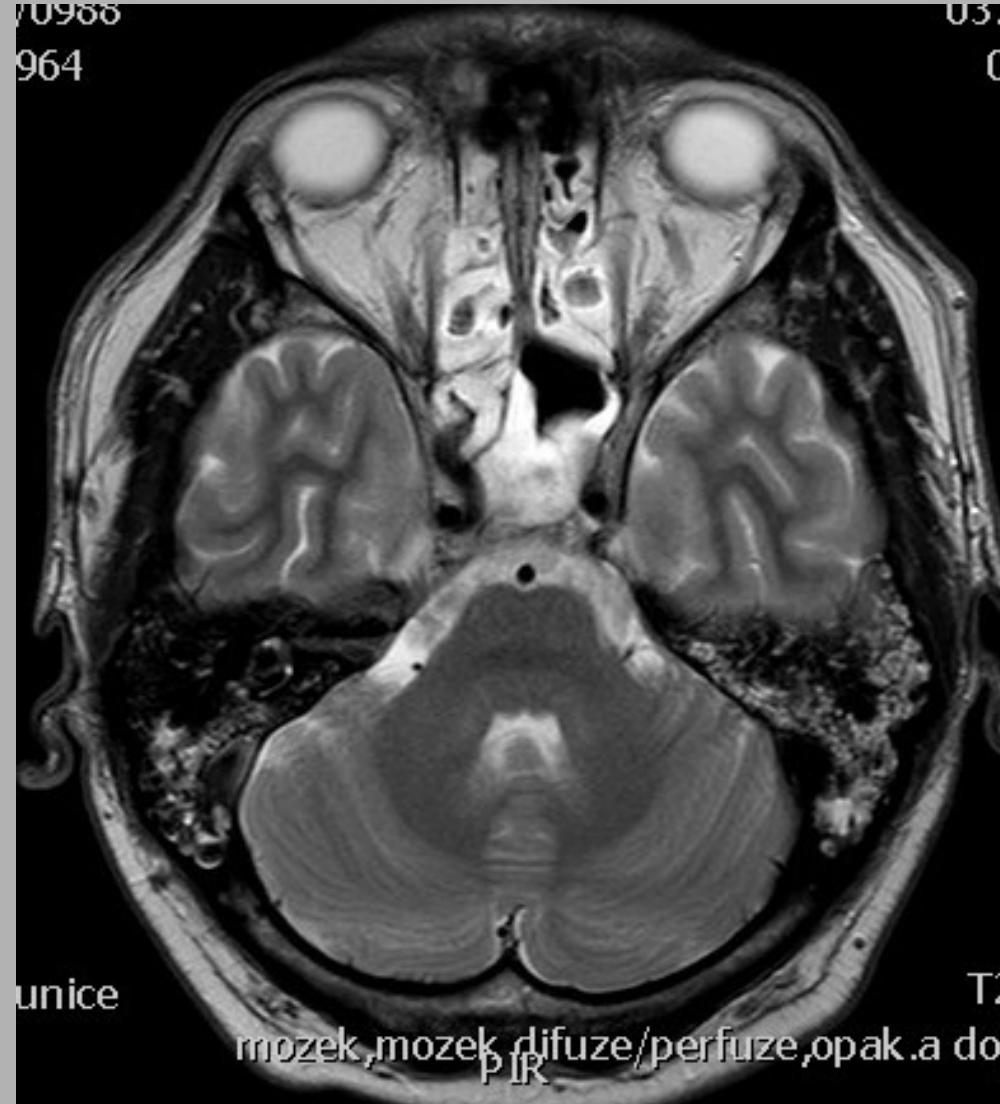
Ethmoid sinus, mastoid cells

Ethmoid. sinusitis

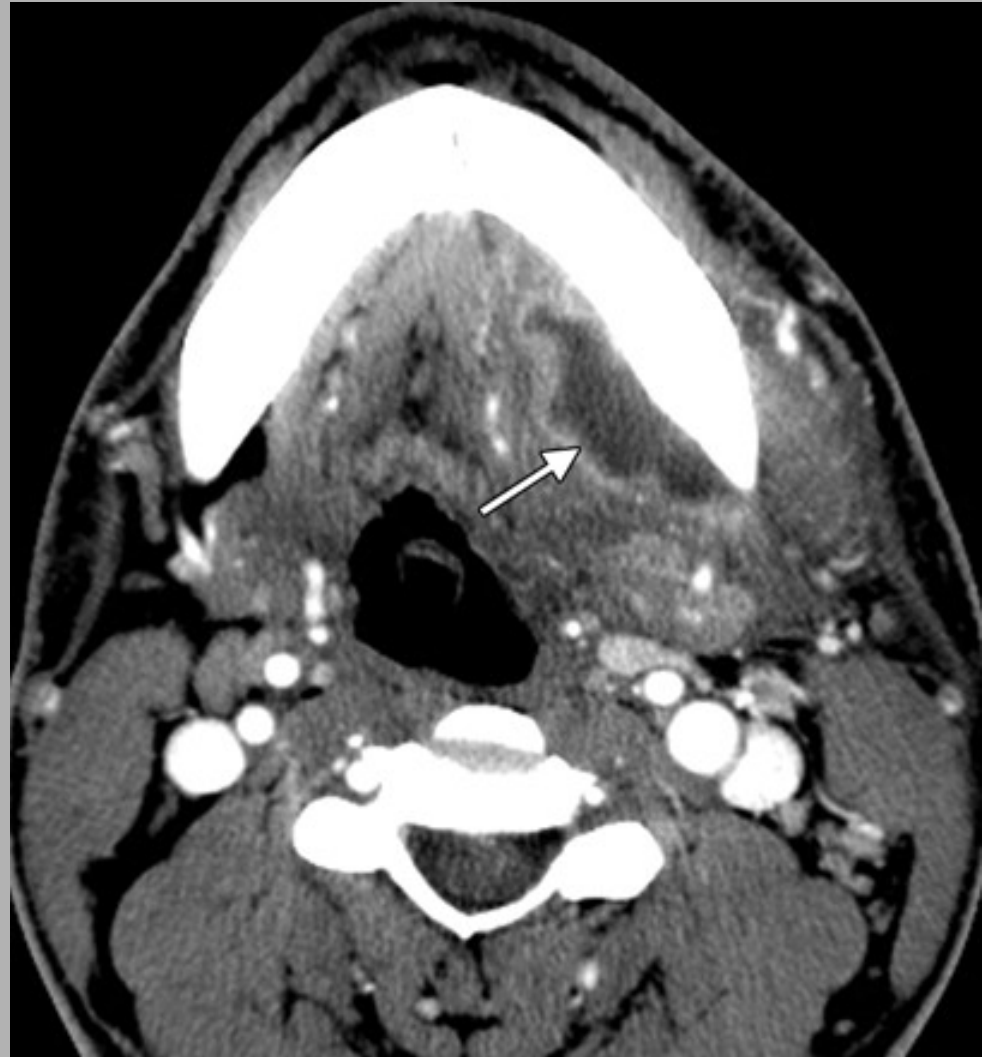Pathologic contents

T2



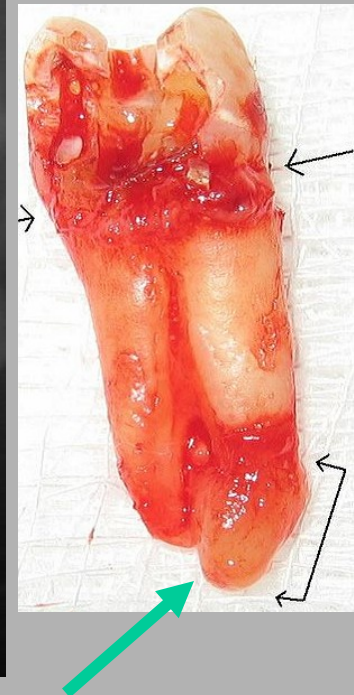
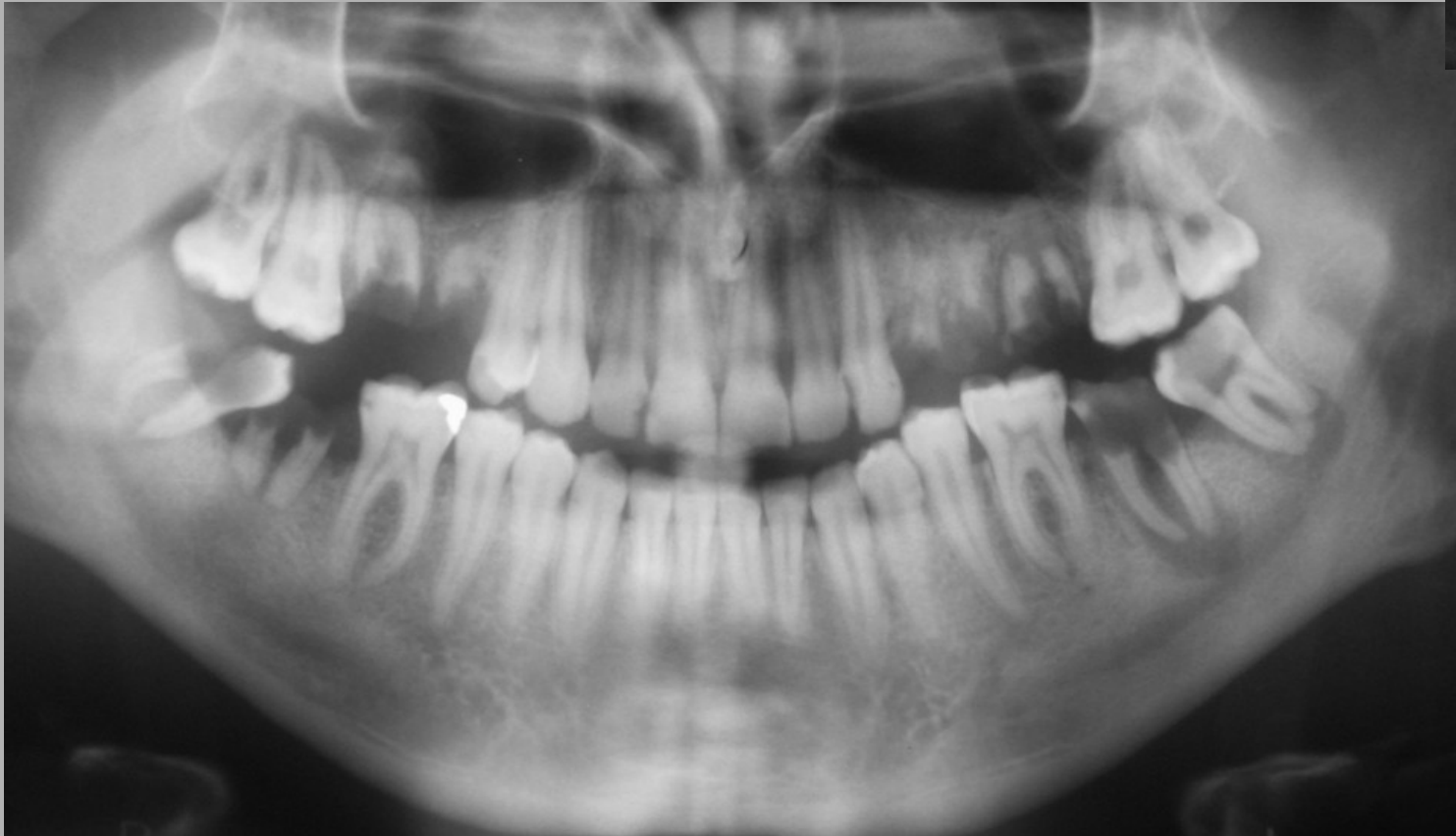
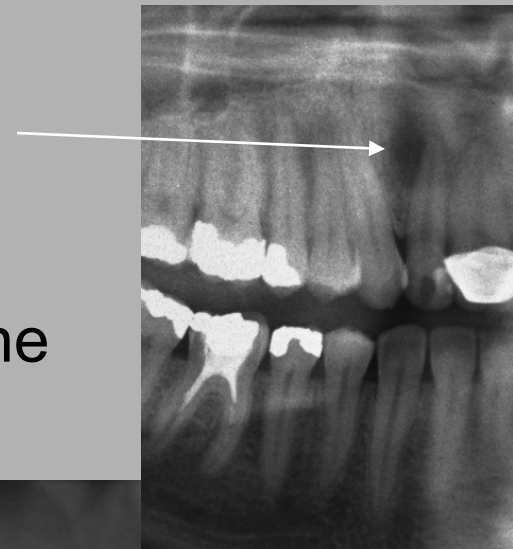
Periapical abscess

- Oral cavity abscess.
- Contrast-enhanced axial CT images obtained with soft-tissue and bone window settings show a fluid collection with rimlike enhancement in the left submandibular space.
- The bone window image better depicts the source of infection.



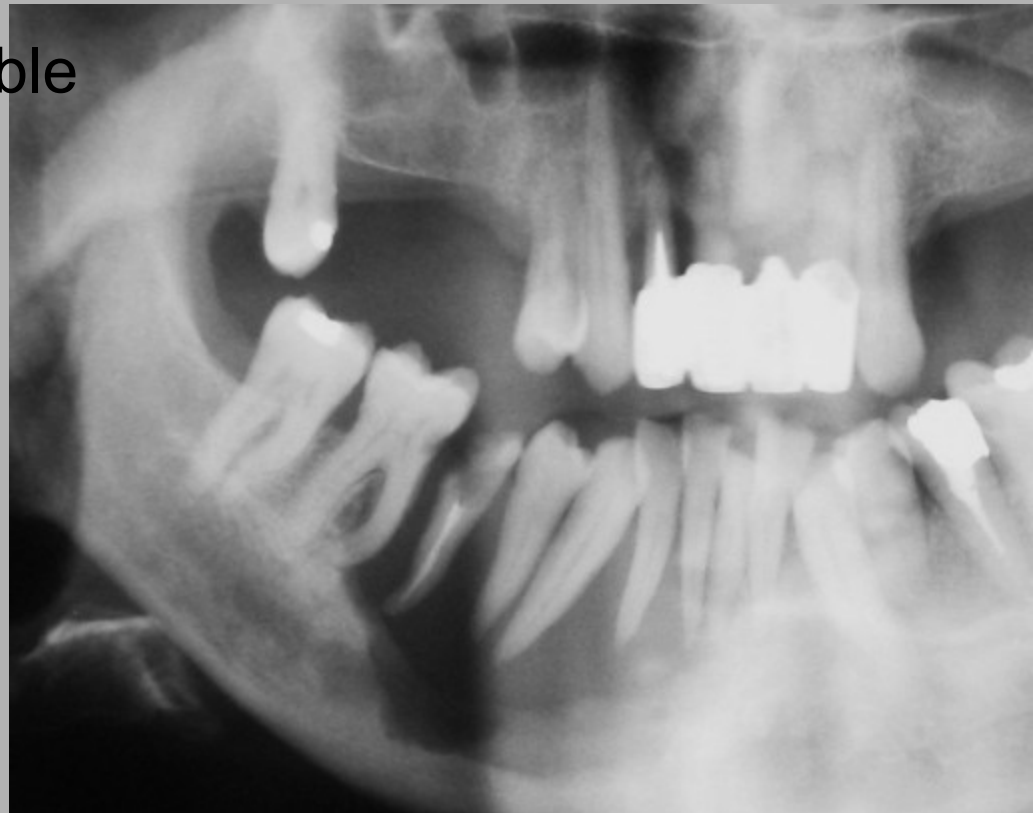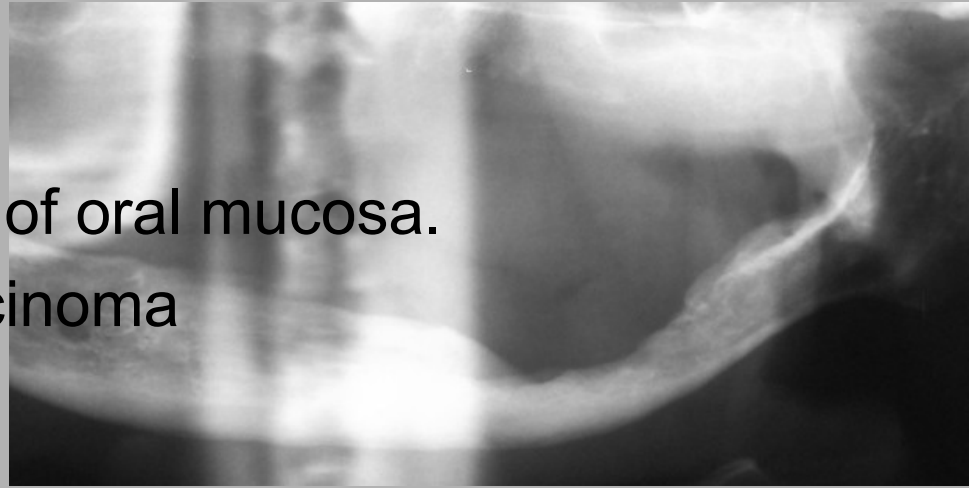
Periapical abscess

A **periapical abscess** is the result of a chronic, localized infection located at the tip, or apex, of the root of a tooth.

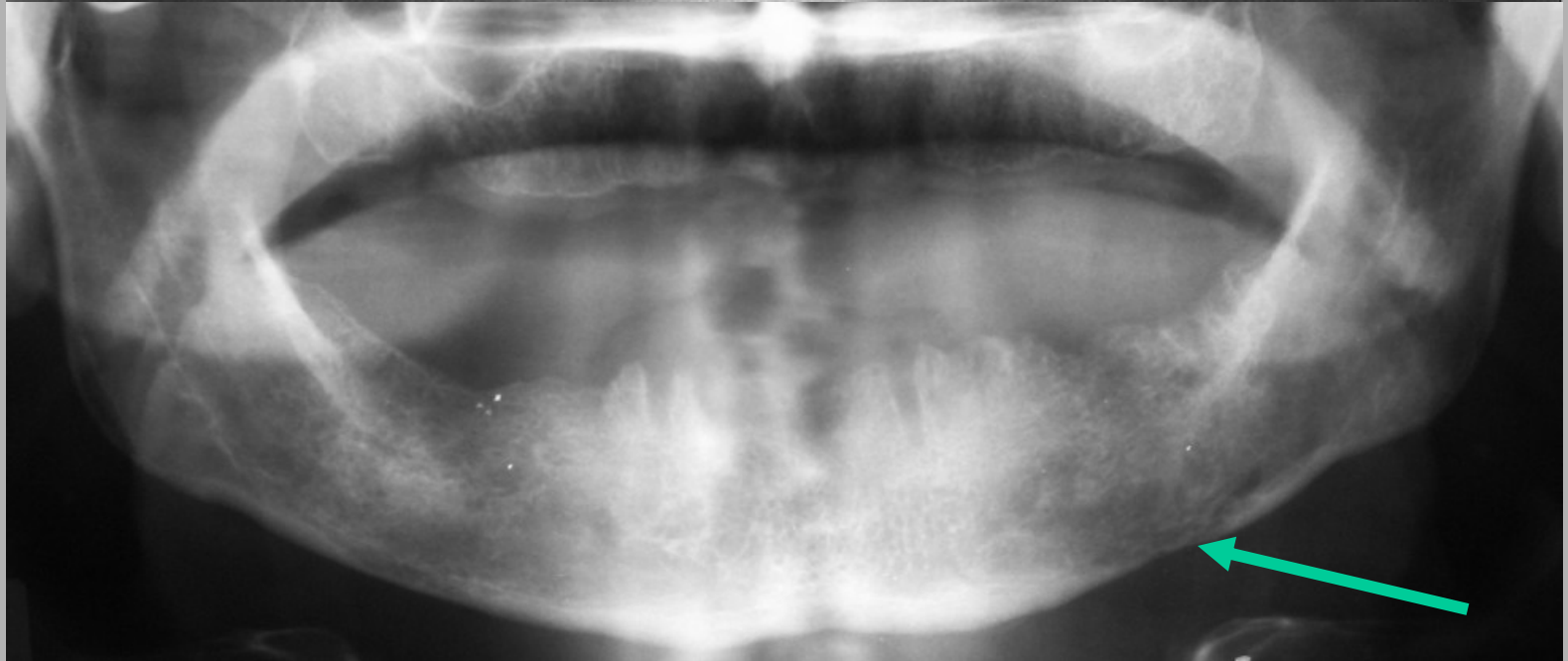
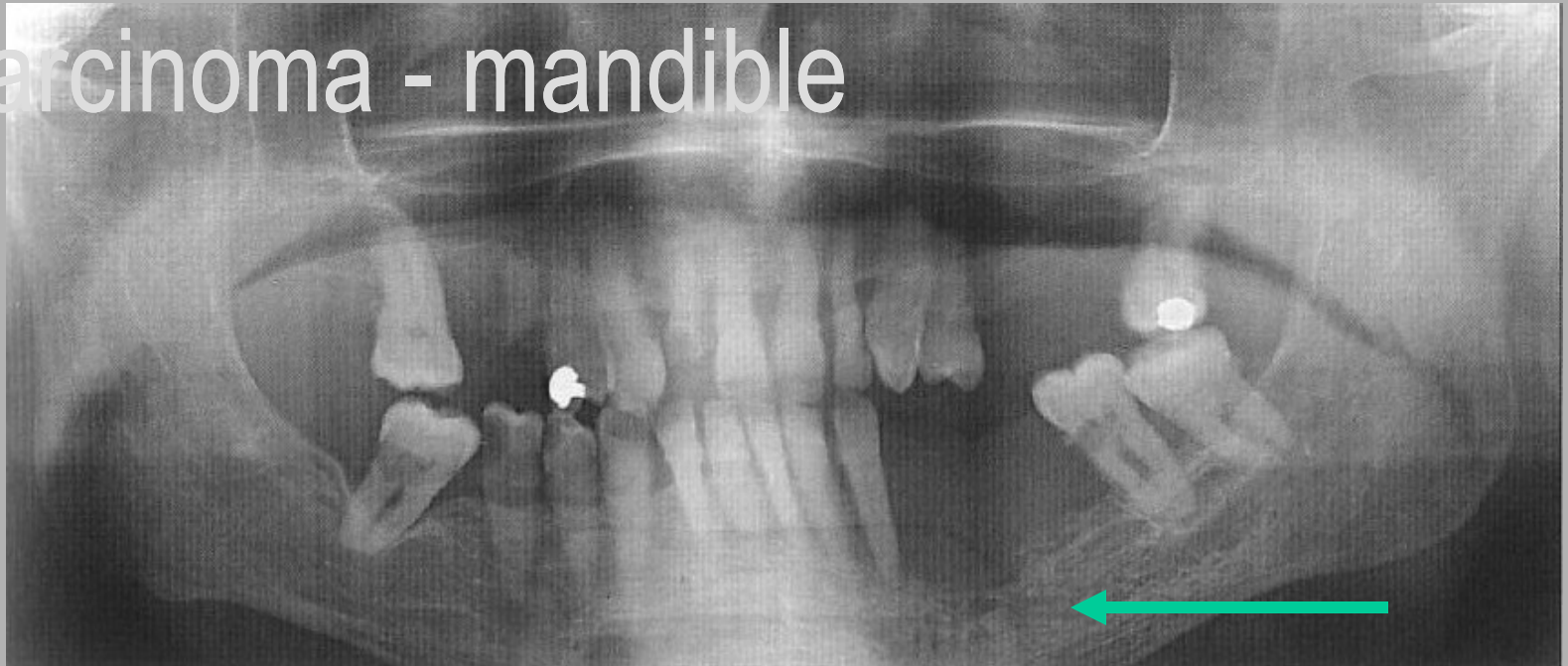

Carcinoma

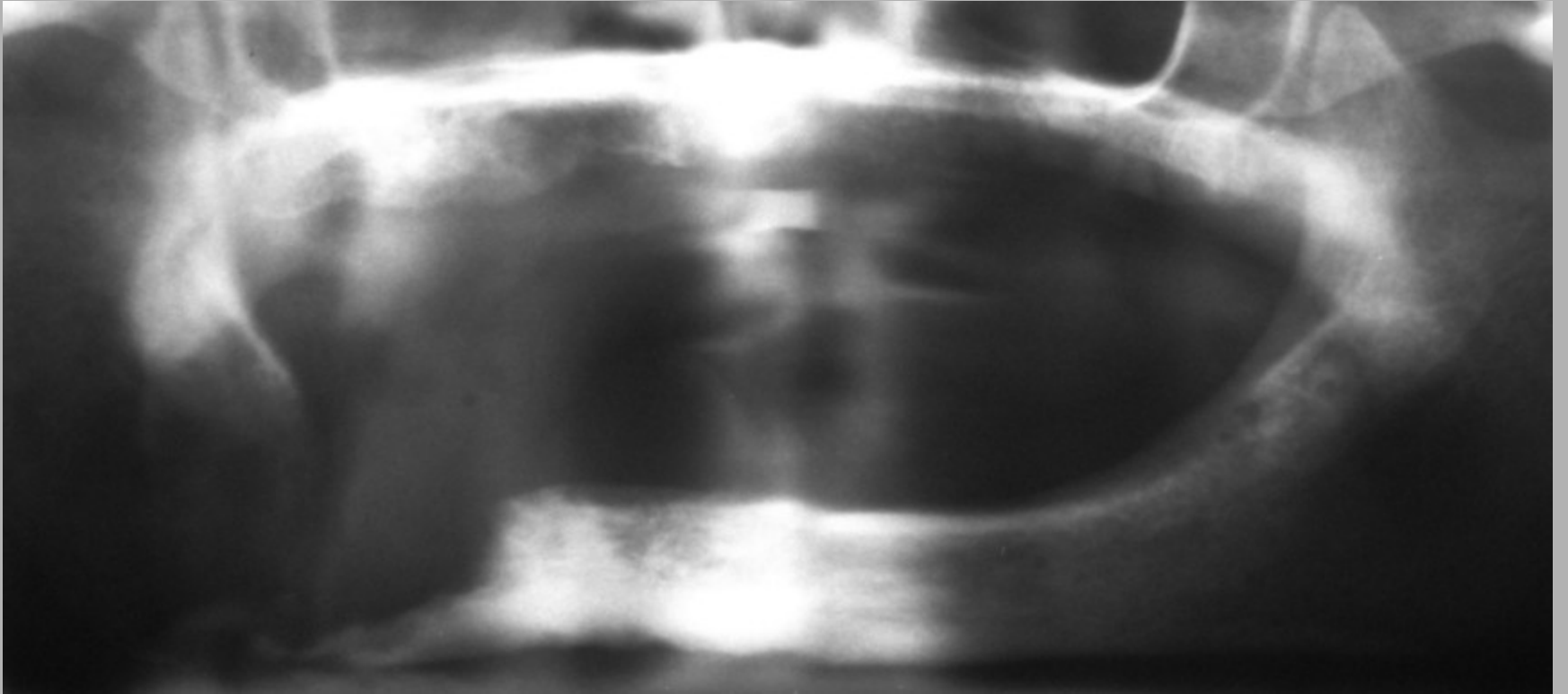
- the most often carcinoma of oral mucosa.
- intraepitelial mucosal carcinoma
- infiltration of:
 - adjacent bones
 - lingual part of mandible
- osteolysis
- paresthesis
- smokers, older age



Carcinoma - mandible

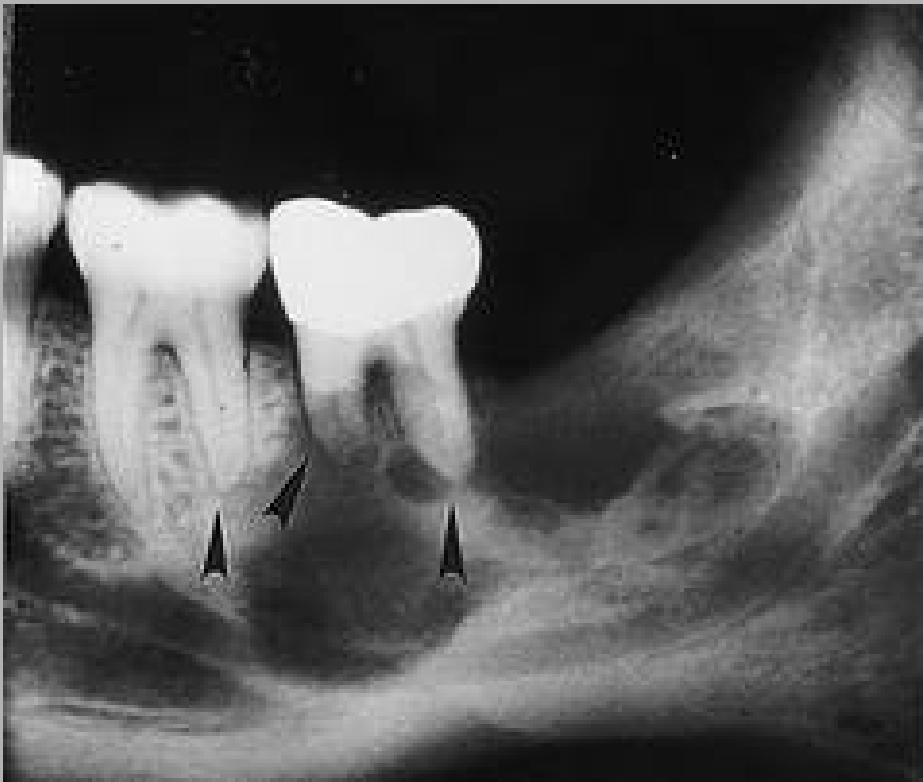

Carcinoma - bone lysis



Carcinoma - mandible

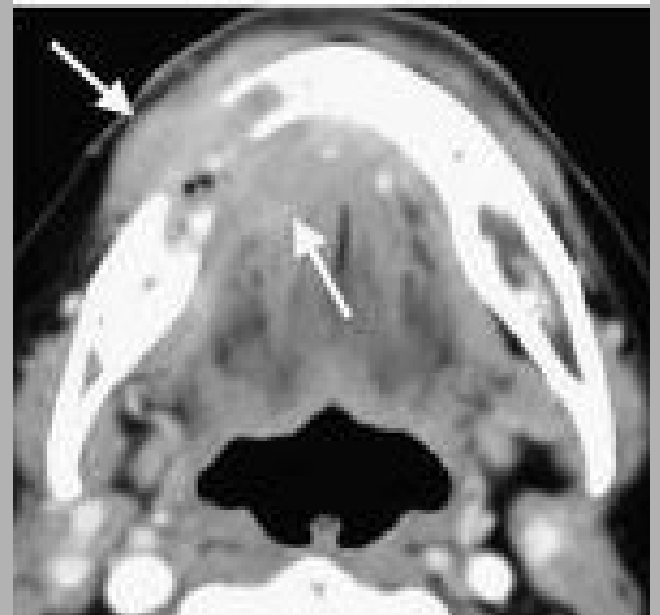
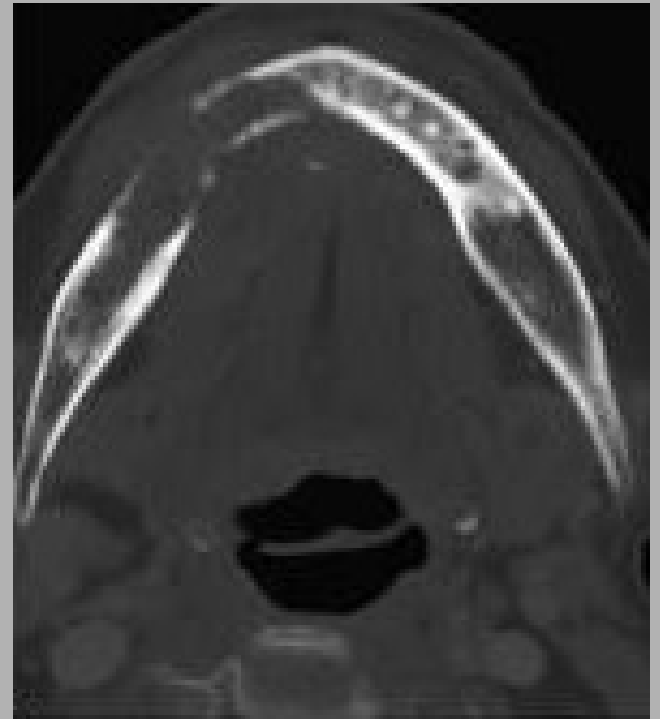
Mucoepidermoid carcinoma in posterior **mandible**



Carcinoma - mandible

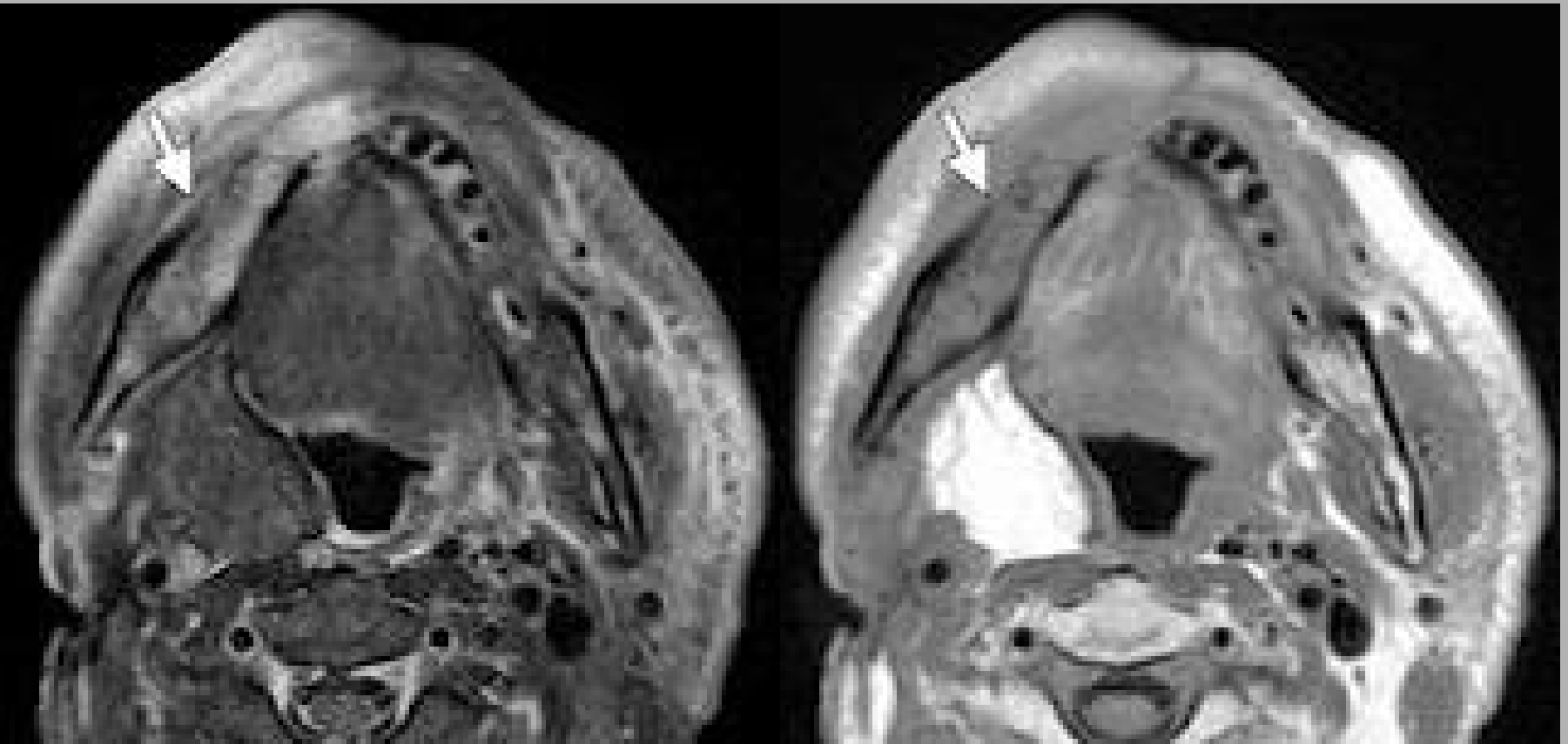
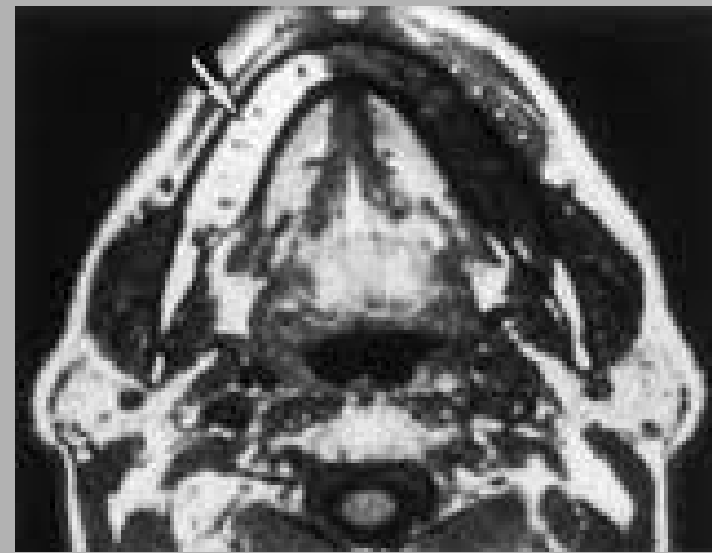CT

squamous carcinoma of
mandible



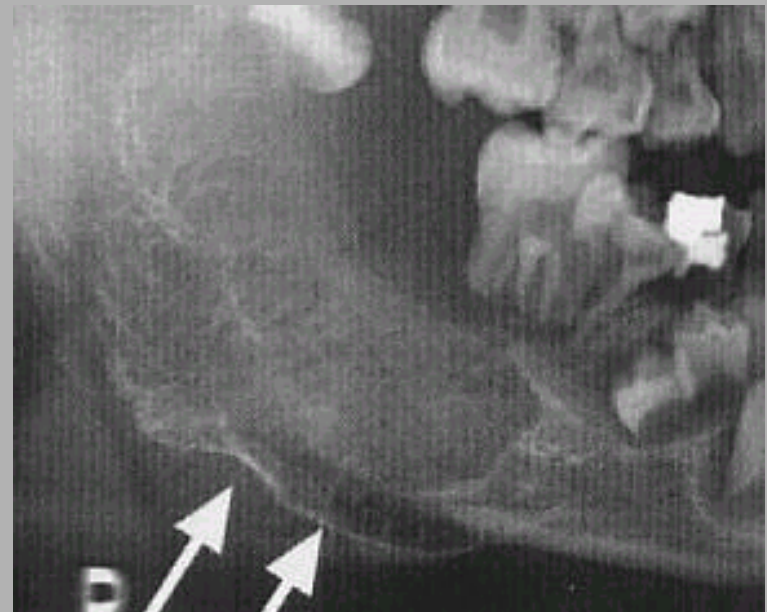
Carcinoma - mandible

Squamous cell carcinoma
70 y old man

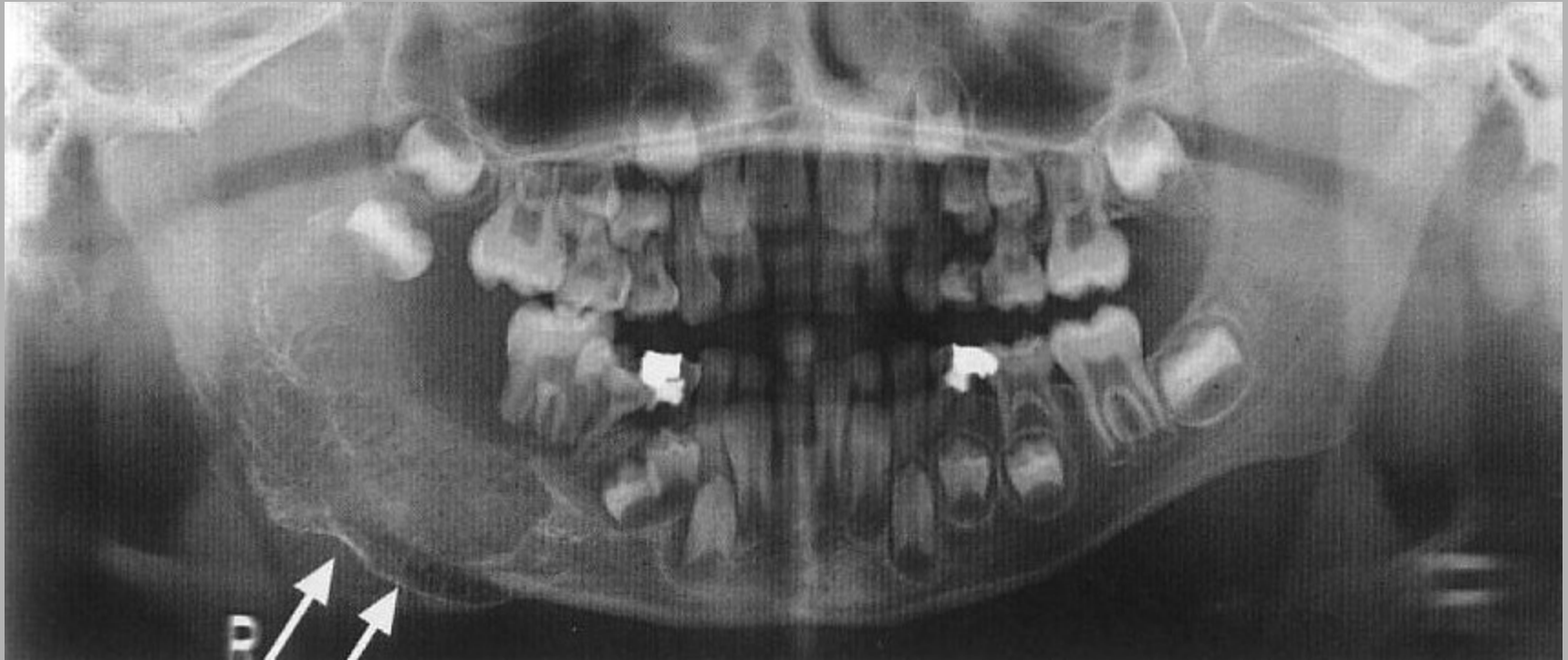


Ewing sarcoma

- children 10-20 y
- high grade malignant
- fast grow
- soon metastatis
- angle of mandible
- painfull
- X-ray: „slices of onion“
- Dif.dg.
 - osteosarcoma
 - endosteal hemangioma



Ewing sarcoma

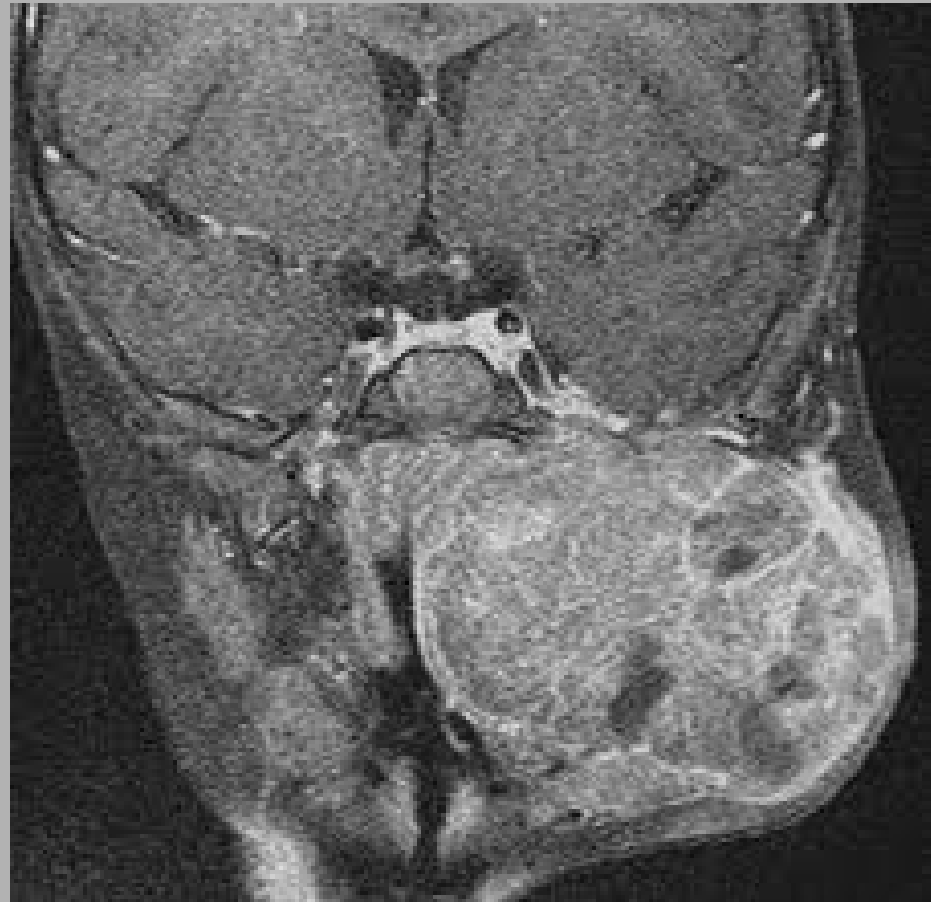


boy, 7 y
difficulty clinics
oedema of low jaw
movement of teeth
periostal reaction

Ewing sarcoma

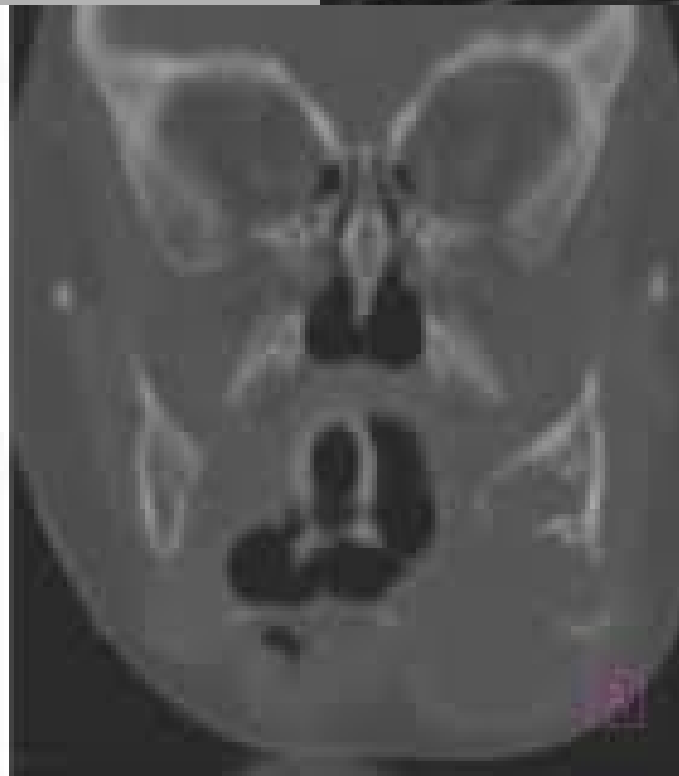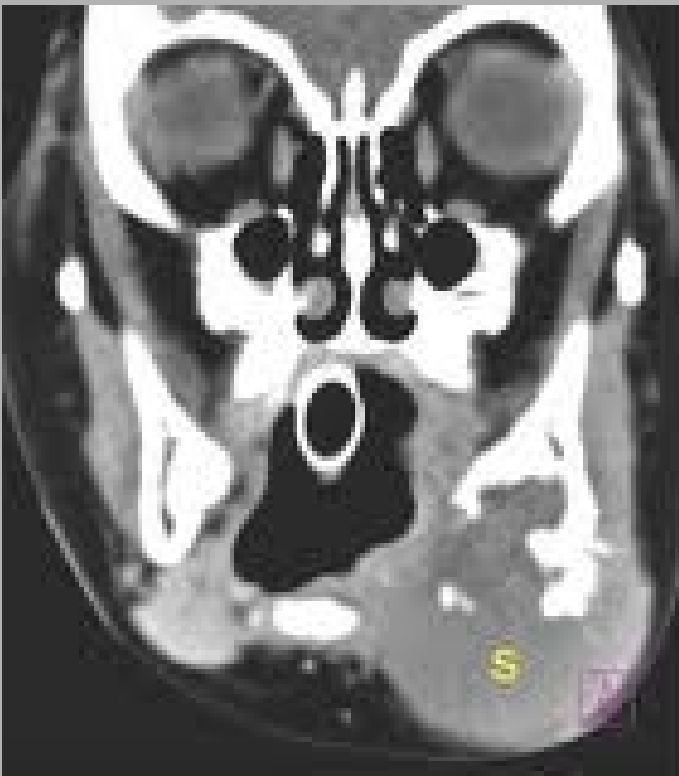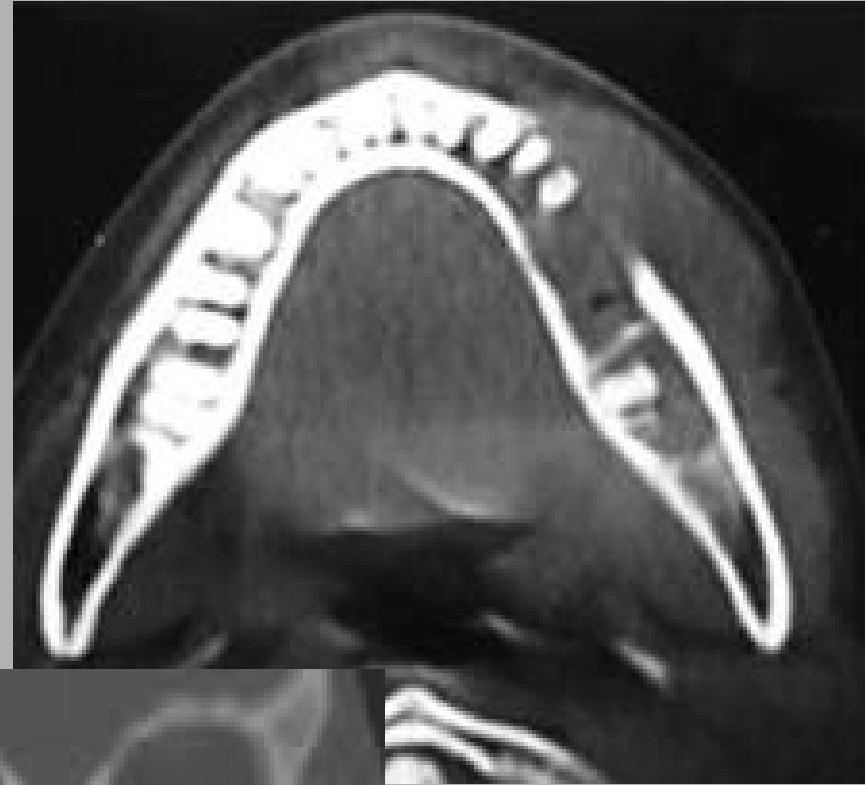
gold diagnostic standard
MRI

Ewing sarcoma.
Axial T1-weighted
MR image



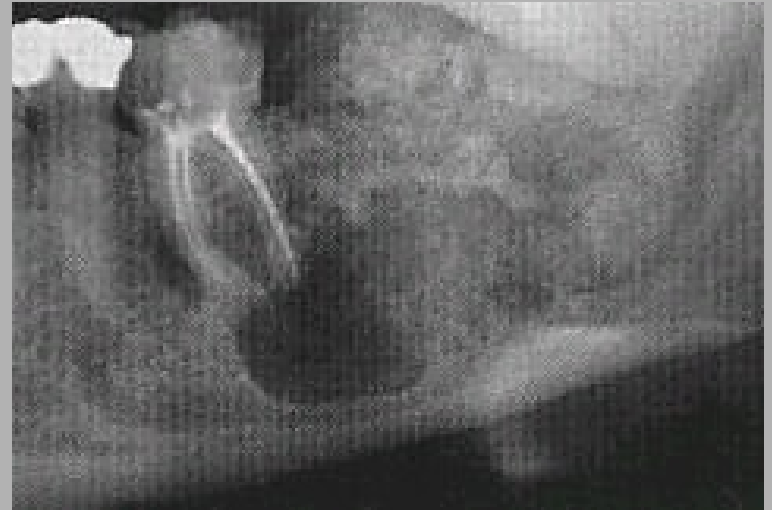
Ewing sarcoma

Ewing sarcoma.
Axial and coronal
CT image



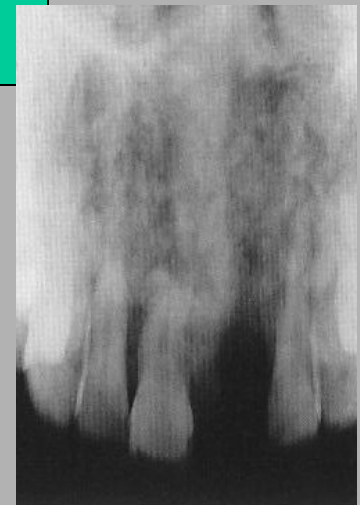Osteosarcoma

- 2. and 3. decennium
- mesenchymal tumor
- histologic
 - osteoblasts
 - chondroblasts
 - fibroblasts

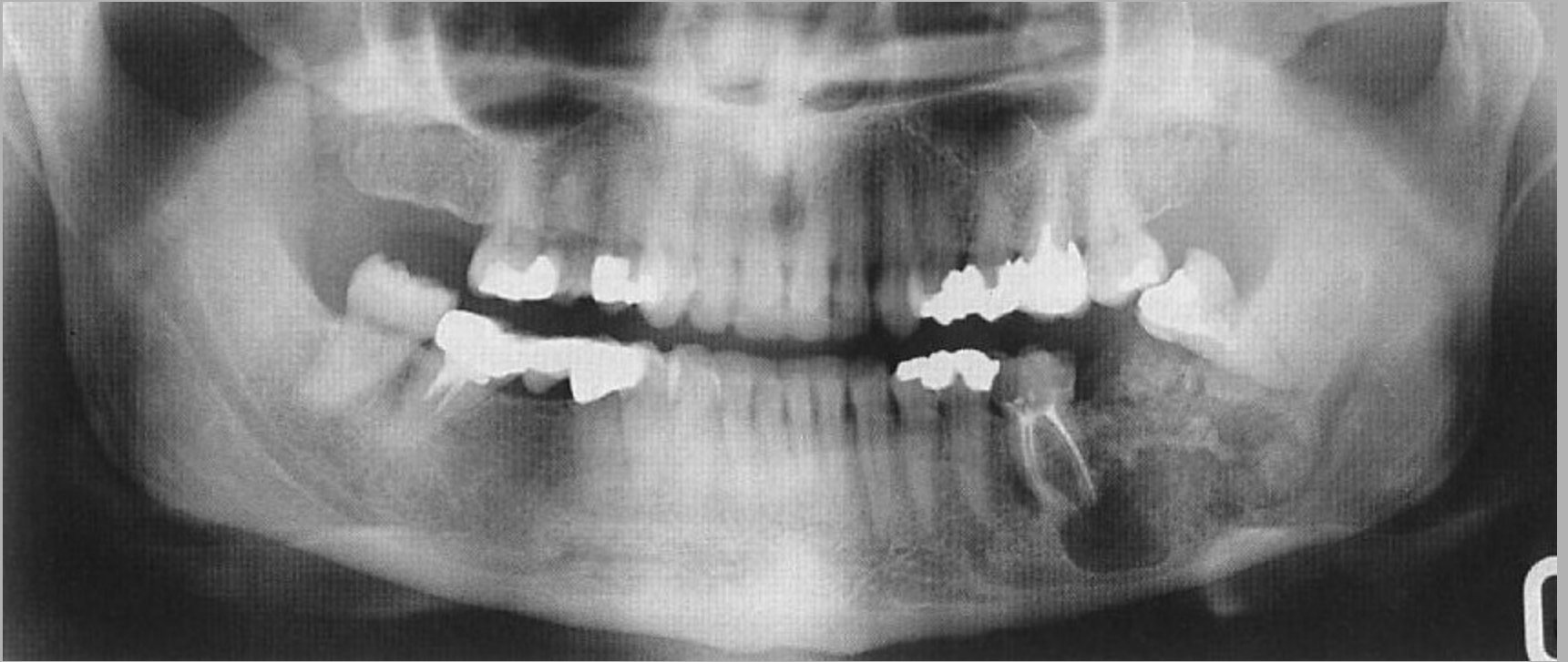


RTG

- osteoblastic + osteolytic
- various image

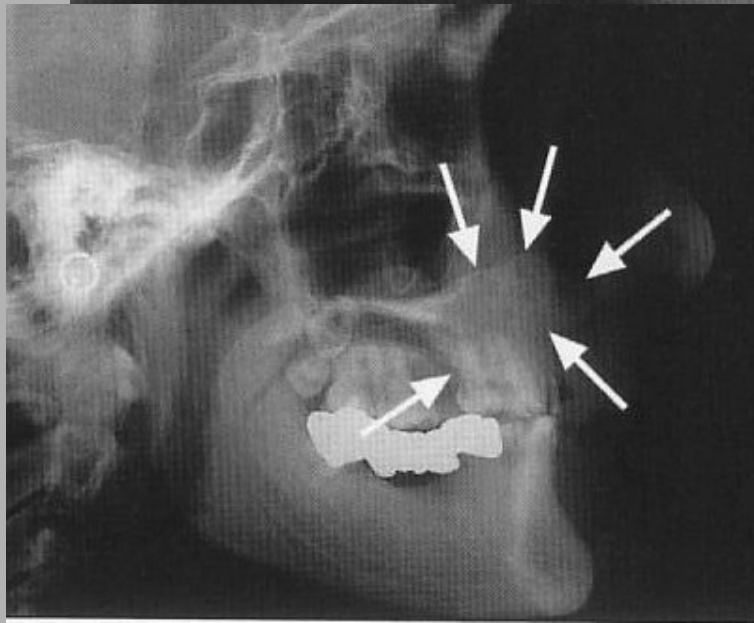
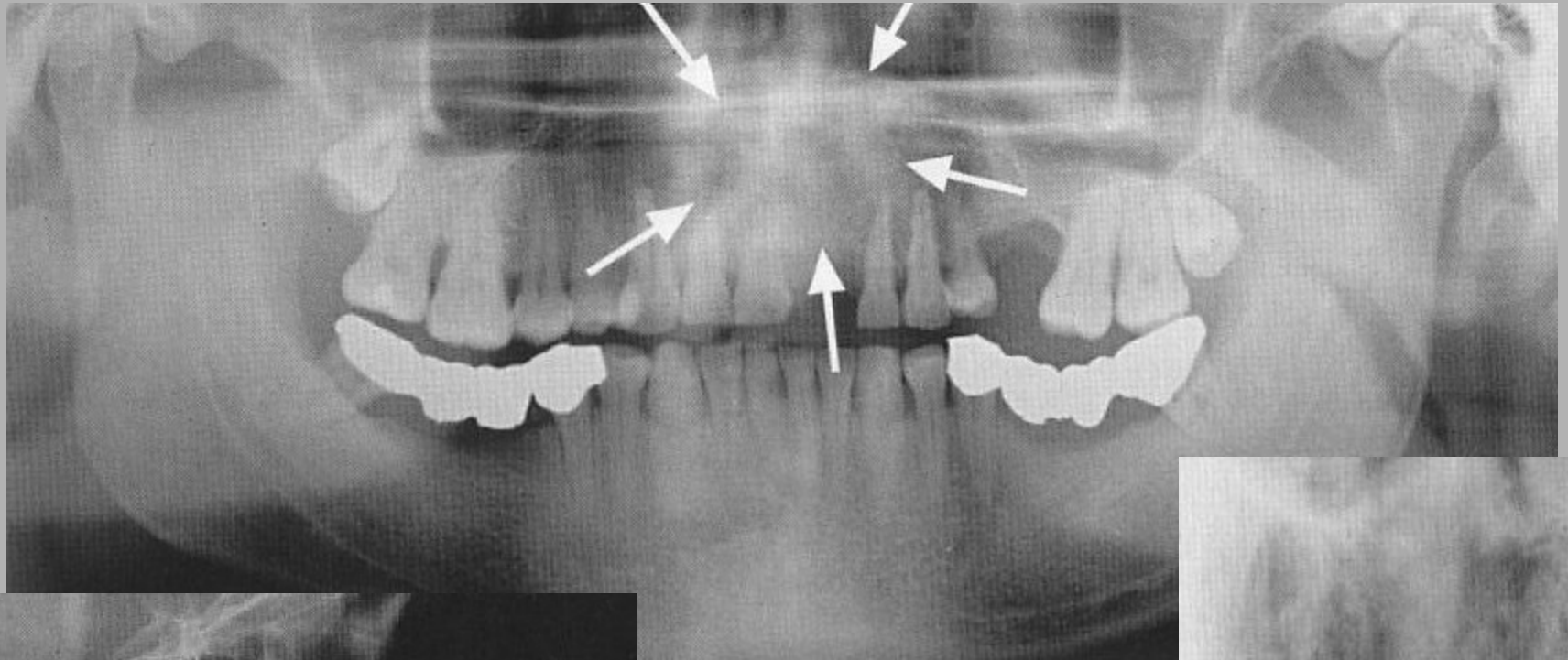


Osteosarcoma

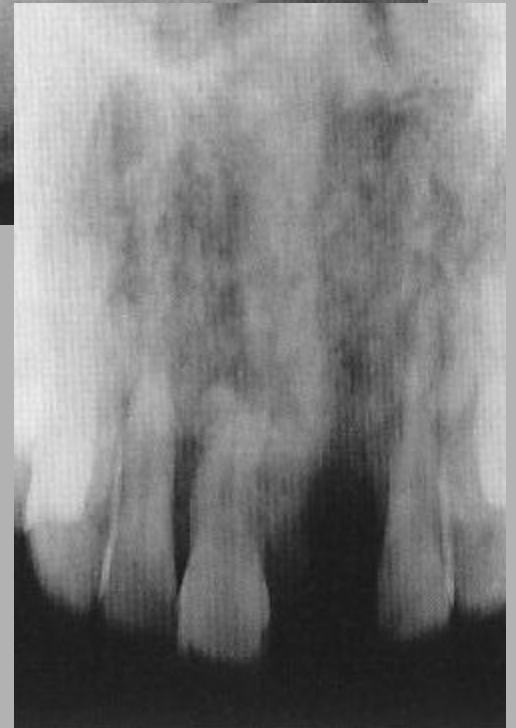

female, 29 y

Osteosarcoma

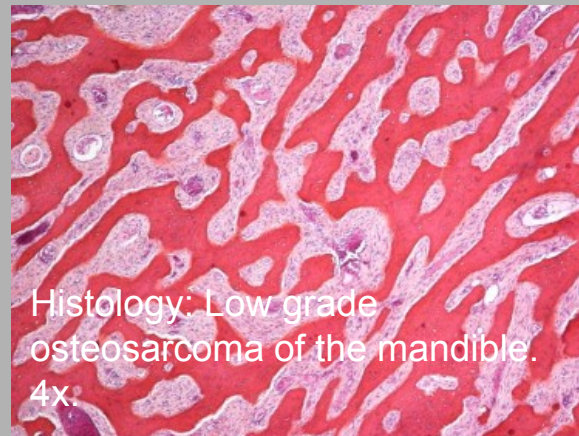
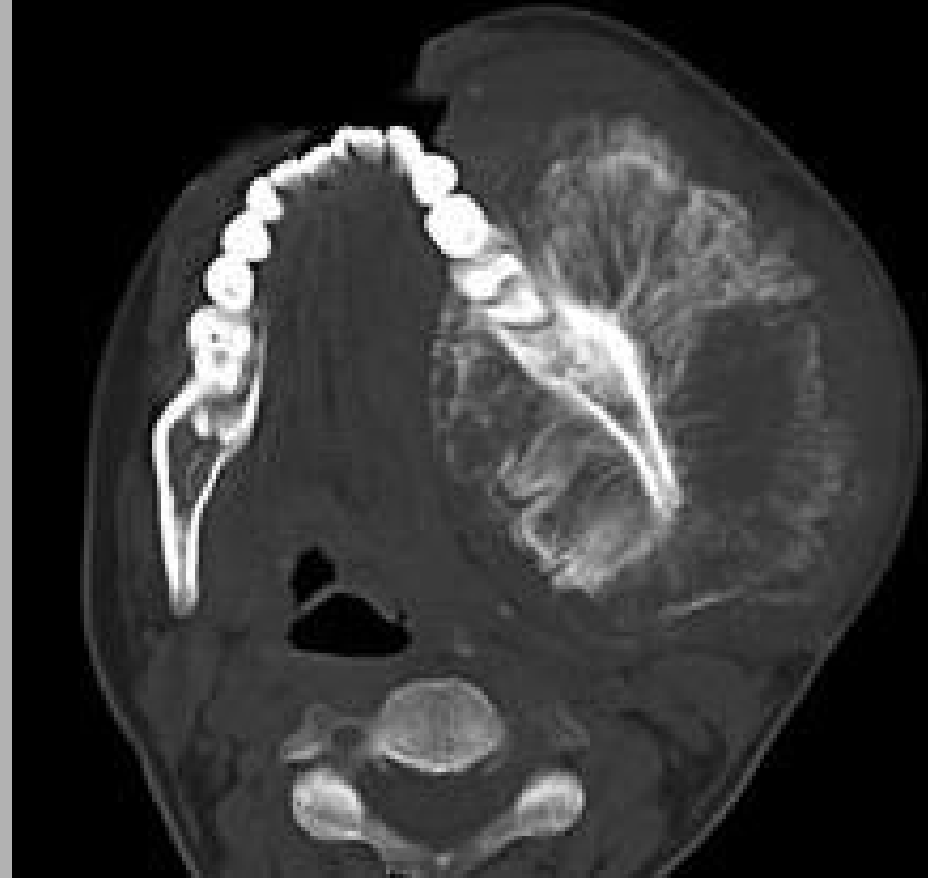
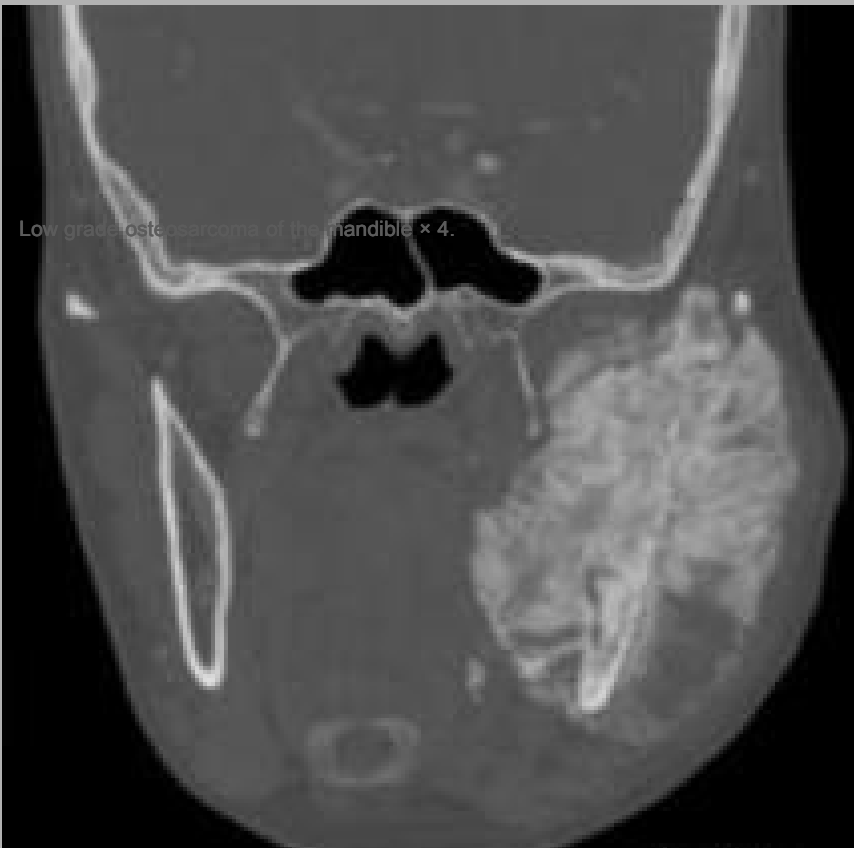male, 40 y

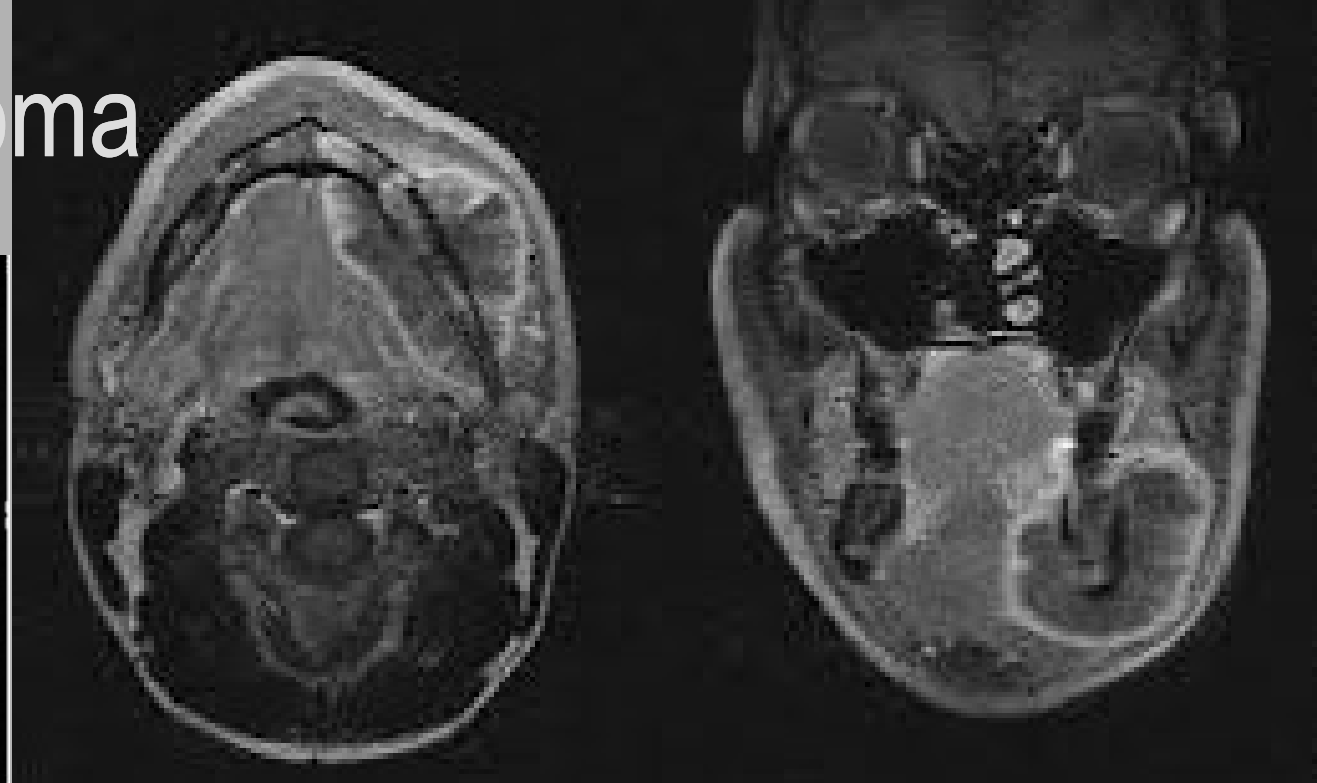
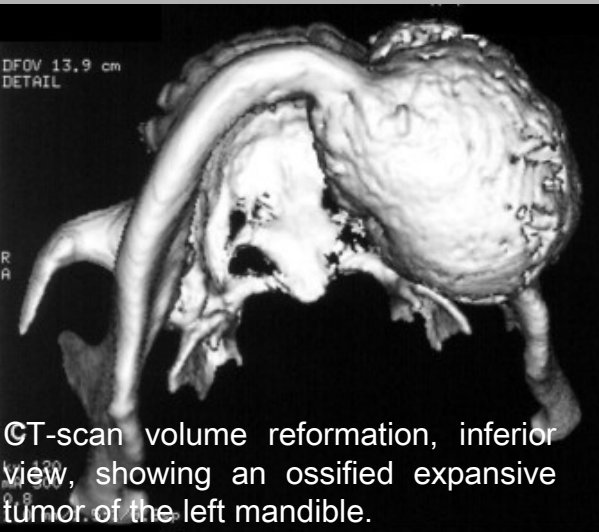


Osteosarcoma

Axial and coronal
CT image



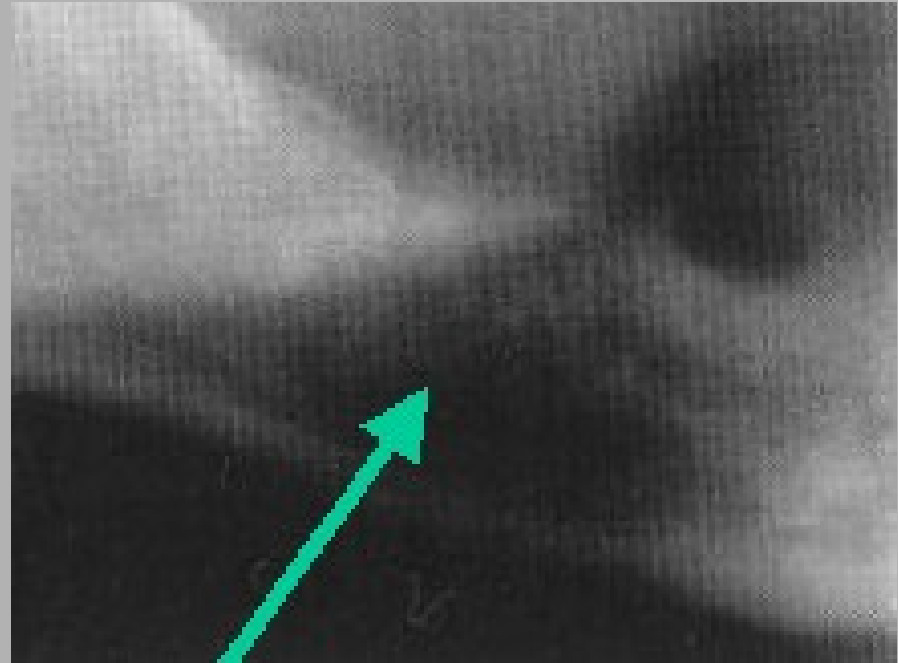
Osteosarcoma



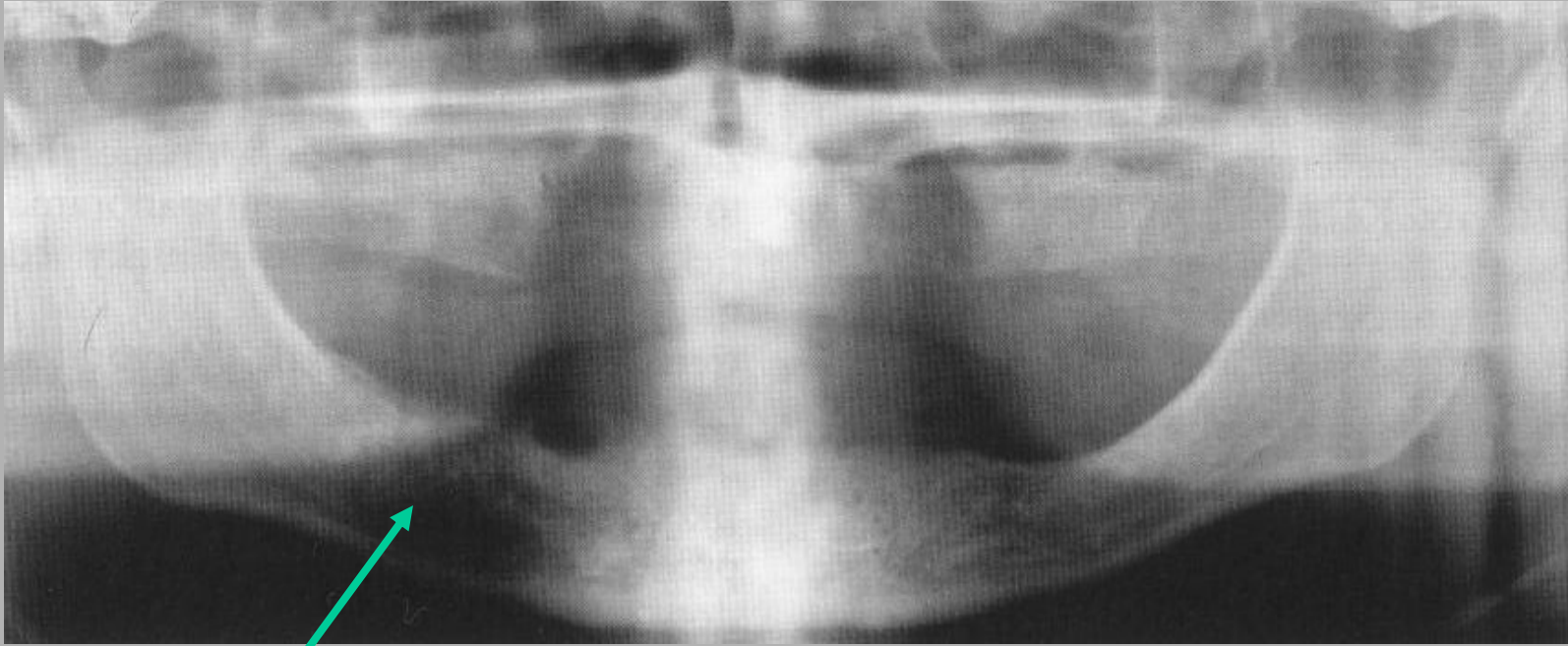
20 year-old woman with left high grade mandibular osteosarcoma. MRI axial and coronal FSE T1-weighted sequence after gadolinium injection showing a well defined juxtacortical mass (tumor bone formation) developed along the surface of the left mandible. This mass is hypointense with mild peripheral rim enhancement. The cortical of the mandible is interrupted and the medulla shows heterogenous enhancement indicating tumor invasion.

Metastasis

- carcinomas of:
 - mamma
 - lung
 - gl. thyreoidea
 - prostate
- blood spread
- clinics:
 - pain in the bones
 - „reasonless“ teeth release
 - paresthesis of lower lip
 - pathological fracture
- suspicion = scintigraphy

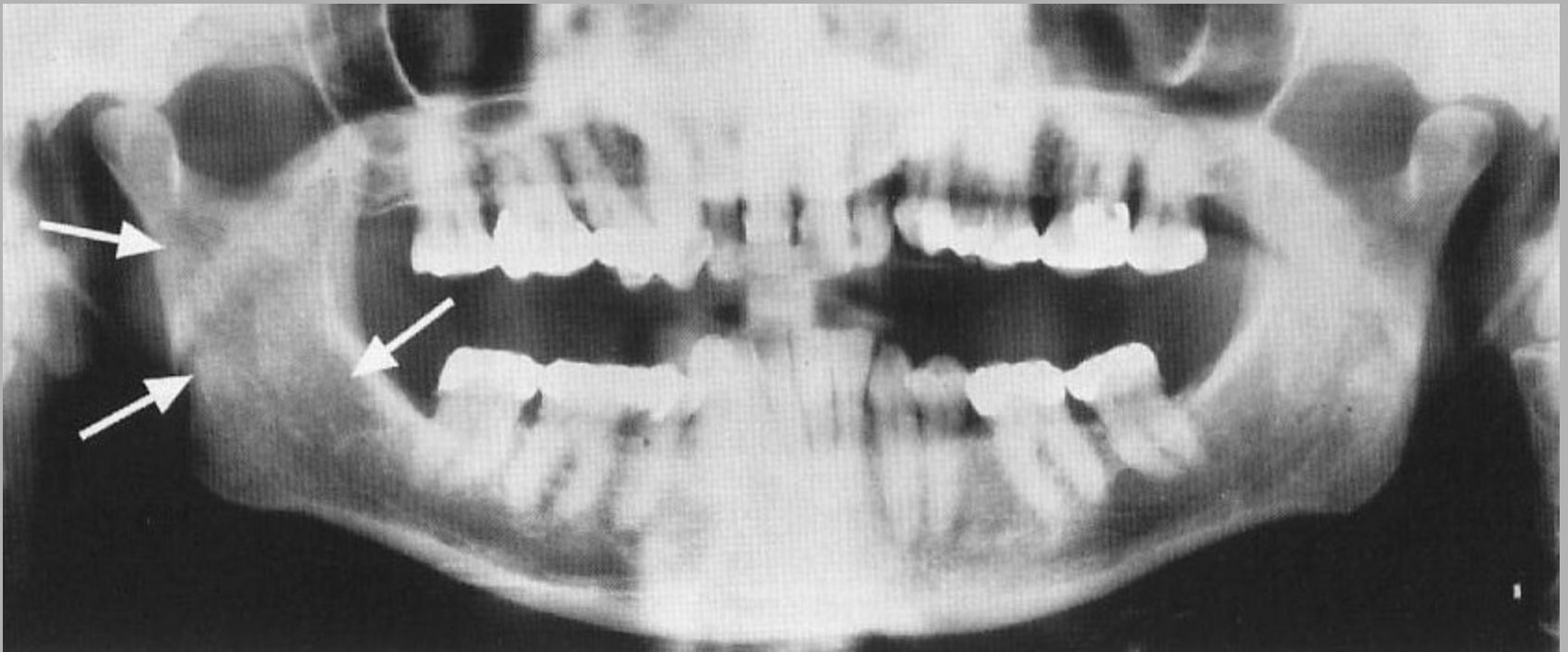


Metastasis



- male, 69 y
- prostate carcinoma
- transparency

Metastasis

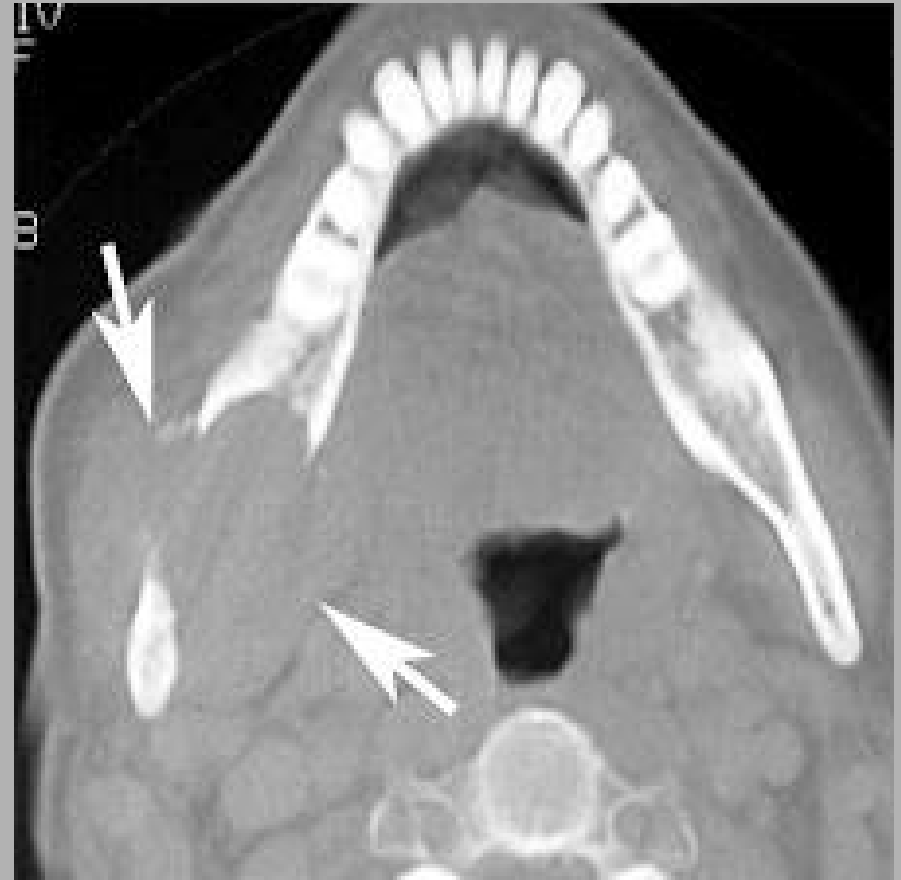

- bowel carcinoma
- spotted, blurred

Metastasis

Metastatic hepatocellular carcinoma in a 61-year-old man.

Contrast-enhanced CT scan demonstrates an expansile, osteolytic mass (arrows) within the right mandibular body.



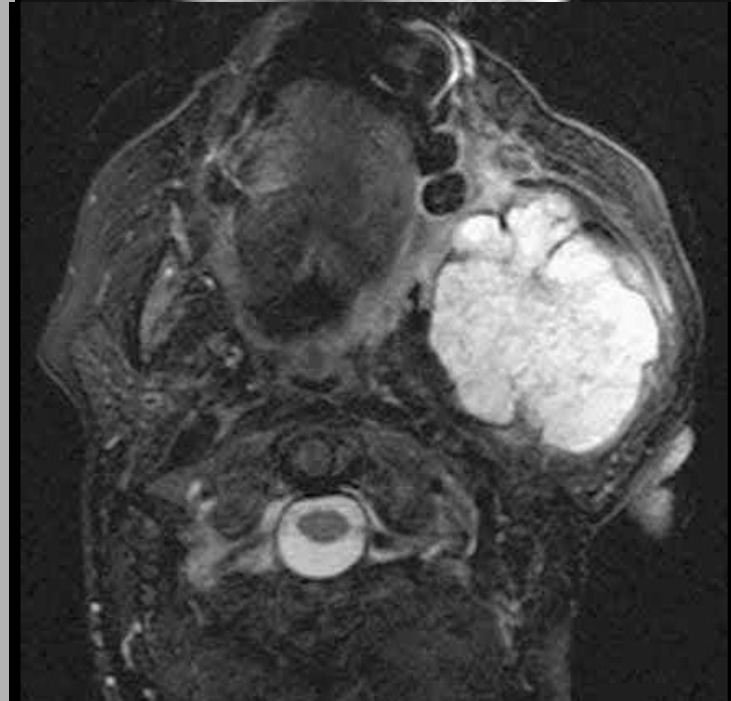
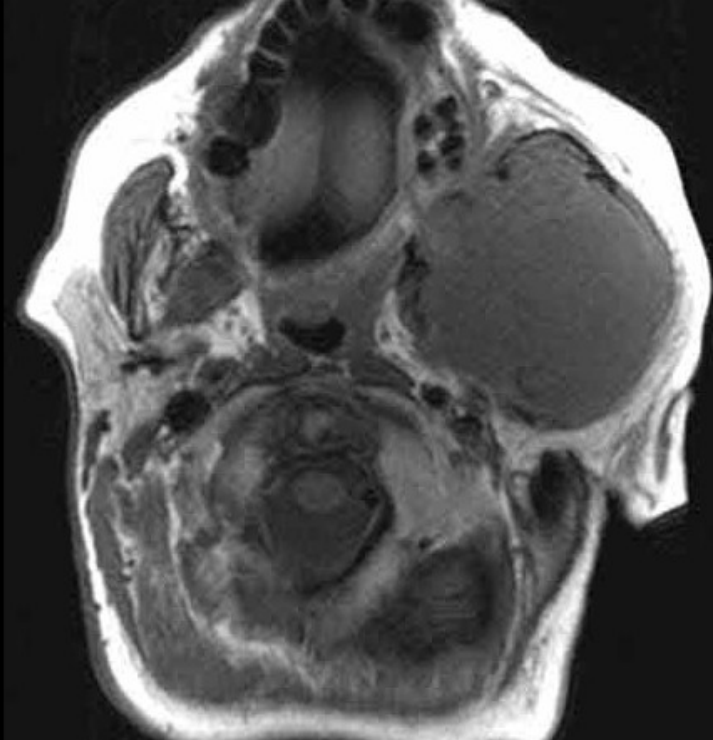
Metastasis

Mandibular metastasis from
colonic adenocarcinoma

T1-weighted axial

T2 FS axial

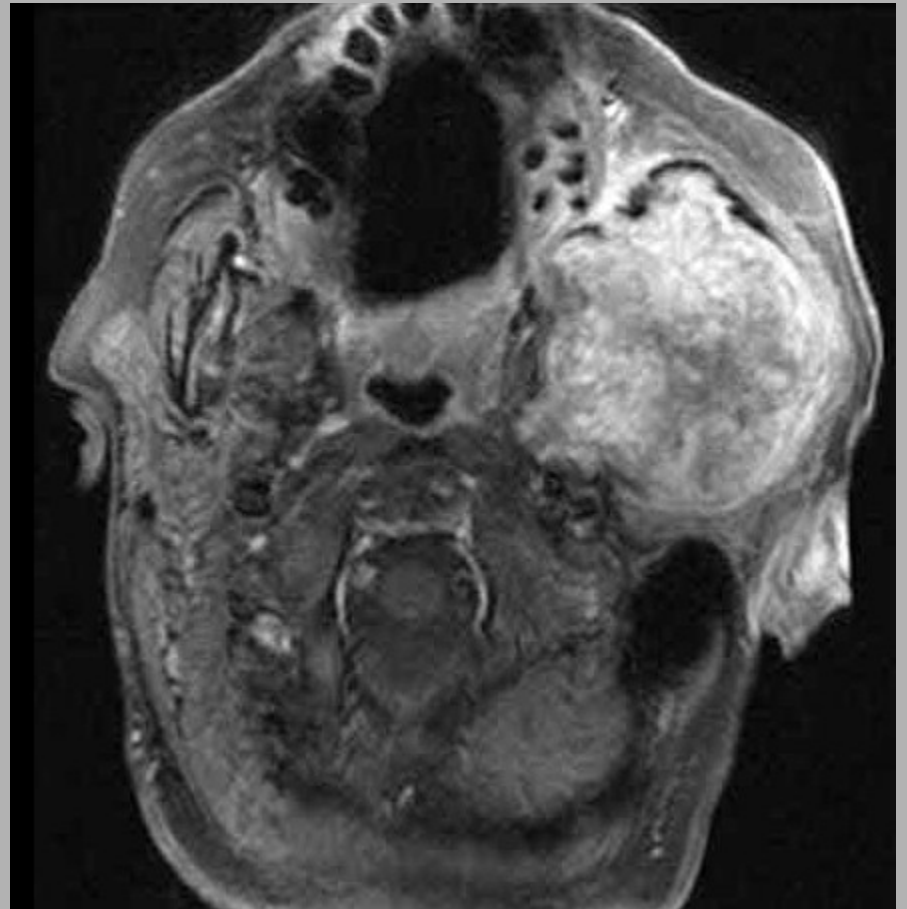
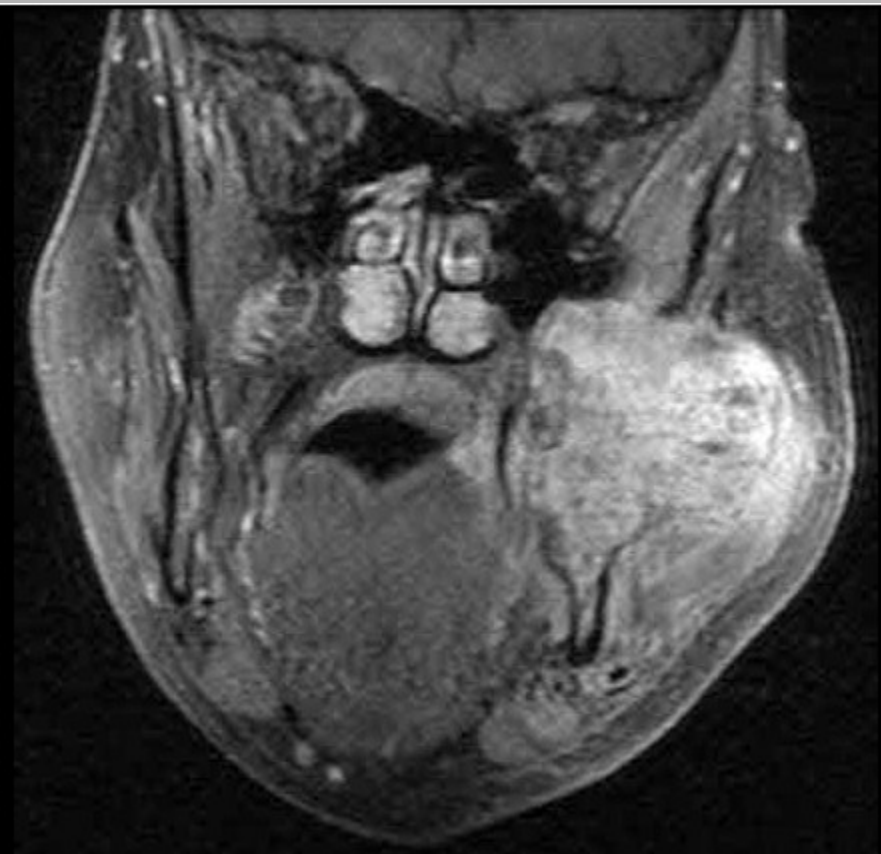A 63-year-old female with history of adenocarcinoma of the colon initially presented to her physician with a swollen left parotid gland. Presumptive diagnosis of sialadenitis was made and the patient was treated with antibiotics. After no response to antibiotics, MRI was performed. Subsequently a fine needle aspiration of the left mandibular mass was performed demonstrating malignant cells derived from adenocarcinoma with mucinous features similar to prior pathology slides of patient's colonic adenocarcinoma.



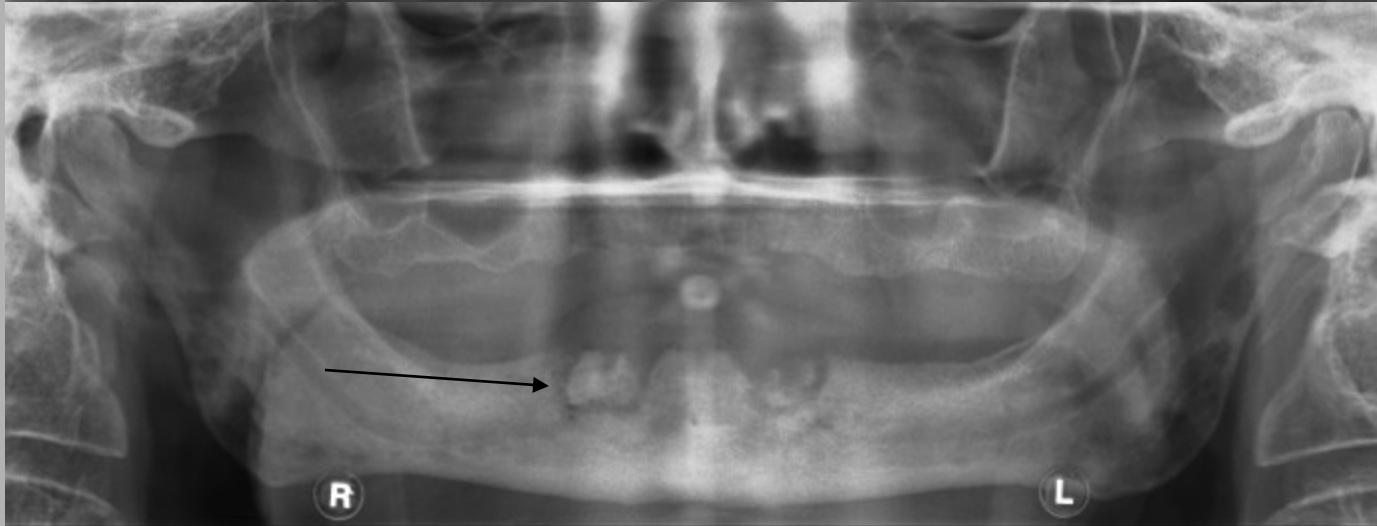
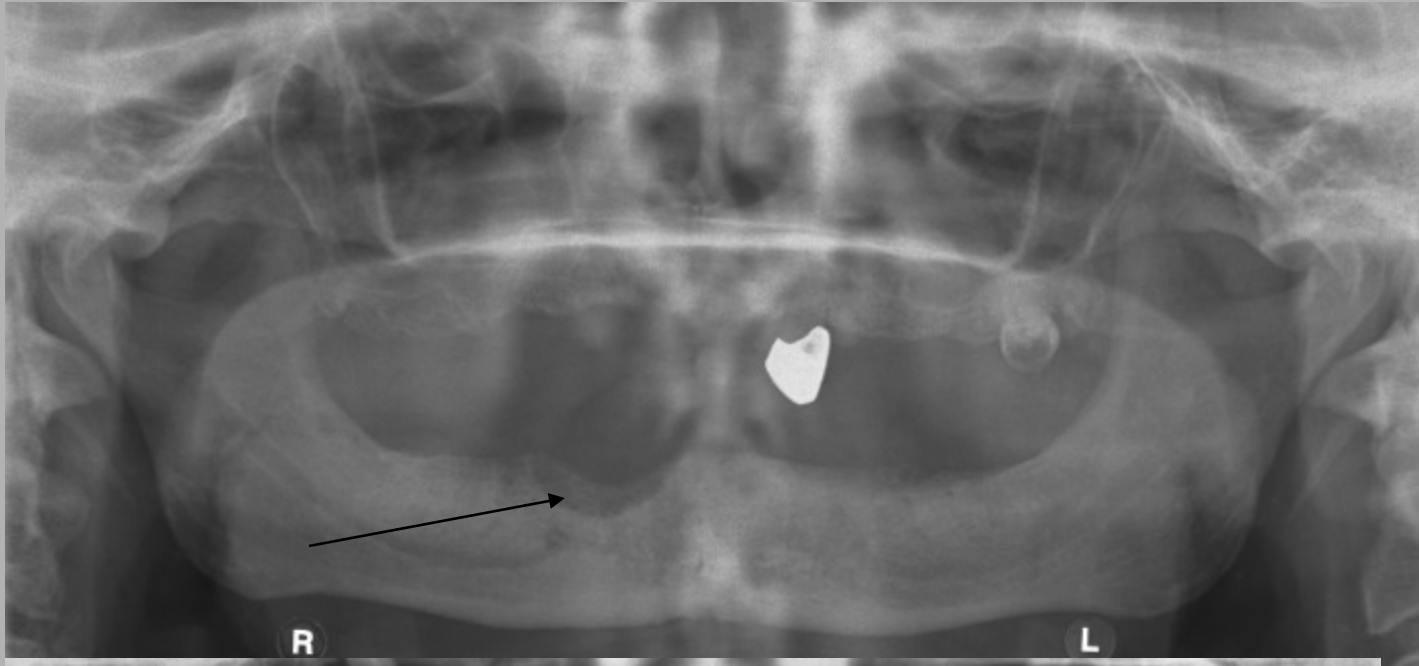
Metastasis

Mandibular metastasis from colonic adenocarcinoma

MRI - post-contrast T1

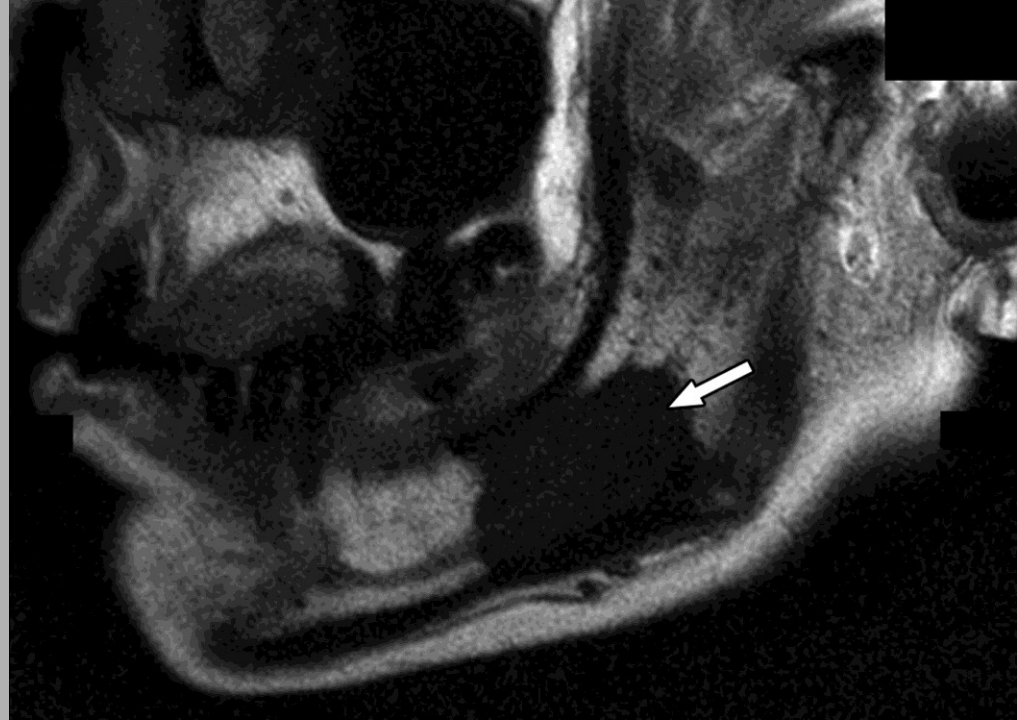

Osteonecrosis mandibulae



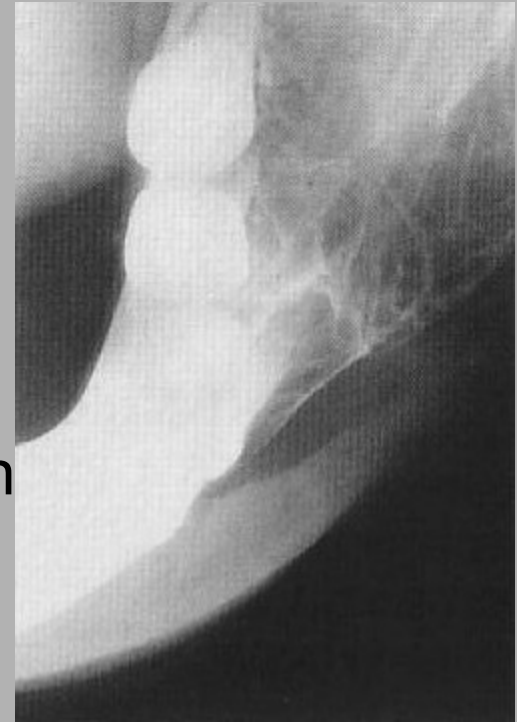Osteonecrosis mandibulae - MRI

- 51-year-old woman with breast cancer.
- Oblique sagittal T1-weighted image shows focal lesion of osteonecrosis (*arrow*) affecting mandibular branch and involving mandibular canal.



Odont. myxoma

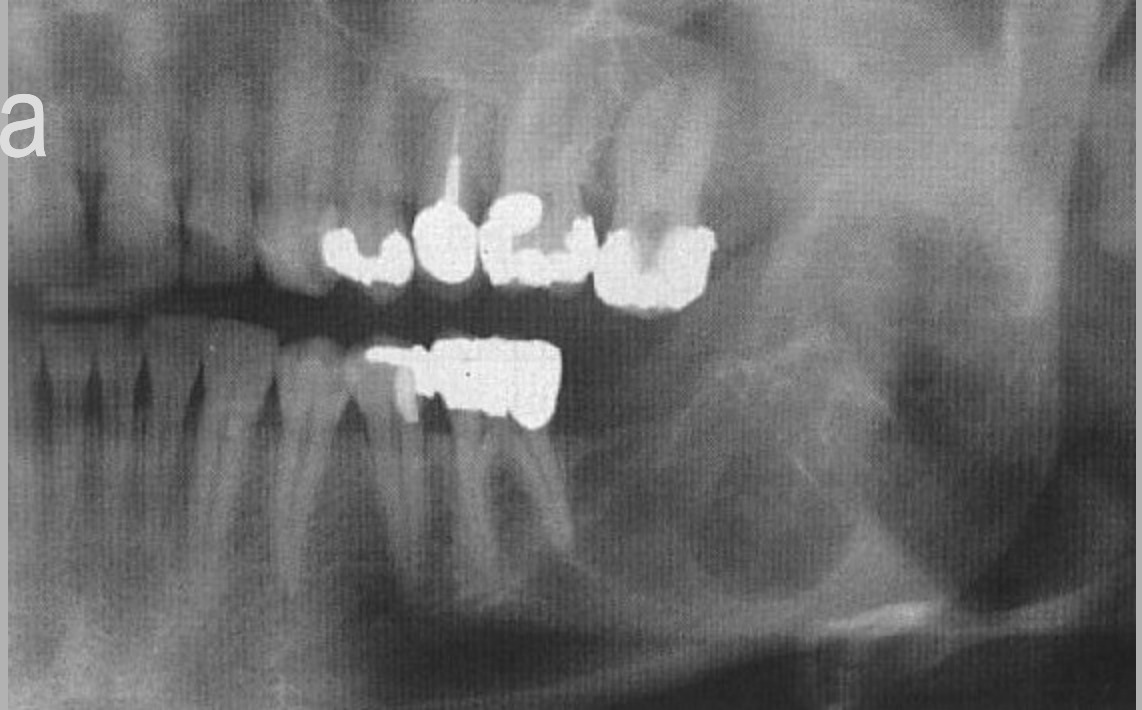- age 10-50 years
- female/male 1:1
- jaws (only)
- most often in lower jaw - caput of man
- growth
 - fast
 - endosteal
 - muscle infiltration (occasionally)
- good bounded, irregular translucency
- often relaps



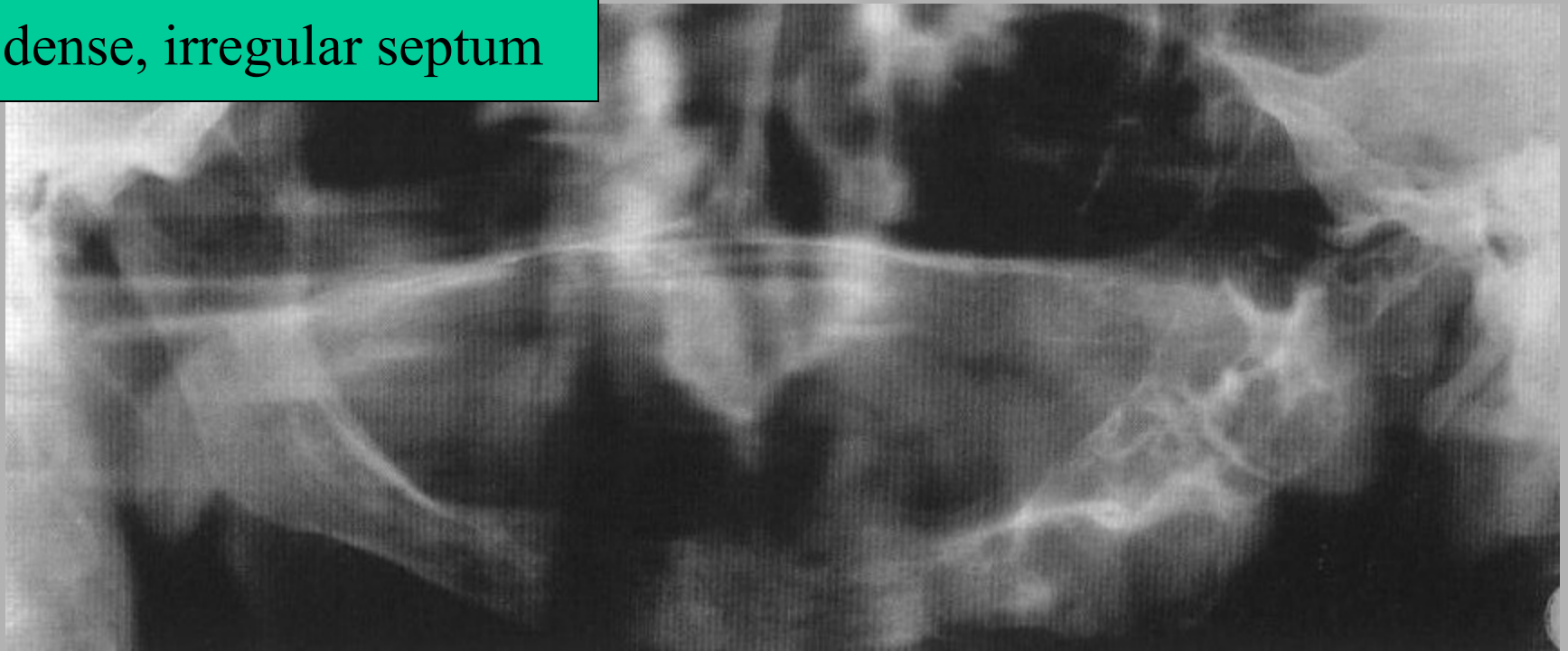
Odont. myxoma

female, 34 y

structure - net

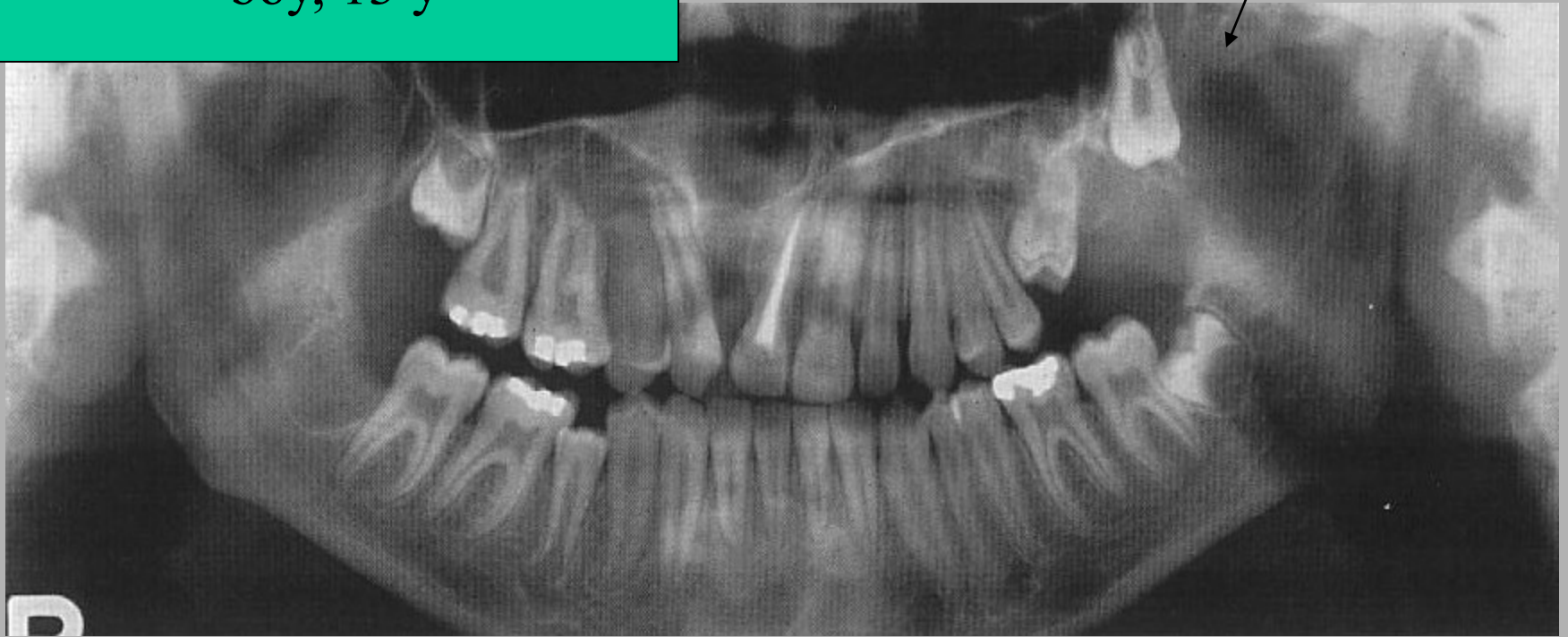

dense, irregular septum



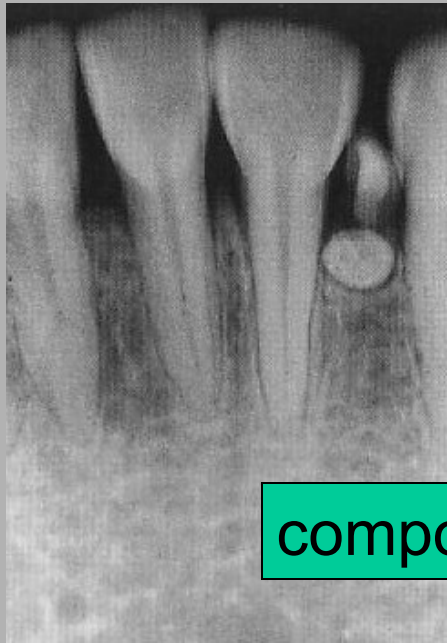Odont. myxoma

boy, 13 y

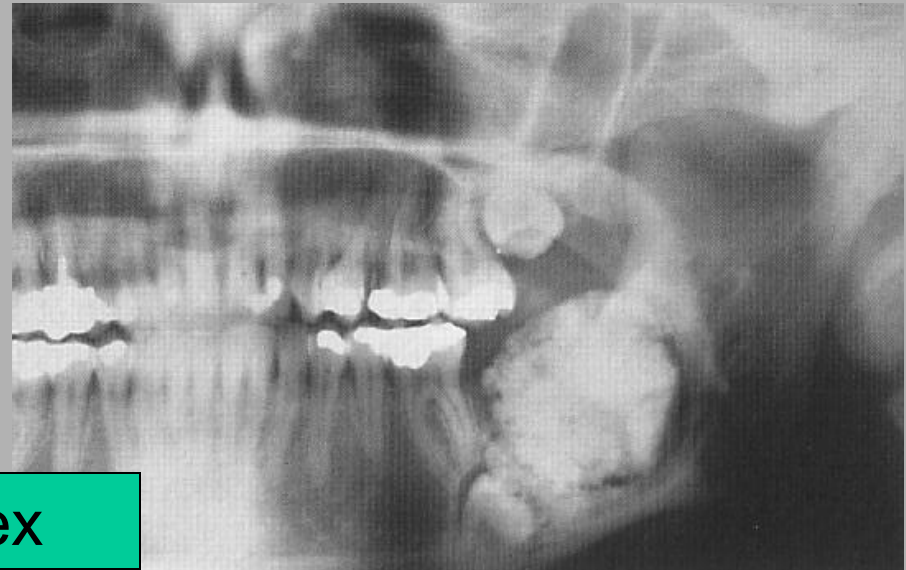


Odontoma

- similar to the hamartomas
- conglomerate of various tooth tissues
 - composite odontoma
 - ✓ contains several developed teeth
 - complex odontoma
 - ✓ contains basic tooth tissues in amorphous mass



composite



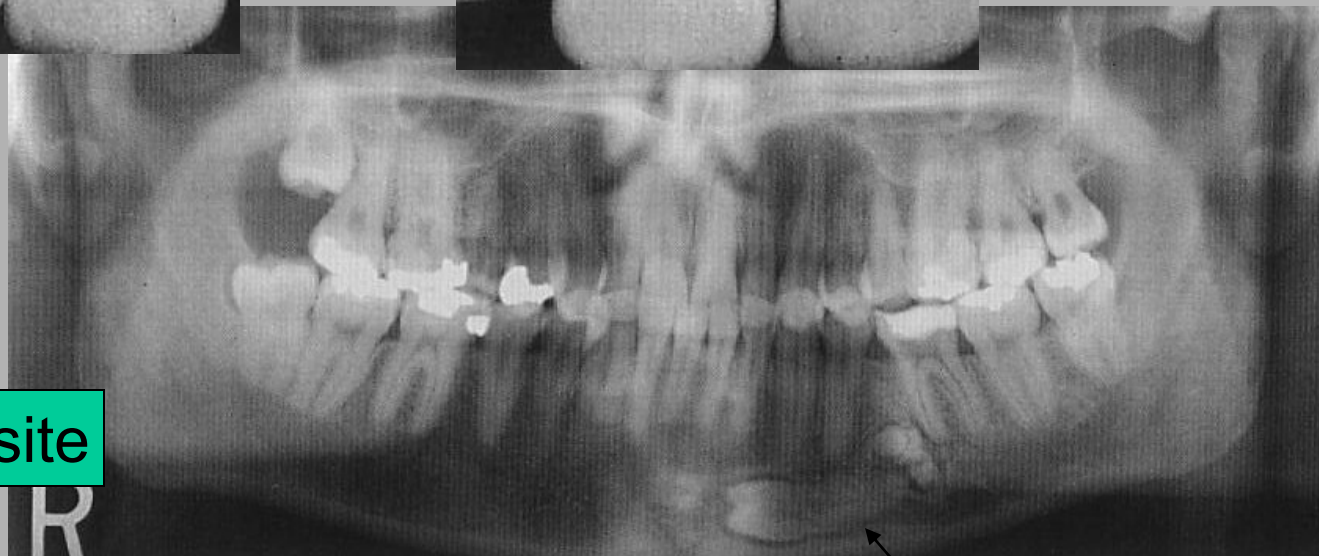
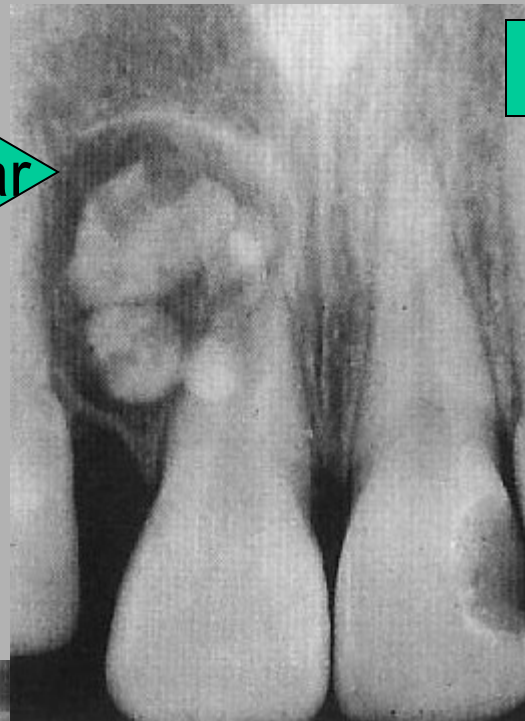
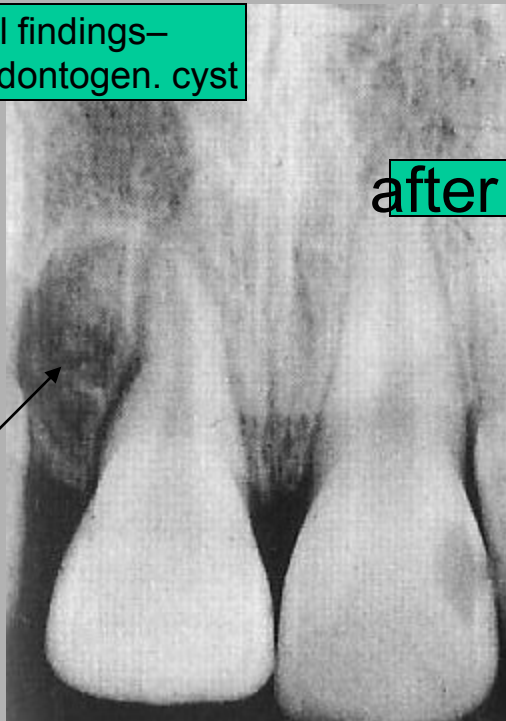
complex

Odontoma

incidental findings—
susp. calc. odontogen. cyst

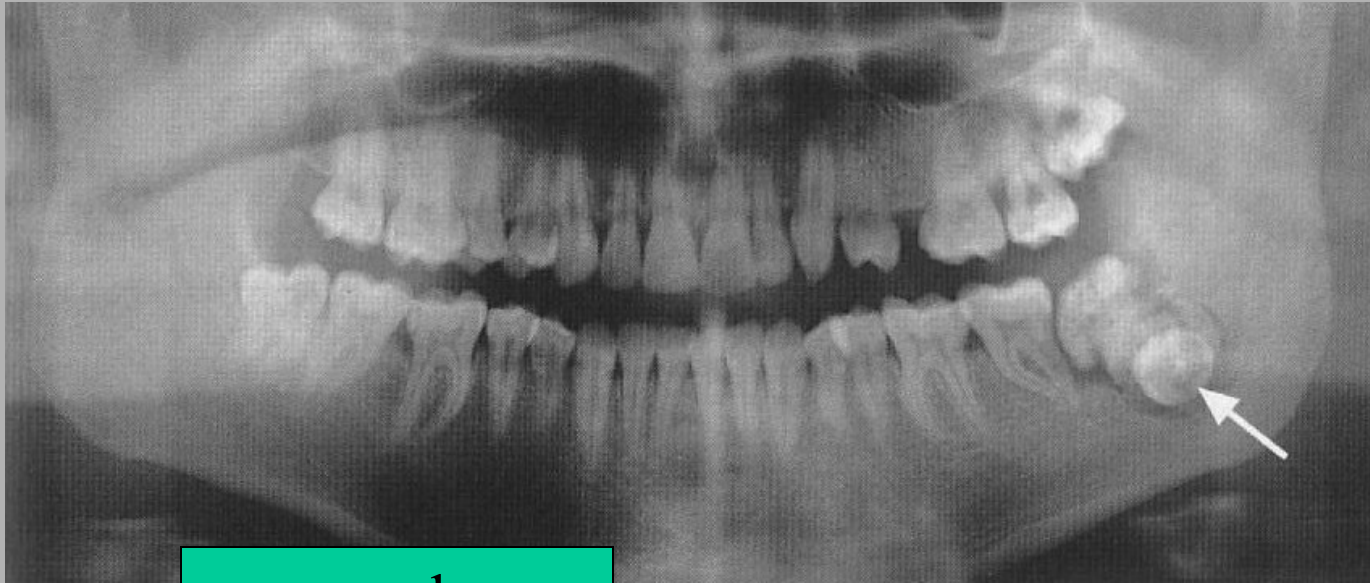composite

after 2,5 year

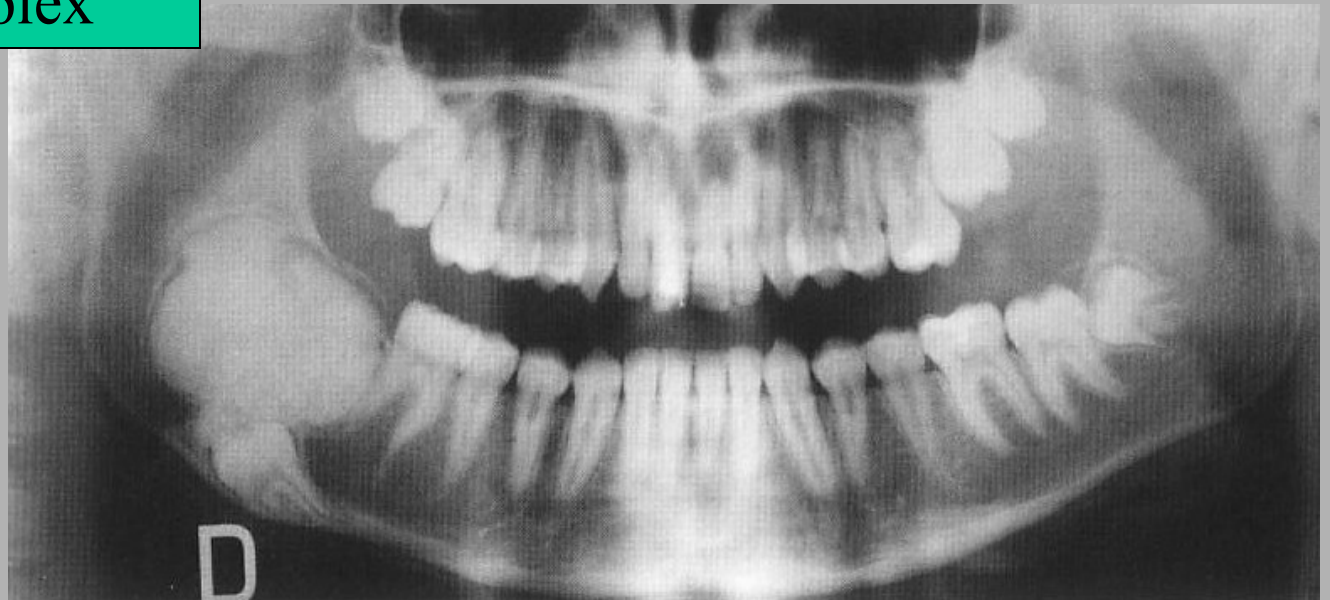


composite

Odontoma

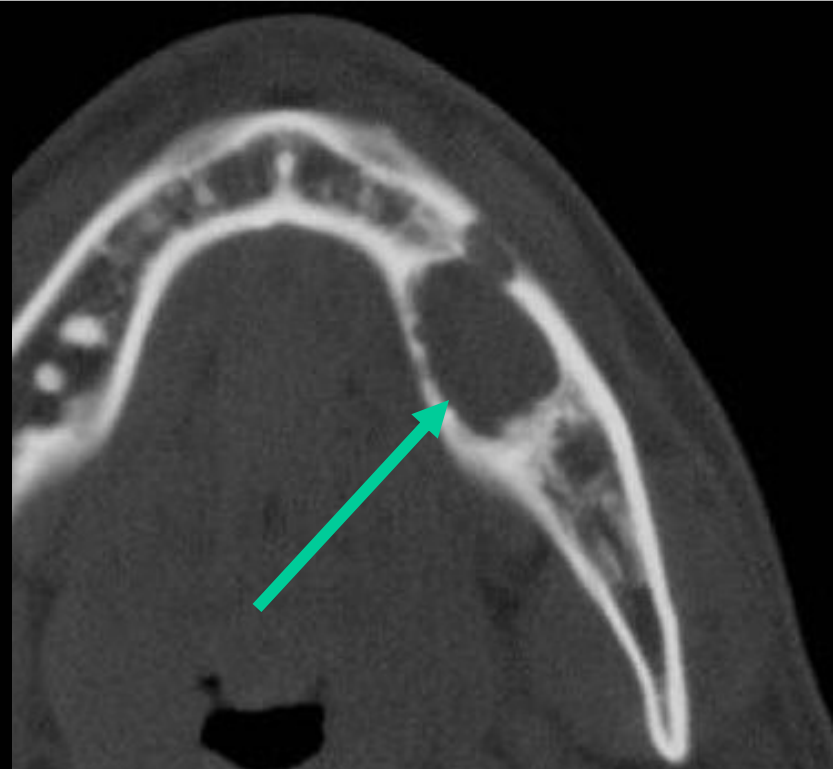
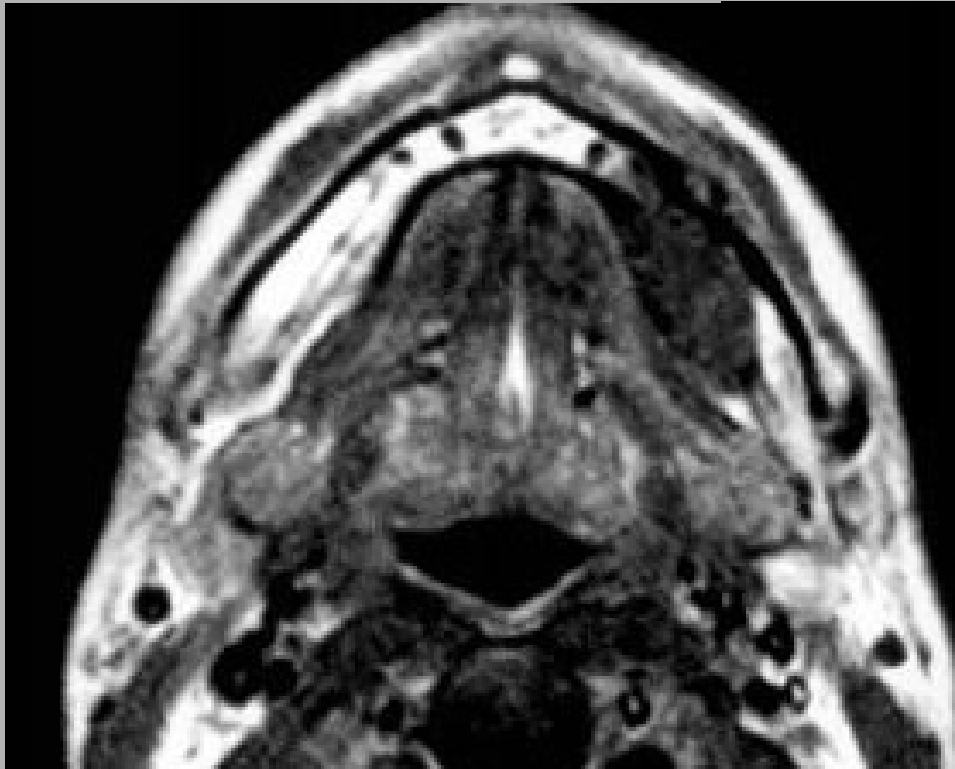


complex



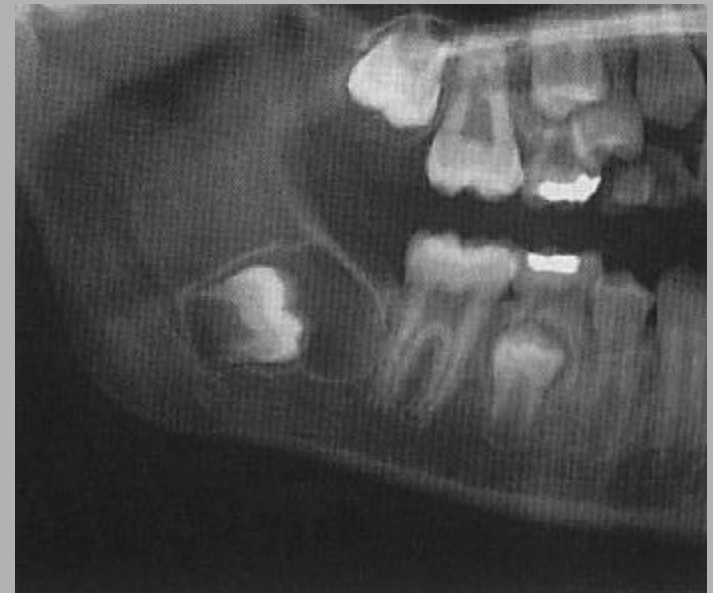Fibroma

- **Fibromas** (or **fibroid tumors** or **fibroids**) are benign tumors that are composed of fibrous or connective tissue.



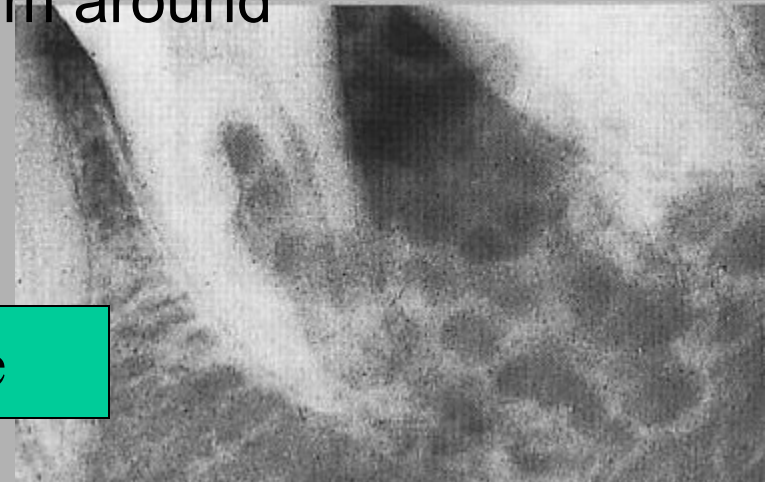
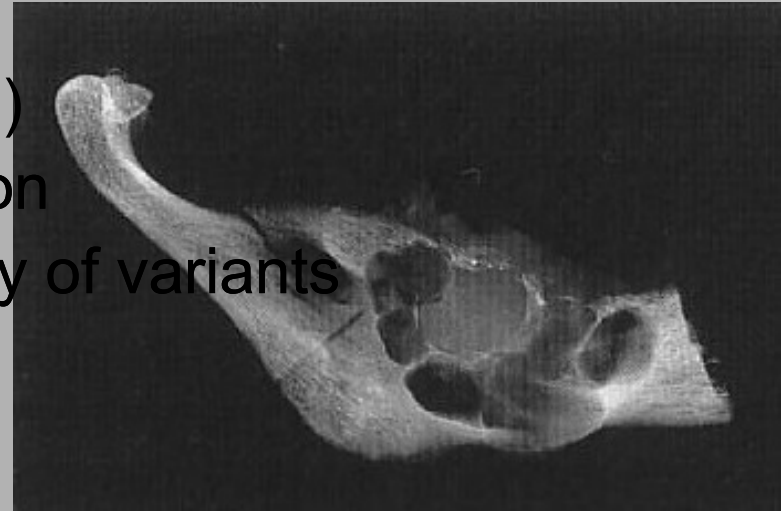
Ameloblastic fibroma

- The **ameloblastic fibroma** is an odontogenic tumor arising from the enamel organ or dental lamina
- tumor with odontogennal epithelium and ectomesenchyma
- benign
- 10-20 y, boys
- in molar mandible region
- dif.dg.
 - follicular cyst
 - ameloblastoma
- Does not relapse



Ameloblastoma

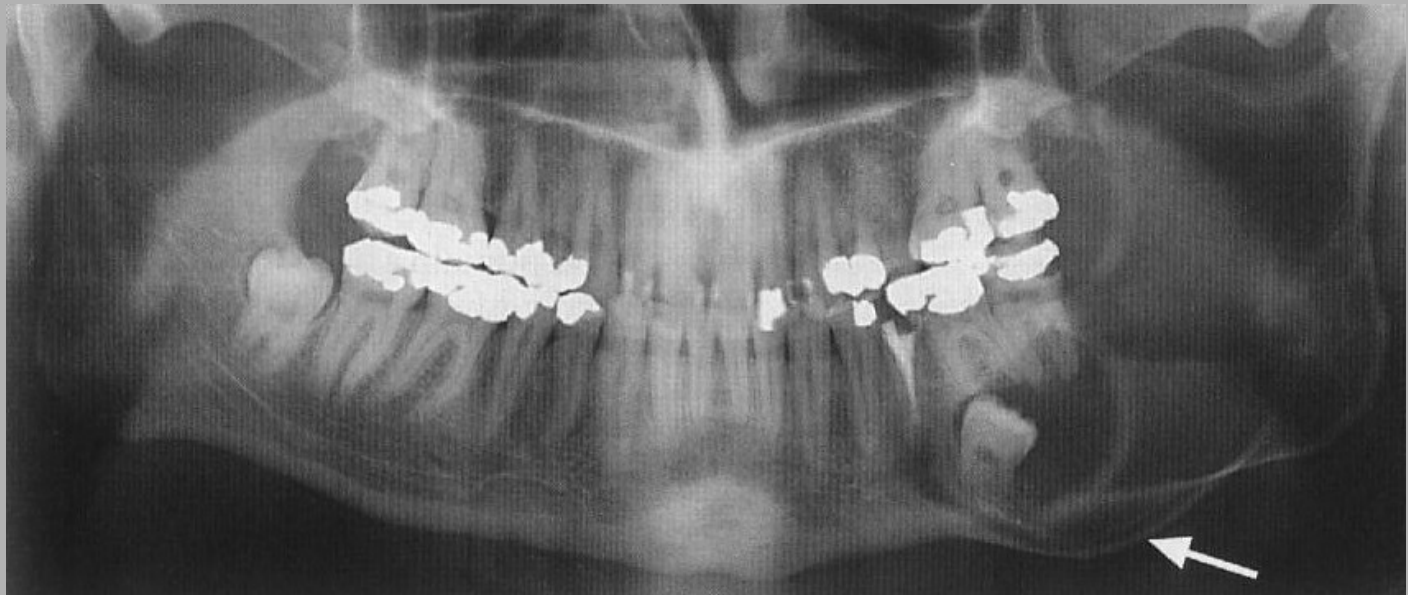
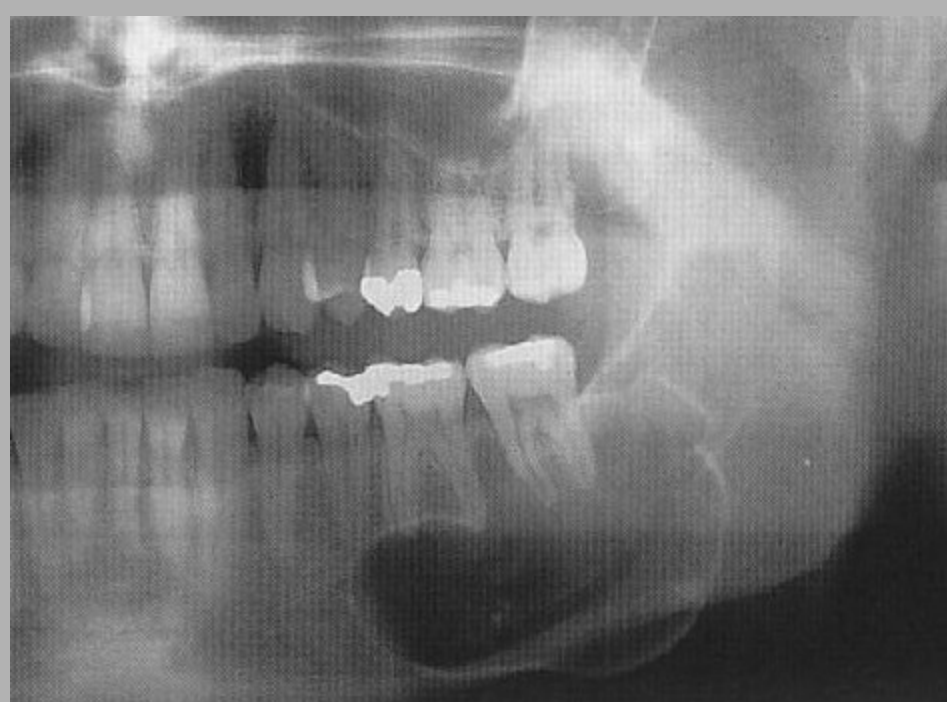- is a rare, benign tumor of odontogenic epithelium
- male/female 1:1
- in a region of caudal molars (80%)
- long-term relaps = radical resection
- variable histological image – many of variants
- RTG
 - multilocular
 - multicystic
 - bubble transparency with septum around
 - compacta thin out
- slow growth, painless
- oedema, facial asymmetry



„honeycomb“ structure

Ameloblastoma

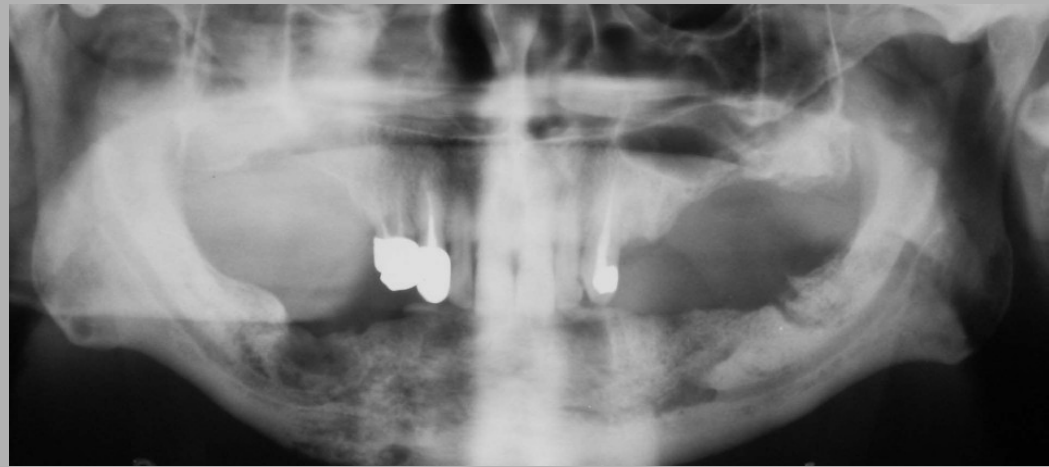
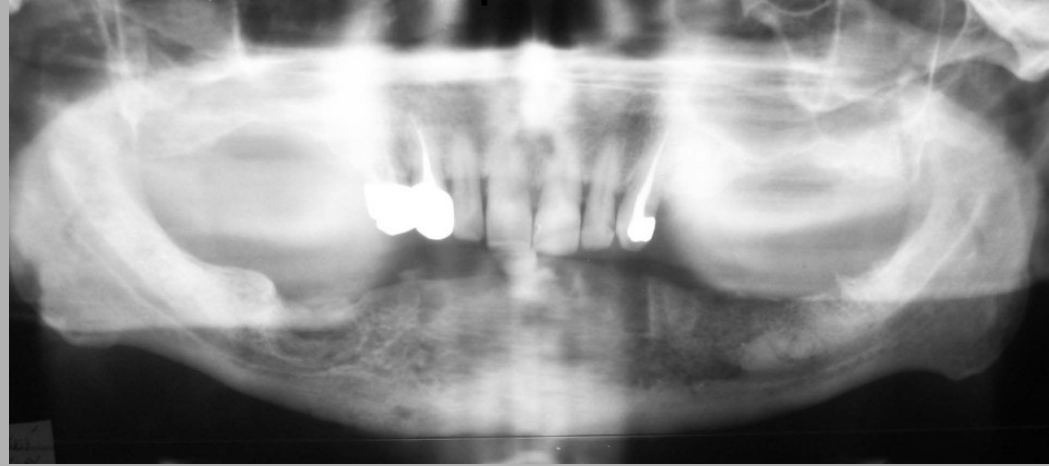
- dif.dg.
 - follicular cysts
 - keratocysts
 - ameloblastic fibroma
 - odontogennal myxoma
 - central eosinofil granuloma



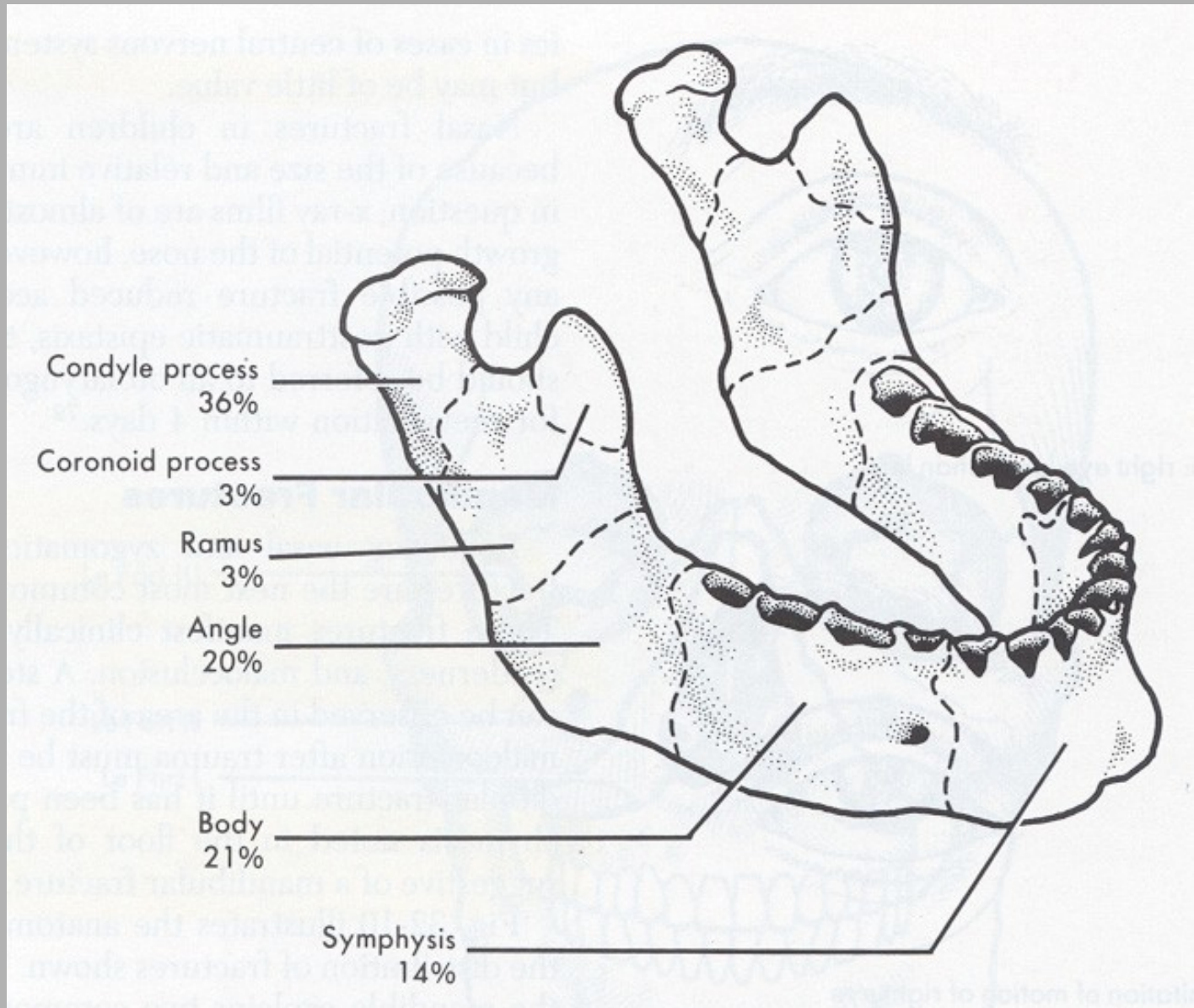
Myeloma

is a cancer of the white blood cells known as plasma cells.

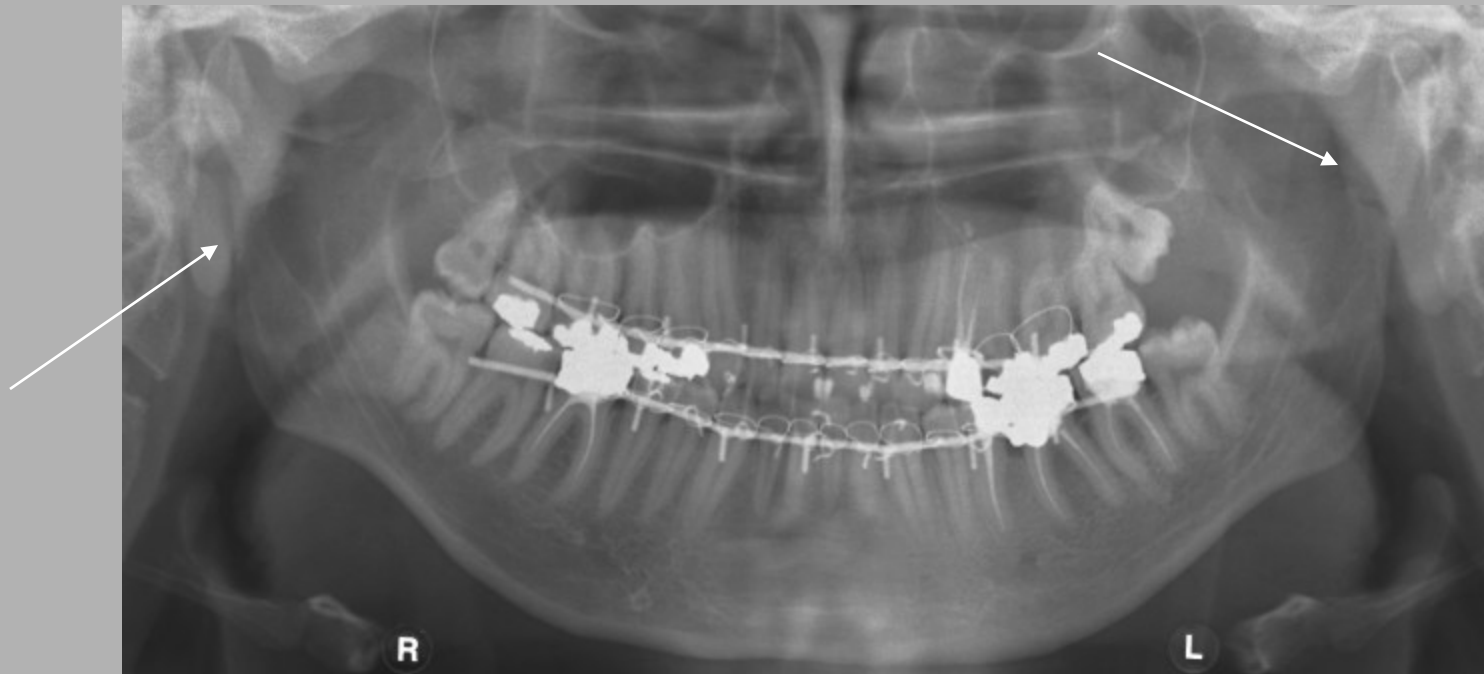
- Hypercalcemia (corrected calcium >2.75 mmol/L)
- Renal insufficiency attributable to myeloma
- Anemia (hemoglobin <10 g/dL)
- Bone lesions (lytic lesions or osteoporosis with compression fractures)
- Frequent severe infections (>2 a year)
- Amyloidosis of other organs
- Hyperviscosity syndrome



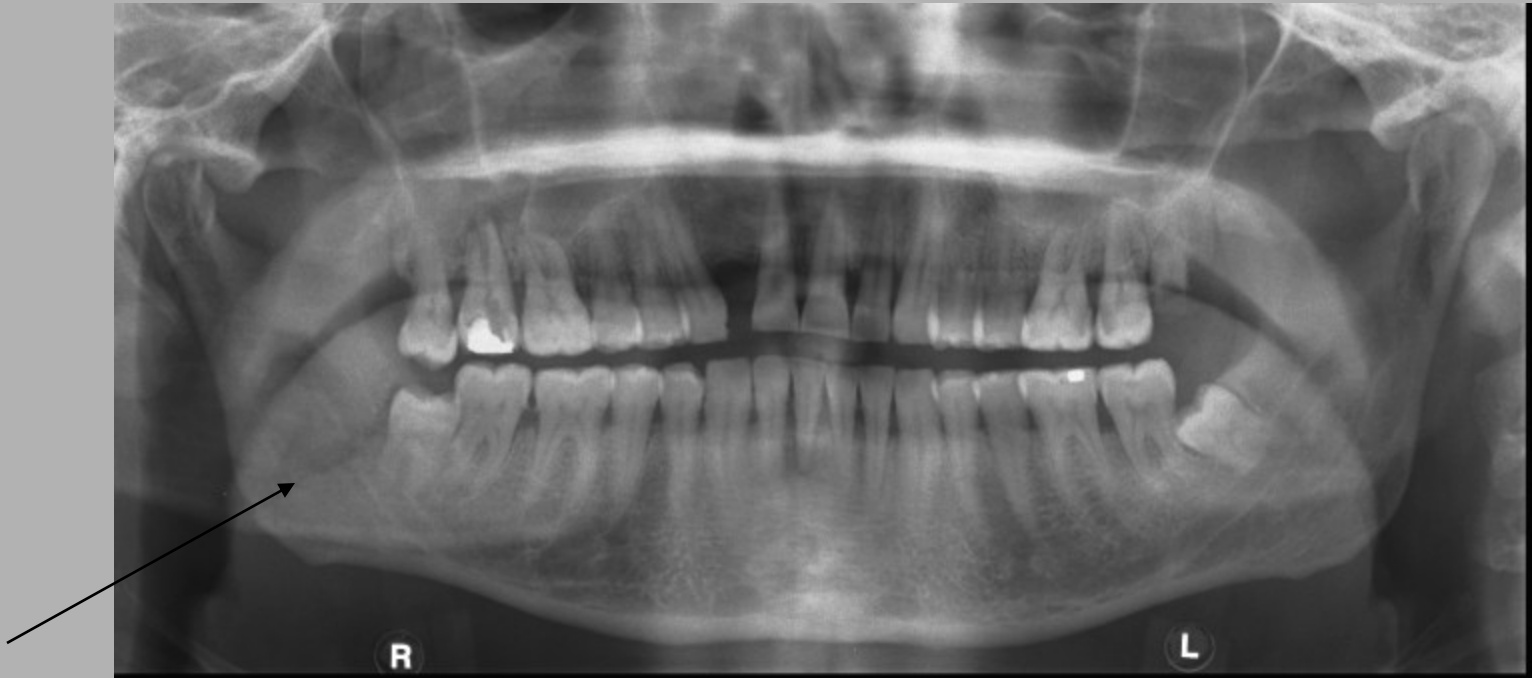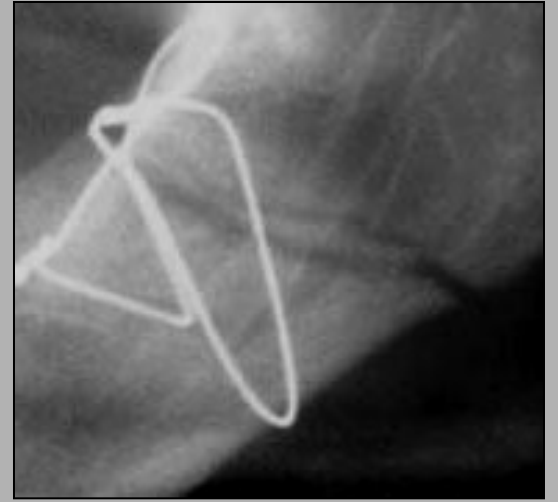Mandible fractures



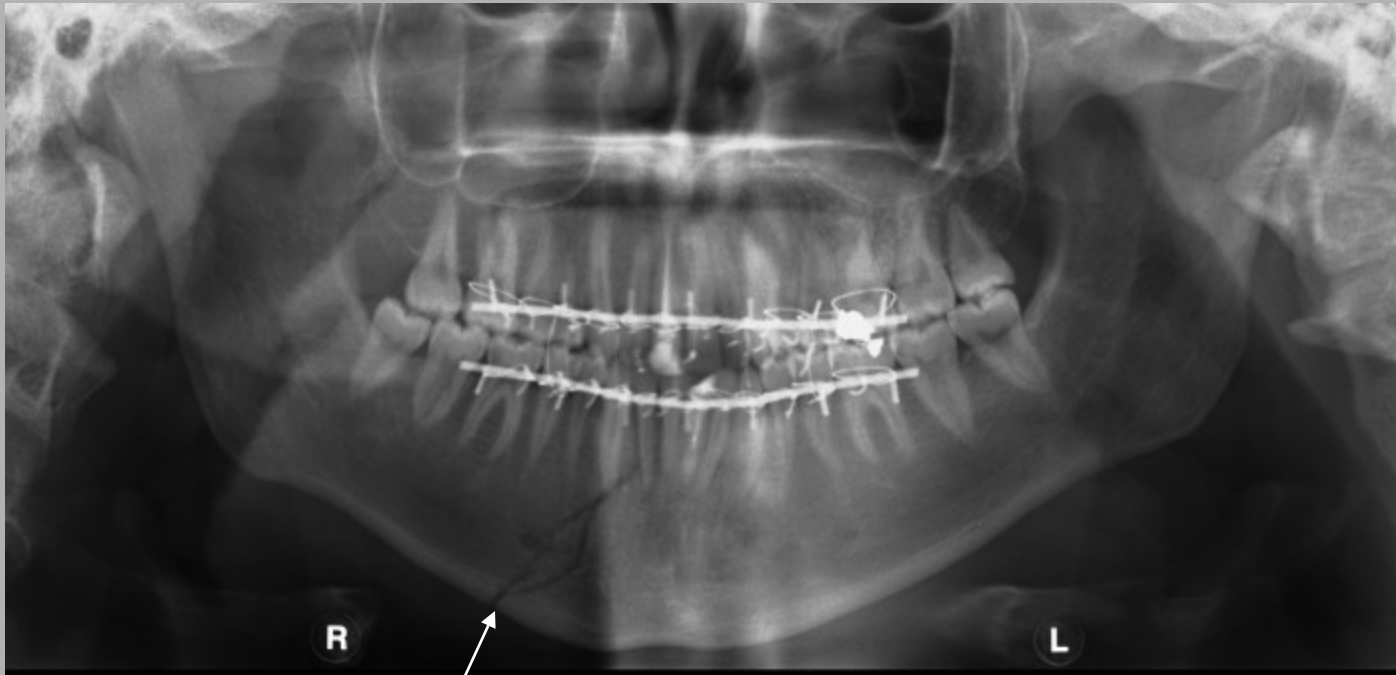Fract. processus articul. mandibulae bilat.



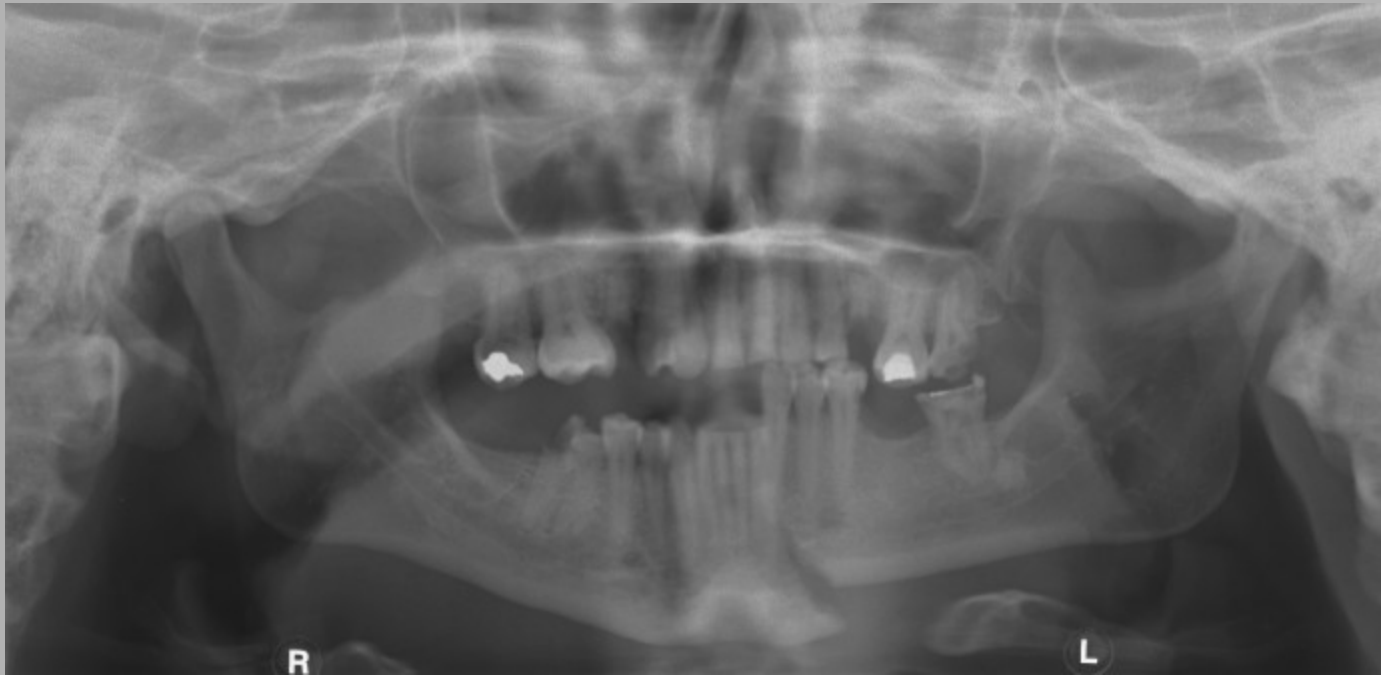mandible angle - sutura

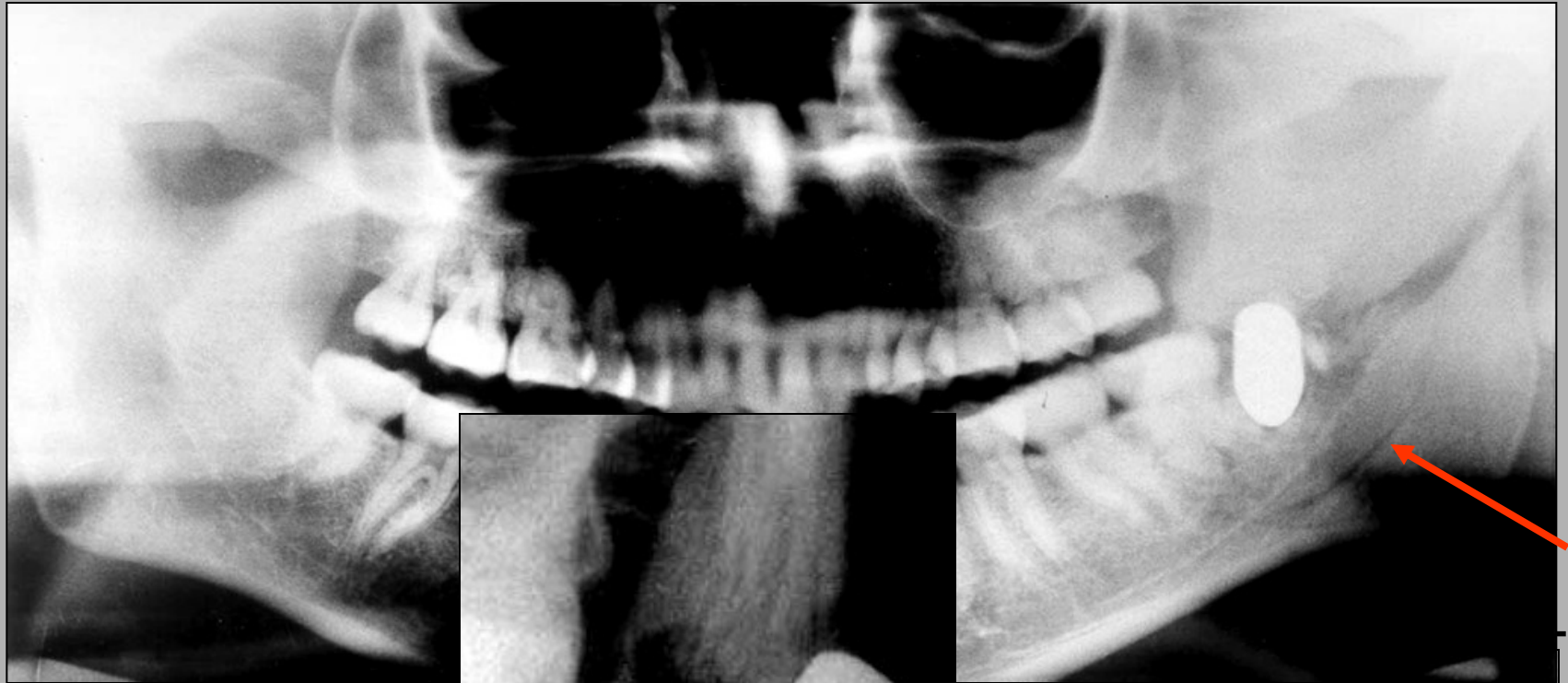


Body



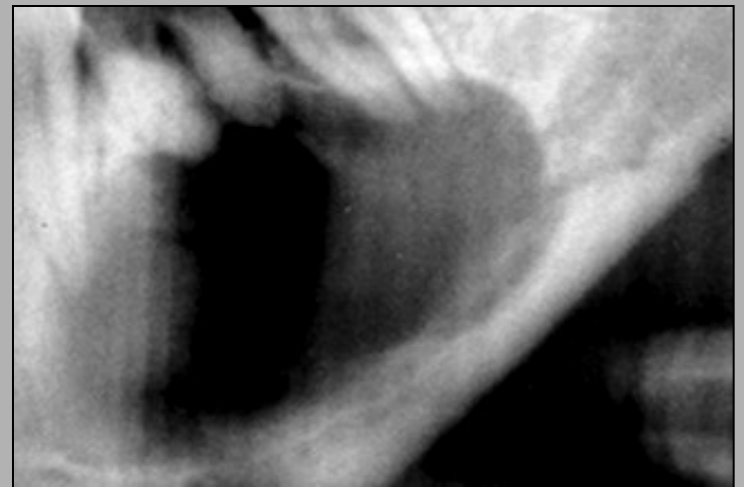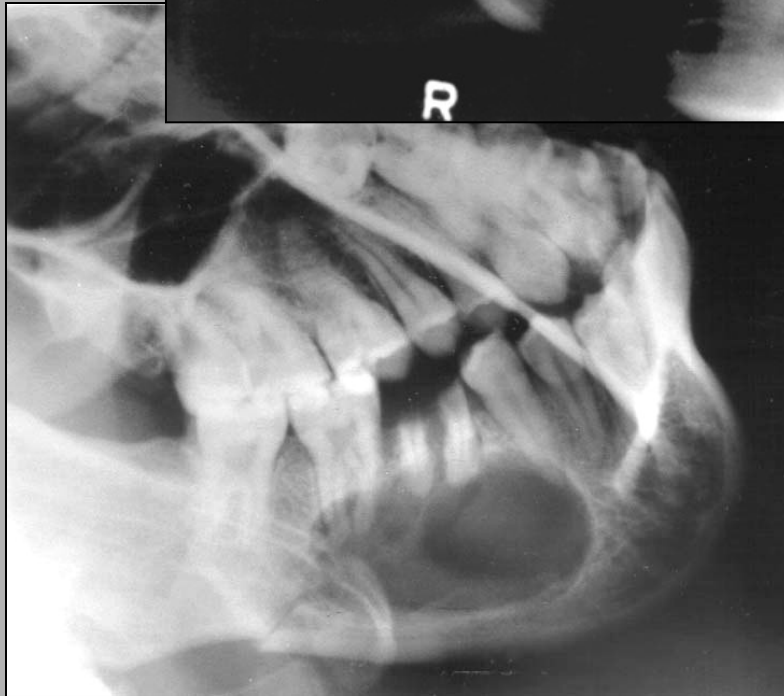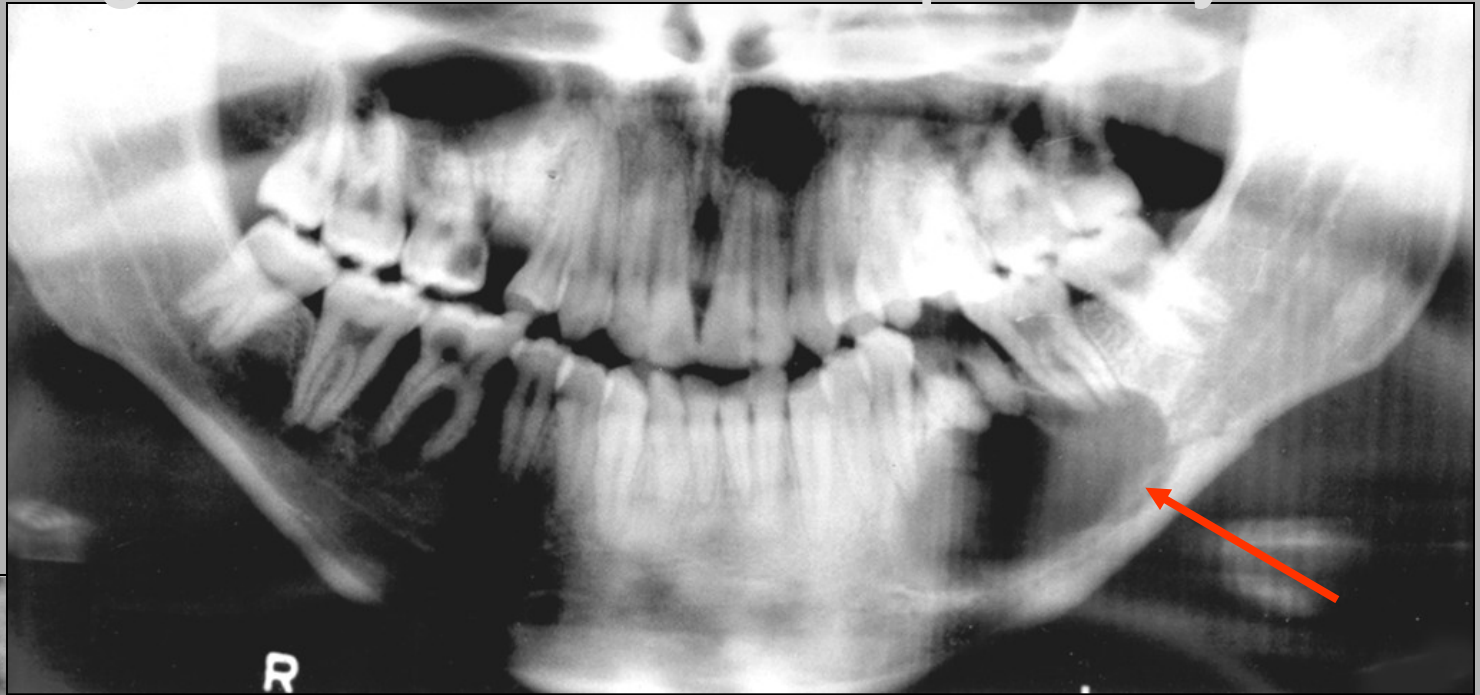
Symphysis





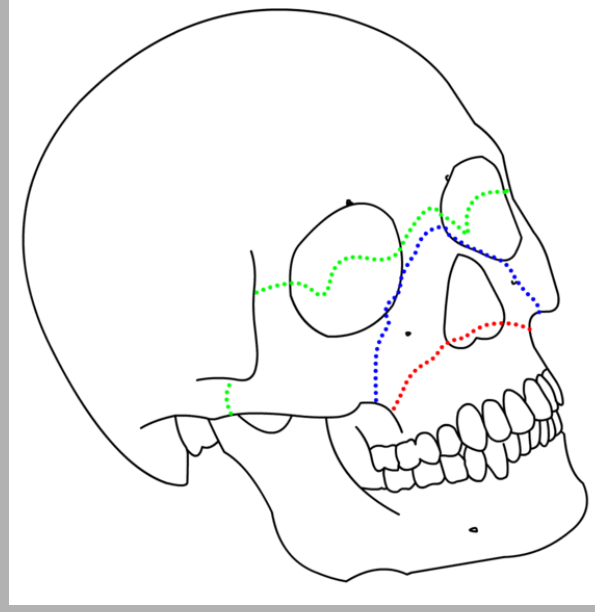
bullet

Pathological fracture and apical cyst



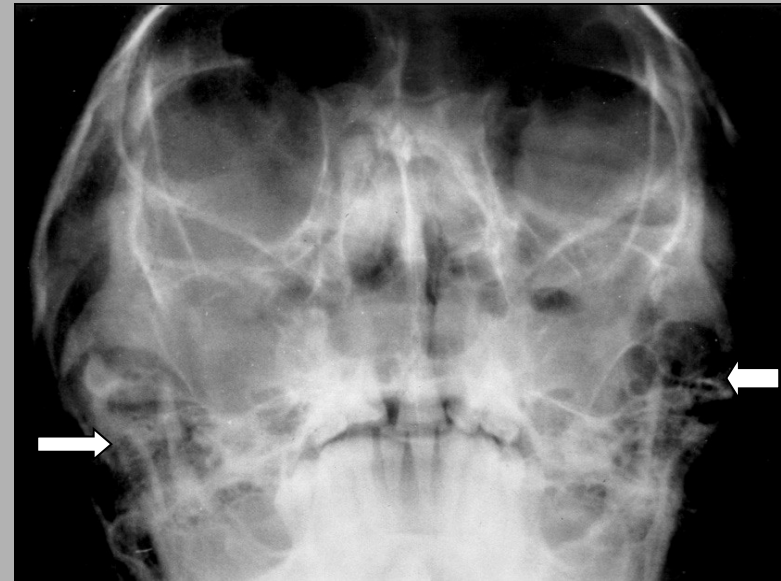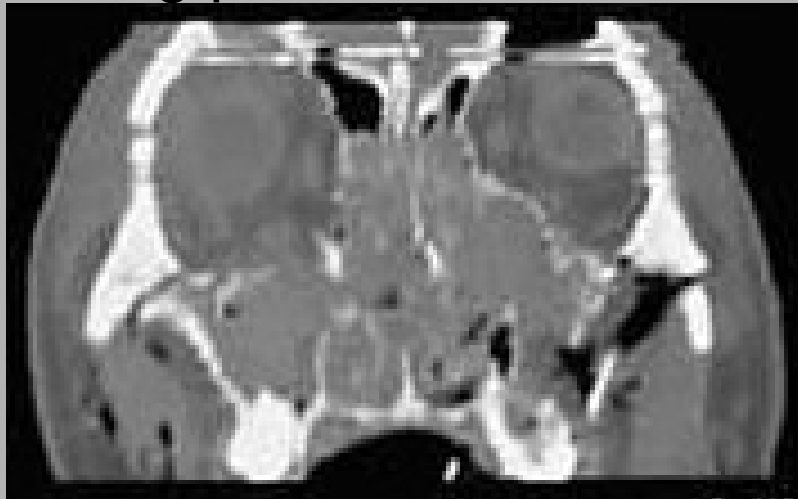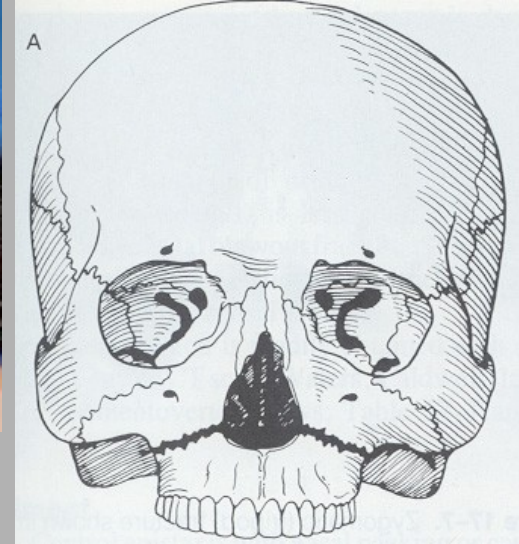
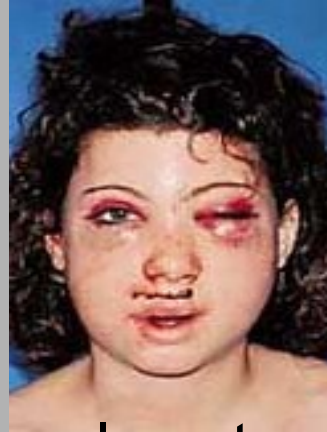Le Forte

- fracture of the maxilla
- high energy trauma
 - 100 times the force of gravity
- patient usually have multisystem trauma
- Classification: **Le-Forte I-III**
- all types Le Forte involve **processus pterygoideus**



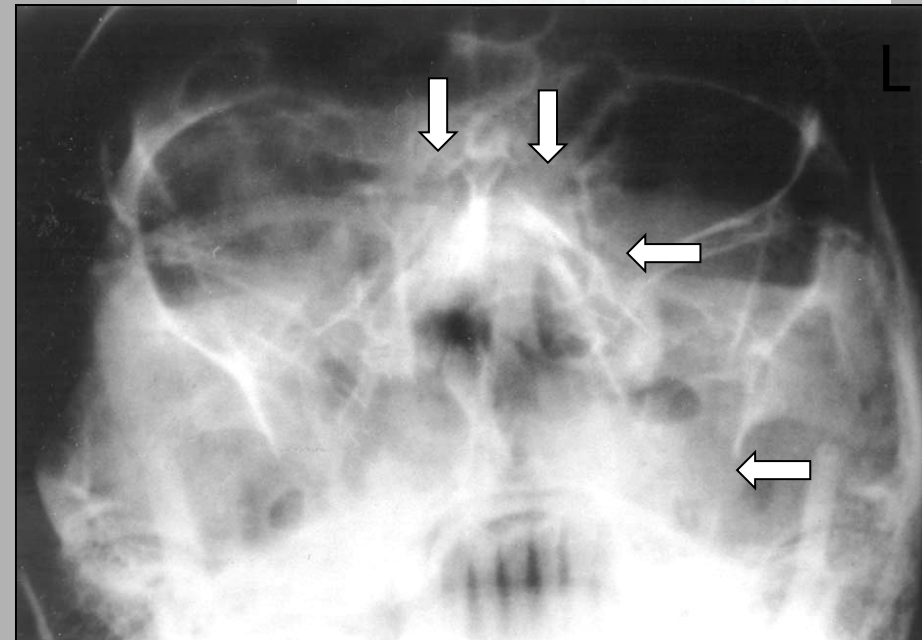
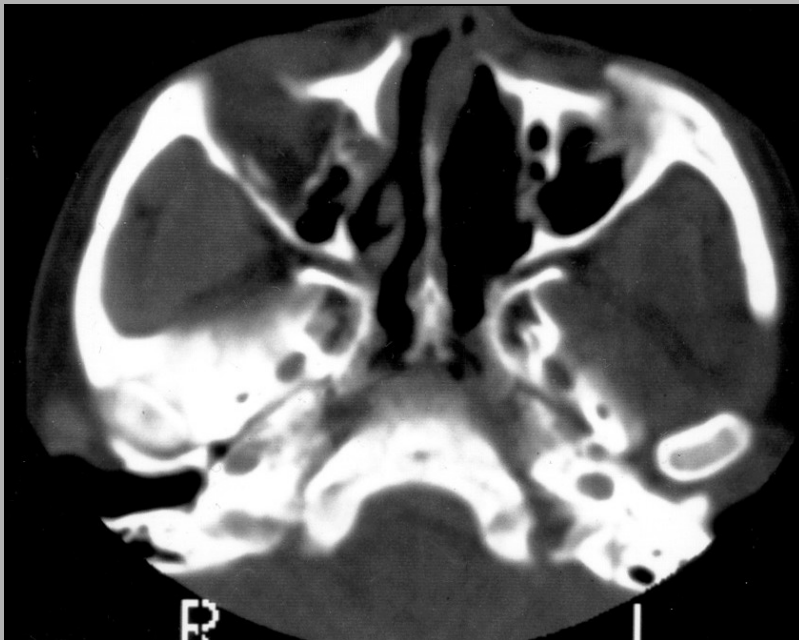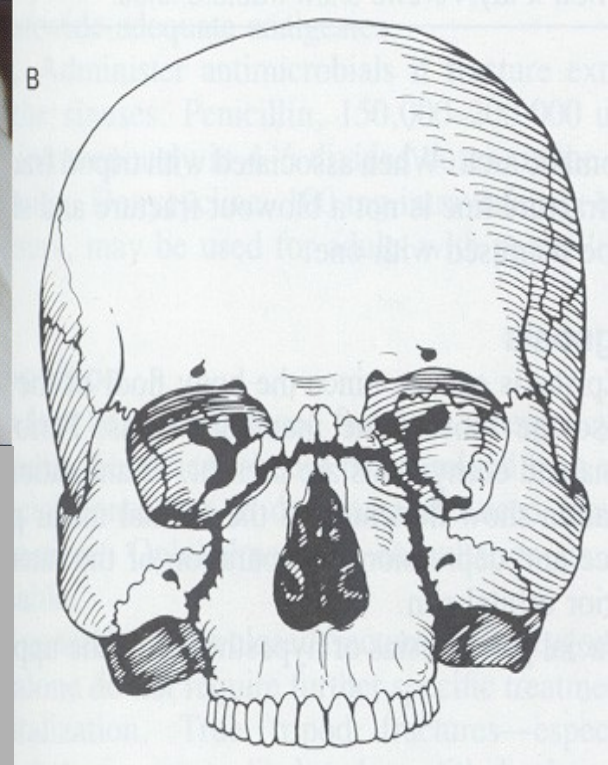
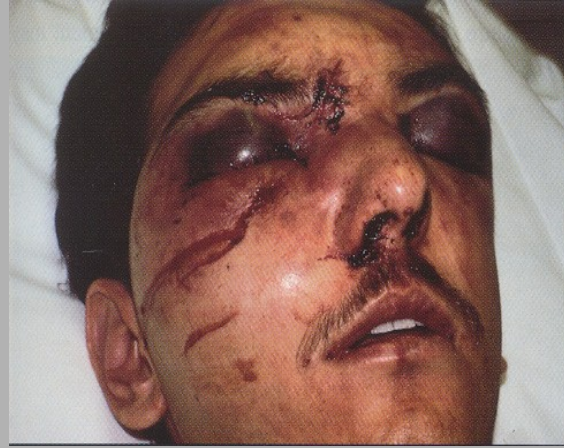LeFort I

- horizontal fracture
- the fracture extends from the nasal septum travels horizontally above the teeth apices
- crosses below the zygomaticomaxillary junction, and traverses the pterygomaxillary junction to interrupt the pterygoid plates.
- floating palate

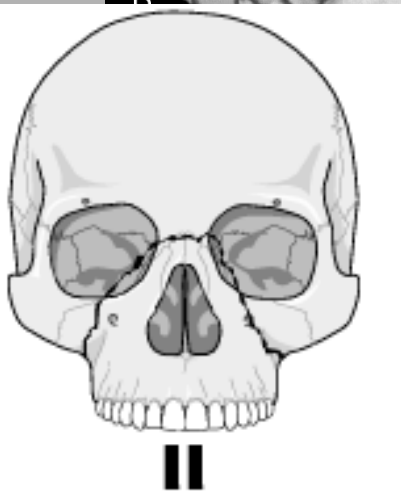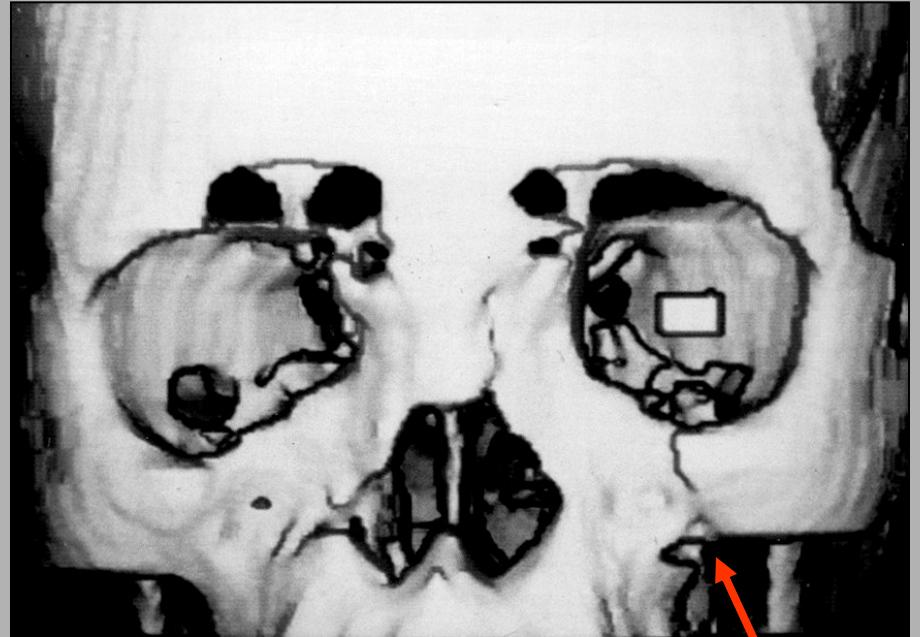
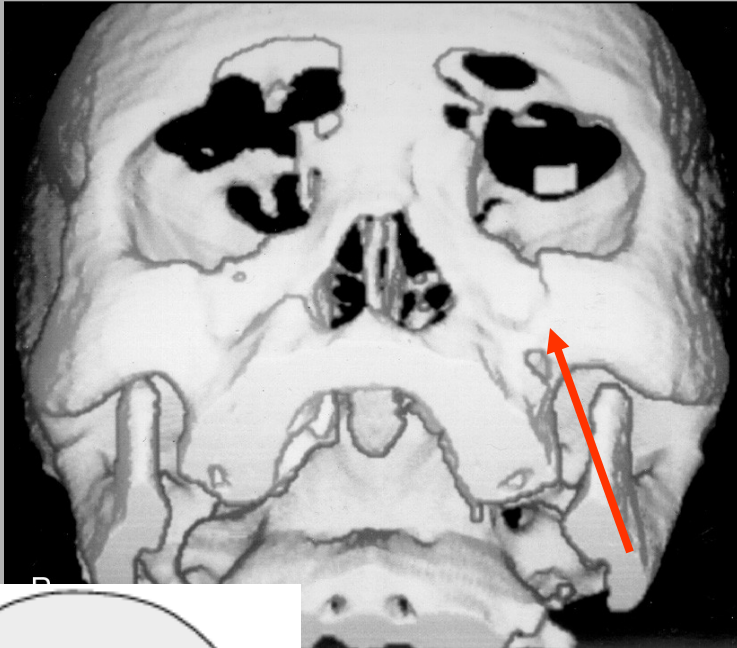


LeFort II

- ✓ Maxilla
- ✓ Medial portion of orbits
- ✓ nasal bones

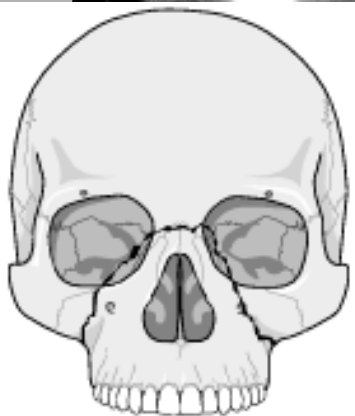
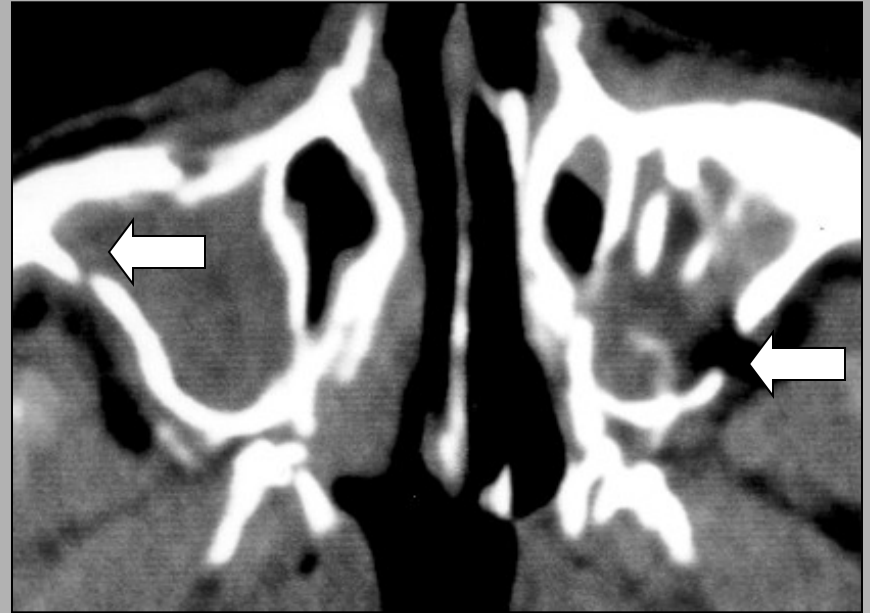
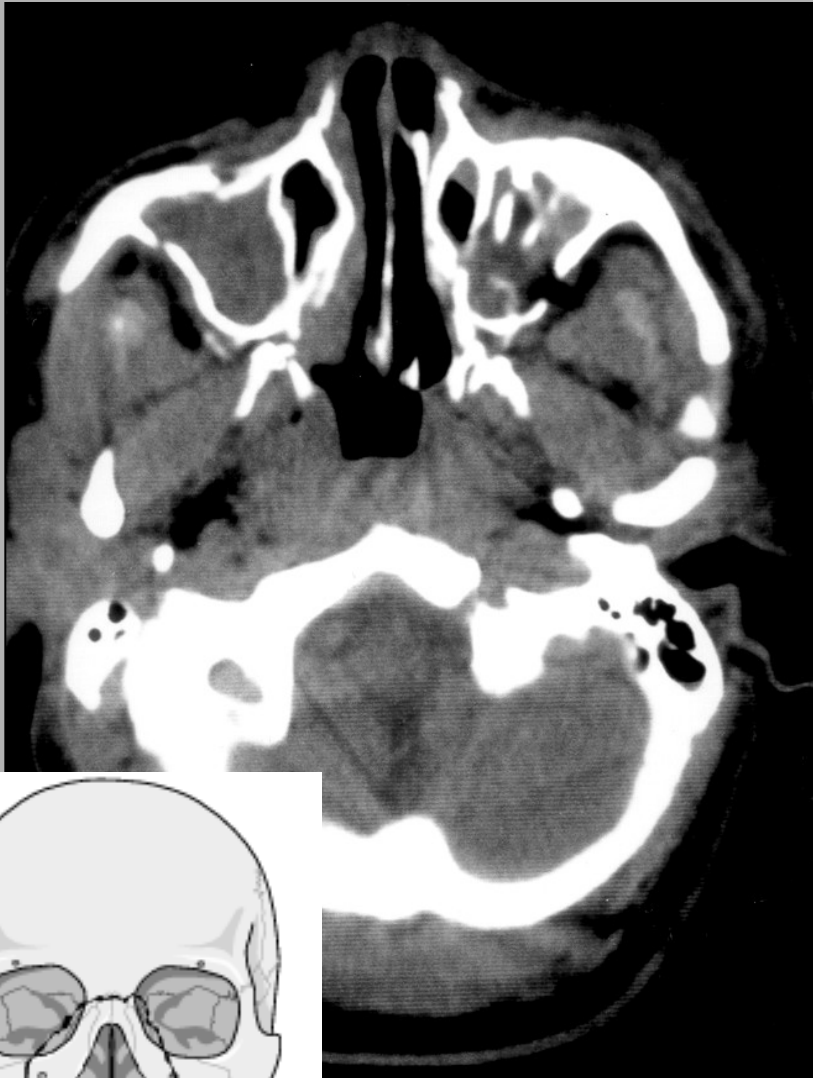
Le Fort II



CT 3-D reconstruction

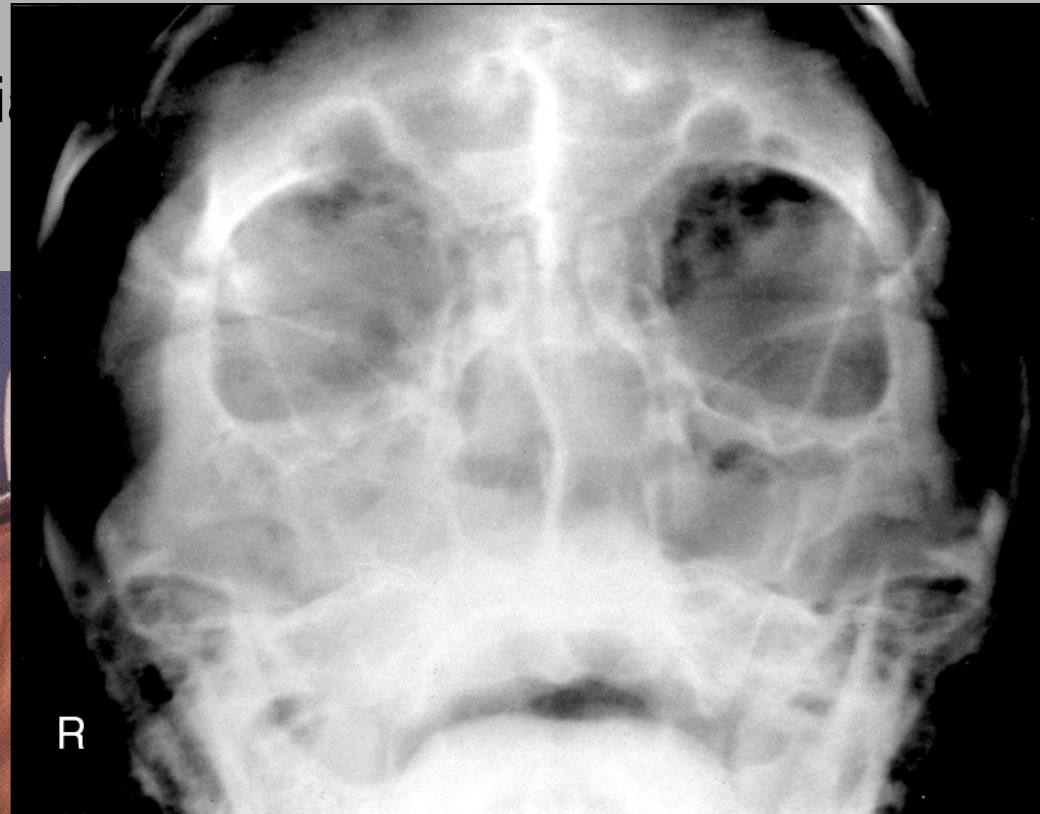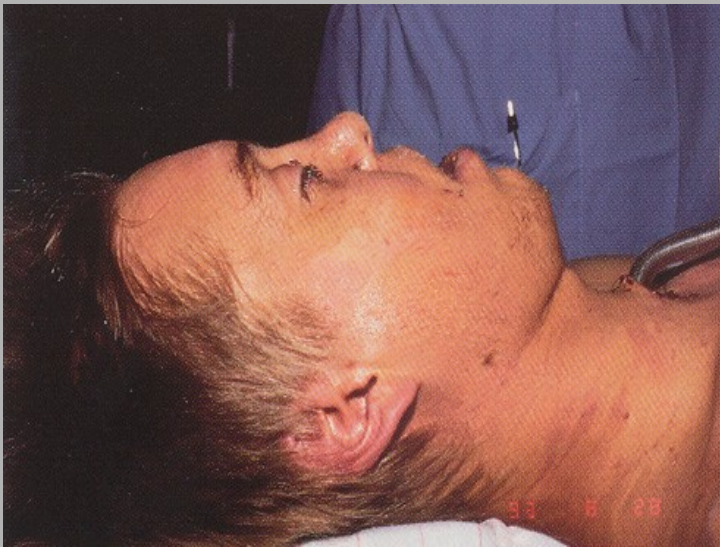
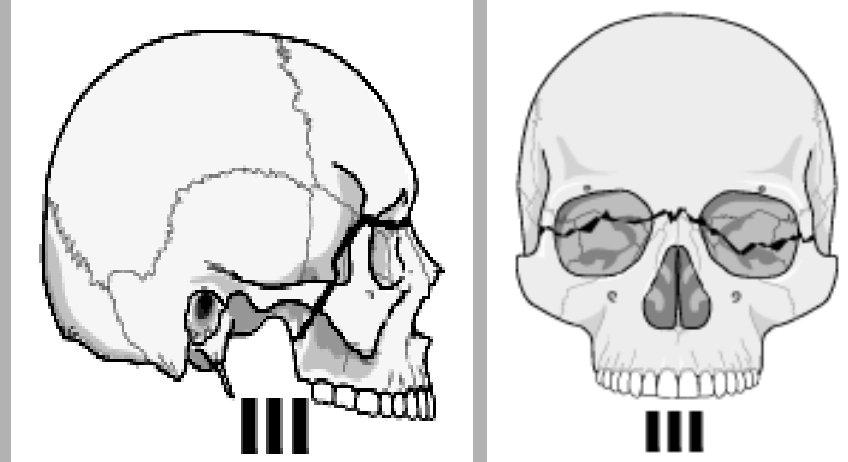
Le Fort II



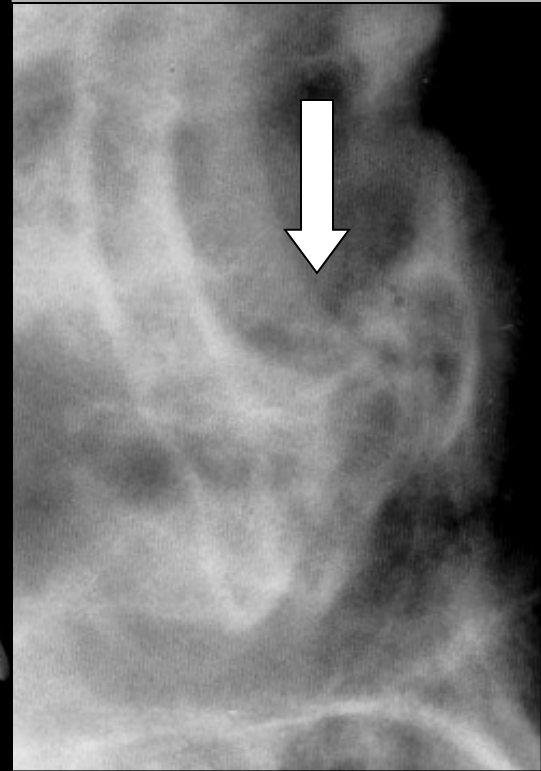
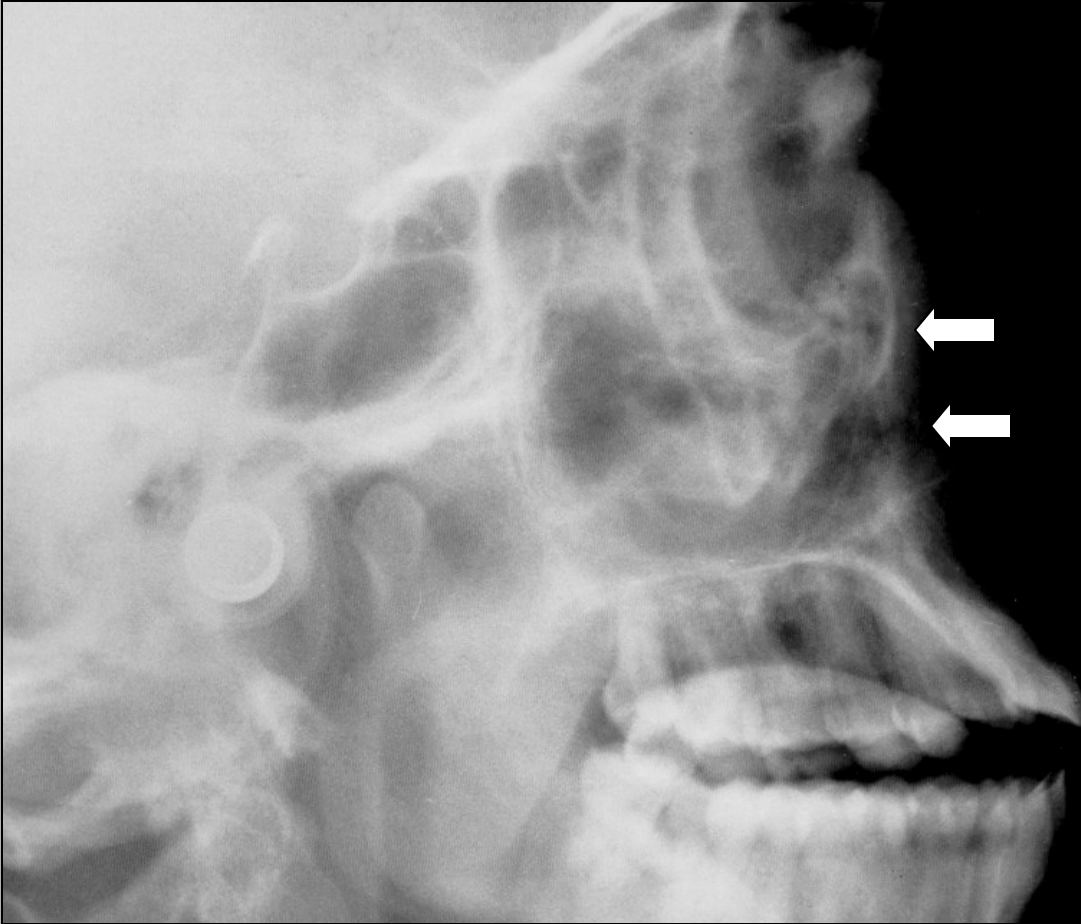
II

Le Fort III

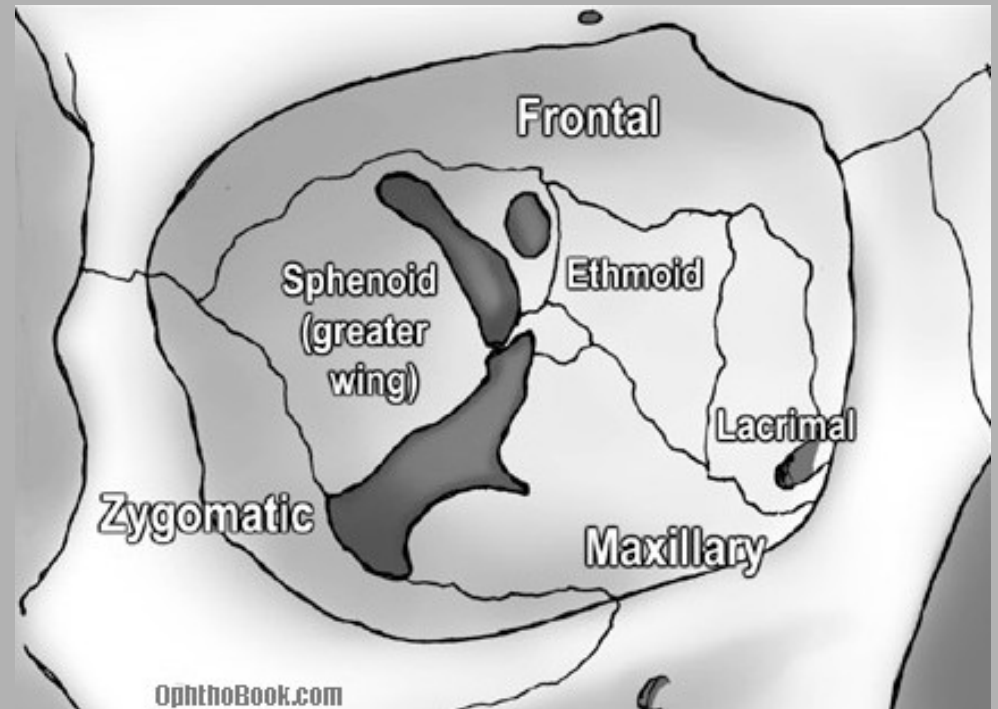
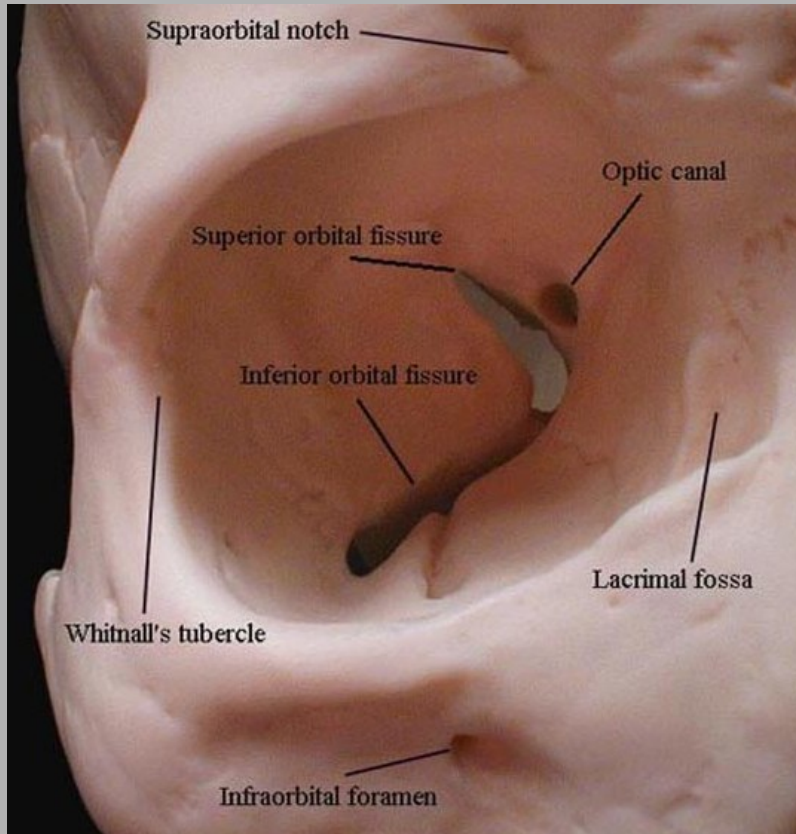
- Transverse fractures
- Zygomatic arch
- Nasofrontal and frontomaxillary sutures
- Nasolacrimal groove and ethmoid bones
- Known as craniofacial dissociation of the zygomatic arch



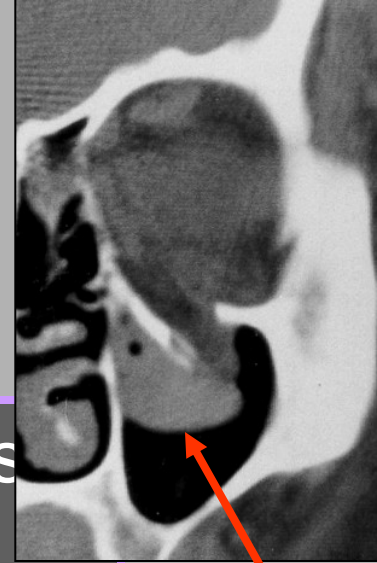
Le Fort III



Orbita - anatomy

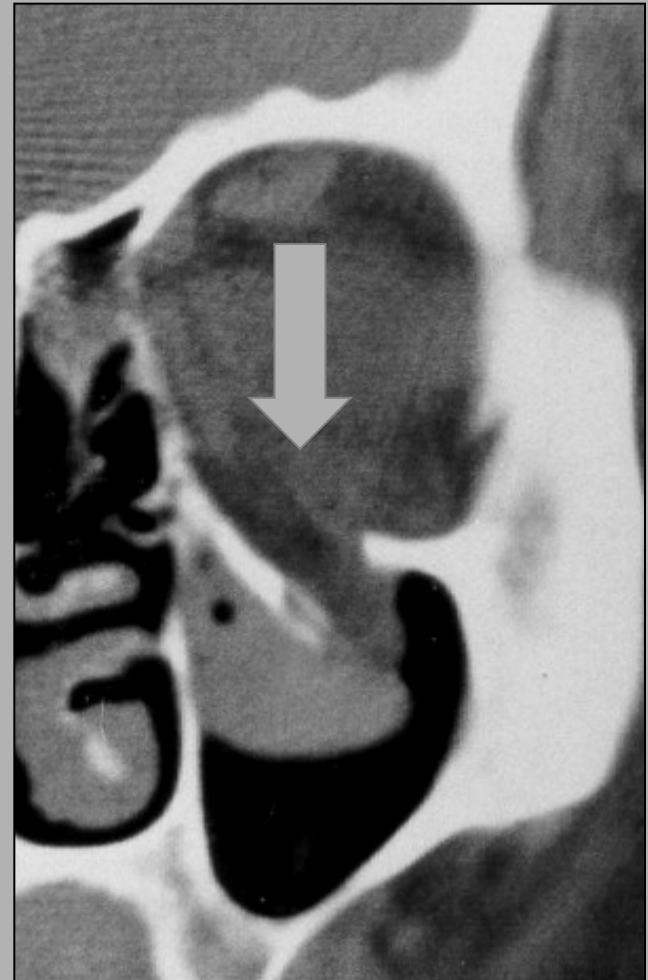
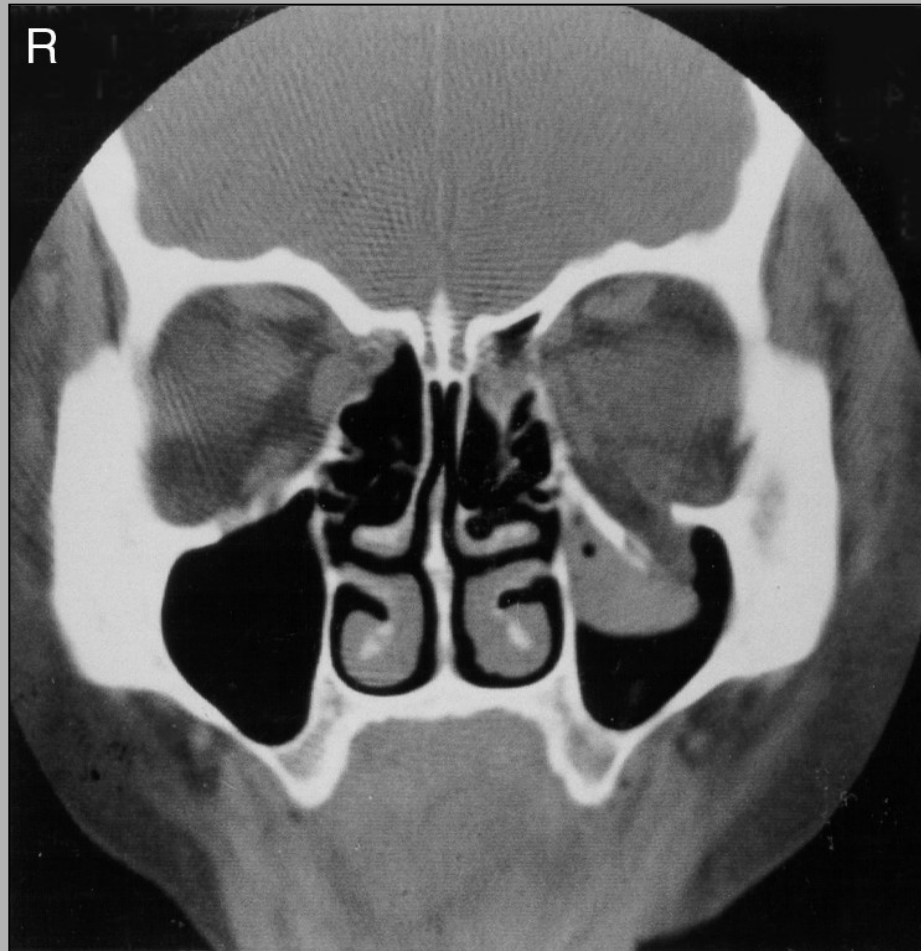


Blow-out fracture



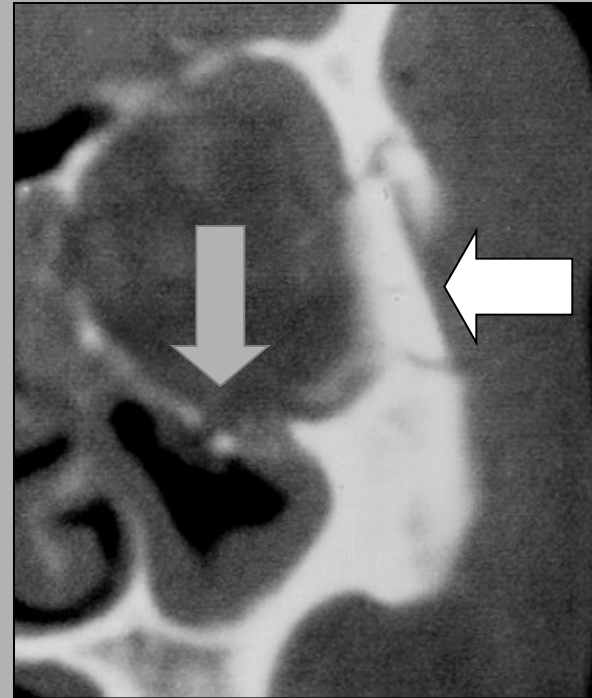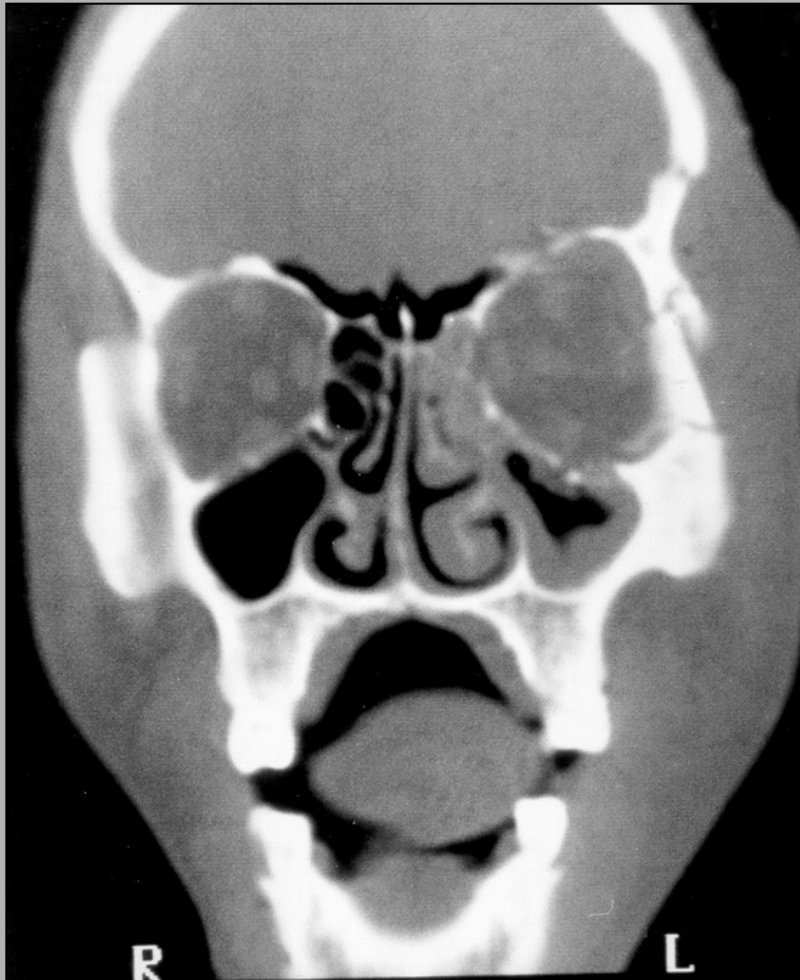
- The force vector goes through thin orbit base where arise fracture near infraorbital canal
- Soft tissue goes beyond orbital rim
- Injury of maxillar sinus
- Dislocation of orbital base
- Polypoid density at the upper maxillar edge and herniation orbital structures into the maxillar sinus
- Buccal parestesis

Blow-out fracture



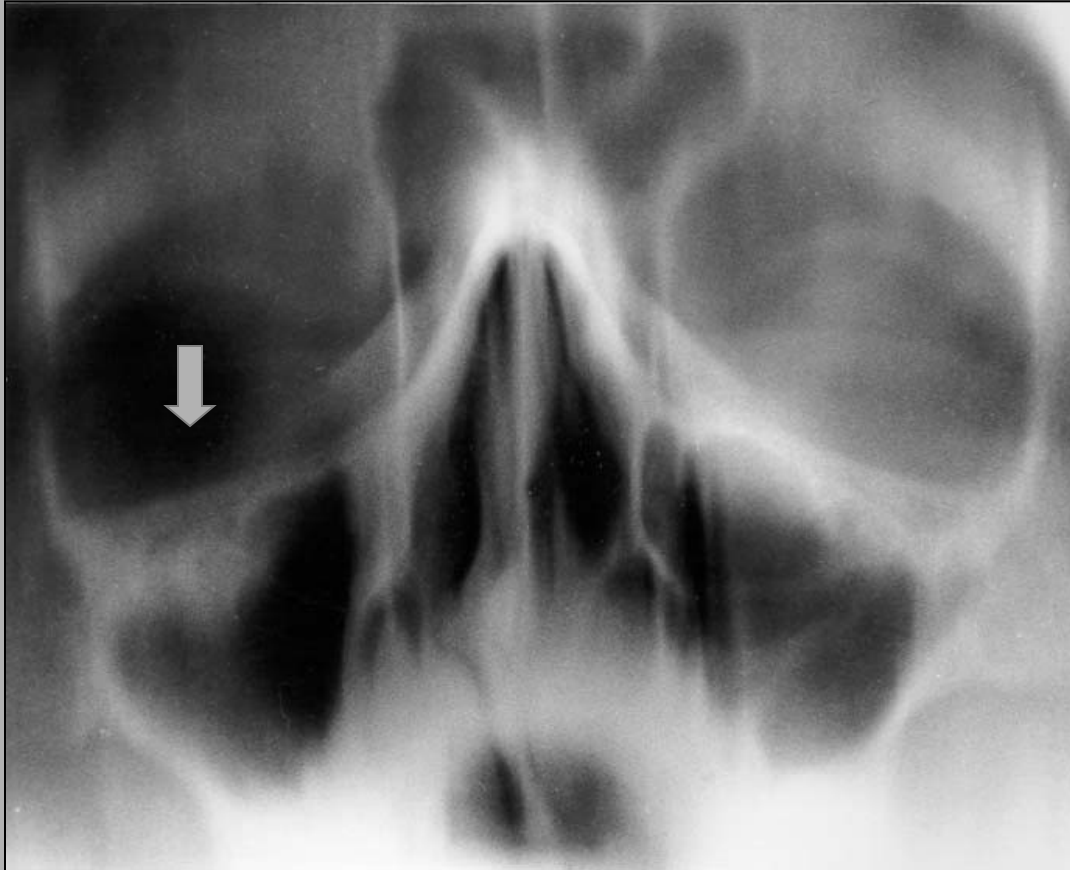
„Blow-out“ of left orbit and infraorbital canal
Coronal CT scans

Blow-out fracture

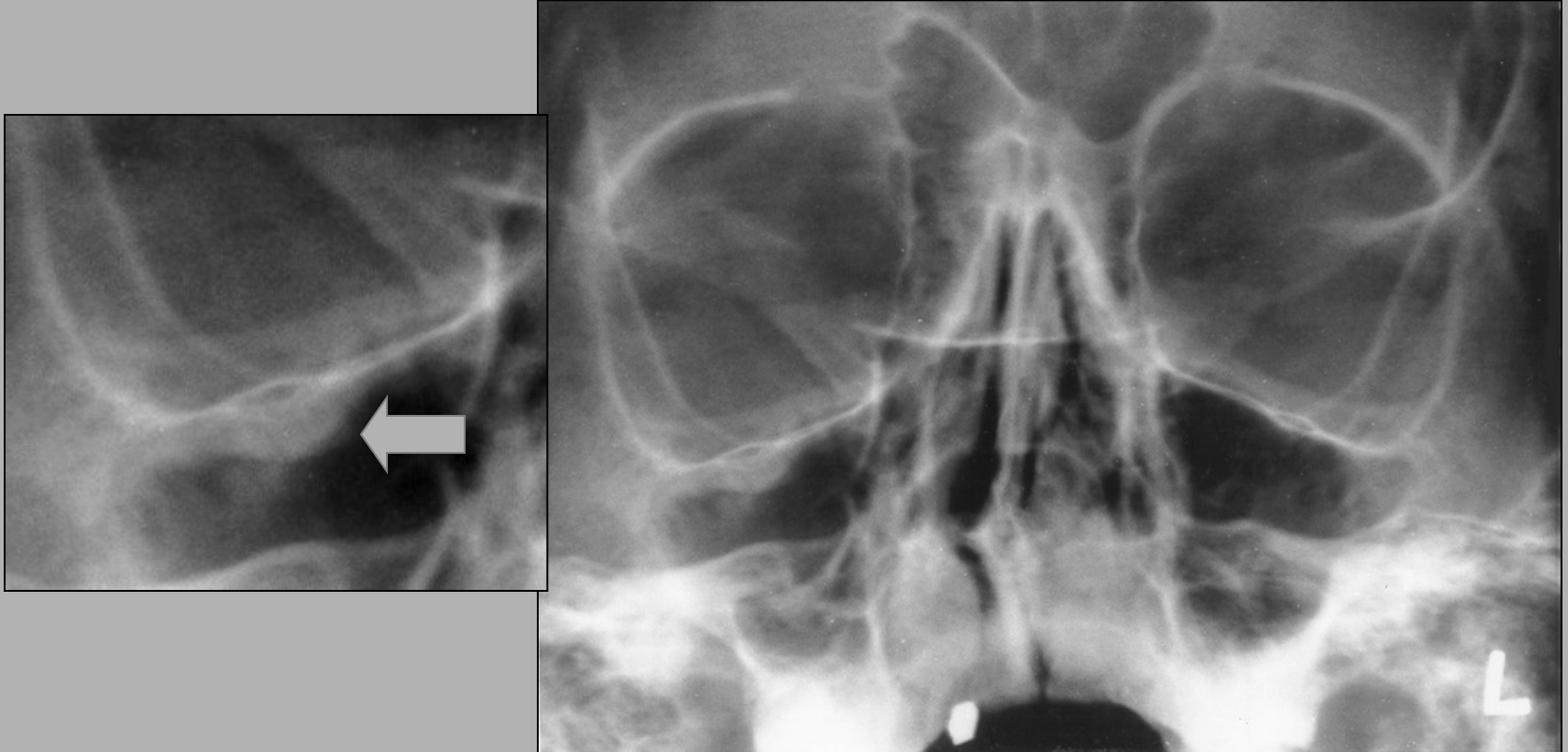


Proc. Frontozygomaticus fracture
+ „blow-out“ fracture of left orbit
Coronal CT scans

Blow-out fracture

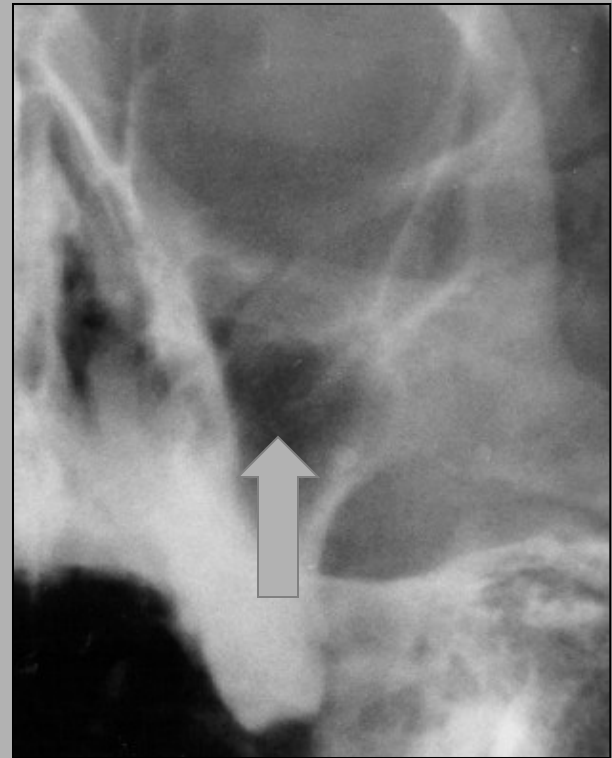
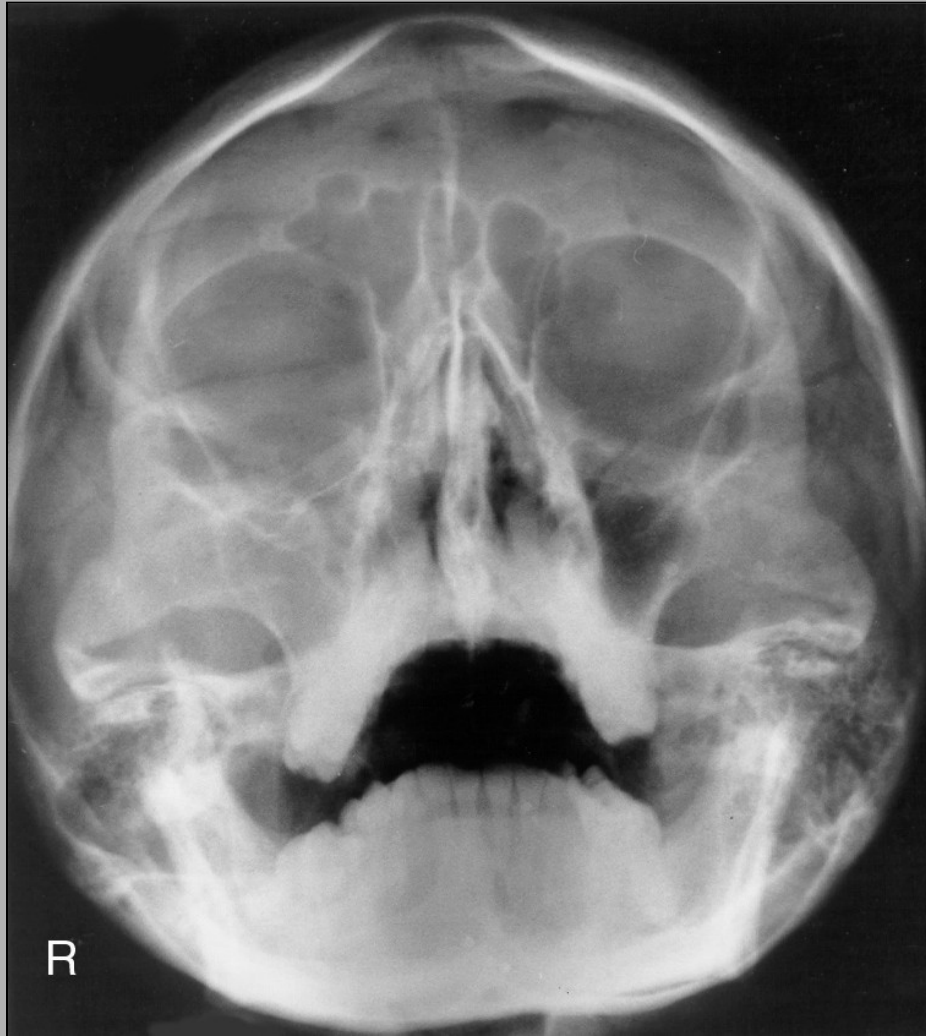

Blow-out fracture

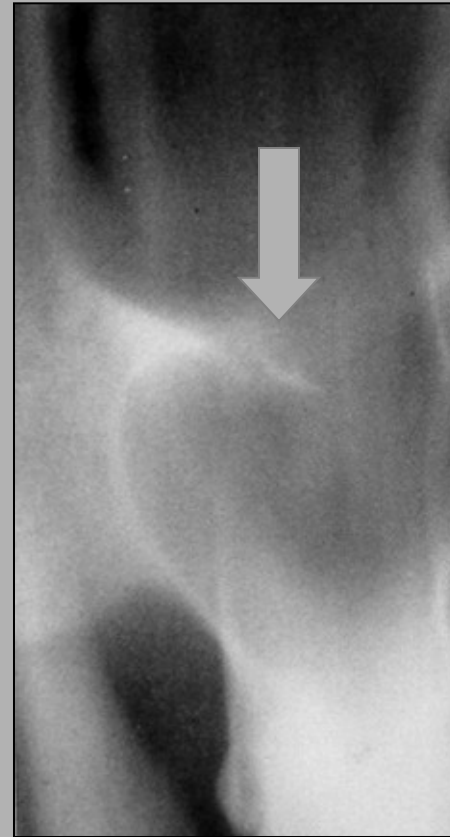
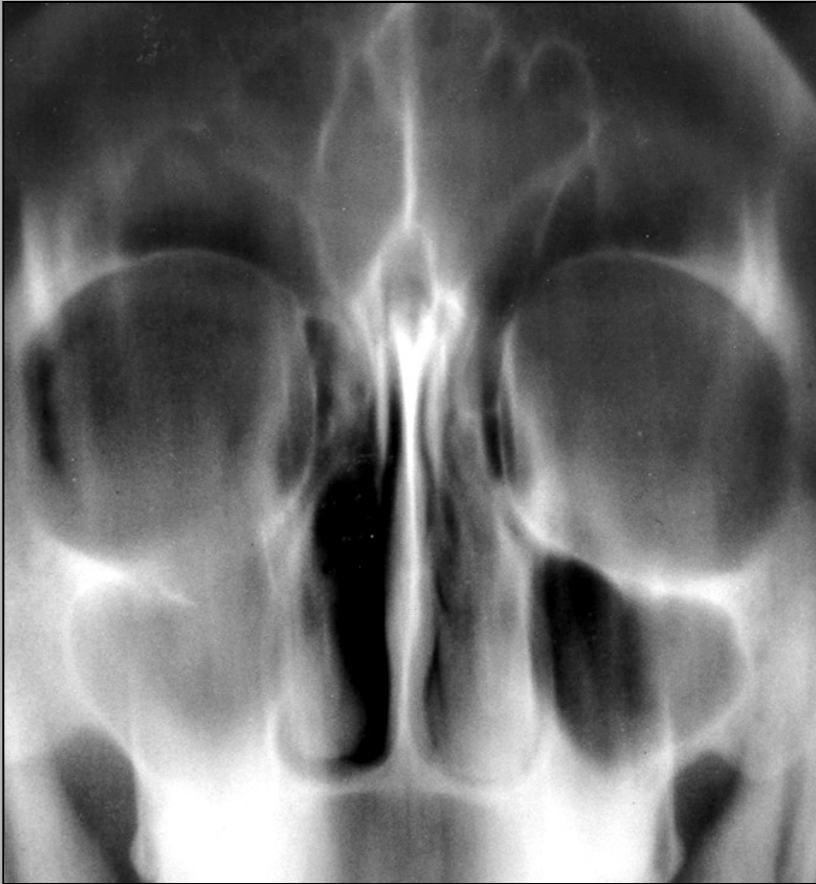

„Blow-out“ fract. Inferior part of right orbit
with mucous enlargement

Blow-out fracture

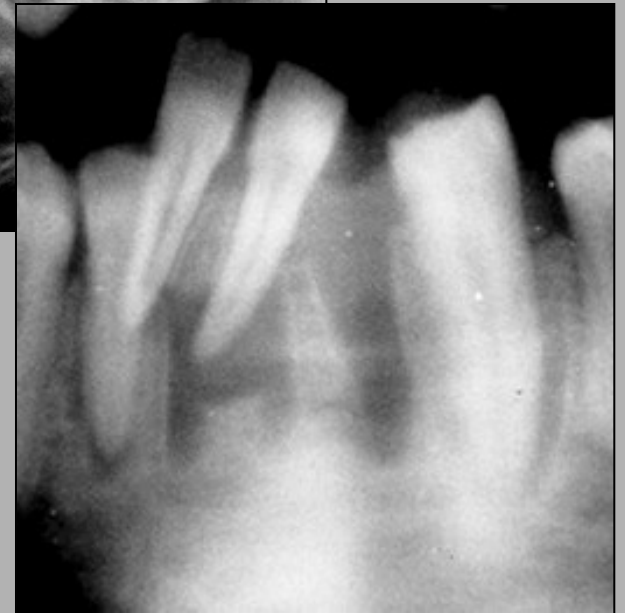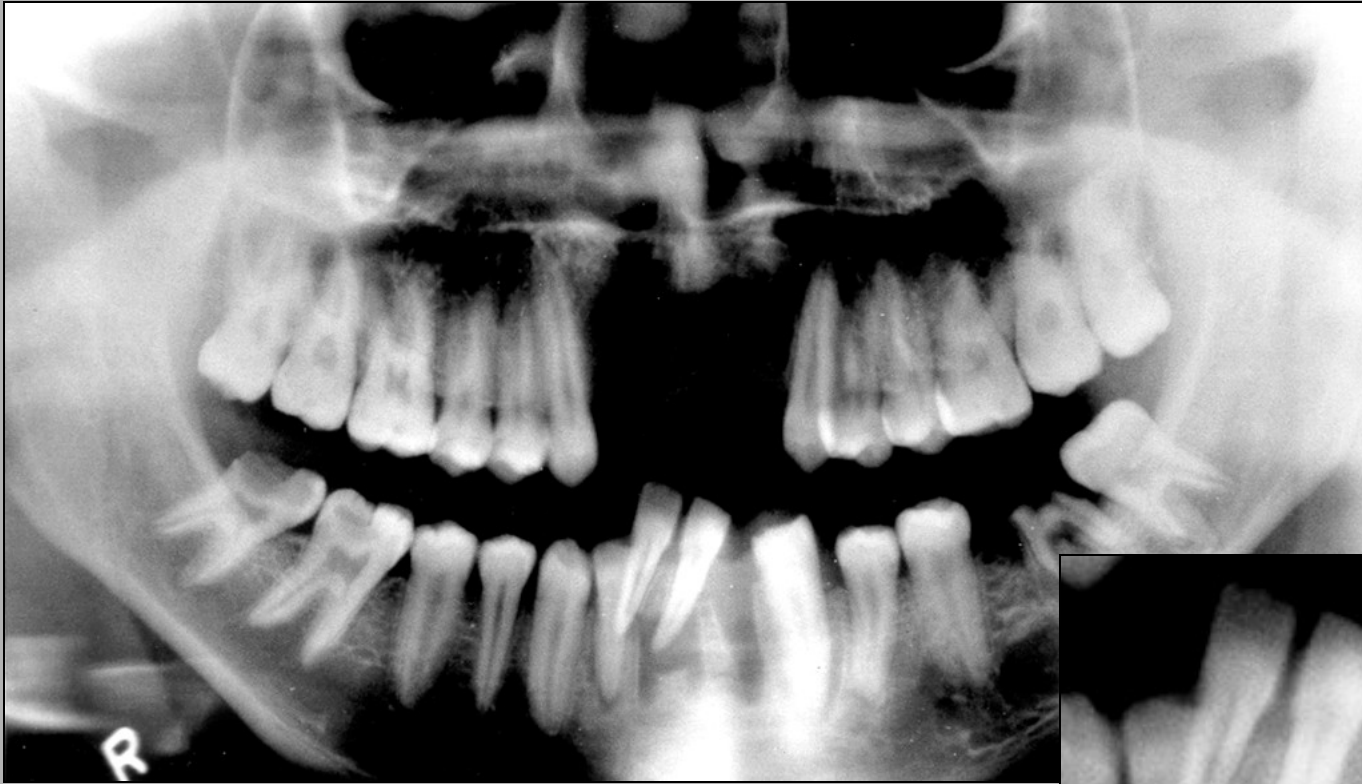


Blow-out fracture



„Blow-out“ fract. of right orbit
“trap door” sign.

Teeth subluxation



Alveolar fracture

