

Class I. cavity preparation and restorations

All pit and fissure restorations. They are assigned in to three groups.

1. Restorations on occlusal surface of premolars and molars
2. Restorations in foramina coeca – usually on occlusal two thirds of the facial and lingual surfaces of molars.
3. Restorations on lingual surface of maxillary incisors.

Materials: Amalgam, composite.

Amalgam:

Pertinent material qualities and propeties

Strength

Longevity

Ease of use

Clinically proven sucess

Indications

1. Moderate to large restorations
2. Restorations that are not in highly aesthetics areas
3. Restorations that have heavy occlusal contacts
4. Restorations that cannot be well isolated
5. Restorations that extend onto the root surface
6. Foundations
7. Abutmjent teeth for removable partioal dentures
8. Temporary or caries control restorations.

Contraindications

Aesthetically prominent areas of posterior teeth

Small moderate classes I. that can be well isolated

Clinical technique

1. Access to the caries

From the occlusal surface using the fissure bur (or diamond burs, see below).

2. Outline

Ideal outline includes all occlusal pits and fissures. If crista transversa od obliqua are no affected, it is recommended no to prepare them.

3. Resistance principles

3.1. Keep the facial and lingual margin extensions as minimal as possible between the central groove and the cusp tips.

3.2. Extending the outline to include fissures, thereby placing the margins on relatively smooth sound tooth structure.

3.3. Minimally extending into the marginal ridge without removing dentinal support.

3.4. Eliminating a weak wall of enamel by joining two outlines that come close together
Enamel.

3.5. Never leave the enamel undermined

3.6. All corners are round, the bottom smooth.

4. Retention principles

4.1. Prepare the box – the bottom is in dentin

4.2. Undercuts can be prepared, the proximal ridges must not be weakened!

5. Removal of carious, infected, dentin and remaining defective enamel.

Removal of carious infected dentin is accomplished with a discoid type spoon excavator or a slowly revolving, round carbide bur of appropriate size. Using the largest instrument that fits the carious area is safest because it is likely to penetrate the tooth uncontrollably.

6. Finishing and polishing

The outline must be smooth – do it with the fine grit diamond bur.

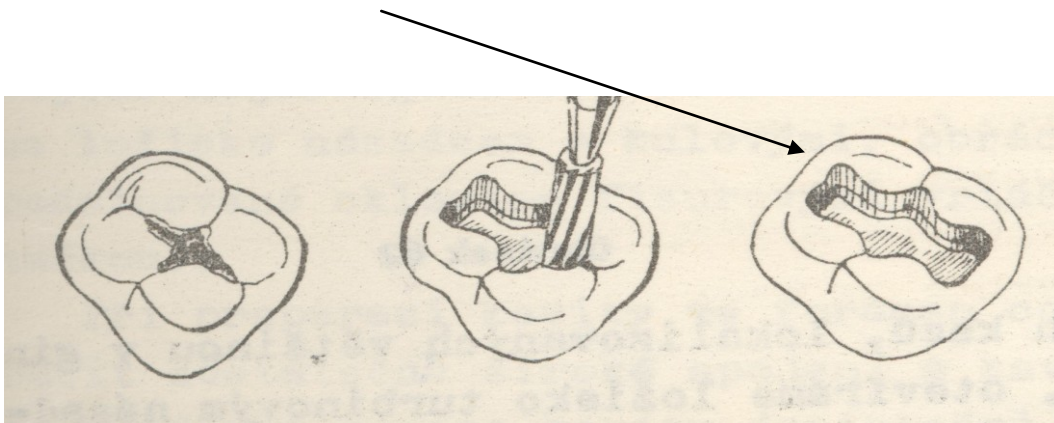
These information are the most important one, they are sufficient for the preclinical part of the study.

The information can be found in the Sturdevand's book.

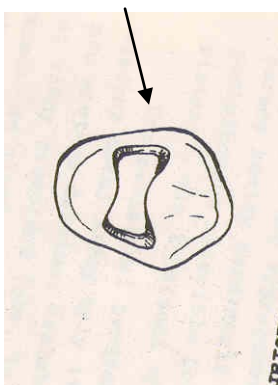
The principles of the preparation :

Notice the form of the cavity

Molar



Premolar



The outlines depend on morphology of the occlusal surface. See materials you have been provided in practice.

