

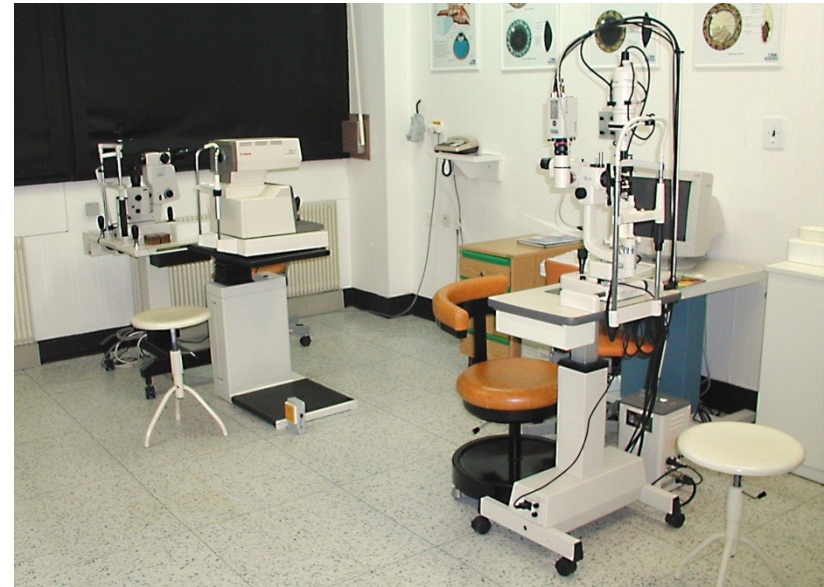# Examination techniques in ophthalmology

E. Vlková et al.



# Basic examination techniques

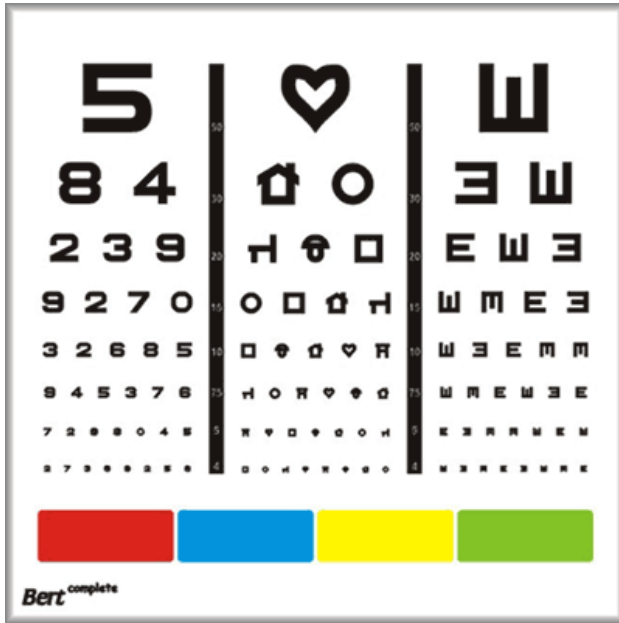
- Visual acuity (natural, best corrected)
- Measurement of intraocular pressure
- Slit lamp examination
- Fundus examination



# Visual acuity

- Visual acuity (natural, best corrected)
- Distance vision
- Near vision
  
- **Charts**
  - Snellen
  - Landolt ring
  - Pictures
  - ETDRS

# Charts



VISUAL ACUITY CHARTS	
Standard Snellen chart	Bailey-Lovie chart
<p><b>E</b> 1</p> <p><b>F P</b> 2</p> <p><b>T O Z</b> 3</p> <p><b>L P E D</b> 4</p> <p><b>P P C F D</b> 5</p> <p><b>K H F C E F</b> 6</p> <p><b>VELOPED</b> 7</p> <p><b>DEVELOPED</b> 8</p> <p><b>XXXXXXXXXX</b> 9</p> <p><b>XXXXXXXXXX</b> 10</p>	<p><b>D S R K N</b></p> <p><b>C K Z O H</b></p> <p><b>O N R K D</b></p> <p><b>K Z V D C</b></p> <p><b>V S H Z O</b></p> <p><b>H D K C R</b></p> <p><b>O S N H N</b></p> <p><b>S Y Z D K</b></p> <p><b>XXXXXXXXXX</b></p> <p><b>XXXXXXXXXX</b></p>

# Near vision

## Jaeger chart



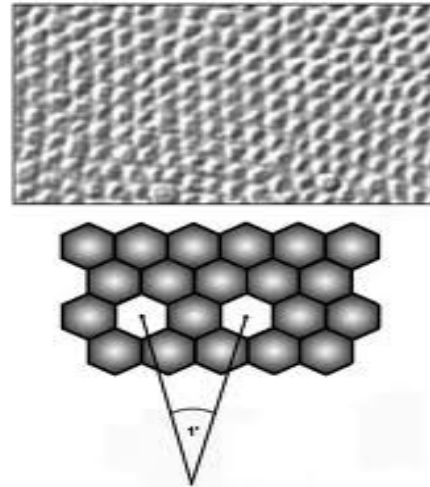
# Visual acuity

- Counting finger (metres )
- Hand movement
- Light perception



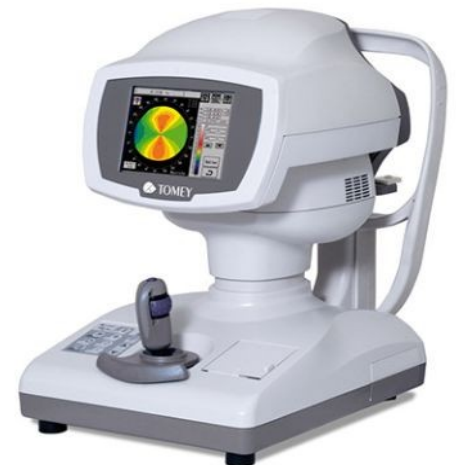# Visual Acuity

- 5/50 (metres, feet 20/200)
- 0,1
- Minimum separabile – minimum angle of resolution



# Refraction

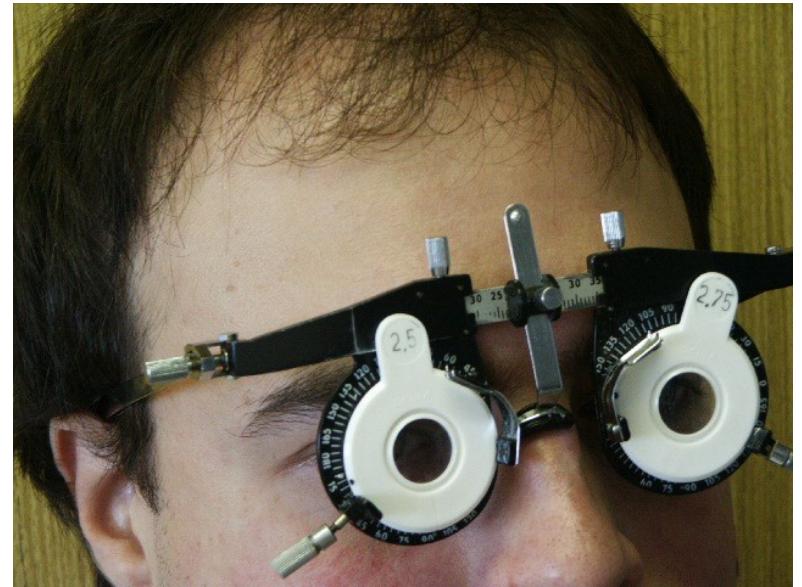
- Refractive error is an optical abnormality in which the shape of the eye fails to bring light into sharp focus on the retina, resulting in blurred or distorted vision.
- In optometry, a "refraction" procedure is the measurement of refractive error
- **Autorefractor**





# Visual acuity

- Frame
- Lenses



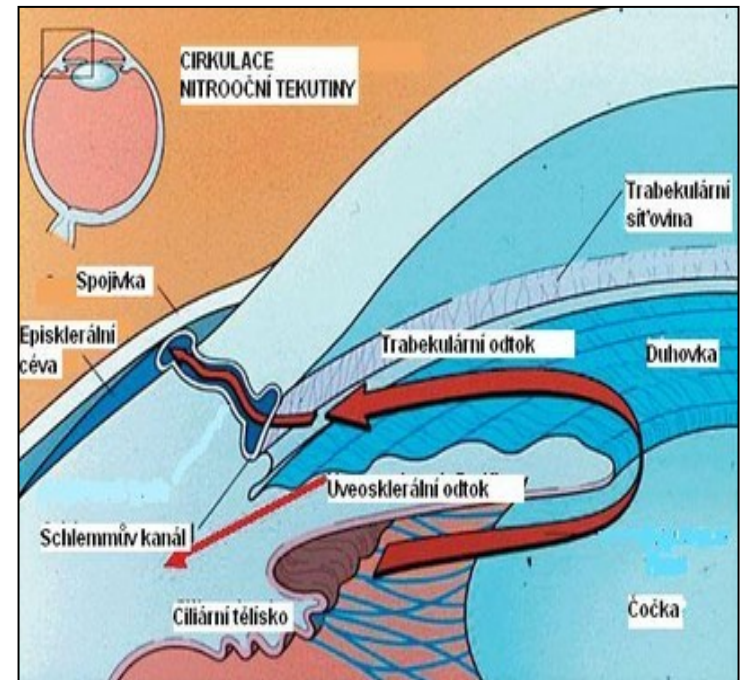
# Tonometry

## Contact techniques

- Schiötz tonometry
- Goldmann applanation tonometry


## Non contact techniques

- Jet air (air puff)

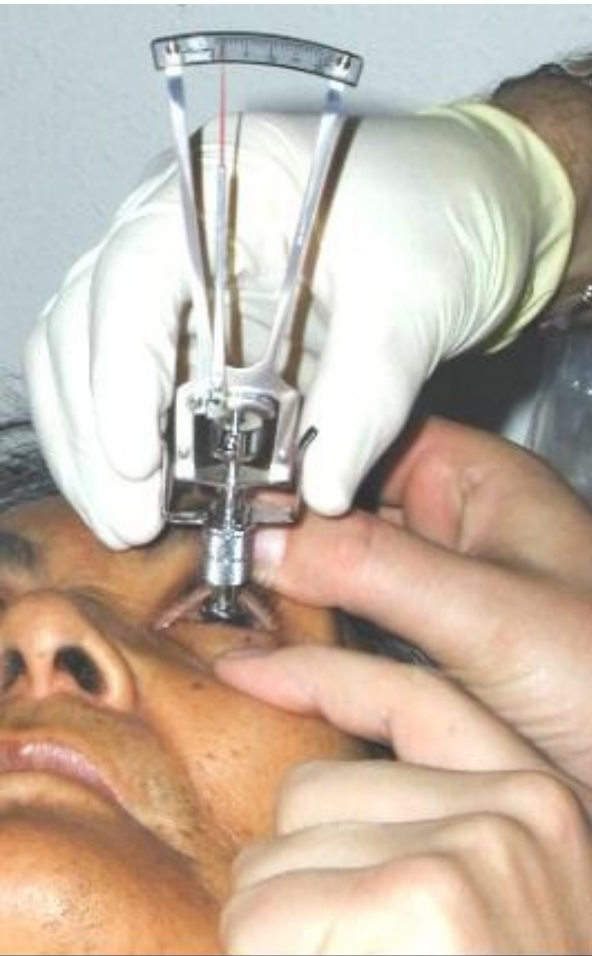

# Schiötz tonometry

- 7/7,5
- Topical aneesthesia



# Schiötz tonometry



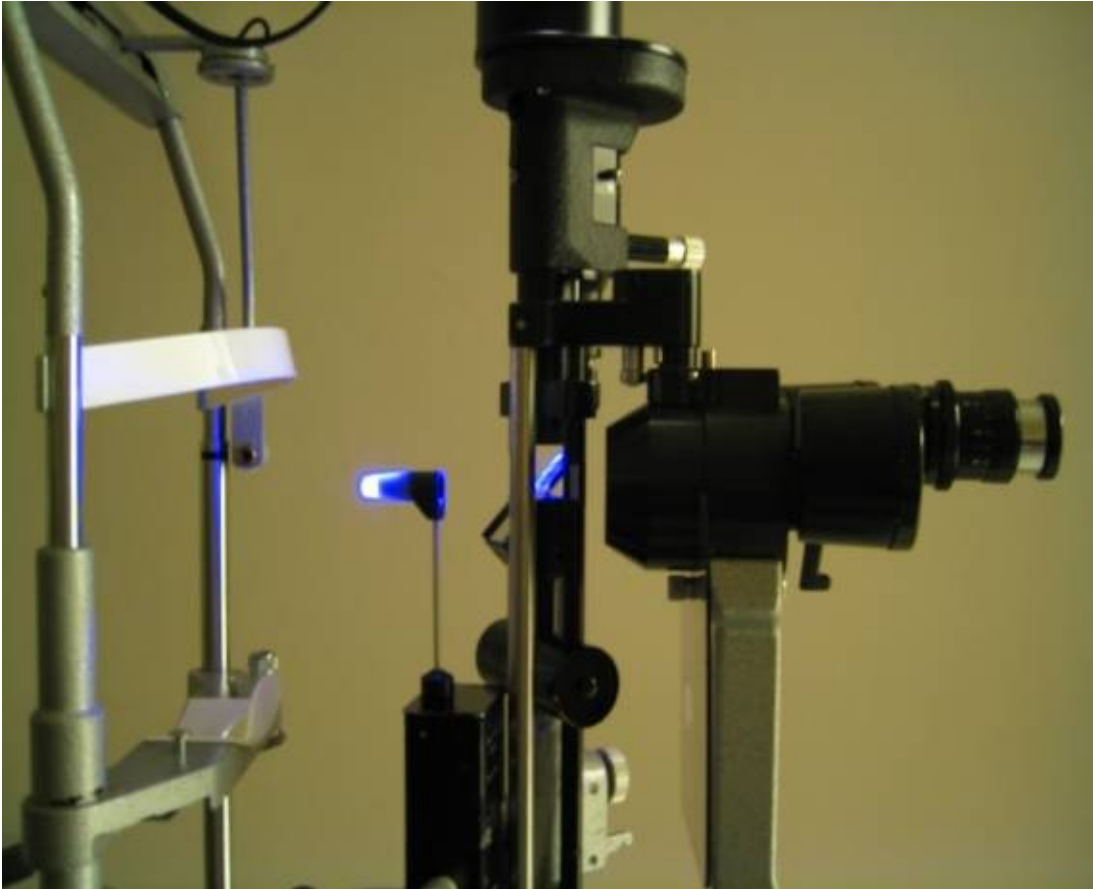


# Goldmann tonometry

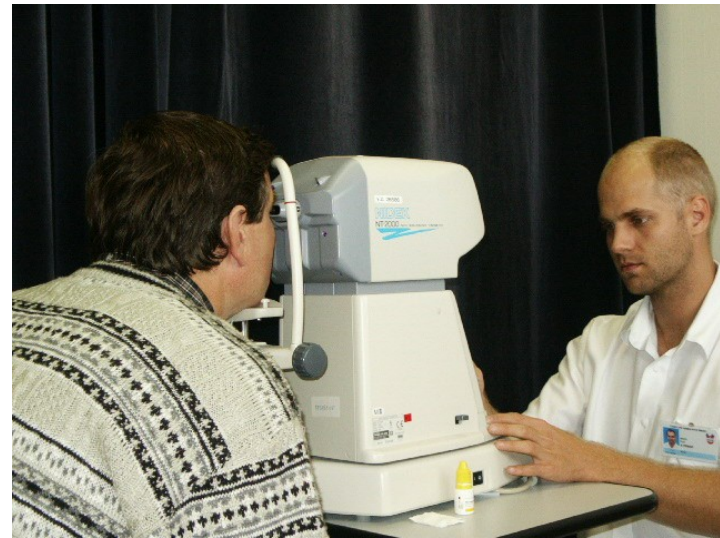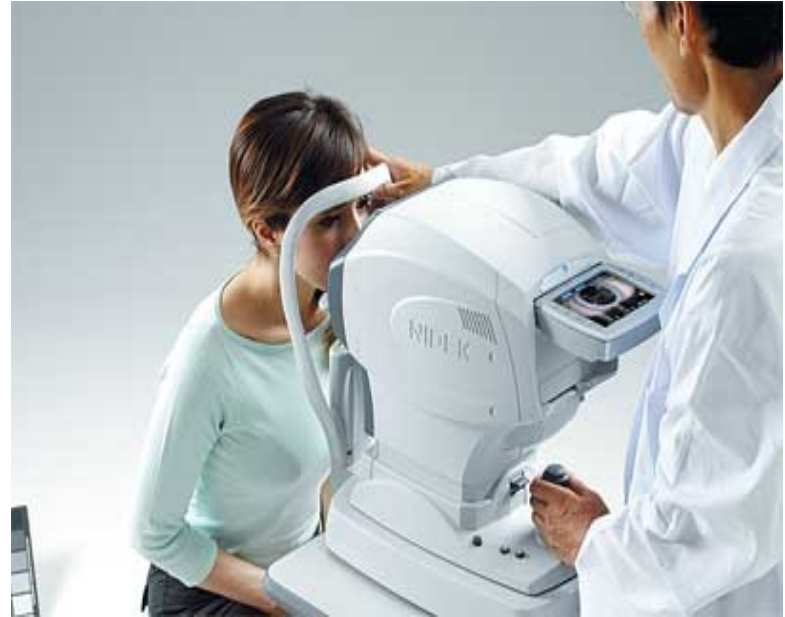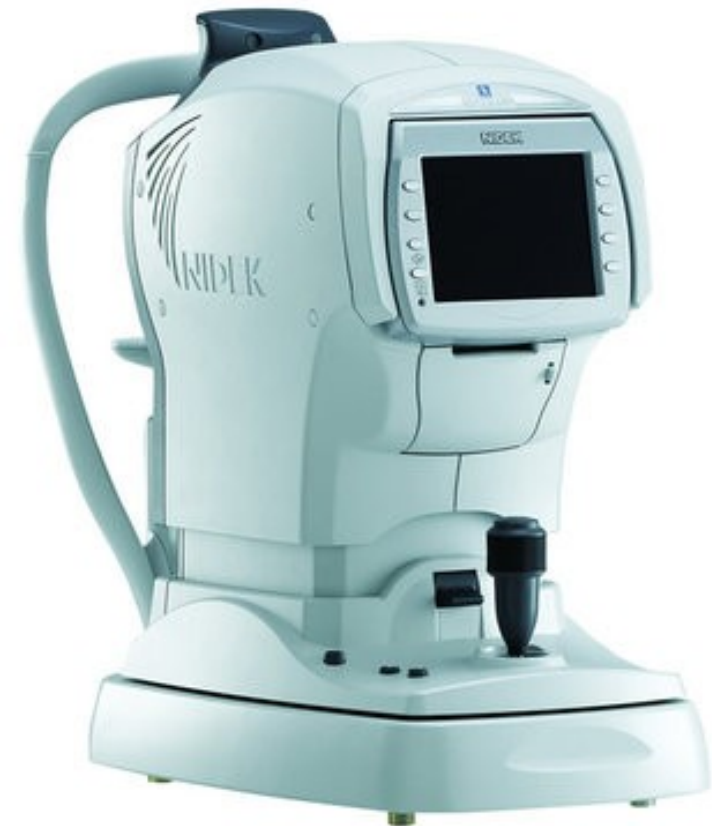- The normal range is 10-21 mmHg
- Topical anesthesia, fluorescein
- Force required to flatten the cornea



# Goldmann tonometry

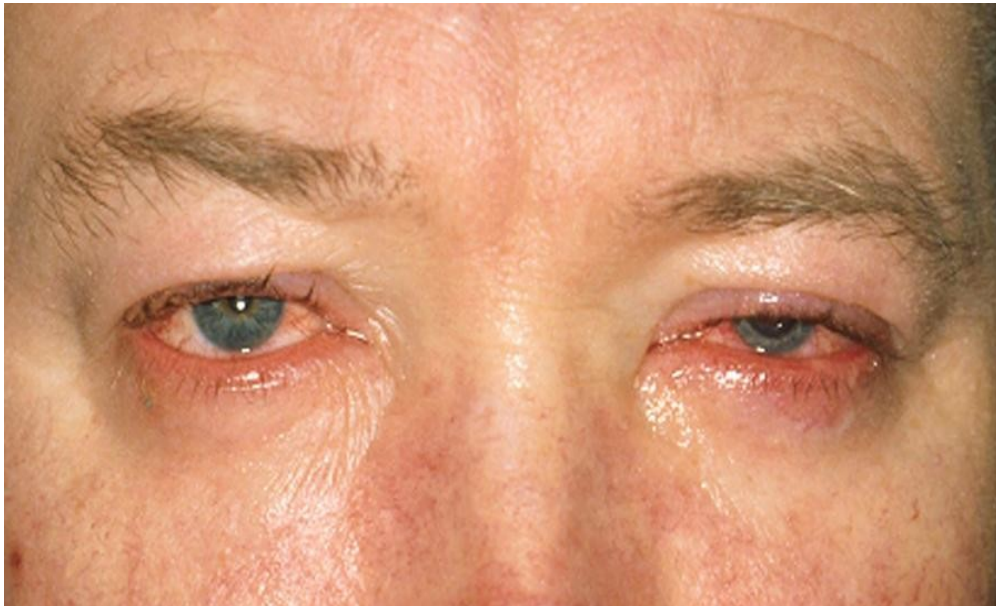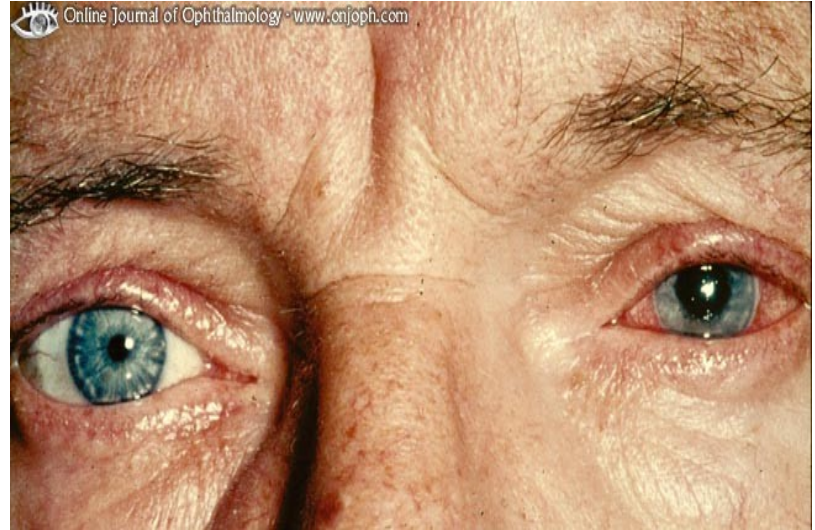


# Non contact tonometry



# Examination of anterior segment

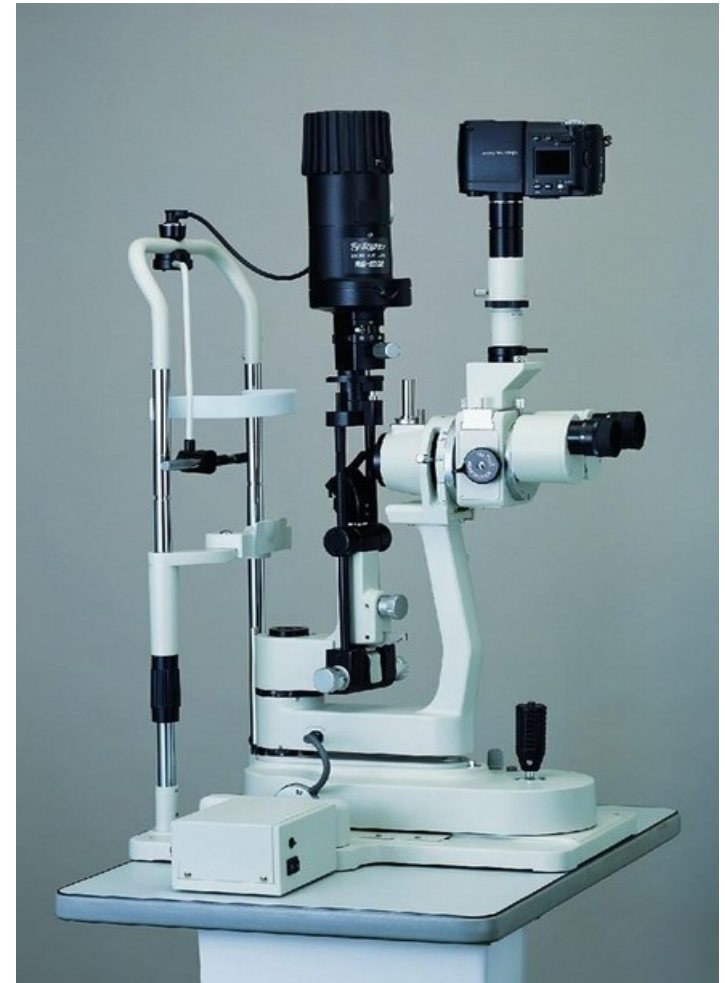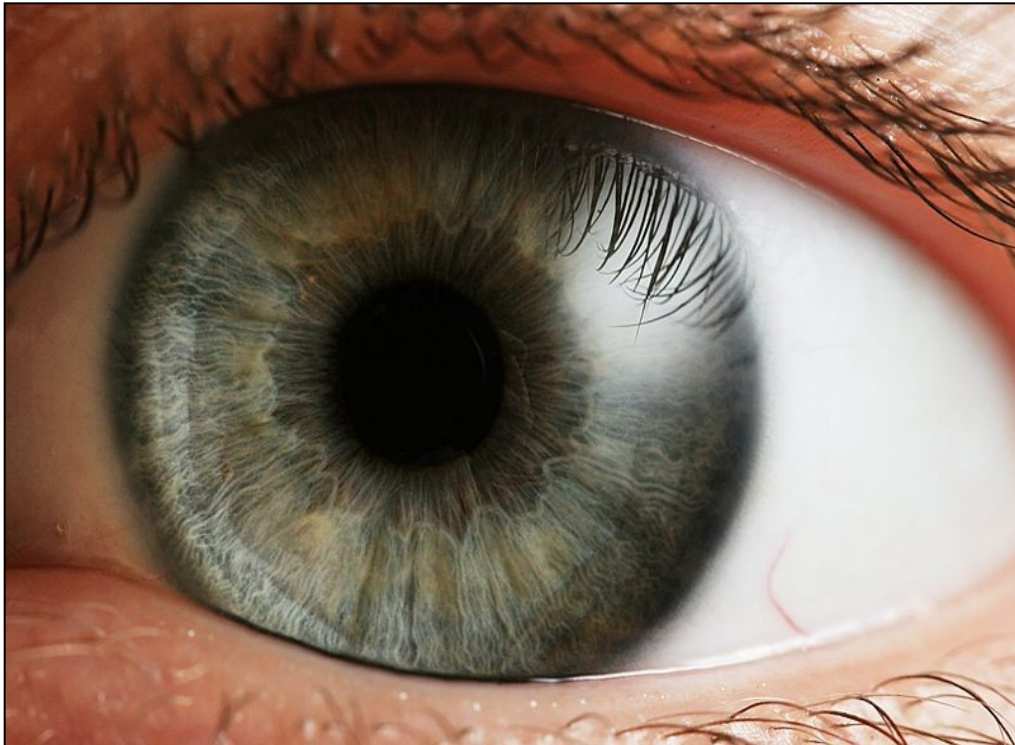
- Aspection



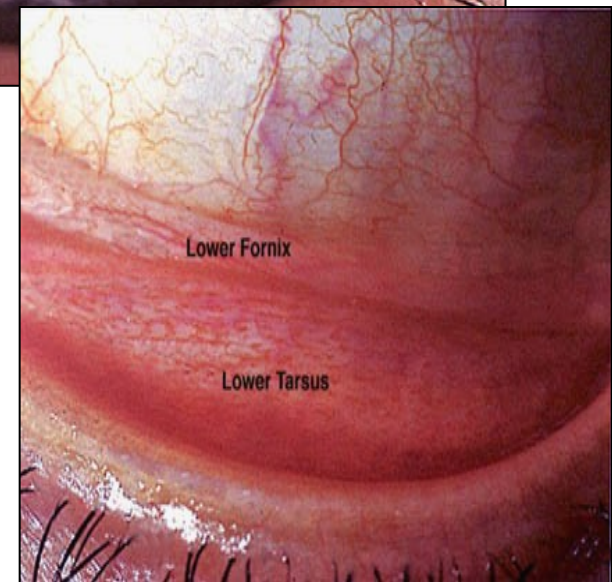
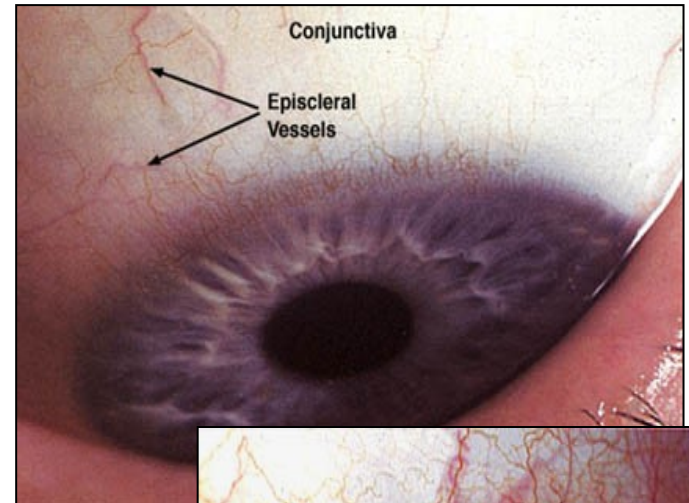
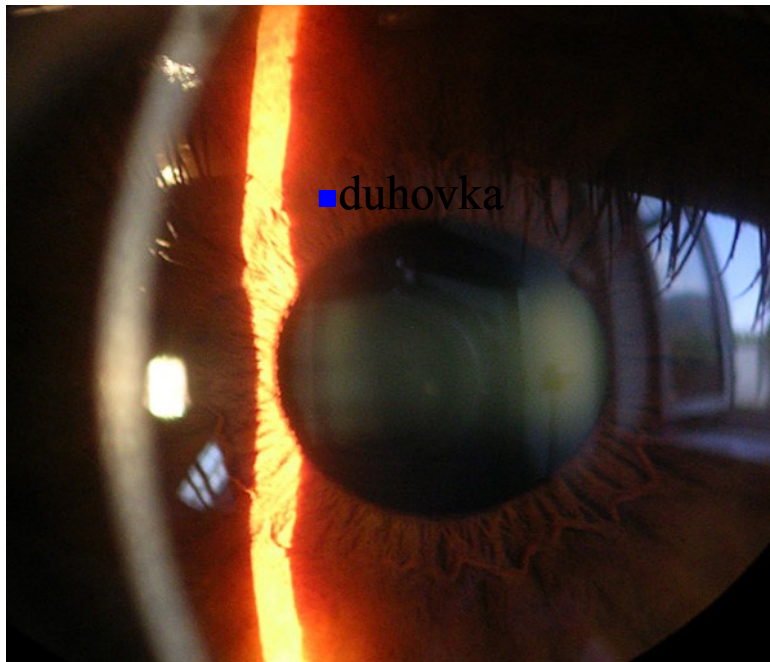


# Slit lamp biomicroscopy

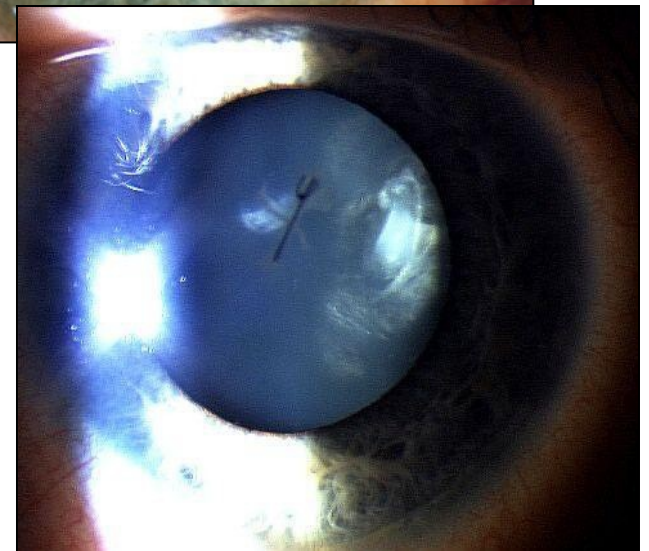
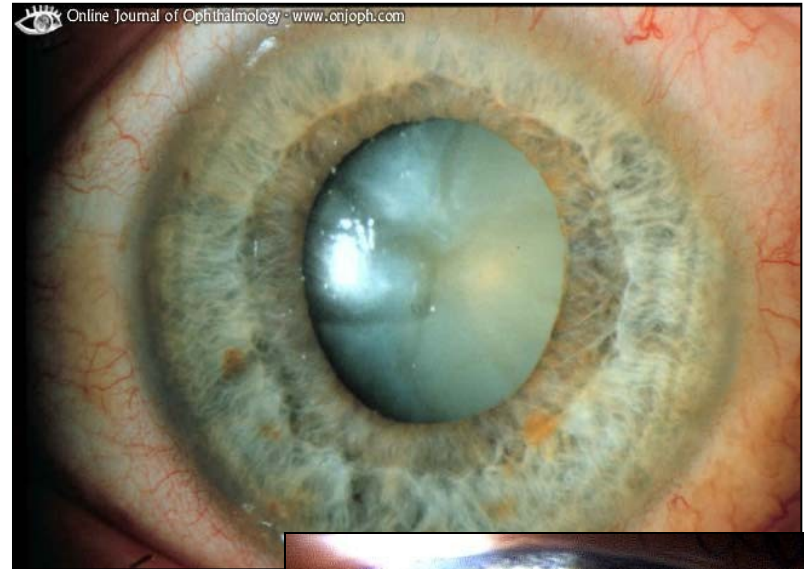
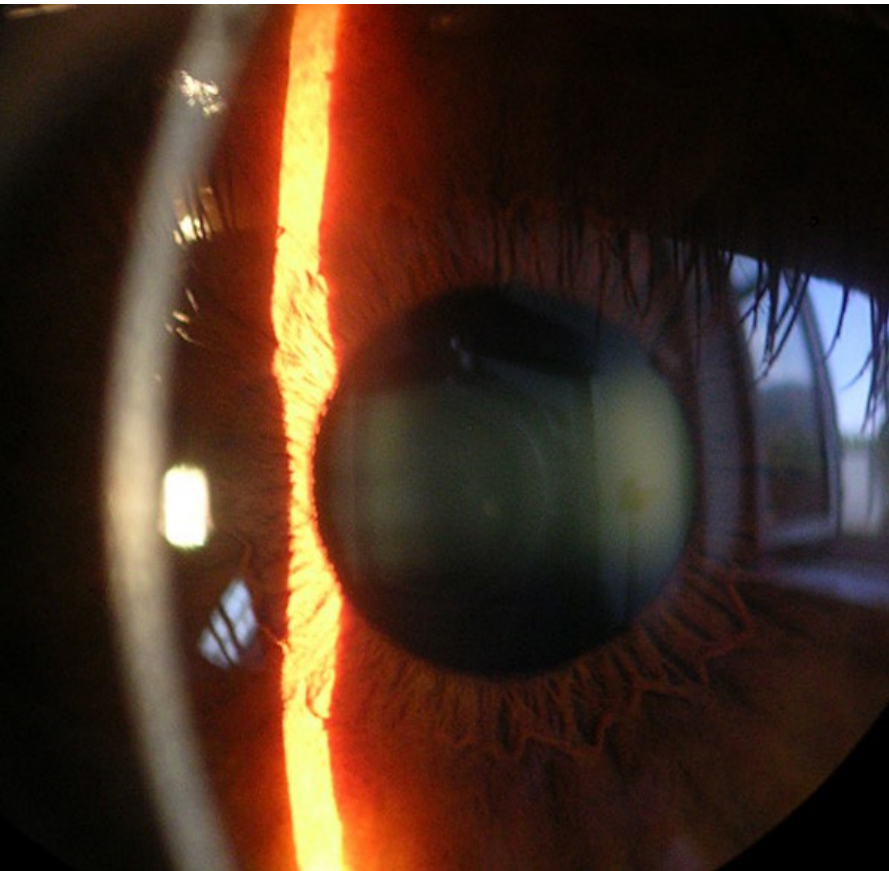
- table mounted microscope with a special adjustable illumination source attached



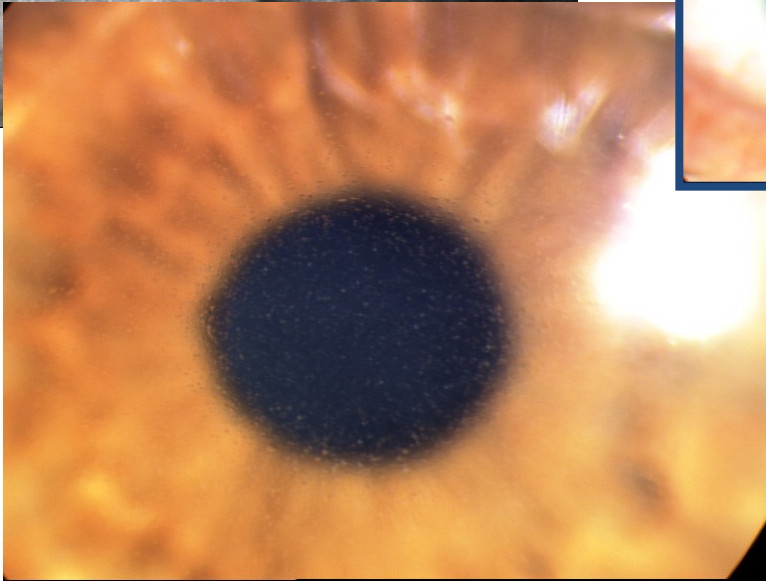
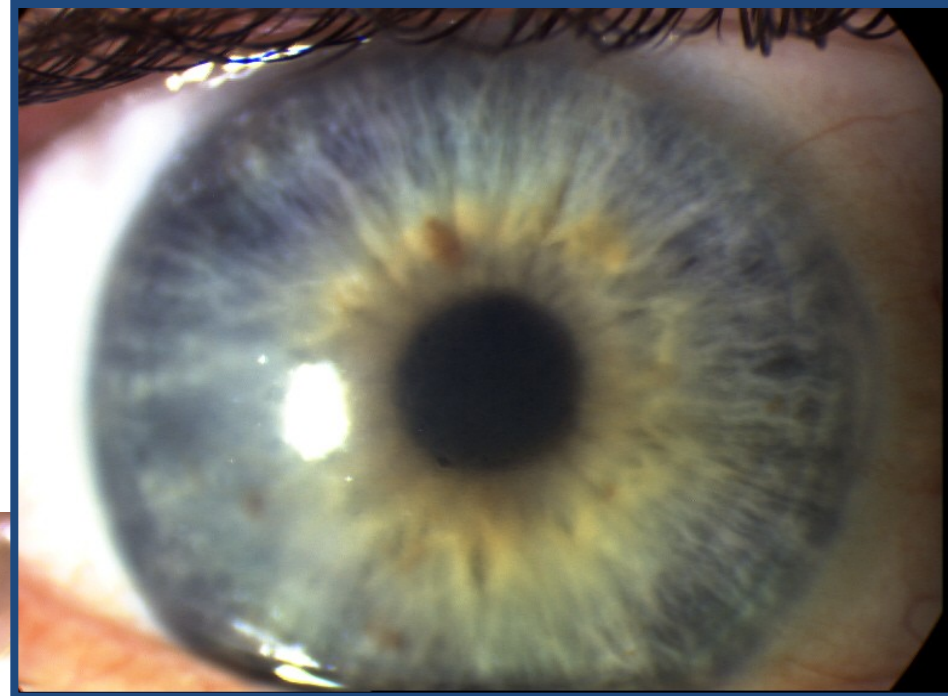
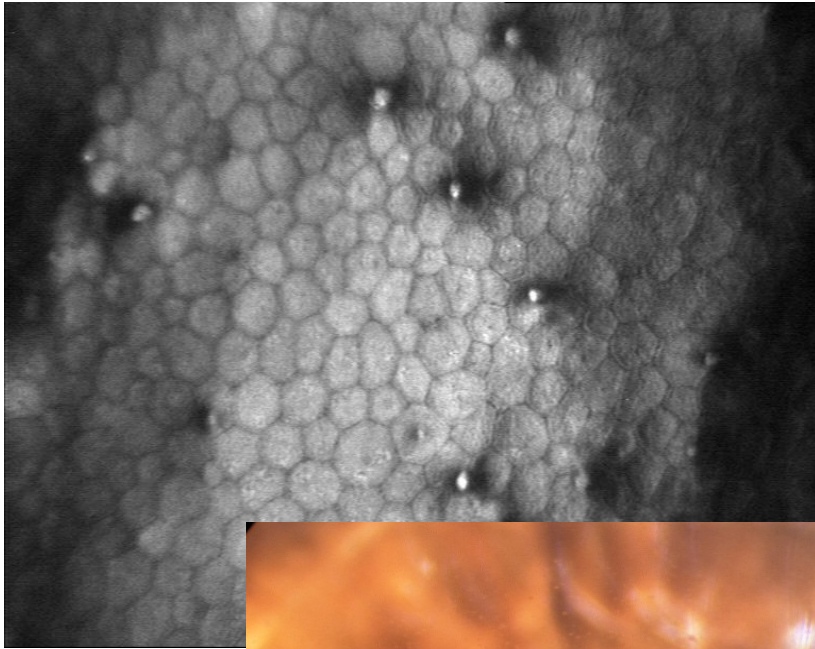
# Slit lamp biomicroscopy



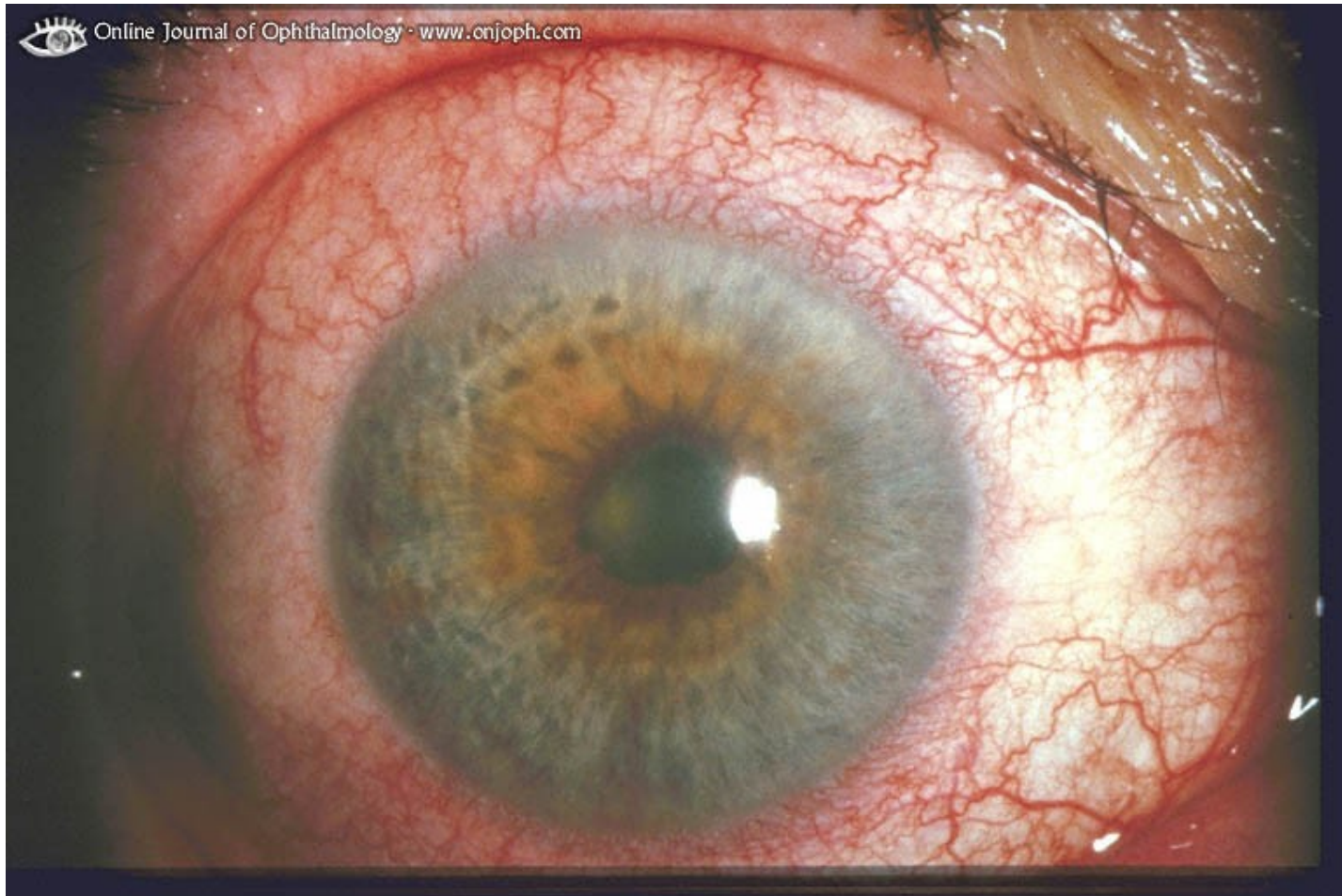# Slit lamp biomicroscopy



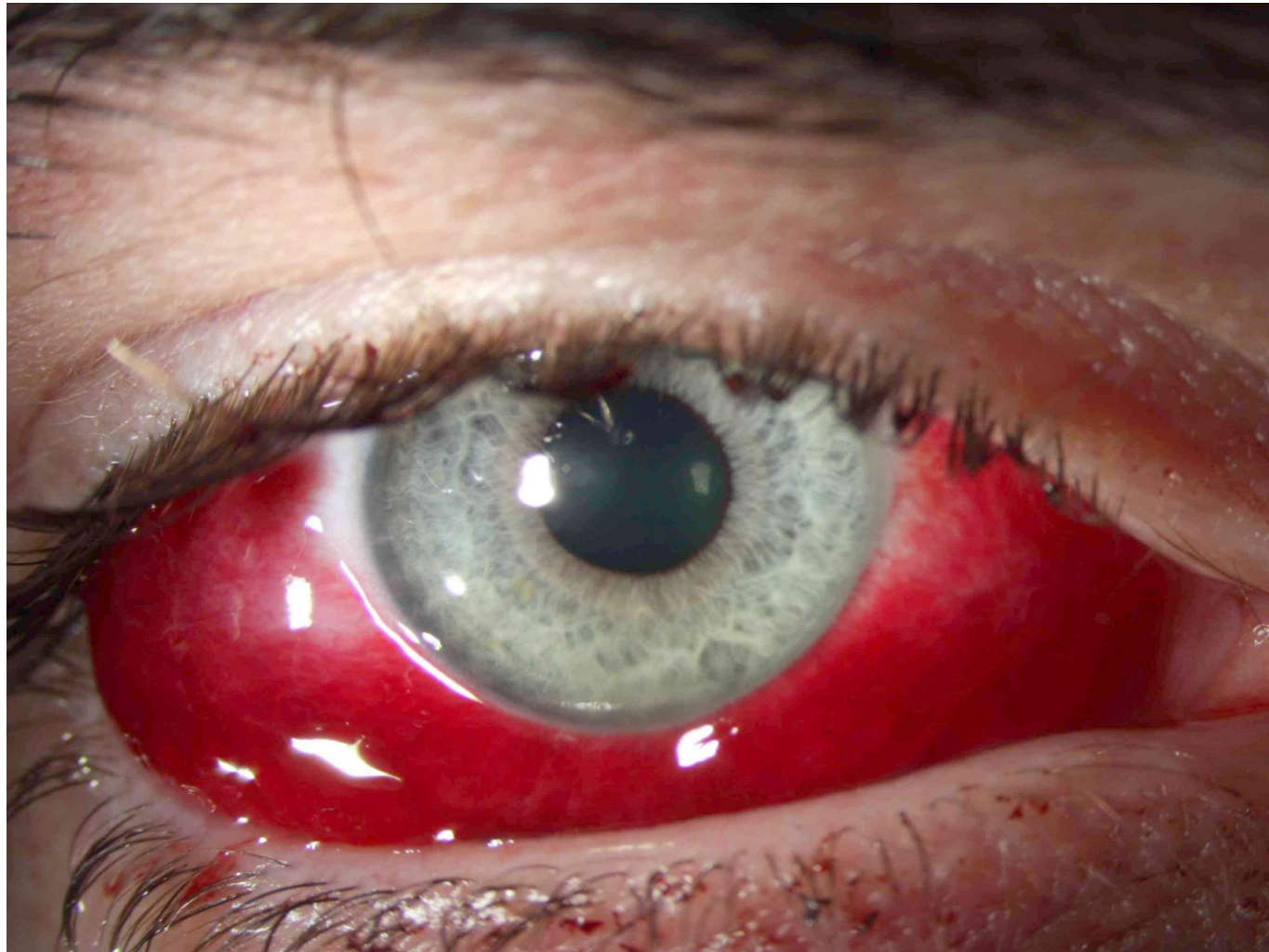
# Fuchs endothelial dystrophy



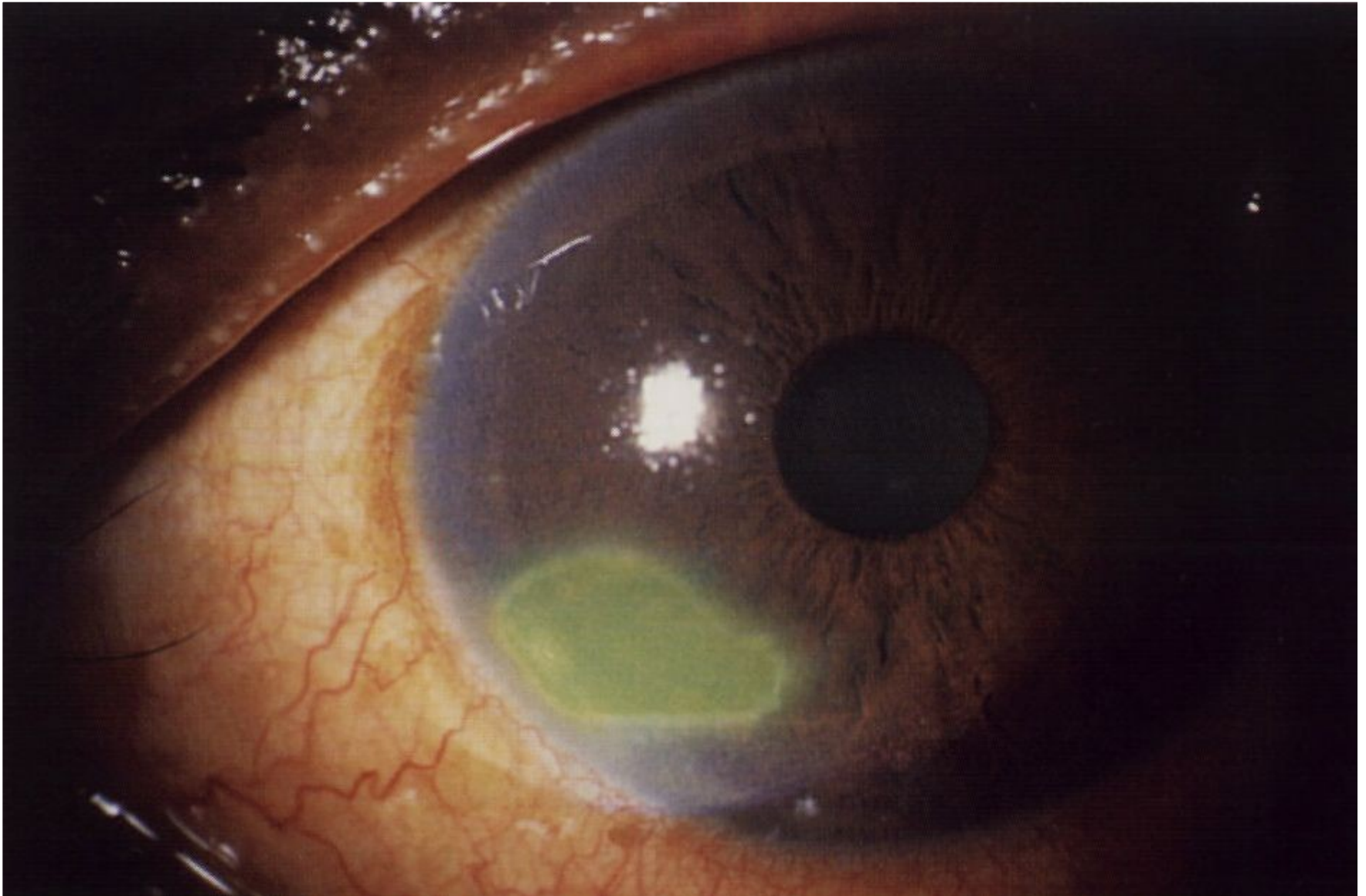
# Synechia posterior



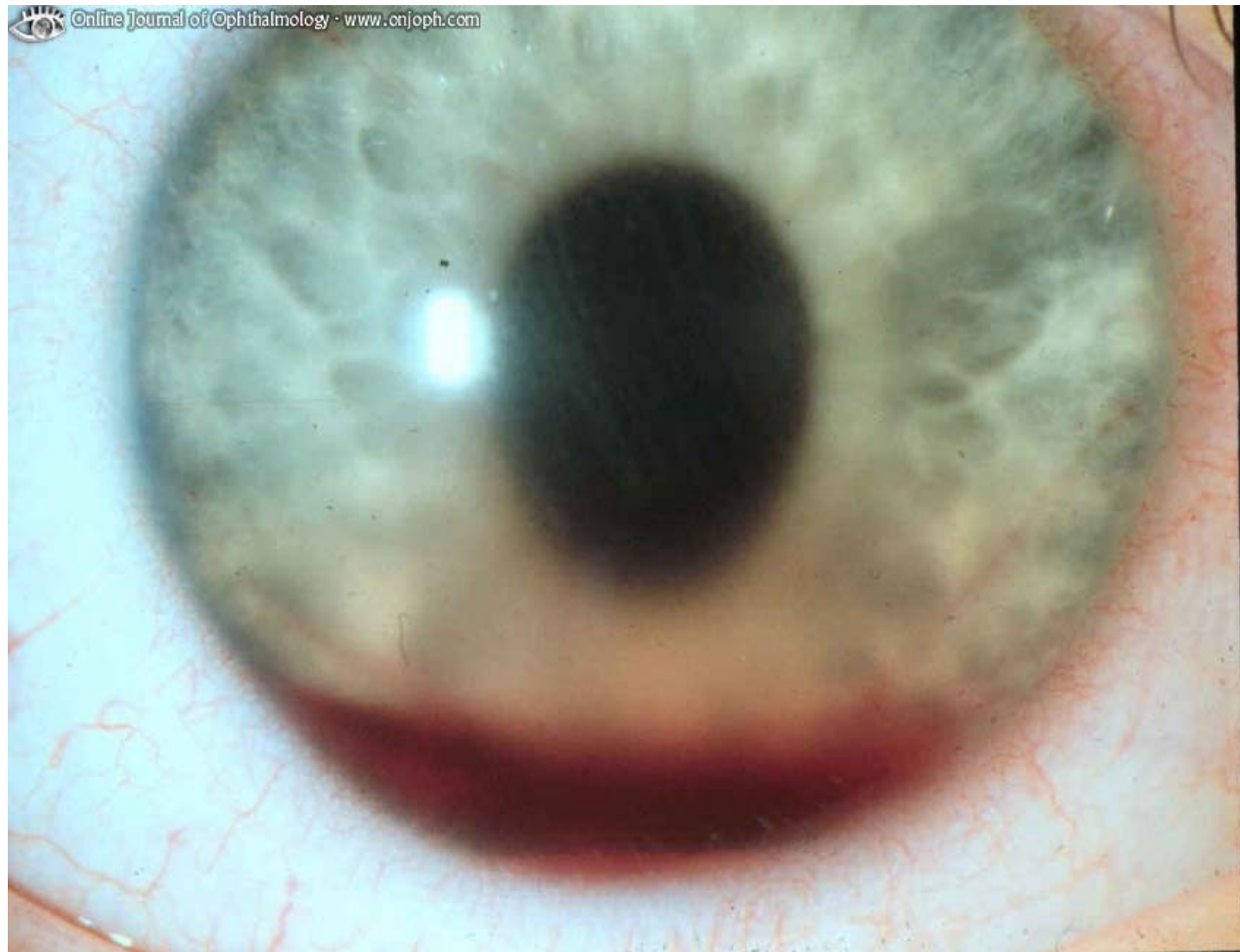# Sunconjunctival haemorrhage



# Corneal abrasion

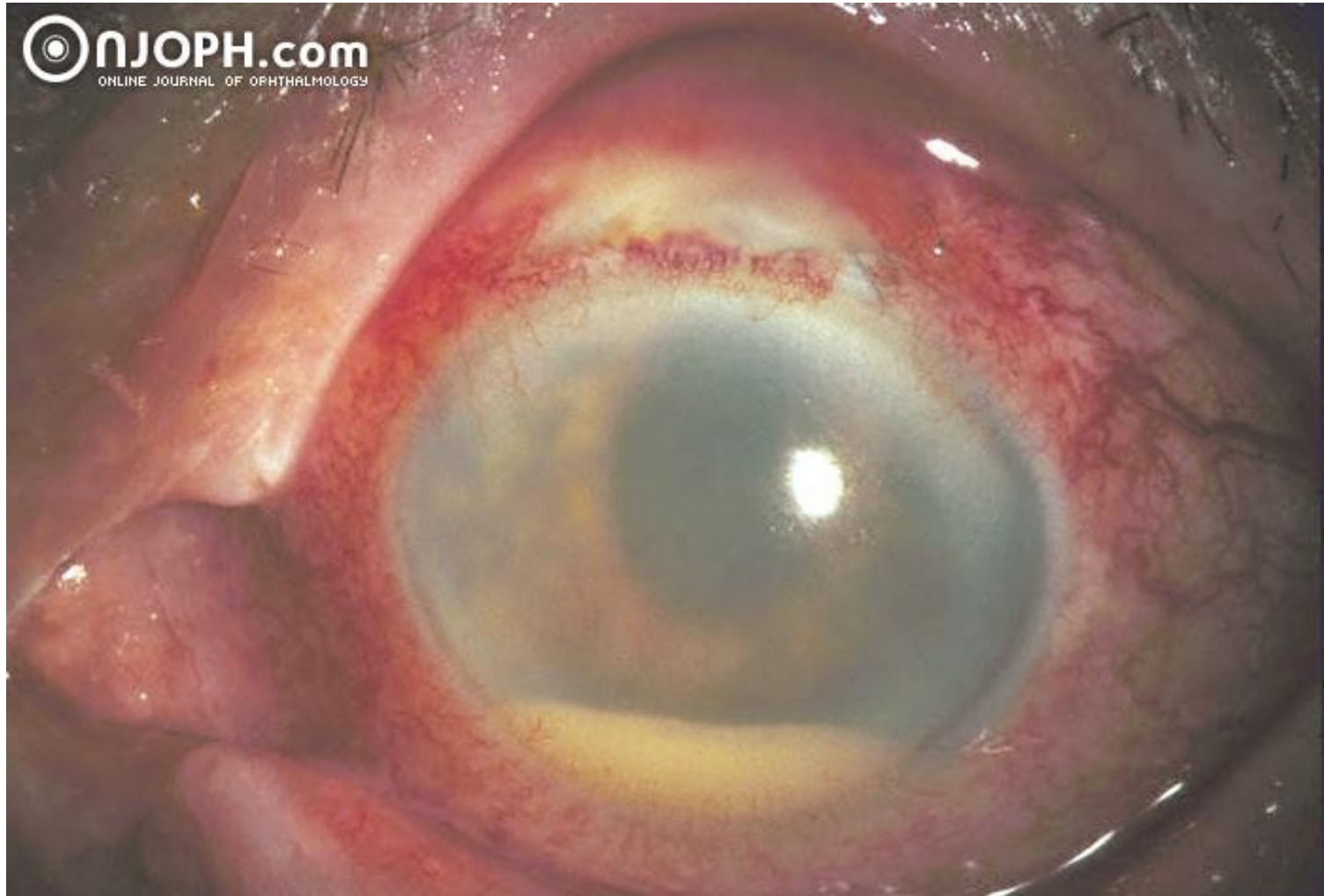

# Hyphema



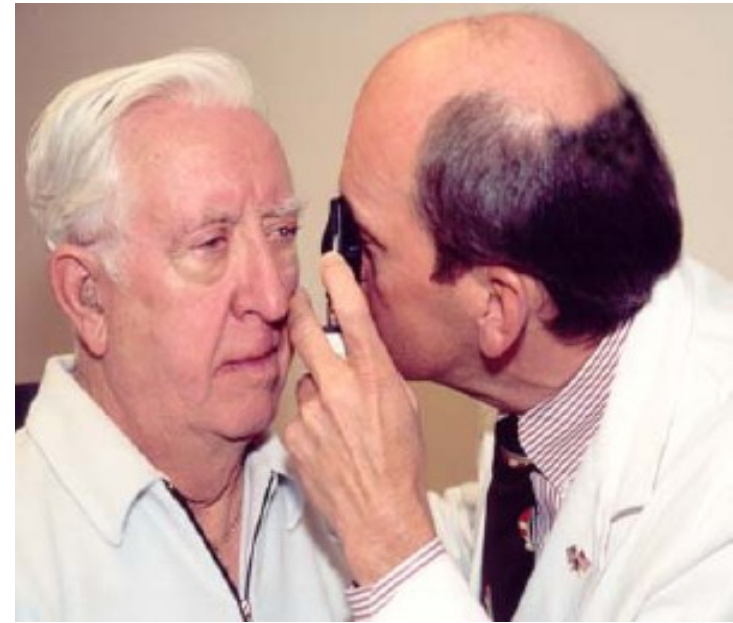
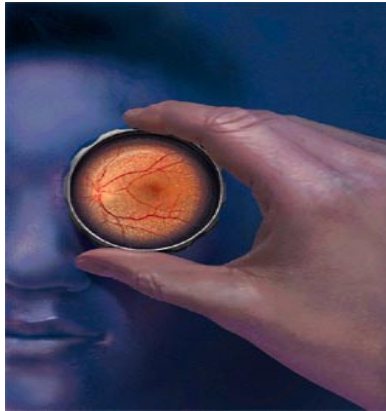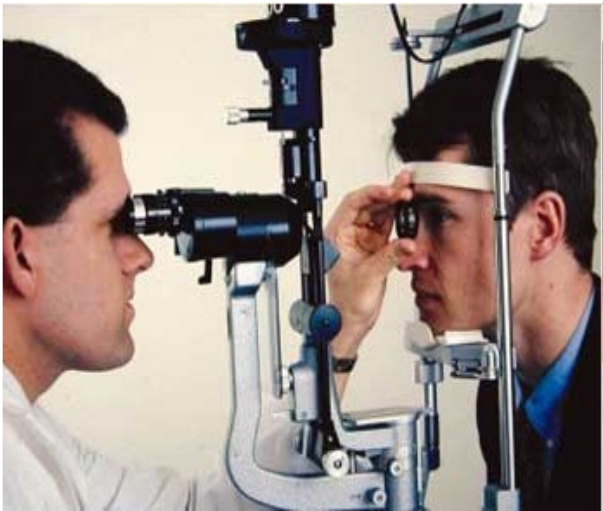


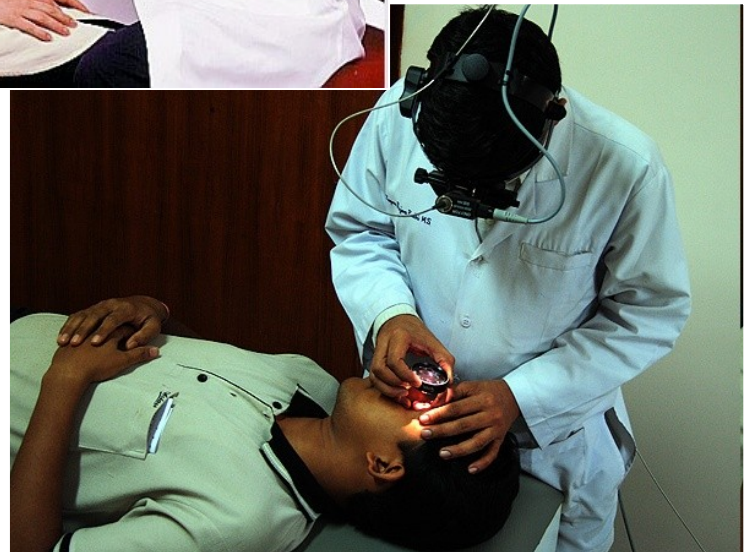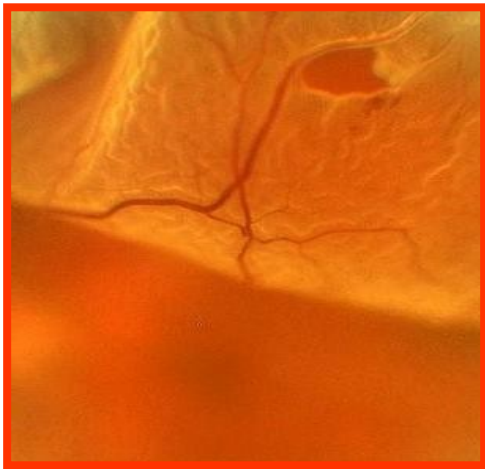
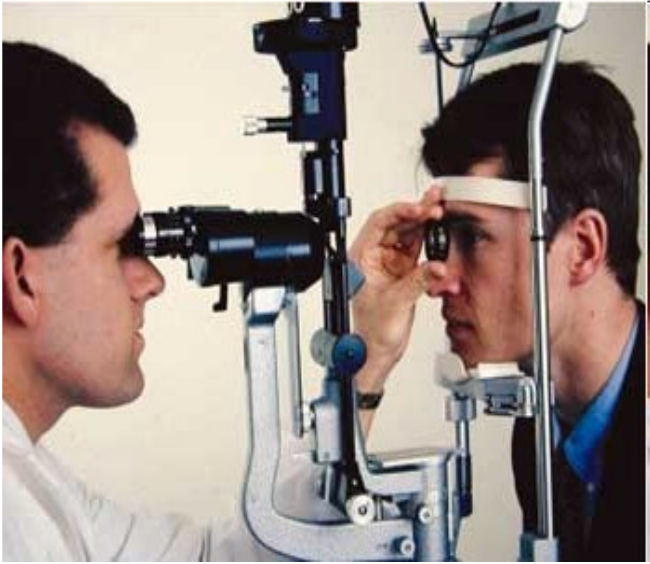# Hypopyon



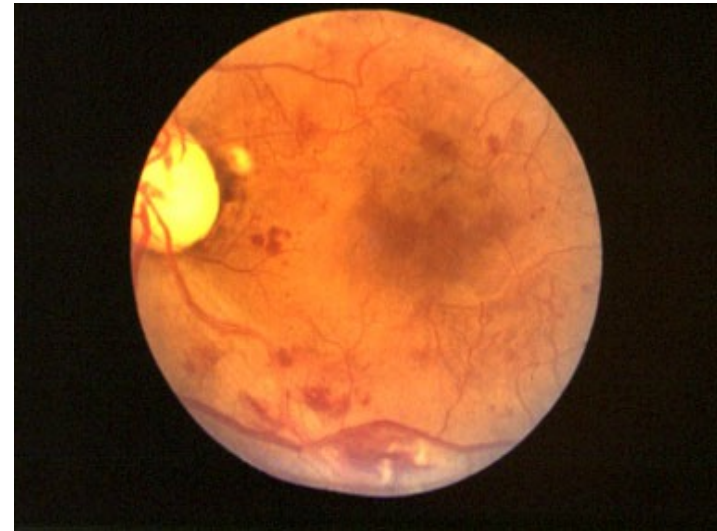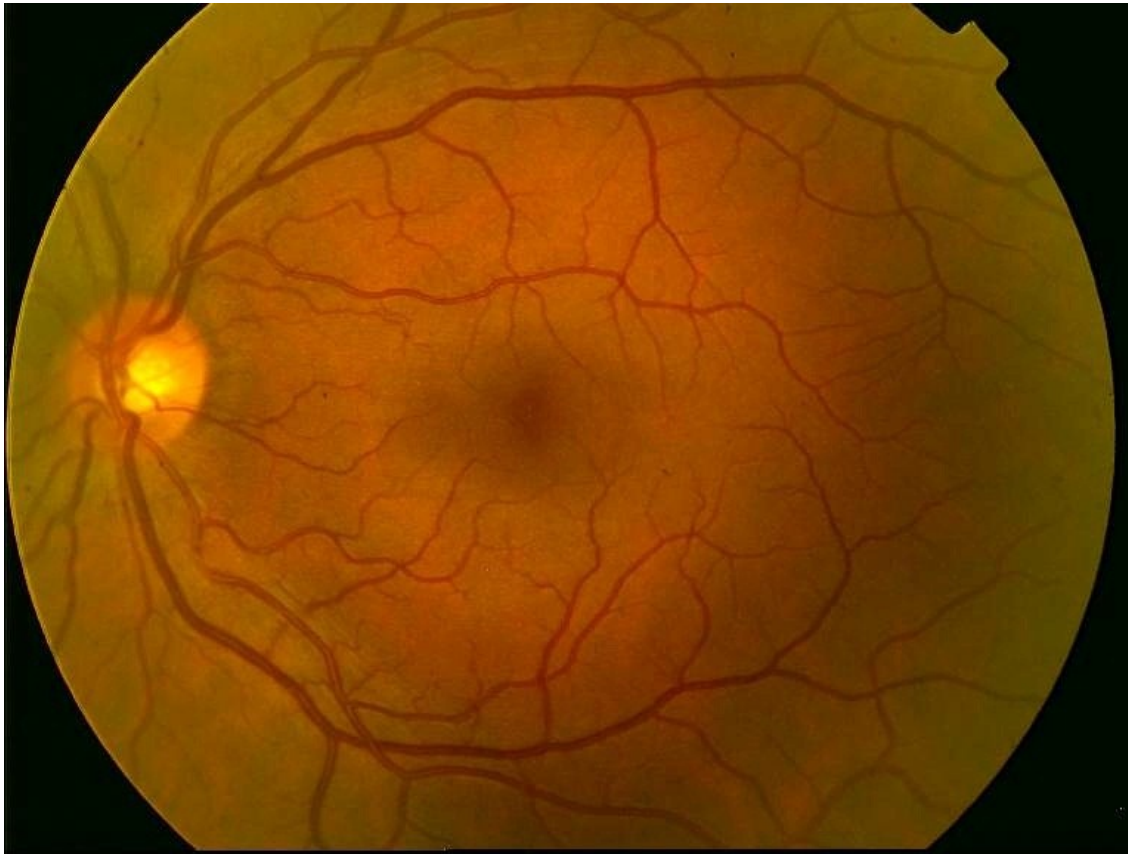
# Examination of fundus

- **Ophthalmoscopy - direct**  
- indirect
- **Slit lamp biomicroscopy**  
(high power convex lens, the image is vertically inverted and laterally reversed)



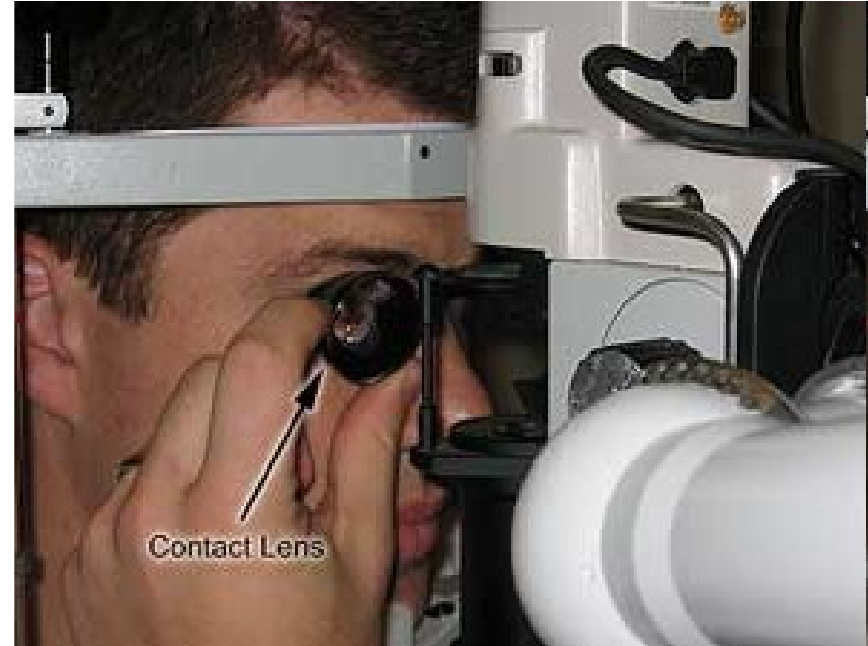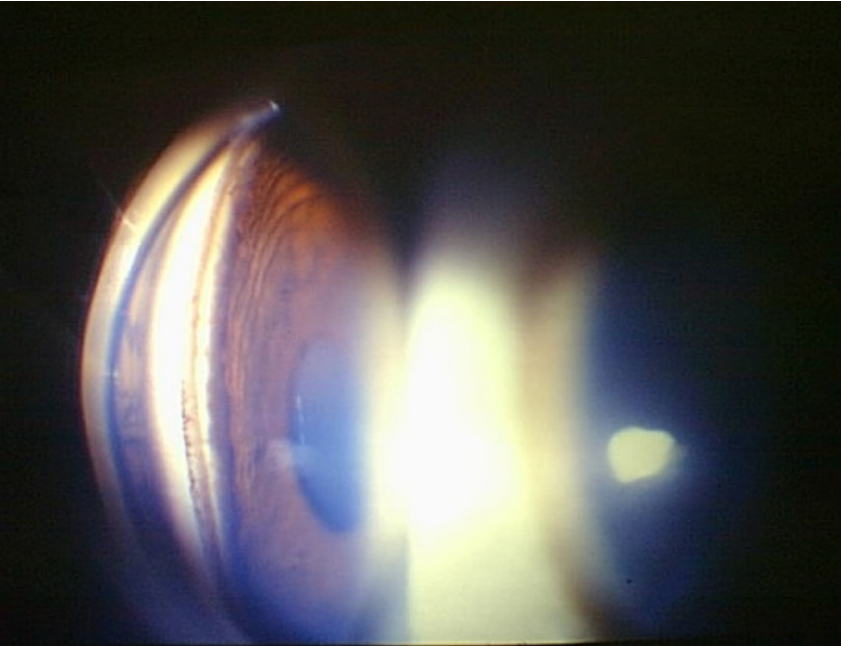


# Ocular fundus

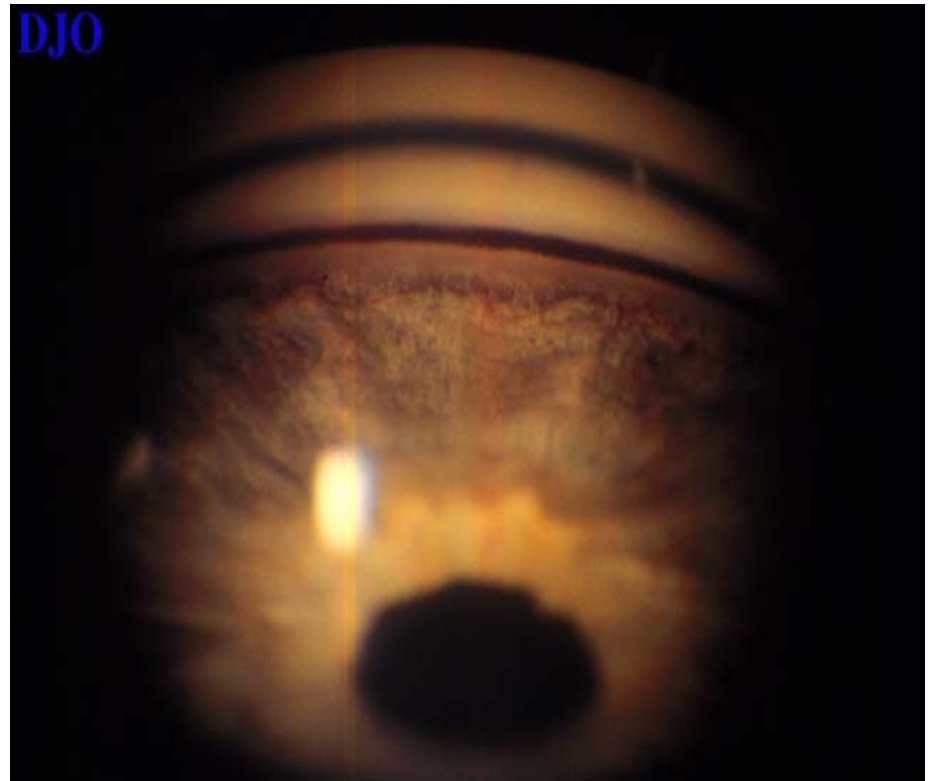
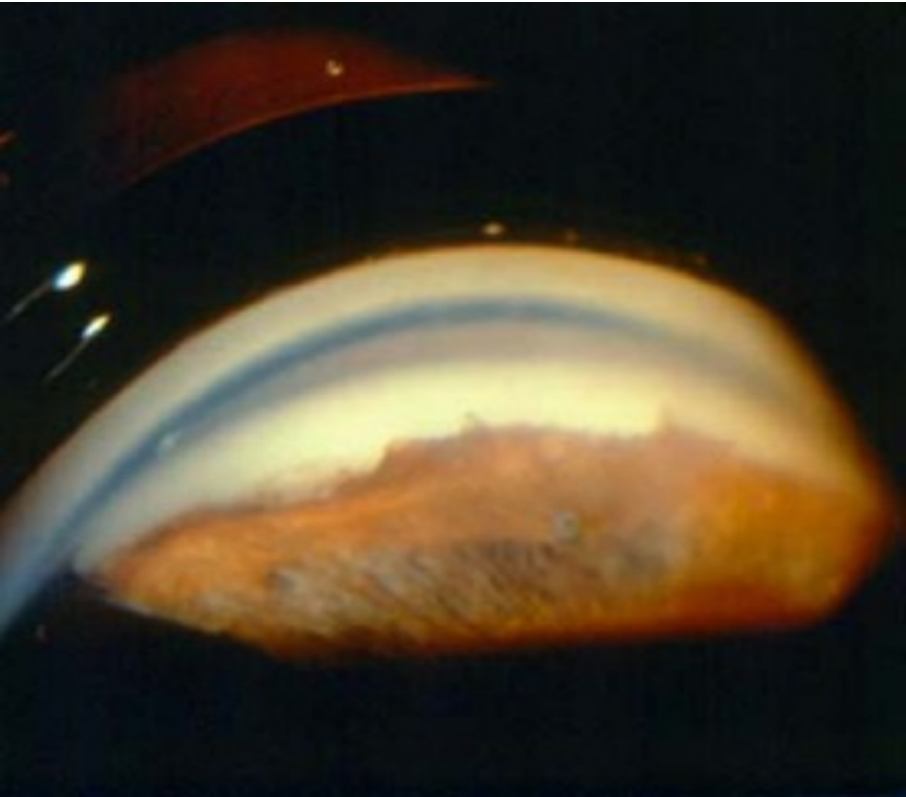

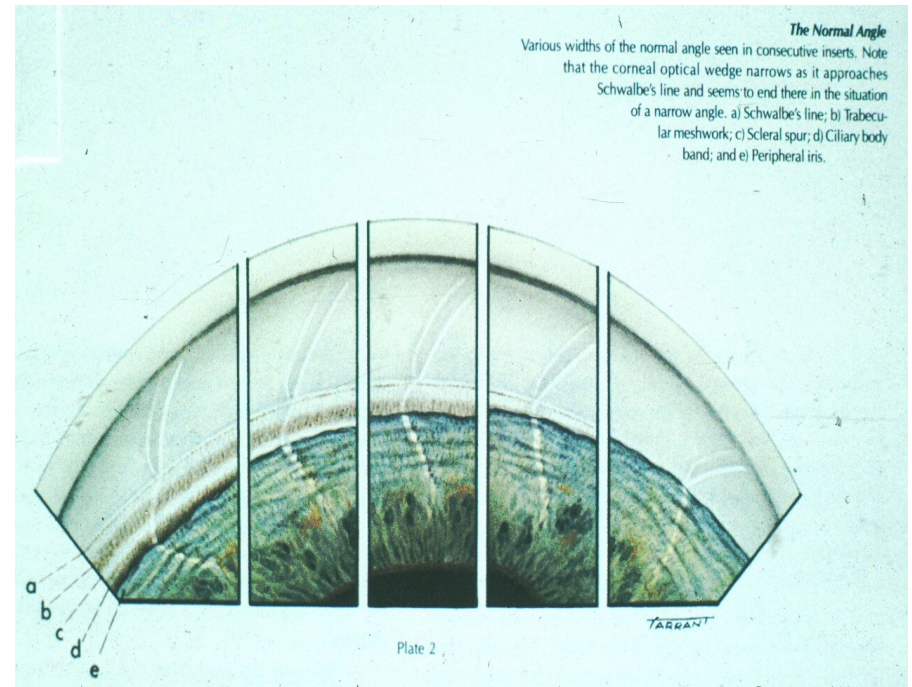
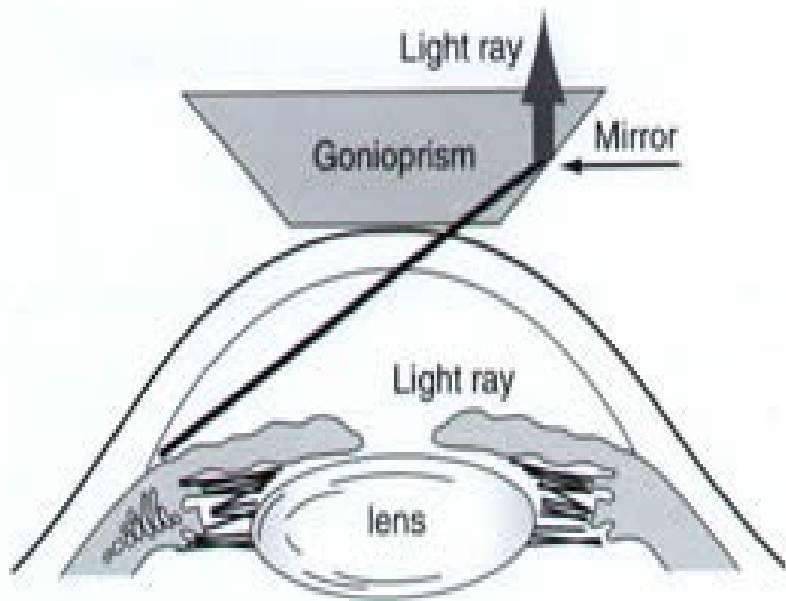
# Special examination techniques

# Gonioscopy



- Gonio lens ( mirrors)
- Angle structures
- Fundus examination



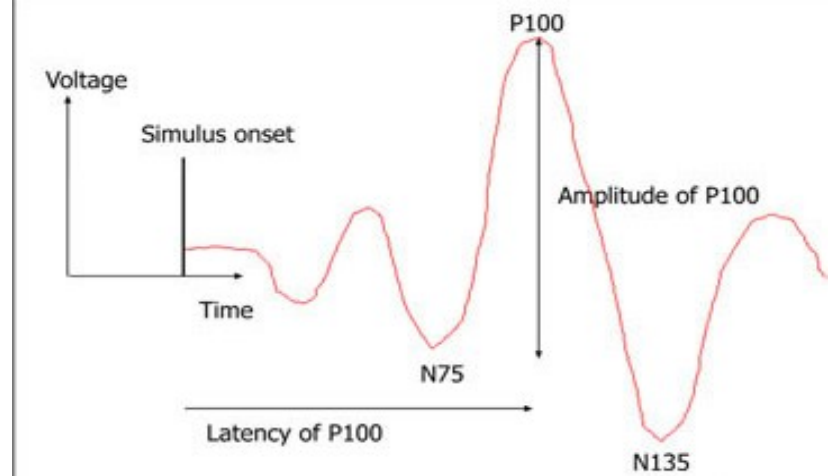
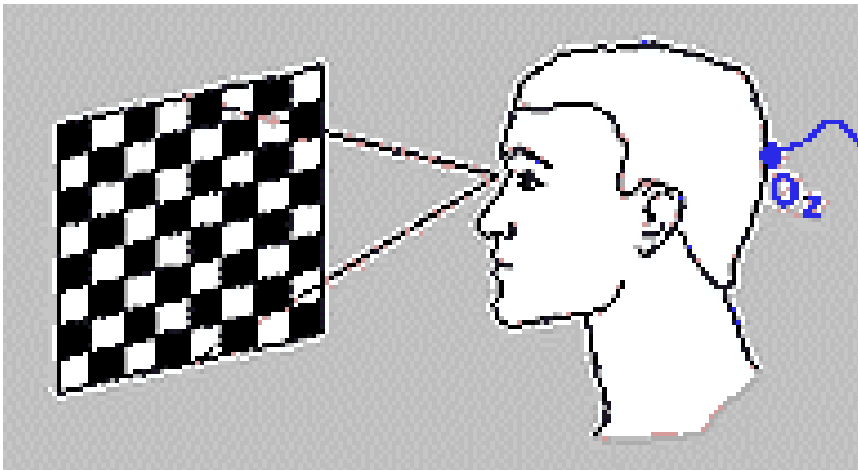




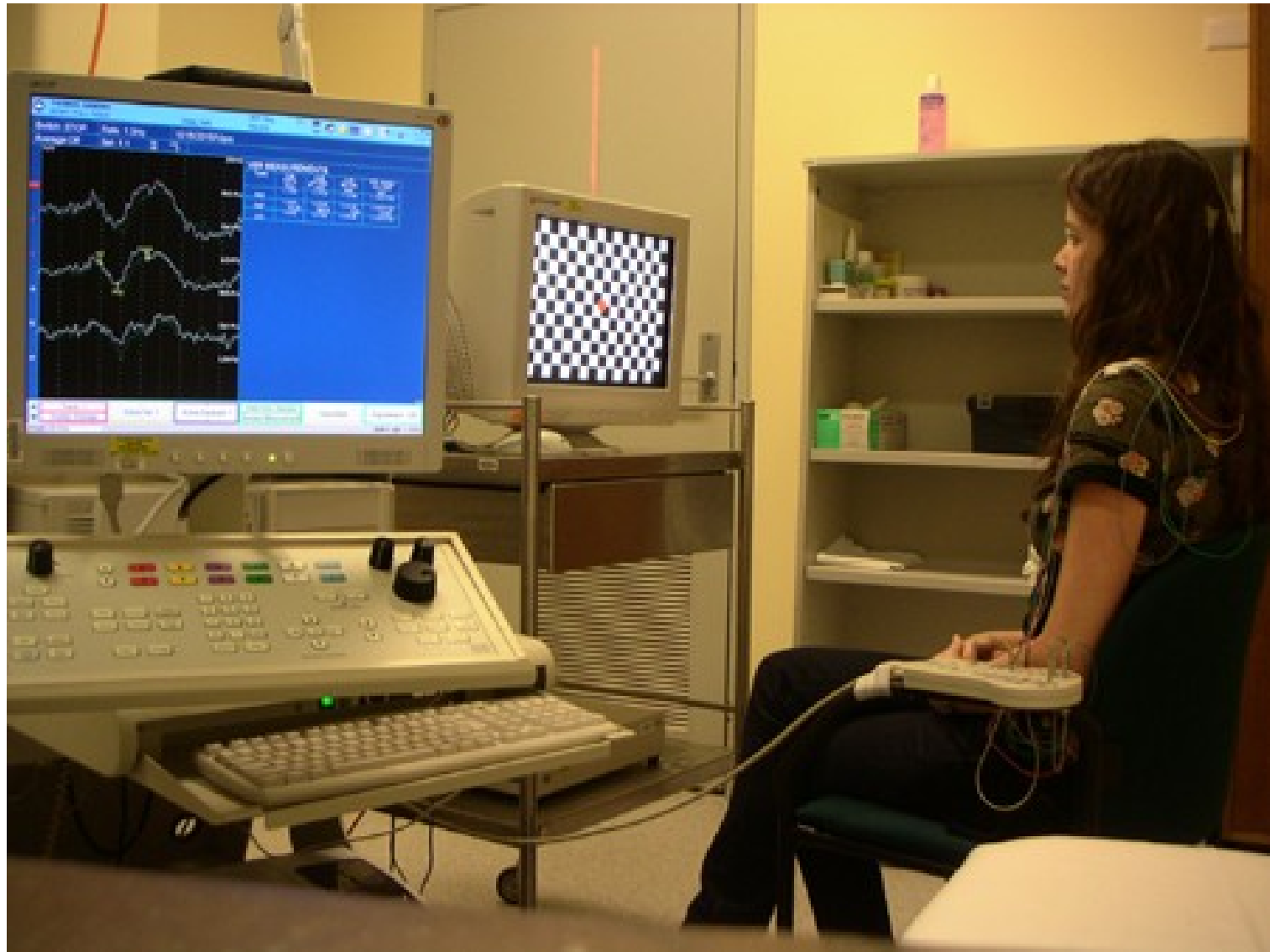# Electrophysical tests

- **ERG (electroretinography)**  
diagnosis of functional defects of retina
- Record of an action potential produced by the retina when it is stimulated by light
  
- **VEP (visual evoked potential)**  
-diagnosis of functional defects of visual pathways
- Record of electrical activity of the visual cortex created by stimulation of the retina

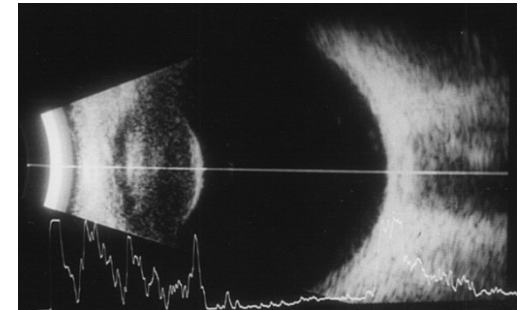
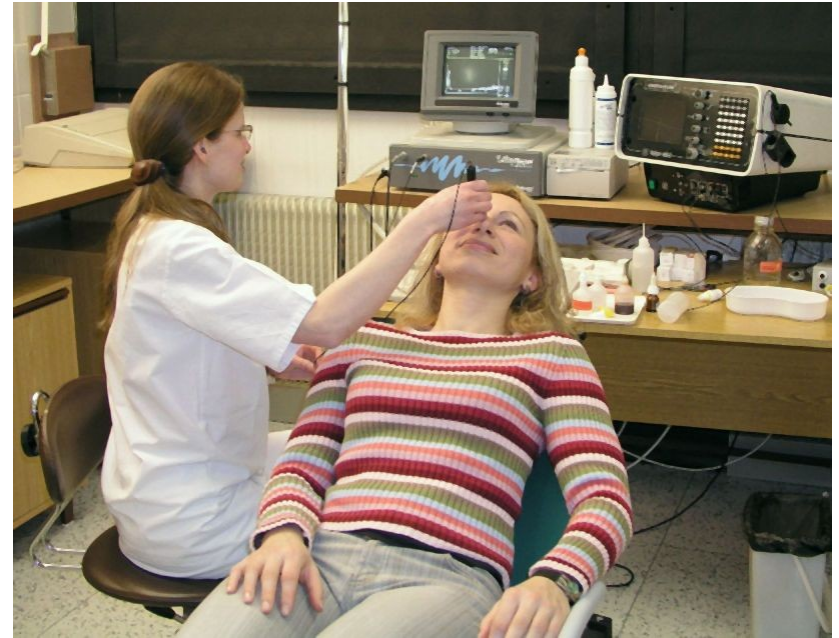# Electrophysical tests



# Electrophysiological tests

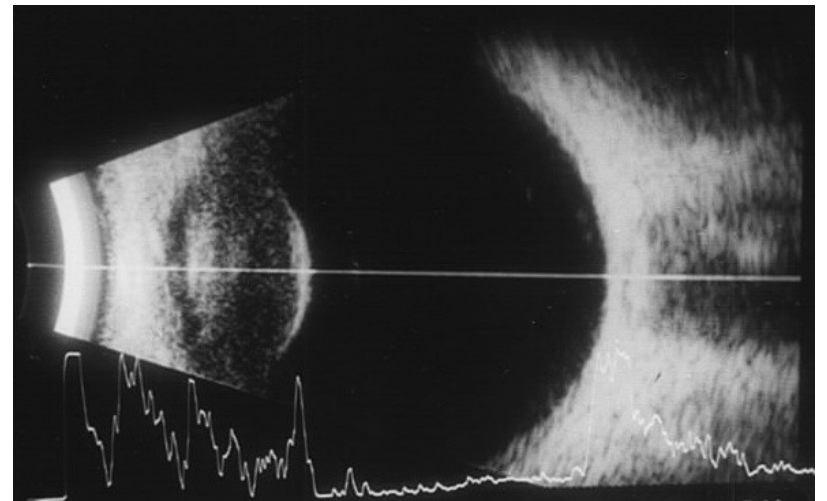
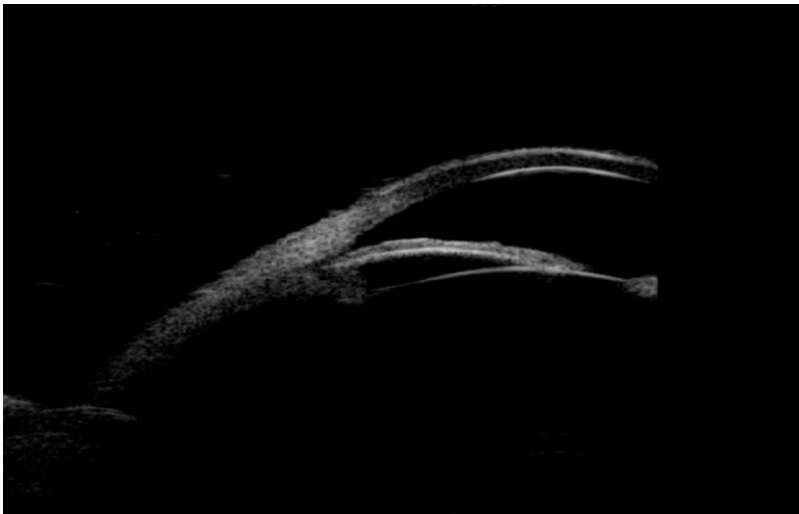


# Ultrasound

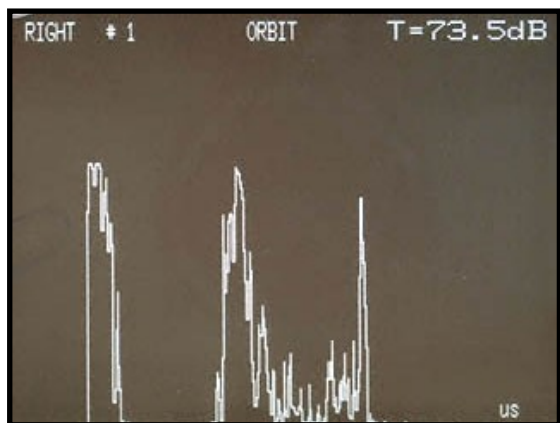


# Ultrasound

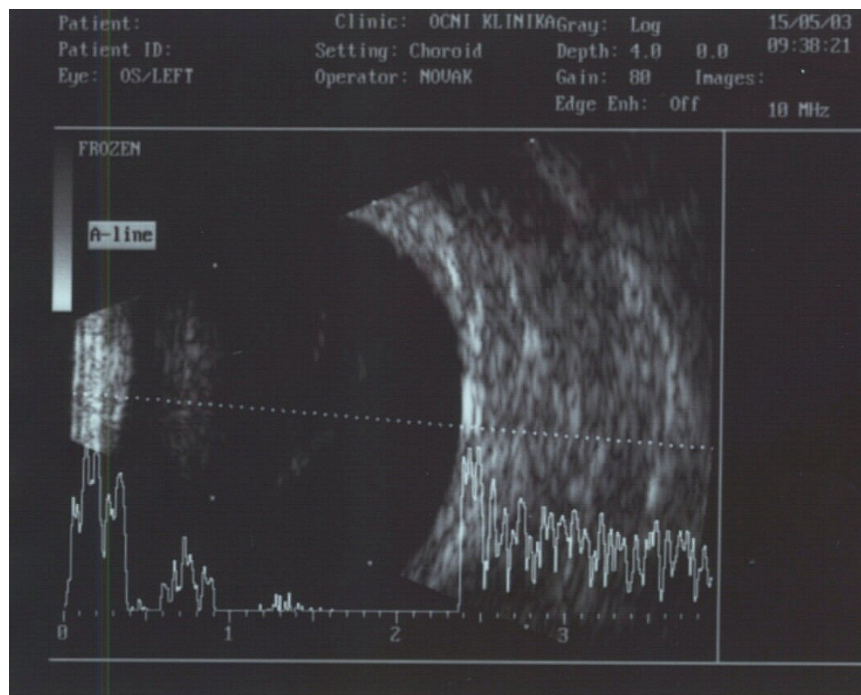
- Non transparent optical media
- UBM- high frequency ultrasound – imaging of anterior segment



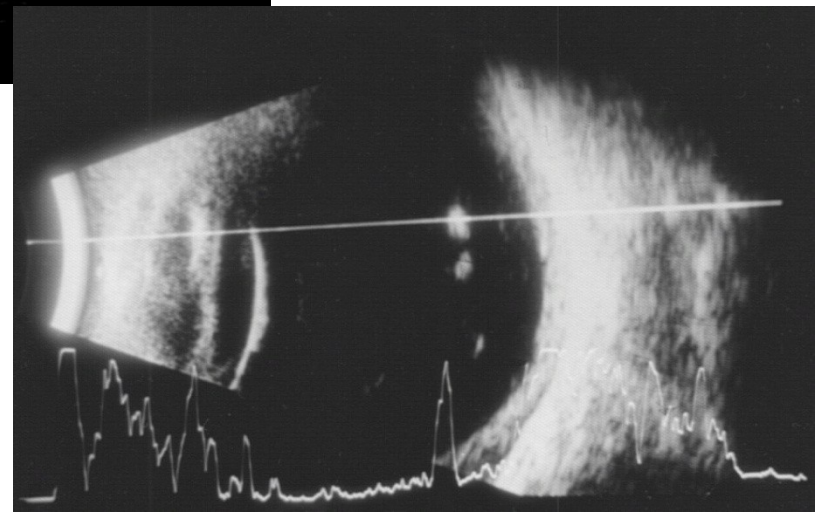
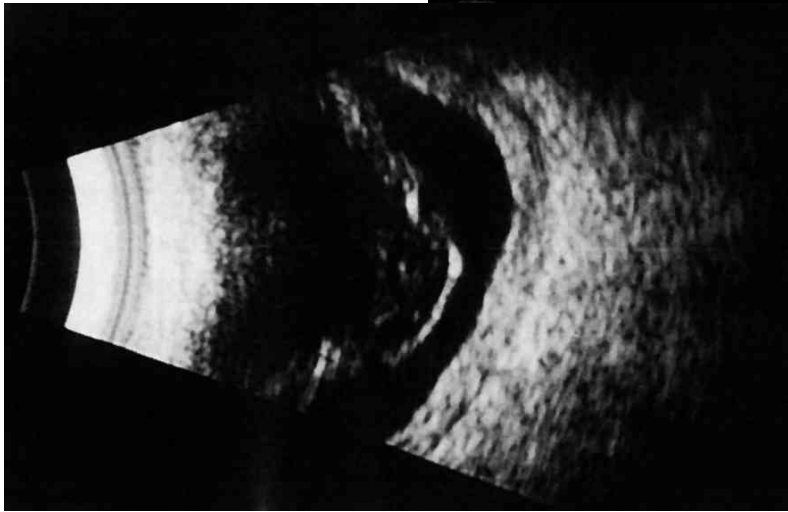
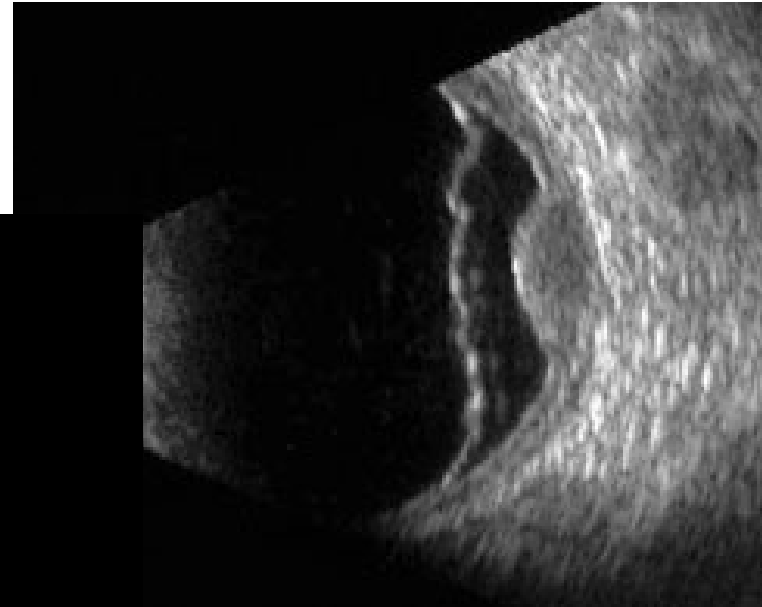
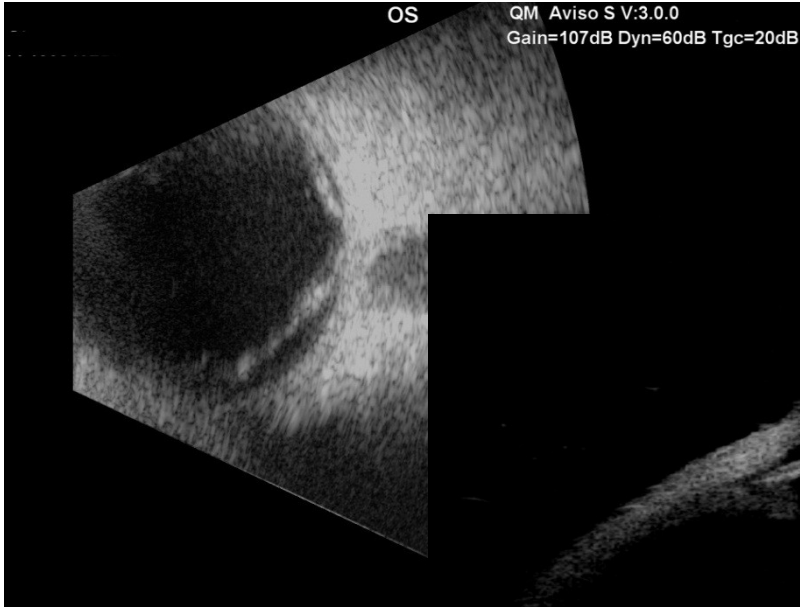
- **A scan ( biometry)**




- **B scan**



# Ultrasound

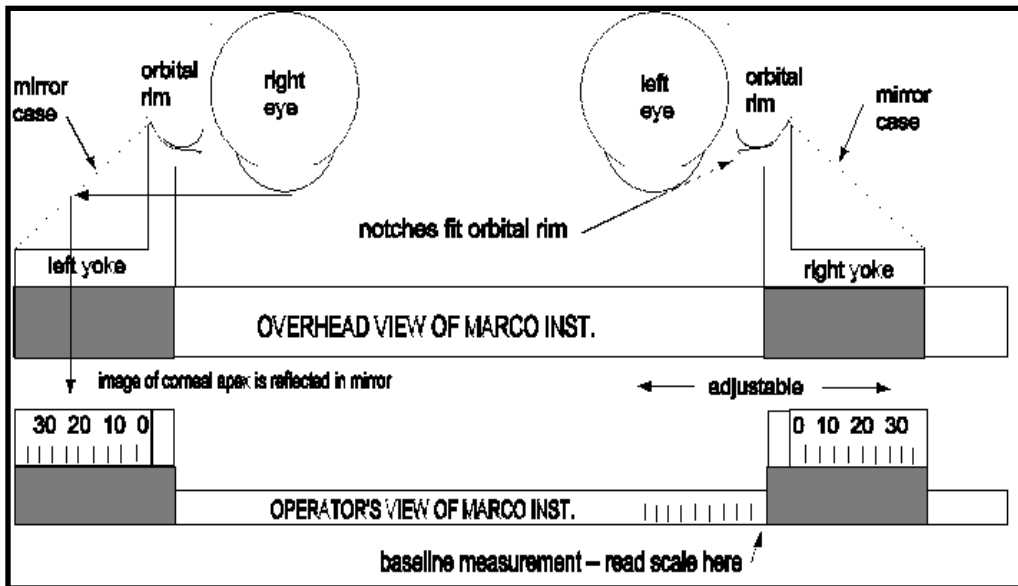




# Color vision – HUE test





# Hertl exoftalmometry



**Děkuji za pozornost!**

