




Aethiology

- Infectious disease
 - Microbs
 - Fermentable sugars

Antony van Leeuwenhoek



**First who observed microbes of oral cavity
17.ct**



Willoughby Dayton Miller (1853 -1907)

1889 „Die Mikroorganismen der Mundhöhle“ „The Micro-Organisms of Human mouth“.

Explained dental caries as a result of decalcification (acids from microbial metabolism)

Green Vardiman Black

(1836 – 1915)



When we will well understand reasons of dental caries, we will be able to heal it.

(G.V. Black 1900)

Microbiom



Human body

10^{14} Living cells


10% Cells of human body

Mikcobiom

Oral microbiom

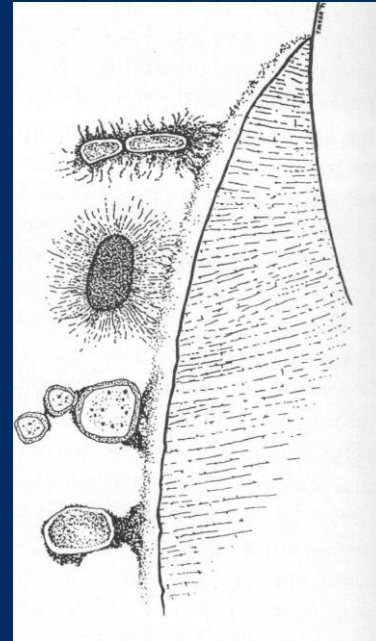
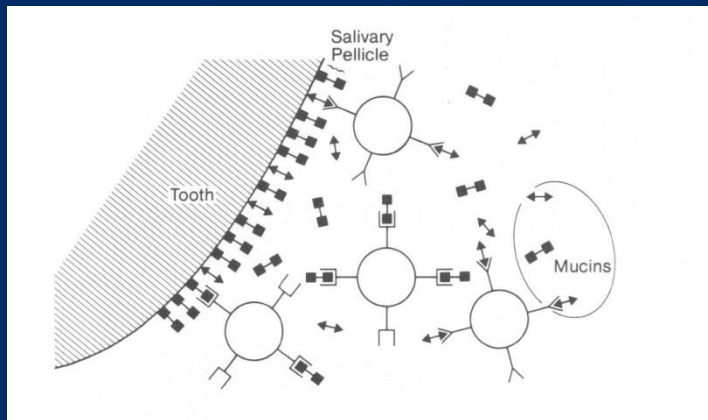
Dental biofilm

- Pelicle–Protektivní efekt
- Pelicle–monomolekular proteinicl ayerrich on prolin and phosphatea and glycoprotein rich on sulphate
- Bind to Ca²⁺ ions of enamel
- Protective effect
 - *Erosion*
 - *Dentin hypersensitivity*
 - *Key role by remineralization*



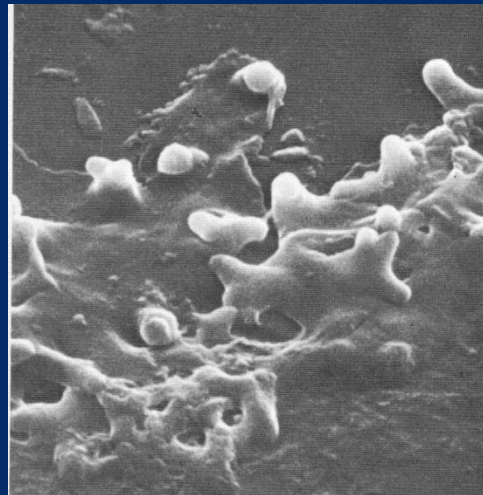
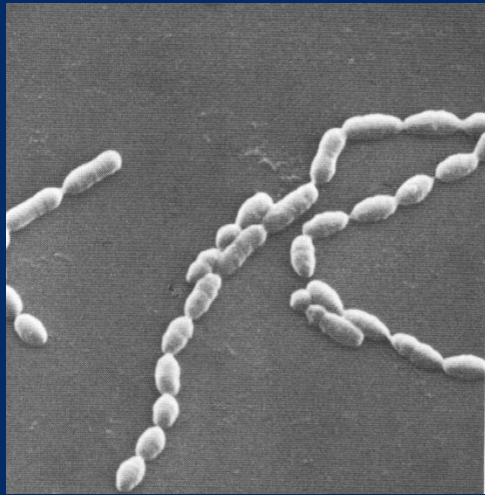
Biofilm

- Adherence
- *Adhezins*
- *Fimbriες*



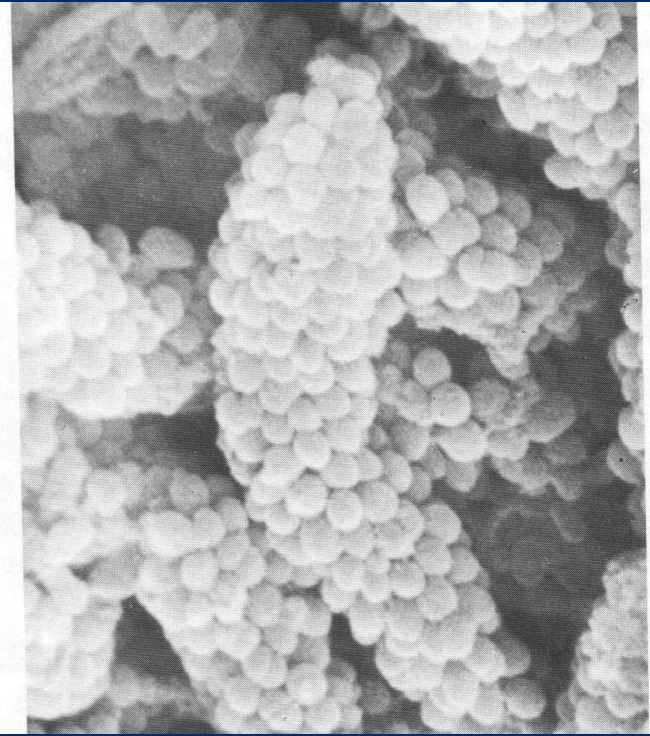
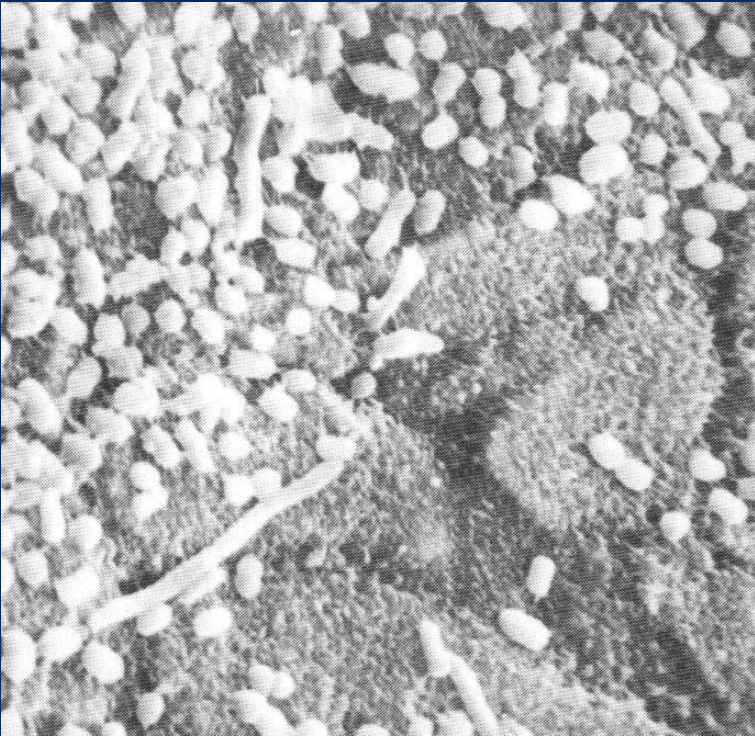Biofilm

- colonization
- *multiplication*
- *koaggregation*

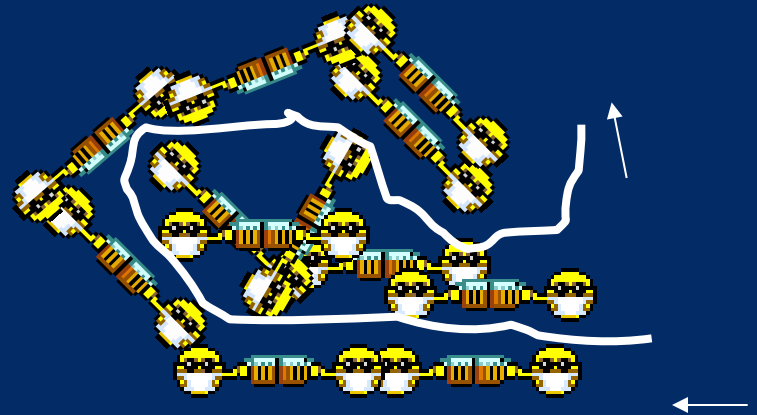
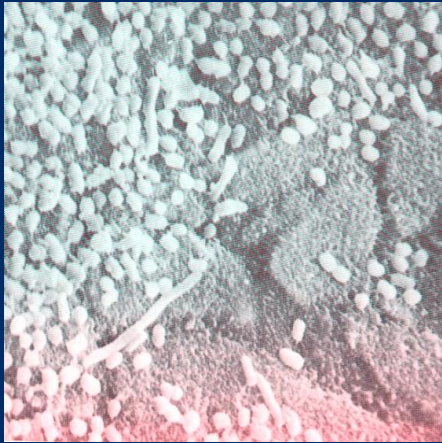


Biofilm

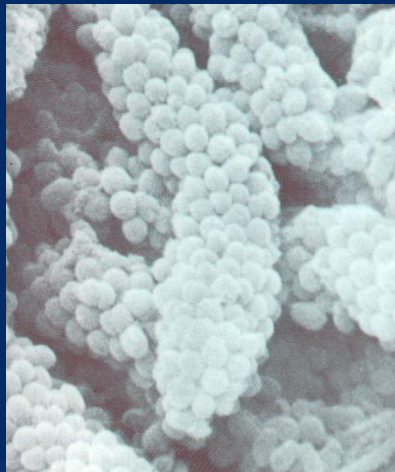
- Maturation



Biofilm



Higher metabolic activity
Higher resistency
(CHX 300x, AF 75x)
Higher virulency
Good conditions for survival



Cariogenicity

- Streptococci : mutans, sanguis, mitis, sobrinus.
- Laktobacil
- *Production of acids (acidogenity)*
- - *Production of extra aand intracelullar polysacharids*
- - *Survival in acidic environment (aciduricity)*

Acidobasic dynamic in biofilm

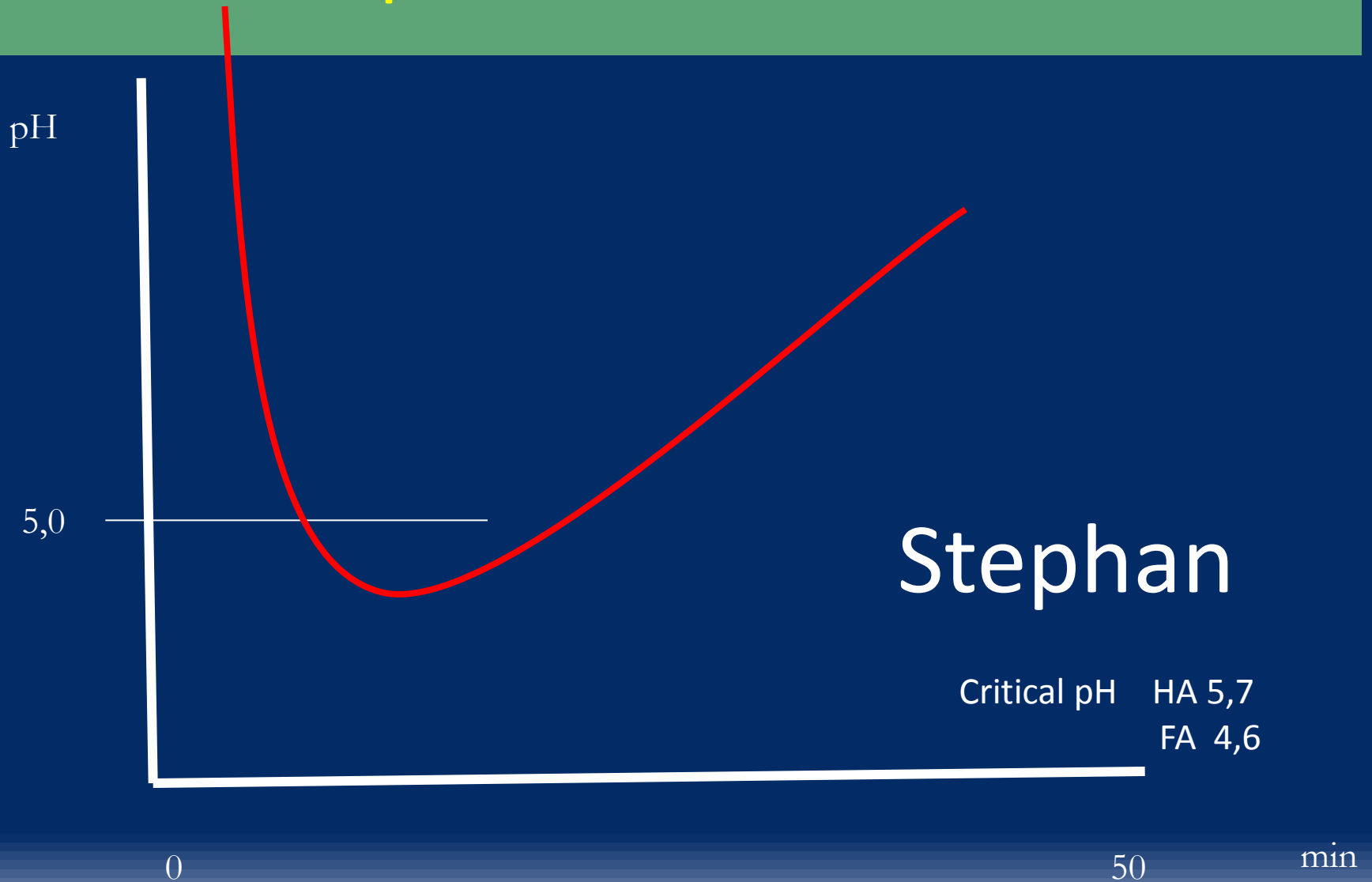
Glykolyysis

- Lactic acid and other acids

Base production

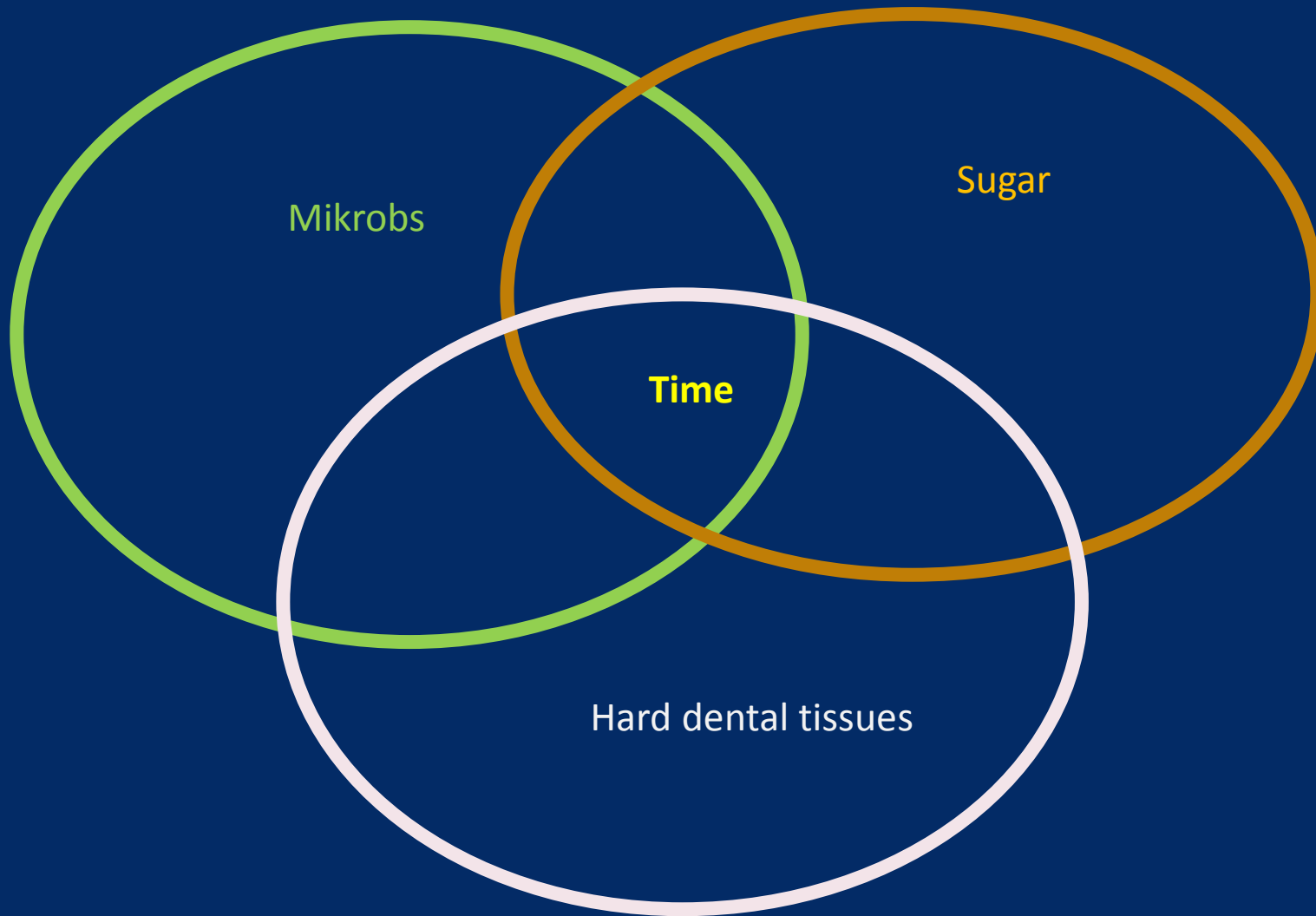
- NH_4^+
- Sugars 20 – 40% - tendency to acid púroduction and decalcification

Metabolic procedures in dental biofilm



Stephan

Critical pH HA 5,7
FA 4,6

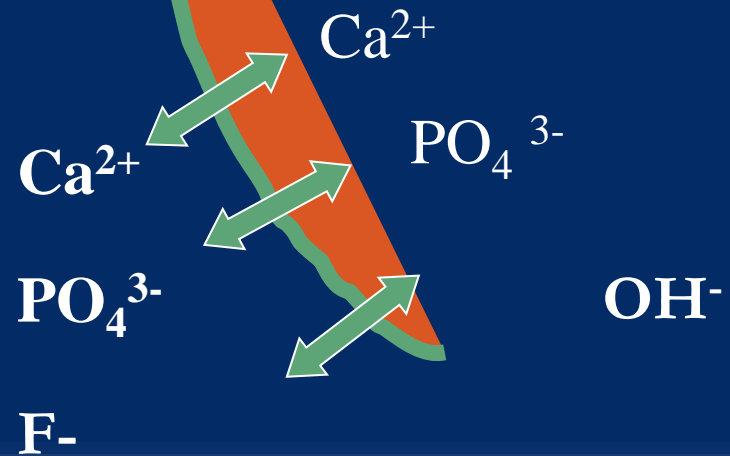
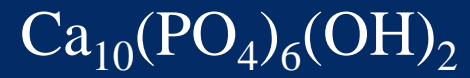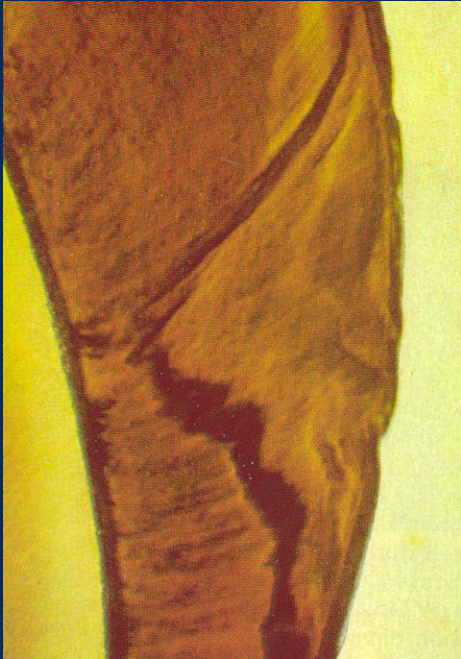


Mikrobs

Sugar

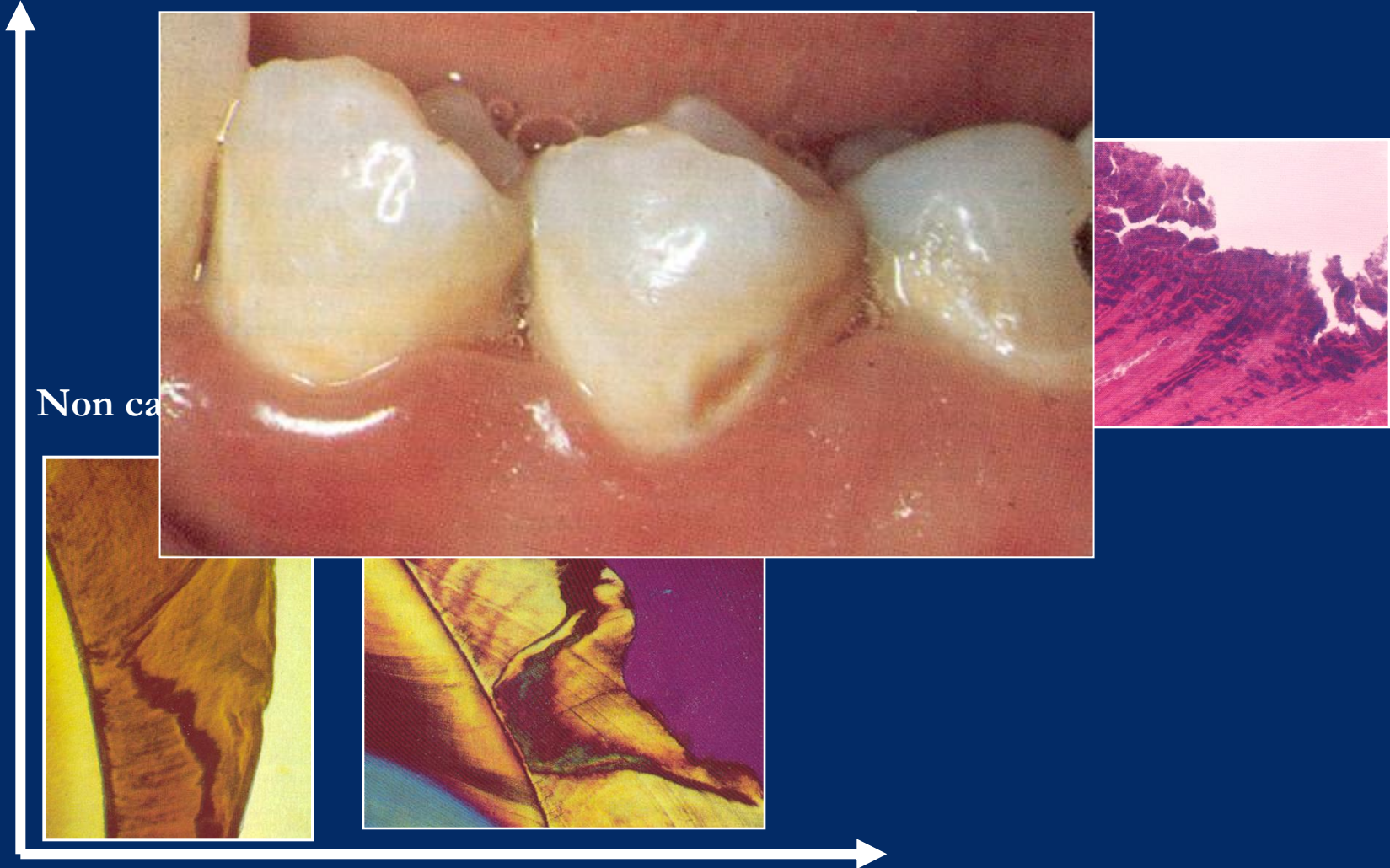
Time

Hard dental tissues



Cavitated lesion

Decalcification



Biofilm

Non specific hypothesis

- Plaque is always the reason
- **Specific hypothesis**
- Only pathogenic plaque is the causal factor

Saliva and dental caries

700 – 800 ml. (0,3 ml), stimulated (1 ml).

- Product of salivary glands 700 – 800 ml.
Klidová (0,3 ml), stimuloaná (1 ml).

Clearance

- Microbs
- Rests of food

Saliva and dental caries

- Minerals
- Calcium and phosphates – oversaturated solution remineralization
- Proteins
- Glykoproteins - pelicle, barrier against overgrowing of crystals on the surface

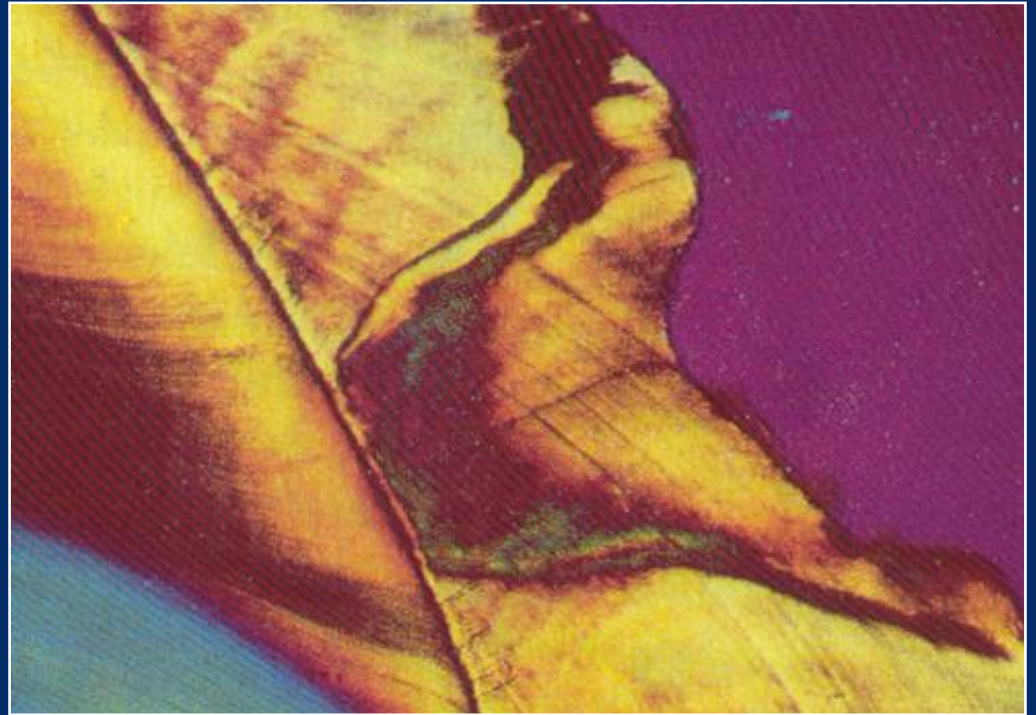
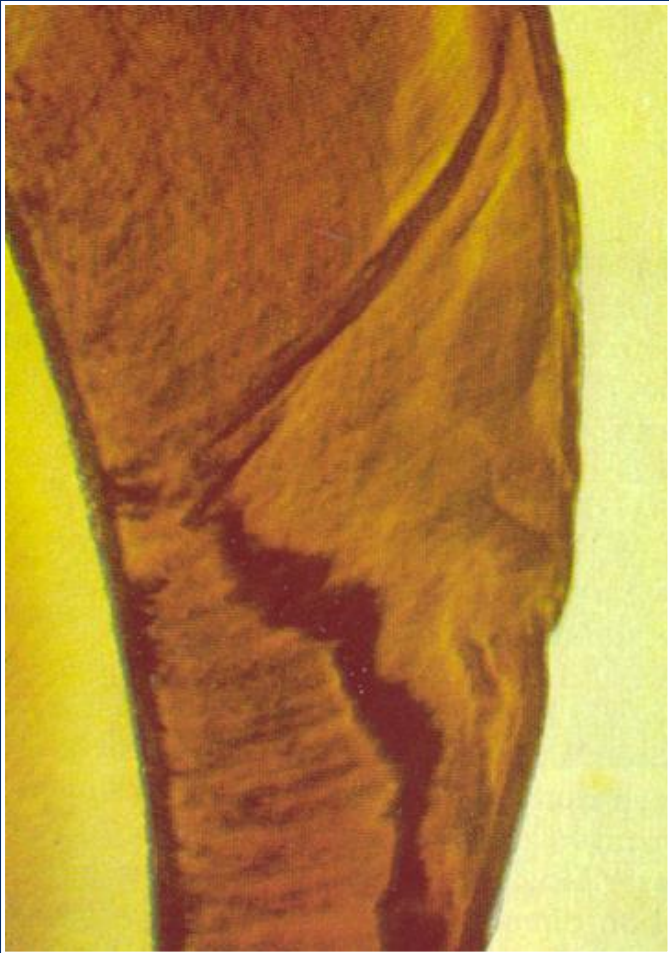Buffer capacity of saliva

- Bicarbonatesystem
- Phosphate system
- In saliva not in plaque


Slina

- Klíčová role v maturaci skloviny
- V remineralizaci iniciálních kazivých lézí
- V remineralizaci demineralizovaných okrsků skloviny

Inicial lesion



Porosity



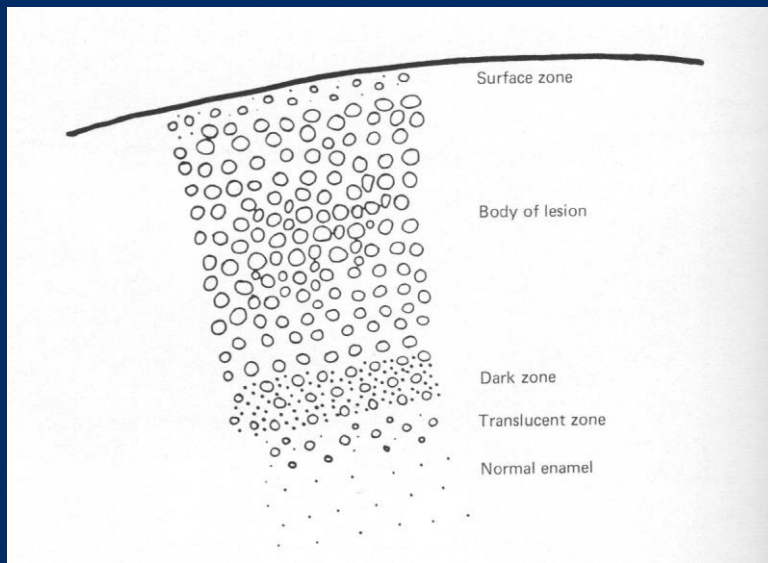
Superficial zone
5 %

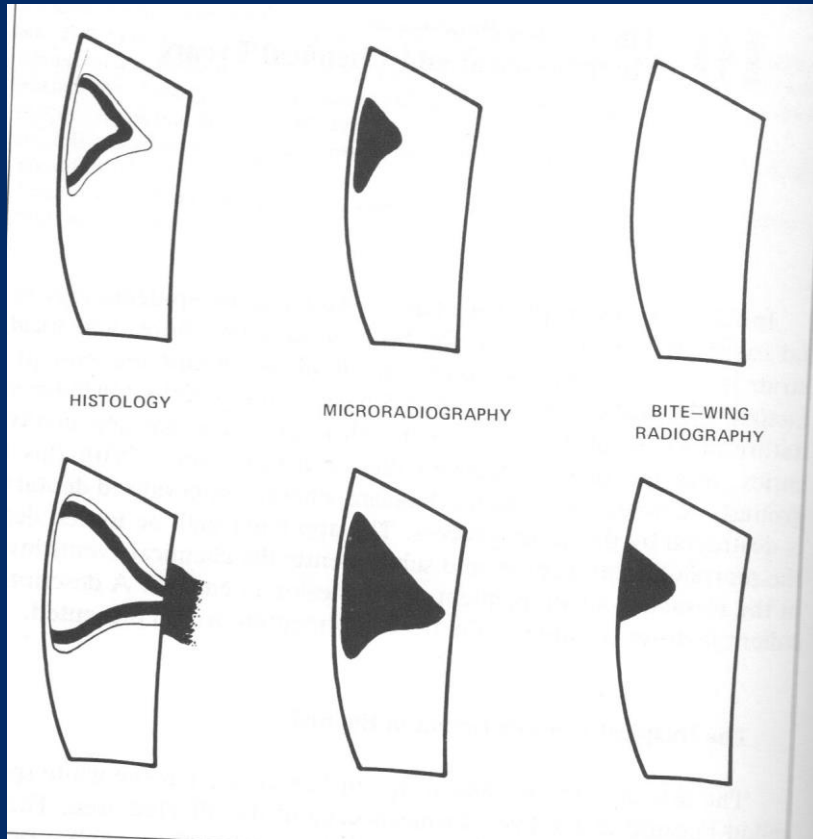
Body of lesion
25%

Dark zone
2 –4%

Translucent zone
1%

Normal enamel
0,1%%






Histology x mikroradiography x BW

Diagnosis

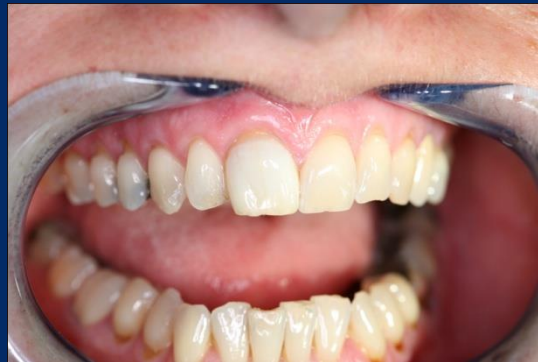- Visual inspection (ICDAS)
- Radiography
- Photography
- Optical nonfluorescent methods
- Optical fluorescent methods
- Transillumination
- Measurement of electrical impedancy

Visual inspection, magnification, dry surface

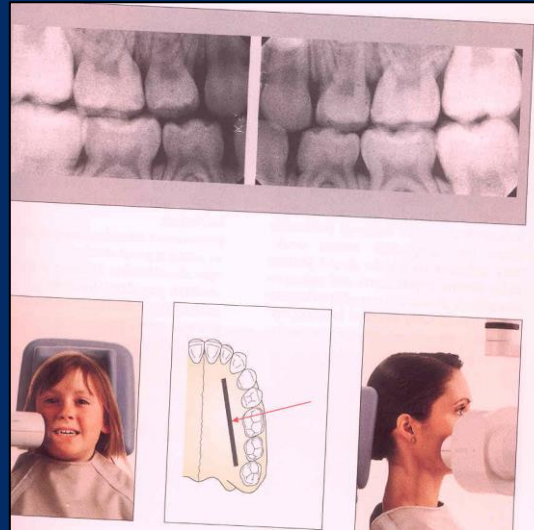
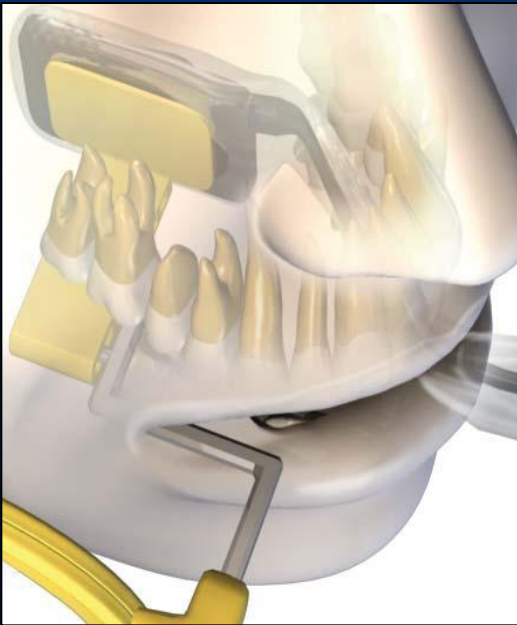


Photography

- Good documentation and evaluation of lesion
- Flash and light can misrepresent



Radiography

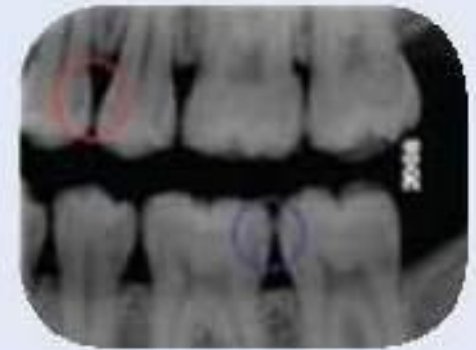
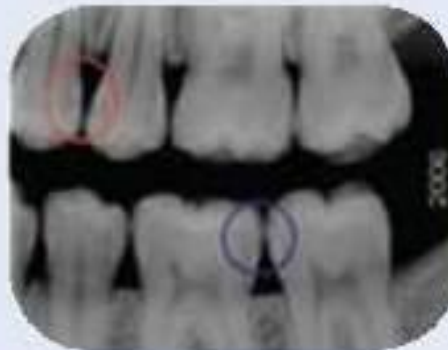


Bite wing

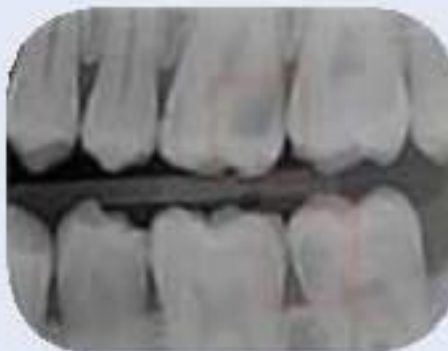Radiography

Klinické: **Identifikace** - Vyšetření: Bitewing rtg

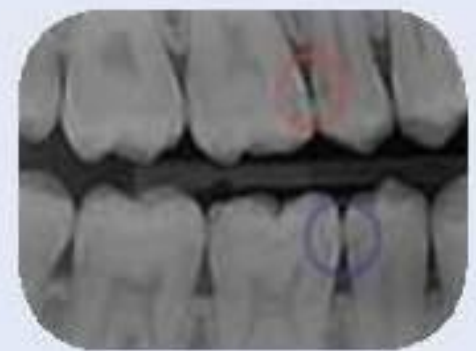
Léze skloviny		ICDAS
E1	Vnější polovina skloviny	0, 1
E2	Vnitřní polovina skloviny	1
Léze dentinu		ICDAS
D1	Vnější třetina dentinu	2
D2	Prostřední třetina dentinu	3
D3	Vnitřní třetina dentinu	4



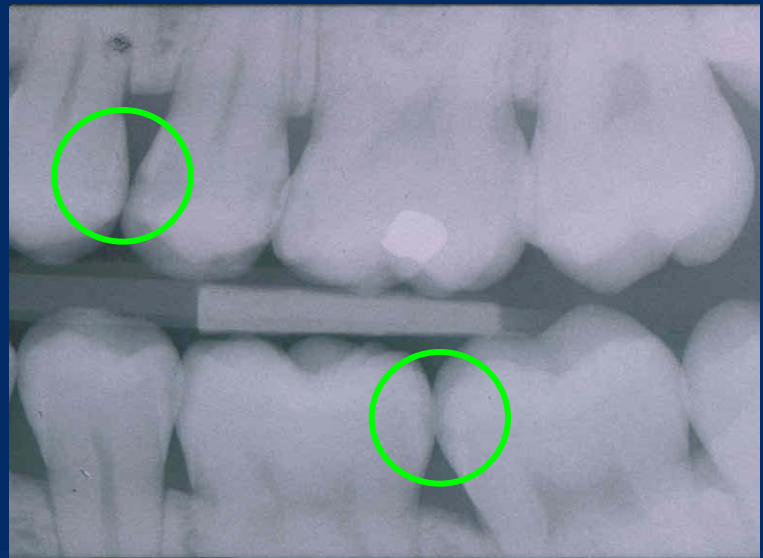
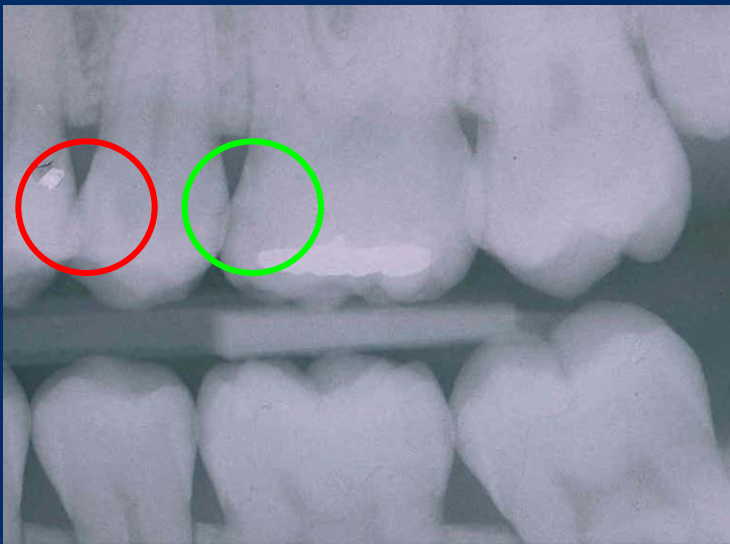
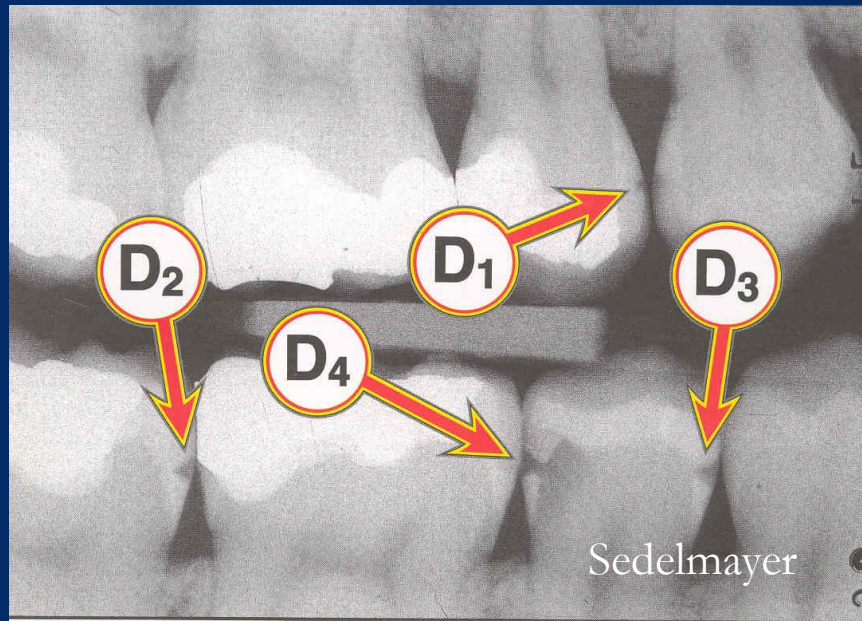
Kontrola za 2 roky u počátečních lézí D-1 (modrá) a D-2 (červená)



D-3



D-1 a D-2



Optical non fluorescent methods

- Distorsion og lihgt (OCM)

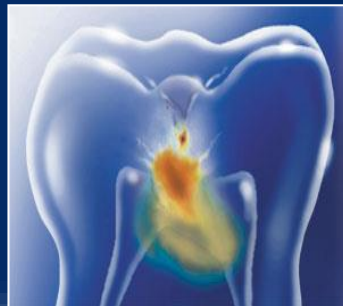
Non invasive, various results

Optical fluorescent methods

- Principle:

Absorption and irradiation back

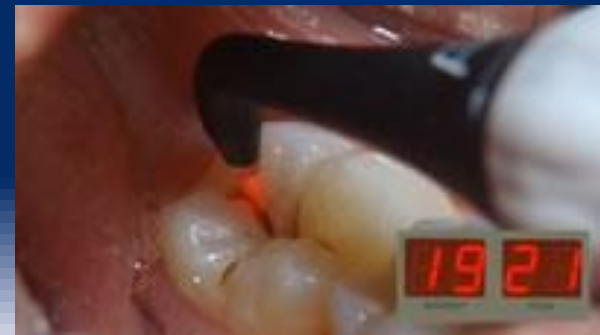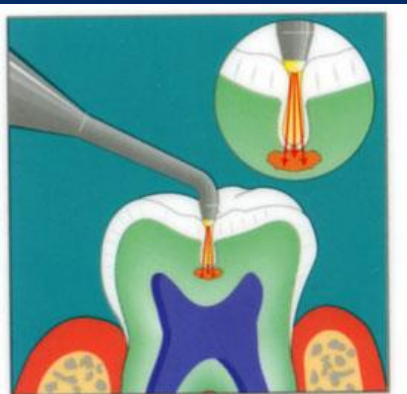
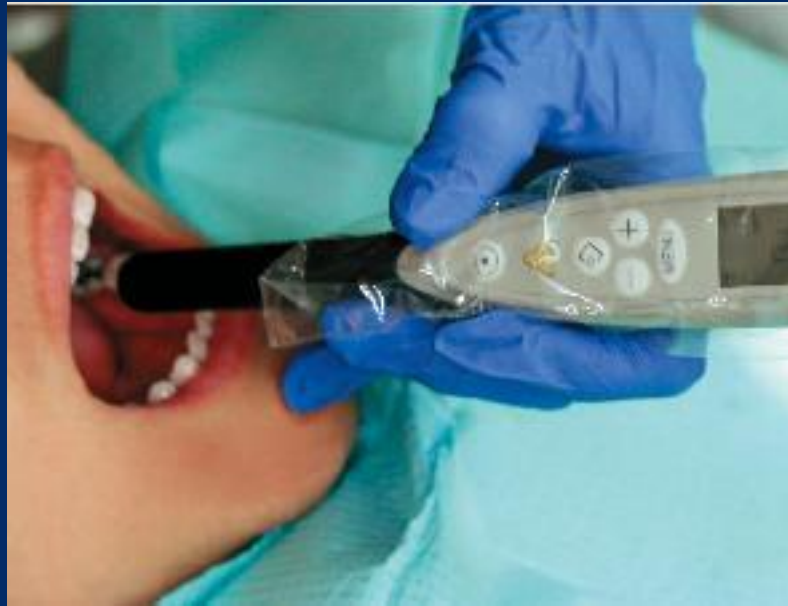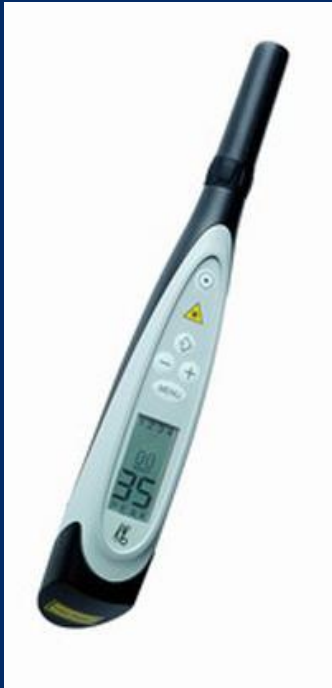- DIAGNOdent, DIAGNOdent pen, QLF, Vista Proof



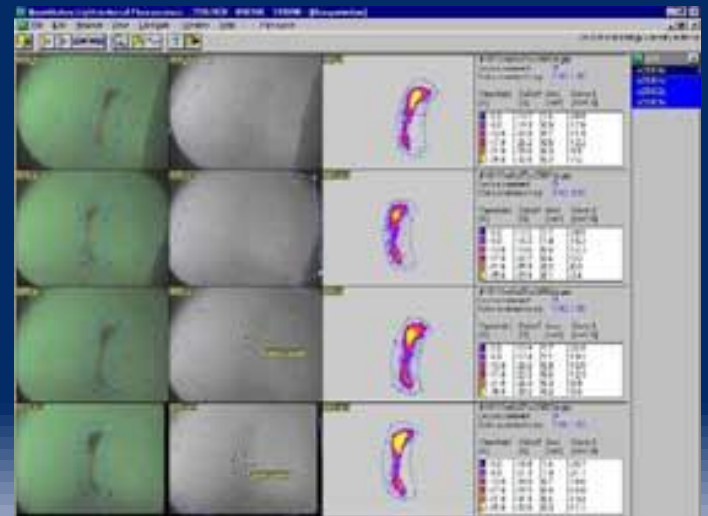
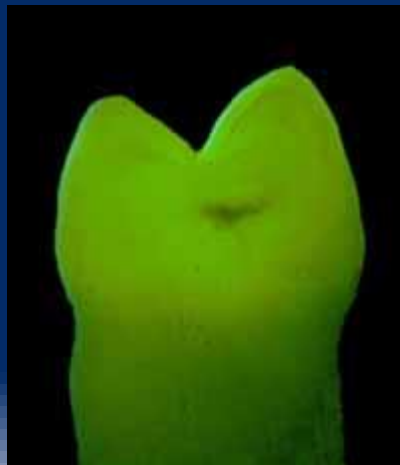
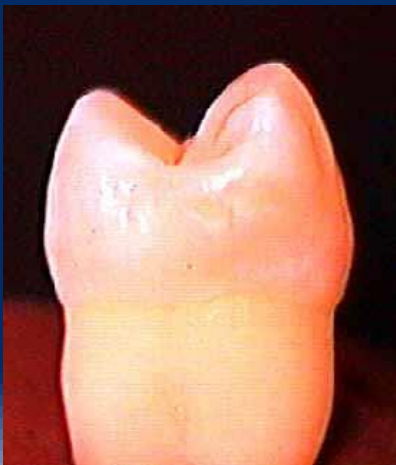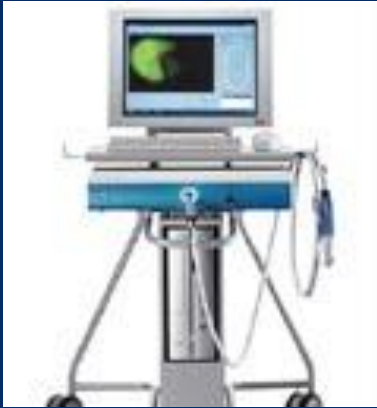Infračervená laserová fluorescence

- **DIAGNOdent, DIAGNOdent pen**
- Toto fluoreskující záření se zobrazuje jako aktuální a rovněž jako maximální hodnota (peak)
- Hodnoty vyšší než 24 (DIAGNOdent), vyšší než 17 (DIAGNOdent pen) – kaz
- Falešně pozitivní výsledky při nedokonale očištěném zubu

DIAGNODENT



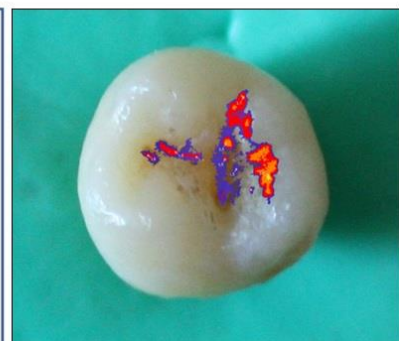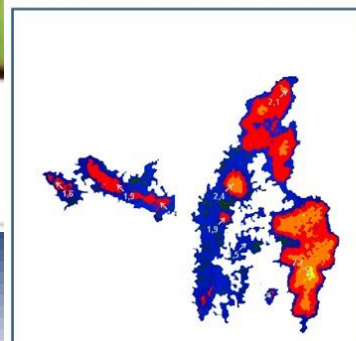
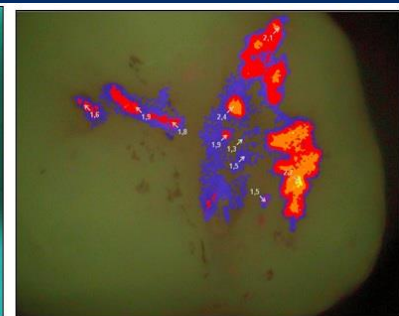
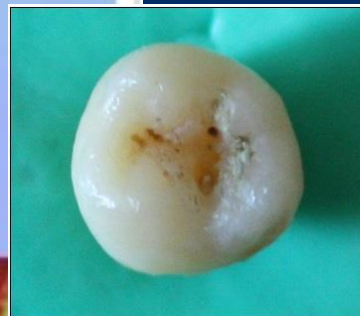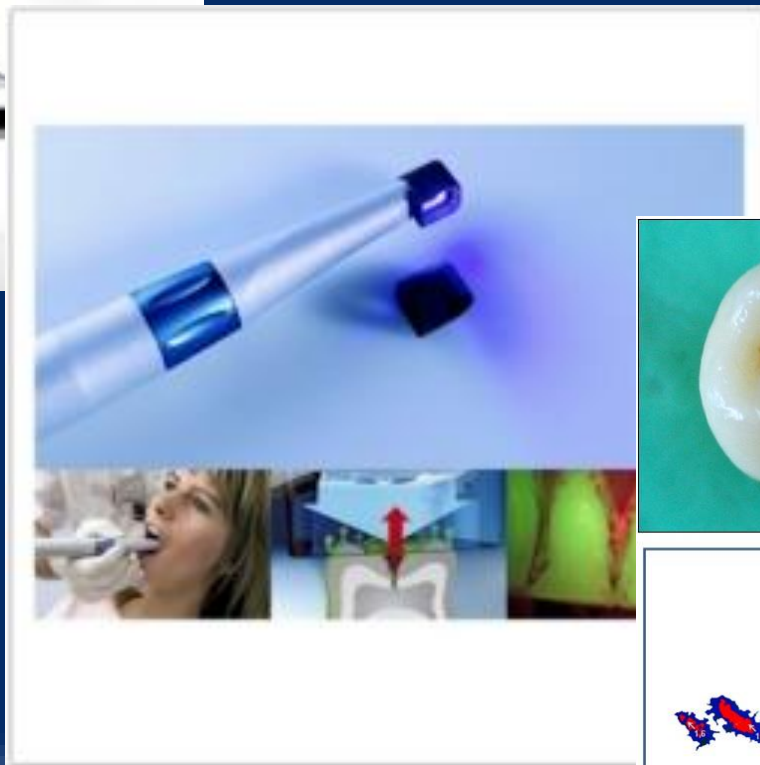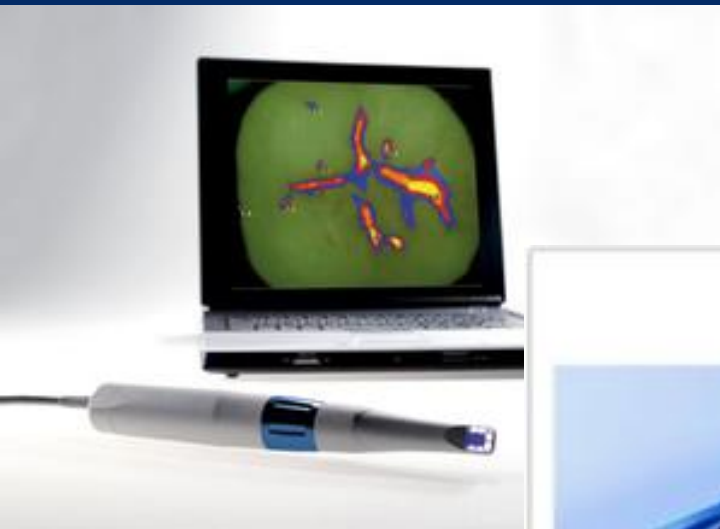Quantitative Light – induced Fluorescence n c y QLF



Vista Proof

- **Intraorální kamera** využívající princip fluorescence
- Kariézně změněné plošky emitují **červené** světlo, zdravé zubní tkáně **zelené** světlo
- Software vyhodnotí poměr červeného a zeleného spektra – zdravá sklovina a kariézní léze se barevně a číselně znázorní (škála 0-4) – sledování vývoje demineralizace + záznam
- Lze znázornit i zubní plak (není nutné použít dalších prostředků)
- Novinky – **Vista Cam iX** – kamera s dvěma vyměnitelnými koncovkami (intraorální X fluorescenční)
- **SoproLife** – zhodnocení zubního kazu v diagnostickém modu + rozlišení mezi zdravou a kariézní tkání v ošetřovacím modu

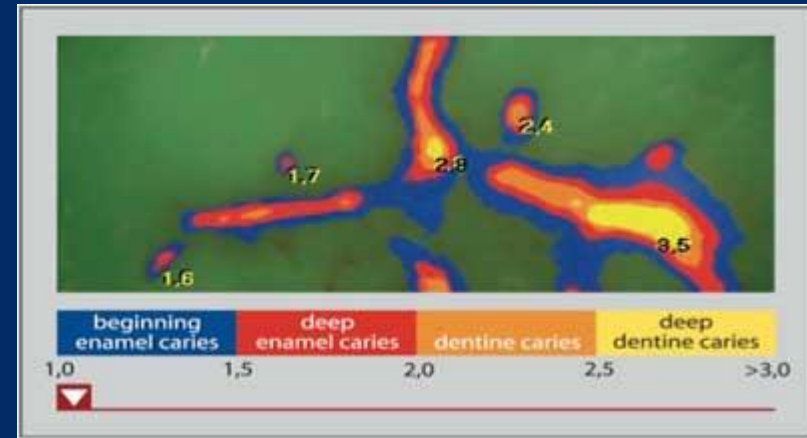
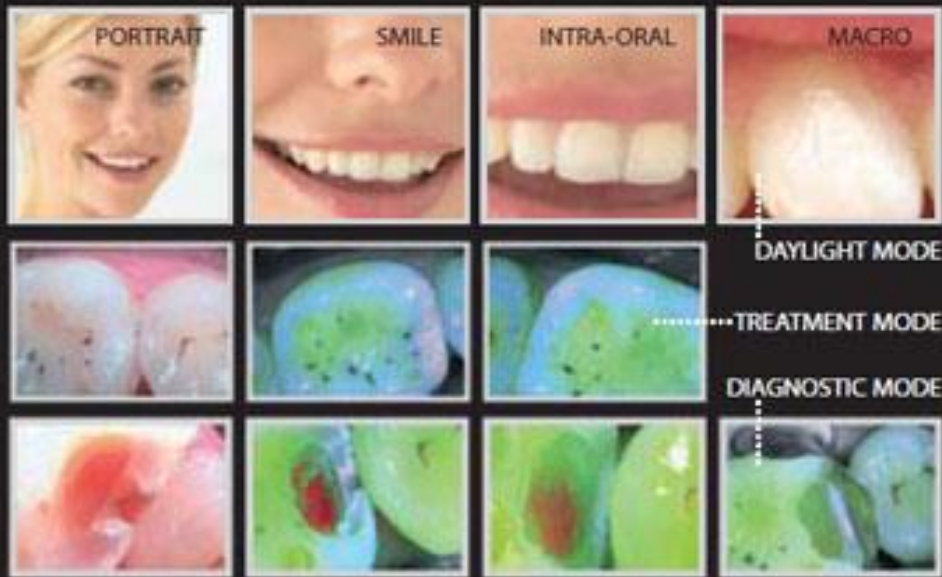Vista Proof



Vista Cam iX

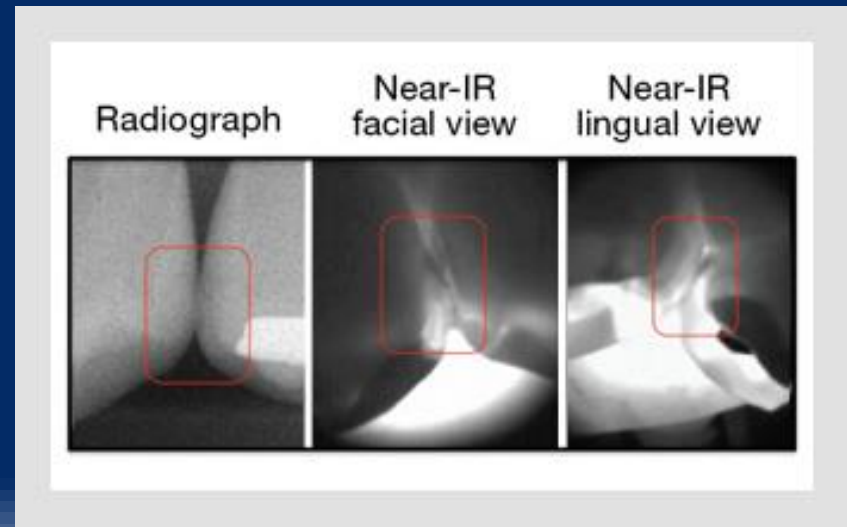
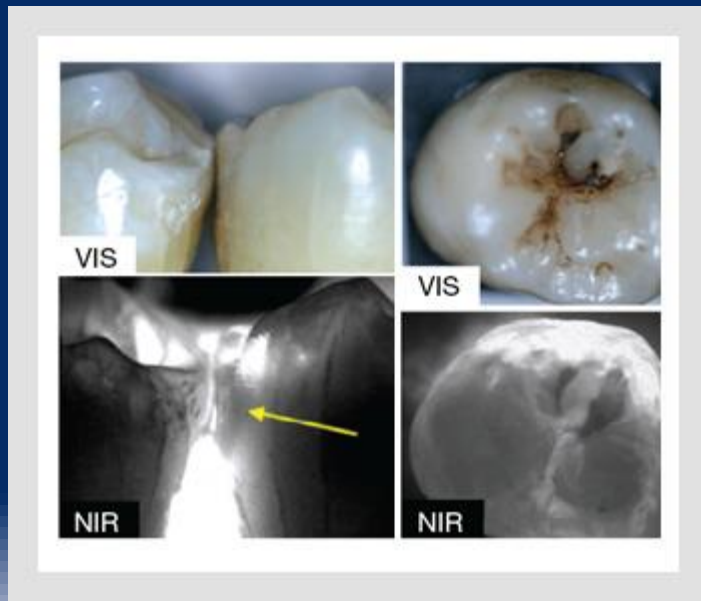


SoproLife



FOTI – fibre optic transillumination

Proximal caries lesion



DIFOTI

(Digital Fibre Optic
Trans-Illumination)

- j bílého světla – kamera s CCD senzorem – počítač – zobrazení jako obrázek



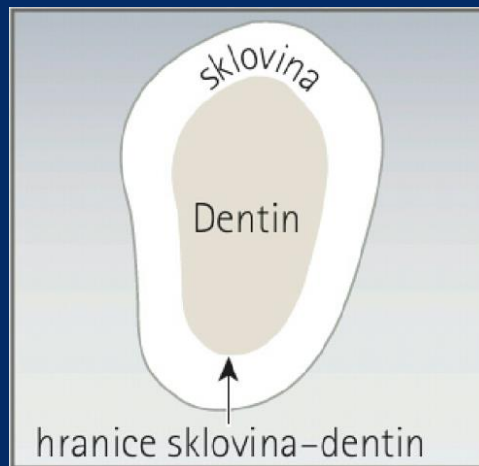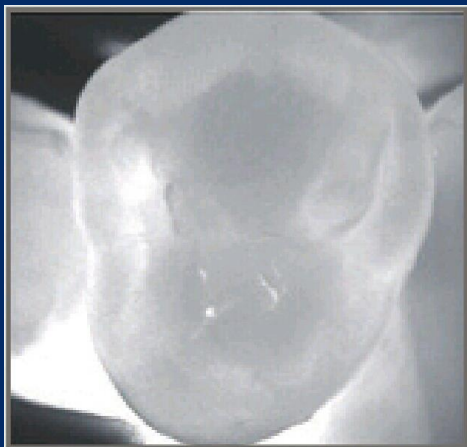DIAGNOCam



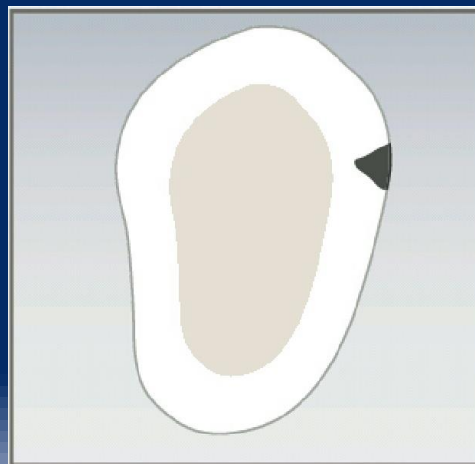
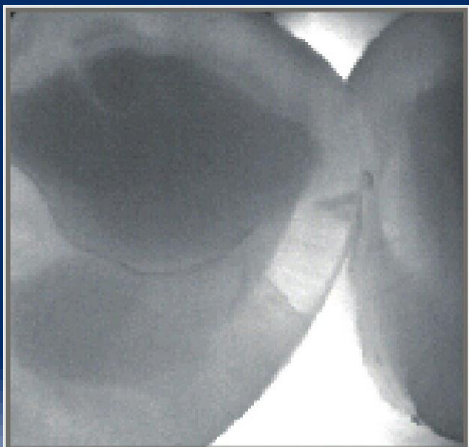
- DIFOTI (Digital Imaging Fiber Optic Transillumination)
- light(700-1400nm)
- Caries lesions and cracks—light absorption—dark spots
- (higher content of water in caries lesions – higher absorption of light)
- Documentation

DIAGNOCam- klasifikace nálezu

- 0 –

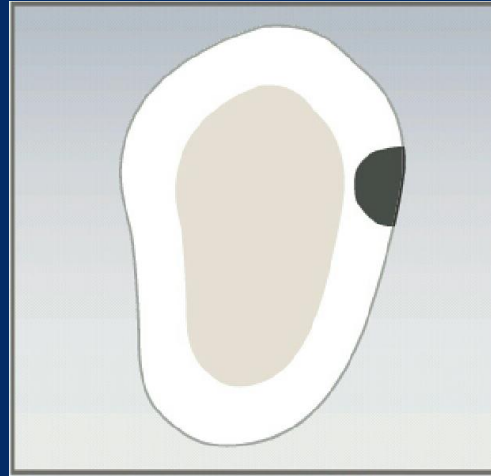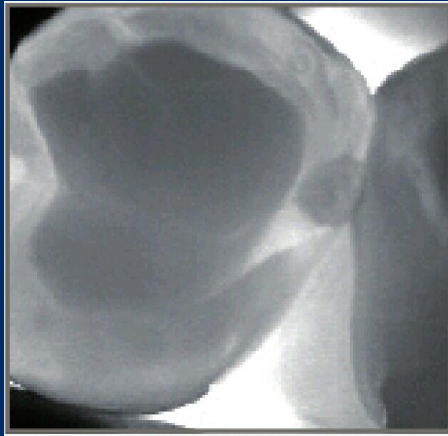


- 1.

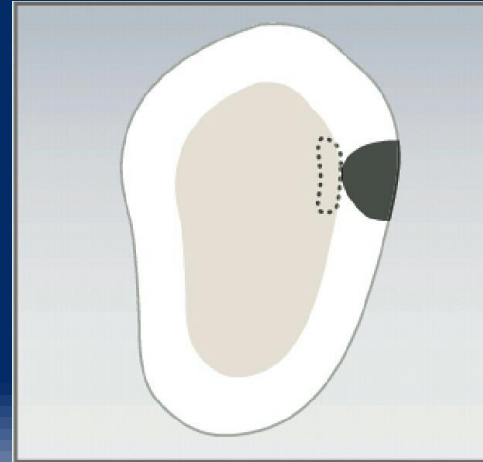
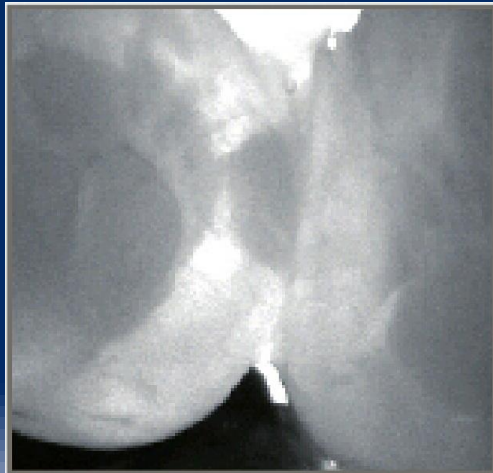


DIAGNOCam- klasifikace nálezu

- 2- caries in enamel

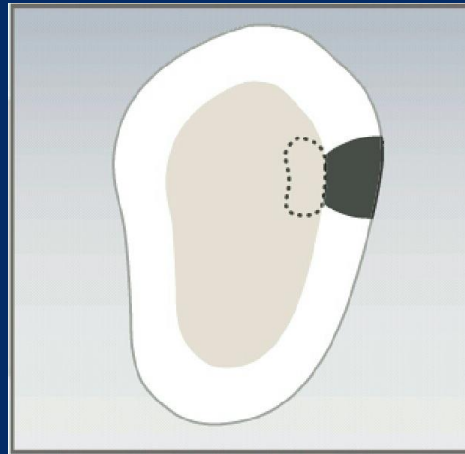
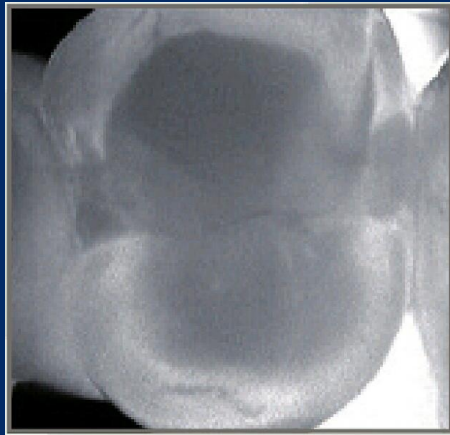


- 3 - caries in enamel and dentin

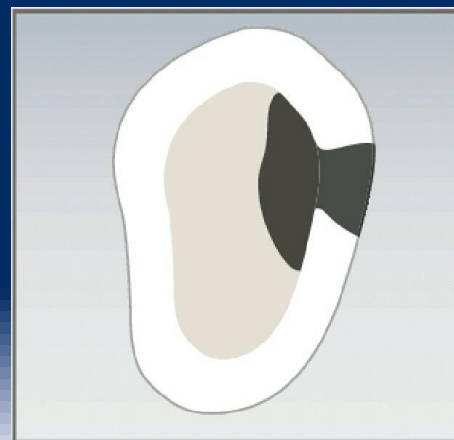
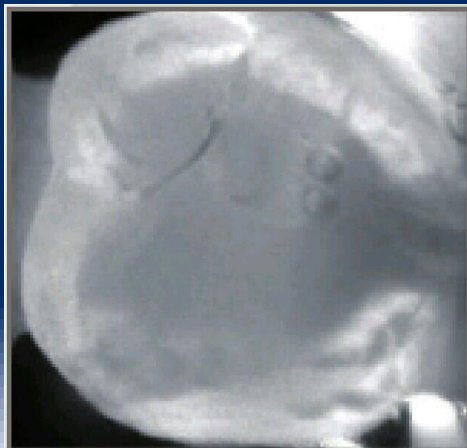

DIAGNOCam- klasifikace nálezu

- 4 - kaz ve sklovině zasahující do dentinu – použít minimálně invazivní metodu


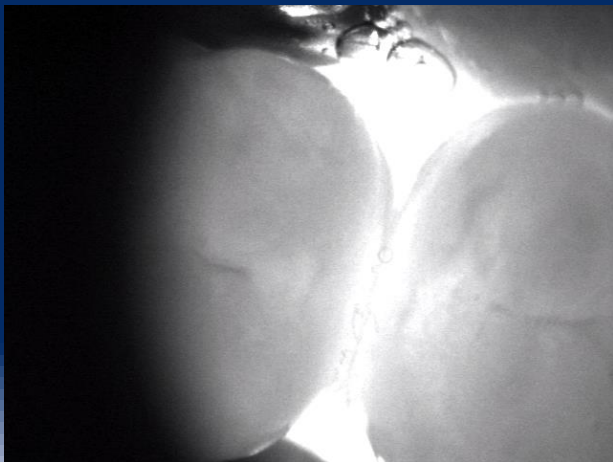
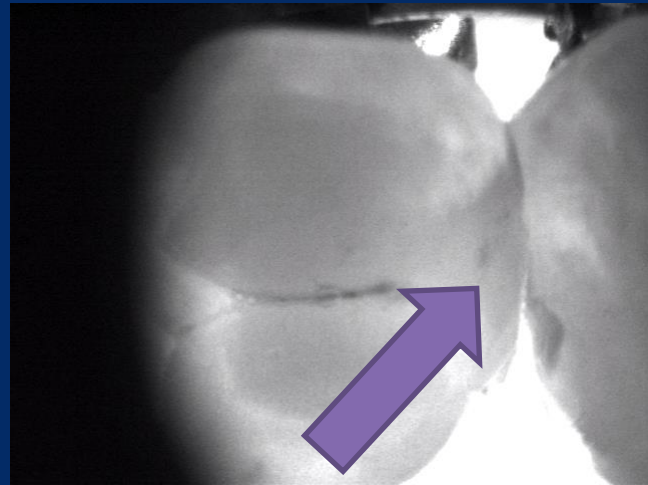
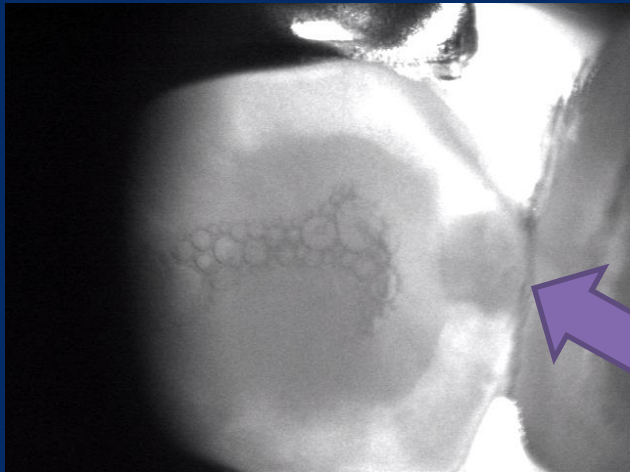

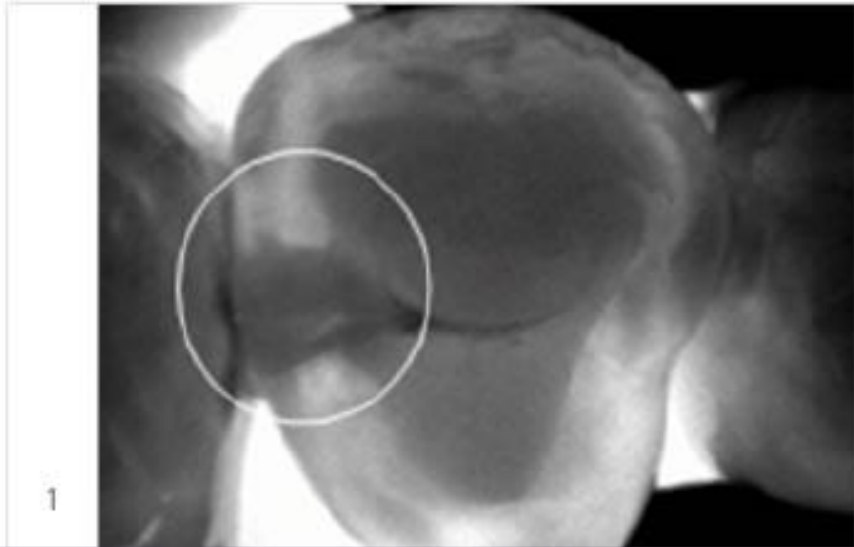
- 5 – kaz rozšířený do dentinu – použít invazivní metodu



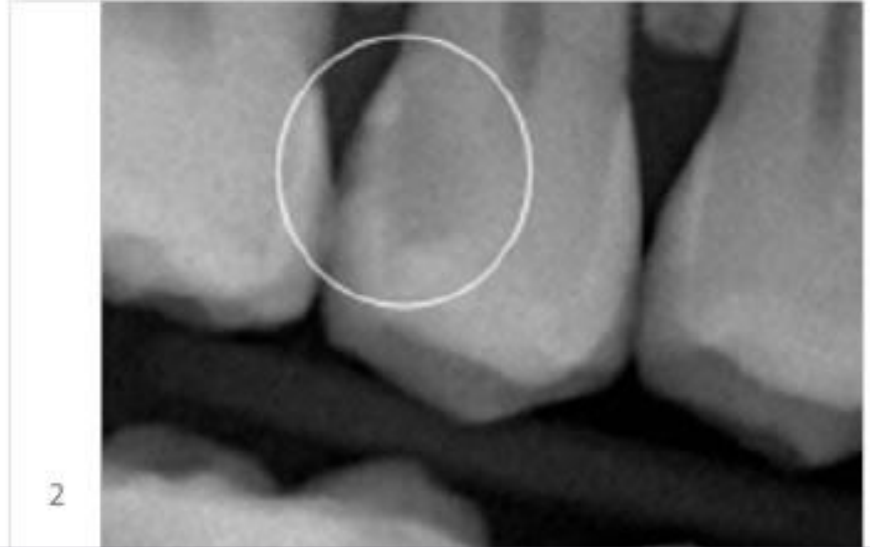DIAGNOCam



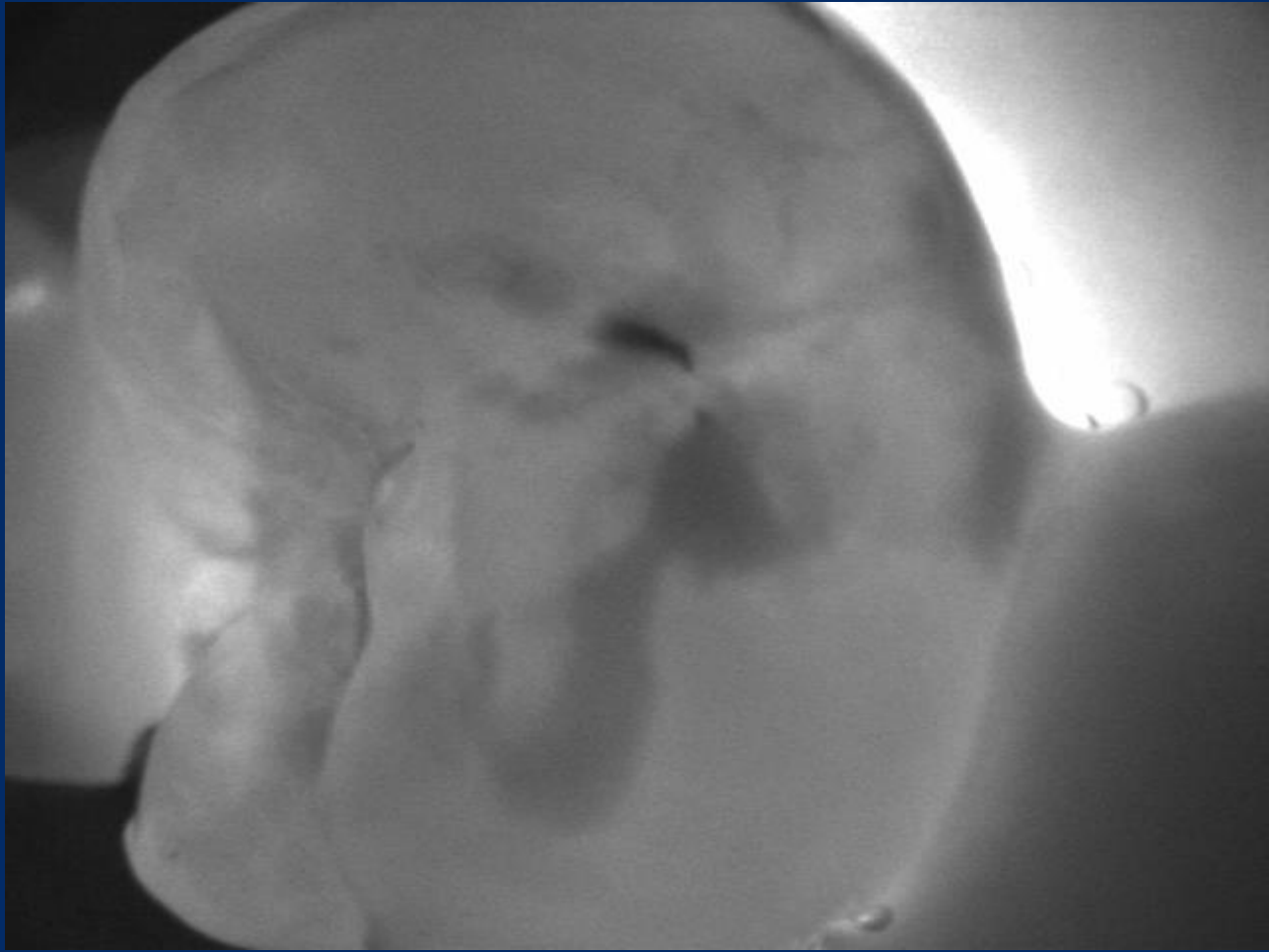


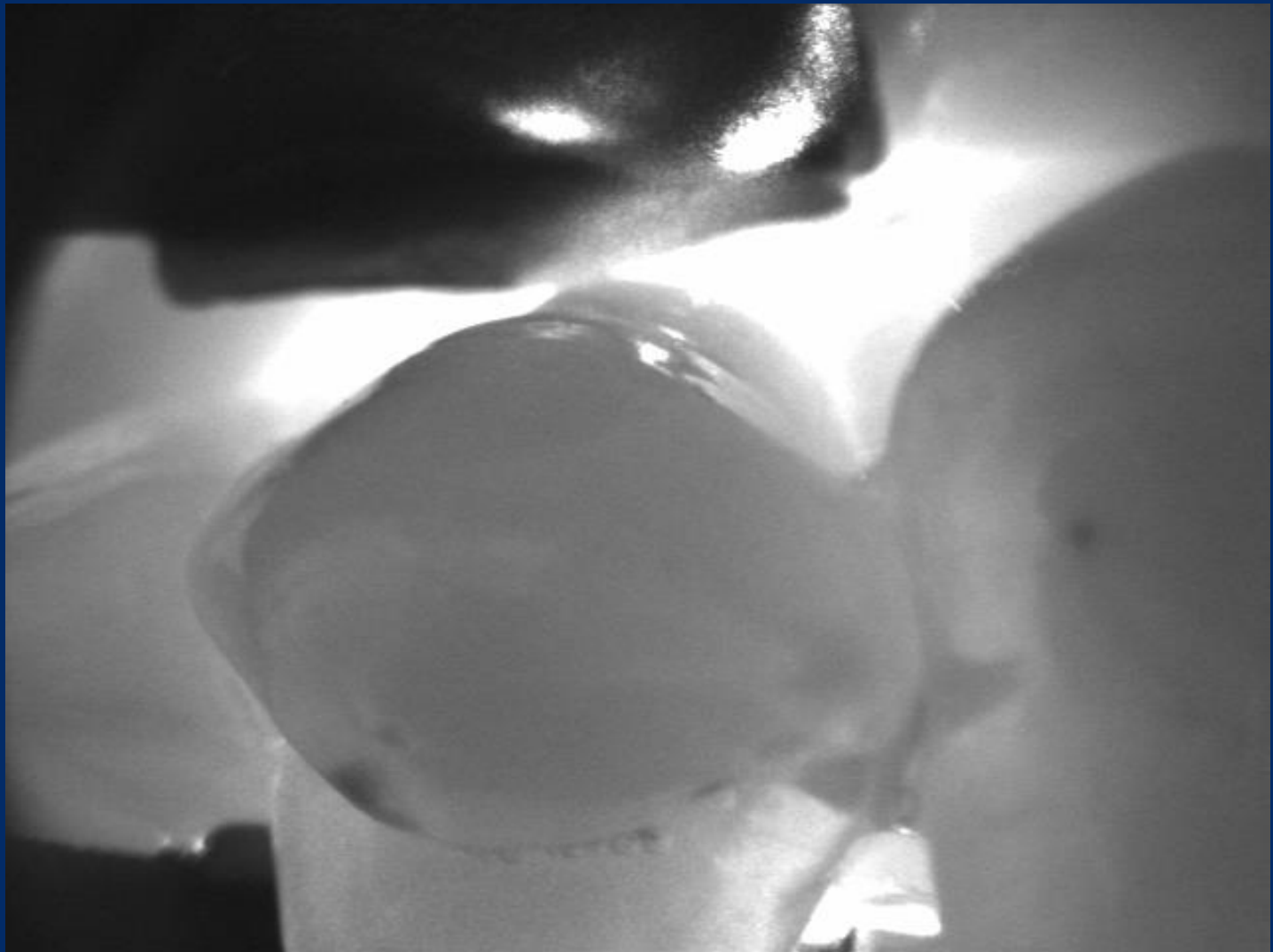


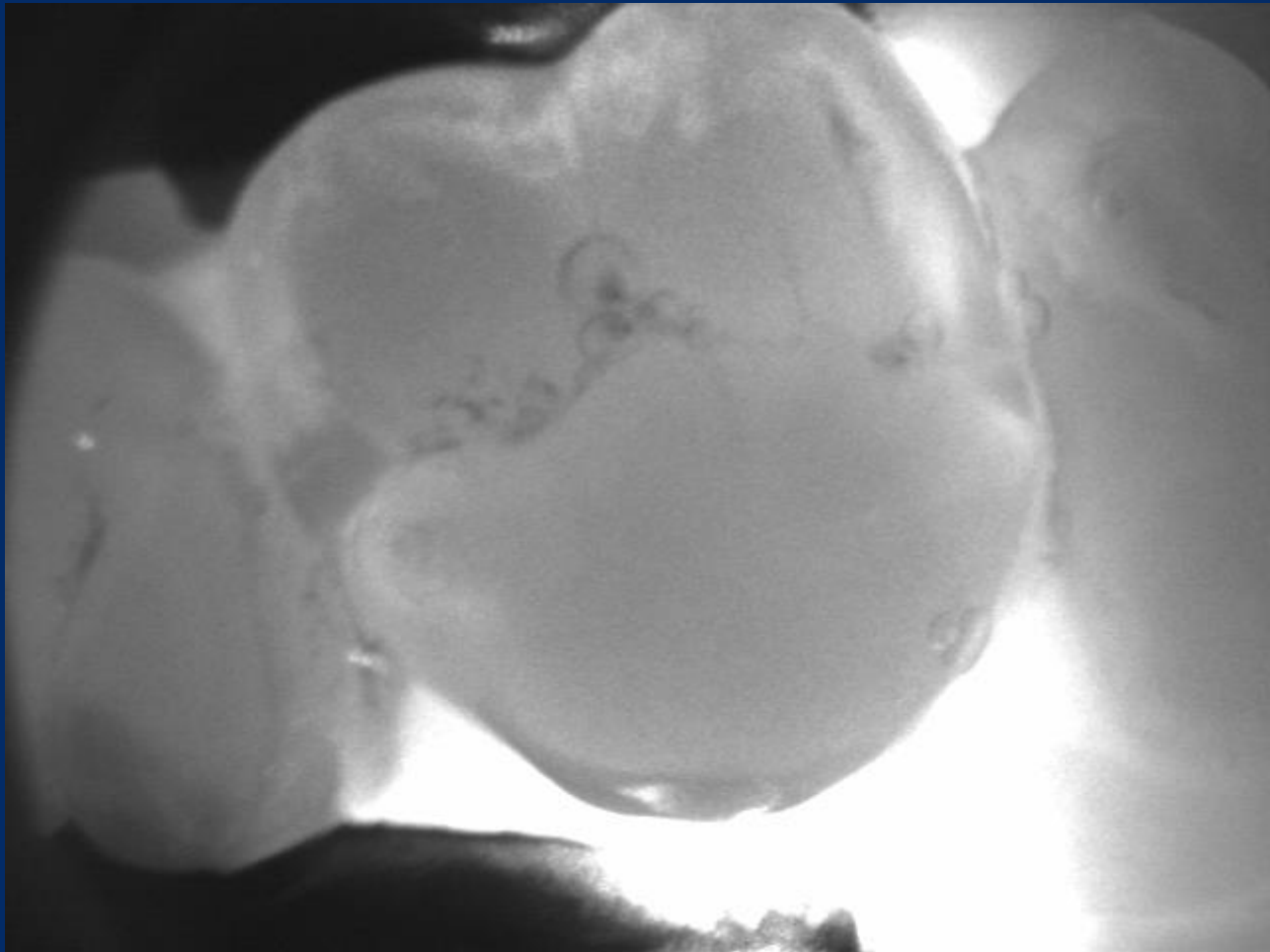
Diagnocam



Bitewing

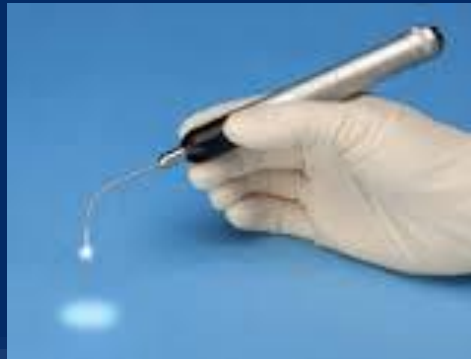
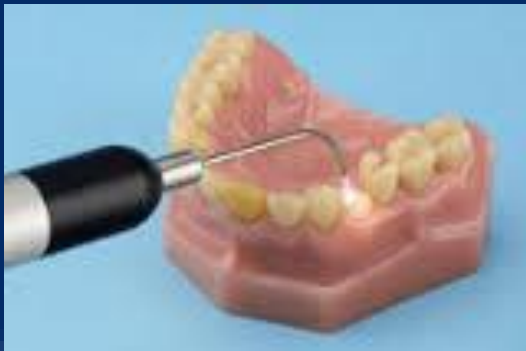


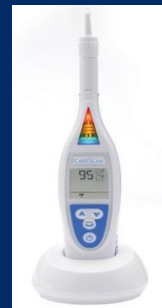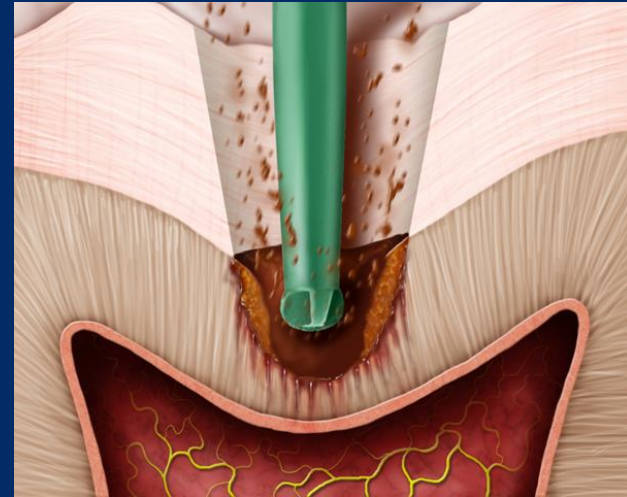


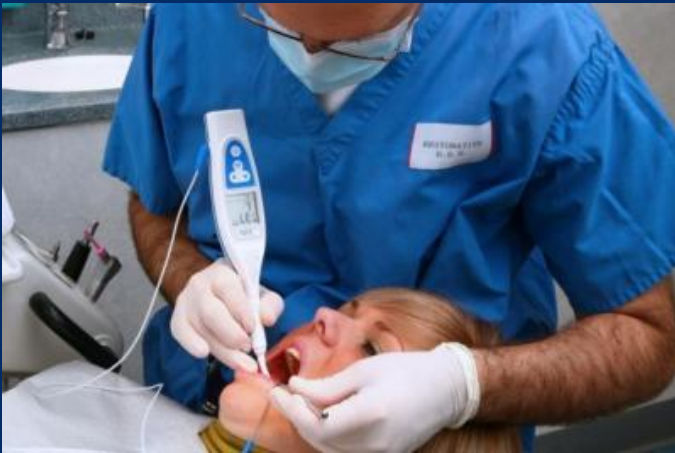Transiluminace pomocí optického vlákna- FOTI

- Přístroje k diagnostice aproximálních kazů (KaVo DIAlux probe)
- + vyšší senzitivita než RTG snímek a opakovatelnost vyšetření
- - necitlivost přístroje na léze kolem výplní a nemožnost zhotovovat snímky a dokumentovat stav



Measurement of electrical resistancy



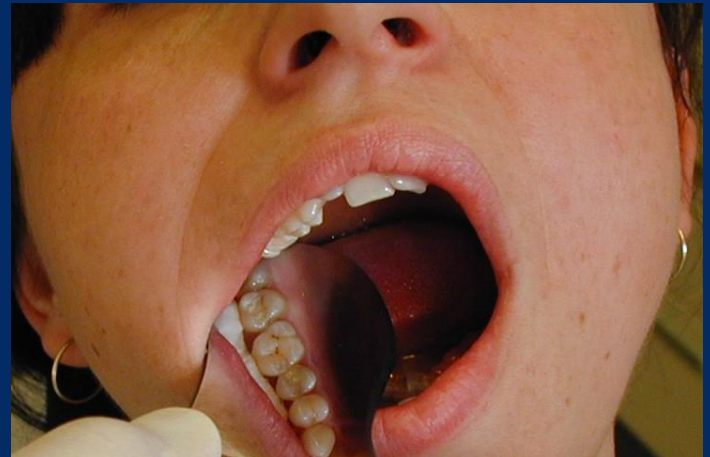Pit and fissure caries

- Class I. acc. to Black

Caries danger area

Special morphology

Special structure of enamel



Diagnosis

ICDAS–INTERNATIONAL CARIES DETECTION
AND ASSESMENT SYSTÉM

ICDAS—INTERNATIONAL CARIES DETECTION AND ASSESMENT SYSTEM



- **ICDAS(2002)**–6 code, later **ICDAS –II –4**code
- ☐ Caries lesions in pit and fissures, smooth surfaces, roots and enext to fillings –**CARS** (Caries Associated with Restoration and Sealants)
- Blunt probe
- Clean and dry surfaces, time of observation 5 s
- <http://www.icdas.org/courses/english/index.html>

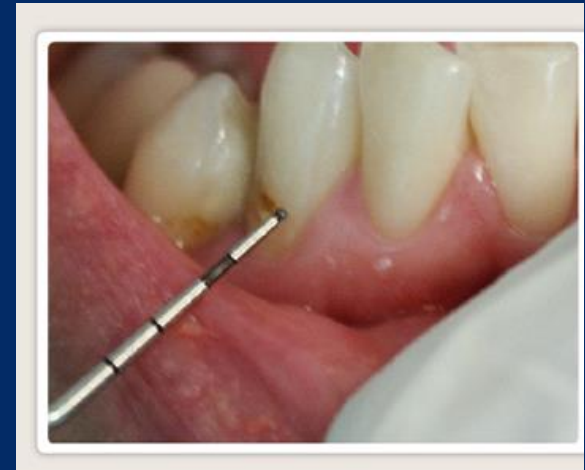ICDAS

Before assesment

Clean and dry teeth surfaces

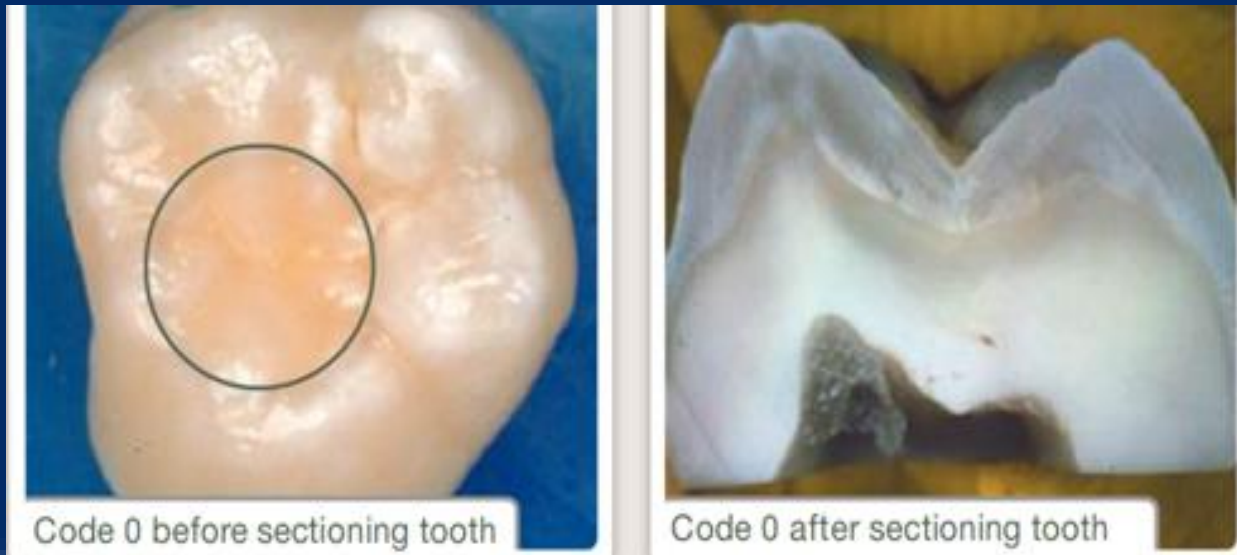Blunt probe

5 seconds observation



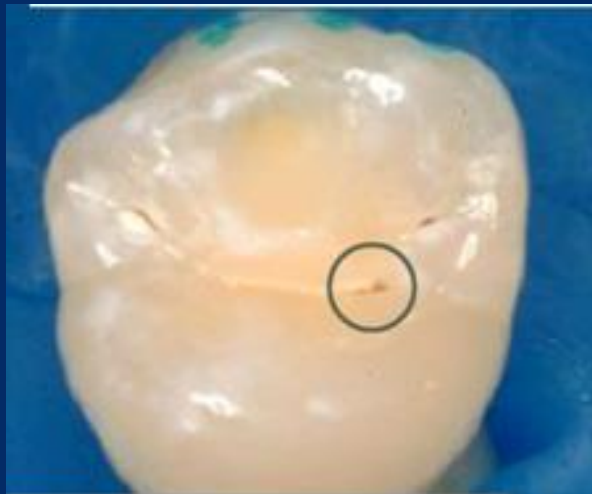
ICDAS – kritéria

- 0 no changes observed

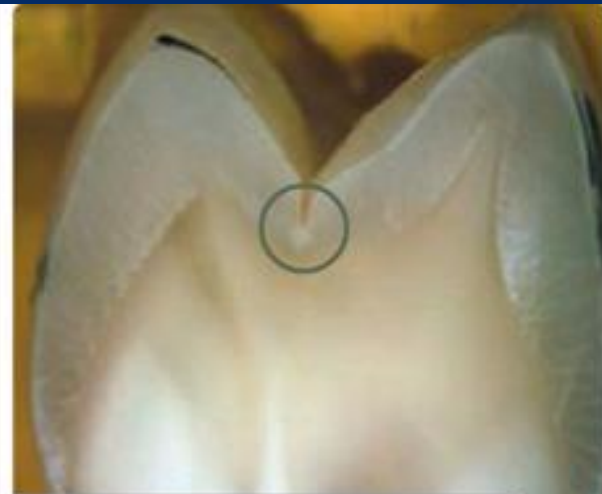

ICDAS - kritéria

- 1.- first visual changes observed on dry surface only (opaque, white, brown)



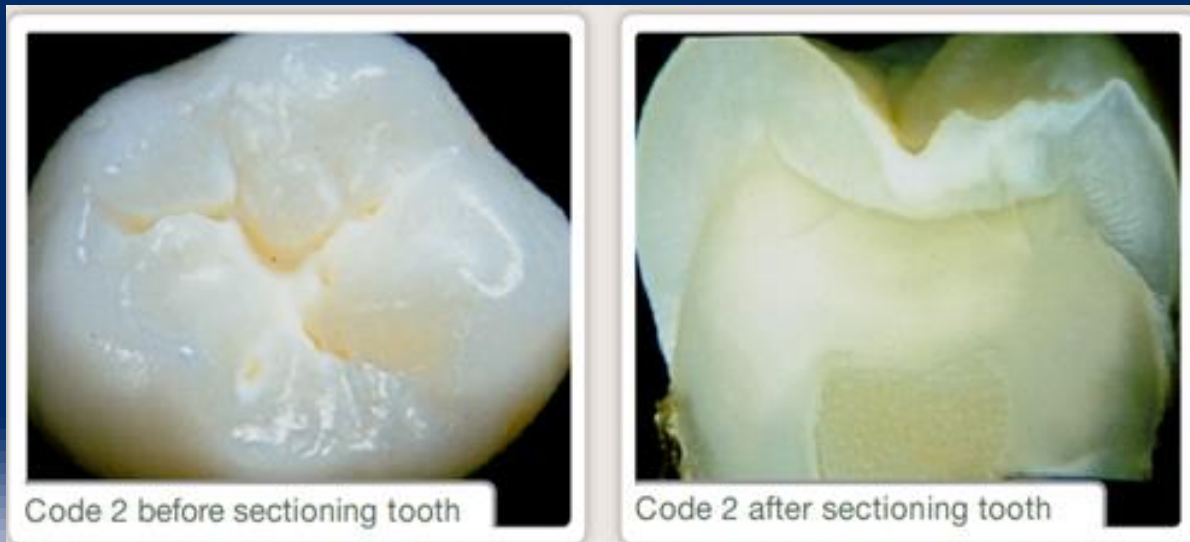Code 1 before sectioning tooth



Code 1 after sectioning tooth

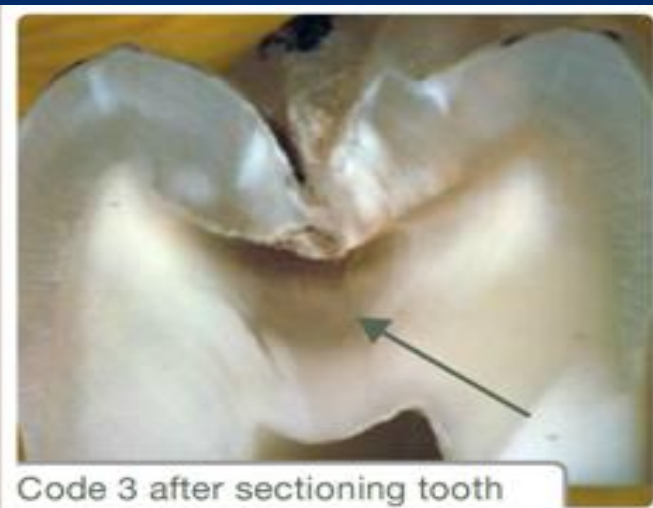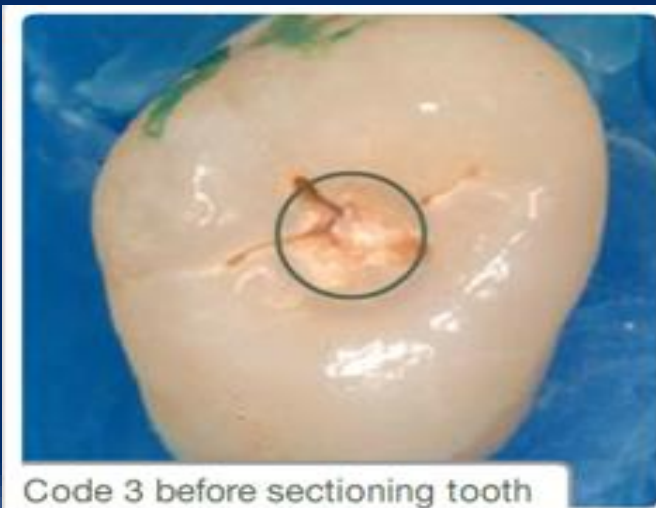ICDAS - kritéria

- 2. – first visual changes on wett surfaces



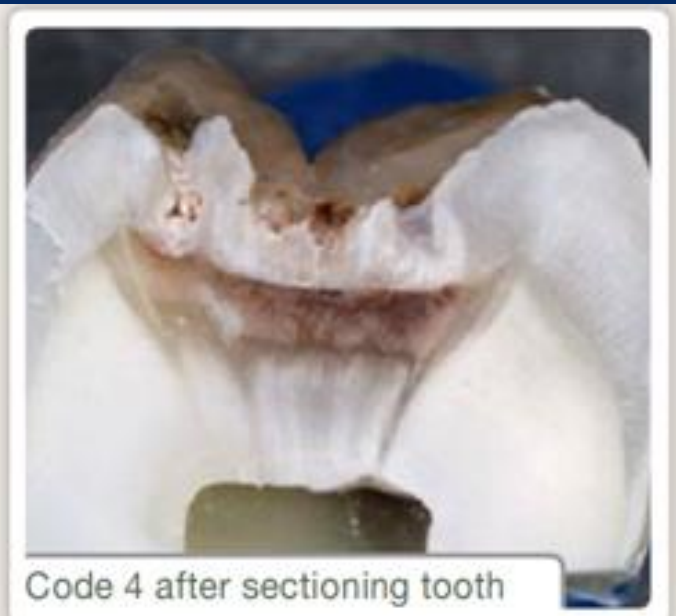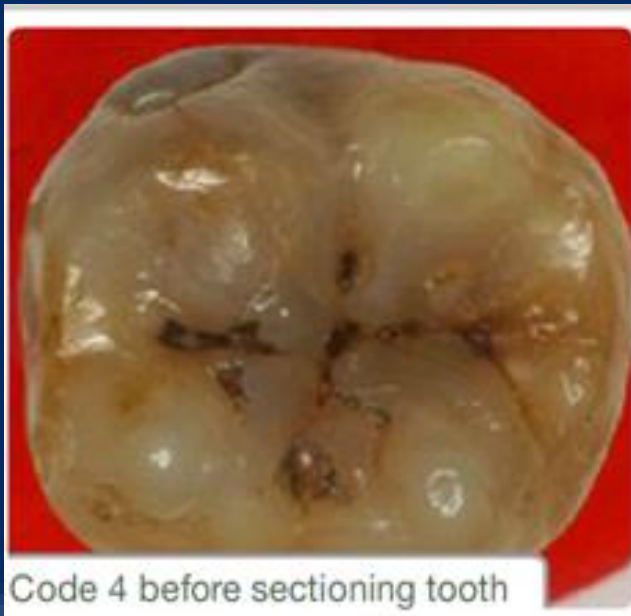ICDAS - kritéria

- **3** – enamel is still present, zone of decalcification is out of fissure, dentin is affected



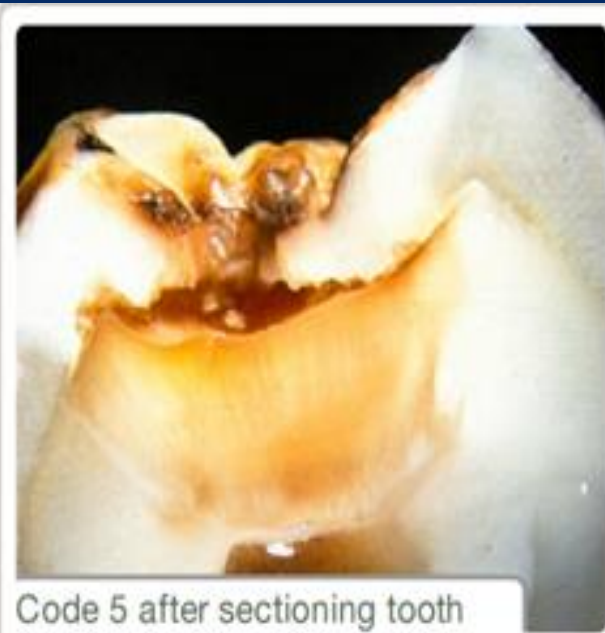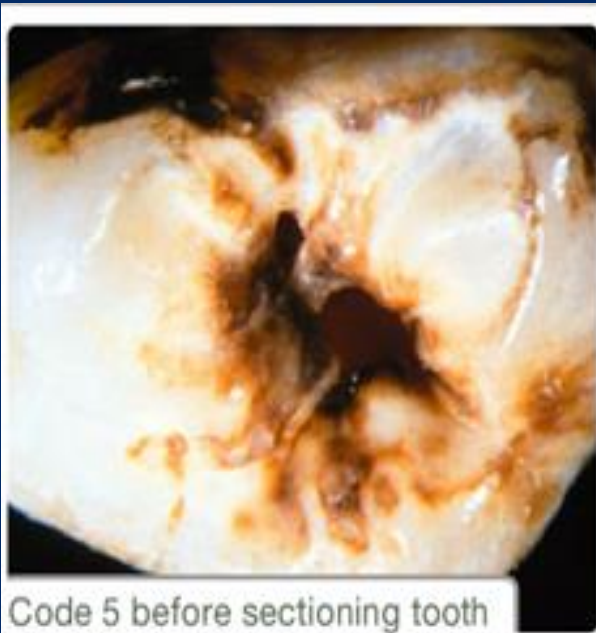ICDAS - kritéria

- 4 – dark colour around the fissure (grey, blue, brown), enamel can be broken



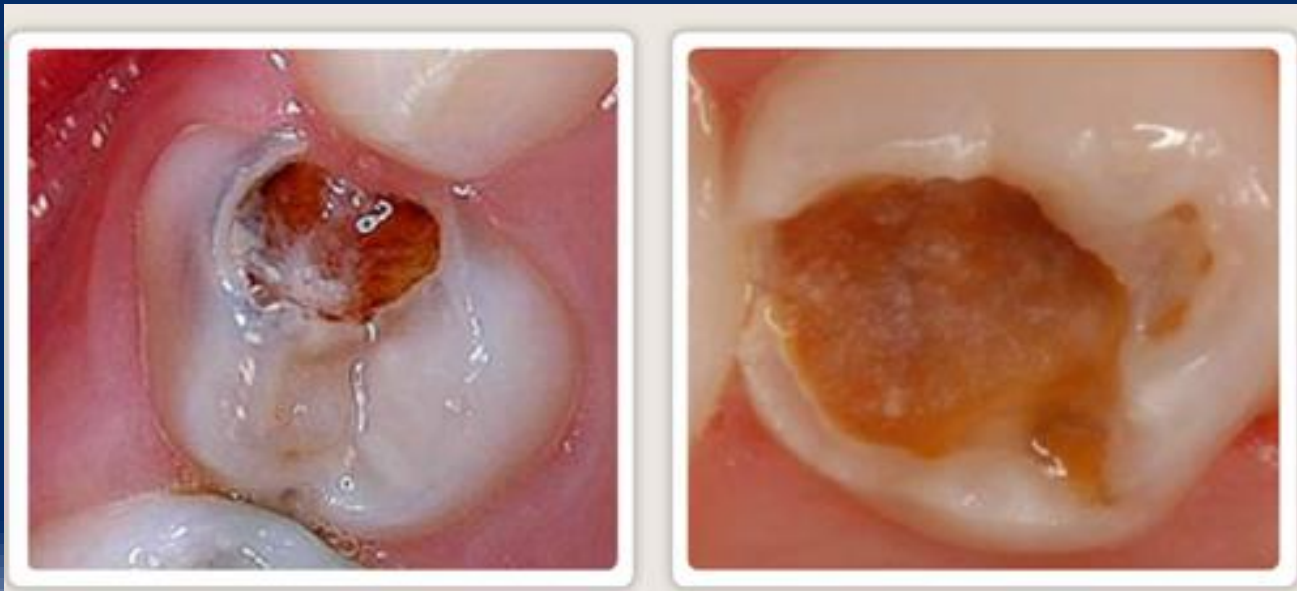ICDAS - kritéria

- 5 – cavitated lesion



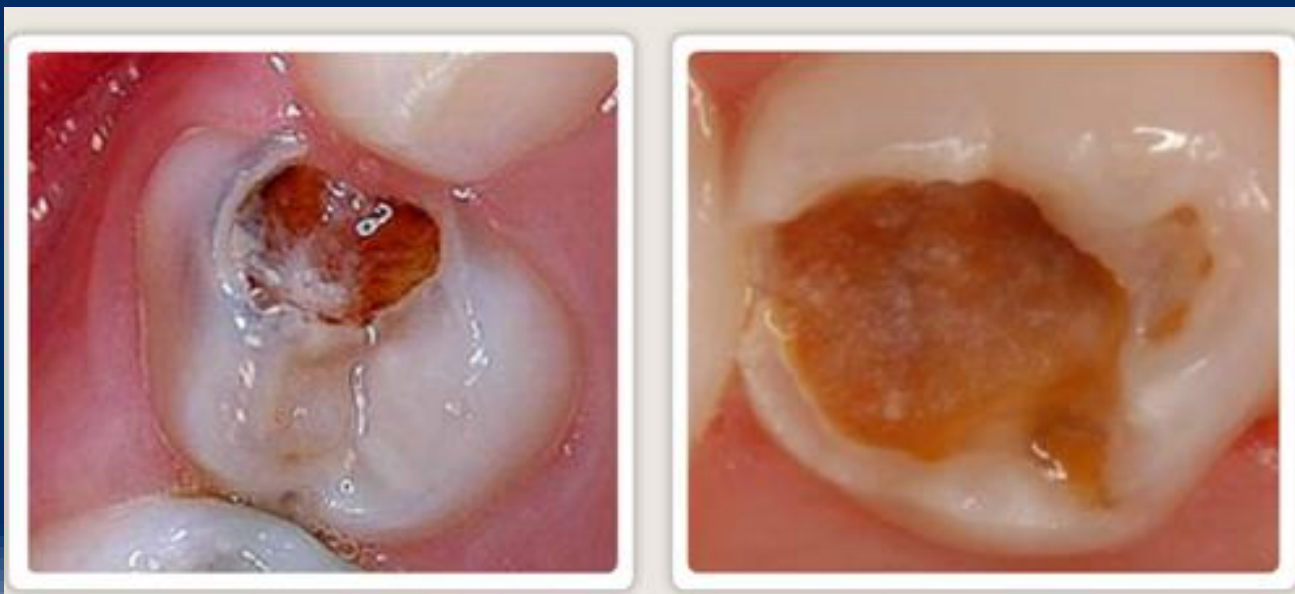ICDAS - kritéria

- 6 – large cavitation



ICDAS - kritéria

























- **KÓD 6 – rozsáhlá kavitace**, přičemž dentin je v hloubce i šířce naprosto zřetelný, minimálně polovina zubní plošky je postižená kazem, pulpa může být zasažena



















ICDAS II - modification

0:			<p>Žádná nebo nepatrná změna v průsvitnosti skloviny po delším osušování vzduchem (>5 sekund).</p> <p>Žádná demineralizace skloviny anebo úzká opákní zóna.</p>
1:			<p>Opacita nebo diskolorace obtížně viditelné na mokřem povrchu, avšak jasně zřetelné po osušení vzduchem.</p> <p>Demineralizace skloviny omezená na vnějších 50 % vrstvy skloviny.</p>
2:			<p>Opacita nebo diskolorace jasně zřetelná bez osušení vzduchem.</p> <p>Bez rozpoznatelné klinické kavitace. Demineralizace zasahující mezi 50 % skloviny a vnější třetinou dentinu.</p>
3:			<p>Lokalizované porušení skloviny v opákní nebo diskolorované sklovině, +/- našedlá diskolorace ze spodního dentinu. Demineralizace zasahuje prostřední třetinu dentinu.</p>
4:			<p>Kavitace v opákní a diskolorované sklovině ohrožující spodní dentin.</p> <p>Demineralizace zasahuje vnitřní třetinu dentinu.</p>

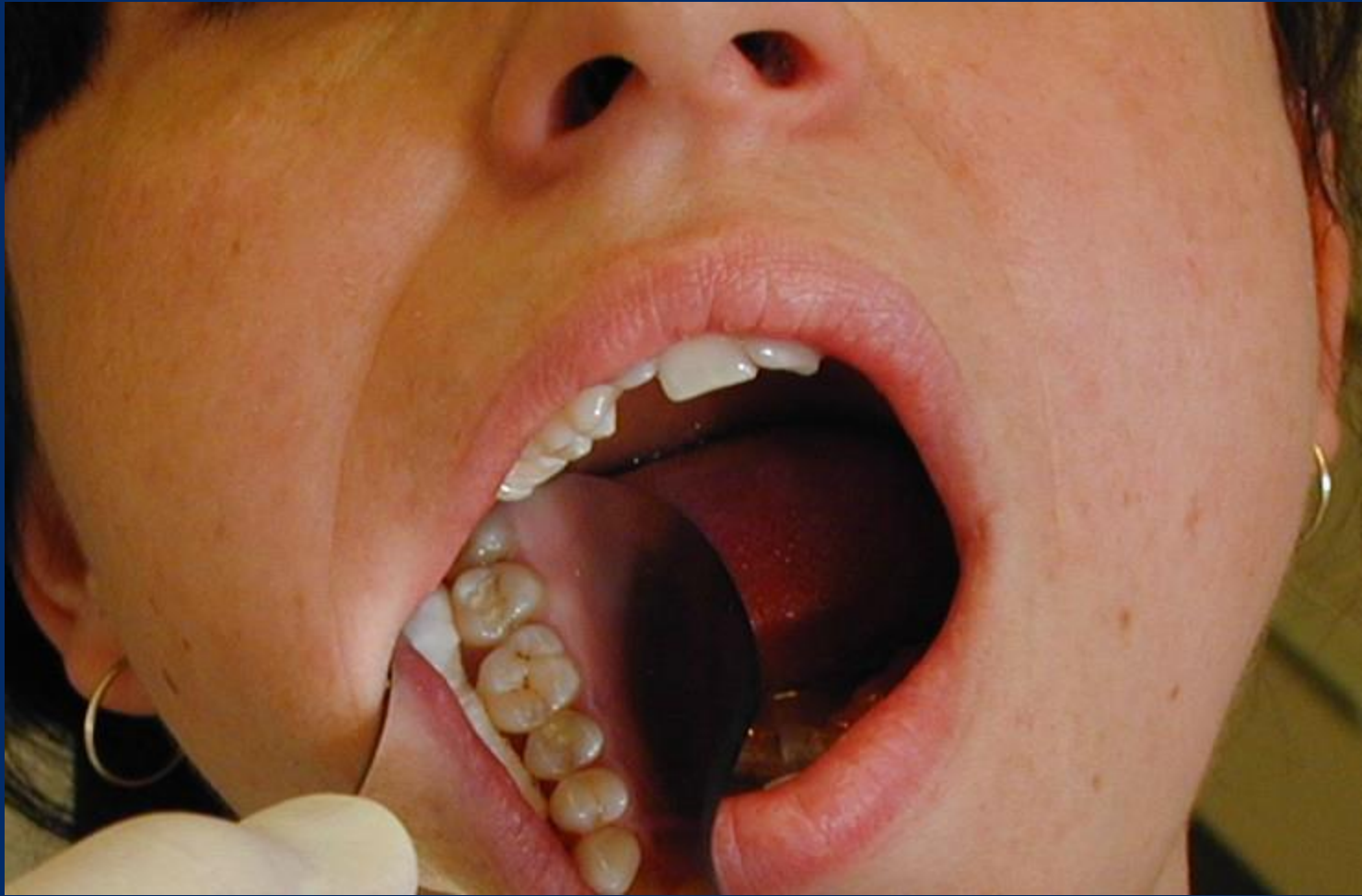UniViss – universal scoring system (occlusal surface)

Universal Visual Scoring System for pits and fissures (UniViSS occlusal)						
Second step: Discoloration Assessment	First step: Lesion Detection & Severity Assessment					
	First visible signs of a caries lesion	Established caries lesion	Microcavity and/or localised enamel breakdown	Dentin exposure	Large cavity	Pulp exposure
	Score F	Score E	Score M	Score D	Score L	Score P
Sound surface (Score 0)	No cavitations or discolorations are detectable.					
White (Score 1)						
White-brown (Score 2)						
(Dark) Brown (Score 3)						
Greyish translucency (Score 4)						

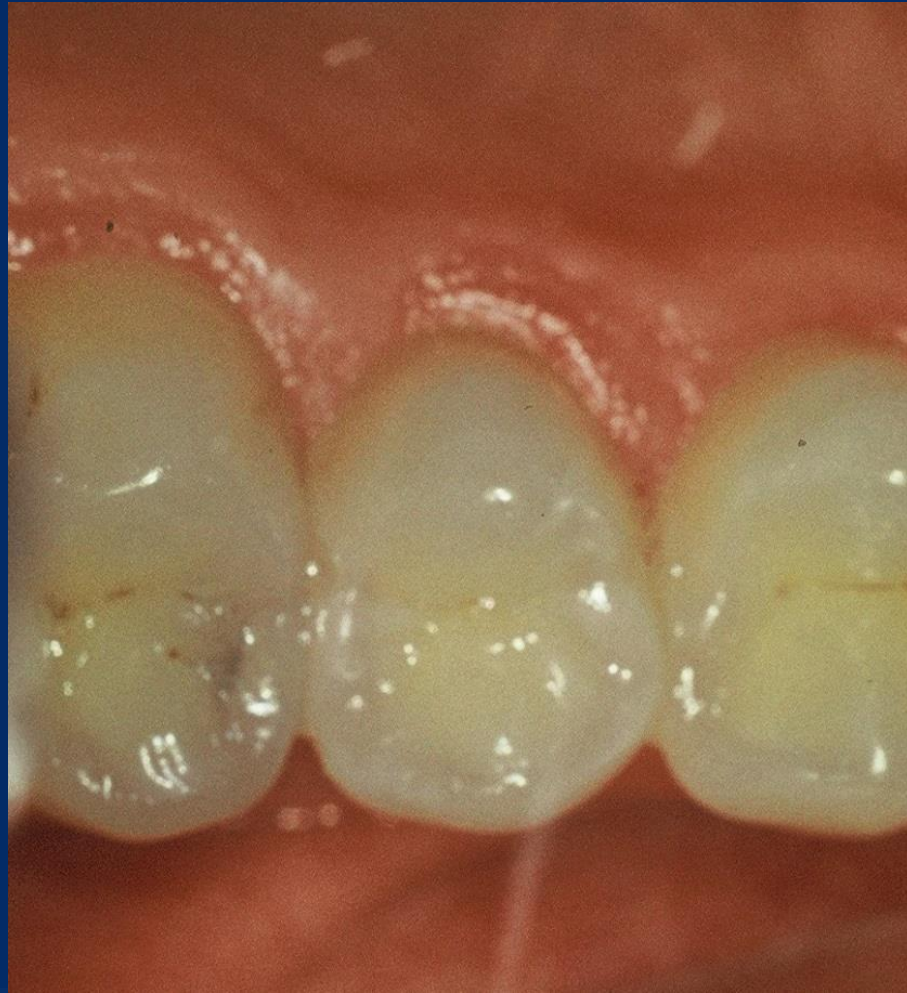UniViss (smooth surface)

Universal Visual Scoring System for smooth surfaces (UniViSS smooth)						
Second step: Discoloration Assessment	First step: Lesion Detection & Severity Assessment					
	First visible signs of a caries lesion	Established caries lesion	Microcavity and/or localised enamel breakdown	Dentin exposure	Large cavity	Pulp exposure
	Score F	Score E	Score M	Score D	Score L	Score P
Sound surface (Score 0)	No cavitations and/or discolorations are detectable					
White (Score 1)						
White-brown (Score 2)						
(Dark) Brown (Score 3)						
Greyish translucency (Score 4)						

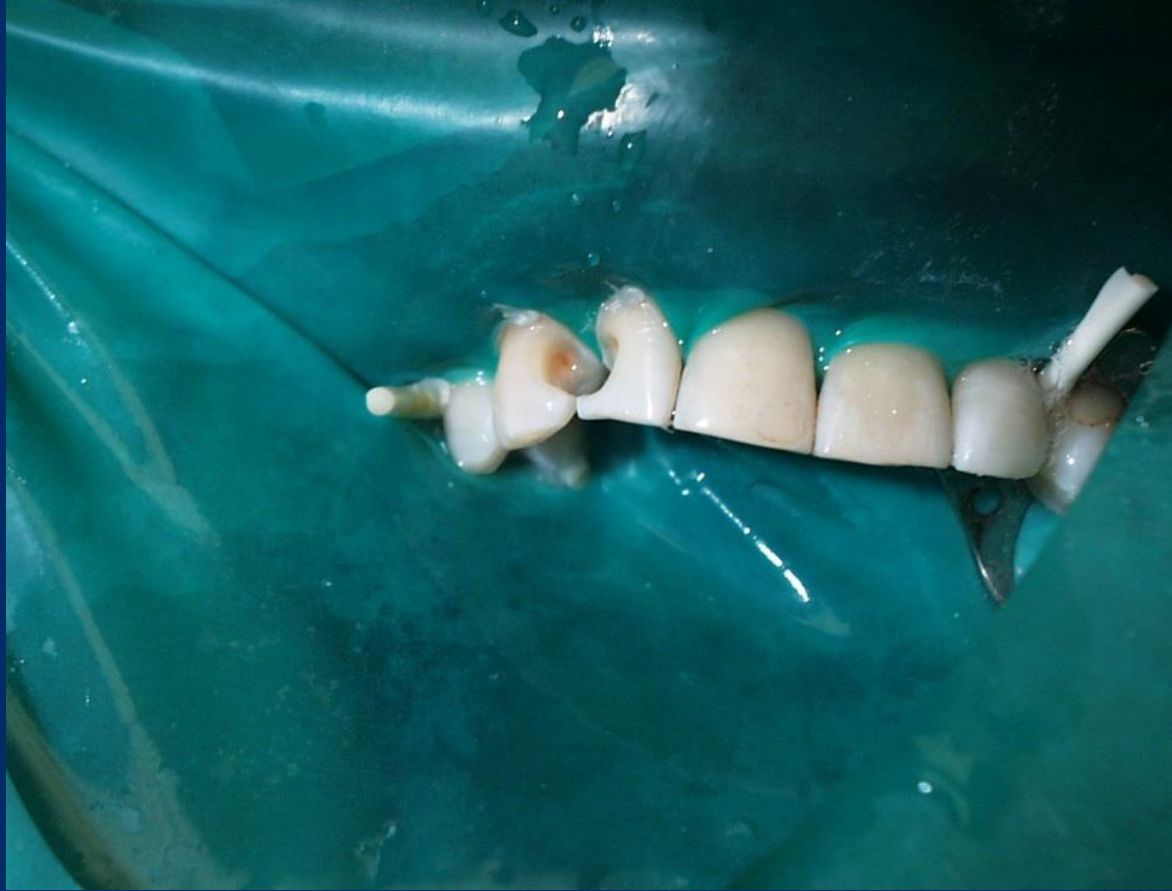Classification acc to Black



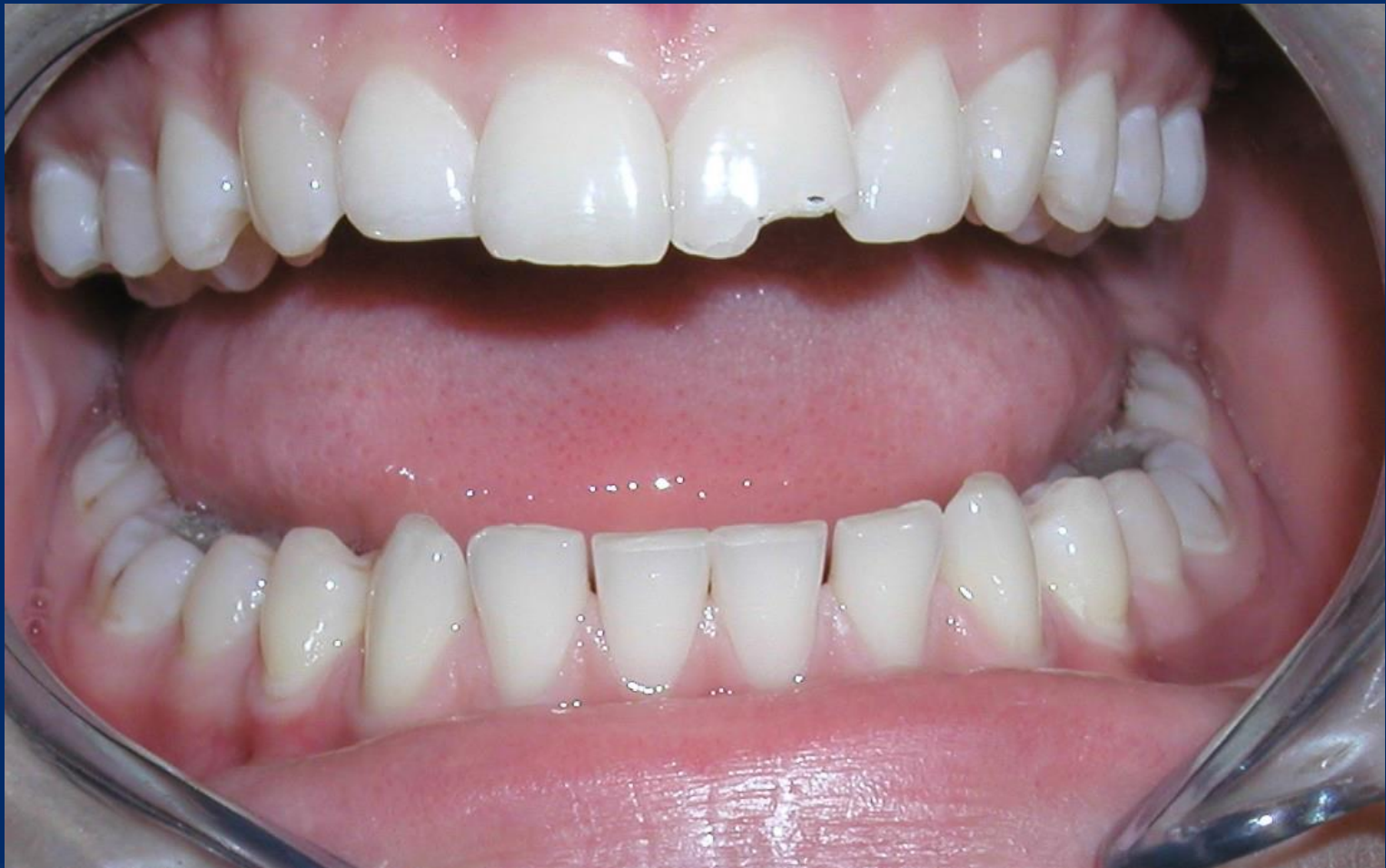Classification acc to Black



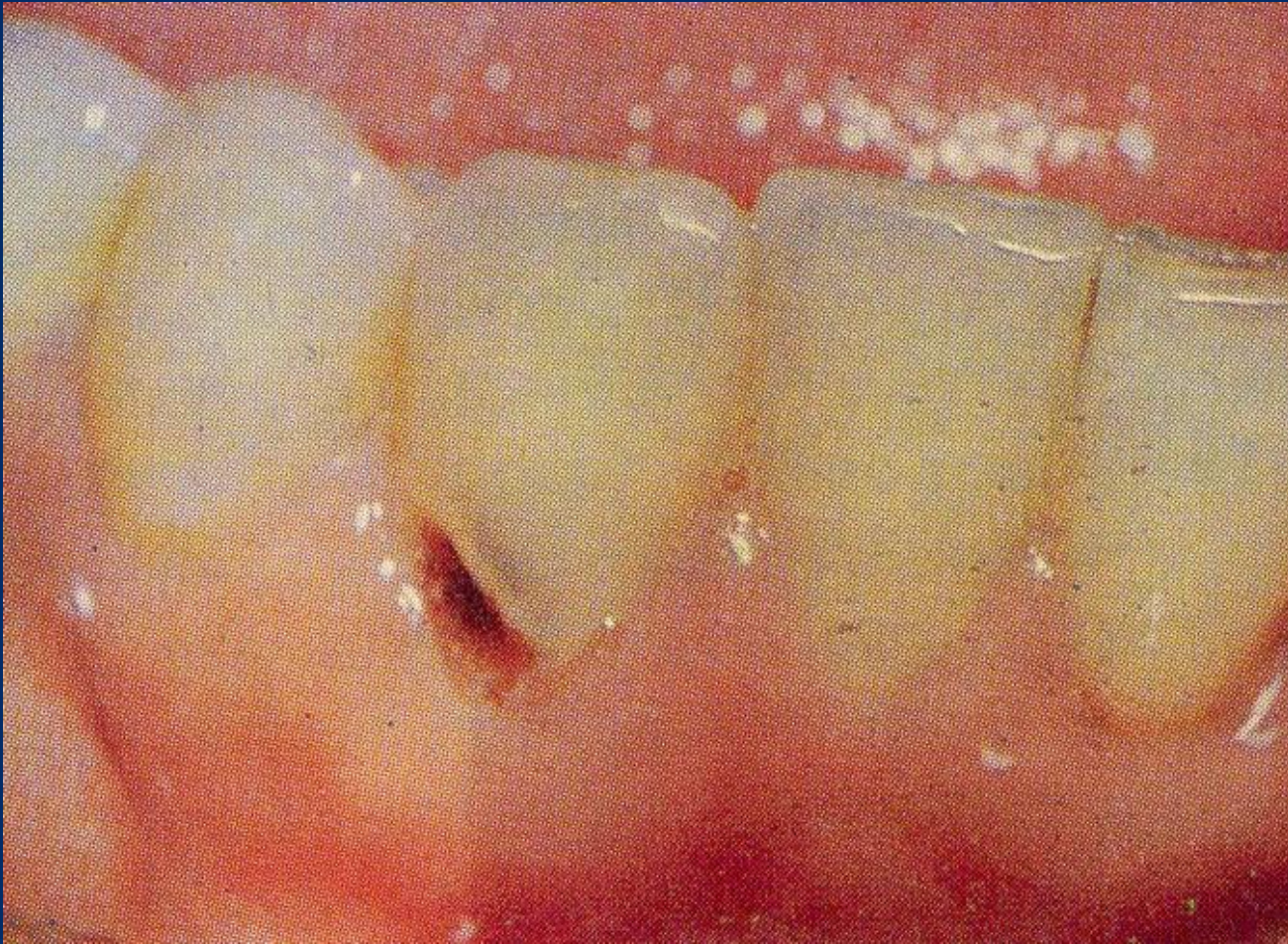Classification acc to Black



Classification acc to Black



Classification acc to Black




Classification of dental caries Mount and Hume

- Location
 - 1.Occlusal
 - 2. Proximal
 - 3.Cervical
- Size
 - 1.Small
 - 2. Medium
 - 3. Big
 - 3.Large

Occlusal caries

- ICDAS 0 – 1 : observation
- ICDAS 2: observation or preventive filling
- ICDAS 3 – 4: filling therapy

Preparation



- Preparation is an instrumental treatment of carious tooth that leaves the rest of the tooth that is restorable, resistant and that prevent the origin of dental caries at the same surface.