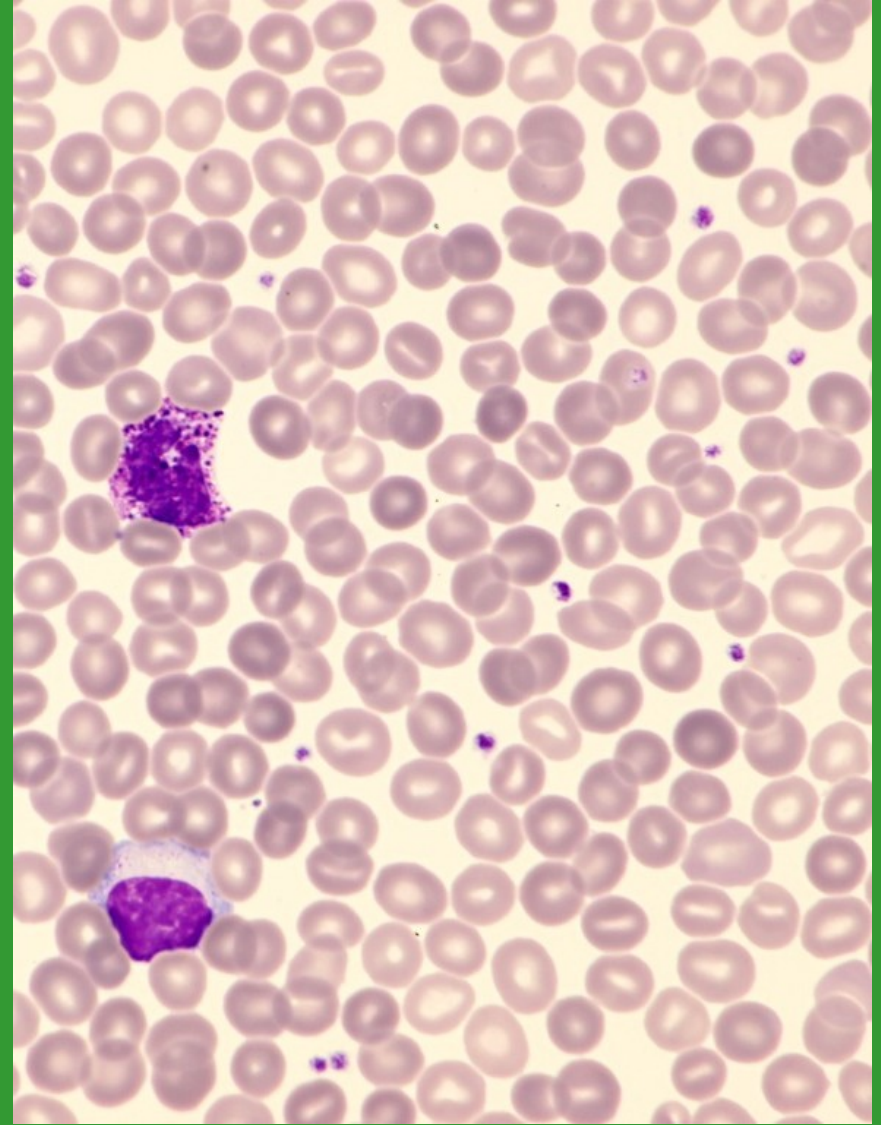
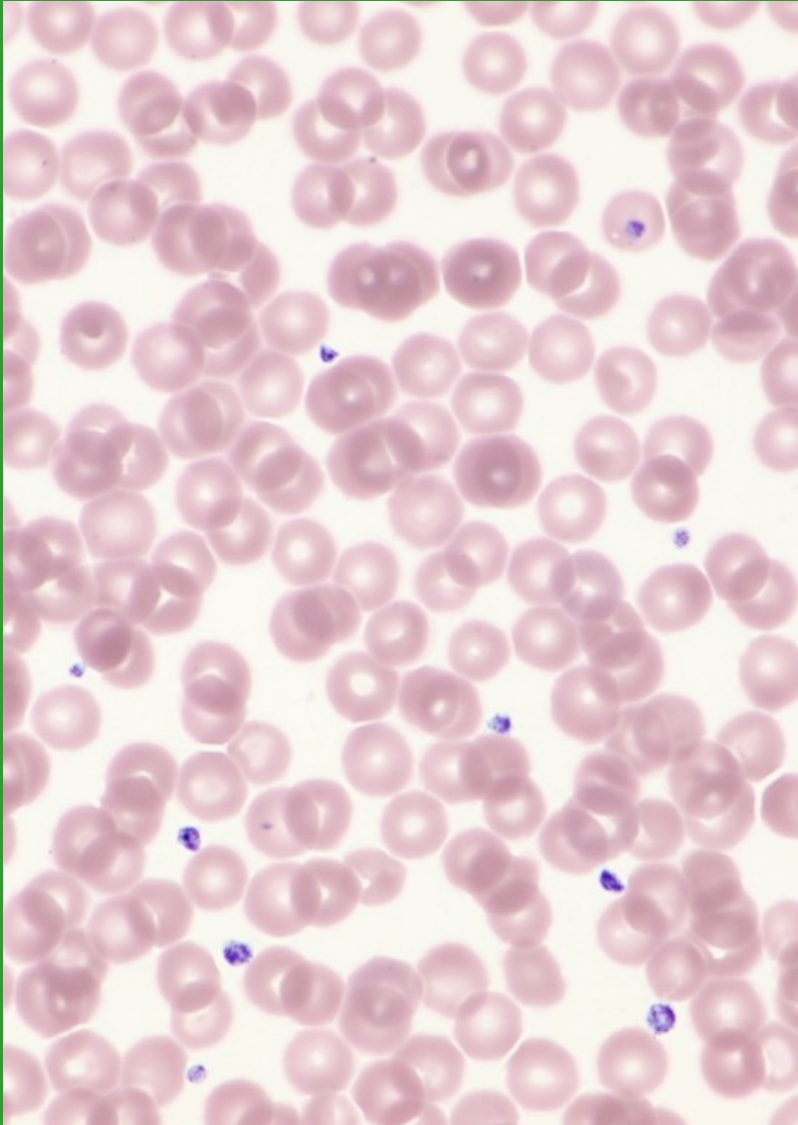


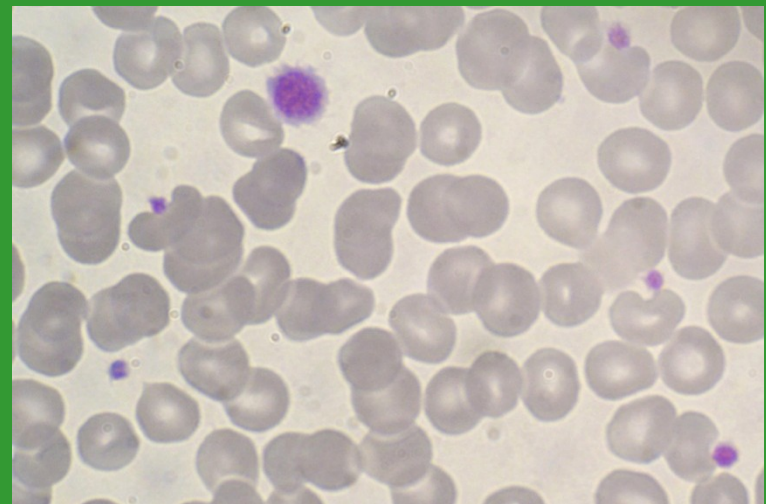
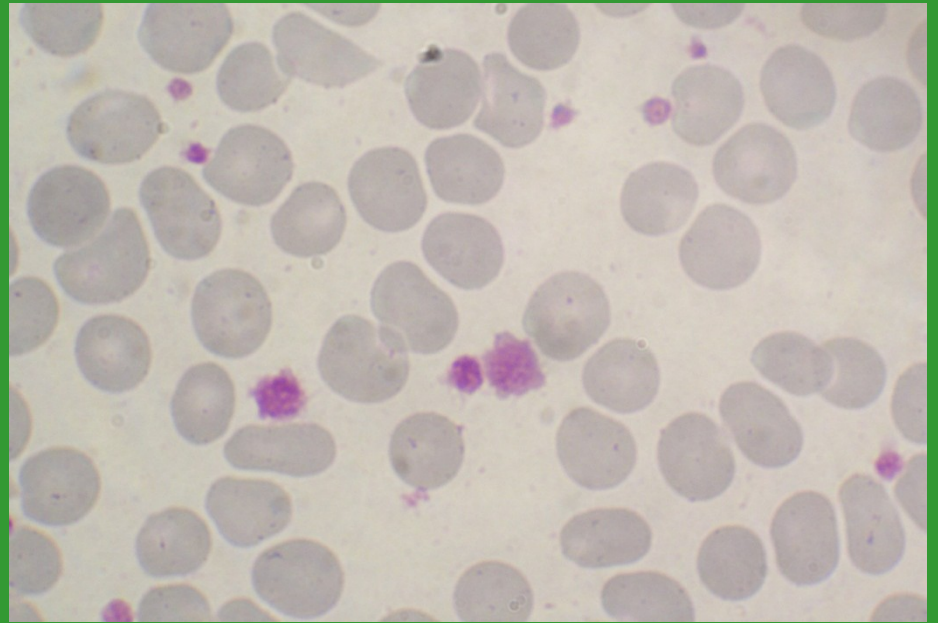
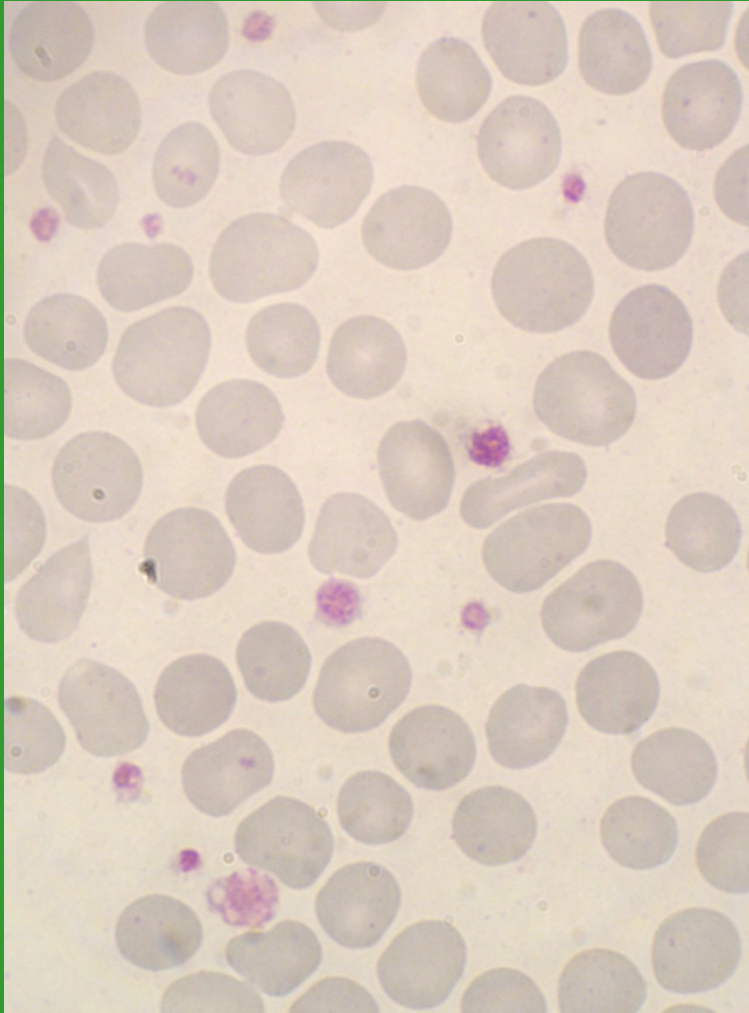
# Morfologie trombocytů

*Bourková L., OKH FN Brno*

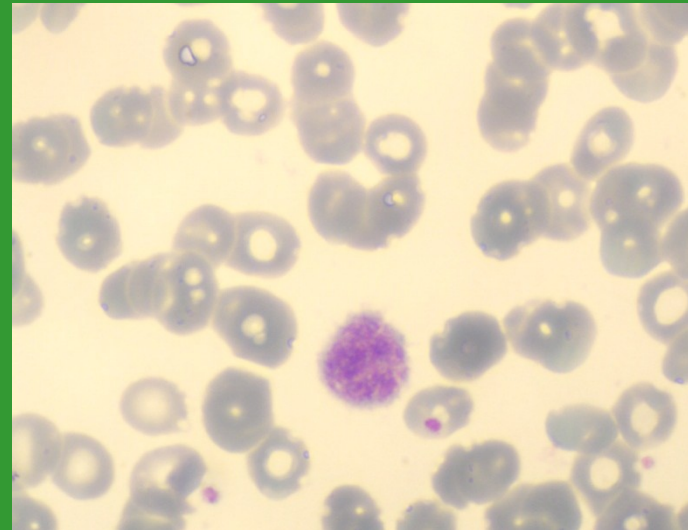
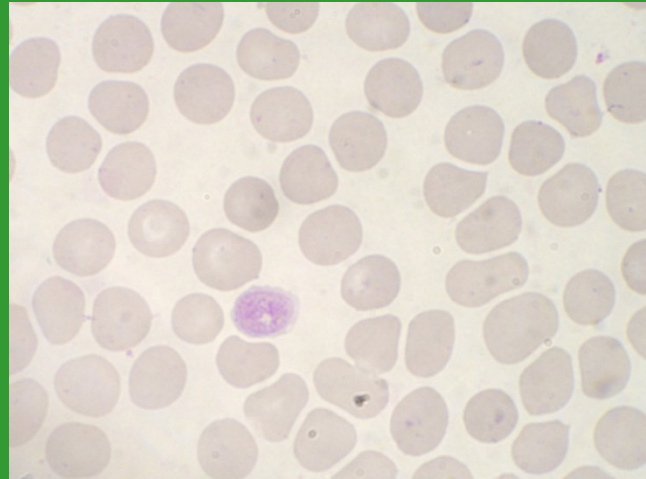
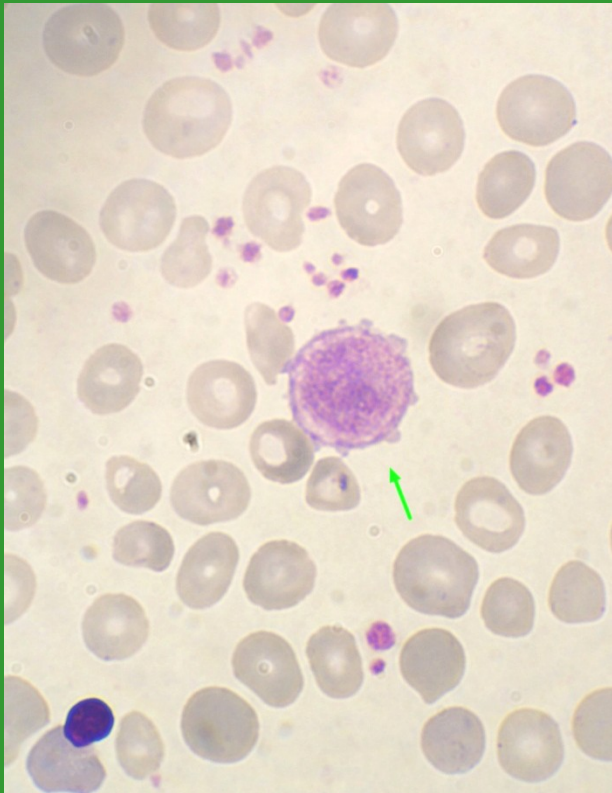
# Fyziologické trombocyty



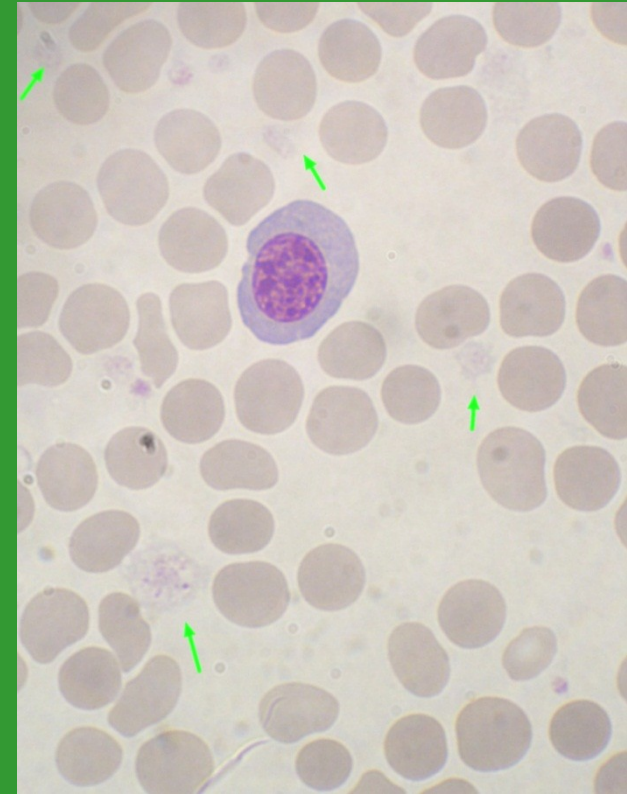
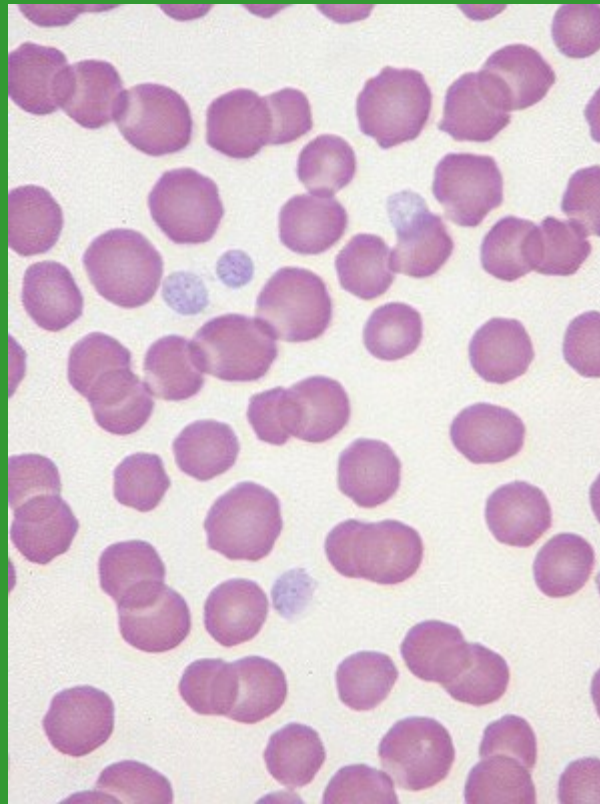
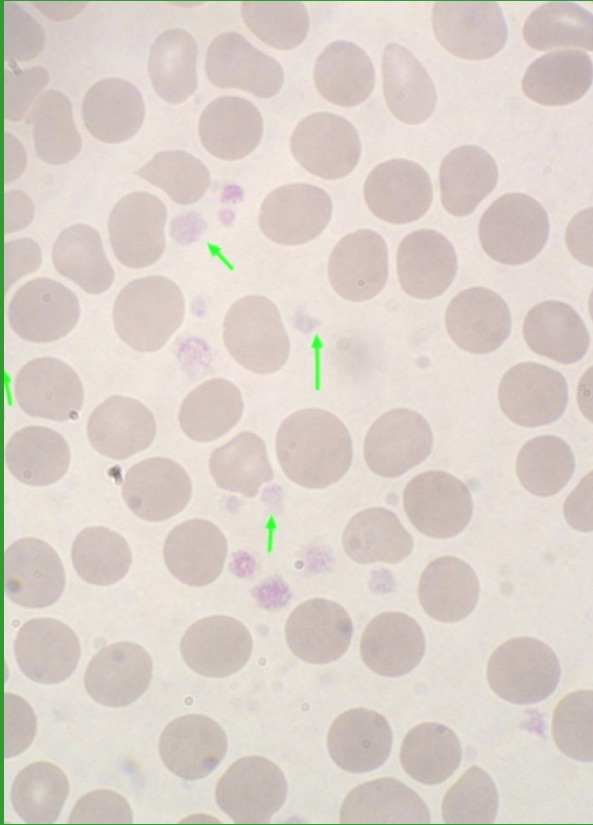
# Anizocytóza trombocytů



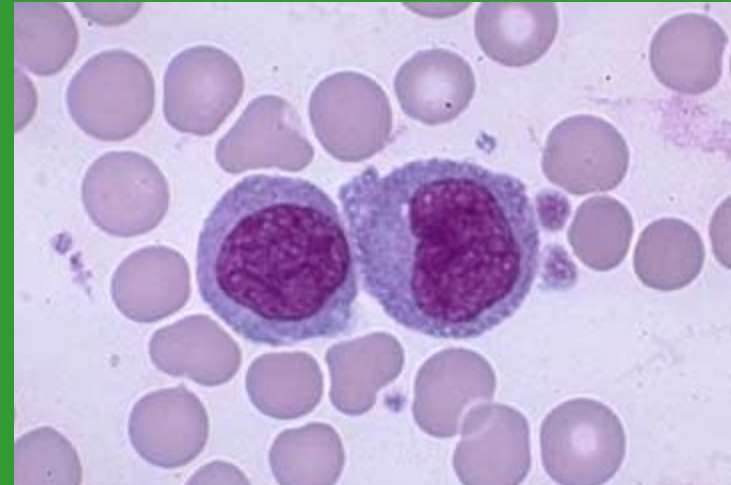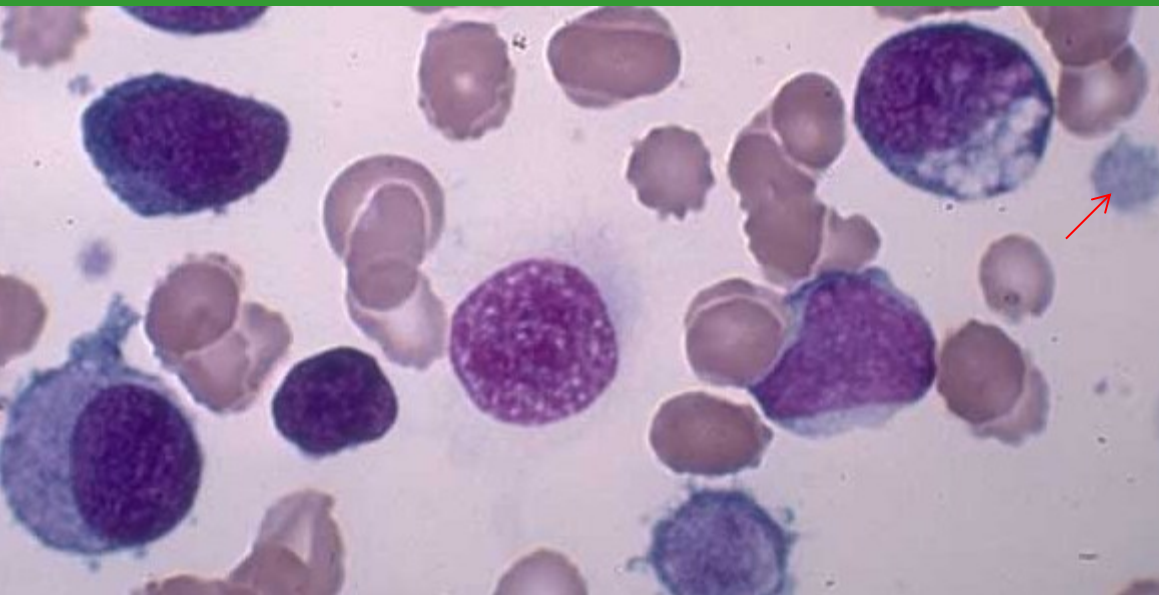
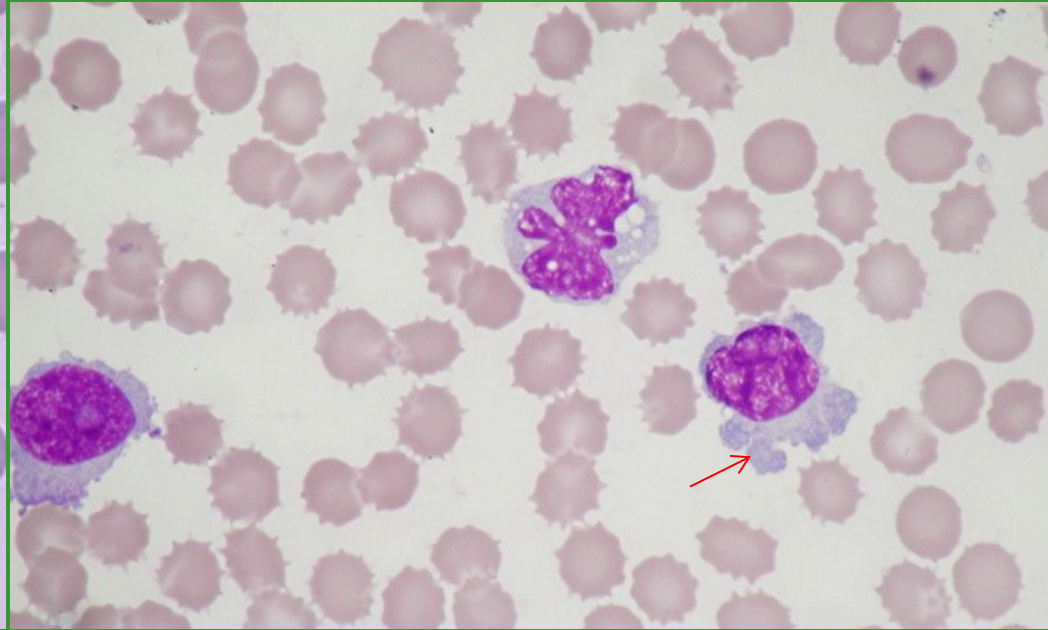
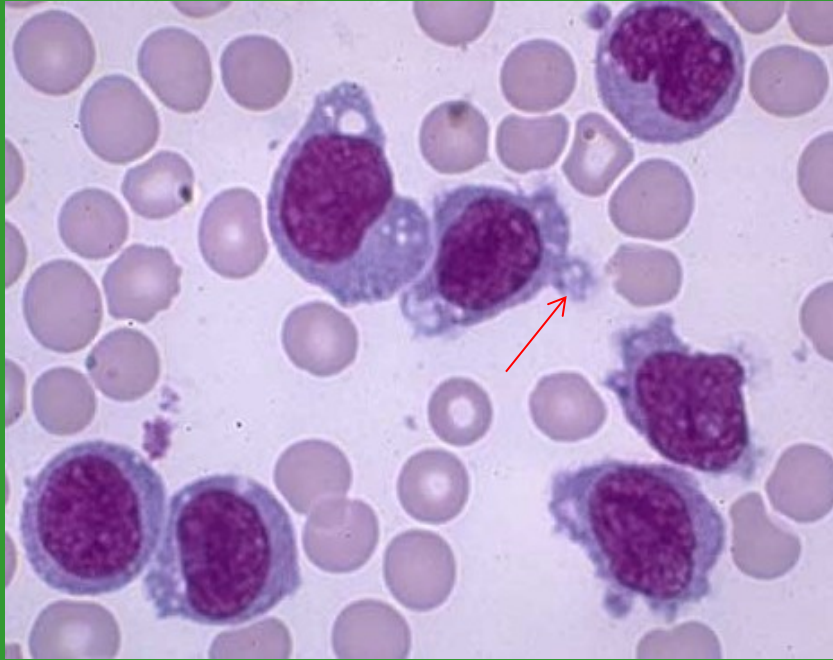
# Makrotrombocyty – gigantické trombocyty



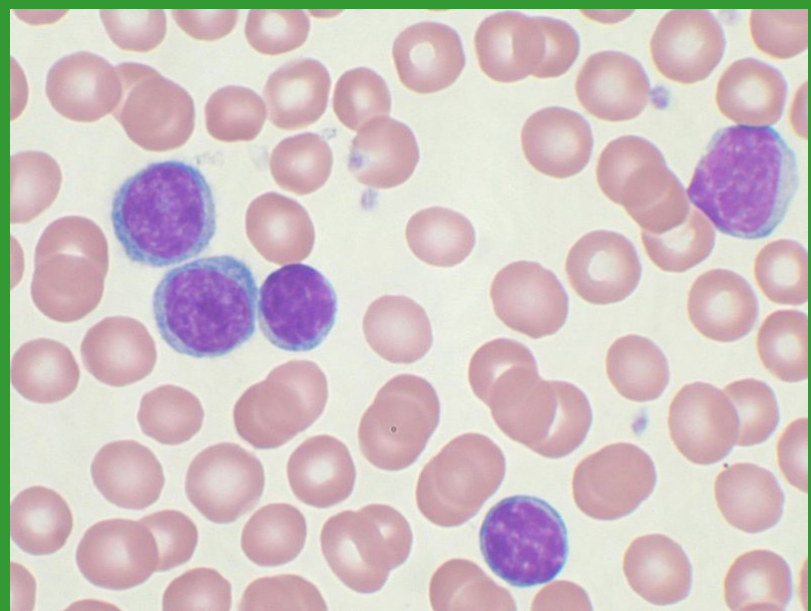
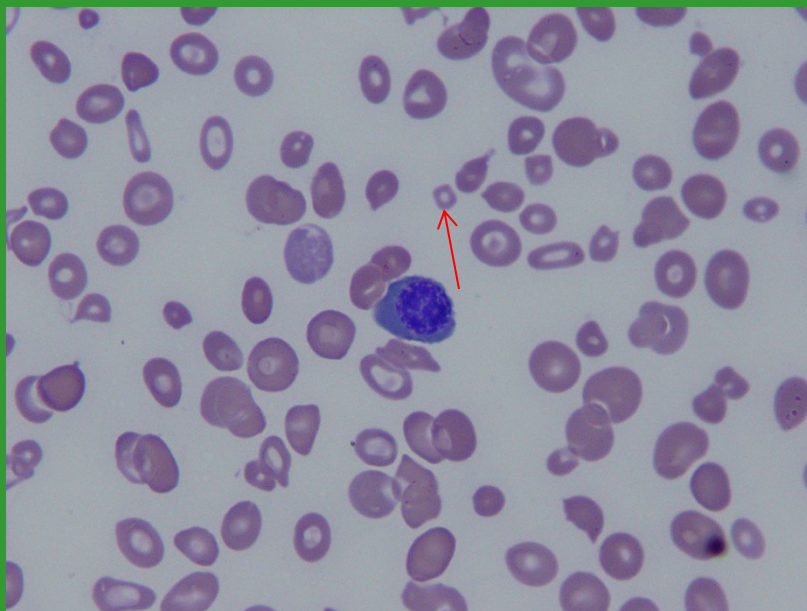
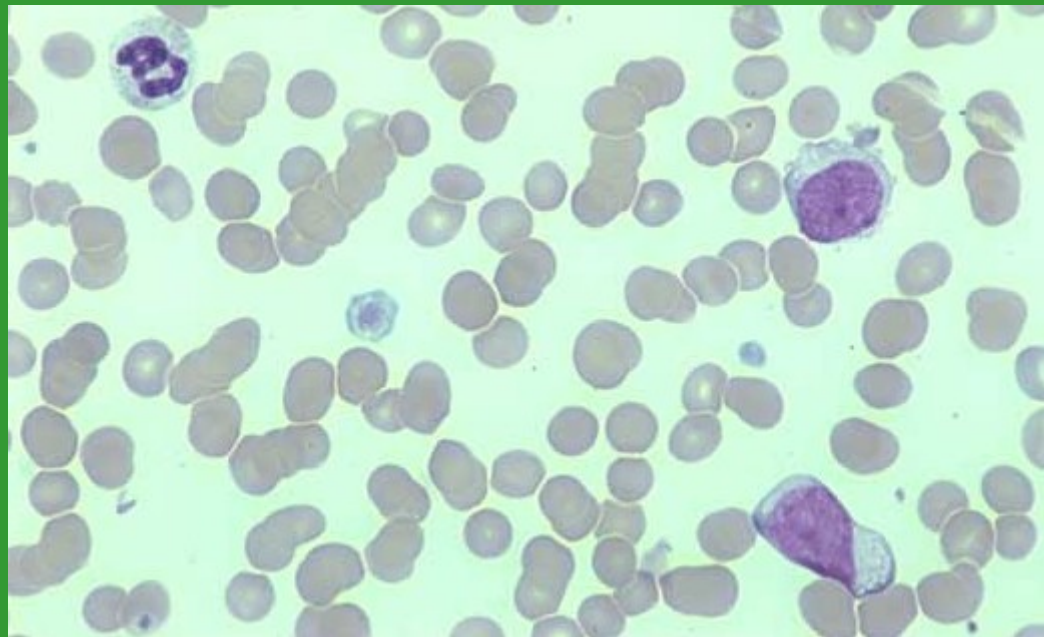
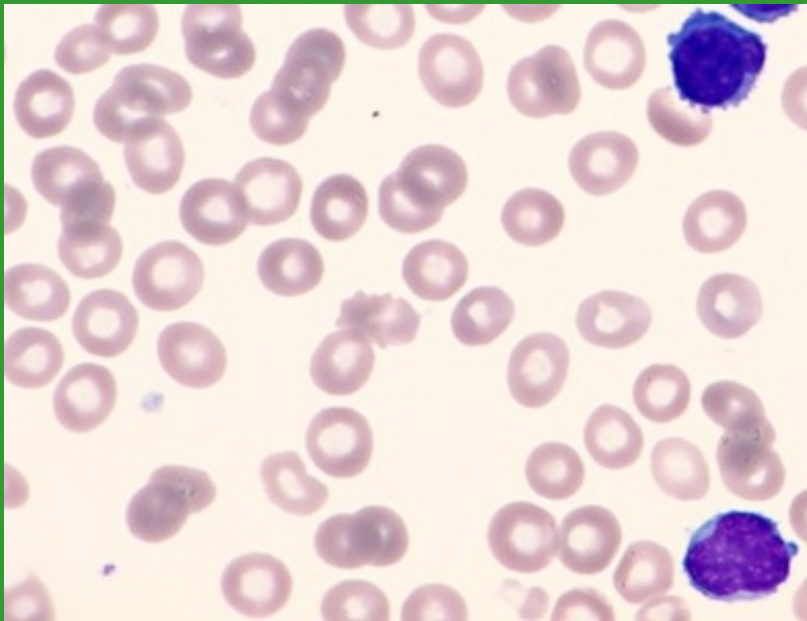
# Hypogranulární trombocyty



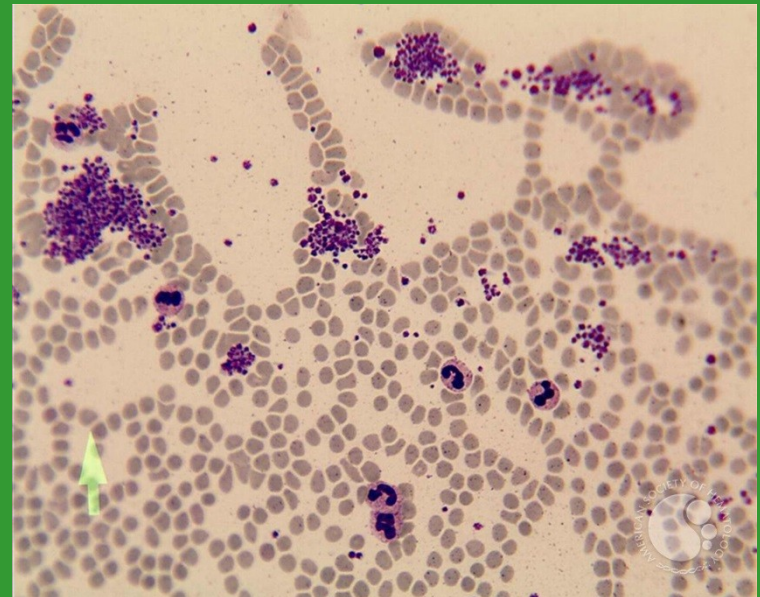
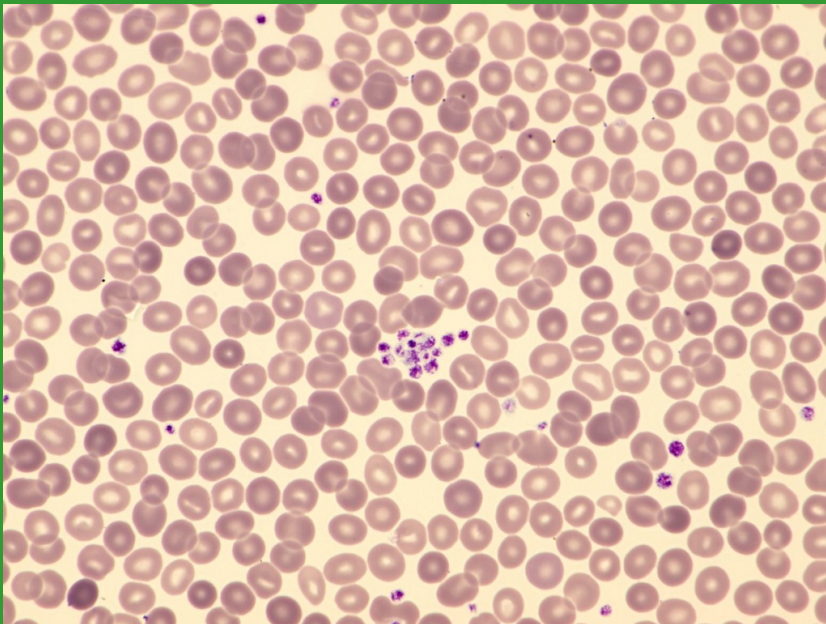
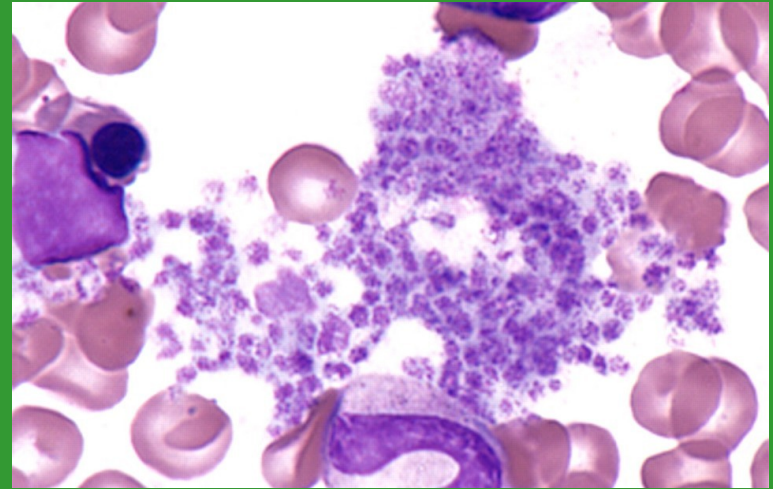
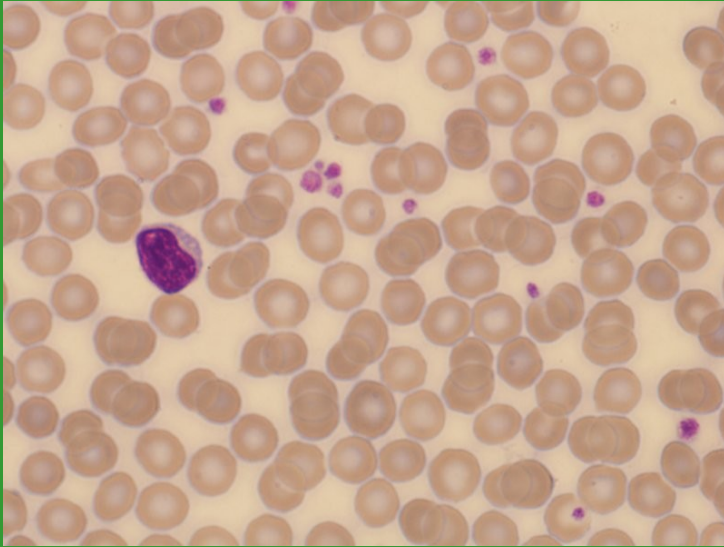
# Fragmenty cytoplazmy (MGK x WBC)



PLT – hypogranulace x buněčné fragmenty x mikrocyty

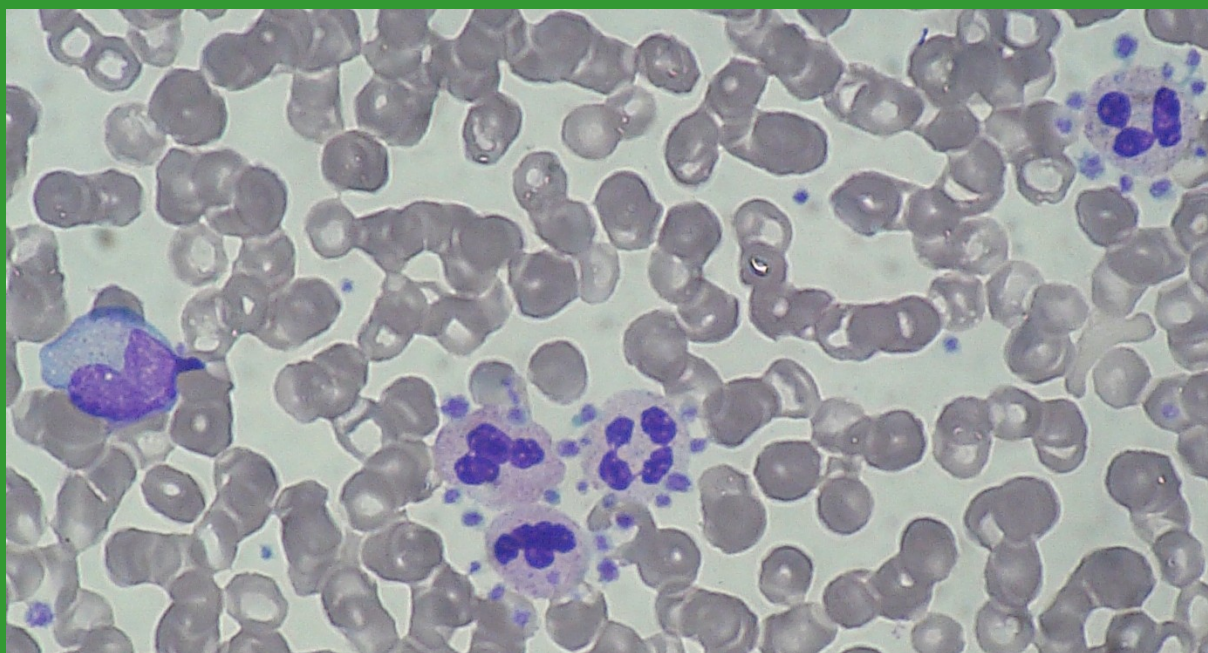
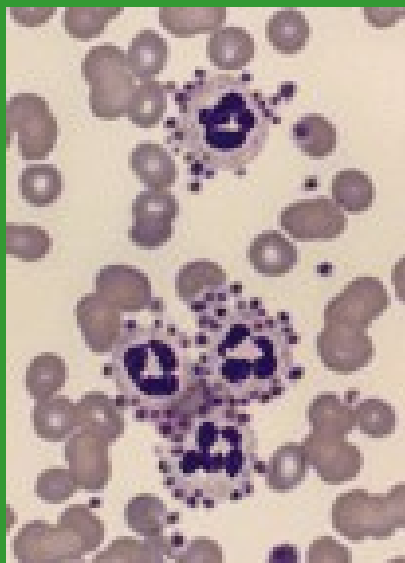
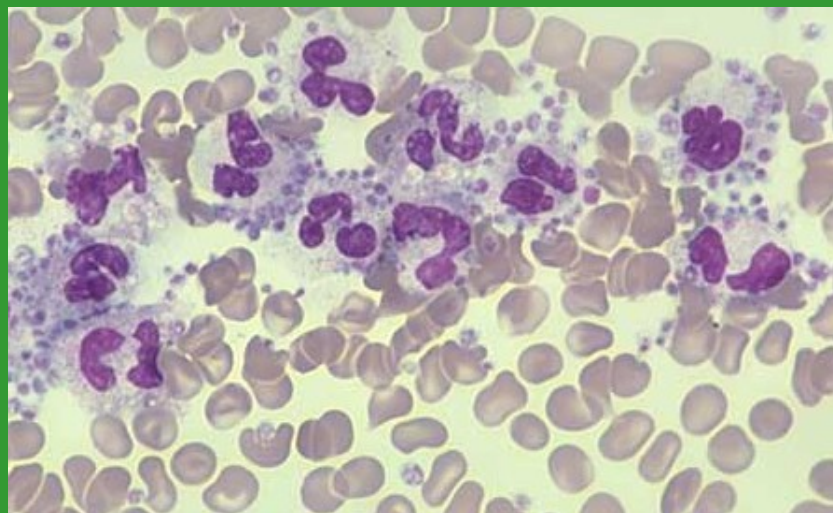
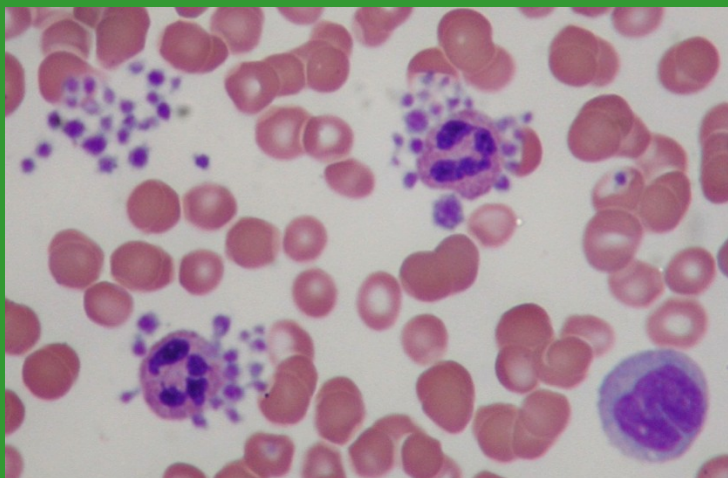


# Shluky/sraženiny trombocytů



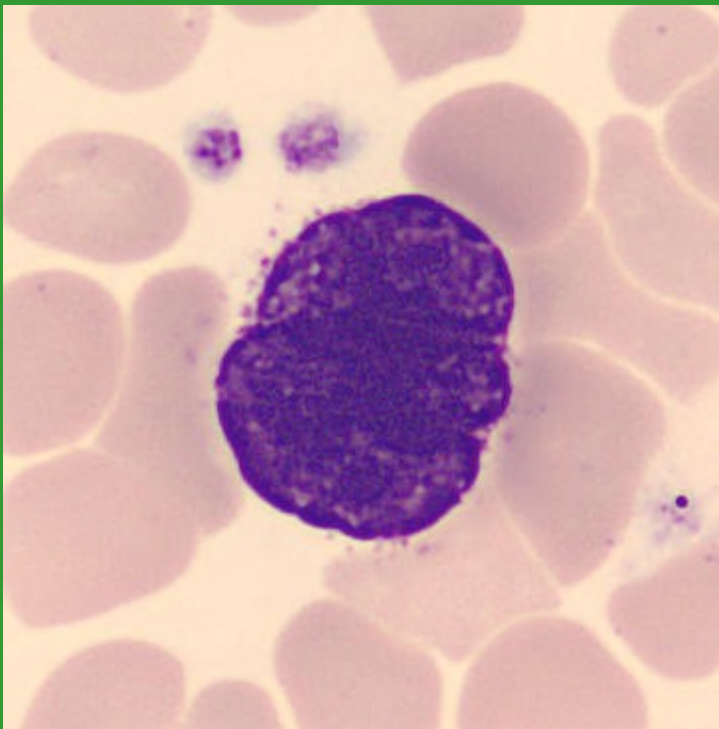


# Satelitismus trombocytů



# Megakaryocyty

holé jádro MGK v PK



MGK v KD

