

First aid

Wounds, bleeding, bandages

Jan Hudec, MD
Tomáš Korbička, MD
KARIM FN Brno



Department of Anaesthesiology
and Intensive Care Medicine
University Hospital Brno
Faculty of Medicine of Masaryk University

Wounds

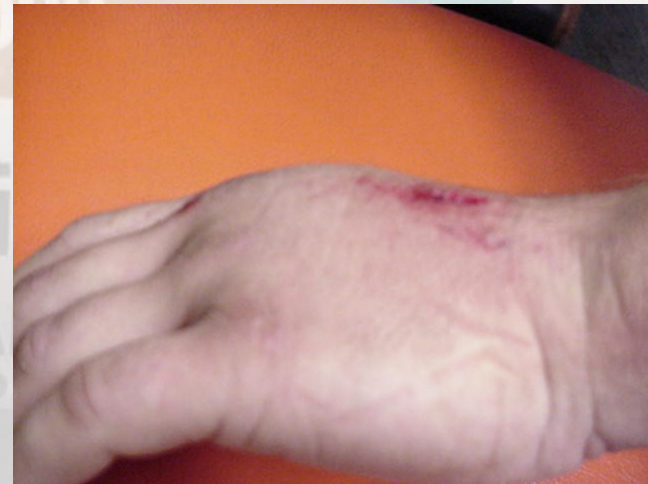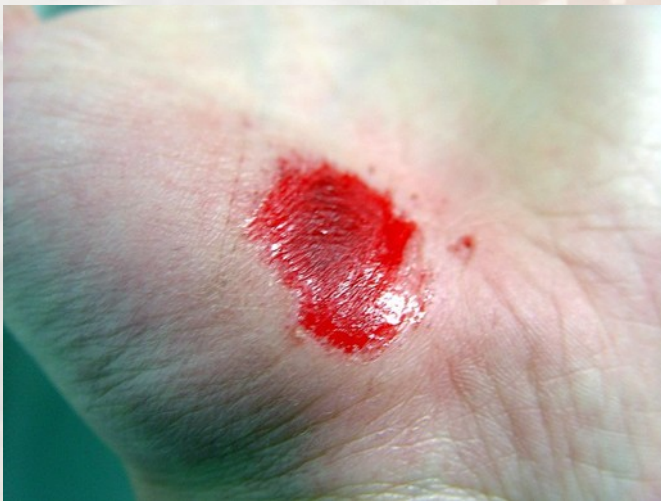- an injury, usually involving division of tissue or rupture of membrane, due to external violence
- infected (tetanus, clostridium, rabies...)
- bleeding
- painfull
- top of iceberg... (how deep, nerve, vessel injury, foreign object)

Wounds:

- superficial X deep
- simple X complicated
- penetrating (reaching internal organs/cavities)
- cleaned X soiled (mechanically)

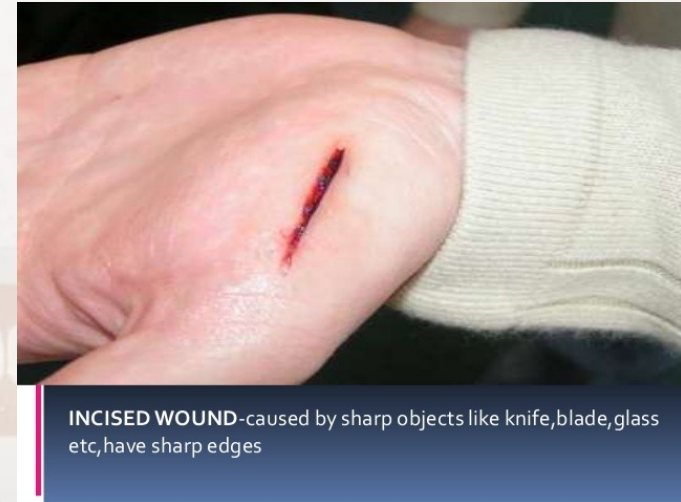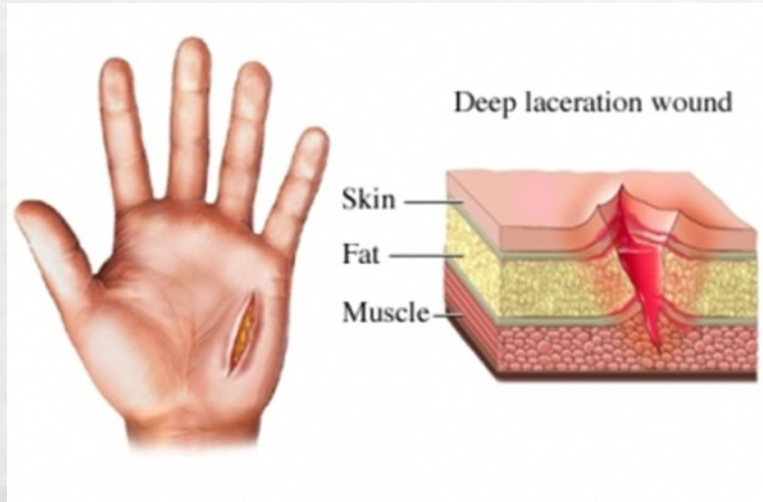
Types of wounds

Abrasion=graze - caused by transverse action of a foreign object against the skin, and usually does not penetrate below the epidermis



Contusion=bruise – vulnus contusum - blunt force trauma damaging tissue under the surface of the skin

Types of wounds



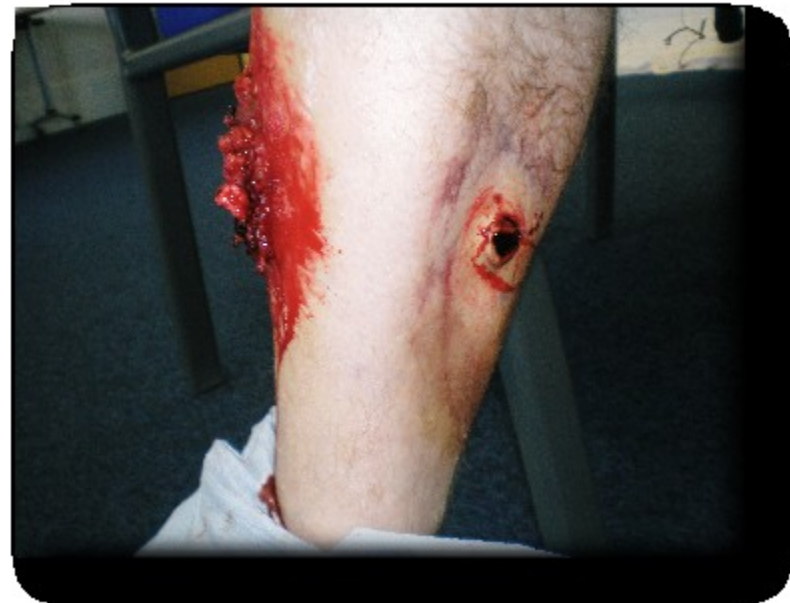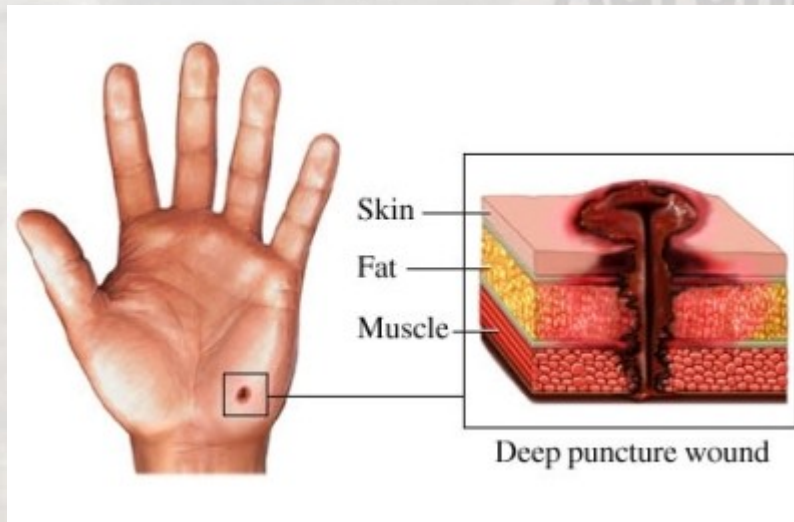
Laceration – *vulnus lacerum* - irregular wound caused by blunt impact to soft tissue overlying hard tissue or tearing such as in childbirth

Incised wound - cut into a body tissue or organ, such as by a scalpel, made during surgery

Types of wounds

Puncture wound - caused by an object that penetrated the skin and underlying layers, such as a nail, needle or knife

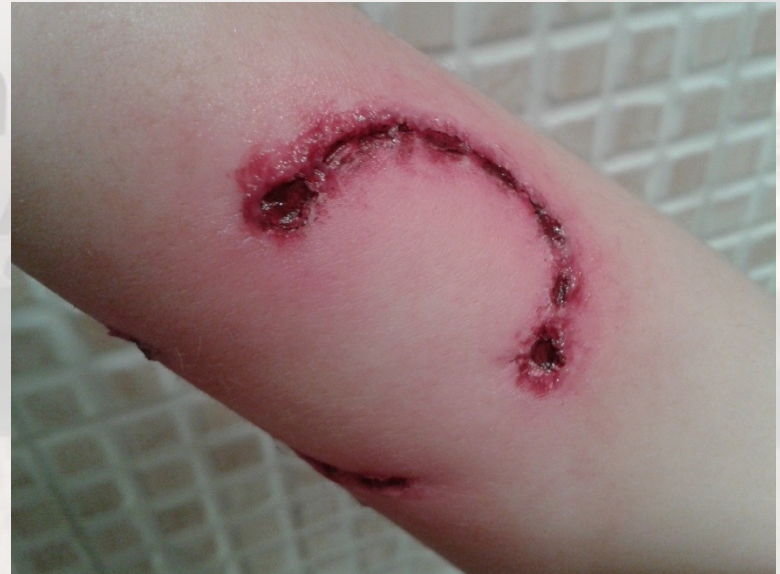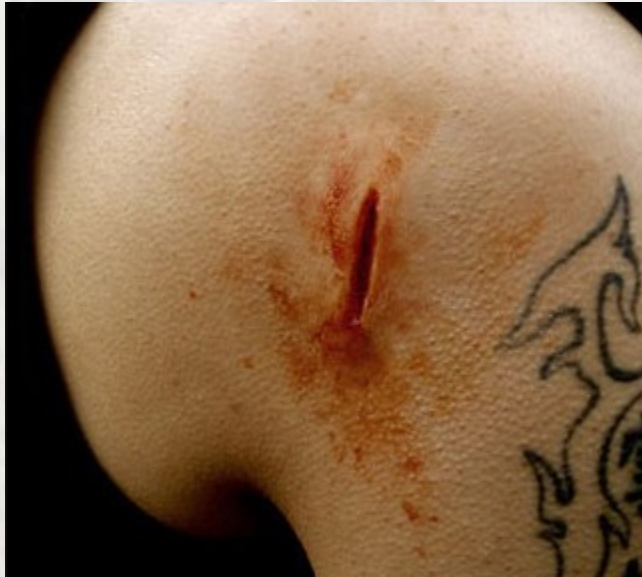Gunshot wound - caused by a projectile weapon such as a firearm (entry and exit)



Types of wounds

Stab wound – caused by long or bladed instrument, penetrating the body

Bite wound – human or animal

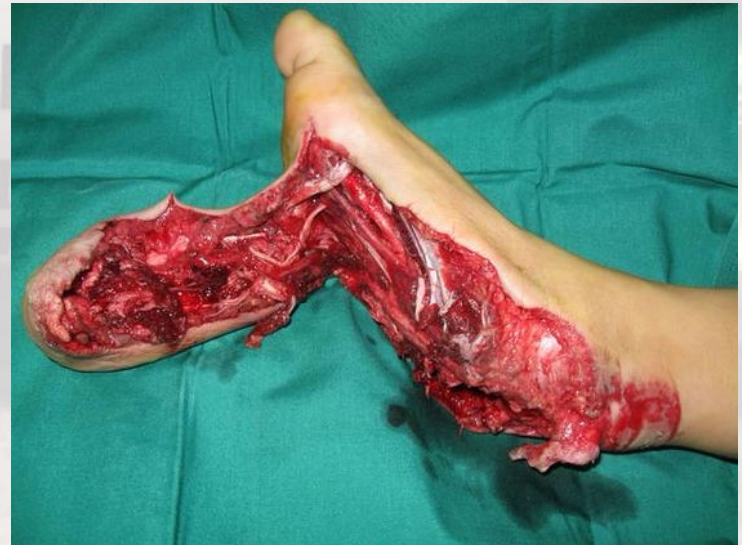

Types of wounds

- incised wound (*Vulnus scissum*)
- puncture wound (*Vulnus punctum*)
- gunshot wound (*Vulnus sclopetarium*)
- bite wound (*Vulnus morsum*)
- laceration (*Vulnus lacerum*)
- contusion (*Vulnus contusum*)

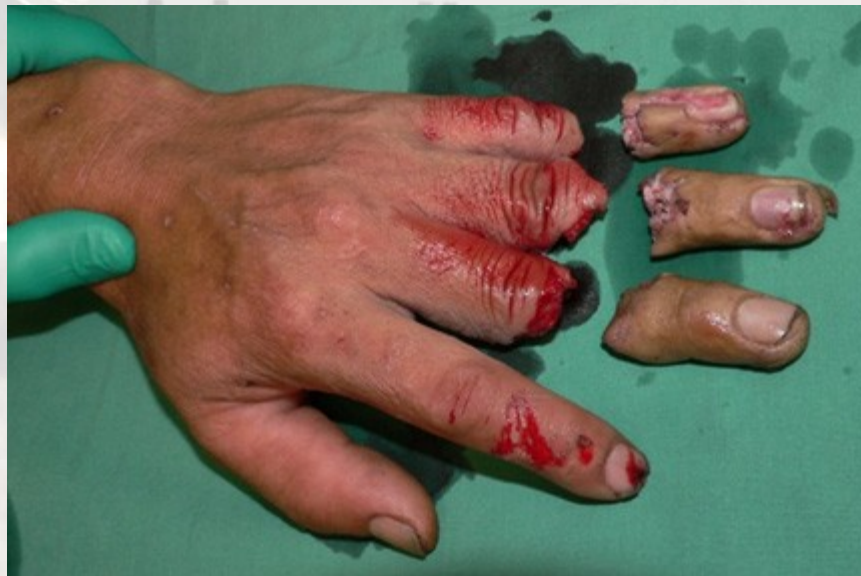Types of wounds

Avulsion - In an avulsion, a portion of skin is torn. This can be partial, with a portion of skin remaining as a "flap." In a total avulsion, a body part is completely torn off.



Amputation

- Do not let the person to eat or drink- GA likely
- Shock possible
- Wrap the severed part into plastic bag , wrap in gauze and place on ice (into container or another plastic bag)
Never place the amputate directly on ice!



Wounds – first aid

- Assess vital functions – pulse, breathing, consciousness, skin colour
- Look for other injuries
- Prevent shock
- If the wound is bleeding severely, call 112.
- Minor cuts and puncture wounds can be treated at home. Take the following steps.

Wounds – first aid

- Wash your hands with soap to avoid infection.
- Wash the cut thoroughly with mild soap and water.
- Use direct pressure to stop the bleeding.
- Apply an antibacterial ointment.
- If the cut is likely to get dirty or be re-opened by friction, cover it (once the bleeding has stopped) with a bandage that will not stick to the injury

Wounds – first aid – punctures and small cuts

Wash your hands.

Use a stream of water for at least five minutes to rinse the puncture wound. Wash with soap.

Look (but DO NOT probe) for objects inside the wound.

If found, DO NOT remove - go to the emergency room.

If you cannot see anything inside the wound, but a piece of the object that caused the injury is missing, also seek medical attention.

Apply antibacterial ointment and a clean bandage.

Wounds – first aid – DO NOT

DO NOT assume that a minor wound is clean because you can't see dirt or debris inside. Wash it.

DO NOT breathe on an open wound.

DO NOT try to clean a major wound, especially after the bleeding is under control.

DO NOT remove a long or deeply embedded object. Seek medical attention.

DO NOT probe or pick debris from a wound. Seek medical attention.

DO NOT push exposed body parts back in. Cover them with clean material until medical help arrives.

Wounds – call emergency

The bleeding is **severe**, spurting, or cannot be stopped (for example, after 15 minutes of pressure).

The person is seriously **injured**.

The **wound is large or deep**, even if the bleeding is not severe.

You think the wound might benefit from stitches (the cut is more than a quarter inch deep, on the face, or reaches bone).

The person has been **bitten** by a human or animal.

Wounds – call emergency

A cut or puncture is caused by a **fishhook or rusty object**.

You step on a **nail** or other similar object

An object or debris is **embedded** -- DO NOT remove yourself.

The wound shows **signs of infection**

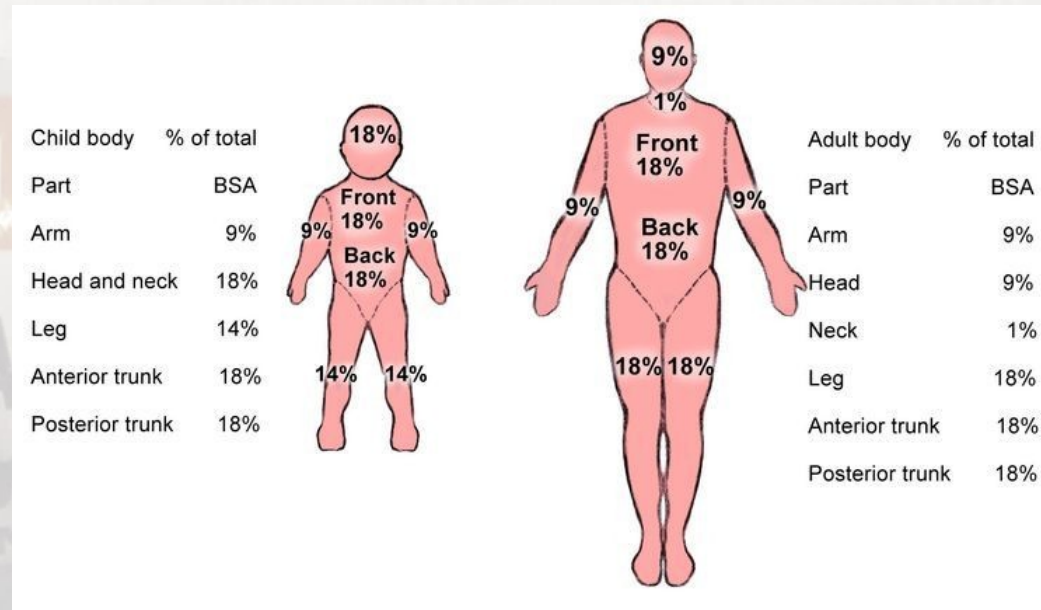
warmth, redness in the area, a painful or throbbing sensation, fever, swelling, or pus-like drainage

You have not had a tetanus shot within the last 10 years.

Burns

A burn can be caused by heat (flames, hot grease, or boiling water), the sun (solar radiation), chemicals or electricity.

Size – rule of 9
3 degree burns

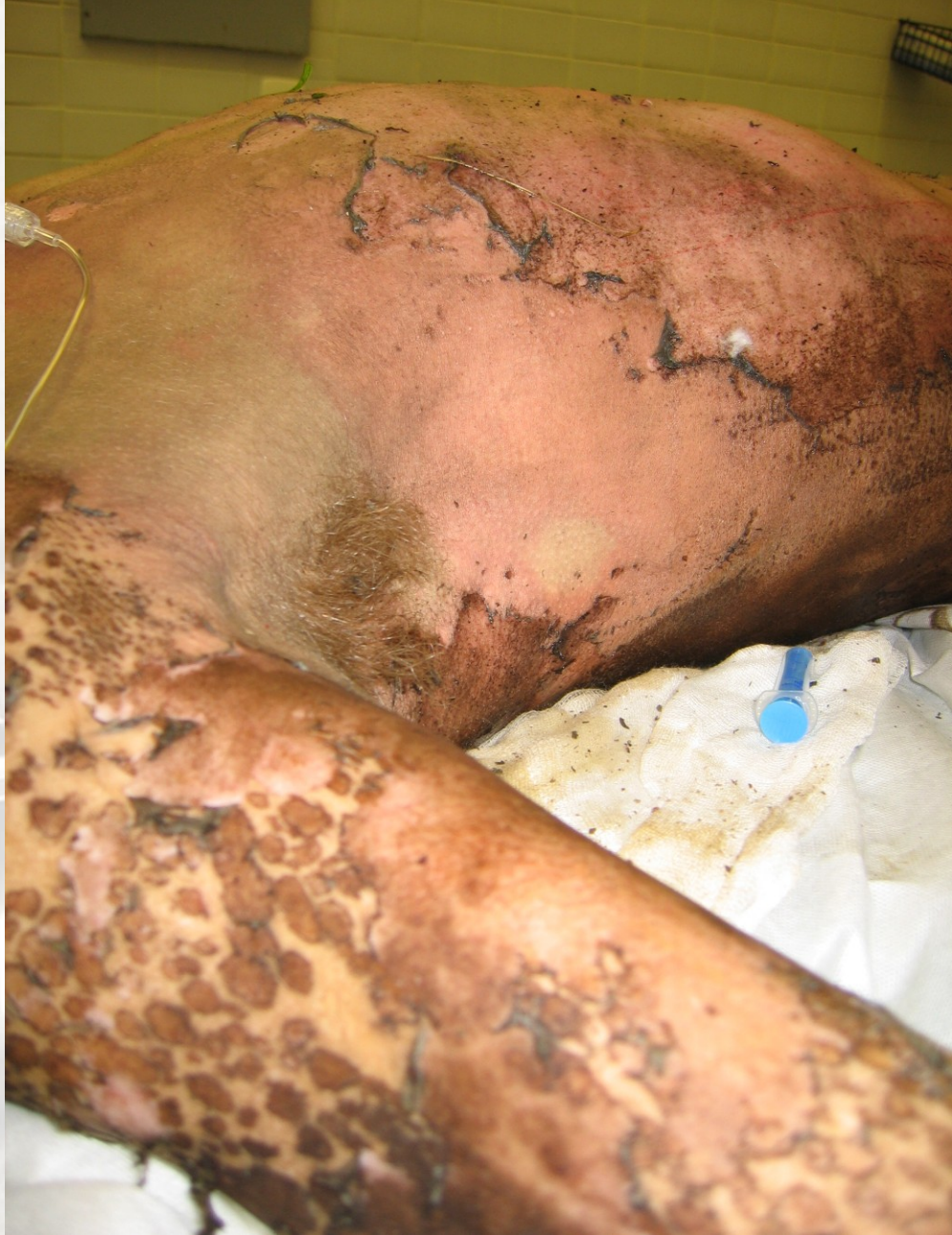

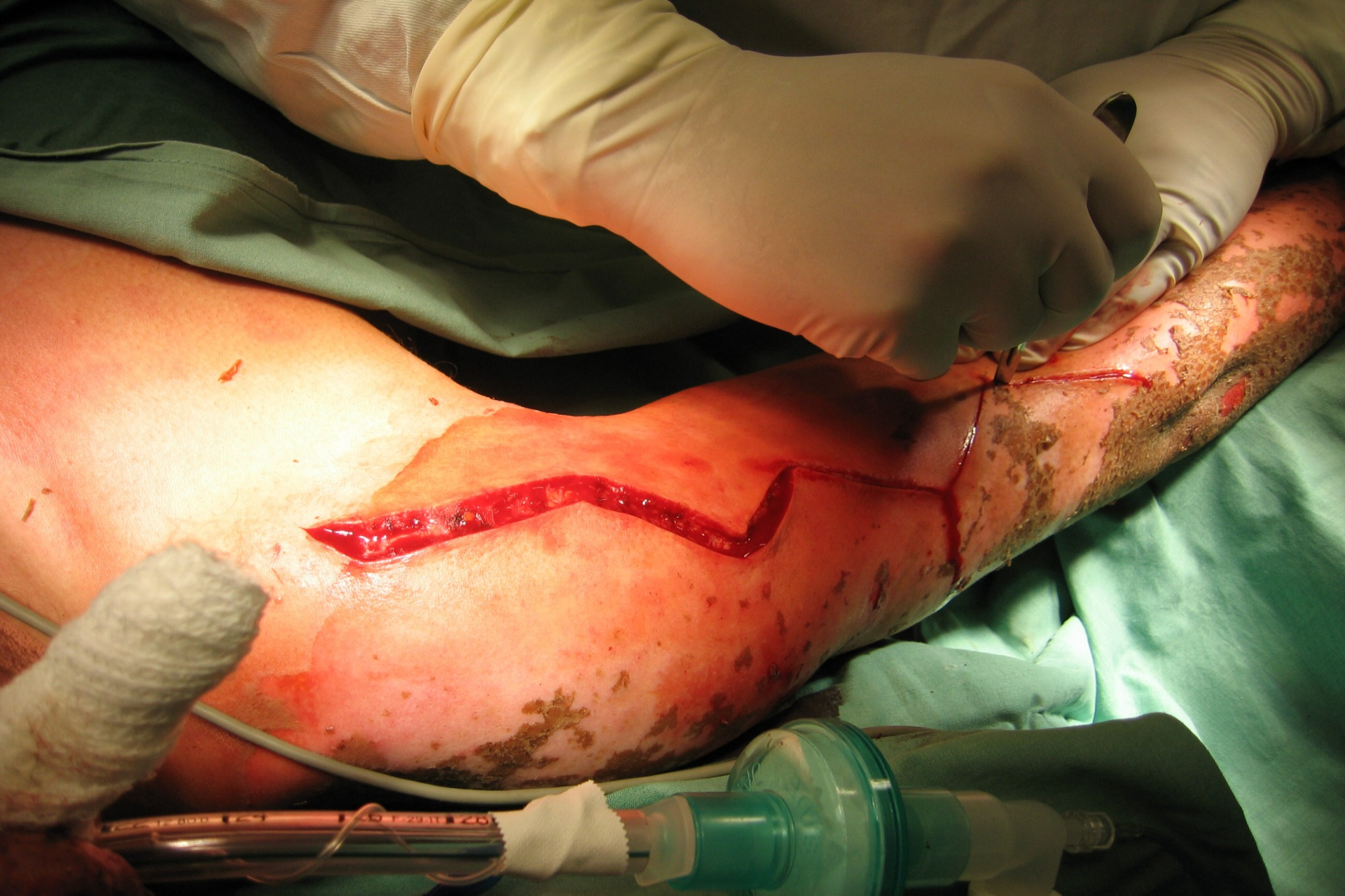Location – complicated – perineum, hands, face, joints, airways

Age – less than 2 years and elderly person (over 60)

Burns – first aid

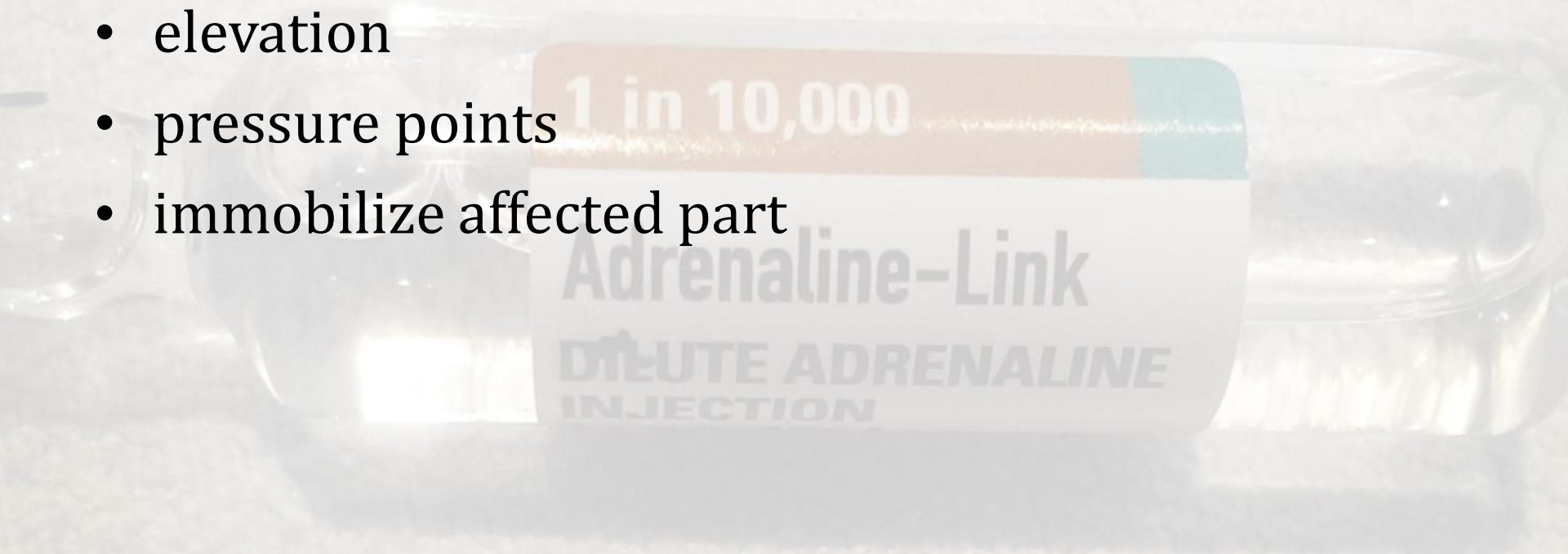
- General assessment – vital signs
- Cooling – at least 10 min running water –tepid, not ice cold
 - no more than 5 % BSA
 - not in shocked patients
- Cover the burn – sterile dressing or cling film
- **Do not** rupture blisters





External bleeding – first aid

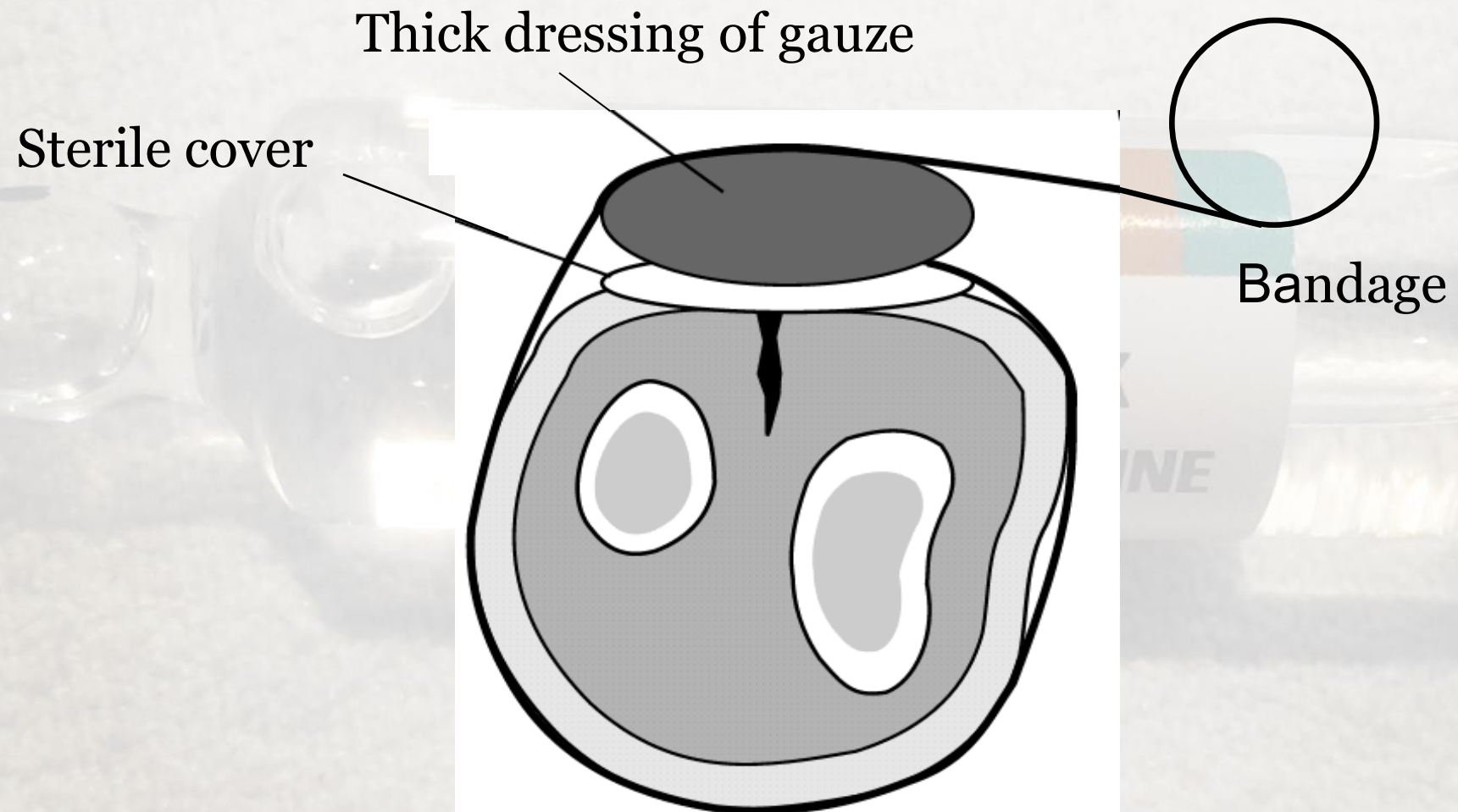
- direct pressure on the wound
- elevation
- pressure points
- immobilize affected part



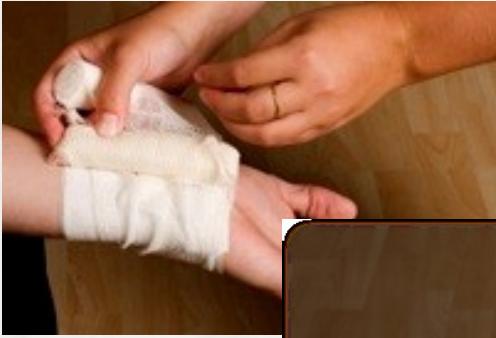Using Direct Pressure to Control Bleeding

1. Clean dressing over the wound and press firmly.
2. Use a pressure bandage to maintain pressure on the dressing.
3. Tie the ends of the bandage over the wound with a bow instead of a knot. The bow allows the bandage to be loosened later to reduce the pressure if the extremity becomes numb or turns blue. A bow also allows the wound to be checked for infection. Then, the bandage can be retied, saving time and supplies.

Arterial bleed - pressure dressing



Pressure dressing



3 layers:

-cover

-pressure

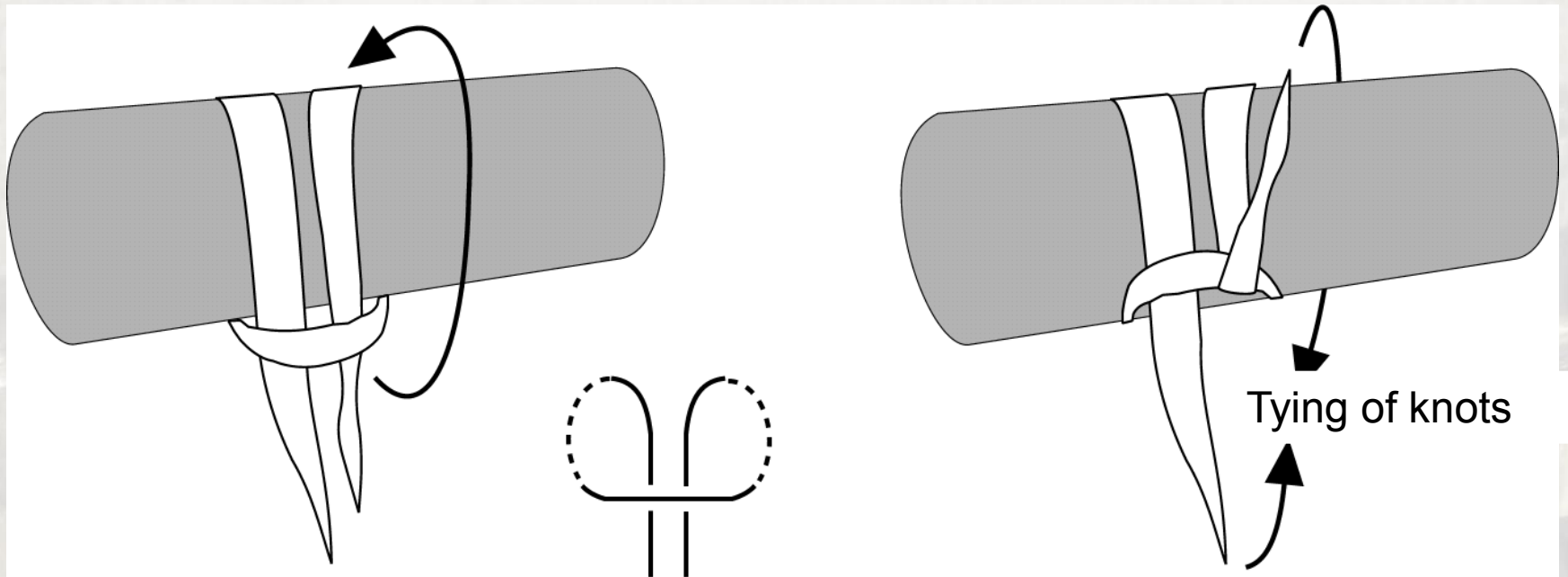
-fixation

The pressure may be increased by twisting the bandage over the pressure layer

Severe bleeding – when to apply tourniquet

- In case direct compression is not possible/effective in the wound
- Massive bleeding from large vessel-arteria
- Amputation
- Poisoned wound
- Provisional solution in major incidents

Application of tourniquet

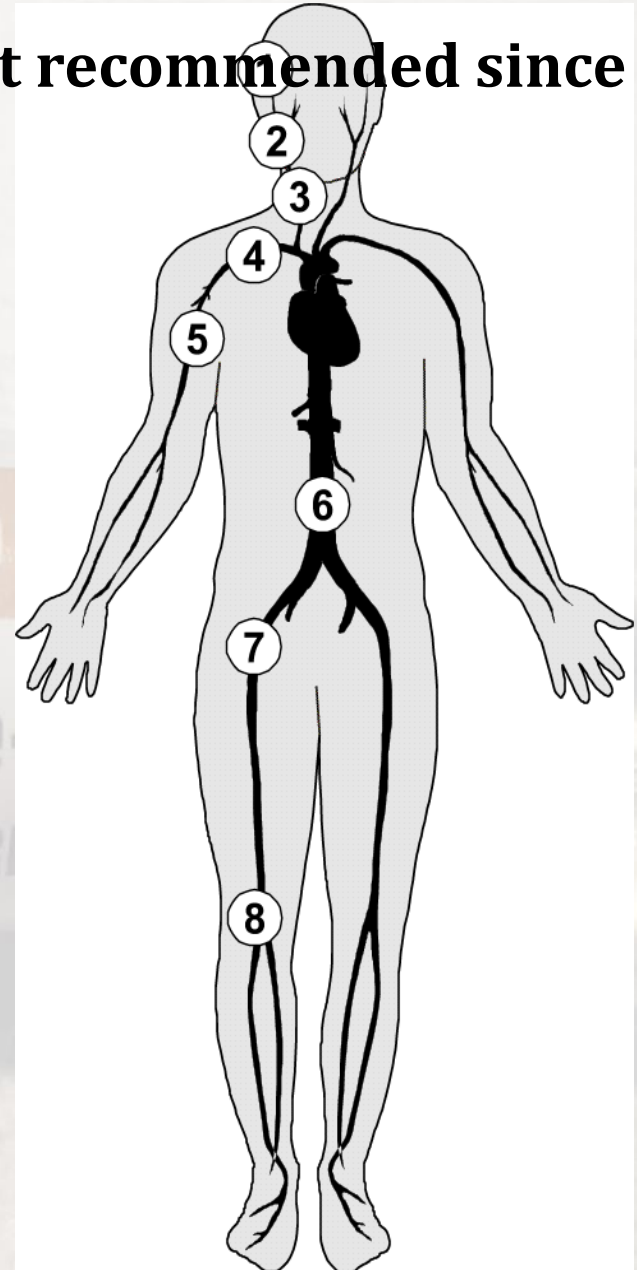


Application of tourniquet

- Width at least 5 cm
- Do not apply at the joints area
- Immobilize (e.g.sling)
- Do not remove till definitive treatment
- Risk of ischemic injury to the limb – when applied over 2 hours

Pressure points - not recommended since 2015

- a.temporalis
- a.facialis
- a.carotis communis
- a.subclavia
- a.brachialis
- aorta abdominalis
- a. femoralis
- a.poplitea



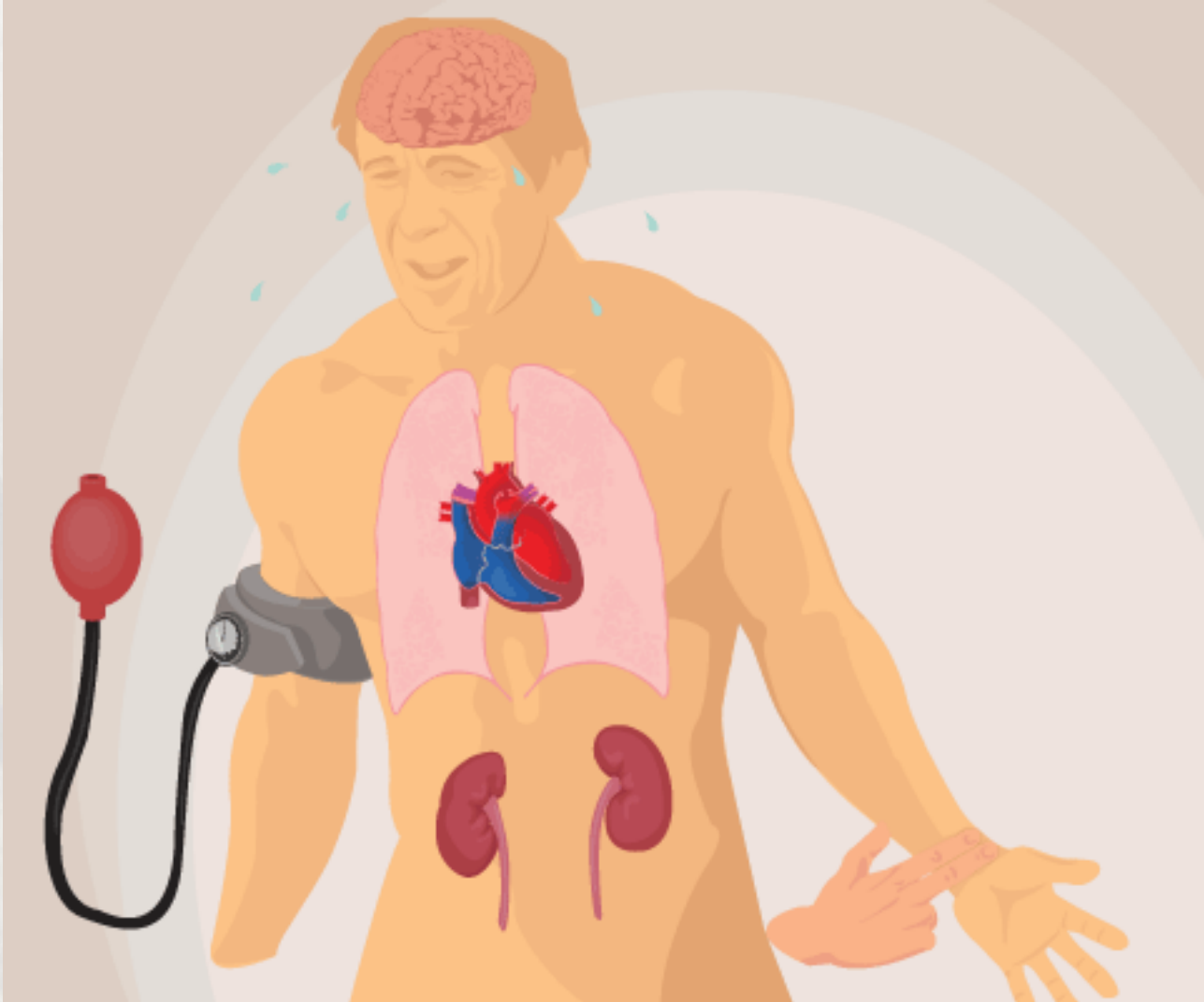
Internal bleeding

- Difficult to recognize
- Often as a result of blunt injury to the chest or abdomen (spleen, liver, kidneys, major vessel injury)

Internal bleeding

Think about when

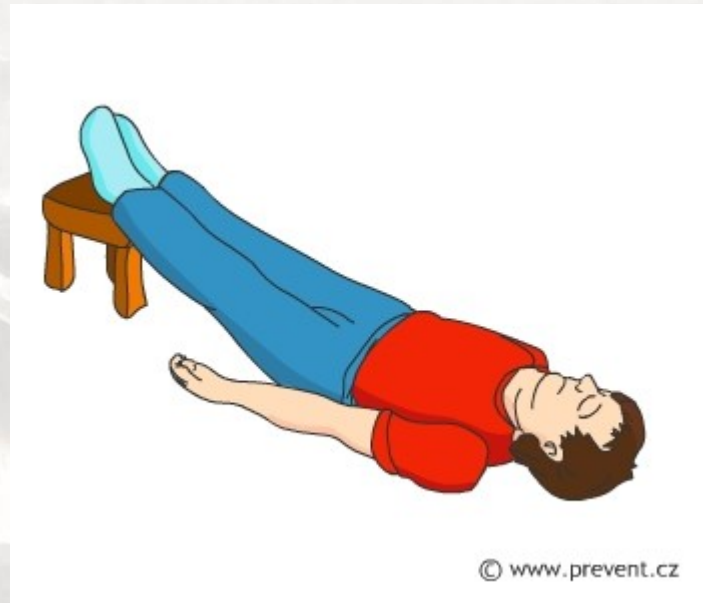- Pale and clammy, sweaty
- Nausea, vomiting
- Dizziness, fainty
- Rapid shallow breathing
- Fast weak pulse
- Minimal/no urine production
- Thirst



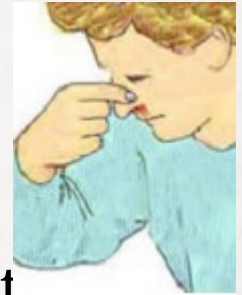
Internal bleeding – first aid

- Keep calm
- Treat any obvious cause of shock
- Anti shock position – improves backflow of blood to vital organs
- Loosen tight clothing, insulate from cold surface, keep in warm
- Do not let eat or drink
- Monitor and record vital signs till the EMS arrives
- Anti shock position – improves backflow of blood to vital organs

Trendelenburg position



Nosebleed



Rupture of blood vessels (sneezing, picking, blowing the nose)


High blood pressure

Till head forward – allow the blood to drain

Breathe through mouth

Pinch the soft part of the nose, keep pinching (10 min)

After 10 min. release the pressure



Bleeding from the ear

Connected with trauma

Half sitting position

Head tilted to the injured side – allow blood to drain away

Sterile dressing or a clean pad in place on the ear

Send to hospital

1 in 10,000

Adrenaline-Link

DUPLICATE ADRENALINE
INJECTION



Bleeding from the mouth

Cuts the tongue, lips

Dental extraction

Blood may be inhaled into the lungs!

Sitting position, head forward

Allow blood to drain from the mouth

Place a gauze pad over the wound, hold the pad and press on the wound for 10 min.

Knocked out adult tooth – place into sterile gauze moistened by water

Eye wound

Potentially serious

Pain and spasm of the eyelid

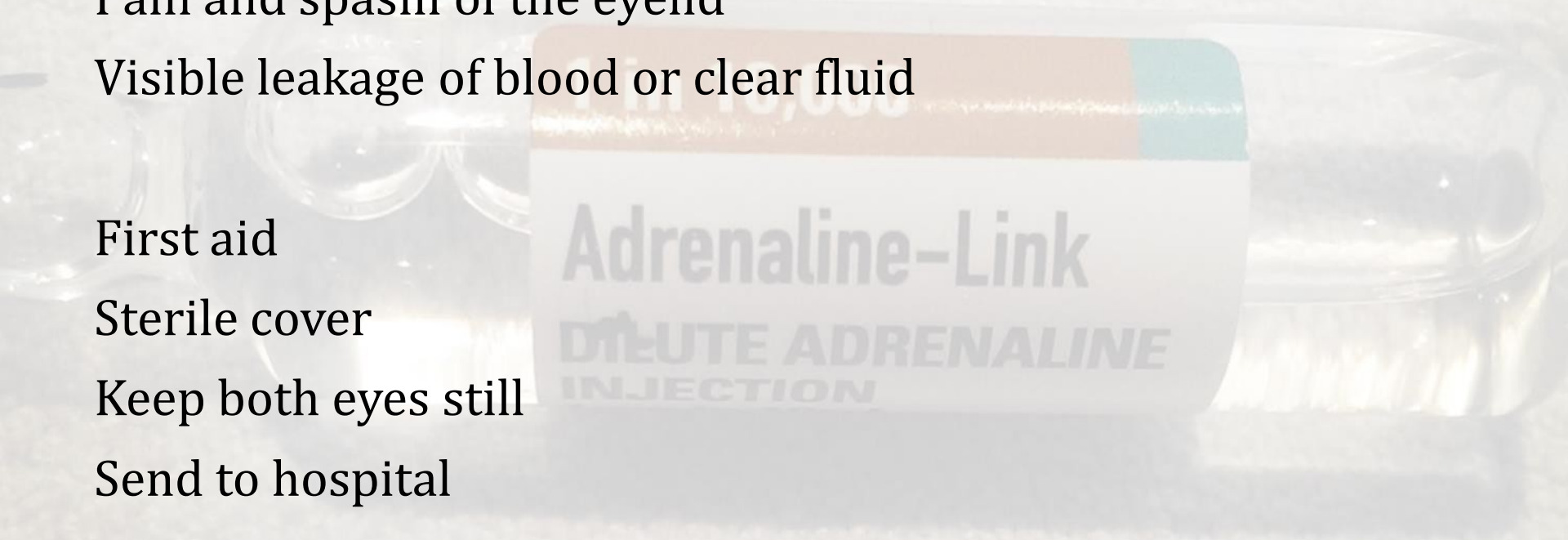
Visible leakage of blood or clear fluid

First aid

Sterile cover

Keep both eyes still

Send to hospital



Bandages techniques

- Calm and reassuring approach
- Facing the casualty
- Keep the bandaged part of the body all the time in the same position – if possible
- Width of the bandage – same or larger than the diameter of the bandaged part
- Start from the narrowest part

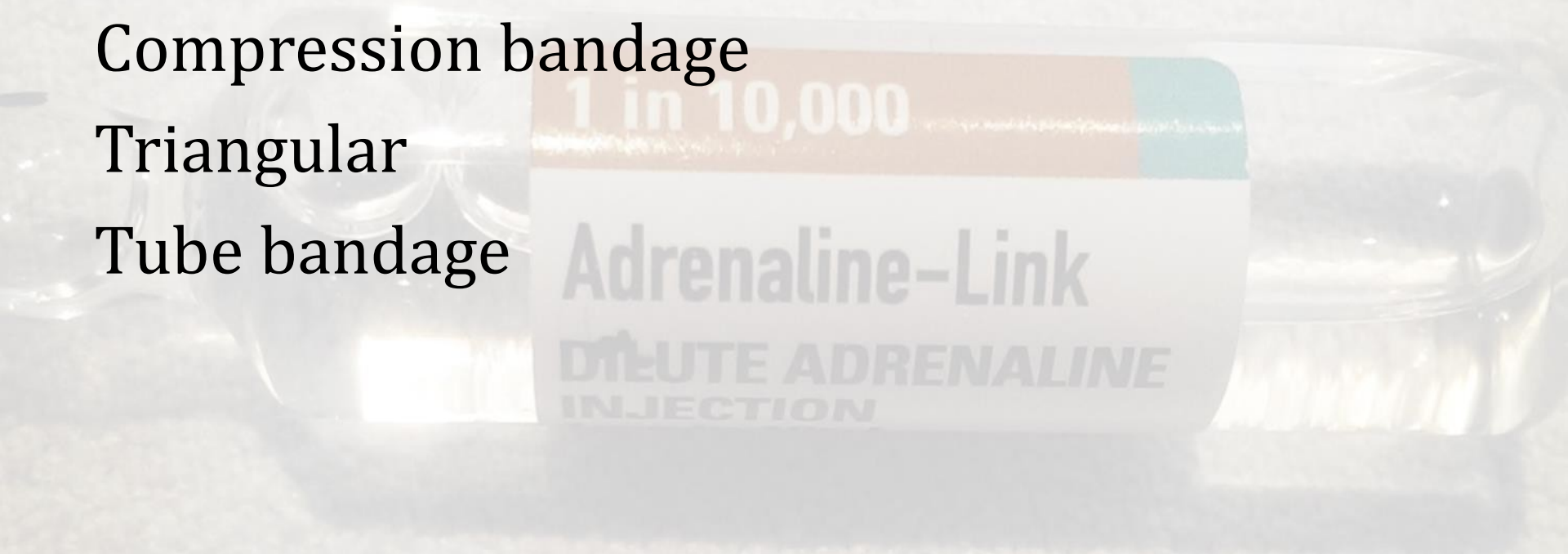
Types of bandages

Gauze bandage

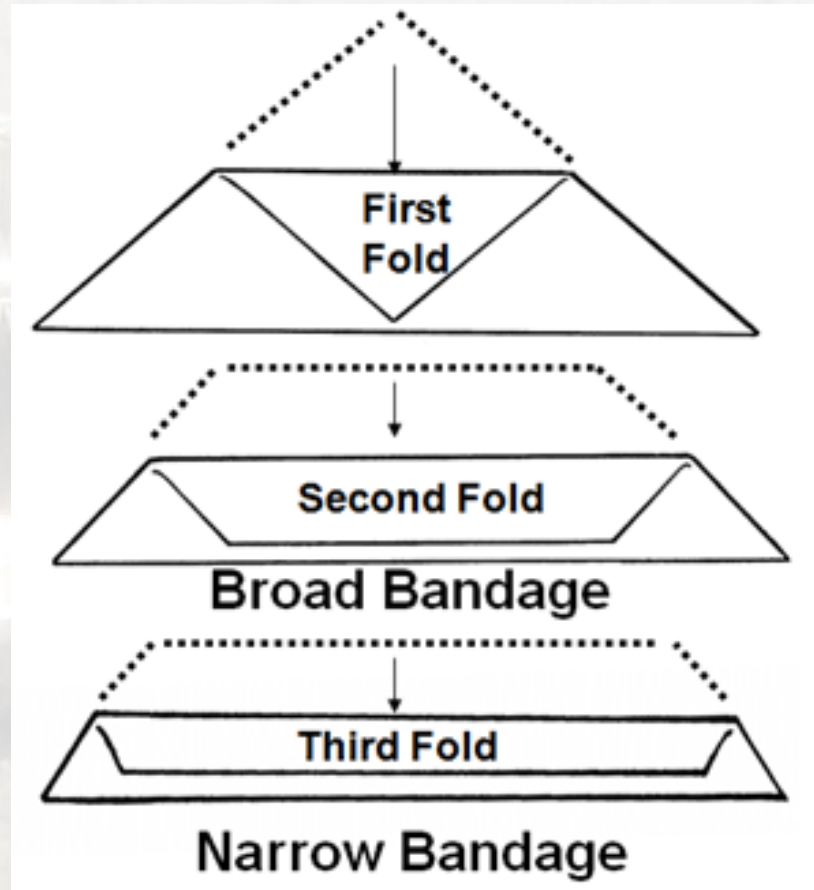
Compression bandage

Triangular

Tube bandage

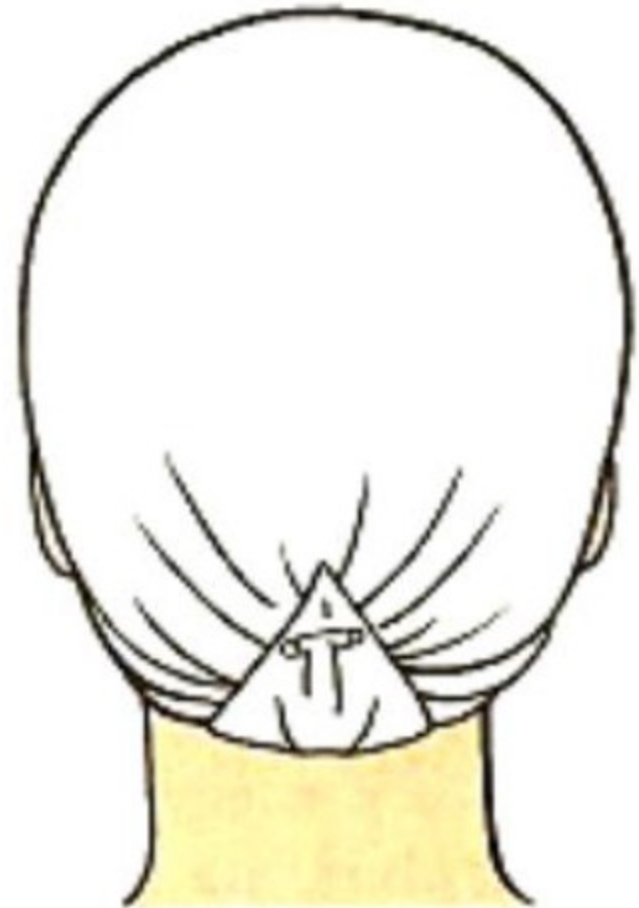
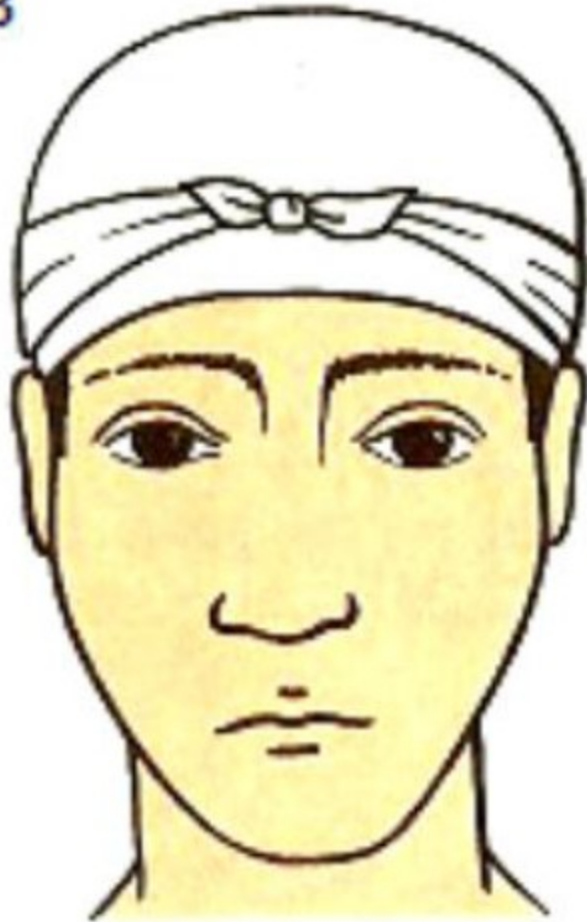

1. Triangular bandage



Head bandage using triangular bandage

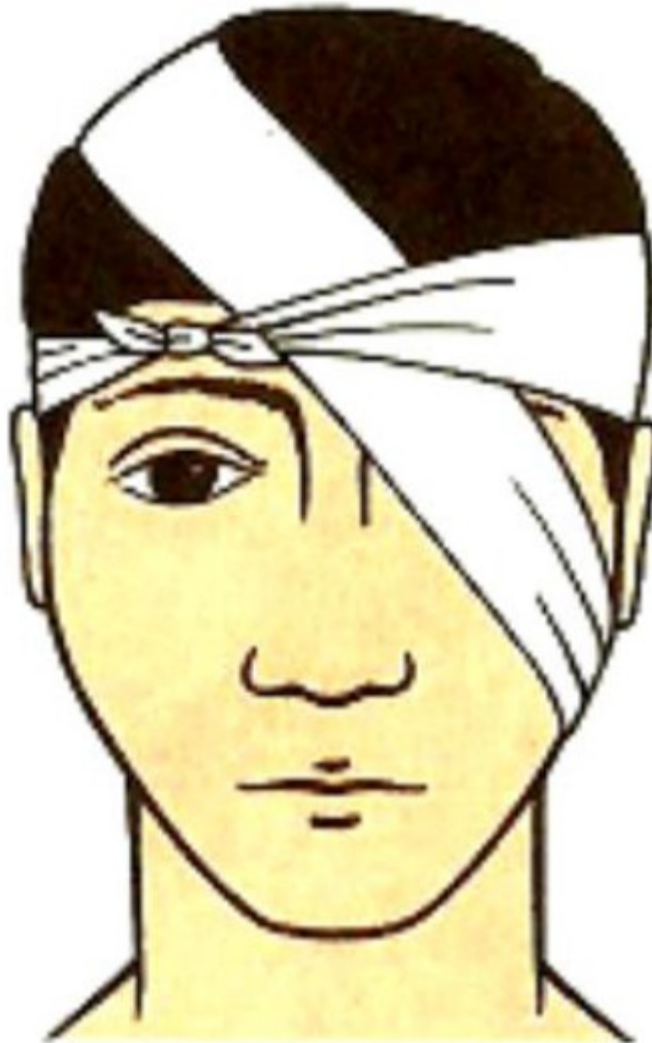3



1

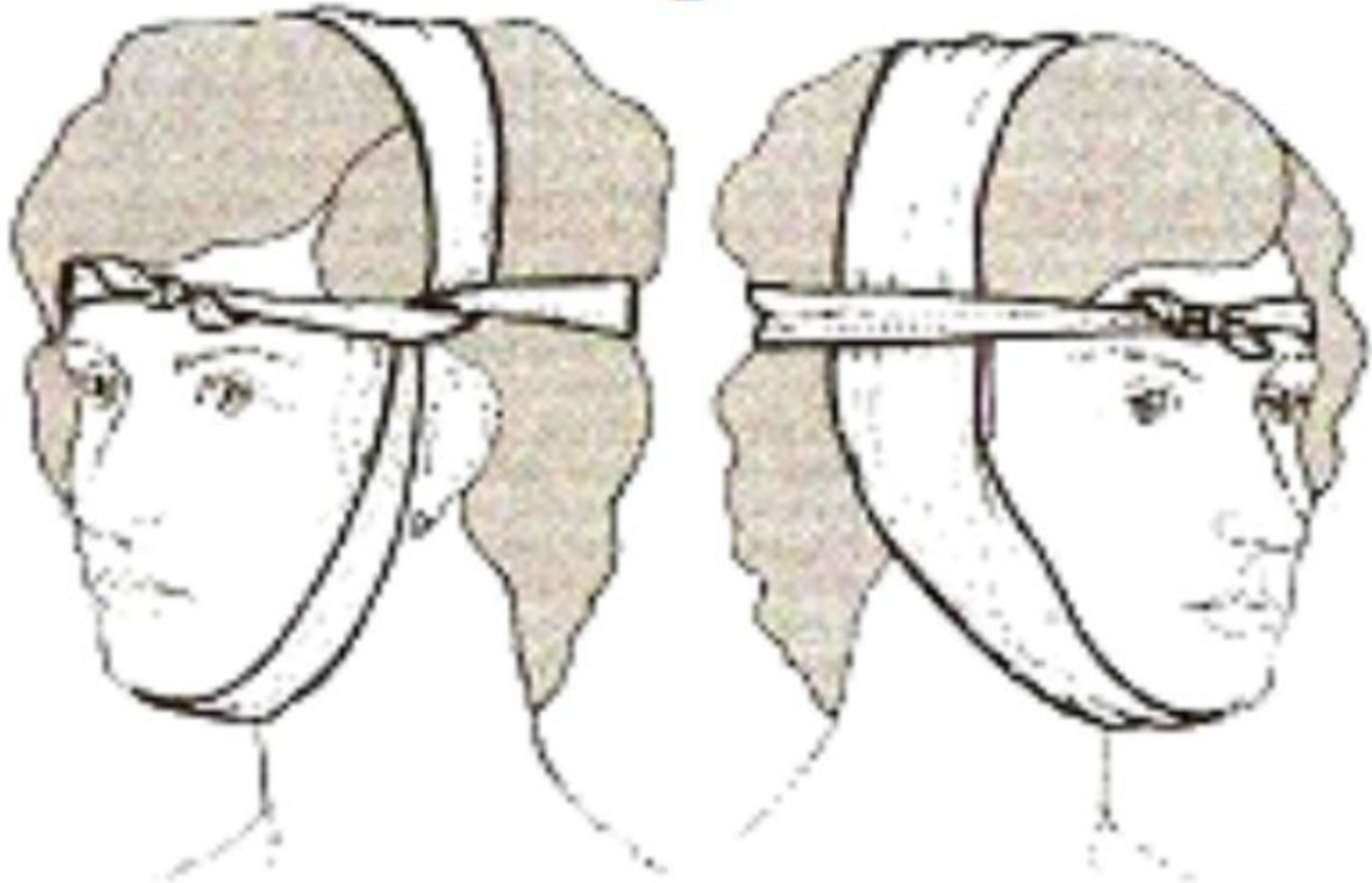
Bandage of the eye

4

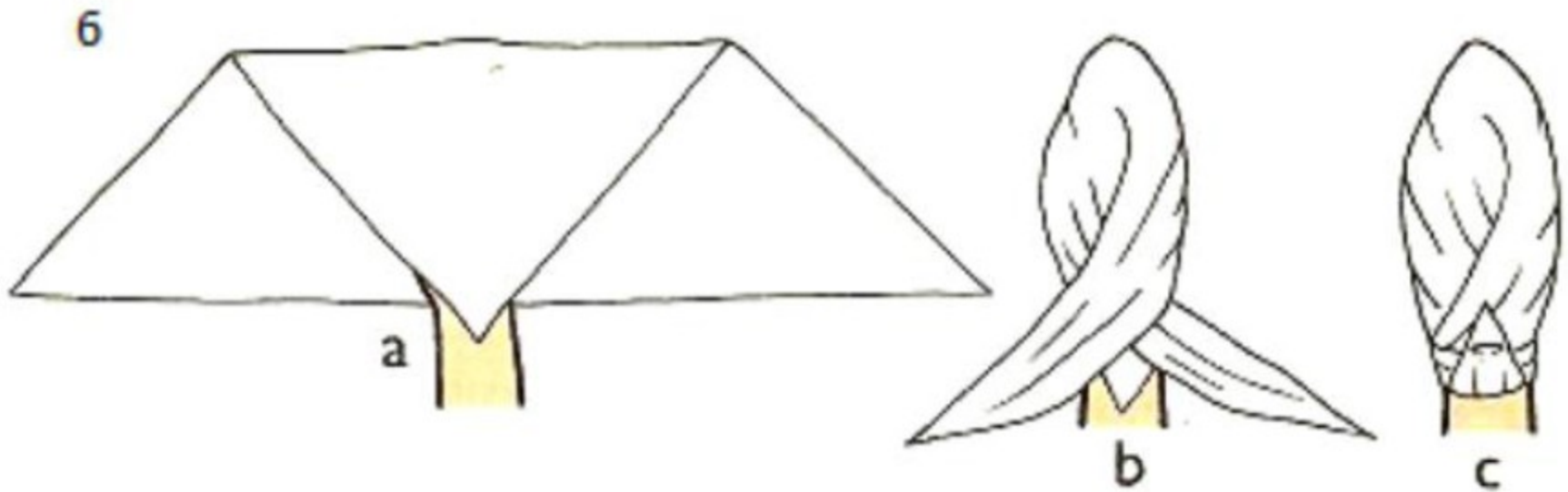


Bandage of the ear

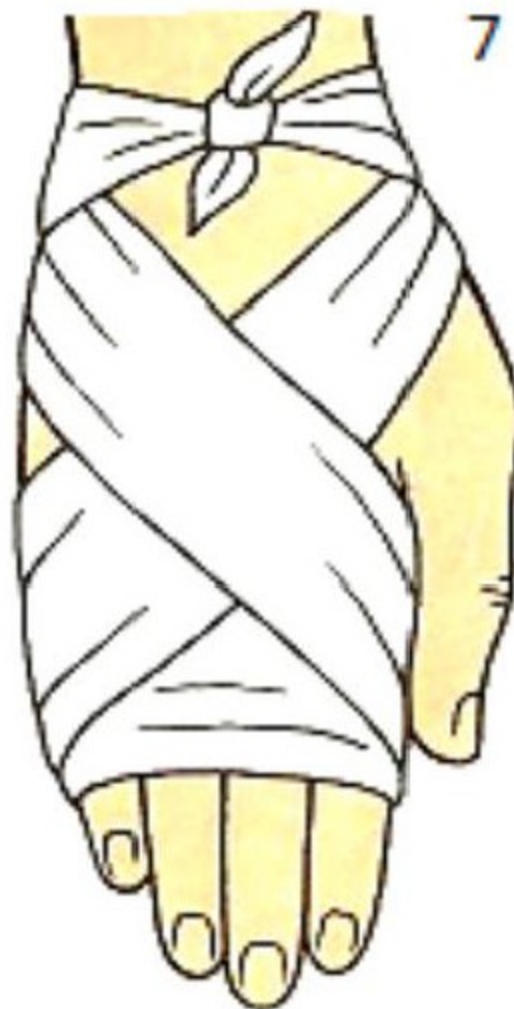5



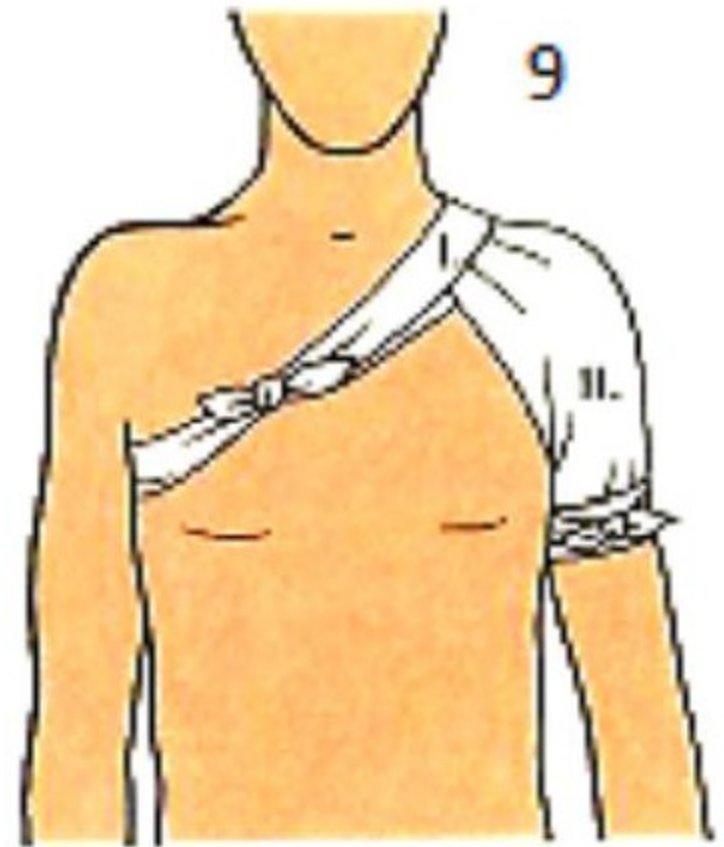
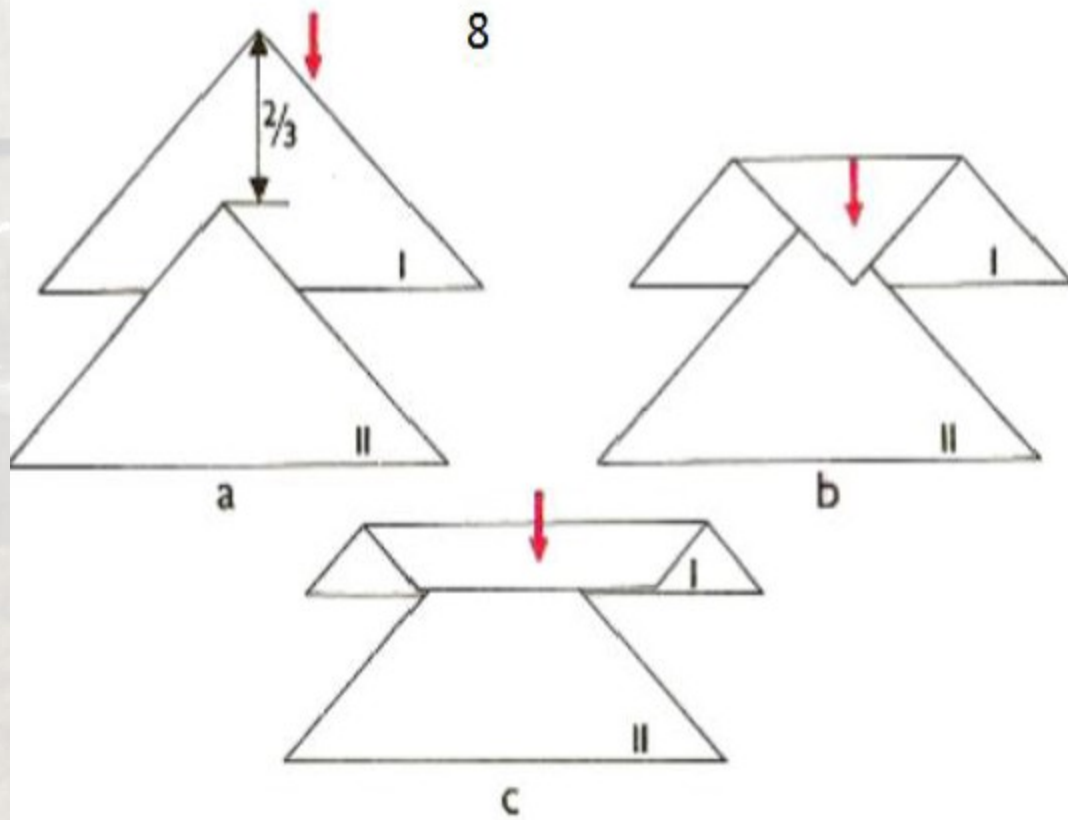
Triangular bandage of the hand



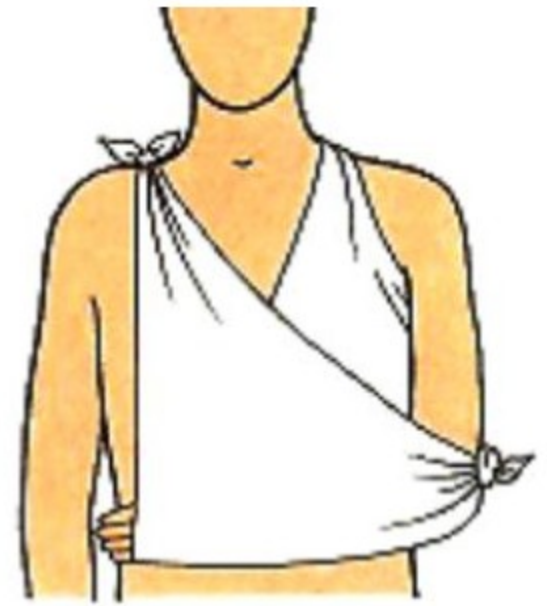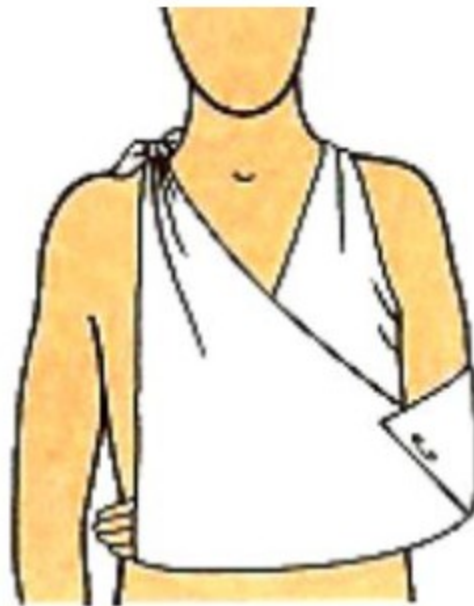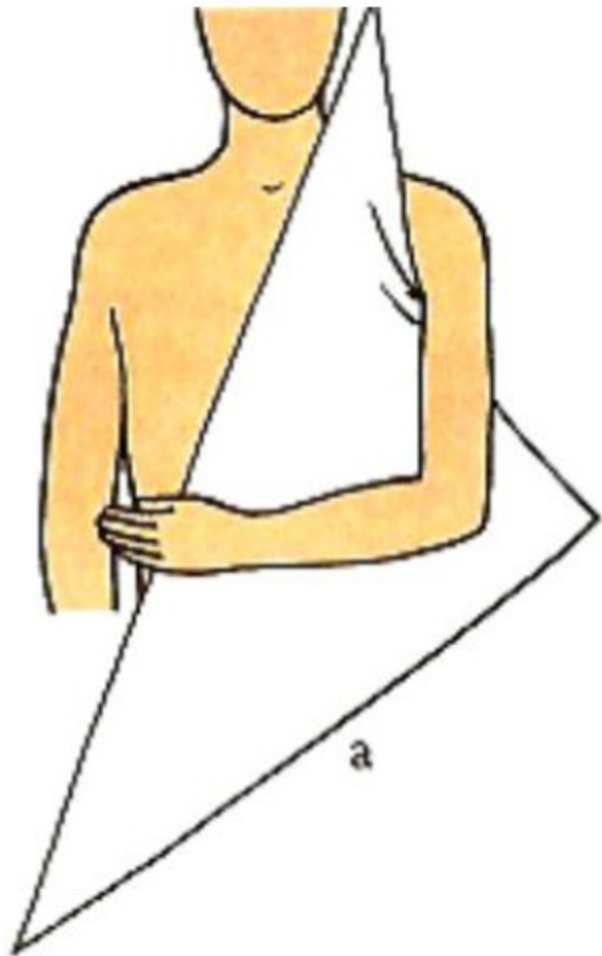Triangular bandage of the palm



Bandage of the shoulder



Sling

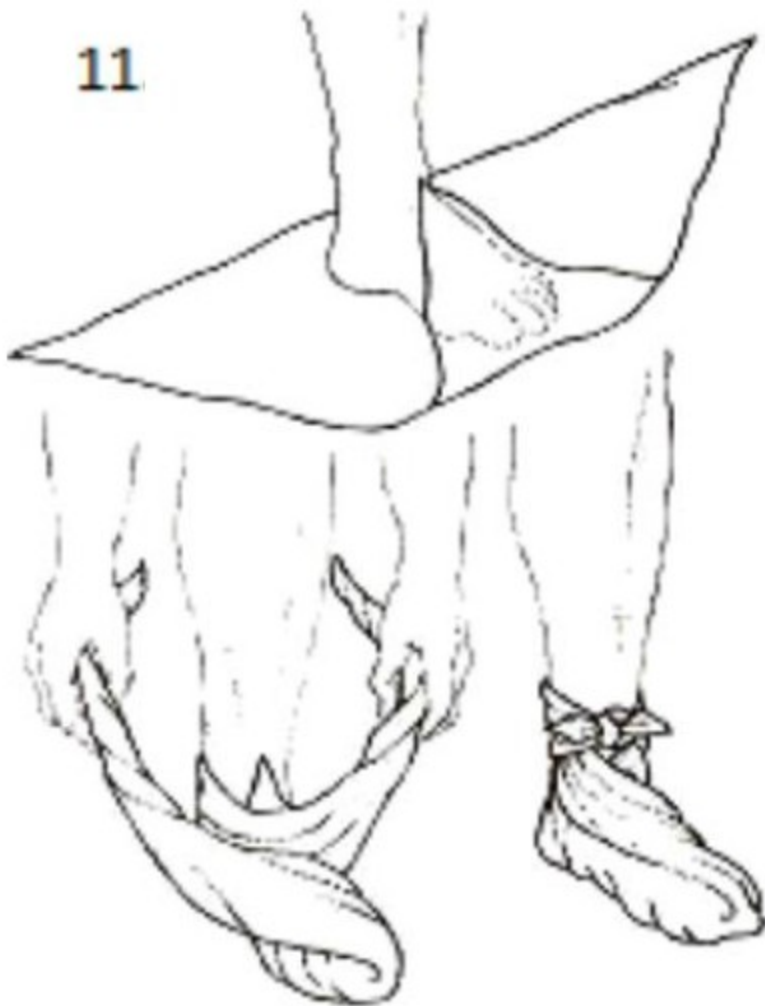


b

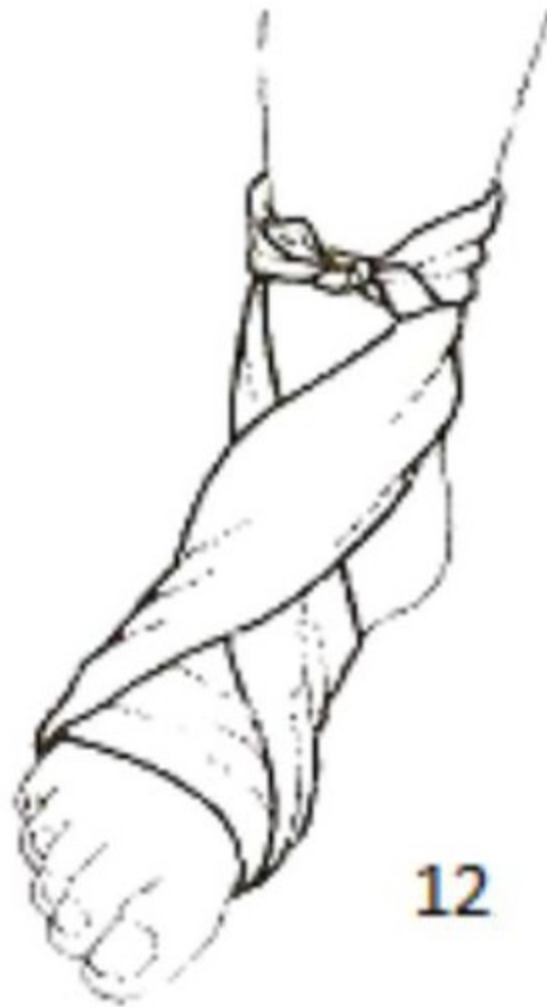c

Foot bandage

11

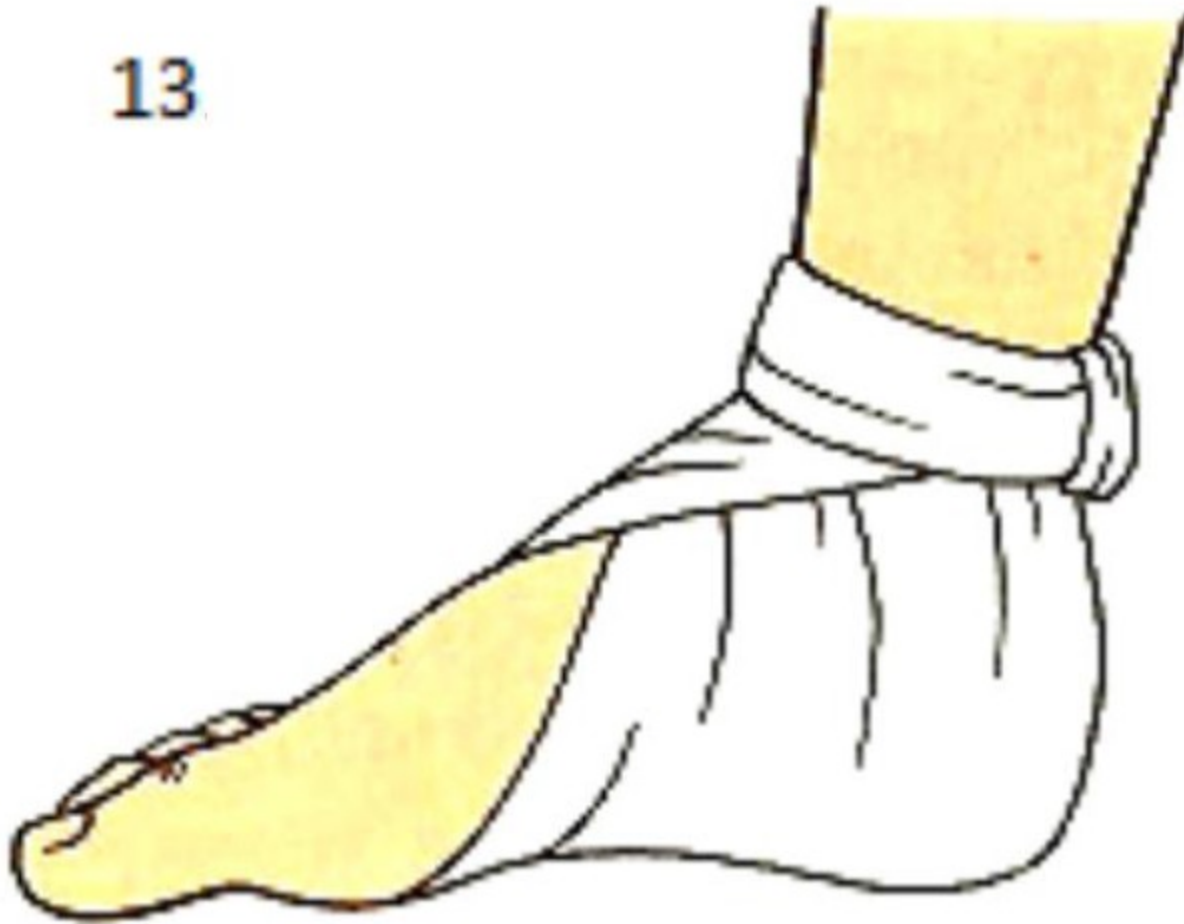

12

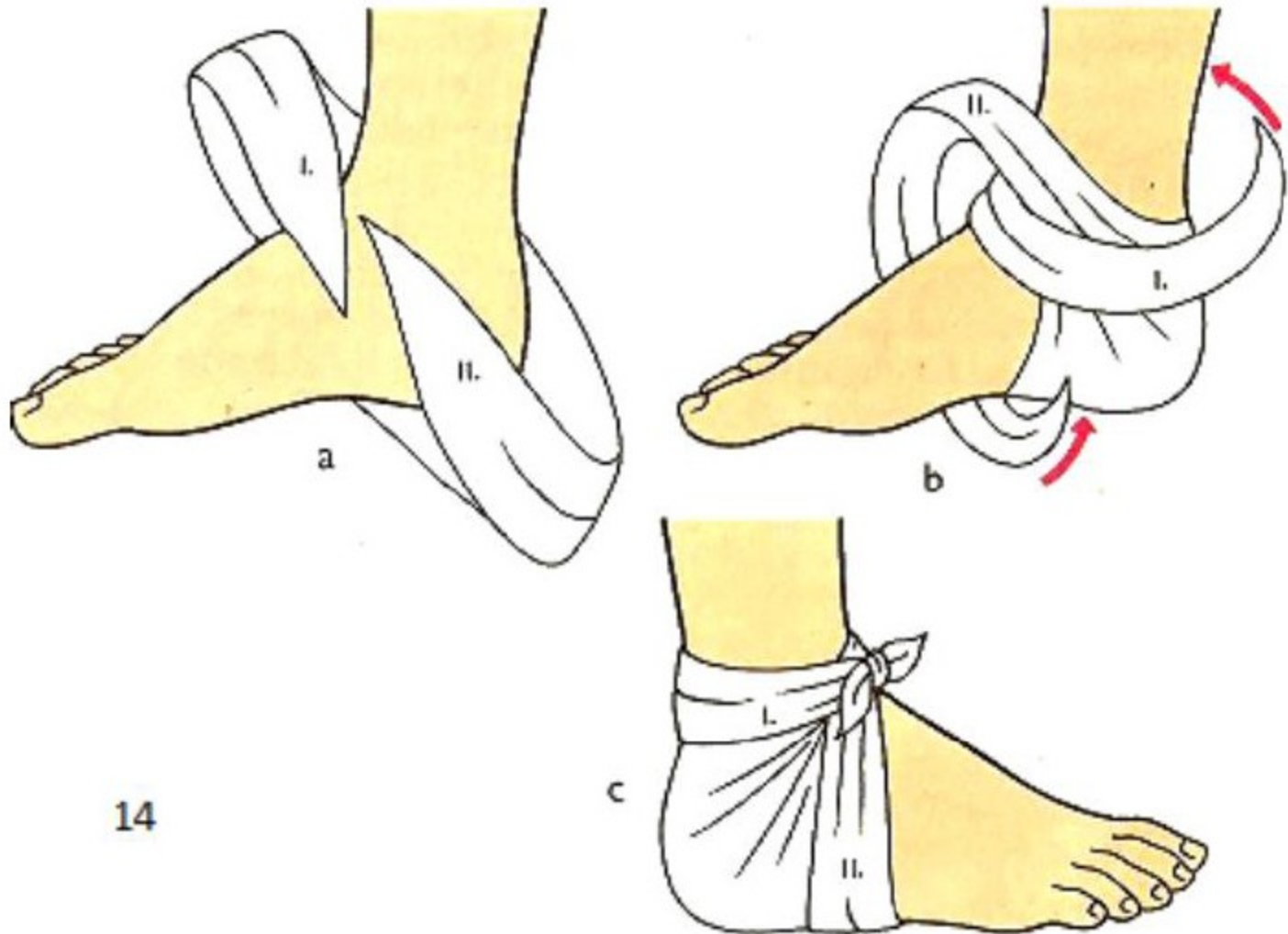


Heel bandage

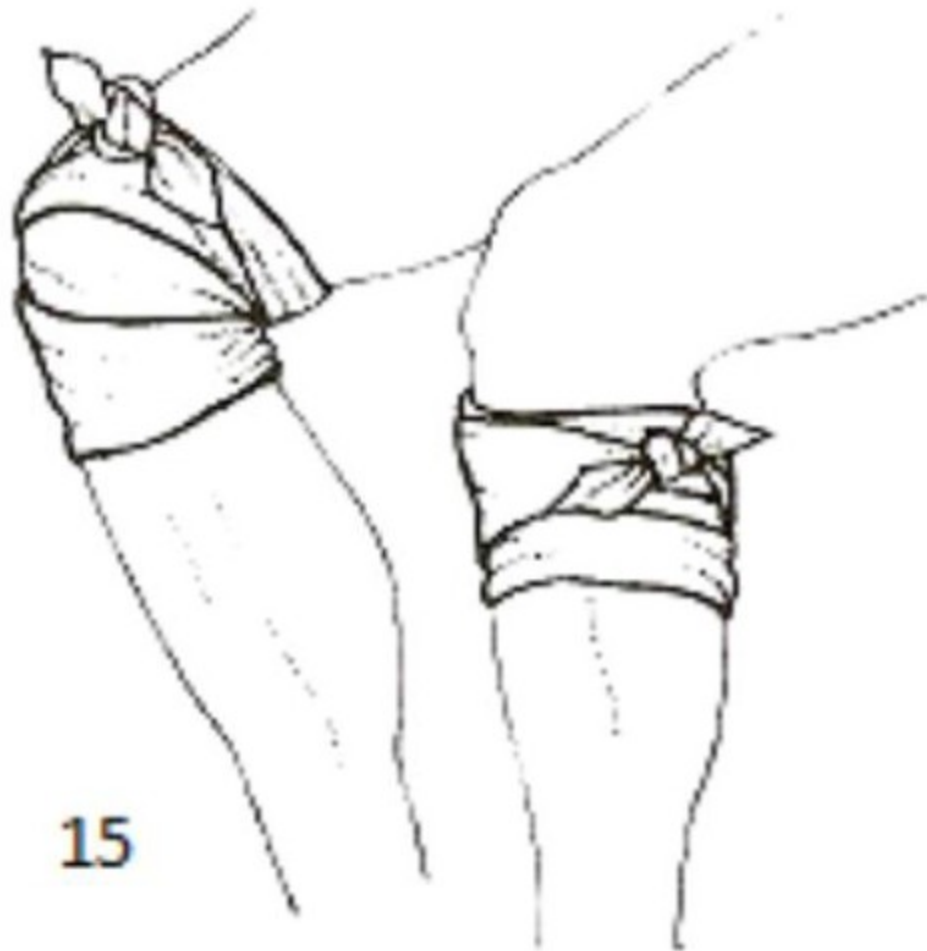
13



Ankle bandage

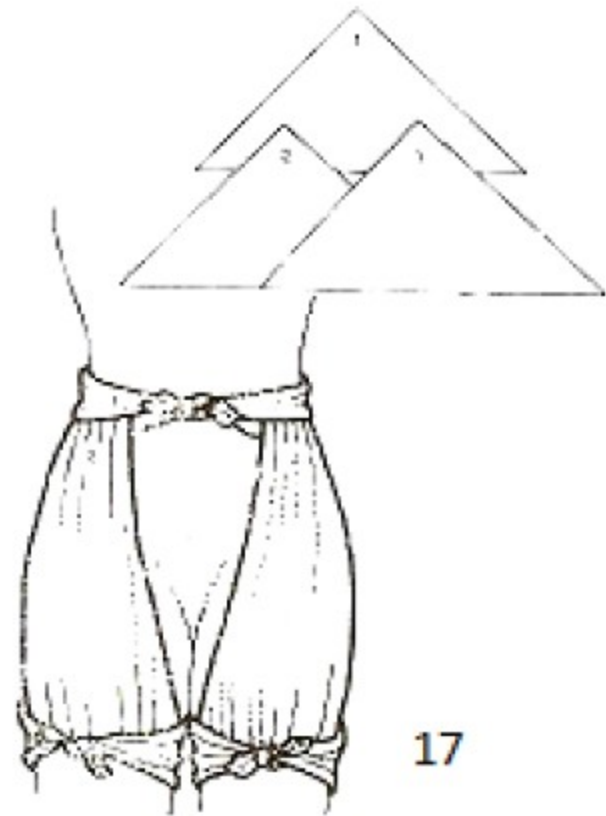
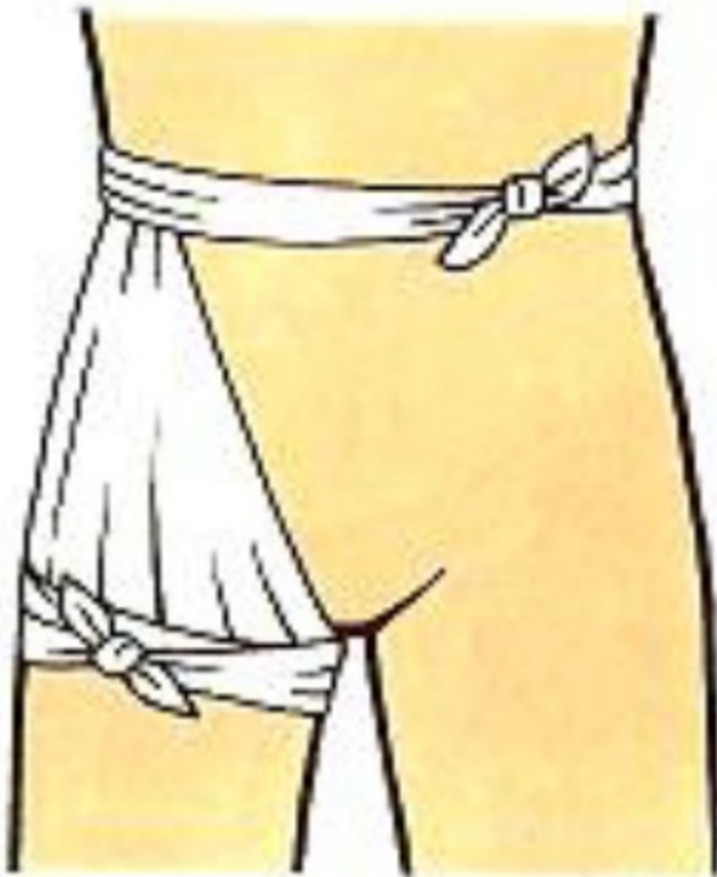


Knee bandage

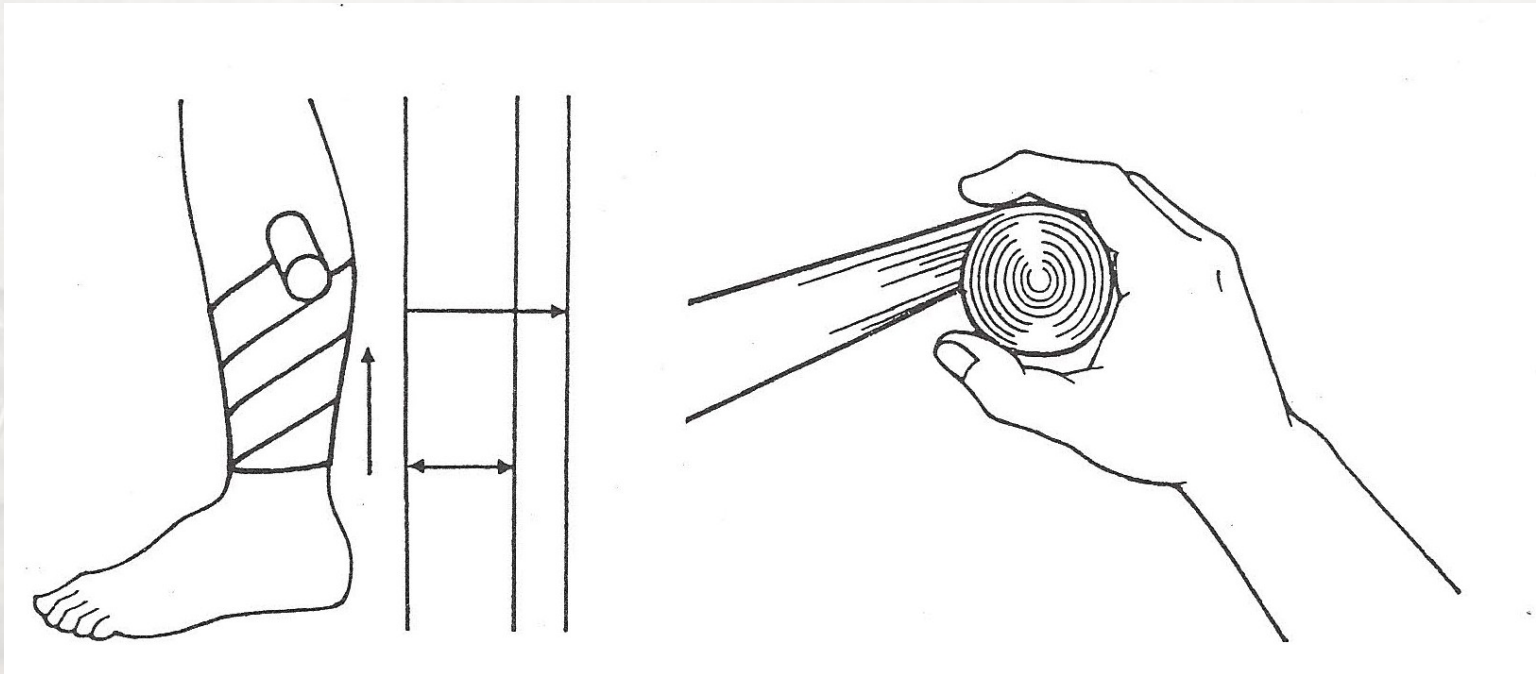


15

Hip bandage

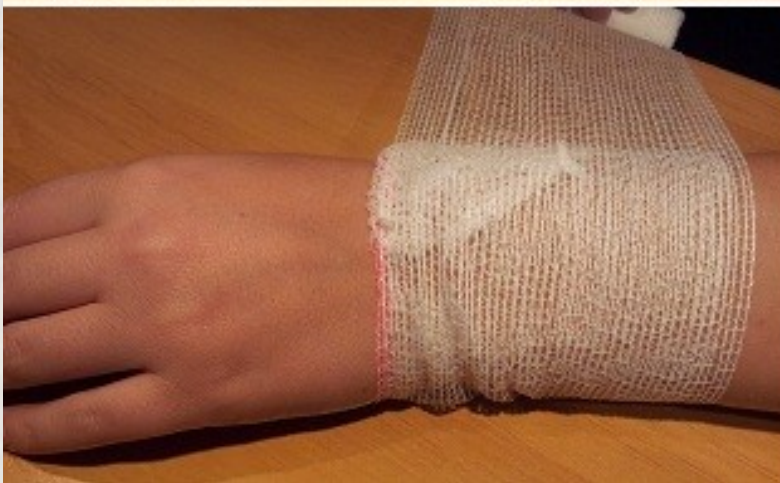
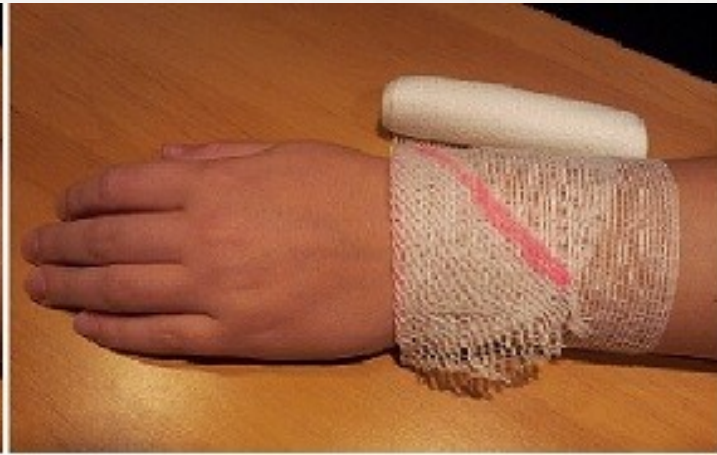
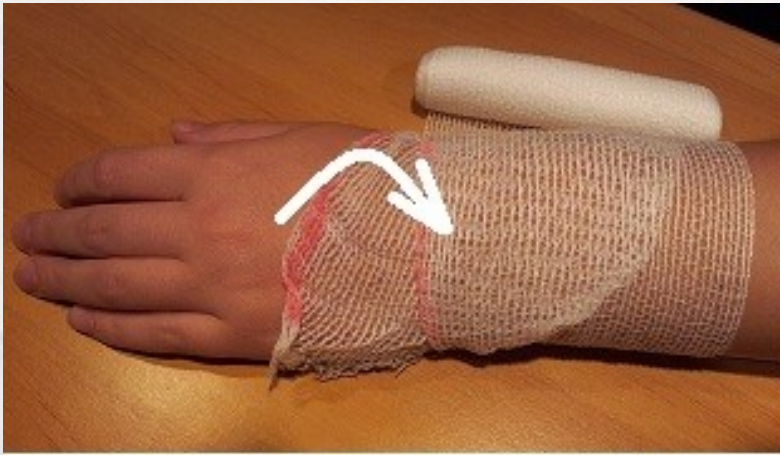2. Work with roller bandages



Hold the tightly rolled bandage with the 'head' of the bandage on top and wrap the 'tail' around the body part without unrolling more than a few centimetres at a time.

Locking turn to hold the start of the bandage securely under each following turn

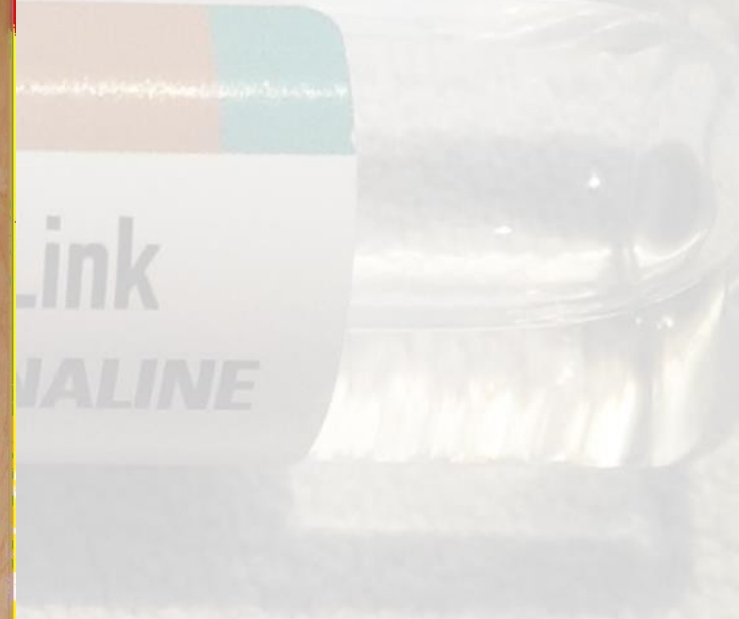
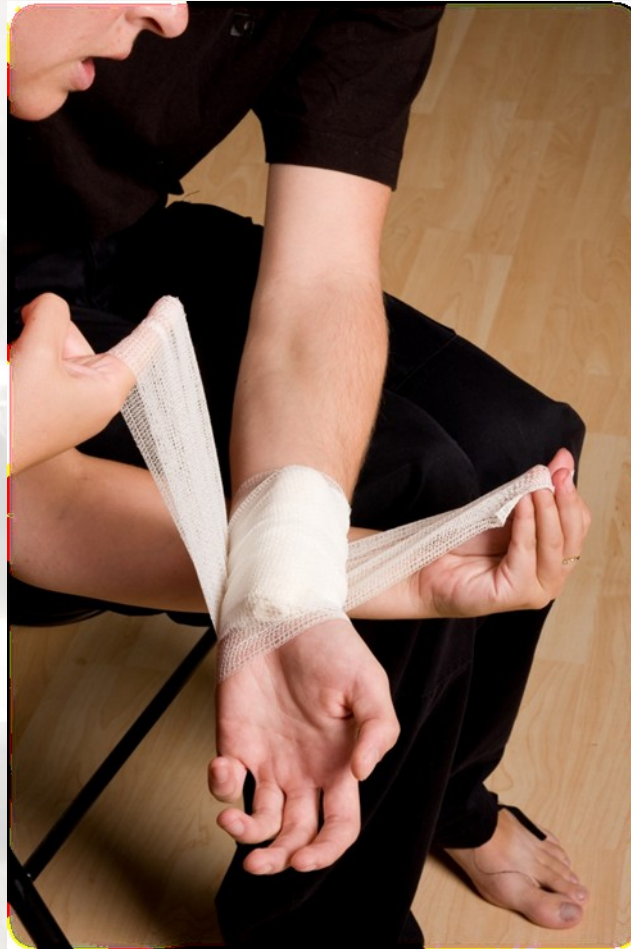
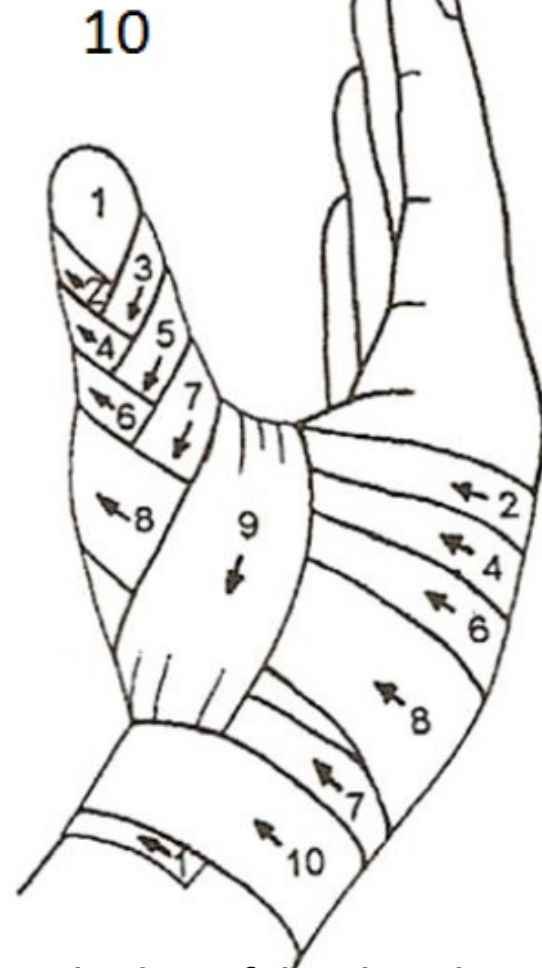
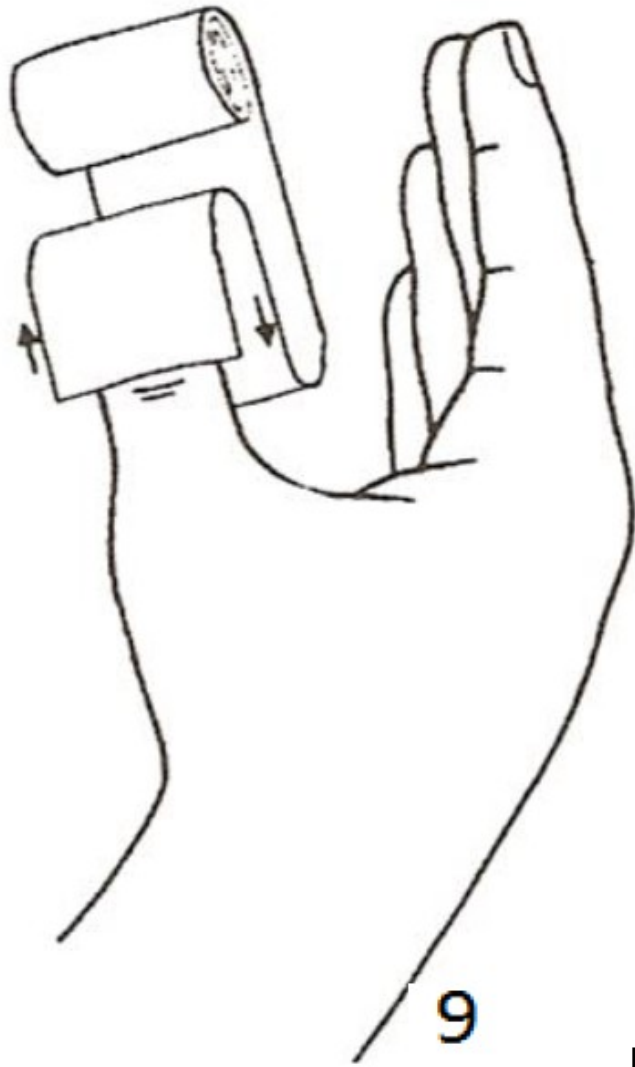
založením cípu
obinadla zabráníme
jeho nechtěnému
otáčení kolem
obvazované části těla

2. Work with roller bandages

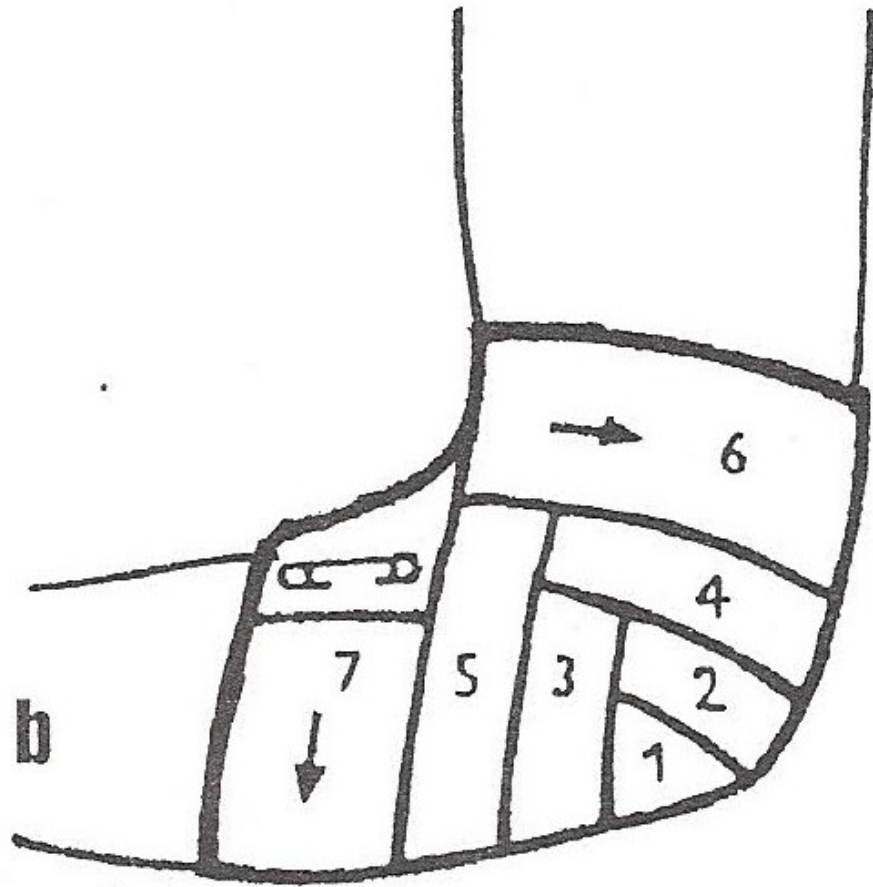
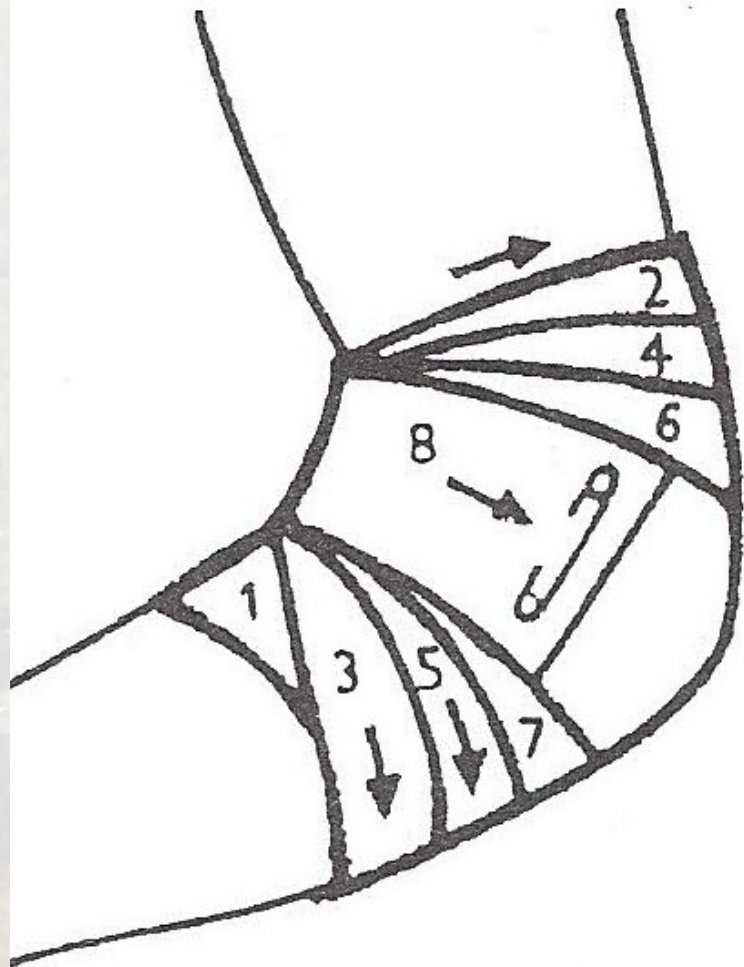
- Work **from the middle** of the body or limb in an outwards direction.
- Work **from the narrowest** part below the dressing and work upwards.
- Ensure that each turn **covers two-thirds** of the previous turn.
- Cover totally any dressing and padding used.
- Finish with a straight turn at the end of the bandage.
- **Secure the bandage** with a safety pin or adhesive tape. Metal clips are possible to use as well.

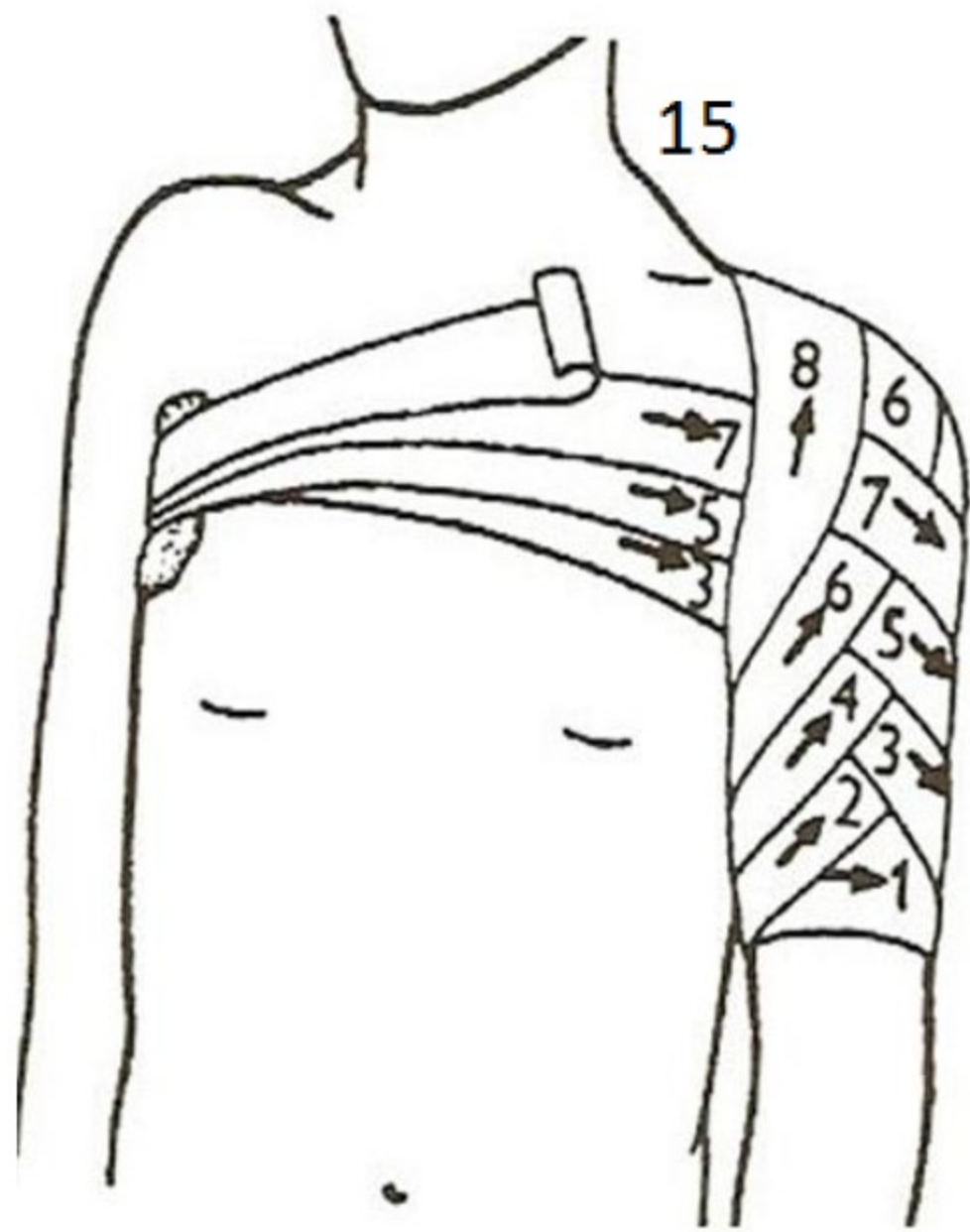
Ending without tearing...

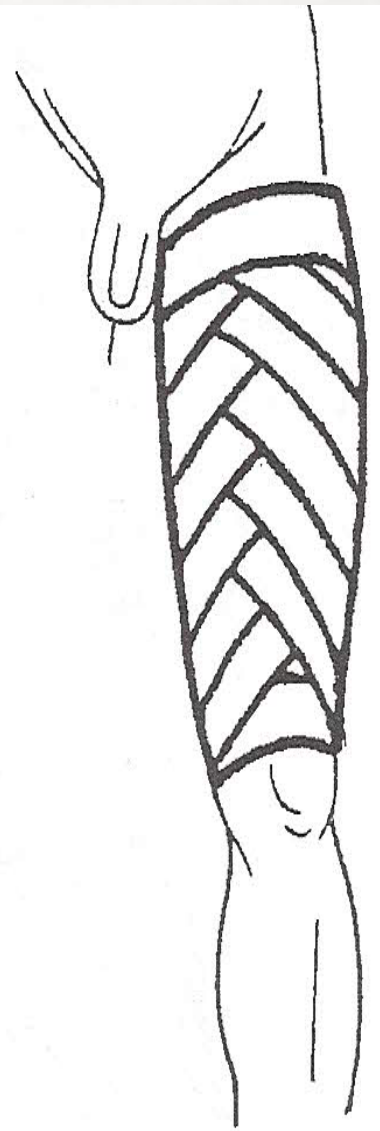
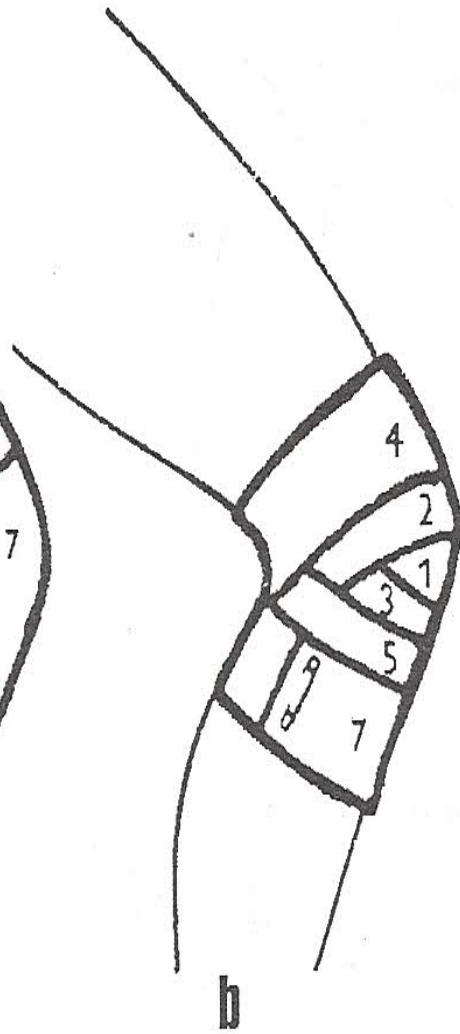
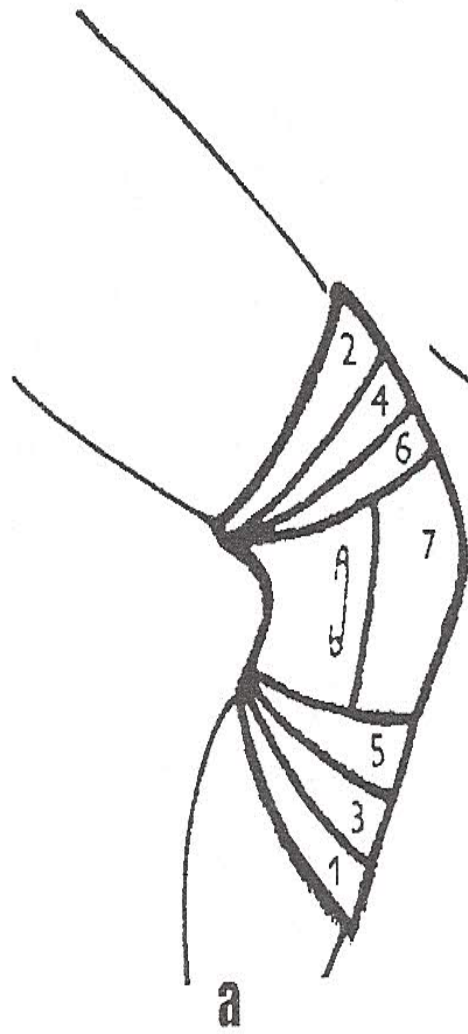
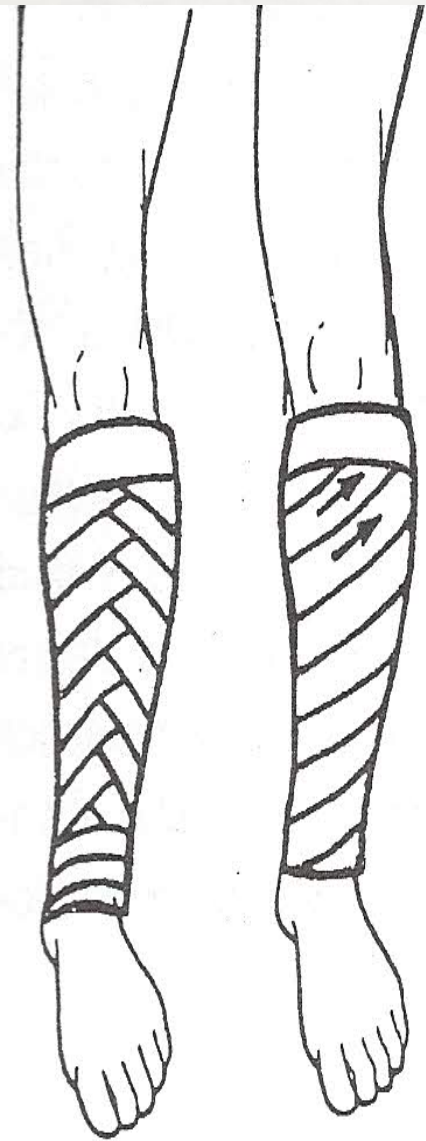




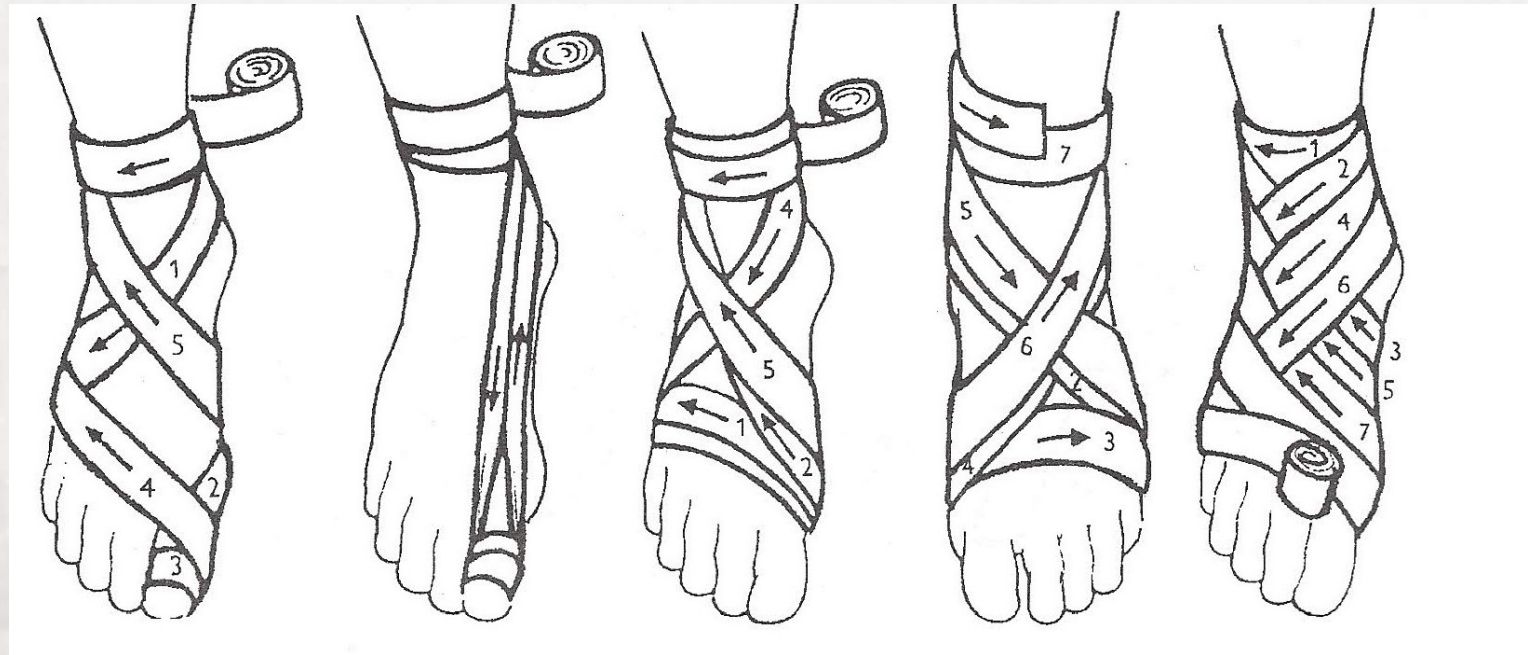
Diagonal bandaging of the thumb



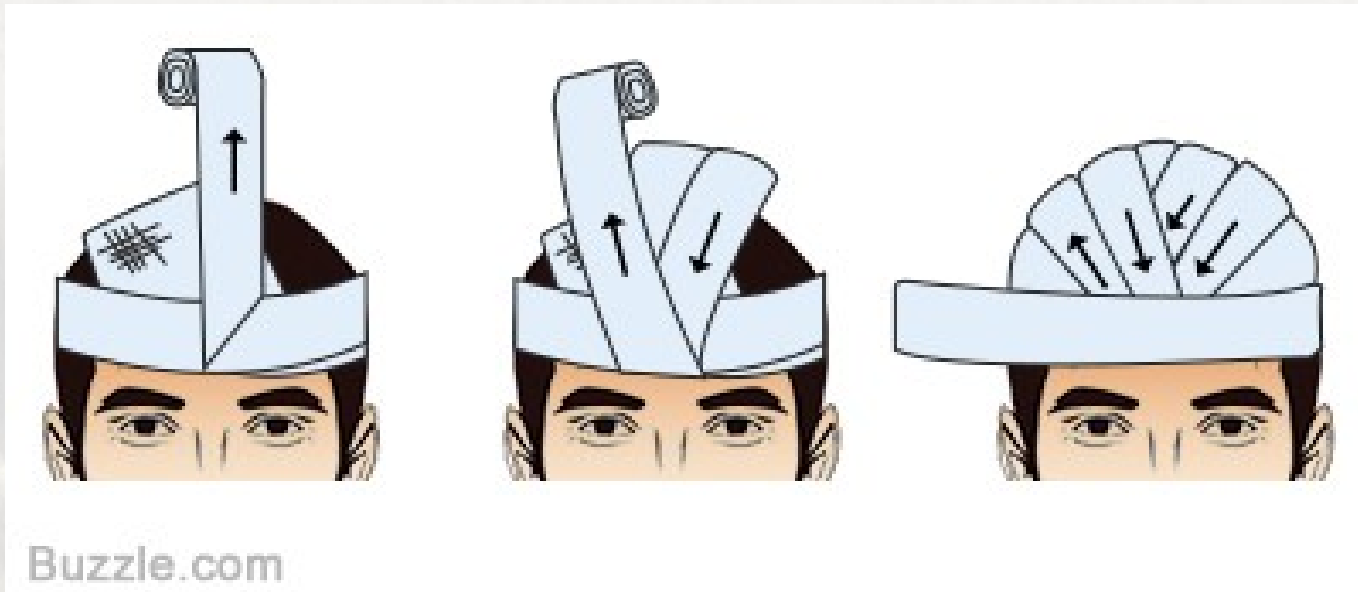




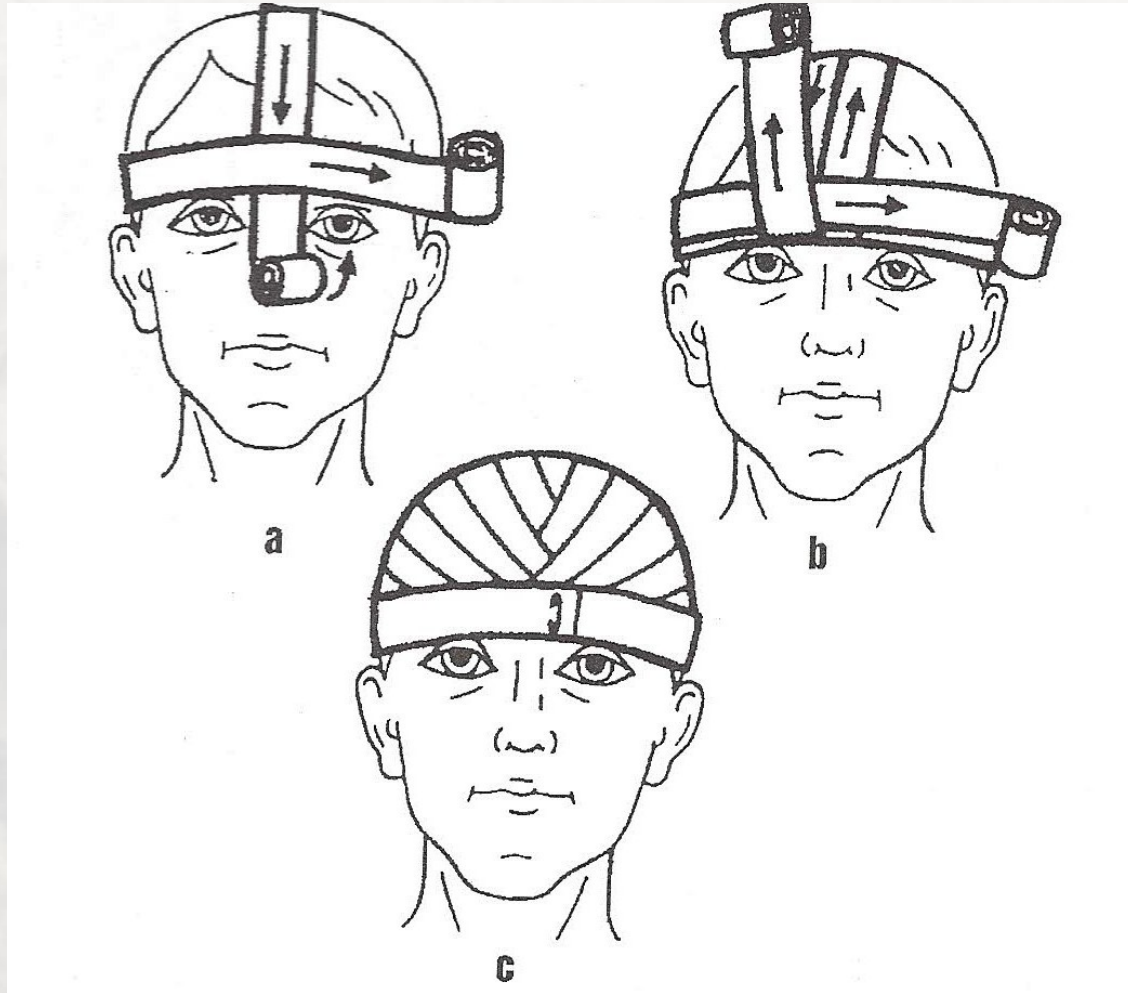
Diagonal bandaging of the foot



Recurrent fold head bandage



Head bandage using two roller bandages



Thank you for your attention 😊

