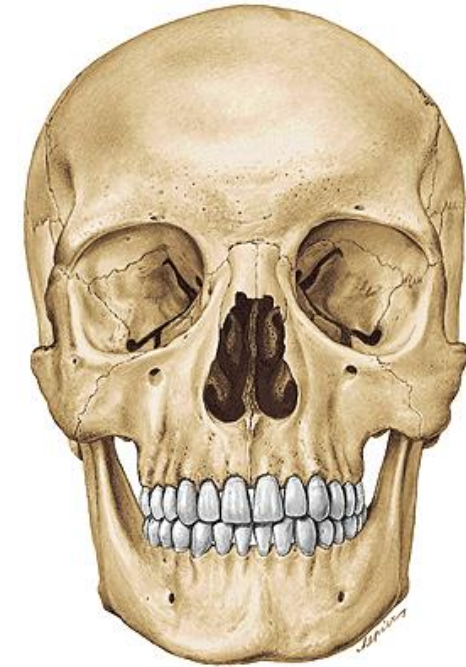

Splanchnocranium

LECTURE 5

DENTISTRY AUTUMN 2016

RNDr. Michaela Račanská, Ph.D.

Splanchnocranium

Maxilla

Os nasale

Os lacrimale

Os zygomaticum

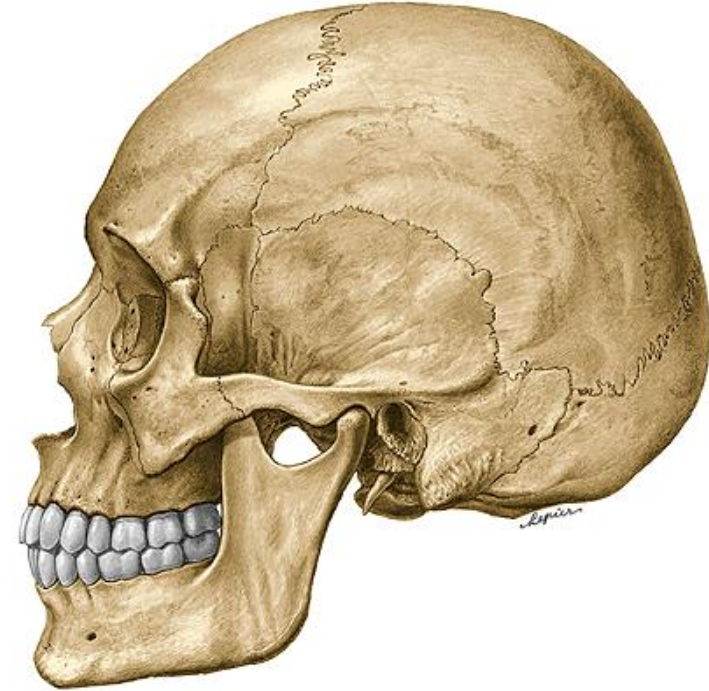
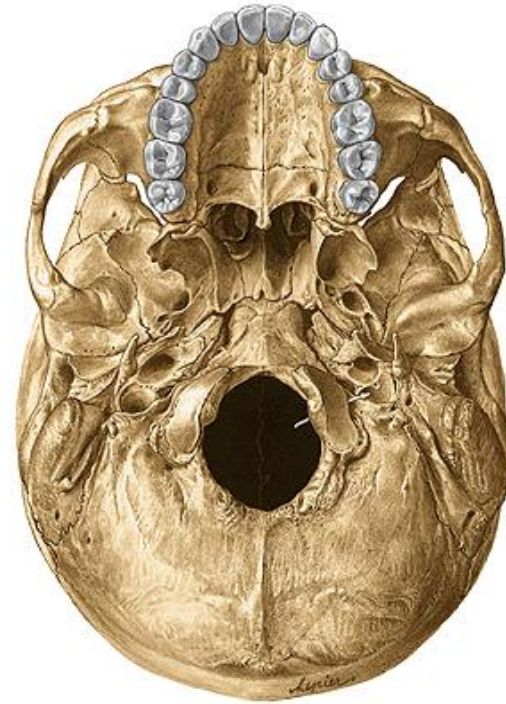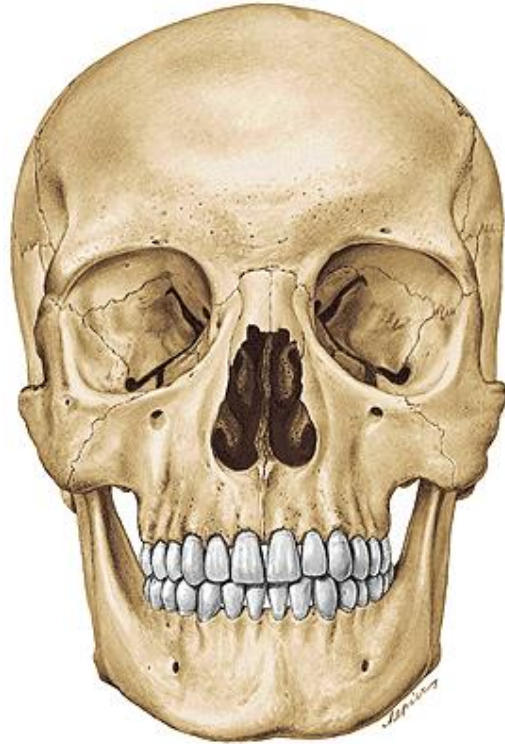
Vomer

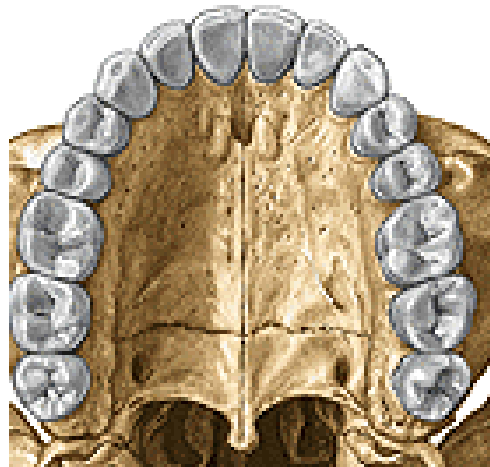
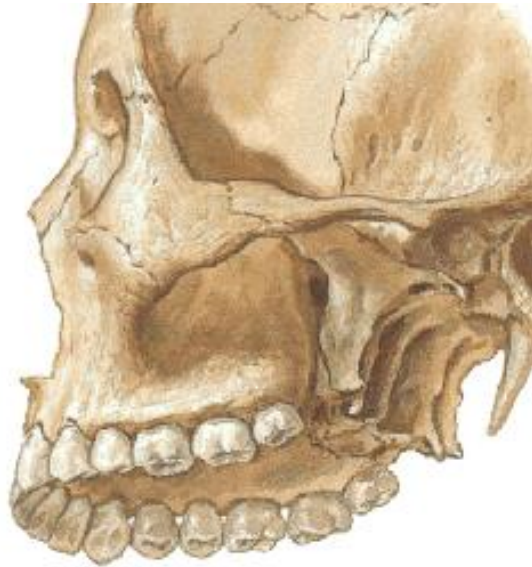Os palatinum

Concha nasalis inferior

Mandibula

Os hyoideum





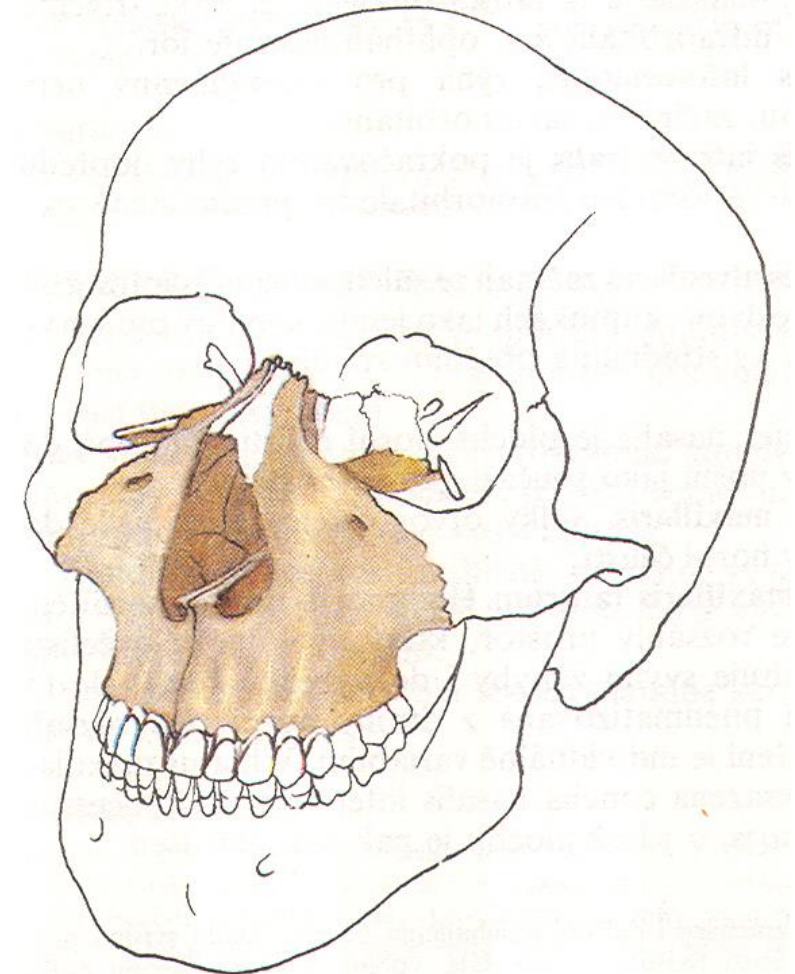
Maxilla

Corpus maxillae

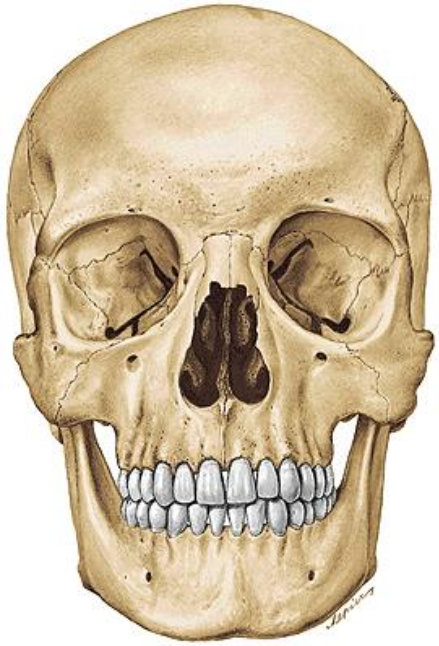
- Facies anterior
- Facies nasalis
- Facies orbitalis
- Facies infratemporalis

Processus maxillae

- Processus frontalis
- Processus zygomaticus
- Processus alveolaris
- Processus palatinus

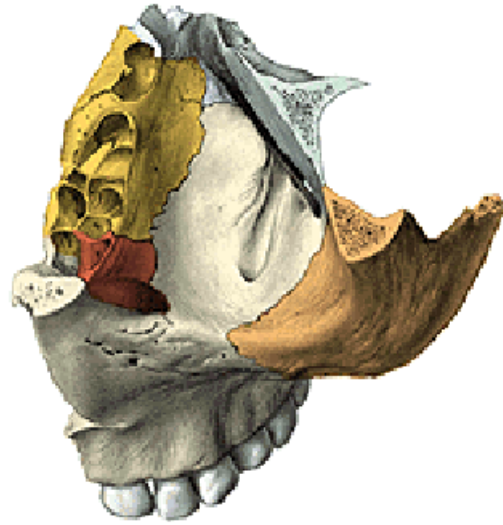


Corpus maxillae



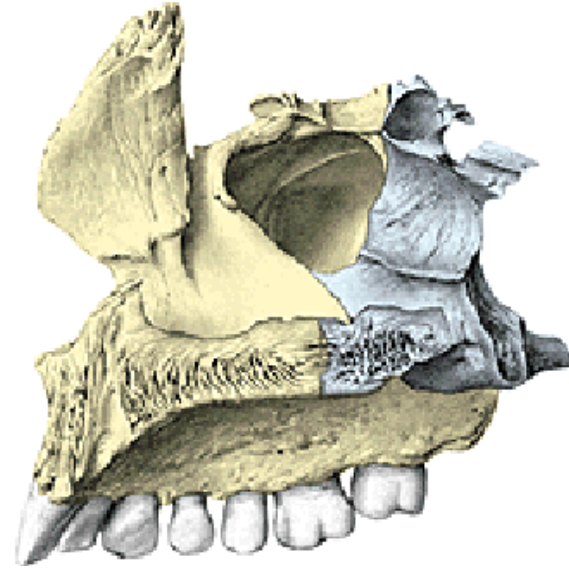
Facies anterior

foramen infraorbitale
fossa canina
incisura nasalis
spina nasalis anterior



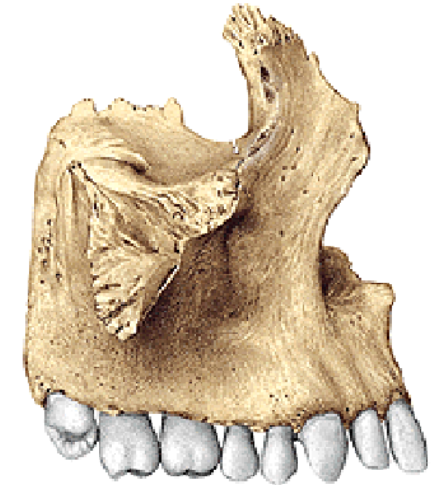Facies orbitalis

margo infraorbitalis
sulcus infraorbitalis
canalis infraorbitalis
(canales alveolares)



Facies nasalis

sinus maxillaris
hiatus maxillaris
(antrum Highmori)

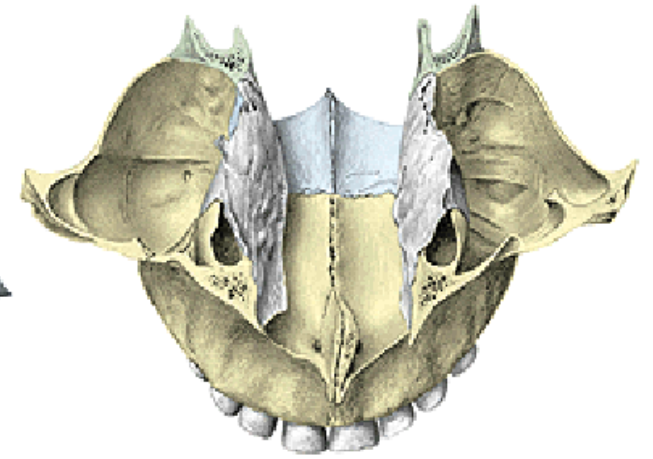
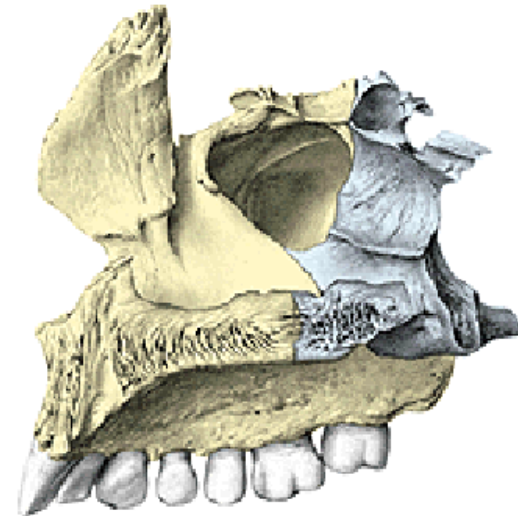
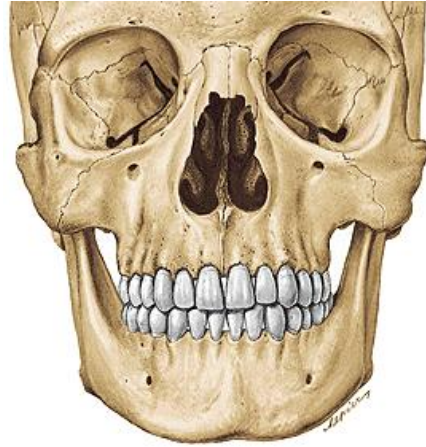
Facies infratemporalis

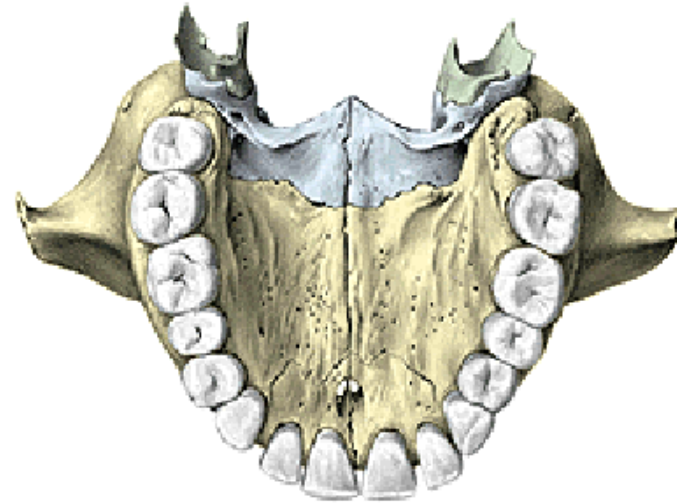
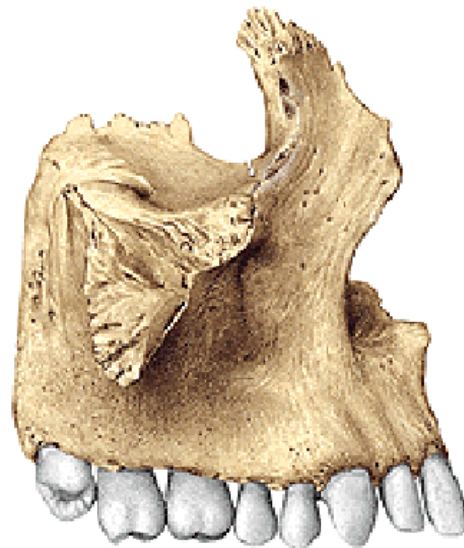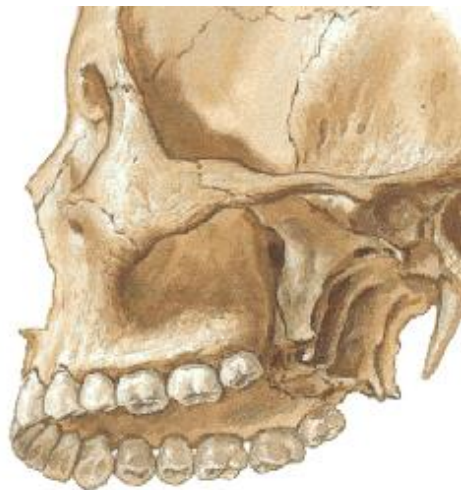crista infrazygomatica
tuber maxillae
foramina et canales alveolares

Processus frontalis maxillae

Incisura nasalis
(apertura piriformis)
Crista lacrimalis anterior
Crista ethmoidalis
Crista conchalis



Processus zygomaticus maxillae

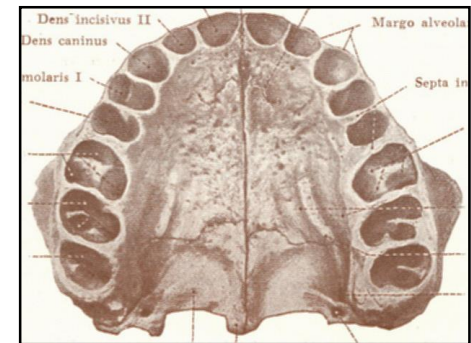
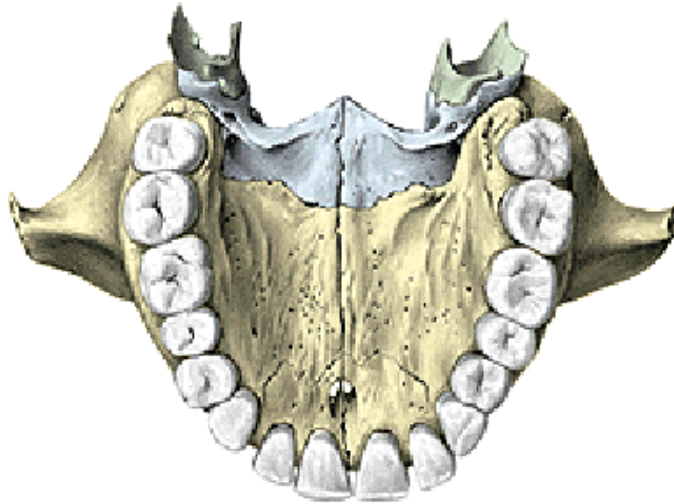
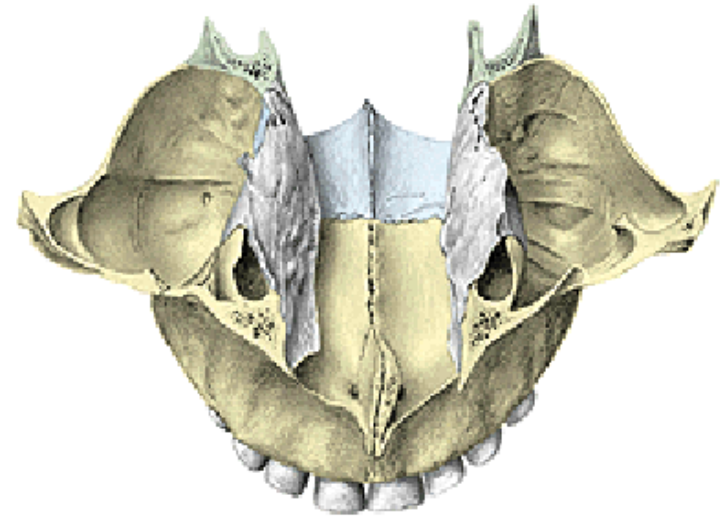
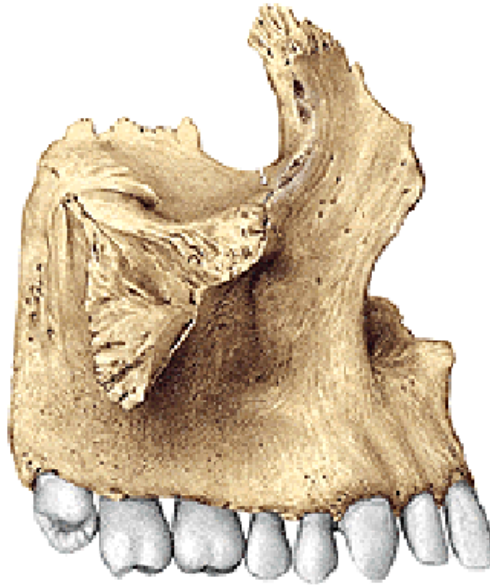

Processus palatinus maxillae

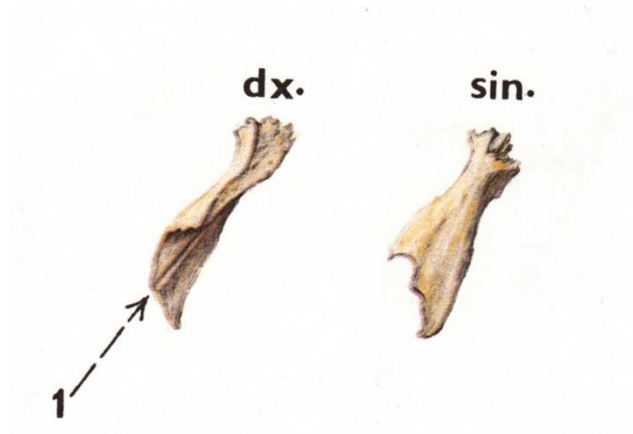
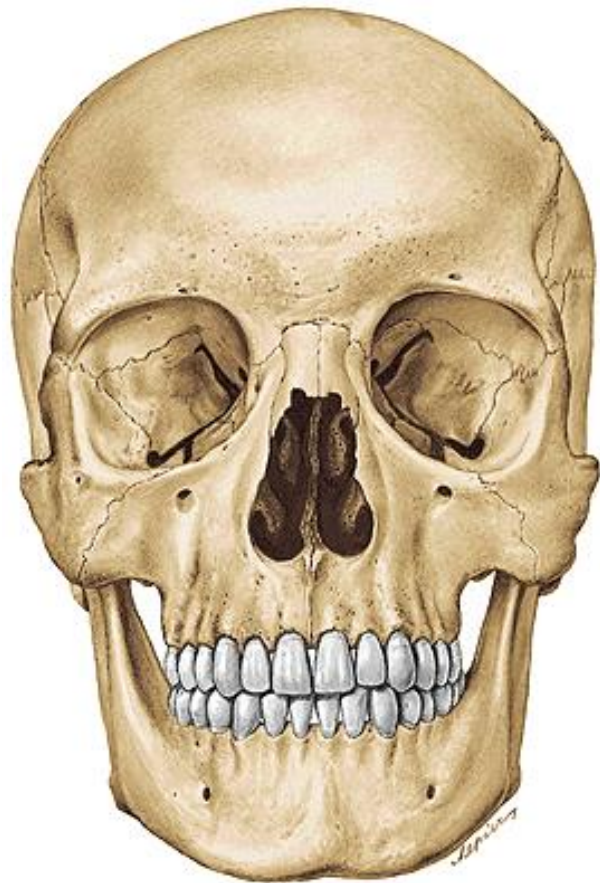
Os incisivum (praemaxilla)
Foramen incisivum
Canalis incisivus
Crista nasalis
Torus palatinus

Processus alveolaris maxillae

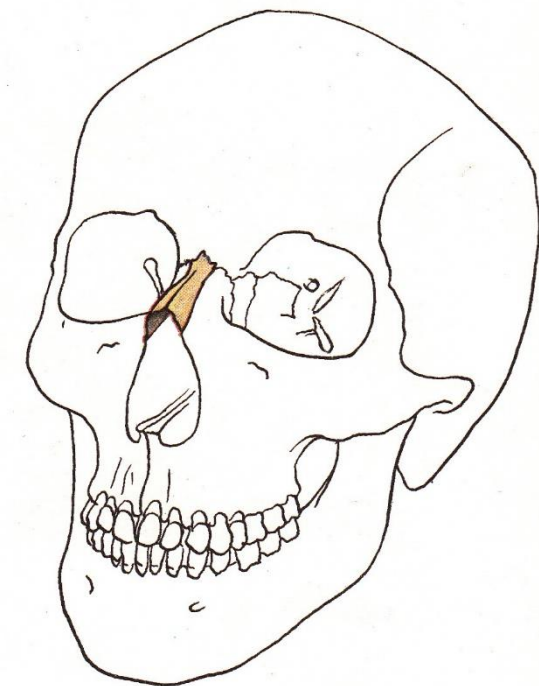
Arcus alveolaris
Alveoli dentales
Juga alveolaria
Septa interalveolaria
Septa intraalveolaria

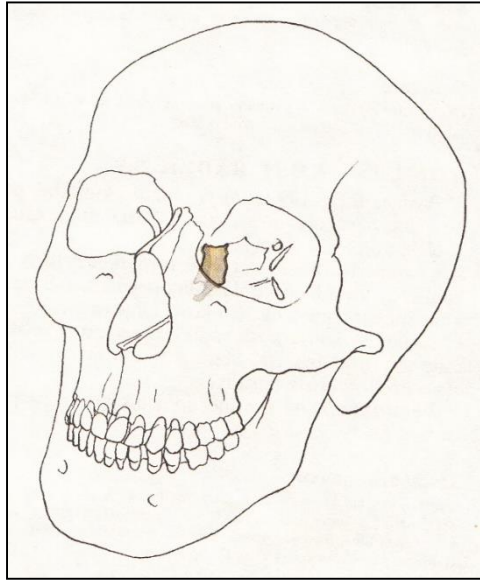


Os nasale



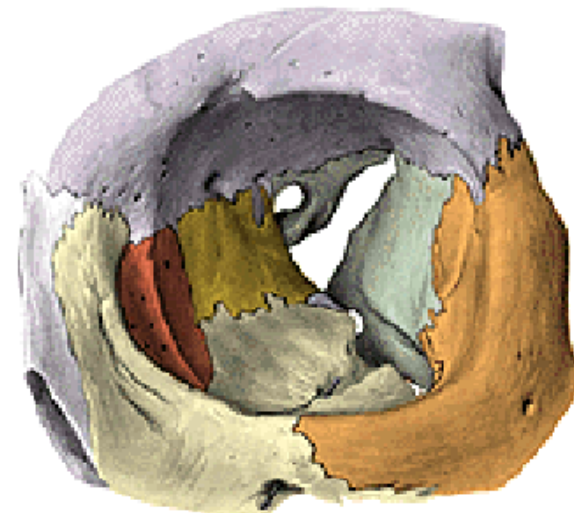
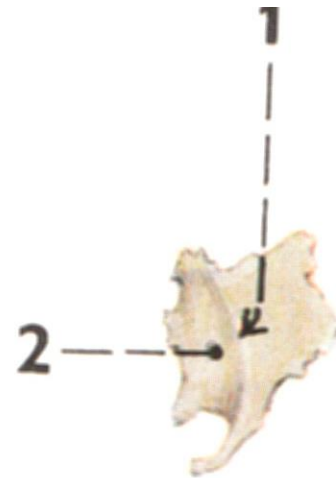
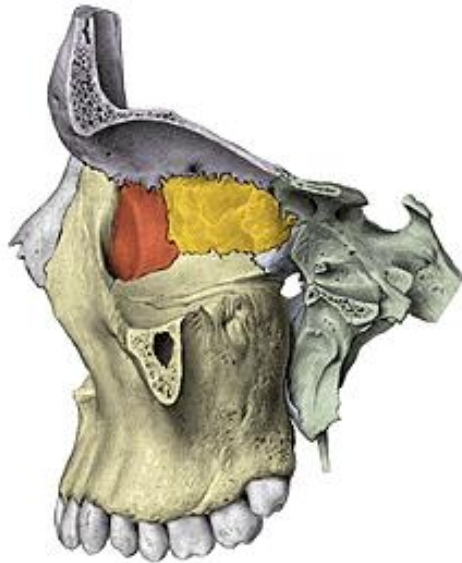
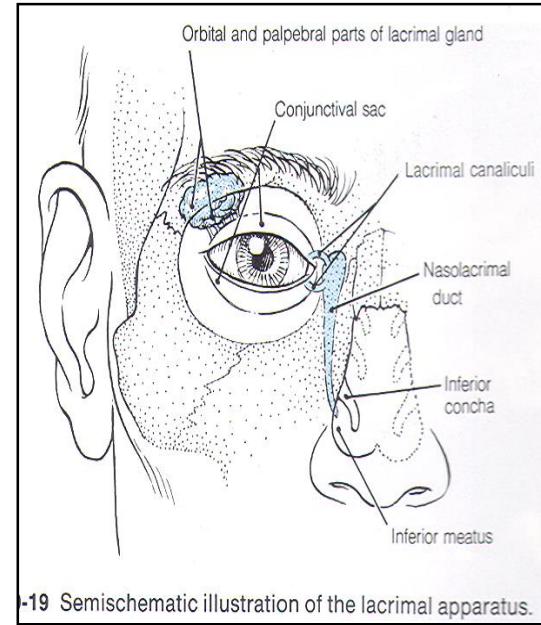
Sulcus ethmoidalis



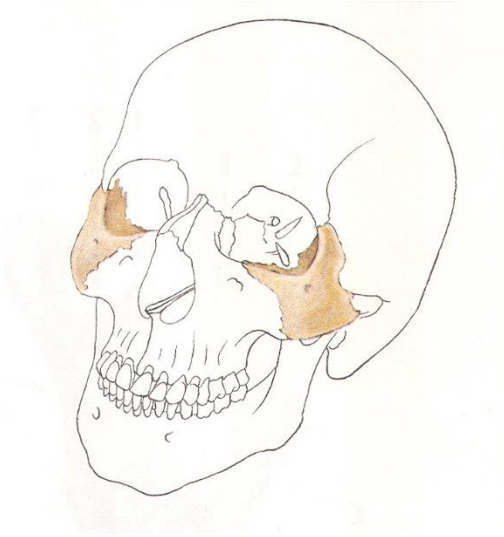


Os lacrimale

- Crista lacrimalis posterior
- Sulcus lacrimalis
- Fossa sacci lacrimalis
- Canalis nasolacrimalis
- Hamulus lacrimalis



Os zygomaticum



Corpus

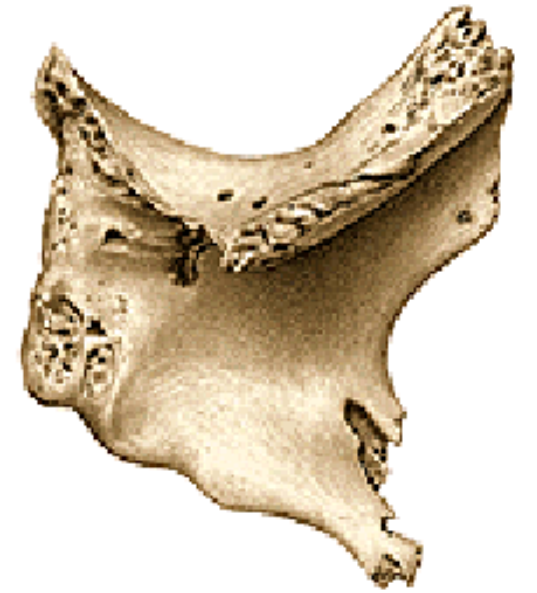Facies lateralis - foramen zygomaticofaciale

Facies orbitalis - foramen zygomaticoorbitale

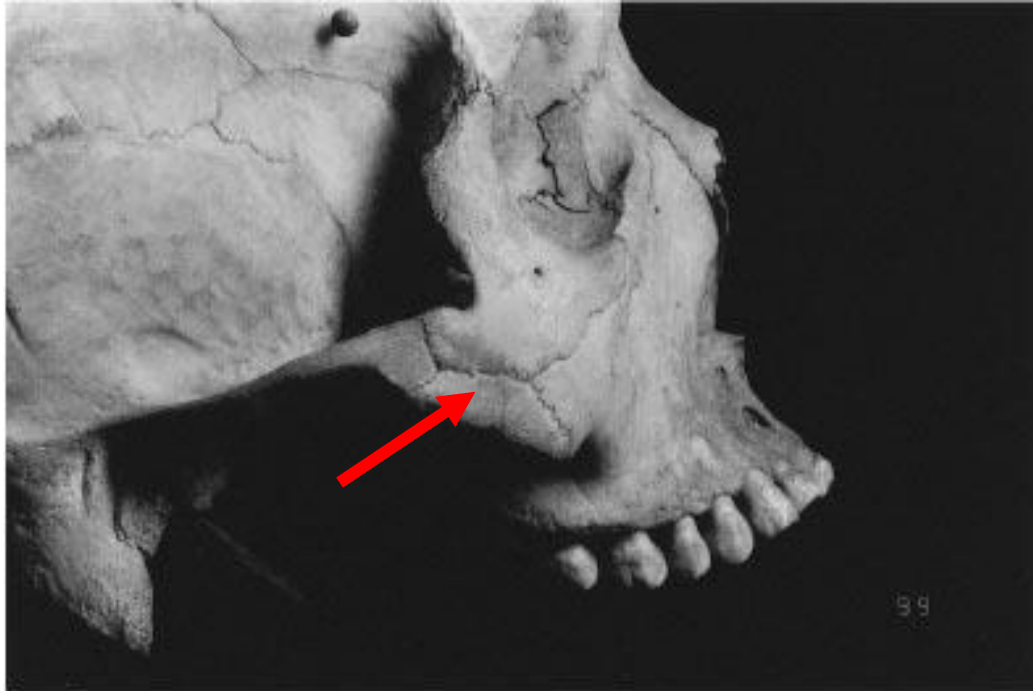
Facies temporalis - foramen zygomaticotemporale

Processus maxillaris, frontalis, zygomaticus

Arcus zygomaticus

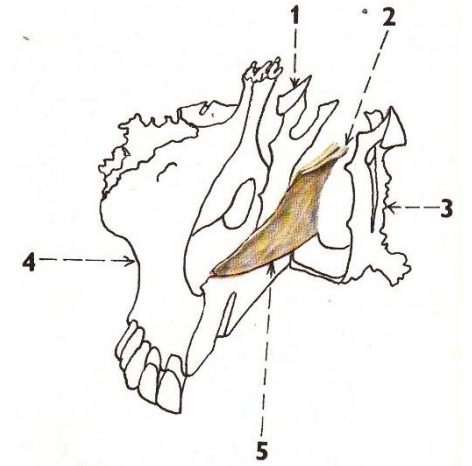
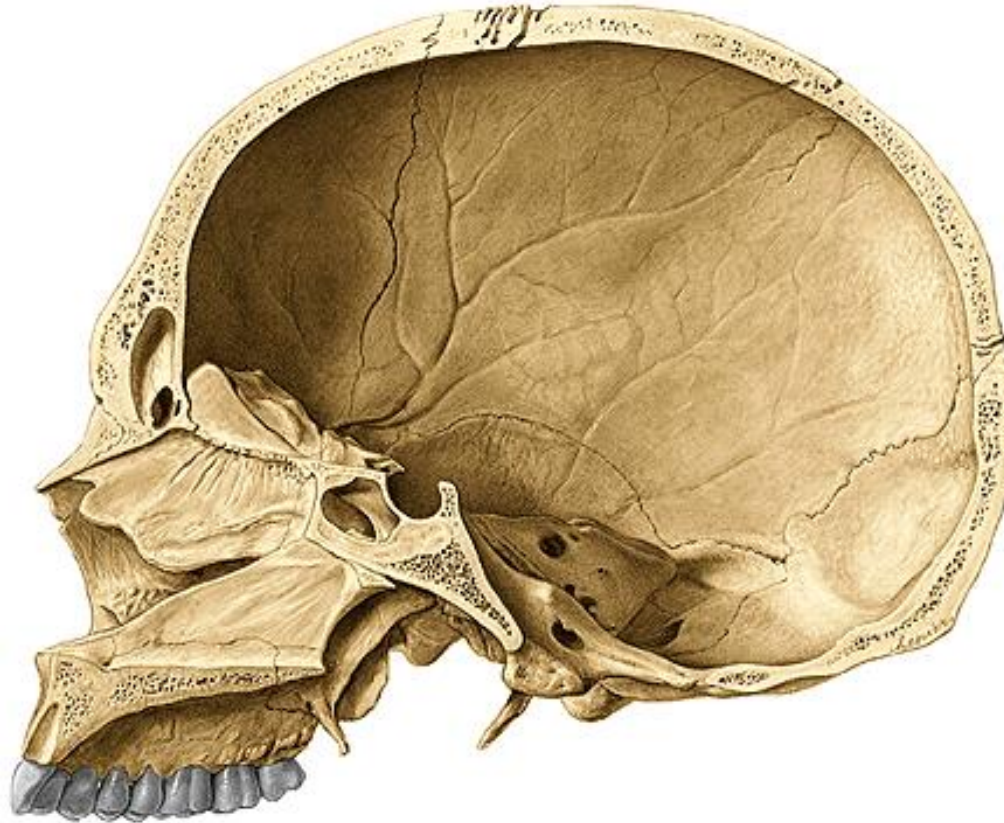
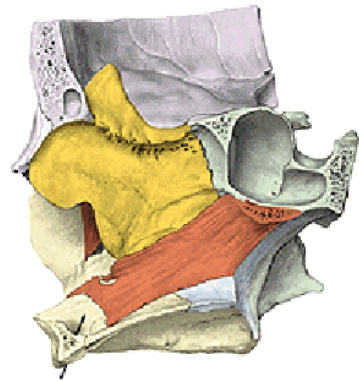


Os zygomaticum bipartitum (os japonicum) – sutura (mostly horizontal one).



Vomer

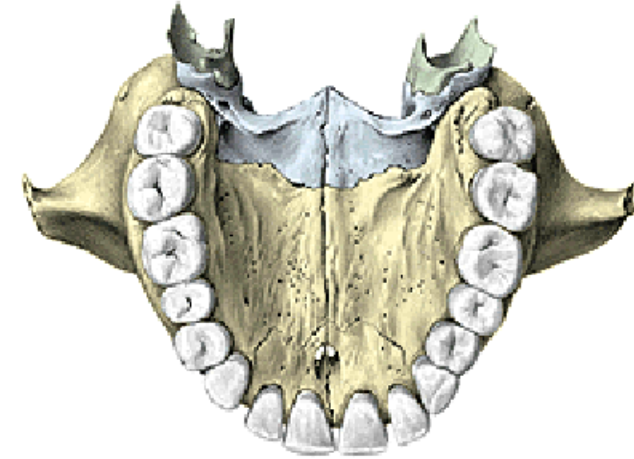
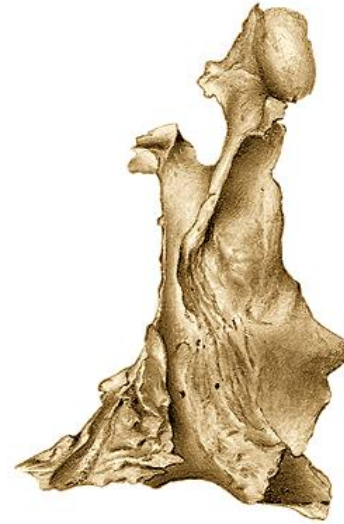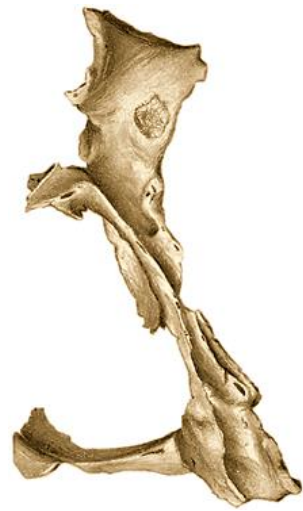Alae vomeris (rostrum ossis sphenoidalis)



Os palatinum

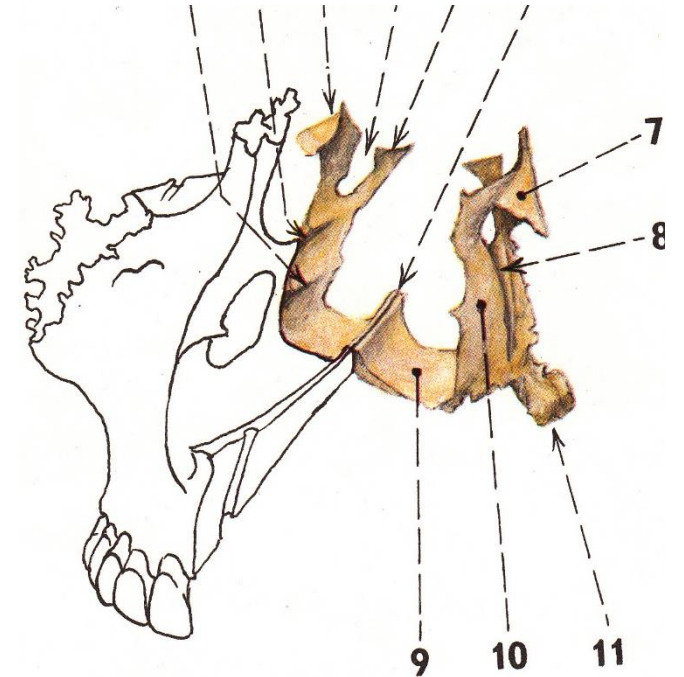
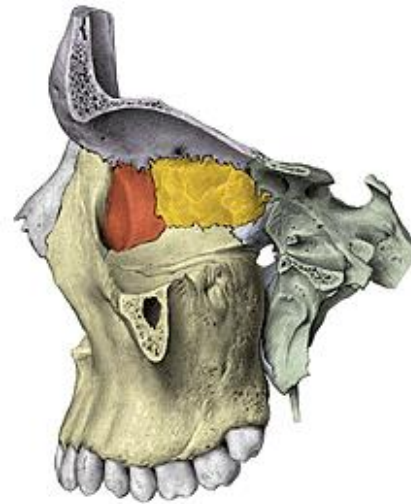
Lamina horizontalis

- Spina nasalis posterior
- Crista nasalis
- Foramen palatinum majus
- Processus pyramidalis
- Foramina palatina minora



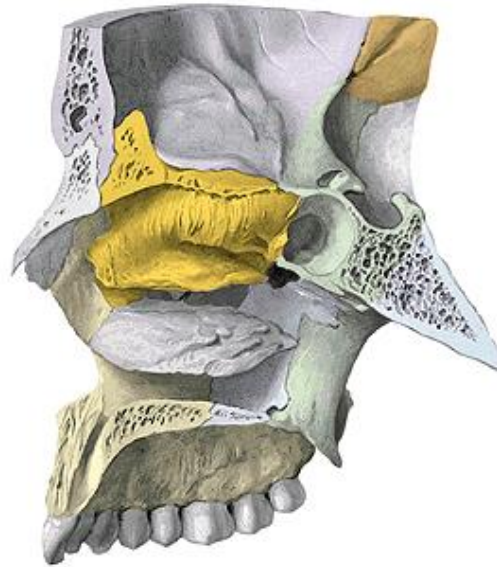
Lamina perpendicularis

- Crista conchalis
- Crista ethmoidalis
- Processus orbitalis et sphenoidalis
- Incisura (foramen) sphenopalatinum
- Sulcus palatinus major (pterygopalatinus)



Concha nasalis inferior

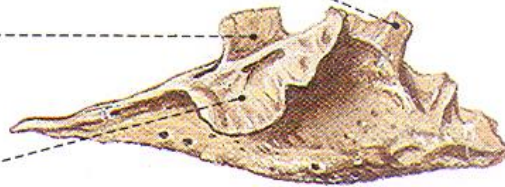
Processus maxillaris
Processus lacrimalis
Processus ethmoidalis



Proc. lacrimalis

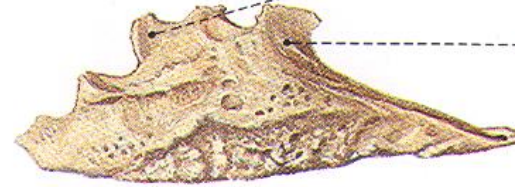
Proc. ethmoidalis

Proc. maxillaris



Proc. lacrimalis

Proc. ethmoidalis

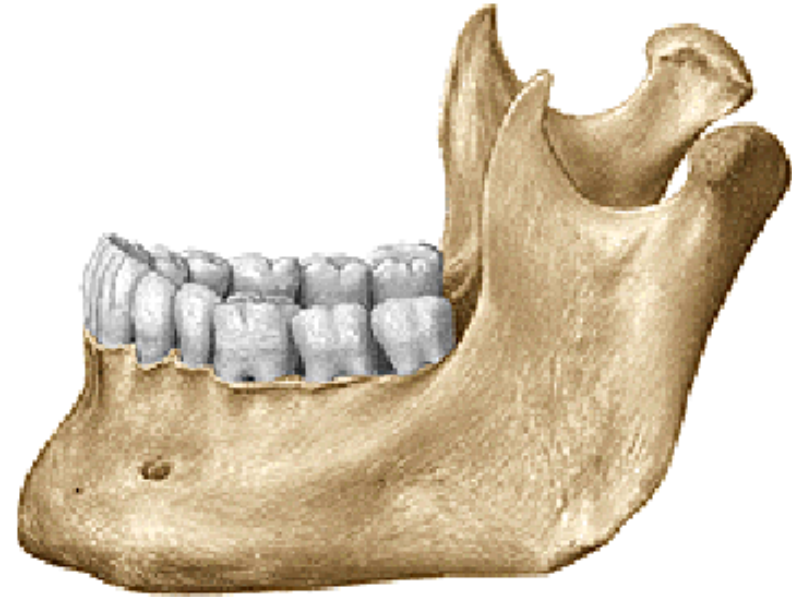
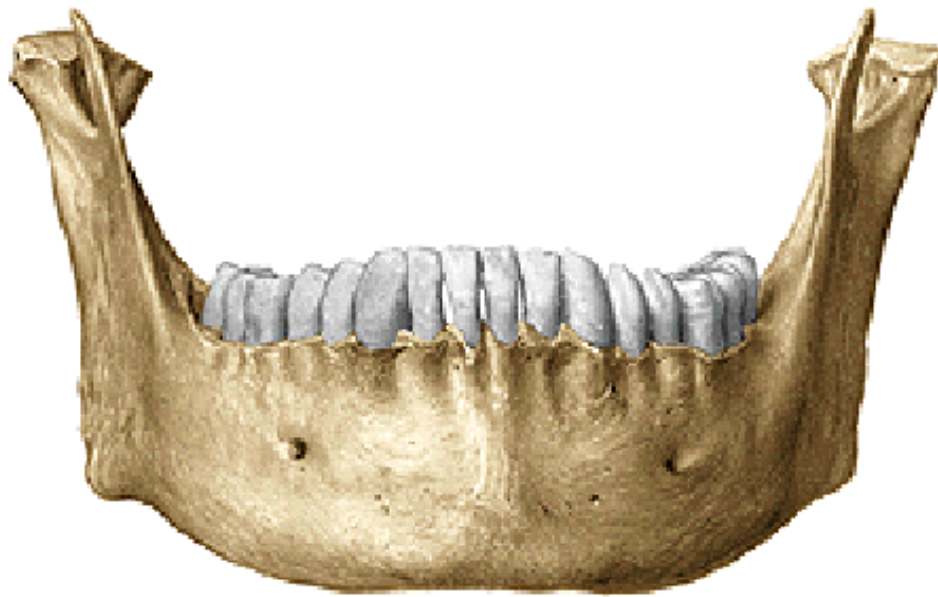

Mandibula

Corpus mandibulae (basis mandibulae)

Ramus mandibulae dx. et sin.

Angulus mandibulae dx. et sin.



Corpus mandibulae

Fossa digastrica

Spina mentalis (sup. et inf.)

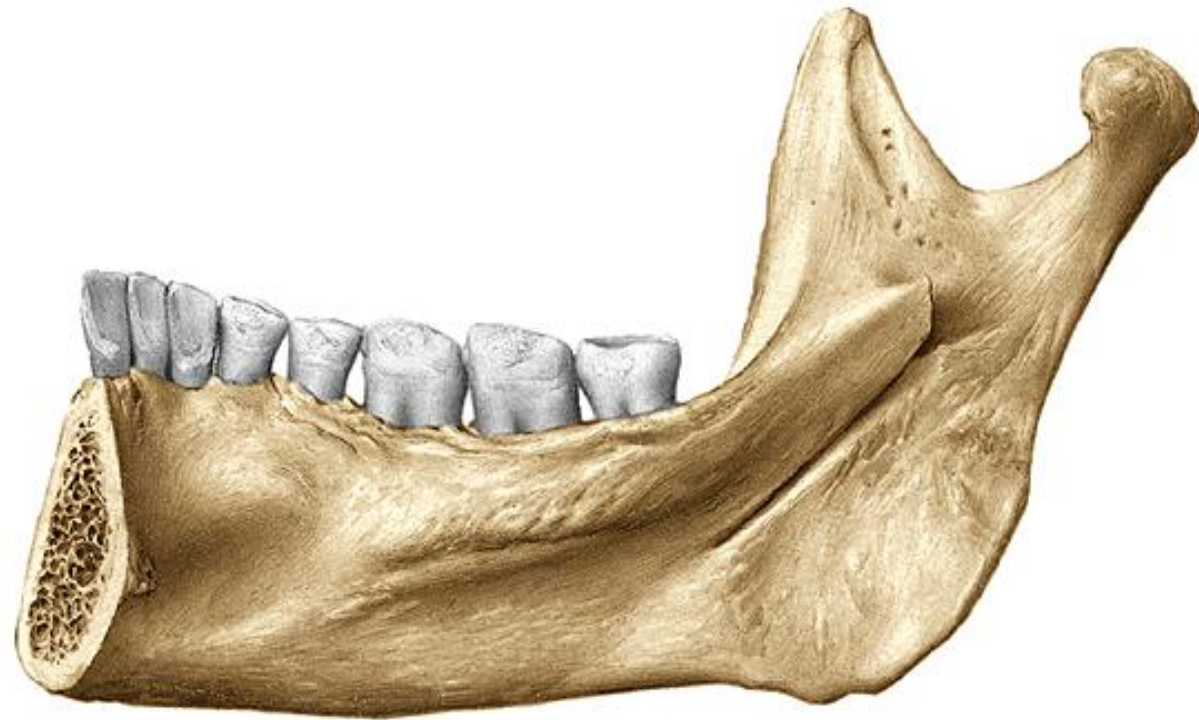Linea mylohyoidea

Fovea sublingualis

Fovea submandibularis

Crista buccinatoria

Trigonum retromolare



Corpus mandibulae

Tuberculum mentale

Protuberantia mentalis

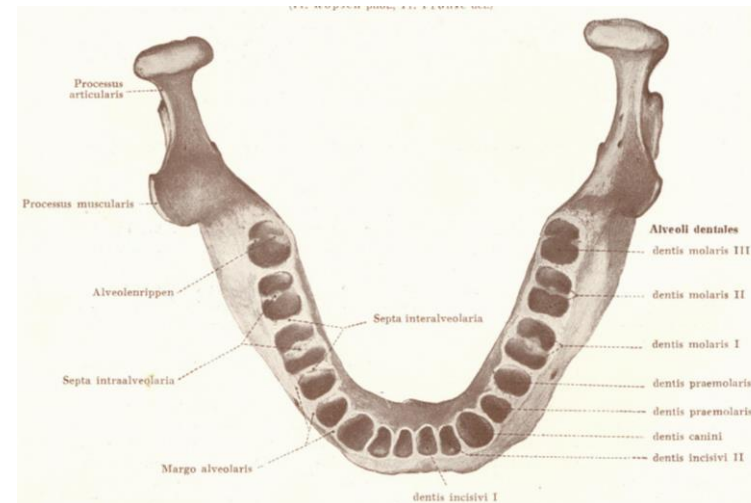
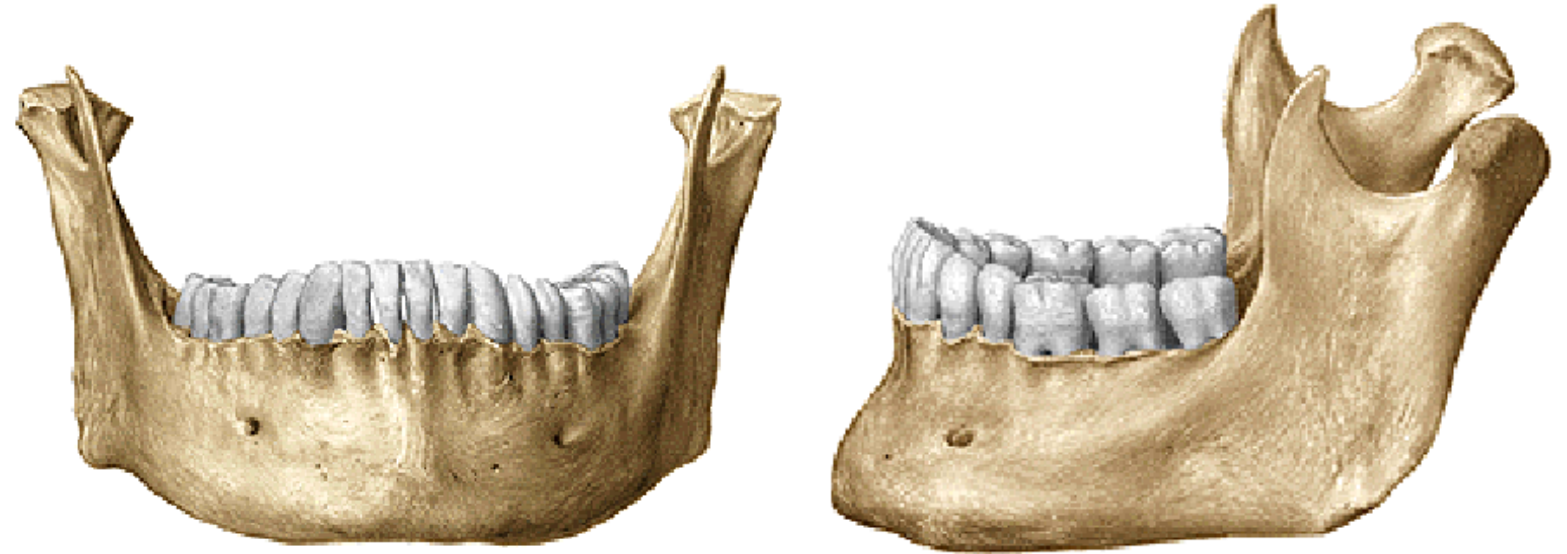
Foramen mentale

Linea obliqua (trigonum retromolare)

Pars alveolaris

Alveoli dentales, juga alveolaria

Septa interalveolaria, intraalveolaria



Ramus mandibulae

Processus condylaris

Caput mandibulae

Collum mandibulae

Fovea pterygoidea

Processus coronoideus

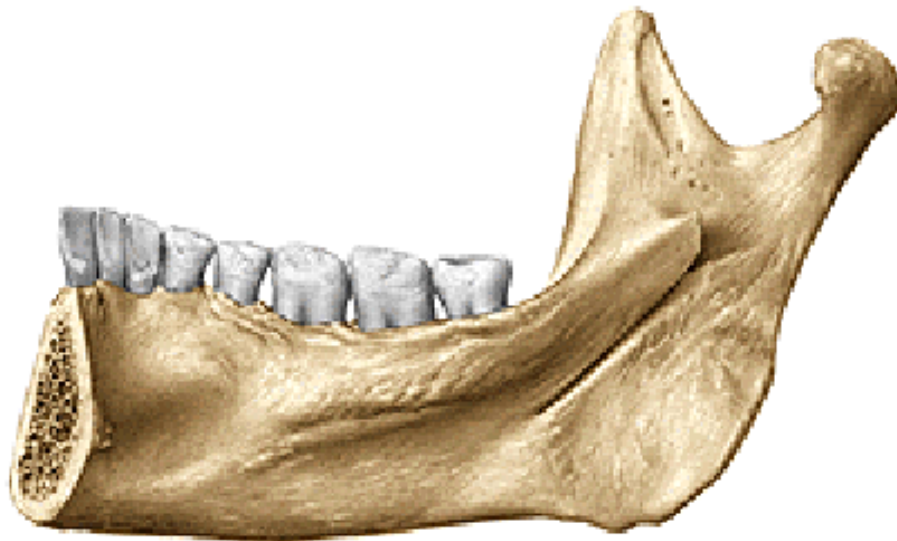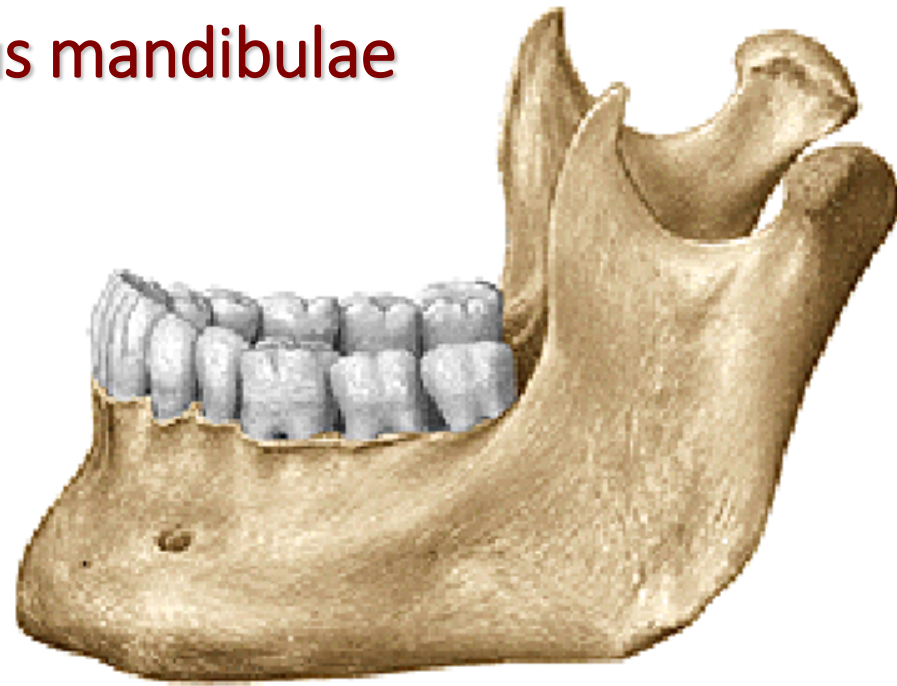
Incisura mandibulae

Foramen mandibulae

Canalis mandibulae

Lingula mandibulae

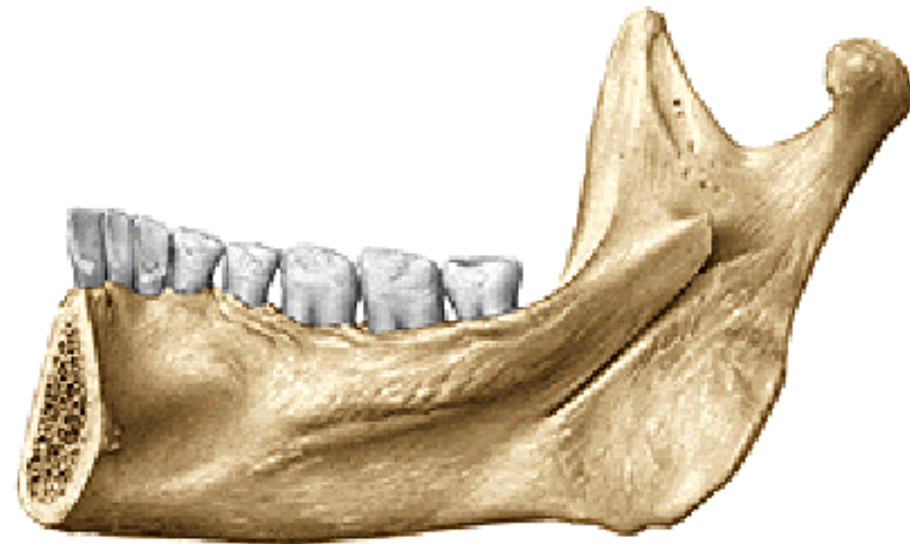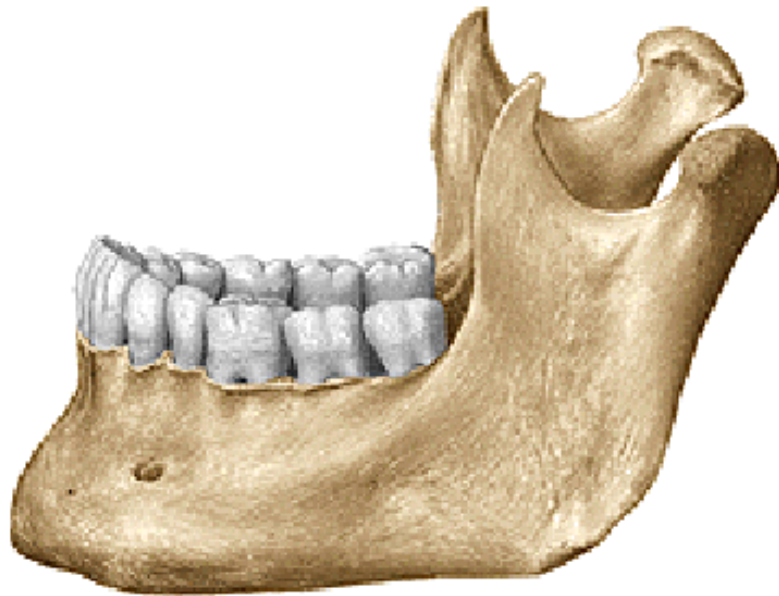Sulcus mylohyoideus



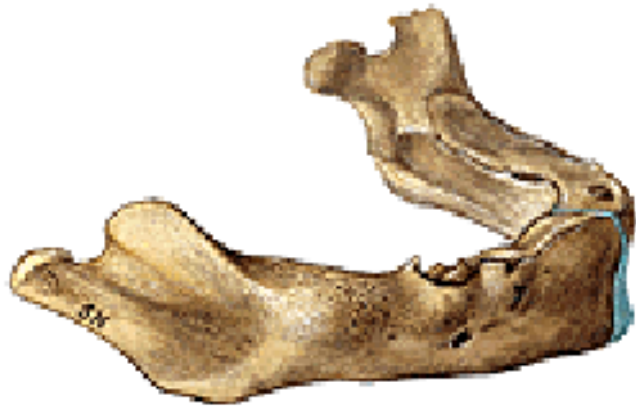Angulus mandibulae (120°-125°)

Tuberositas masseterica

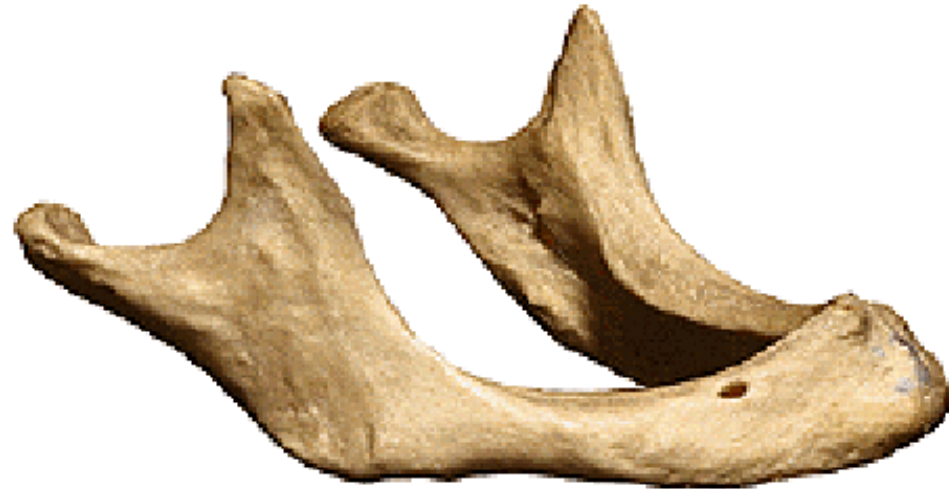Tuberositas pterygoidea



Mandible of a newborn



Mandible of an senilis

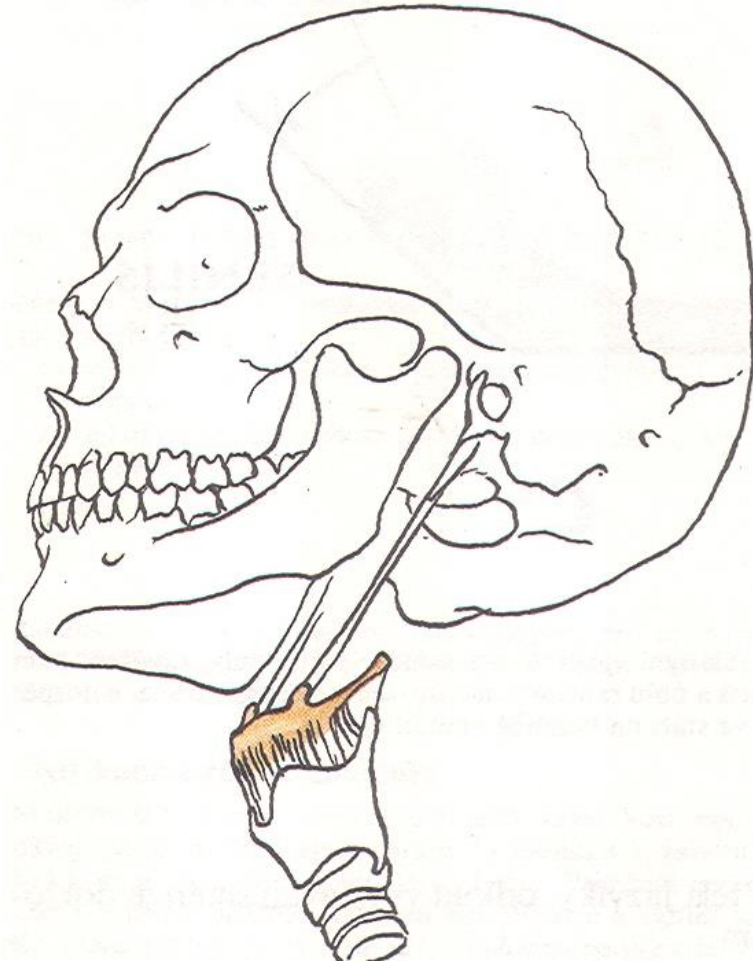
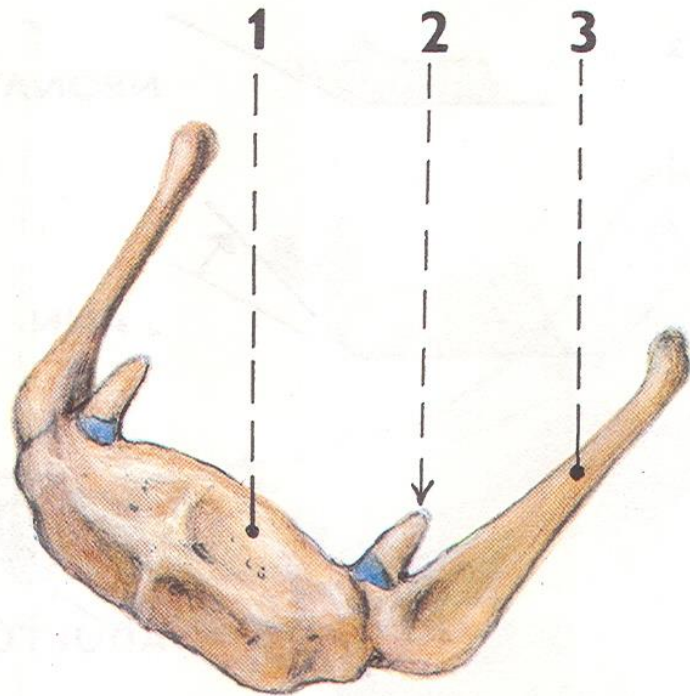


Os hyoideum

Corpus ossis hyoidei

Cornua minora ossis hyoidei

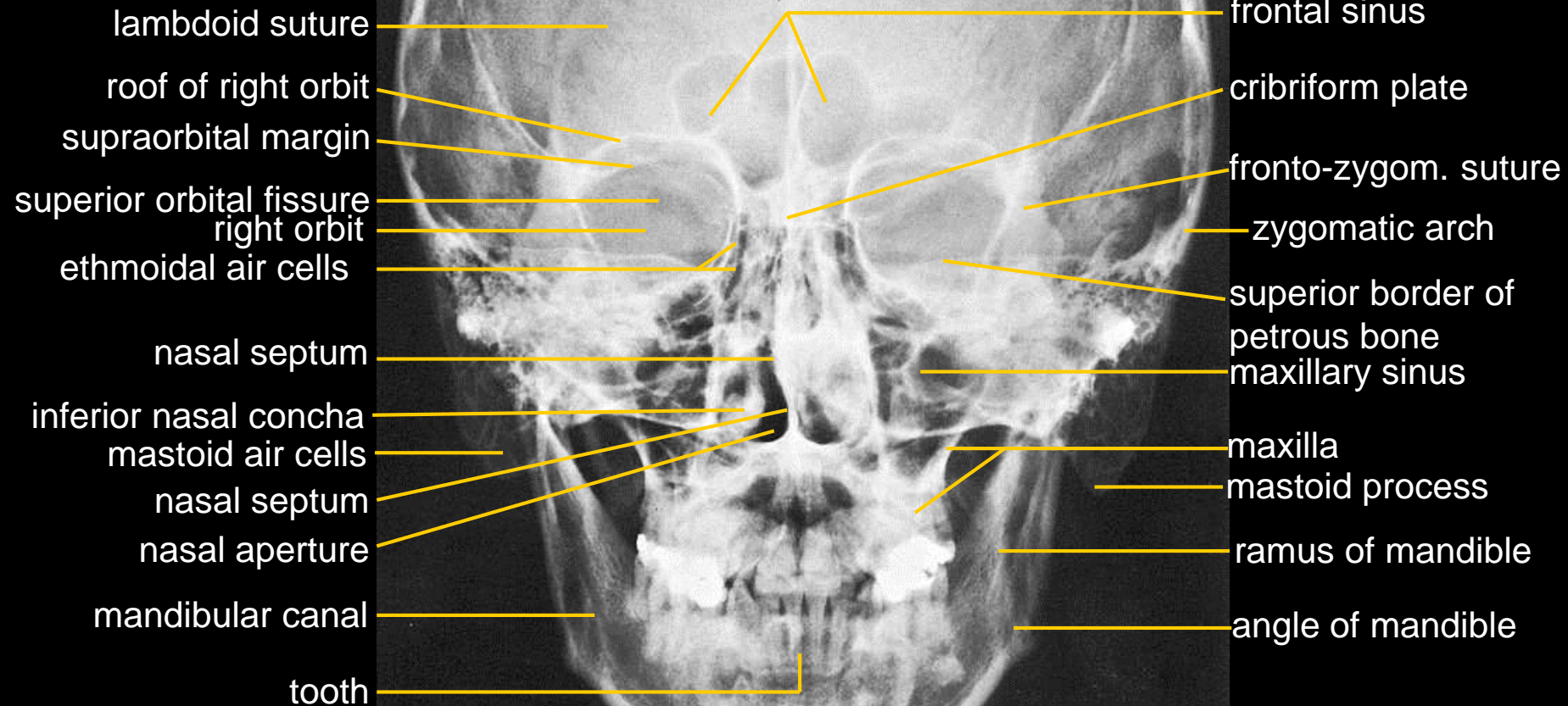
Cornua majora ossis hyoidei



X-RAYS

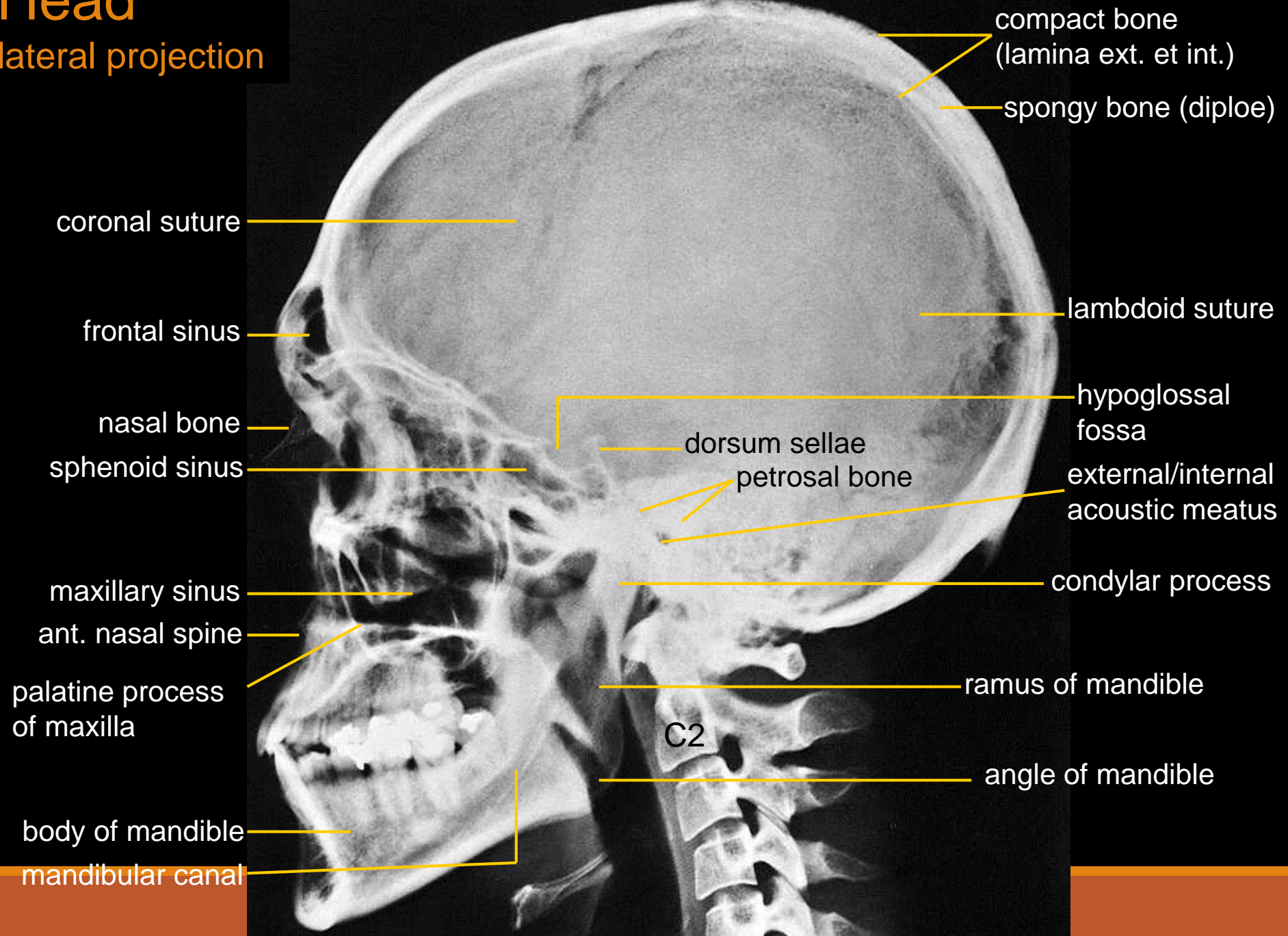
Head

axial projection



Head

lateral projection



The pictures used in this lectures were taken from following sources:

Drake et al (2010):

Gray's Anatomy for Students.

Putz, R. (2008):

Atlas of Human Anatomy Sobotta. Elsevier Books.

Keith L. Moore, Arthur F. Dalley (2005):

Clinically Oriented Anatomy. Williams and Wilkins.

Platzer, W., Kahle, W., Leonhardt H. (1992):

Locomotor system. Georg Thieme Verlag, Stuttgart, New York, 4th edition.

Čihák, R. (1987): Anatomie 1. Avicenum, Zdravotnické nakladatelství.

Own archiv of the lecturer