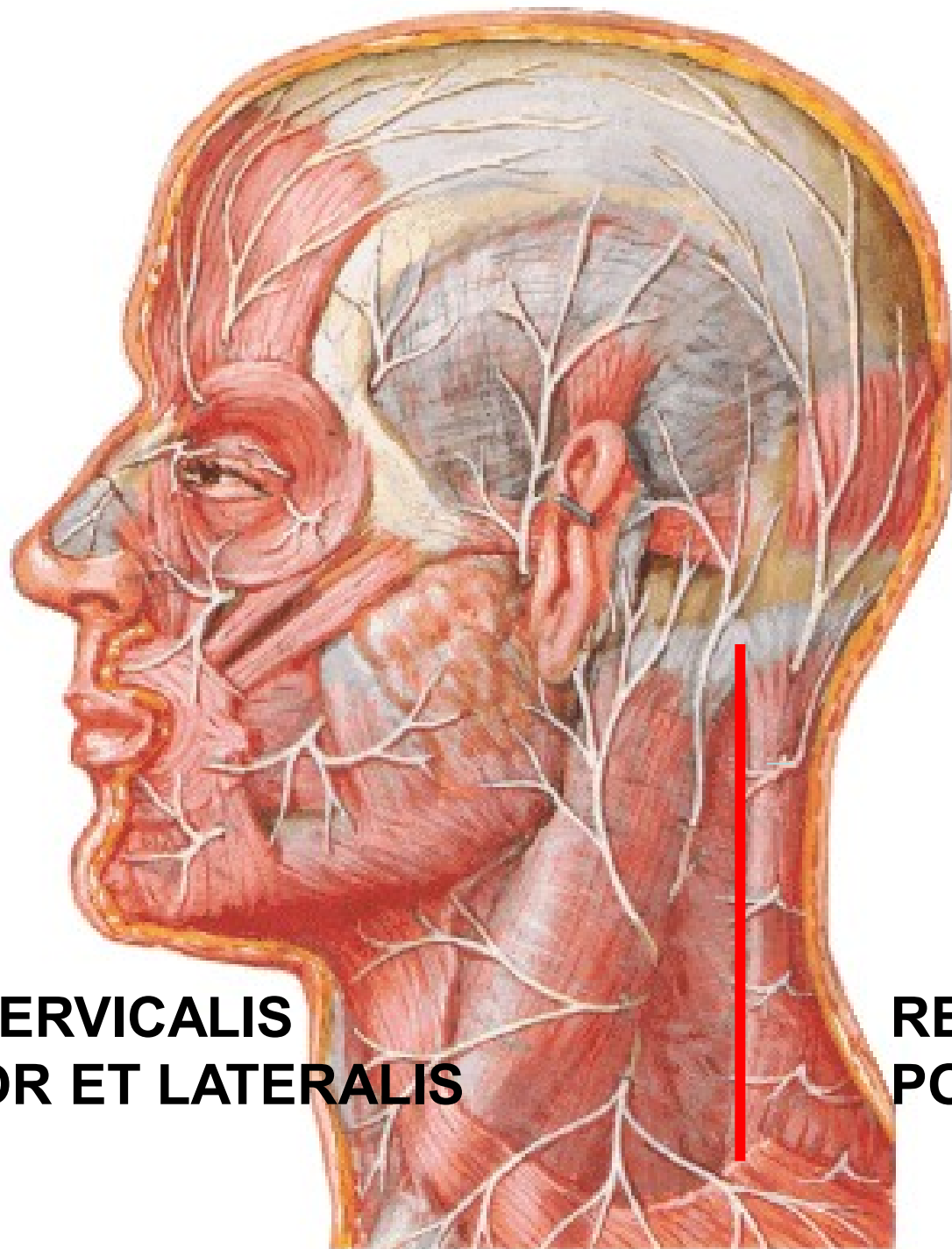
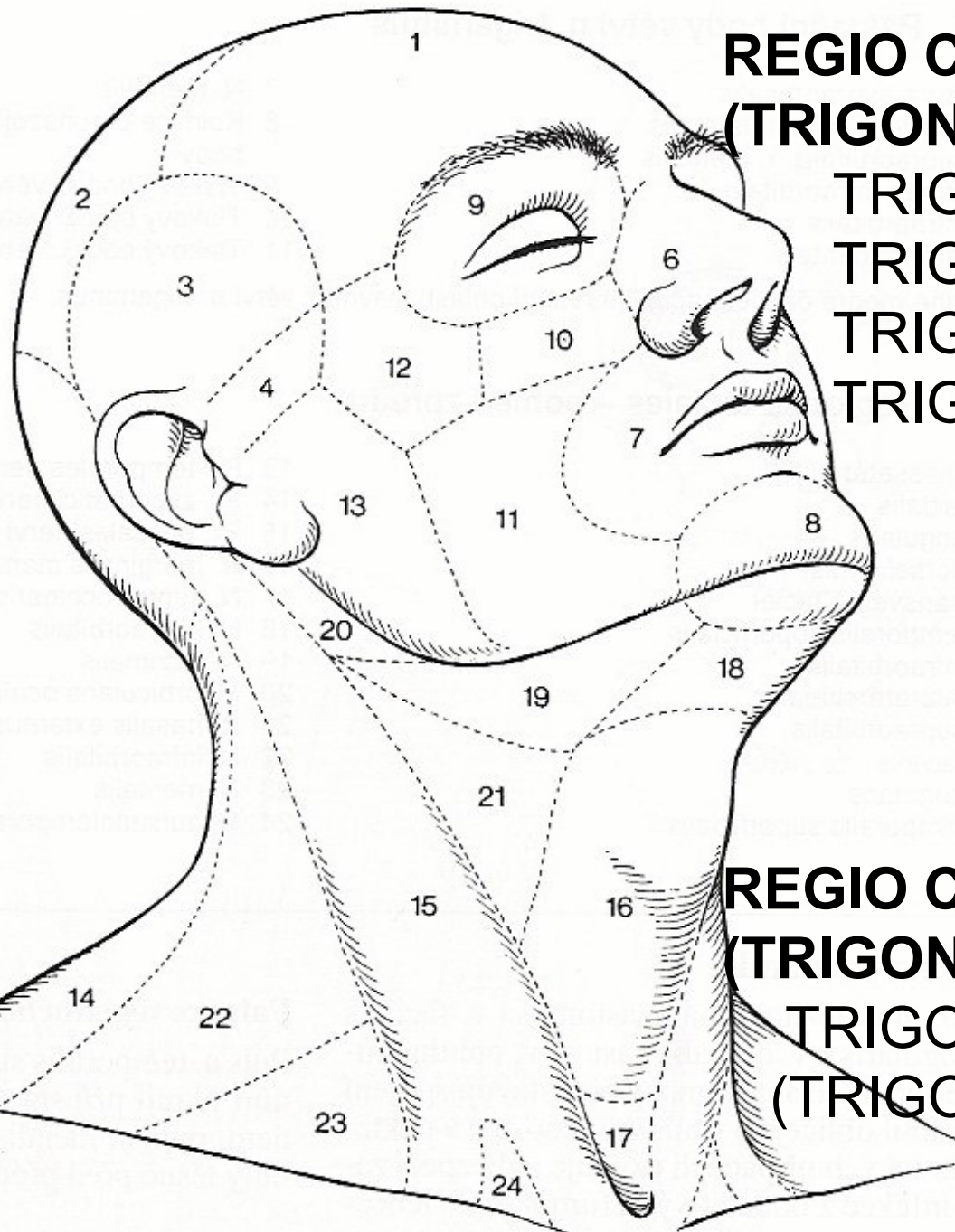


REGIONAL ANATOMY OF THE NECK



**REGIO CERVICALIS
ANTERIOR ET LATERALIS**

**REGIO CERVICALIS
POSTERIOR**



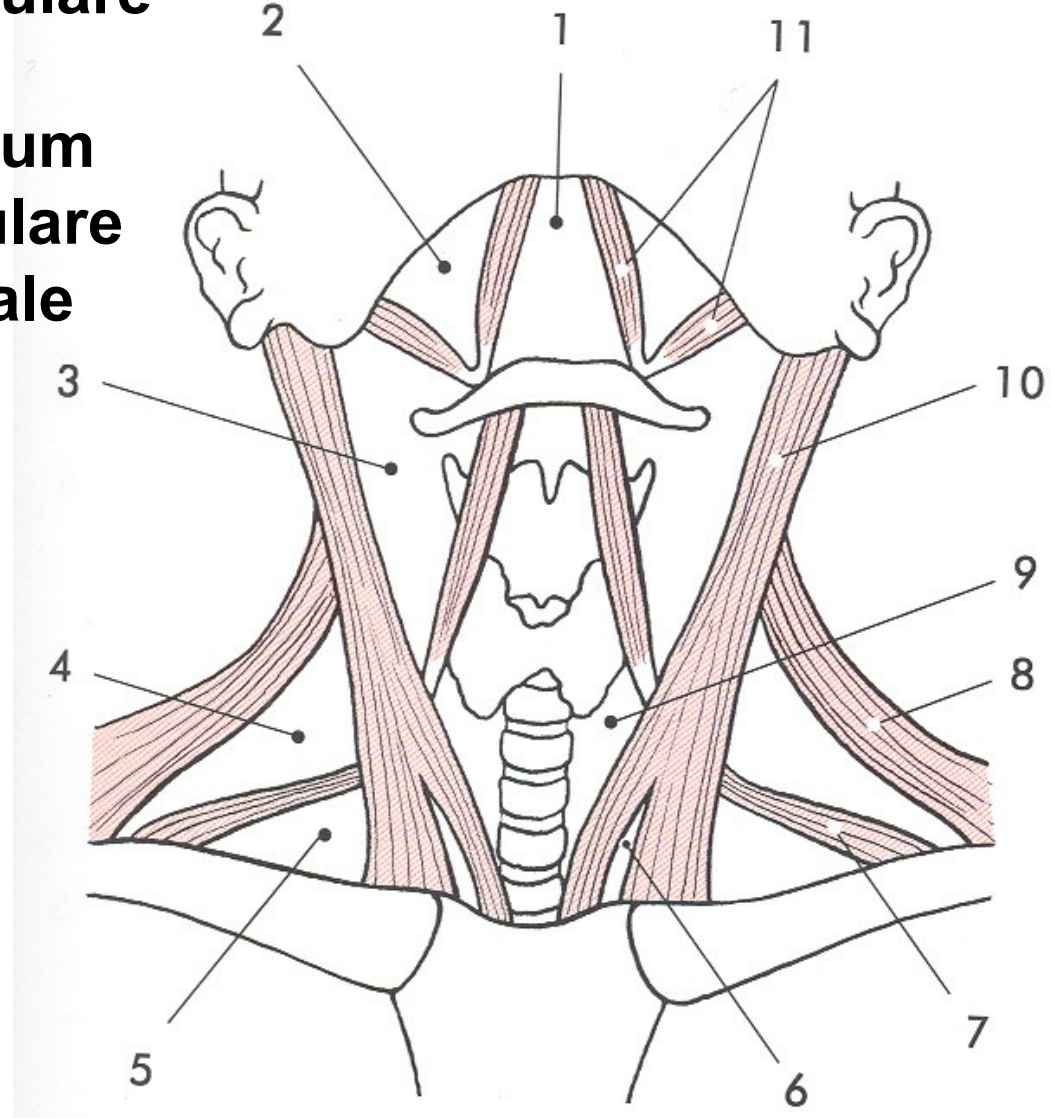
**REGIO CERVICALIS ANTERIOR
(TRIGONUM CERVICALE MEDIALE):**

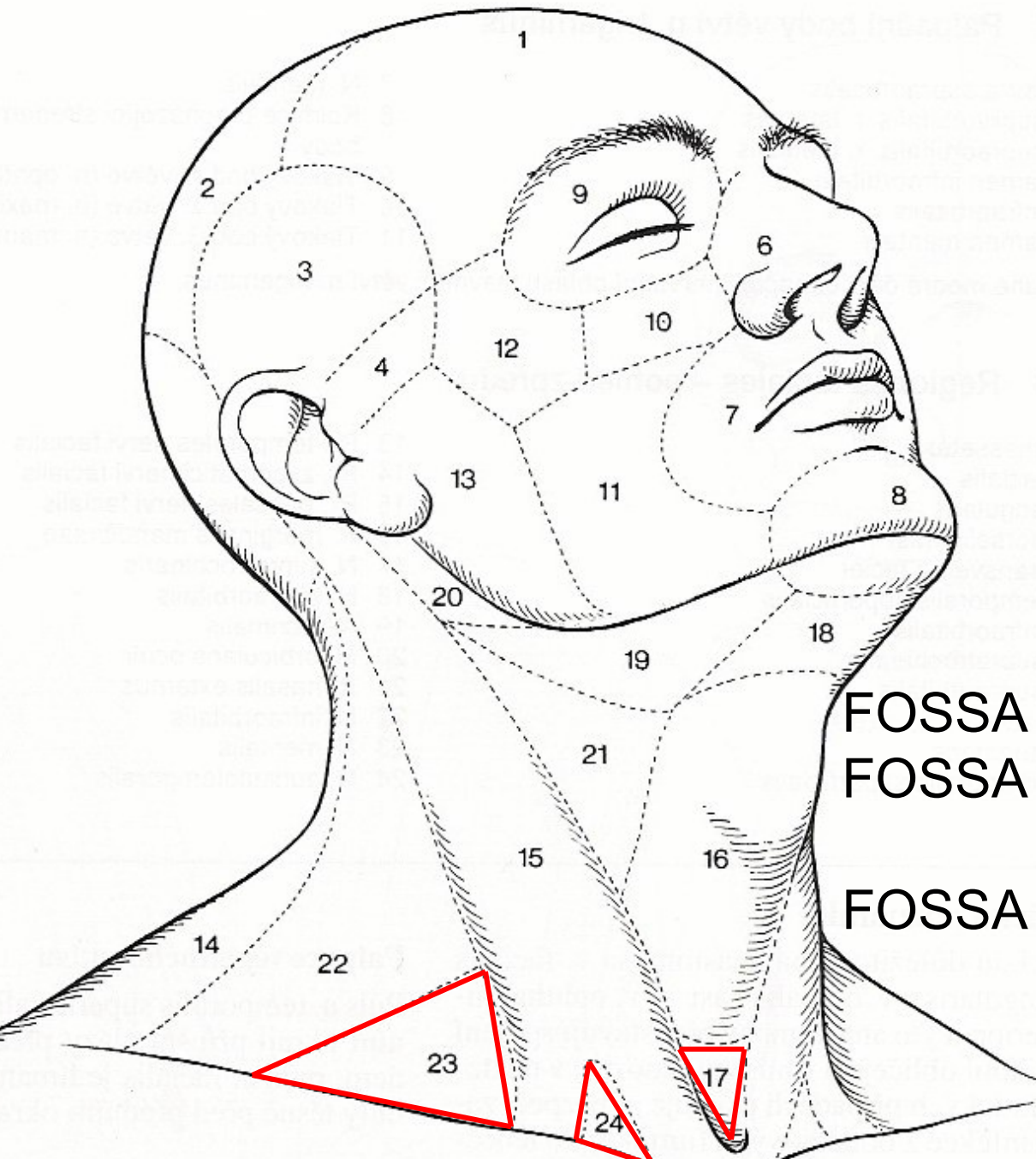
- TRIGONUM SUBMENTALE
- TRIGONUM SUBMANDIBULARE
- TRIGONUM CAROTICUM
- TRIGONUM MUSCULARE/
OMOTRACHEALE

**REGIO CERVICALIS LATERALIS)
(TRIGONUM CERVICALE LATERALE:**

- TRIGONUM OMOCLAVICULARE
(TRIGONUM OMOTRAPEZIUM)

- 1 – trigonum submentale
- 2 – trigonum submandibulare
- 3 – trigonum caroticum
- 4 – trigonum omotrpezium
- 5 – trigonum omoclaviculare
- 9 – trigonum omotracheale

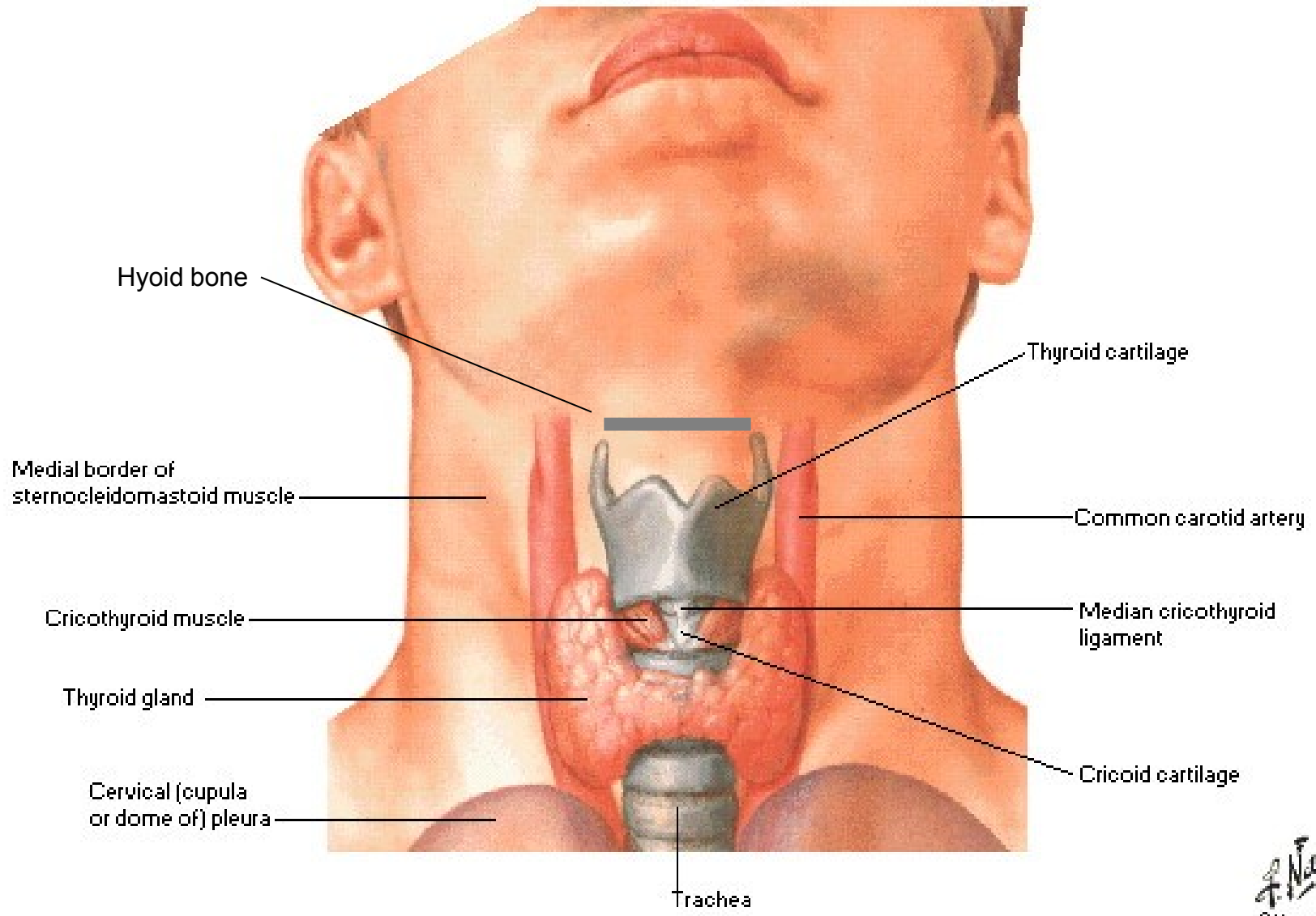


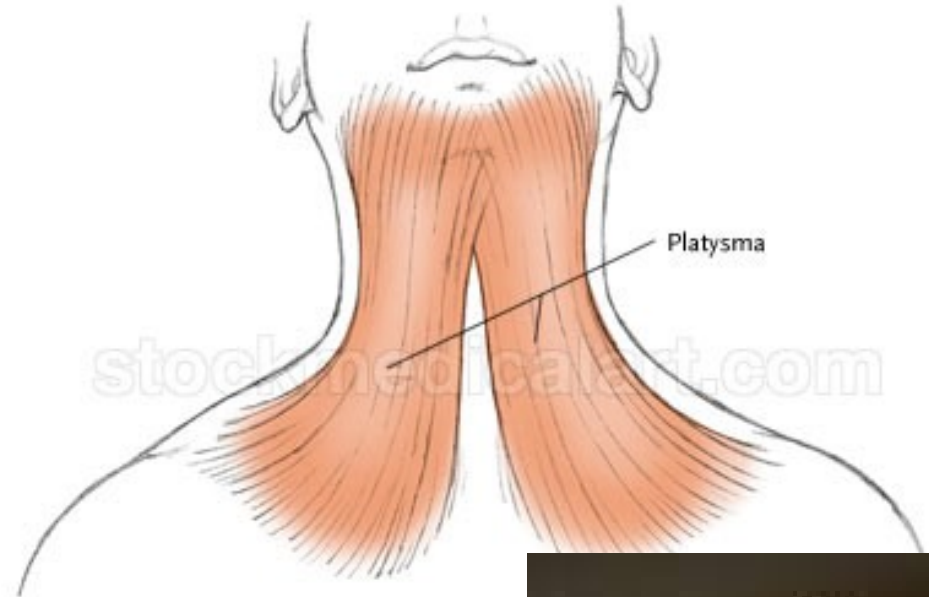
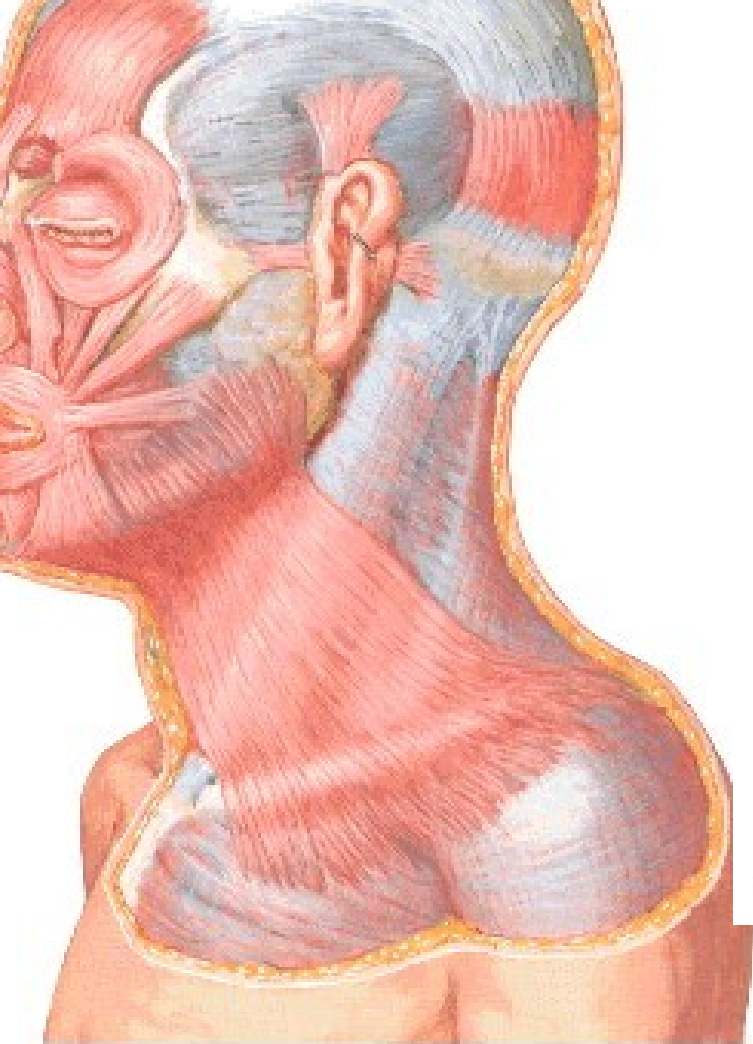


FOSSA JUGULARIS
FOSSA SUPRACLAVICULARIS
MINOR
FOSSA SUPRACLAVICULARIS
MAJOR

Thyroid Gland in Situ

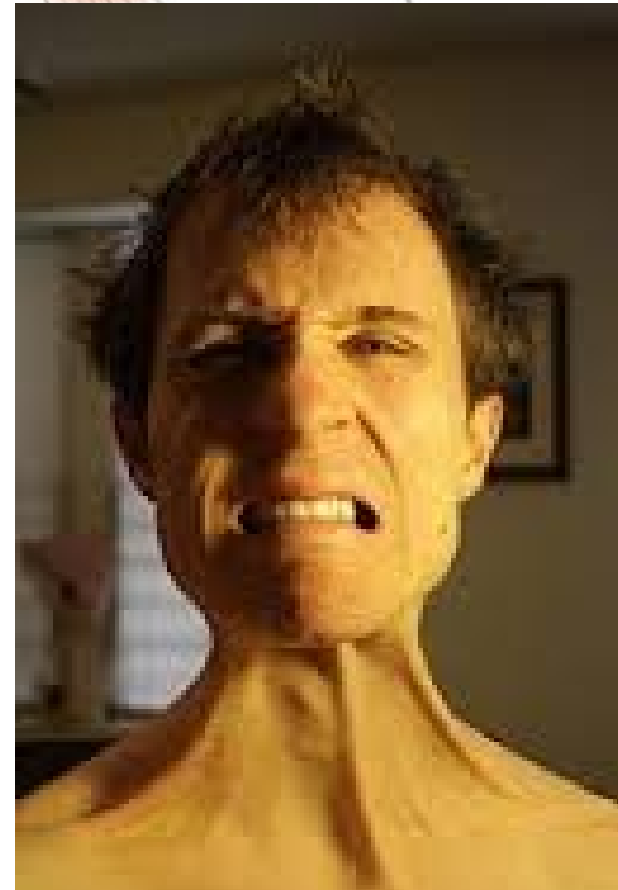Anterior View





© 2013 stockmedicalart.com

Novartis
©Novartis



PLATYSMA

Punctum nervosum (Erb)

N. OCCIPITALIS MINOR

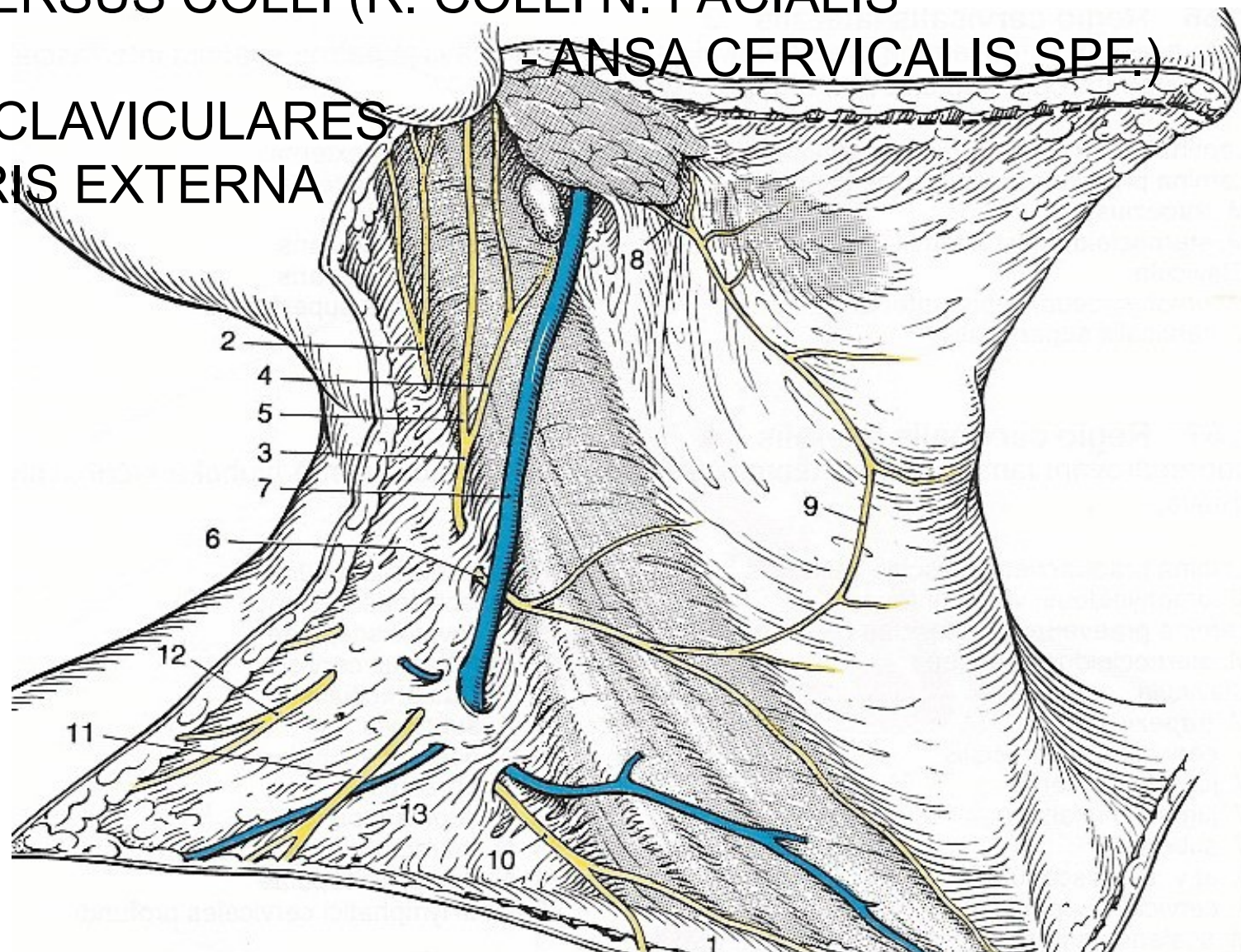
N. AURICULARIS MAGNUS

N. TRANSVERSUS COLLI (R. COLLI N. FACIALIS

- ANSA CERVICALIS SPF.)

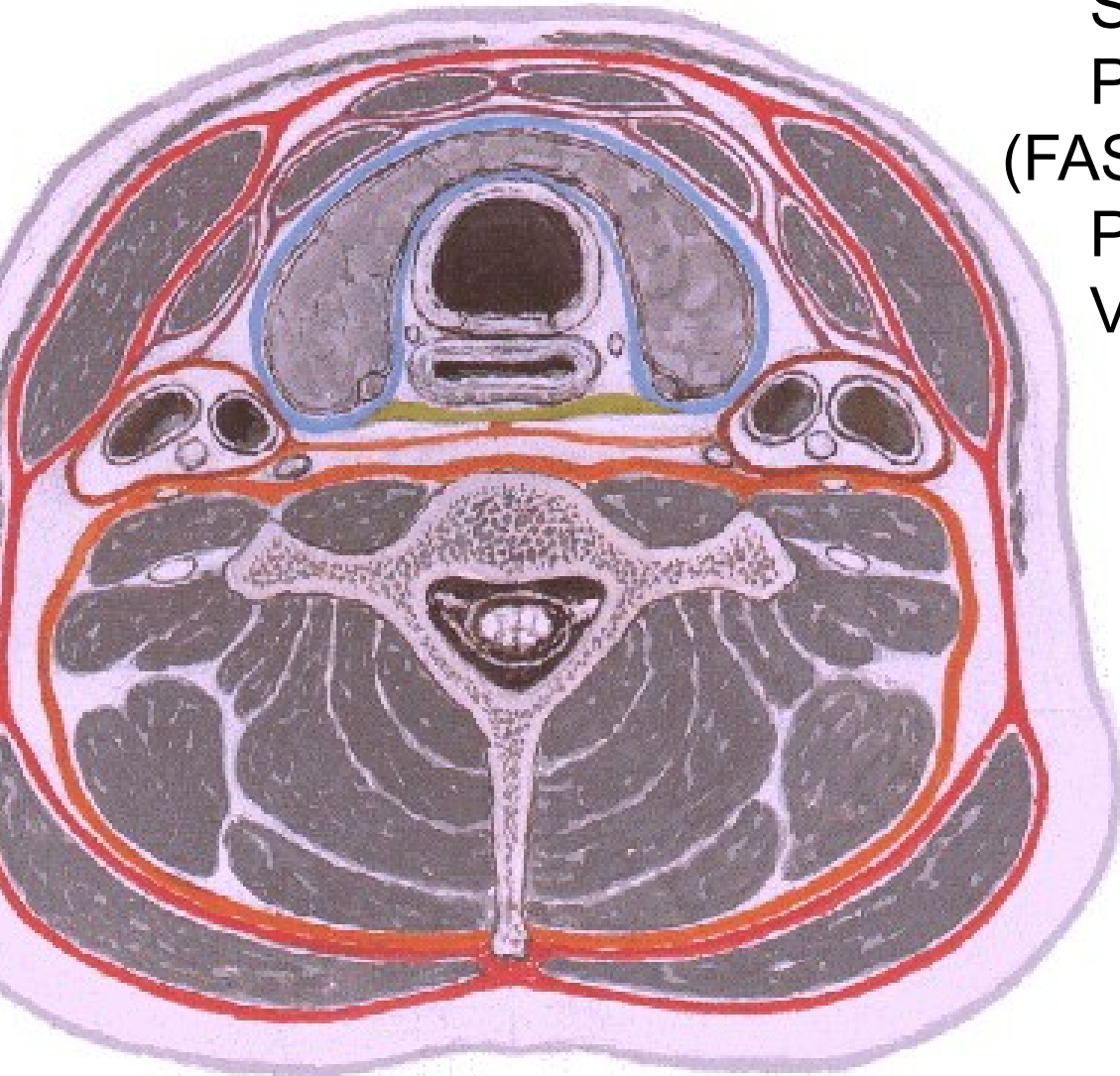
NN. SUPRACLAVICULARES

V. JUGULARIS EXTERNA



Fascial Layers of Neck

Cross Section



FASCIA CERVICALIS:

LAMINA

SUPERFICIALIS

PRAETRACHEALIS

(FASCIA BUCCOPHARYNGEA)

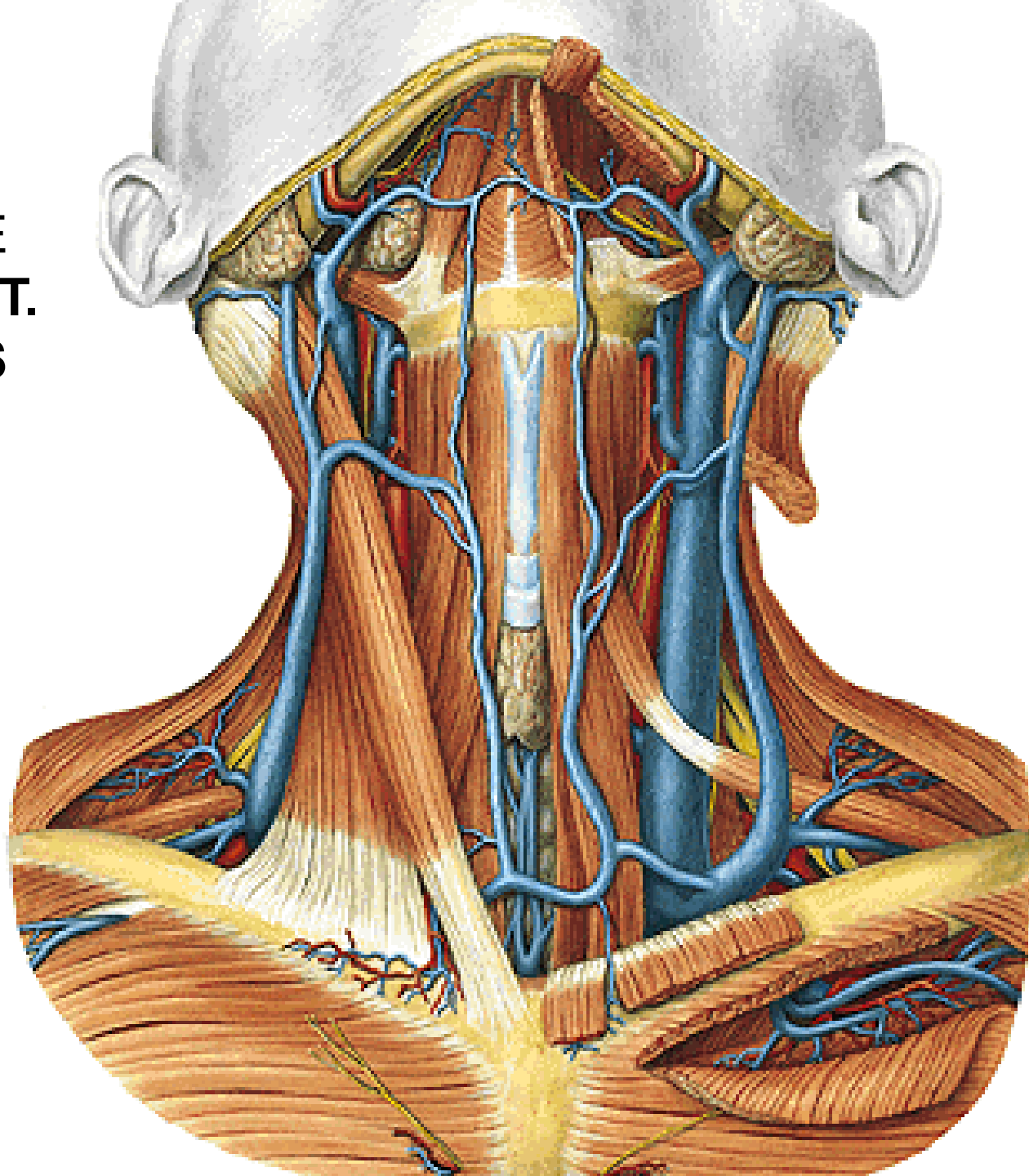
PRAEVERTEBRALIS

VAGINA CAROTICA

SPATIUM

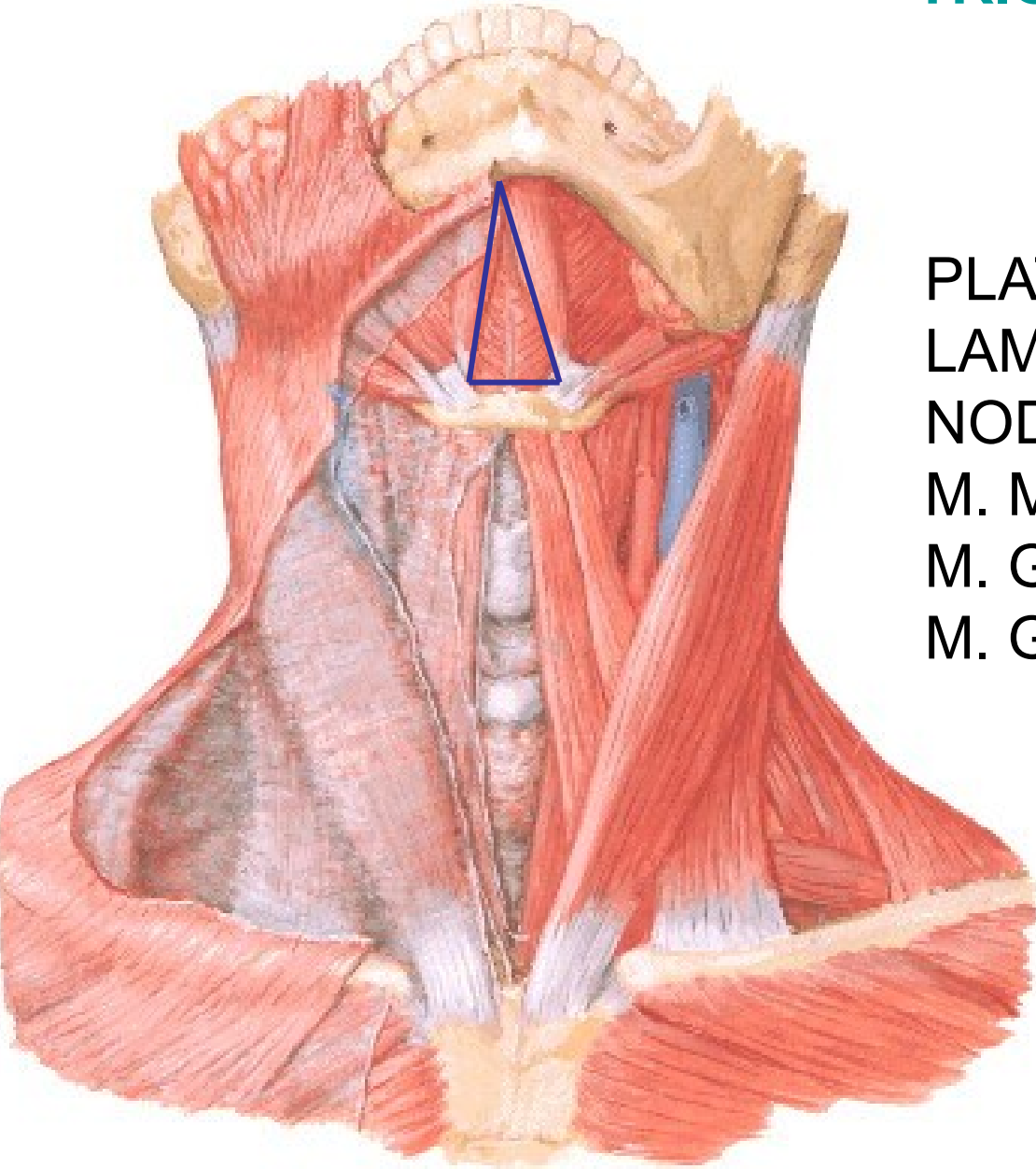
RETROPHARYNGEALE

**SPATIUM
SUPRASTERNALE
V. JUGULARIS ANT.
ARCUS VENOSUS
JUGULI**



Anterior View

TRIGONUM SUBMENTALE



PLATYSMA

LAMINA SPF. FASCIAE CERVICIS

NODI LYMPH. SUBMENTALES

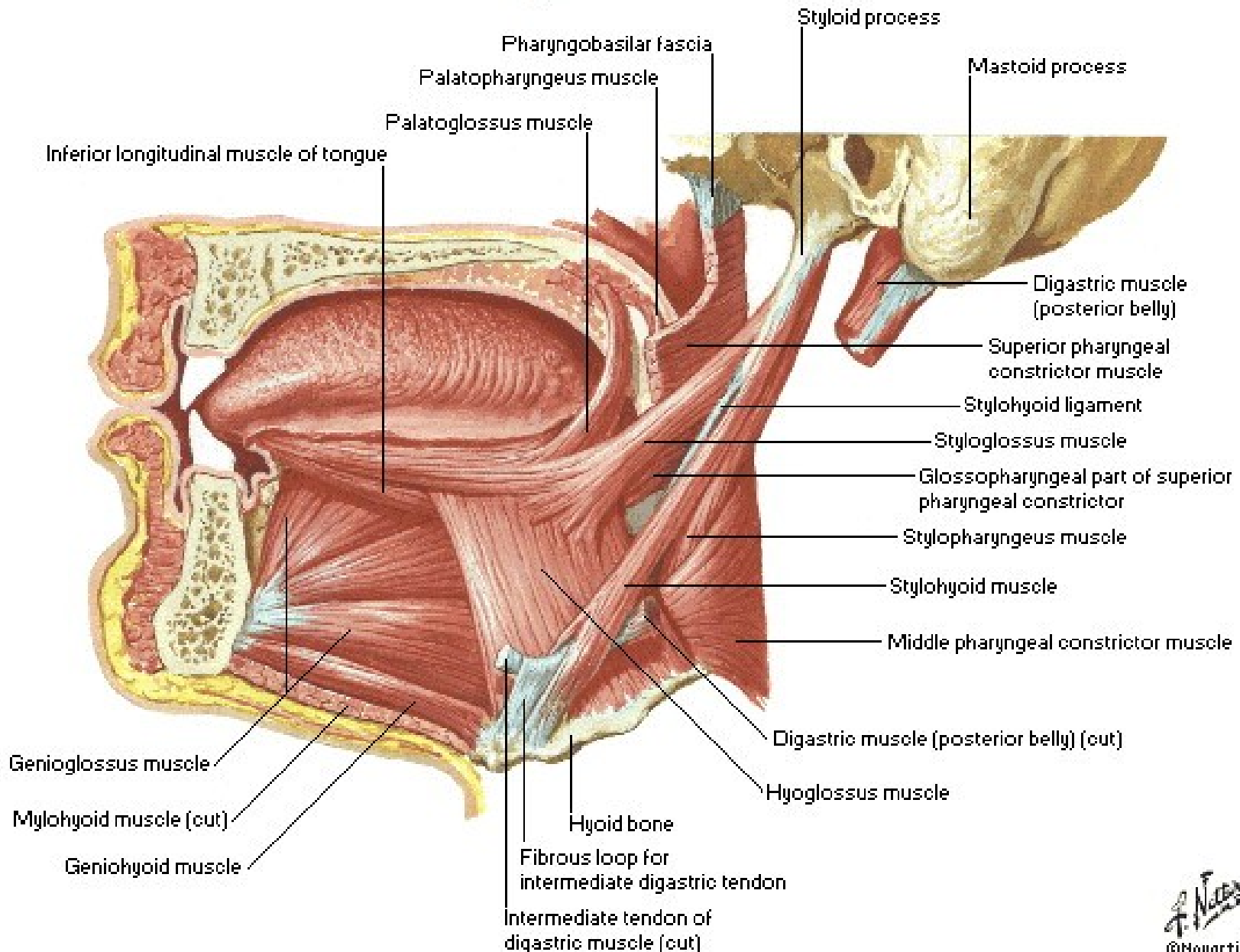
M. MYLOHYOIDEUS

M. GENIOHYOIDEUS

M. GENIOGLOSSUS

Muscles of Tongue

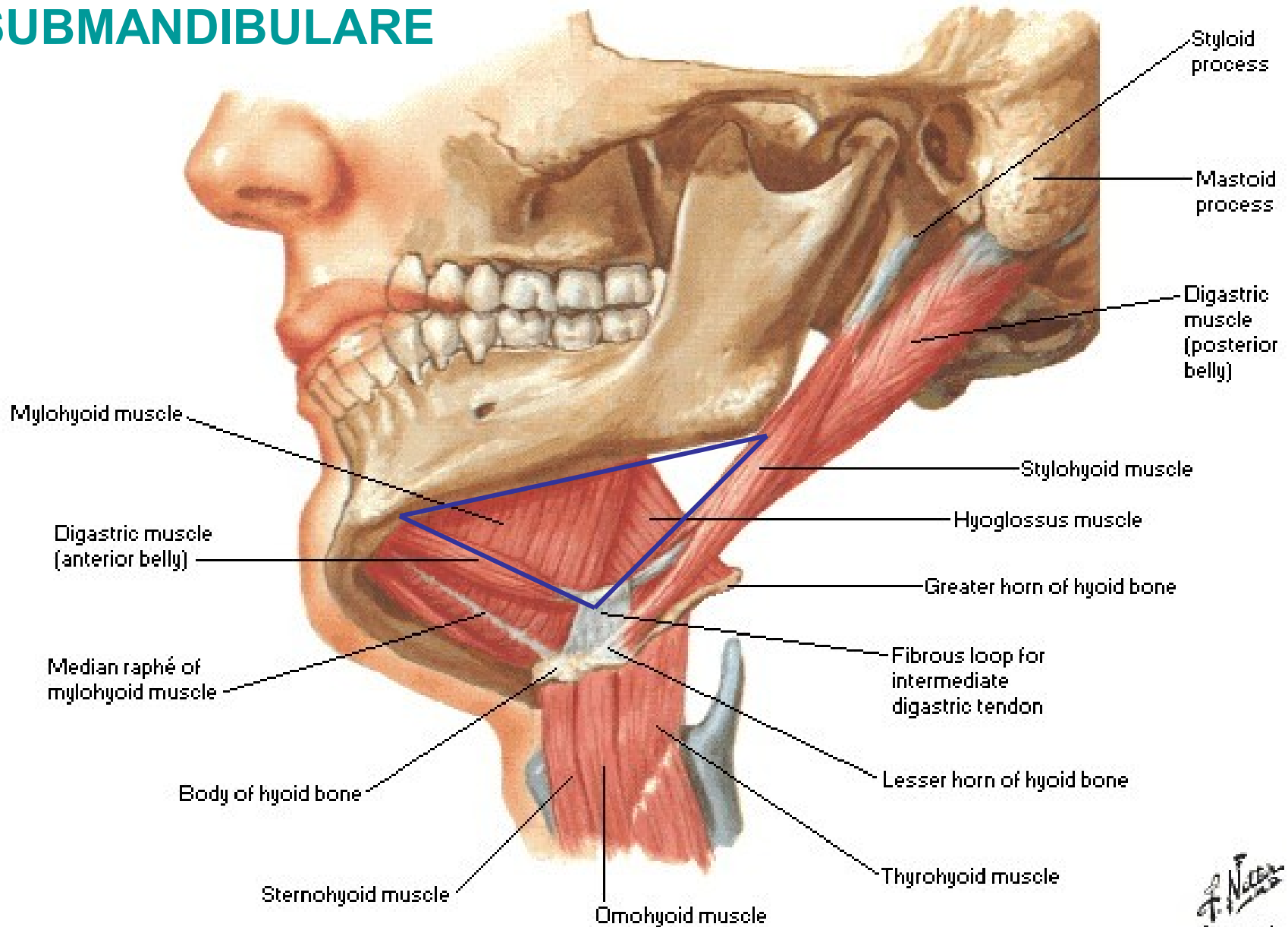
Sagittal Section

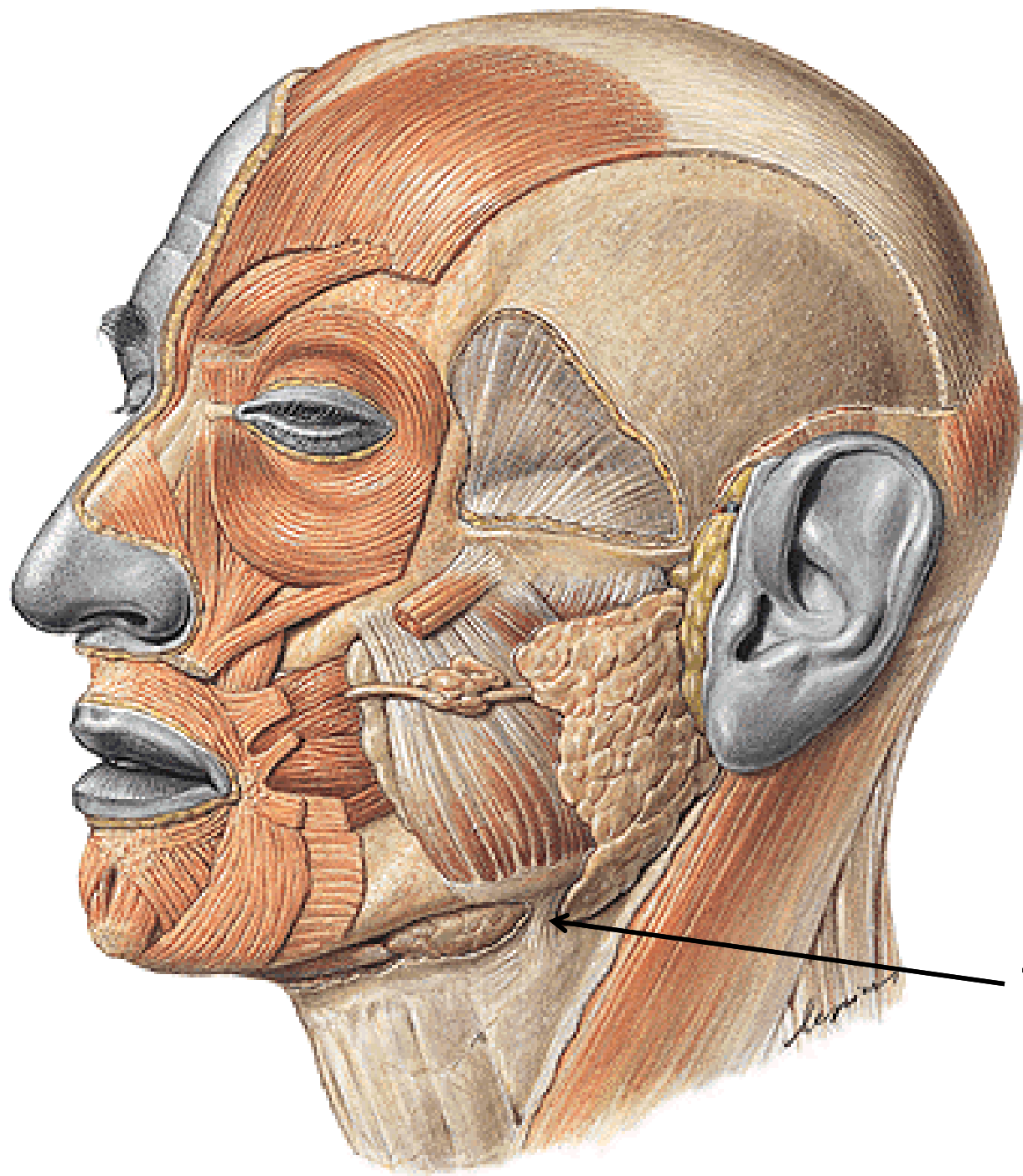


Floor of Mouth - Musculature

Lateral, Slightly Inferior View

TRIGONUM SUBMANDIBULARE

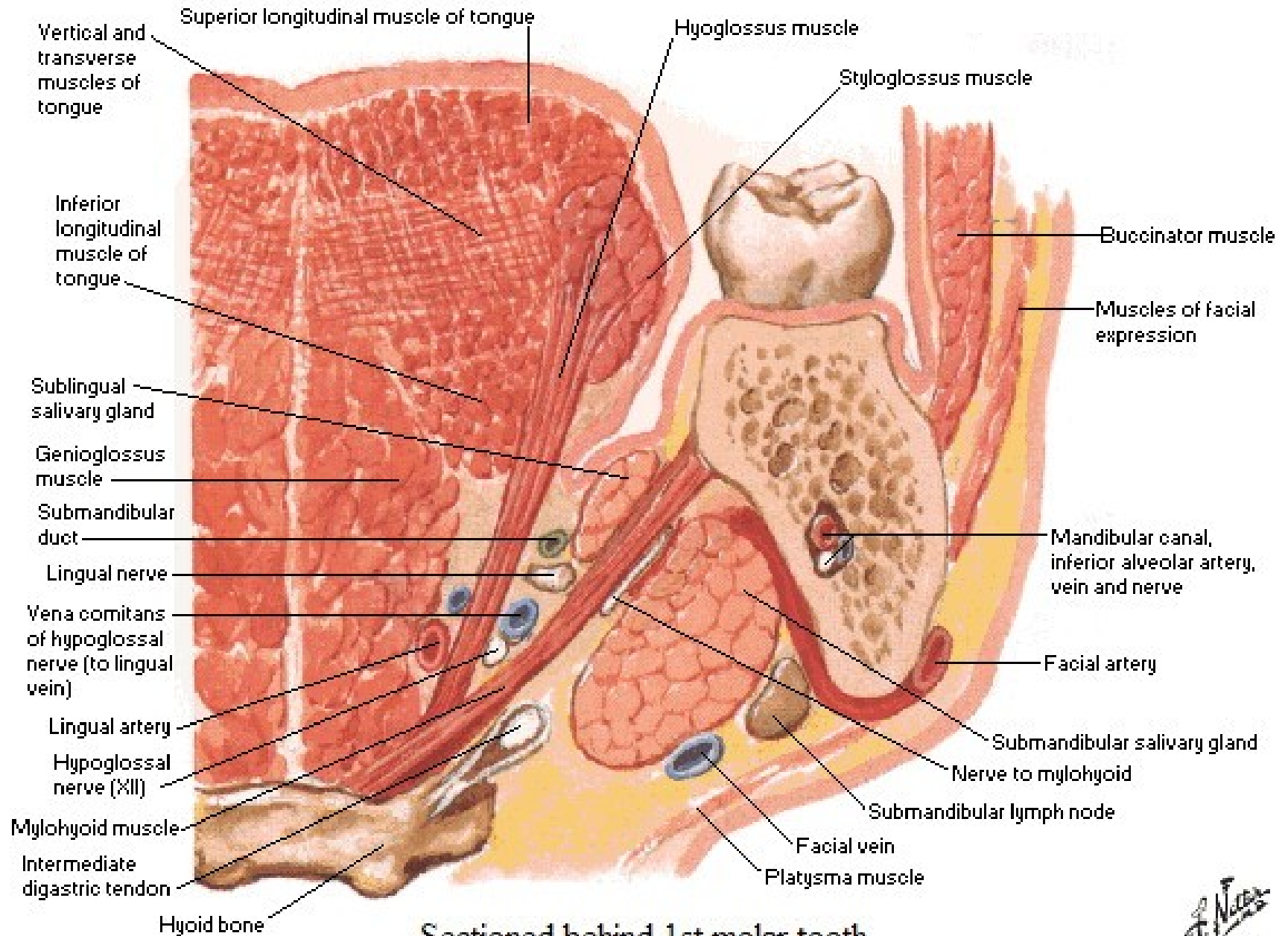


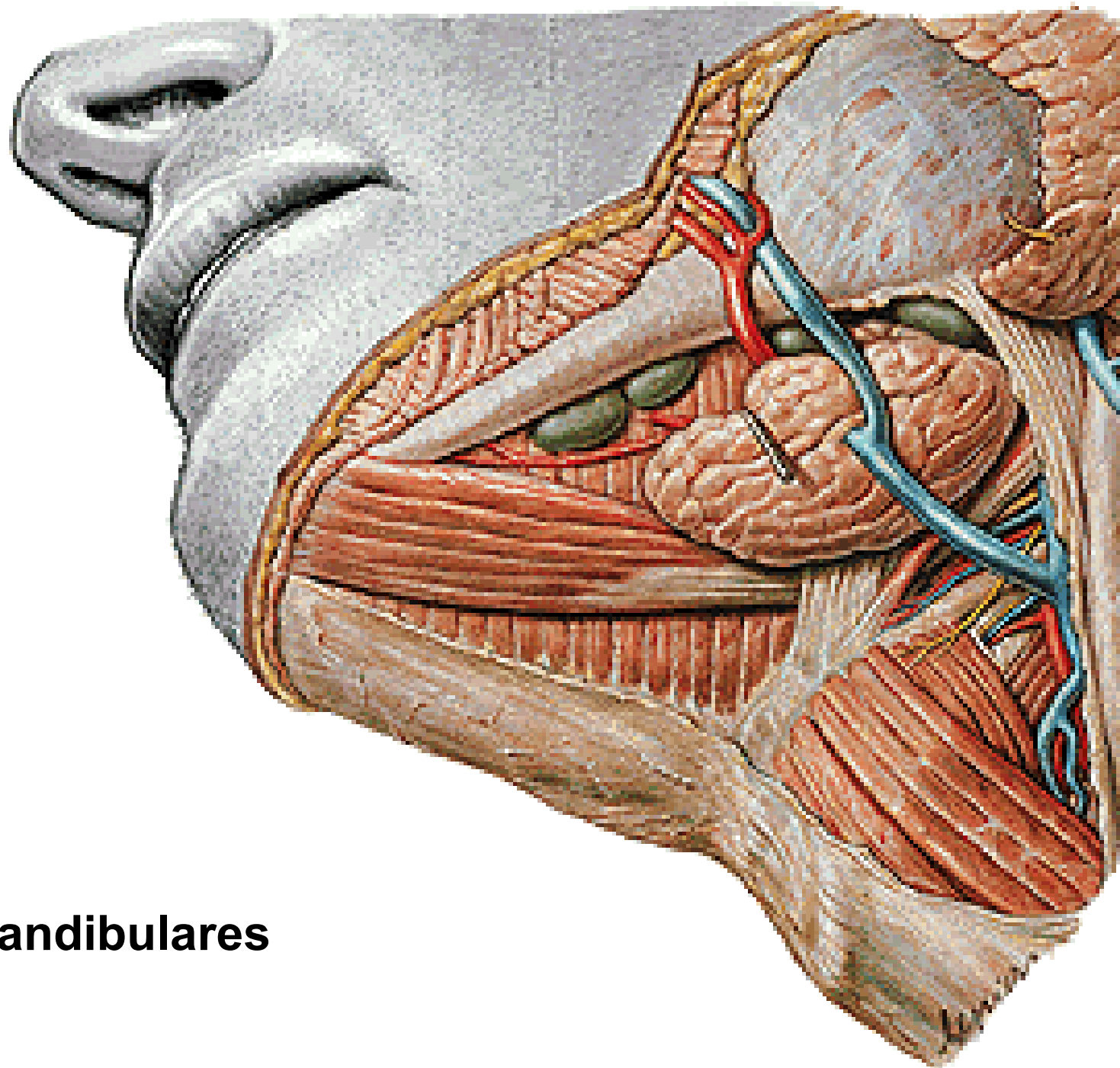


TRACTUS
ANGULARIS

Tongue and Mouth

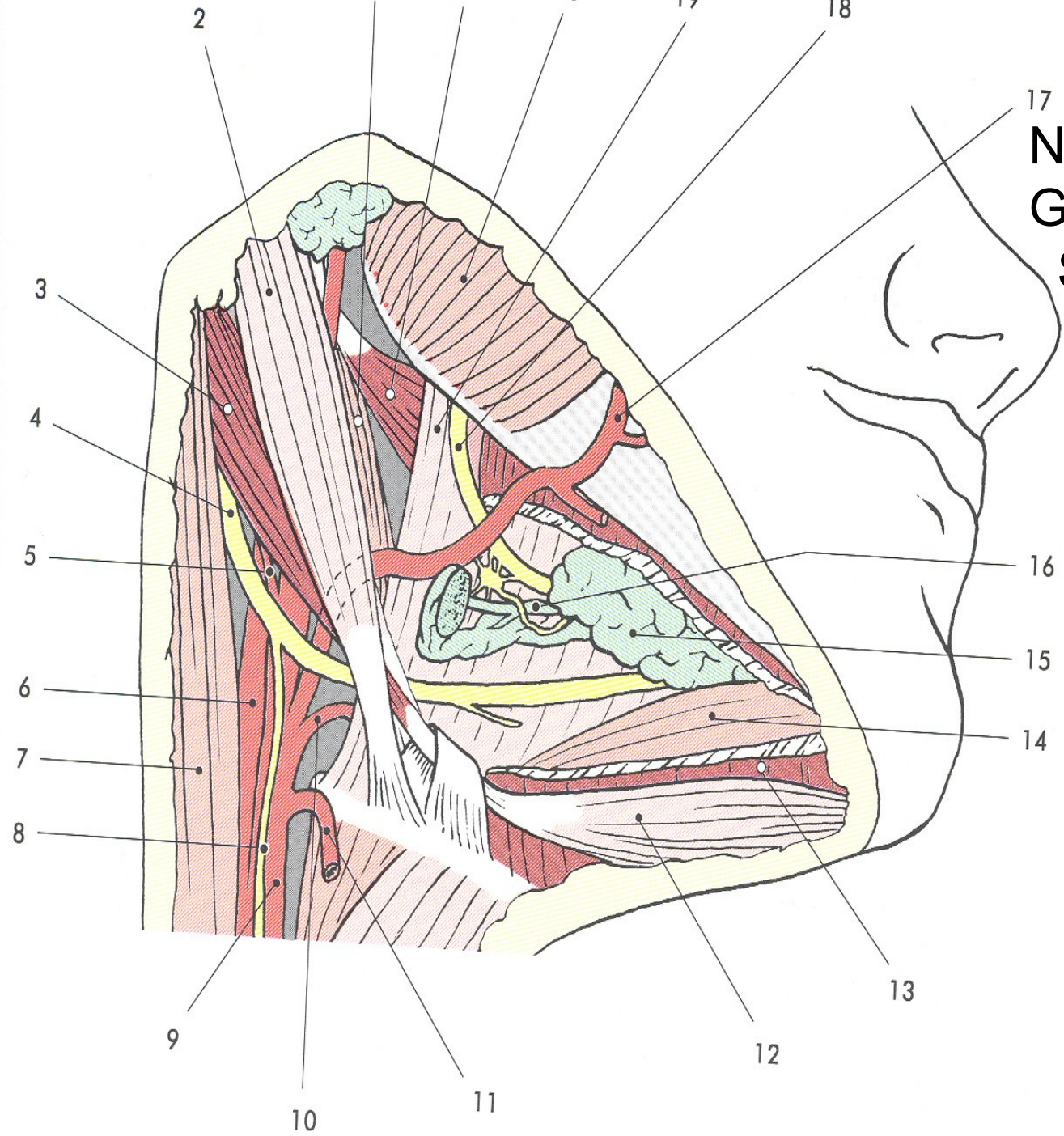
Frontal Section - Anterior View

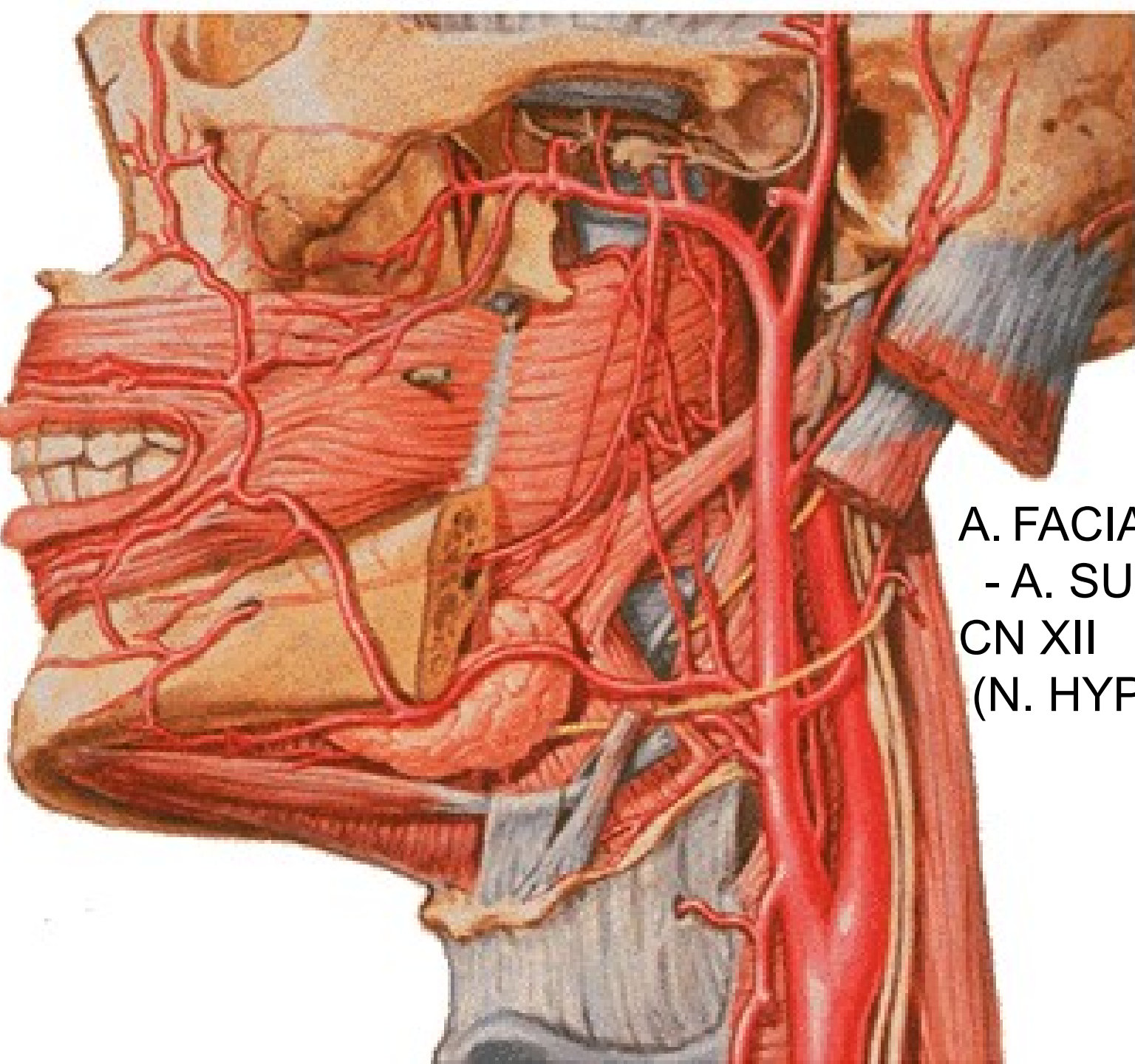




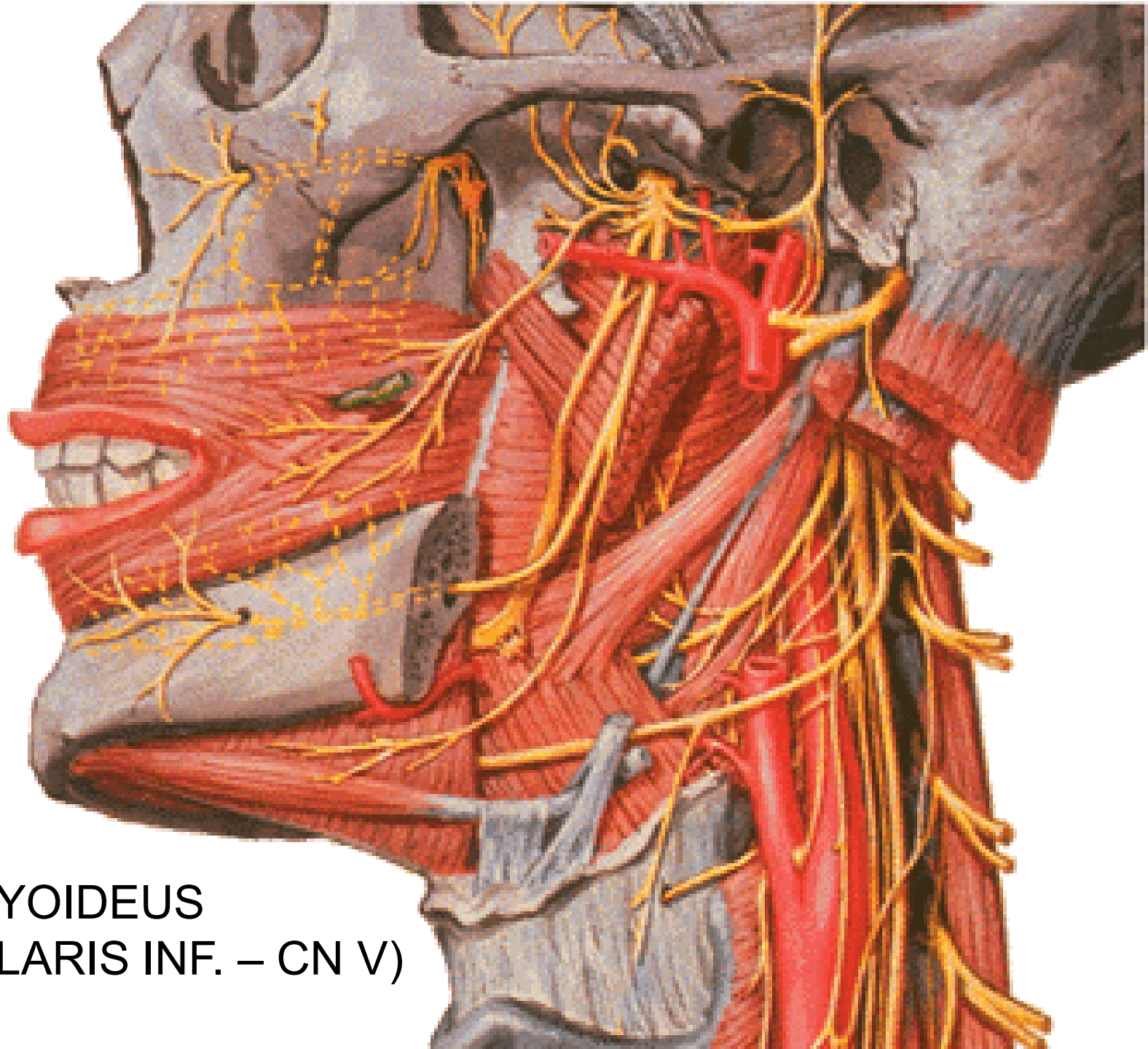
III. submandibulares

17
N. LINGUALIS
GANGLION
SUBMANDIBULARE



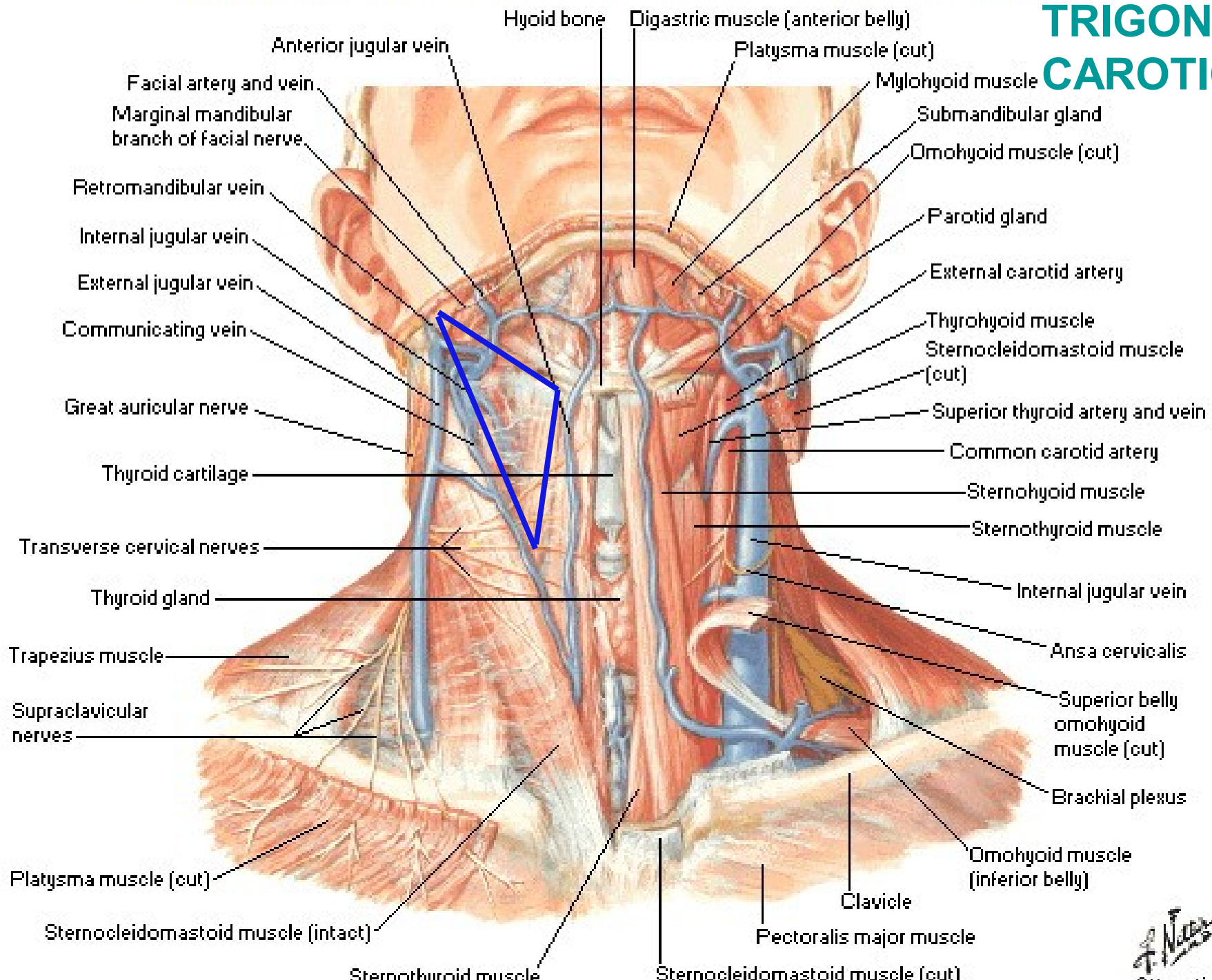


A. FACIALIS
- A. SUBMENTALIS
CN XII
(N. HYPOGLOSSUS)

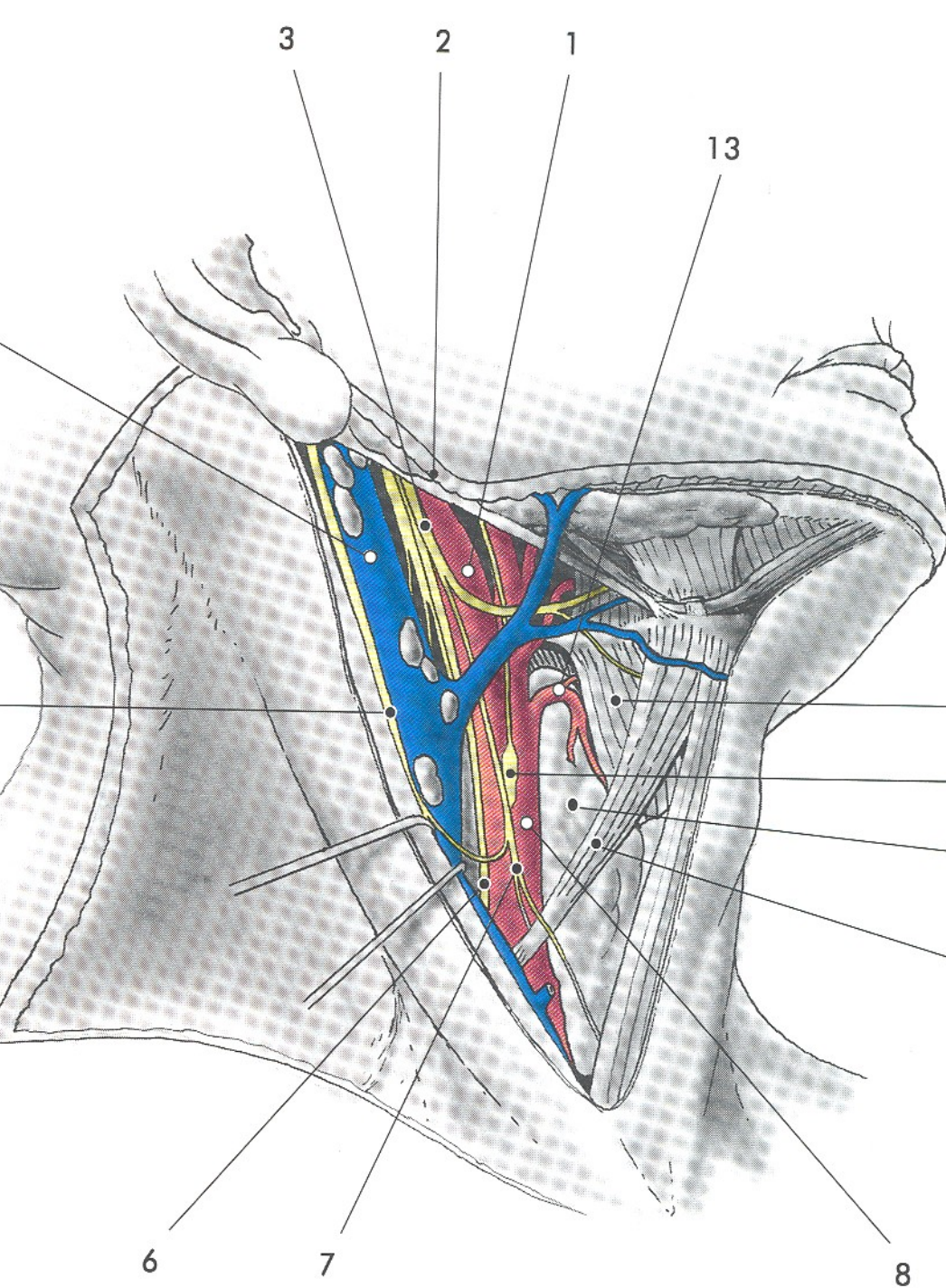


N. MYLOHYOIDEUS
(N. ALVEOLARIS INF. – CN V)

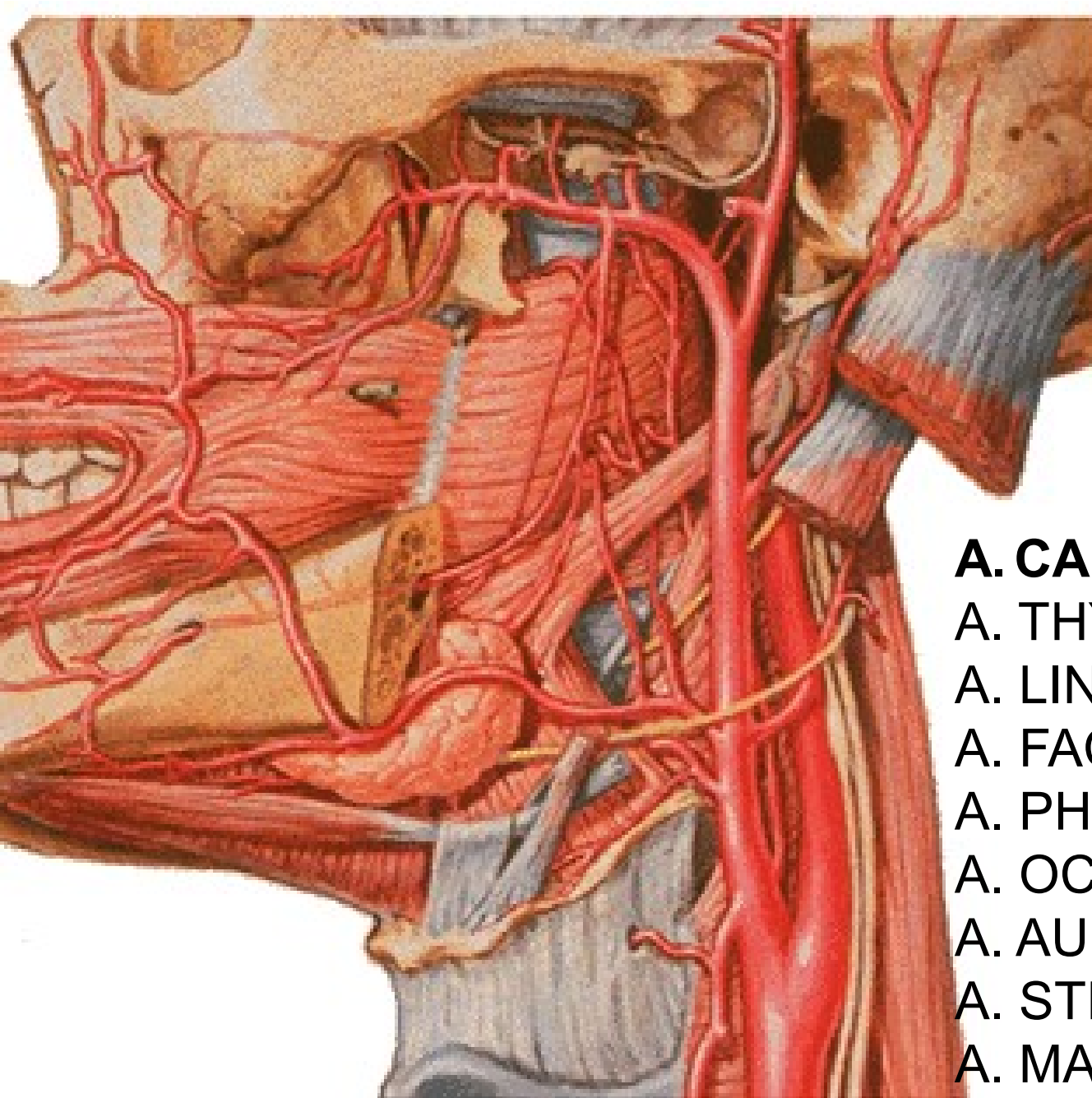
TRIGONUM CAROTICUM



F. Netter



CONTENTS:
 V. FACIALIS
 V. JUGULARIS INT.
 NL. CERVICALES PROF.
 A. CAROTIS COMM.-
 EXT.+INT.
 N. VAGUS
 N. HYPOGLOSSUS
 ANSA CERVICALIS PROF.
 GLOMUS CAROTICUM
 SINUS CAROTICUS



A. CAROTIS EXT:

A. THYROIDEA SUP.

A. LINGUALIS

A. FACIALIS

A. PHARYNGEA ASC.

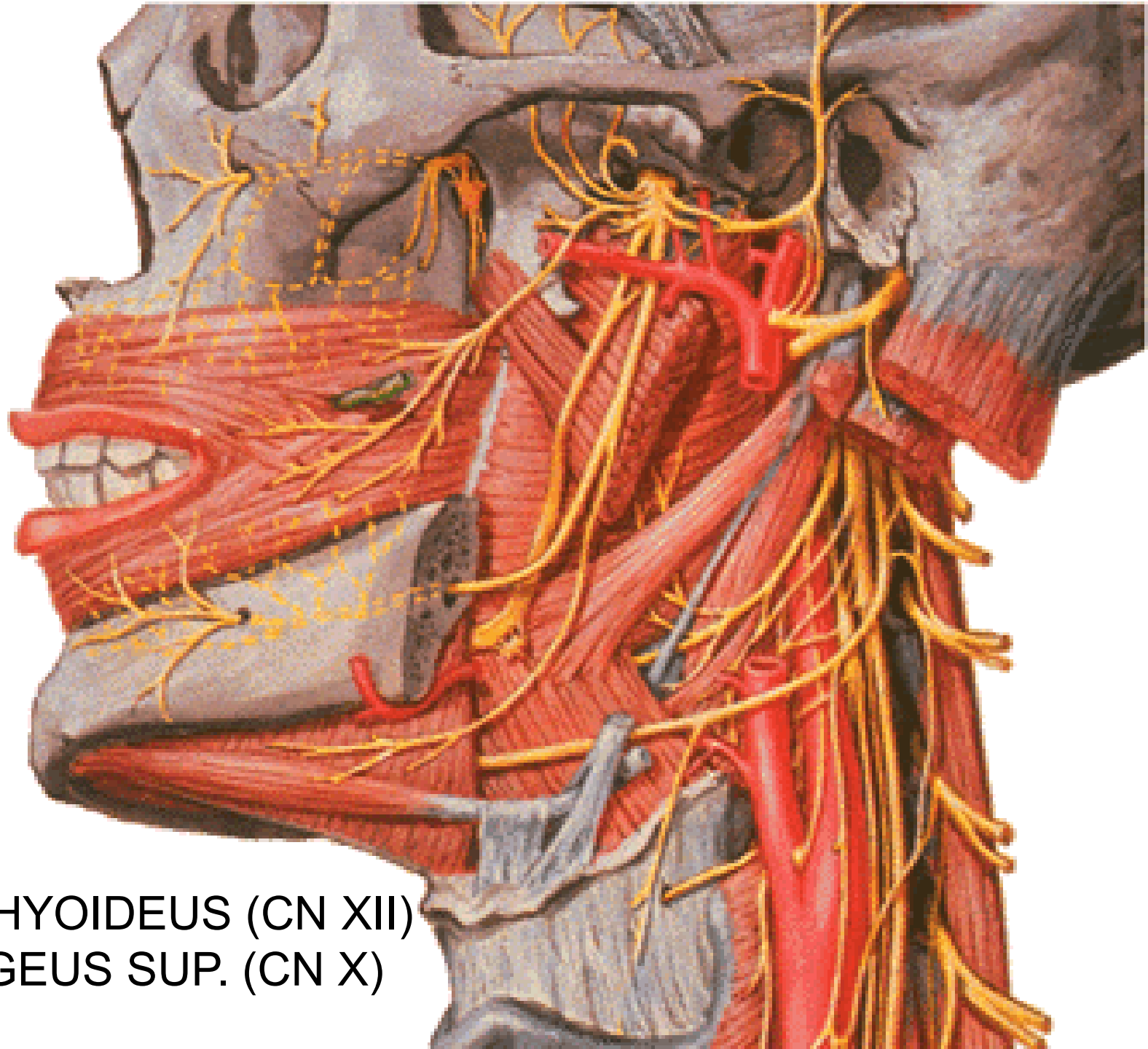
A. OCCIPITALIS

A. AURICULARIS POST.

A. STERNOCLEIDOMAST

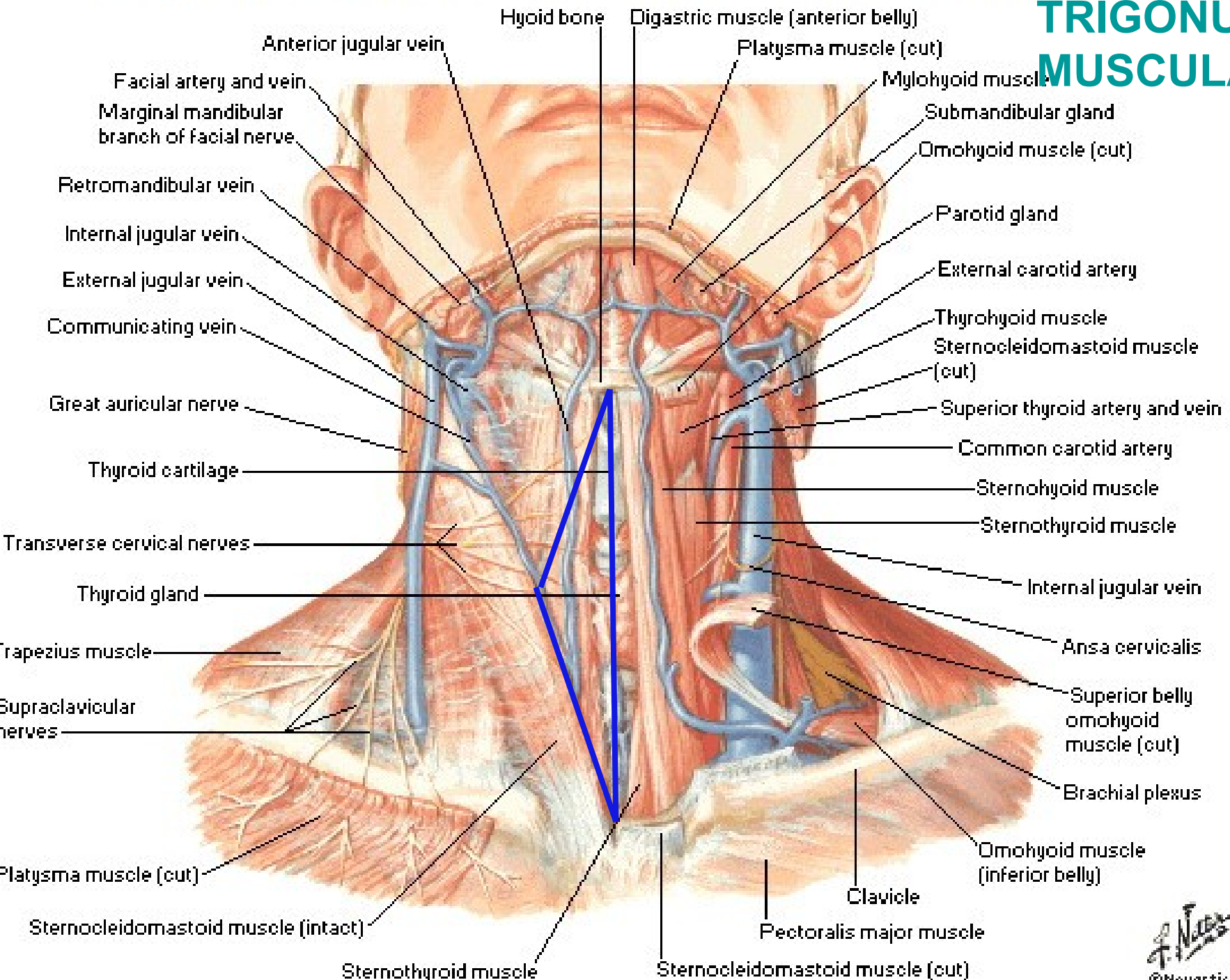
A. MAXILLARIS

A. TEMPORALIS SPF.

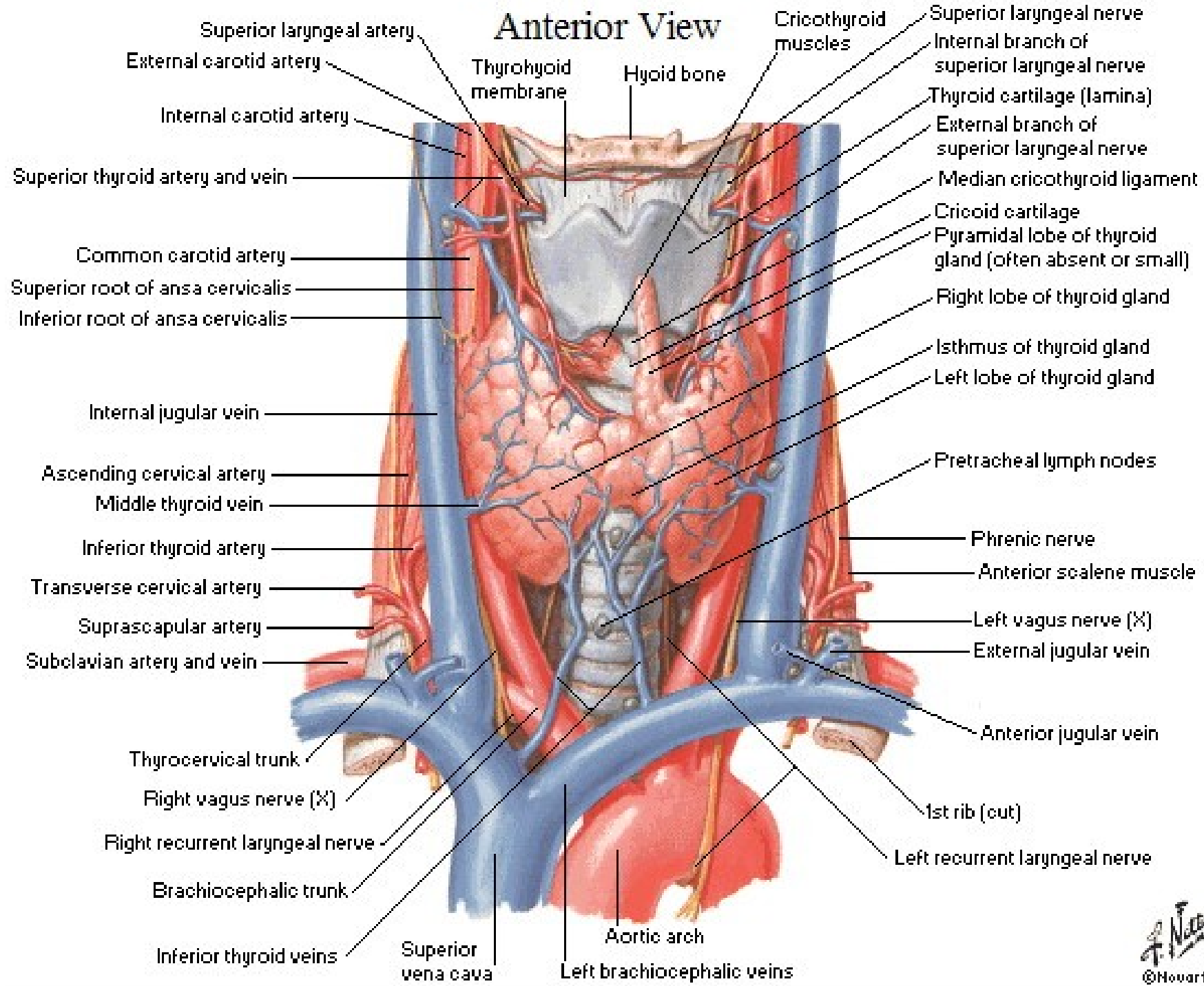


R. THYROHYOIDEUS (CN XII)
N. LARYNGEUS SUP. (CN X)

TRIGONUM MUSCULARE



Anterior View



Superior laryngeal artery
 External carotid artery
 Internal carotid artery

Thyroid membrane
 Hyoid bone

Cricothyroid muscles

Superior laryngeal nerve
 Internal branch of superior laryngeal nerve
 Thyroid cartilage (lamina)
 External branch of superior laryngeal nerve
 Median cricothyroid ligament
 Cricoid cartilage
 Pyramidal lobe of thyroid gland (often absent or small)
 Right lobe of thyroid gland

Superior thyroid artery and vein
 Common carotid artery
 Superior root of ansa cervicalis
 Inferior root of ansa cervicalis

Isthmus of thyroid gland
 Left lobe of thyroid gland

Internal jugular vein

Pretracheal lymph nodes

Ascending cervical artery
 Middle thyroid vein

Phrenic nerve
 Anterior scalene muscle

Inferior thyroid artery
 Transverse cervical artery

Left vagus nerve (X)
 External jugular vein

Suprascapular artery
 Subclavian artery and vein

Anterior jugular vein

Thyrocervical trunk
 Right vagus nerve (X)

1st rib (cut)

Right recurrent laryngeal nerve

Left recurrent laryngeal nerve

Brachiocephalic trunk

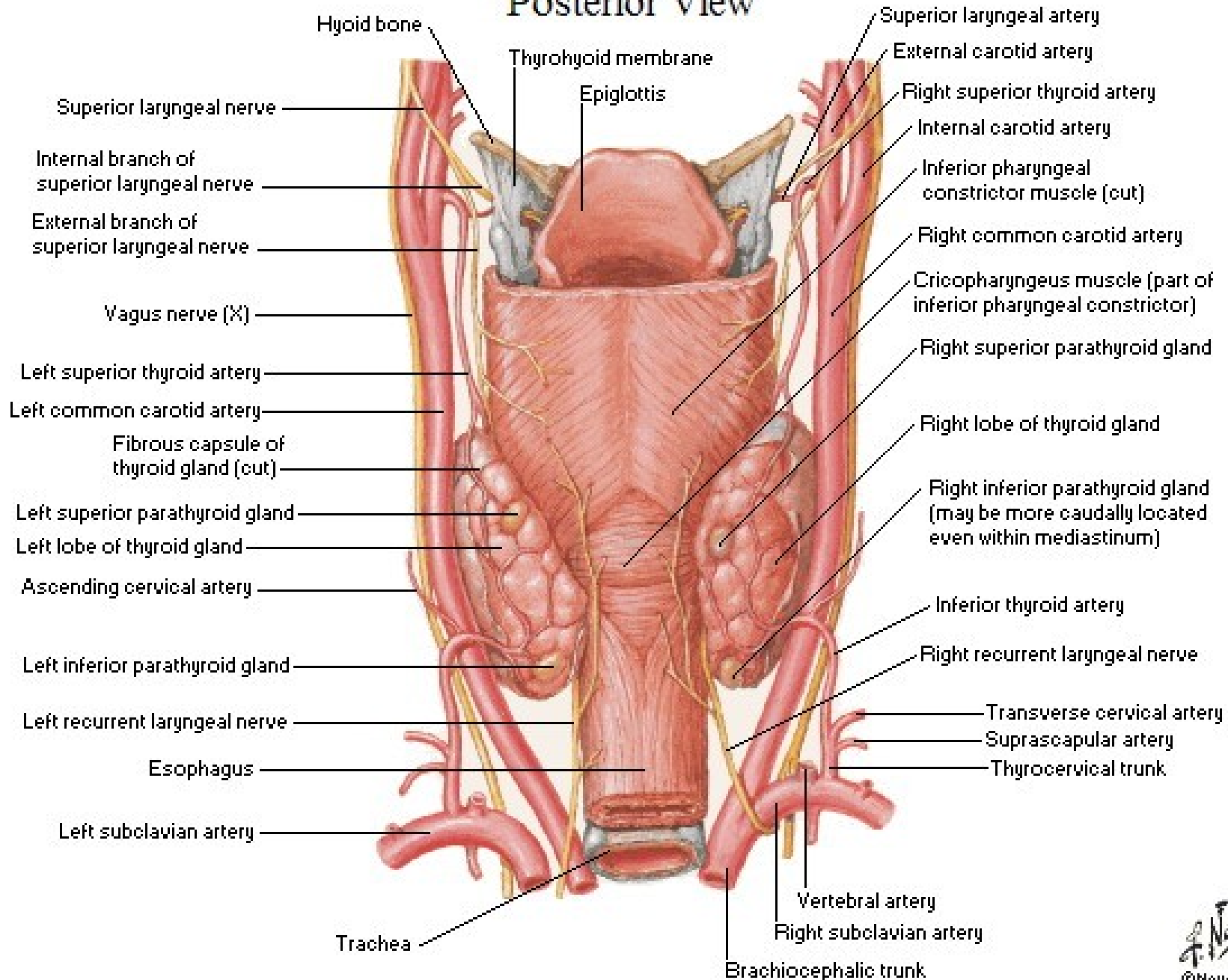
Aortic arch

Inferior thyroid veins
 Superior vena cava

Left brachiocephalic veins

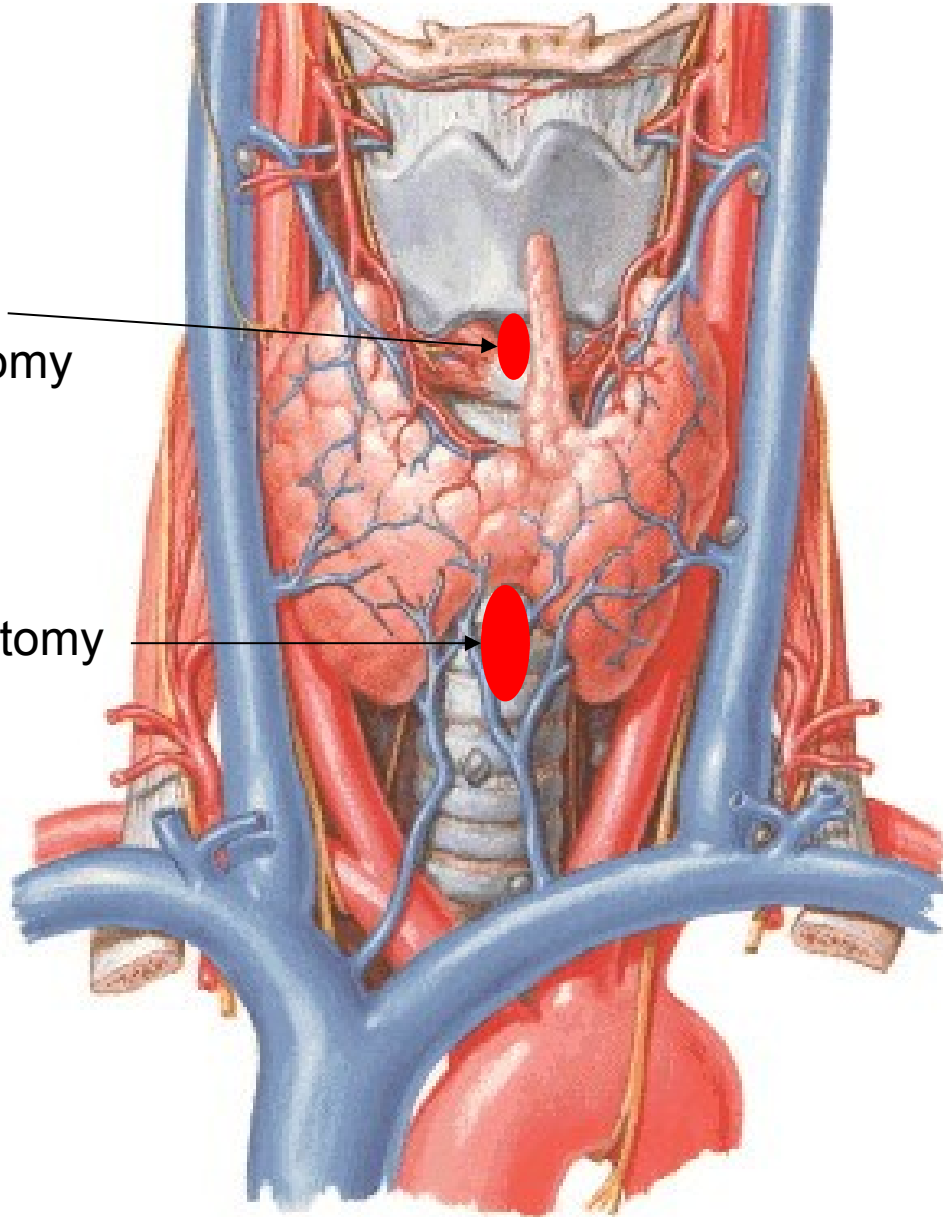
Parathyroid Glands

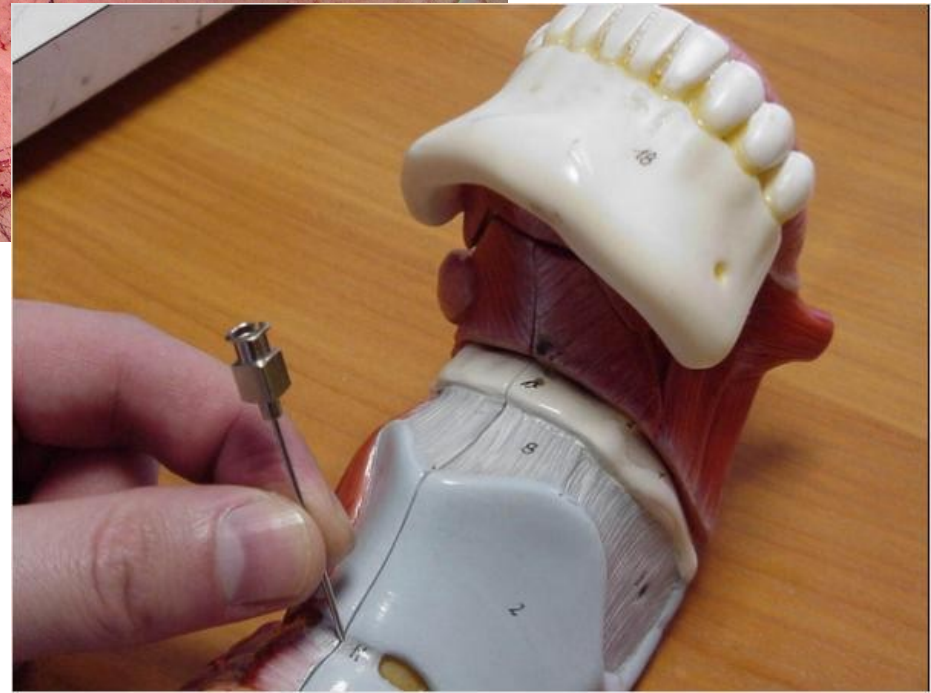
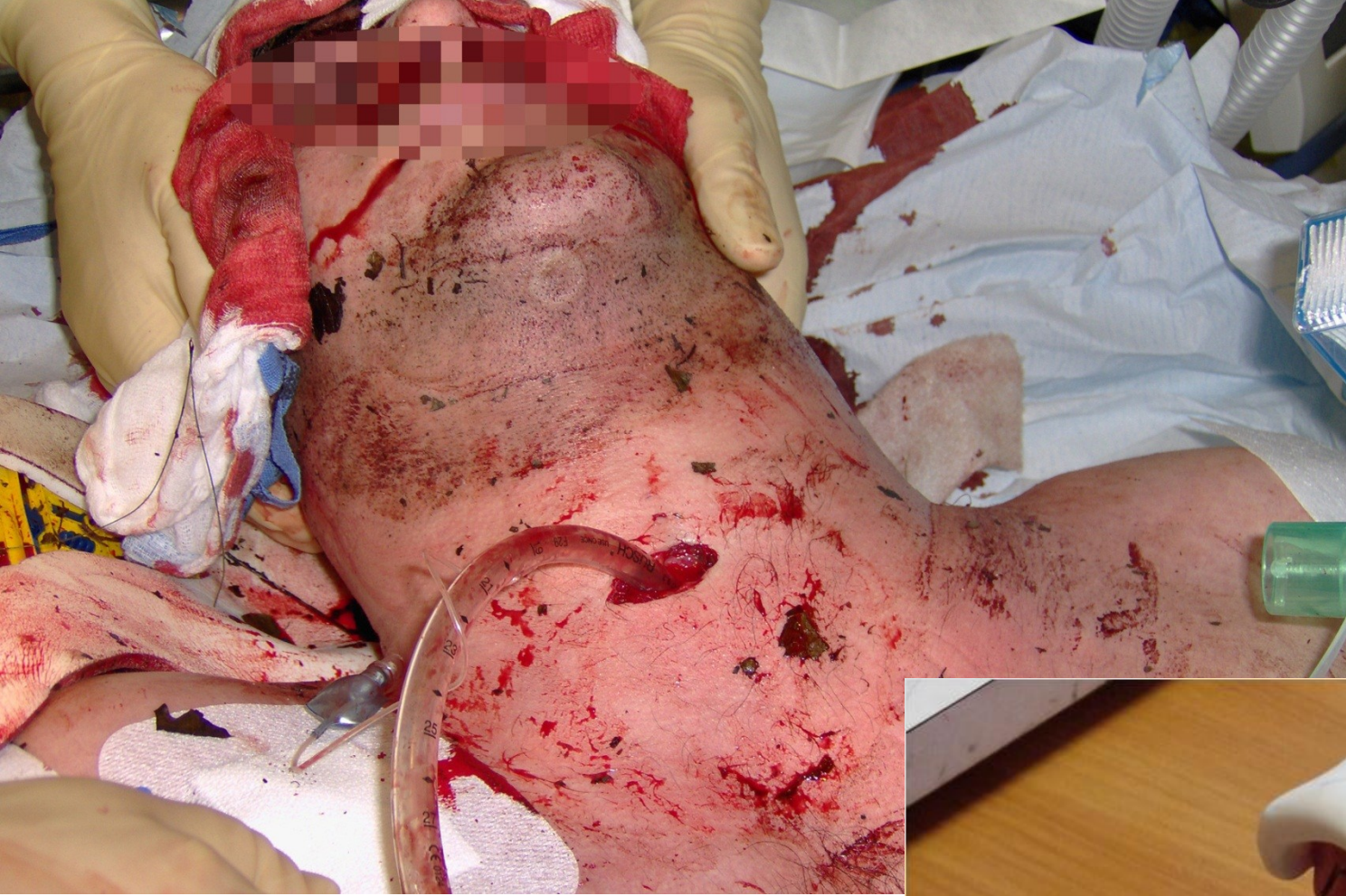Posterior View

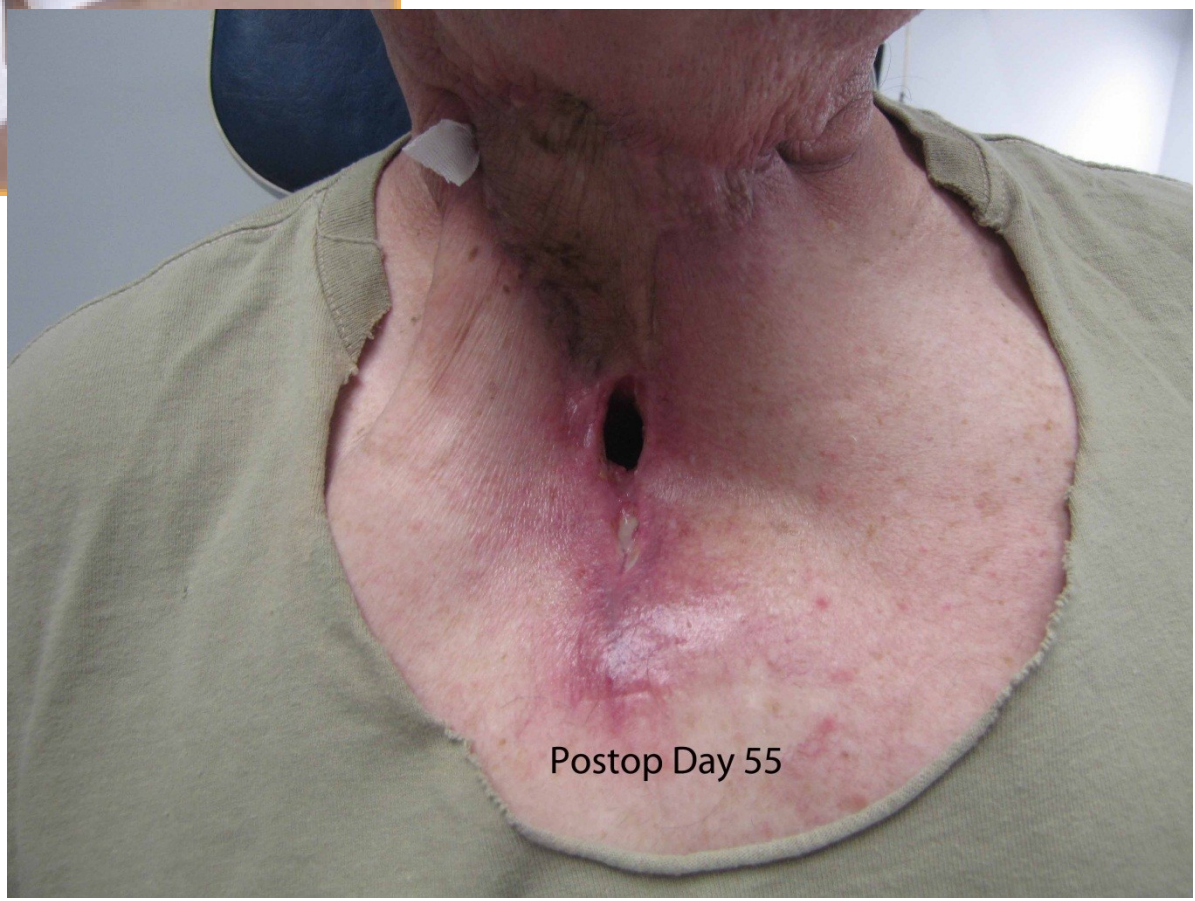
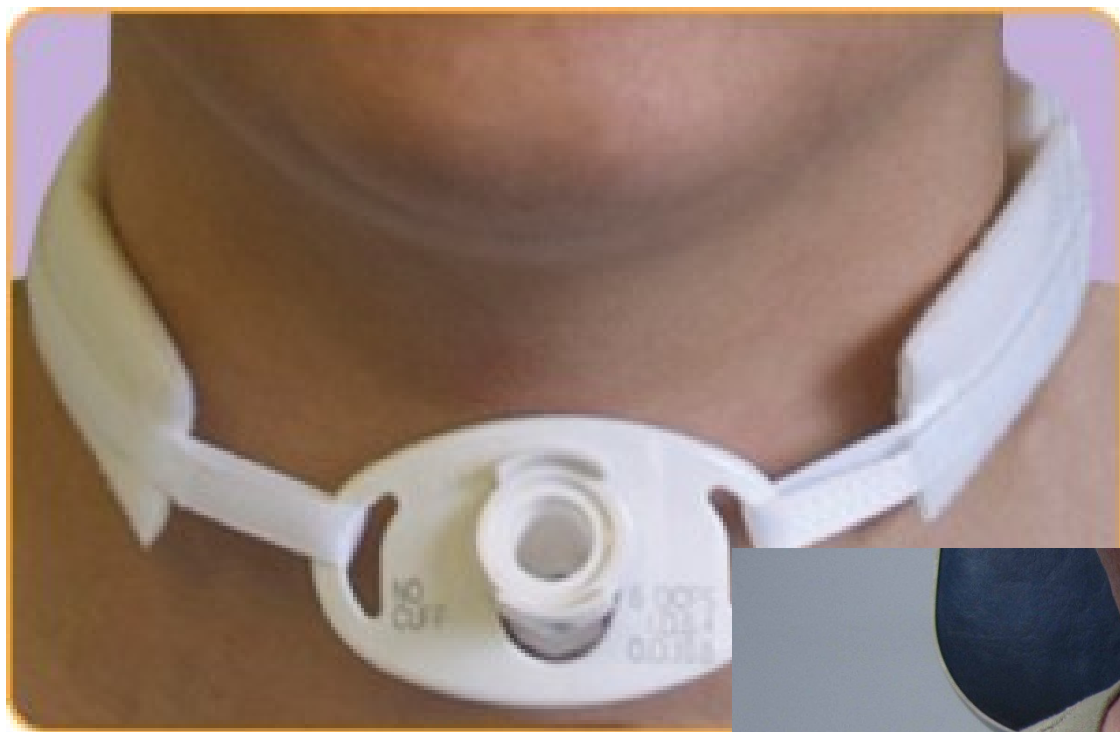
Coniotomy/
Cricothyrotomy

Inferior tracheotomy

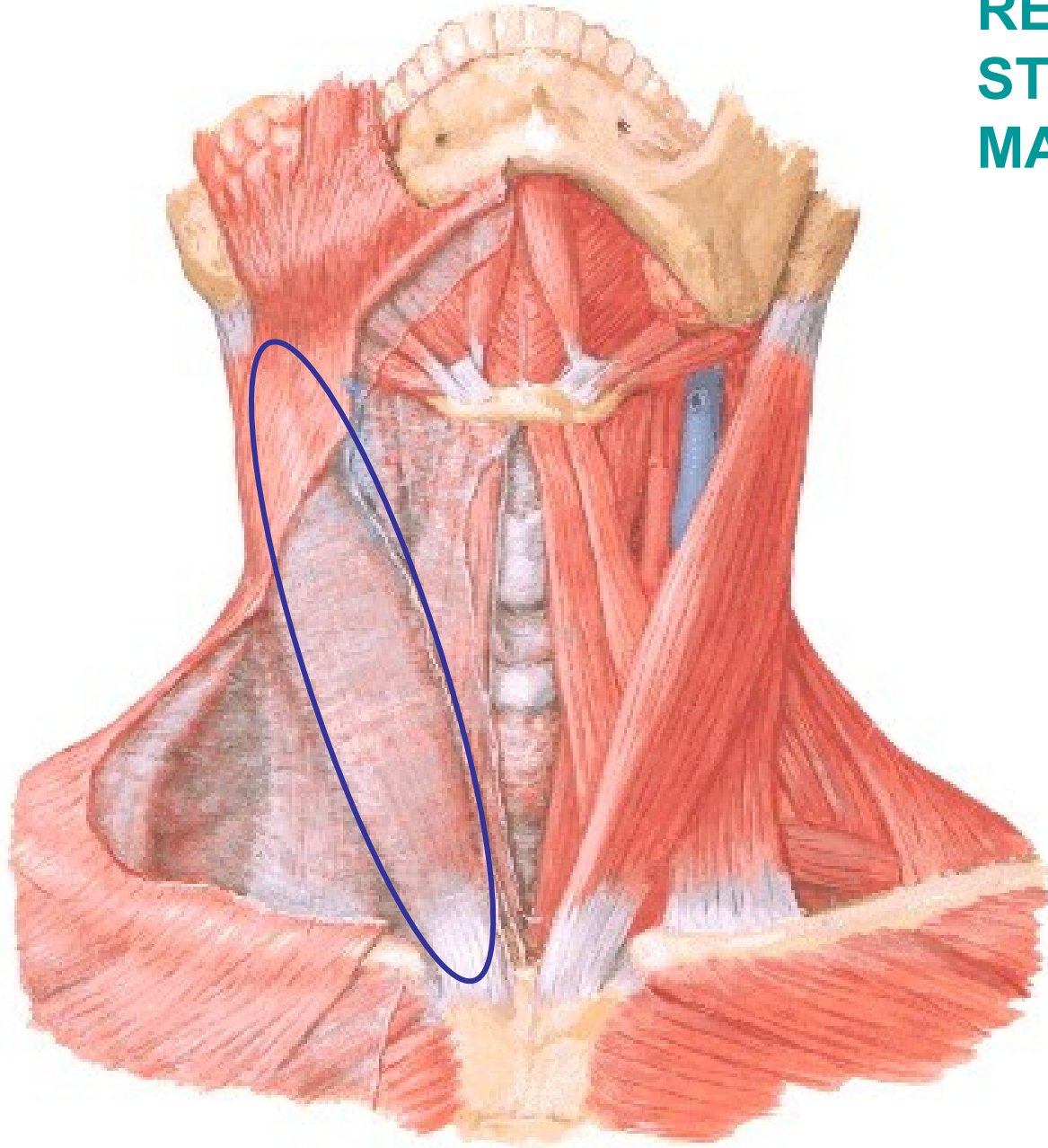


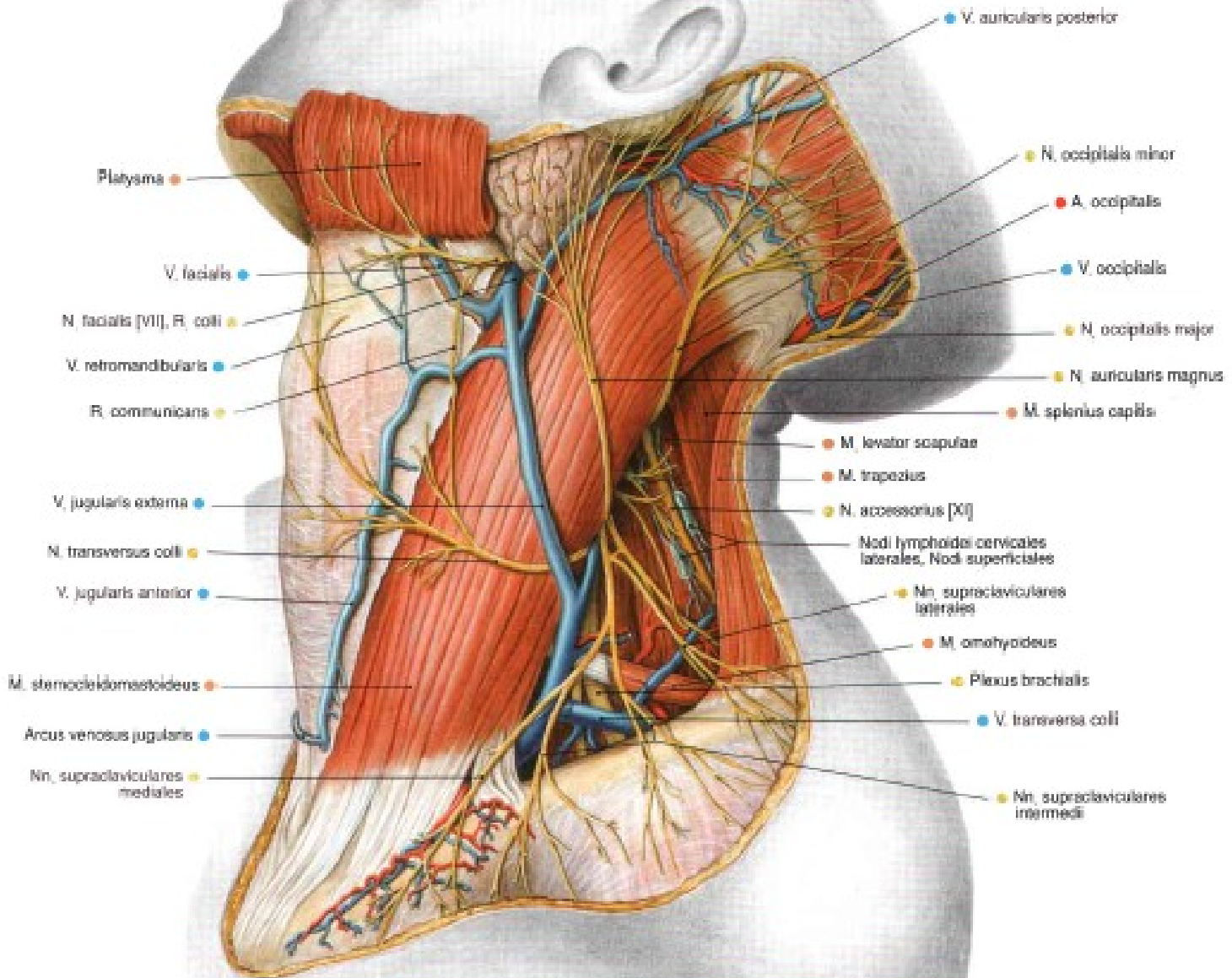




Postop Day 55

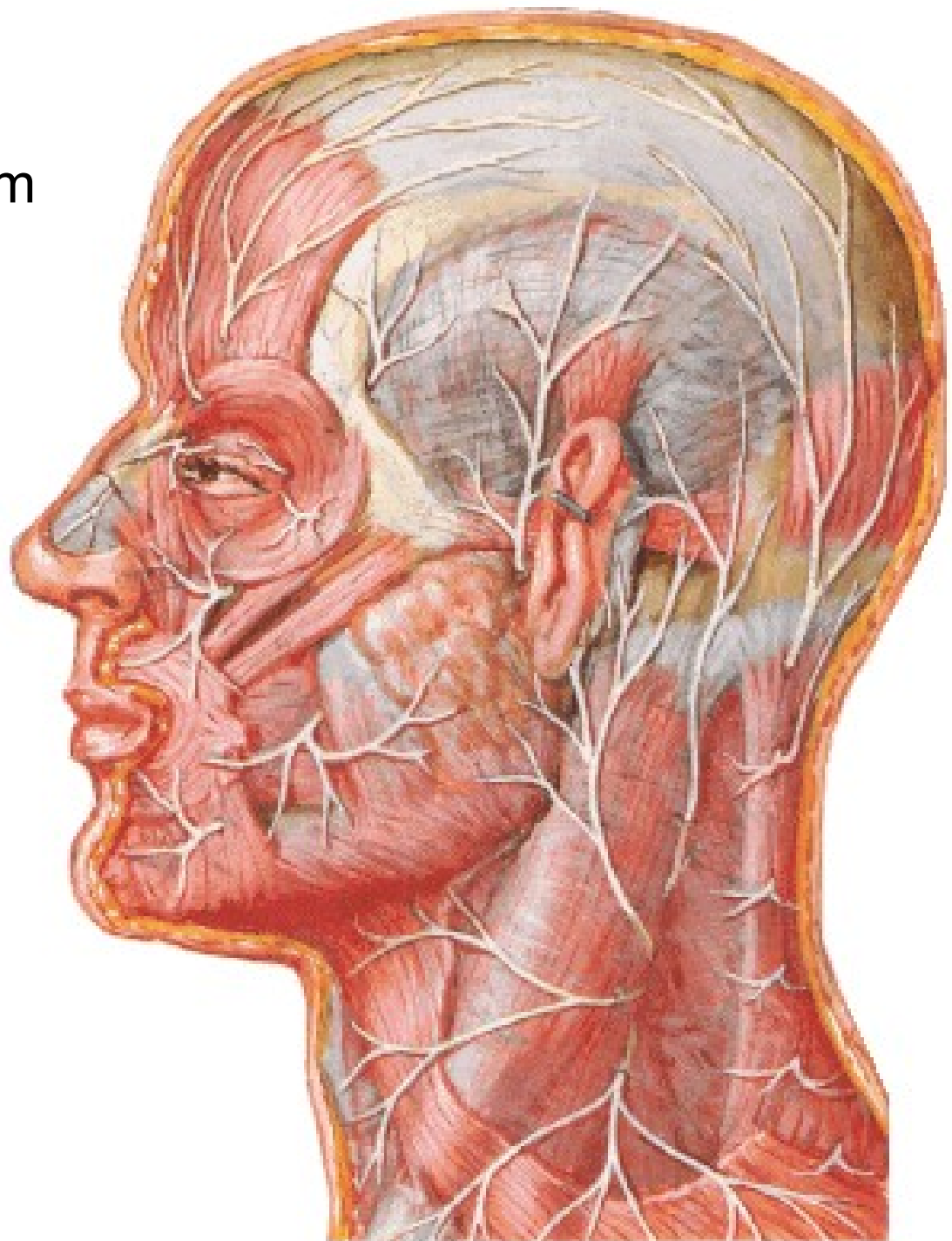
REGIO STERNOCLEIDO- MASTOIDEA





- V. auricularis posterior
- N. occipitalis minor
- A. occipitalis
- V. occipitalis
- N. occipitalis major
- N. auricularis magnus
- M. splenius capitis
- M. levator scapulae
- M. trapezius
- N. accessorius [XI]
- Nodi lymphoidei cervicales laterales, Nodi superficiales
- Nn. supraclaviculares laterales
- M. omohyoideus
- Plexus brachialis
- V. transversa colli
- Nn. supraclaviculares intermedii
- Platyisma
- V. facialis
- N. facialis [VII], R. colli
- V. retromandibularis
- R. communicans
- V. jugularis externa
- N. transversus colli
- V. jugularis anterior
- M. sternocleidomastoideus
- Arcus venosus jugularis
- Nn. supraclaviculares mediales

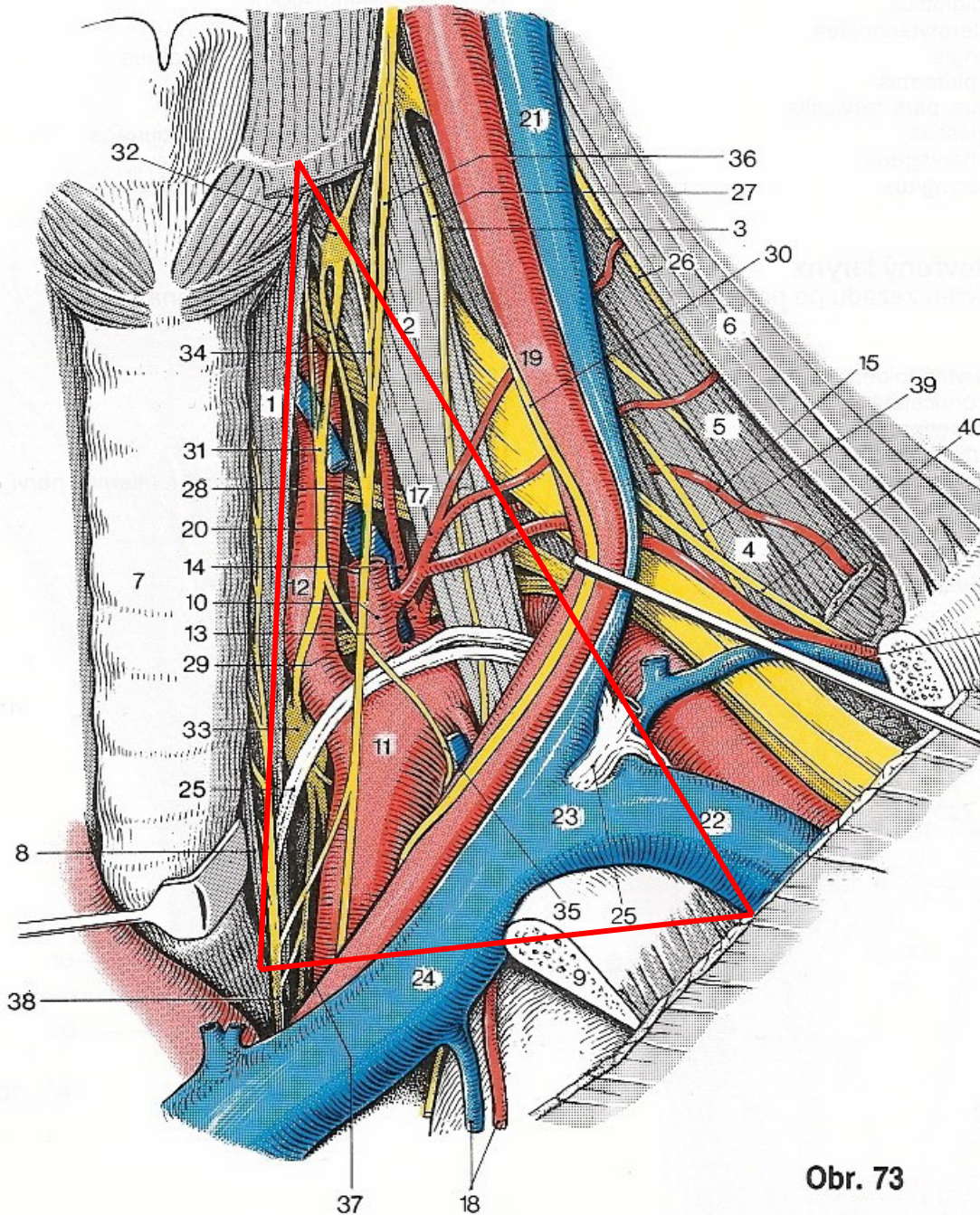
Punctum nervosum
(Erb's point)

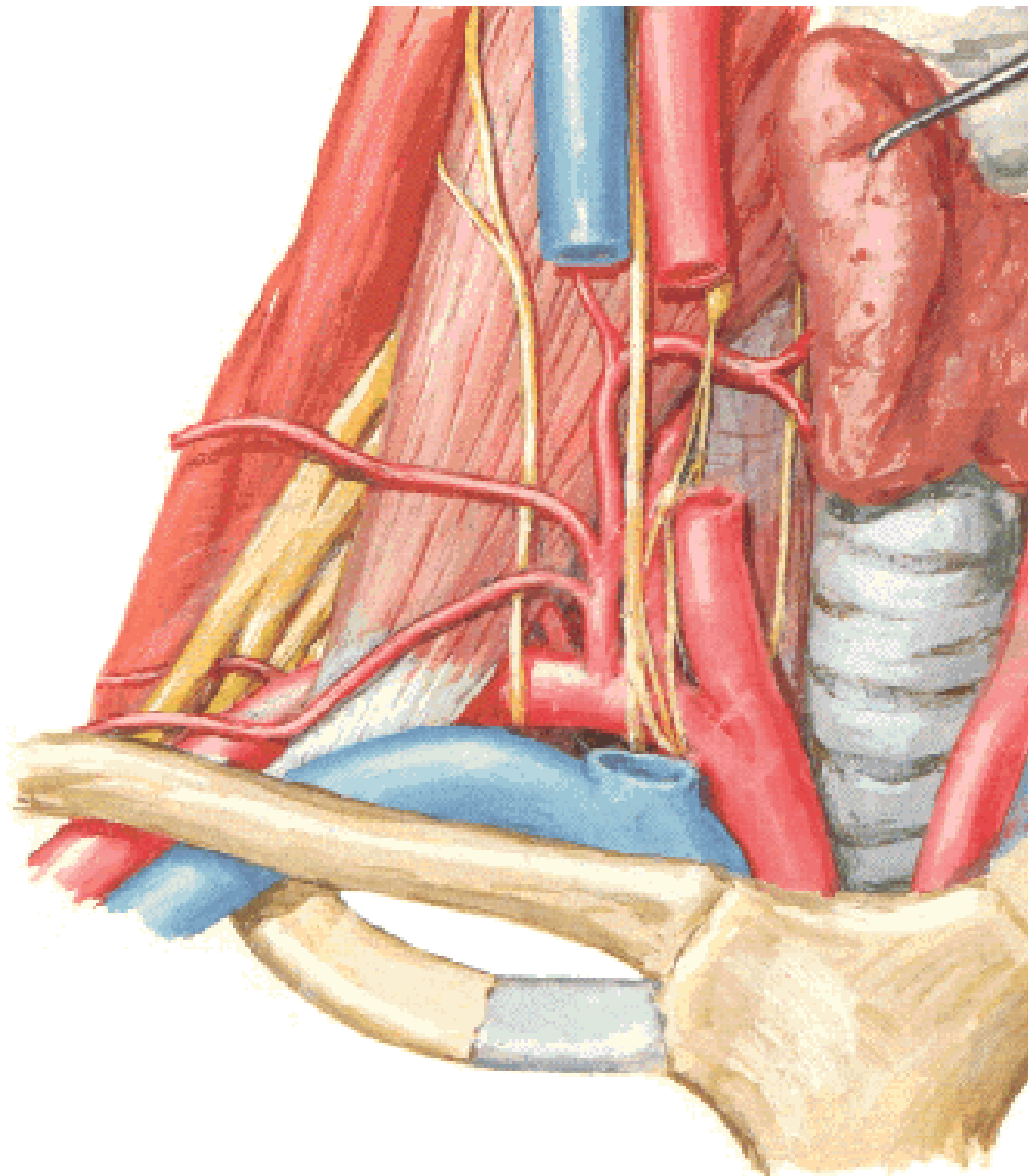


TRIGONUM SCALENOVERTEBRALE S. SUBCLAVIAE

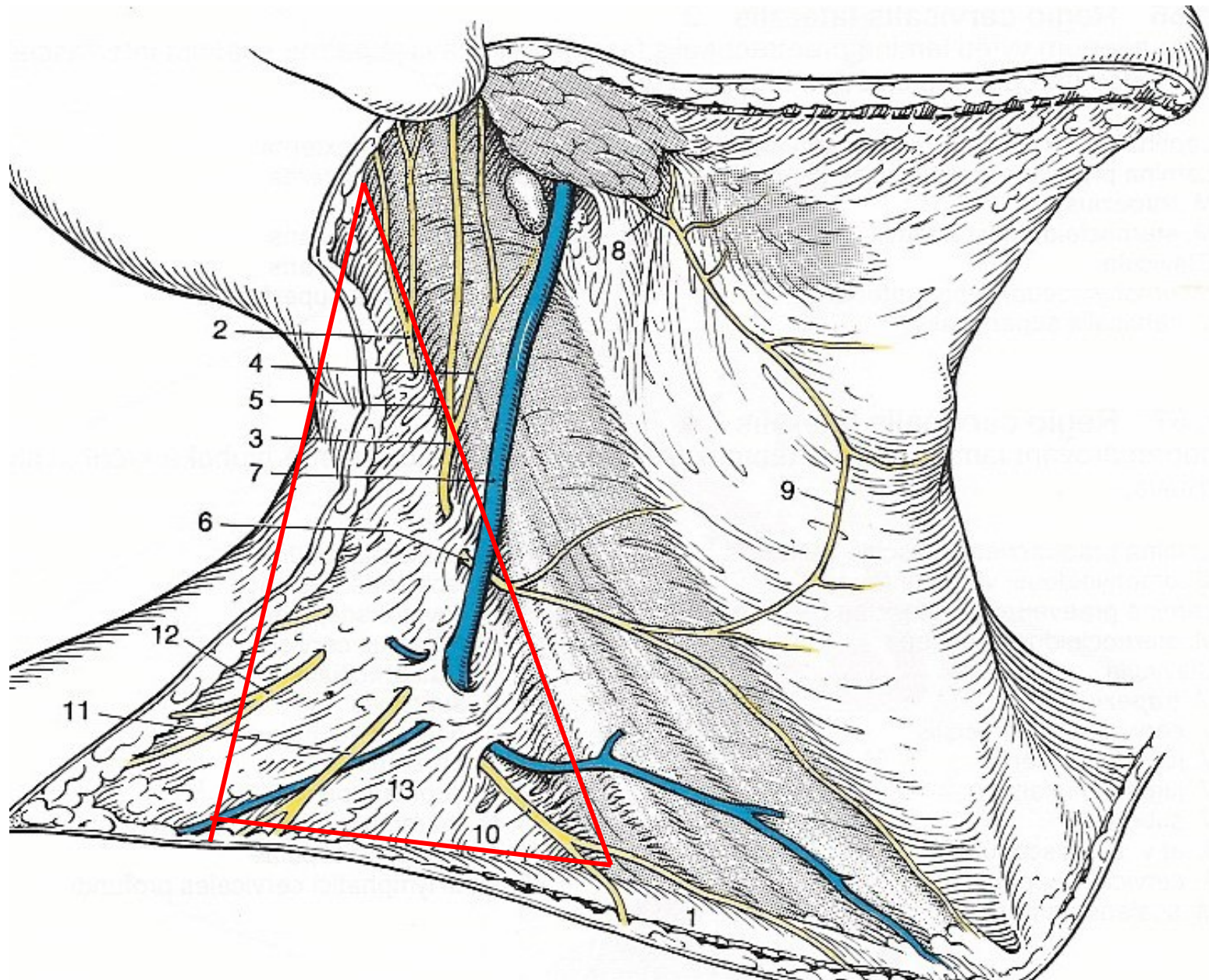
CONTENTS:

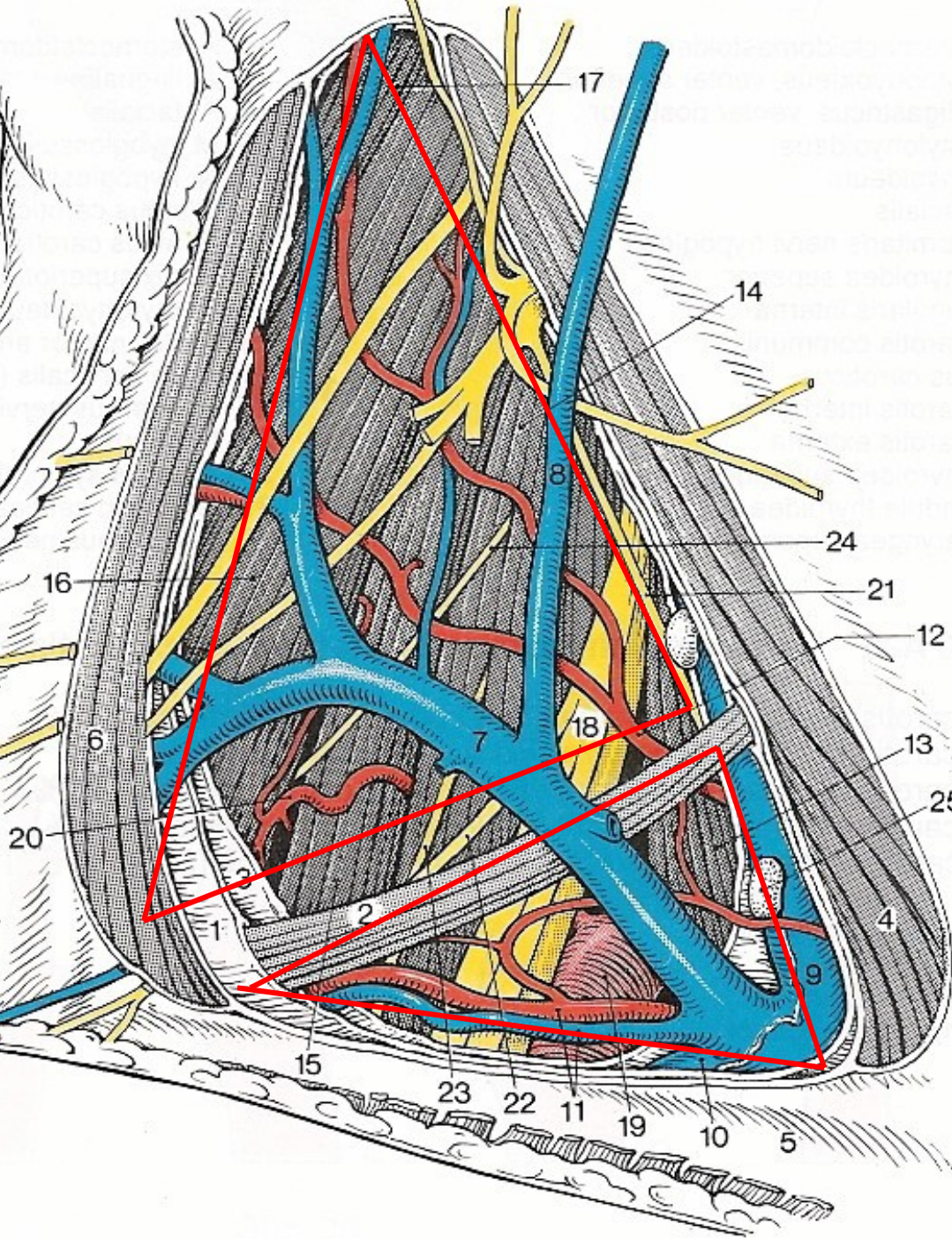
V. SUBCLAVIA
V. JUGULARIS INT.
V. JUGULARIS EXT.
DUCTUS THORACICUS
(TR. LYMPH. DEXTER)
A. CAROTIS COMM.
A. SUBCLAVIA
TR. SYMPATICUS
ANSA SUBCLAVIA
N. VAGUS
NN.+RR. CARDIACI
N. PHRENICUS





TRIGONUM COLLI LATERALE





TRIGONUM OMOTRAPEZIUM

A. ET V. CERVICALIS SPF.
 A. DORSALIS SCAPULAE
 CN XI
 PLEXUS CERVICALIS
 N. DORSALIS SCAPULAE
 N. THORACICUS LONGUS
 N. SUPRASCAPULARIS

TRIGONUM OMOCLAVICULARE

V. SUBCLAVIA
 A. SUBCLAVIA
 A. SUPRASCAPULARIS
 PLEXUS BRACHIALIS
 NL. SUPRACLAVICULARES

Illustrations were copied from:

**Atlas der Anatomie des Menschen/Sobotta.
Putz,R., und Pabst,R. 20. Auflage. München:
Urban & Schwarzenberg, 1993)**

**Čihák R: Anatomie 2 (Splanchnologia).
Avicenum,
zdravotnické nakladatelství, Praha, 1988.**