

MUSCLES OF THE UPPER LIMB

MUSCULI (MM.) HUMERI

M. deltoideus

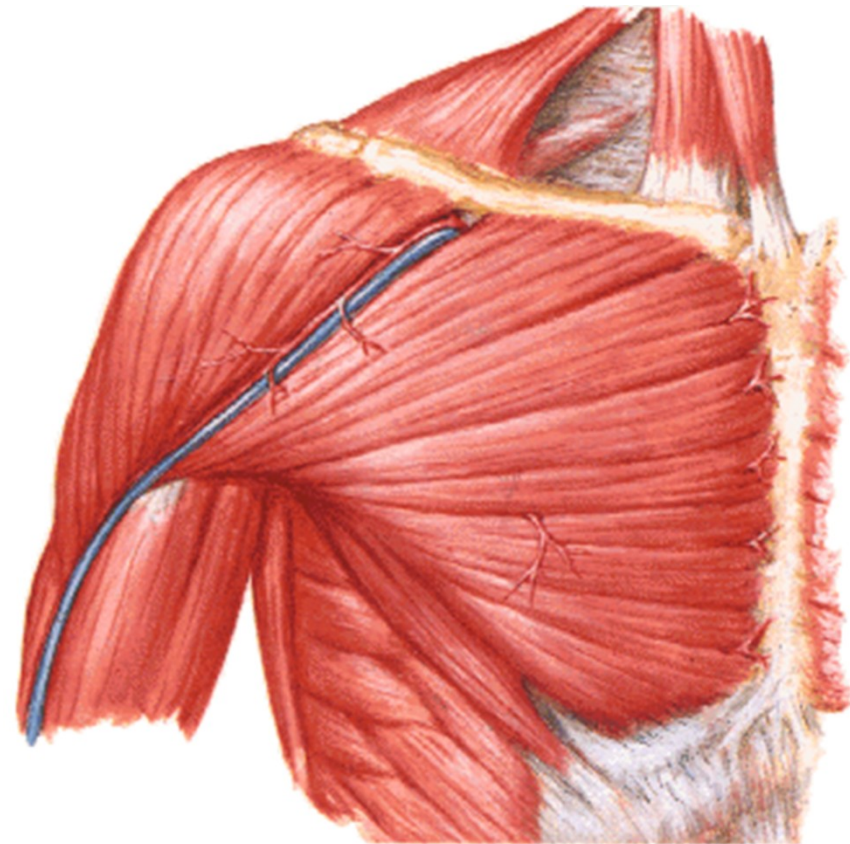
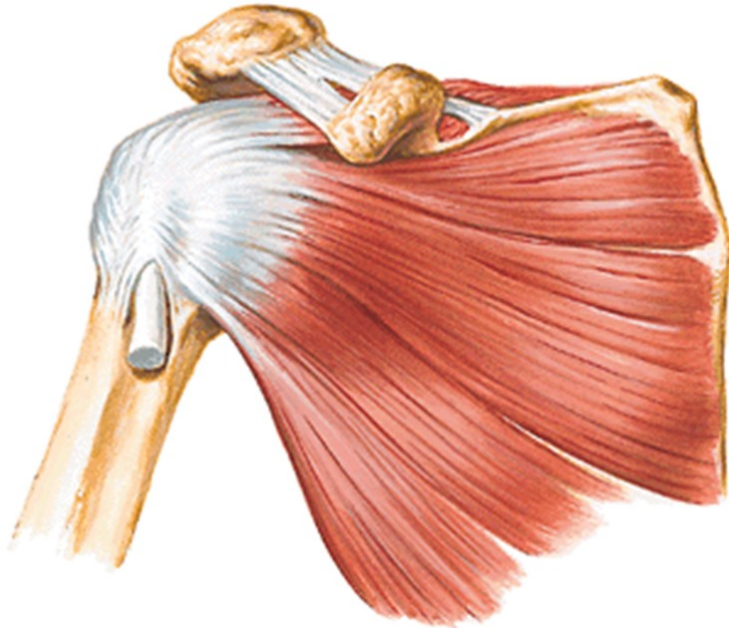
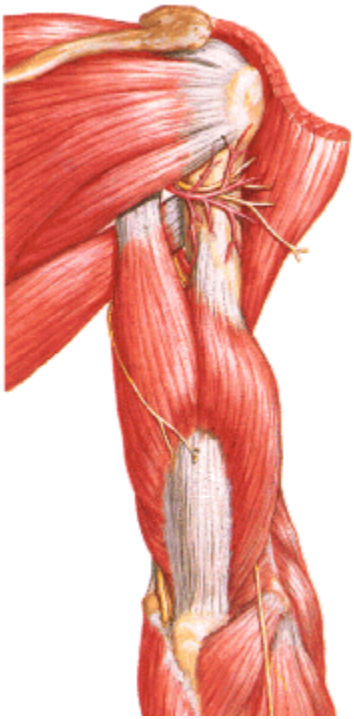
M. supraspinatus

M. infraspinatus

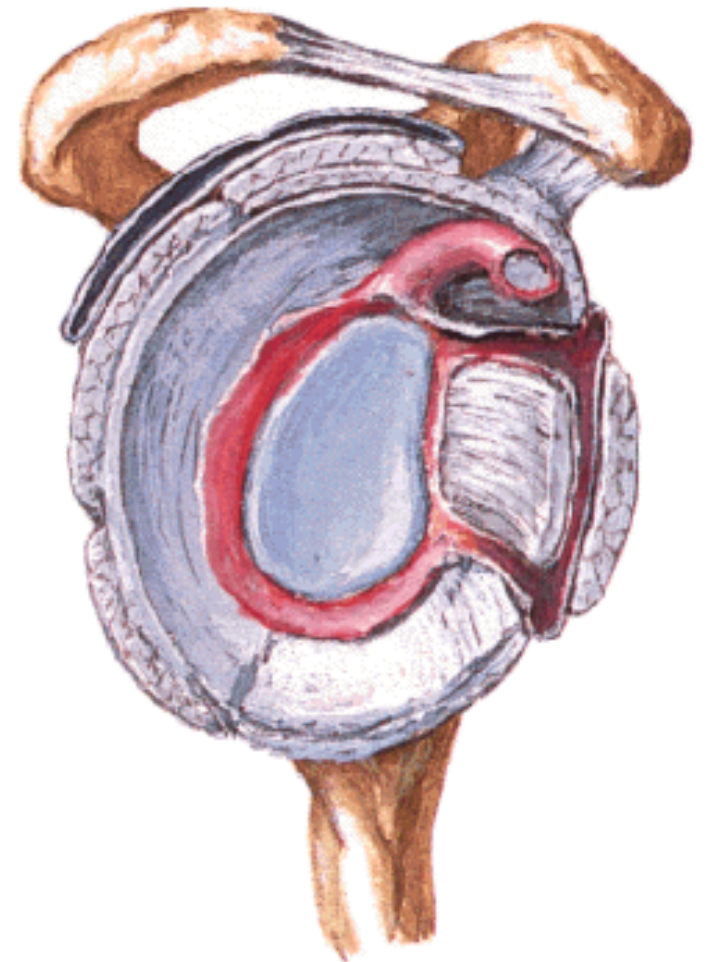
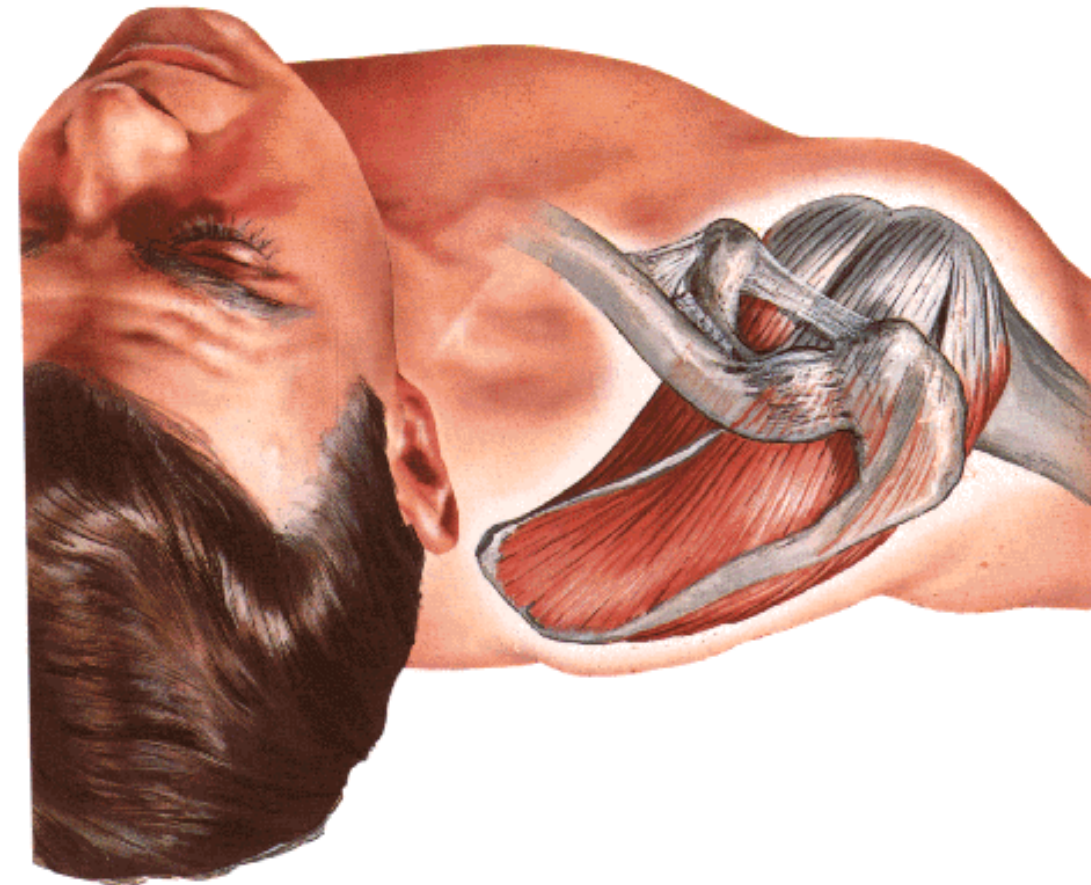
M. teres minor

M. teres major

M. subscapularis



Rotator cuff



MM. BRACHII

Anterior group of muscles:

M. biceps brachii

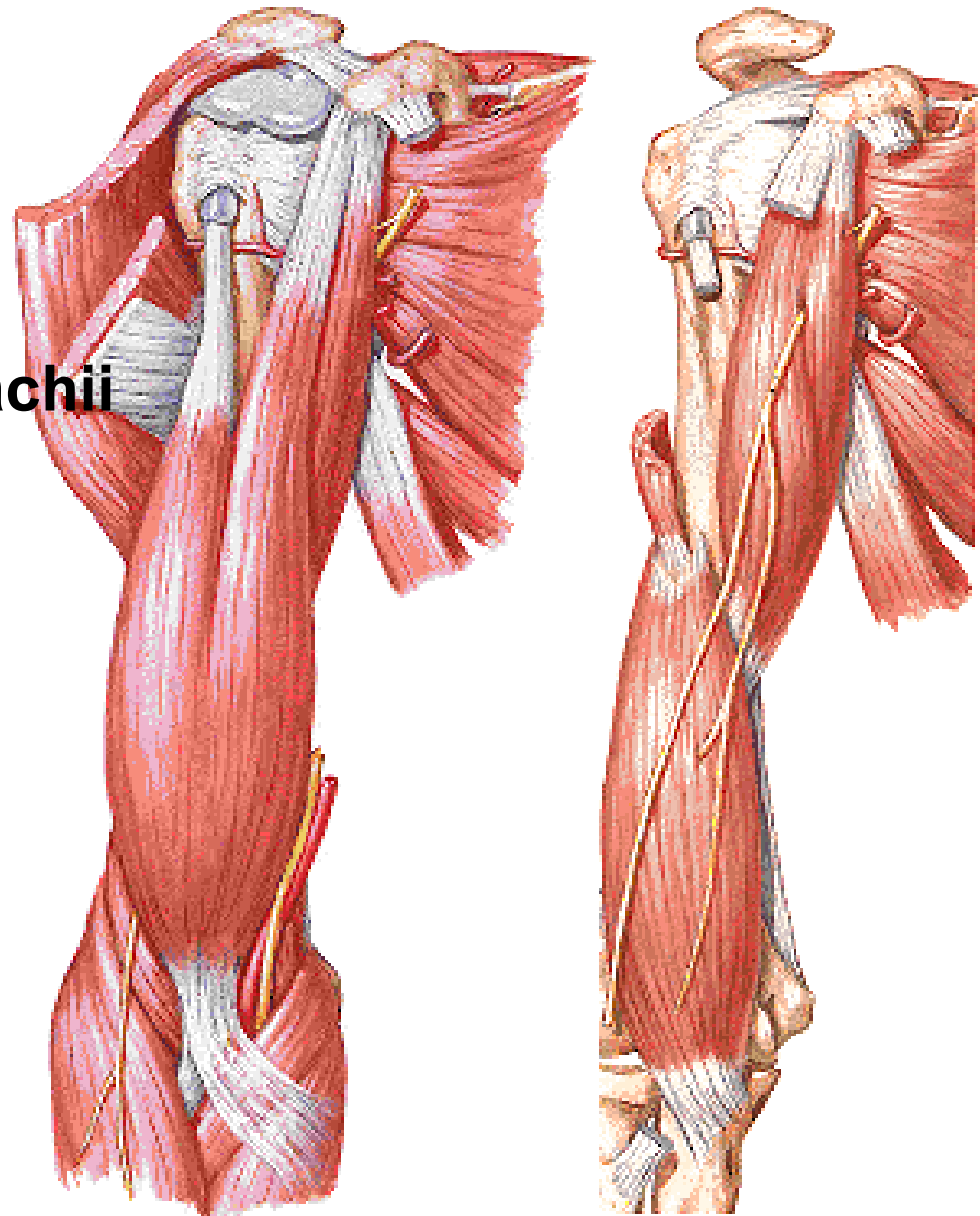
caput longum

caput breve

aponeurosis m. bicipitis brachii

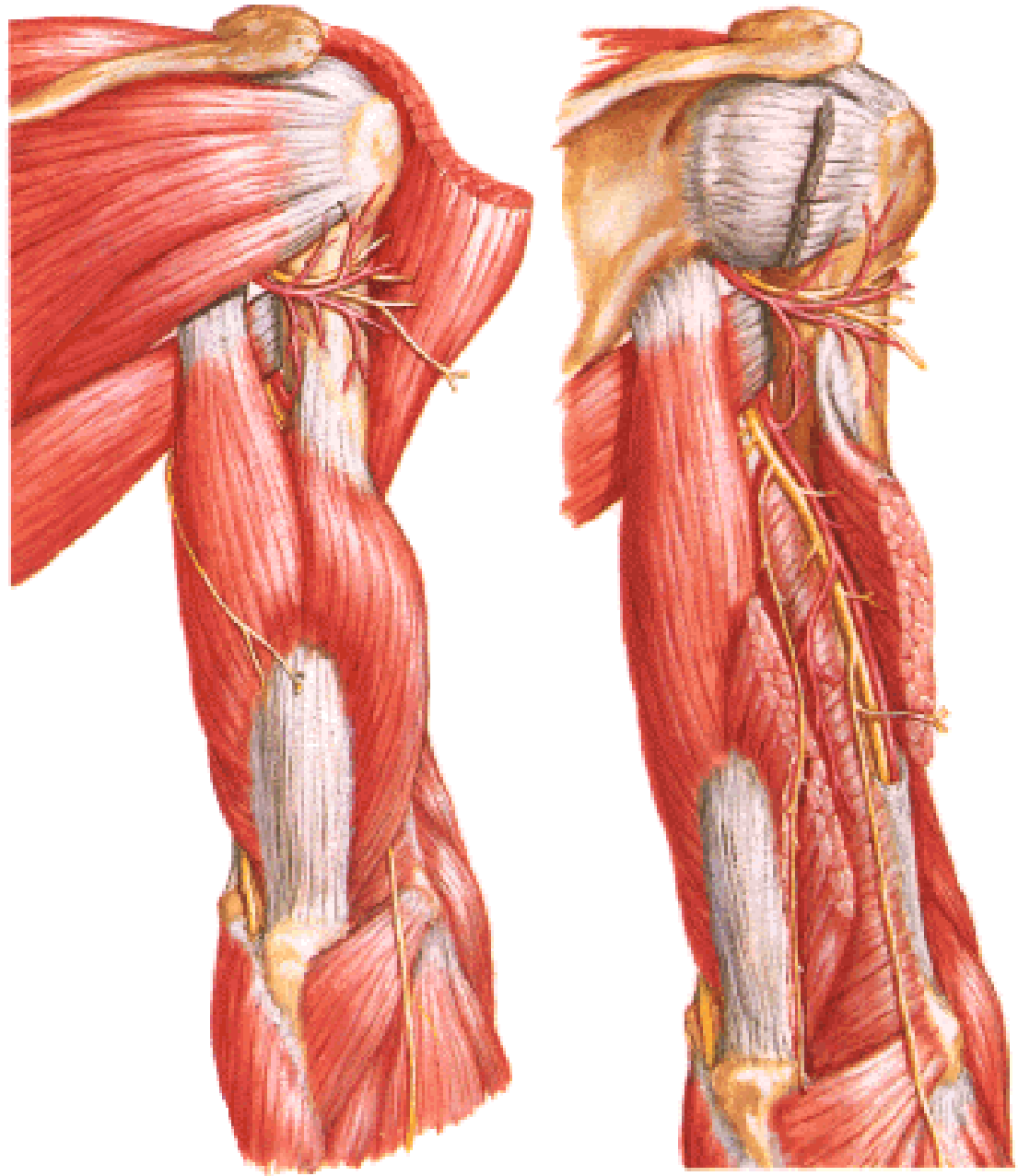
M. coracobrachialis

M. brachialis

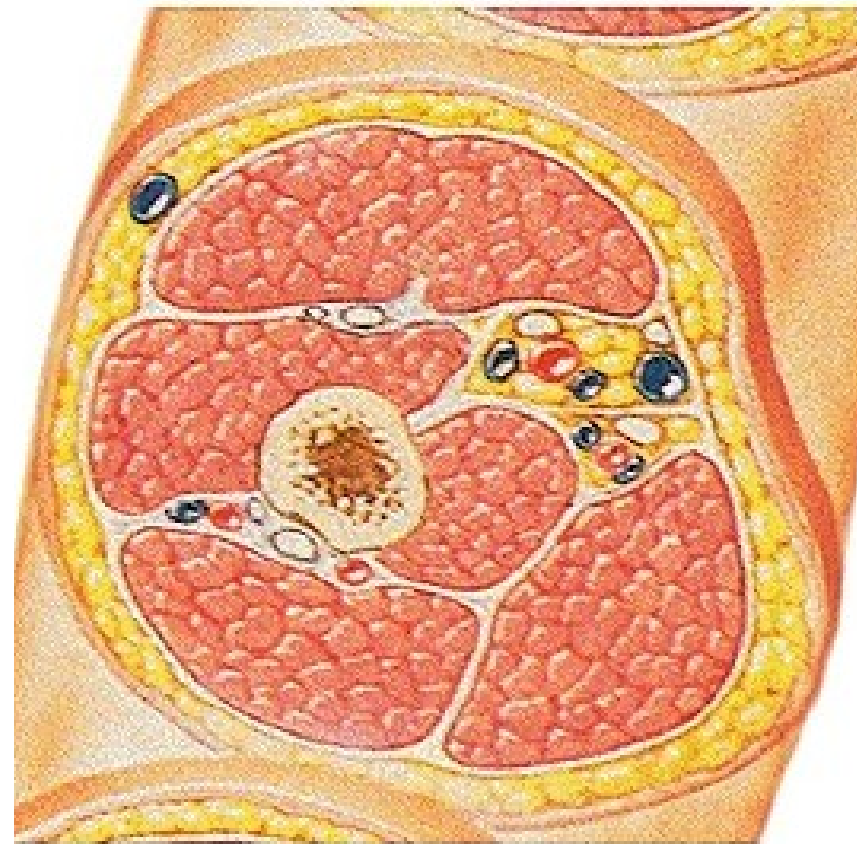
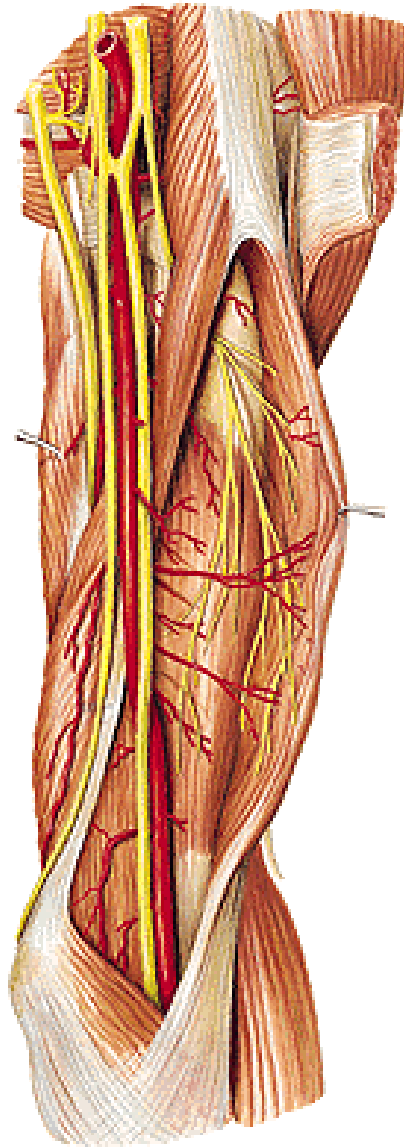
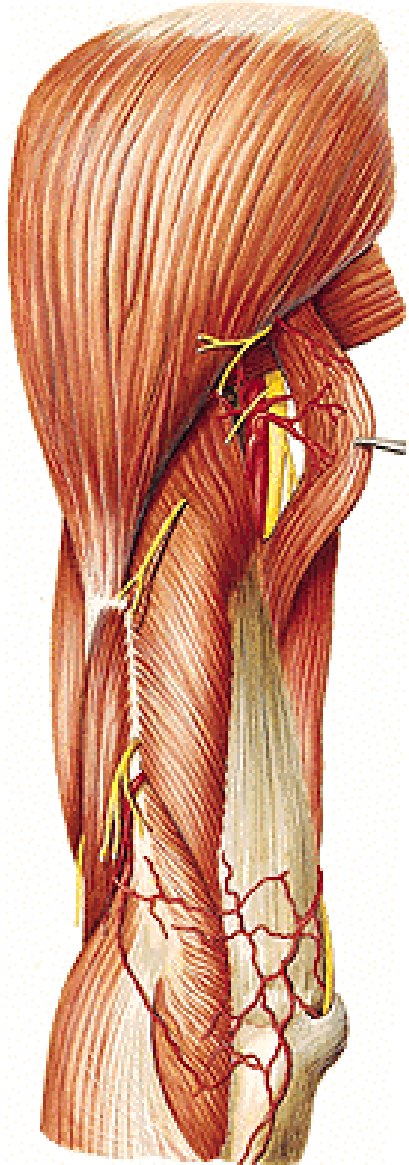


Posterior group of muscles:

M. triceps brachii
caput longum
caput laterale
caput mediale



Septum intermusculare mediale et laterale



MM. ANTEBRACHII

Anterior group of muscles:

M. pronator teres

M. flexor carpi radialis

M. palmaris longus

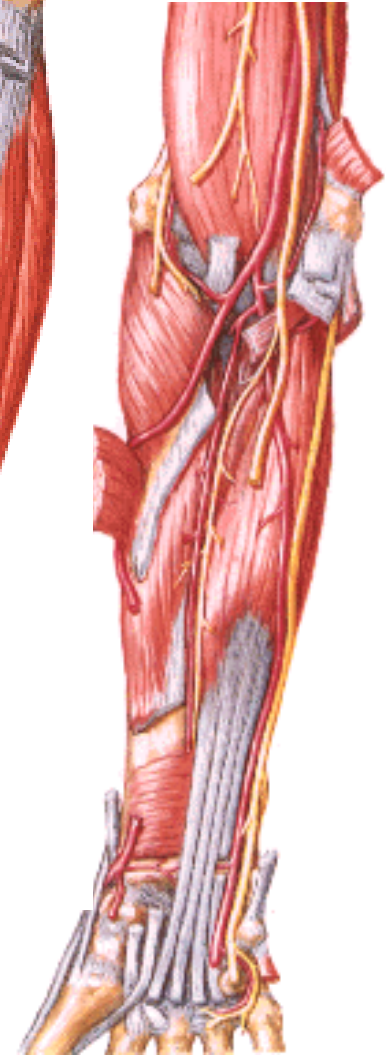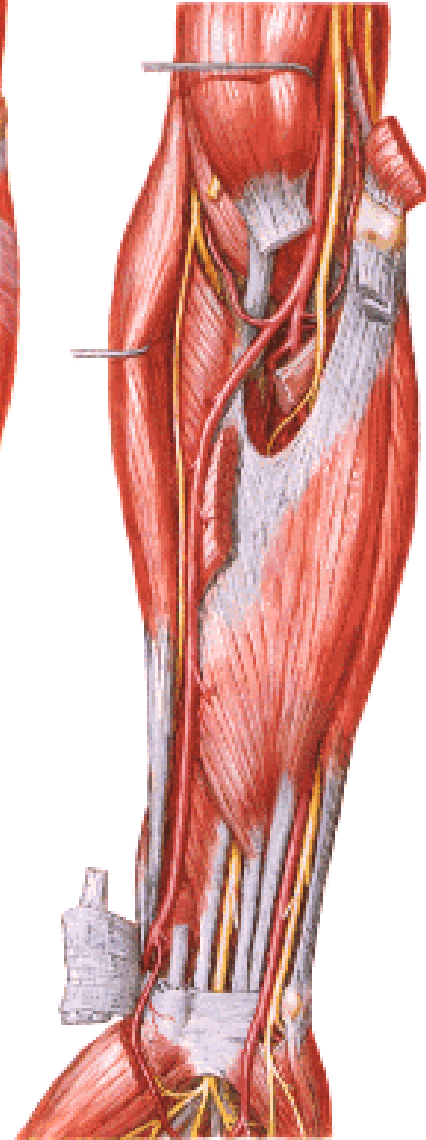
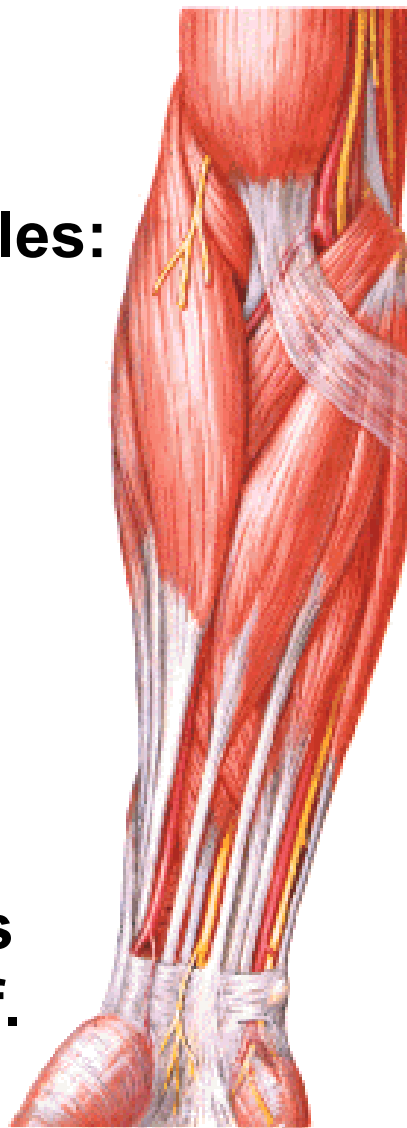M. flexor carpi ulnaris

M. flexor digitorum spf.

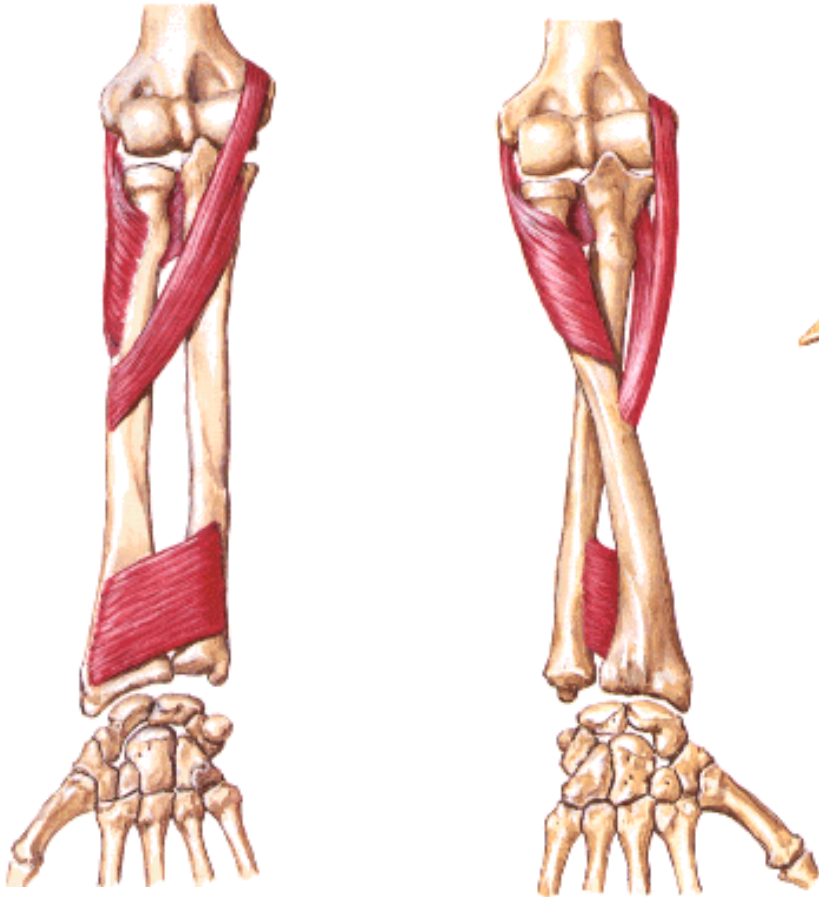
M. flexor pollicis longus

M. flexor digitorum prof.

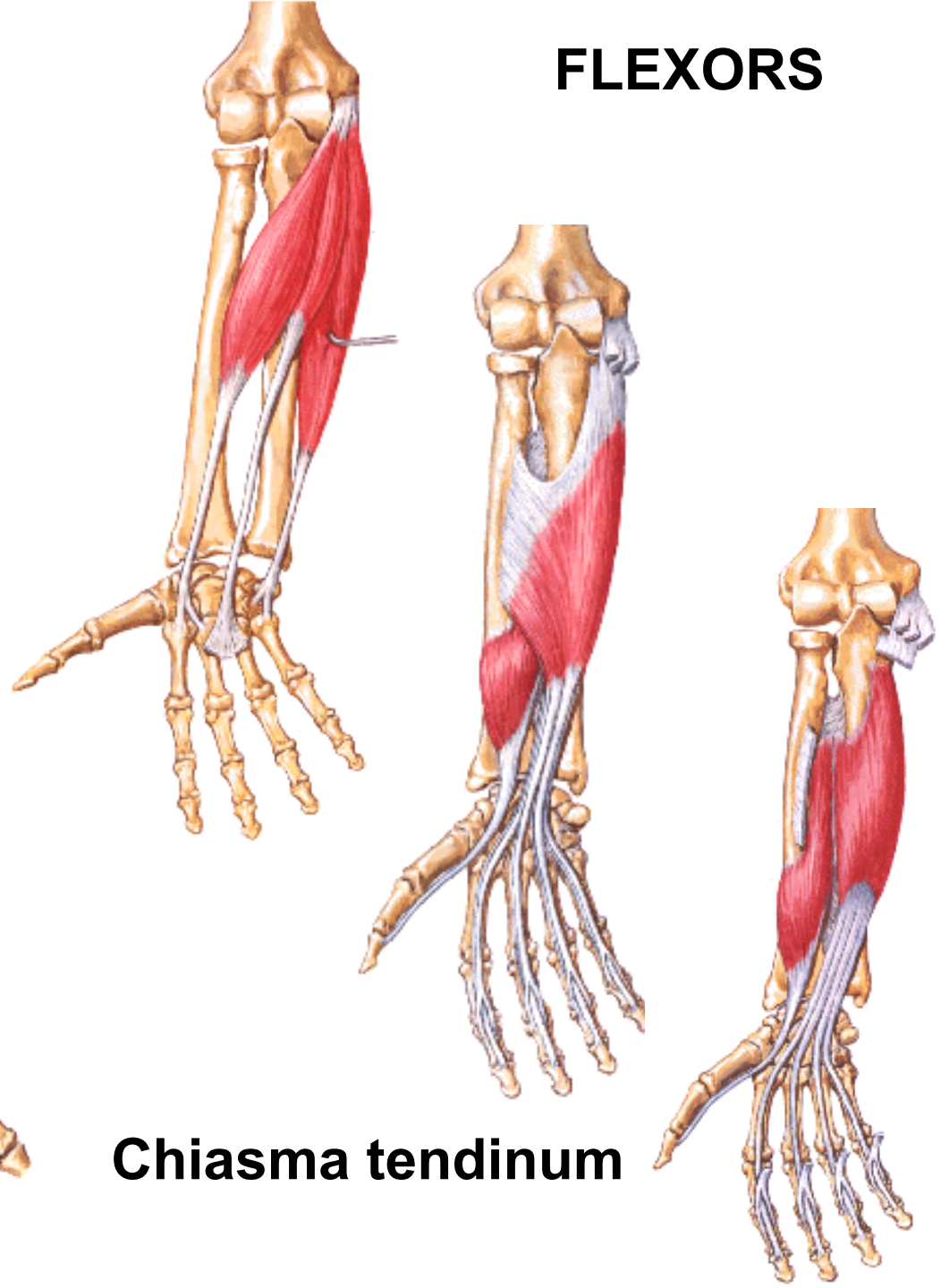
M. pronator quadratus



**PRONATION
-
SUPINATION**



FLEXORS



Chiasma tendinum

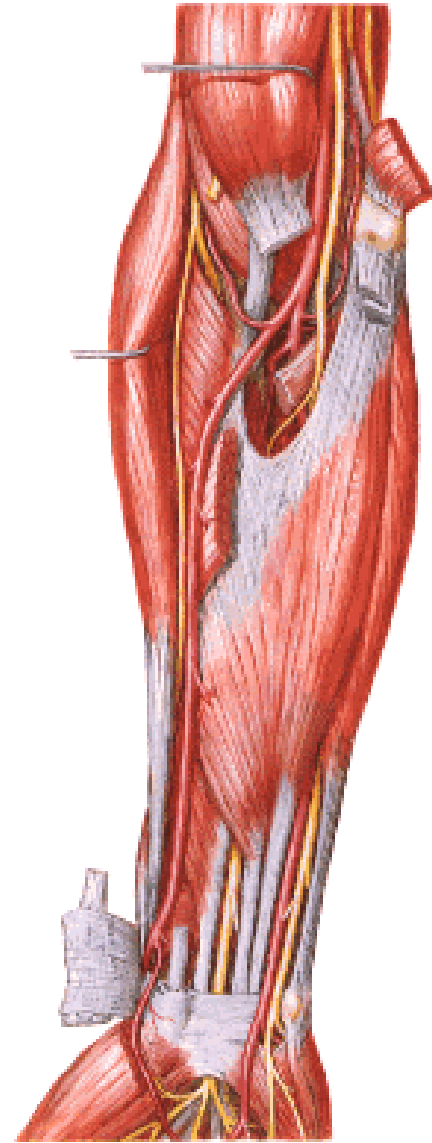
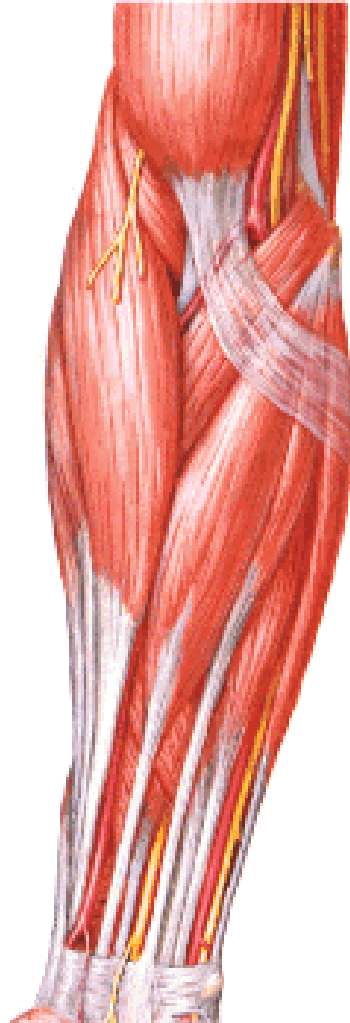
Lateral group of muscles:

M. brachioradialis

M. extensor carpi radialis longus

M. extensor carpi radialis brevis

M. supinator



Posterior group of muscles:

M. anconeus

M. extensor digitorum

M. extensor digiti minimi

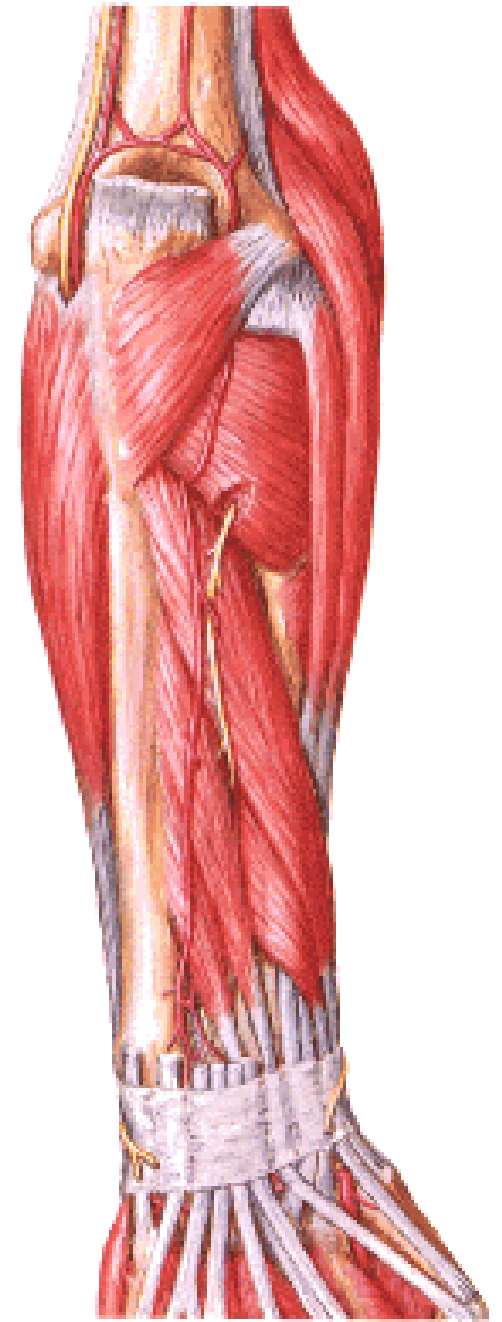
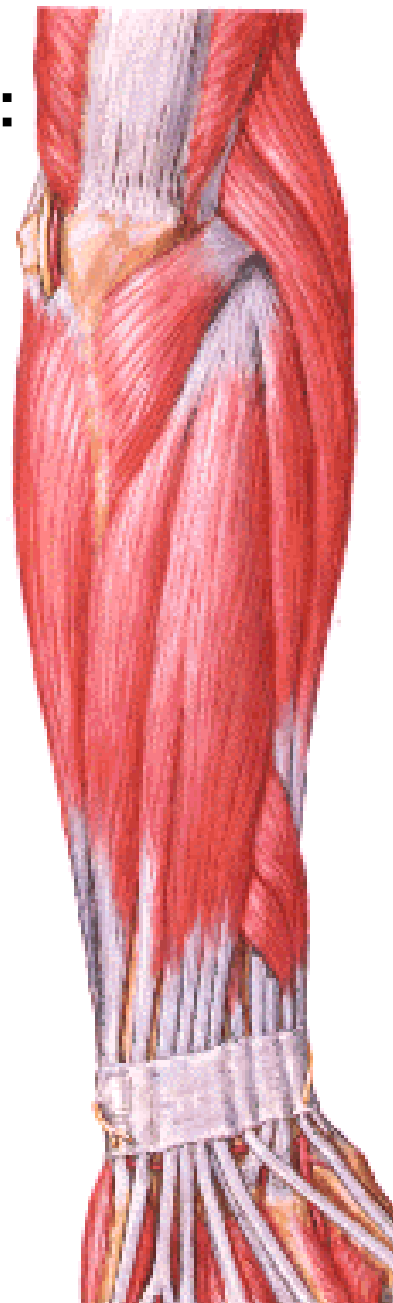
M. extensor carpi ulnaris

M. abductor pollicis longus

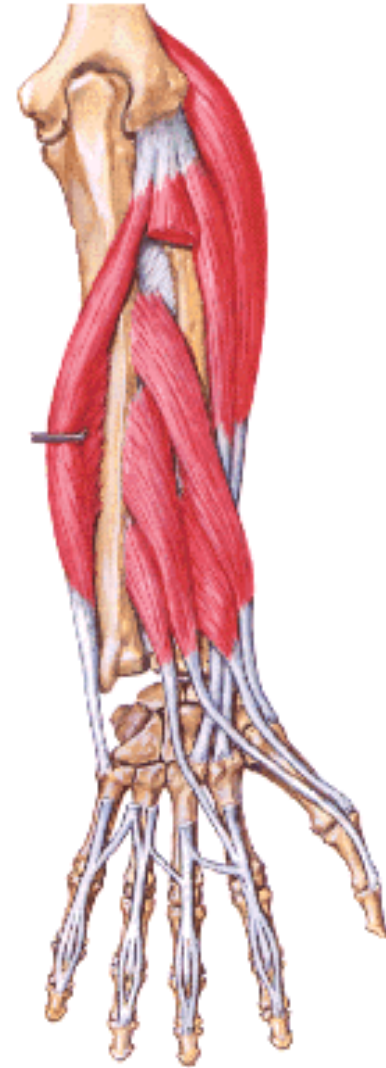
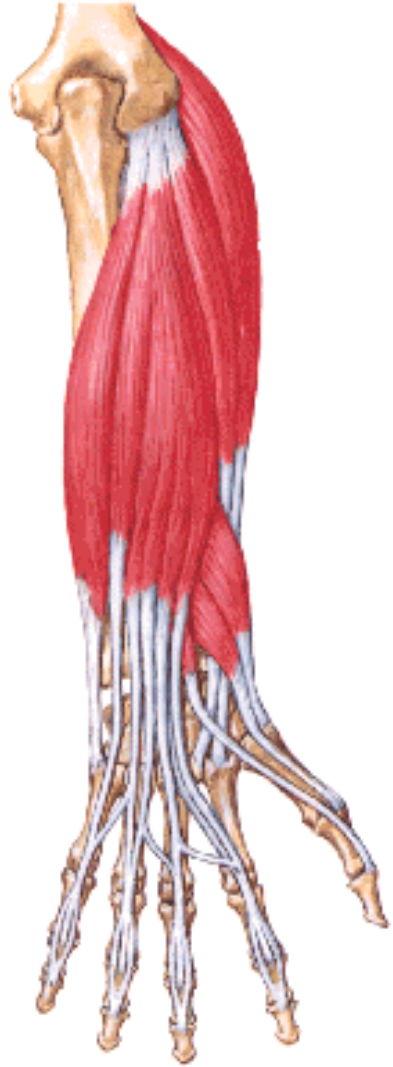M. extensor pollicis brevis

M. extensor pollicis longus

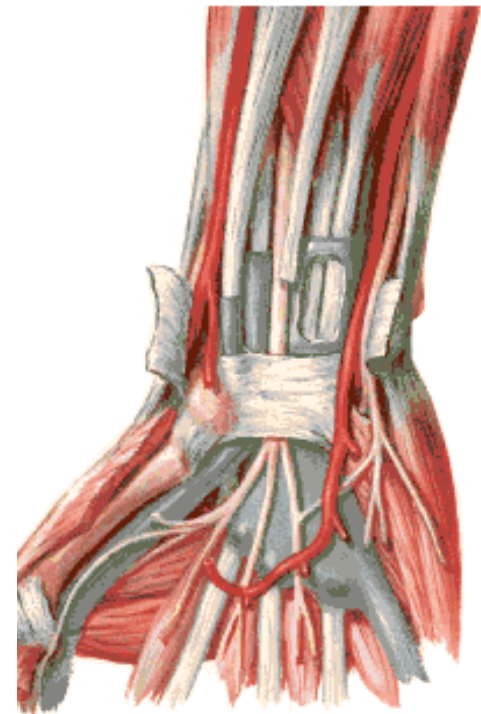
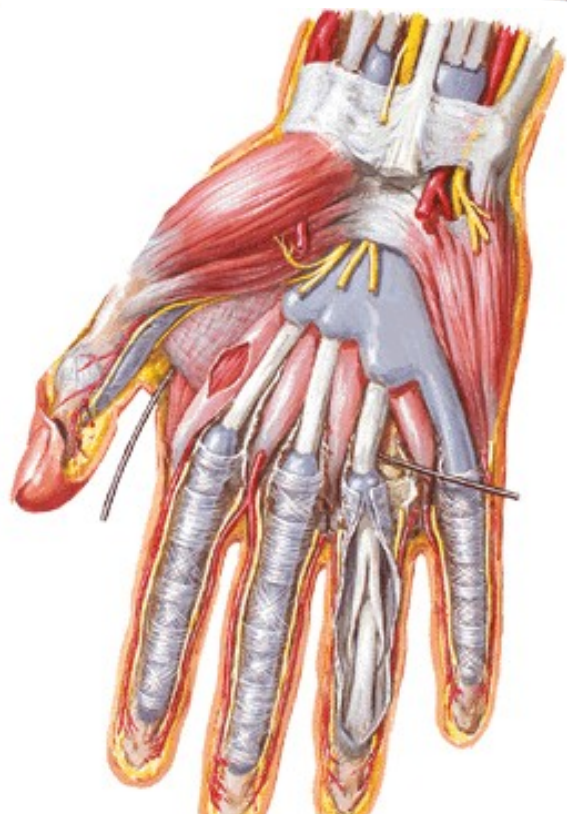
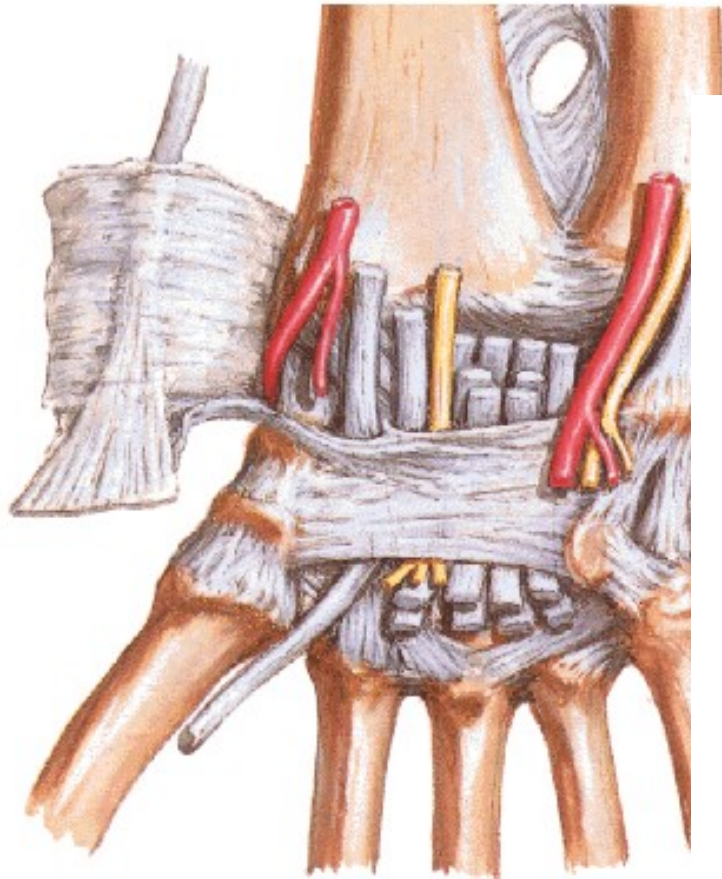
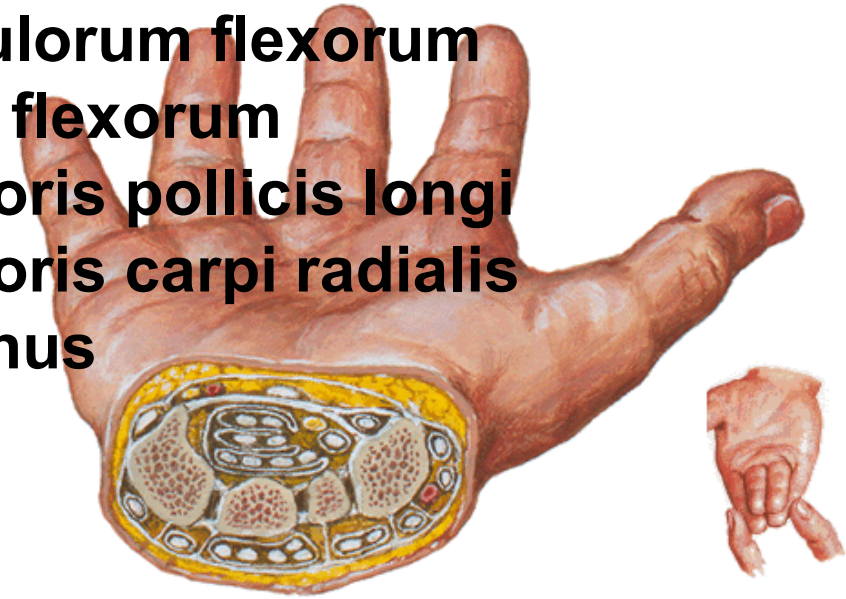
M. extensor indicis



EXTENSORS

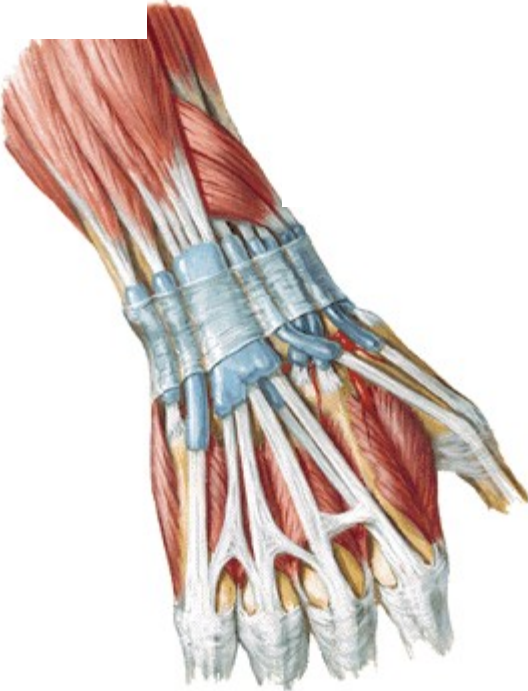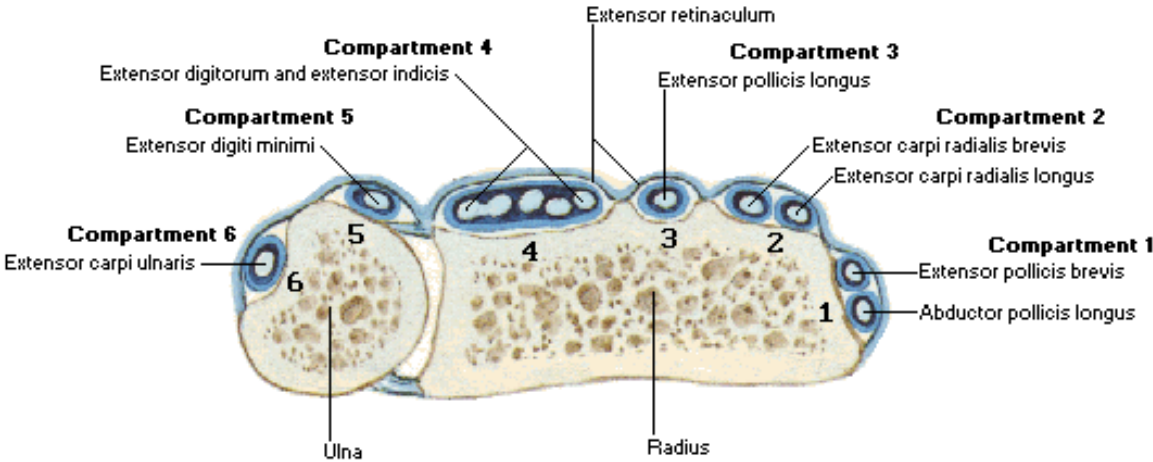
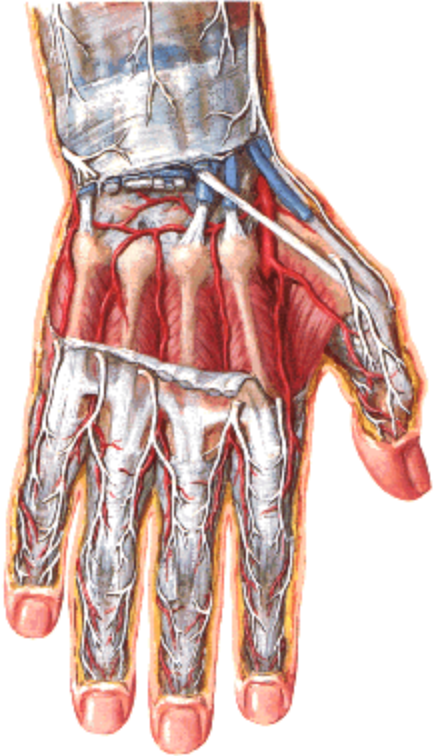


Canalis carpi - retinaculum musculorum flexorum
Vagina synovialis communis mm. flexorum
Vagina synovialis tendinis m. flexoris pollicis longi
Vagina synovialis tendinis m. flexoris carpi radialis
Vaginae synoviales digitorum manus

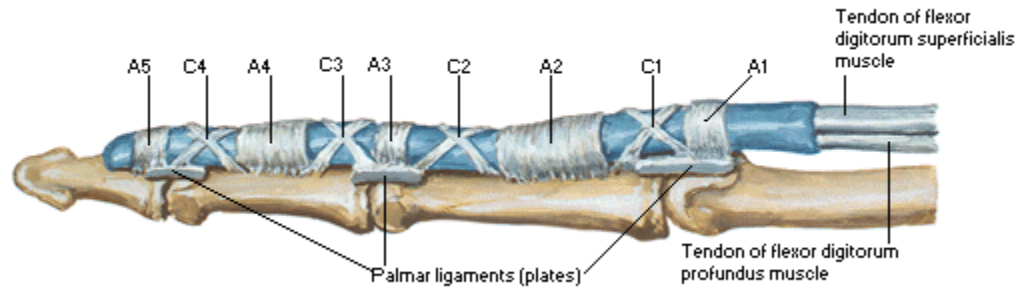


Retinaculum musculorum extensorum

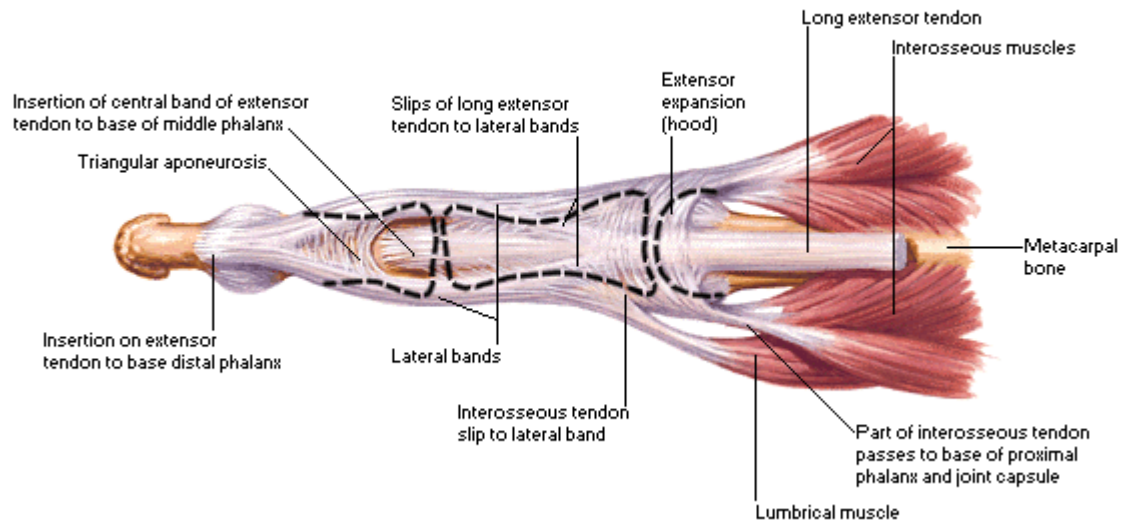
Extensor compartments



Vagina fibrosa digiti



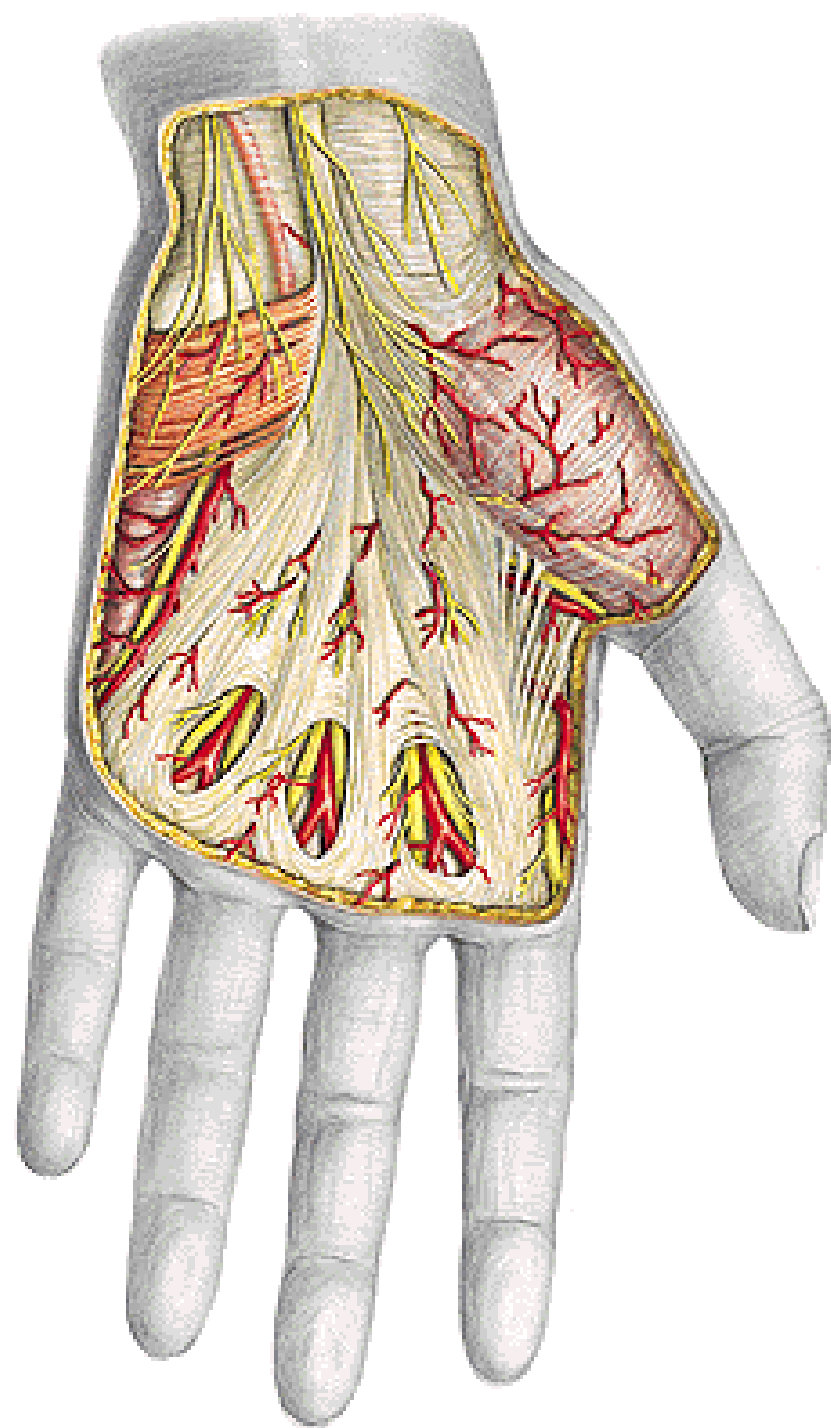
Aponeurosis dorsalis digiti



MM. MANUS

M. palmaris brevis

Aponeurosis palmaris



Thenar muscles:

M. abductor pollicis brevis

M. flexor pollicis brevis

M. opponens pollicis

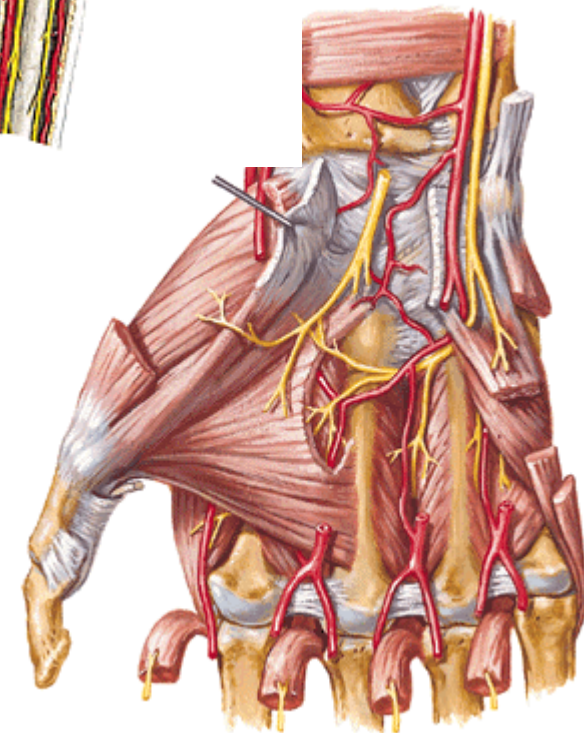
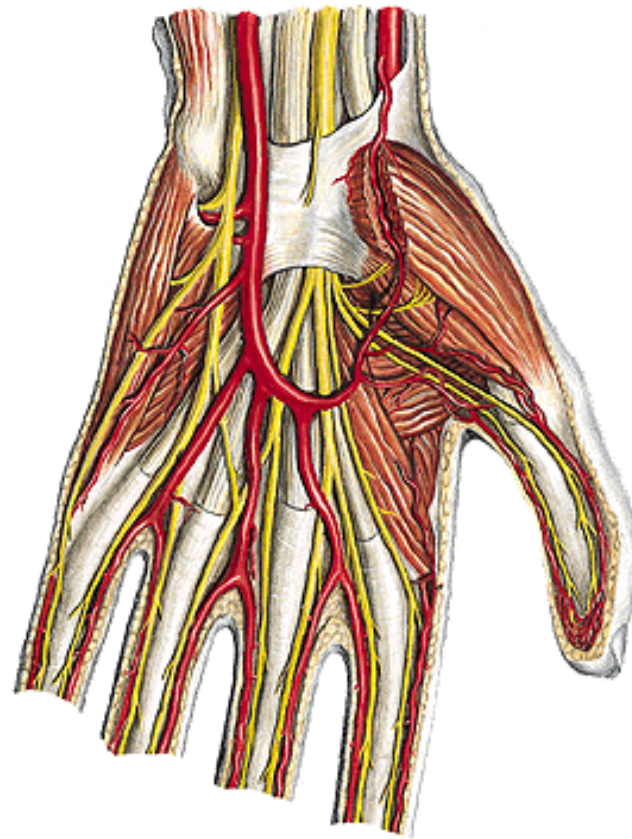
M. adductor pollicis

Hypothenar muscles:

M. abductor digiti minimi

M. flexor digiti minimi brevis

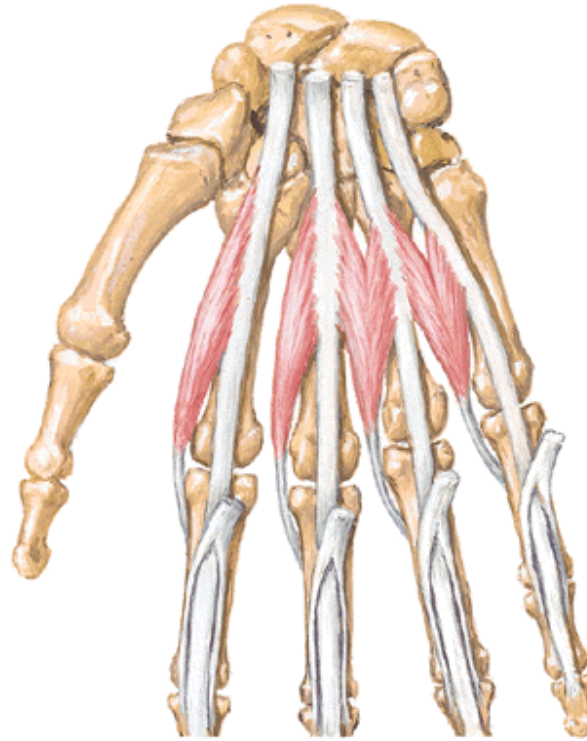
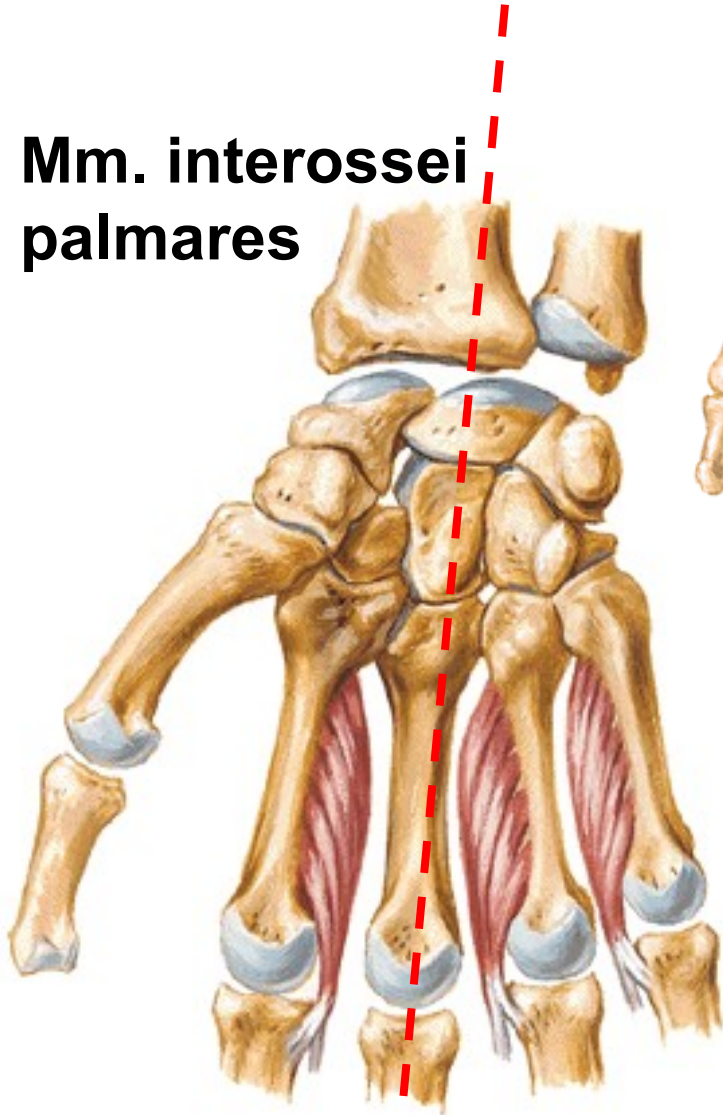
M. opponens digiti minimi



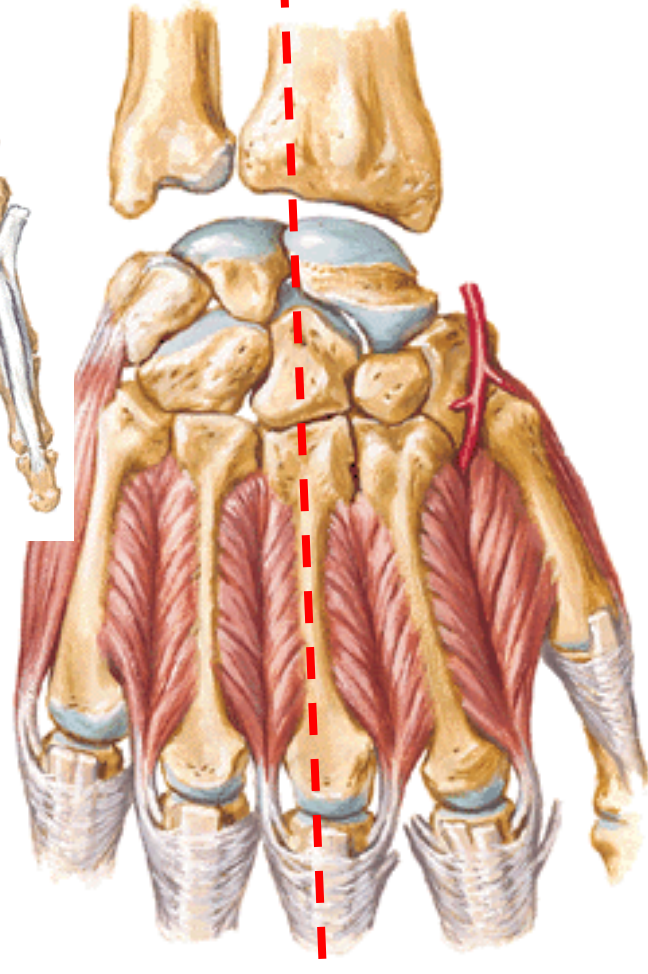
Middle group of muscles:

Mm. lumbricales

Mm. interossei palmares



Mm. interossei dorsales



Illustrations and photographs were copied from:
Atlas der Anatomie des Menschen/Sobotta.
Putz,R., und Pabst,R. 20. Auflage. München:
Urban & Schwarzenberg, 1993
Netter: Interactive Atlas of Human Anatomy.
Windows Version 2.0