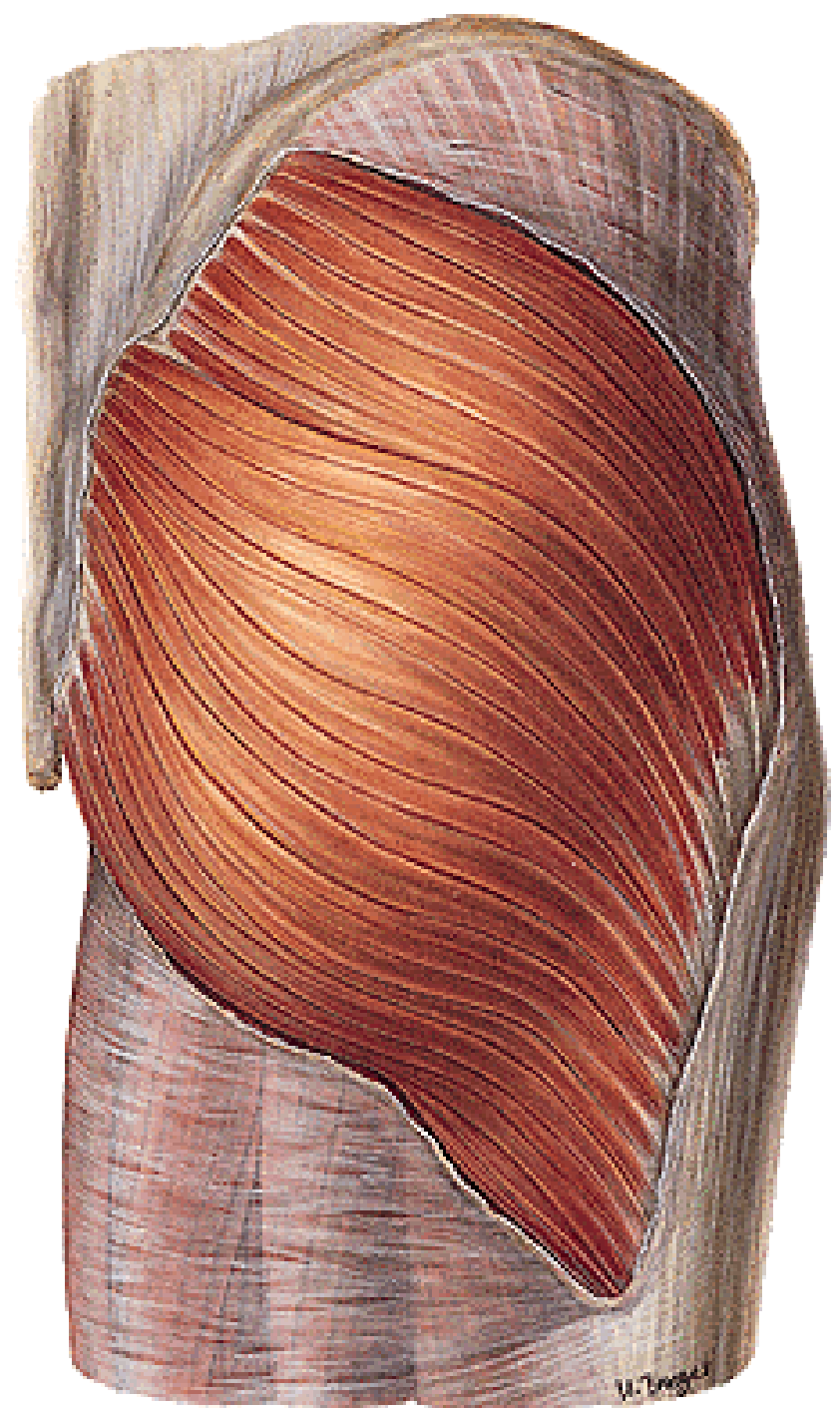


MUSCLES OF THE LOWER LIMB

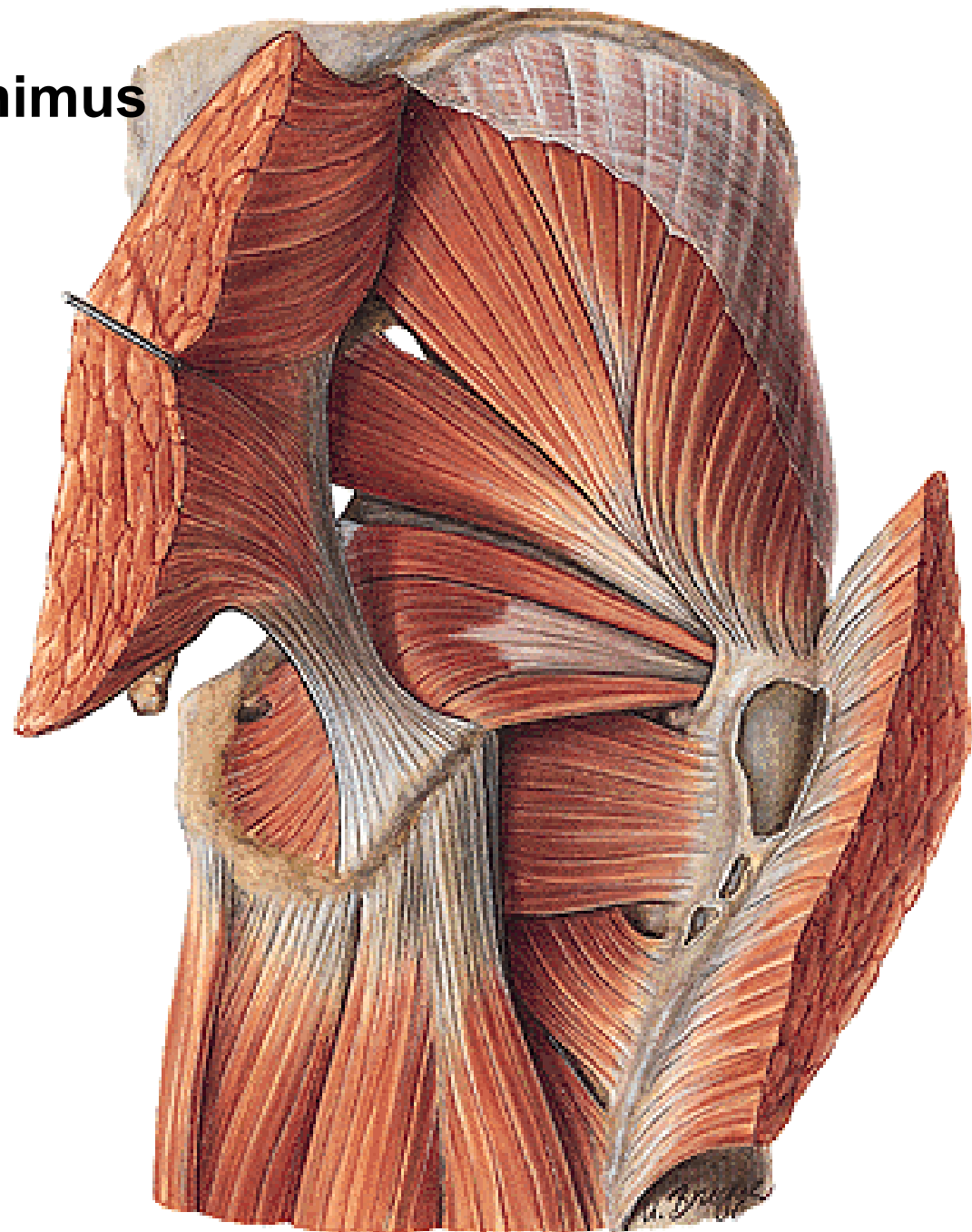
MUSCULI COXAE

Posterior group:

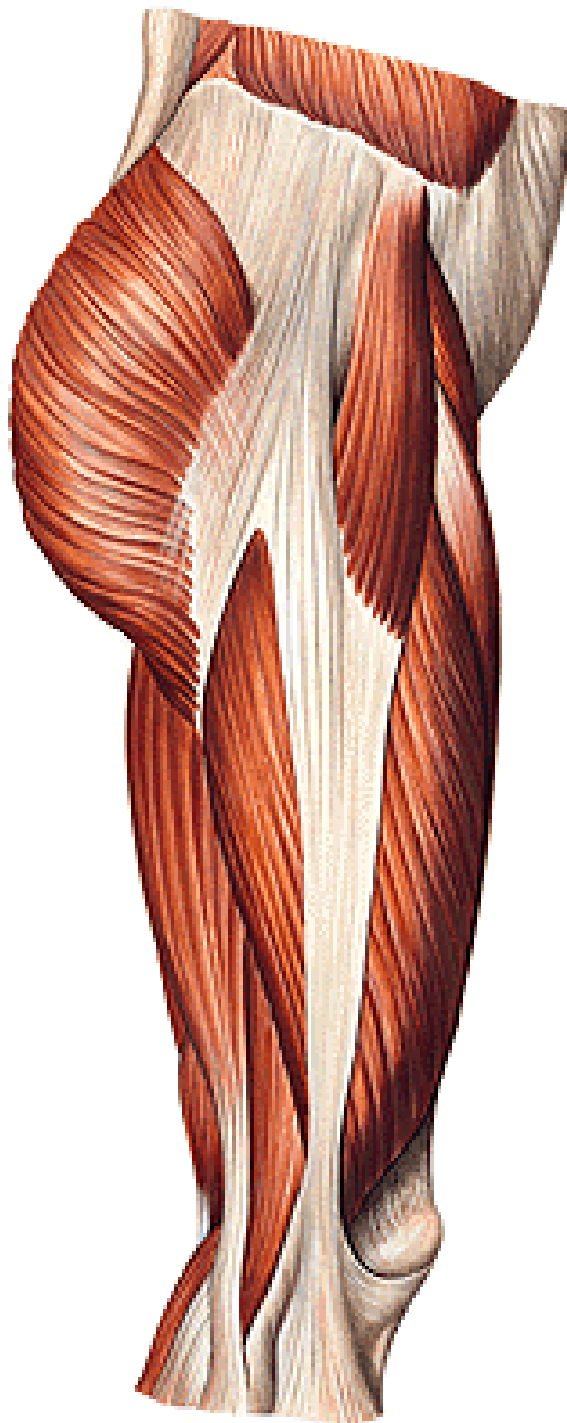
M. gluteus maximus



M. gluteus medius et minimus
M. piriformis →
Foramen suprapiriforme
Foramen infrapiriforme
M. obturatorius internus
M. gemellus superior et inferior
M. quadratus femoris



M. tensor fasciae latae
Tractus iliotibialis



MUSCULI COXAE

Anterior group:

M. psoas major
(M. psoas minor)

M. iliacus

→ M. iliopsoas

MUSCULI FEMORIS

Anterior group:

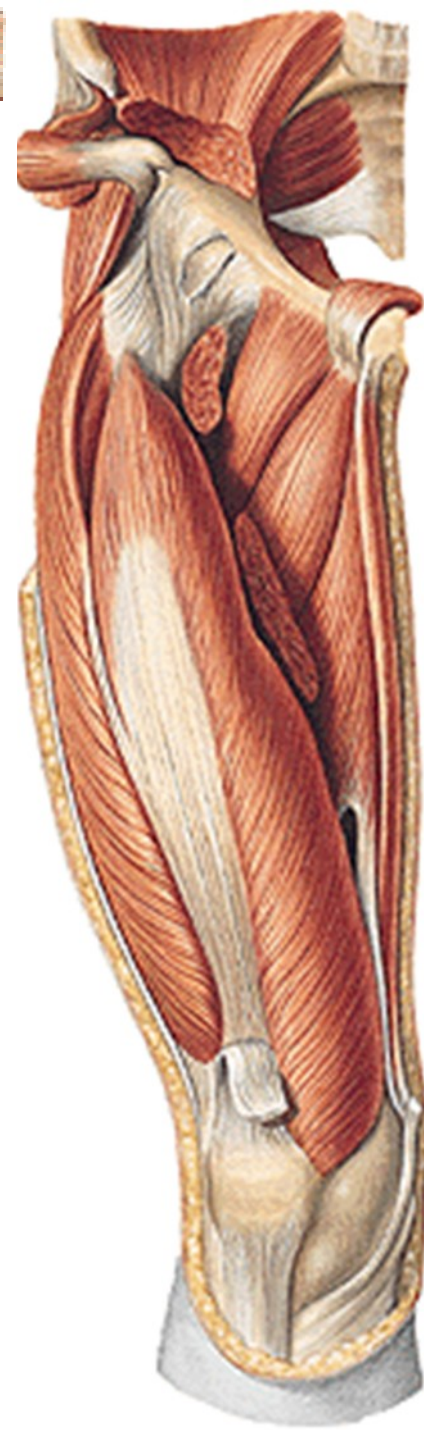
M. sartorius

M. quadriceps femoris:

m. rectus femoris

m. vastus med., lat.,

intermedius



MUSCULI FEMORIS

Medial group:

M. pectineus

M. adductor longus

M. adductor brevis

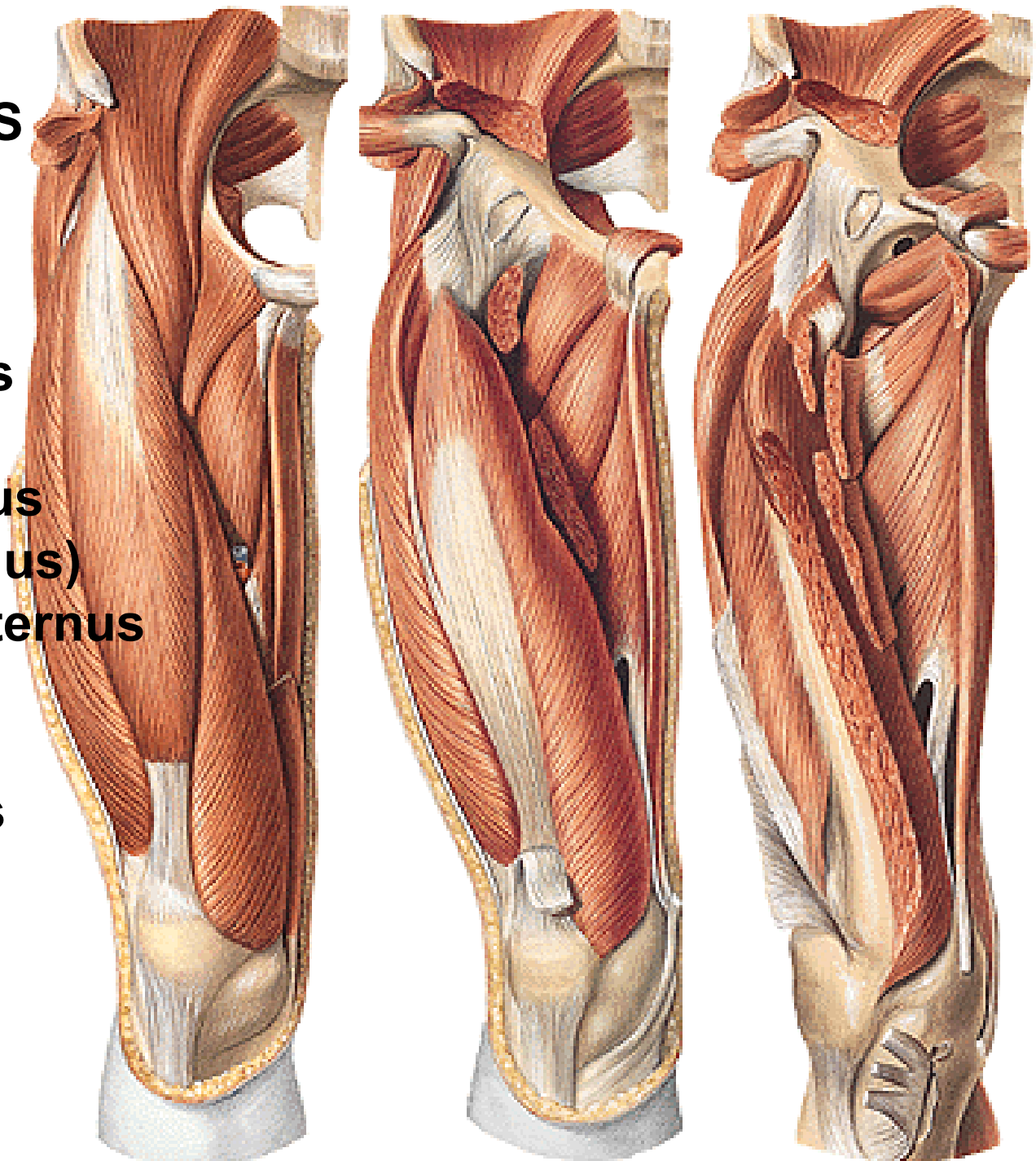
M. adductor magnus

(m.adductor minimus)

M. obturatorius externus

M. gracilis

Hiatus adductorius

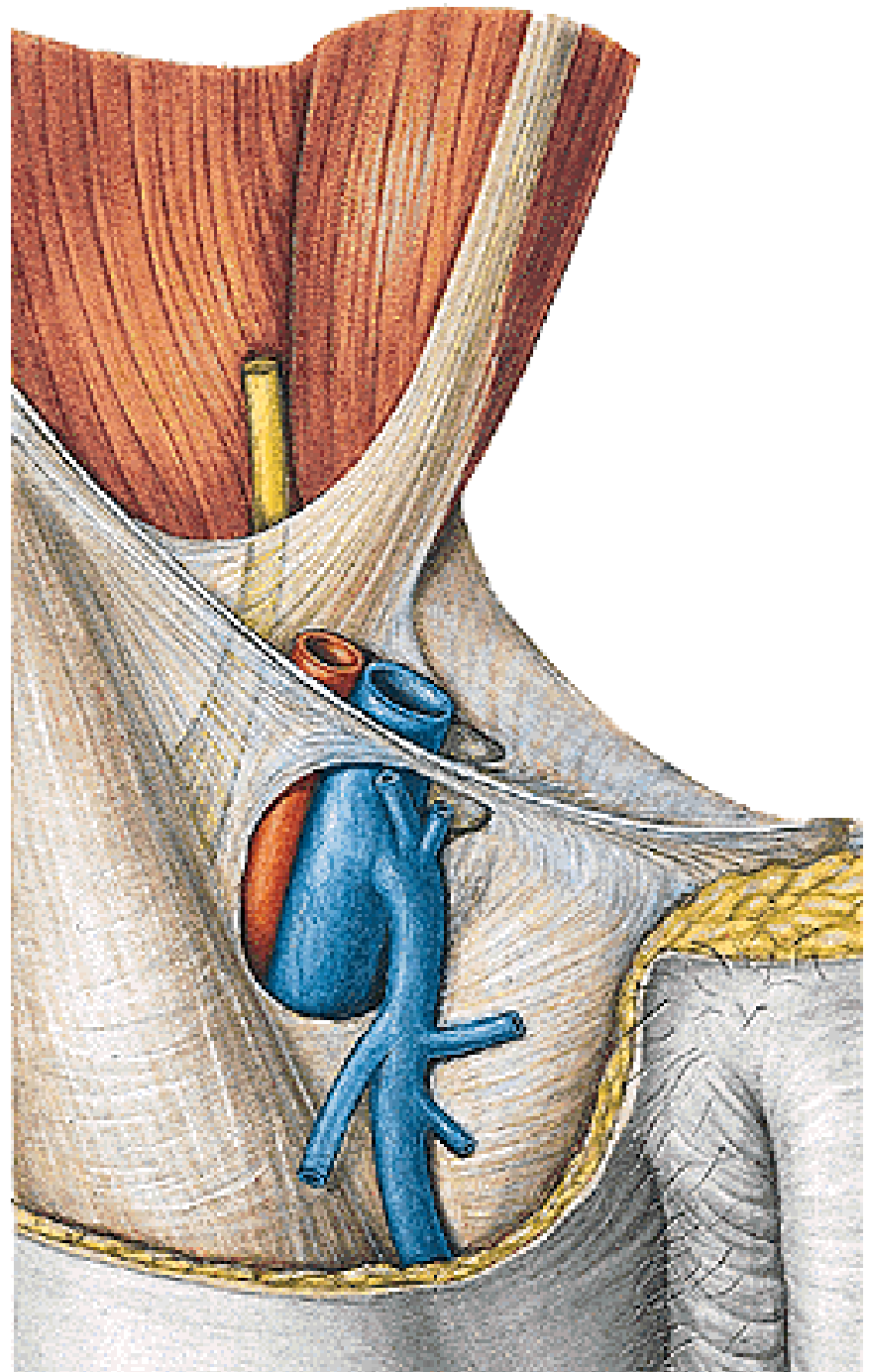


Lacuna musculorum
Lacuna vasorum

Arcus iliopectineus

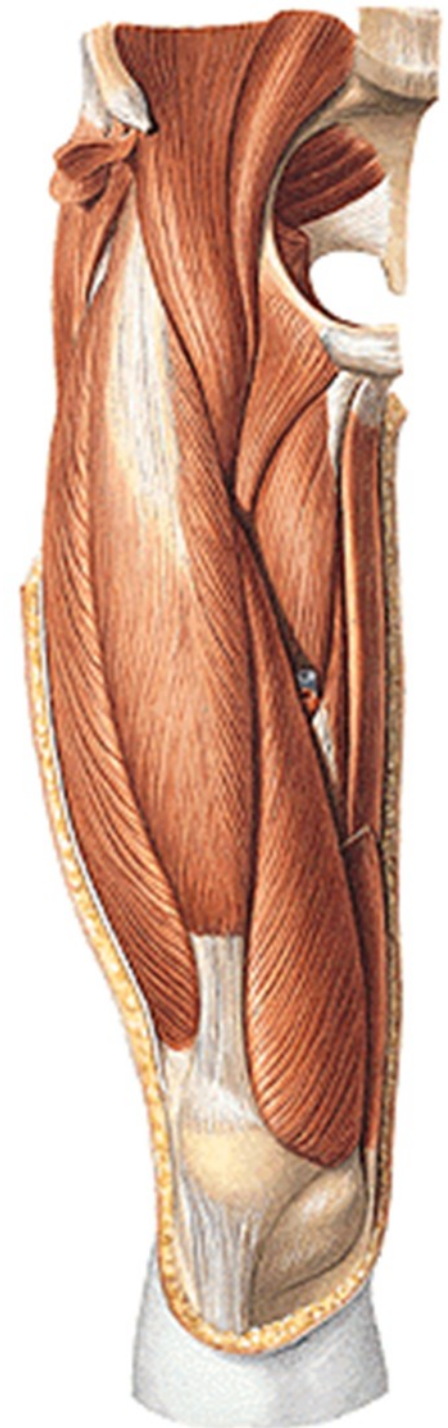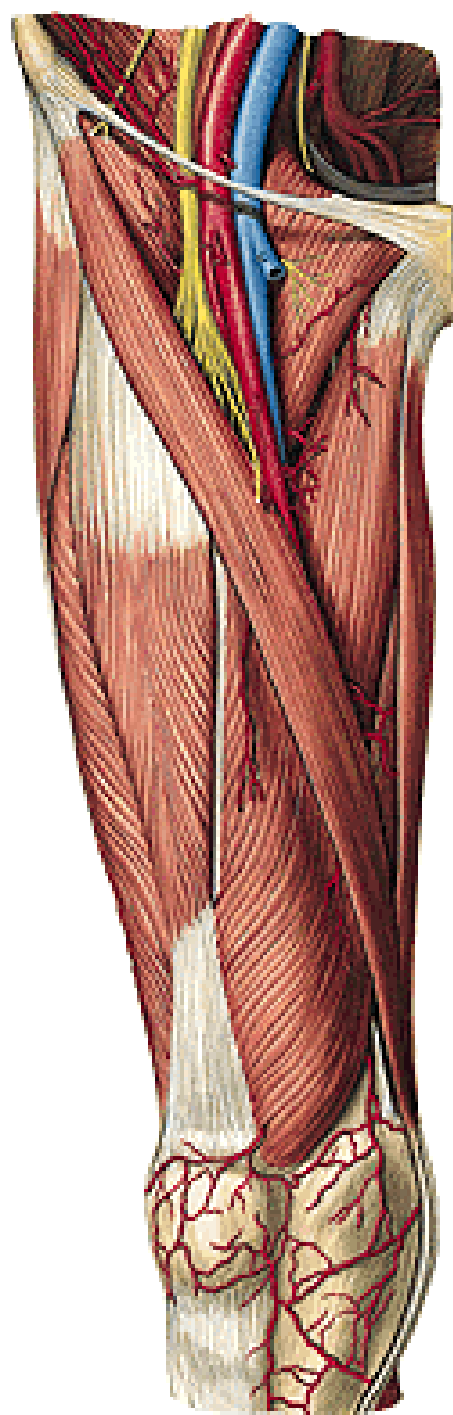
Lig. inguinale
Lig. lacunare

Canalis femoralis

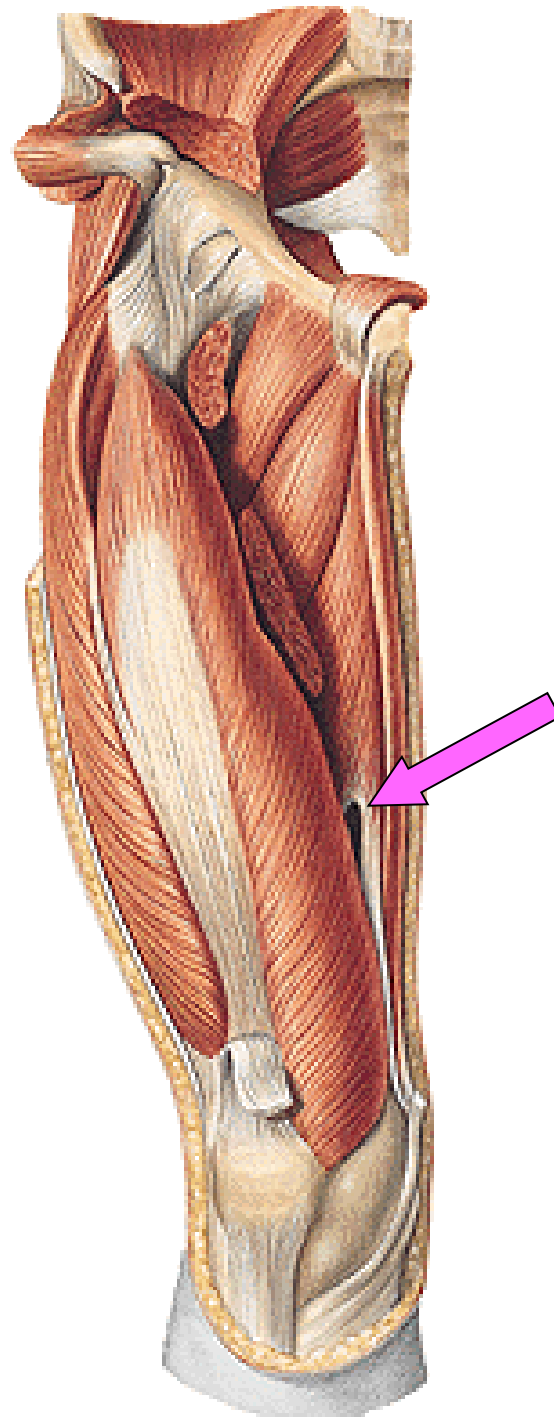
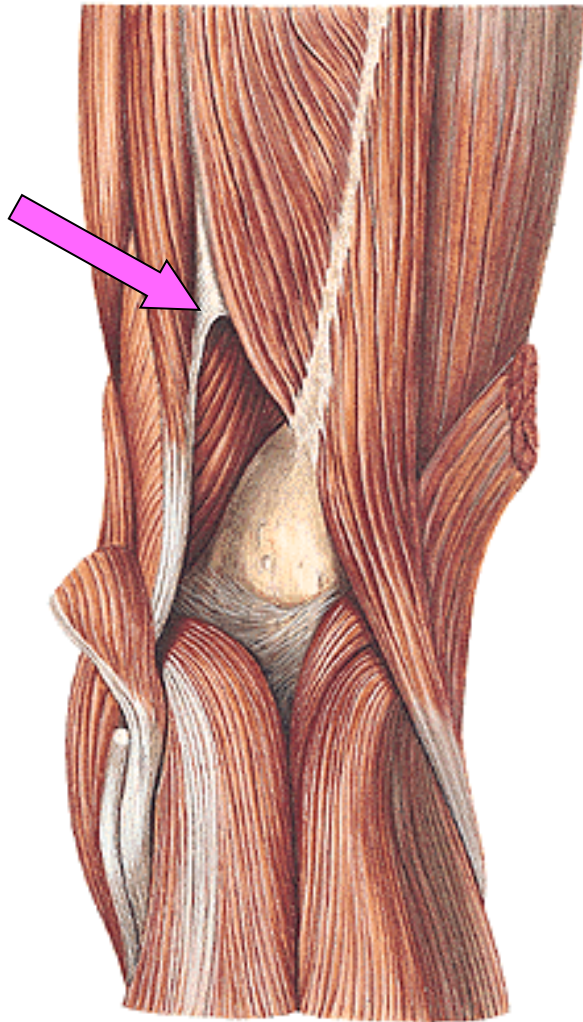


Trigonum femorale

Fossa iliopectinea

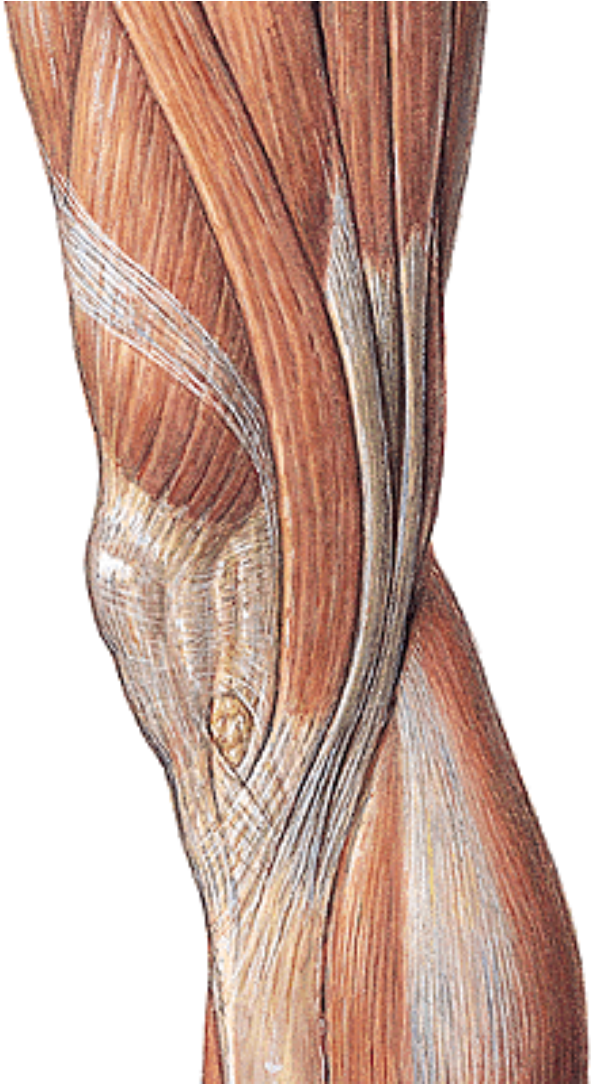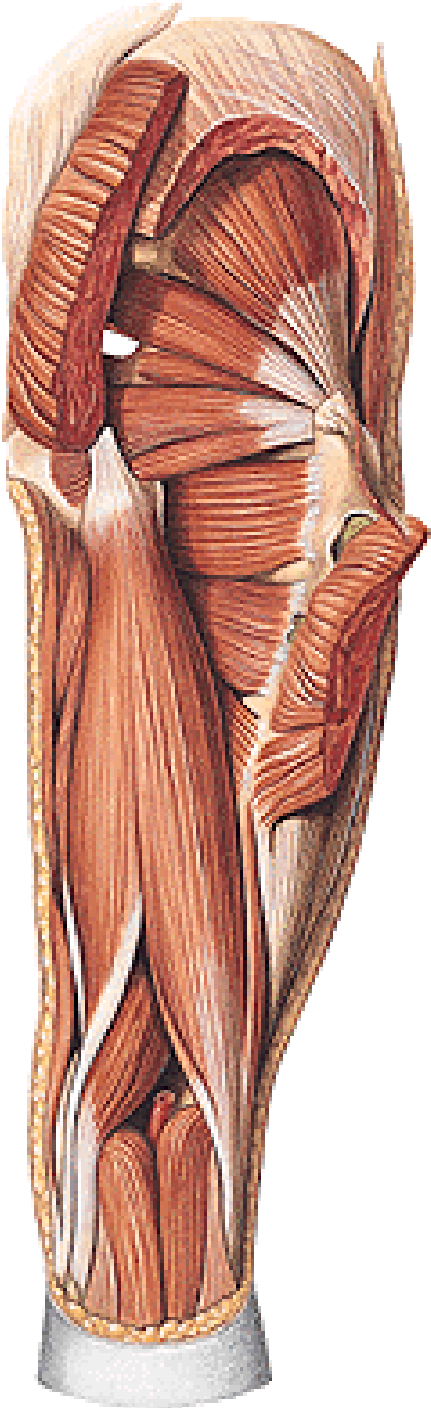


Hiatus tendineus/adductorius (Hunter)

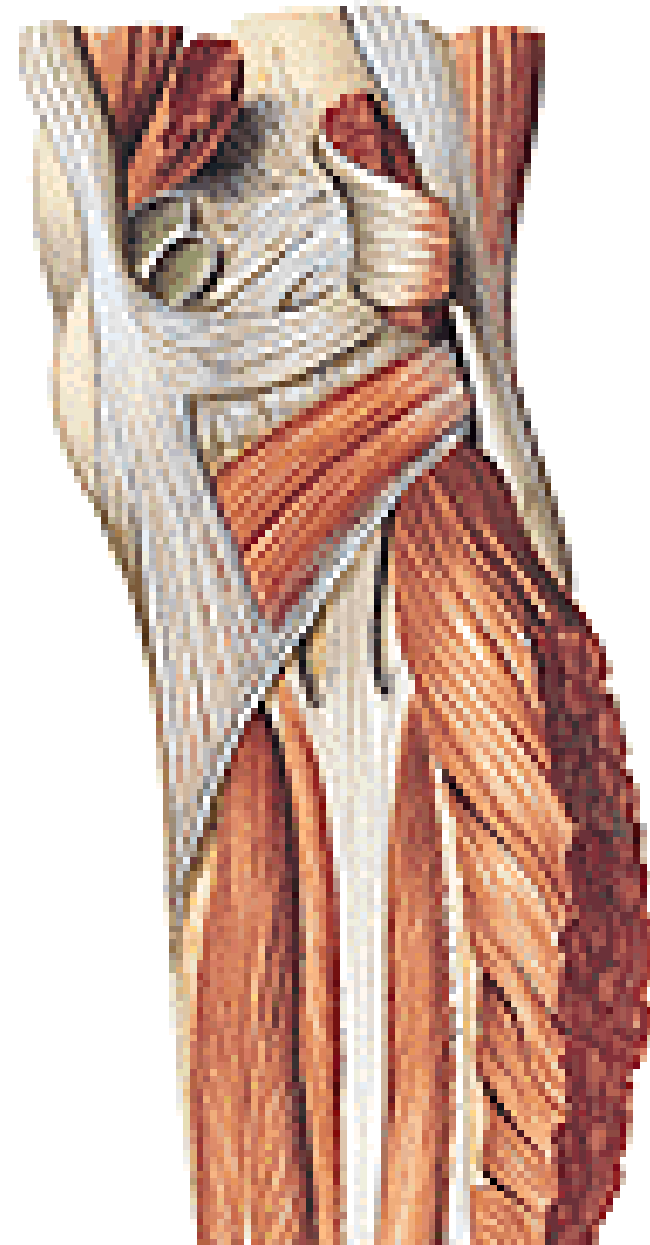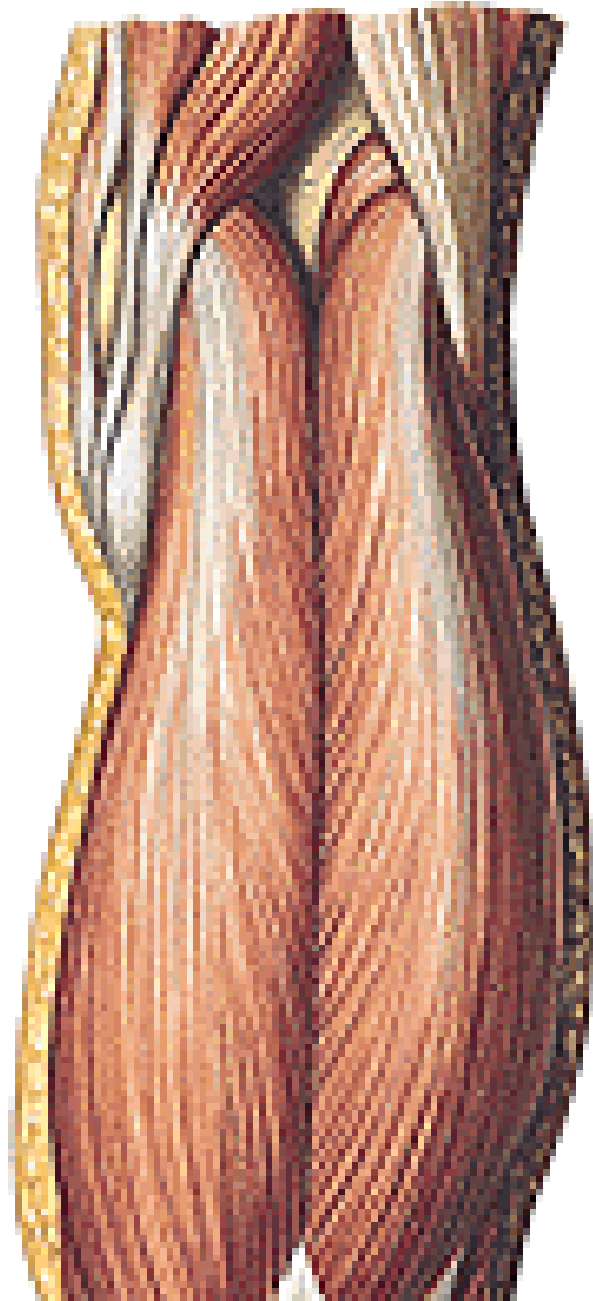


Hamstrings

Pes anserinus



Fossa poplitea



MUSCULI CRURIS

Anterior group:

M. tibialis ant.

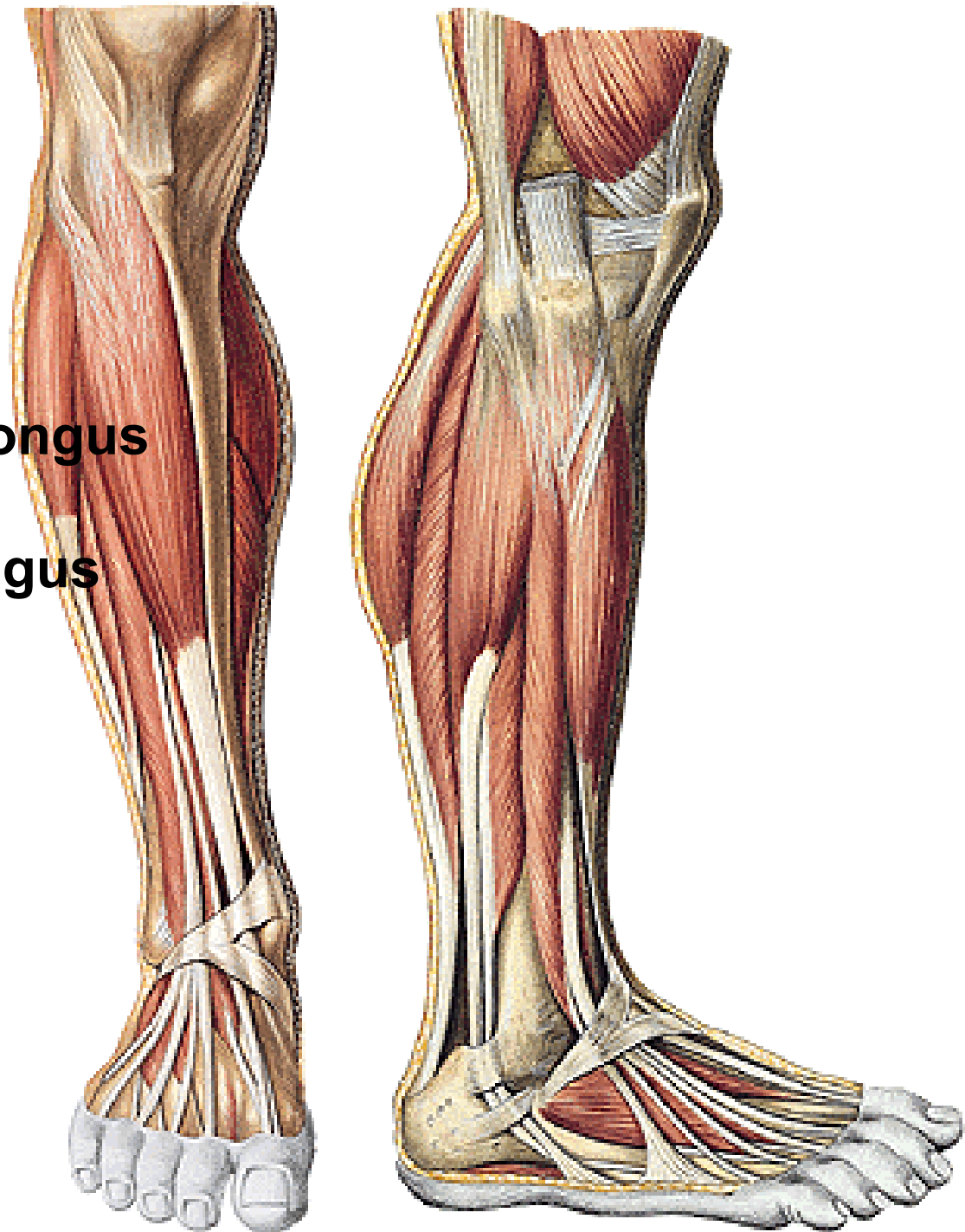
**M. extensor digitorum longus
(m. fibularis tertius)**

M. extensor hallucis longus

Lateral group:

M. fibularis longus

M. fibularis brevis



MUSCULI CRURIS

Posterior group:

M. triceps surae

- m. gastrocnemius
 - caput lat.
 - caput med.
- m. soleus

Arcus tendineus m. solei

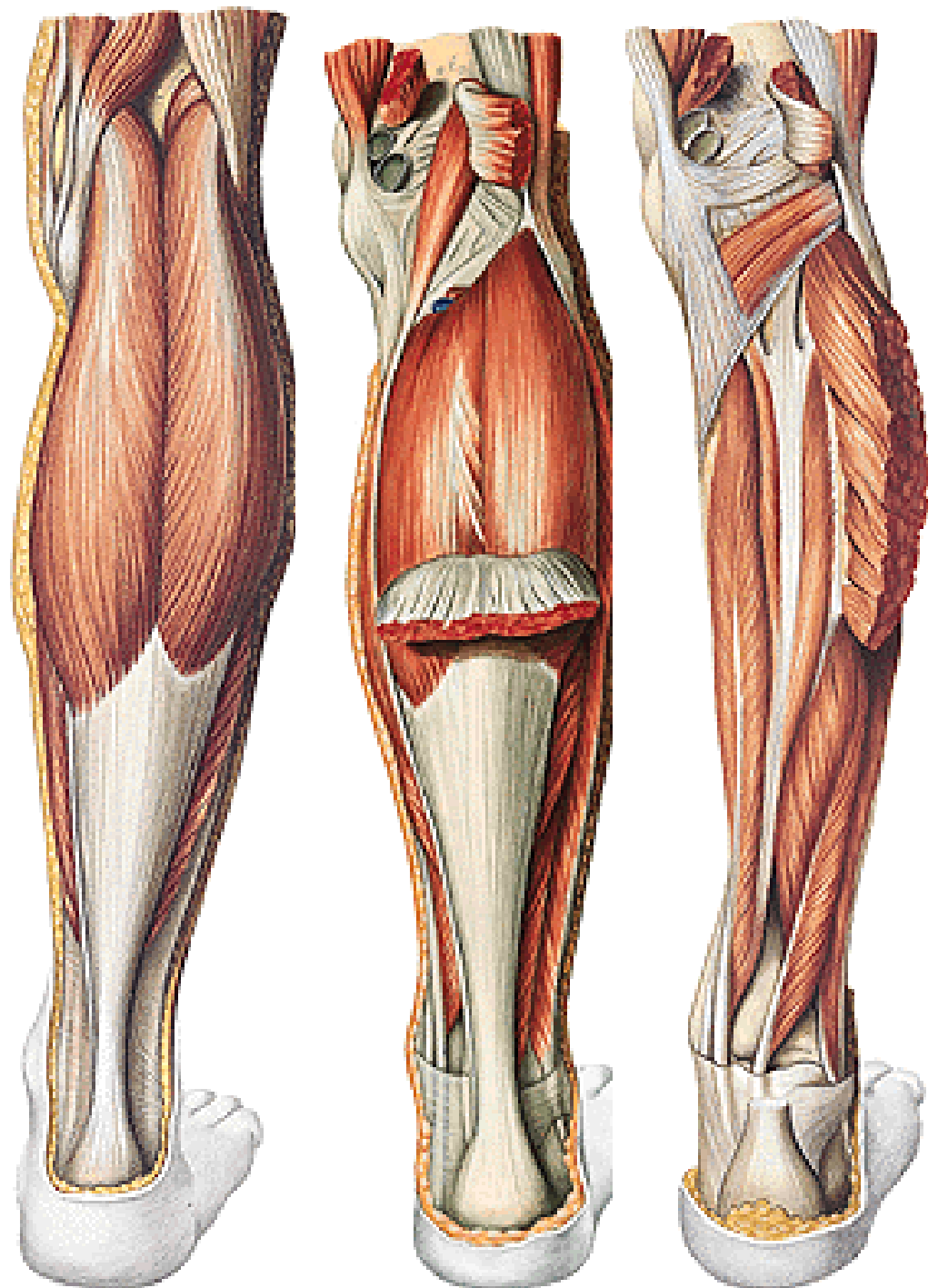
M. plantaris

M. popliteus

M. tibialis post.

M. flexor digitorum longus

M. flexor hallucis longus

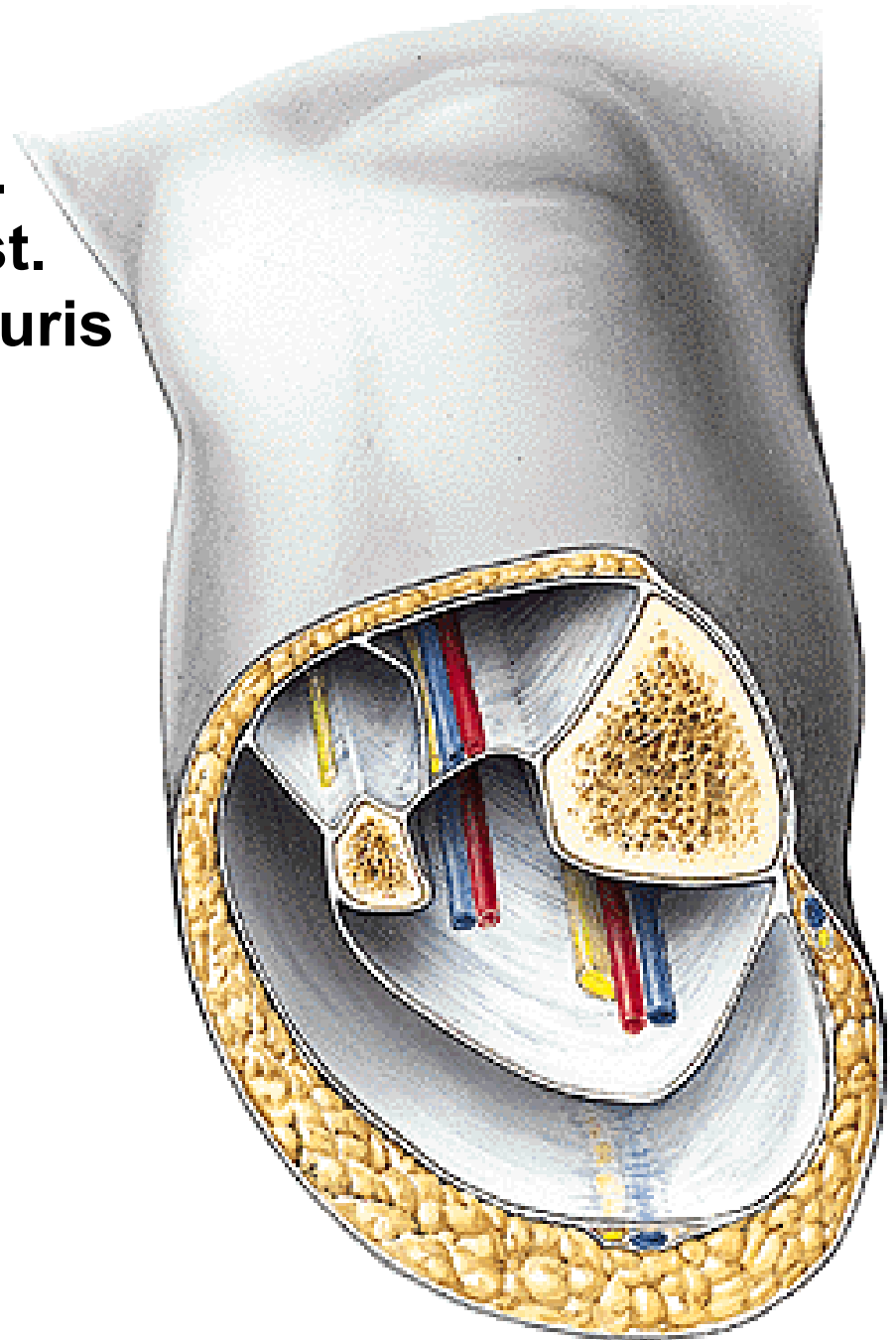


Fascia cruris

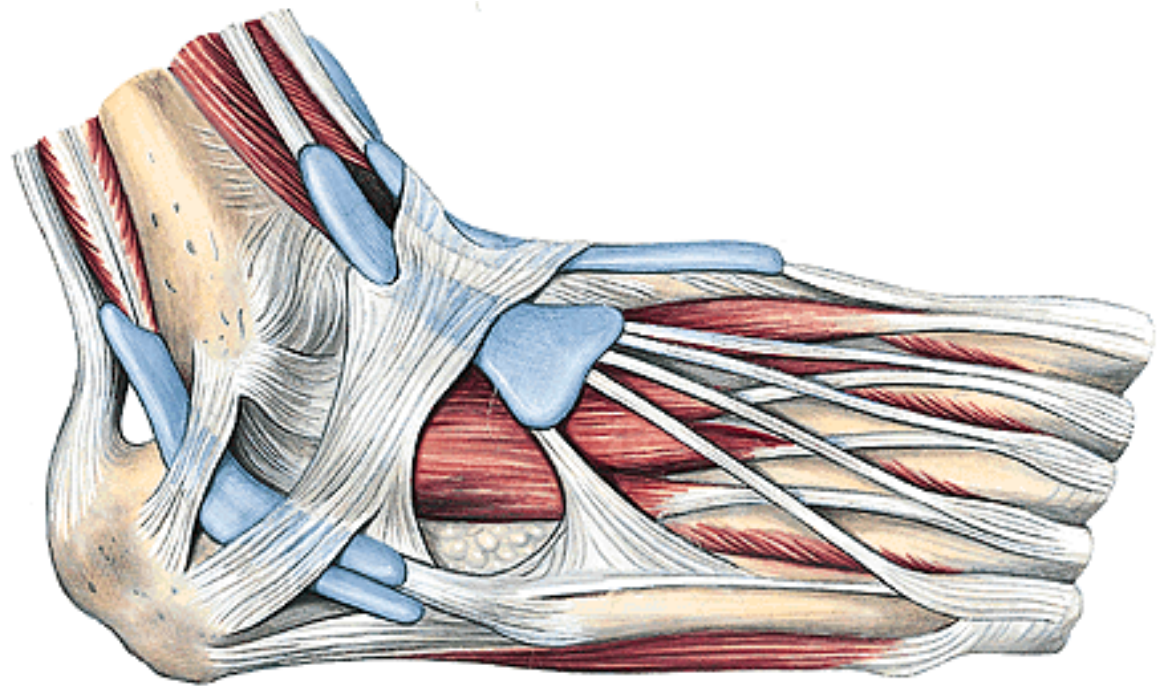
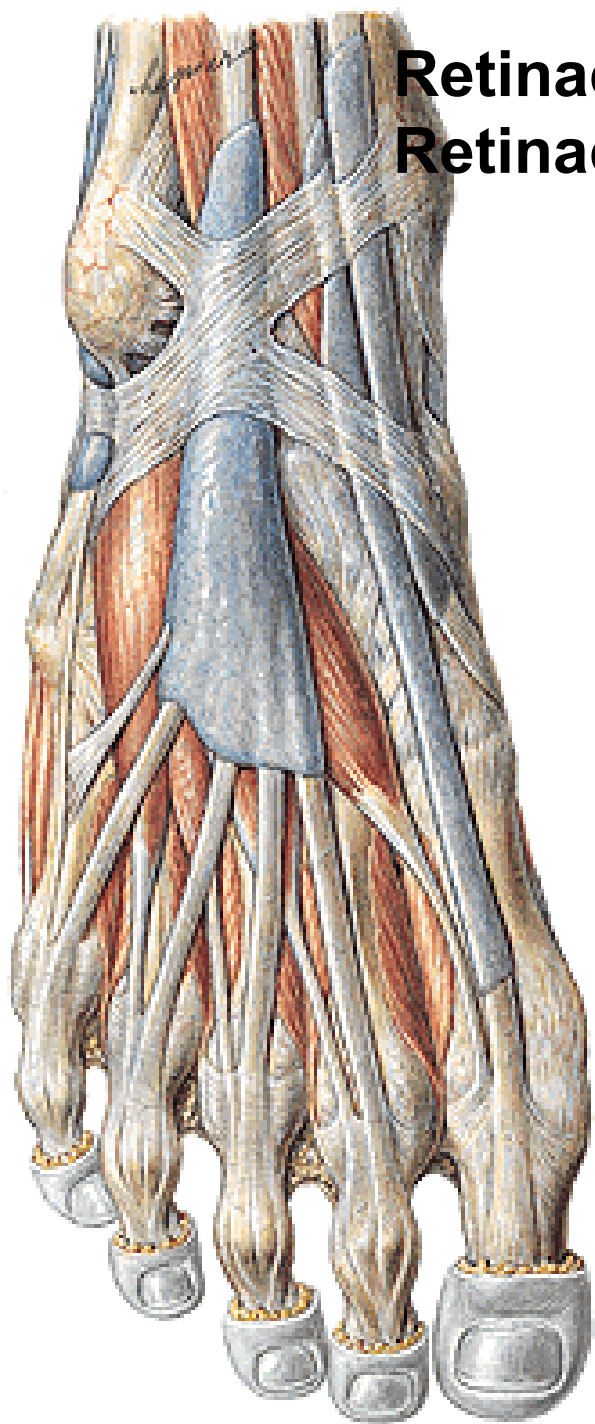
Septum intermusculare ant.

Septum intermusculare post.

Lamina profunda fasciae cruris



**Retinaculum musculorum extensorum sup. et inf.
Retinaculum musculorum fibularium sup. et inf.**



MUSCULI PEDIS

Dorsal group:

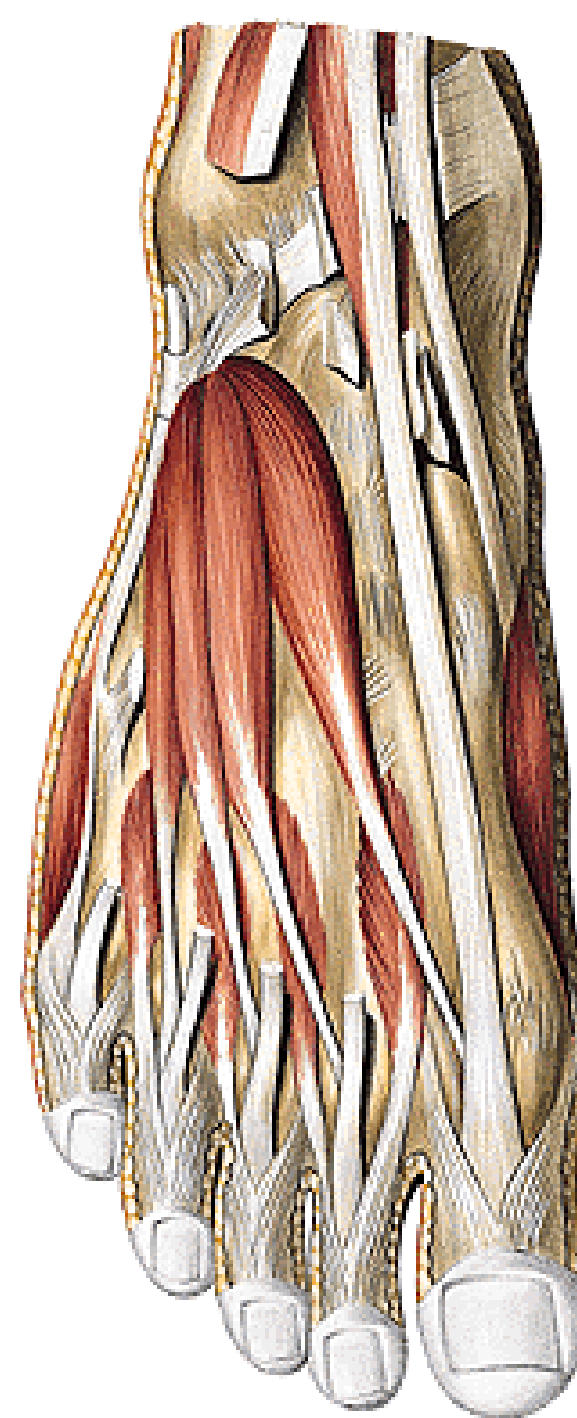
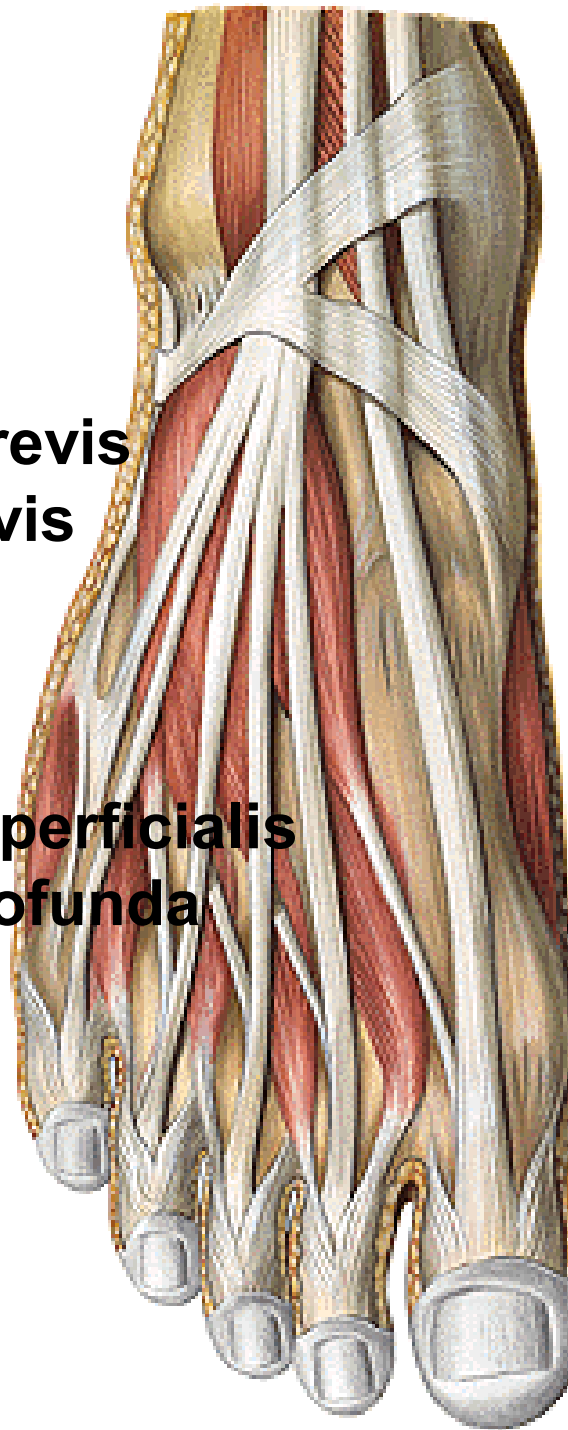
M. extensor digitorum brevis

M. extensor hallucis brevis

Mm. interossei dorsales

Fascia dorsalis pedis superficialis

Fascia dorsalis pedis profunda



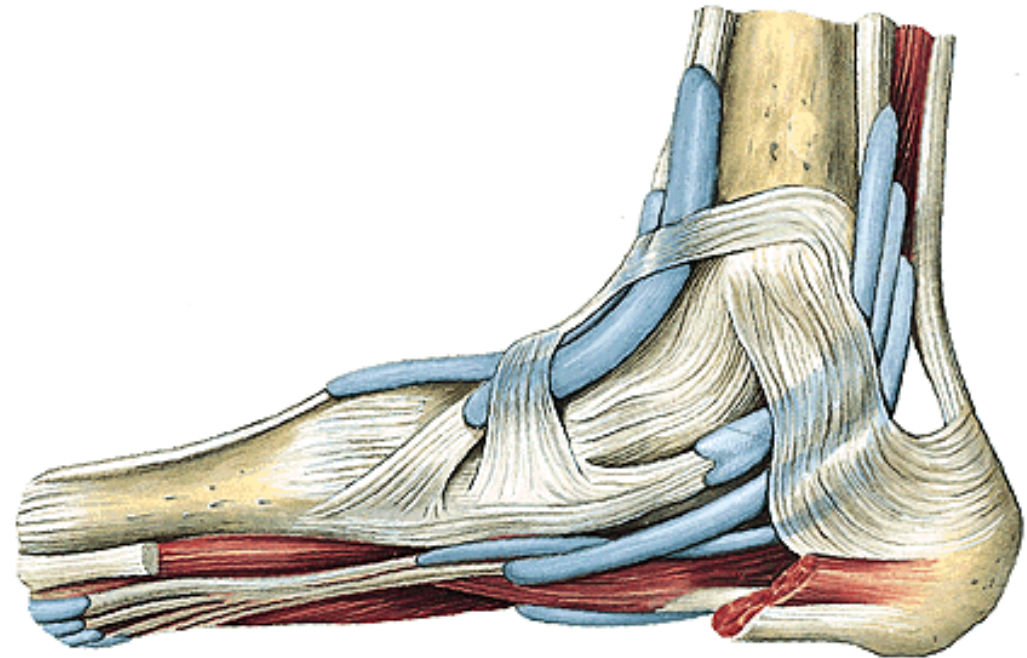
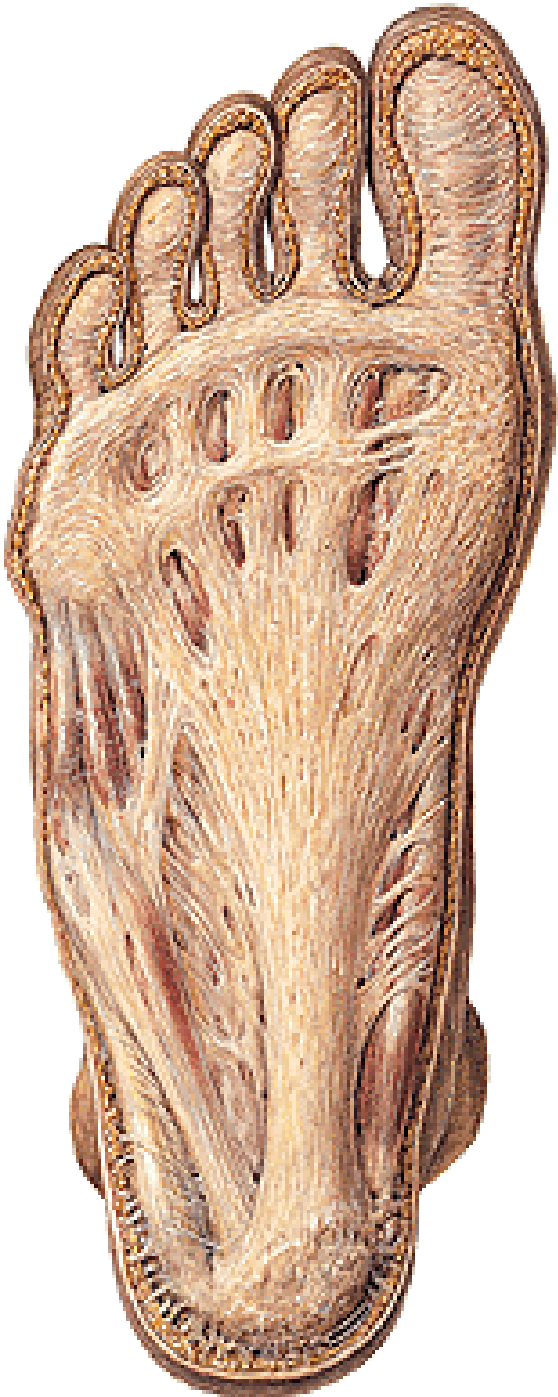PLANTA PEDIS

Fascia plantaris superficialis

Aponeurosis plantaris

Fascia plantaris interossea

Retinaculum musculorum flexorum



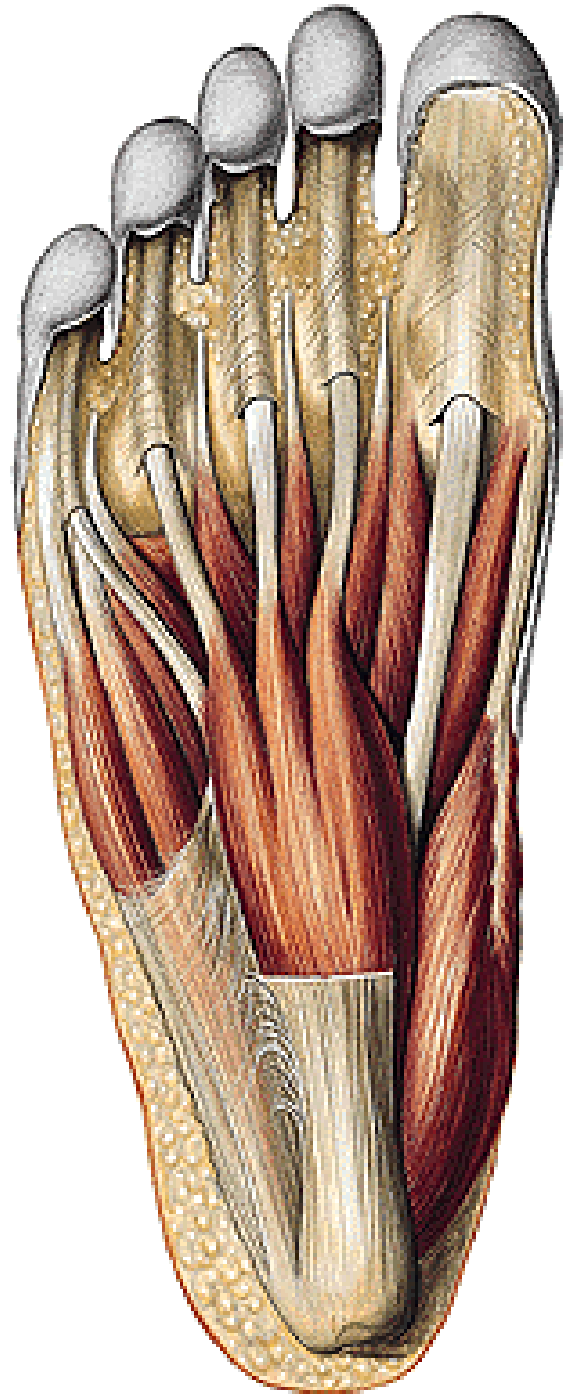
MUSCULI PEDIS

Plantar group:

M. abductor hallucis

M. flexor digitorum brevis

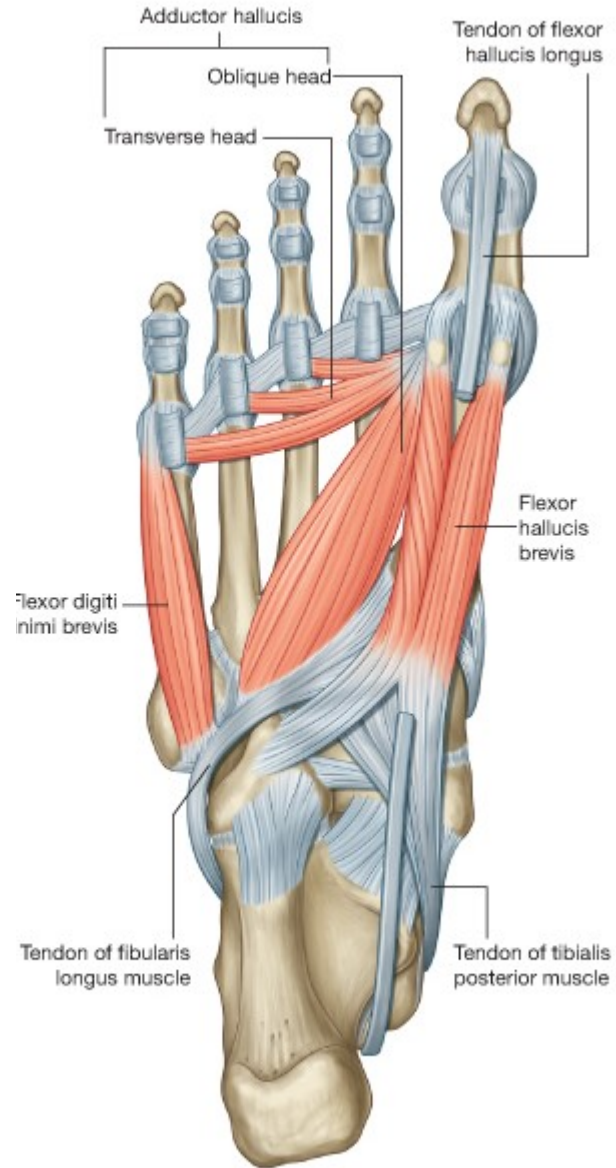
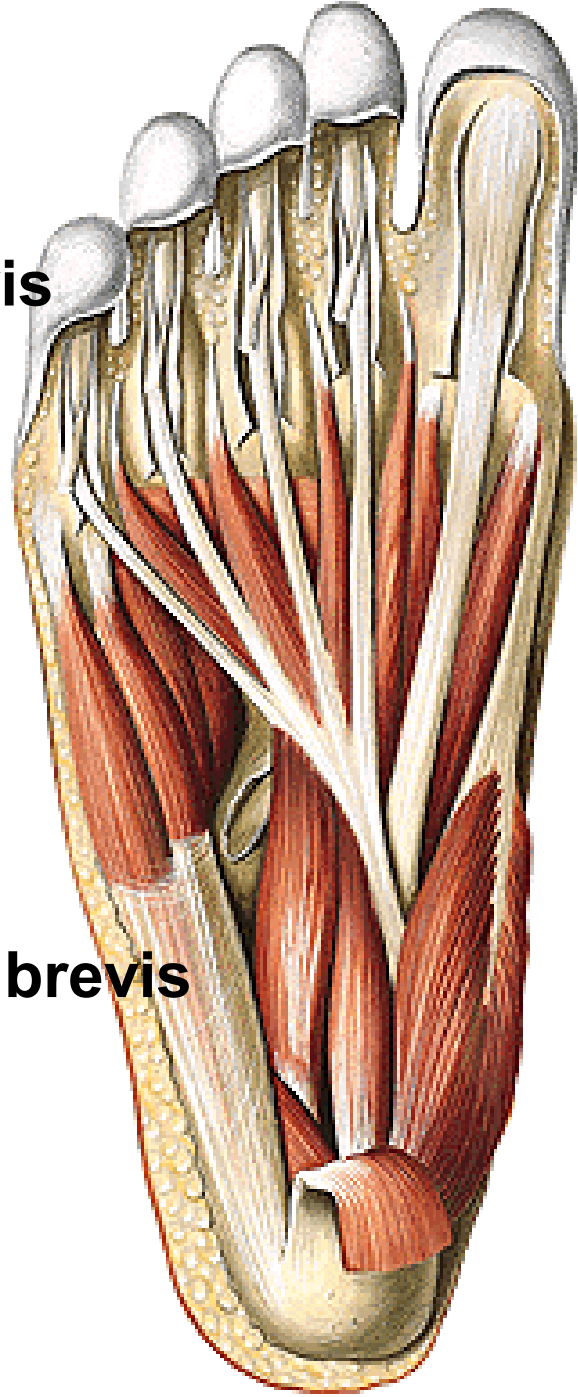
M. abductor digiti minimi



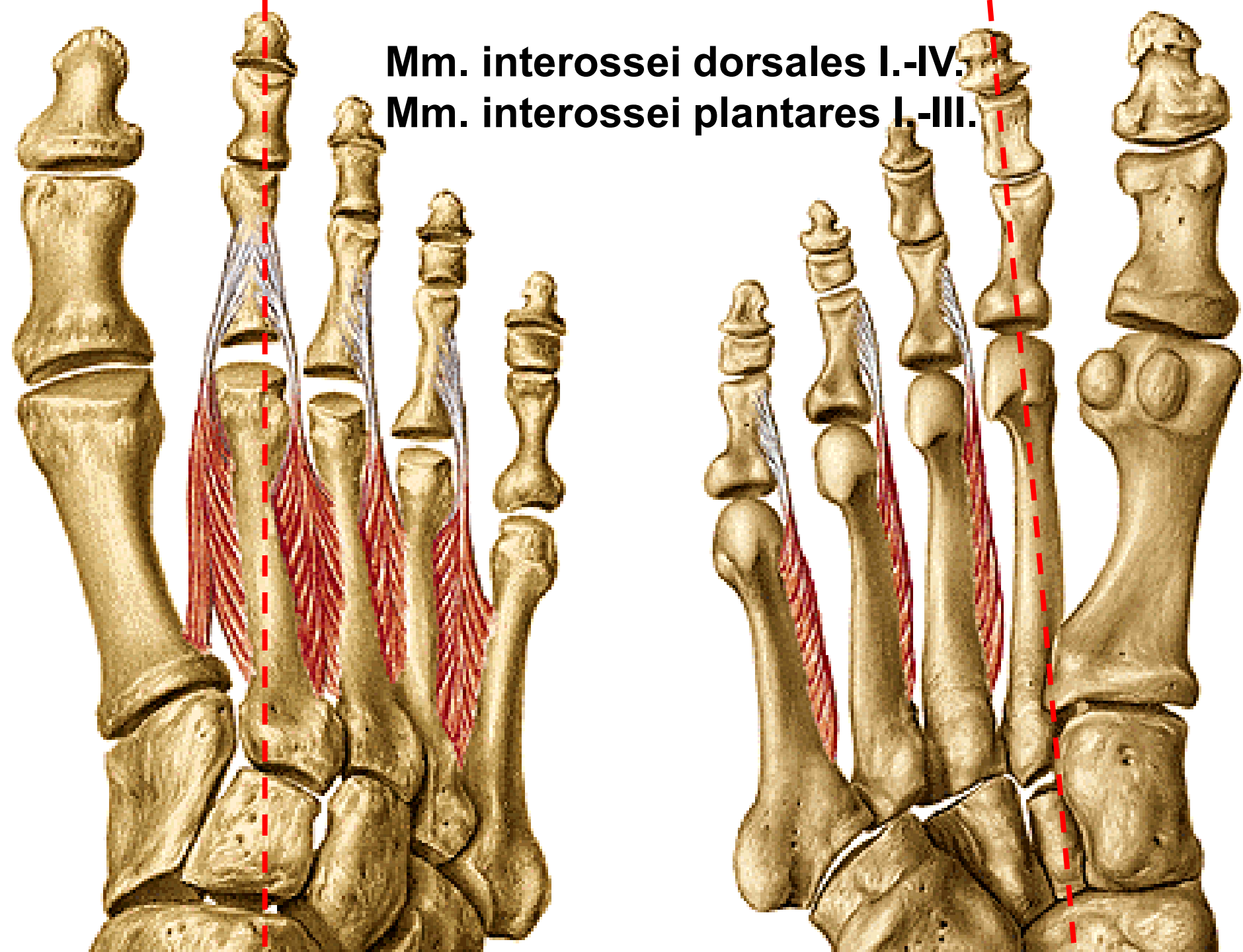
M. quadratus plantae
Mm. lumbricales I.-IV.

M. flexor hallucis brevis
M. adductor hallucis
- caput obliquum
- caput transversum

M. flexor digiti minimi brevis



Mm. interossei dorsales I.-IV.
Mm. interossei plantares I.-III.



Illustrations were copied from:

**Atlas der Anatomie des Menschen/Sobotta.
Putz,R., und Pabst,R. 20. Auflage. München:
Urban & Schwarzenberg, 1993)**