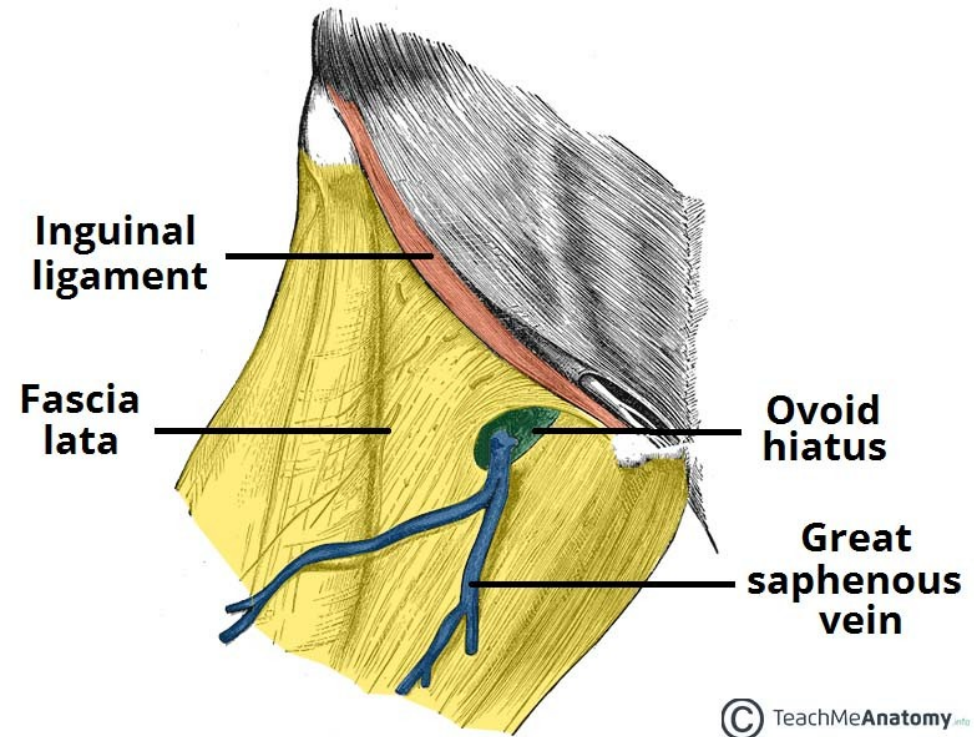


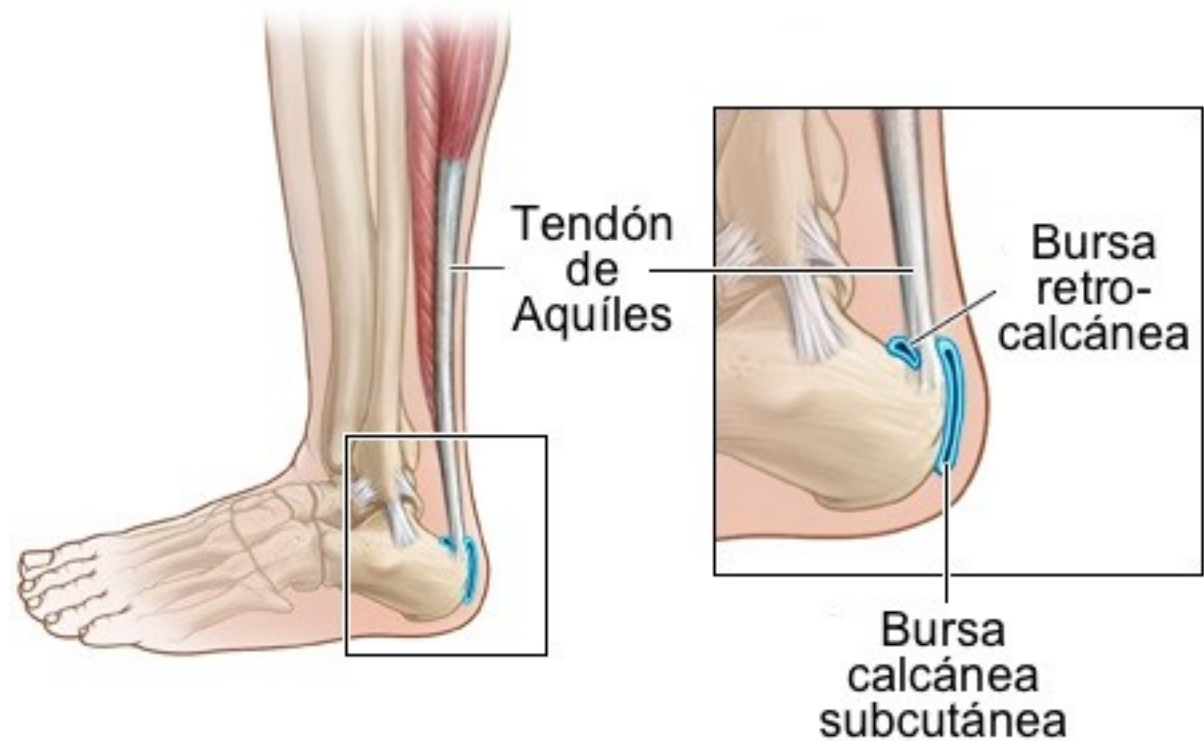
Tutorium Week 2

Exercise 1

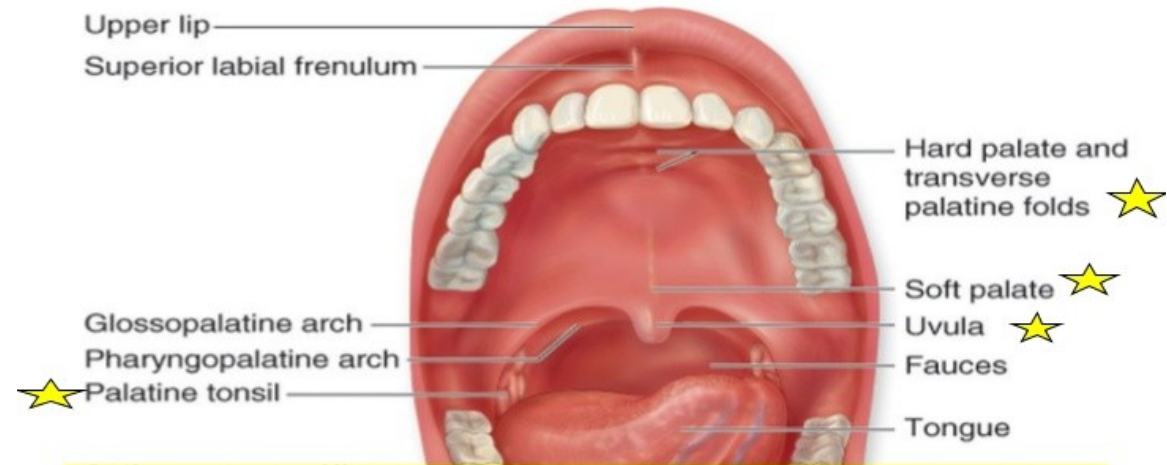
- Fascia lata - the deep fascia of the thigh



- Bursa subcutanea - the frequently occurring bursa between the acromion and the skin.

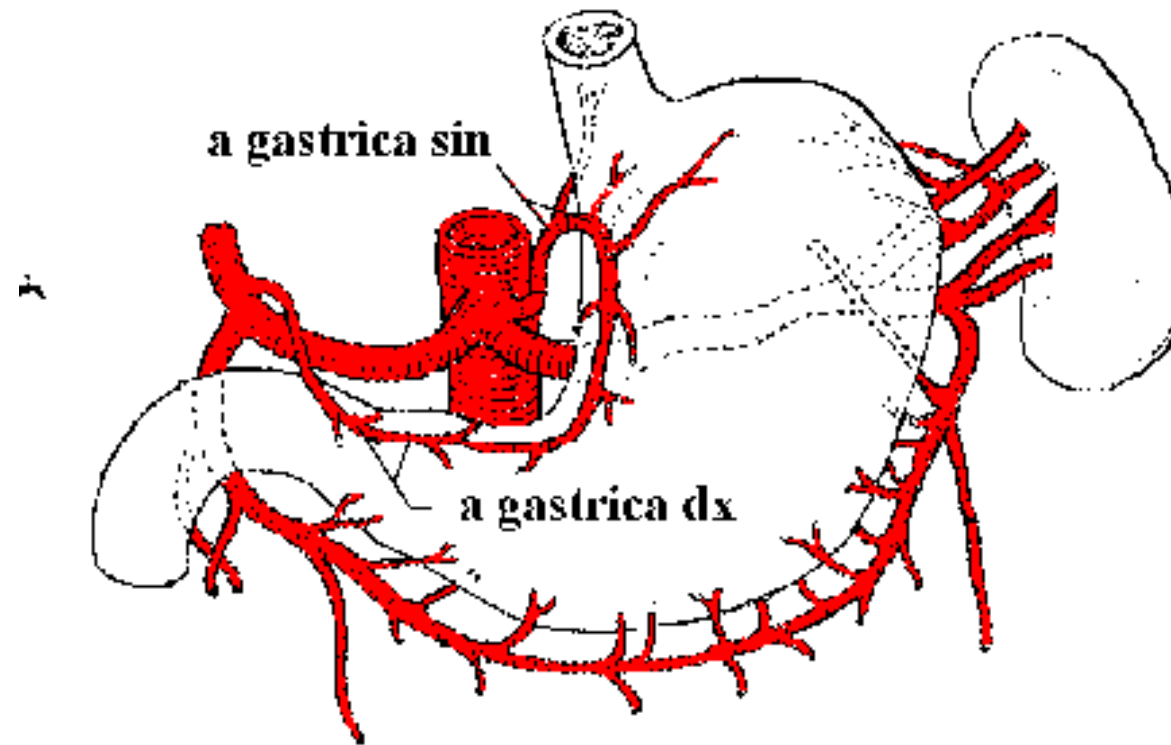


- Plica palatina - transverse palatine fold



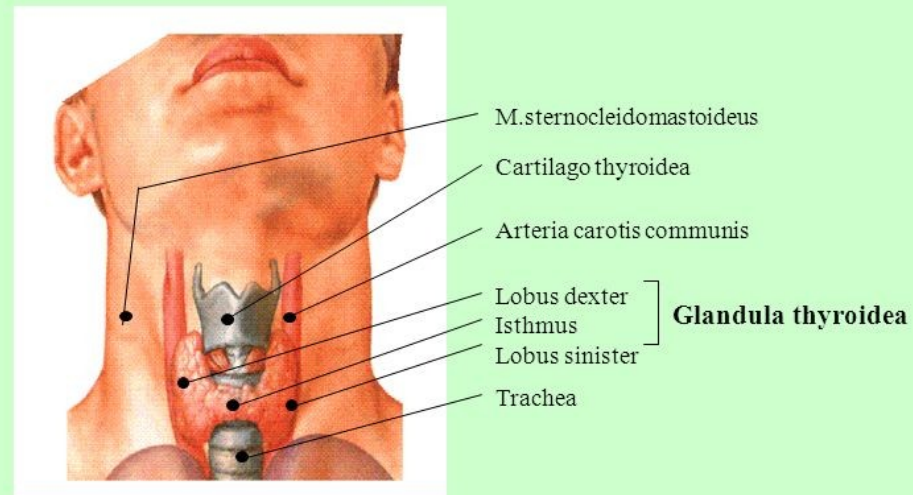
The **hard palate** is formed by the palatine processes of the maxillae and the horizontal plates of the palatine bones. Transverse folds assist the tongue in manipulating food. The **soft palate** is mostly composed of skeletal muscle. The **uvula** and soft palate rise superiorly during swallowing to close off the nasopharynx. The **palatine tonsils** monitor ingested food and drink for harmful antigens.

- Arteria gastrica – gastric artery - the arteries that supply the walls of the stomach

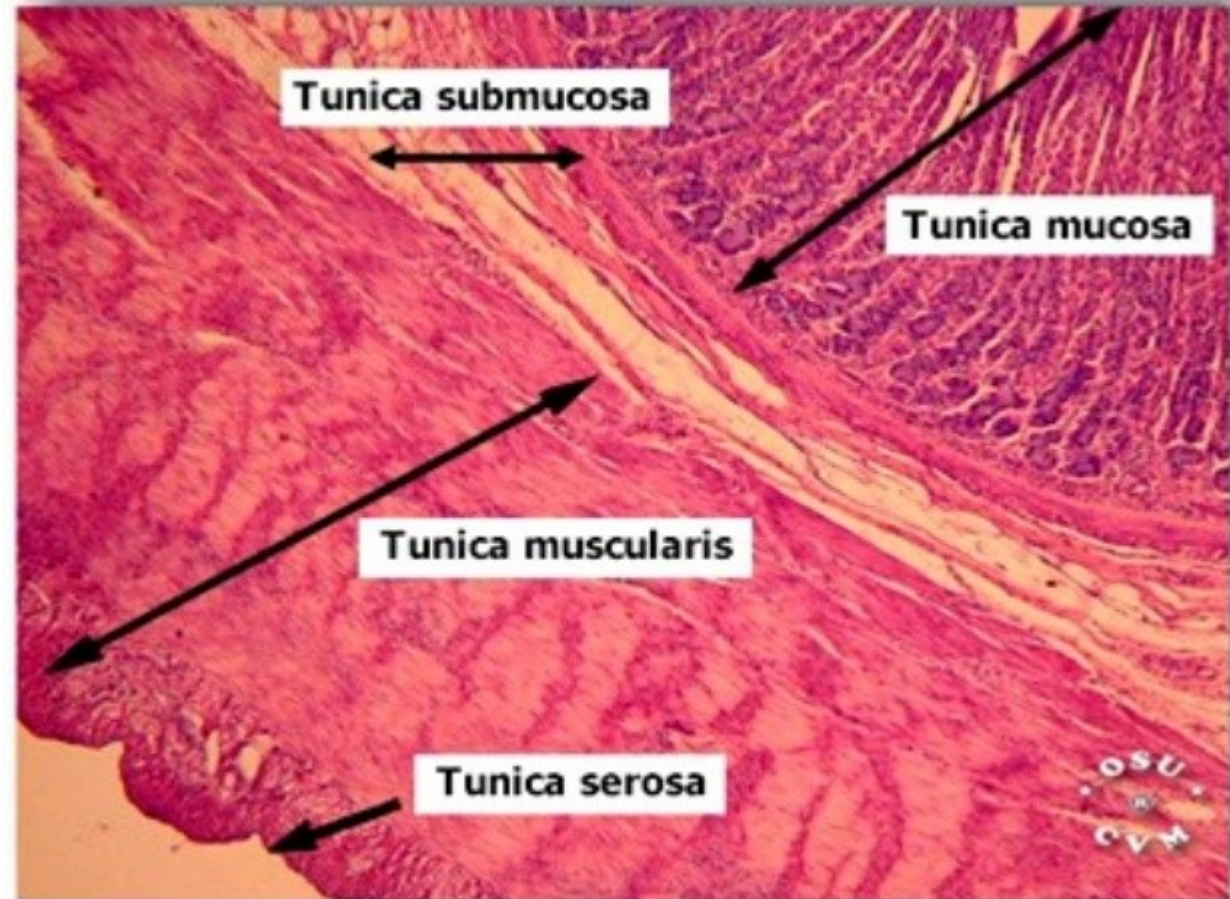


- Glandula thyroidea - The thyroid gland, or simply the thyroid

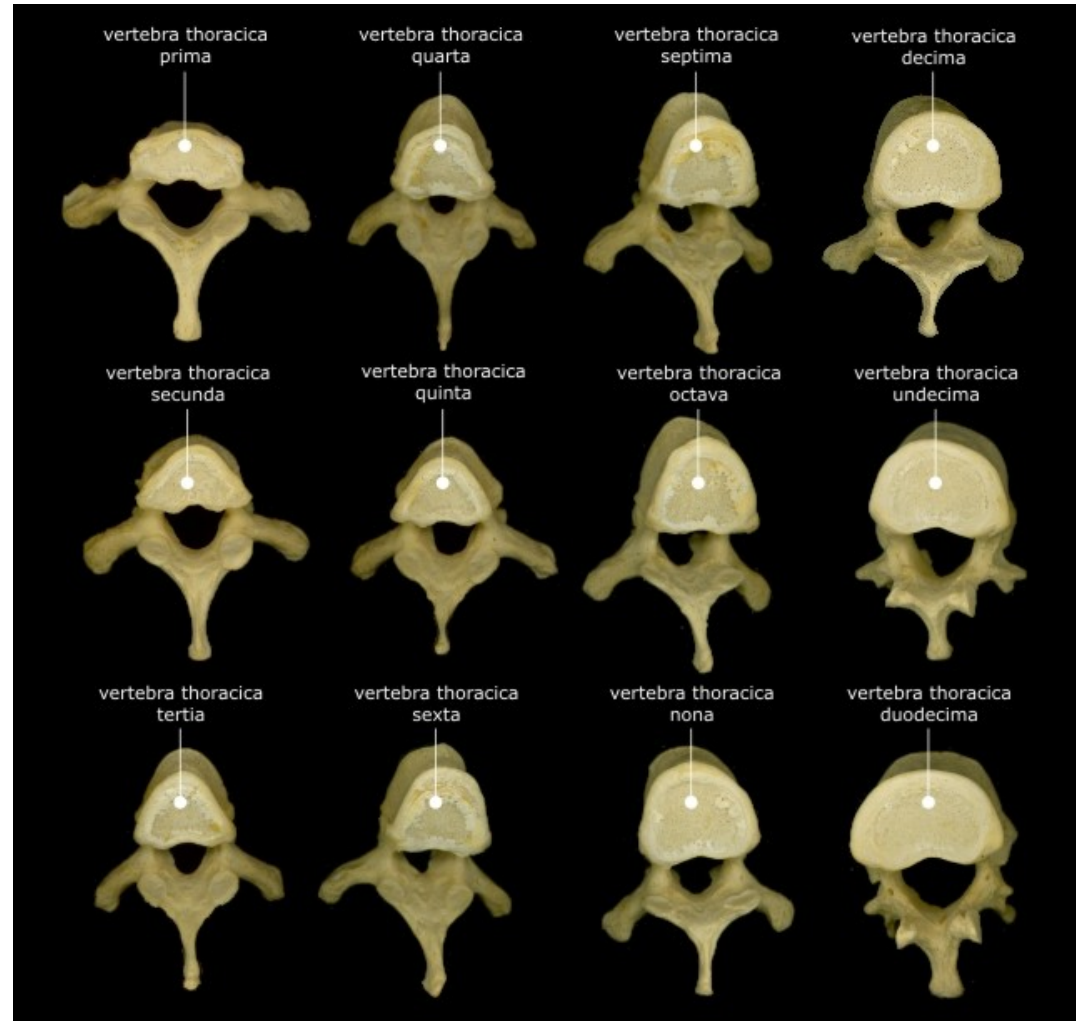
Glandula Thyroidea



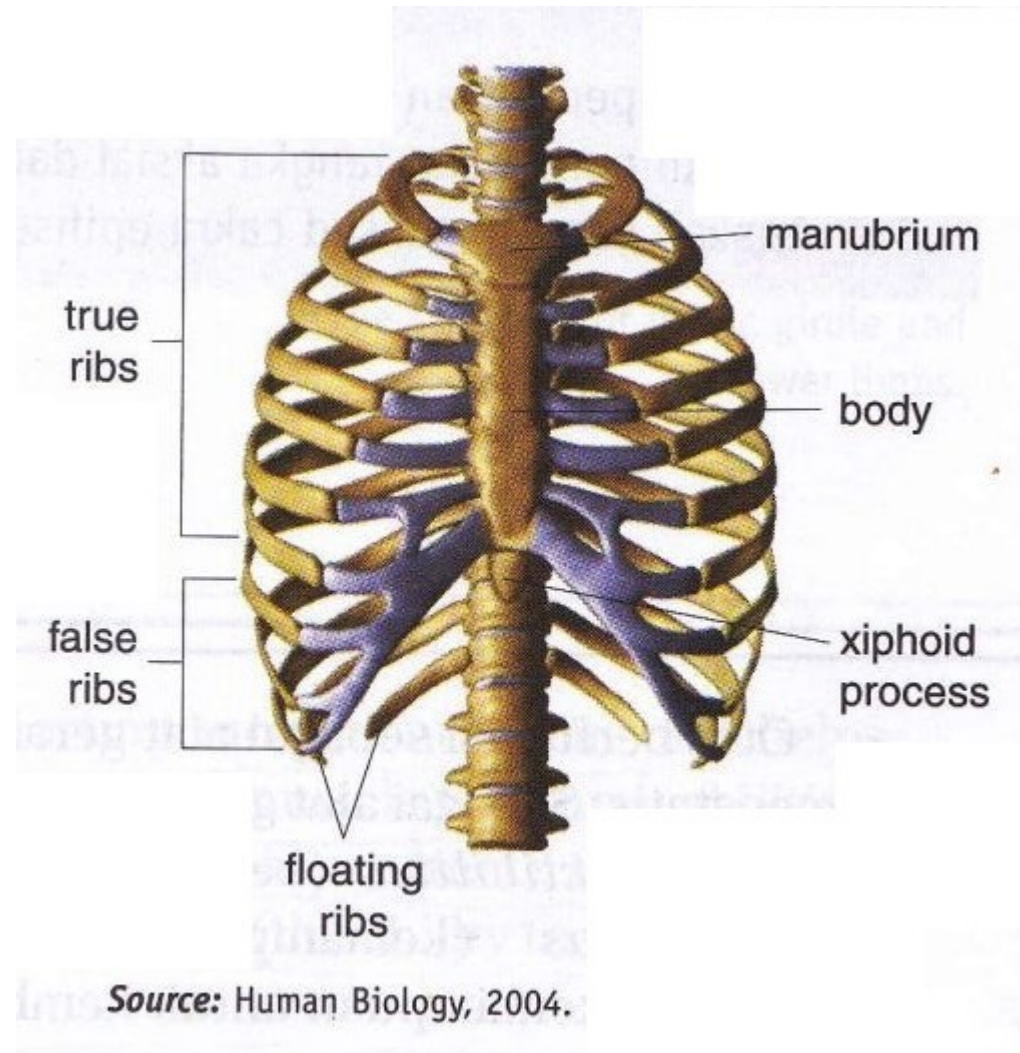
- Tunica mucosa - A mucous membrane



Vertebrae thoracicae - thoracic vertebrae

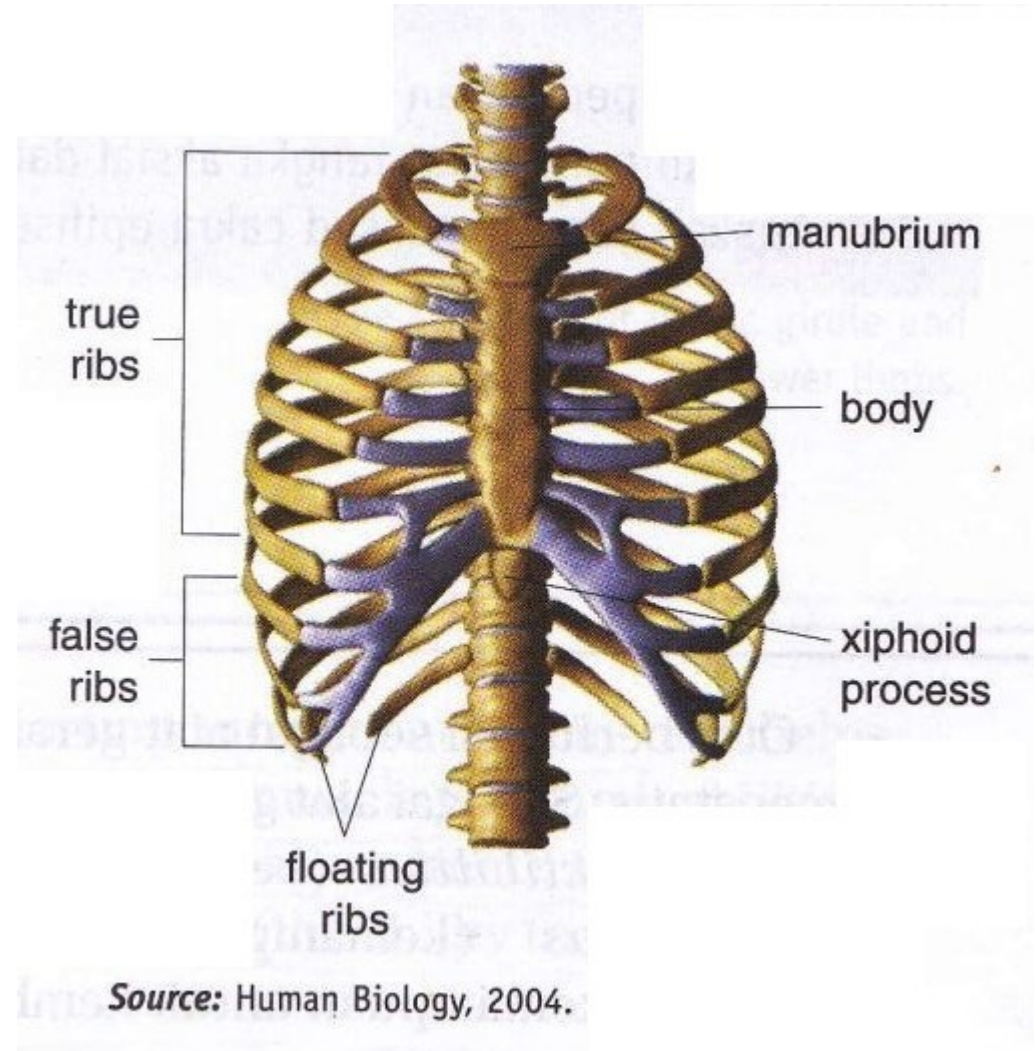


- Costa spuria – false ribs



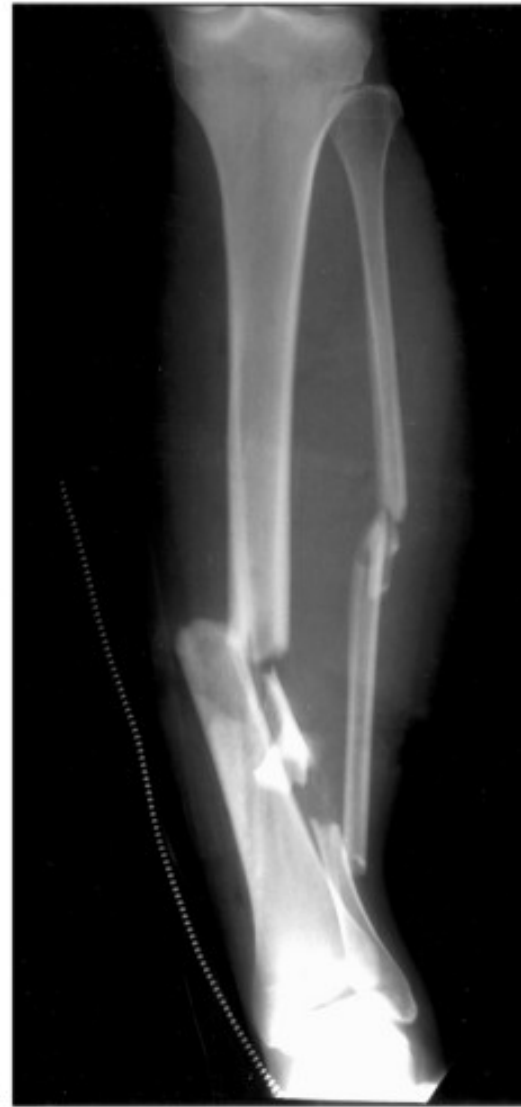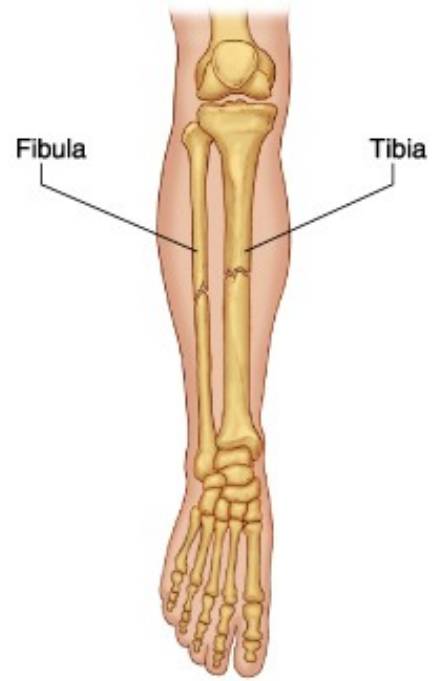
The structure of rib cage.

- Costa vera – true ribs

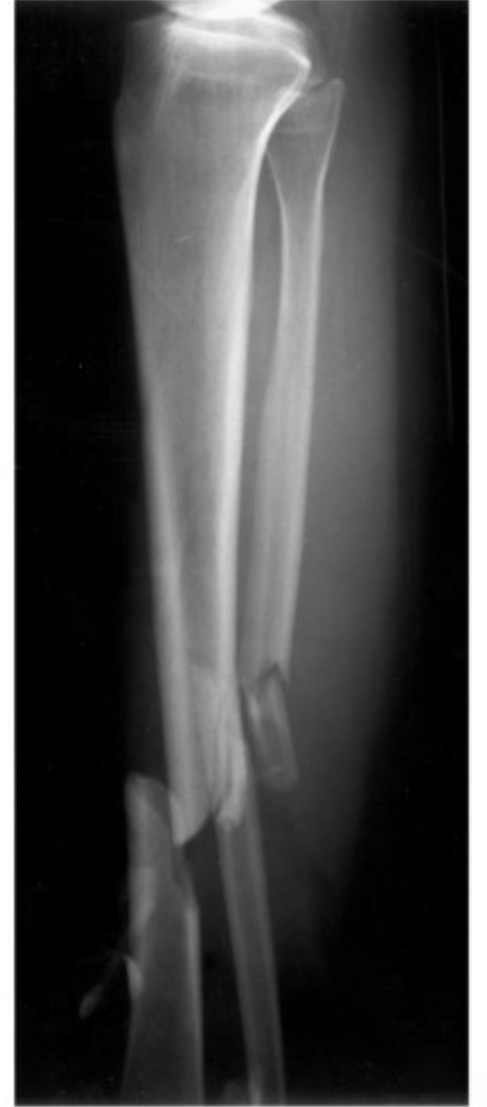

The structure of rib cage.

- Tibia et fibula fracta

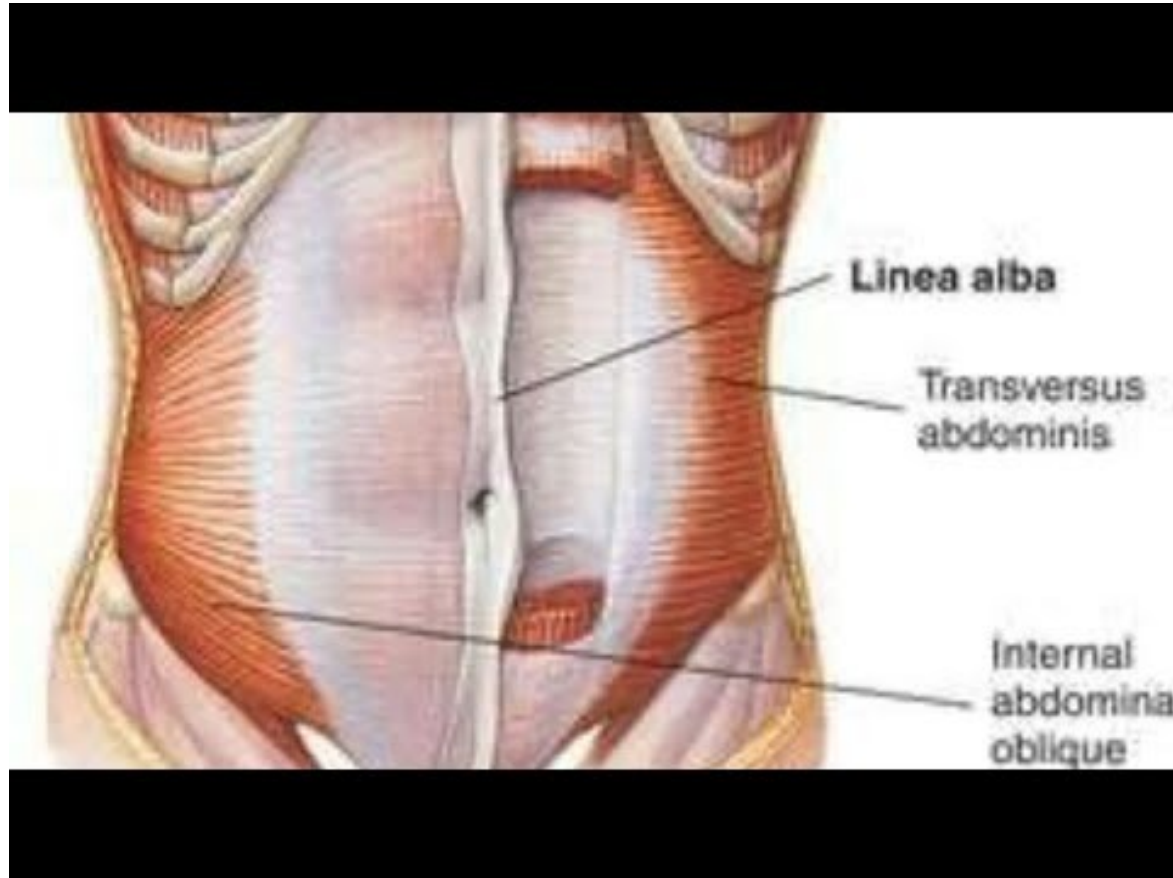


A

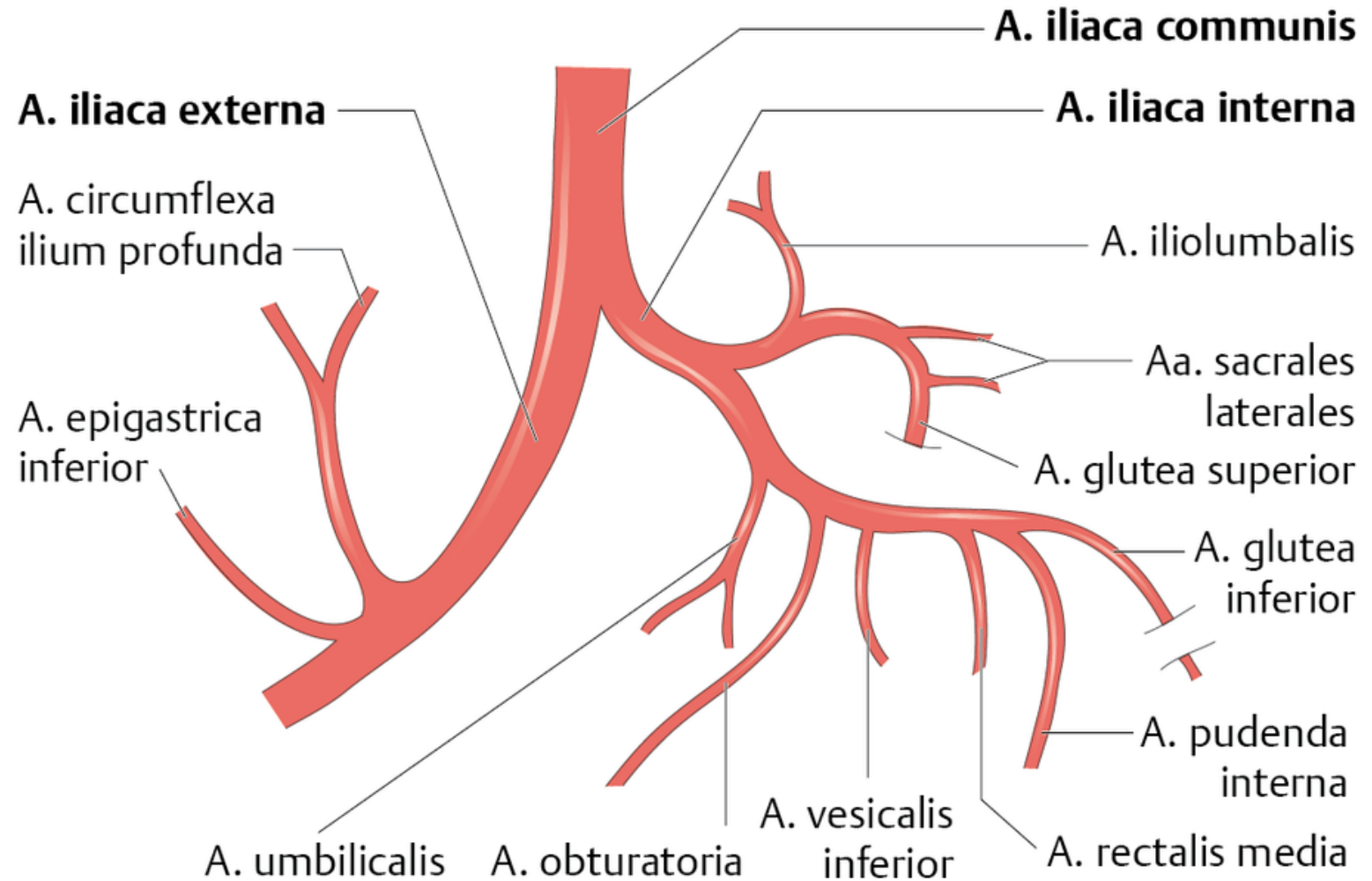


B

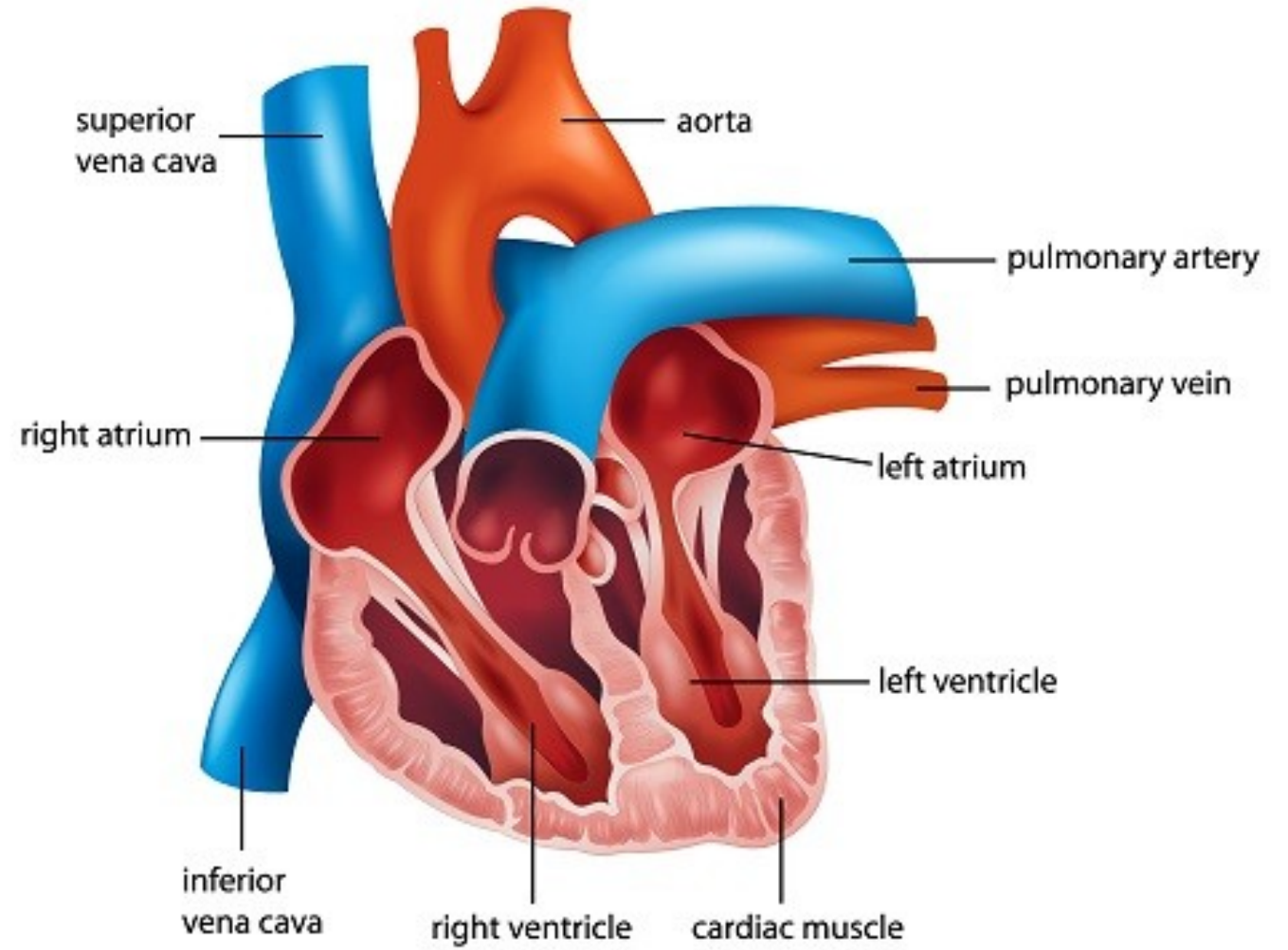
- Proper lineam albam – because of the white line - is a fibrous structure that runs down the midline of the abdomen in humans and other vertebrates



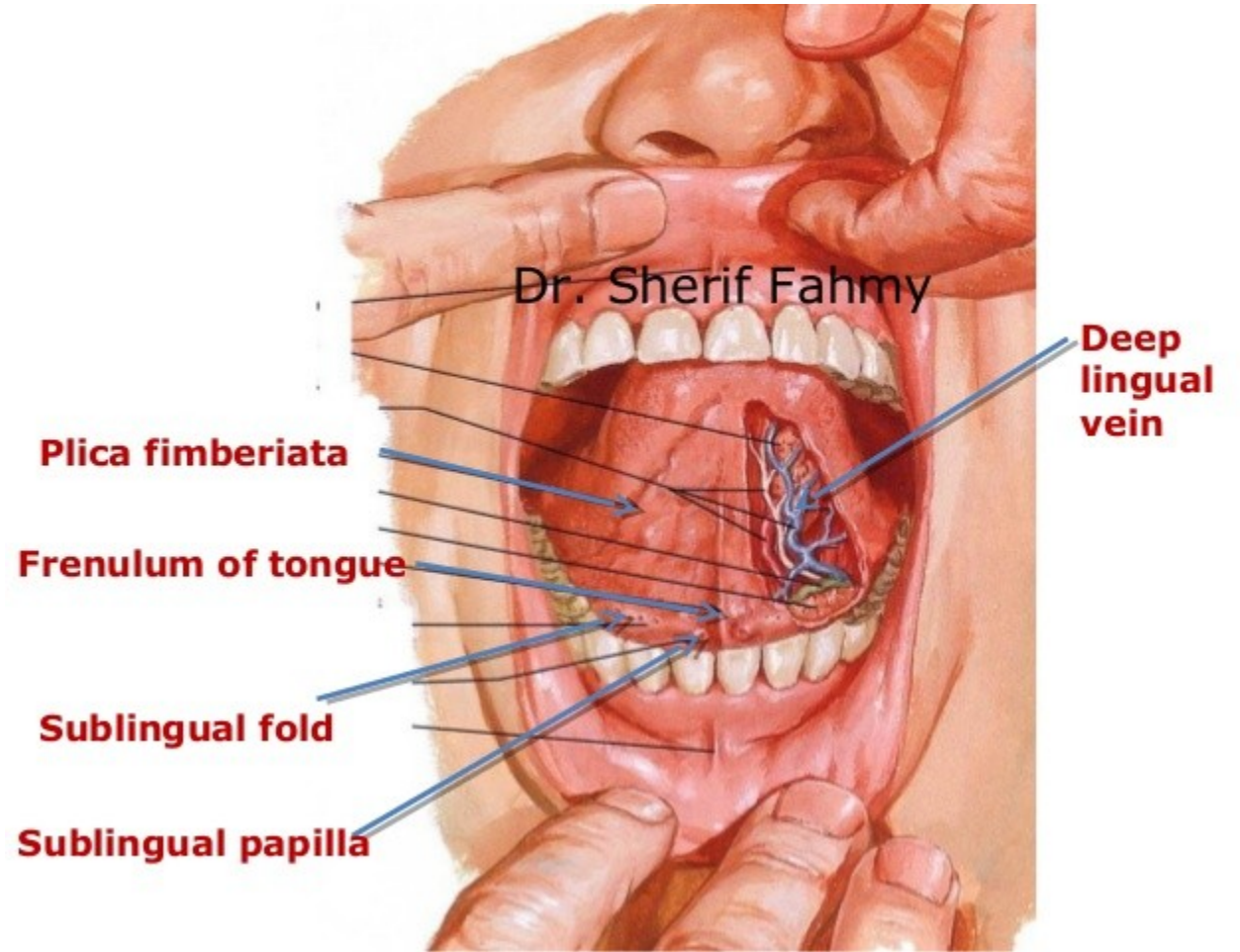
- Arteria iliaca interna – internal iliac artery



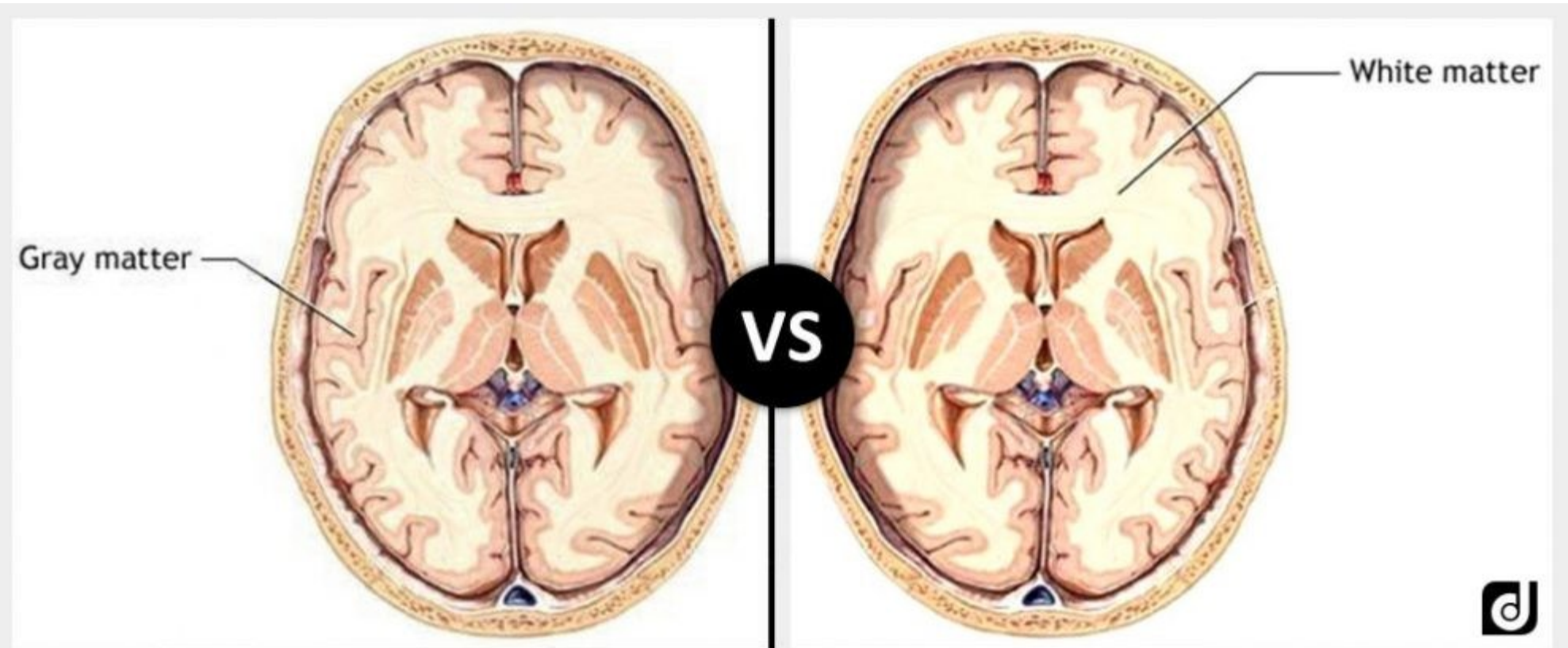
- Vena cava – caval vein



- Vena profunda linguae – deep lingual vein

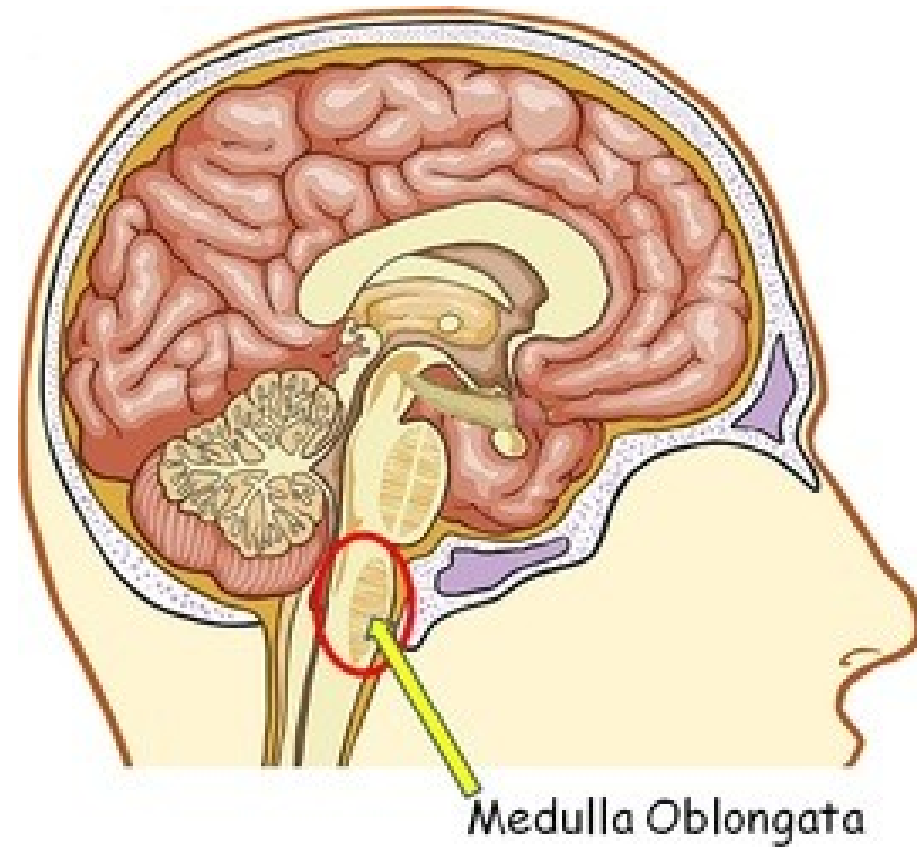


- Substantia alba et grisea - White and grey matter (substance)



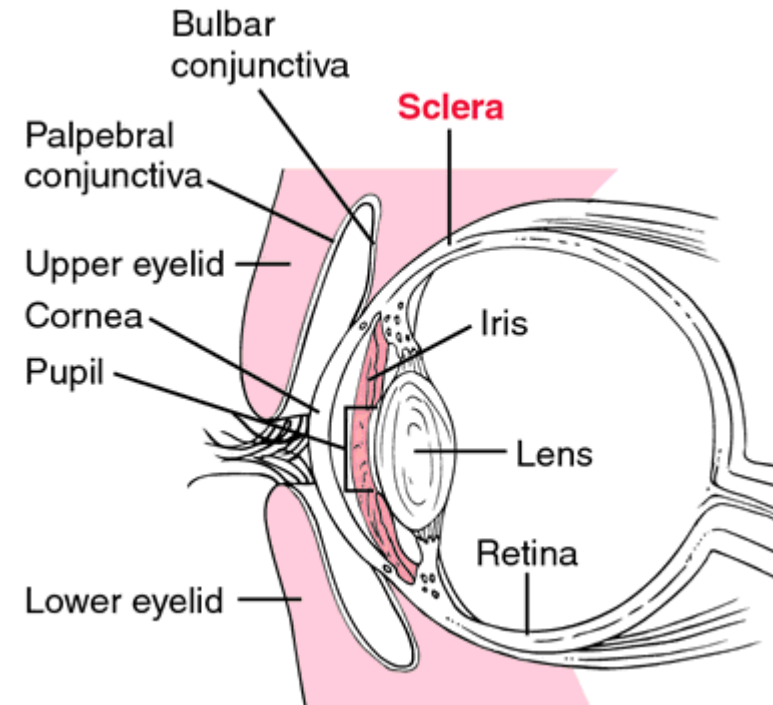
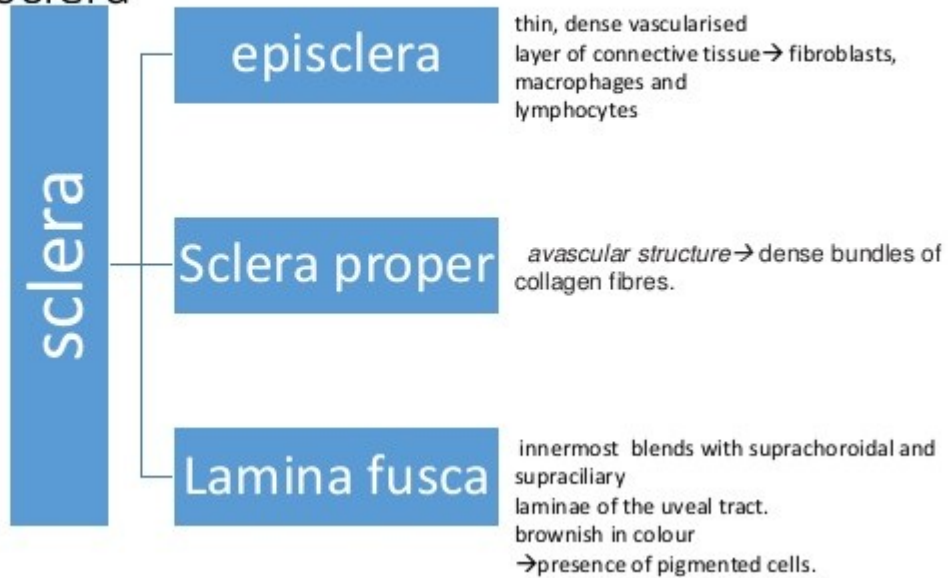
Grey Matter vs. White Matter

- Myelencephalon; Medulla oblongata; Bulb



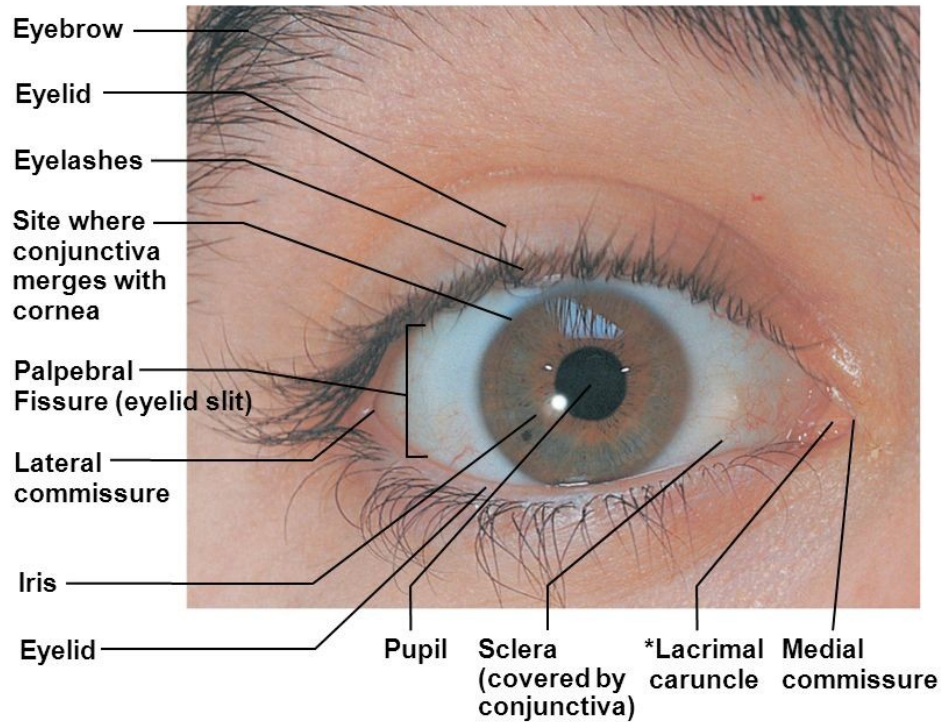
- lamina fusca sclerae – lamina fusca of sclera

Layers of sclera



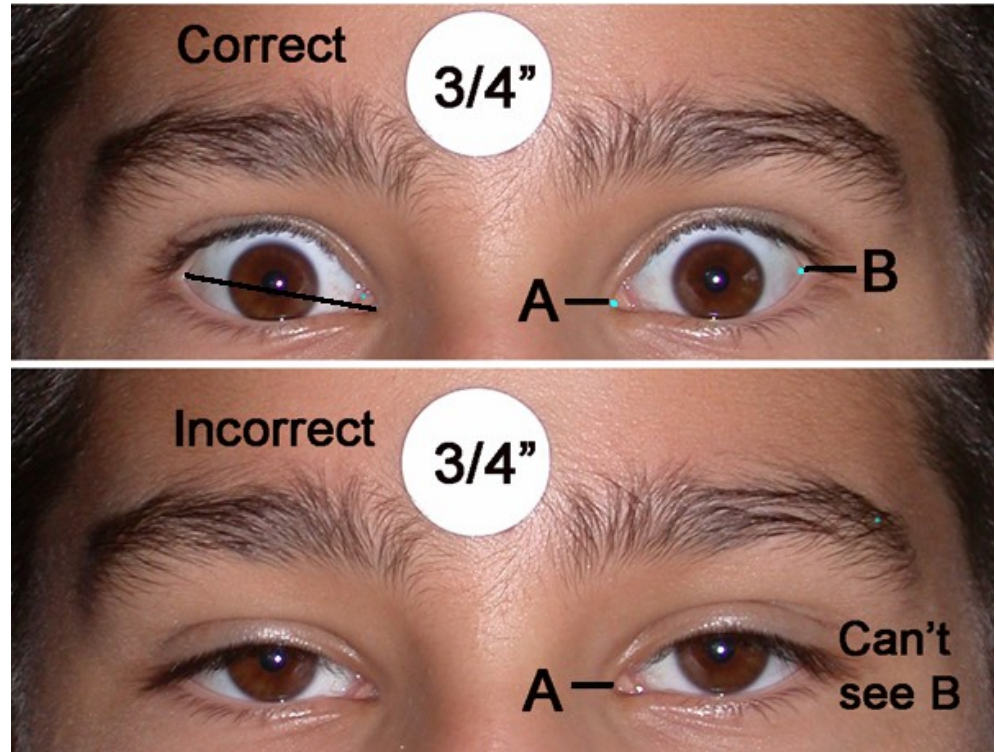
- rima palpebrarum - Palpebral fissure

Figure 15.1a The eye and accessory structures.



(a) Surface anatomy of the right eye

*Contains oil and sweat glands



- In tuba auditiva – in auditory tube

Auditory tube

➤ Pharyngo-tympanic tube or Eustachian tube

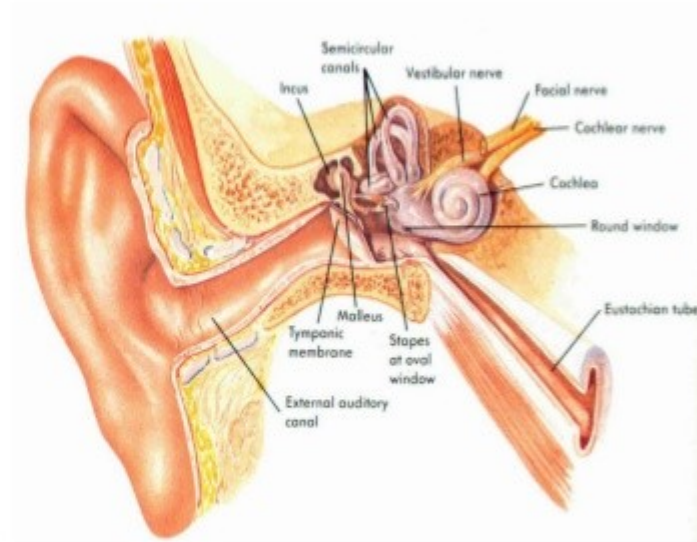
➤ Connects middle ear with nasopharynx

➤ Trumpet shaped

➤ 4cm long

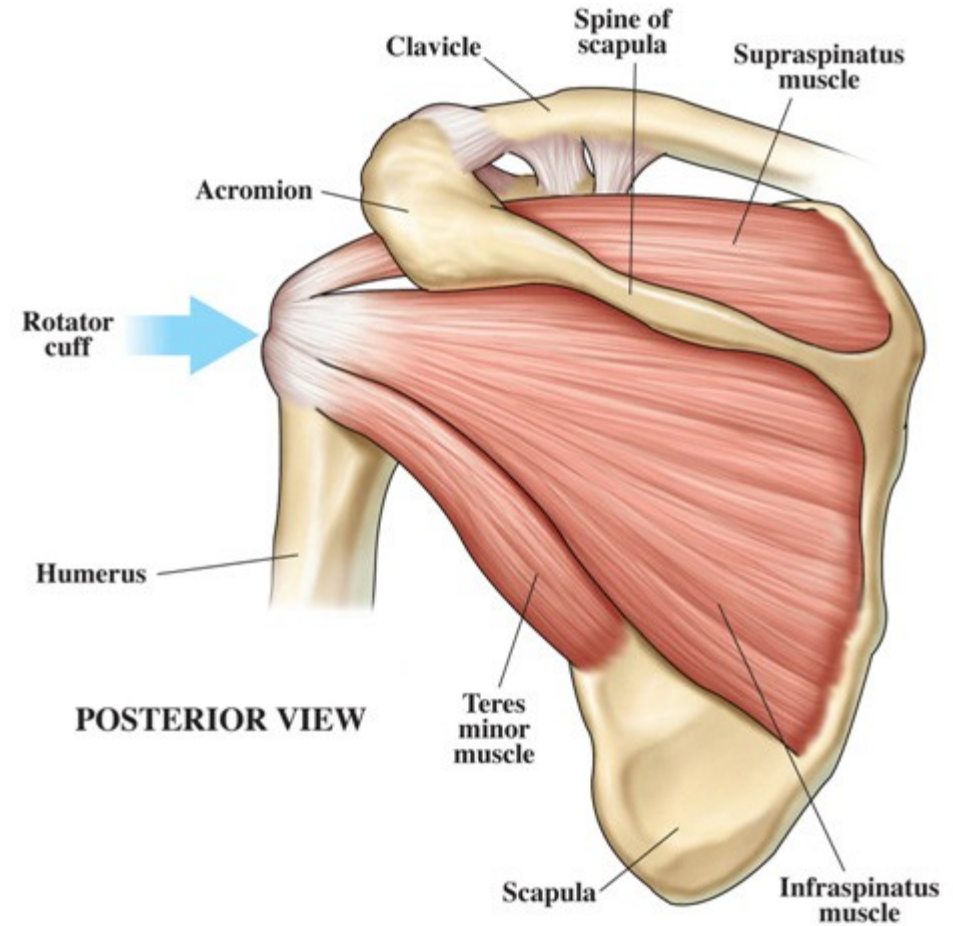
➤ 2 parts :

1. Bony part
2. Cartilaginous part

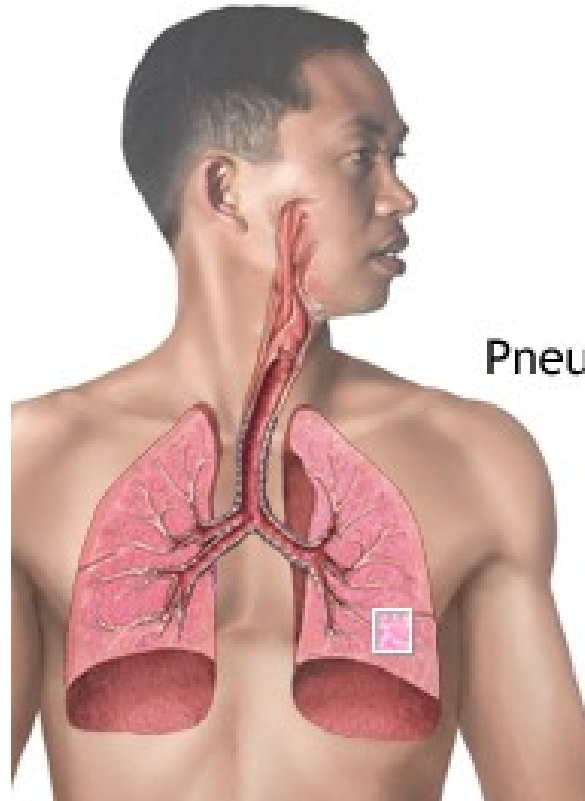


- Spina scapulae – spine of scapula

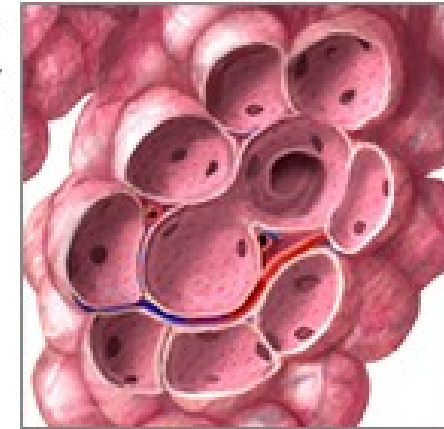
NORMAL SHOULDER ANATOMY



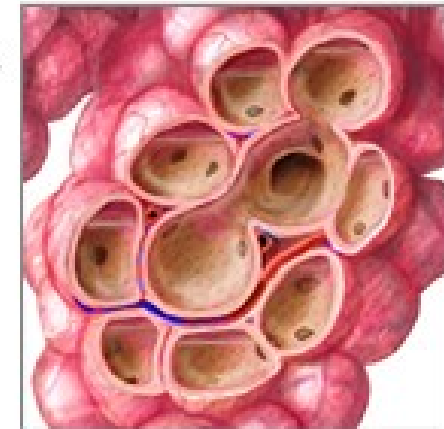
- Propter pneumoniam



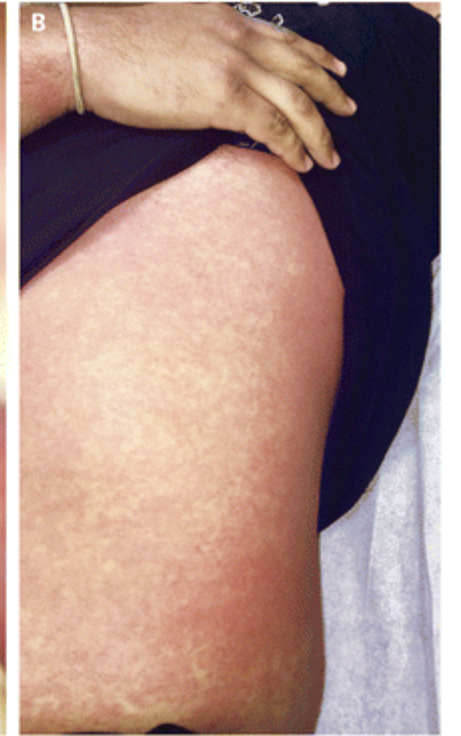
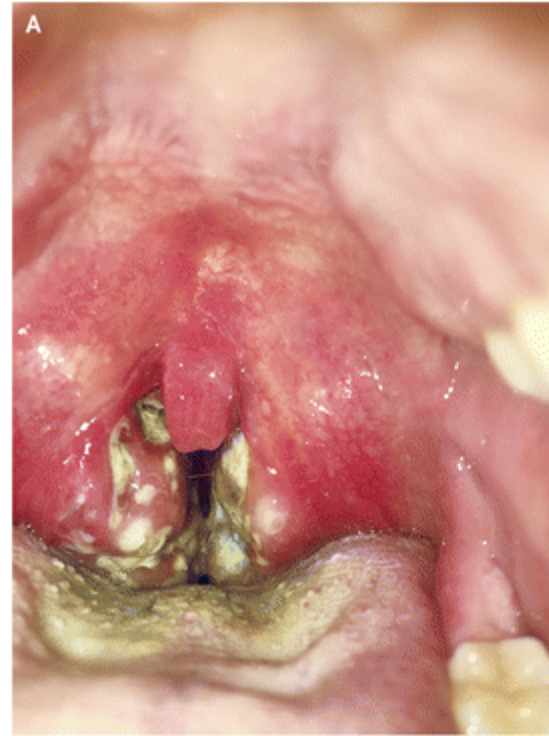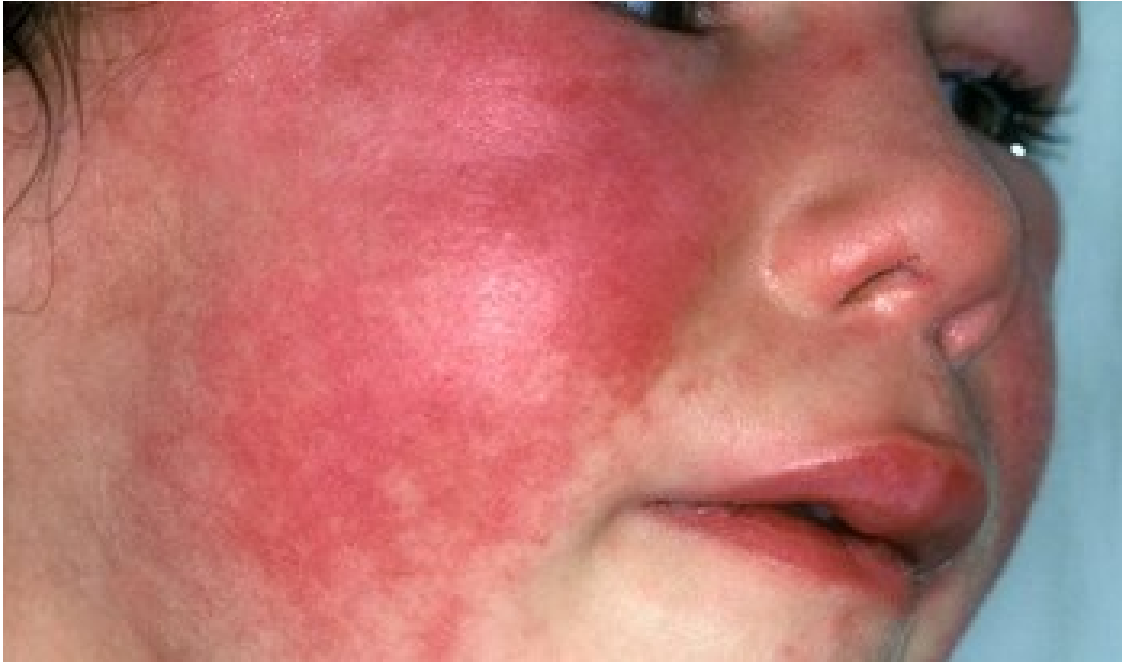Normal
alveoli



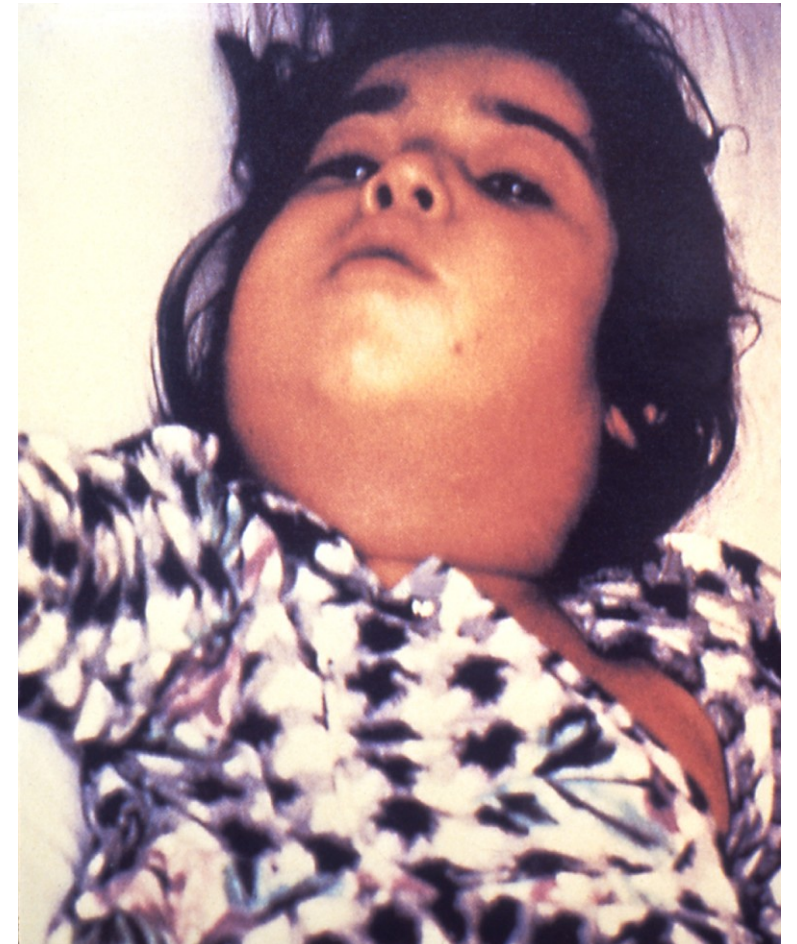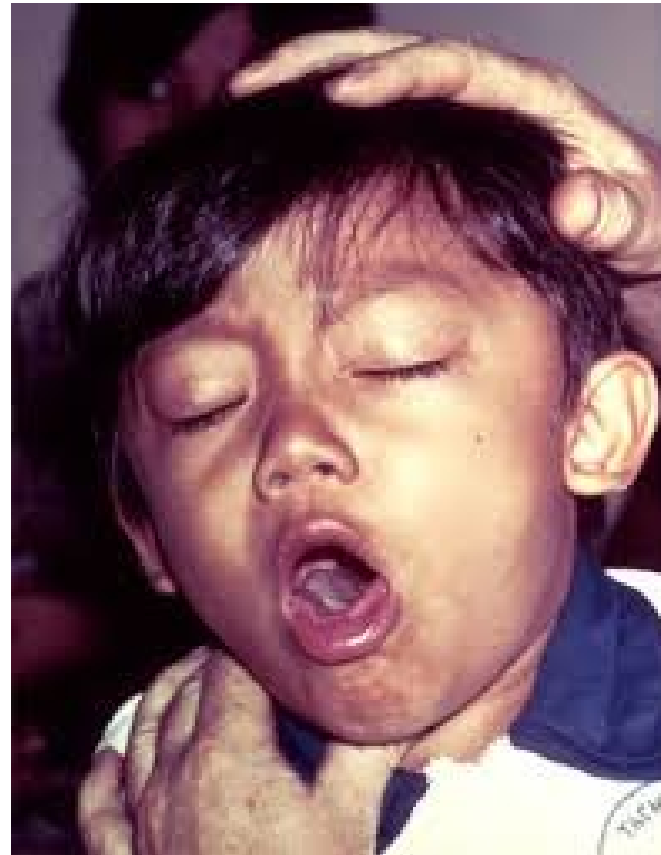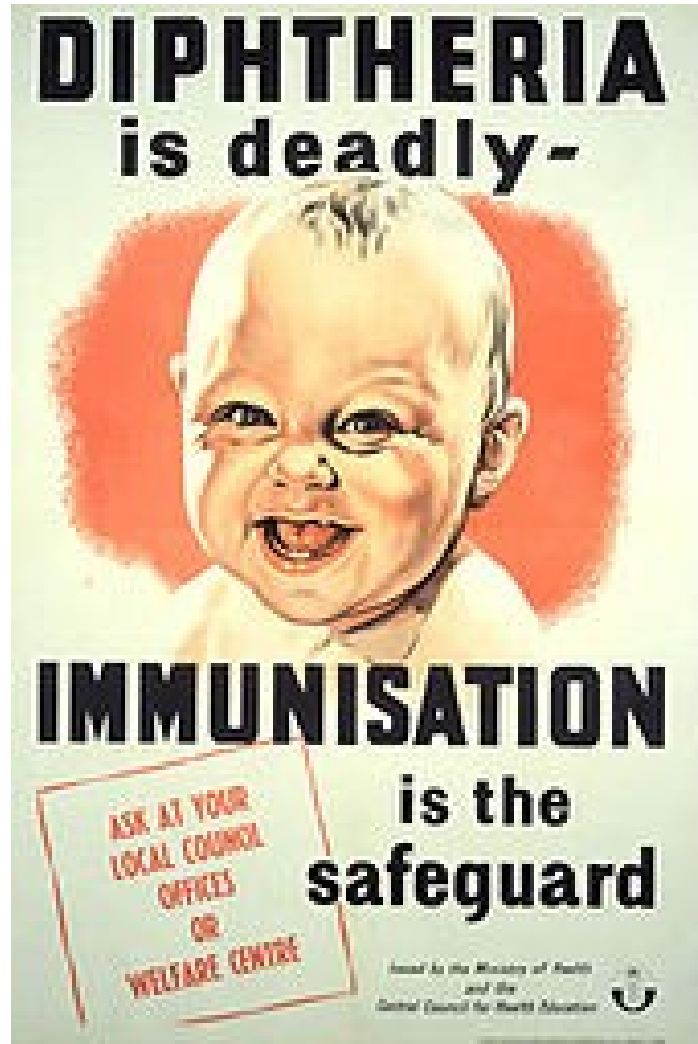Pneumonia



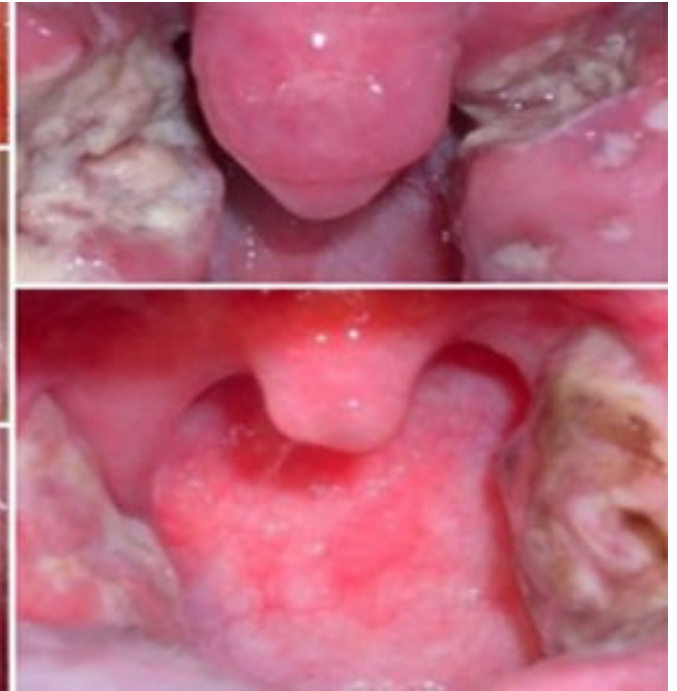
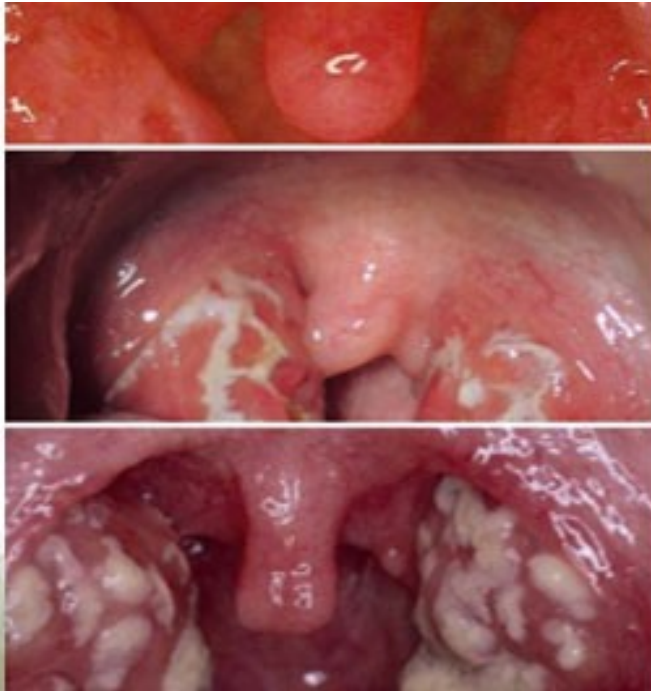- Post scarlatinam – after the scarlet fever



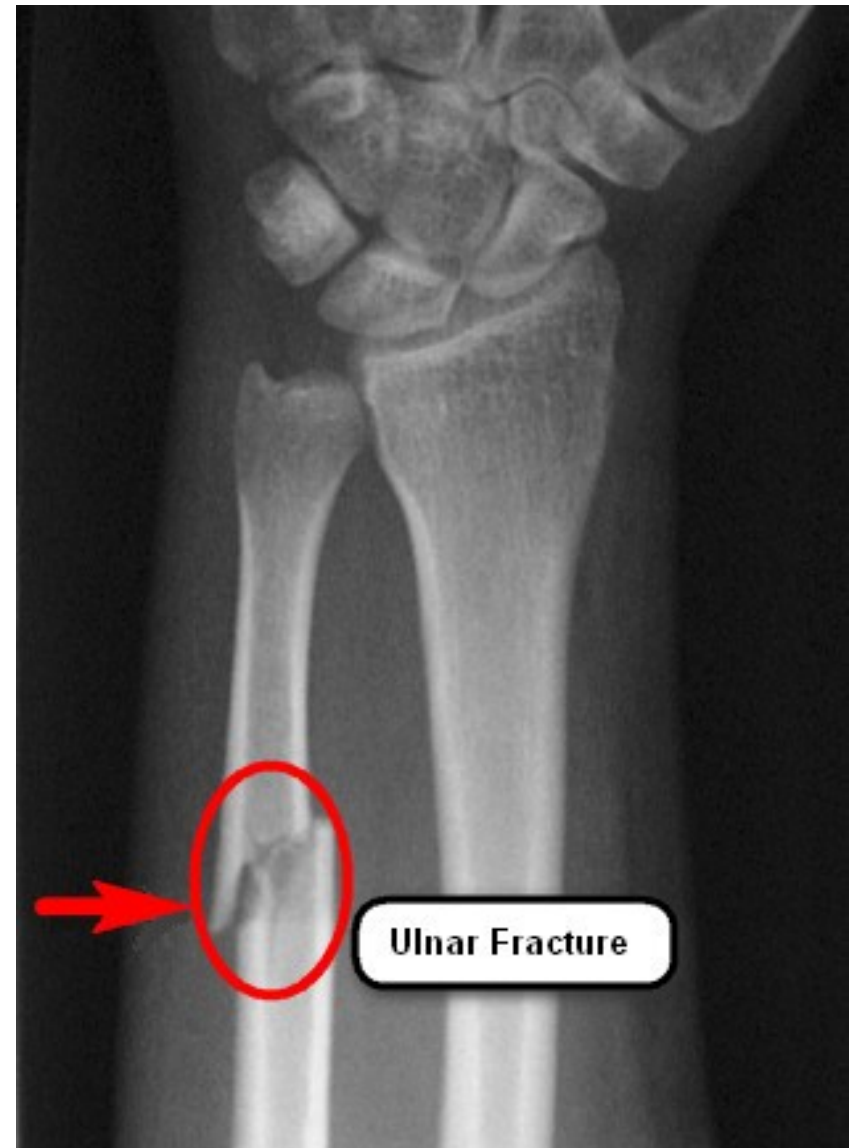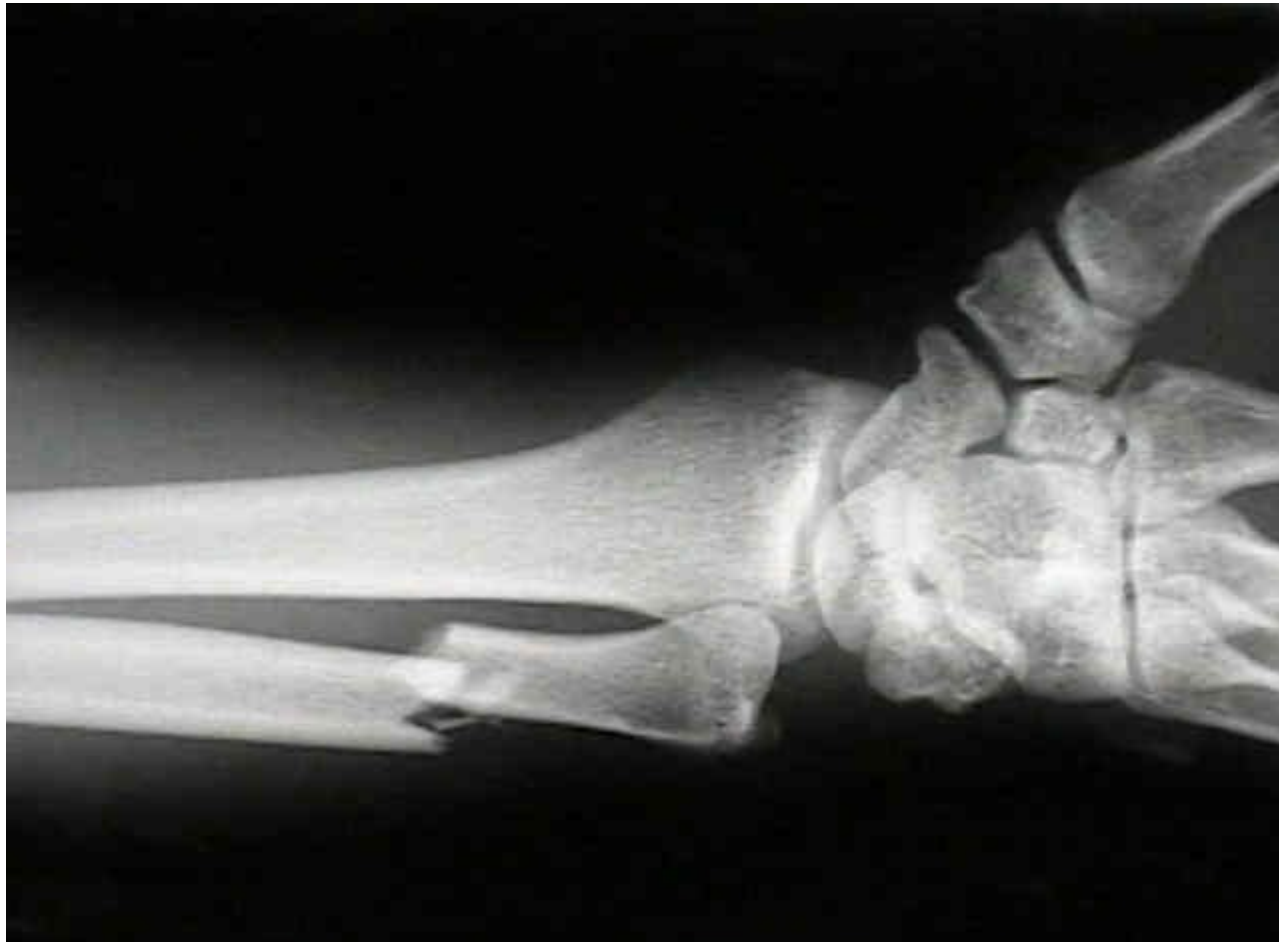- Diphtheria maligna – malignant throat infection



- angina gangraenosa - angina gangrenosa An obsolete term for:
- (1) Acute necrotising ulcerative gingivitis;
- (2) Pseudomembranous pharyngitis.



- fractura ulnae

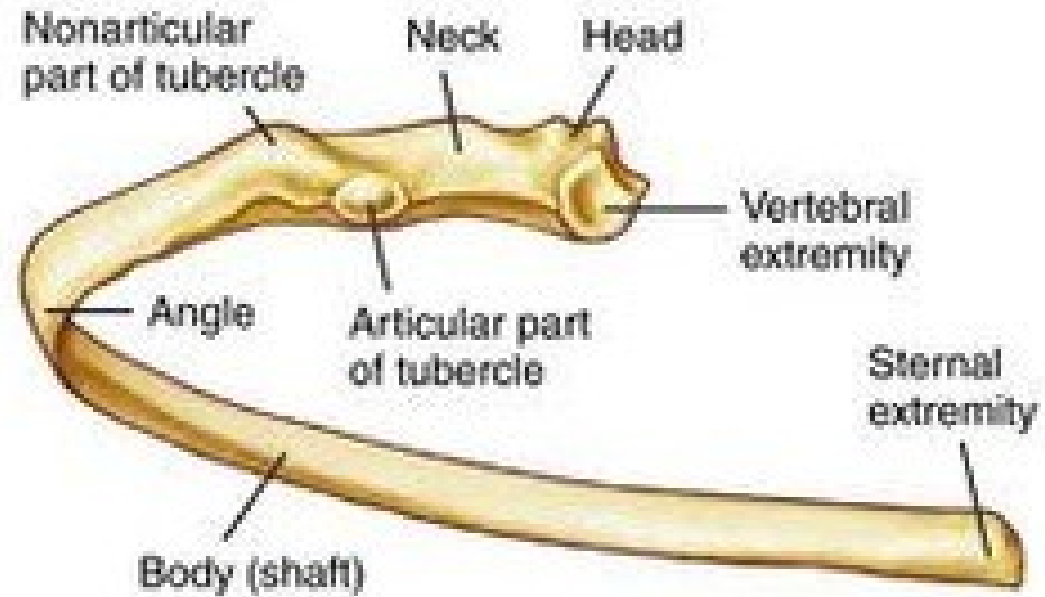


Exercise 5. Translate anatomical terms into Latin:

- *E.g. Body of the vertebra – corpus vertebrae*

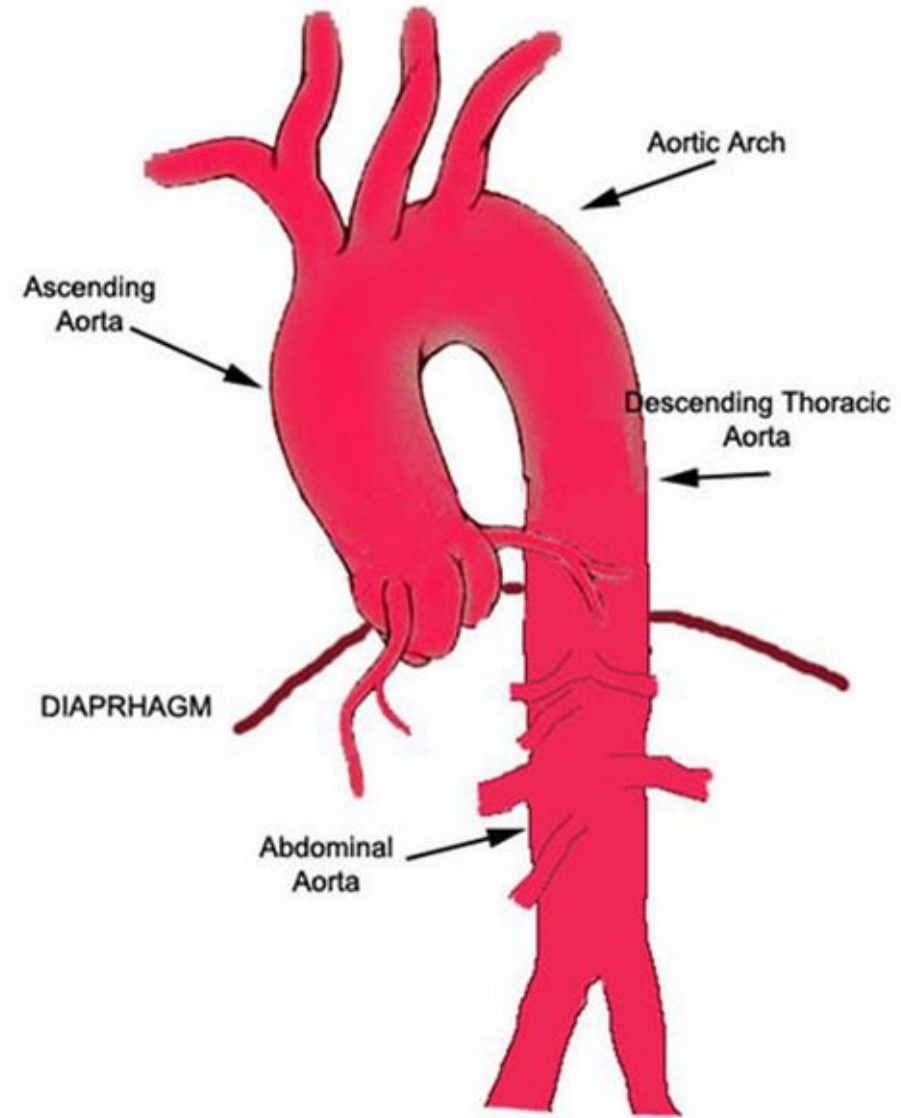
head of the rib

- Caput costae



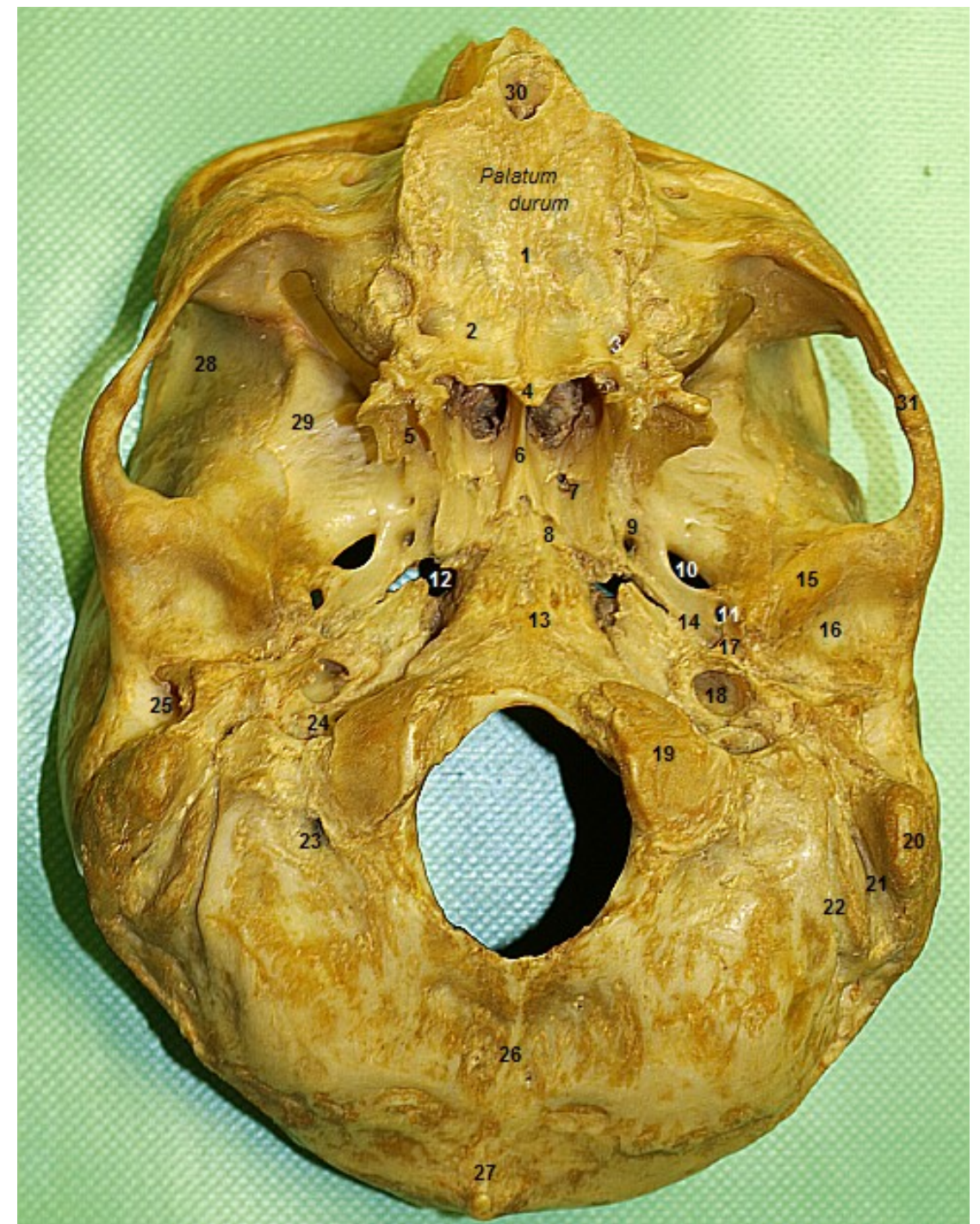arch of the aorta

- Arcus aortae



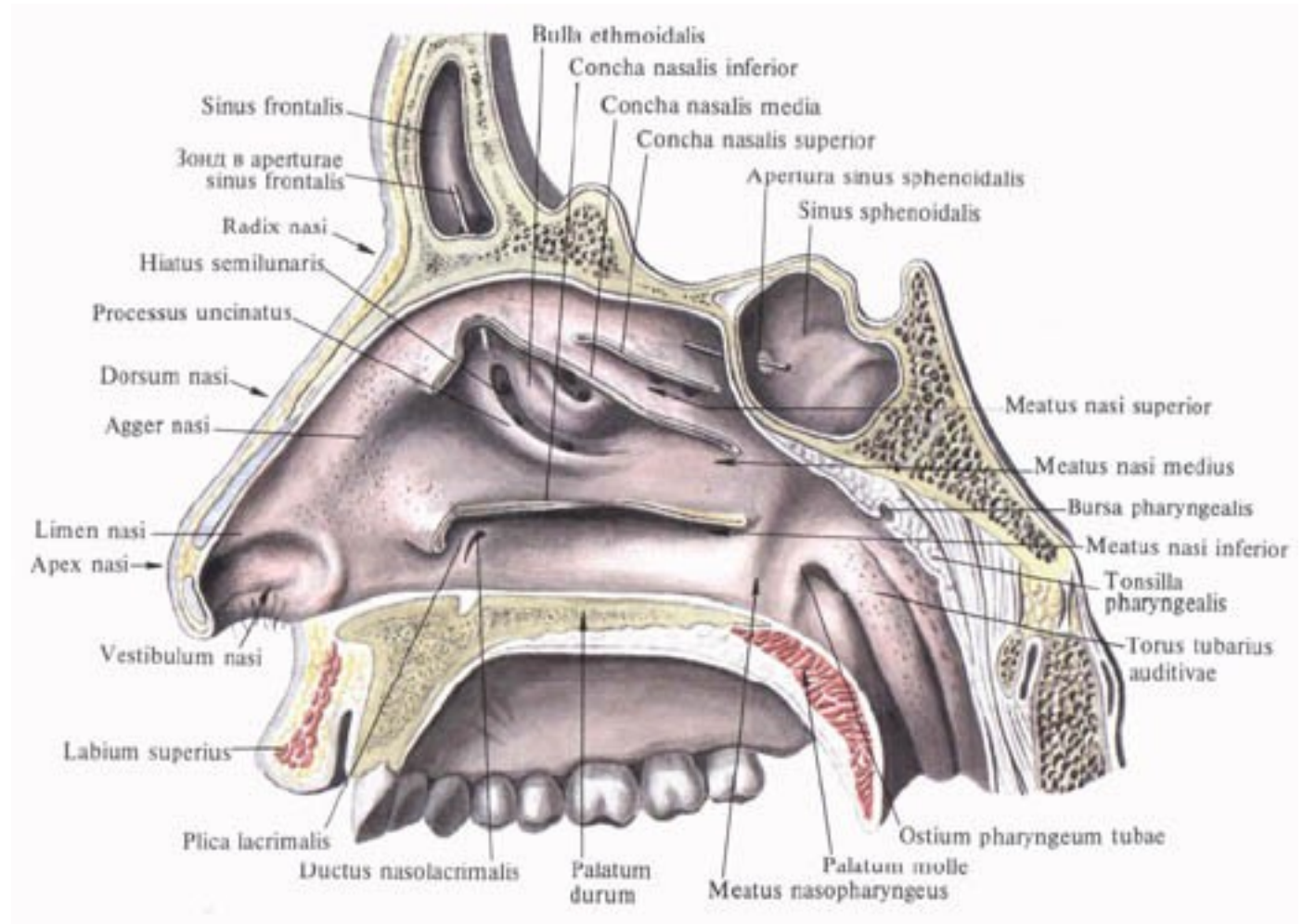
base of the skull

- Basis cranii



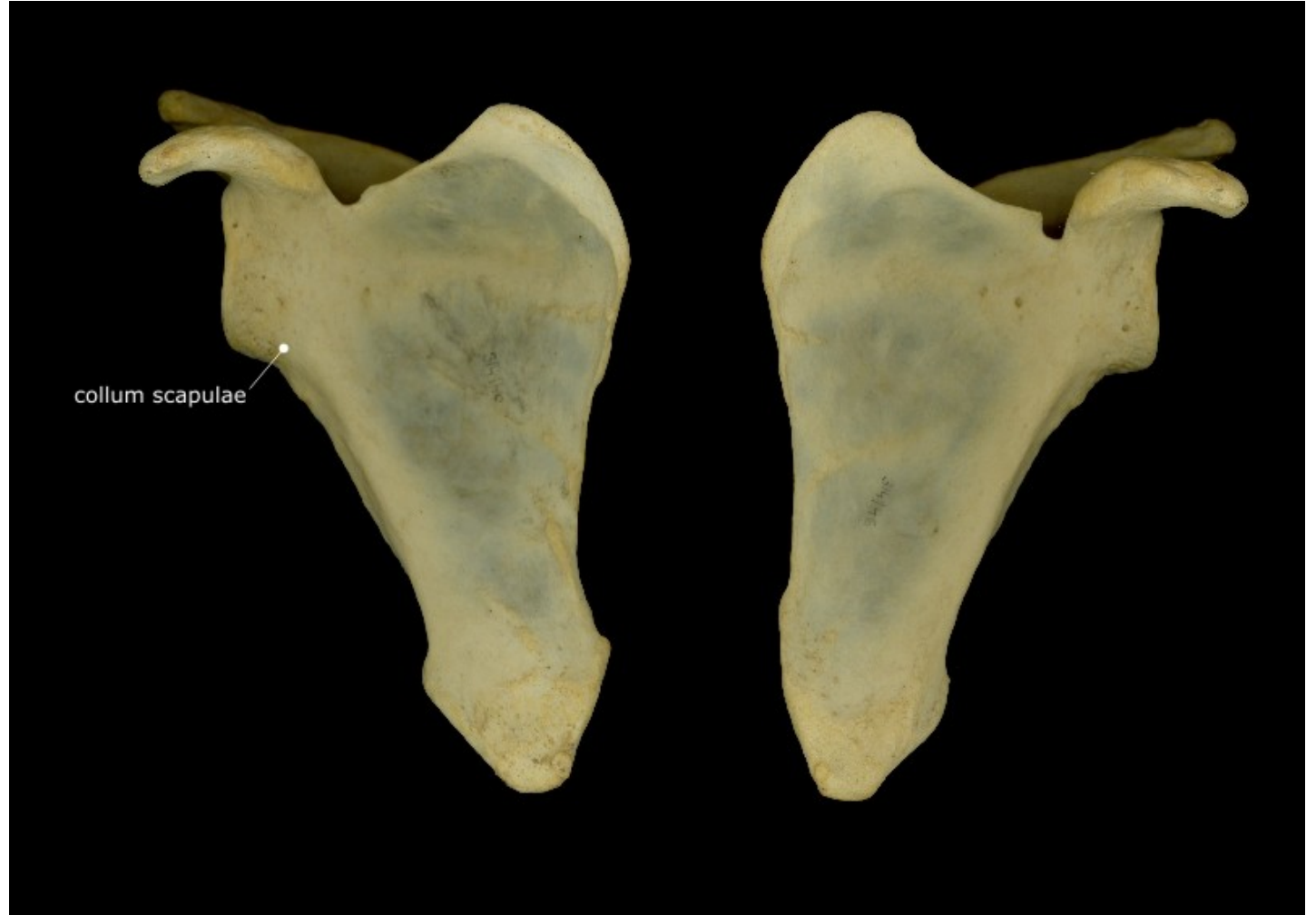
cavity of the nose

- Cavitas nasi



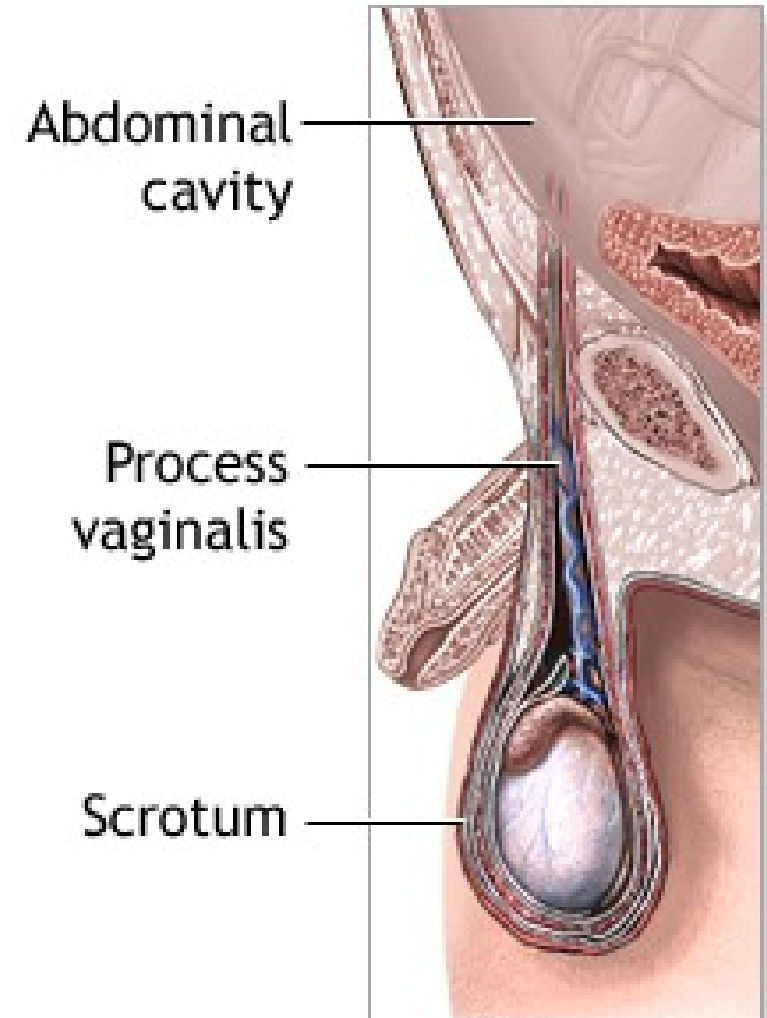
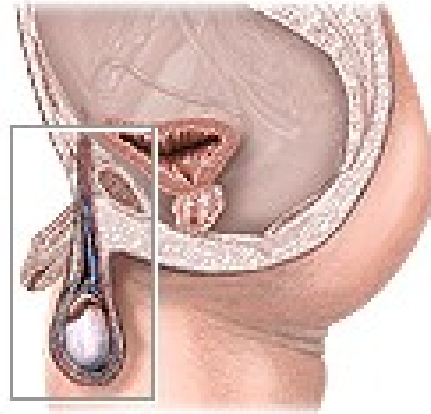neck of the scapula

- Collum scapulae



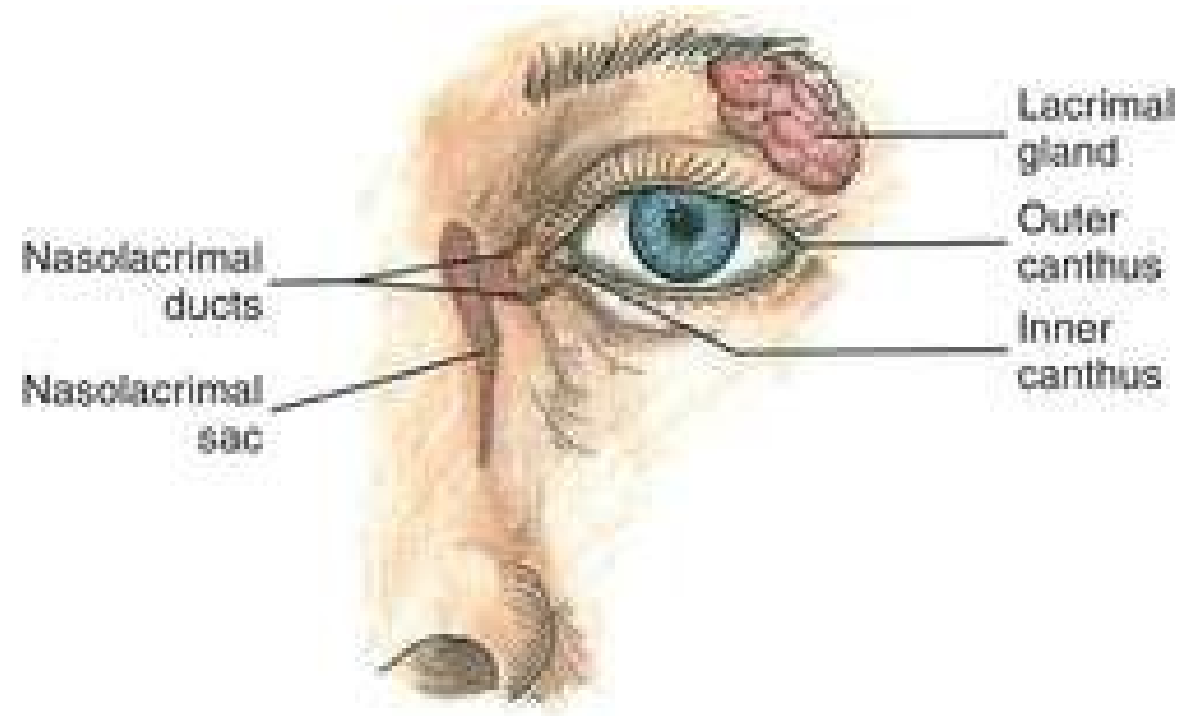
Vaginal process

- Processus vaginalis



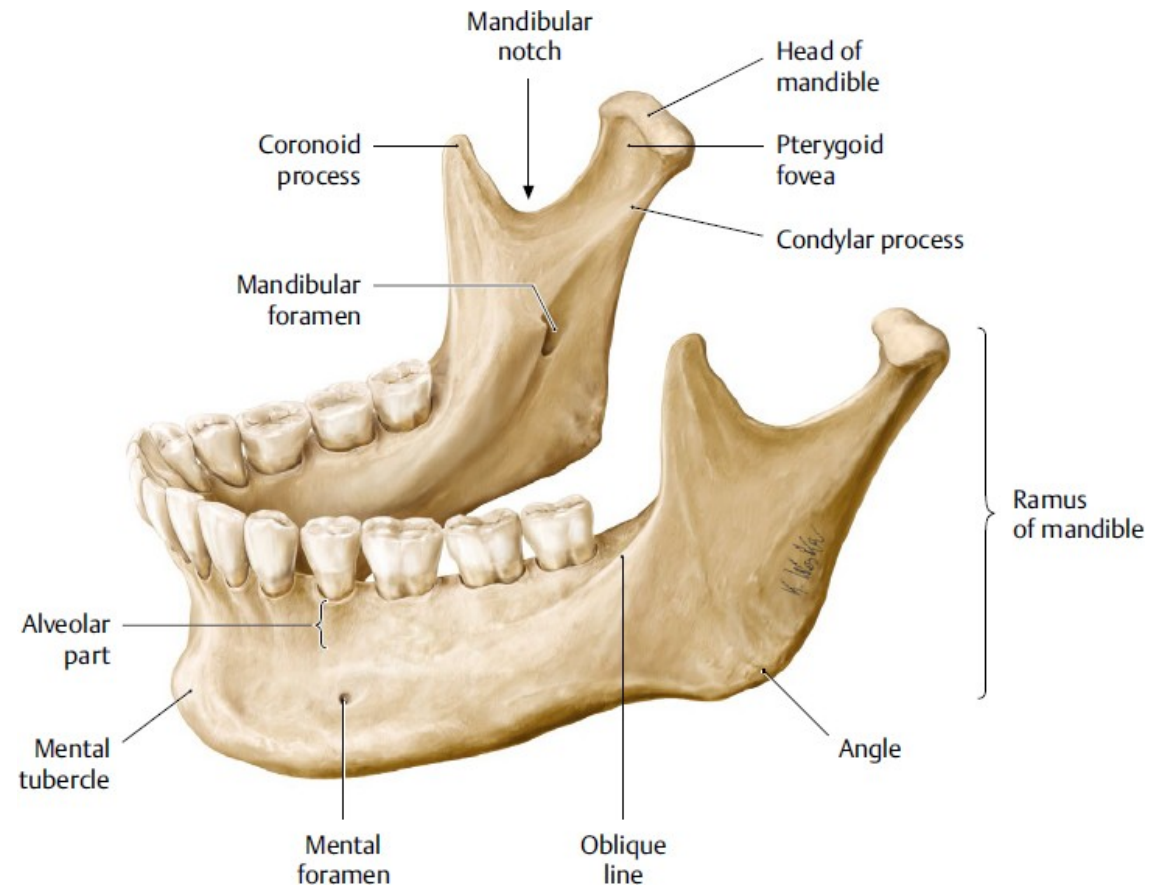
duct of the nose

- Ductus nasi



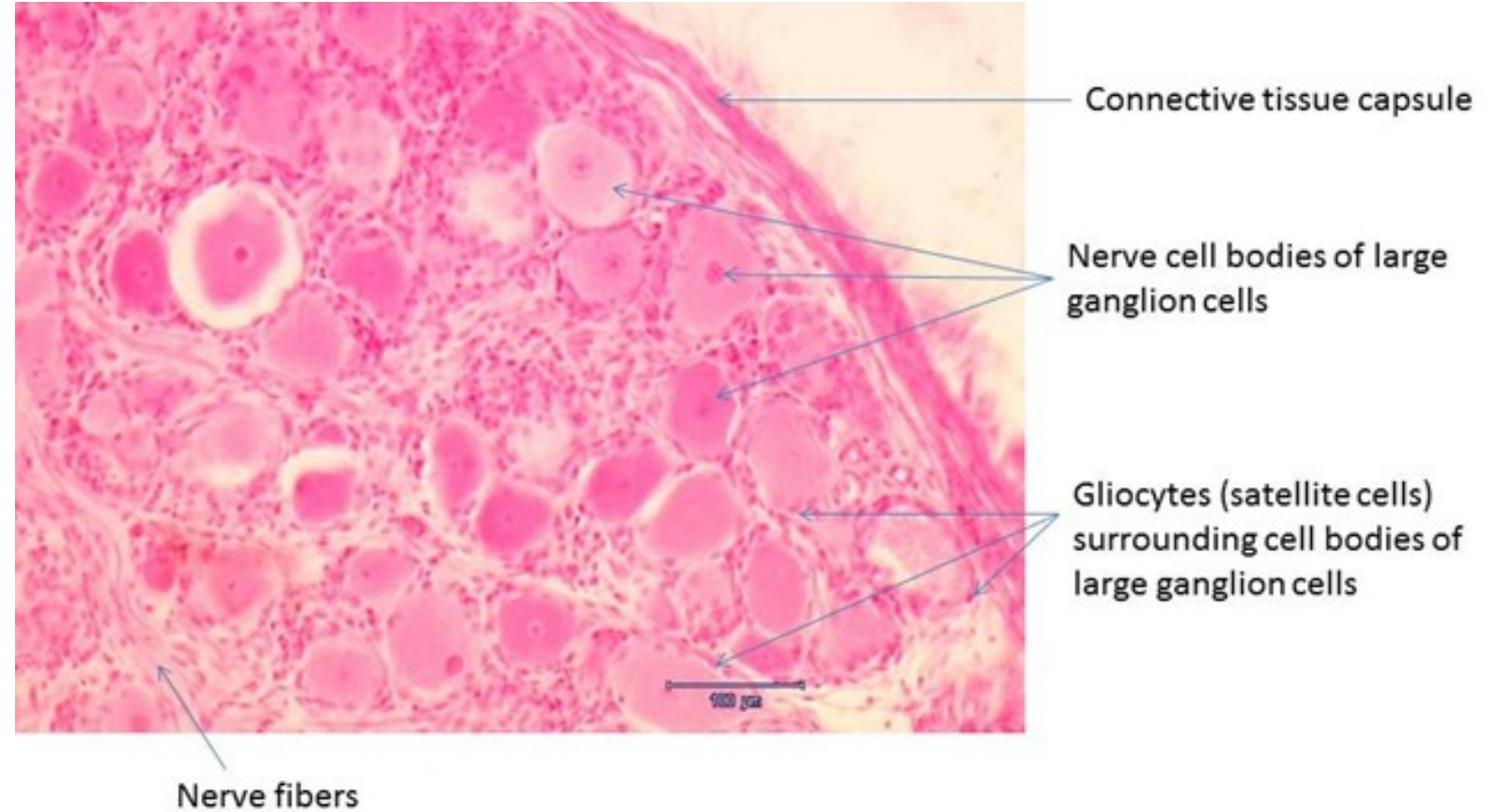
pitch (incisure) of the lower jaw

- Incisura mandibulae inferioris



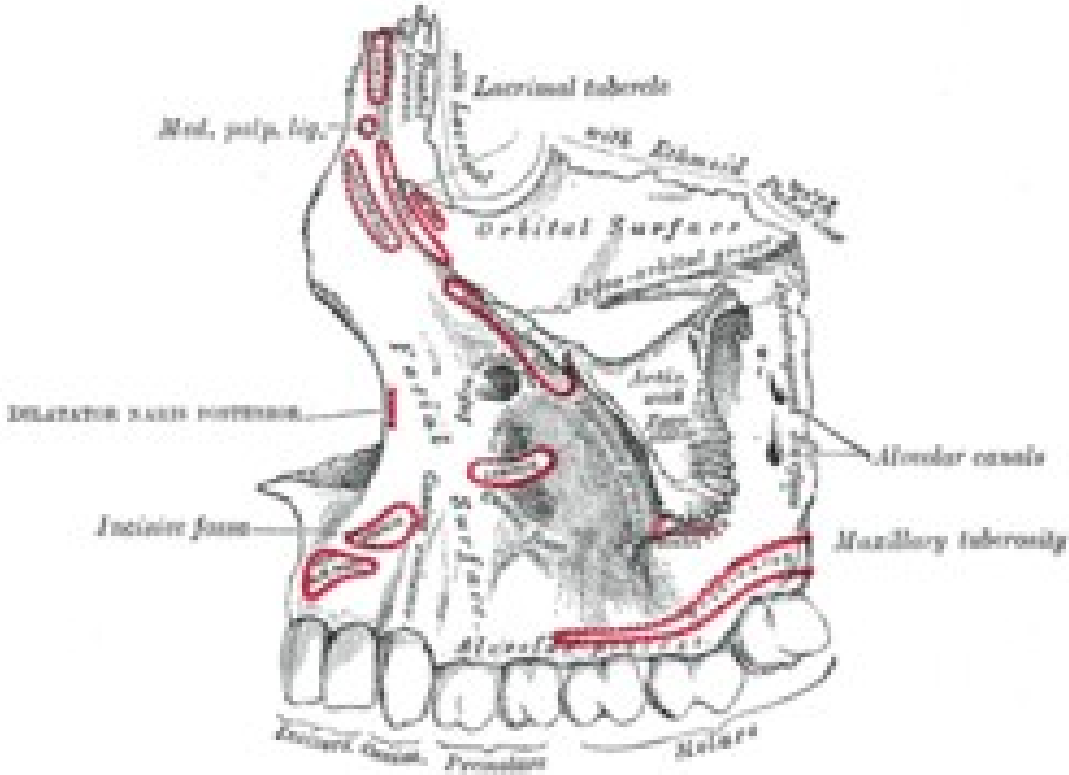
capsule of the ganglion

- Capsula gangli



tuber of the upper jaw

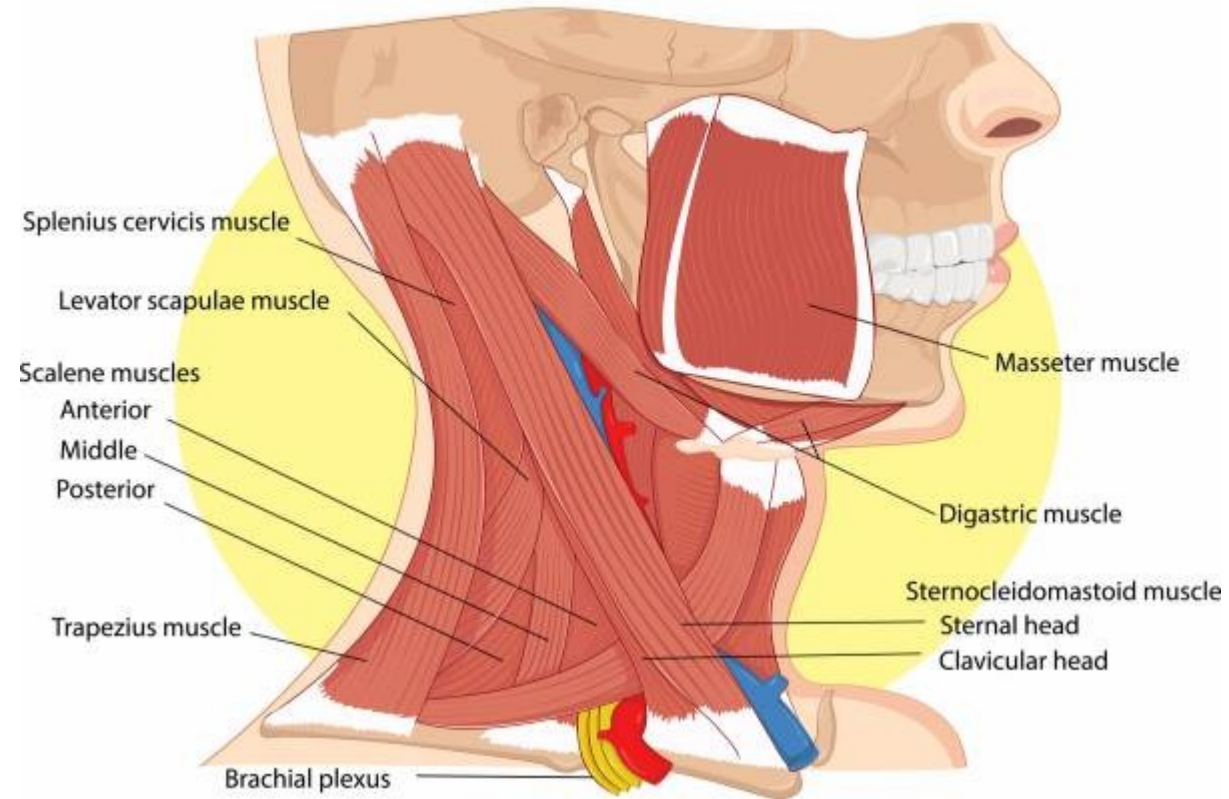
- Tuber maxillae superioris



muscle of the neck

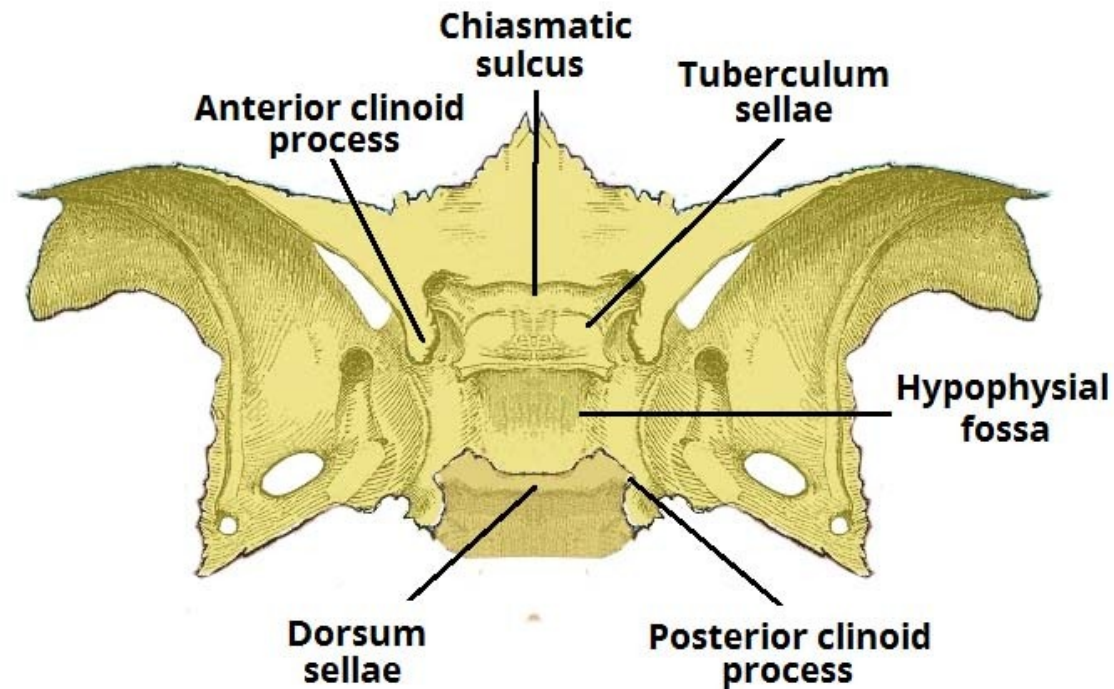
- Musculus colli

Neck-muscles



dorsum of the saddle (sella, ae f)

- Dorsum sellae

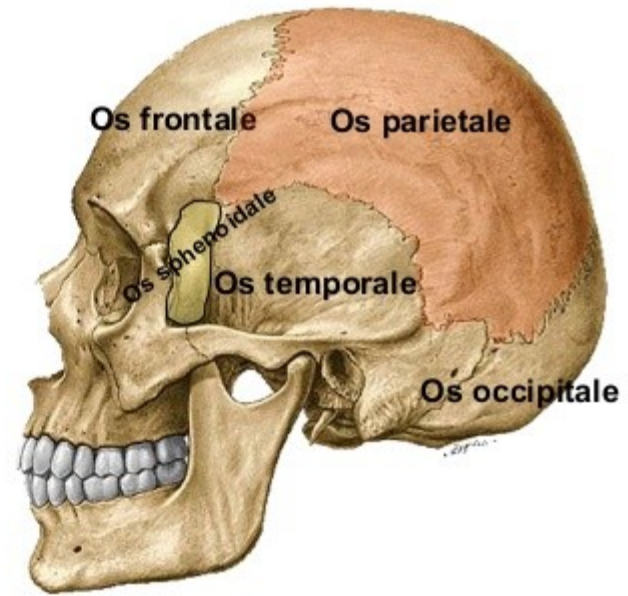
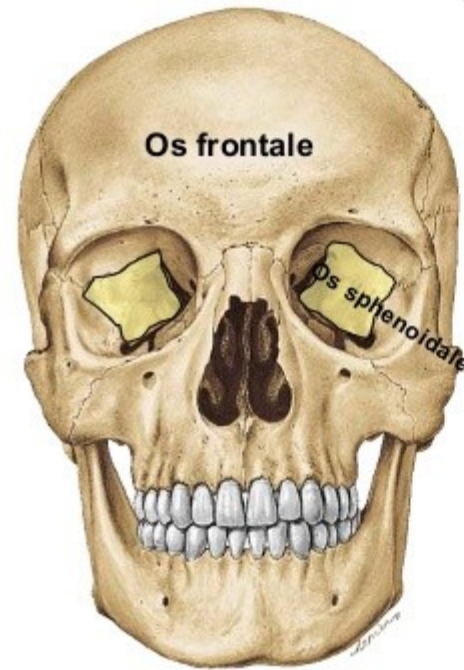


bone of the skull

- Os cranii

Ossa cranii

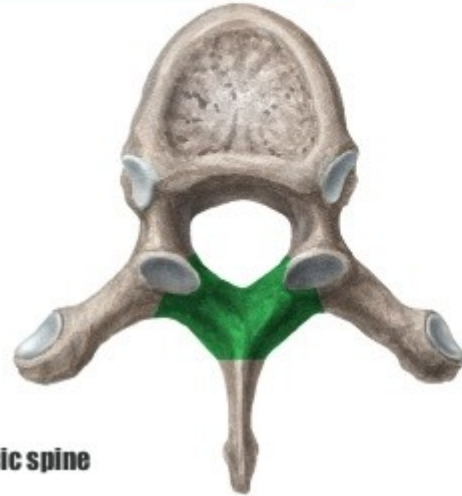
Кости главе се деле на кости лобање и кости лица. Кости лобање су: чеона (os frontale), темена (os parietale), потиљачна (os occipitale), слепоочна (os temporale) и клинаста кост (os sphenoidale). Чеона и клинаста кост садрже синусе и представљају пнеуматичне кости.



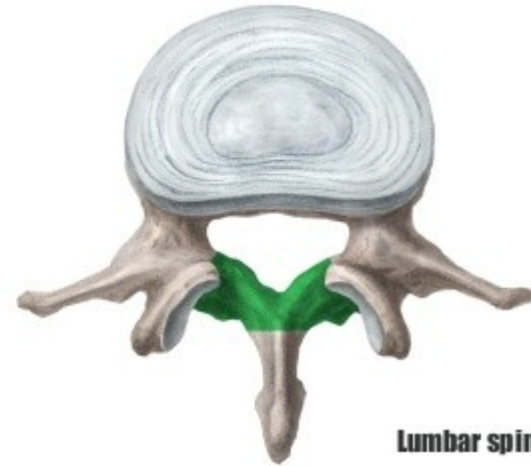
arch of the vertebra

- Arcus vertebrae

Lamina of the
vertebral arch
LATIN
Lamina arcus vertebrae



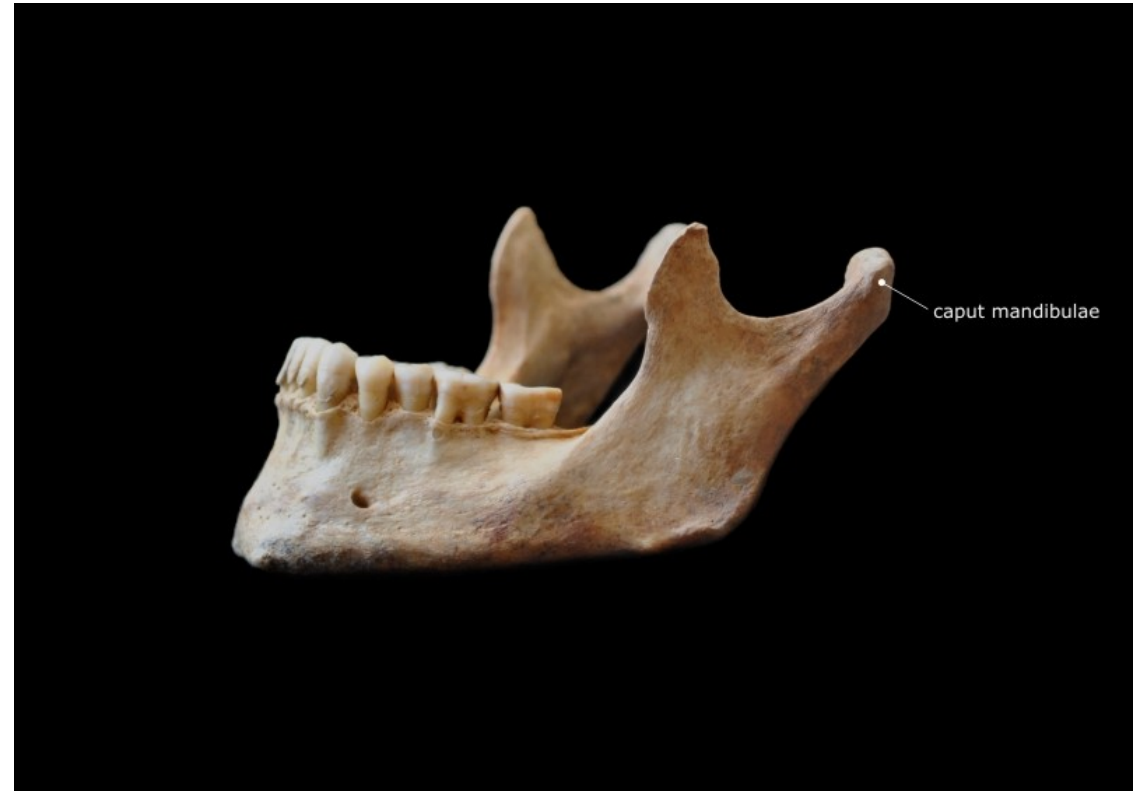Thoracic spine



Lumbar spine

head of the lower jaw

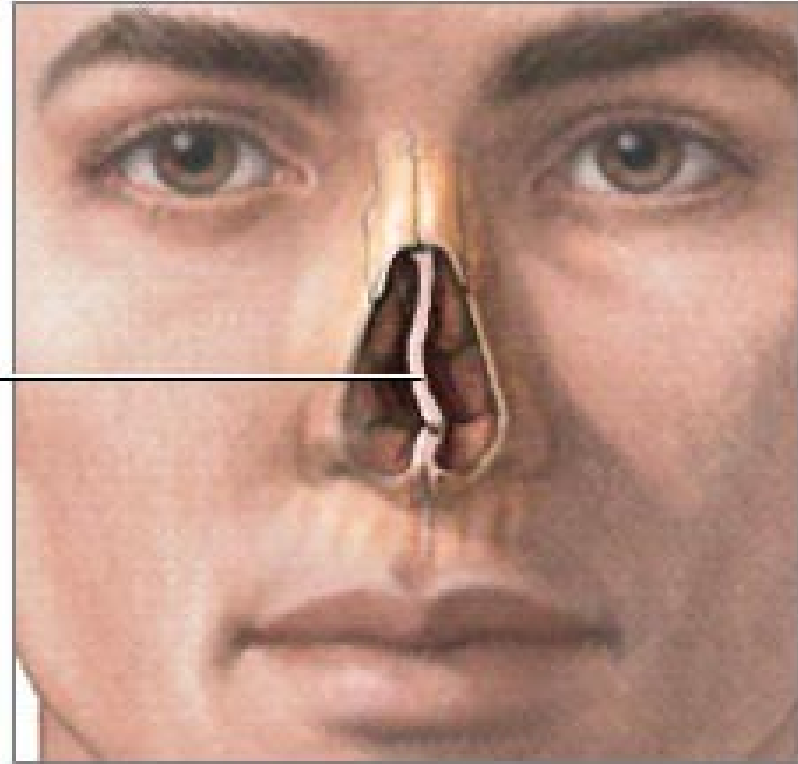
- Caput mandibulae inferioris



dividing wall of the nose

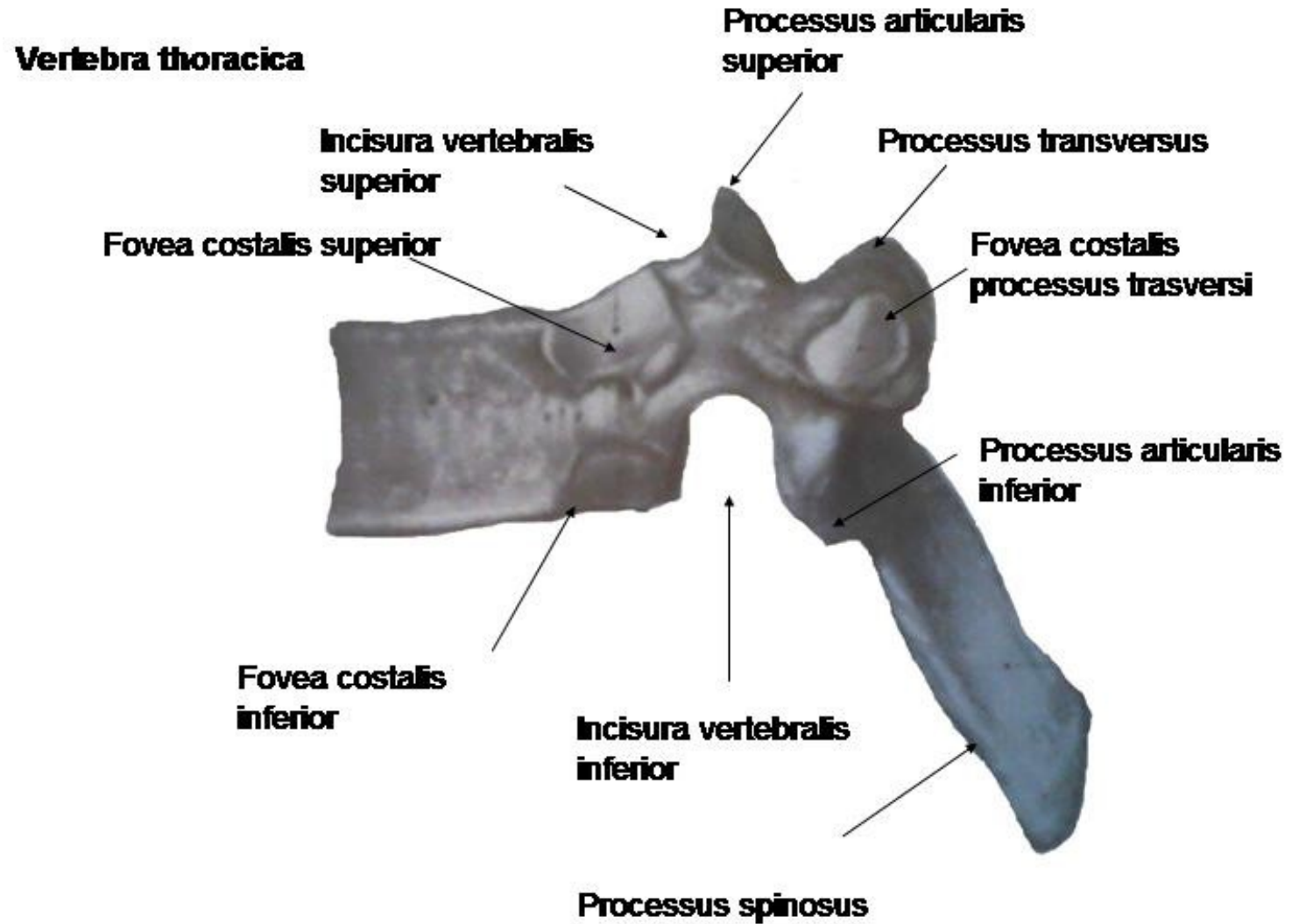- Septum nasi

Deviated
or irregular
nasal septum



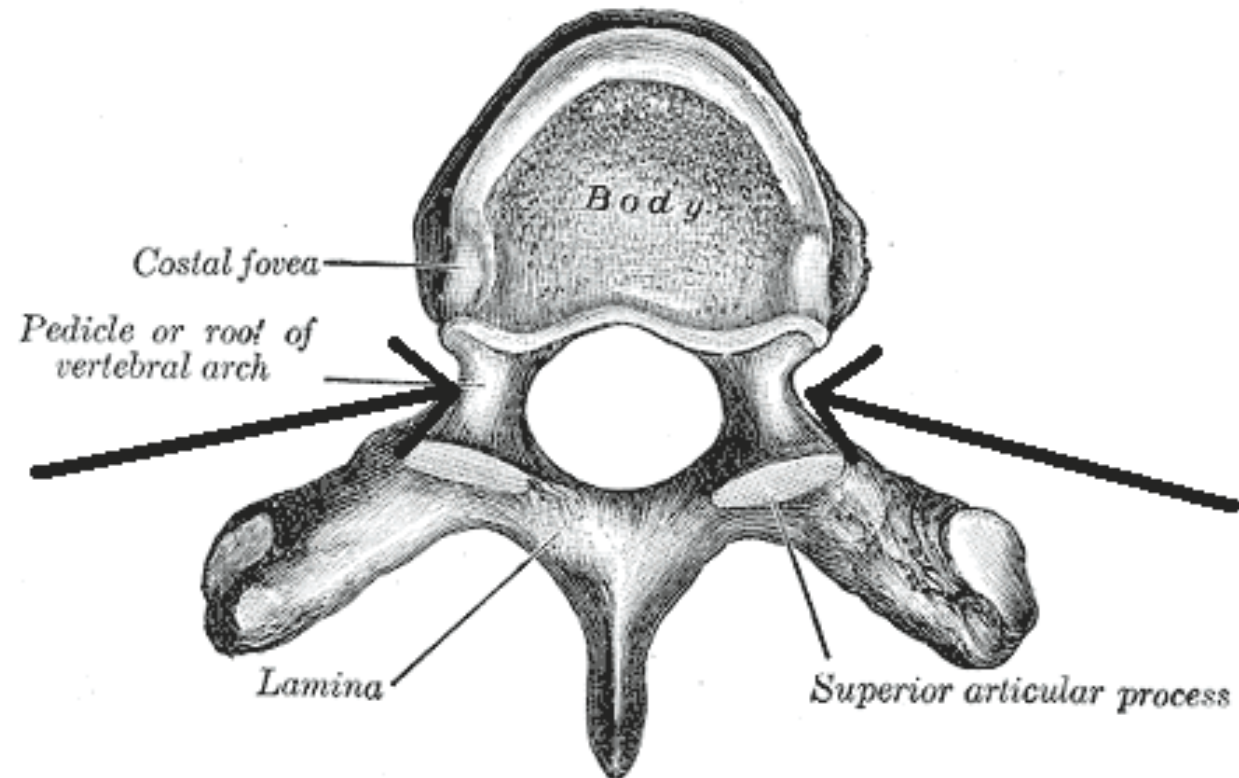
fovea of the process

- Fovea processus



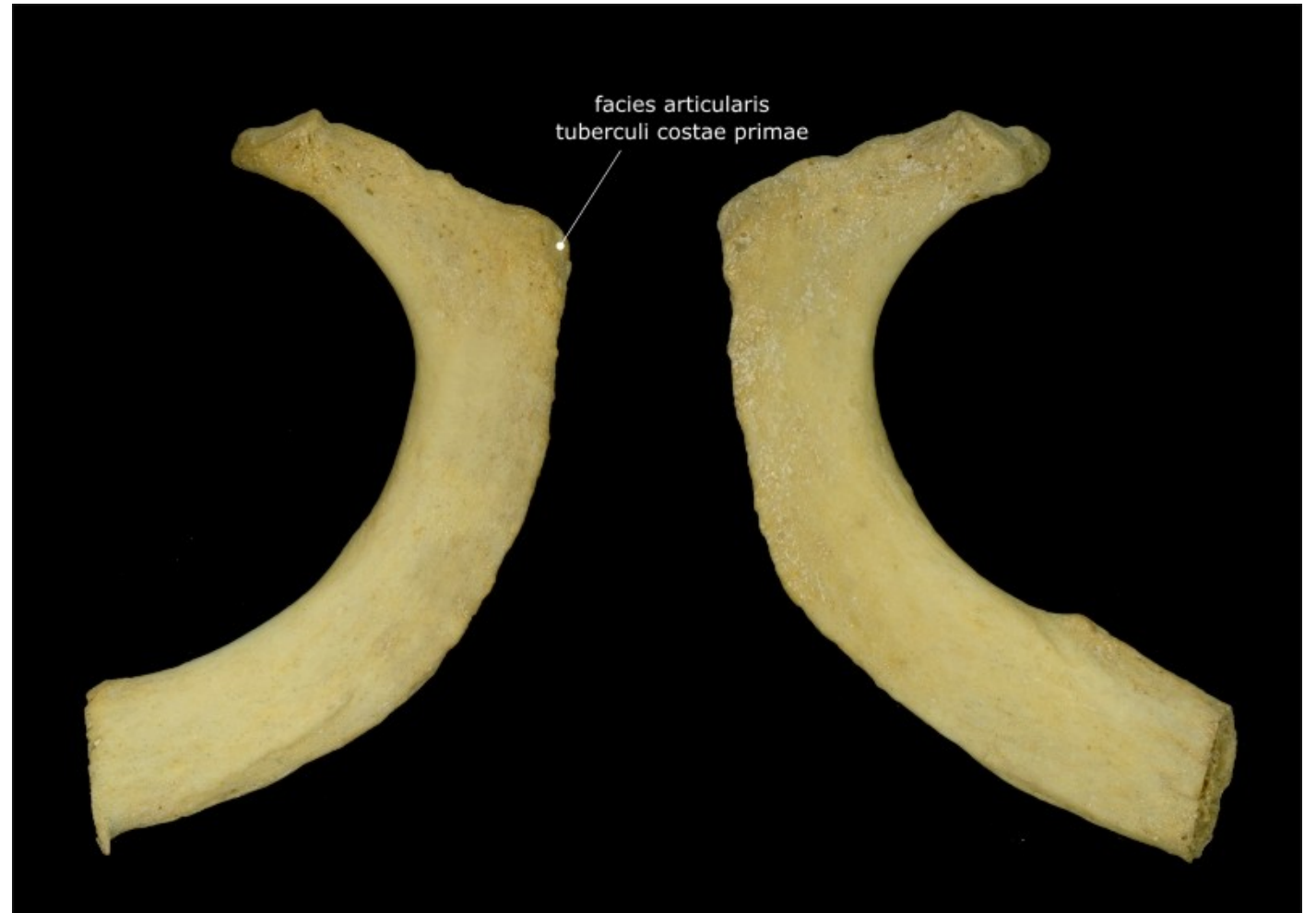pedicle (pediculus, i m) of the arch of the vertebra

- *Pediculus arcus vertebrae*



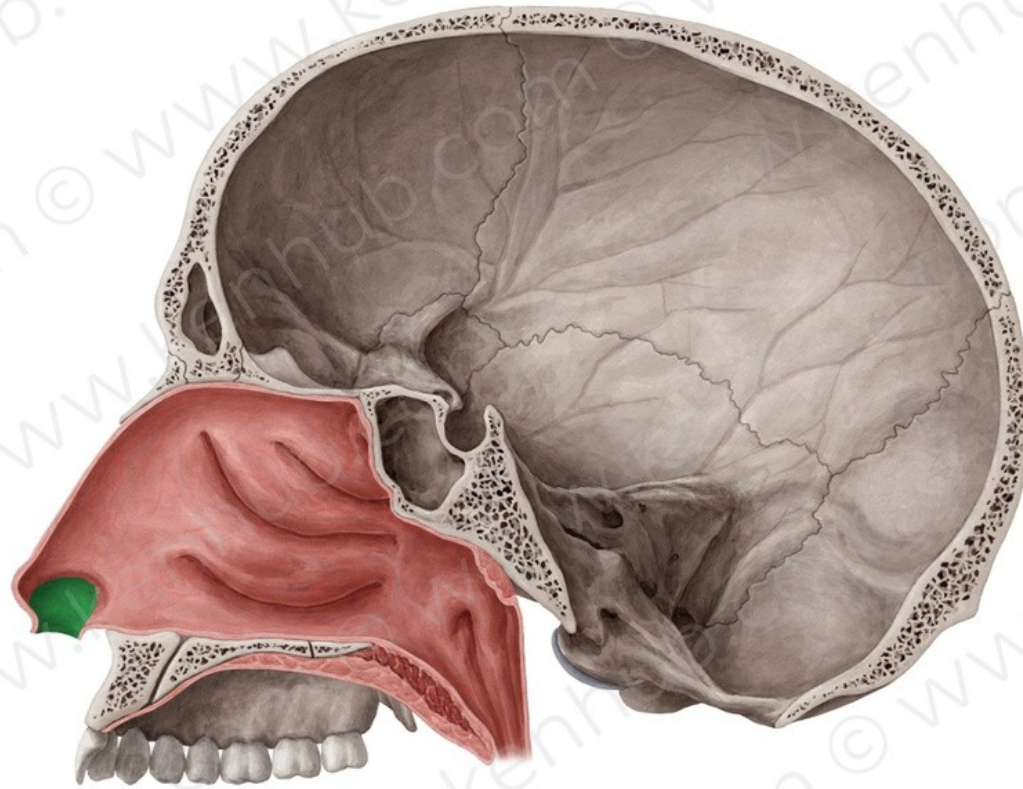
face of the tubercle (tuberculum, i n) of the rib

- Facies tuberculi costae



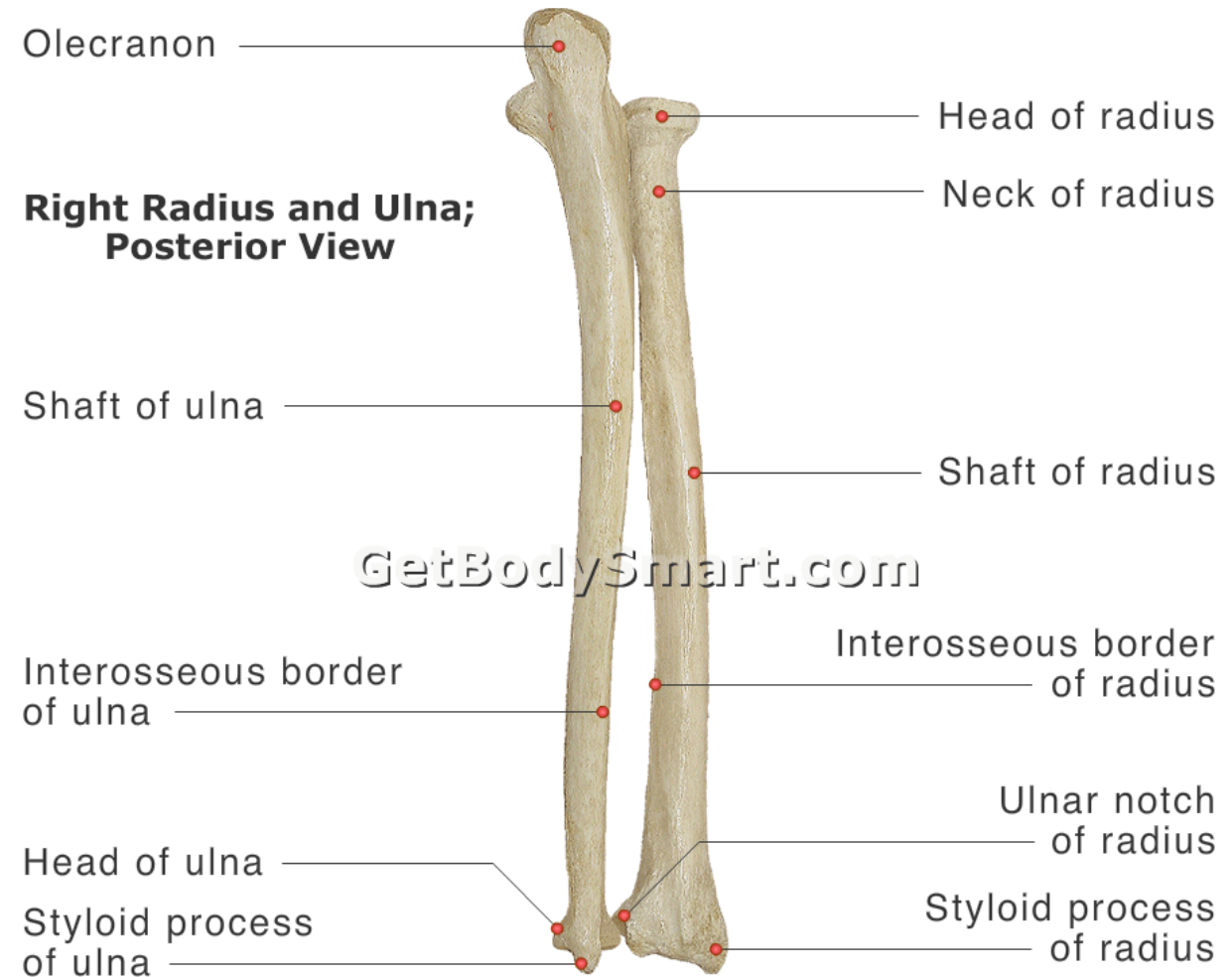
vestibule (vestibulum, i n) of the nose

- Vestibulum nasi



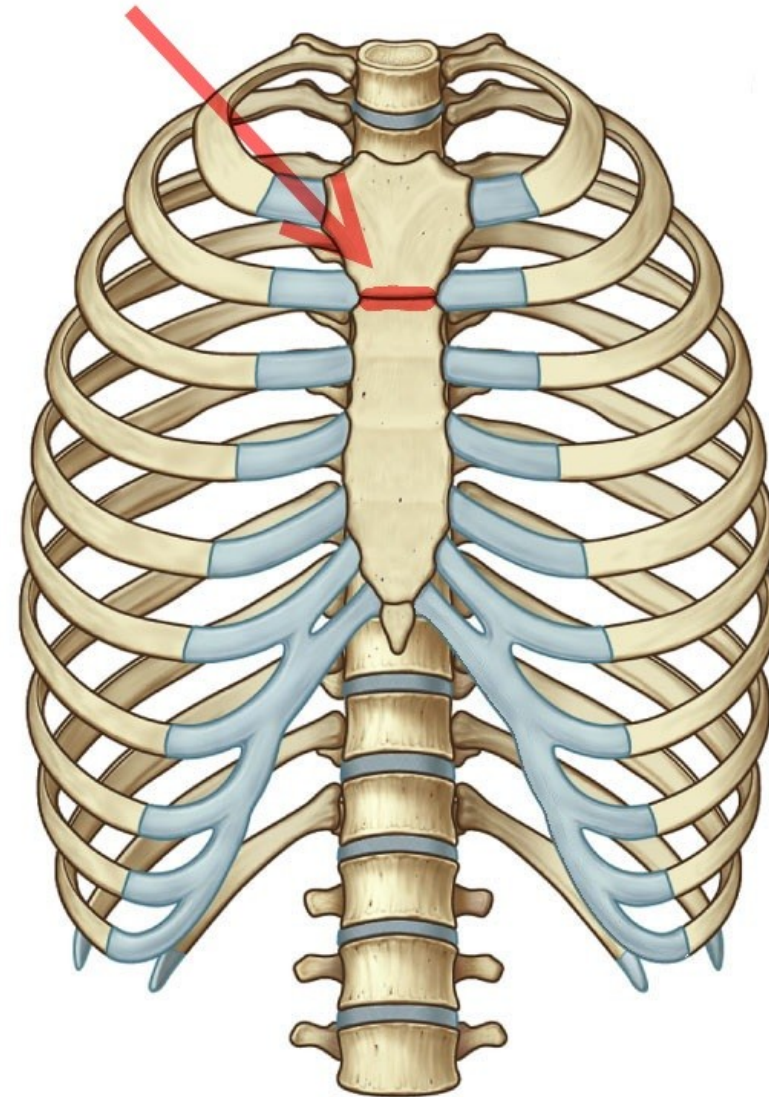
neck of the ulna

- Collum ulnae



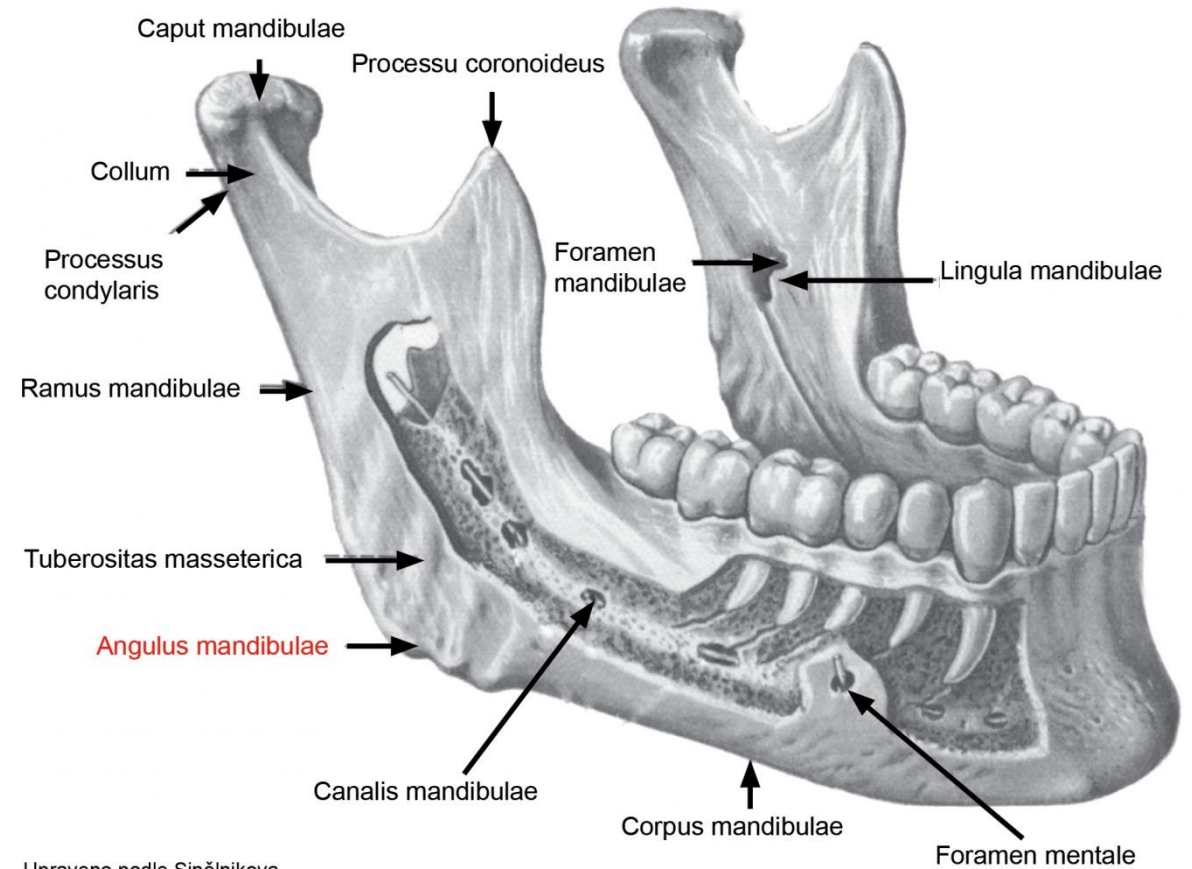
angle of the sternum

- Angulus sterni



angle of the lower jaw

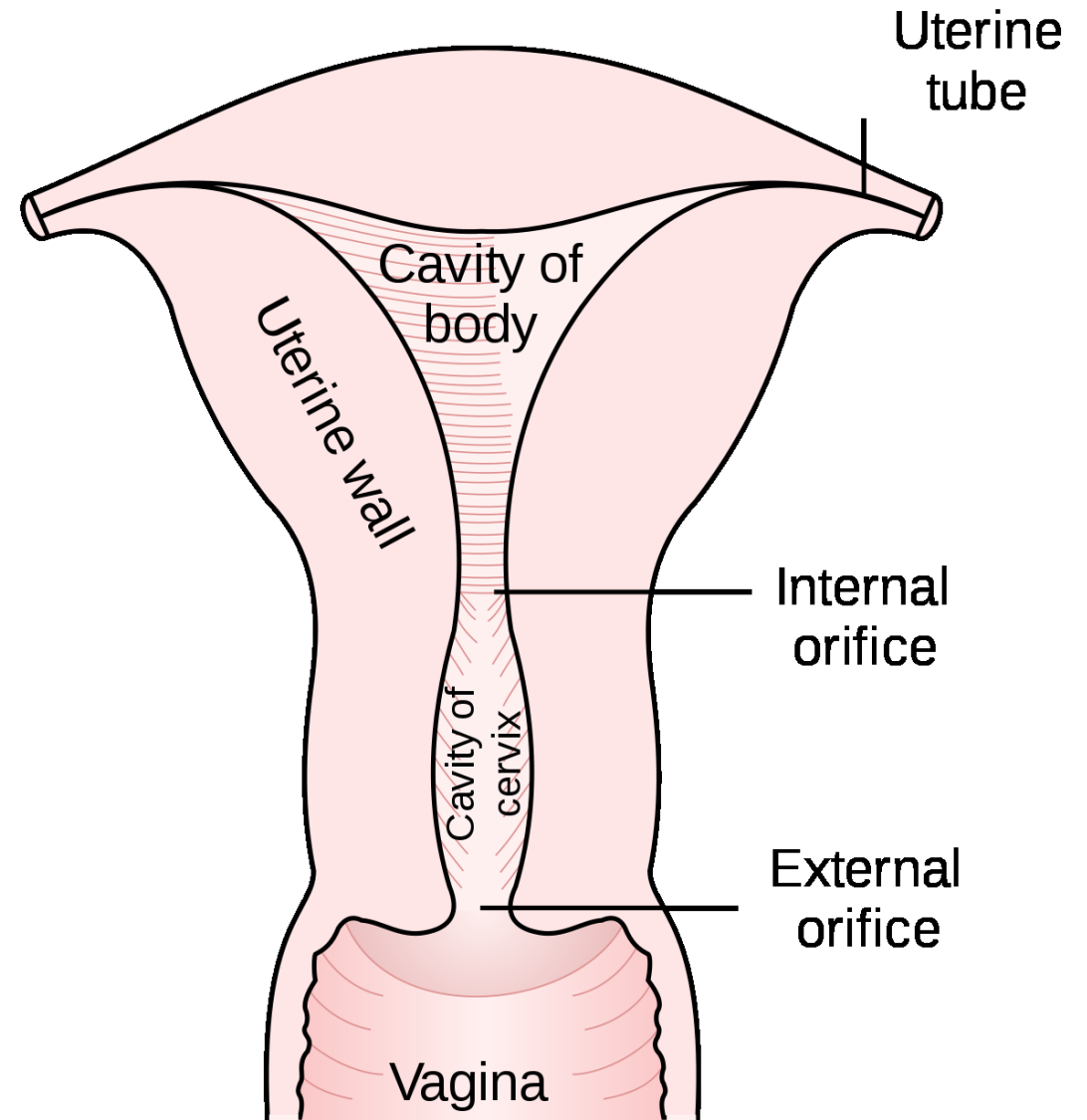
- Angulus mandibulae inferioris



Upraveno podle Siněnikova

cavity of the uterus

- Cavum uteri



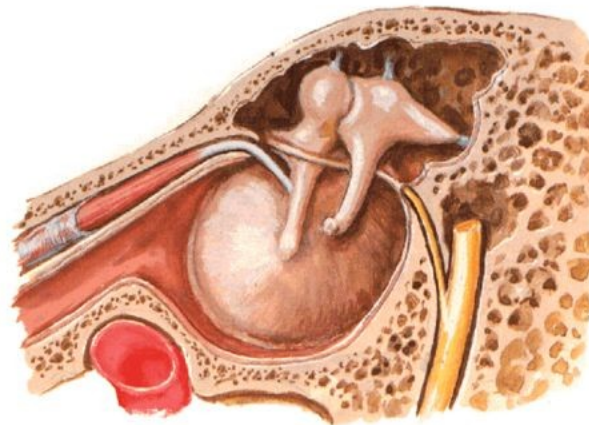
cavity of the tympanum

- Cavum tympani

CAVUM TYMPANI

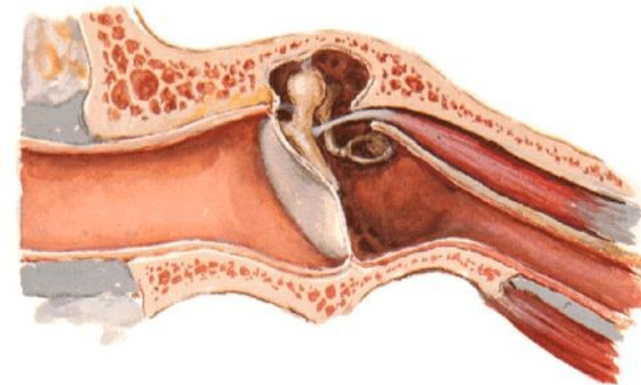
- cavum tympani proprium
- recessus epitympanicus

Tympanic Cavity - Lateral Wall
Medial View



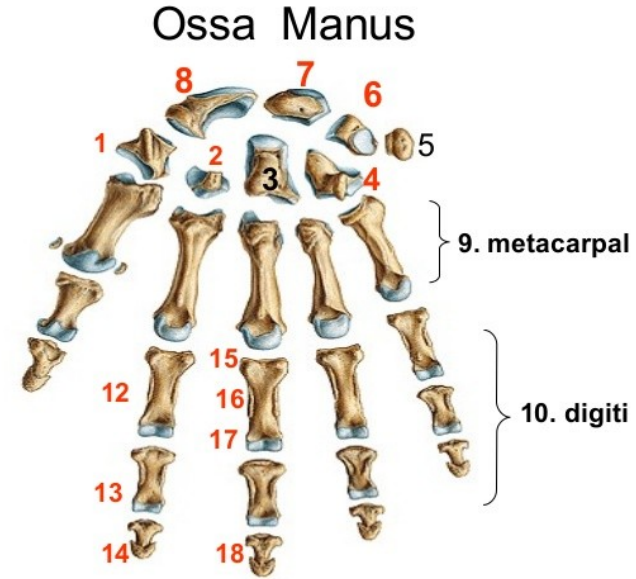
Paries tegmentalis
Paries jugularis
Paries caroticus
Paries mastoideus
Paries labyrinthicus
Paries membranaceus

External Ear and Tympanic Cavity
Coronal Oblique Section



bone of the finger

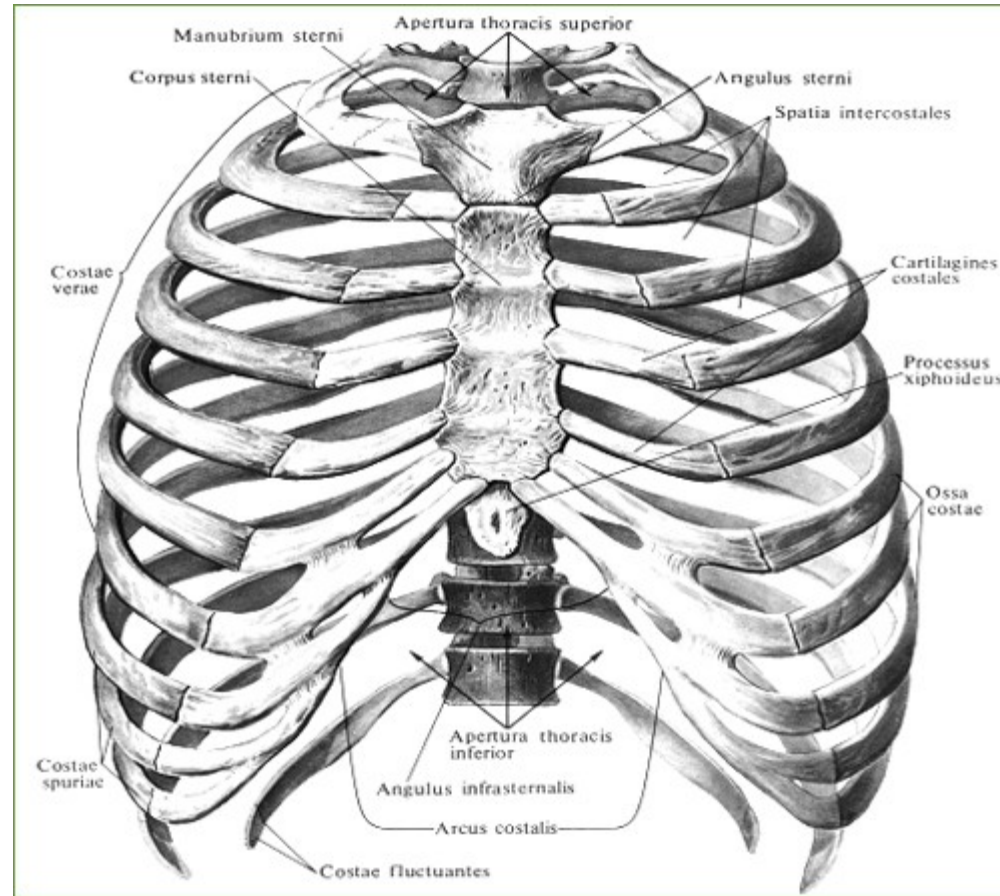
- Os digiti



- | | |
|--------------------|-----------------------------|
| 1. Os Trapezium | 9. Os Metacarpal |
| 2. Os Travezoideum | 10. Os Digiti |
| 3. Os Capitatum | 11. Phalanges |
| 4. Os Hamatum | 12. Phalanx Proximal |
| 5. Os Fisiform | 13. Phalanx Medial |
| 6. Os Triquetrum | 14. Phalanx Distal |
| 7. Os Lunatum | 15. Basis |
| 8. Os Scaphoideum | 16. Corpus |
| | 17. Caput |
| | 18. Tub. Phalangis Distalis |

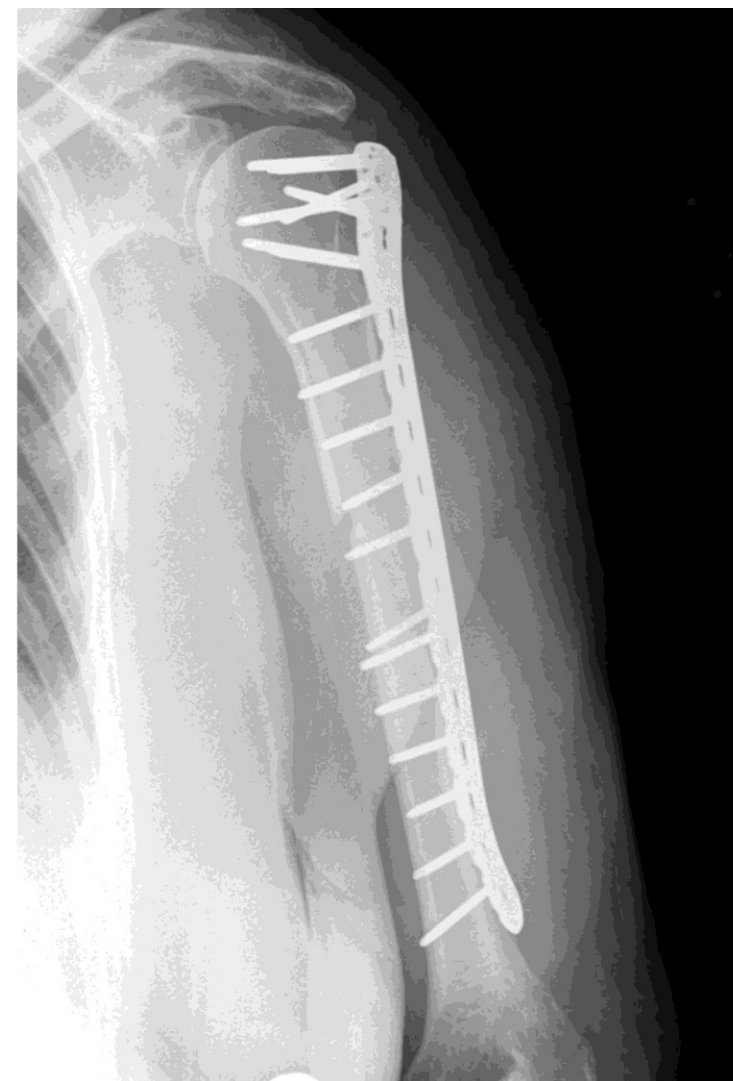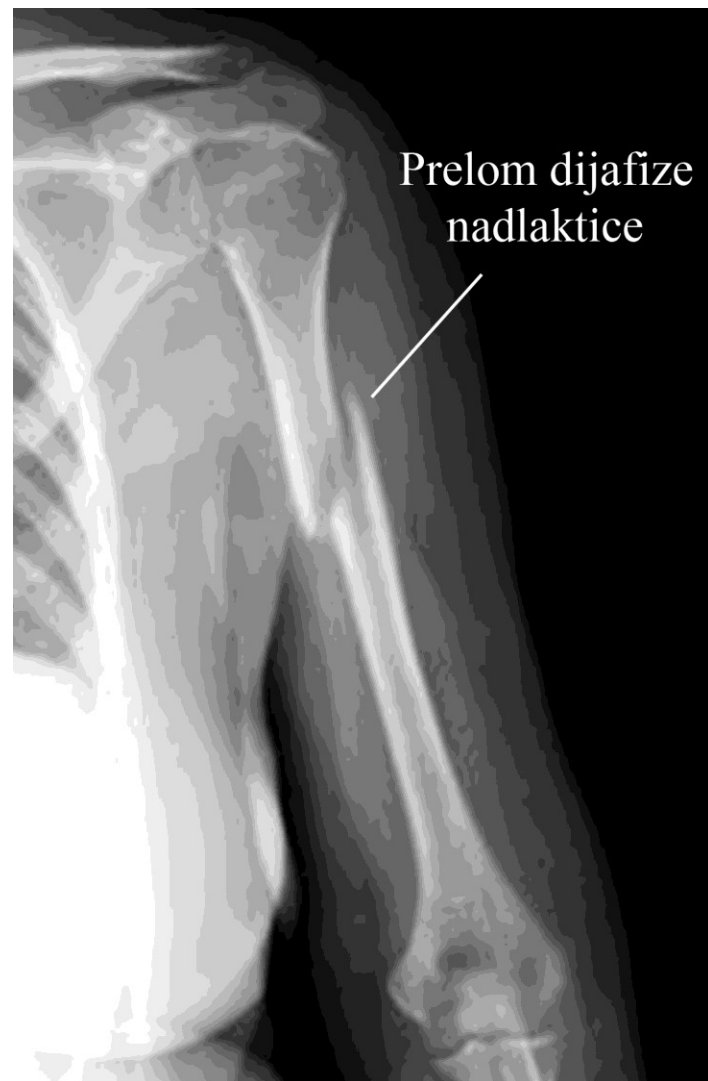bones of the trunk

- Ossa trunci



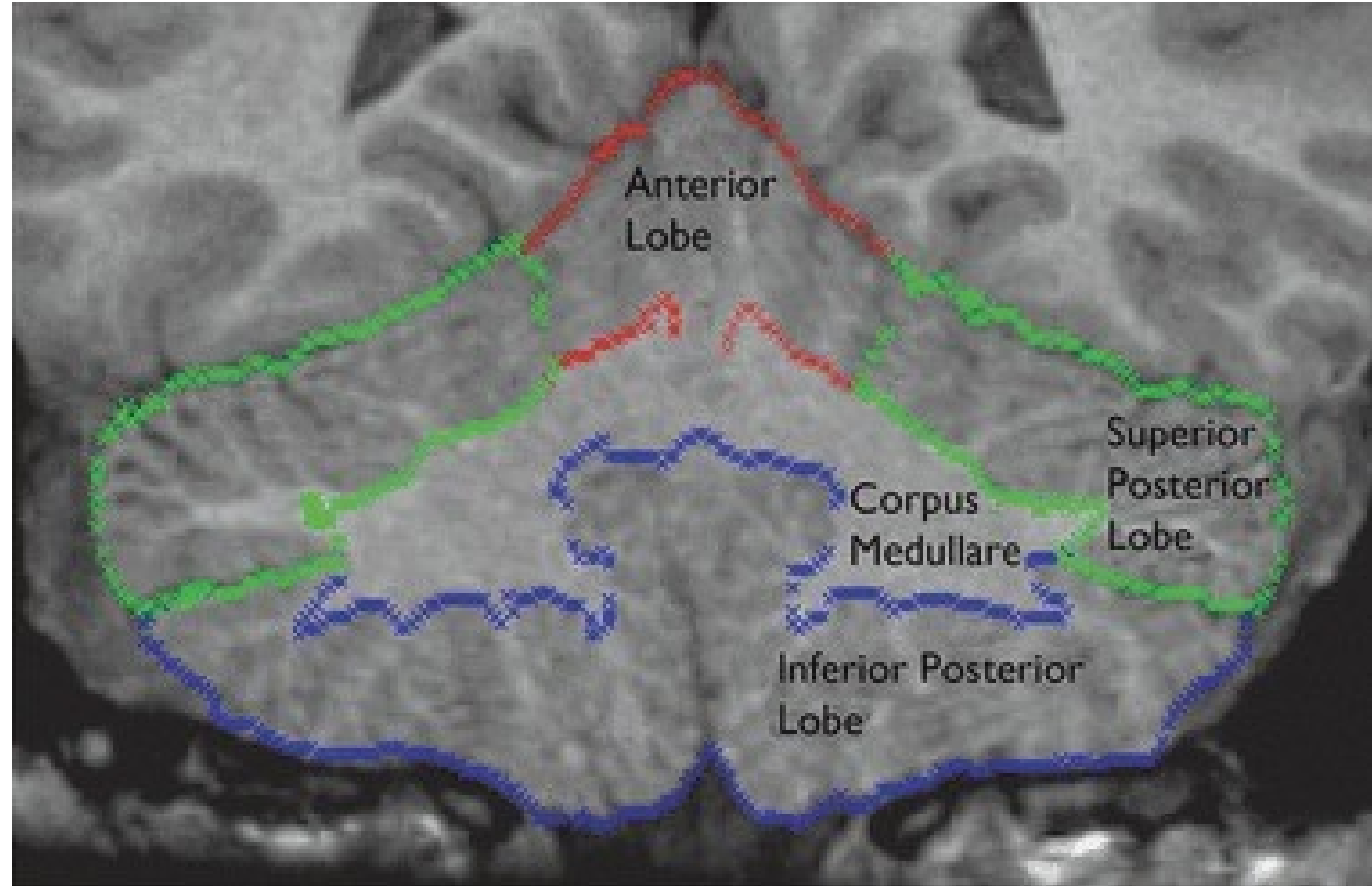
fracture of the humerus

- Fractura humeri



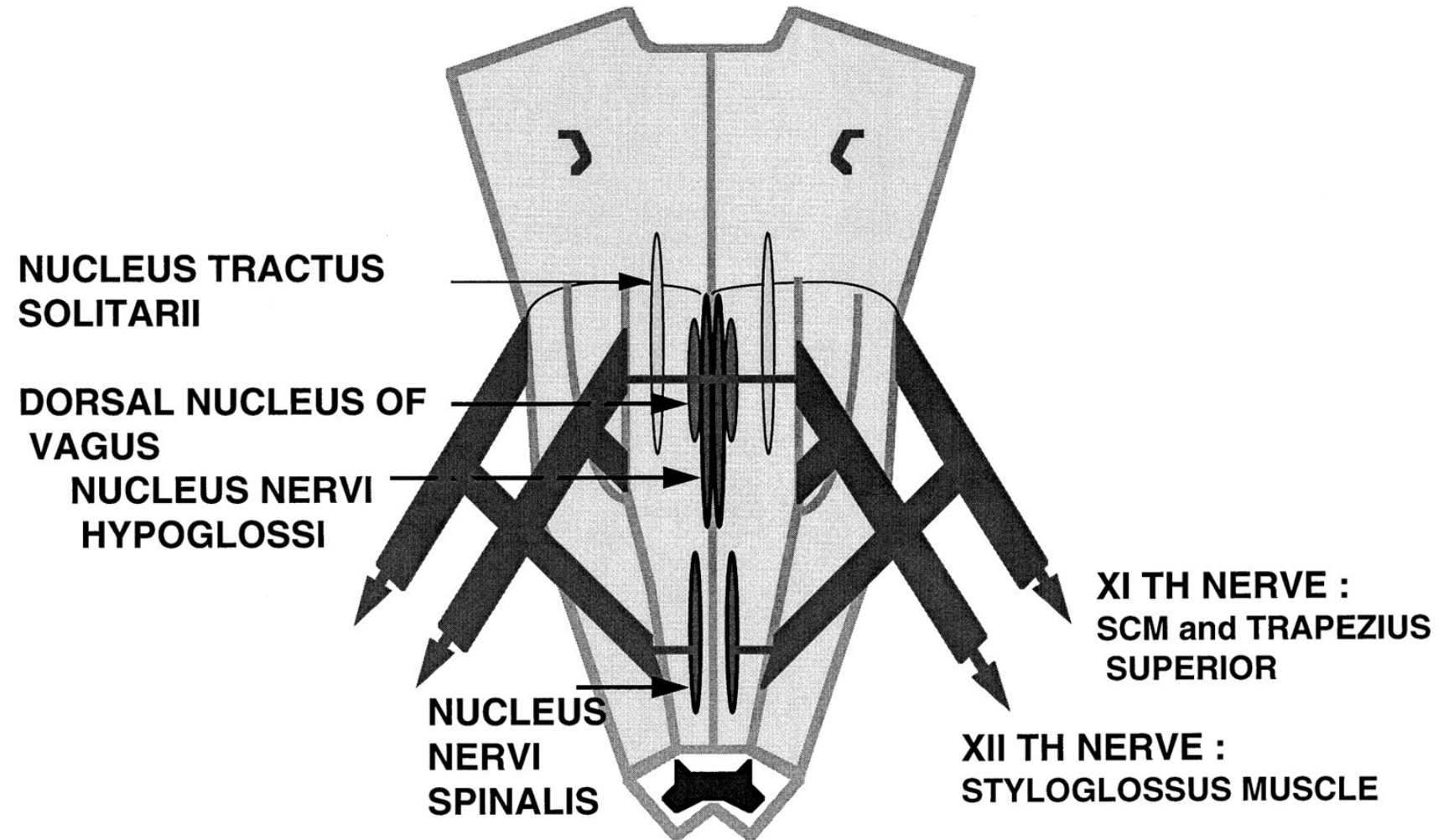
body of the marrow

- Corpus medullare



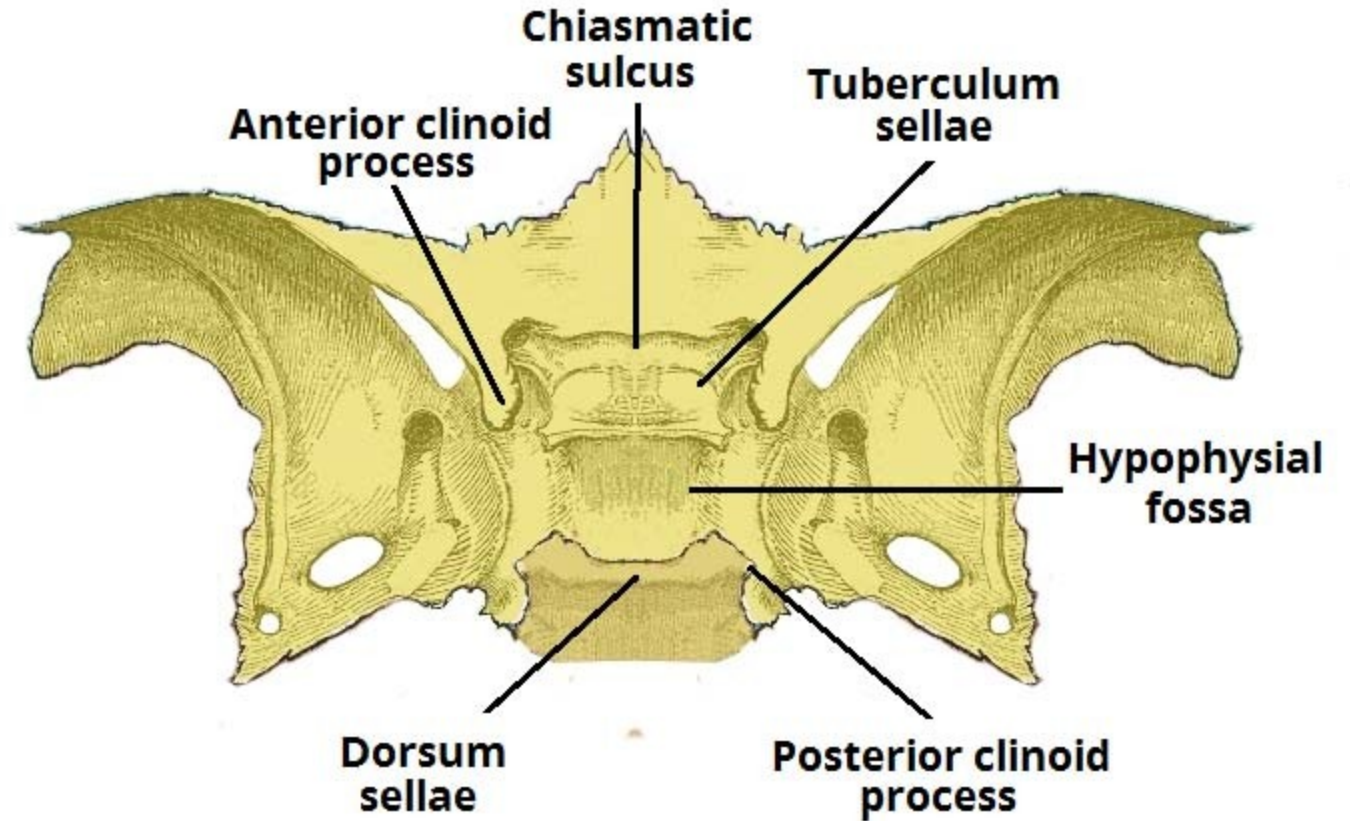
nucleus of the nerve

- Nucleus nervi



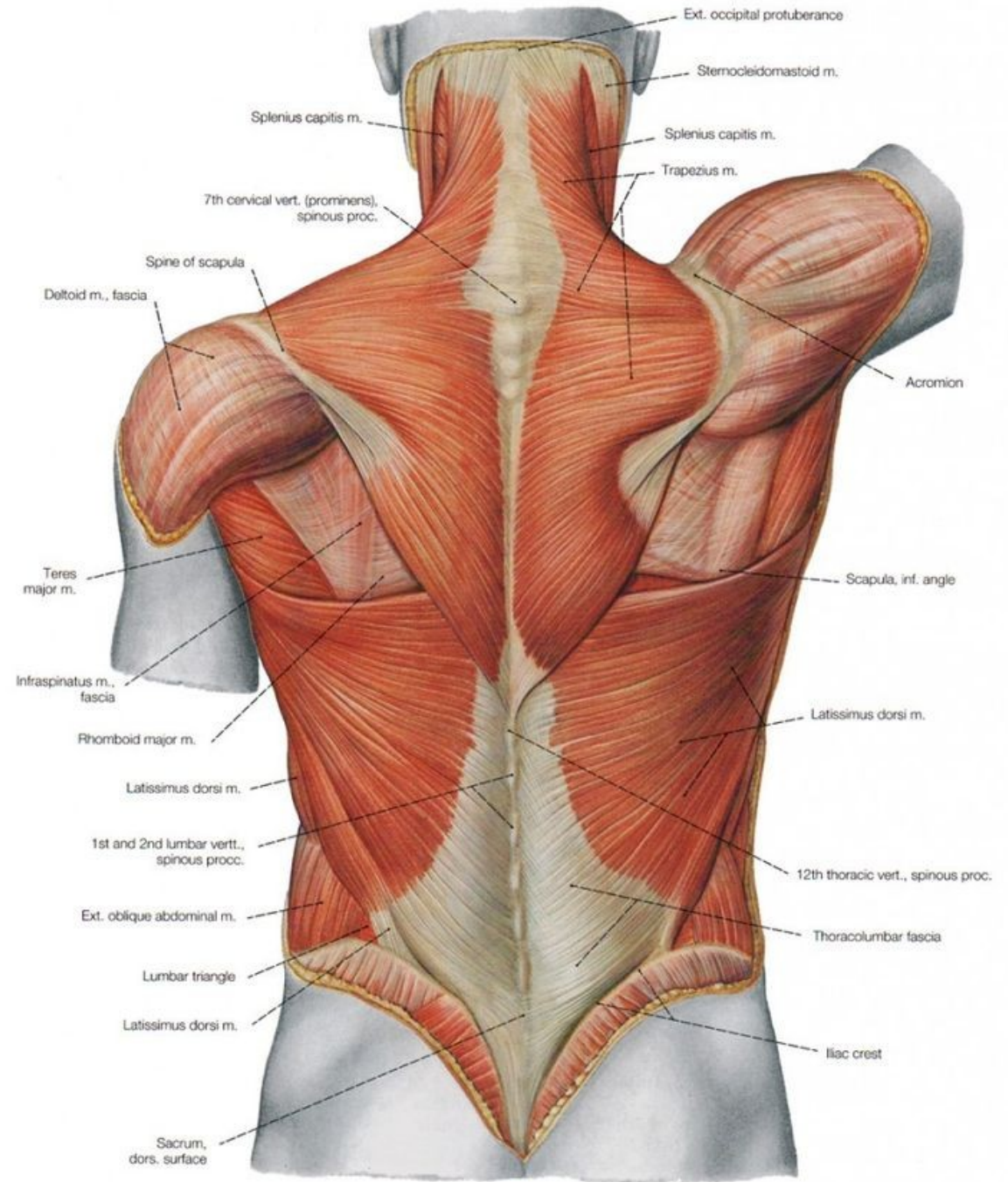
tubercle of the saddle

- Tuberculum sellae



muscle of the back

- Musculus dorsi



muscle of the uvula (uvula, ae f)

- Musculus uvulae

Muscles of palate

Musculus uvulae

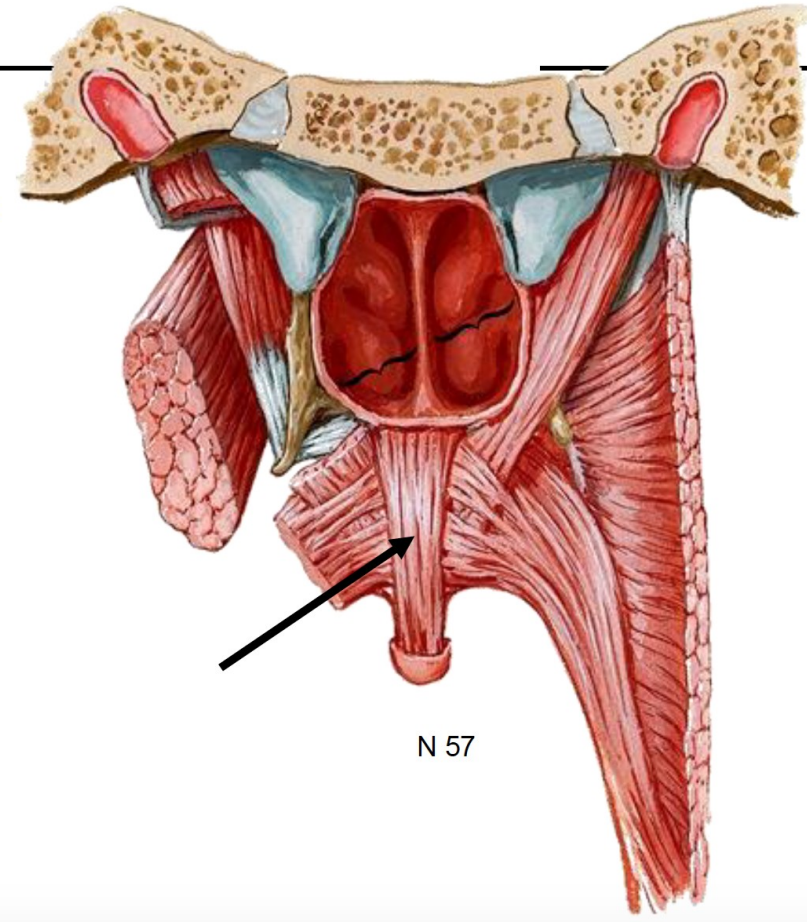
SA: Palatine, tissue of soft palate

IA: Mucosa of uvula

INN: Vagus (CN X)

Act: shortens, raises uvula

Has right and left sides

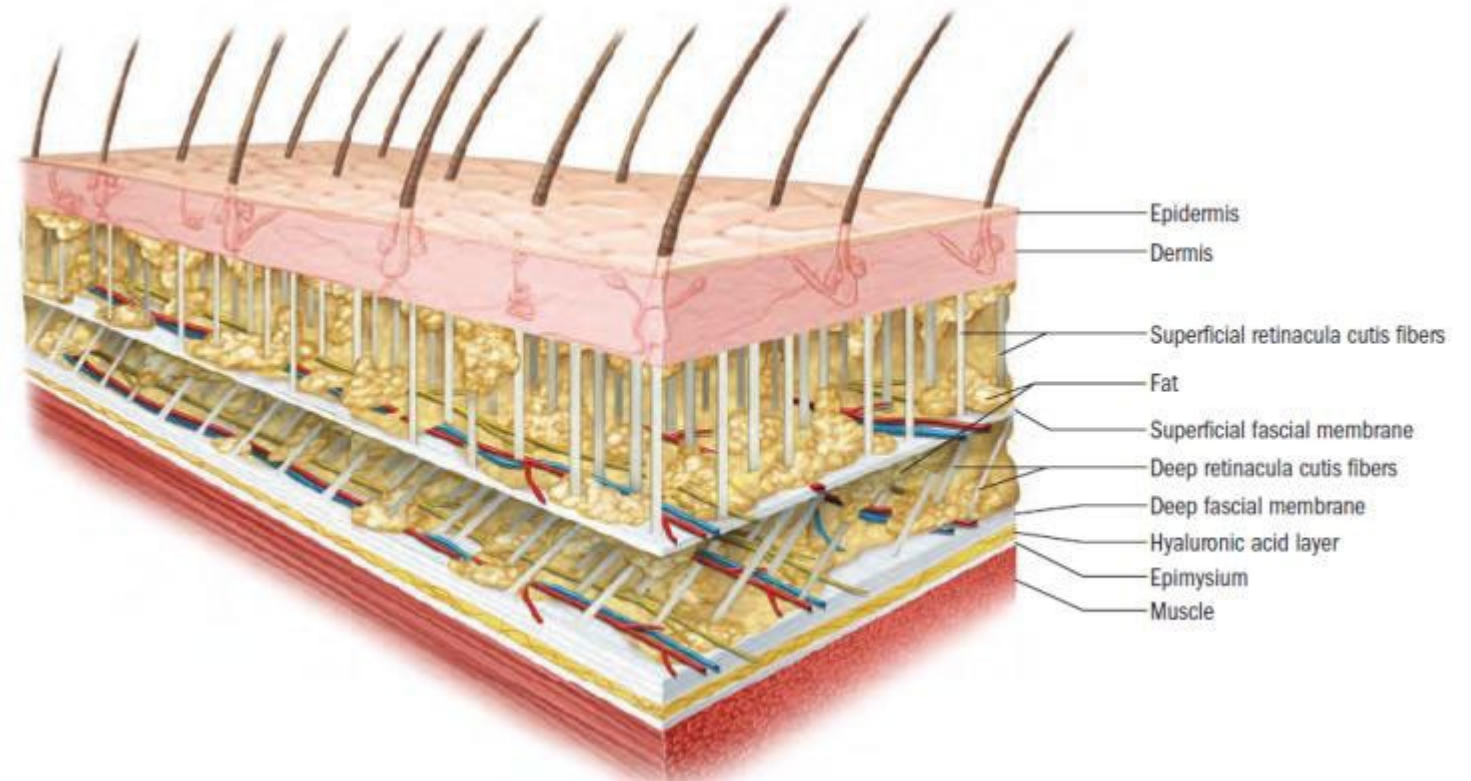


Exercise 6. Translate anatomical terms into English

- *E.g. Ligamentum pylori – ligament of the pylorus*

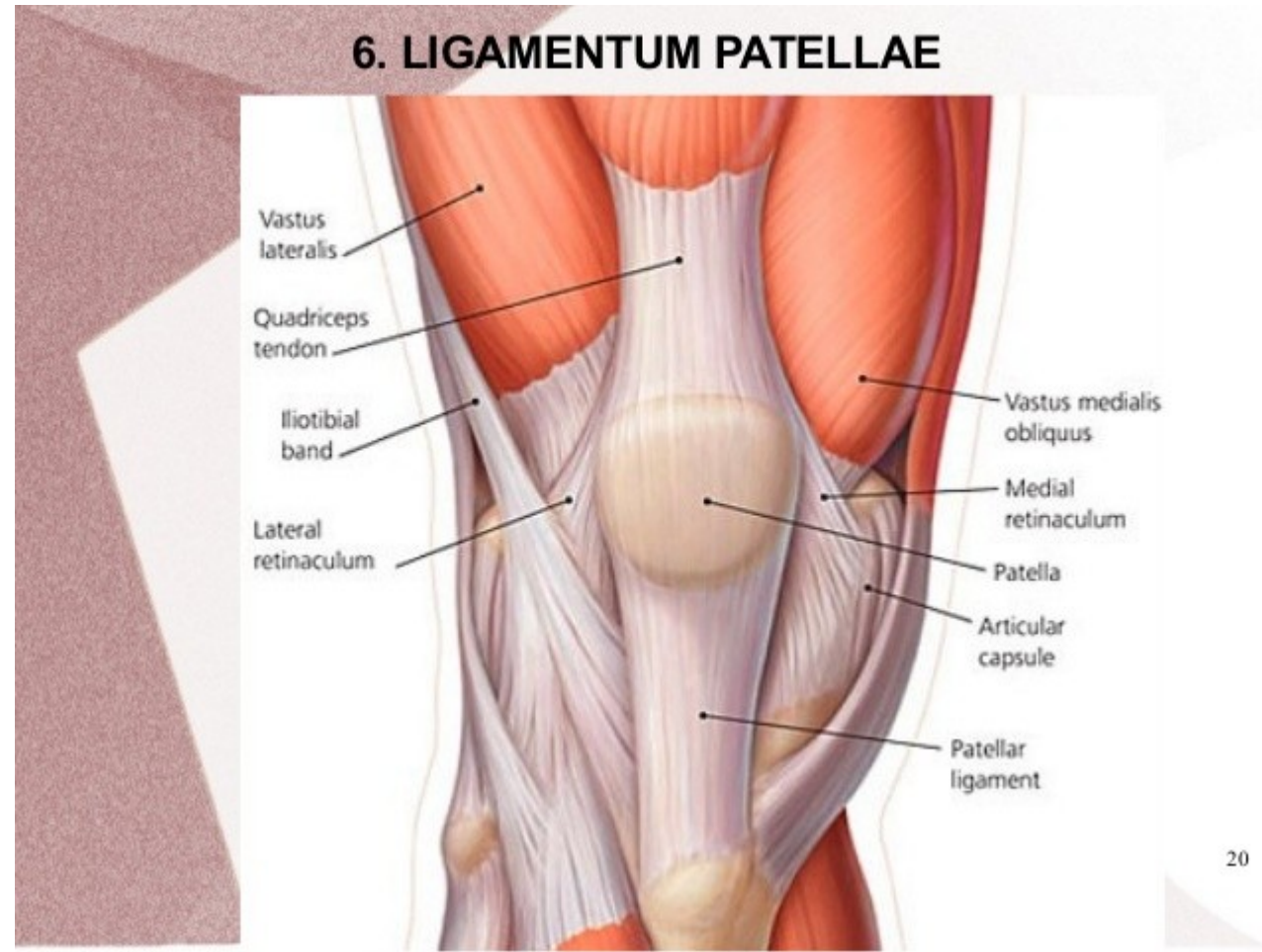
retinaculum cutis

- Skin ligaments



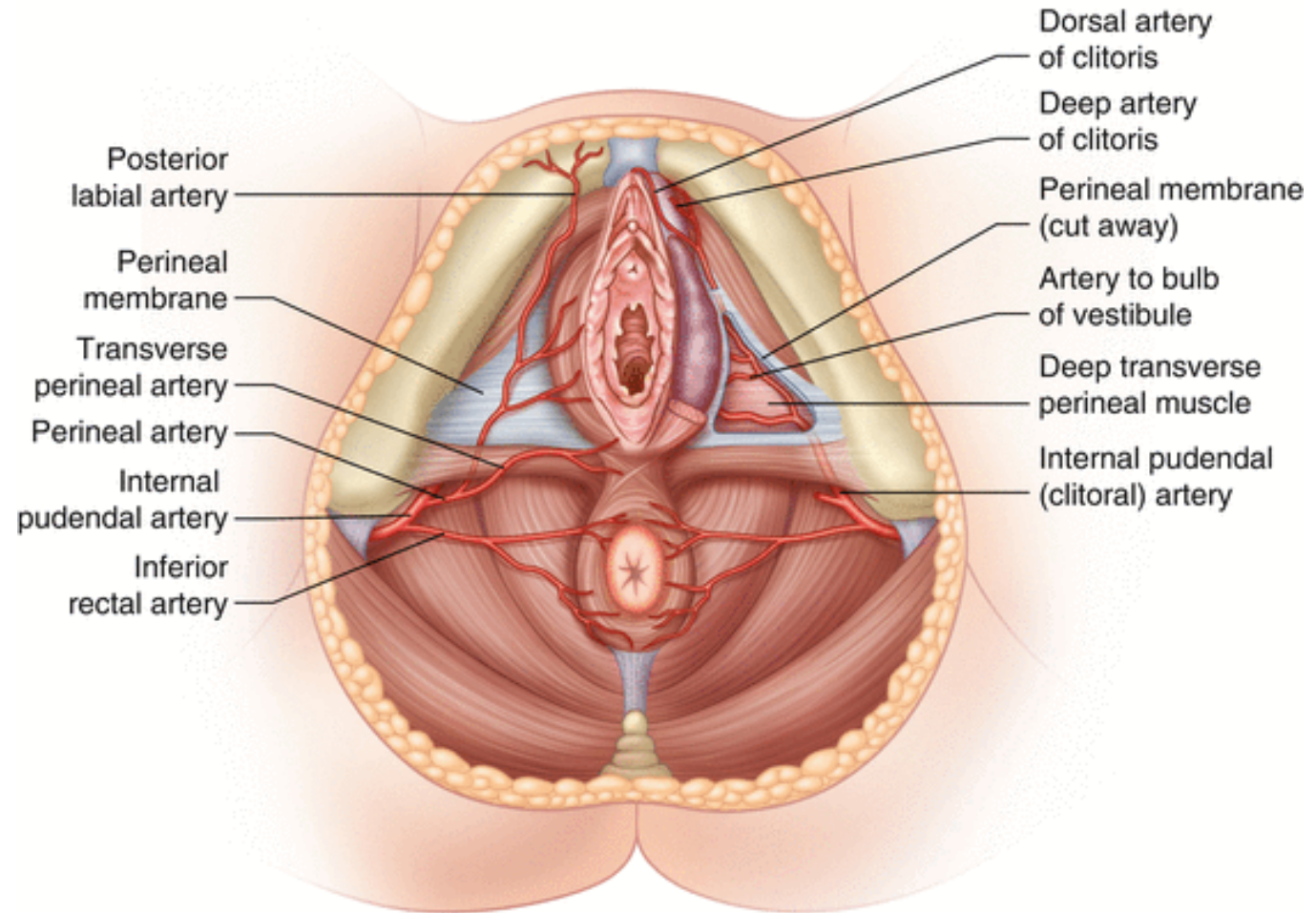
ligamentum patellae

- Patellar ligament



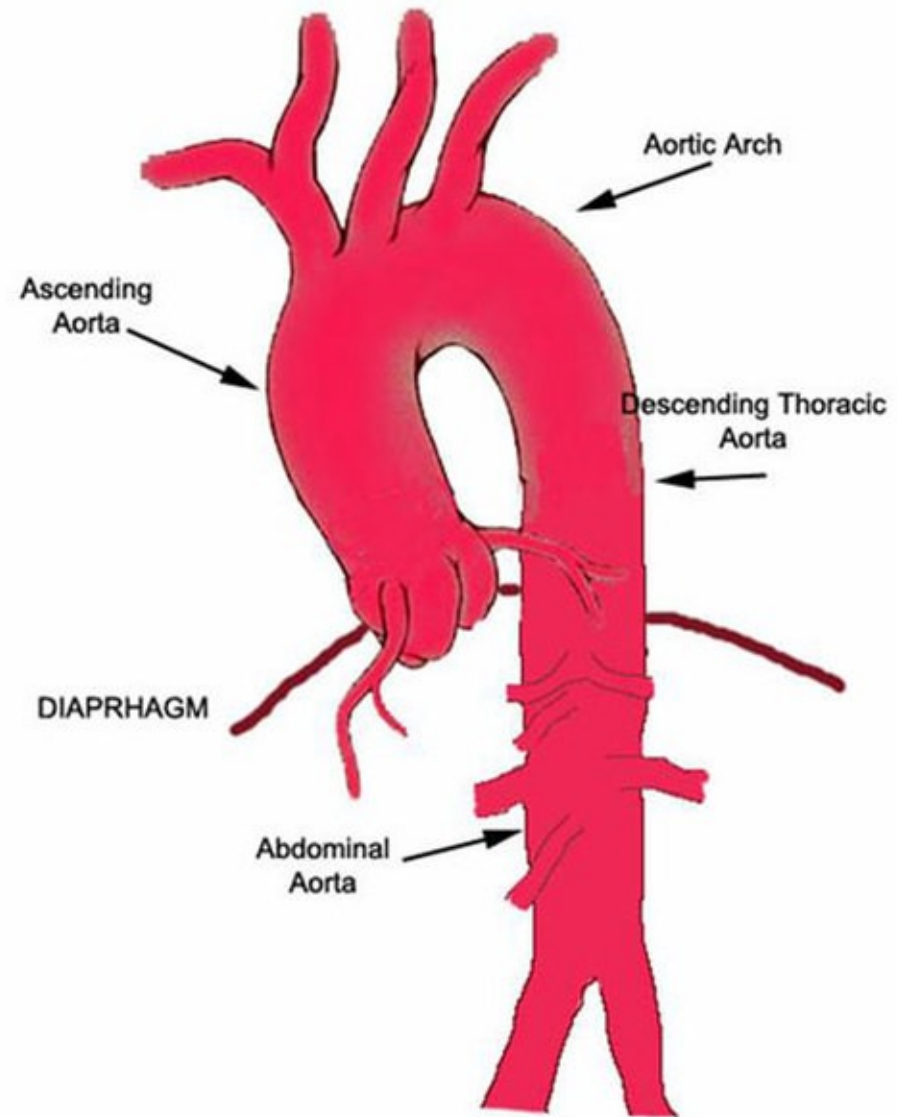
arteria perinei

- Perineal artery



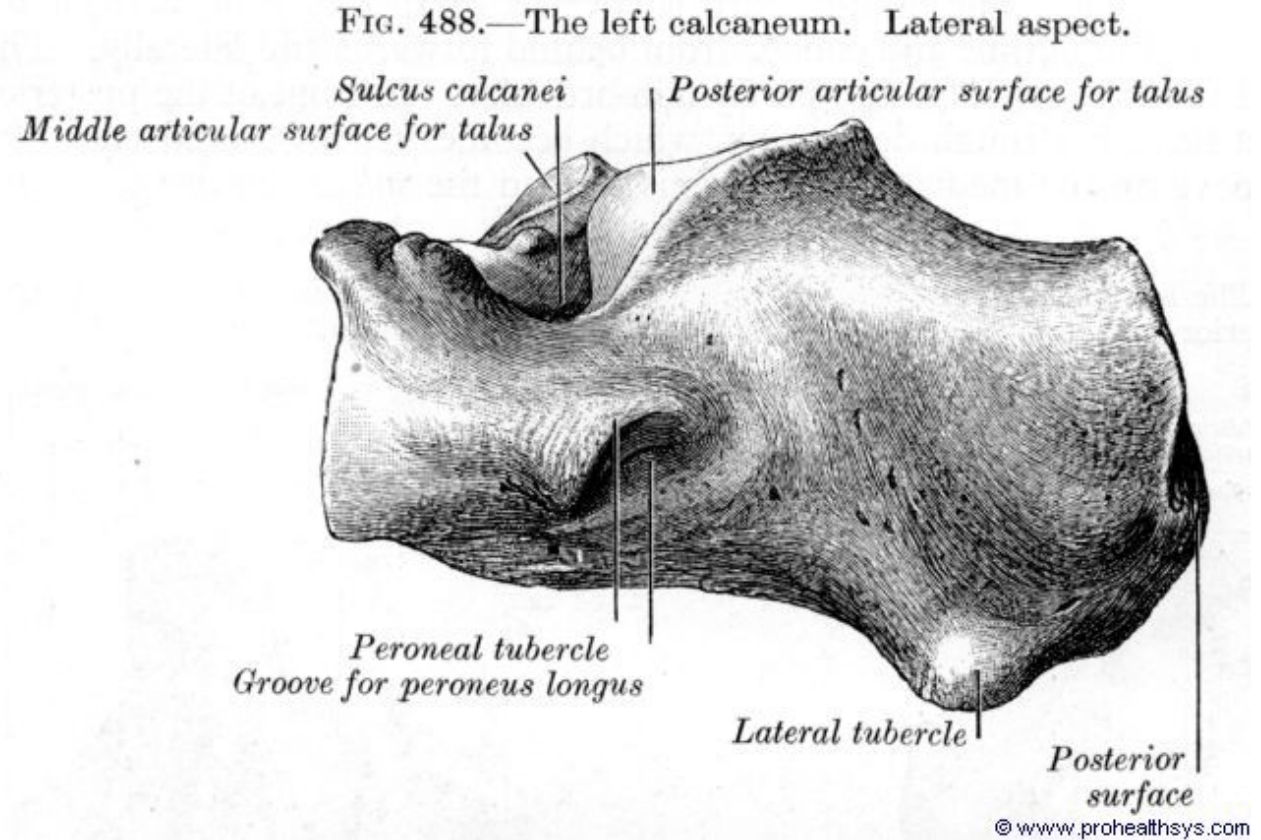
arcus aortae

- Aortic arch



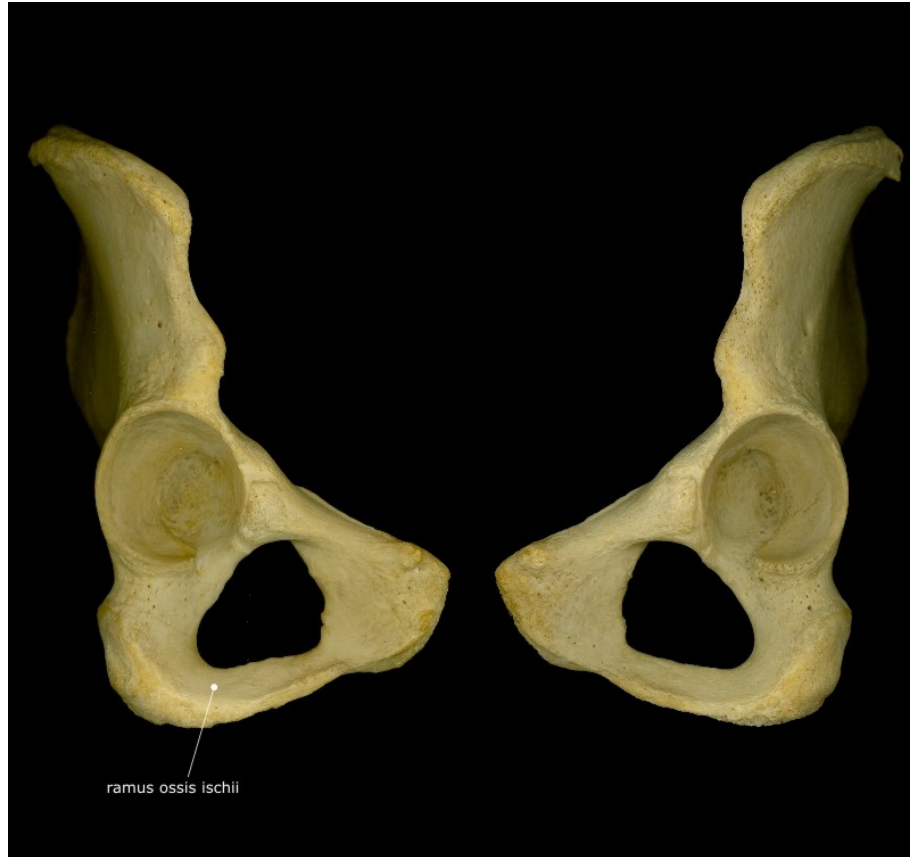sulcus calcanei

- Calcaneal sulcus



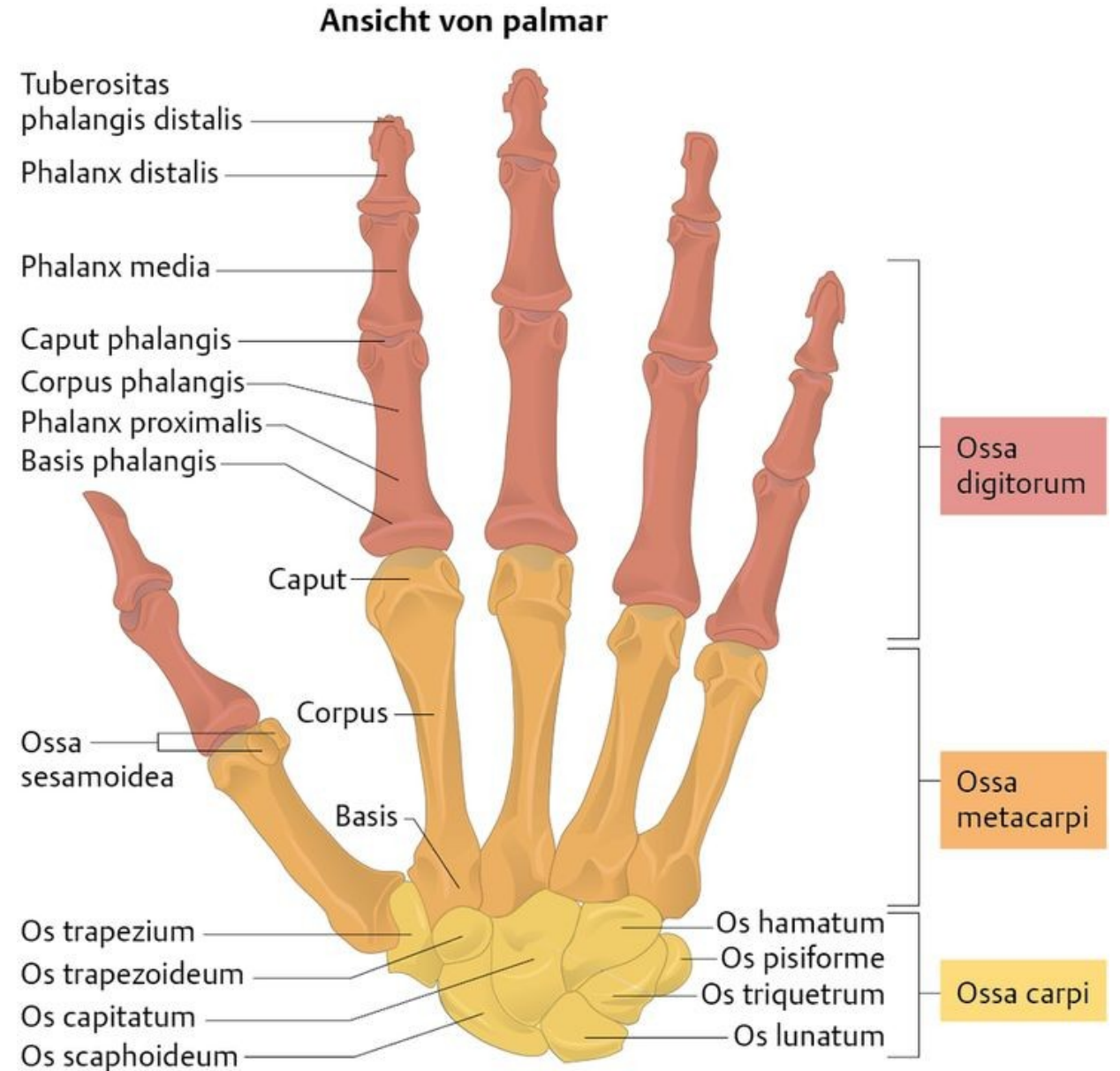
ramus ossis ischii

- the branch of the ischial bone, formerly called inferior branch of the ischium



caput phalangis

- Head of phalanx

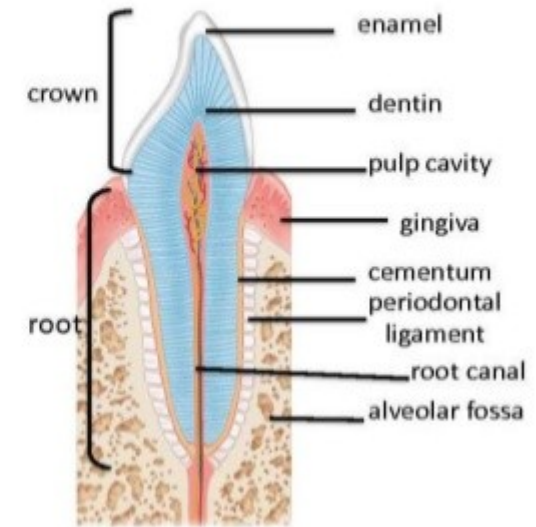
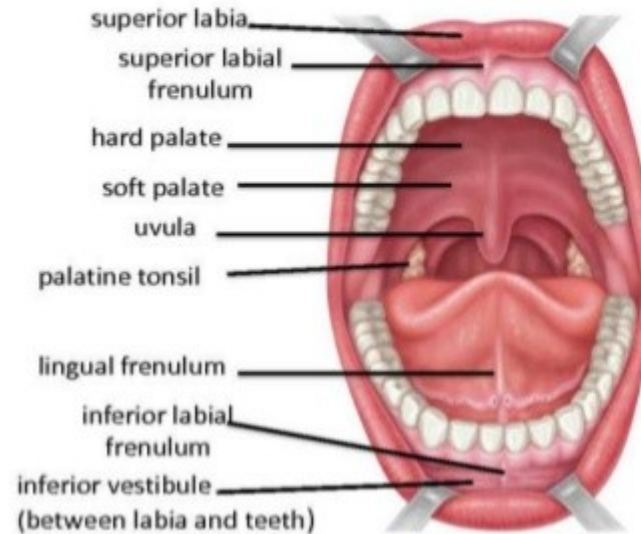


cavum oris

- Oral cavity

ORAL CAVITY

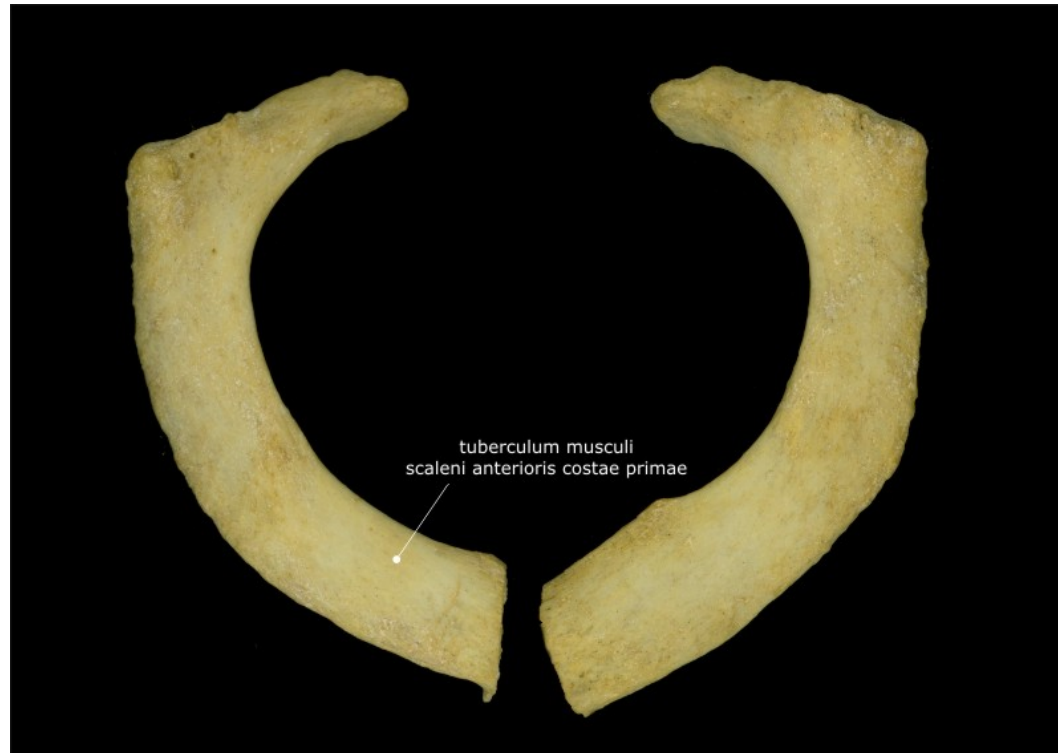Oral Cavity Anatomy



Tooth Anatomy

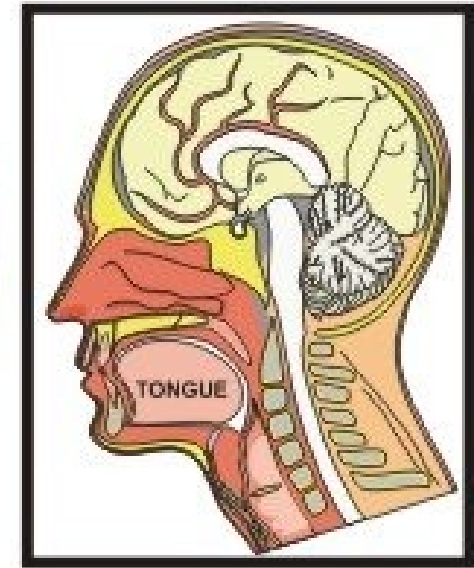
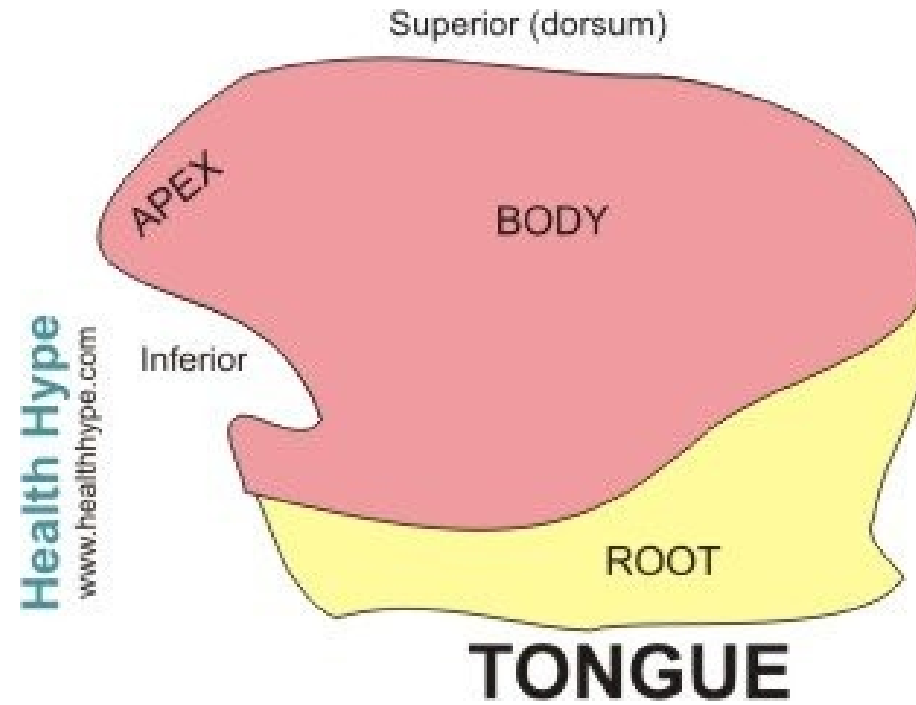
tuberculum musculi

- Scalene tubercle; Tubercle for anterior scalene muscle



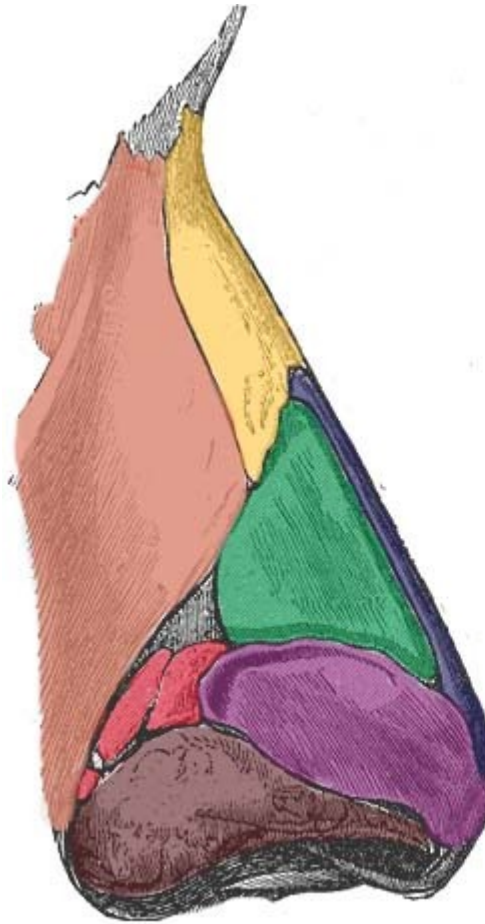
corpus linguae

- Body of tongue



cartilago nasi

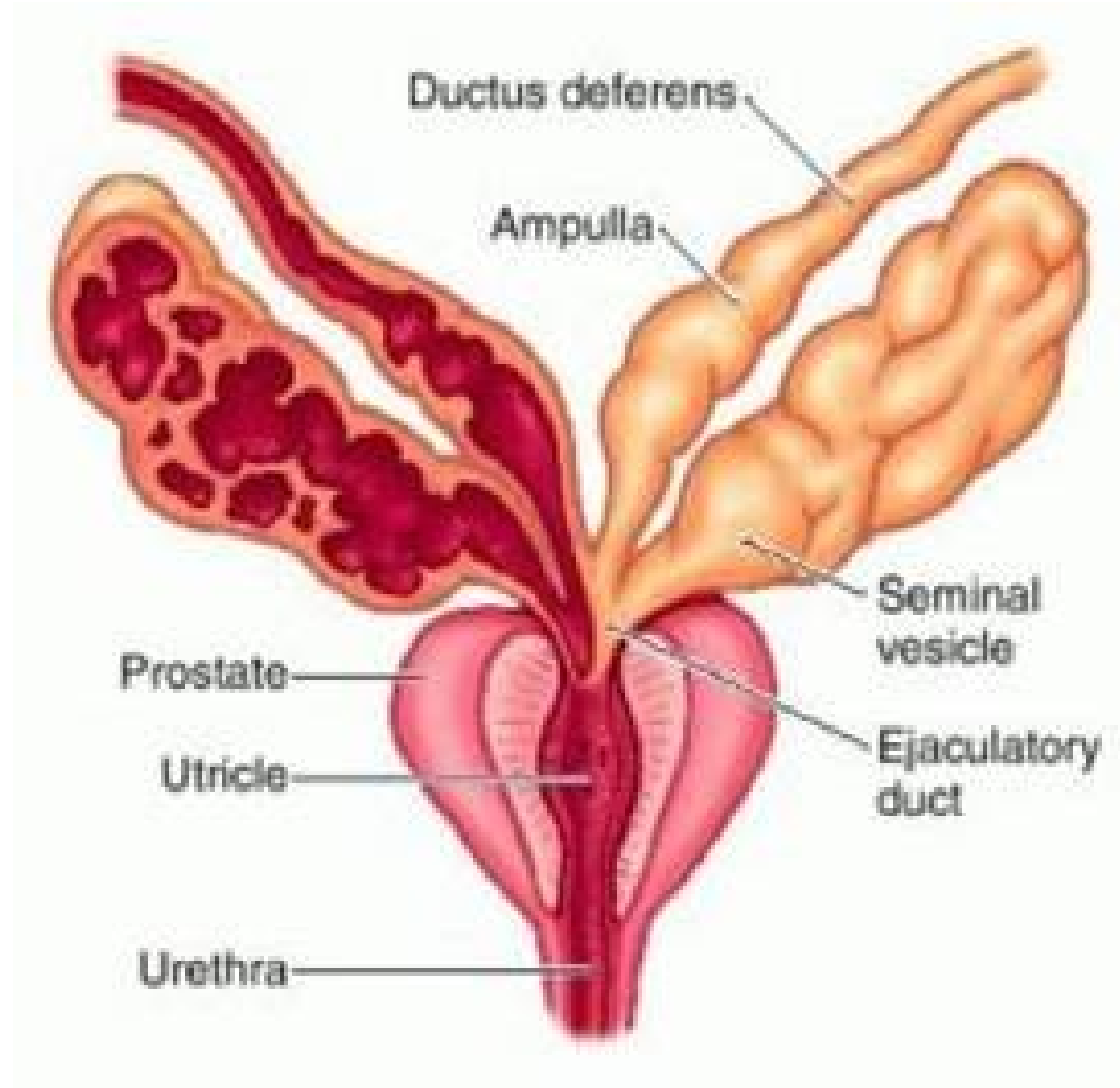
- nasal cartilage



- Nasal Bone
- Maxilla
- Septal Cartilage
- Lateral Cartilage
- Major Alar Cartilage
- Minor Alar Cartilages
- Fibro-fatty Tissue

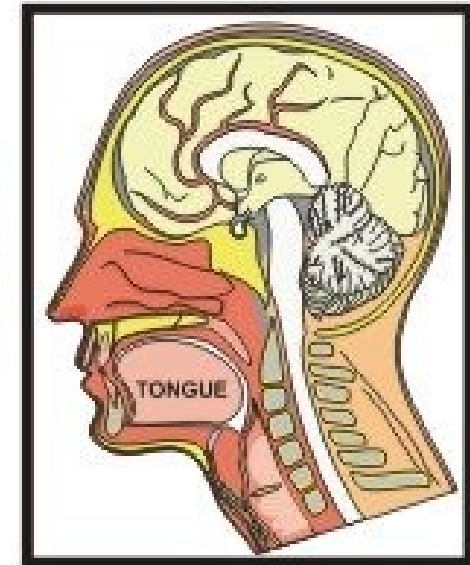
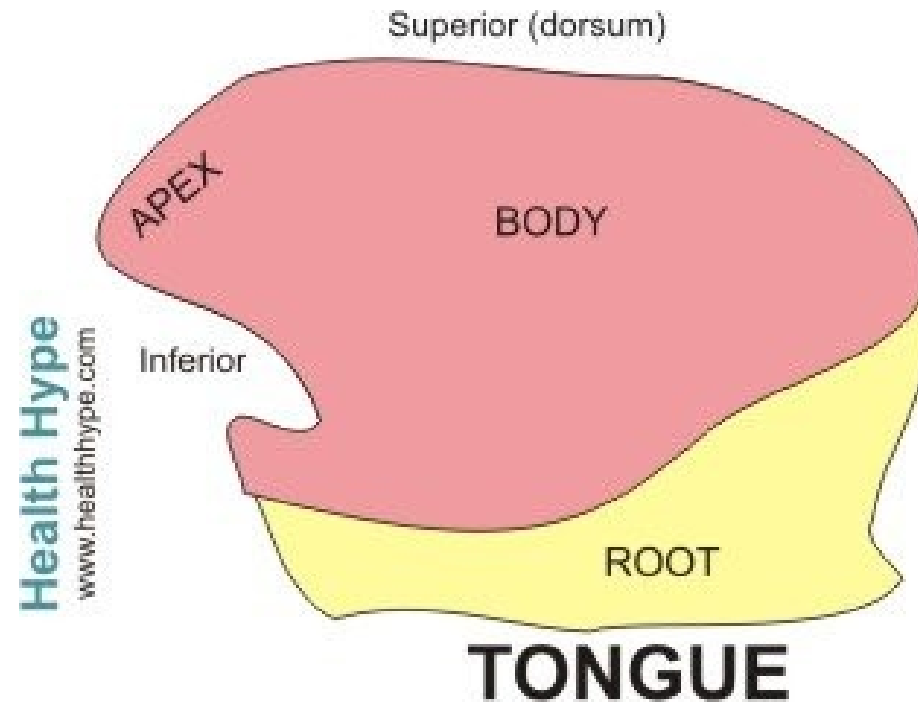
ampulla ductus

- Ampulla of ductus



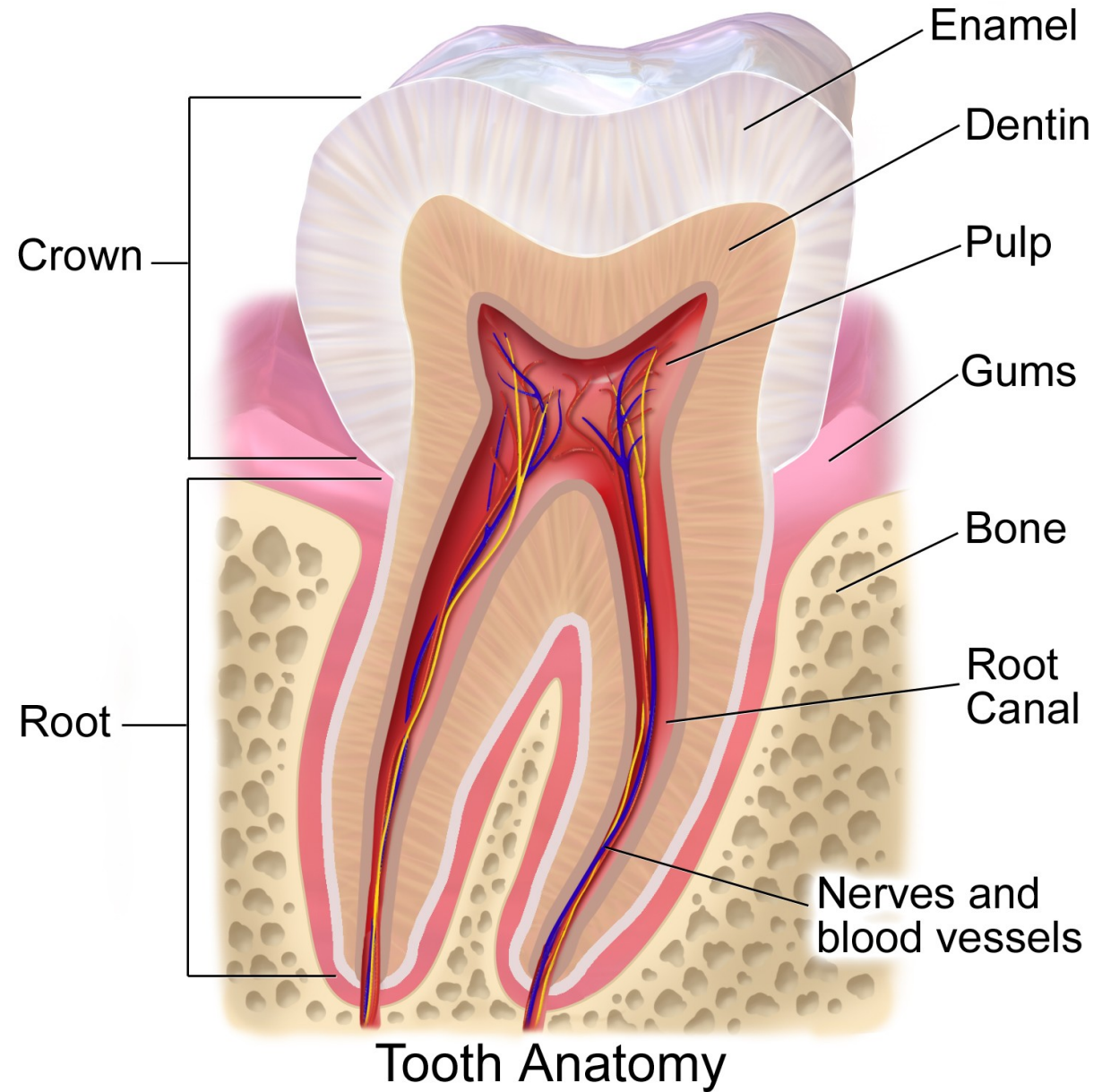
apex linguae

- Apex of tongue; Tip of tongue



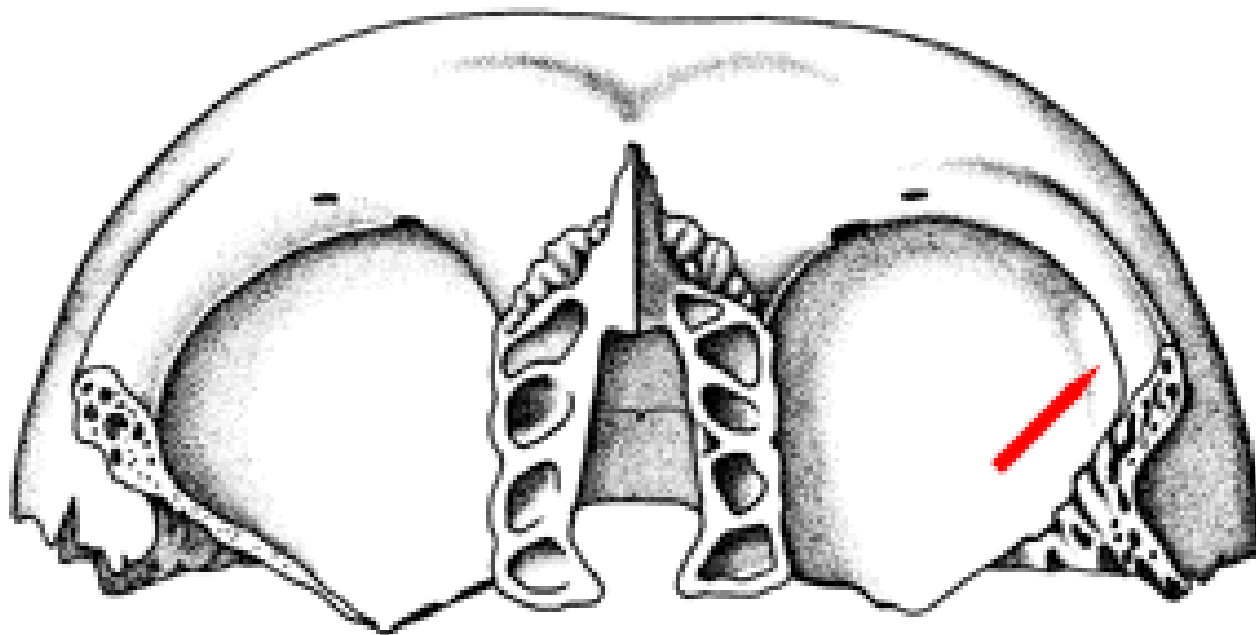
radix dentis

- Root of tooth



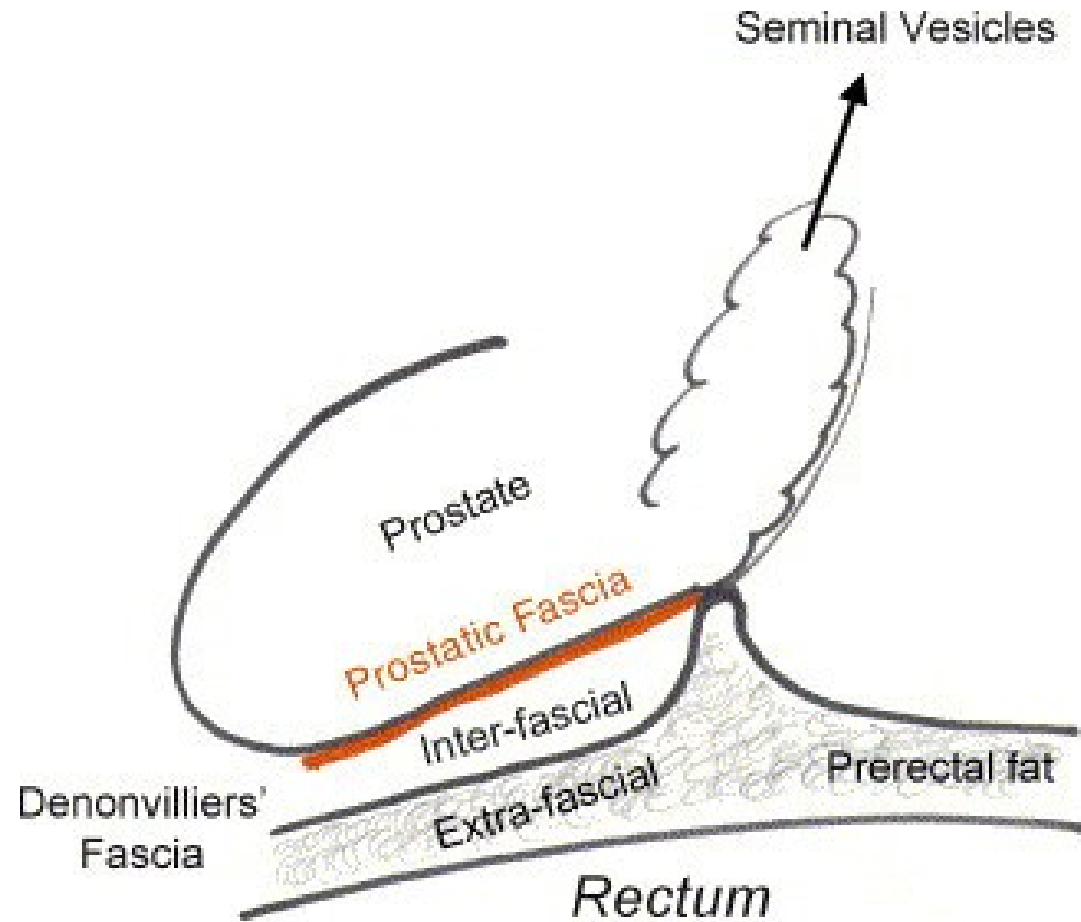
fossa glandulae lacrimalis

- Fossa for lacrimal gland; Lacrimal fossa



fascia prostatae

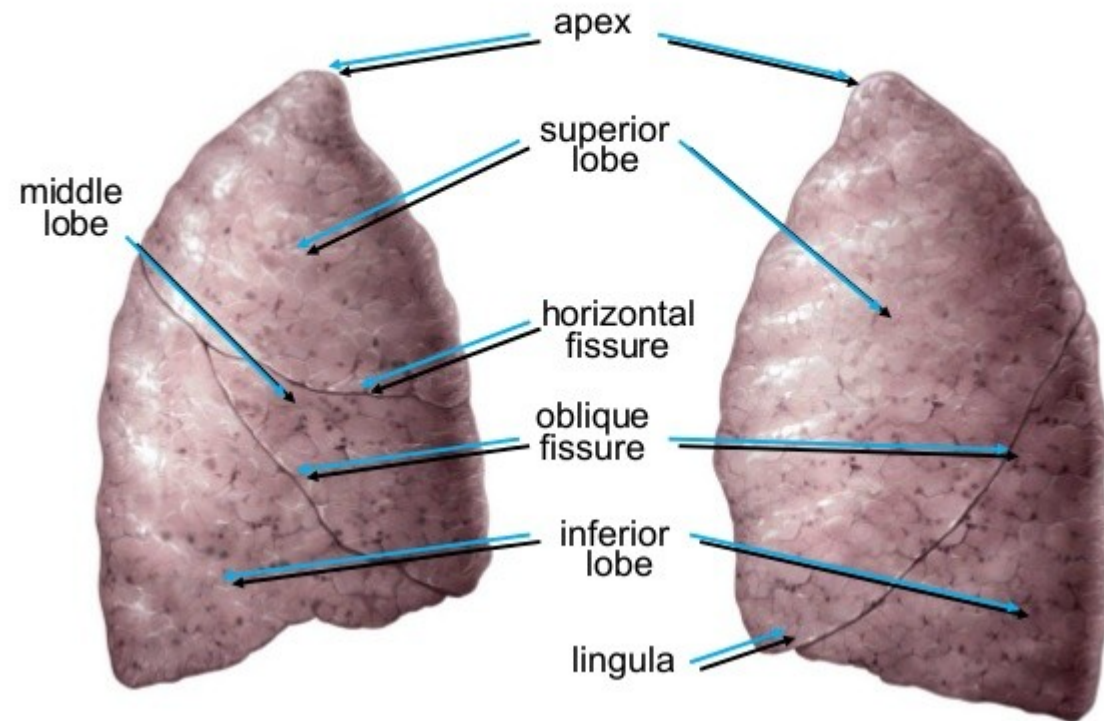
- fascia of prostate



apex pulmonis

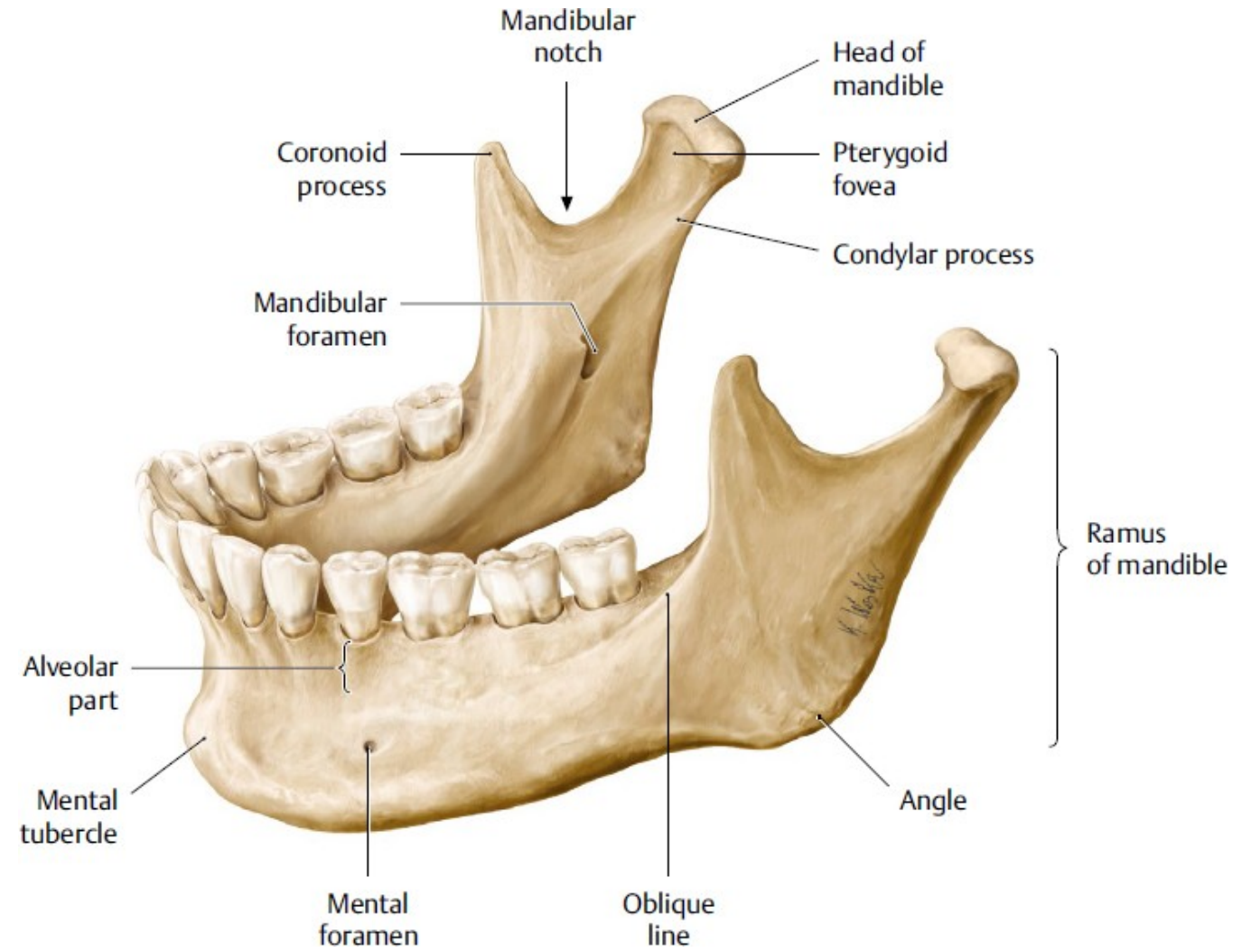
- Apex of lung

Superficial lungs: lateral view



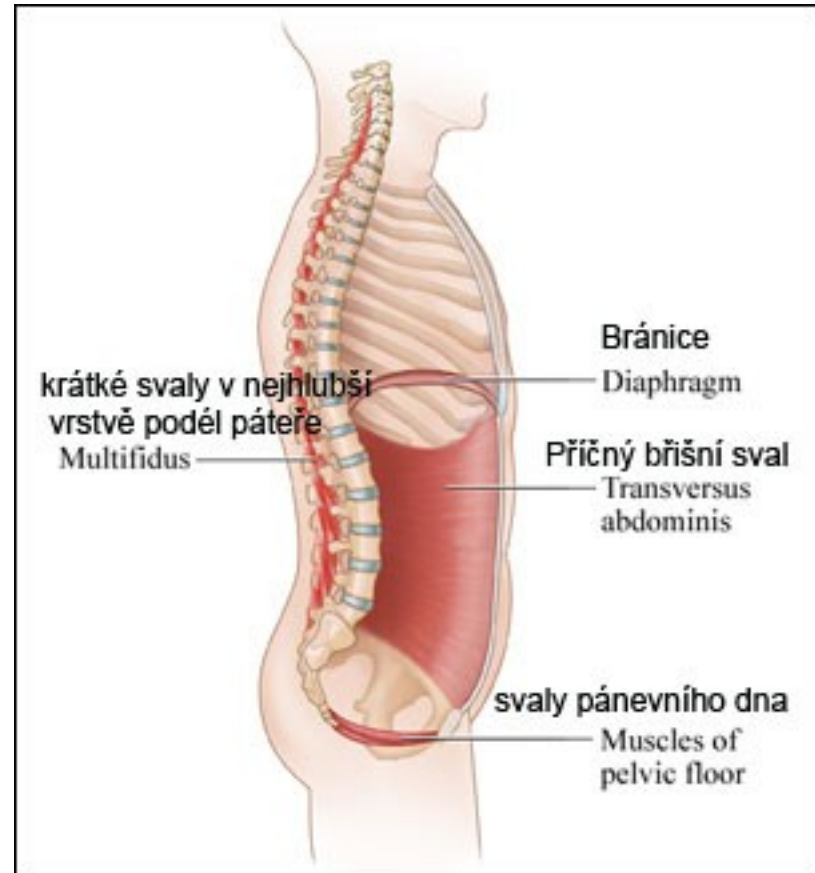
caput mandibulae

- Head of mandible



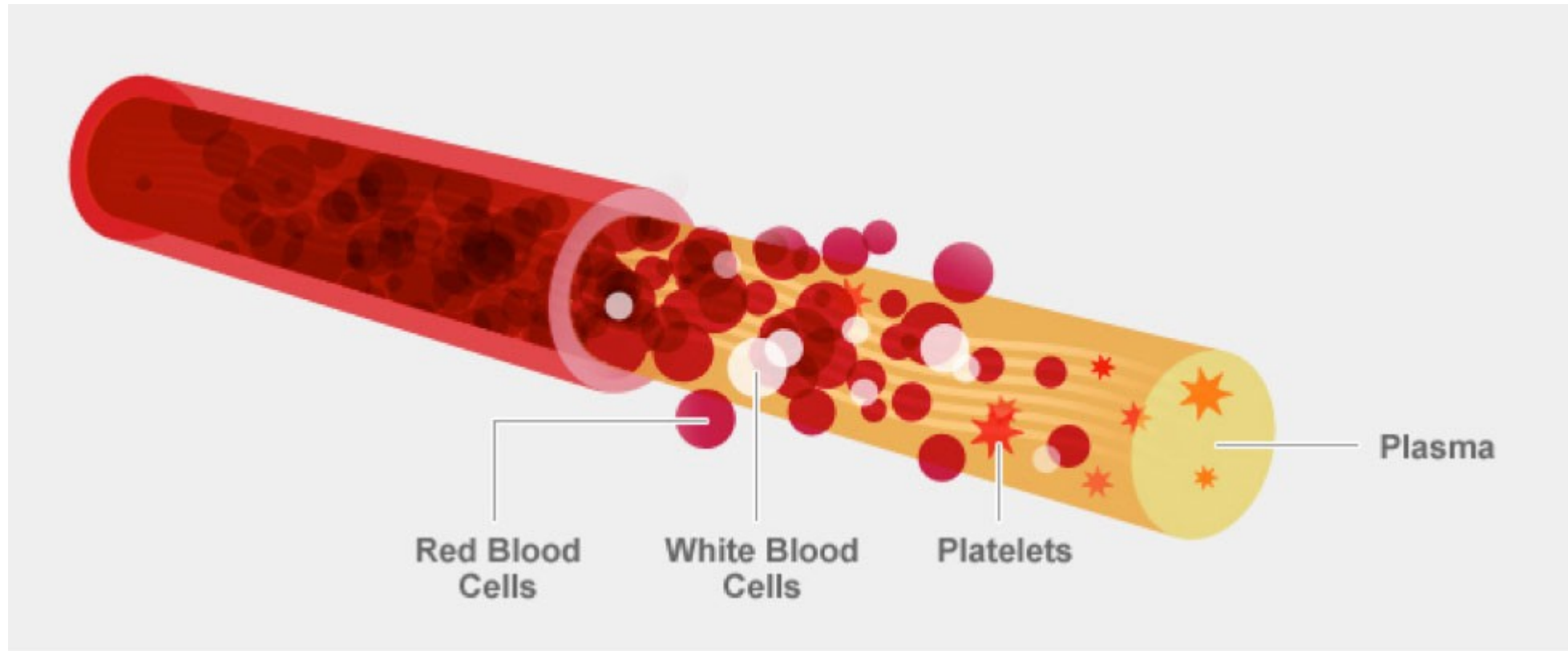
diaphragma pelvis

- The pelvic floor or pelvic diaphragm



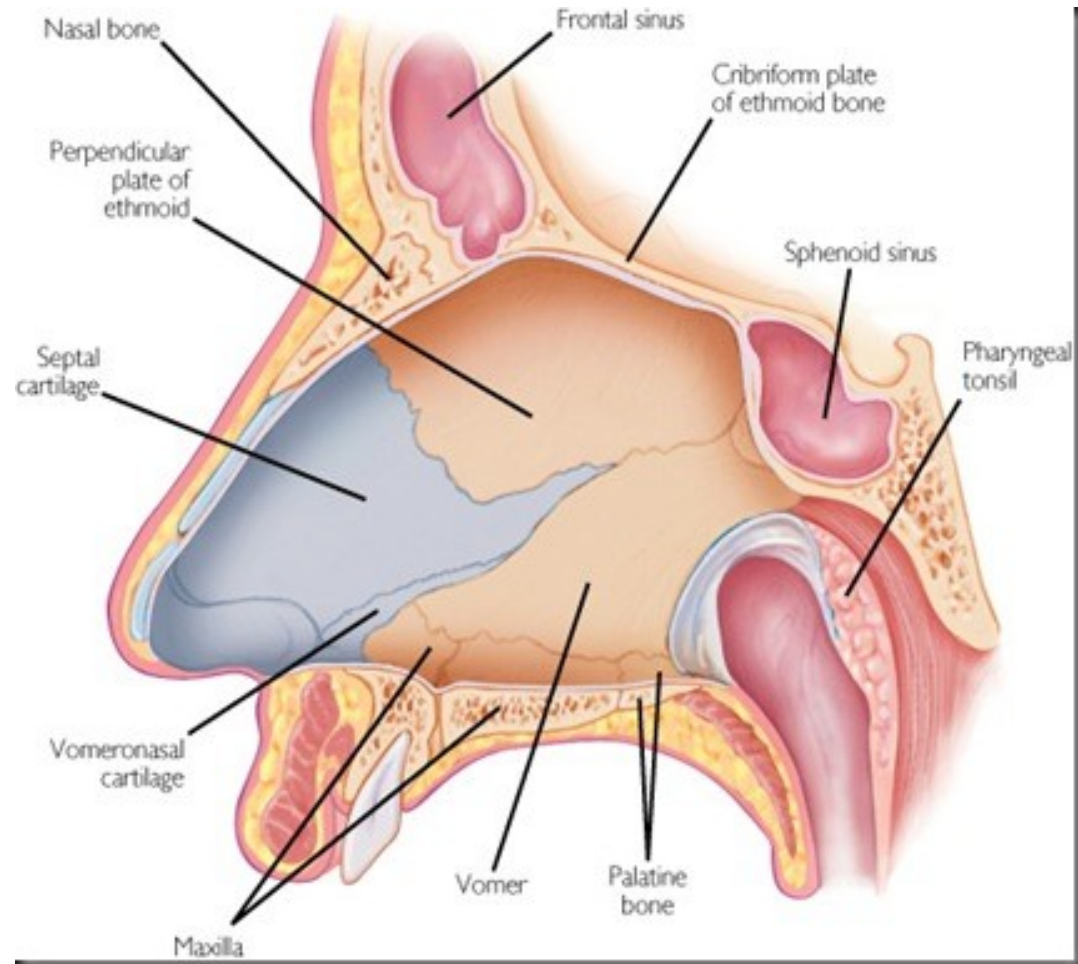
plasma sanguinis

- Blood plasma



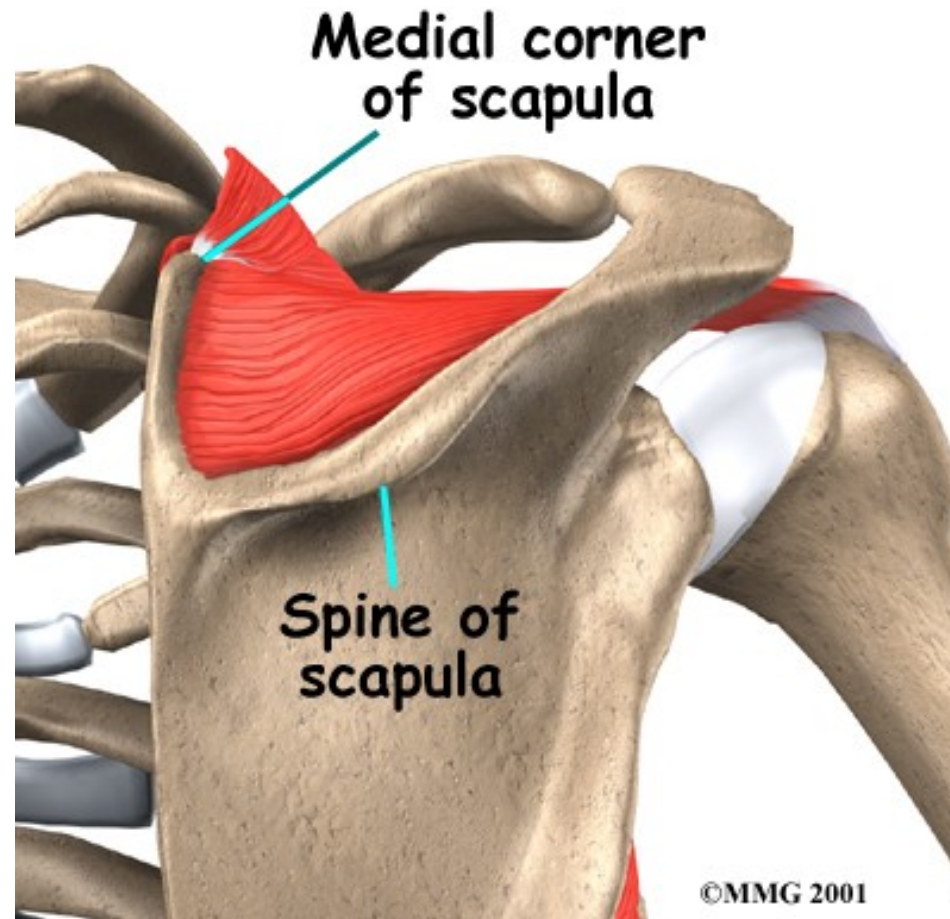
cartilago septi nasi

- Septal nasal cartilage



spina scapulae

- Spine of scapula

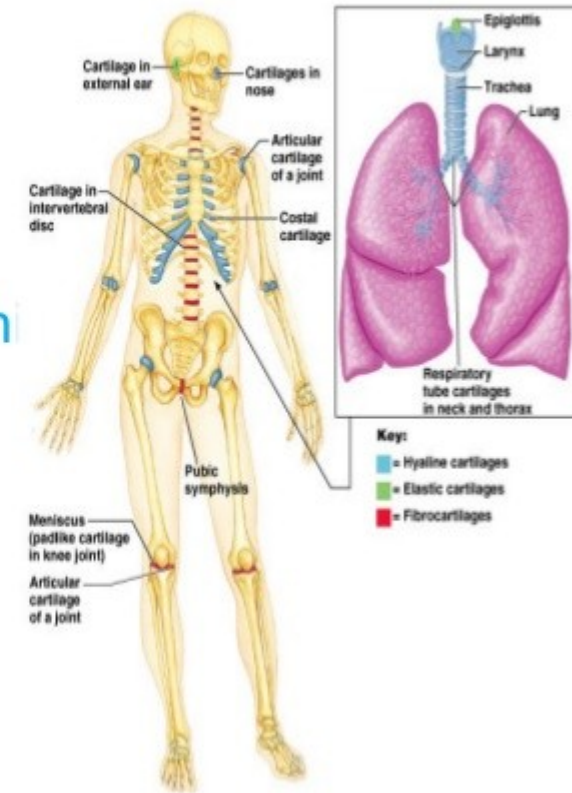


cartilago tubae

- Cartilage of tube

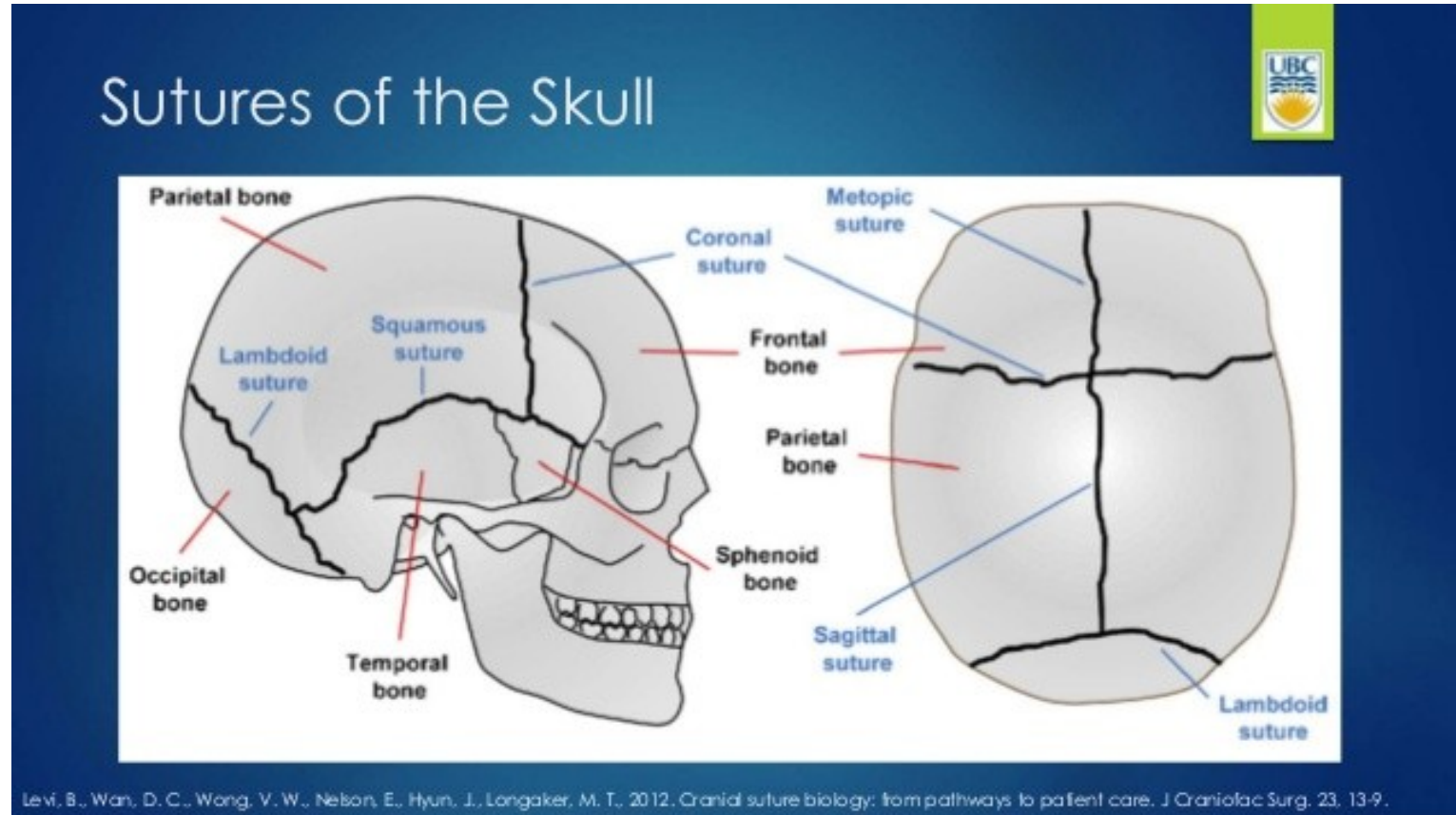
cartilage in adults

- Nose
 - Joint surfaces
 - Costal
 - Larynx - voice box
 - rings of trachea & bronch
-
- External ear
 - Epiglottis
 - Eustachian tube
-
- IVDs
 - Pubic symphysis
 - meniscus in knee joint



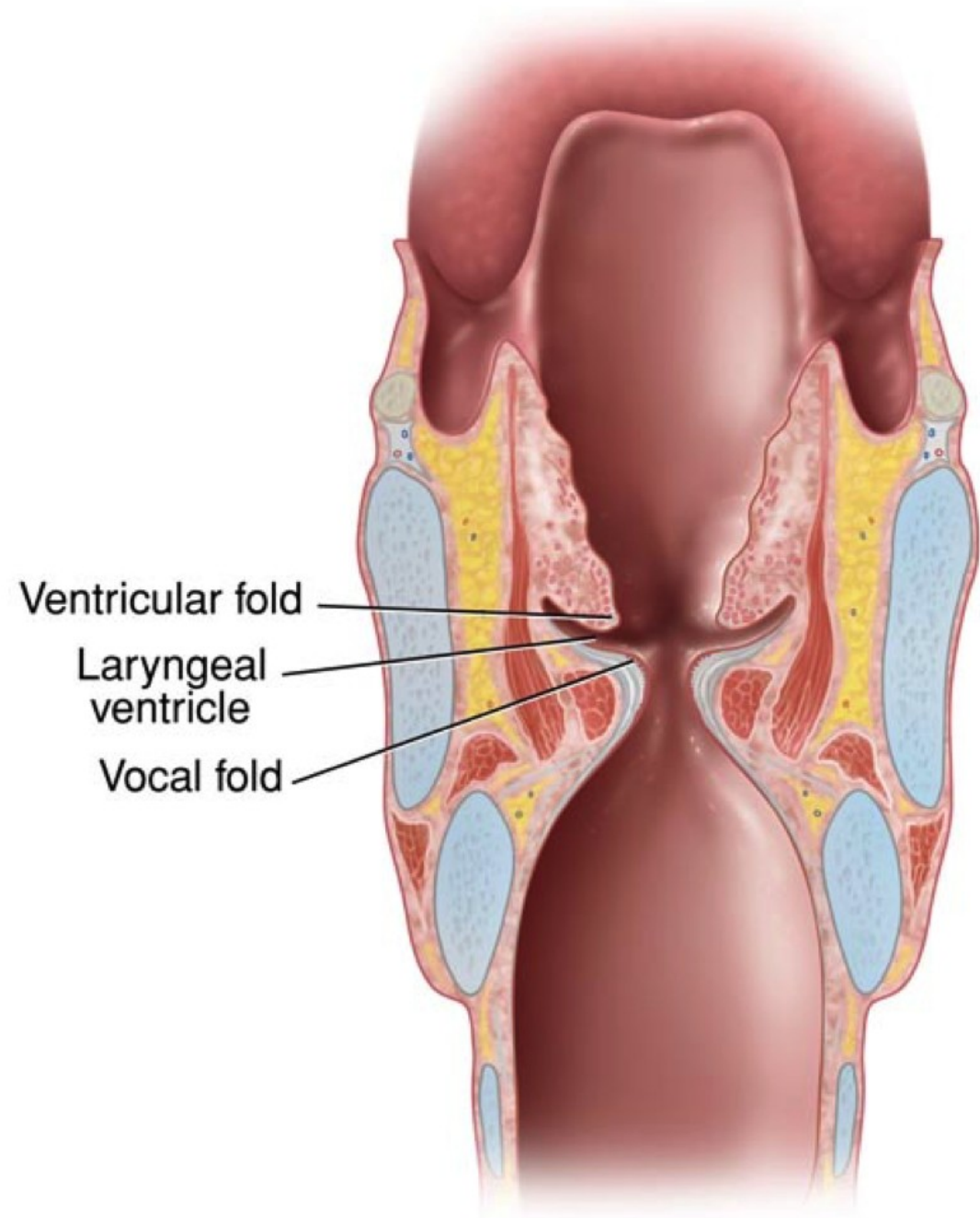
sutura cranii

- Sutures of skull



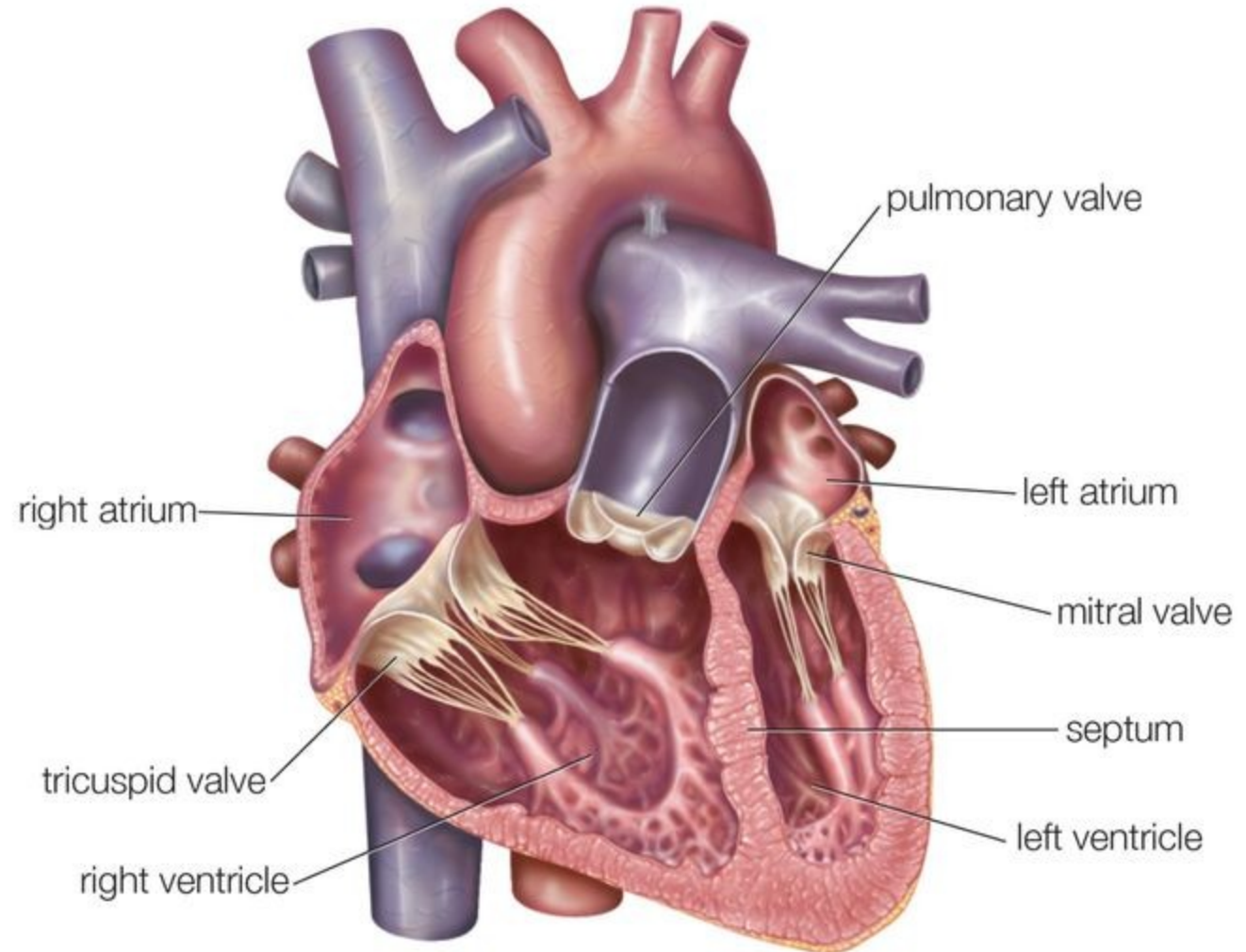
ventriculus laryngis

- Laryngeal ventricle



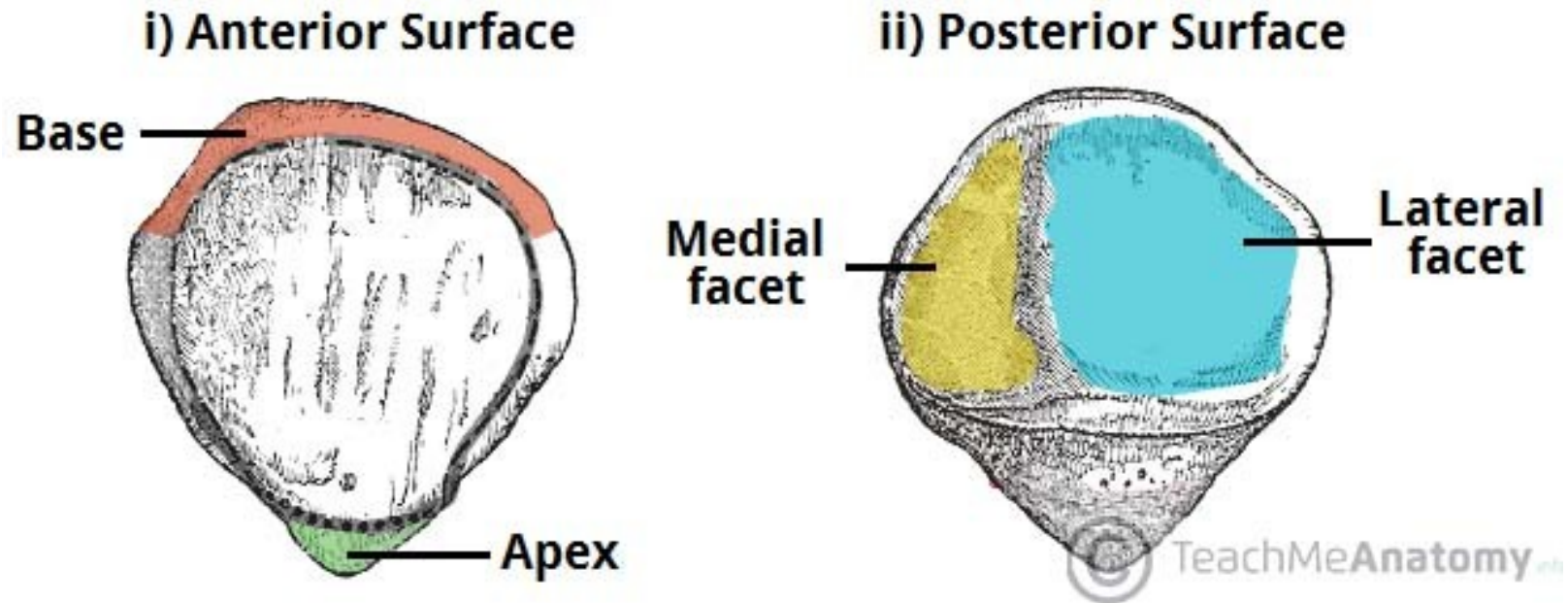
atrium cordis

- Atrium of heart



basis patellae

- Base of patella



Exercise 7. Translate anatomical terms into English

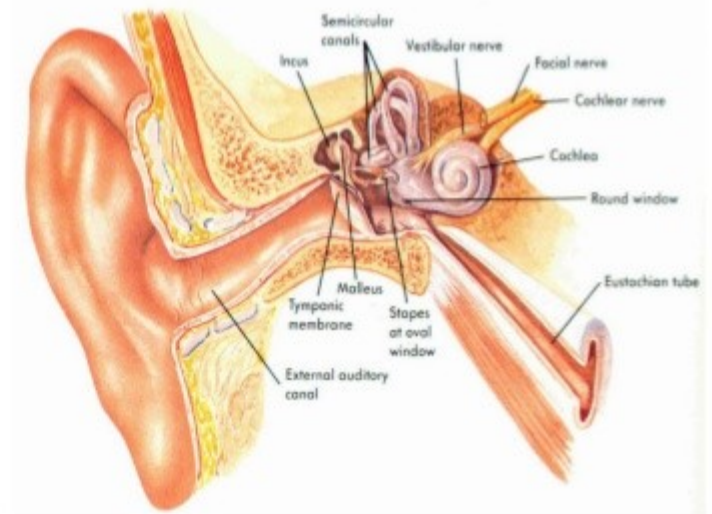
- *E.g.: Sulcus ethmoidalis ossis nasalis – ethmoidal sulcus of the nasal bone*

Pars cartilaginea tubae auditivae

- Cartilaginous part of auditory tube

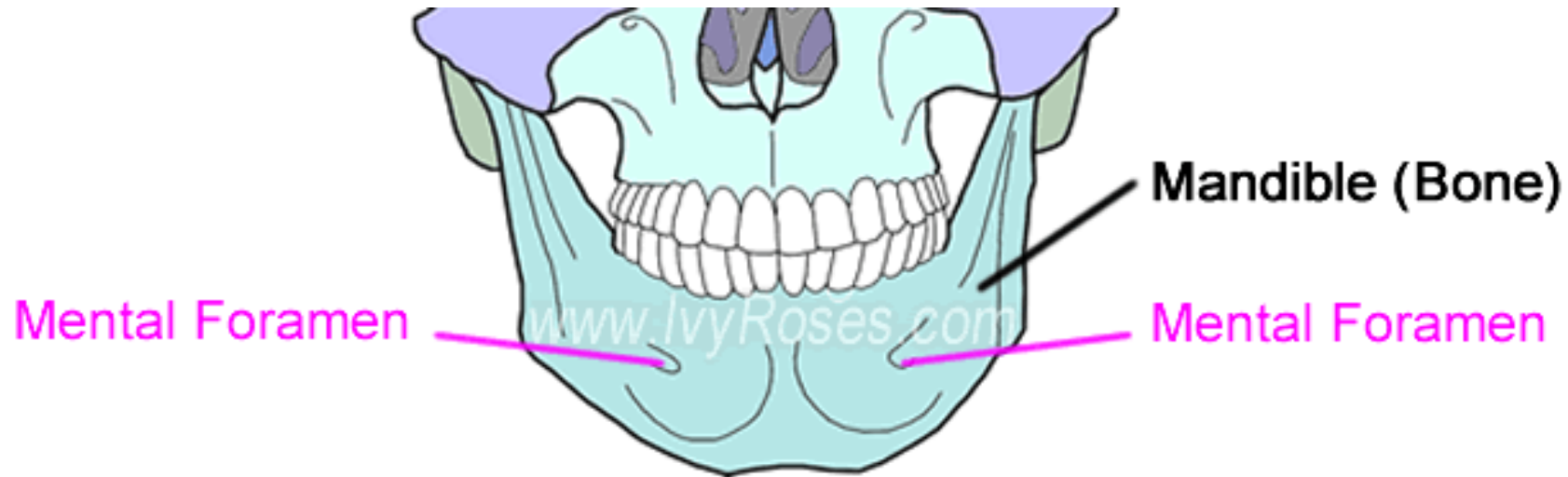
Auditory tube

- Pharyngo-tympanic tube or Eustachian tube
- Connects middle ear with nasopharynx
- Trumpet shaped
- 4cm long
- 2 parts :
 1. Bony part
 2. Cartilaginous part



foramen mentale

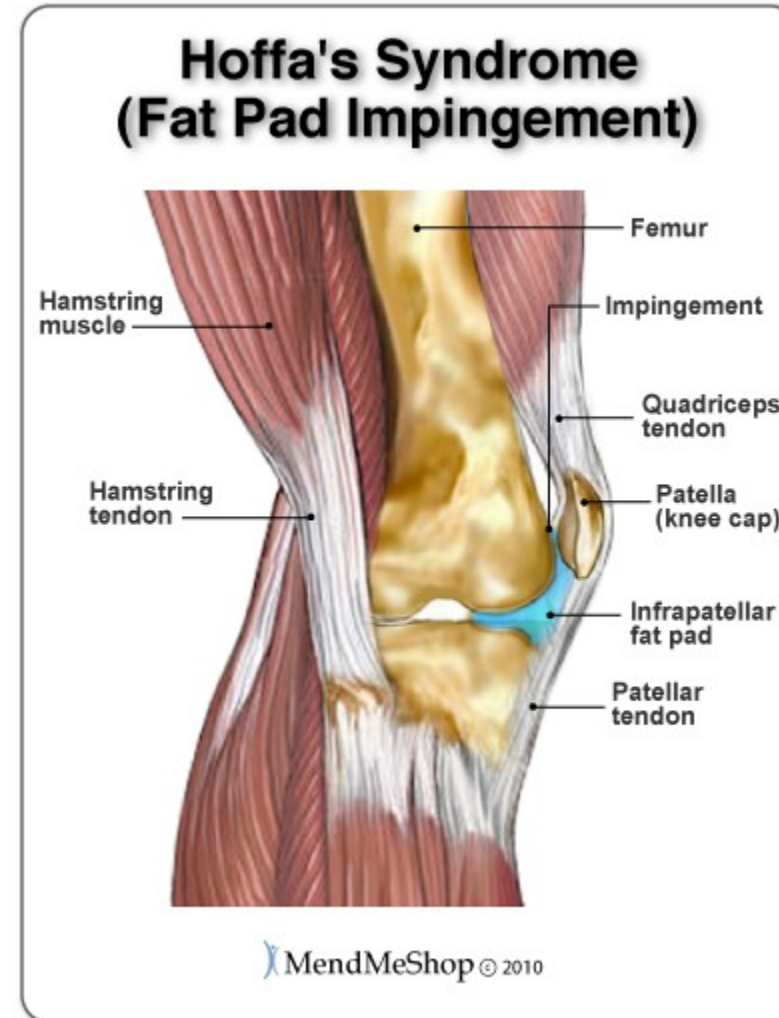
- Mental foramen



Above: Anterior View of the Mandible showing the approximate locations of the mental foramina

corpus adiposum infrapatellare

- Infrapatellar fat pad

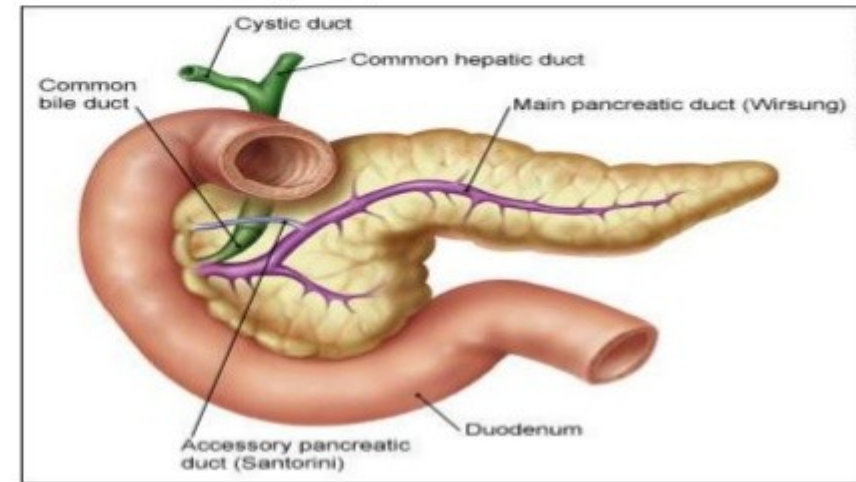


pancreas accessorium

- Accessory pancreas



- Accessory pancreatic duct (duct of Santorini) drains into duodenum through a separate minor papilla.
- In many adults, main pancreatic duct merges with common bile duct thus creating ampulla of Vater.

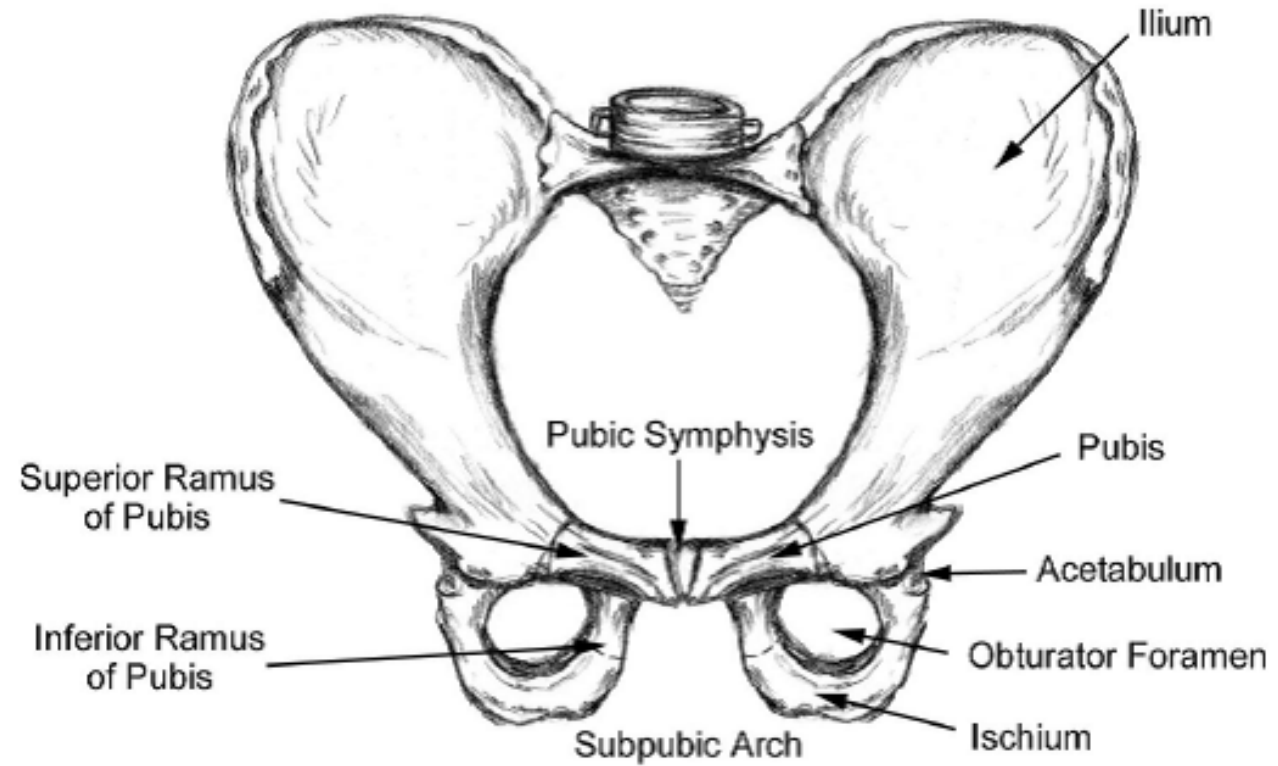


pars optica retinae

- Optic part of retina

symphysis pubica

- Pubic symphysis

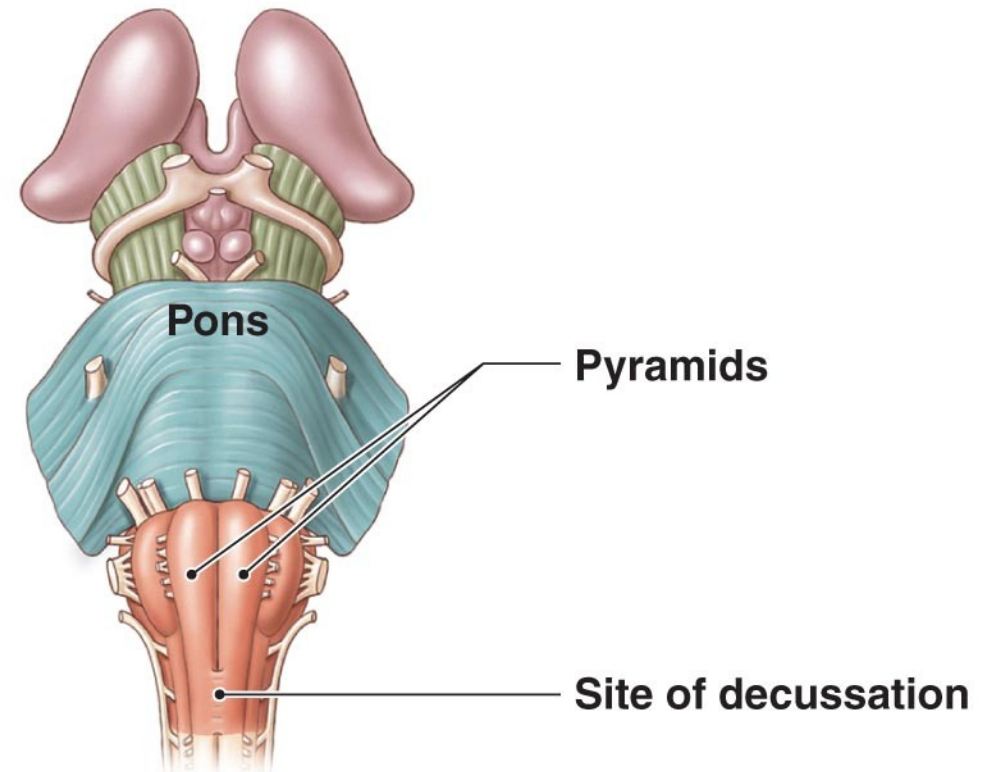


pyramis medullae oblongatae

- Pyramid of medulla oblongata

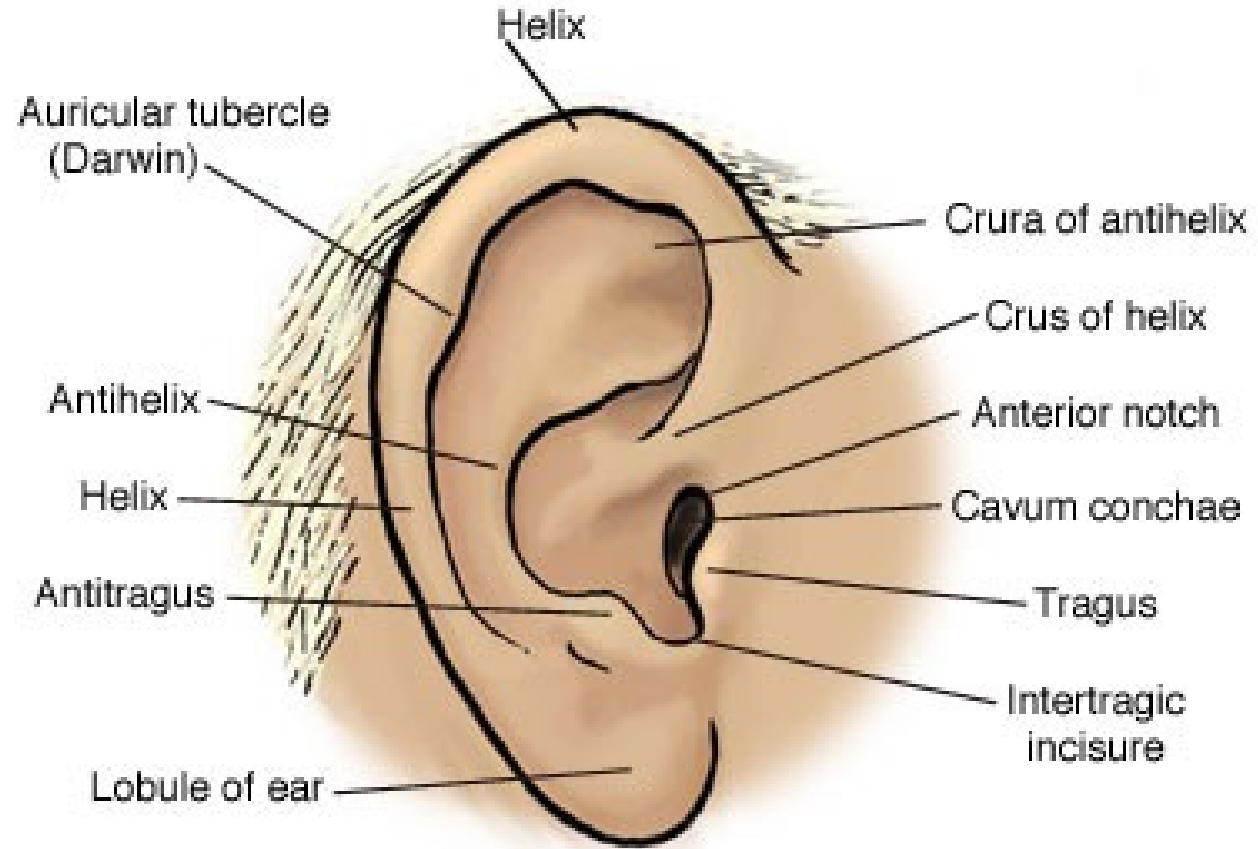
Structure of the medulla oblongata

The anterior surface of the medulla oblongata



auris externa

- External ear

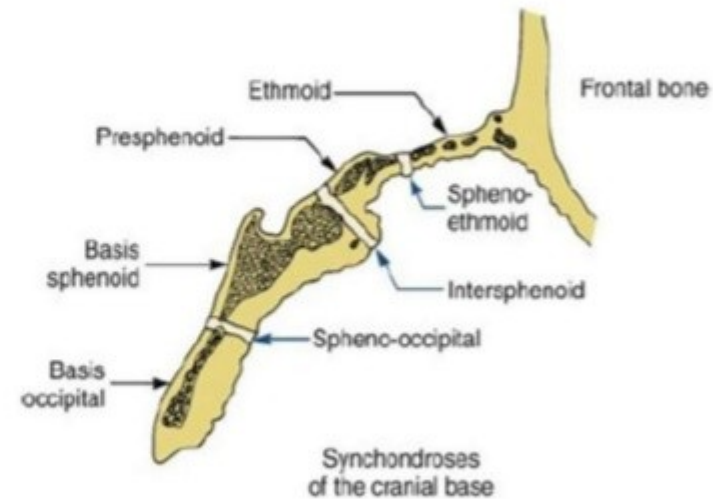


synchondrosis sphenoccipitalis

- Spheno-occipital synchondrosis

SYNCHONDROSES

- Cranial base(midline)
 1. fronto-ethmoidal synchondrosis
 2. spheno-frontal synchondrosis
 3. spheno-ethmoidal synchondrosis.(3-5yrs)
 4. intersphenoid synchondrosis (birth fused)
 5. spheno-occipital synchondrosis(12-15yr)
(principle growth cartilage of basicranium)

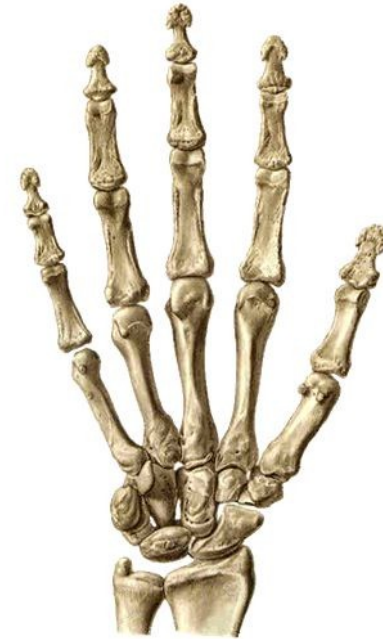

tuberositas phalangis distalis

- Tuberosity of distal phalanx

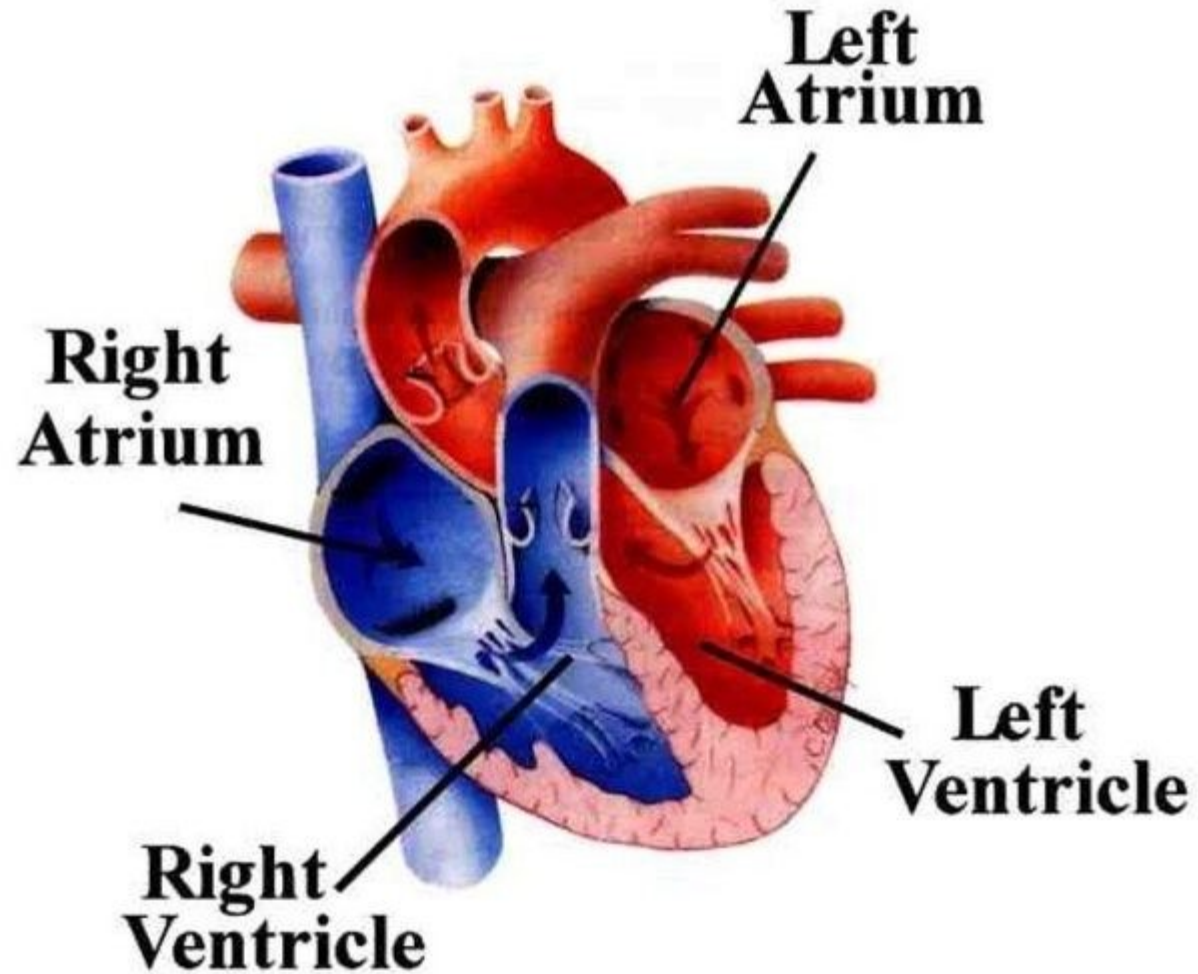
Phalanges of fingers

- Consist of 14 —two for first digit (thumb) and three for each of other four digits
- **Structure of each**
 - base (proximally)
 - Shaft
 - trochlea of phalanx (distally)
 - tuberosity of distal phalanx



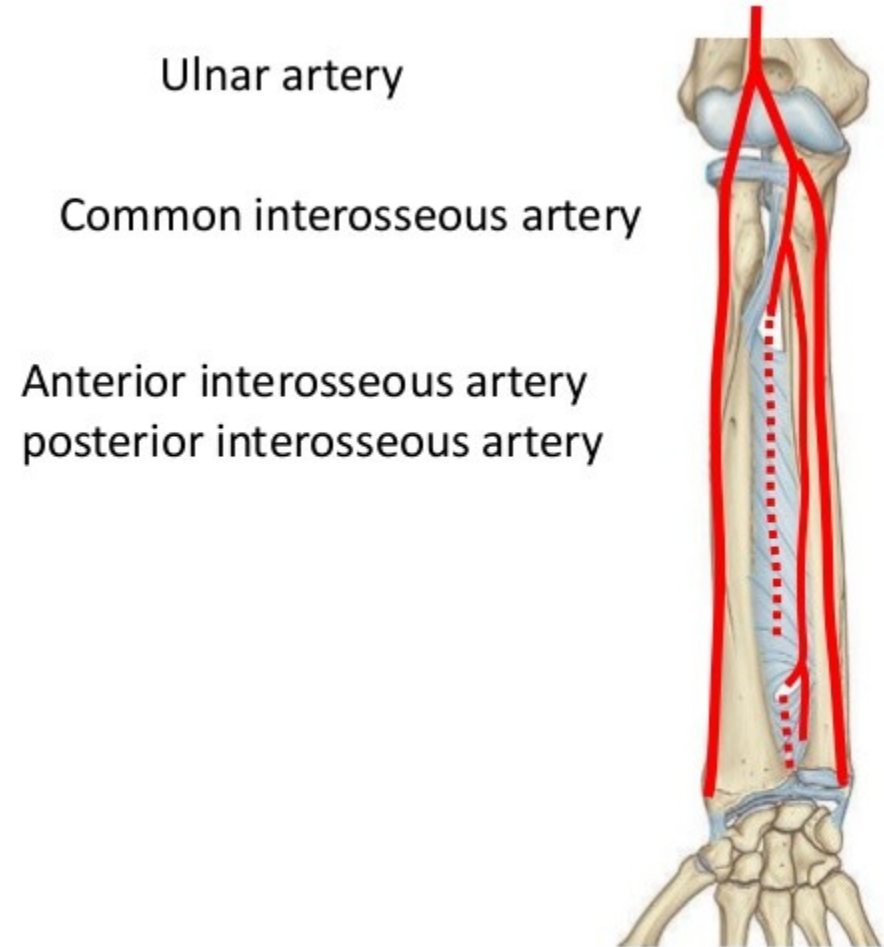
ventriculus sinister cordis

- Left ventricle



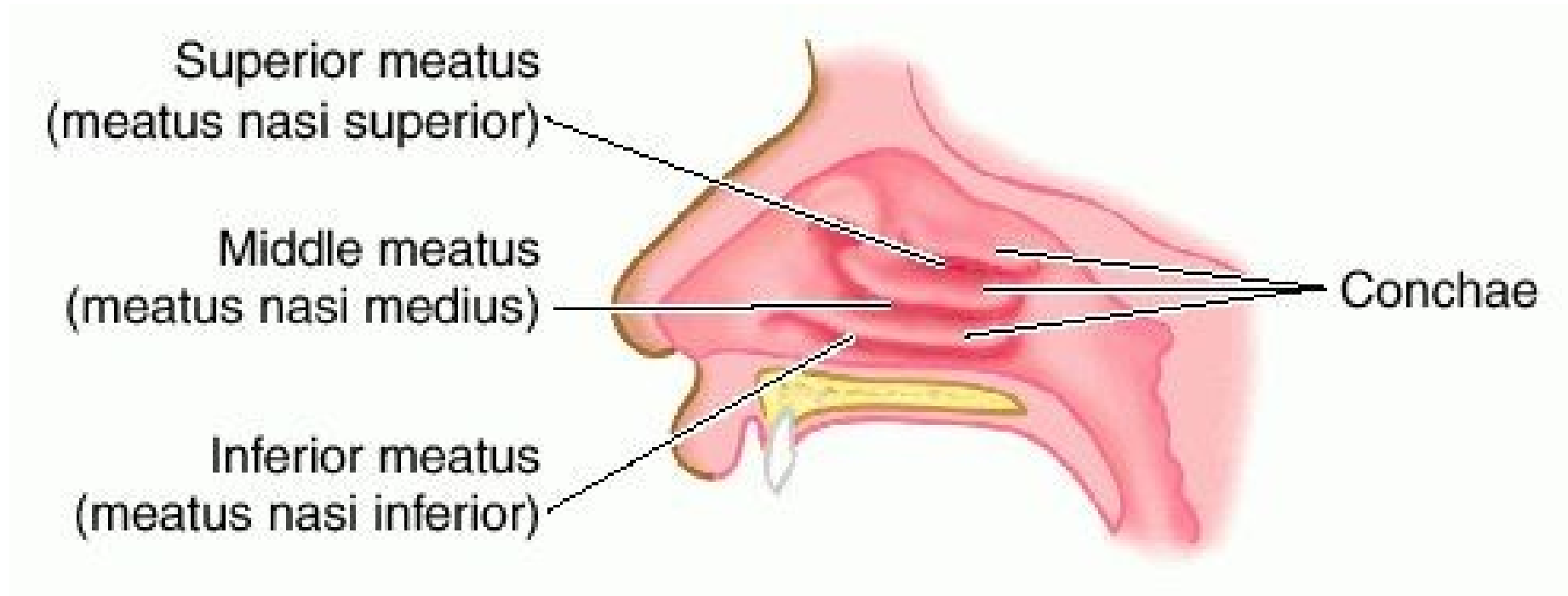
arteria interossea communis

- Common interosseous artery



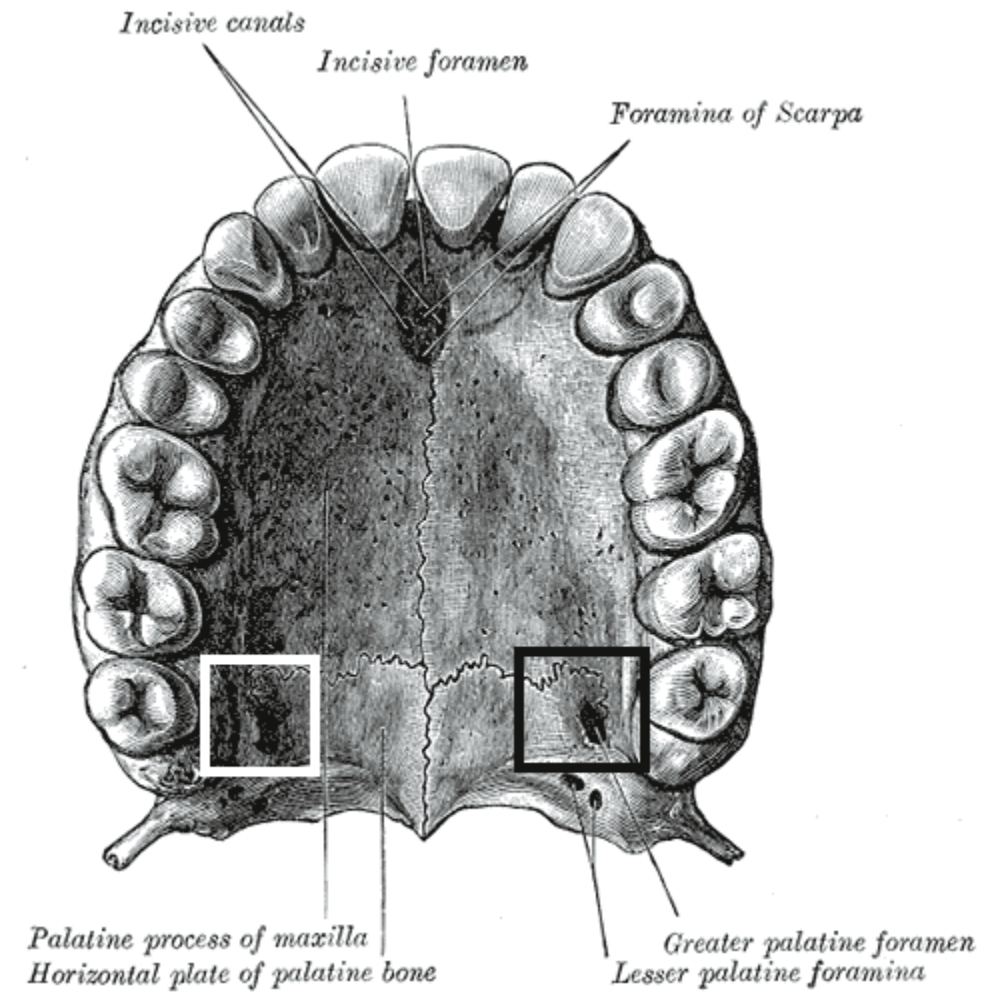
Meatus nasi inferior

- Inferior nasal meatus



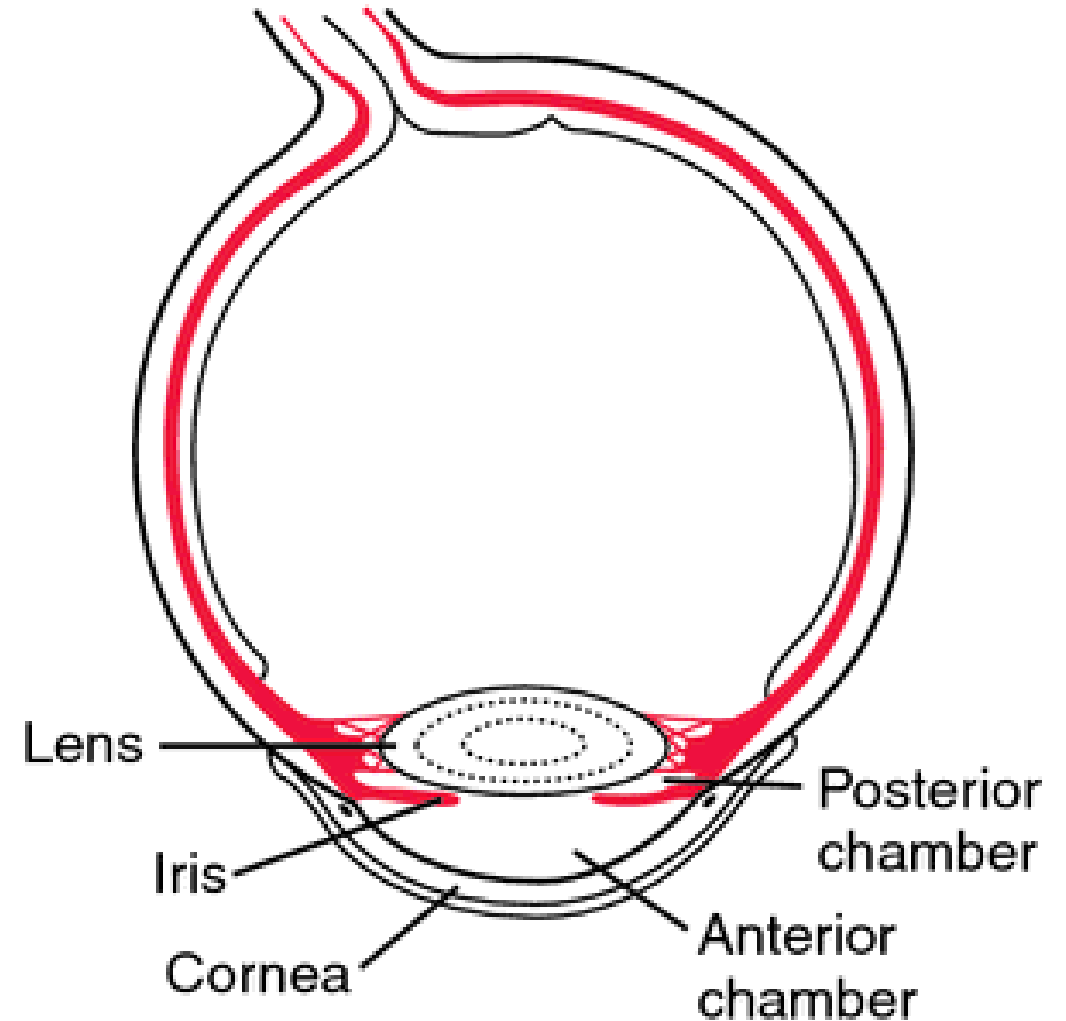
Foramen palatinum minus

- Lesser palatine foramen



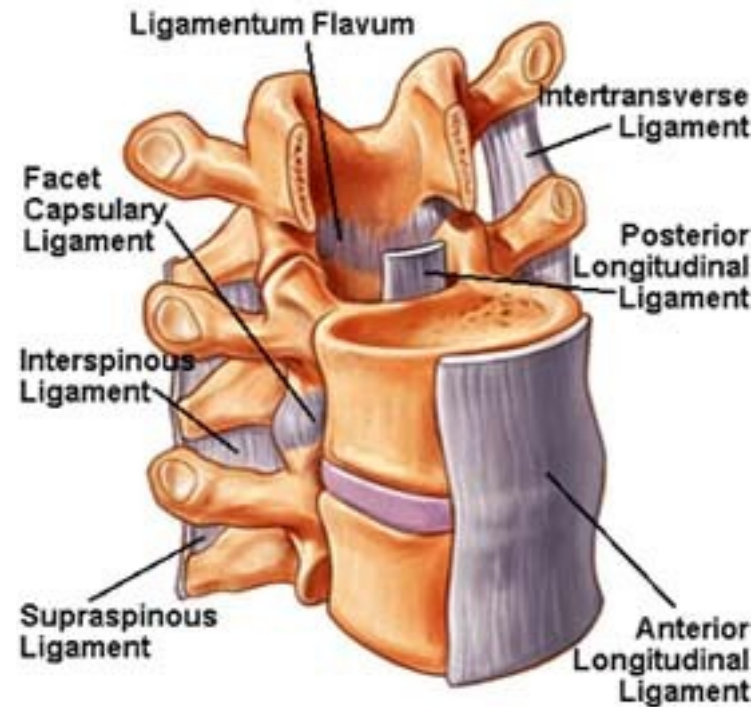
Camera anterior bulbi oculi

- Anterior chamber of the eyeball



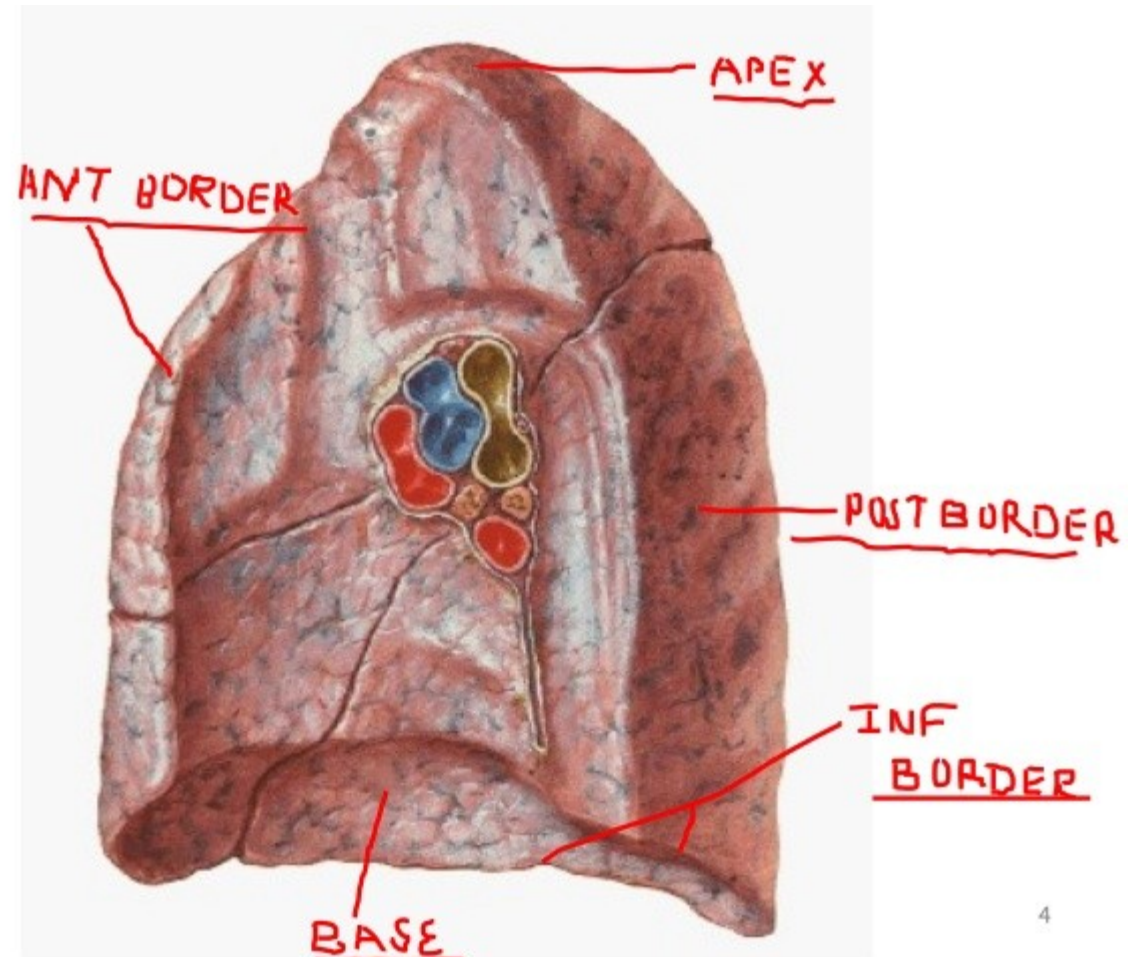
Ligamentum longitudoale anterius columnae vertebralis

- Anterior longitudinal ligament of the vertebral column



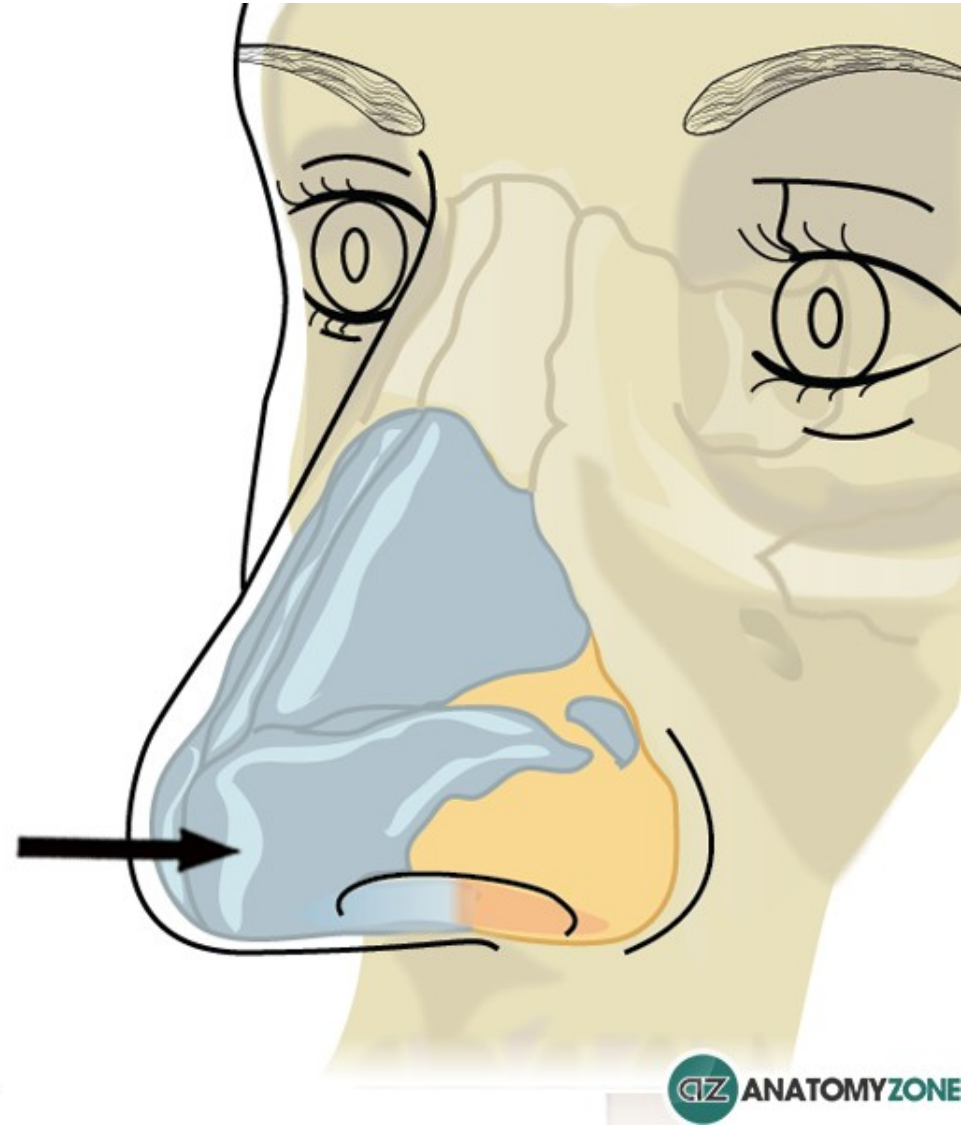
Margo inferior pulmonis sinistri

- Inferior border of the left lung



Cartilago alaris maior

- Major alar cartilage



Facies posterior lentis

- Posterior surface

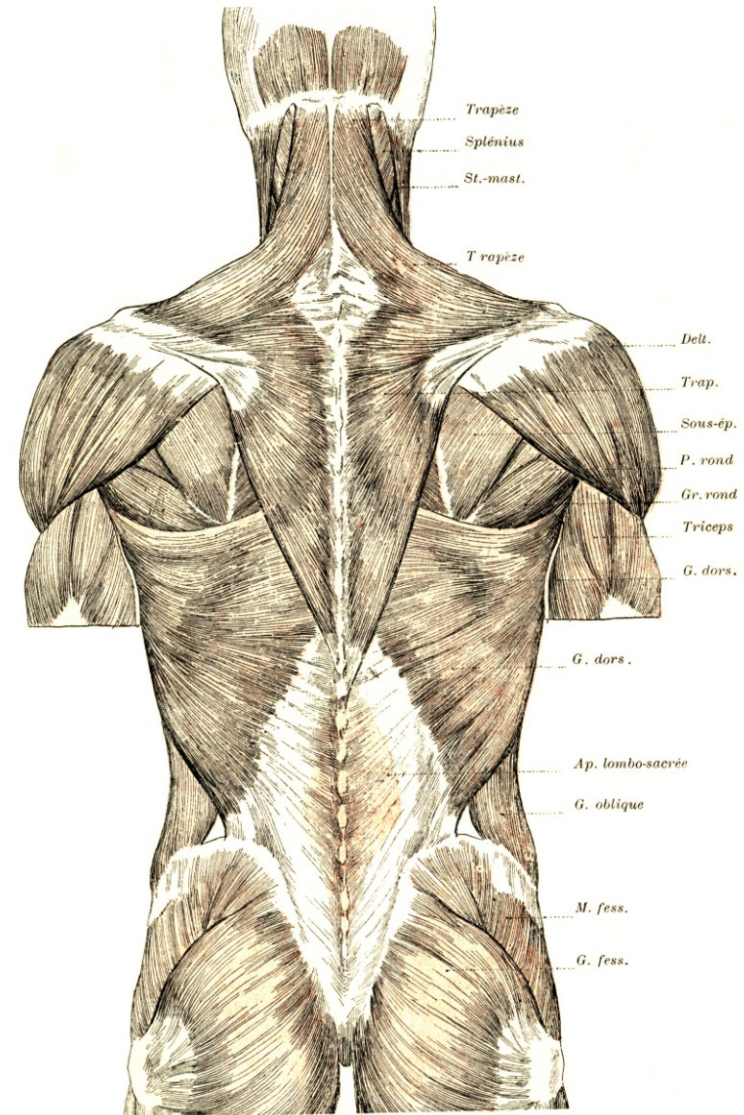
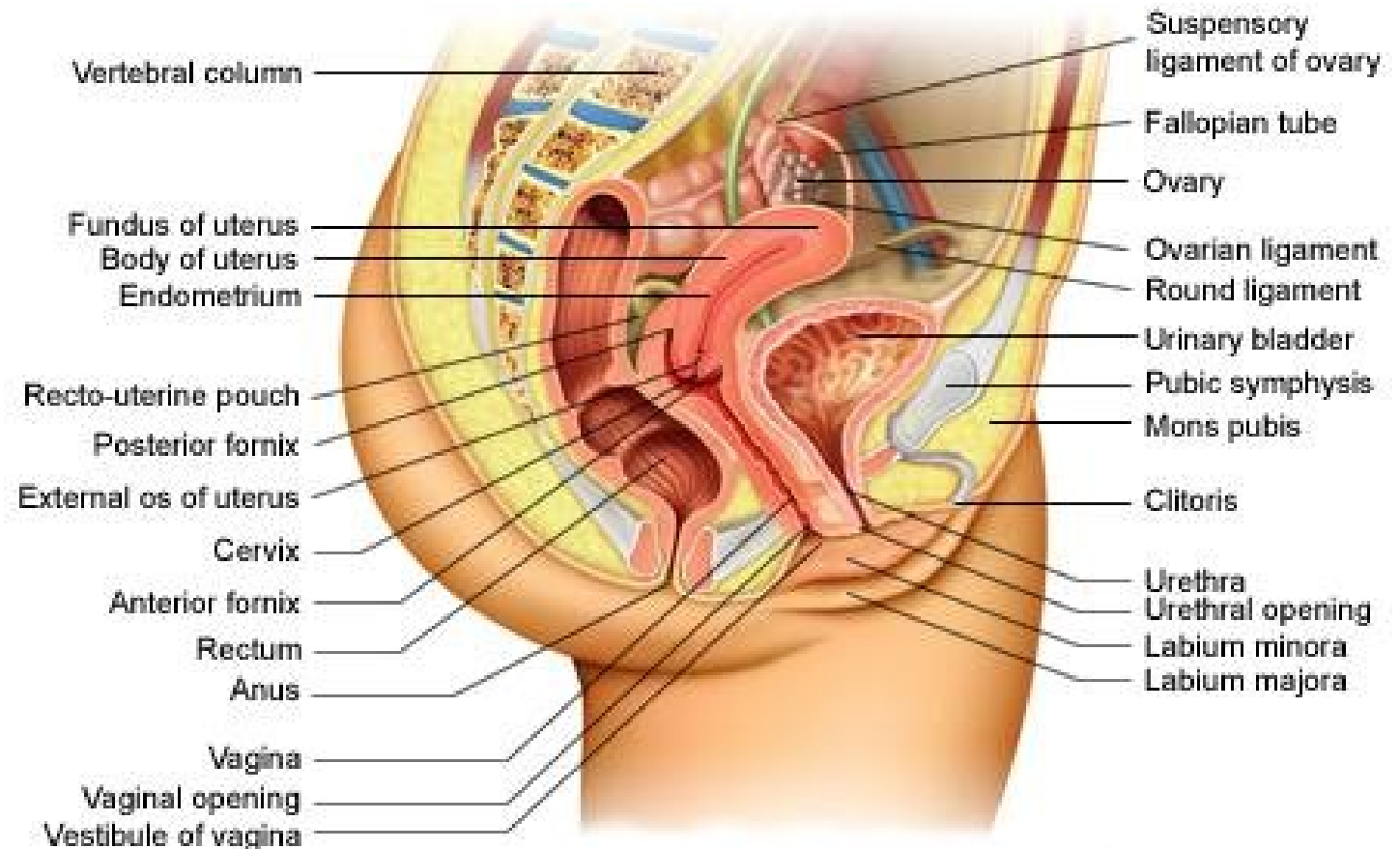


FIG. 309. — Muscles de la face postérieure du tronc (couche superficielle).

Regio cervicis anterior

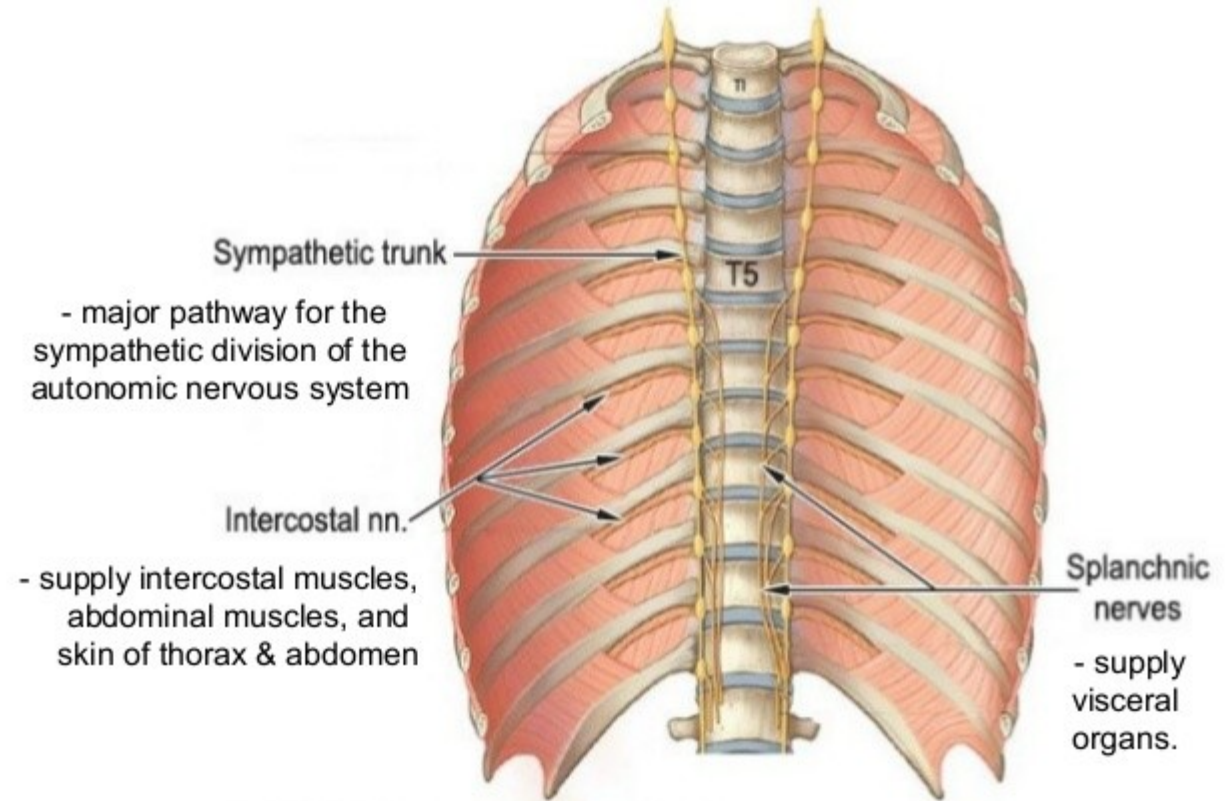
- Anterior cervix region



Regio thoracis posterior

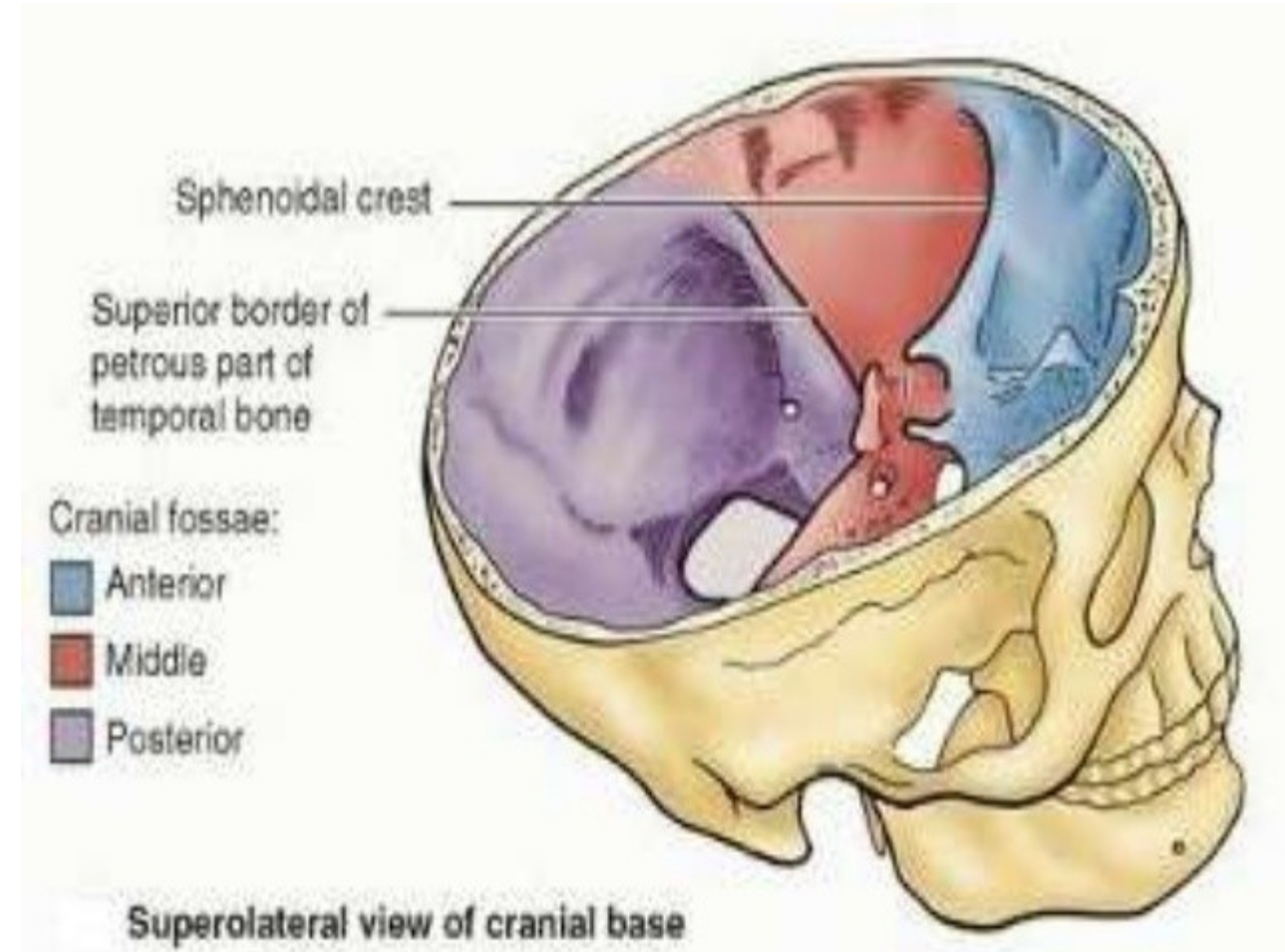
- Posterior thorax region

Nerves of the Posterior Thoracic Wall



Margo superior partis petrosae

- Superior border of petrous part



Crus anterius capsulae internae

- Anterior limb of internal capsule

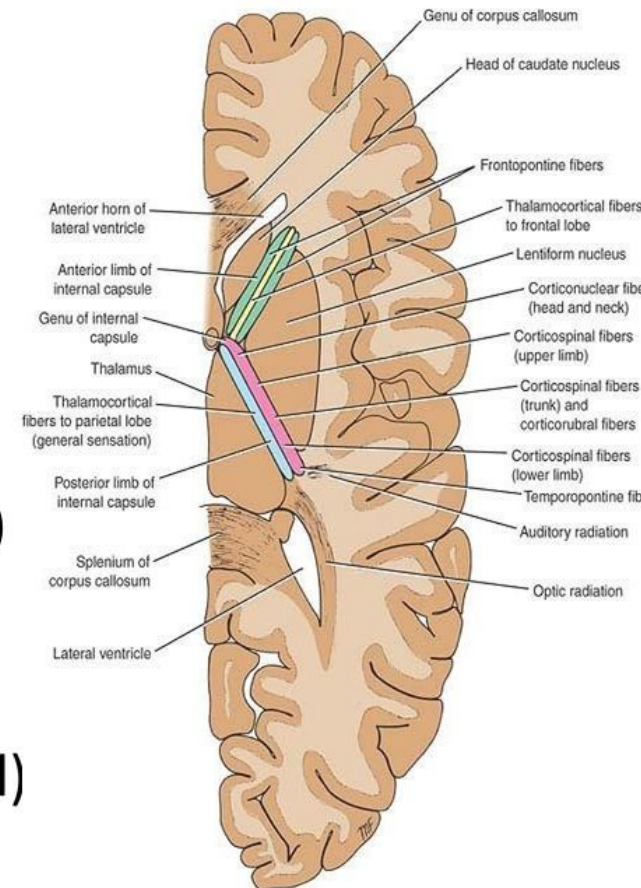
Anterior limb:

- **Site:** between head of caudate nucleus & lentiform nucleus

- **Contents:**

1. Fibres from anterior nuclear group of thalamus to cingulate gyrus (Thalamocortical)
2. Fibres from medial nuclear group of thalamus to prefrontal cortex (Thalamocortical)
3. Frontopontine fibres

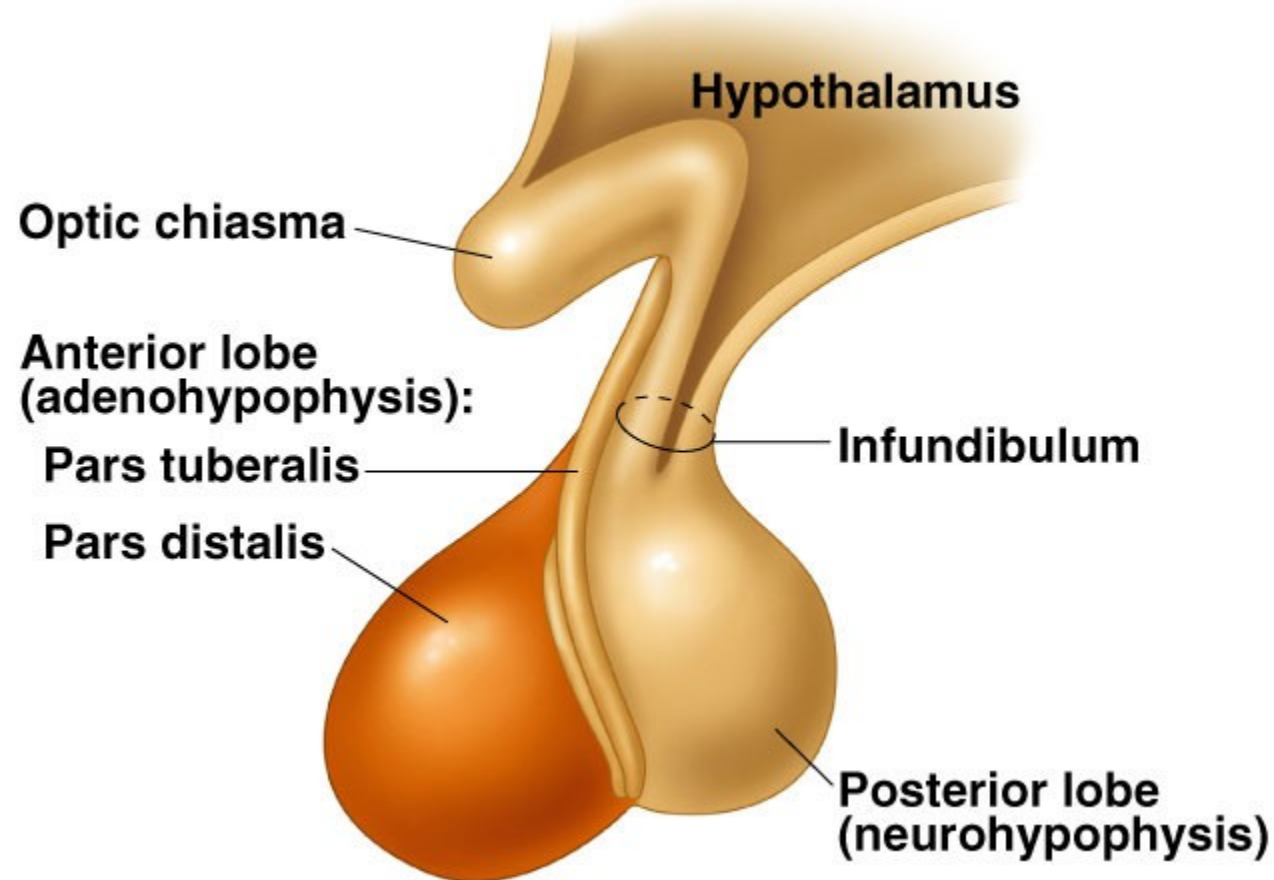
INTERNAL CAPSULE



Lobus anterior hypophysis

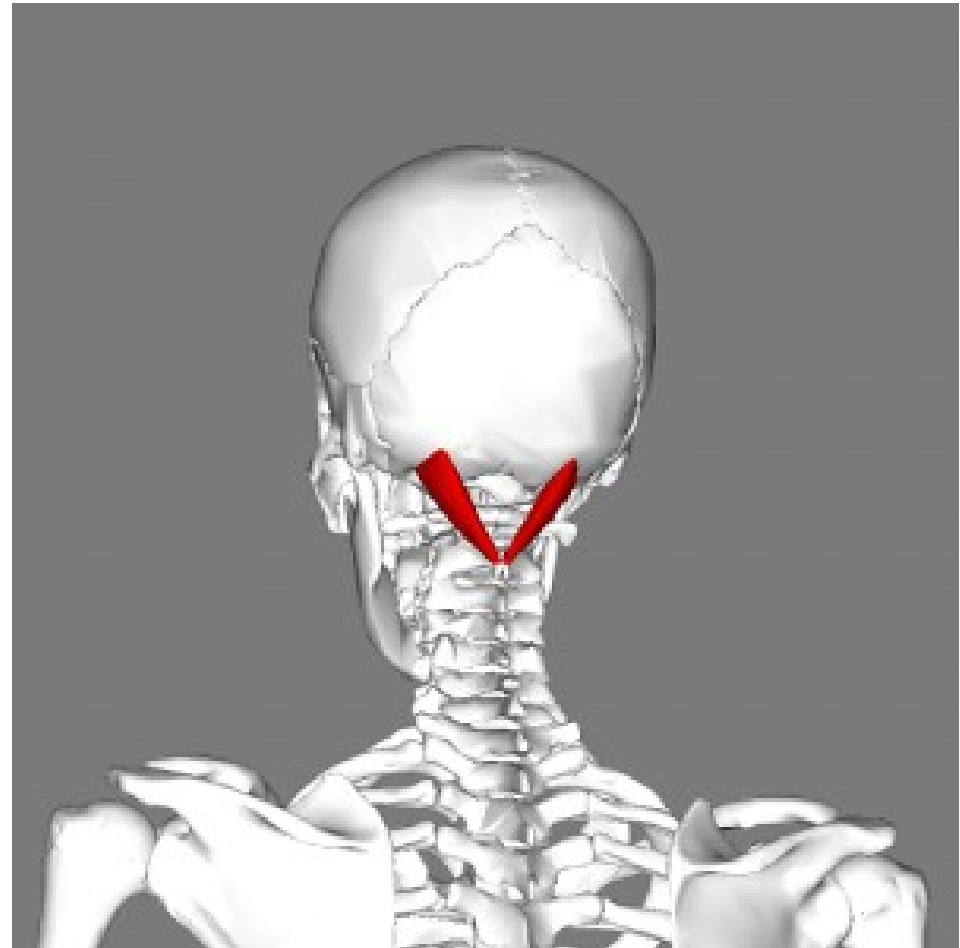
- Adenohypophysis; Anterior lobe

Copyright © The McGraw-Hill Companies, Inc. Permission required for reproduction or display.



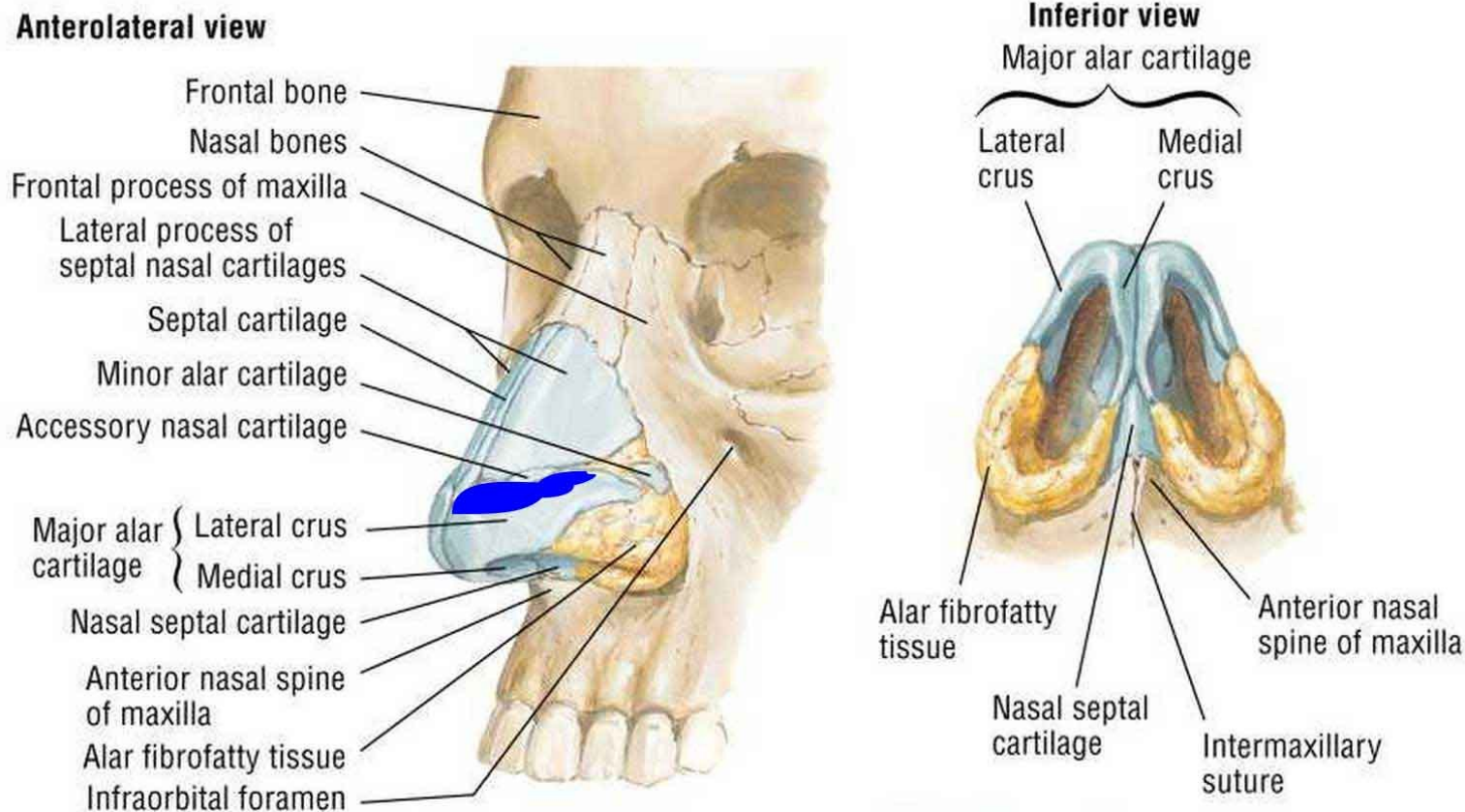
Musculus rectus capitis posterior maior

- Rectus capitis posterior major



Crus mediale cartilaginis alatis maioris

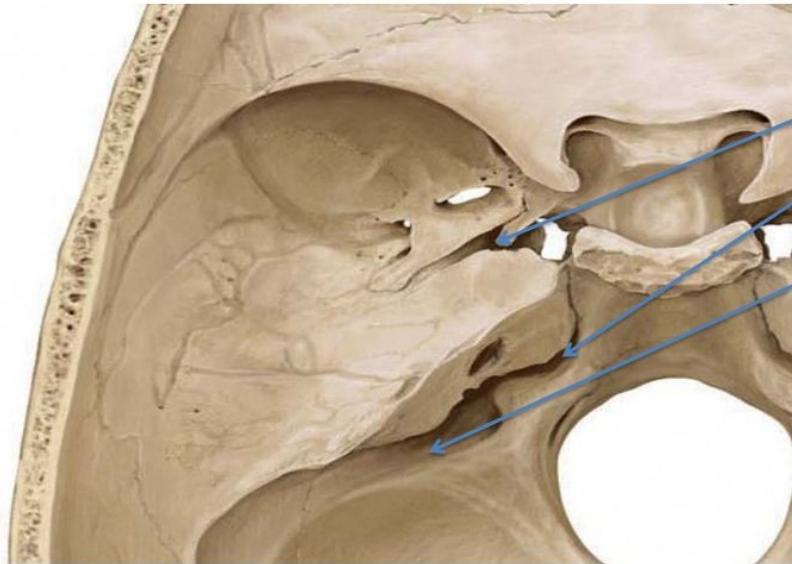
- Medial crus of the major alar cartilage



Hiatus canalis nervi petrosi maioris

- Hiatus for greater petrosal nerve


Middle Cranial Fossa

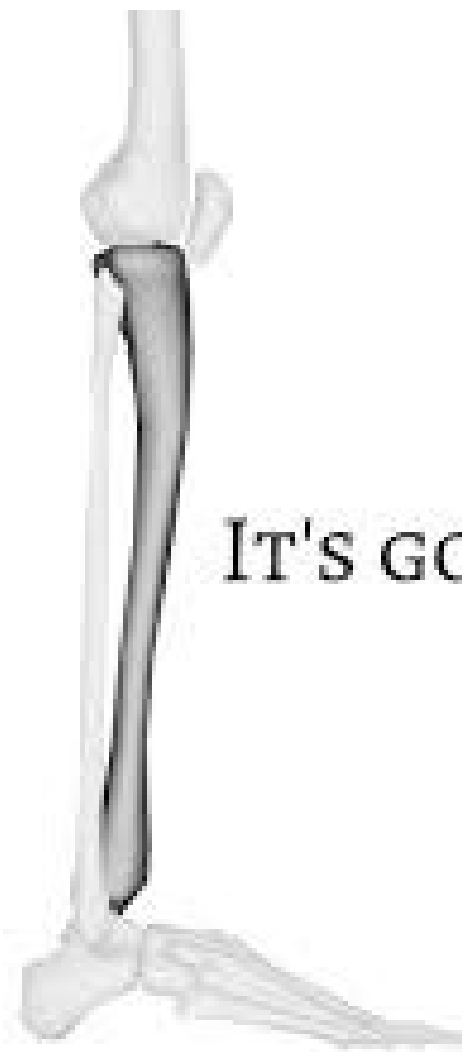

- Carotid groove
- Hiatus for greater petrosal nerve
- Hiatus for lesser petrosal nerve



**I found
this
humerus**





IT'S GOING **TIBIA** OK.