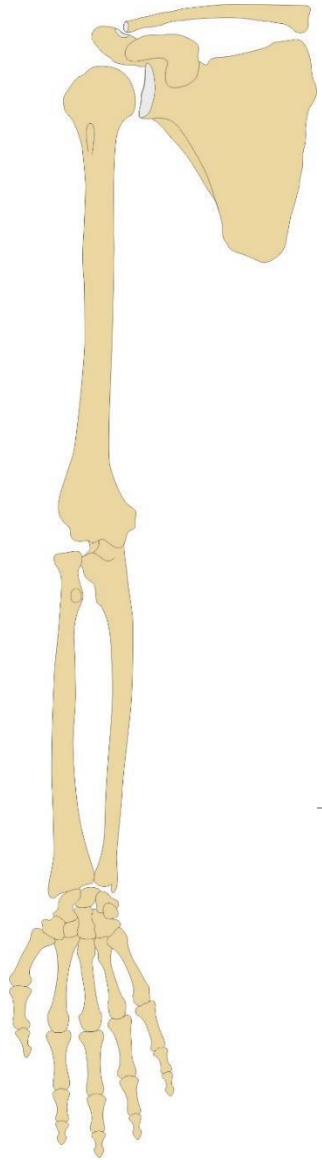

# SKELETON OF THE UPPER LIMB

---

LECTURE 2

DENTISTRY 2017

RNDR. MICHAELA RAČANSKÁ, PH.D.

# Skeleton of the upper limb (*ossa membri superioris*)

Thirty-four bones form the skeletal framework of each upper limb

---

## I. Shoulder girdle (*cingulum membri superioris*)

Collar bone, clavicle – *clavicula*

Shoulder blade – *scapula*

## II. Bones of free part of the upper limb (*ossa membri superioris liberi*)

Arm bone – humerus

Radius – *radius*

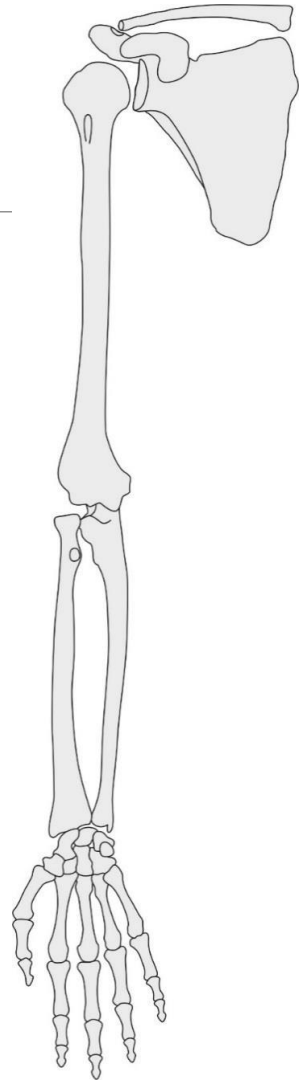
Ulna – ulna

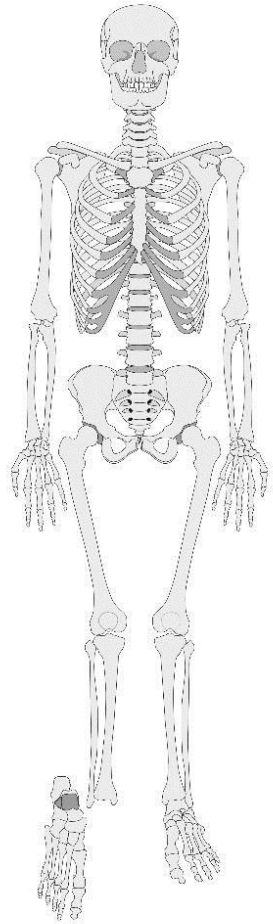
Carpal bones – *ossa carpi* 8

Metacarpal bones – *ossa metacarpi* 5

Phalanges, hand digits – *ossa digitorum manus* 14

*Sesamoid* - 2





# Clavicula (collar bone)

---

Connects upper limb with the trunk

Connection with the shoulder blade

Connection with the breast bone

# Clavicula (collar bone)



Medial end (sternal end)

**extremitas sternalis** (facies articularis sternalis) sternal articular facet  
tuberositas costalis Costal tuberosity (impressio ligamenti  
costoclavicularis) (impression for costoclavicular ligament)

Lateral (acromial) end

**extremitas acromialis** (facies articularis acromialis)  
tuberositas coracoidea (tuberculum conoideum et linea trapezoidea)  
conoid tubercle + trapezoid line

**Side orientation**



Sternal end

Left one –superior view

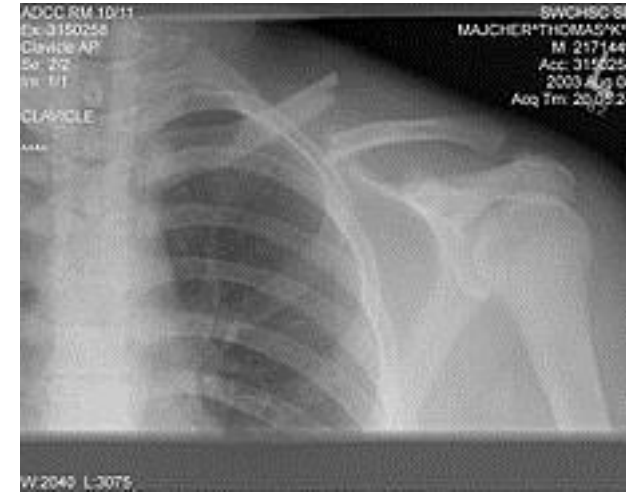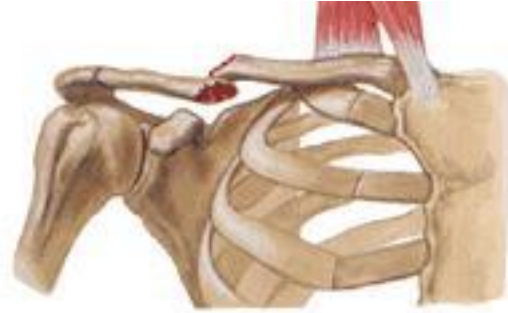acromial end



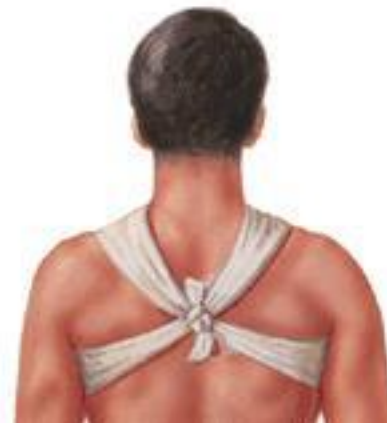Left one –inferior view

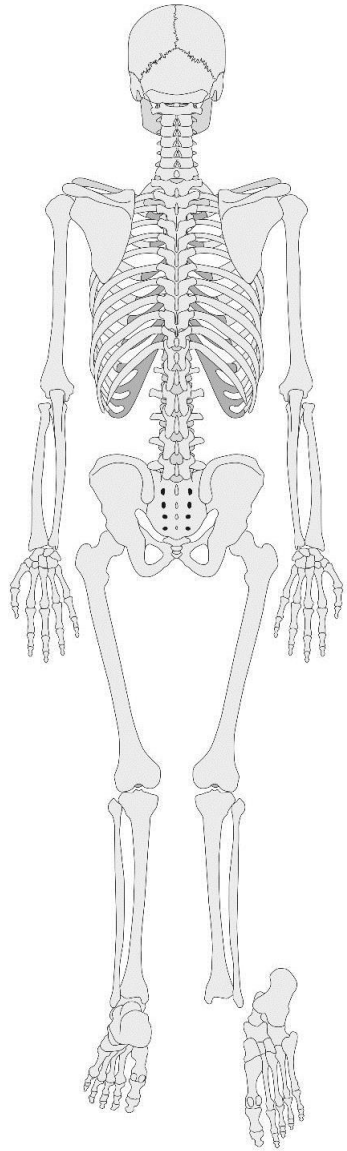
# Fracture of the collar bone

X-ray of a left clavicle fracture



[https://en.wikipedia.org/wiki/Clavicle\\_fracture](https://en.wikipedia.org/wiki/Clavicle_fracture)






# Scapula

Connection to humerus, clavicle

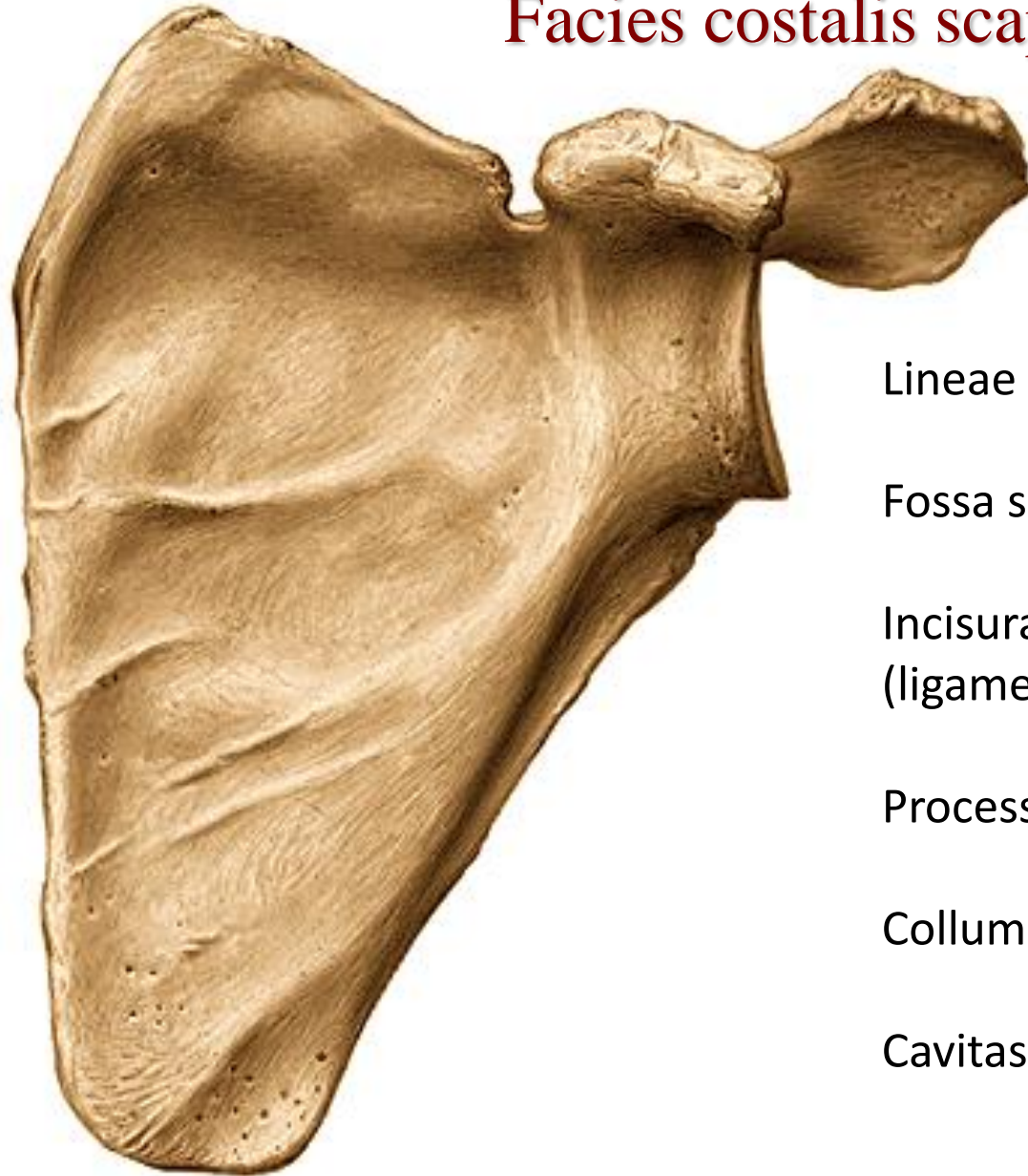
Margo: superior  
medialis  
lateralis

angulus: superior, inferior, lateralis

facies: costalis, dorsalis



## Facies costalis scapulae



Lineae musculares (transverae)

Fossa subscapularis

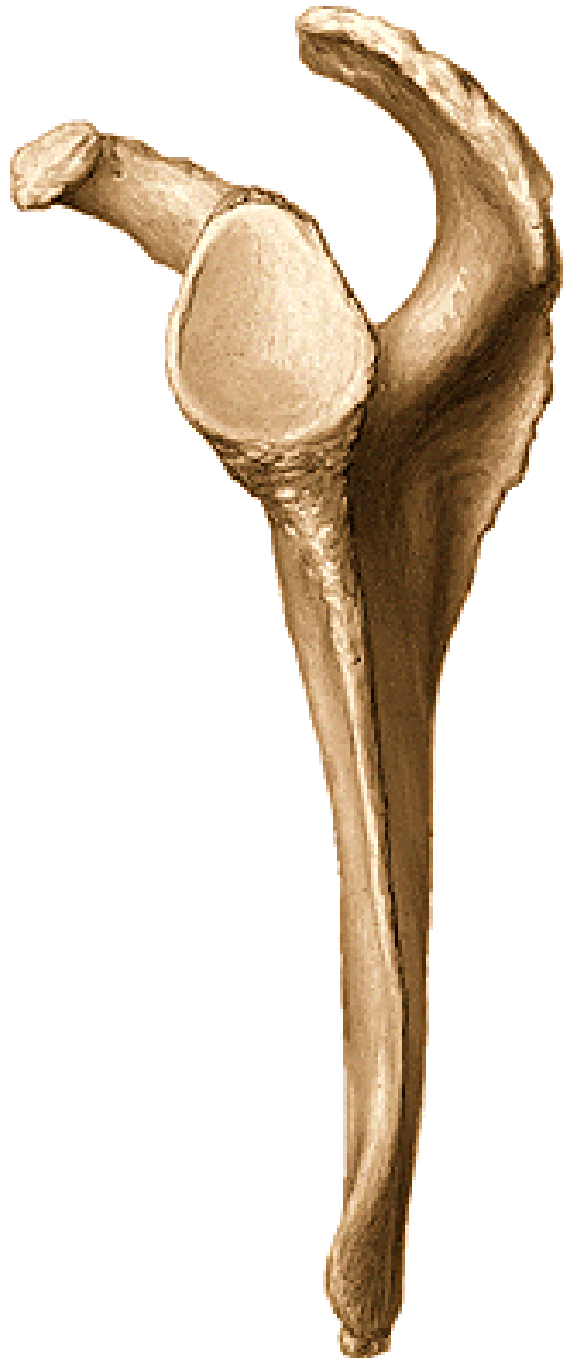Incisura scapulae  
(ligamentum transversum scapulae)

Processus coracoideus

Collum scapulae

Cavitas glenoidalis





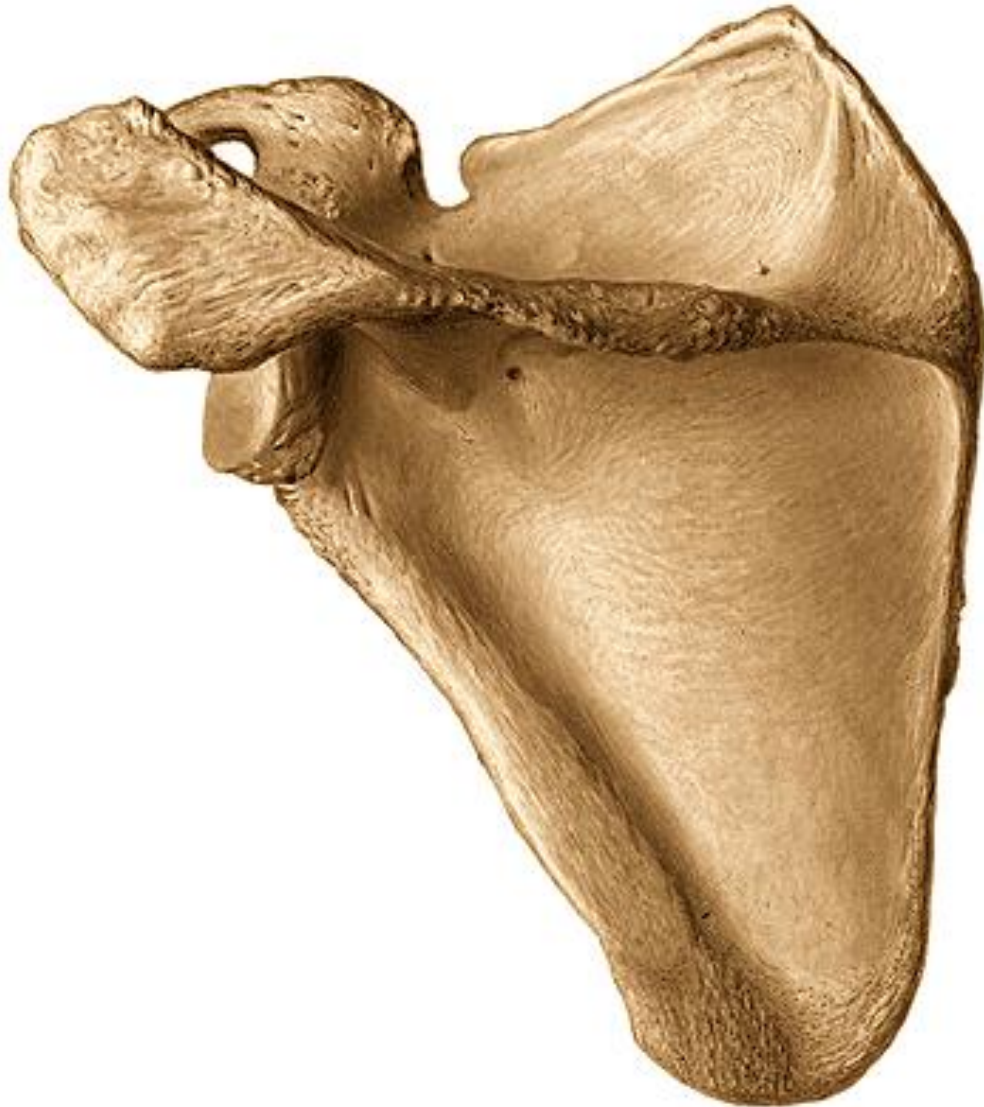cavitas glenoidalis

tuberculum supraglenoidale  
(musculus biceps brachii)

tuberculum infraglenoidale  
(musculus triceps brachii)

collum scapulae

## Facies dorsalis scapulae



spina scapulae

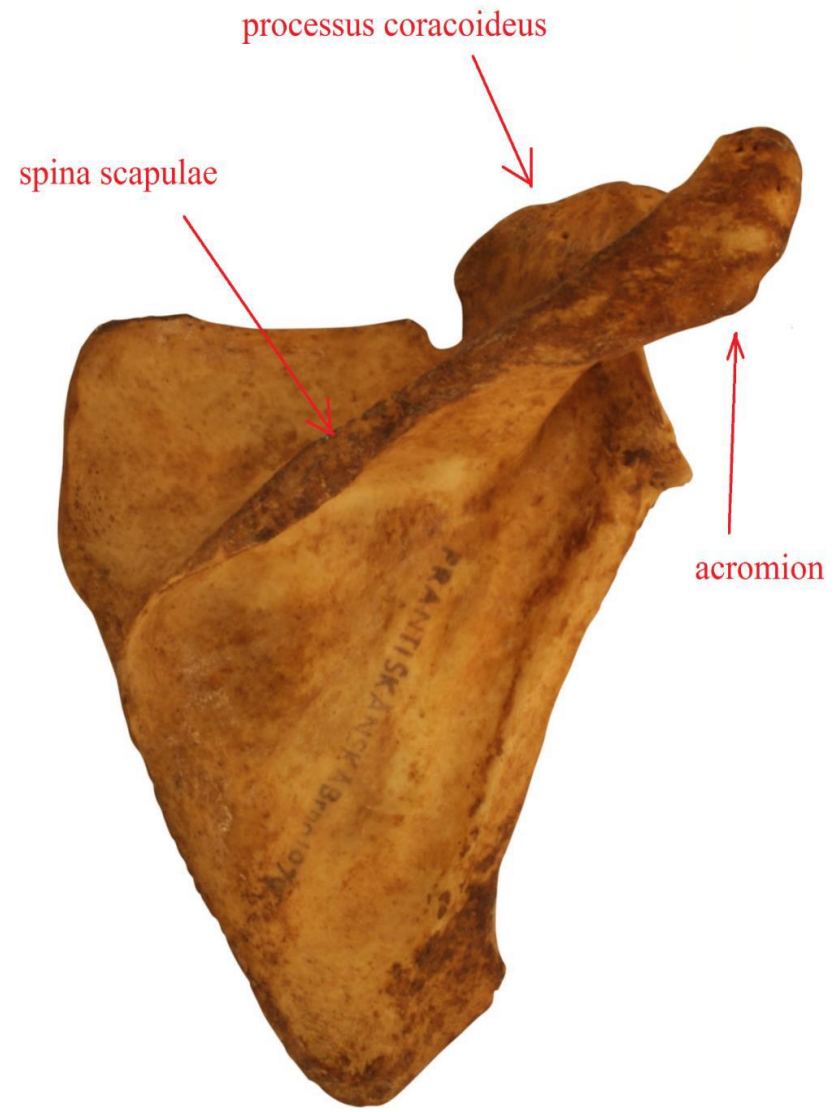
acromion

facies articularis acromii

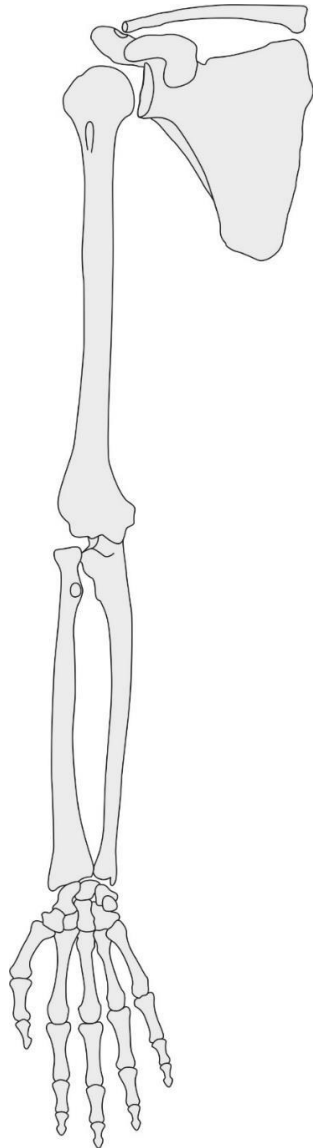
fossa supraspinata

fossa infraspinata

## Side orientation



# Humerus (arm bone)



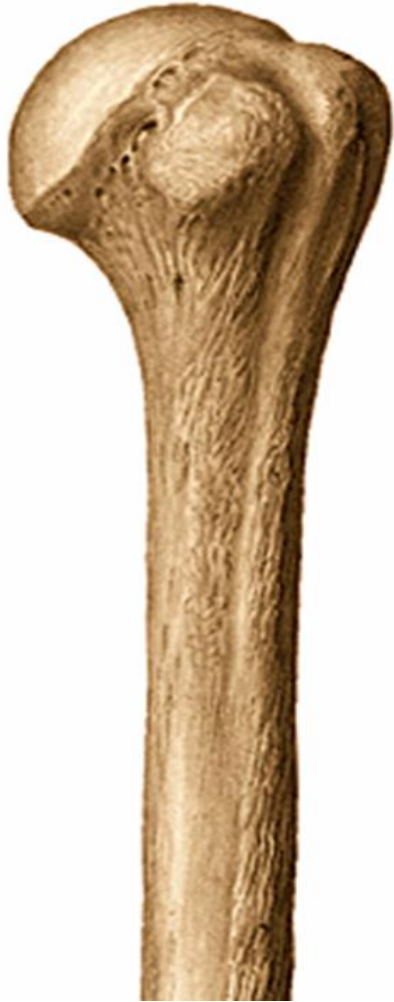Connects shoulder blade and forearm bones

Proximal end

Body

Distal end

# Humerus



## Proximal end

caput humeri

---

collum anatomicum

tuberculum majus

tuberculum minus

crista tuberculi majoris et minoris

sulcus intertubercularis

collum chirurgicum

# Humerus

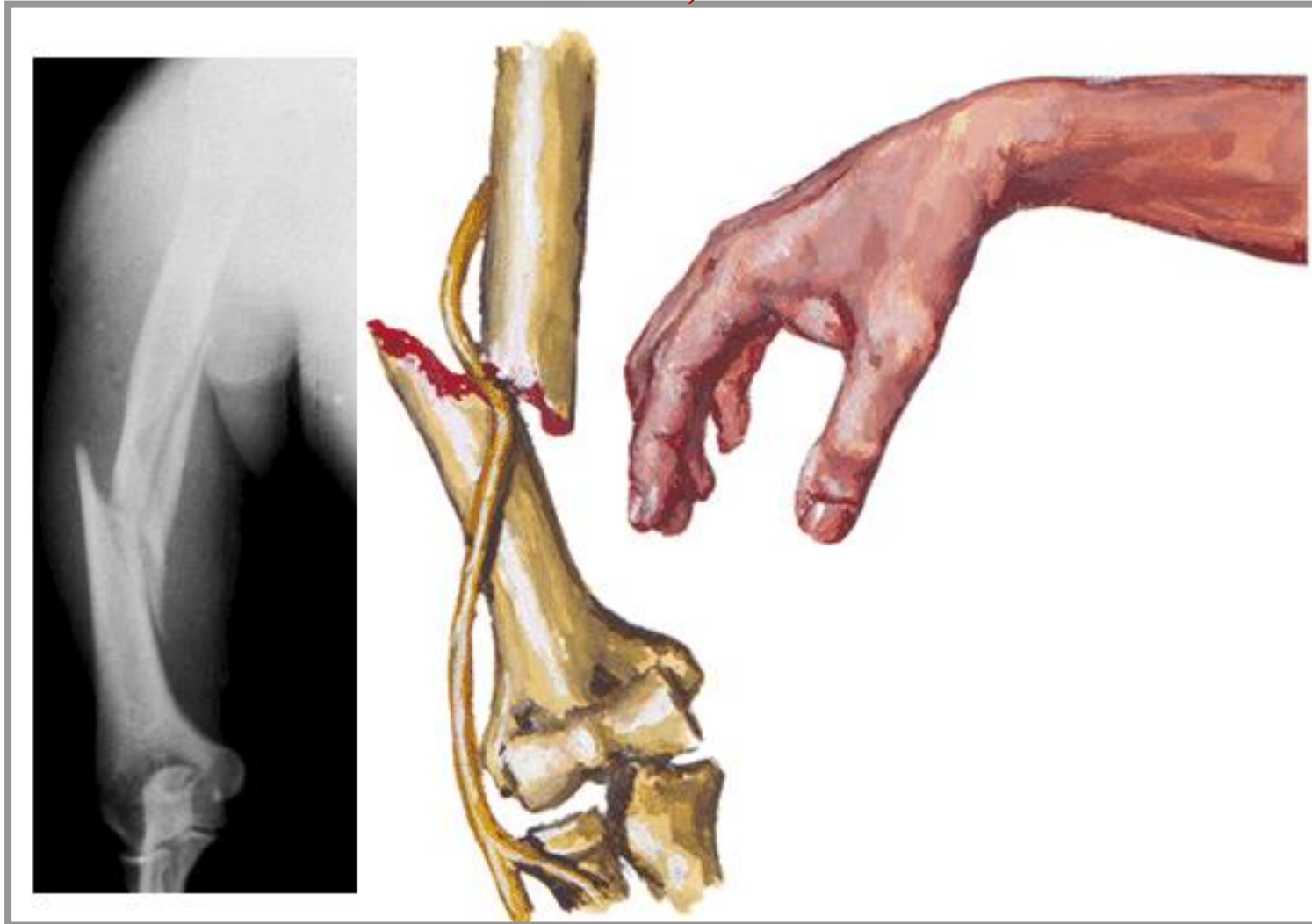


corpus - body

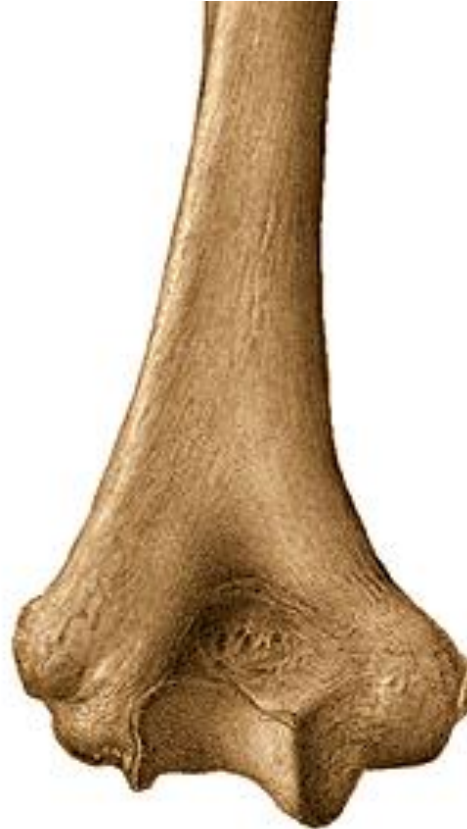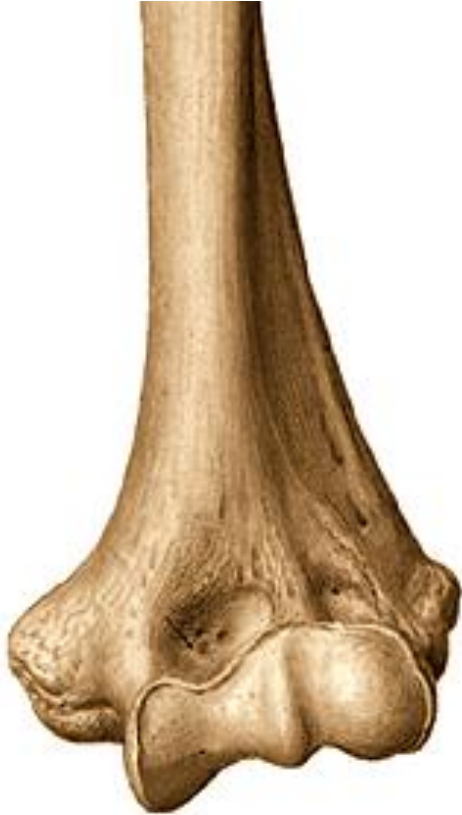tuberositas deltoidea

sulcus nervi radialis  
(nervus radialis)

## Fracture of the midshaft of the humerus (entrapment of radial nerve)



# Humerus



## Distal end

epicondylus medialis

sulcus nervi ulnaris

epicondylus lateralis

trochlea humeri

fossa coronoidea

capitulum humeri

fossa radialis

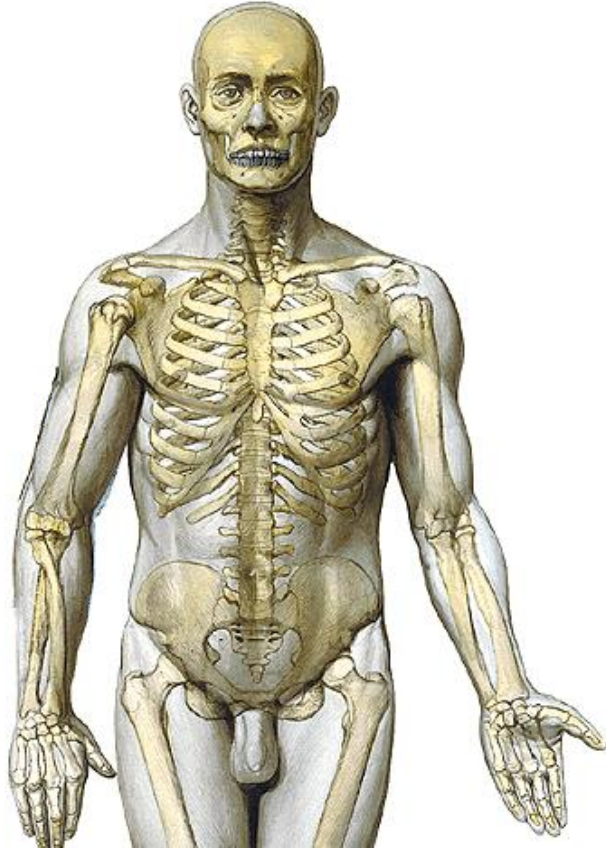
fossa olecrani



**Side orientation**



# Radius



Lateral side of the forearm

Connects to the humerus

Connects to the ulna

Connects to the carpal bones



Proximal end

body

Distal end



# Radius



Proximal end

caput radii

---

fovea capitis radii

circumferentia articularis capitis radii

collum radii

corpus (body)

tuberositas radii

margo interosseus

# Radius



---

## Distal end

processus styloideus radii

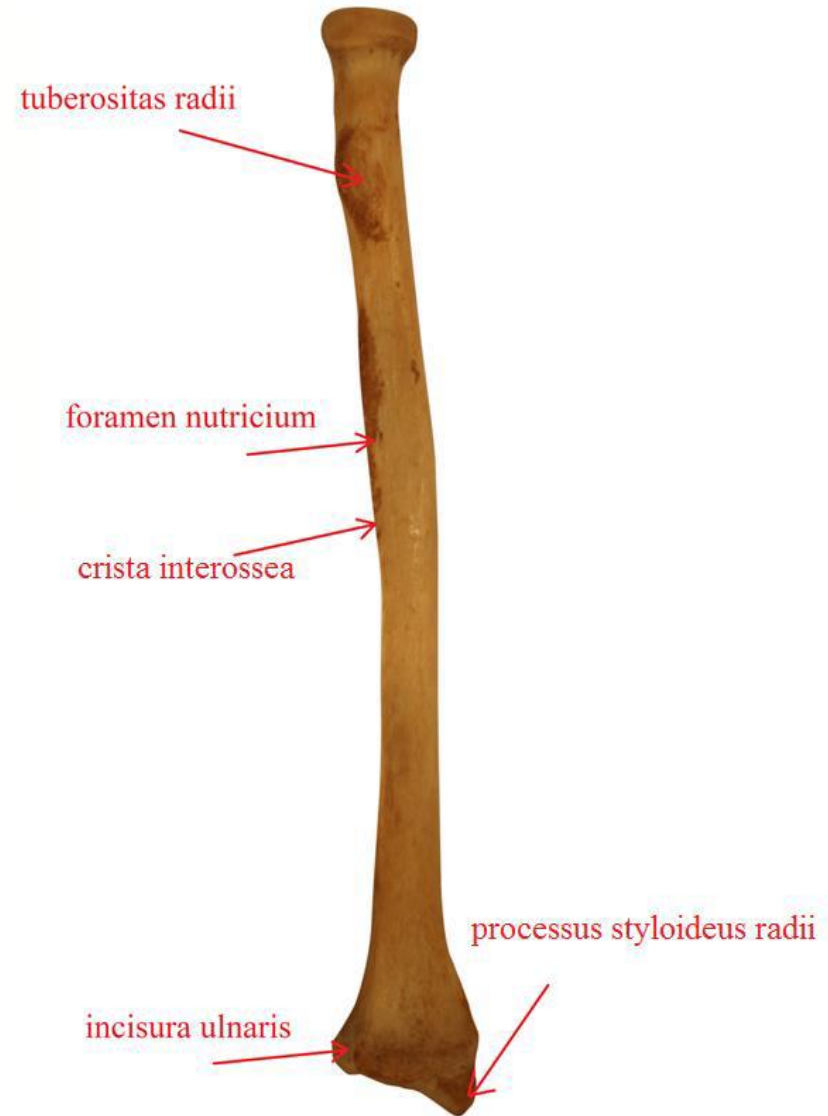
facies articularis carpea radii

incisura ulnaris radii

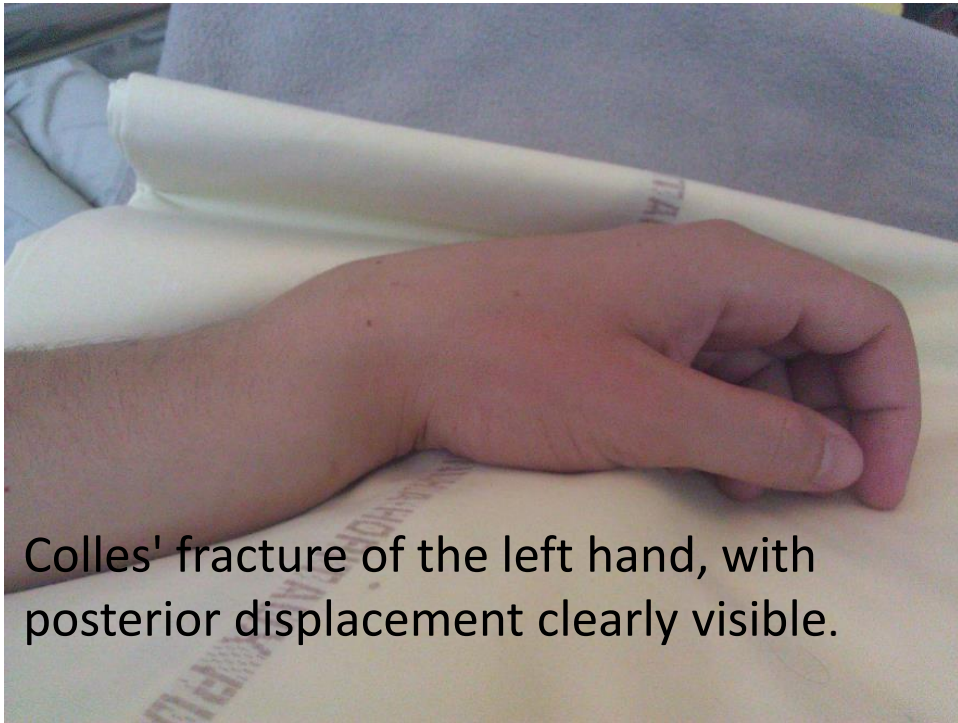Dorsal side –grooves for extensors tendons

## Side orientation

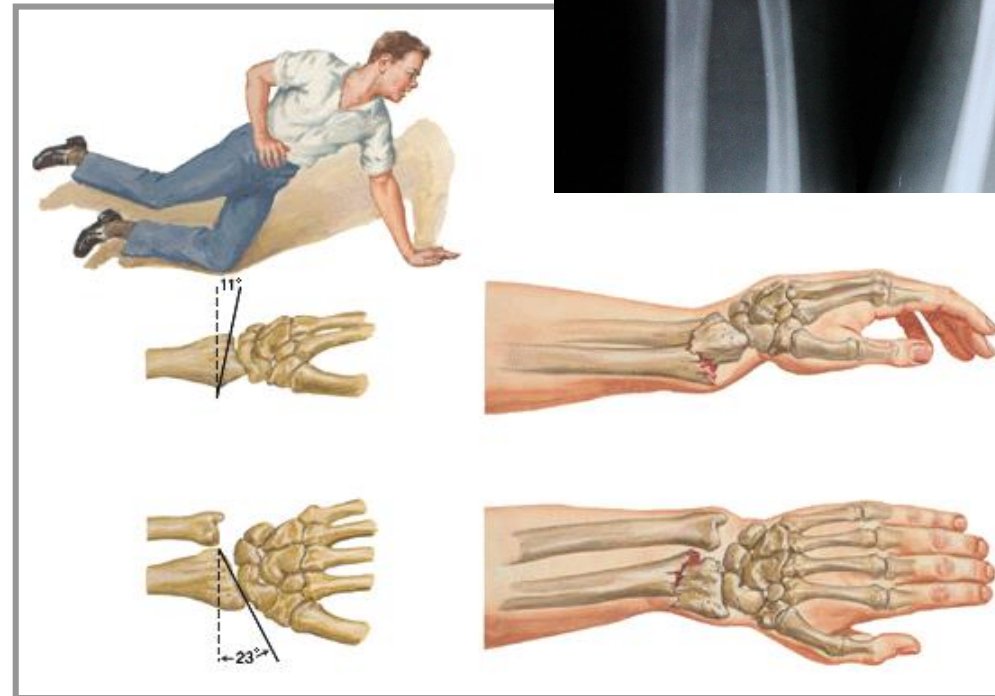
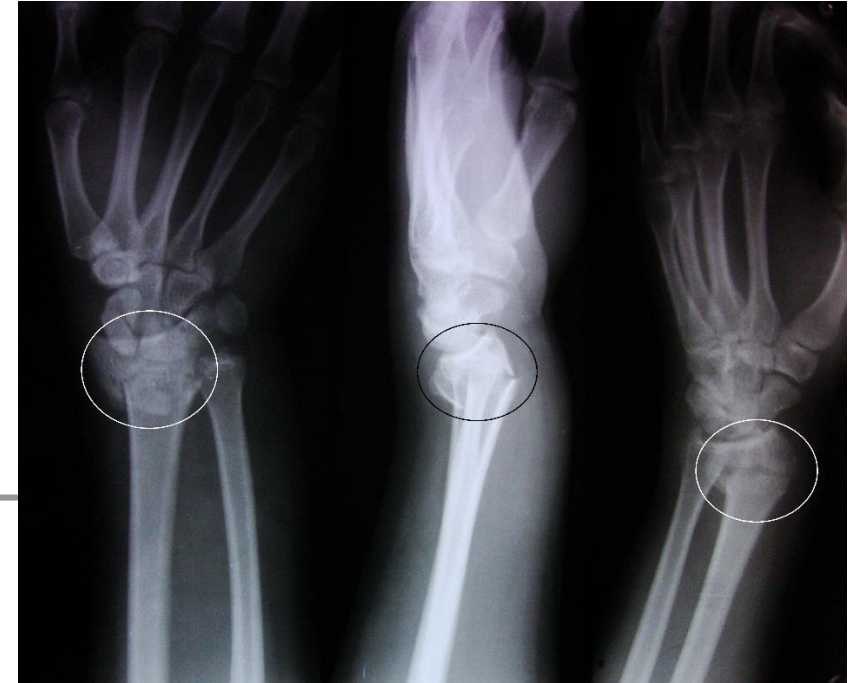---



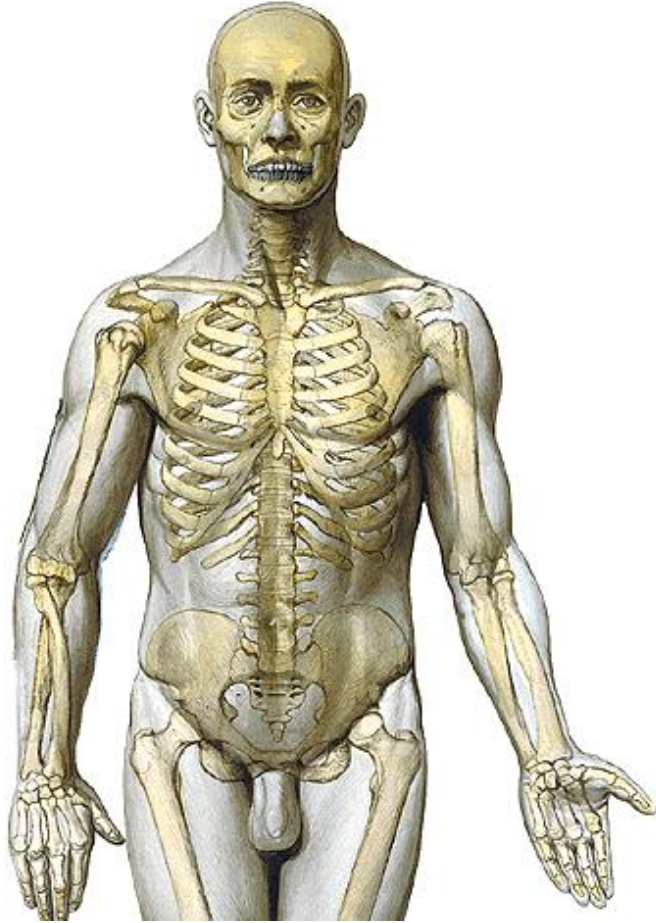
## Fracture of the distal end of radius (Colle's fracture)



An X-ray image of a fractured radius showing the characteristic Colle's fracture with displacement and angulation of the distal end of the radius.



# Ulna



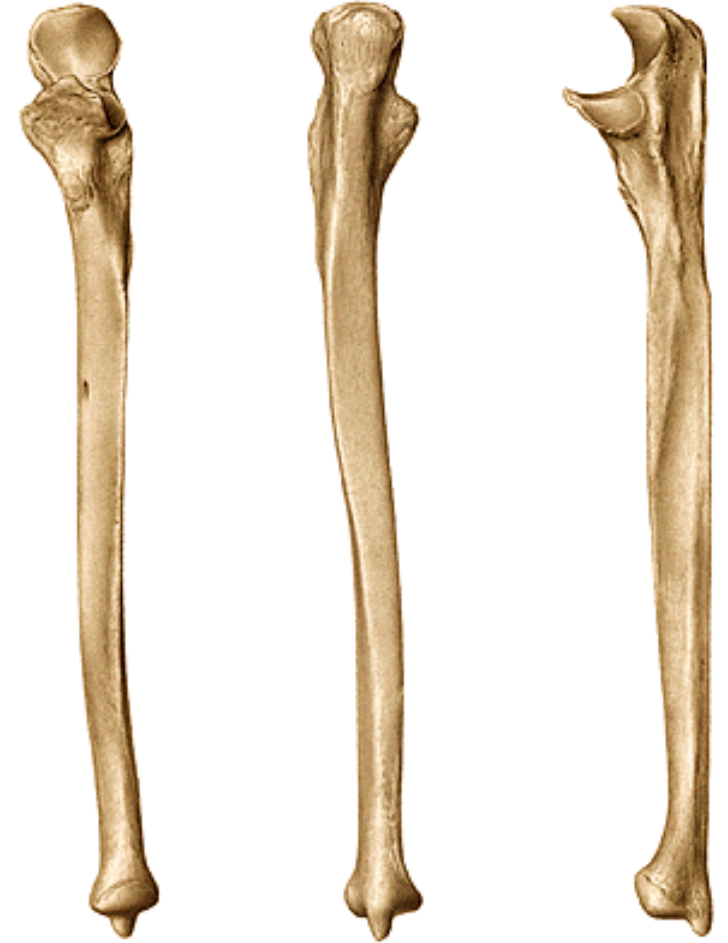Forearm (medial side)

Connects to humerus and radius




Proximal end

Body

Distal end



# Ulna



## Proximal end

olecranon ulnae

---

incisura trochlearis

processus coronoideus

incisura radialis ulnae

## body:

tuberositas ulnae

margo interosseus




crista musculi supinatoris



# Ulna

Distal end:

---



caput ulnae

circumferentia articularis capitis ulnae

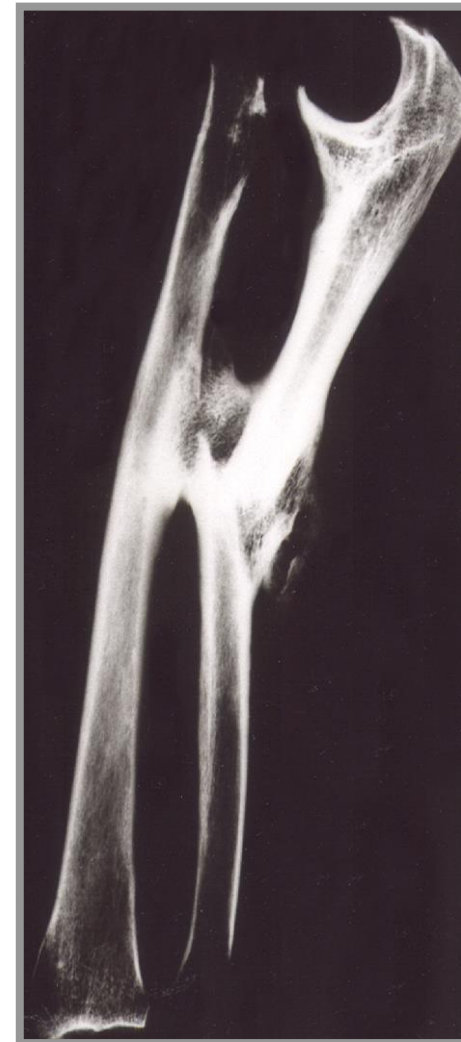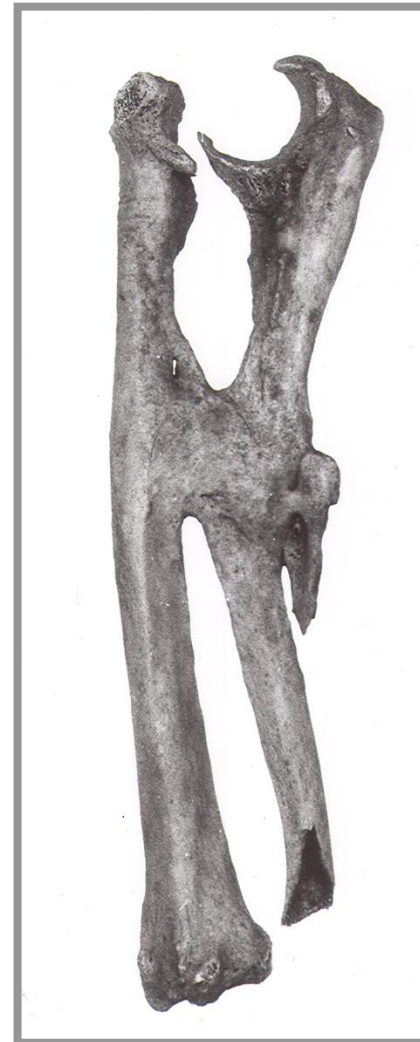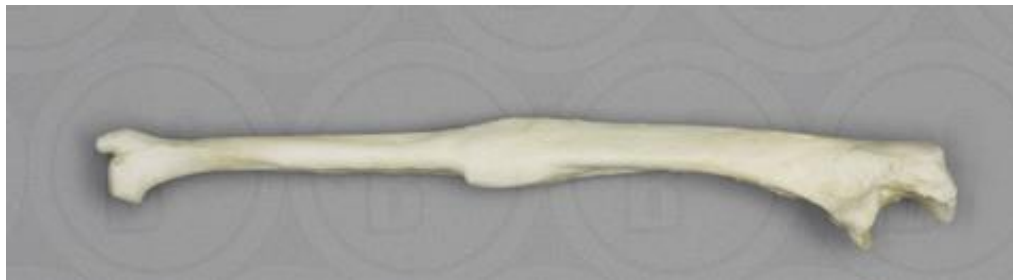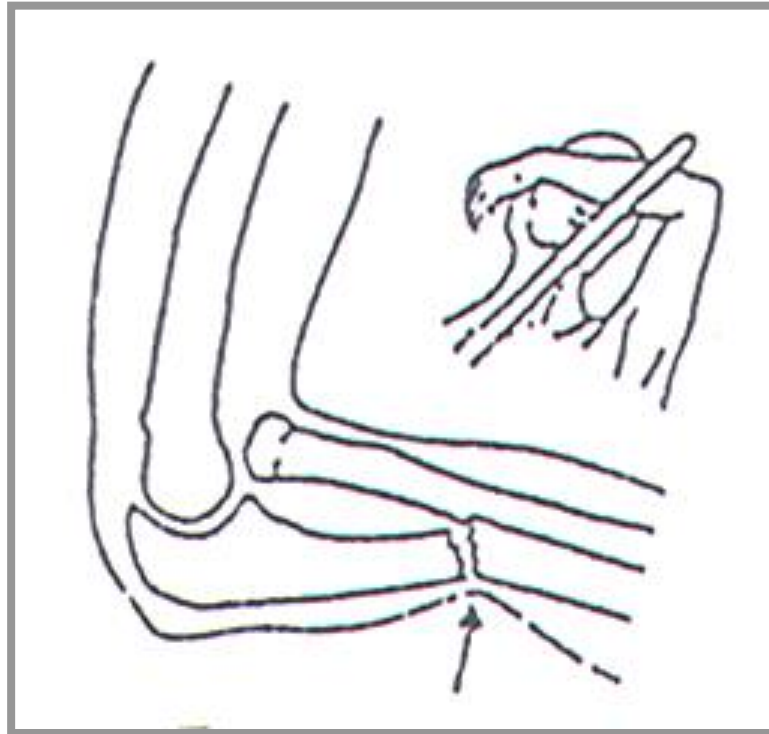
processus styloideus ulnae

## Side orientation

---

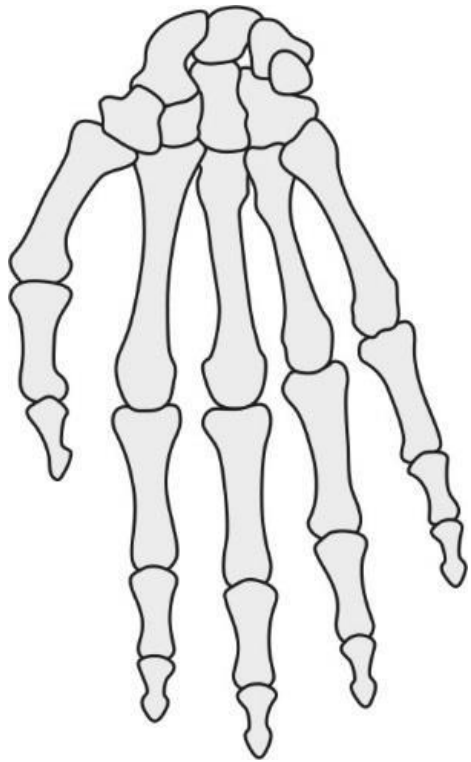


## Fracture of the ulna („parry fracture“)



## Bones of the hand

---

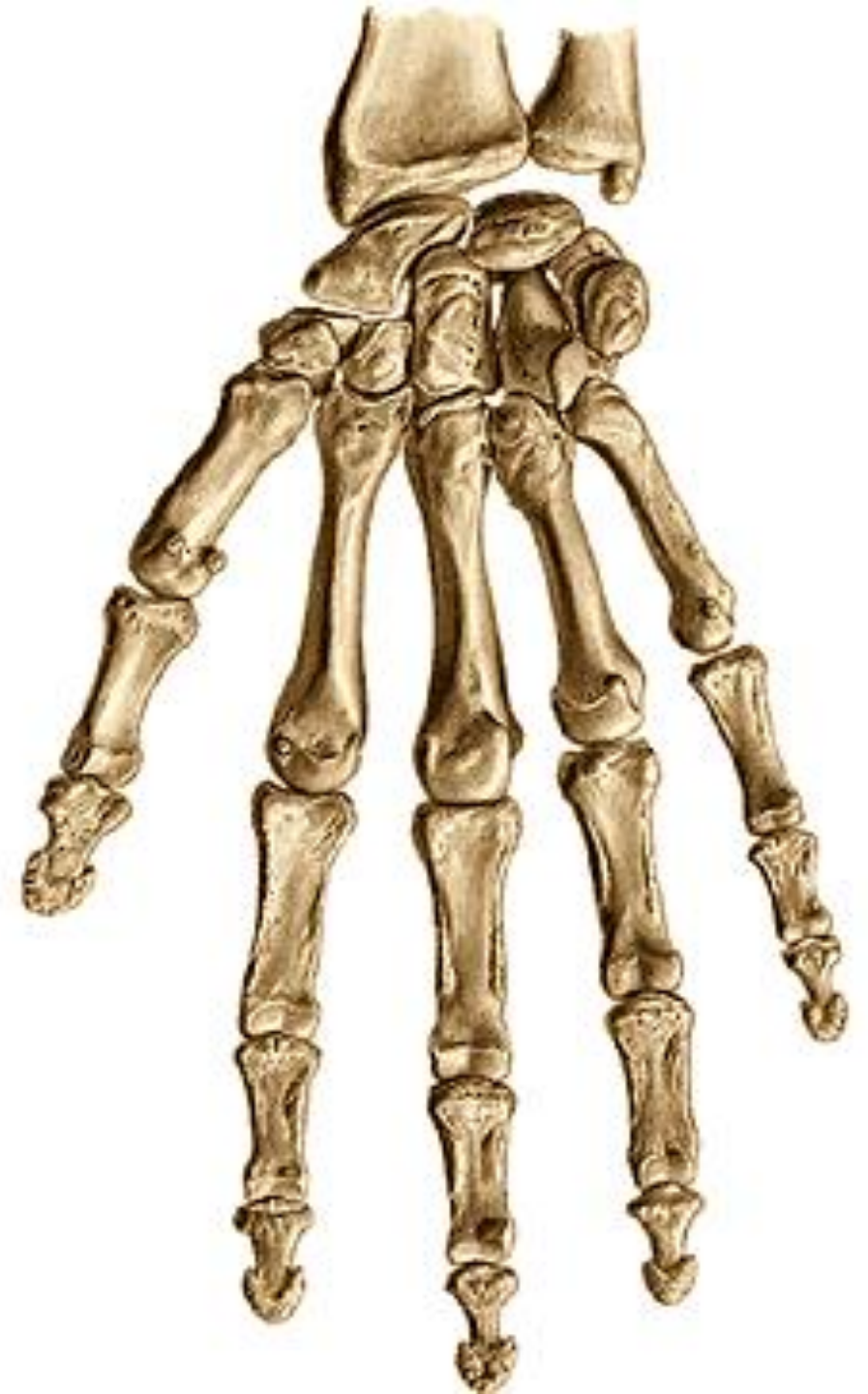

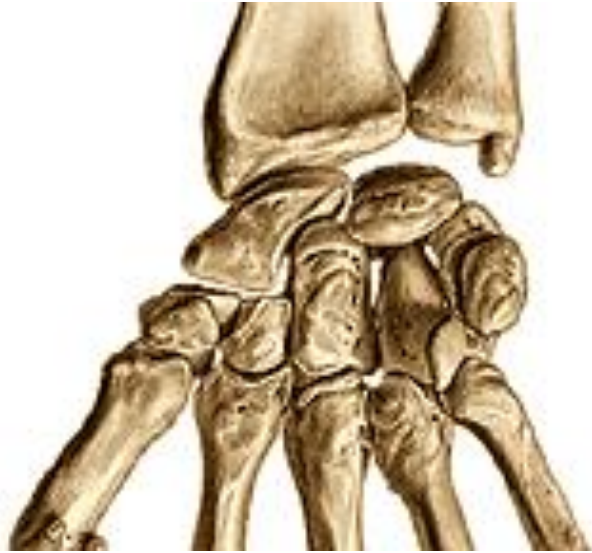**Ossa carpi** (carpal bones)

**Ossa metacarpi** (metacarpal bones)

**Ossa digitorum manus, phalanges**  
(digits)

**Sesamoid bones**





## Carpal bones - Ossa carpi (8)

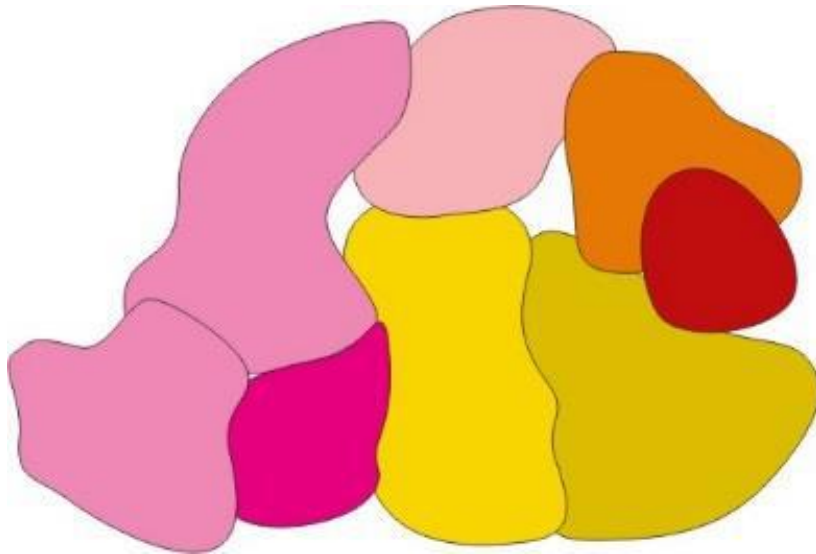
Proximal row (from the thumb):

os scaphoideum (scaphoid)  
(tuberculum ossis scaphoidei)

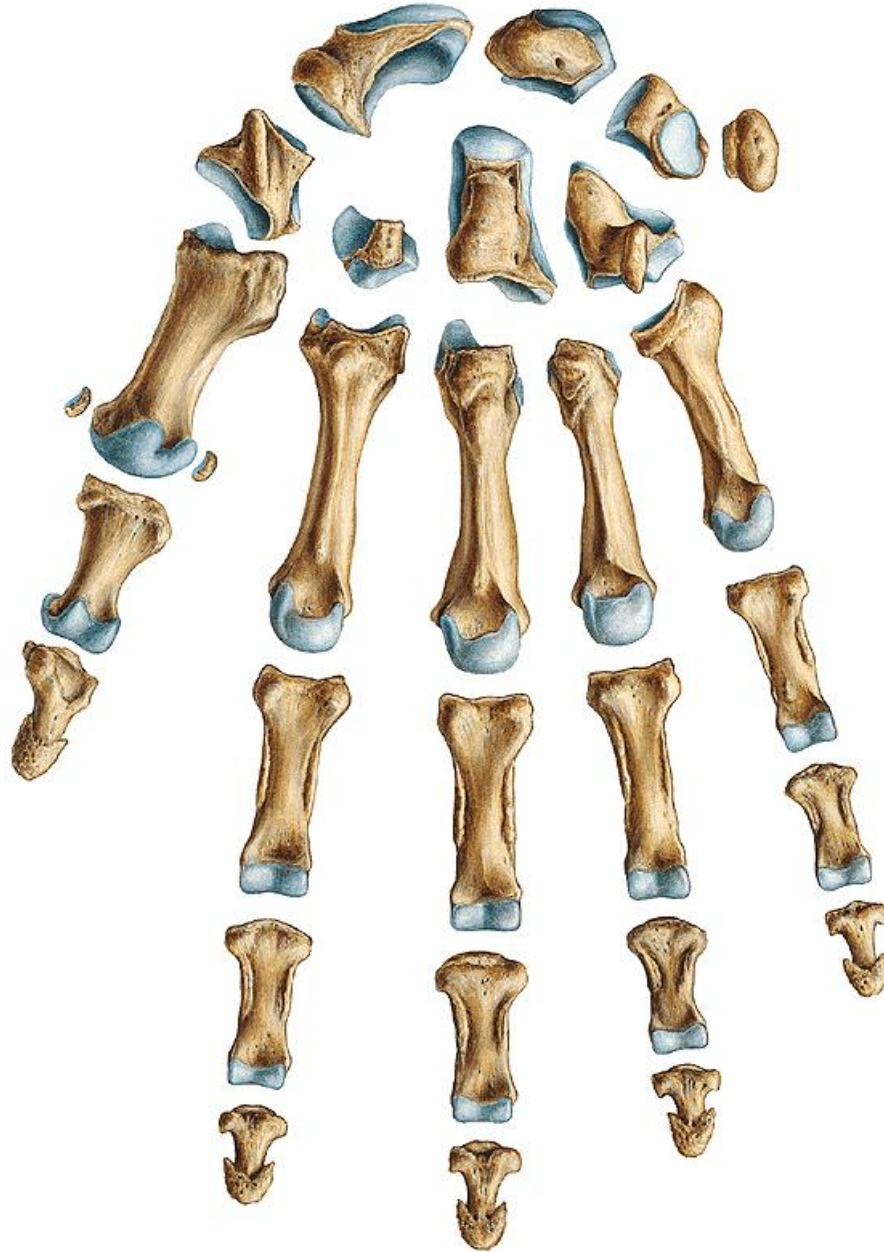
os lunatum (lunate)

os triquetrum (triquetrum)

os pisiforme (pisiform)



## Ossa carpi (8)



Distal row:

**os trapezium** (trapezium)  
(tuberculum ossis trapezii)

**os trapezoideum** (trapezoid)

**os capitatum** (capitate)

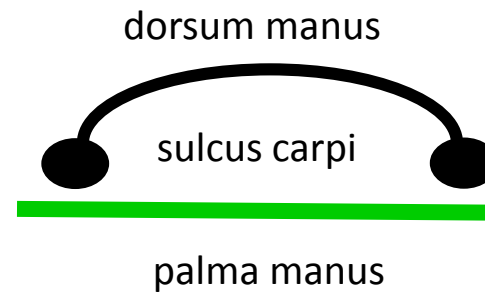
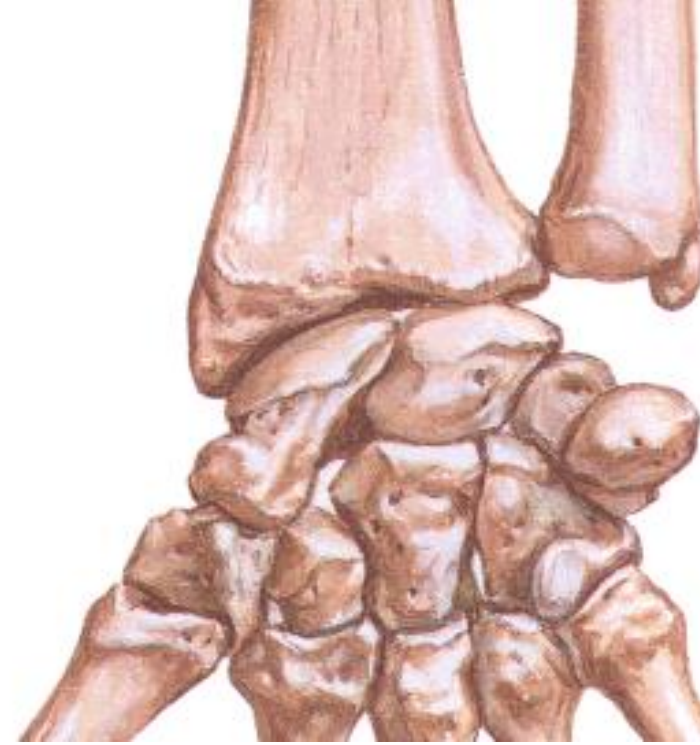
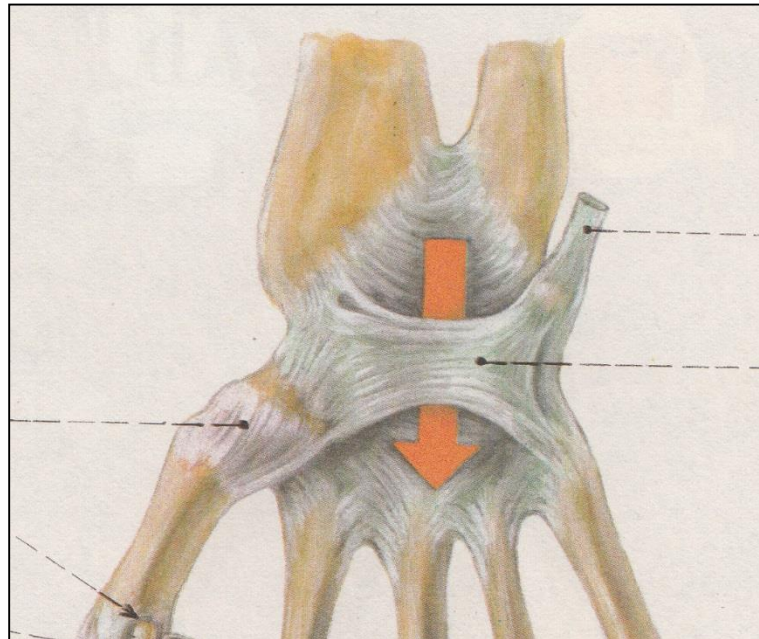
**os hamatum** (hamate)  
(hamulus ossis hamati)

**eminentia carpi radialis**  
(tuberculum ossis scaphoidei et trapezii)

**eminentia carpi ulnaris**  
(hamulus ossis hamati et os pisiforme)

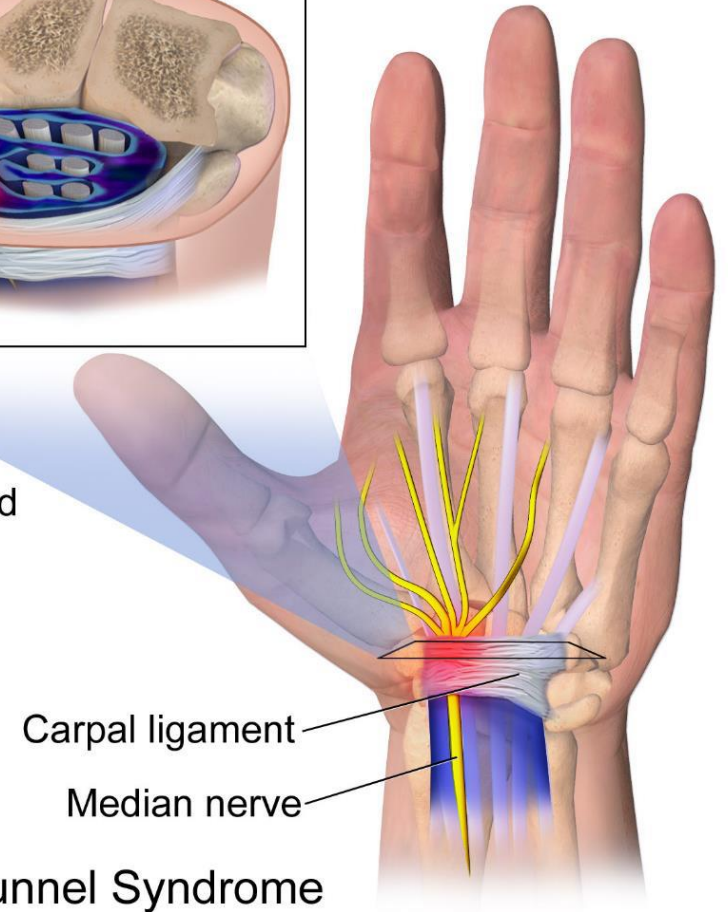
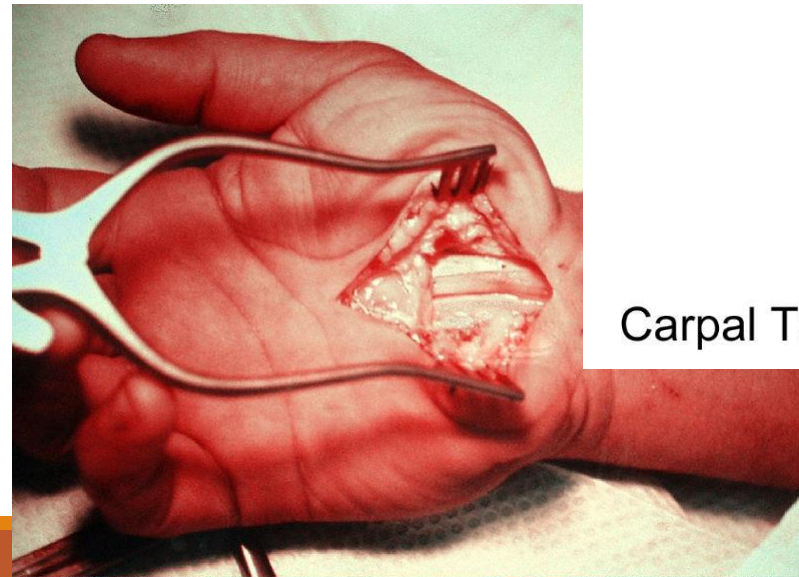
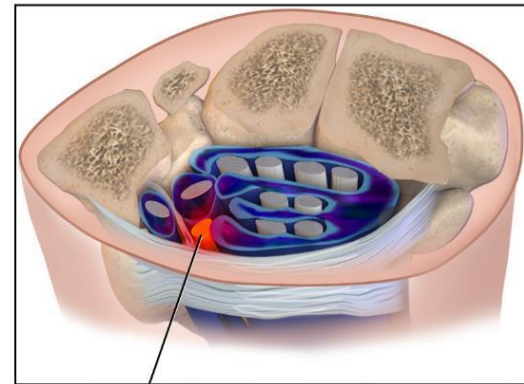
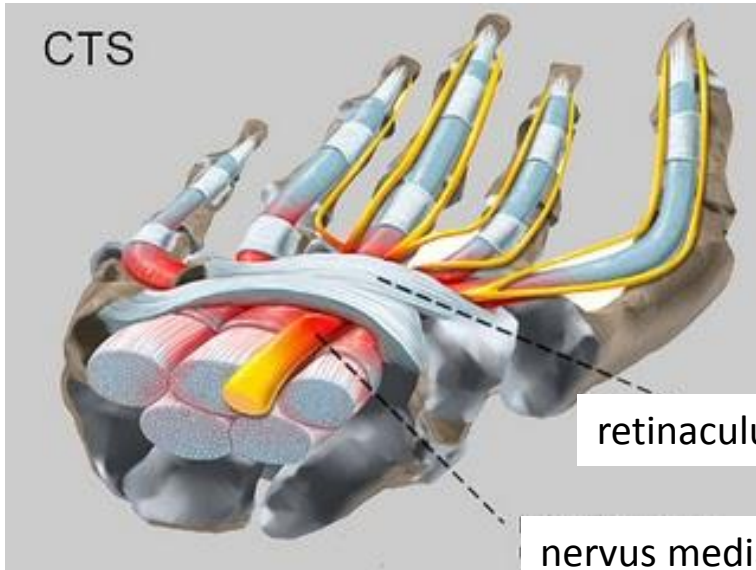
**sulcus carpi** (retinaculum flexorum)

**canalis carpi**



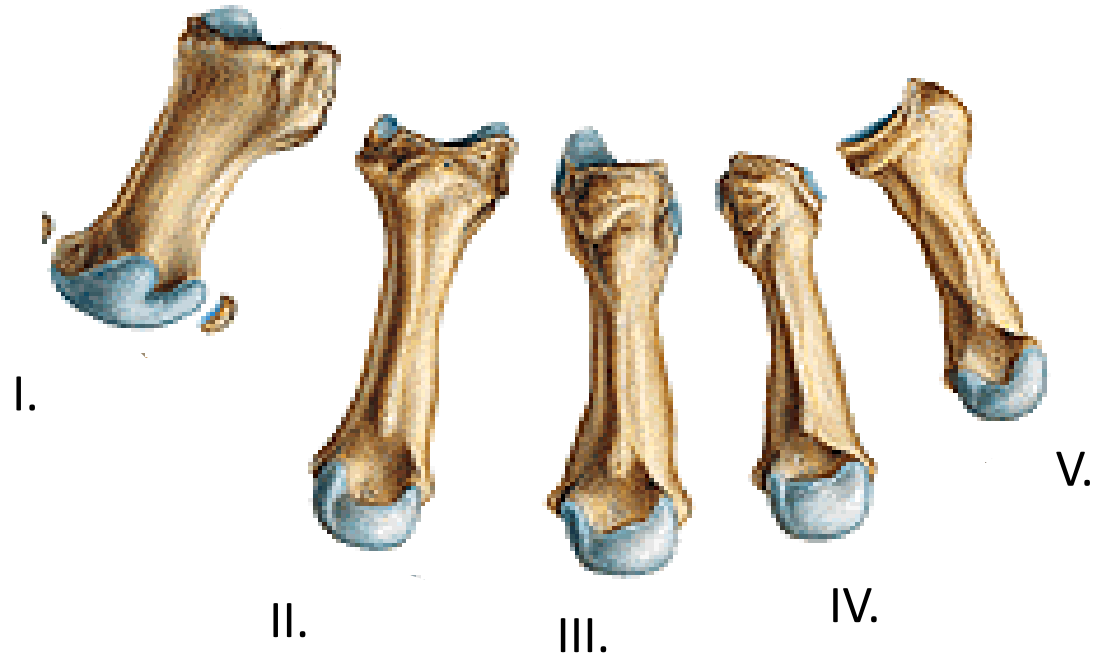
Both rows of carpal bones form together **an arch** and with flexor retinaculum (*retinaculum flexorum*) form **carpal tunnel** for tendons of flexor muscles and median nerve (*nervus medianus*).

# Carpal tunnel syndrom





## Ossa metacarpi (metacarpal bones I.-V.)



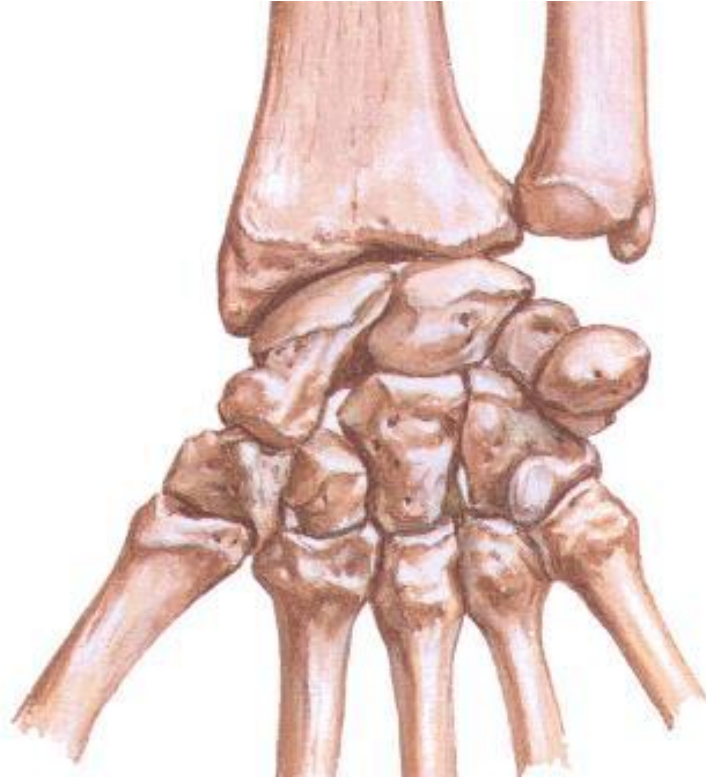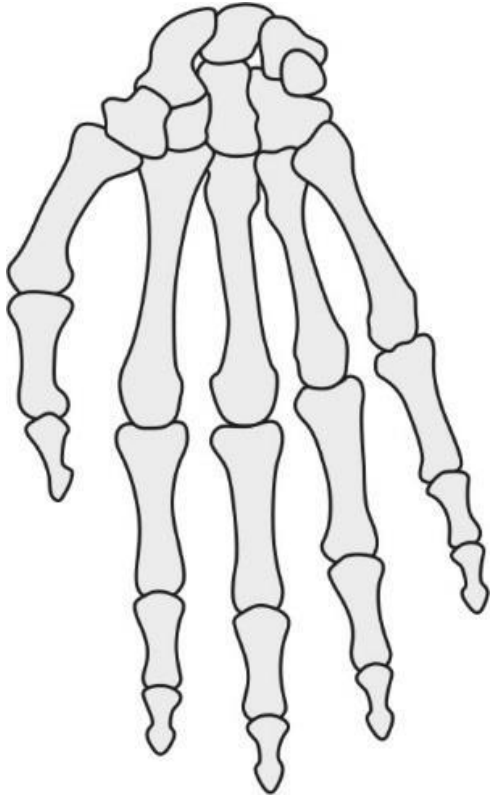
**BASE** - Basis ossis metacarpalis (III. MC – processus styloideus)

**BODY** - Corpus ossis metacarpalis

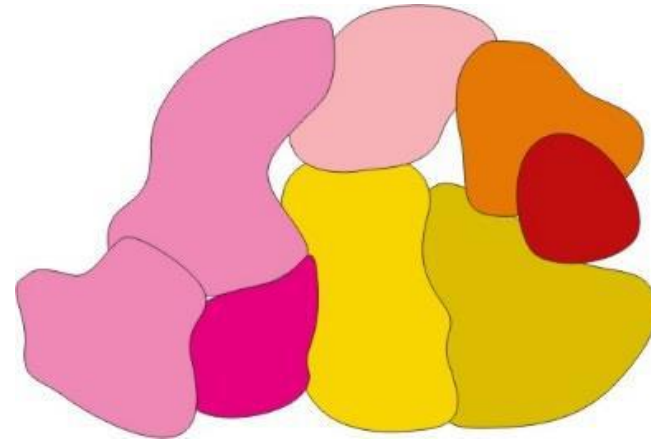
**HEAD** - Caput ossis metacarpalis

Ossa sesamoidea - Sesamoid bones -in the joints between metacarpal and the basis of proximal phalanx of the thumb.

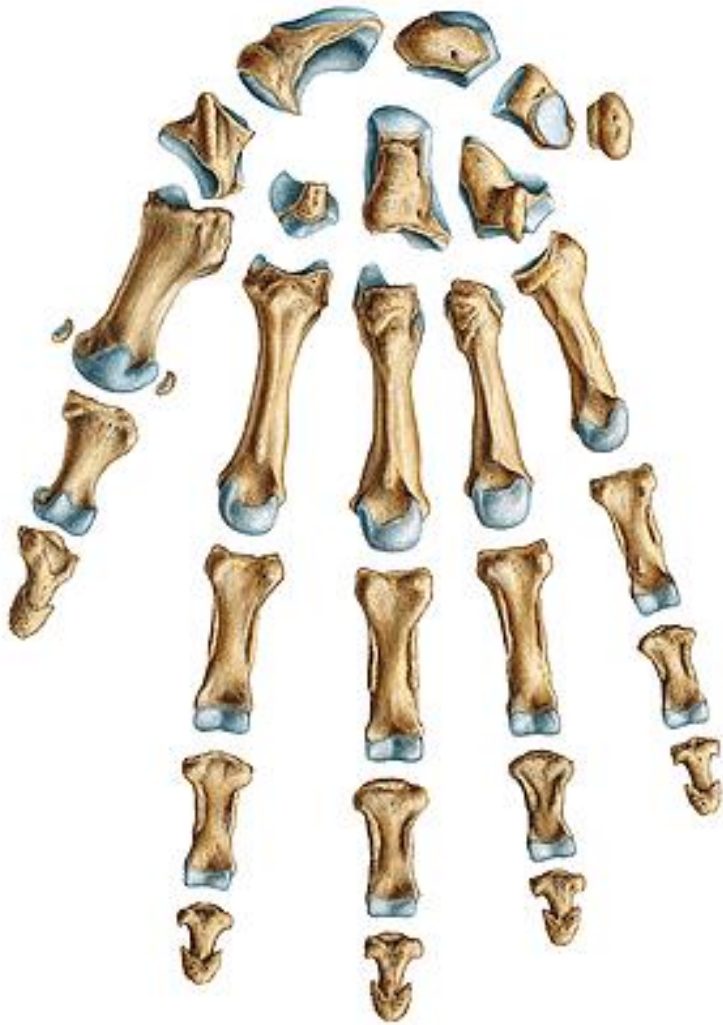## Connections with basis ossis metacarpi



- I. MC – trapezium
- II. MC – trapezium, trapezoid, capitate
- III. MC – capitate
- IV. And V. MC – hamate



## Ossa digitorum manus, phalanges of the hand, bones of the digits



Each digit (II.-V.)

---

3 phalanges: phalanx proximalis, media et distalis

Thumb: 2 phalanges: phalanx proximalis et distalis

Base - Basis phalangis (prox., media, dist.)

Body - Corpus phalangis (prox., media, dist.)

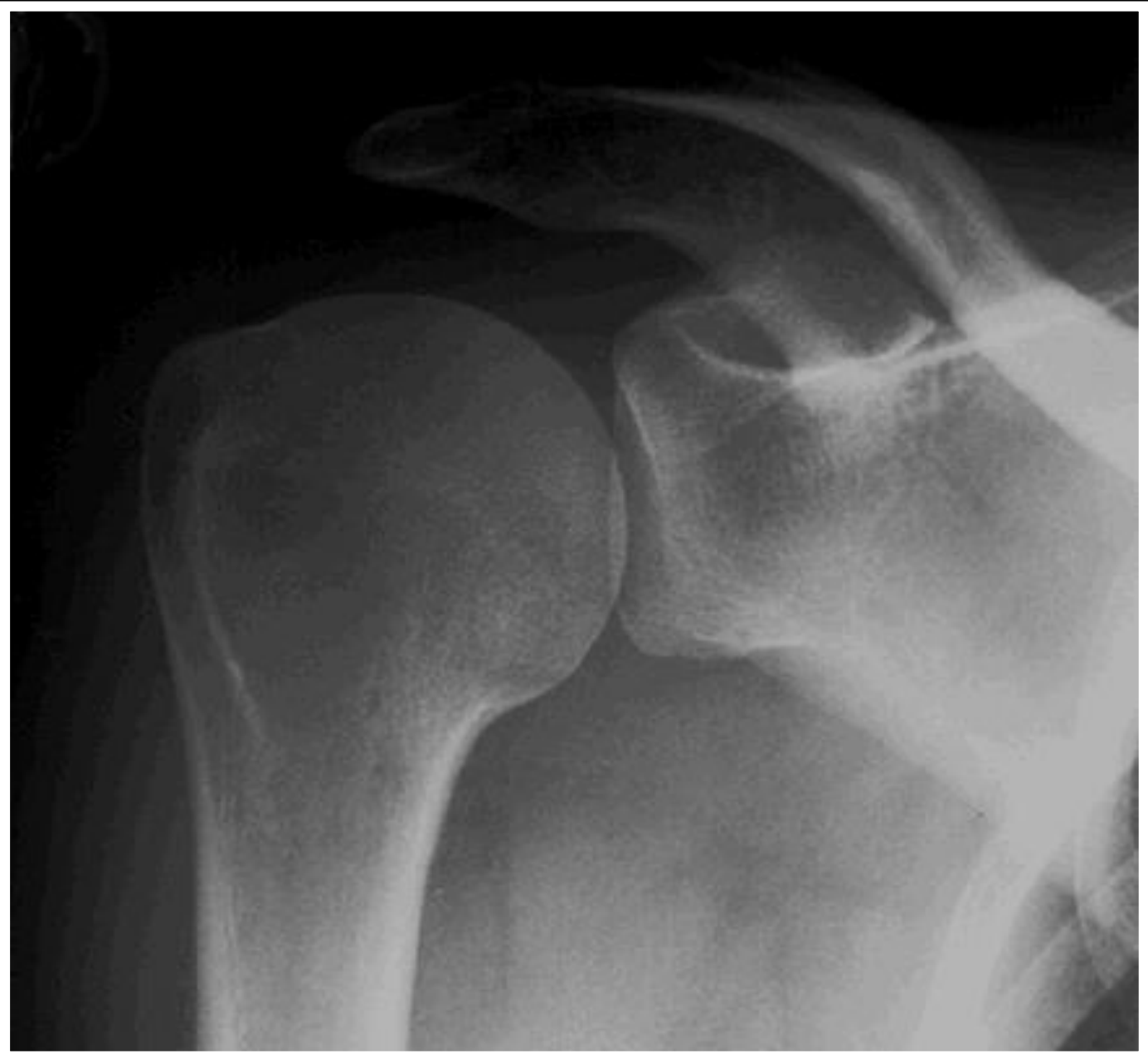Head, trochles - Trochlea phalangis (prox., media, dist.)

Tuberositas phalangis distalis - at the distal end there is a rough palmar surface for insertion of the tendon of the muscle –the tuberosity of the distal phalanx

---

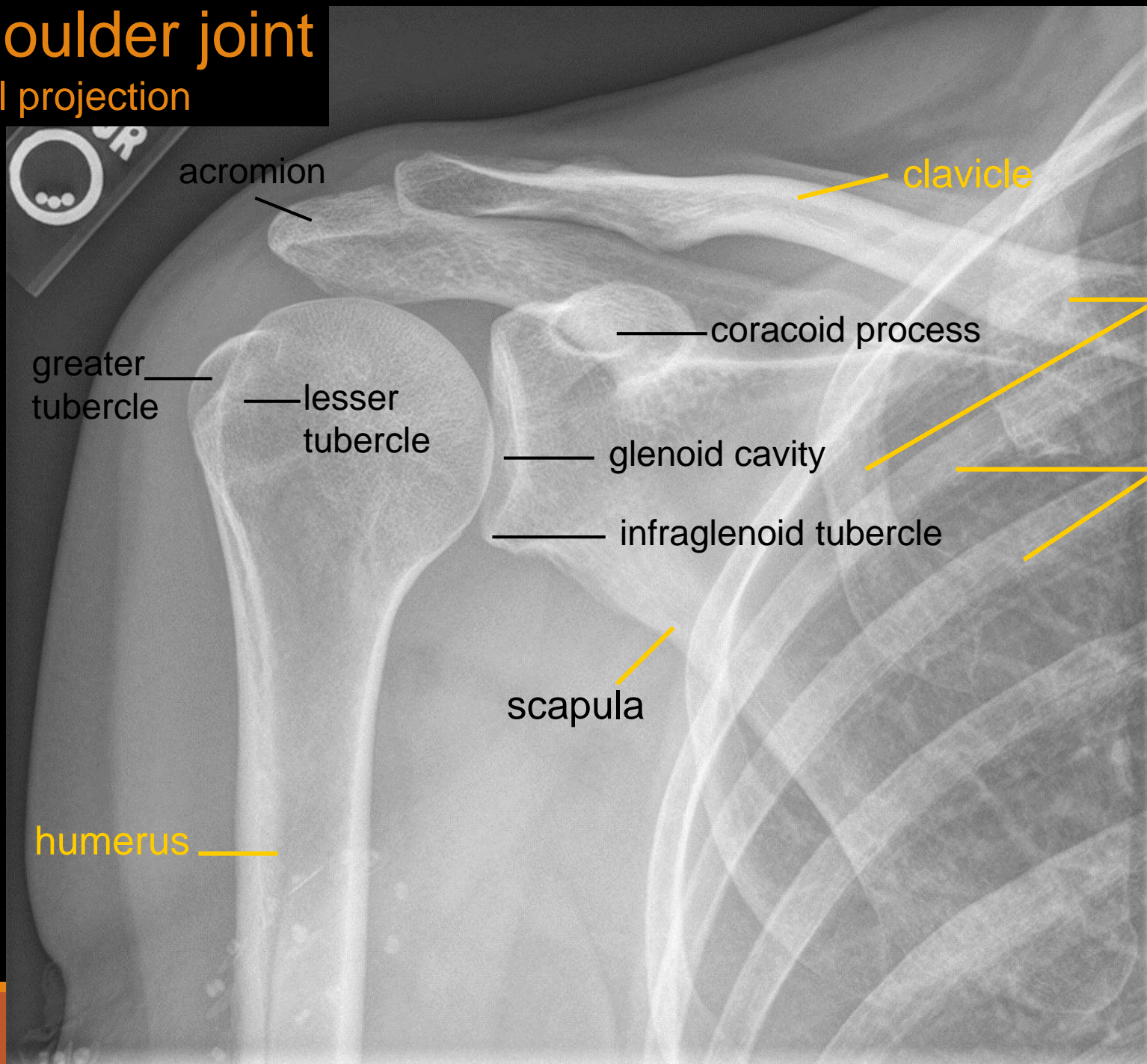
**X-rays**





# Shoulder joint

axial projection



acromion

clavicle

coracoid process

anterior ribs

greater tubercle

lesser tubercle

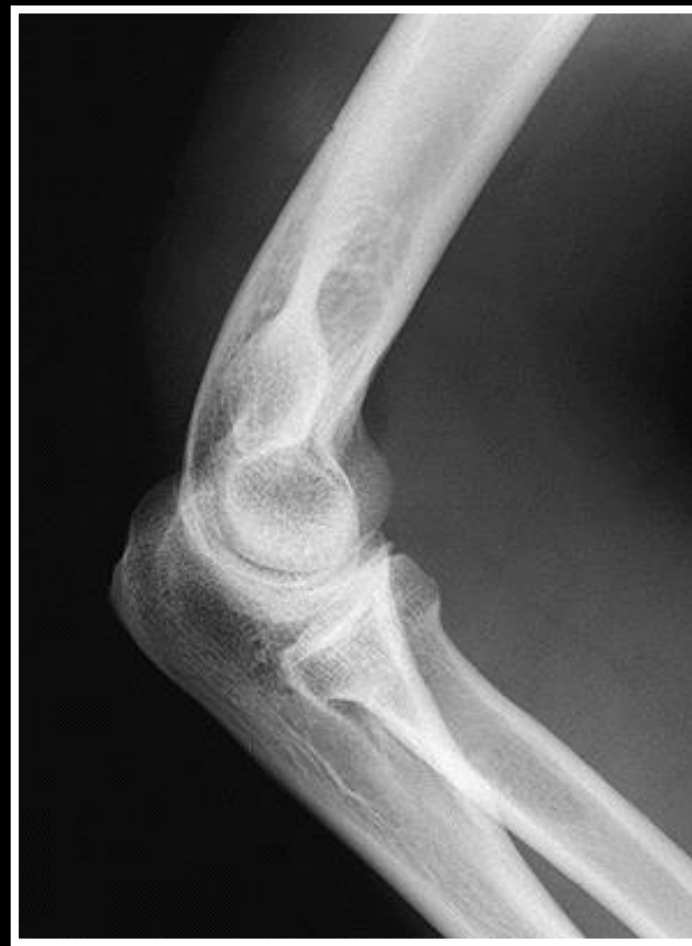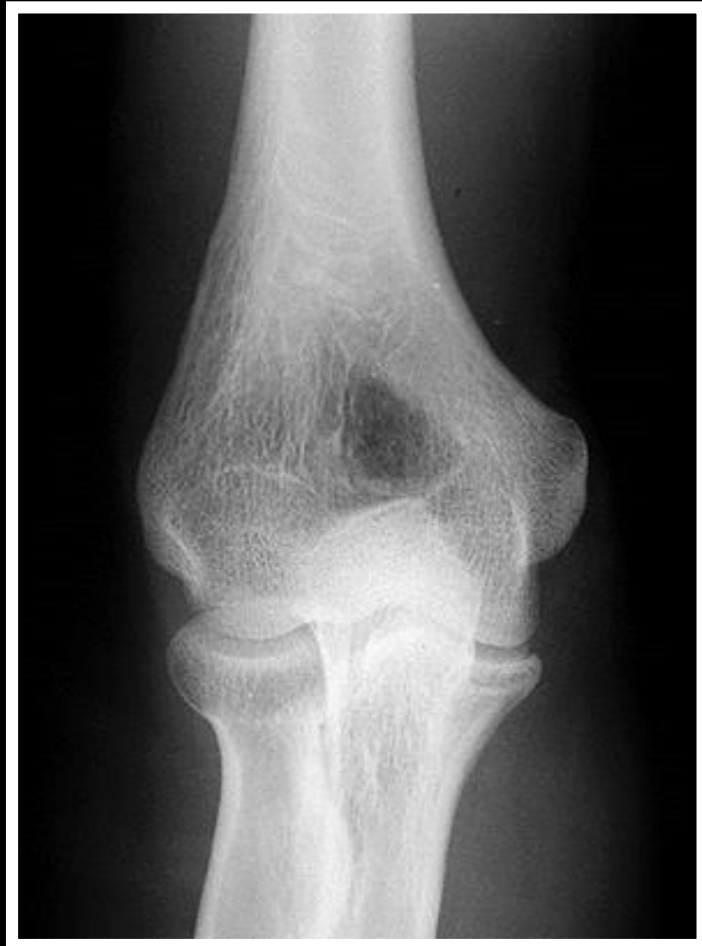glenoid cavity

posterior ribs

infraglenoid tubercle

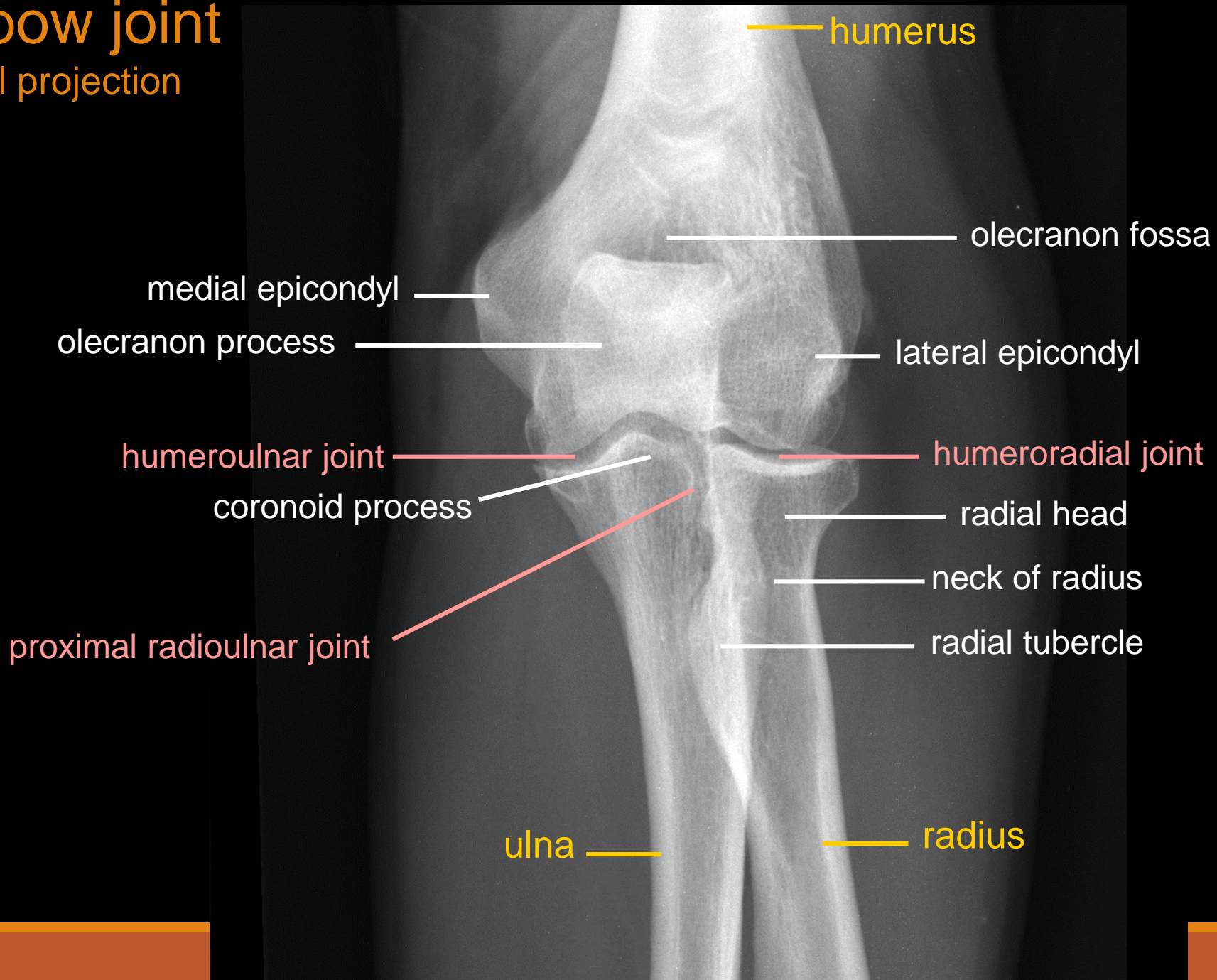
scapula

humerus



# Elbow joint

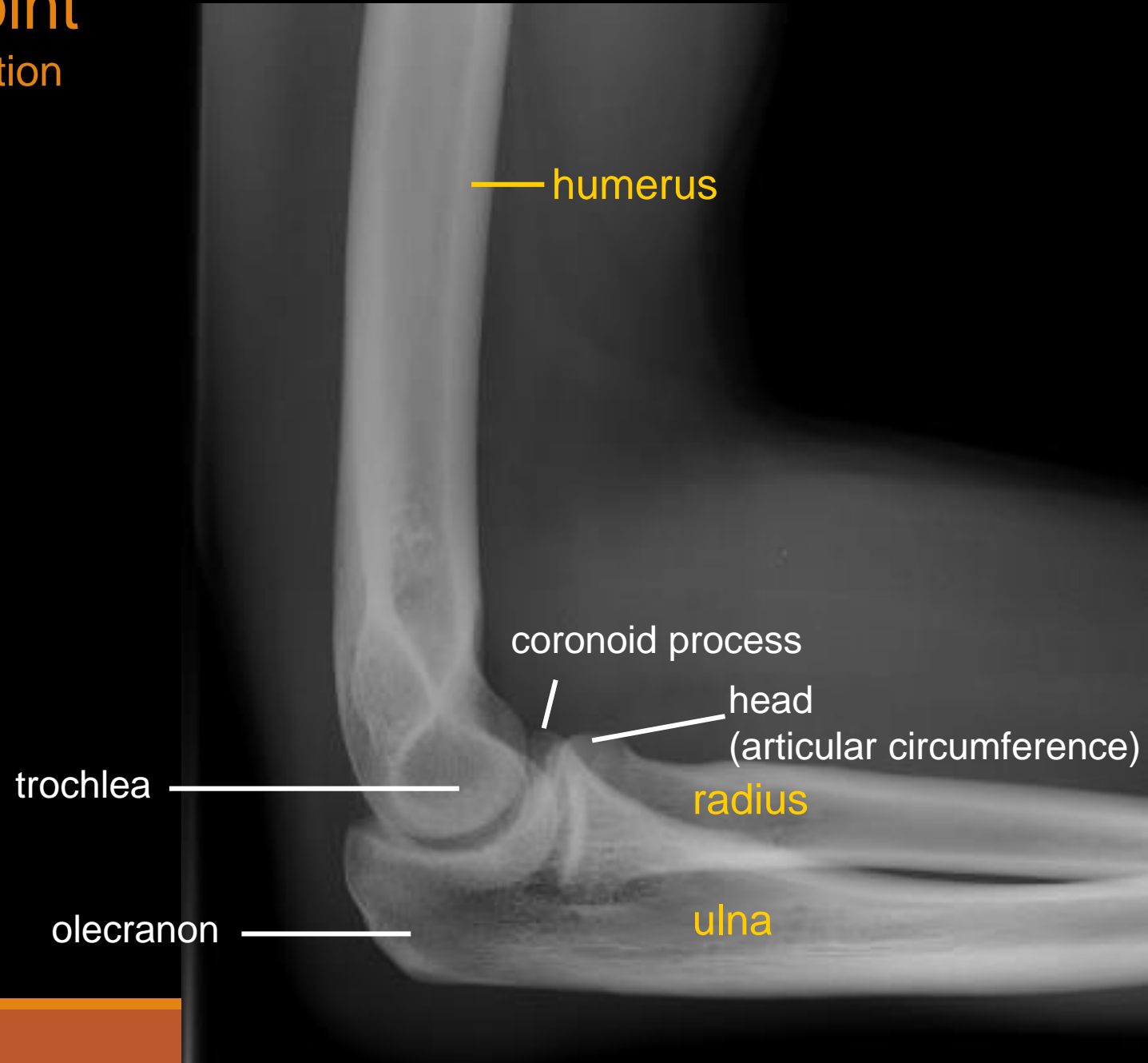
axial projection



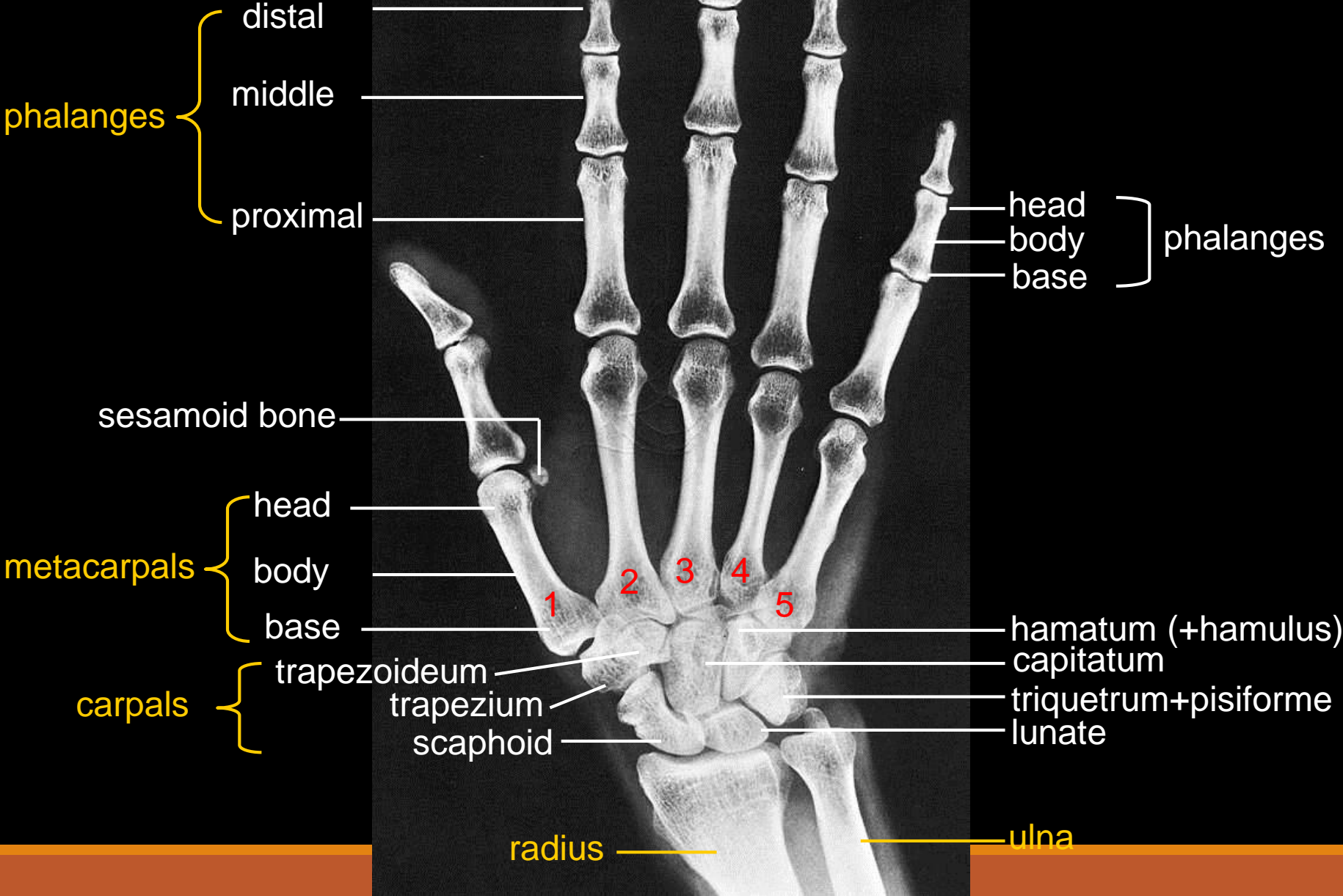


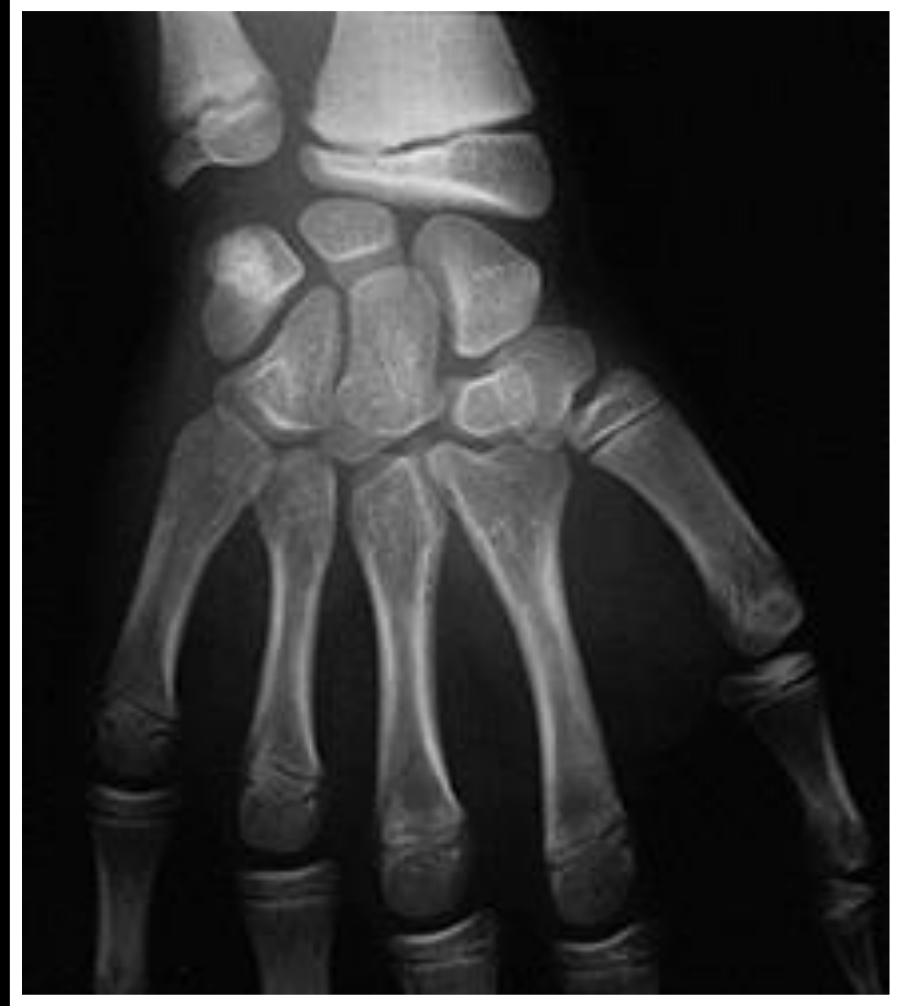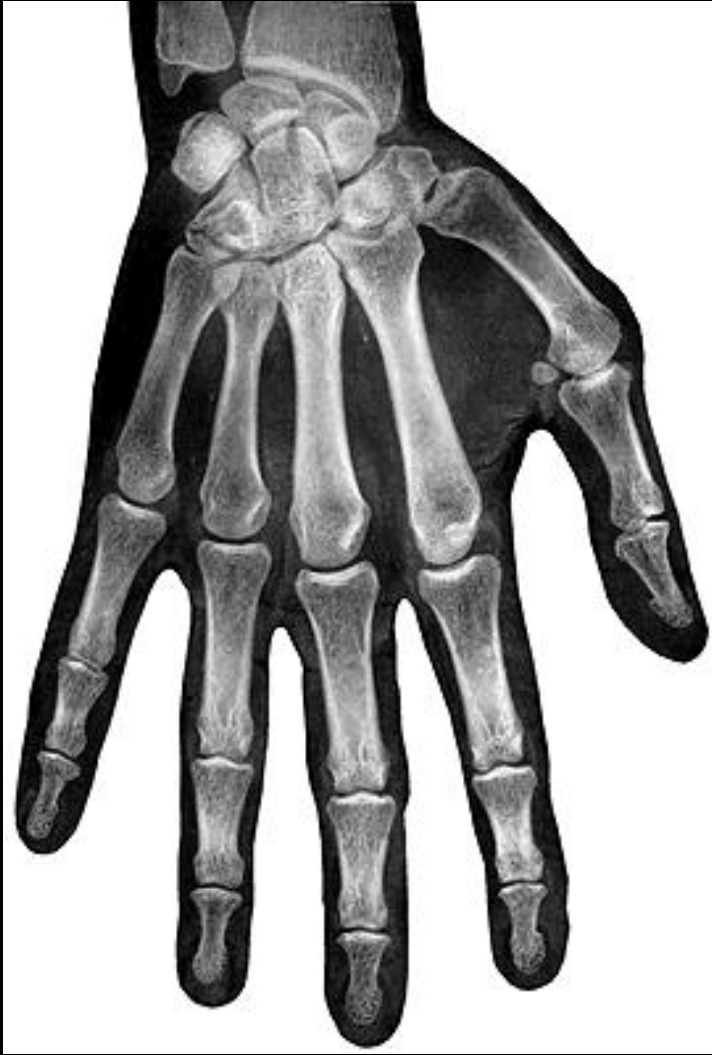# Elbow joint

lateral projection

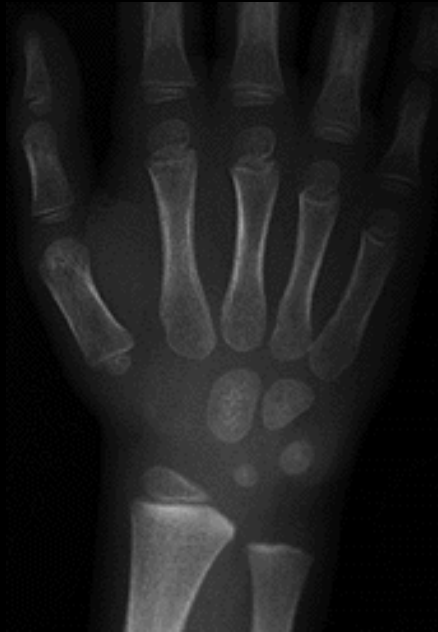

# Hand and wrist adult

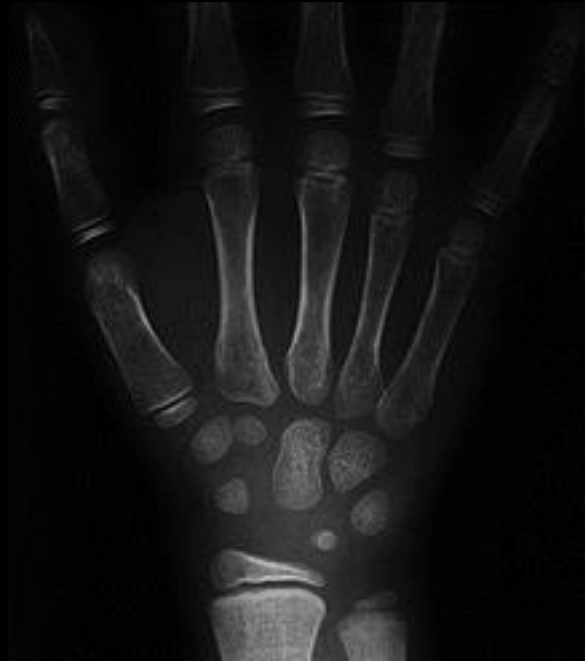



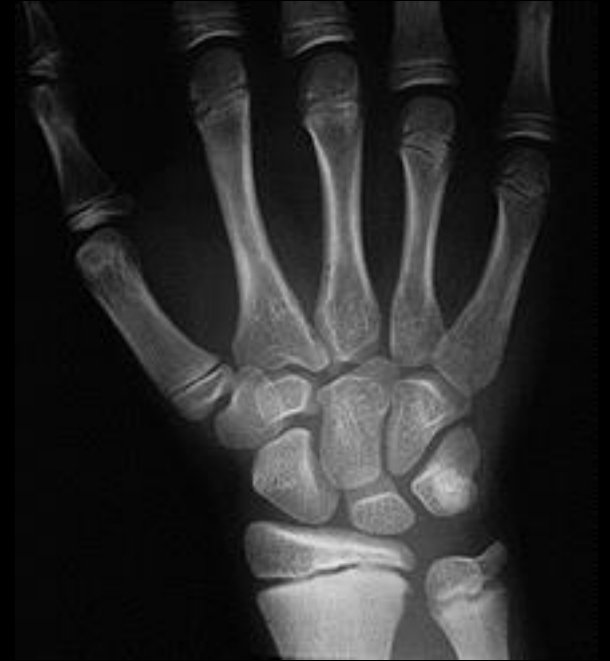# Hand and wrist child



**4,5 years old child**  
(4 carpal bones are ossificated)



**7 years old child**  
(7 carpal bones are ossificated)



**13 years old child**

---

**The pictures used in this lecture were taken from following sources:**

- Atlas der Anatomie des Menschen/Sobotta. Putz,R., und Pabst,R. 20. Auflage. München:Urban&Schwarzenberg, 1993
- Netter: Interactive Atlas of Human Anatomy.
- Naňka, Elišková: Přehled anatomie. Galén, Praha 2009.
- Čihák: Anatomie I, II, III.
- Drake et al: Gray's Anatomy for Students. 2010
- Own archiv of the lecturer