

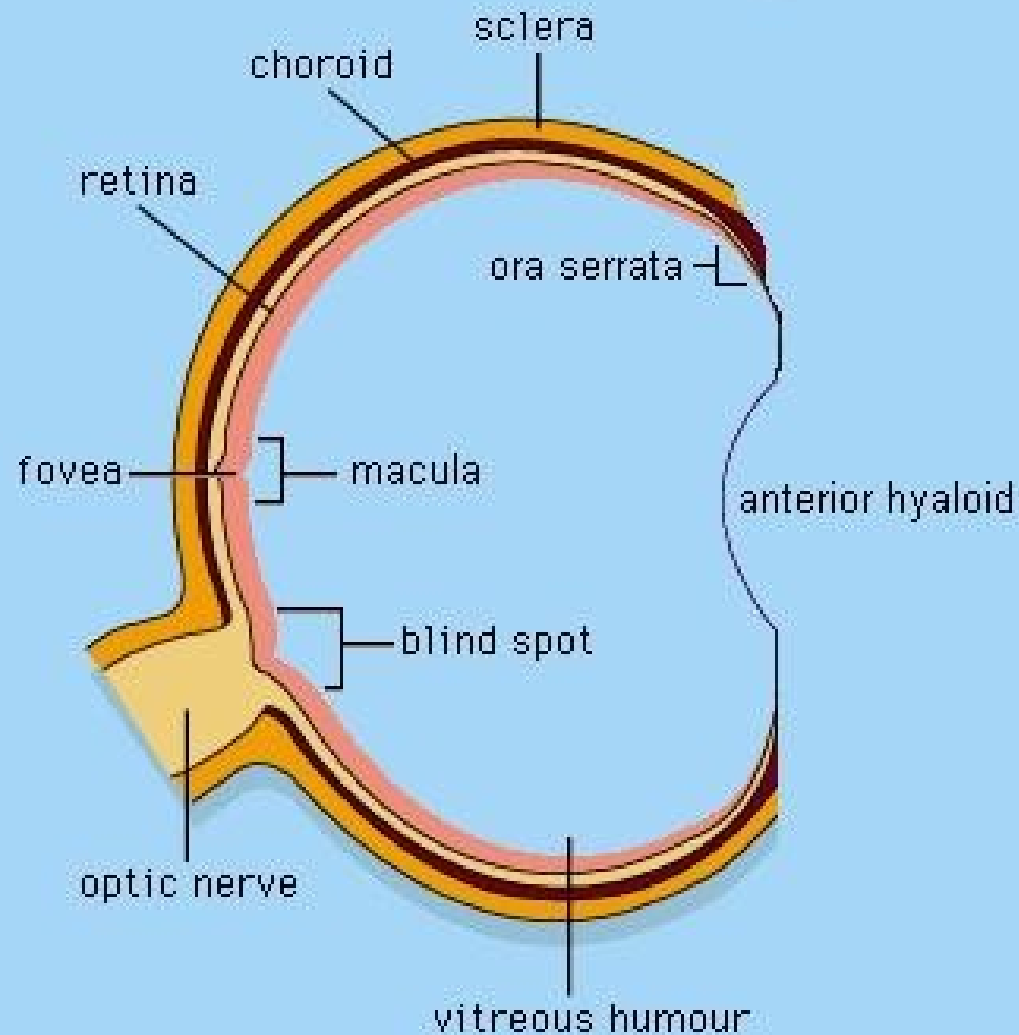


# Posterior segment surgery

MUDr. Veronika Matušková  
Oční klinika FN Brno

Přednosta prof. MUDr. Eva Vlková, CSc.

# The Posterior Segment



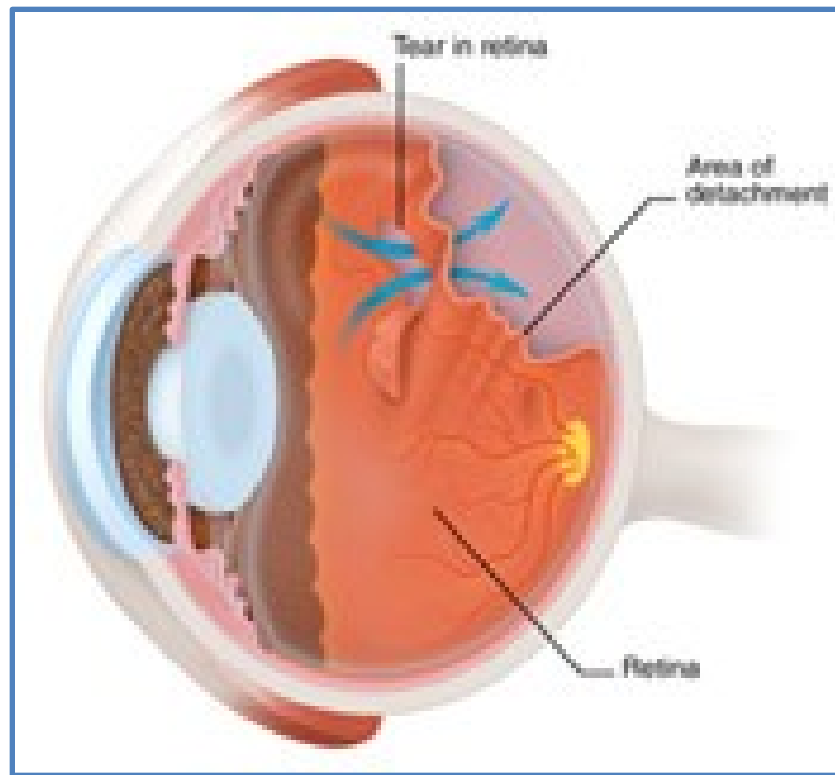
# Retinal detachment

Rhegmatogenous - tear

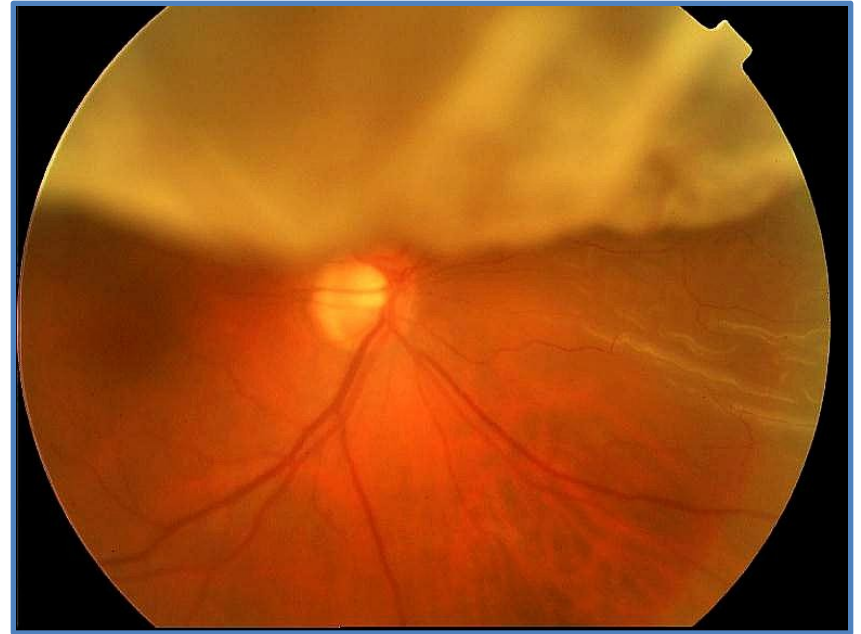
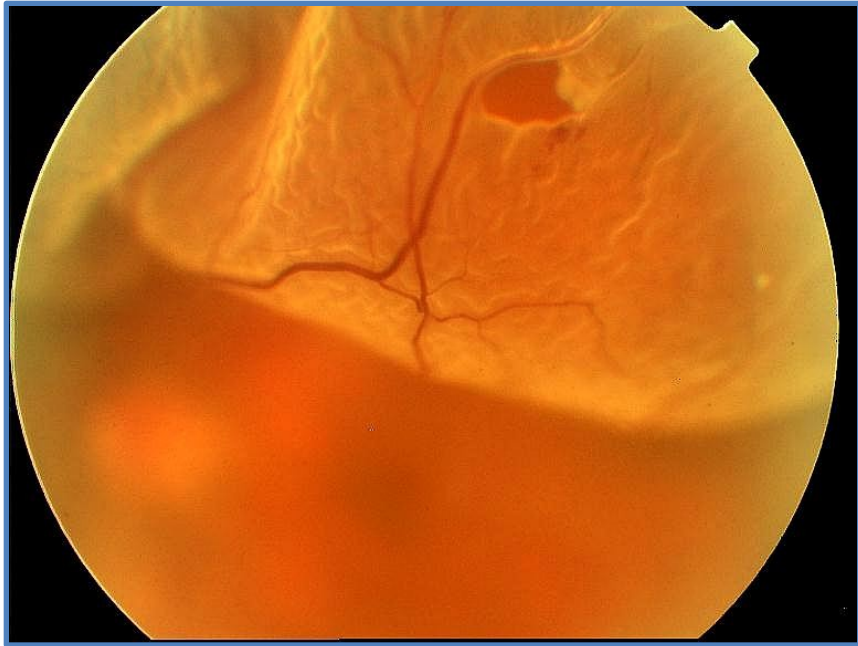
Tractional - traction of corpus vitreum

Serose – production of fluid

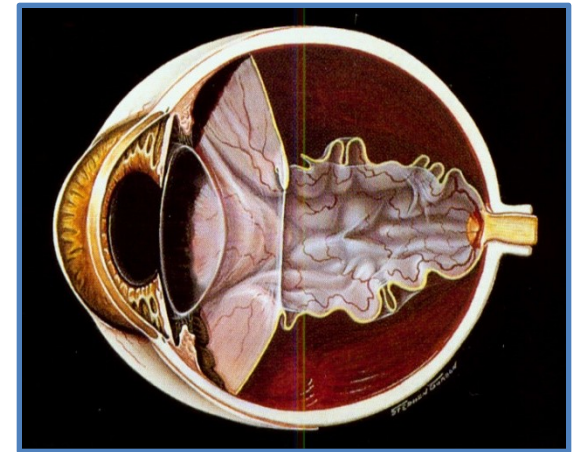
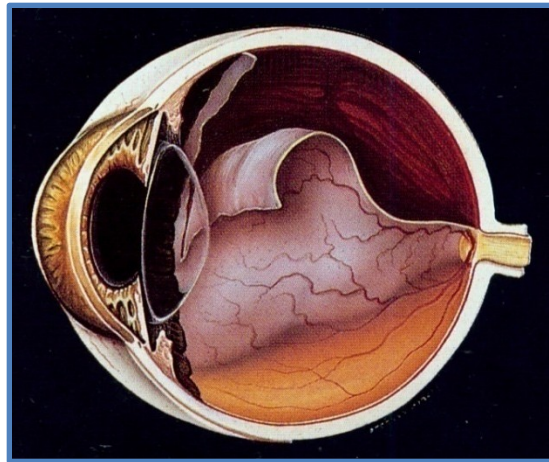
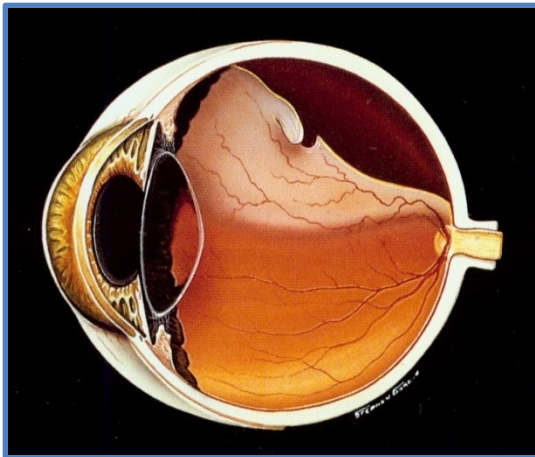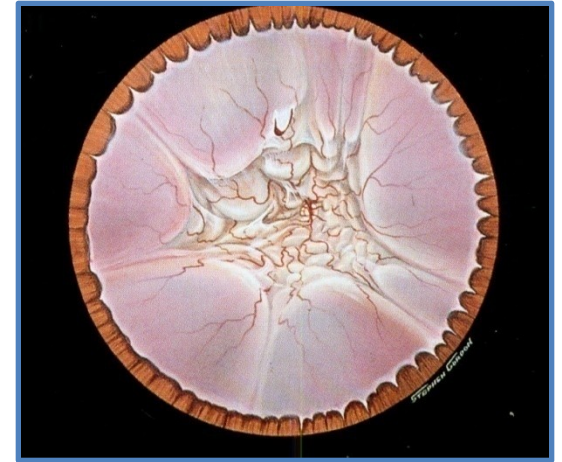
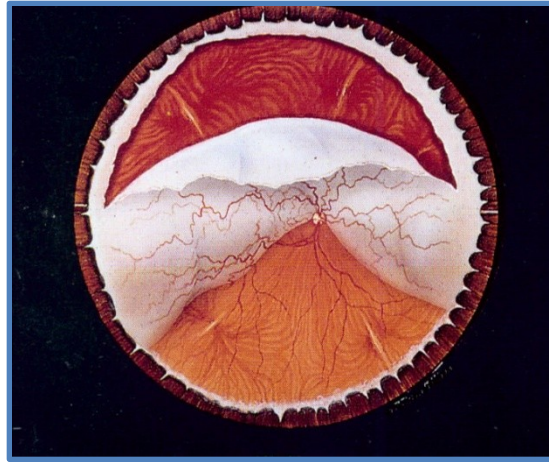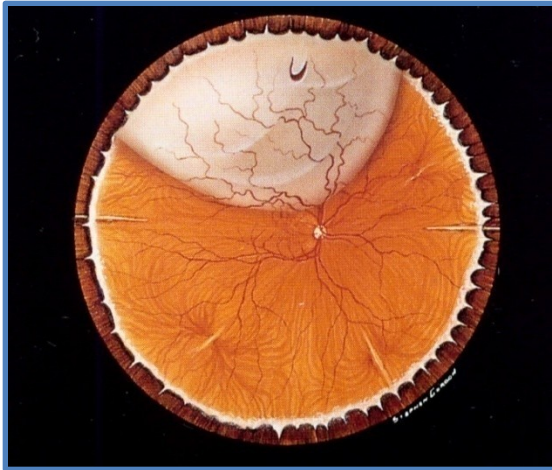
# Retinal detachment



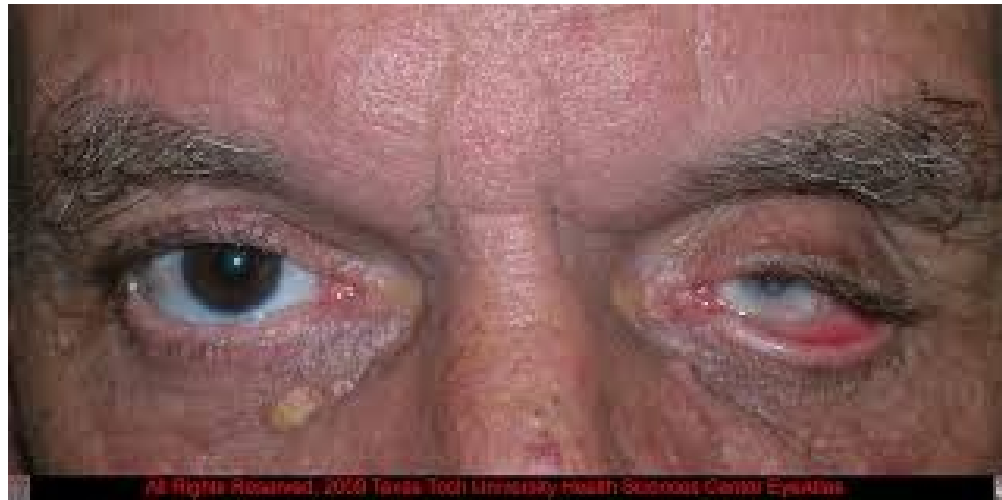# Retinal detachment



# Retinal detachment



# Phtisis bulbi



All Rights Reserved, 2000 Texas Tech University Health Sciences Center EyeNet

# Retinal detachment - symptoms

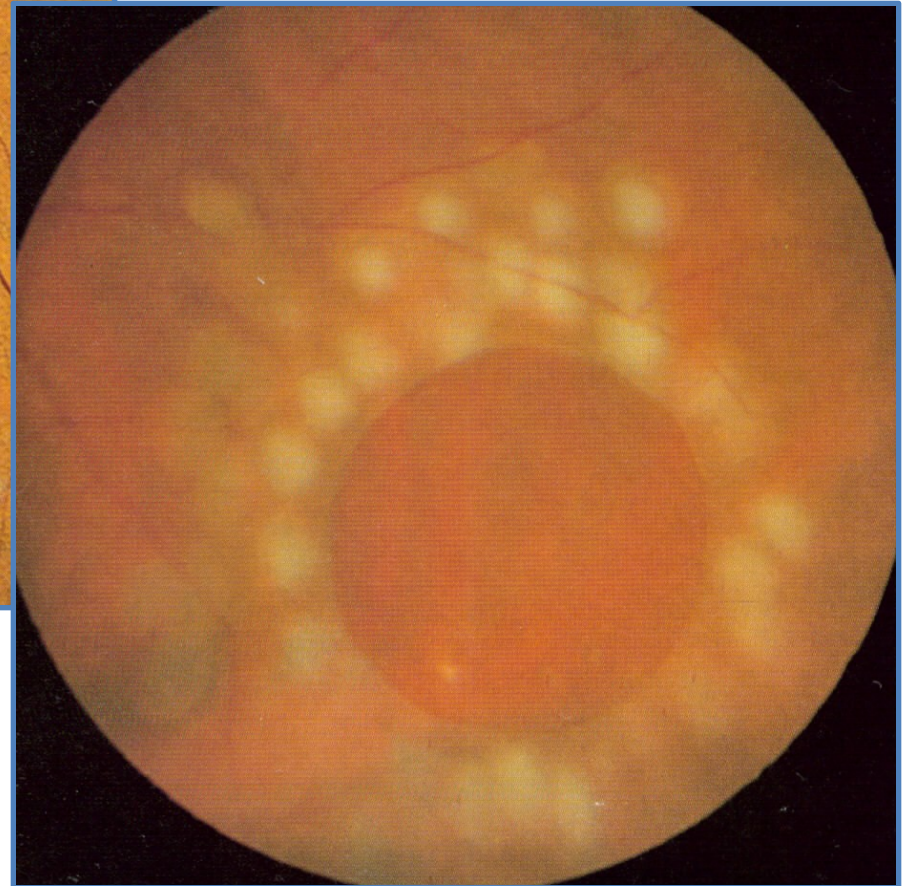
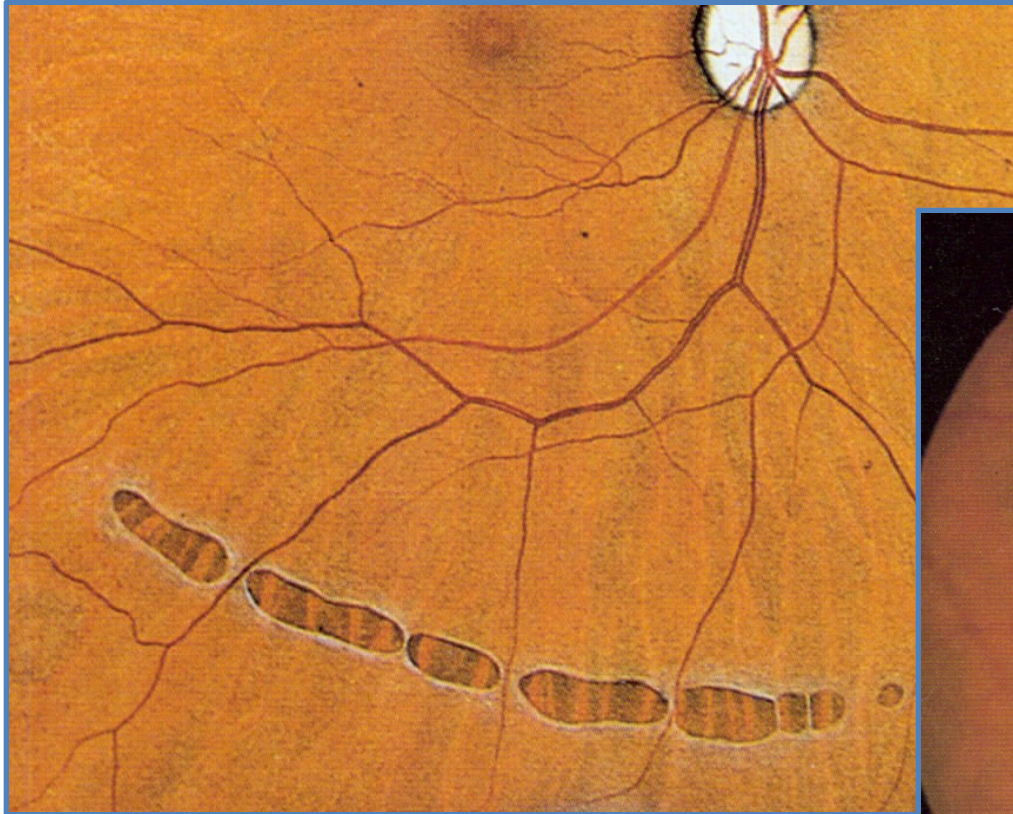
- Fotopsia (flashes)
- Black spots (black snow)
- **Scotoma** (black spot in peripheral visual field)
- Decrease of visual acuity
- Metamorfopsia



Surgery:

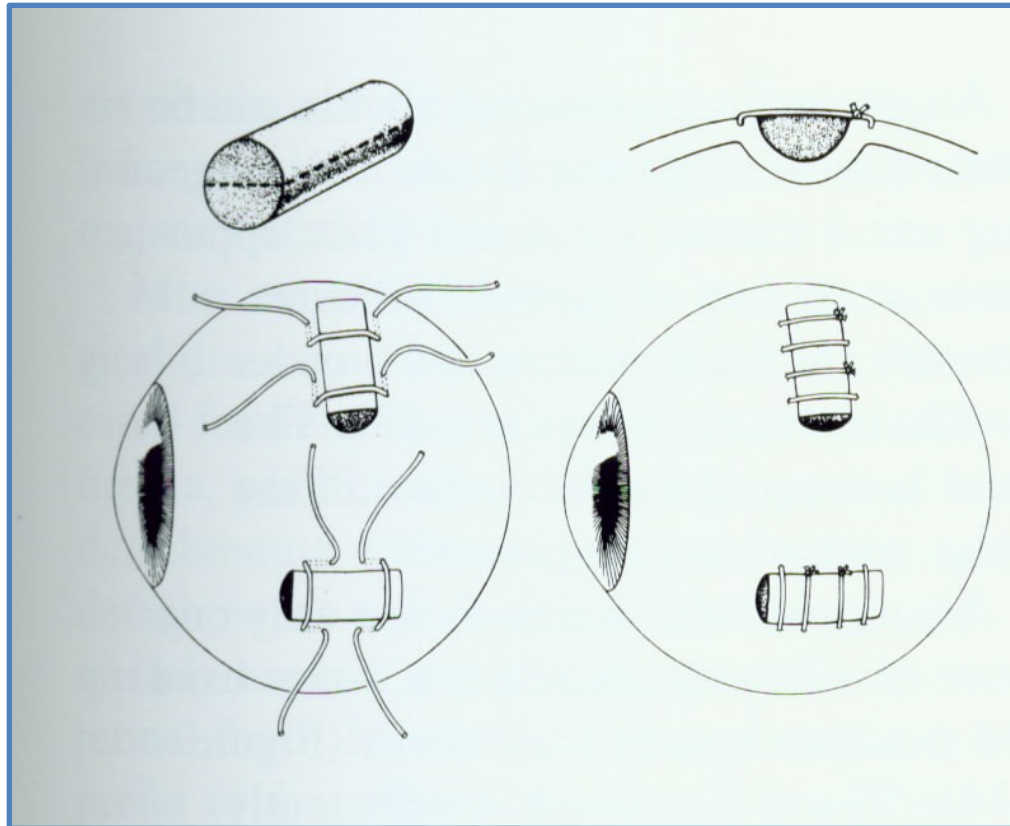
**Close the tear**

# Laser photocoagulation

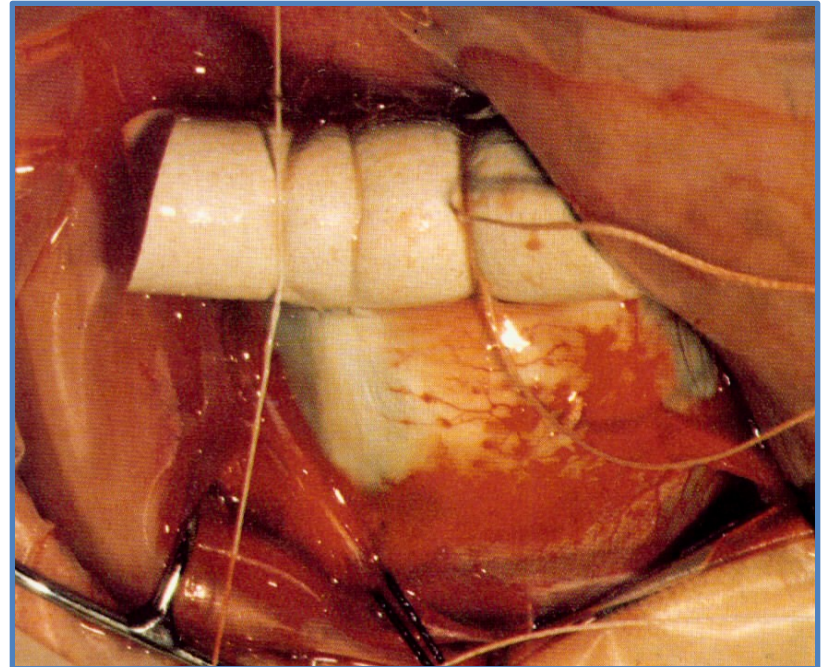
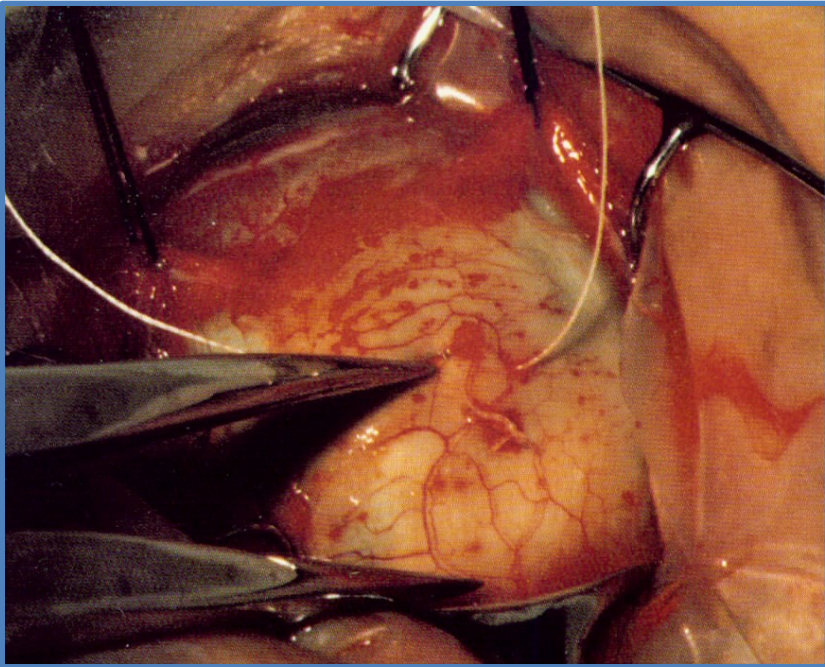


# Extrabulbar operations

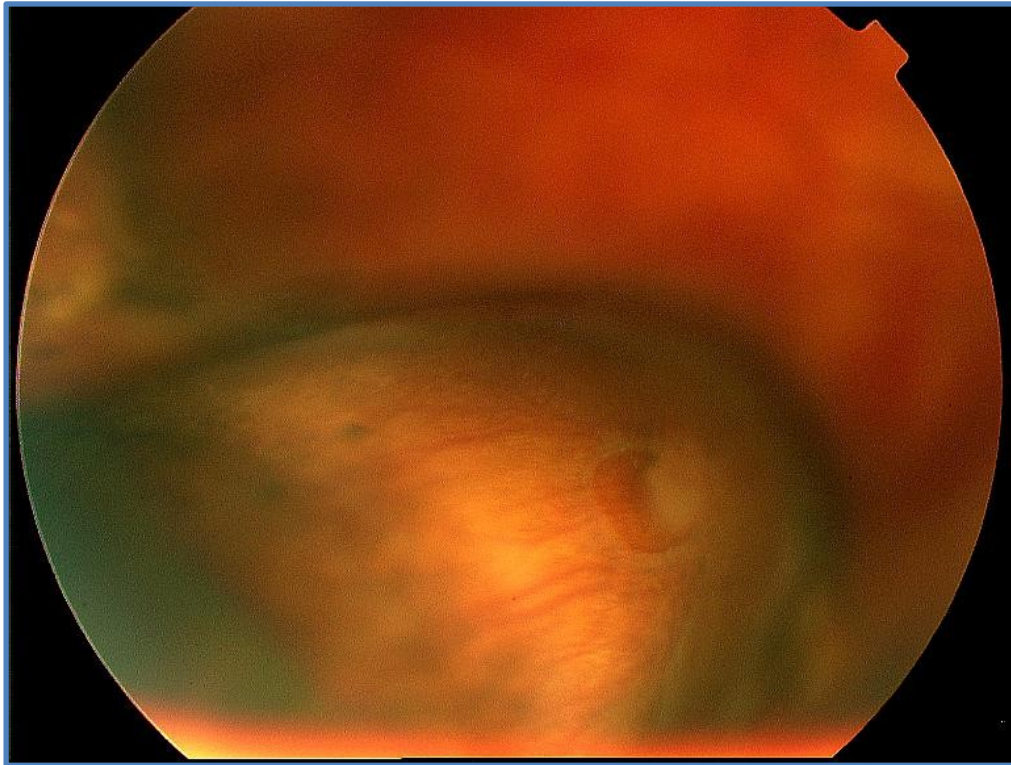
## Cryotherapy and plombage



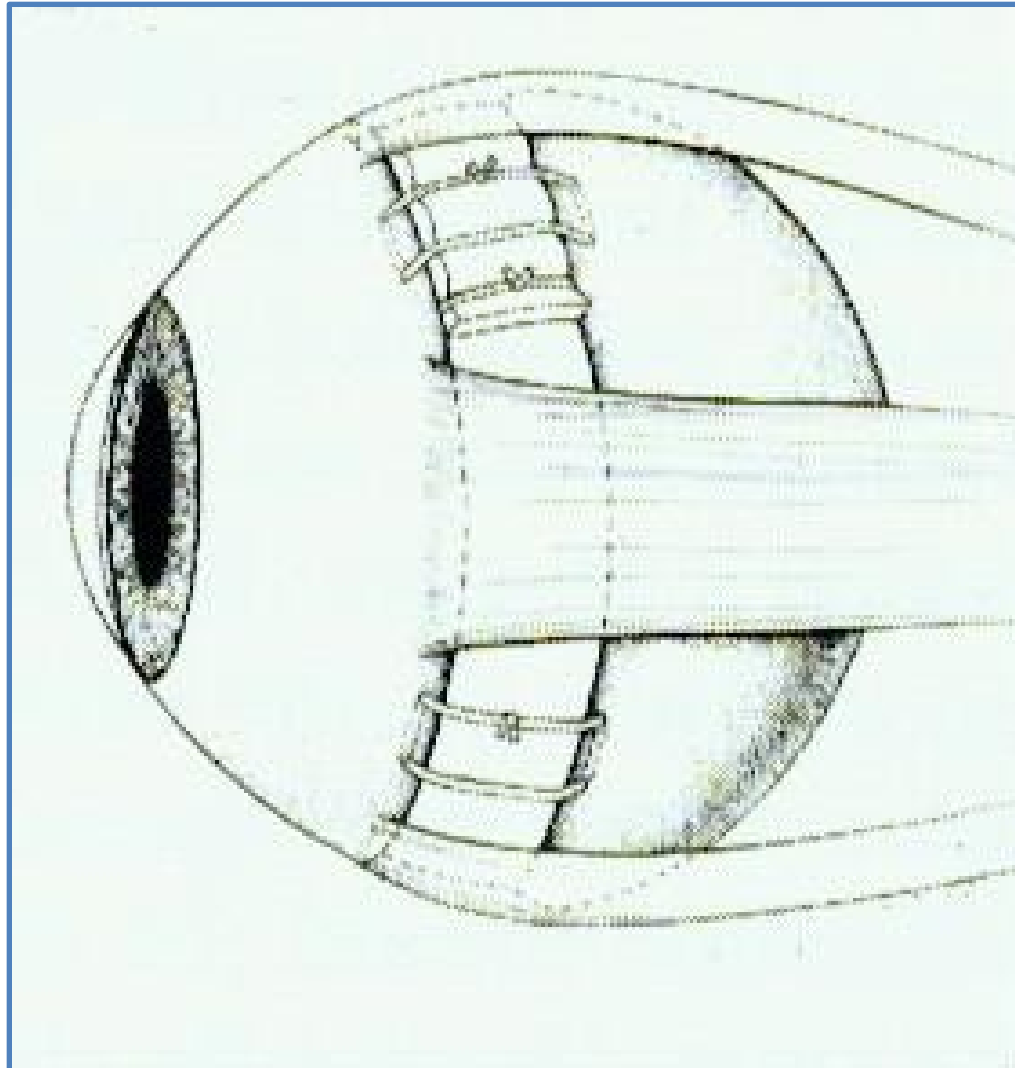
# Plombage



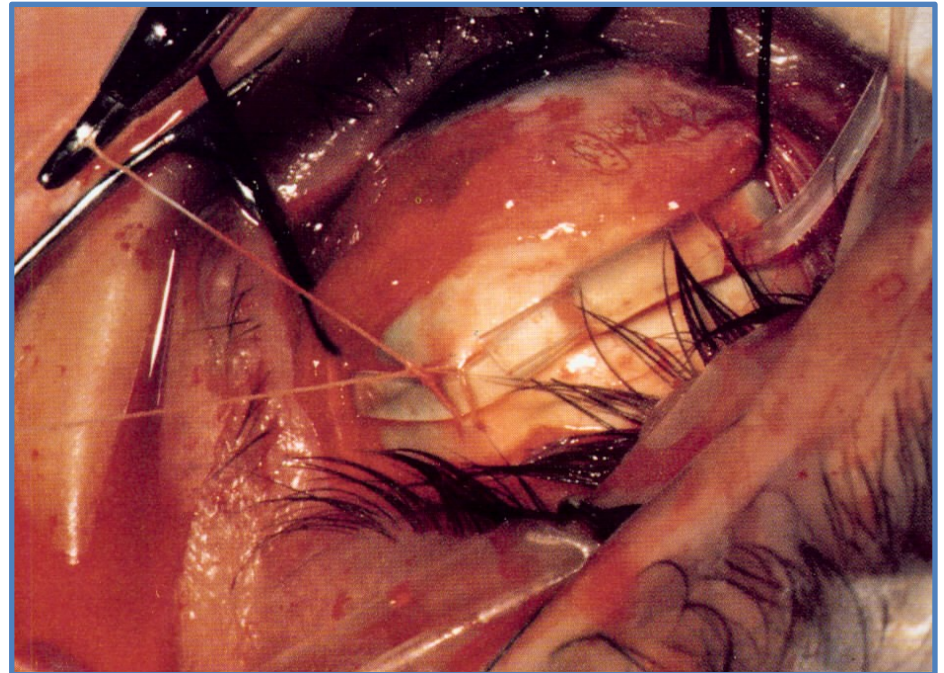
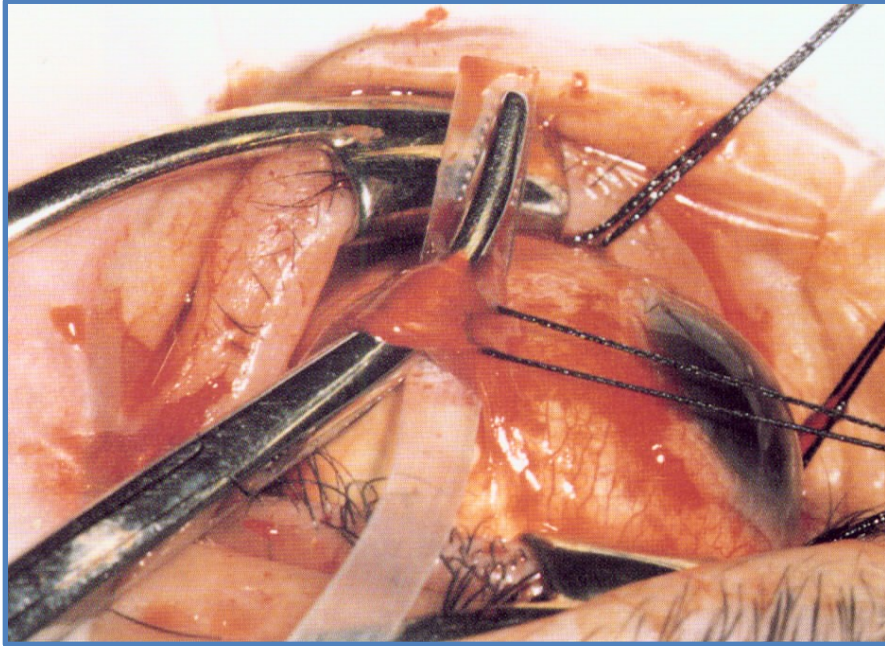
# Plombage



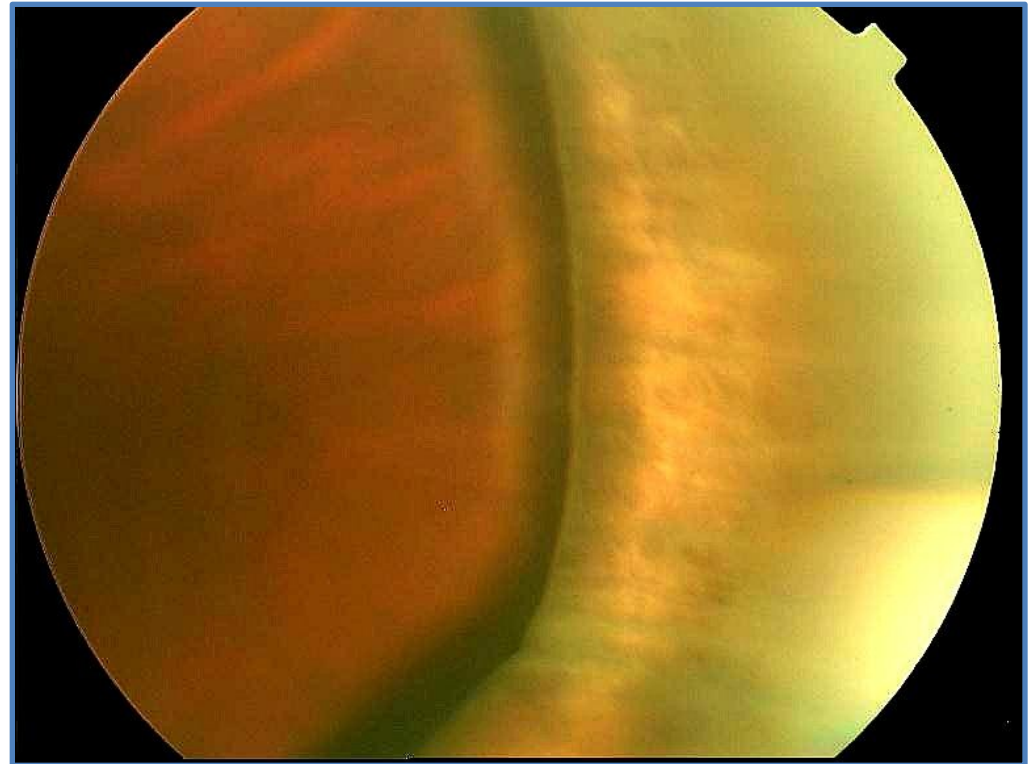
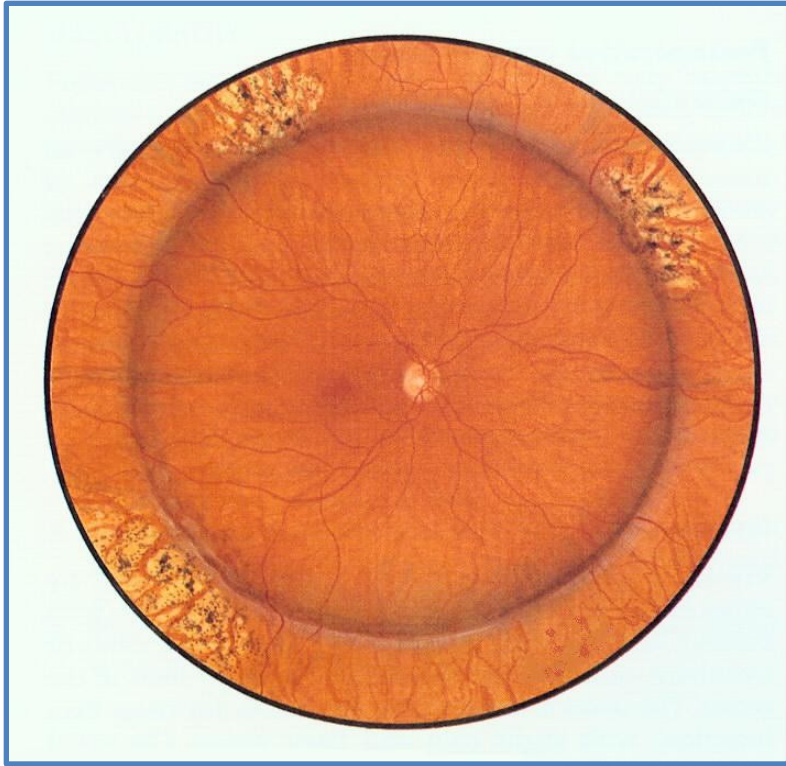
# Cerclage



# Cerclage

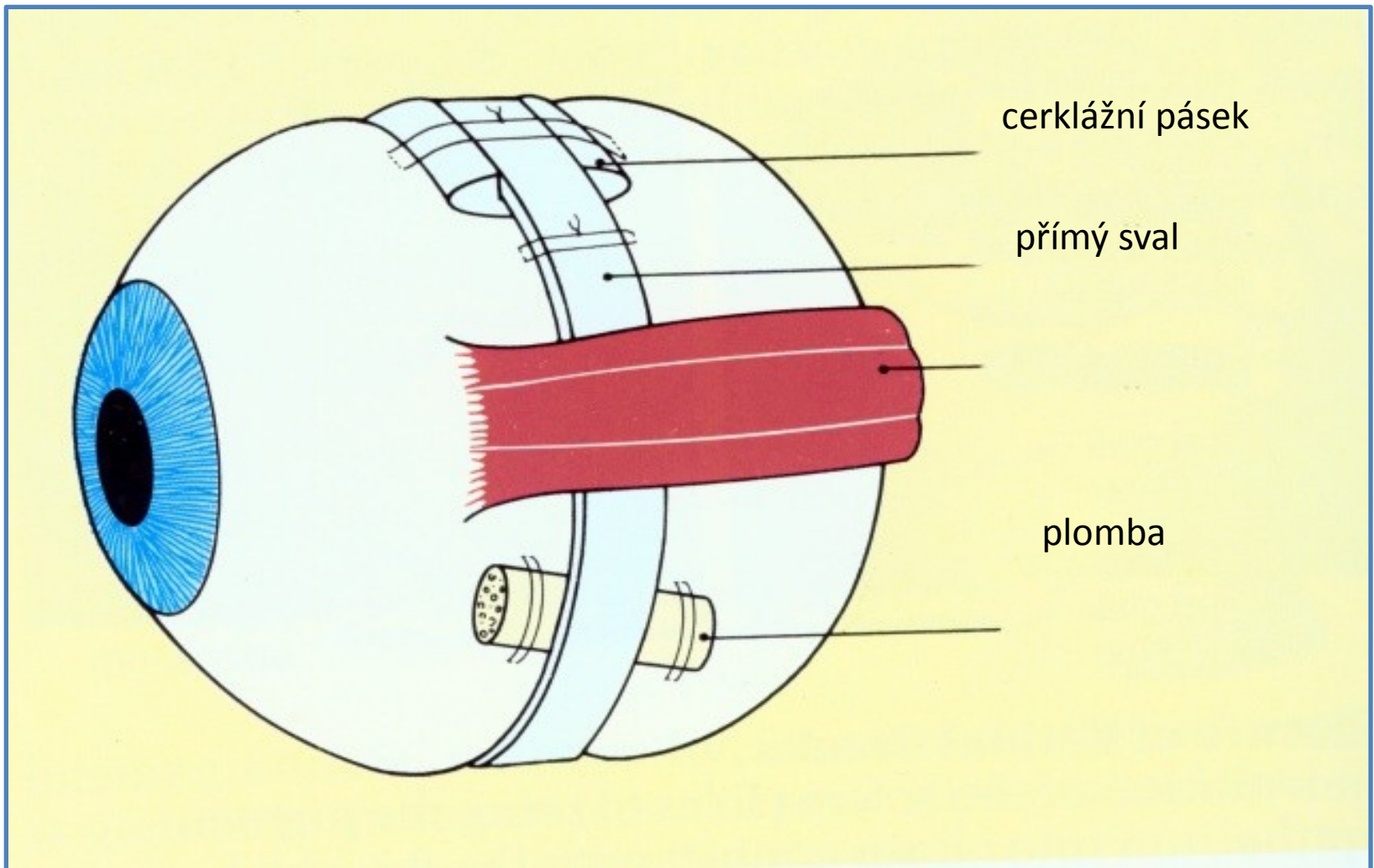


# Cerclage

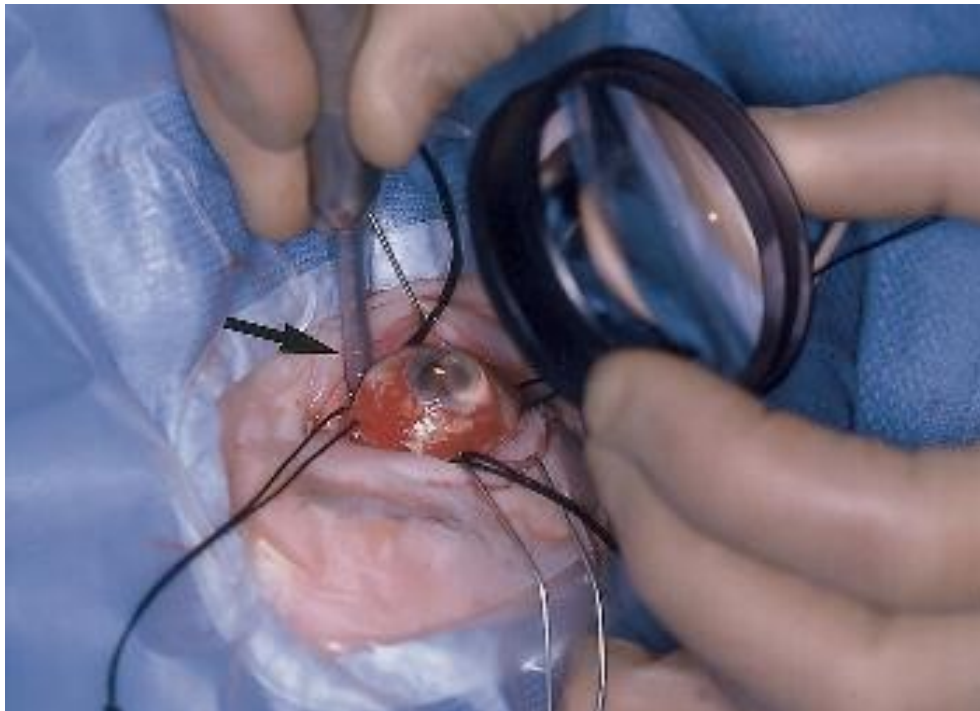




# Extrabulbar surgery



# Cryotherapy - development of chorioretinal adhesion (scar)

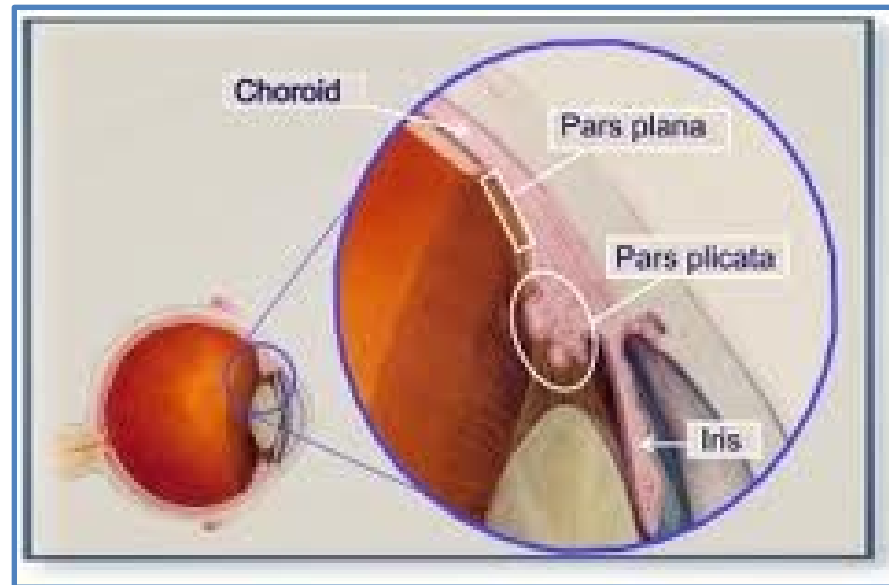


# Complications

- Fenestra is not closed
- PVR - proliferative vitreoretinopathy

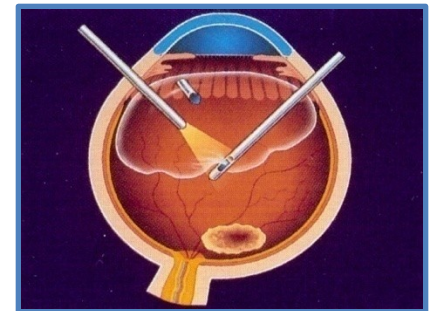
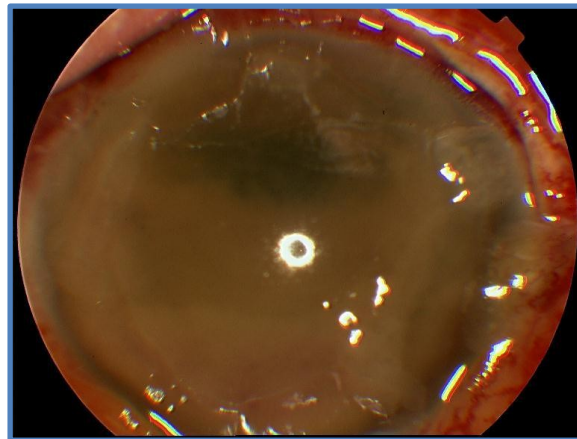
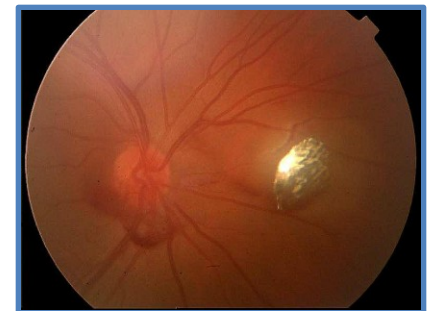
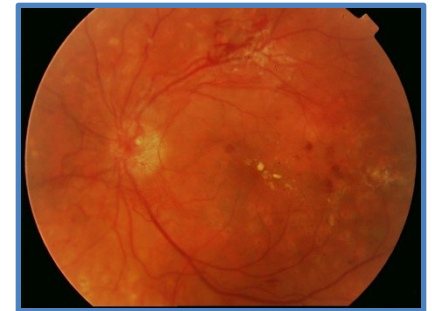# PPV

- Pars plana vitrektomie

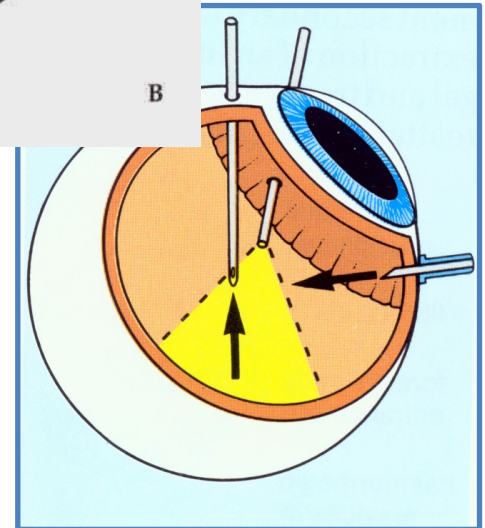
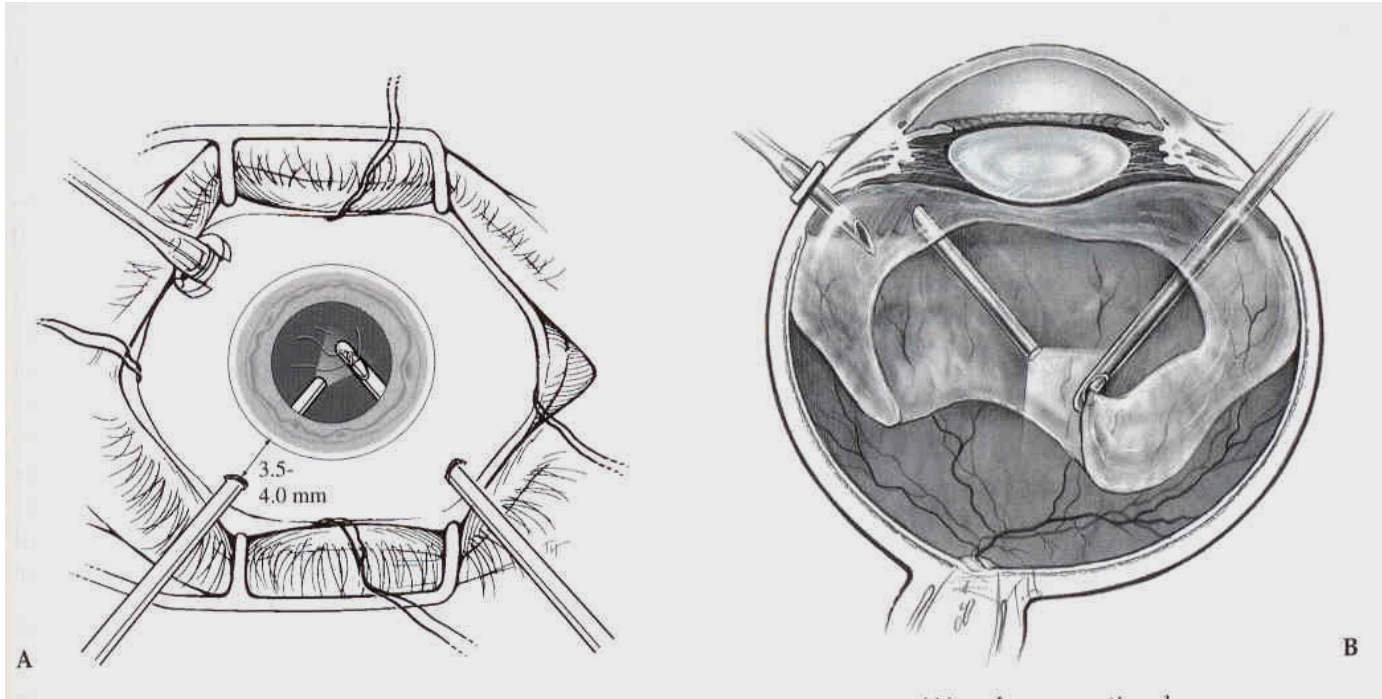


# Pars plana vitrectomy

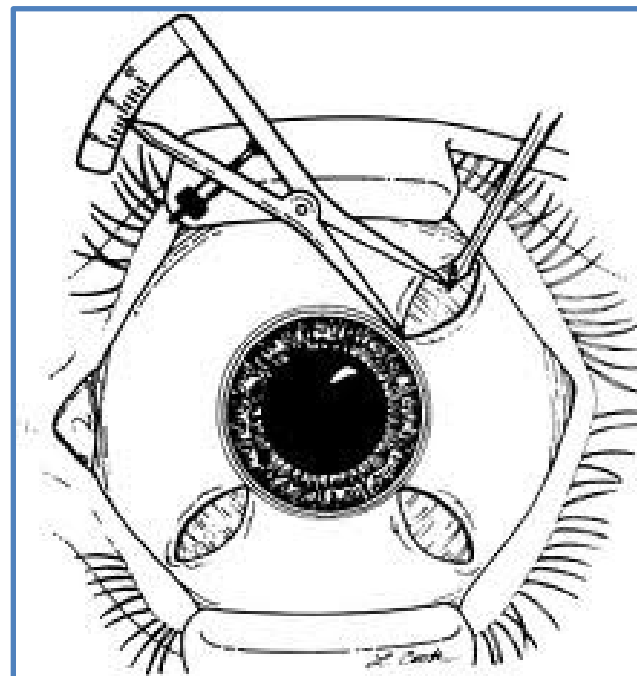
- Haemophthalmus
- PDR
- Retinal detachment
- Complications of cataract surgery
- Posterior luxation of lens
- Foreign intraocular body
- Endophthalmitis



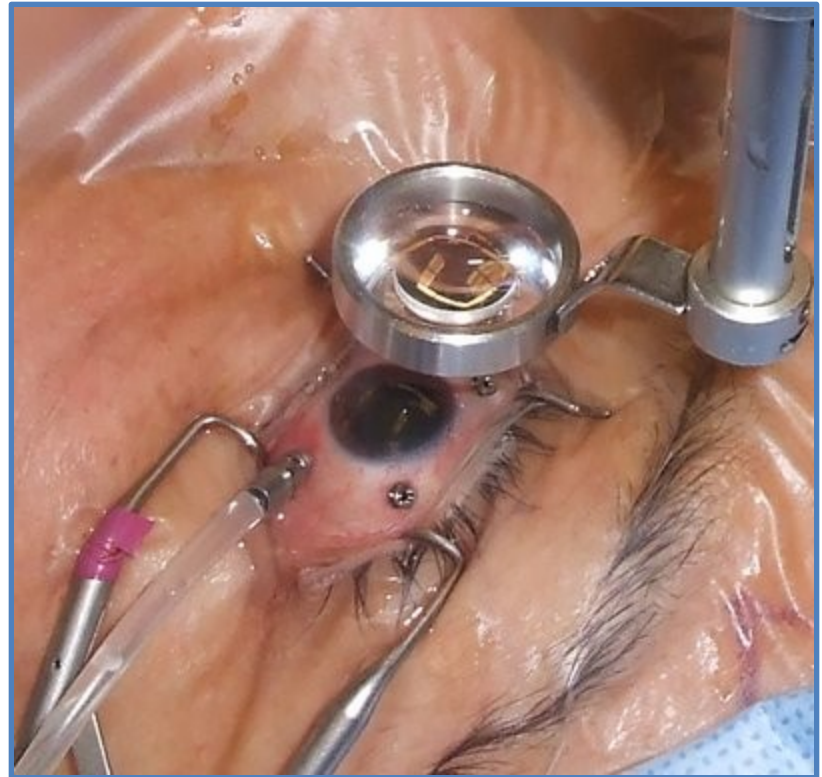
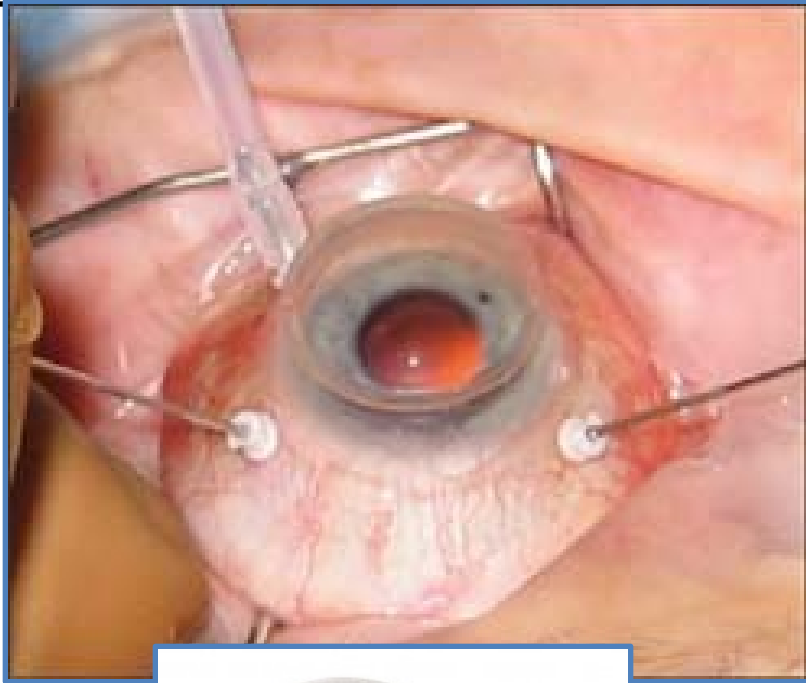
# Pars plana vitrectomy -PPV



# PPV – pars plana

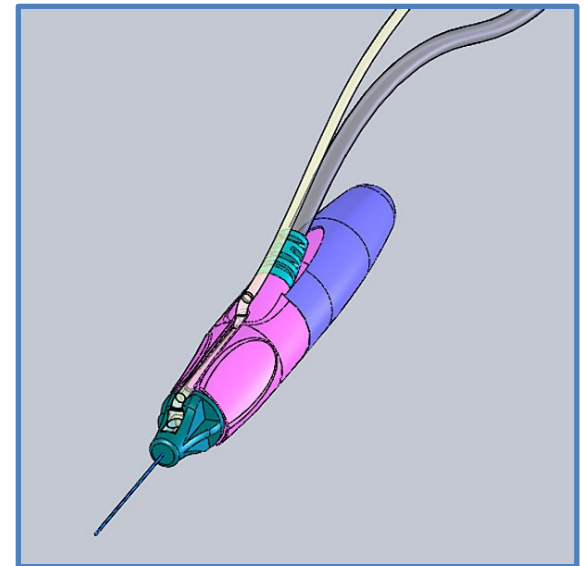
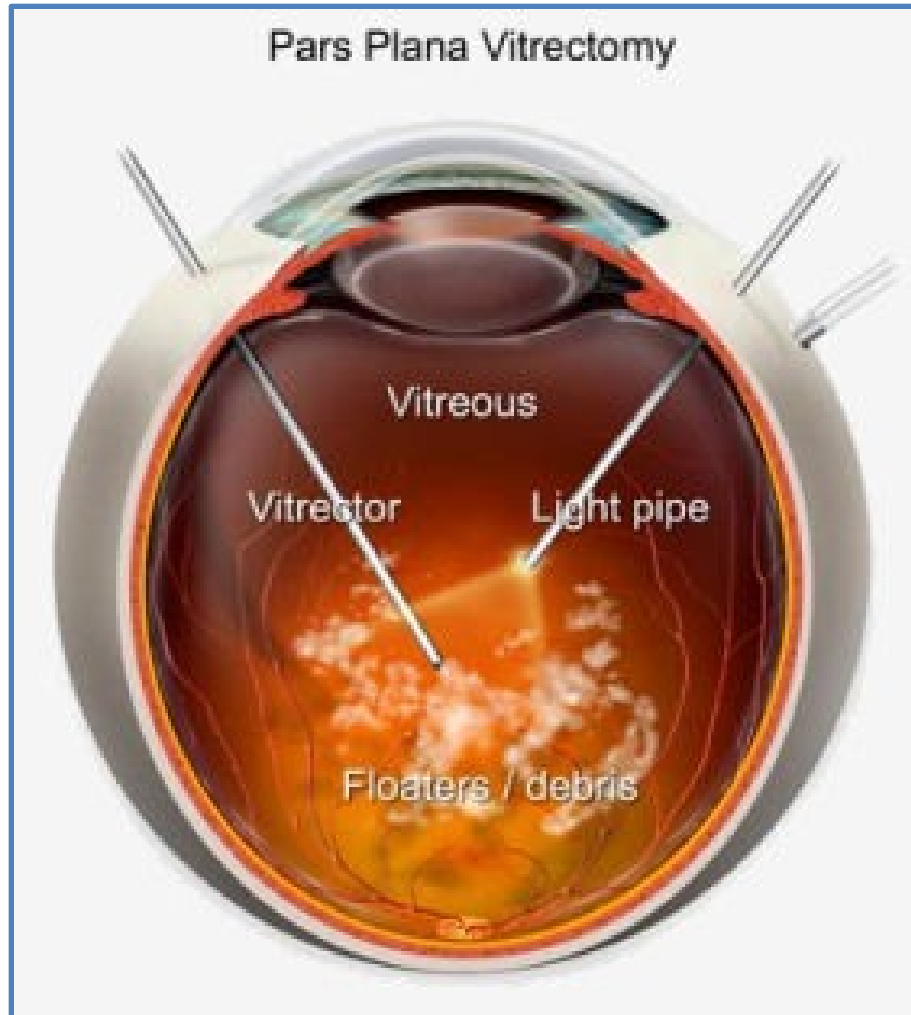


# PPV



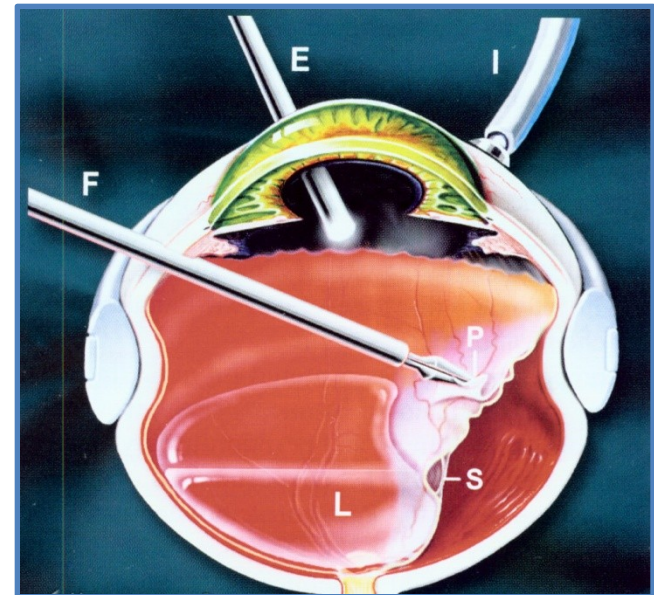
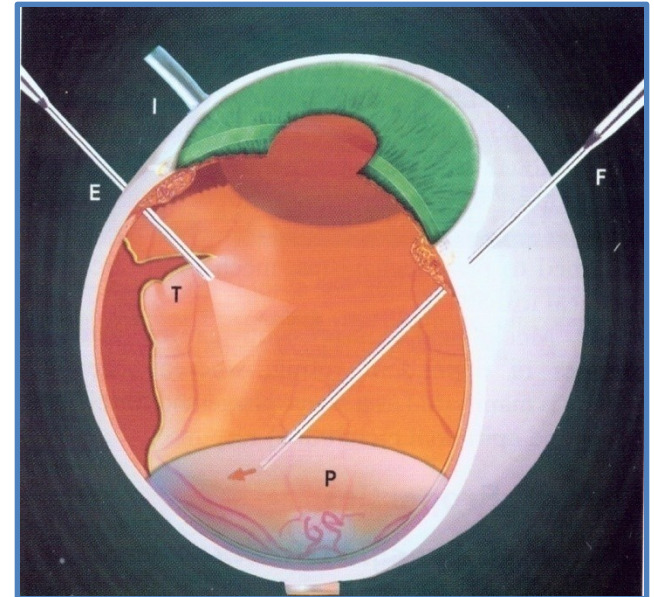


# PPV

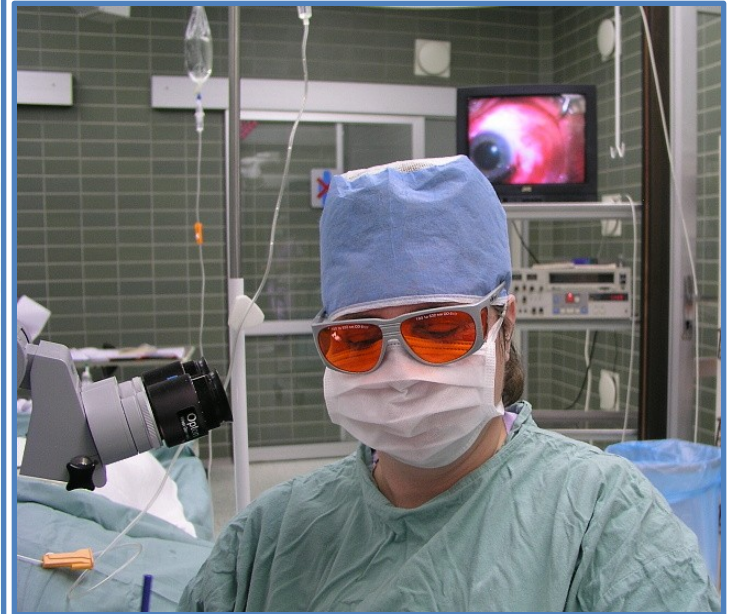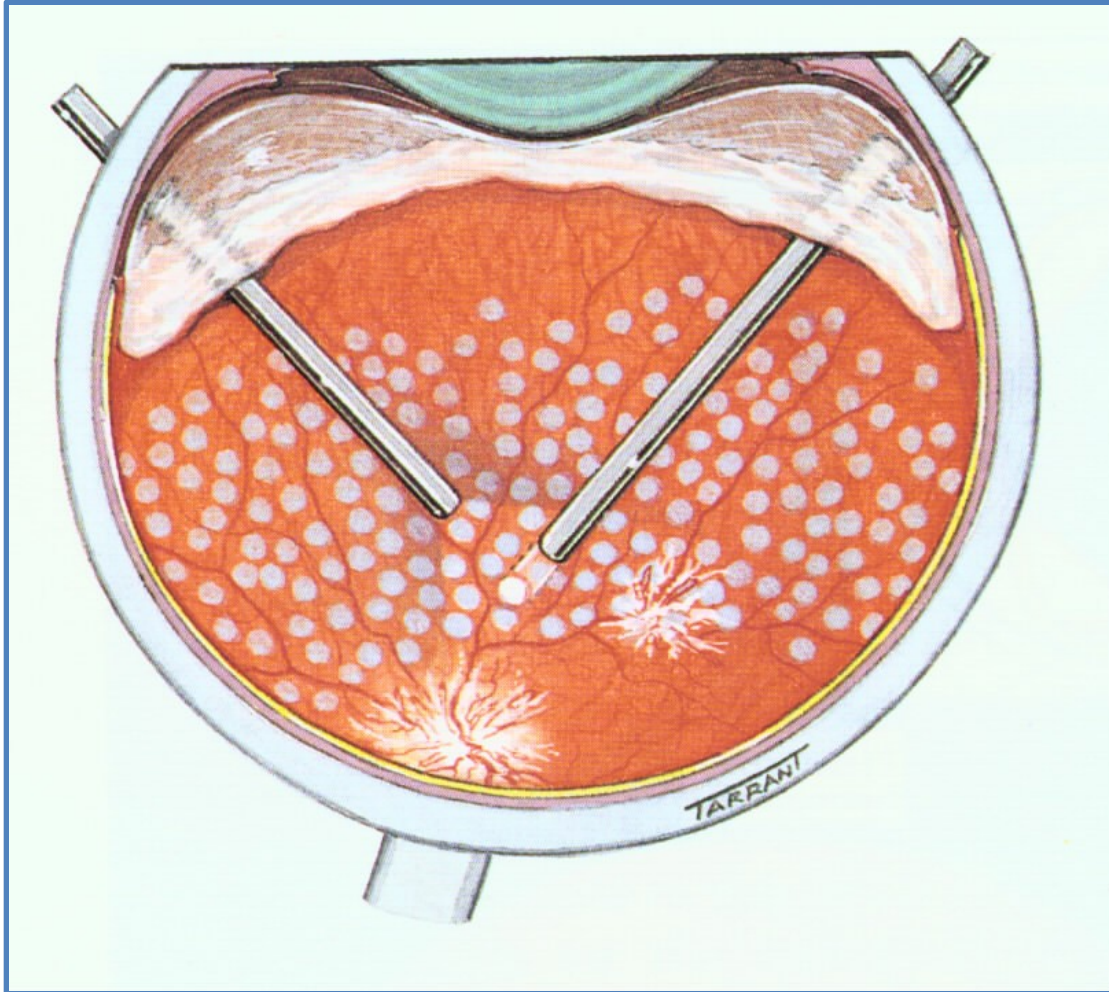


# Internal tamponade

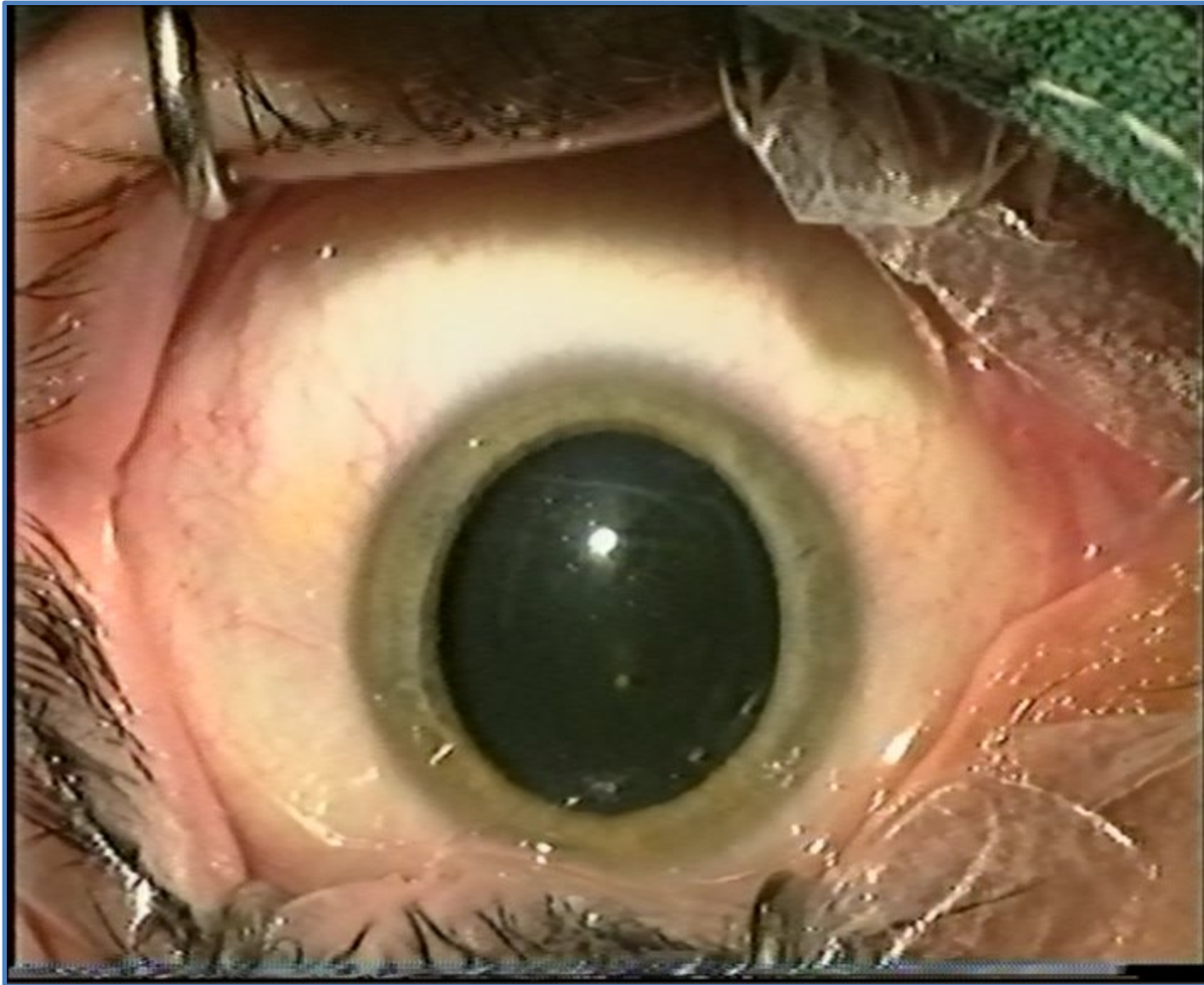
- a) Infusion solution
- b) Silicone oil
- c) Gas ( C3F8, SF6)



# Endolaser

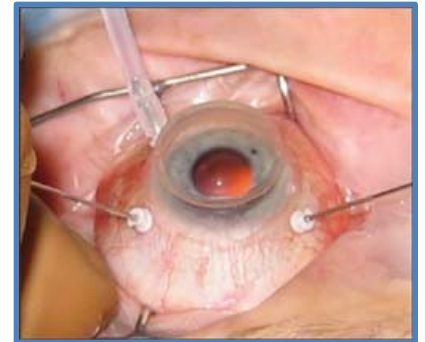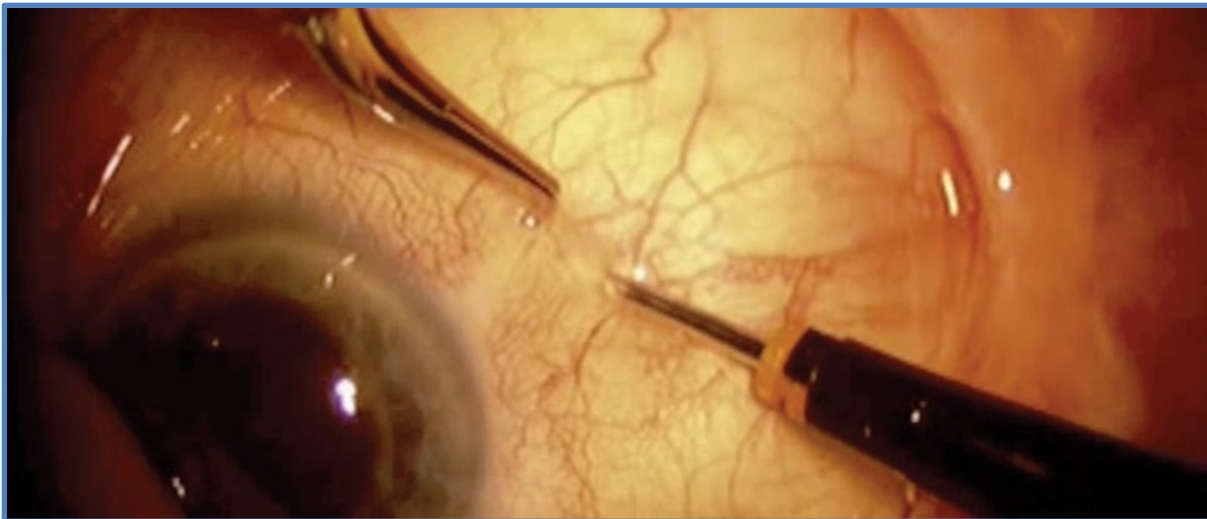
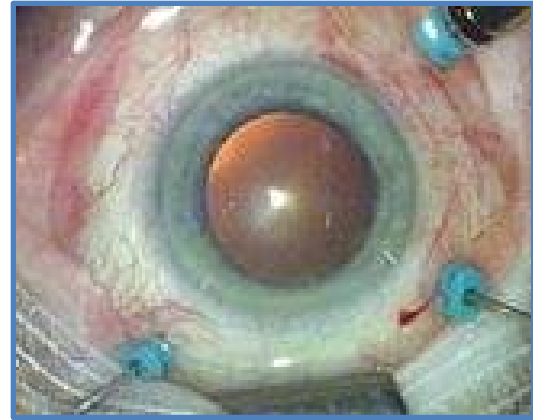


# PPV-video

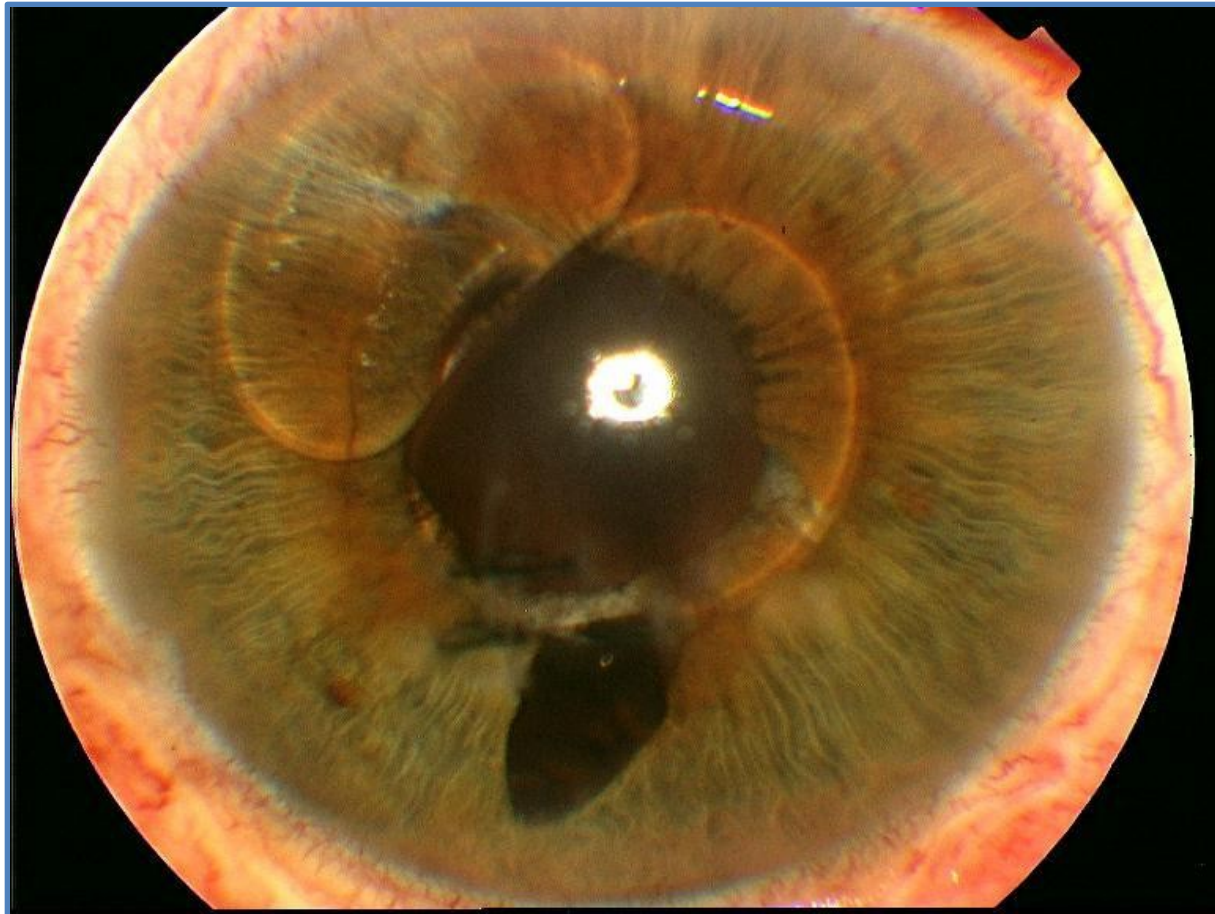


# PPV -23 or 25 G

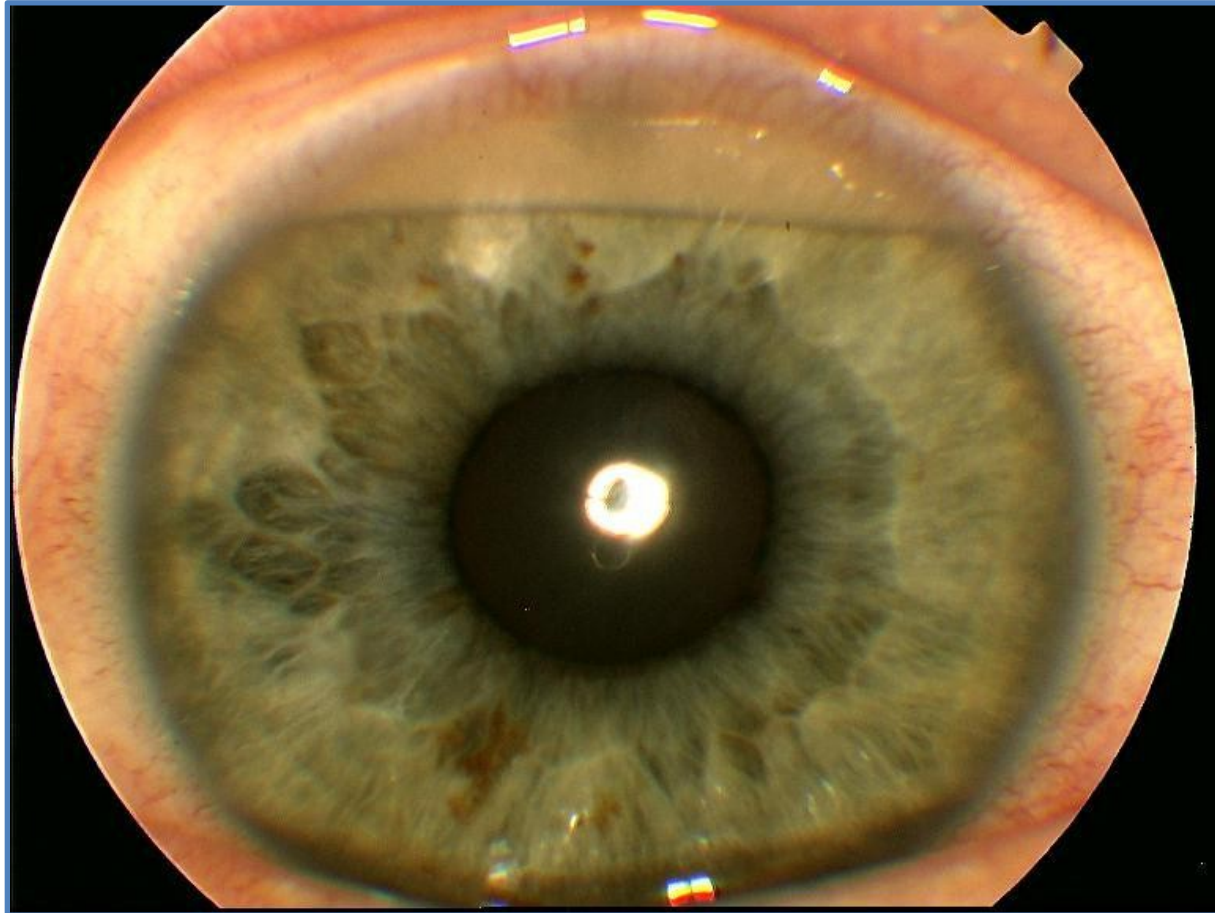
- Sutureless surgery
- 23 G (0,57 mm)
- 20 G (0,45 mm)



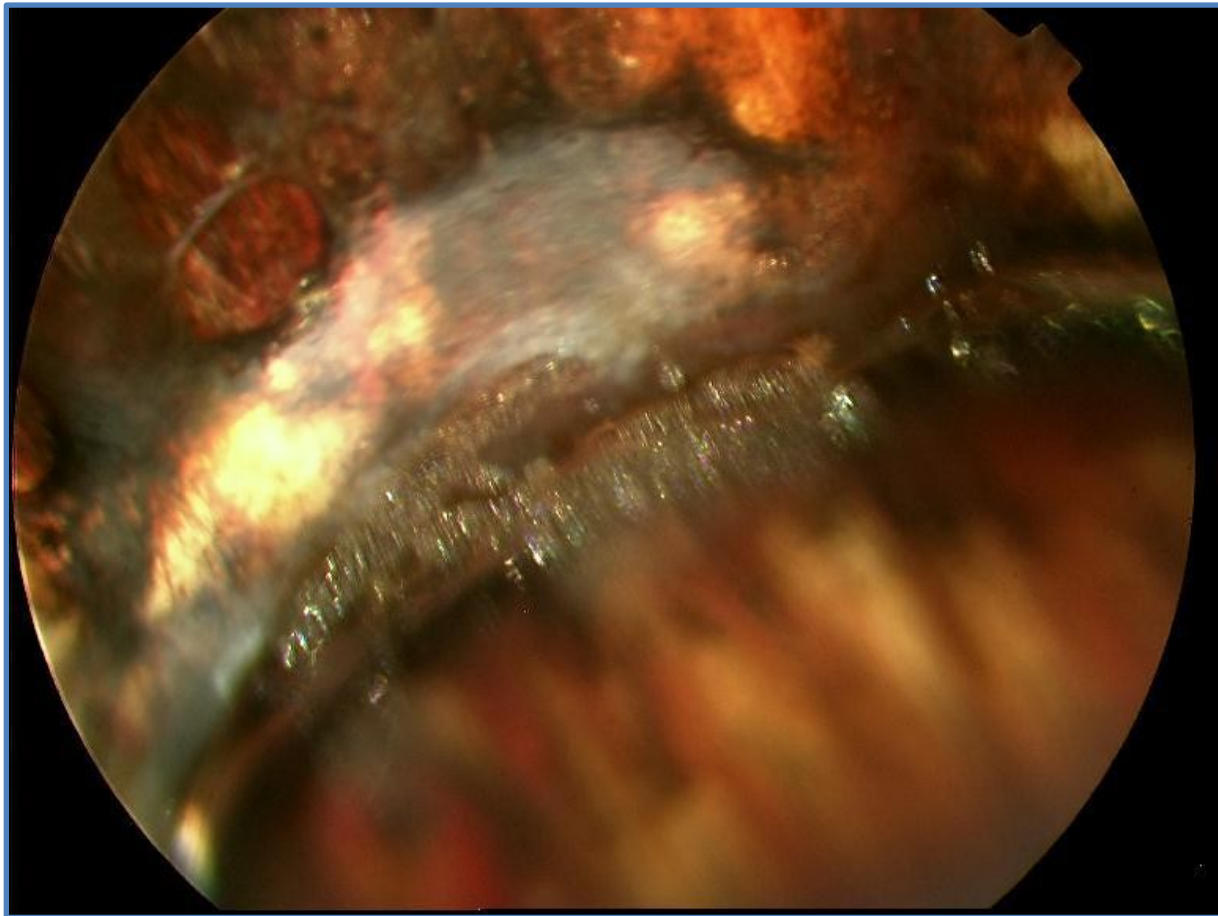
# Complications



# Complications

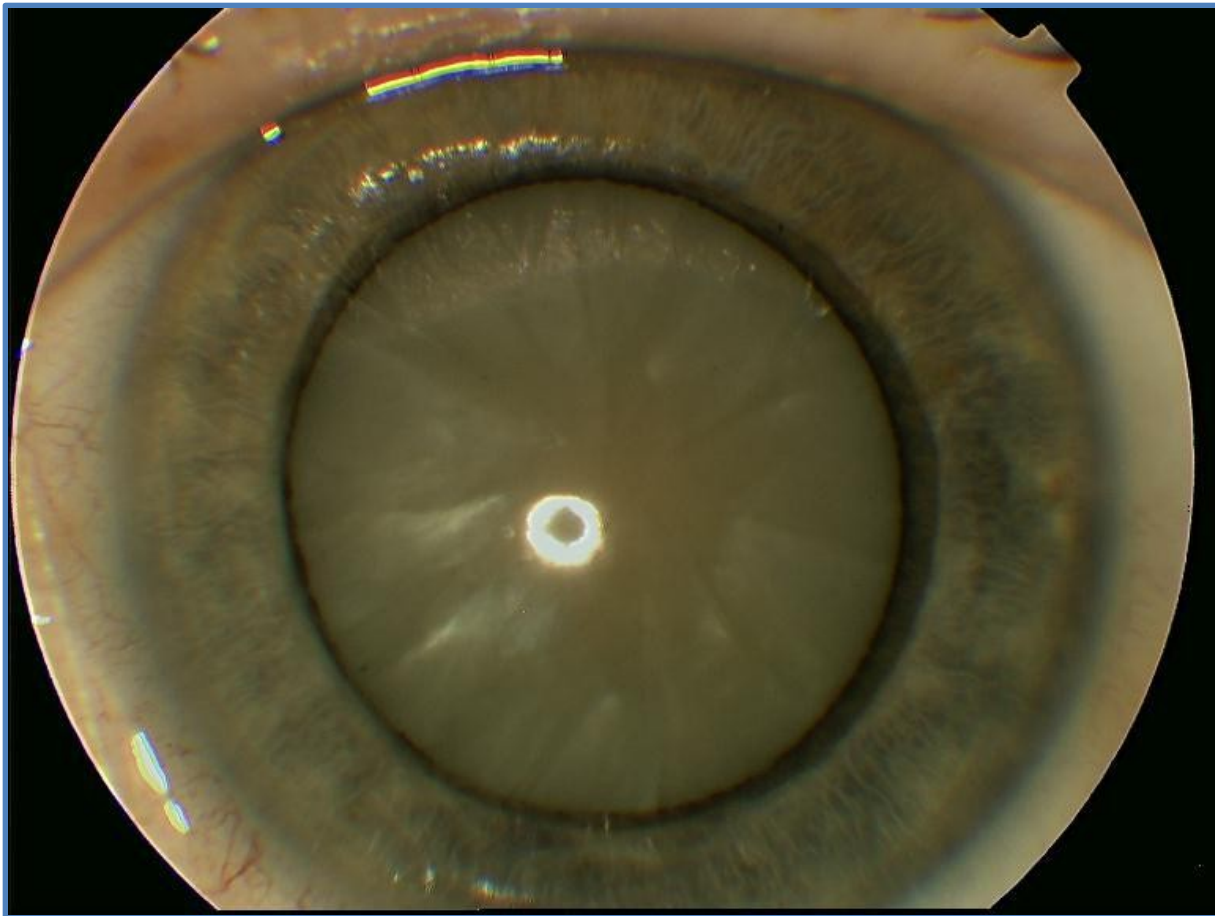


# Complications - emulsification

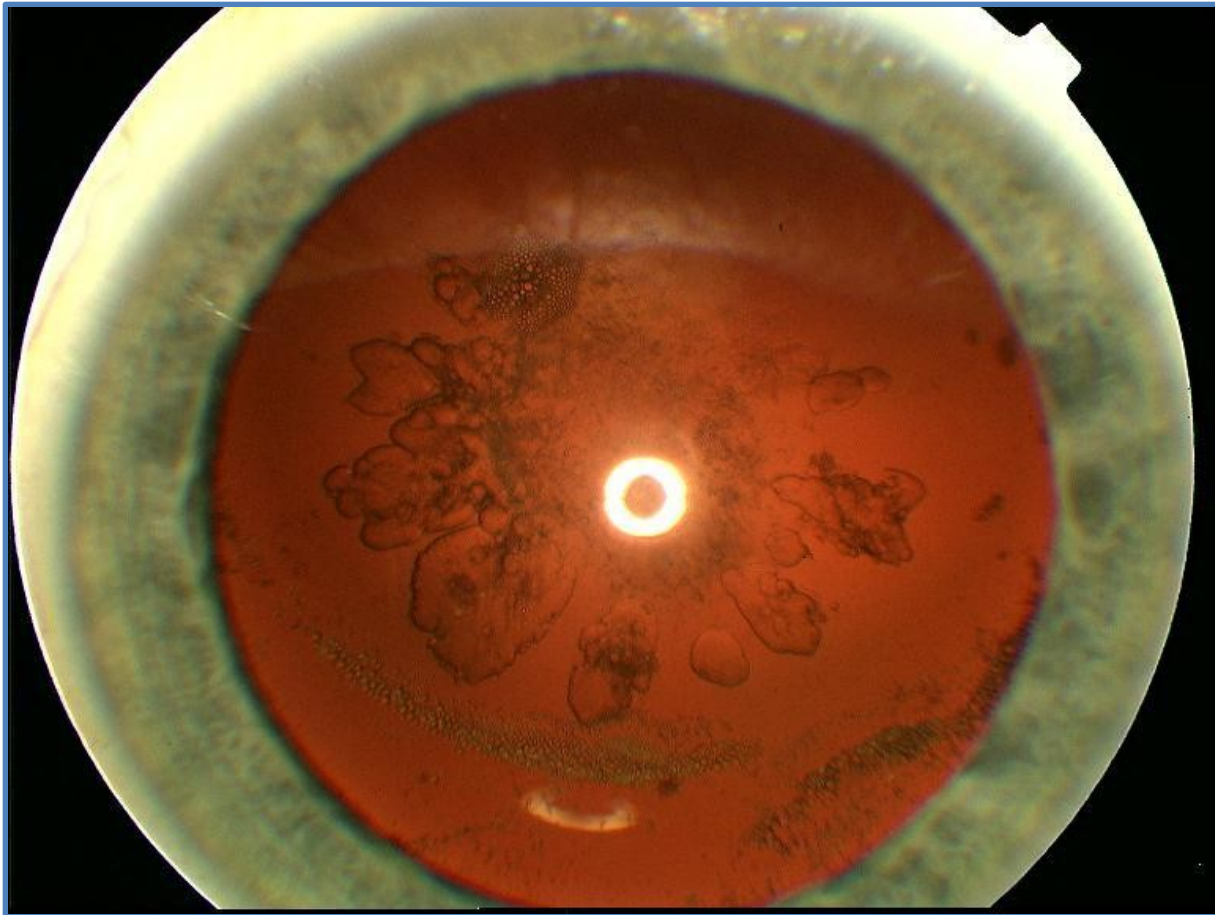




# Complications

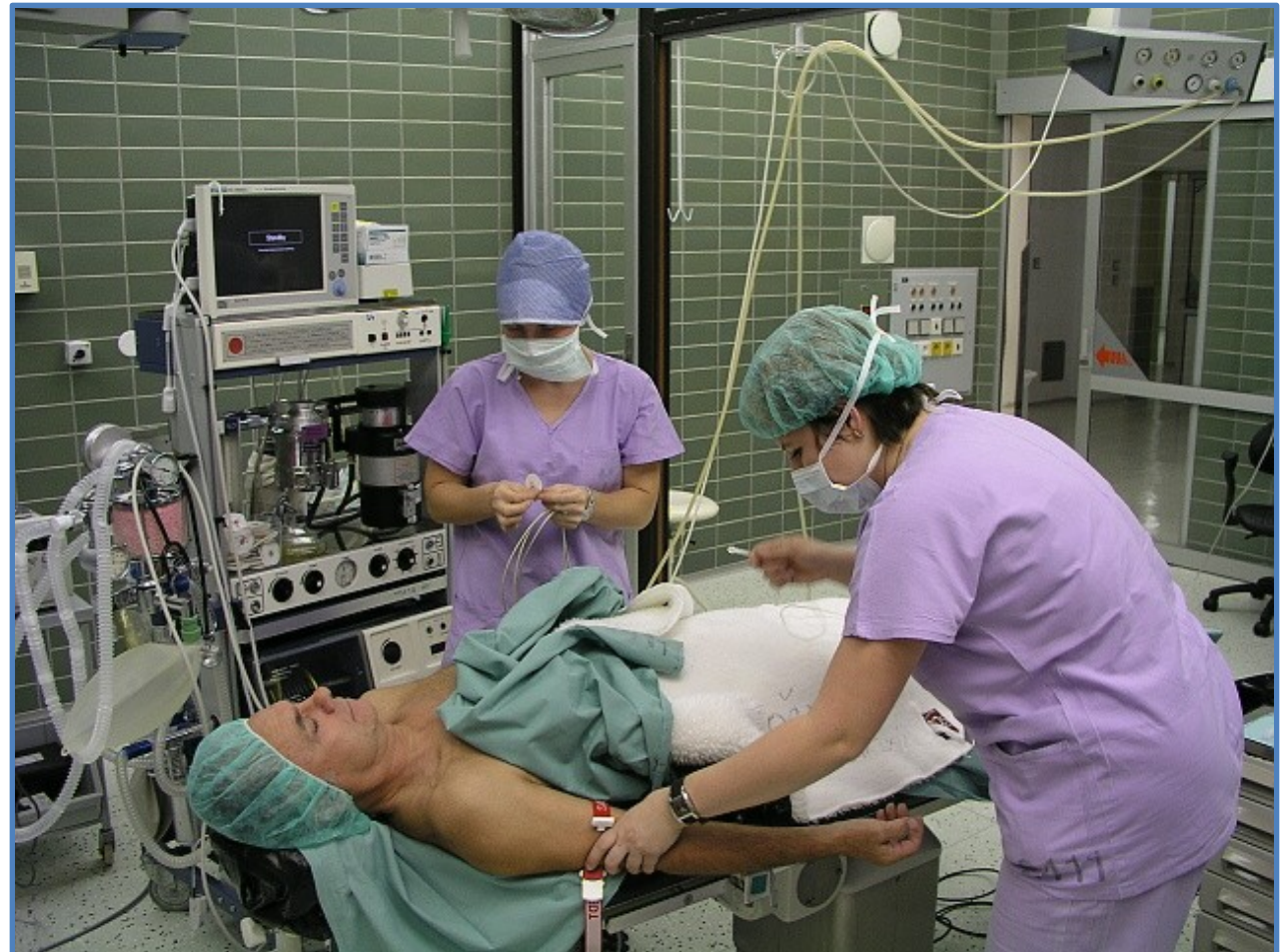

# Complications

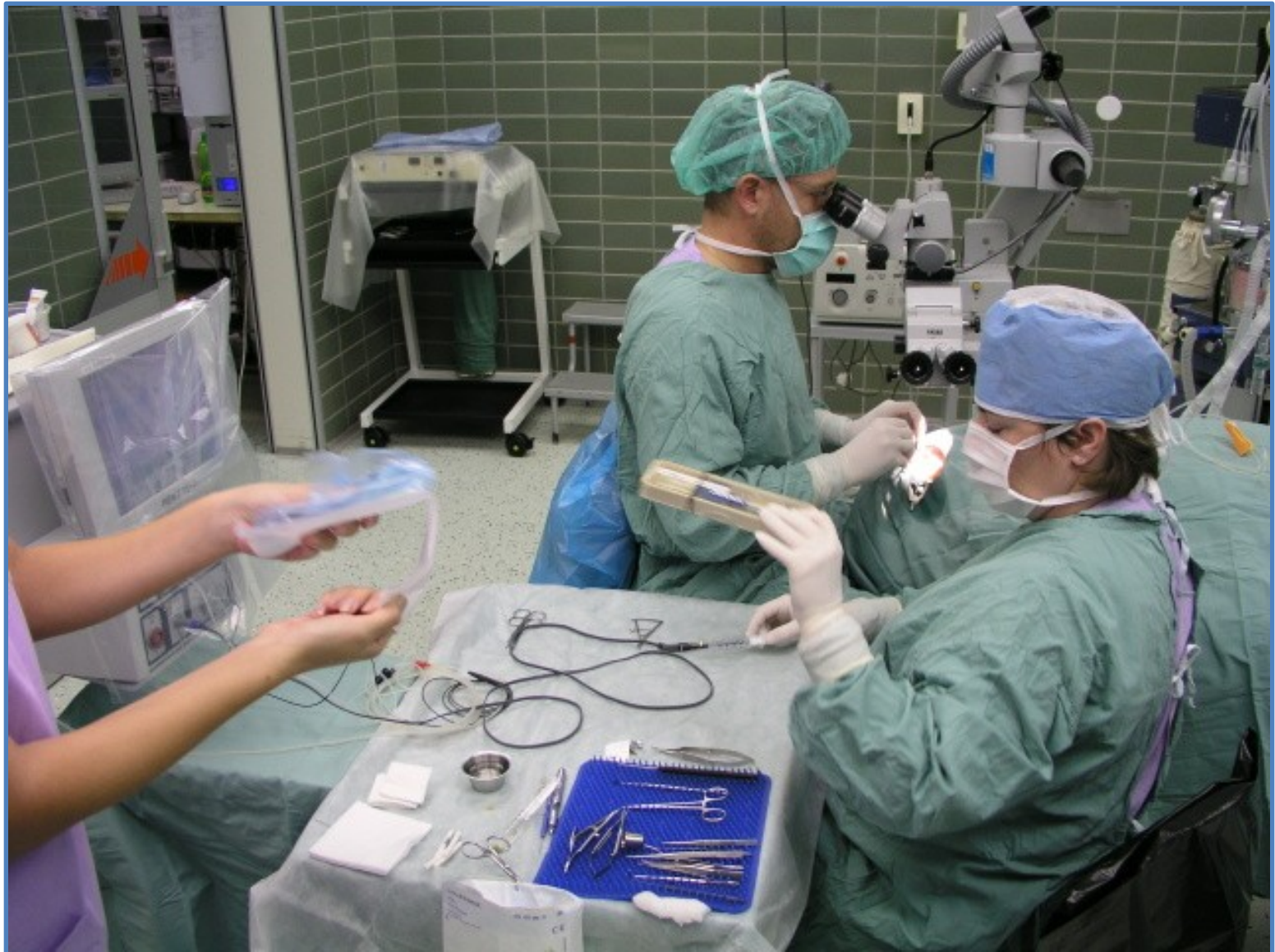

# Anesthesia

- GA
- ANS
- LA



# Surgery



# Surgery

