

Introduction to osteology

GENERAL OSTEOLOGY


- skeleton - firm support of the body, protection for organs
- deposit of minerals
- haematogenesis

BONE TYPES

Long bones

- diaphysis
- epiphysis proximal and distal
- metaphysis
- cavitas medullaris

- substantia compacta (corticalis)
- substantia spongiosa



Short bones

(various shapes)

- 1) On the surface - **corticalis**
- 2) Inside - **substantia spongiosa**

Flat bones

1) Compact bone has two layers:

lamina externa and interna and between them,
there is **spongy bone – diploe**

Sesamoidal bones

In some muscle ligaments

Pneumatized bones

STRUCTURE OF BONES

PERIOSTEUM

a) Fibrous layer(external)

b) Cambious layer (internal) – rich sensory innervation

1 – **periosteum**

2 – Sharpey fibres

3 – vessels

4 – **endosteum**

We know two forms of bone tissue

a) Compact bone (**substantia compacta**)

b) Spongy bone (**substantia spongiosa**)

Compact bone

- 1 – Haversian lamellas**
- 2 – intersected lamellas**
- 3 – superficial lamellas**
- 4 – spongy bone**

The spongy bone

- Substantia spongiosa
- Substantia compacta
- Skull - diploe

BONE MARROW

Medulla ossium rubra - red bone marrow
(active hematopoietic tissue)

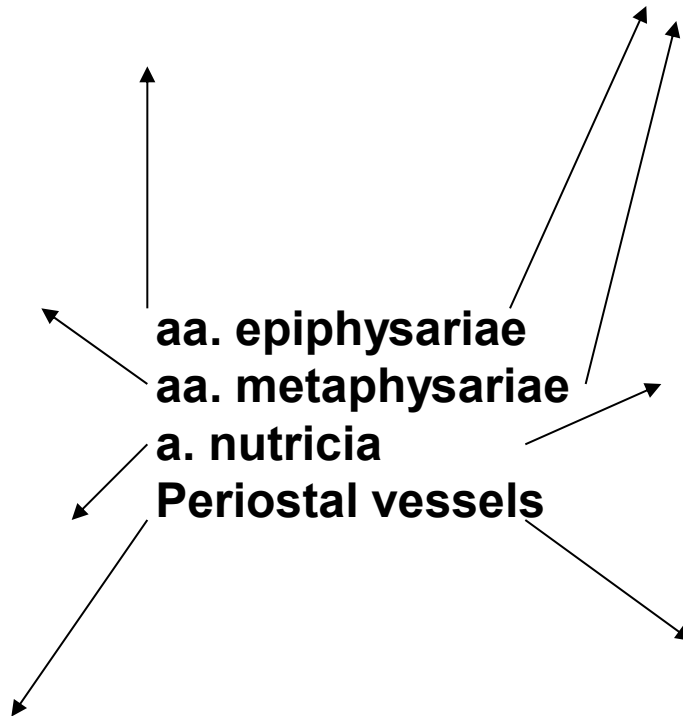
Medulla ossium flava - yellow bone marrow
(source of energy for organism)

Medulla ossium gelatinosa - grey bone marrow

BONE VESSELS

- The most important bone vessels come through periosteum via **Volkmann's channels**

Blood supply of the long bone



X-RAY PICTURES

4,5 years

7 years

11 years

14 years

SPECIAL OSTEOLOGY

SKELETON OF THORAX

COLUMNA VERTEBRALIS - SPINE

- During development: 33-34 vertebrae
- After fusion: 24 vertebrae

Vertebrae

7 cervical

12 thoracic

5 lumbar

4-5 sacral- os sacrum

4-5 coccygeal- os coccygis



VERTEBRA

corpus vertebrae

facies terminalis superior et inferior

arcus vertebrae

pediculus arcus vertebrae

lamina arcus vertebrae

foramen vertebrale

incisura vertebralis

processus

processus articulares

processus transversi

processus spinosus

DEVELOPMENT OF THE VERTEBRAE

Corpus vertebrae

Arcus vertebrae

Processus articulares

Processus transversus

Processus spinosus

Costa

CERVICAL VERTEBRAE

- uncus corporis vertebrae
- processus transversus -
tubercula anteriora et
posteriora, foramina processus
transversi
- oval body
- Triangular foramen vertebrale
- cleft processus spinosus
- processus articulares - in
oblique plane

Corpus vertebrae

Arcus vertebrae

Processus articulares

Processus transversus

Processus spinosus

Costa

ATLAS - C1

- **arcus anterior**
tuberculum anterius
fovea dentis
- **arcus posterior**
tuberculum posterius
sulcus a. vertebralis
- **massae laterales**
processus transversi
foramina pr. transversi

Corpus vertebrae

Arcus vertebrae

Processus articulares

Processus transversus

Processus spinosus

Costa

AXIS - C2

- dens axis (original body of atlas)- apex dentis
- facies articularis anterior et posterior
- os odontoideum

Corpus vertebrae

Arcus vertebrae

Processus articulares

Processus transversus

Processus spinosus

Costa

C6- TUBERCULUM CAROTICUM

VERTEBRA PROMINENS- C7

VERTEBRAE THORACICAE

- **corpus:** foveae costales - superiores, inferiores
- **processus transversus 1.-10.Th:** fovea costalis pr. transversi
- **processus articulares:** in frontal plane
- **Th4 - 9:** impressio aortica

Corpus vertebrae

Arcus vertebrae

Processus articulares

Processus transversus

Processus spinosus

Costa

VERTEBRAE LUMBALIS

- **processus costarii**
- **processus accessorius**- more caudally
- **processus mamillaris**- more cranially
- **processus articulares**- in sagittal plane
- **processus spinosi**- flat plate
- **Sacralization of last lumbar vertebra**

Corpus vertebrae

Arcus vertebrae

Processus articulares

Processus transversus

Processus spinosus

Costa

OS SACRUM

- **facies dorsalis**- crista- mediana, medialis, lateralis
- **facies auricularis**- partes laterales ossis sacri
- **facies pelvina**- lineae transversae
- **foramina sacralia**- dorsalia, pelvina
- **canalis sacralis**- hiatus sacralis- cornua sacralia
- **basis ossis sacri**
- **apex ossis sacri**

Corpus vertebrae

Arcus vertebrae

Processus articulares

Processus transversus

Processus spinosus

Costa

OS COCCYGIS

- cornua ossis coccygis=
processus transversi Co1
- apex coccygis

Corpus vertebrae

Processus articulares

Processus transversus

COSTAE - RIBS

- 12 pairs of ribs:
- **costae verae**: 7 pairs, true ribs
- **costae spuriae**: 8th-10th pair, false ribs
- **costae fluctuantes (liberae)** : 11th and 12th pair- free ribs
- length- from 1st to 8th increases, the smallest: 1st and 12th, the largest 6th - 9th

RIB

os costae + cartilago:

- caput costae, crista
- collum costae
- tuberculum costae
- corpus costae
- crista costae
- sulcus costae
- angulus costae

Facies articularis capitis costae
Facies articularis tuberculi costae

COSTA PRIMA/the first rib

- sulcus arterie subclaviae
- (sulcus venae subclaviae)
- tuberculum m. scaleni anterioris
- insertion of m. scalenus medius
- beginning of m. subclavius

COSTA SECUNDA/the second rib

- tuberculum m. scaleni posterioris
- tuberositas m. serrati anterioris

STERNUM

- **manubrium sterni**- incisura-jugularis, clavicularis and places for connection with cartilages of the first pair of ribs
- **angulus sterni**
- **corpus**- incisurae costales
- **processus xiphoideus**

X-RAY of cervical spine

X-RAY of thoracic spine

X-RAY of lumbar spine

Thank you for your attention!

Pictures:

**Atlas der Anatomie des Menschen/Sobotta. Putz,R., und Pabst,R. 20. Auflage.
München:Urban & Schwarzenberg, 1993**

Netter: Interactive Atlas of Human Anatomy.

Naňka, Elišková: Přehled anatomie. Galén, Praha 2009.

Čihák: Anatomie I, II, III.

Drake et al: Gray's Anatomy for Students. 2010