

- **GENERAL MYOLOGY**

MUSCULAR SYSTEM

unit- muscle = musculus (myos)

- **Active component of the locomotor system- it is controlled by nerves**
- The main demonstration of mechanical function of muscle fibers (on the base of excitations coming through the motor nerve fibers) is their shortening—**contraction** (movement)
- Contractile proteins myosin and actin, form the basis of myofibrils of muscle fibers

Smooth muscle

Heart muscle

Striated muscle

Function of the muscular system

- **motion** function – muscular system constitutes active component of the locomotor system
- **shape** function - musculature forms exterior (external shape) of a man
- **termoregulation** – it is releasing heat
- It helps **blood circulation**
- It keeps **basic muscle tension**

ATTACHMENT

To the bones: skeletal muscles- mm. sceleti- over 600 in the body, mostly paired, they form 1/3-1/2 of entire body weight

To the skin: skin muscles- mm. cutanei- mainly on head and neck

Relationship to organs: organ muscles

To the articular capsules: mm. articulares

The internal structure of striated muscle

- 1) Striated muscle tissue (myosin and actin)- muscle fiber
- 2) Fibrous tissue (it covers the muscle fibers, primary and secondary fasciculi – important for metabolism between muscle fiber and blood circulation of muscle, on the surface, there is unbroken covering fascia = fascia)
- 3) Logistic components (vessels and nerves)
- 4) Special apparatus

INTERNAL STRUCTURE OF MUSCLE

Muscle part: the basic structural and functional unit of muscular system, it is the muscular fiber, which was created by fusion of many consecutive cells= multinucleated formation

- The fibers inside muscle have following arrangement— form muscle fasciculi, they combine into bundles until they create the entire muscle
- Muscle fibers are interconnected with thin collagenous fibrous tissue, so-called **perimysium internum (endomysium)**
- the surface of whole muscle is covered by fibrous tissue, so-called **perimysium externum (epimysium)**

Tendon: tendon is created by regularly arranged fibers of tough collagenous fibrous tissue, which have hierarchical arrangement – single fibers combine to fasciculi, then to larger bundles until they form the whole tendon

- fibers are connected with thin collagenous fibrous tissue, so-called **peritenonium internum (endotenonium)**
- On the surface, there is a fibrous covering, so-called **peritenonium externum (epitenonium)**
- **aponeurosis**- flat tendons

EXTERNAL STRUCTURE OF MUSCLE

- **origin (*origo*)**: part of the muscle that runs from bone (or skin); it is the place, where the muscle doesn't change its position during contraction (so-called: fixed point- **punctum fixum**), it is usually formed by tendon
- **belly (*venter*)**: fleshy part of muscle, its beginning is called **caput** (head), its end is called **cauda** (tail)
- **insertion (*insertio*)**: is formed by tendon; it is the place, where the muscle changes its position during contraction (so-called: mobile point- **punctum mobile**), the tendon attaches usually to a bone, sometimes to skin or organ

CLASSIFICATION OF MUSCLES

1. ACCORDING TO PREVAILING SIZE

- **Long muscles:** they have ribbon-like or rope-like tendons
- **Short muscles:** they have ribbon-like or rope-like tendons
- **Flat muscles:** they usually have wide flat tendons=**aponeurosis**
- **Round muscles:** ring-like shape, they encircle some openings, they are narrowing during contraction

3. ACCORDING TO A NUMBER OF HEADS

- **Muscles with one head**: one head
- **Muscles with more heads**: more heads (more origins), which connect into one muscle belly. (musculus biceps, musculus triceps, musculus quadriceps)

4. ACCORDING TO A NUMBER OF BELLIES

- **With one belly**: only one belly
- **With more bellies**: two or more consecutive bellies, which are separated from each other by tendons (*tendo intermedius*)

CLASSIFICATION ACCORDING TO FUNCTION

- Muscle can make its function, only if it span minimal one movable bone junction
- muscle making specific movement is called **agonist** (executor)
- Muscle which participate in some movement are called **synergists**
- Muscles making opposite movement are called **antagonists**

flexors × **extensors**

adductors × **abductors**

sphincters × **dilatators**

pronators × **supinators**

levators × **depressors**

erectors

elevators

tensors

Contraction

Isotonic: change of length **concentric**: shortens

excentric: extends

Izometric: change of tension

Vessels- blood and lymphatic- nutrition of muscle. They enter the muscle in place called porta musculi (hilus musculi)- neurovascular hilus.

Nerves

- diploneural muscles- innervated from two nerves
- plurineural muscles- innervated from more nerves
- **motor fibers**: they bring impulses for contraction of muscle fibers, they are terminated as motor plates on the muscle fiber
- **Senzor fibers**: bring information from muscle into central nervous sytem, about pain, tension.

SPECIAL APPARATUS

- 1. Fascia (*fasciae*):** fibrous membranes, which cover one whole muscle or group of some muscles.
- Septa intermuscularia-** separates single groups of muscles, they are attached to a bone
- Retinacula-** eyelets, which holds muscle tendons to a bone.
- 2. Synovial bursae(*bursae synoviales*):** pouches around the joint, derivatives of the joint capsule, in the places, where tendons and muscle lie directly on the bone
- 3. Synovial sheath (*vaginae tendinum*):** cover long tendons of muscles in areas exposed to mechanical loading.

Layer- superficial- vagina fibrosa- **peritenonium**
- deep- vagina synovialis- **epitenonium**

Muscles of the head

Mm. masticatorii

M. temporalis

M. temporalis

origin: linea temporalis inferior, temporal fascia

insertion: processus coronoideus mandibulae

innervation: N. trigeminus (nn. temporales profundi from 3rd branch)

function: elevation, partly retraction of mandible

M. masseter

**origin: arcus
zygomaticus and os
zygomaticum
insertion: tuberositas
masseterica
innervation: N.
trigeminus (n.
massetericus from 3rd
branch)
function: elevation of
mandible, chewing
movements**

M. pterygoideus medialis

M. pterygoideus lateralis

3) M. pterygoideus medialis

origin: fossa pterygoidea and tuber maxillae

insertion: tuberositas pterygoidea

innervation: N. trigeminus (n. pterygoideus medialis from the 3rd branch)

function: elevation of mandible

4) M. pterygoideus lateralis

**origin: lamina lateralis processus pterygoidei, facies infratemporalis
 alae majoris ossis sphenoidalis**

insertion: fovea pterygoidea mandibulae

innervation: N. trigeminus (n. pterygoideus lateralis from the 3rd branch)

function: by double-sided contraction: protraction of mandible

- **Mimic muscles**

Mimic muscles

m. occipitofrontalis

m. temporoparietalis

Muscles of palpebral fissure

m. orbicularis oculi

m. depressor supercilii

m. corrugator supercilii

m. procerus

3) Muscles of the mouth

m. orbicularis oris

m. depressor anguli oris

m. depressor labii inferioris

m. risorius

**m. levator labii superioris
alaeque nasi**

m. levator labii superioris

m. zygomaticus major

m. zygomaticus minor

m. levator anguli oris

m. buccinator

m. mentalis

4) Muscles of the nose

m. nasalis

**m. levator labii superioris
alaeque nasi**

Head fasciae

Fascia temporalis

- together with skull bones, it creates a cavity for m. temporalis

Fascia masseterica

- continues as fascia parotideomasseterica (to the gland)

Fascia

buccopharyngea

- from the lips to pharynx

Musculi colli
(muscles of the neck)

M. platysma

Platysma

- Subcutaneous muscle, on superficial cervical fascia from clavicle to the face

O: fascia pectorialis, fascia deltoidea

I: skin of the face

F: it stretches cervical skin

IN: ramus colli n. facialis

M. sternocleidomastoideus

M. sternocleidomastoideus

O: manubrium sterni, sternal end of clavicle

I: processus mastoideus, external edge of linea nuchae superior

F: at unilateral contraction – lateroflexion, bilateral contraction – retroflexion, auxiliary inspiratory muscles (at fixed head and cervical spine)

IN: n. accessorius + C2 - C4

Musculi suprahyoidei

M. DIGASTRICUS

M. STYLOHYOIDEUS

M. MYLOHYOIDEUS

M. GENIOHYOIDEUS

M. digastricus

M. DIGASTRICUS

Muscle with two bellies

O: venter anterior: fossa digastrica,
it is changing into tendon on hyoid
bone, continues as **venter posterior**

I: incisura mastoidea

F: depression of mandible, elevation
Of hyoid bone

I: venter anterior - n. mylohyoideus
(n. trigeminus)

venter posterior - n. facialis

M. stylohyoideus

M. STYLOHYOIDEUS

Through its cleft tendon m. digastricus passes

O: processus styloideus

I: body of the hyoid bone

F: it elevates the hyoid bone during swallowing

I: n. facialis

M. mylohyoideus

M. MYLOHYOIDEUS

Forms the flexible bottom
of the mouth- diaphragma
oris

O: linea mylohyoidea

I: os hyoideum

raphe mylohyoidea -
fibrous connection of both
muscles

F: depression of mandible
at fixed mandible, elevation
of hyoid bone

I: n. mylohyoideus (n.
trigeminus)

M. geniohyoideus

M. GENIOHYOIDEUS

Above m. mylohyoideus

O: spina mentalis

I: body of the hyoid bone

F: it participates in forming
of the bottom of the mouth

I: fibers from C1

Mm. infrahyoidei

1. m. sternohyoideus
2. m. sternothyroideus
3. m. thyrohyoideus
4. m. omohyoideus

F: they fix the hyoid bone,
they participate in
swallowing reflex

I: ansa cervicalis profunda
C1 - C3 - except m.
thyrohyoideus -> C1

M. sternohyoideus

M. STERNOHYOIDEUS

O: dorsal surface of
manubrium sterni + sternal
end of clavicle

Ú: body of hyoid bone

M. sternothyroideus

M. STERNOTHYROIDEUS

behind m. sternohyoideus and
more laterally

O: manubrium sterni and 1st rib

I: linea obliqua

M. thyrohyoideus

M. THYROHYOIDEUS

O: linea obliqua on cartilago
thyroidea

I: cornu majus of hyoid bone

M. omohyoideus

M. OMOHYOIDEUS

With two bellies

O: venter inferior- margo scapulae
sup., below m.

sternocleidomastoideus it continues
as a tendon and then int chnages
into venter superior

I: body of hyoid bone

mm. suprahyoidei et infrahyoidei

The larynx and the hyoid bone are elevated by the suprahyoid muscles during swallowing, infrahyoid muscles return them back

- Mm. scaleni

Musculi scaleni

Common function:

at fixed thorax, the muscles by unilateral contraction cause lateroflexion and rotation of the cervical spine, at bilateral contraction they cause anteflexion of cervical column

- auxilliary inspiratory muscles

/: rami ventrales of cervical nerves

M. SCALENUS ANTERIOR

Z: transverse processes of C3 - C6

Ú: tuberculum m. scaleni anterioris of 1st rib

M. SCALENUS MEDIUS

Z: transverse processes of C1 - C7

Ú: 1st rib, behind sulcus a. subclaviae

M. SCALENUS POSTERIOR

Z: transverse processes of C5 - C7

Ú: 2nd rib

- Deep cervical muscles

Deep cervical muscles

IN: rami ventrales of cervical nerves

M. LONGUS CAPITIS

O: tuberculum ant. processus transversi C3 - C6

I: skull base

F: anteflexion of head

M. LONGUS COLLI

O: caudal cervical and cranial thoracic vertebrae

I: tuberculum anterius atlantis + tuberculum ant. proc. transversi C5, C6 + bodies of C2 – C4

F: flexion, lateroflexion, rotation of the head

M. RECTUS CAPITIS ANTERIOR

Z: processus transversus atlantis

Ú: skull base (behind m. longus capitis)

F: bilateral: anteflexion

unilateral: lateroflexion

M. RECTUS CAPITIS LATERALIS

Z: processus transversus atlantis

Ú: skull base

F: lateroflexion

Musculi thoracis
(Thoracic muscles)

- Heterochtonous muscles of
thorax

(common innervation from pars
supraclavicularis plexus
brachialis)

M. pectoralis major

M. PECTORALIS MAJOR

O: clavícula, sternum (+ adjacent parts of ribs 1st – 6th)

I: crista tuberculi majoris humeri,

F: pars clavicularis – it helps at flexion of arm

pars sternalis and abdominalis

- adduction of arm, pronation

M. pectoralis minor

M. PECTORALIS MINOR

O: 3. až 5. žebro

I: processus coracoideus

F: it pulls scapula forward and downward

F: auxiliary inspiratory muscles

M. subclavius

M. SUBCLAVIUS

O: costa prima

I: sulcus m. subclavii

F: it pulls clavicle downward, it elevates the 1st rib

M. serratus anterior

M. SERRATUS ANTERIOR

O: nine teeth at 1st-9th rib

I: medial edge of scapula and
angulus inferior

F: it holds scapula to the thorax,
it pulls angulus inferior scapulae
laterally

Autochthonous thorax muscles

Common innervation: nn.

intercostales I - XI

MM. INTERCOSTALES EXTERNI

external layer, they direct like hands into the pockets, they continue forward as **membrana intercostalis externa**

F: inspiratory muscles

MM. INTERCOSTALES INTERNI

middle layer, they direct like hand to the breasts, they continues backward as **membrana intercostalis interna**

F: expiratory muscles

MM. INTERCOSTALES INTIMI

internal layer

the same course and function like
mm. intercostales interni

M. TRANSVERSUS THORACIS

flat muscle on the internal surface
of sternum

it is diverging in a ray-shaped form
cranially and laterally

F: auxiliary inspiratory muscle

The diaphragm (*diaphragma*)

Flat muscle that separates the abdominal and thoracic cavity

The edges- muscle bundles, **centrum tendineum**

a) ***pars lumbalis***: starts from *lig. longitudinale anterius*, from lumbar vertebrae

b) ***pars costalis***: starts from 7th– 12th rib

c) ***pars sternalis***: starts from *processus xiphoideus sterni*

I: centrum tendineum

IN: n. phrenicus

F: main inspiratory muscle

Openings:

In centrum tendineum: foramen v. cavae inferioris

In muscular part: hiatus aorticus (ductus thoracicus), hiatus esophageus (nn. vagi), nn. splanchnici, v. azygos

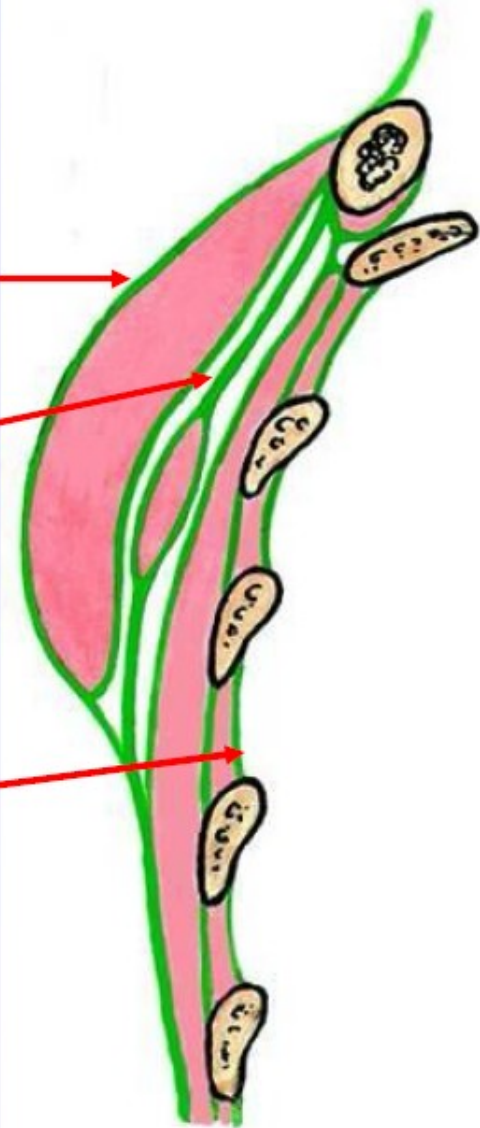
Fascie hrudníku

fascia pectoralis spfc.

fascia clavipectoralis

– fossa ovalis infraclavicularis

fascia endothoracica
(Sibsonova fascie)



HYPERTROPHY

ATROPHY