

Gynaecological conditions

Z. Rozkydal

Vaginal bleeding

Severe menstrual bleeding

Miscarriage

Recent termination of pregnancy

Recent childbirth

Injury

Signs

Vaginal bleeding, shock

First aid

Sanitary towel

To minimise the shock

Transport

Pyosalpinx

Inflammation of uterine tube

Inflammation fluid

Adhesions

Blockage of the tube

Peritonitis

Often in women with intrauterine device

Signs

Pain, discharge, fever, abdominal pain

Signs of peritonitis

First aid

Positioning, no fluids orally, transport

Toxic shock syndrom

Toxins of *Staphylococcus aureus* go through mucose membrane into the blood and peritoneal cavity

Often in women with vaginal swabs

Mortality 8-15 %

Signs

Headache, fever, abdominal pain, diarrhoea, letargy, muscle pain, hypotensis, shock

Failure of kidney, liver, myolysis

First aid

To remove the swab

To minimise the shock

Antibiotics

Ovarial cyst

Asymptomatic

Acute situation in a case of rupture or torsion

Signs

Sudden onset of a sharp pain in lower part of the abdomen

Signs of peritonitis

First aid

Positioning

Transport

Hyperemesis gravidarum

Severe vomiting in pregnancy
in the first 3 months

Signs

Persistent vomiting, loss on weight, dehydration

First aid

Sedatives, drugs against vomiting

Admission to the hospital

Graviditas extrauterina

Extrauterine pregnancy

Implantation of the embryo outside the uterus
(tuba uterina, ovarium, abdominal cavity)

Signs

Pain, convulsions, intraabdominal bleeding, shock

First aid

To minimise the shock

Transport

Spontaneous abortion

Miscarriage

Loss of foetus before 20 weeks of pregnancy

Usually malformation of the foetus

Weight under 500 g

Signs

Gynaecological bleeding, convulsions, abdominal pain

First aid

To minimise the shock

Transport

Preeclampsy

Hypertension, proteinuria, oedema

Second week of pregnancy- the first week after birth

Eclampsy

Preeclampsy

Convulsions

Unconsciousness

Occurs in 5 % of pregnant women

Fatal end- intracranial bleeding, respiratory failure

Signs

Swelling of hands, face, lungs, brain

Oliguria, headache, dizziness, high blood pressure

Convulsions, lethargy

Opisthotonus, convulsions in flexion and extension

Unconsciousness

First aid

Care as for casualty in unconsciousness

Transport to hospital

Childbirth

Premature childbirth between 29.– 38. week

Normal childbirth between 39.– 42. week

Late childbirth 43. week and later

I. stage

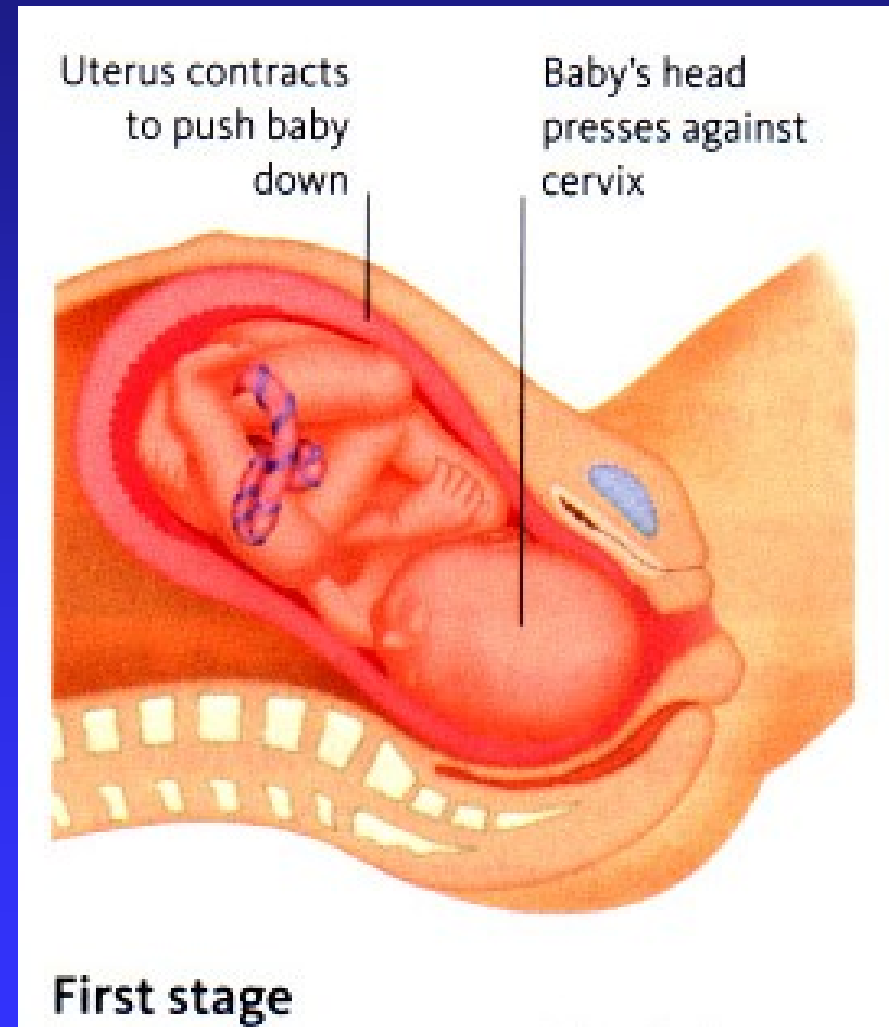
The cervix of the uterus is opening

Contractions become stronger and more frequent in 10- 20 minutes

Mucose plug is expelled

Amniotic fluid leaks out from the vagina

At the end is cervix fully dilated



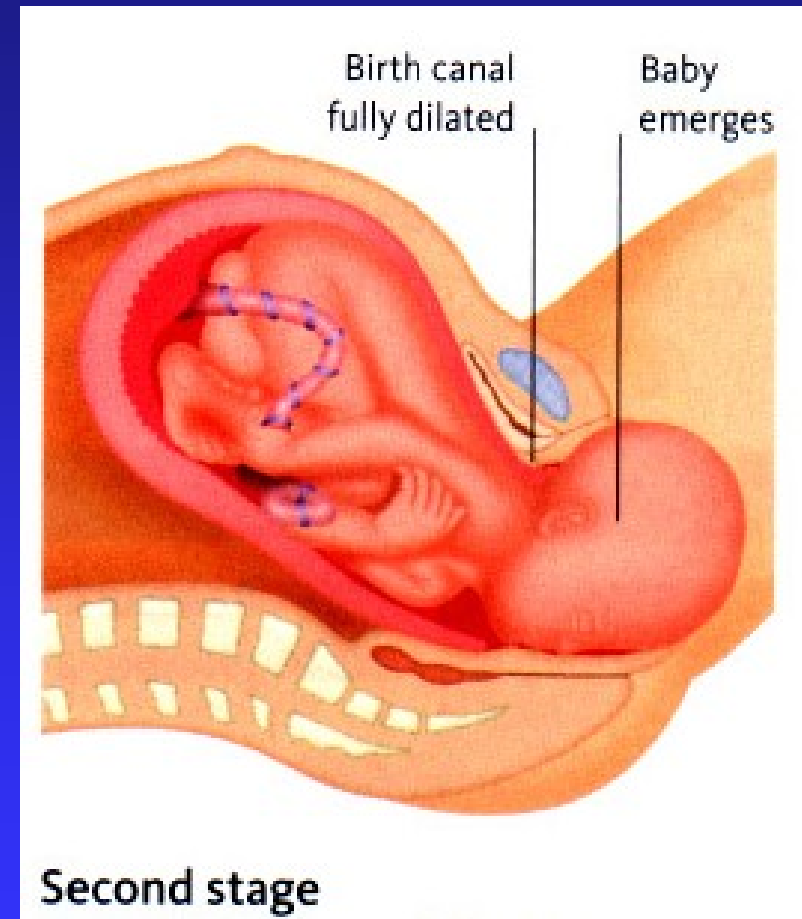
II. stage

It lasts several minutes till 2 hours

Uterus contractions are strong
in frequency of two minutes
Baby's head will press down
on the mother's pelvis floor

Birth canal stretches
as the baby travels through it

The head emerges first
then the body (arms, trunk,
lower limbs) is delivered afterwards
Episiotomy



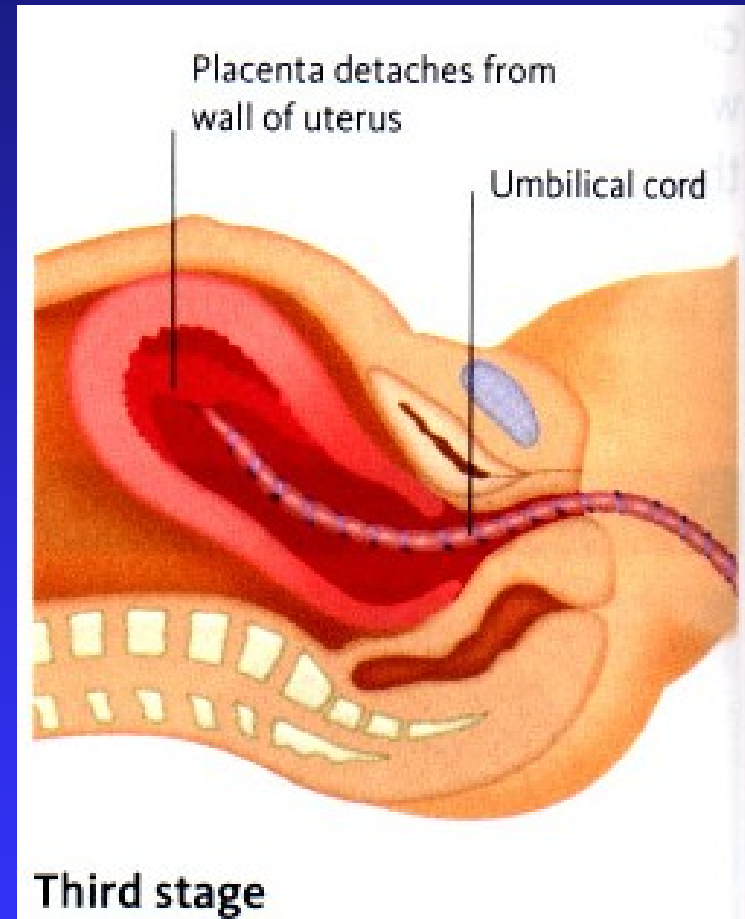
III. stage

After 30 minutes

The uterus begins to contract again pushing the placenta out

The placenta and the umbilical cord will be expelled from the uterus

The uterus closes down
- it reduces the bleeding



At the delivery

After the umbilical cord stops pulsation
ligate it and cut it 5 cm from umbiliculus
between ligated sites

Do not pull on the baby's head or shoulders

Check the umbilical cord is loose- to prevent strangulation

Remove mucose membrane from the mouth
of the child and keep the child's head down,
so the water can float out

Healthy child will start breathing normally in several seconds

If it does not start breathing, do 5 initial breaths
and continue CPR

Complications in the mother

Bleeding, thrombembolism, cardiac arrest, shock, eclampsy, infection

Complications in the child

Asphyxia (strangulation by umbilical cord)

Hypoxia- anaemia, heart failure

Kephalhematoma, subdural haematoma

Fracture of the clavicle, of the skull

Palsy of plexus brachialis- obstetric paralysis

Subdurální hematom

Infection

Newborn jaundice can cause damage of CNS

Foetal erythroblastosis can cause damage of CNS

Foetal erythroblastosis

Haemolytic anemia of the foetus

Incompatibility of Rh factor

Mother Rh -, father Rh+, foetus Rh+

It's erythrocytes go to the circulation of the woman

They produce antibodies

In the next pregnancy her antibodies go back through placenta

into the foetus causing destruction of foetal erythrocytes

High level of bilirubin causes anemia and damage of CNS

Signs

Haemolytic anemia

Cerebral palsy, diminished hearing

Mental deficiency, chorea