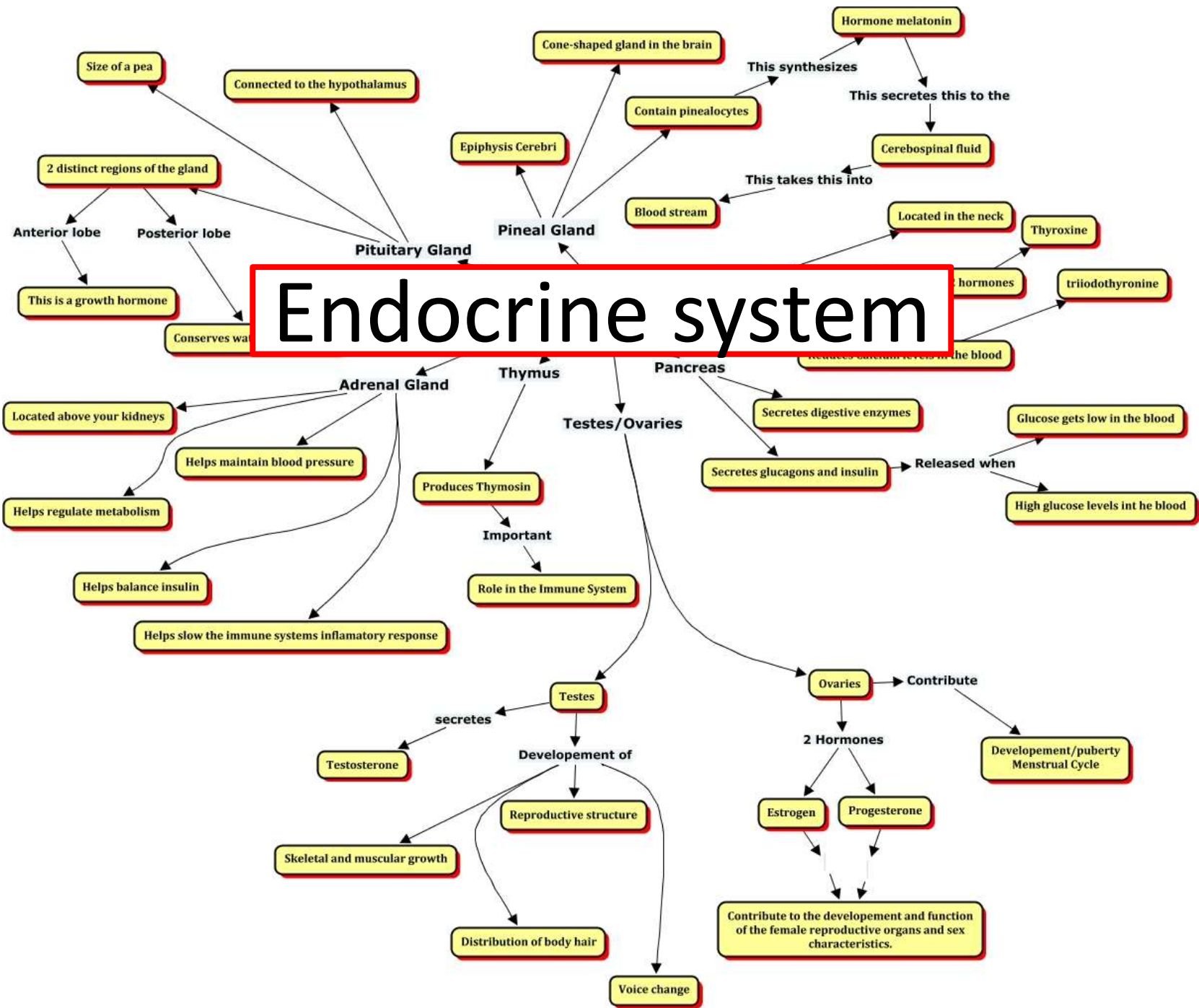
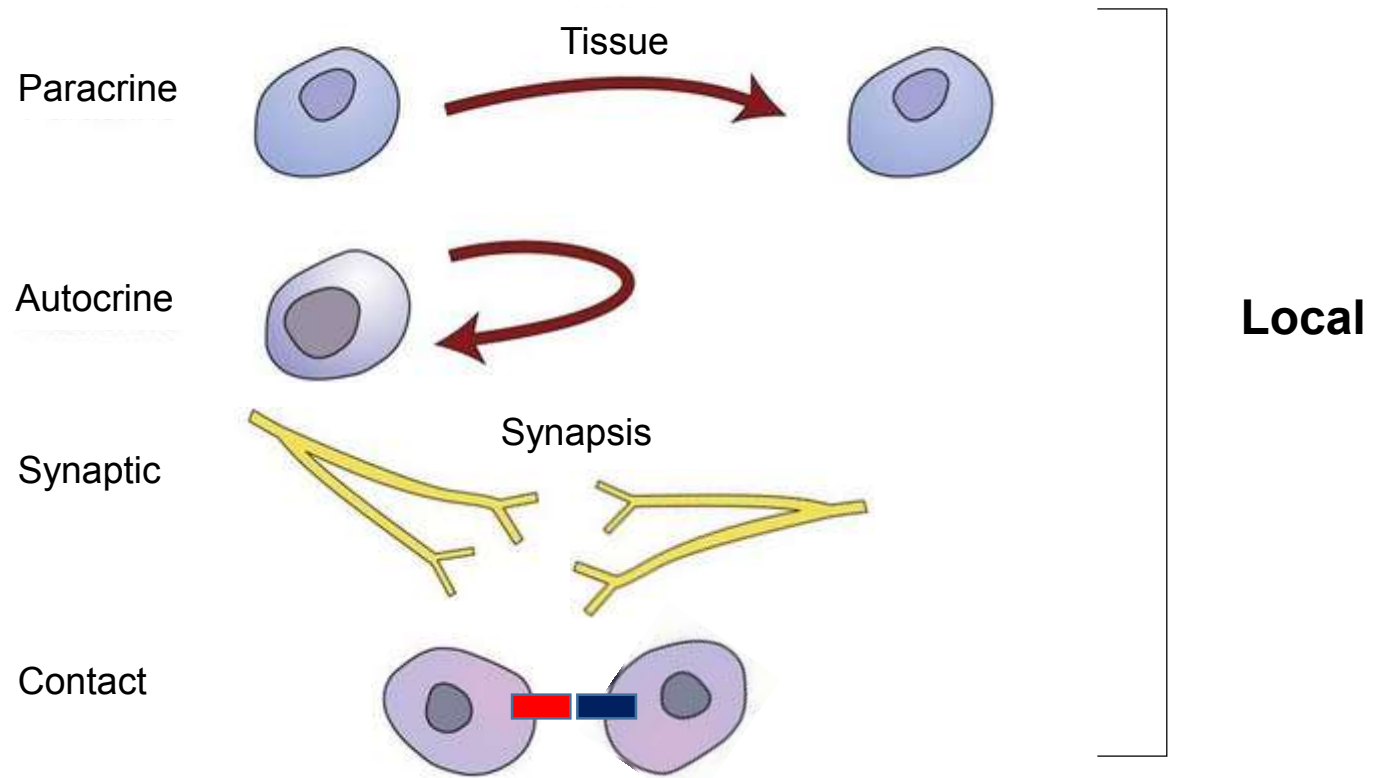


Endocrine system

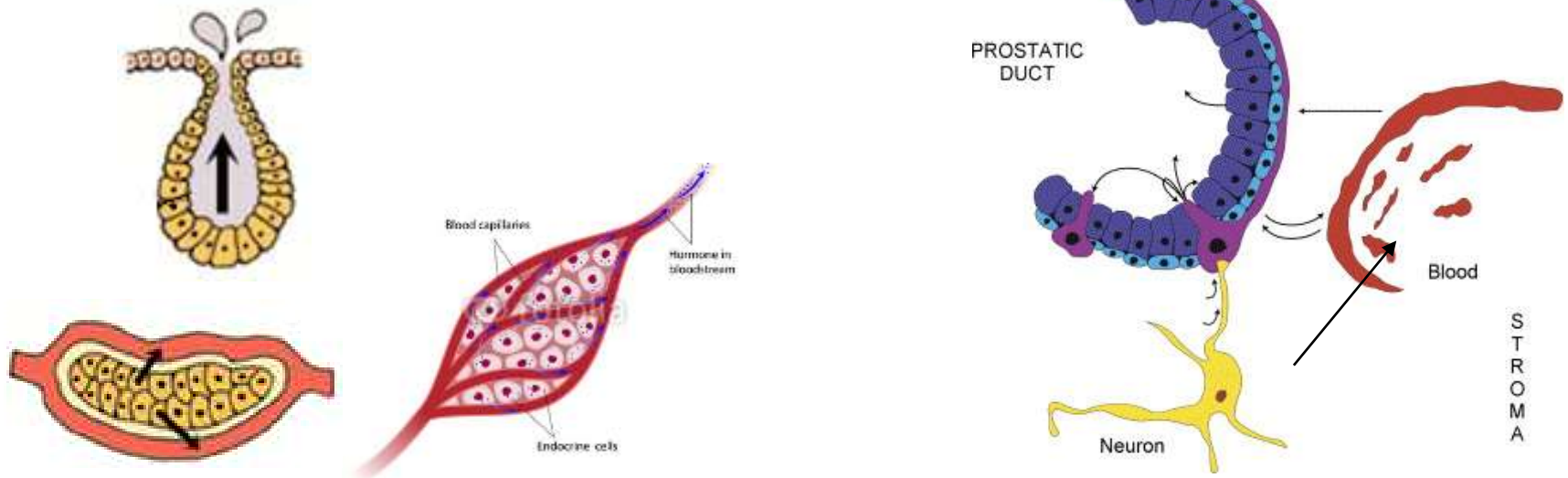


Intercellular communication



General properties of endocrine organs

- **Endocrine organs** (e.g. pituitary, thyroid, parathyroid, adrenal)
- **Endocrine tissue within other organs**
(pancreas, gonads, kidneys, placenta)
- **Isolated endocrine cells** (DNES, APUD)
- **Neuroendocrine cells**
- **Common developmental scheme**
 - invagination of epithelia, losing contact with the original tissue
 - ducts absents



General properties of endocrine organs

- c.t. capsule + septs
- Trabecules of glandular epithelium, follicles or clusters of glandular cells

or

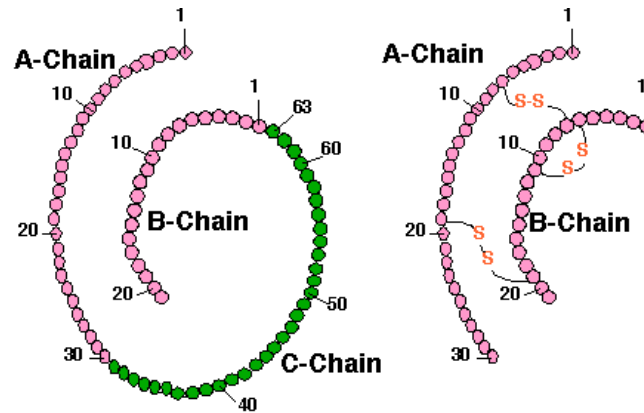
- **Neurosecretory cells**

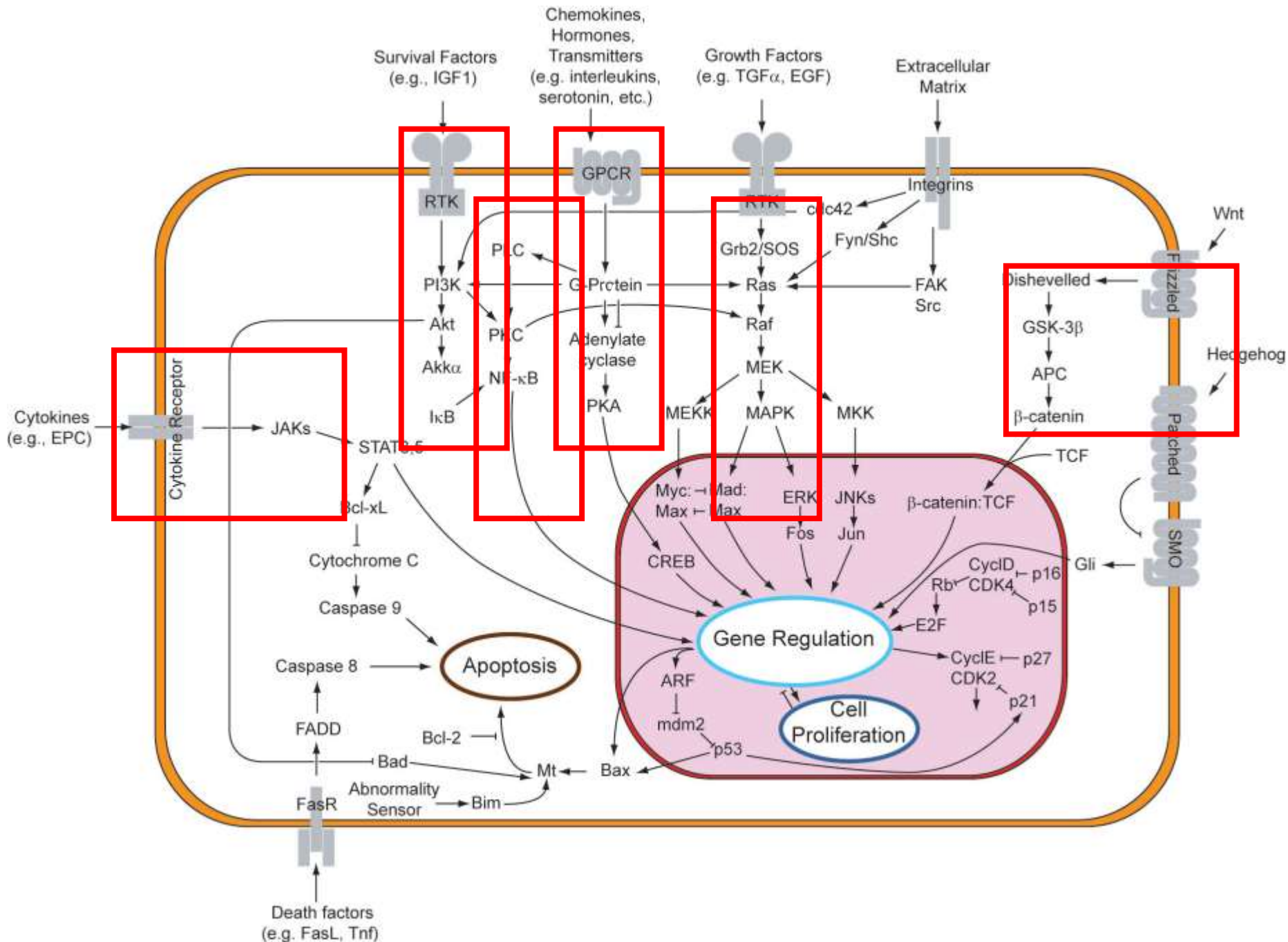
- **Capillary network**
 - Fenestrated capillaries
 - Sinusoids

- **Merocrine secretion**
 - not only hormones – endocrine gland is *sensu lato* also liver

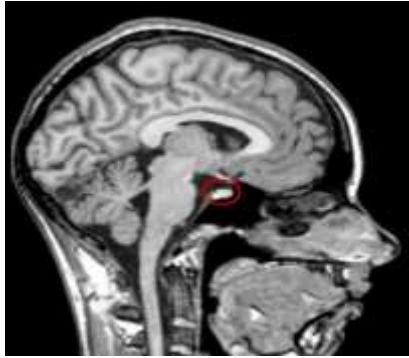
General properties of hormones

- **steroids** – hydrophobic, intracytoplasmic or nuclear receptors (sex hormones, corticoids)
- **proteins and polypeptides** – hydrophilic, plasma membrane receptors (insulin, pituitary hormones, PTH, ...)
- **aminoacids** and their derivatives (adrenalin, noradrenalin, thyroxin)





Pituitary gland (*gl. pituitaria*)



Corpus callosum

Hypothalamus

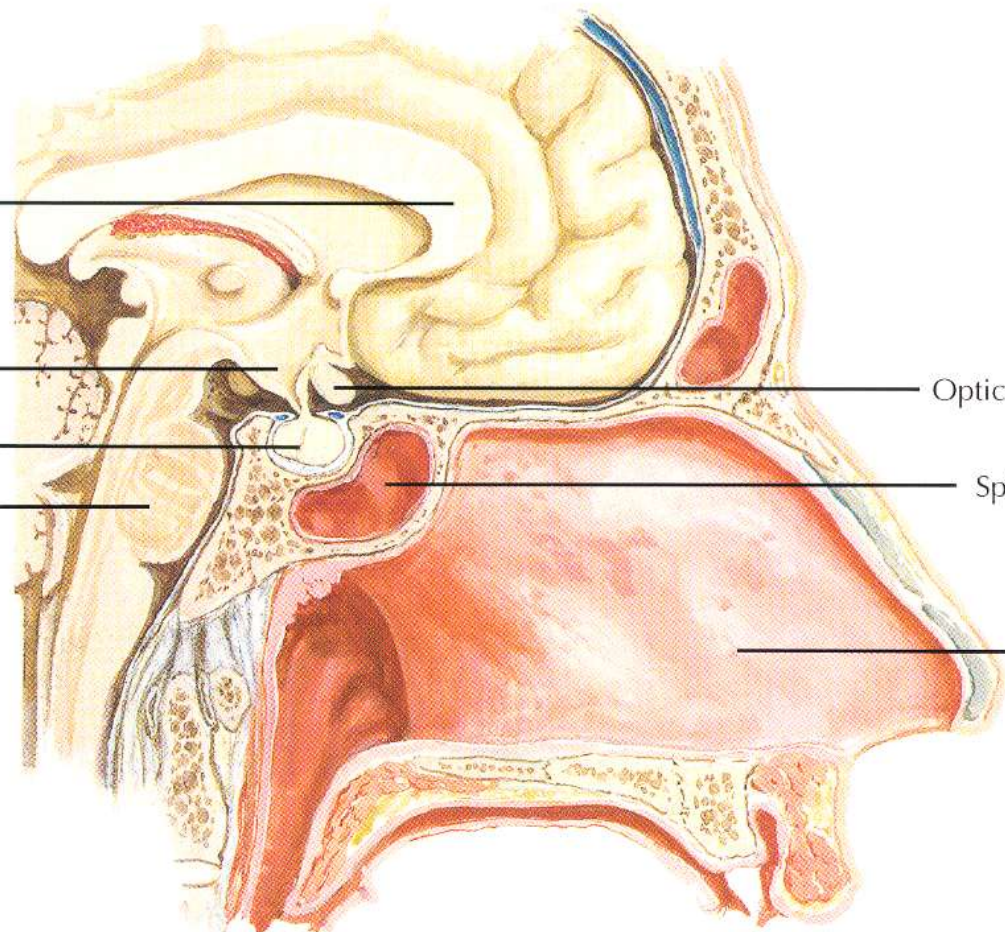
Pituitary gland

Brainstem (pons)

Optic chiasm

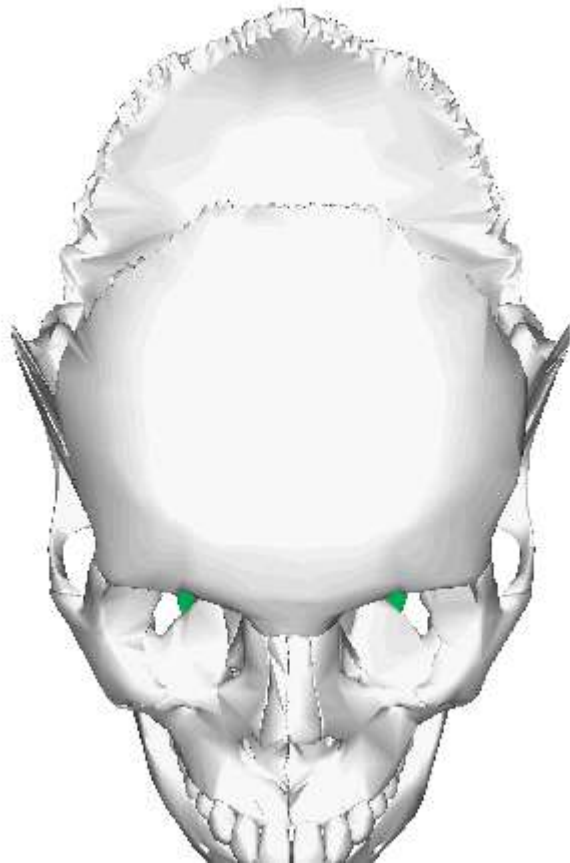
Sphenoid sinus

Nasal septum

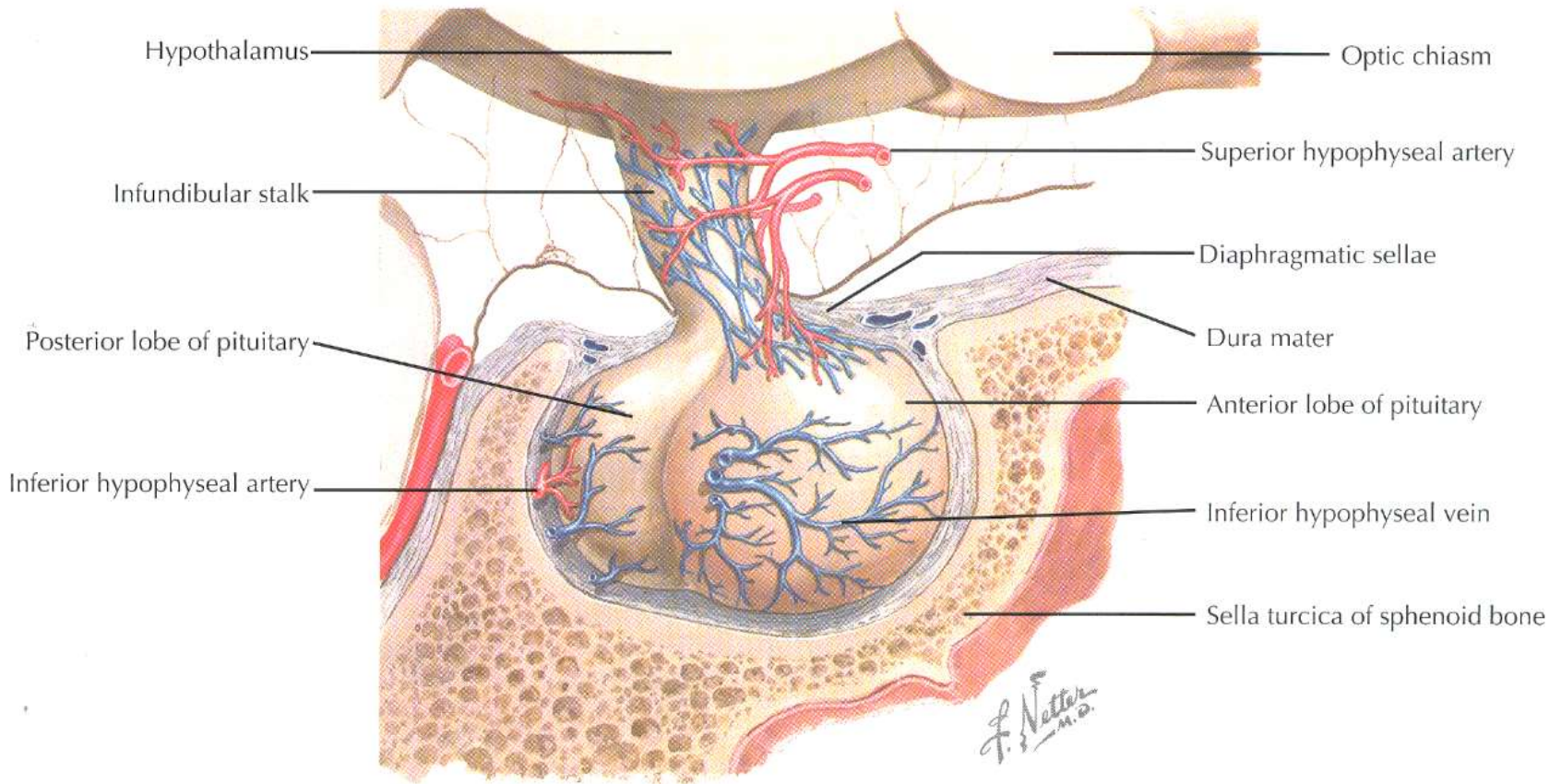
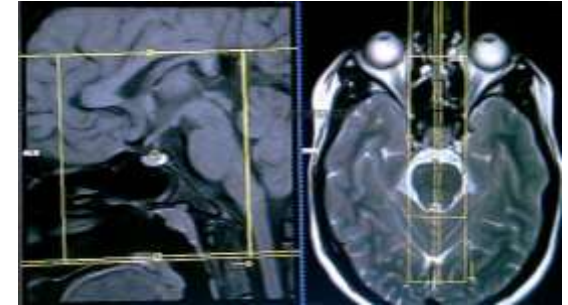


Pituitary gland (*gl. pituitaria*)

- sphenoid bone
- sella turcica
- fossa hypophysialis

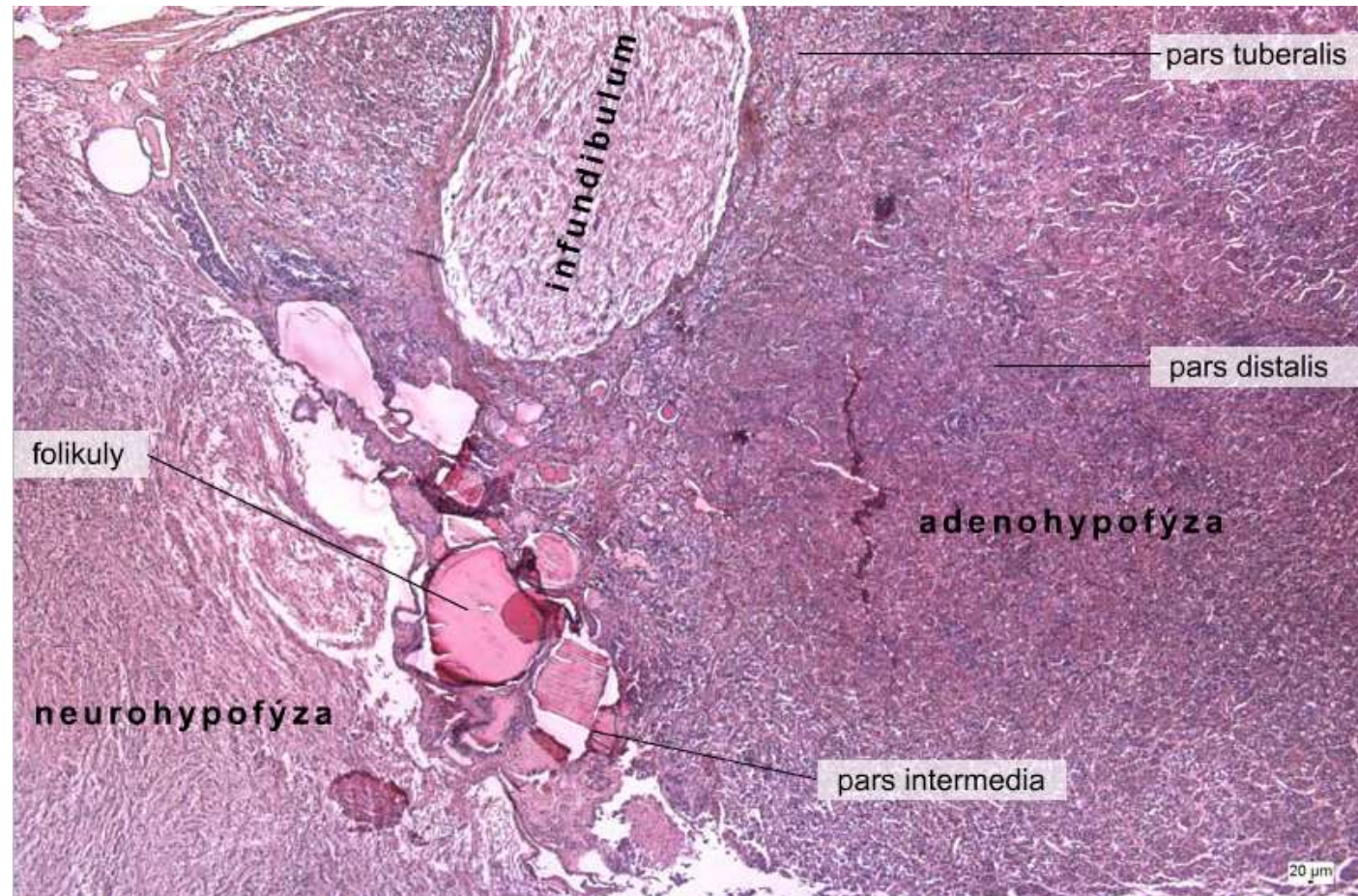


Pituitary gland (*gl. pituitaria*)



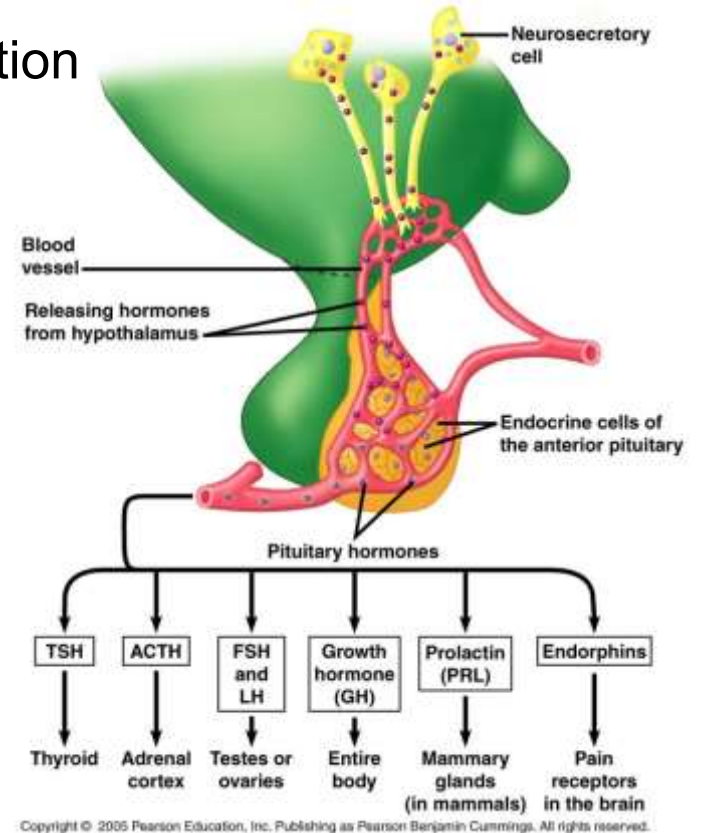
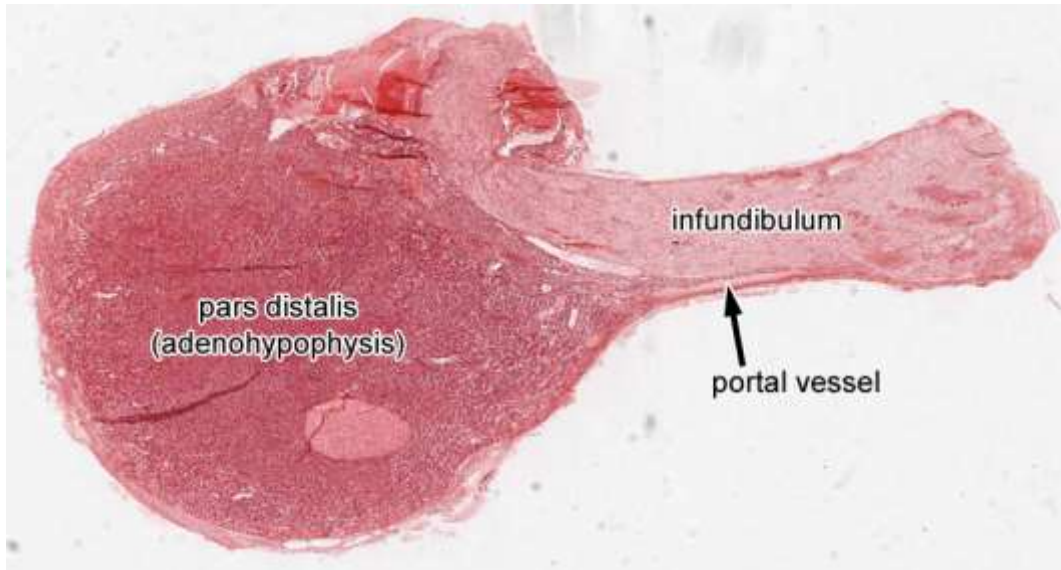
Pituitary gland (*gl. pituitaria*)

- adenohypophysis (*pars distalis*, *pars tuberalis*, *pars intermedia*)
- neurohypophysis (*pars nervosa*)
- *infundibulum*, *eminentia mediana*



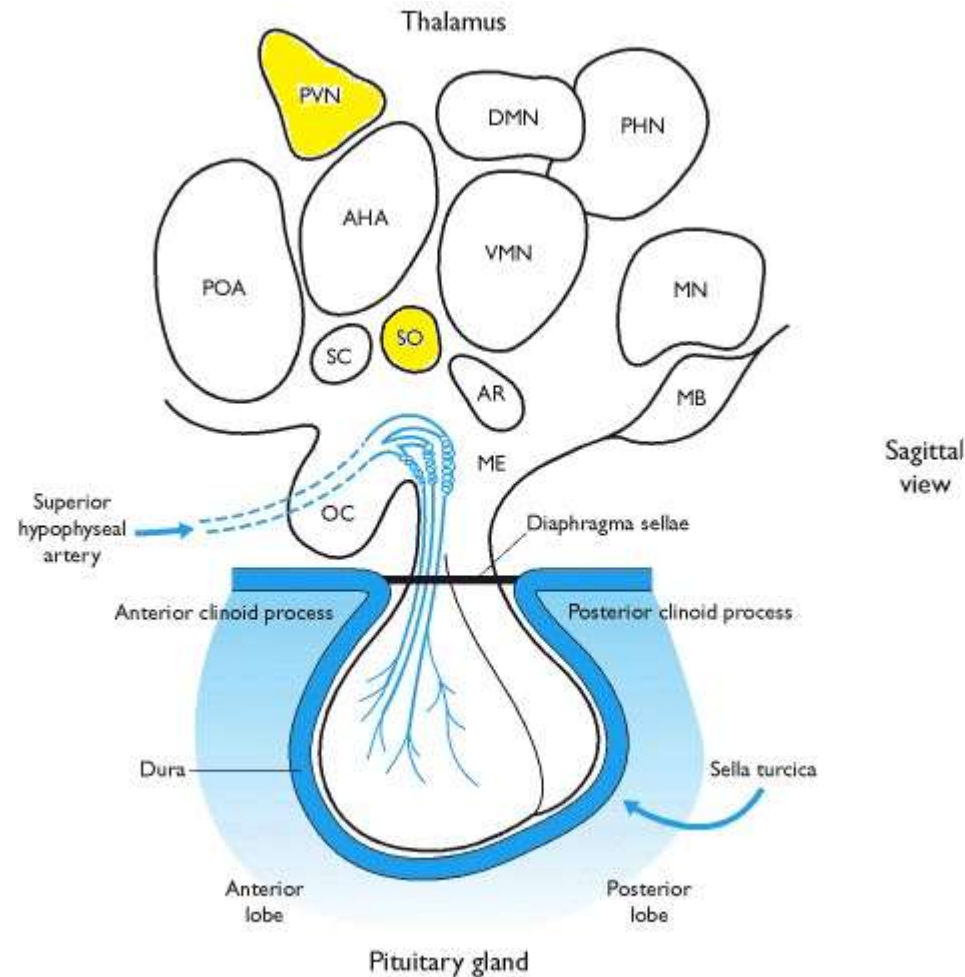
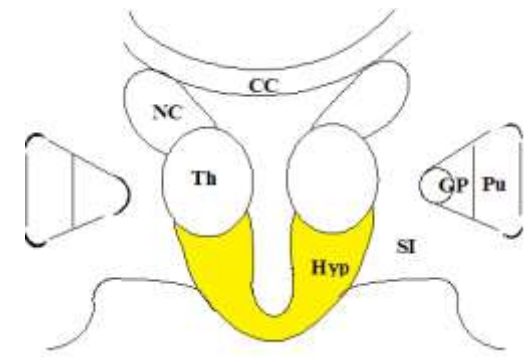
Pituitary gland (*gl. pituitaria*)

- adenohypophysis - glandotropic hormones, prolactin, GH
- neurohypophysis - hypothalamic hormones - ADH, oxytocin
- anatomical and functional association with hypothalamus
- capillary systems and neuroendocrine secretion

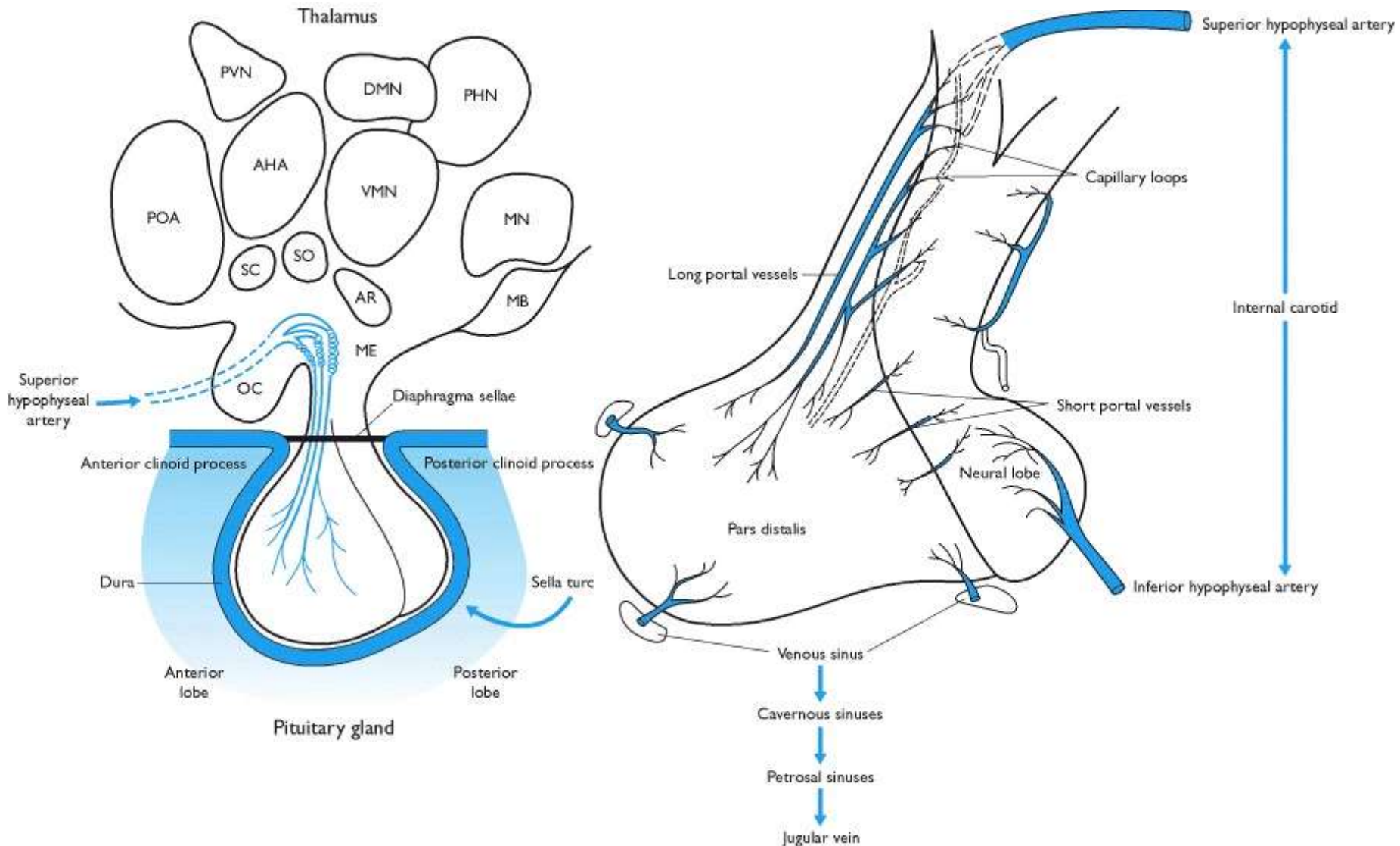


Hypothalamus

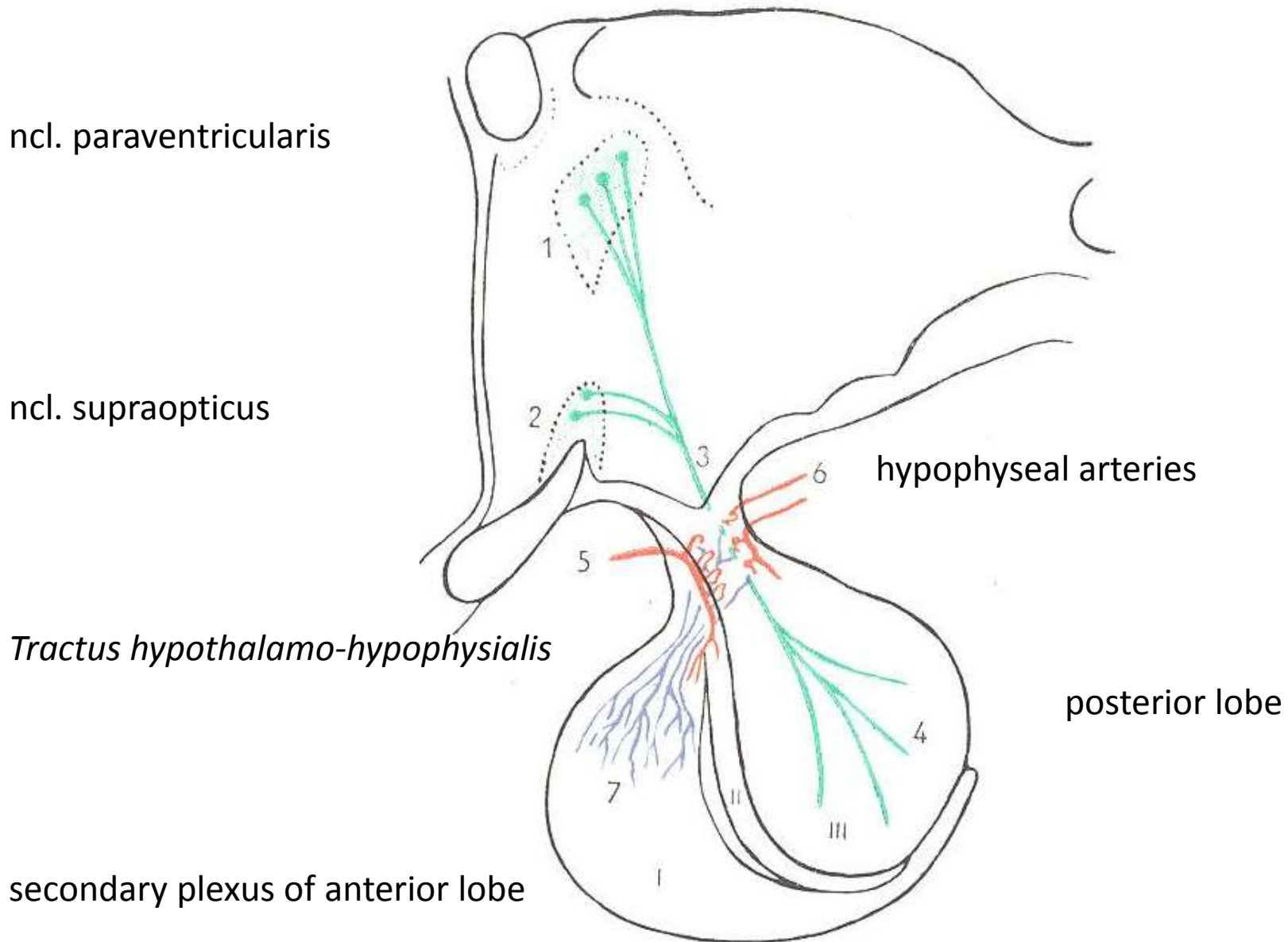
- small region of diencephalon
- complex neuroarchitecture
- core of the limbic system
- complex functions
 - regulation of temperature, emotions, eating behavior, circadian rhythms
 - hormonal regulation controlled by various stimuli (osmoreception, concentration of nutrients, electrolytes, systemic functions - pain)
- hypothalamic nuclei
 - *n. supraopticus, n. paraventricularis*
 - magnocellular neurons - *tractus hypothalamo-hypophysialis*
 - parvocellular neurons - capillaries in *eminentia mediana*

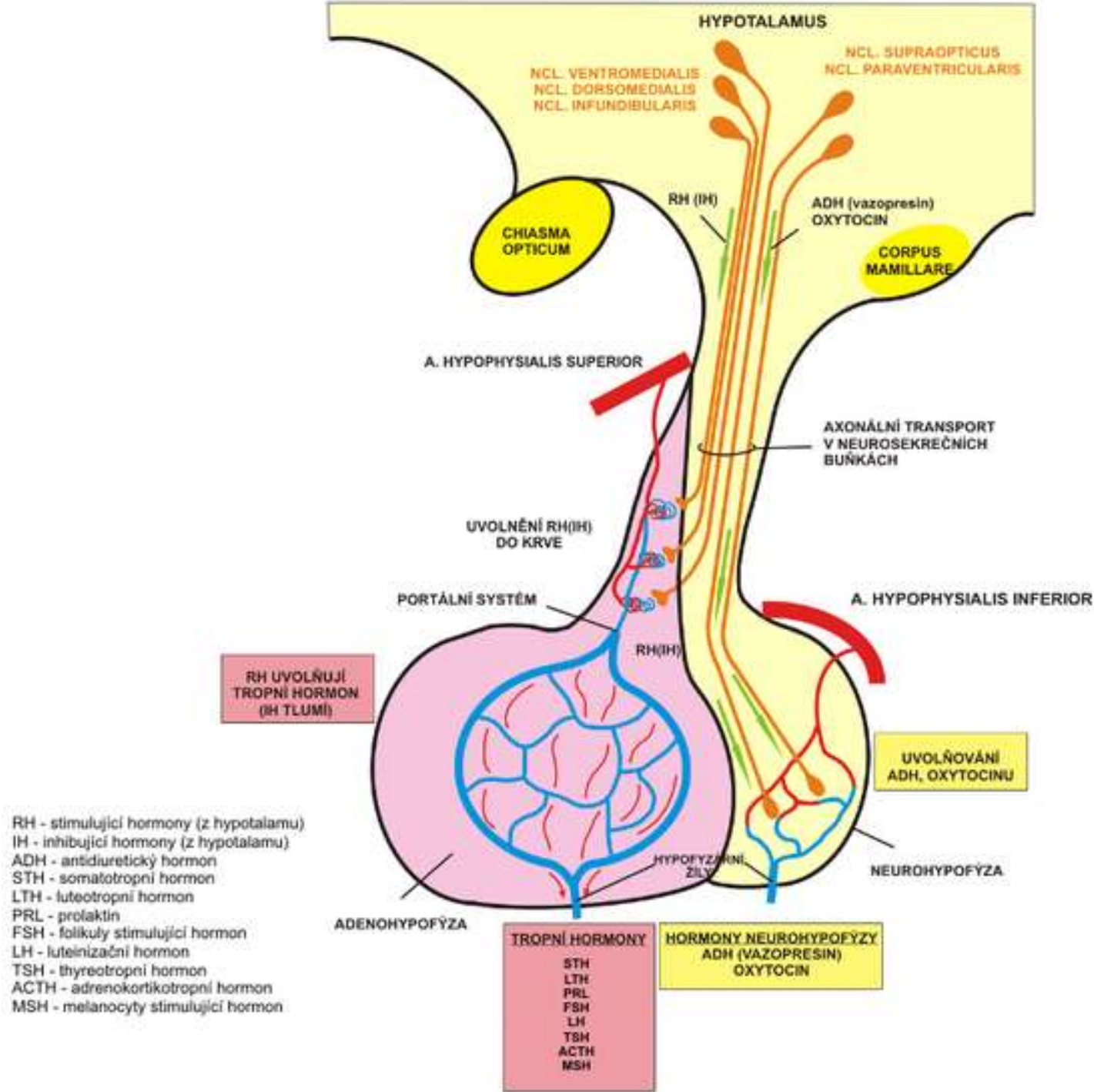


Hypothalamo-hypophyseal system



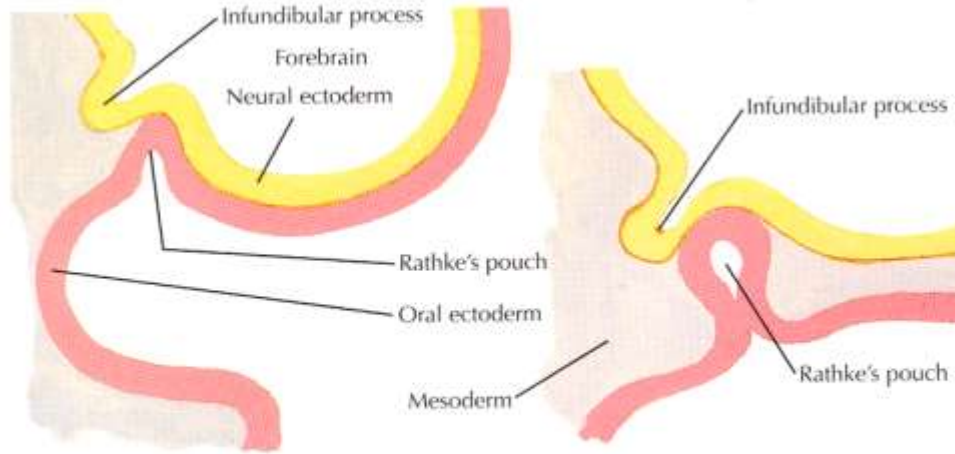
Capillary system of hypophysis





Embryonal development of pituitary gl.

- Ectoderm (Rathke's pouch)
- Neuroectoderm of ventral wall of diencephalon

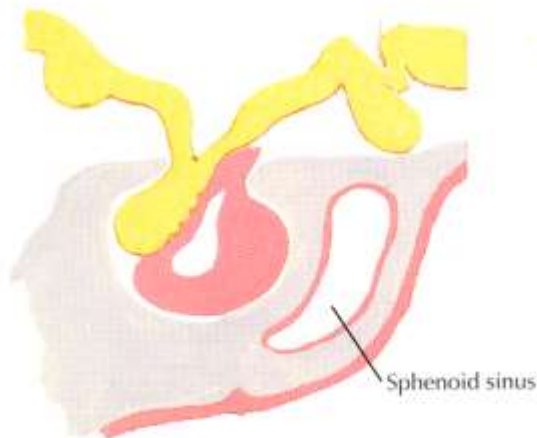


1. Beginning formation of Rathke's pouch and infundibular process

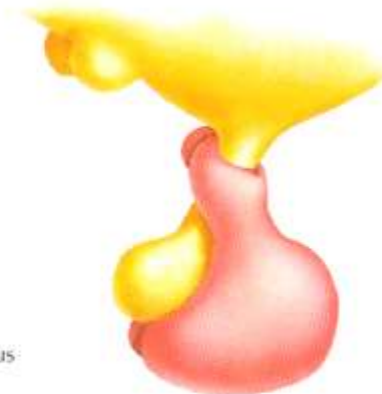
2. Neck of Rathke's pouch constricted by growth of mesoderm



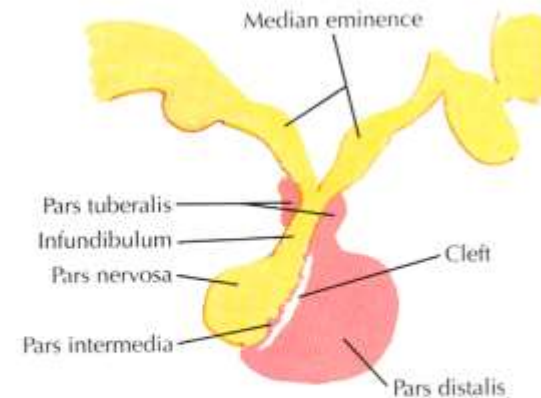
3. Rathke's pouch "pinched off"



4. "Pinched off" segment conforms to neural process, forming pars distalis, pars intermedia and pars tuberalis



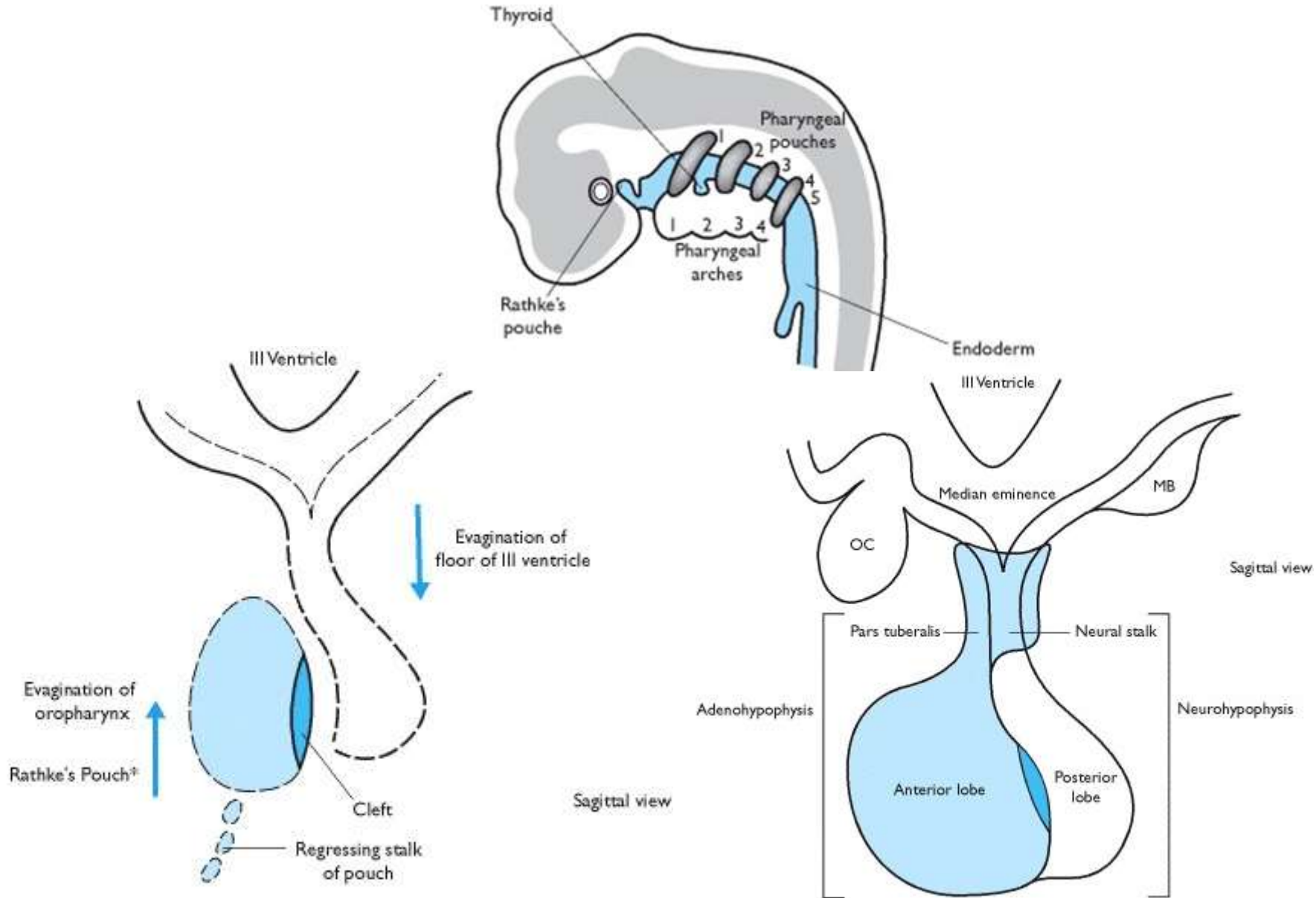
5. Pars tuberalis encircles infundibular stalk (lateral surface view)

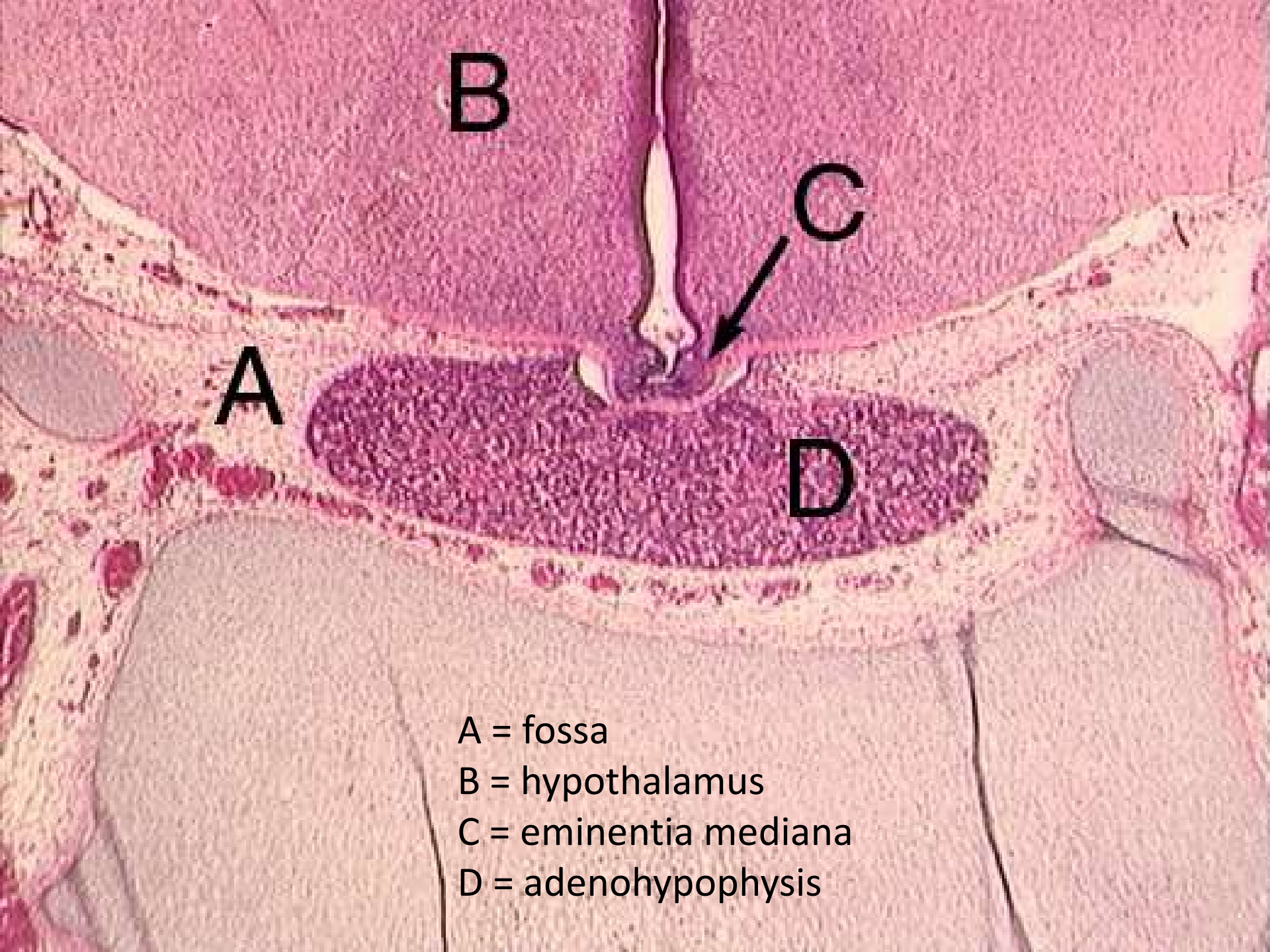


6. Mature form

F. Netter M.D.

Embryonal development of pituitary gl.





- A = fossa
- B = hypothalamus
- C = eminentia mediana
- D = adenohypophysis

Adenohypophysis (anterior lobe)

Chromophilic cells

Acidophils

Nonglandotropic

- direct effect on target tissues

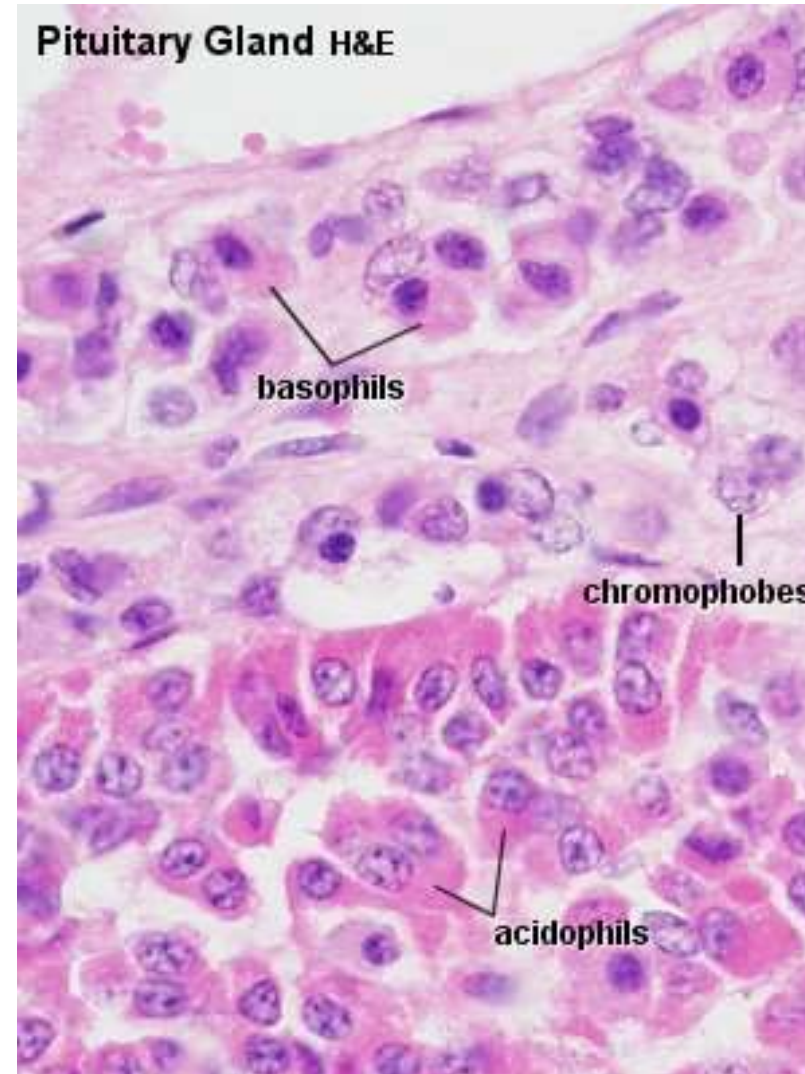
Bazophils

Glandotropic

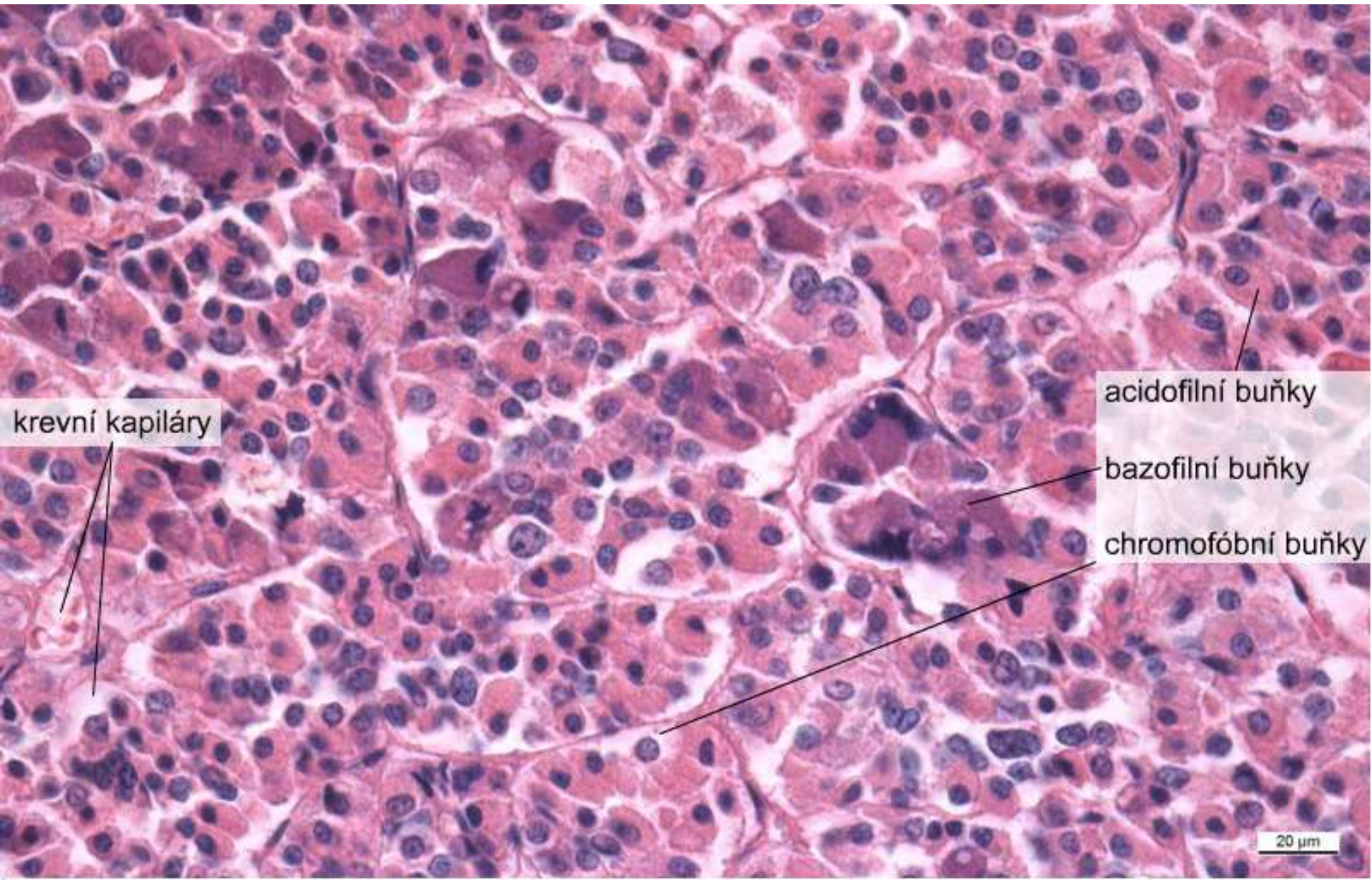
- regulation of other endocrine glands

Chromophobic cells

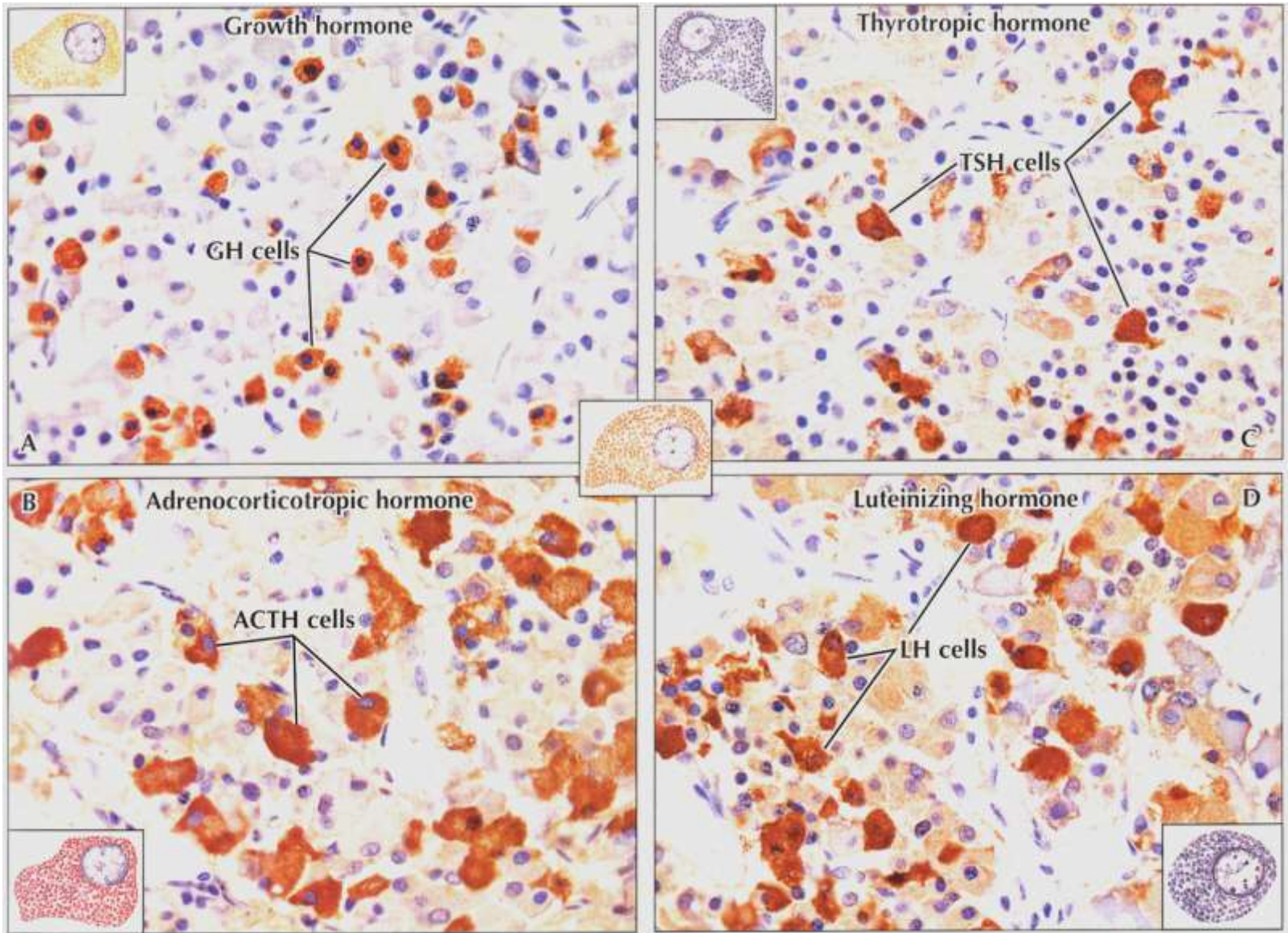
- undifferentiated cells
- degranulated (“empty”) chromophils
- stromal cells



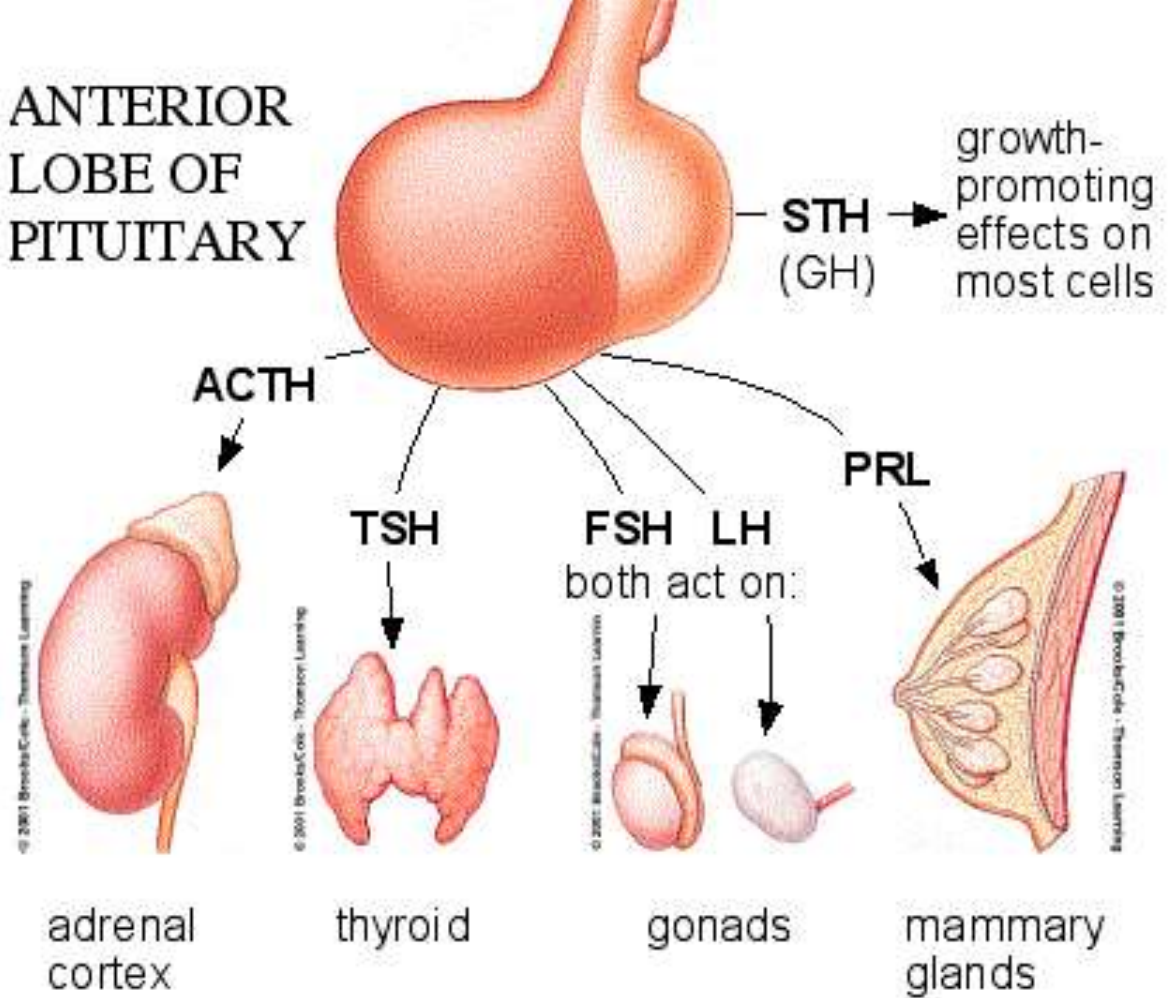
Adenohypophysis (anterior lobe)



Adenohypophysis (anterior lobe)



ANTERIOR LOBE OF PITUITARY



”FLAT PEG”

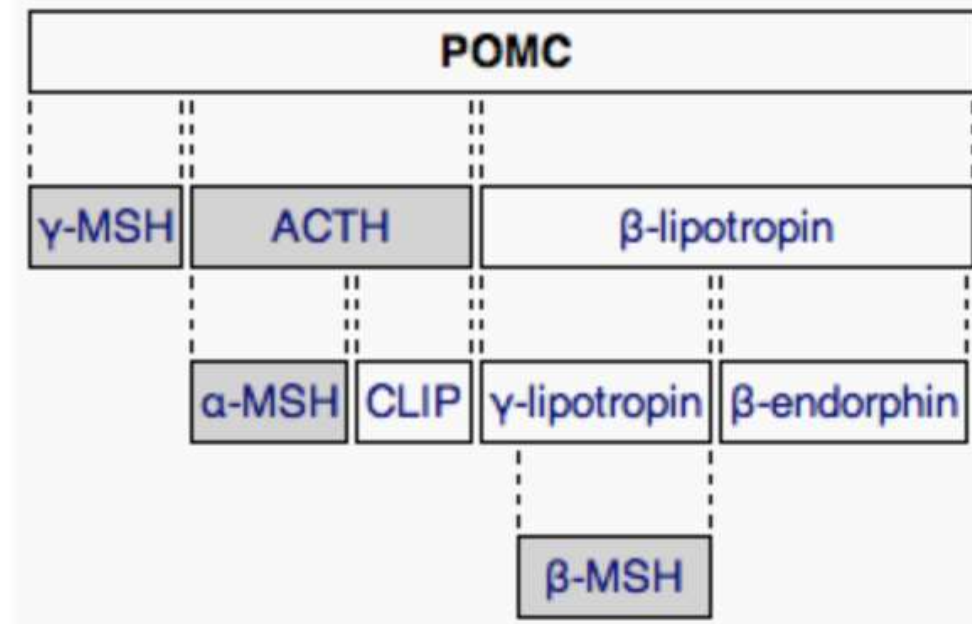
- FSH
- LH
- ACTH
- TSH
- Prolactin
- Endorphins
- Growth hormone

Pro-opio-melanocortin (POMC)

rough ER → pre-prohormon
produced by various tissues

cleavage to

- ACTH (target: adrenal cortex → kortisol)
- MSH (target: melanocytes - mostly in paracrine way)
- lipotropin (lipolysis, steroidogenesis)
- endorphins



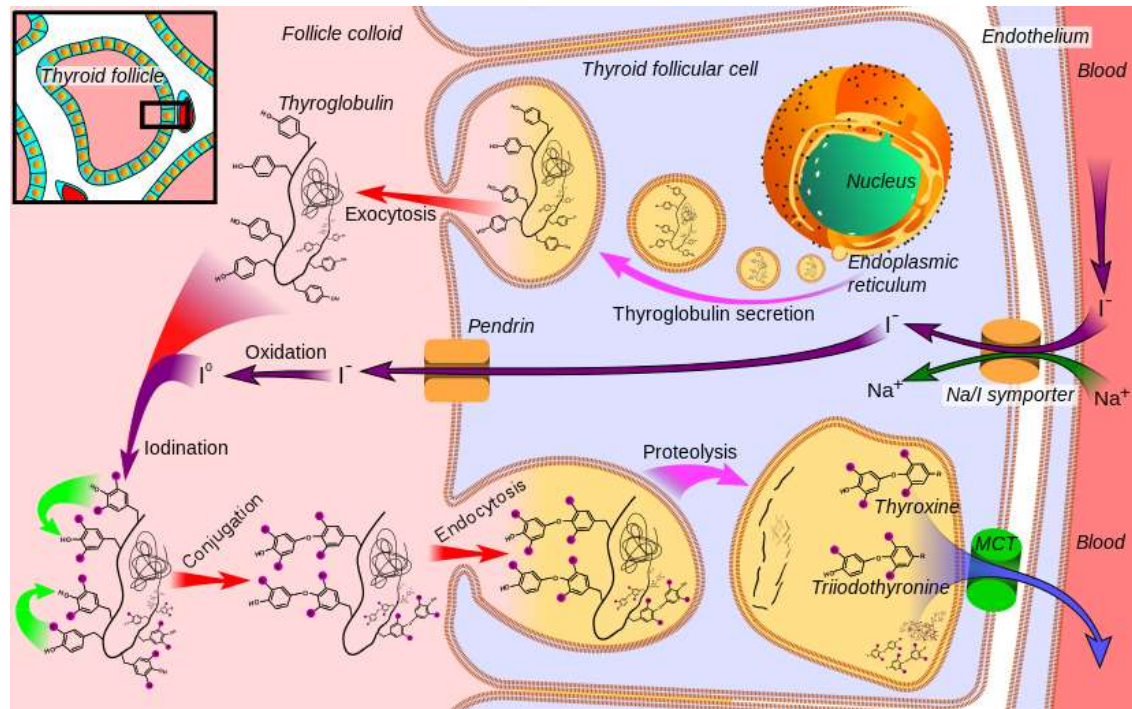
FSH (folitropin), LH (lutropin)

- gonadotropic cells of adenohypophysis stimulated by GnRH
- glycoproteins, 30kDa
- heterodimer, two noncovalent bound subunits (**a/α** - common for - LH, FSH, TSH, hCG, **b/β** - specific)
- FSH receptor (testes, ovarium, uterus) G-protein coupled receptor
 - glycosylated extracellular domain of 11 leucine rich repeats specific to FSH
 - after ligand binding, activation of G-protein and cAMP signaling
 - alternative activation of MAPK cascade (ERK)
 - complex signaling response (prostaglandins, PLPc, NO)

	FSH	LH
ovarium	follicle development (FSHR in m. <i>granulosa cells</i>)	ovulation, development of corpus luteum, production of androgens in thecal cells
testes	spermatogenesis, FSHR in Sertoli cells	production of testosterone in Leydig cells (expression of LHR)
extragonadal	FSHR in secretory endometrium of luteal phase uterus (endometrial functions, embryo-endometrial interactions)	uterus, seminal vesicles, prostate, skin... unknown function

TSH, thyrotropin

- thyrotropic cells of adenohypophysis stimulated by TRH
- production of T4 (thyroxine) and T3 (triiodothyronin) by thyroid gland
- glycoprotein, 28,5 kDa, heterodimer, two noncovalent bound subunits (α, β)
- TSH receptor on thyroid follicular cells
- G-protein signaling → adenylylcyklase → cAMP
- cAMP → iodide channels (pendrin), transcription of thyroglobulin, endo- and exocytic pathway
- cross-reactivity with hCG → in pregnancy - alterations in synthesis of thyroid hormones (gestational hyperthyroidism)



GH, somatotropin, growth hormone

- somatotropic cells of adenohypophysis stimulated by GHRH (somatocrinin)
- several molecular isoforms (alternative splicing), ~20-24 kDa
- broad spectrum of target cell types and physiological circuits
 - transcription of DNA, translation of RNA, proteosynthesis
 - lipid use (fatty acid mobilization, conversion to acetyl-CoA)
 - inhibition of direct use of glucose, stimulation of glukoneogenesis
 - transmembrane transport of aminoacids
 - proteosynthesis in chondrocytes and osteoblasts, proliferation, osteogenesis
- GHR in various tissues
 - RTK, JAK-STAT
- somatomedins
 - small proteins (MW 7,5 kDa), IGF-like
 - produced by liver
- various pathologies associated with GH

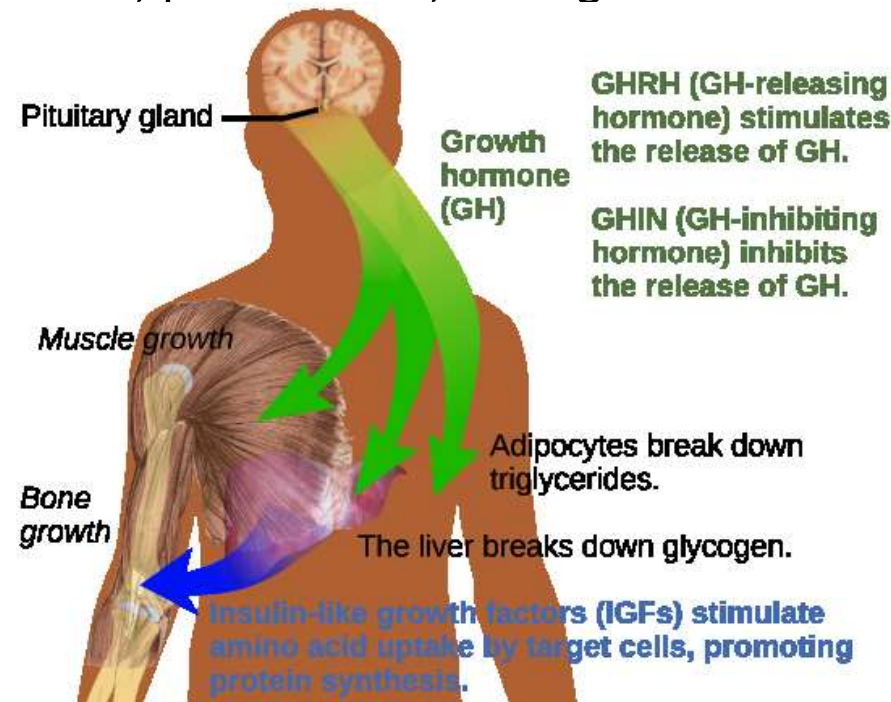


Table 2. Nonclassical Anterior Pituitary Substances and Cell(s) of Origin

Substances	Cell Types
PEPTIDES	
ACTIVIN B, INHIBIN, FOLLISTATIN	F,G
ALDOSTERONE STIMULATING FACTOR	UN
ANGIOTENSIN II (ANGIOTENSINOGEN, ANGIOTENSIN I CONVERTING ENZYME, CATHEPSIN B, RENIN)	C,G,L,S
ATRIAL NATURETIC PEPTIDE	G
CORTICOTROPIN-RELEASING HORMONE-BINDING PROTEIN	C
DYNORPHIN	G
GALANIN	L,S,T
GAWK (CHROMOGRANIN B)	G
GROWTH HORMONE RELEASING HORMONE	UN
HISTIDYL PROLINE DIKETOPIPERAZINE	UN
MOTILIN	S
NEUROMEDIN B	T
NEUROMEDIN U	C
NEUROPEPTIDE Y	T
NEUROTENSIN	UN
PROTEIN 7B2	G,T
SOMATOSTATIN 28	UN
SUBSTANCE P (SUBSTANCE K)	G,L,T
THYROTROPIN RELEASING HORMONE	G,L,S,T
VASOACTIVE INTESTINAL POLTPEPTIDE	G,L,T
GROWTH FACTORS	
BASIC FIBROBLAST GROWTH FACTOR	C,F
CHONDROCYTE GROWTH FACTOR	UN
EPIDERMAL GROWTH FACTOR	G,T
INSULIN-LIKE GROWTH FACTOR I	S,F
NERVE GROWTH FACTOR	UN
PITUITARY CYTOTROPIC FACTOR	UN
TRANSFORMING GROWTH FACTOR ALPHA	L,S,G
VASCULAR ENDOTHELIAL GROWTH FACTOR	F
CYTOKINES	
INTERLEUKIN-1 BETA	T
INTERLEUKIN-6	F
LEUKEMIA INHIBITORY FACTOR	C,F
NEUROTRANSMITTERS	
ACETYLCHOLINE	C,L
NITRIC OXIDE	F

C = corticotroph, F = folliculostellate cell, G = gonadotroph, L = lactotroph,
S = somatotroph, T = thyrotroph, UN = unknown

Clinical links

Hypophyseal tumors

- compression of surrounding structures (optic chiasma)
- hyperfunction of endocrine component
 - prolactinoma - galactorrhea
 - hypogonadism (alterations of GnRH)
 - gigantism - acromegaly
 - nanism



Posterior hypophysis (neurohypophysis)

nonmyelinated nerve fibers

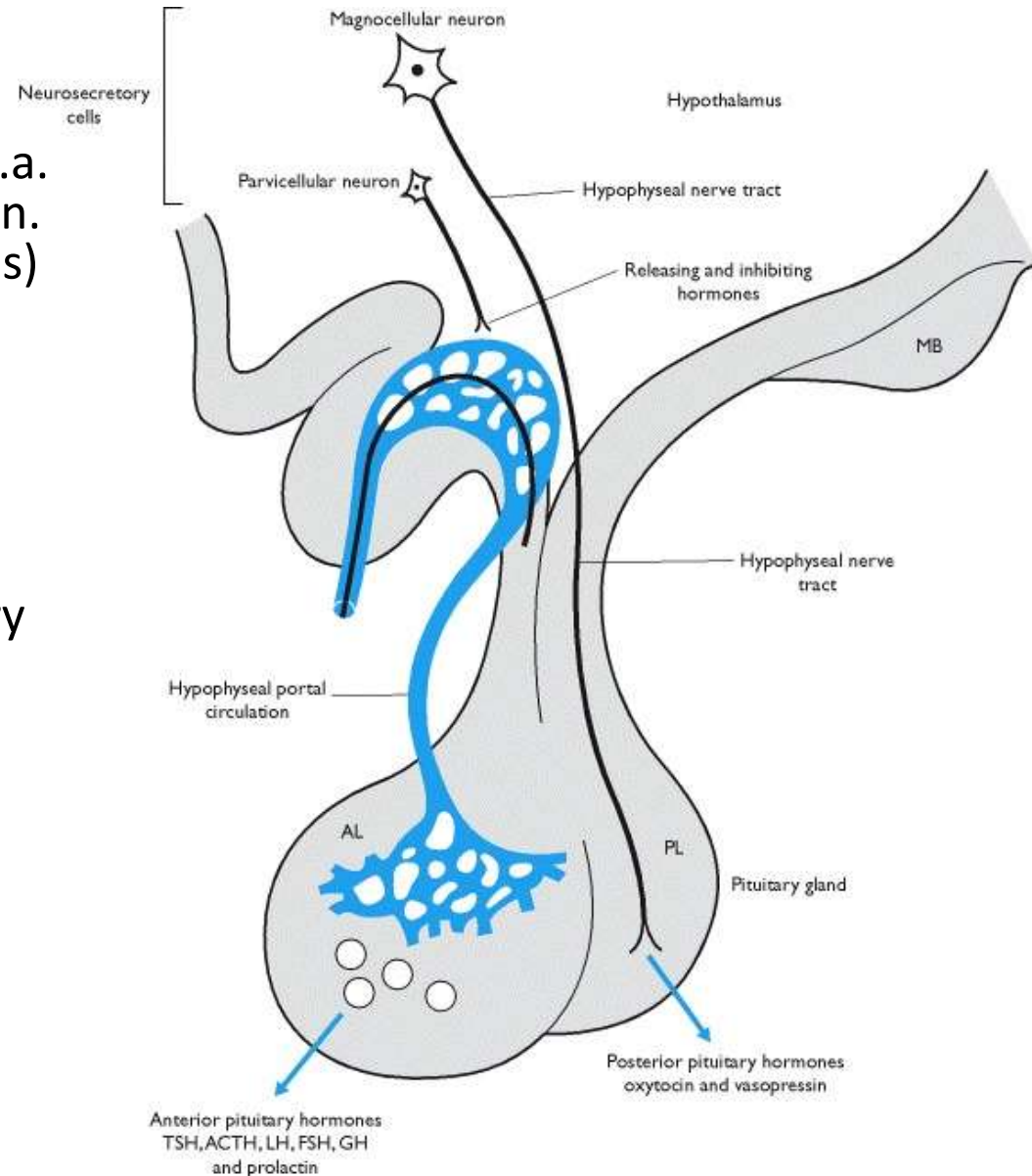
– axons of neurosecretory cells (c.a. 100 000) of hypothalamic nuclei (n. supraopticus and paraventricularis)

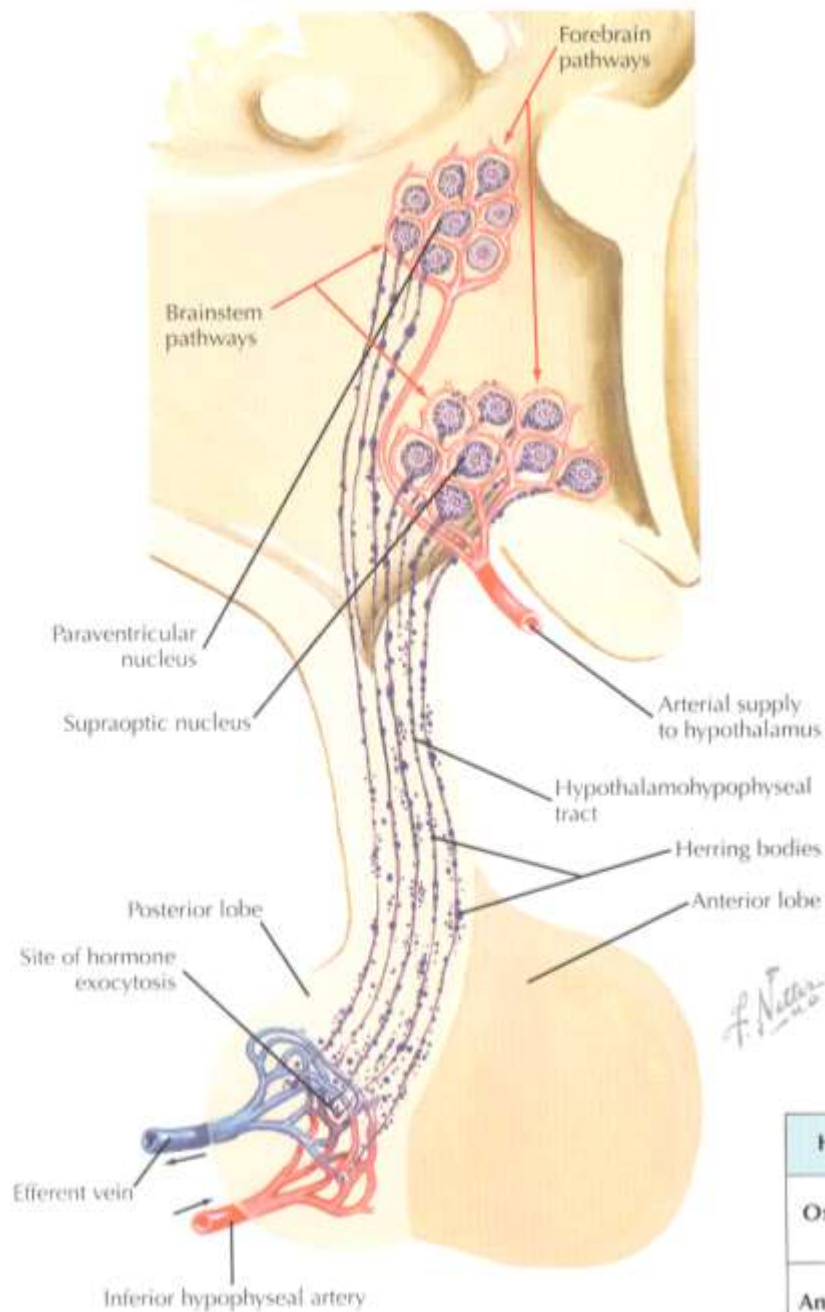
pituicytes (neuroglia)

- astrocyte-like (intermediate filaments, GFAP)
- local control of secretion from neurosecretory termini
- Herring bodies – neurosecretory endings – dilatation close to capillaries

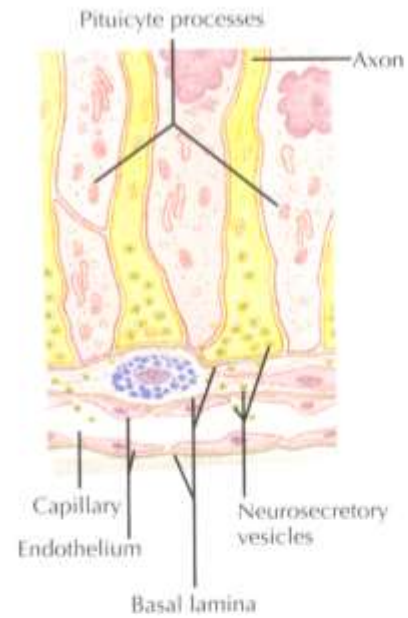
Hormones

- oxytocin (OT)
- antidiuretic hormone (ADH, vasopressin)

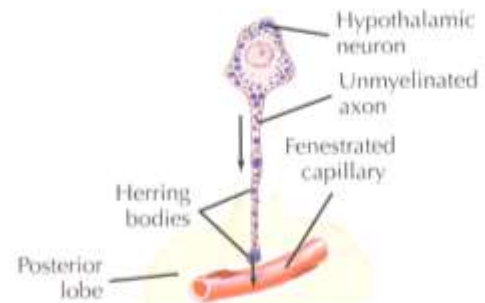




▼ Neurosecretory Ending (posterior pituitary).

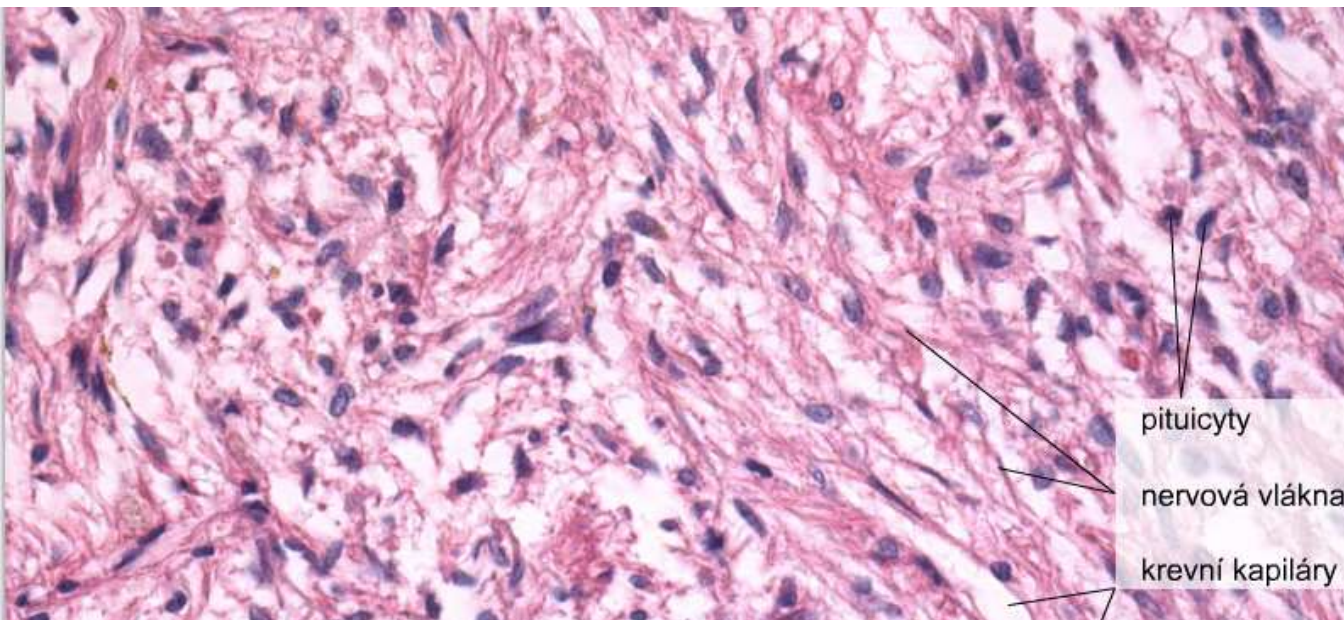


▼ Origin of ADH.

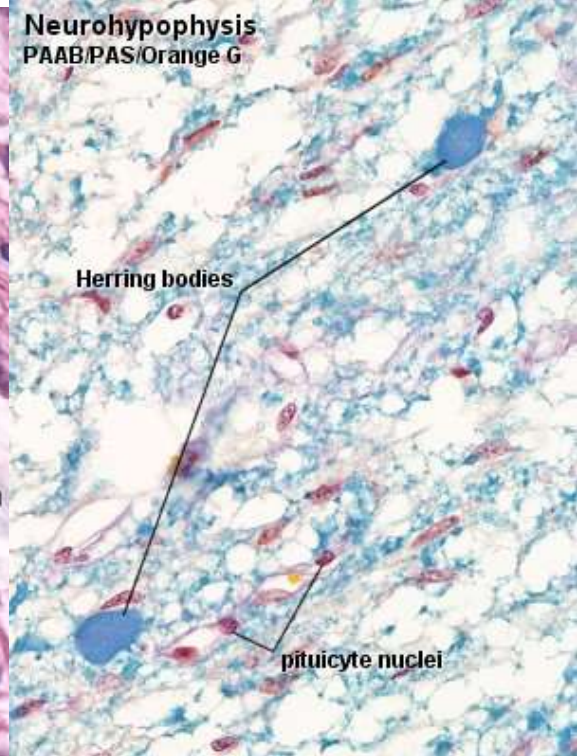


F. Netter M.D.

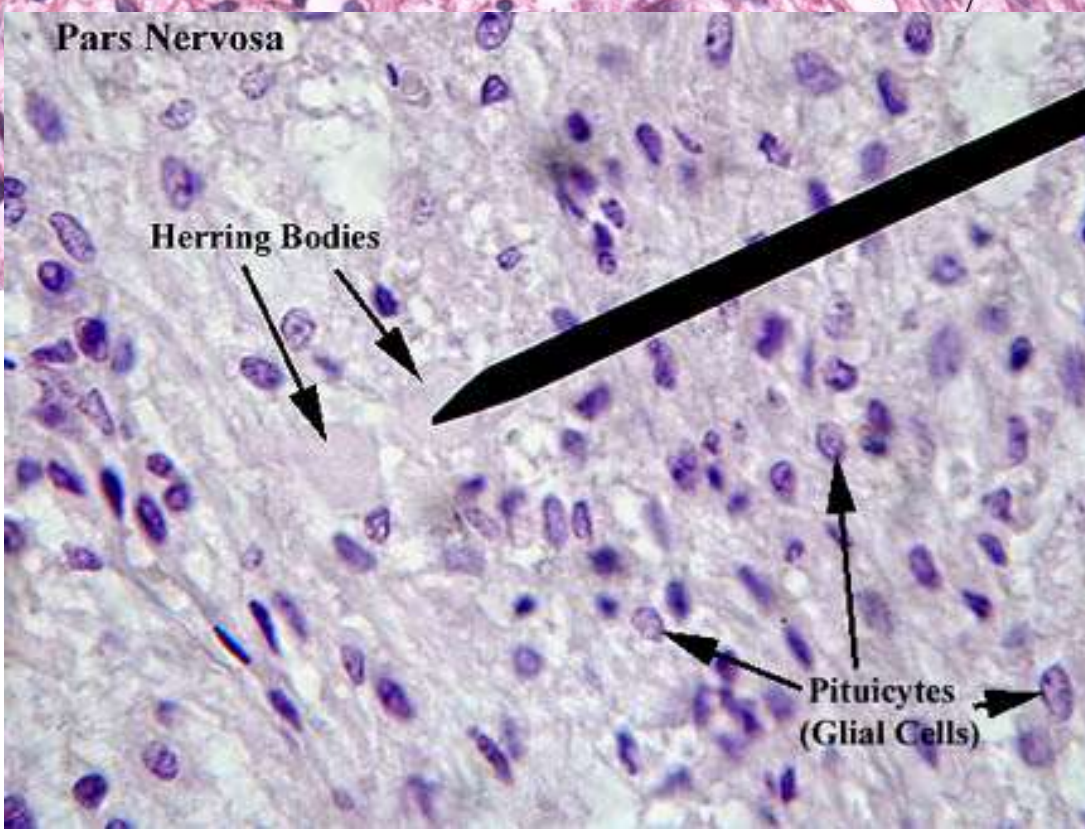
Hormone	Principal Action	Principal Nucleus of Origin
Oxytocin (OXY)	Uterine contraction, milk ejection	Paraventricular
Anti-diuretic hormone (ADH)	Water excretion in kidney, arteriolar constriction	Supraoptic



pituicyty
nervová vlákna
krevní kapiláry



Herring bodies
pituicyte nuclei



Pars Nervosa

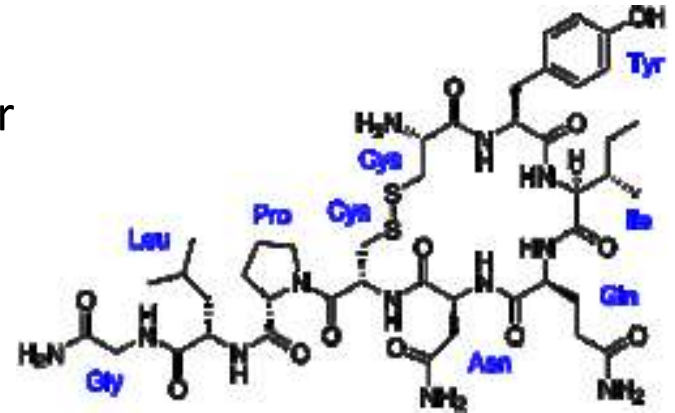
Herring Bodies

Pituicytes
(Glial Cells)

20 μm

Oxytocin

- nonapeptide
- magno-cellular supraoptic and paraventricular hypothalamus
- OR - G-coupled receptor
- lactation reflex
- uterine contraction
- social behavior



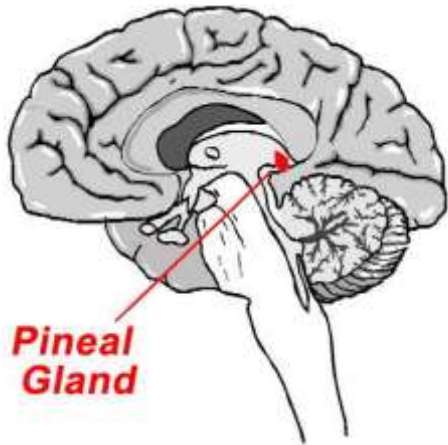
Vasopressin

- nonapeptide
- retention of water
- effective in collecting duct and distal convoluted tubule (aquaporine translocations)
- blood pressure regulation by affecting t. media
- diabetes insipidus, hypernatremia, polyuremia

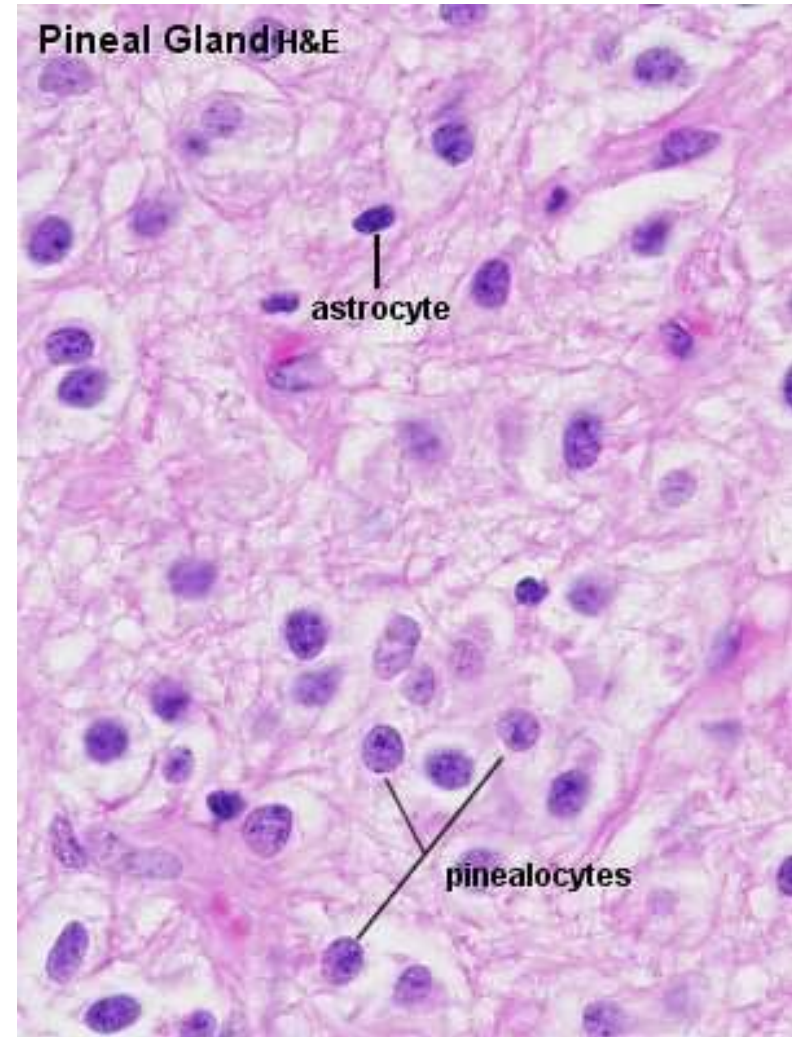


Anatomy			Microscopic anatomy		Hormones and target tissues			
Anterior lobe (adenohypophysis)	pars distalis	superior hypophyseal arteries → primary capillary plexus → hypophyseal portal veins + inferior hypophyseal arteries → secondary capillary plexus → hypophyseal portal veins → vv. jugulares internae	trabecular epithelium in cords and clusters, reticular fibers		lack hormonal activity			
			chromophobes	undifferentiated cells degranulated chromophilic cells stromal cells				
			pars tuberalis	chromophils	acidophilic nonglandotropic	mammotropic cells	small polypeptides	dopamin (PIH) ⊥ (PRF → prolactin)
	somatotropic cells					somatostatin (GHIH) ⊥ GHRH → somatotropin (STH)		directly liver and growth plates other tissues via somatomedins
	chromophils			basophilic glandotropic	corticotropic cells	glycoproteins	CRH → ACTH, MSH	adrenal cortex → cortisol melanocytes
			thyrotropic cells		TRH → TSH		thyroid → thyroxin, T3	
gonadotropic cells	GnRH → FSH (ICSH), LH	gonads → androgens, estrogens, progesterone						
pars intermedia	Rathke's cysts							
Posterior lobe (neurohypophysis)	eminentia mediana → infundibulum	anterior and posterior superior hypophyseal arteries →	nonmyelinated axons of hypothalamic neurons n. supraopticus, n. paraventricularis (tractus hypothalamohypophysialis), pituicytes			small peptides	ADH	tubulus reuniens, ductus colligens t.media of vessels
	pars nervosa	primary capillary plexus, fenestrated capillaries					oxytocin	myometrium of uterus during gravidity myoepithelium of lactating mammary gland

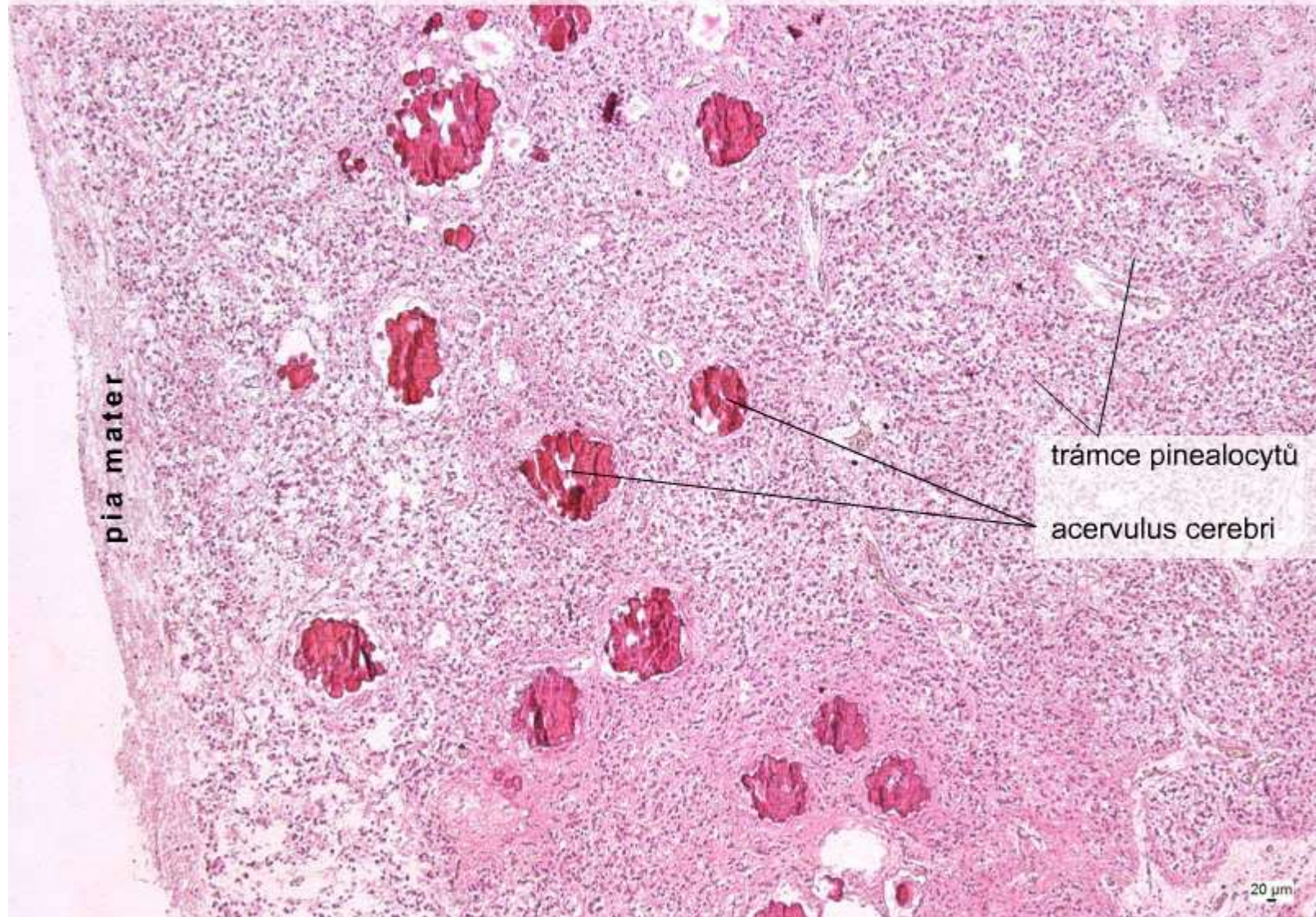
Epiphysis (*c. pineale*)



- epithalamus
- c.t. capsule continuous to pia mater
- thin c.t. septa
- nonmyelinated nerve fibers
- **pinealocytes** (95%, large, pale, round nuclei)
- interstitial neuroglia (astrocytes, dark, elongated nuclei)
- *acervulus cerebri*
- melatonin



Epiphysis, (HE), objektiv 5×



pia mater

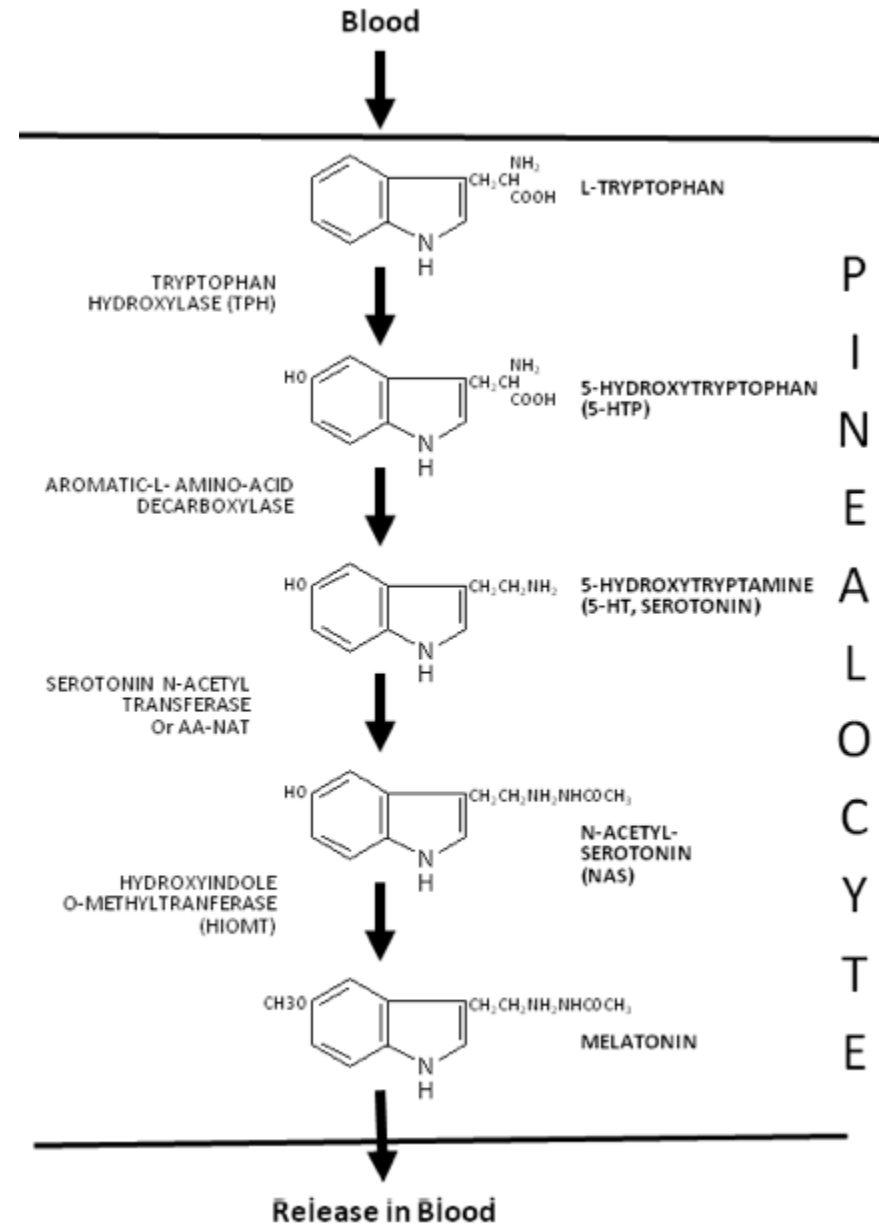
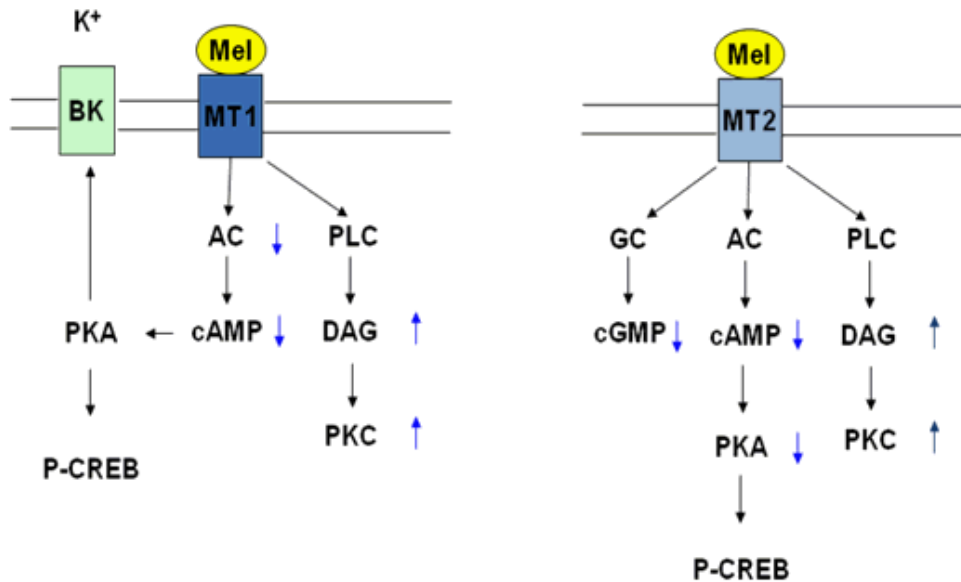
trámce pinealocytů

acervulus cerebri

20 μm

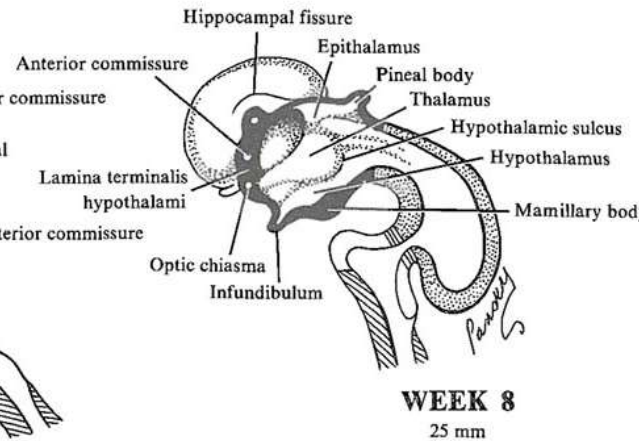
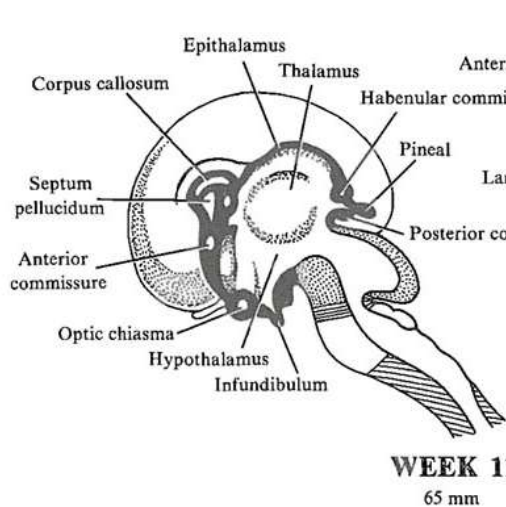
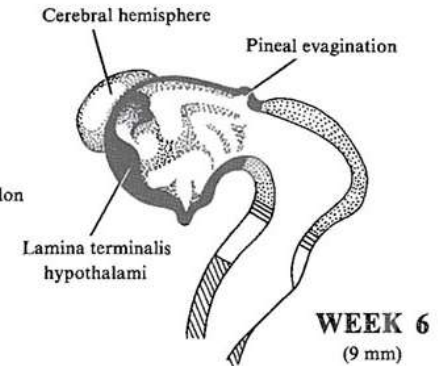
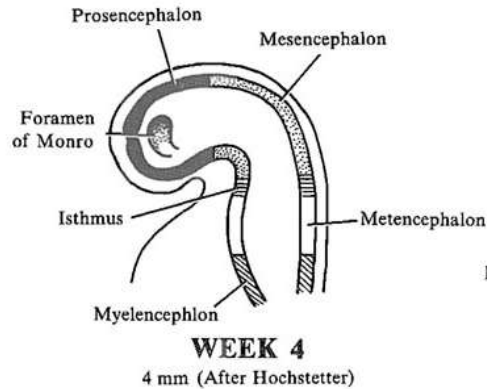
Epiphysis (*c. pineale*)

- pinealocytes
- star-like, modified neurons in trabecules
- association with fenestrated capillaries
- neurosecretory dilatations
- nonvisual photoreception



Embryonic development of epiphysis (*c. pineale*)

- thickening of caudal part of ependyma that does not contribute to development of choroid plexus at the roof of diencephalon
- neuroectoderm



Thyroid gland (*gl. thyroidea*)

- Follicular cells → thyroid hormones (T3, T4)
- **C cells** → calcitonin

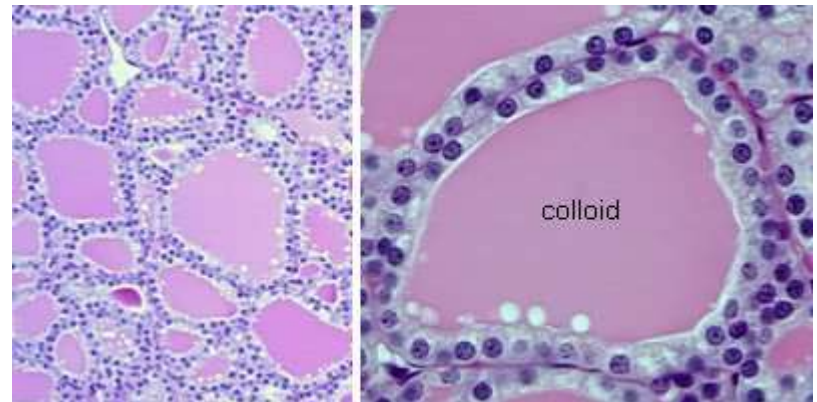
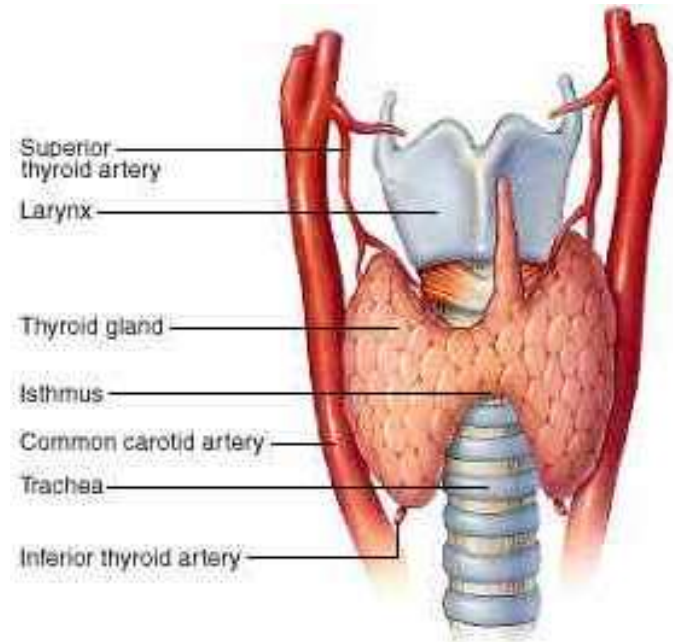
C.t. capsule, septa

Lobes → lobuli - follicles

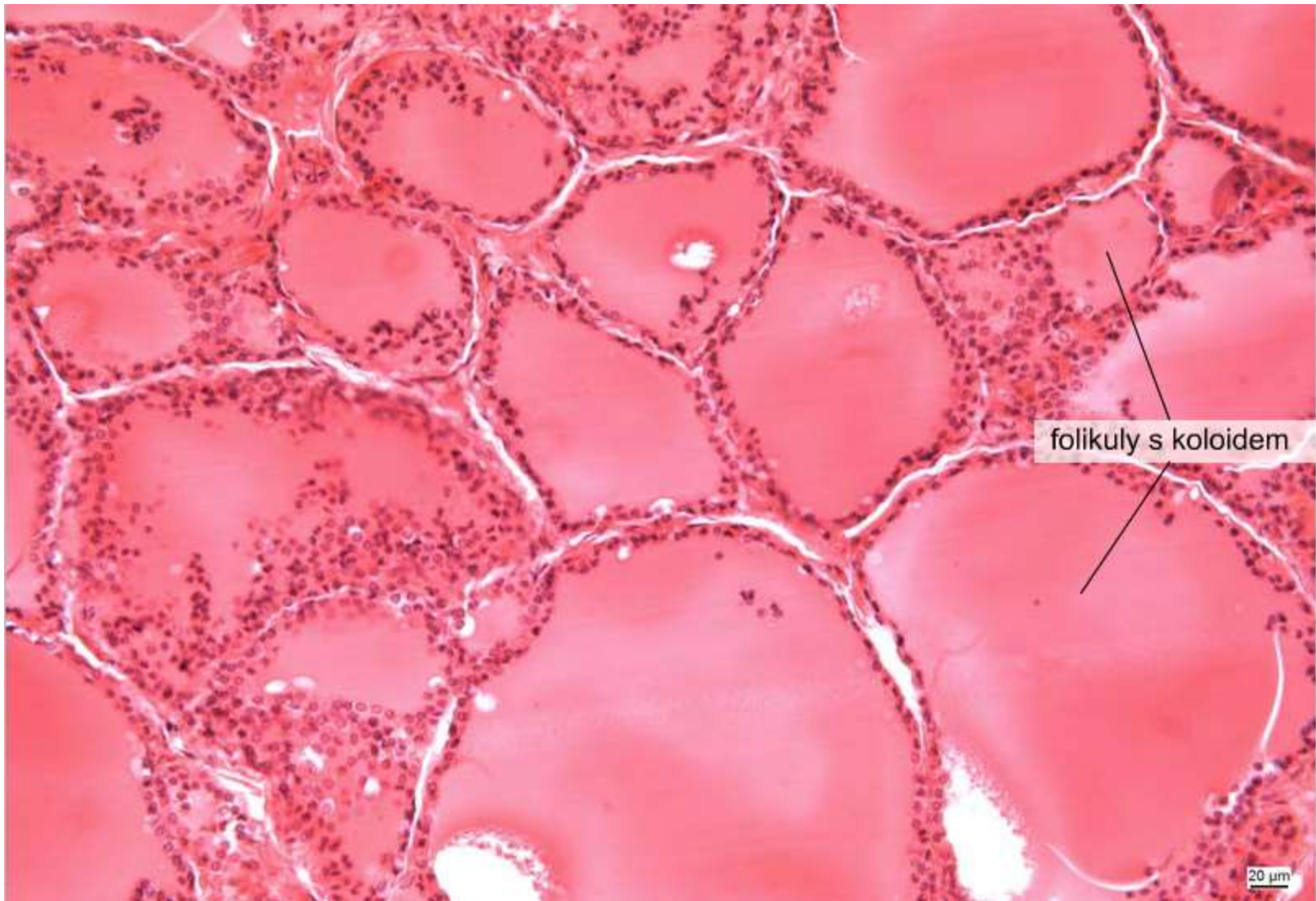
Follicles (50 μm - 1 mm)

- separated by interstitial loose collagen c.t.
- simple epithelium (flat to cubic, according to secretory activity)
- colloid

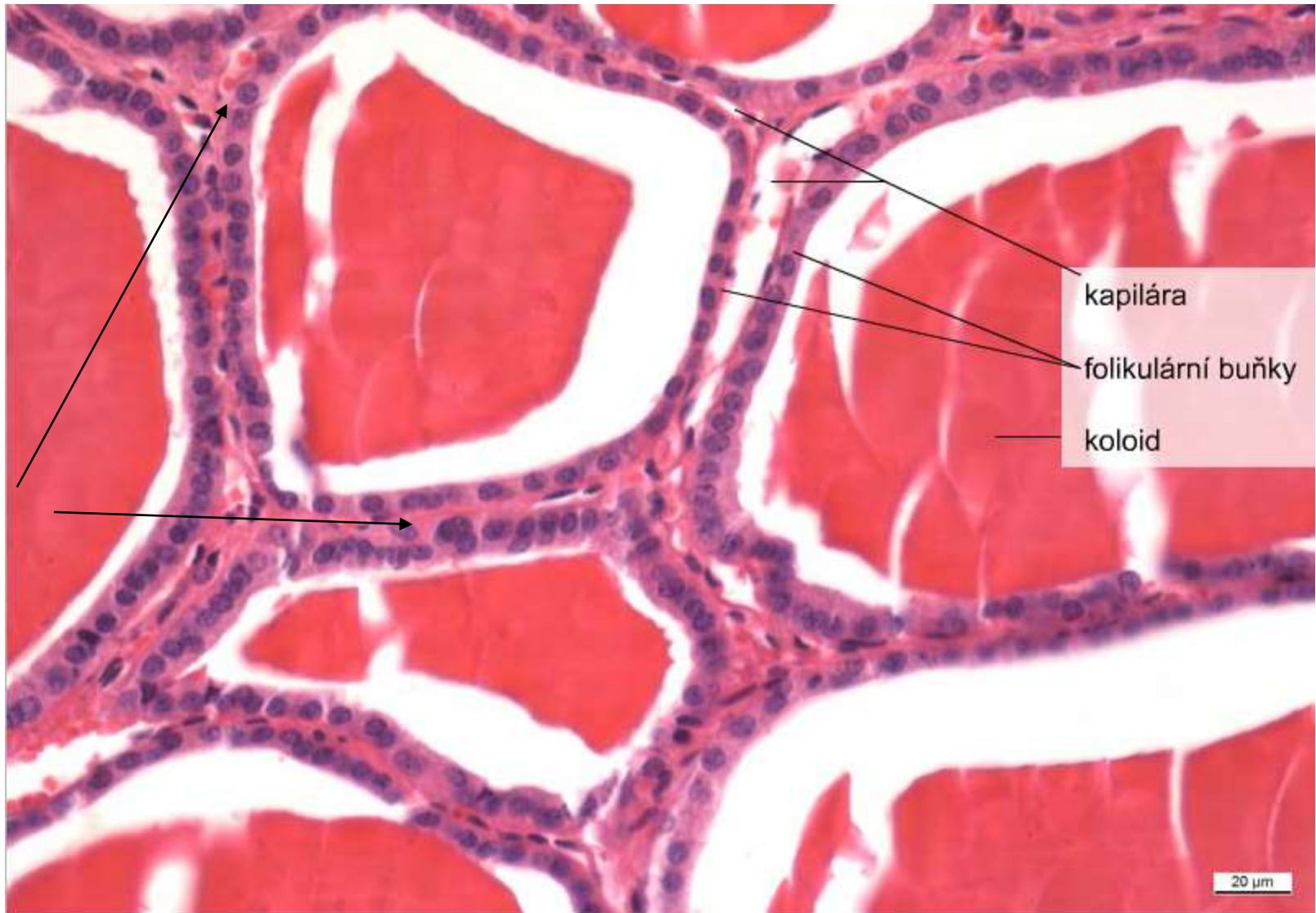
Capillary network from thyroid arteries



Thyroid gland - follicles



Thyroid gland - follicles



C-cells

kapilára

folikulární buňky

koloid

20 µm

Follicular cells and C-cells (parafollicular)

Synthesis of T3 and T4

T4 synthesis in thyroid

- sodium-iodide symporter transports two Na^+ and one I^- across the basement
- I^- is moved across the apical membrane into the colloid of the follicle.
- thyroperoxidase oxidises $2 \text{I}^- \rightarrow \text{I}_2$.
- thyroperoxidase iodinates the tyrosyl residues of thyroglobulin
- (TSH) stimulates the endocytosis of the colloidal content
- endocytic vesicles + lysosomes, lysosomal enzymes cleave T_4 from the iodinated thyroglobulin
- exocytosis

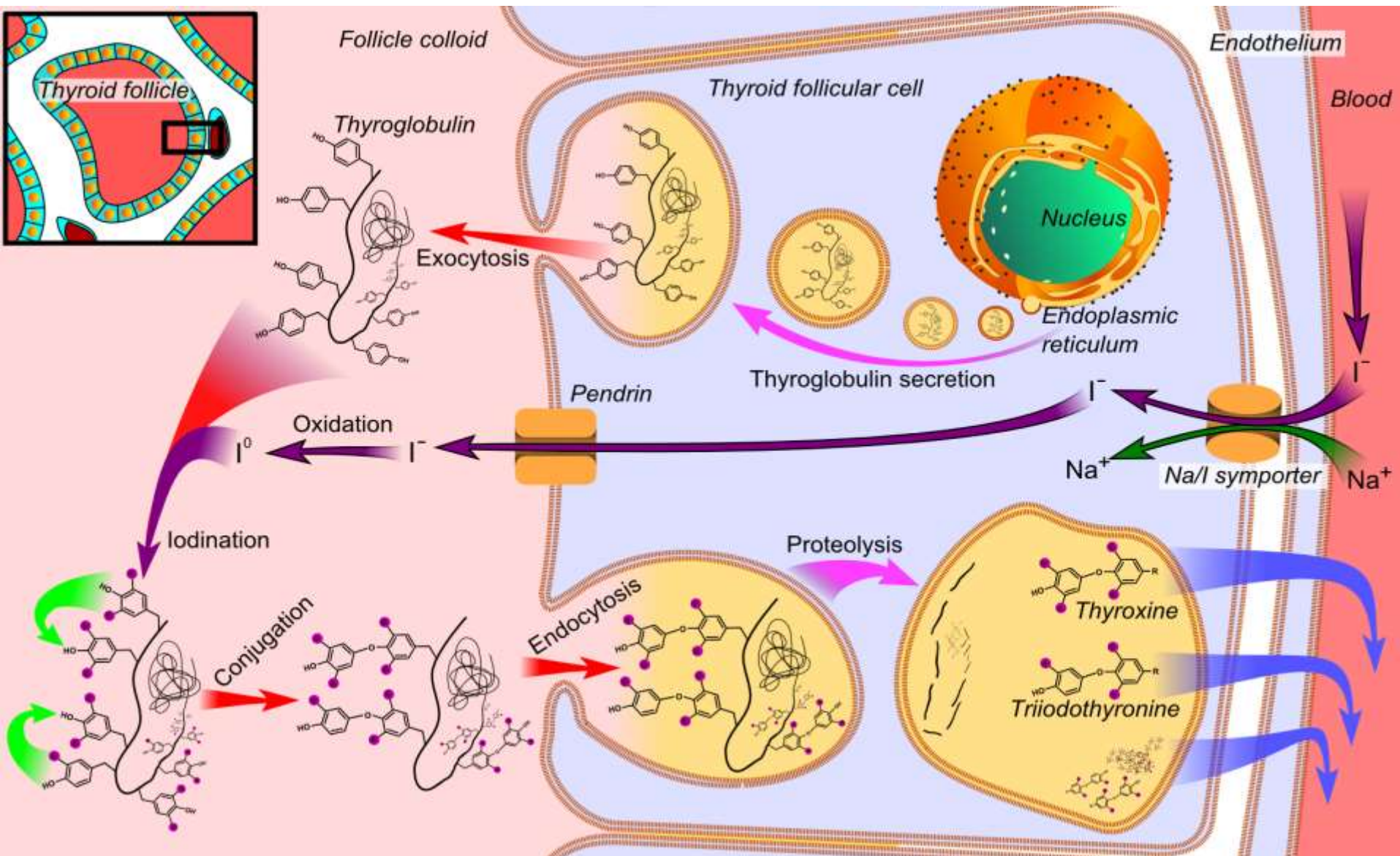
T3 synthesis from T4

- T4 half-life in blood 6.5 days, T3 2.5 (T4 is a reservoir for T3)
- deiodination by tissue specific deiodinase enzymes generates T3

thyreoglobulin

triiodothyronin T_3

tetraiodothyronin (thyroxin) T_4



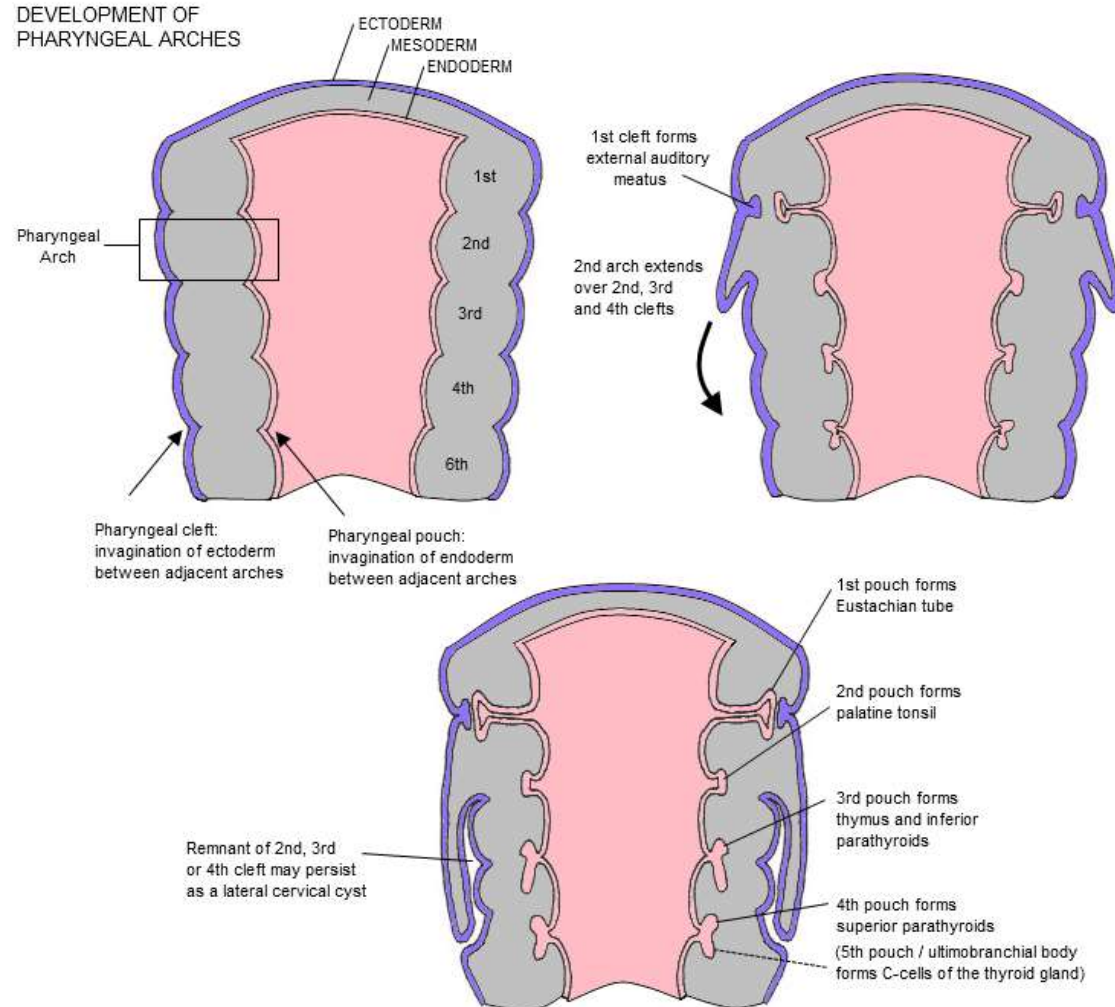
C-cells of thyroid

Neuroendocrine cells

- pale staining
- epithelial basis, under basal lamina no contact with colloid
- derived from neural crest
- associate with ultimobranchial body, (derivative of the 4th pharyngeal pouch)

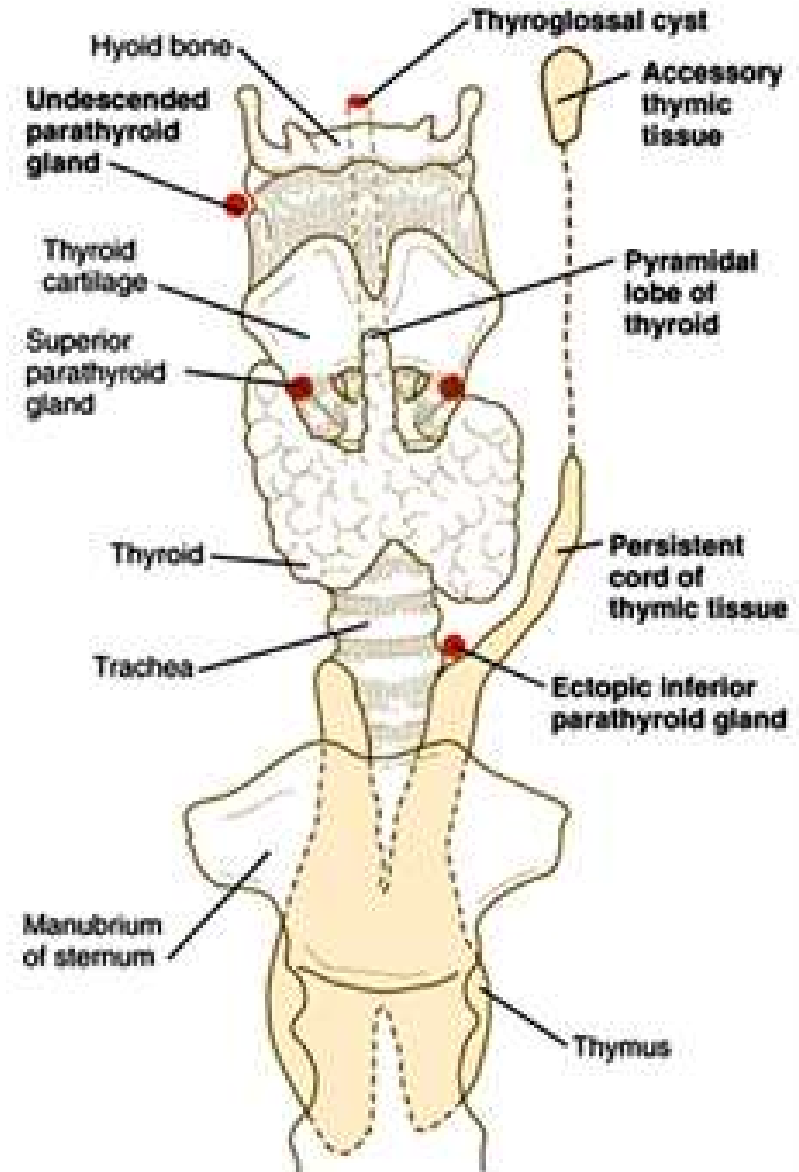
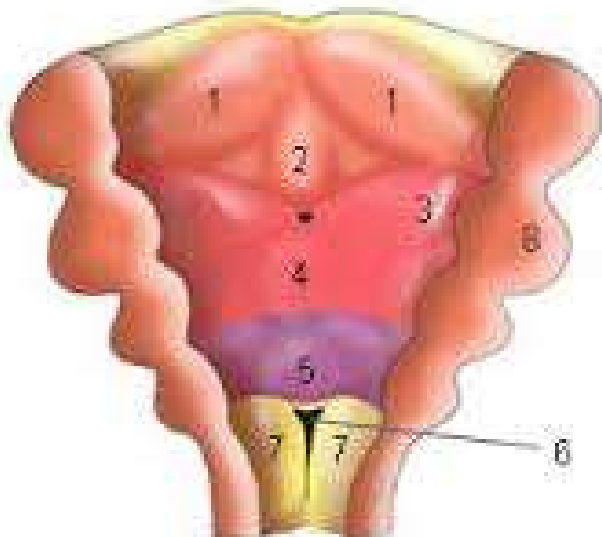
Calcitonin

- inhibition of osteoclasts



Thyroid development

- endodermal proliferation of pharyngeal floor
- hypobranchial eminence and foramen caecum
- bilobed diverticulum
- ductus thyreoglossus



Parathyroid gland (gl. parathyreoidea)

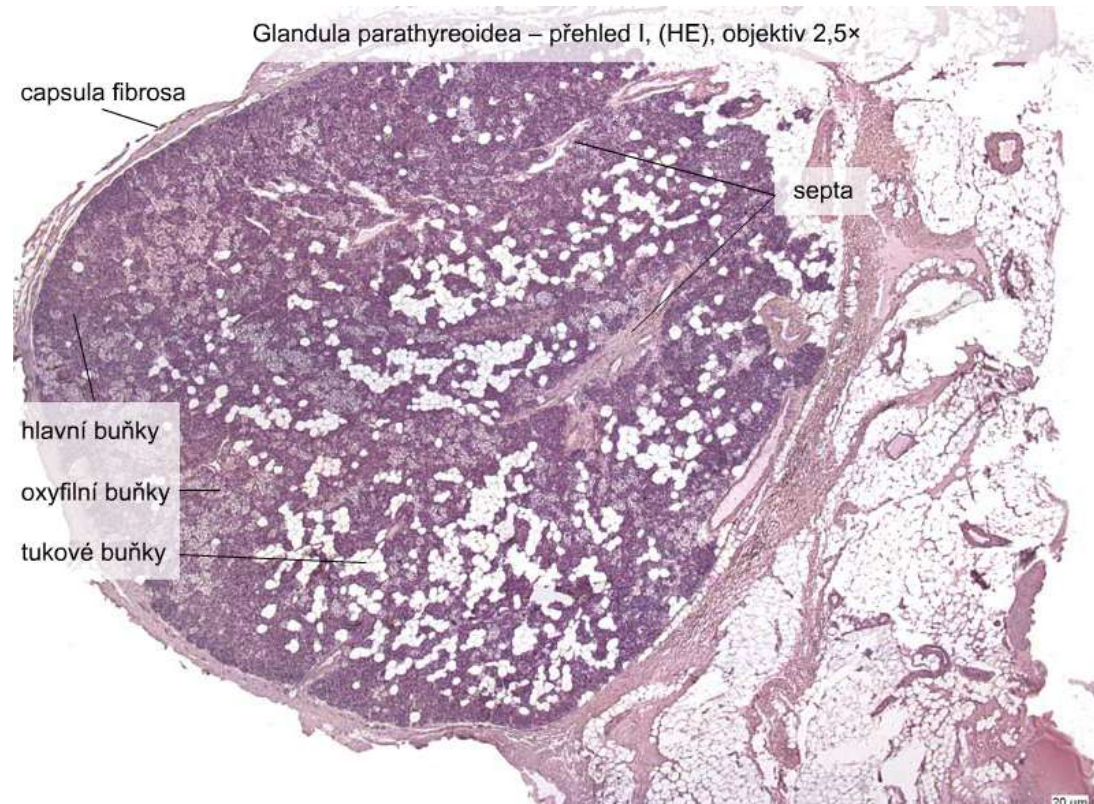
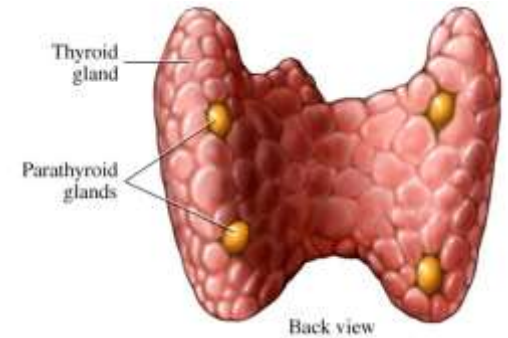
6 mm, 130 mg

c.t. capsule and septa

Capillary network

Cords and clusters of glandular cells

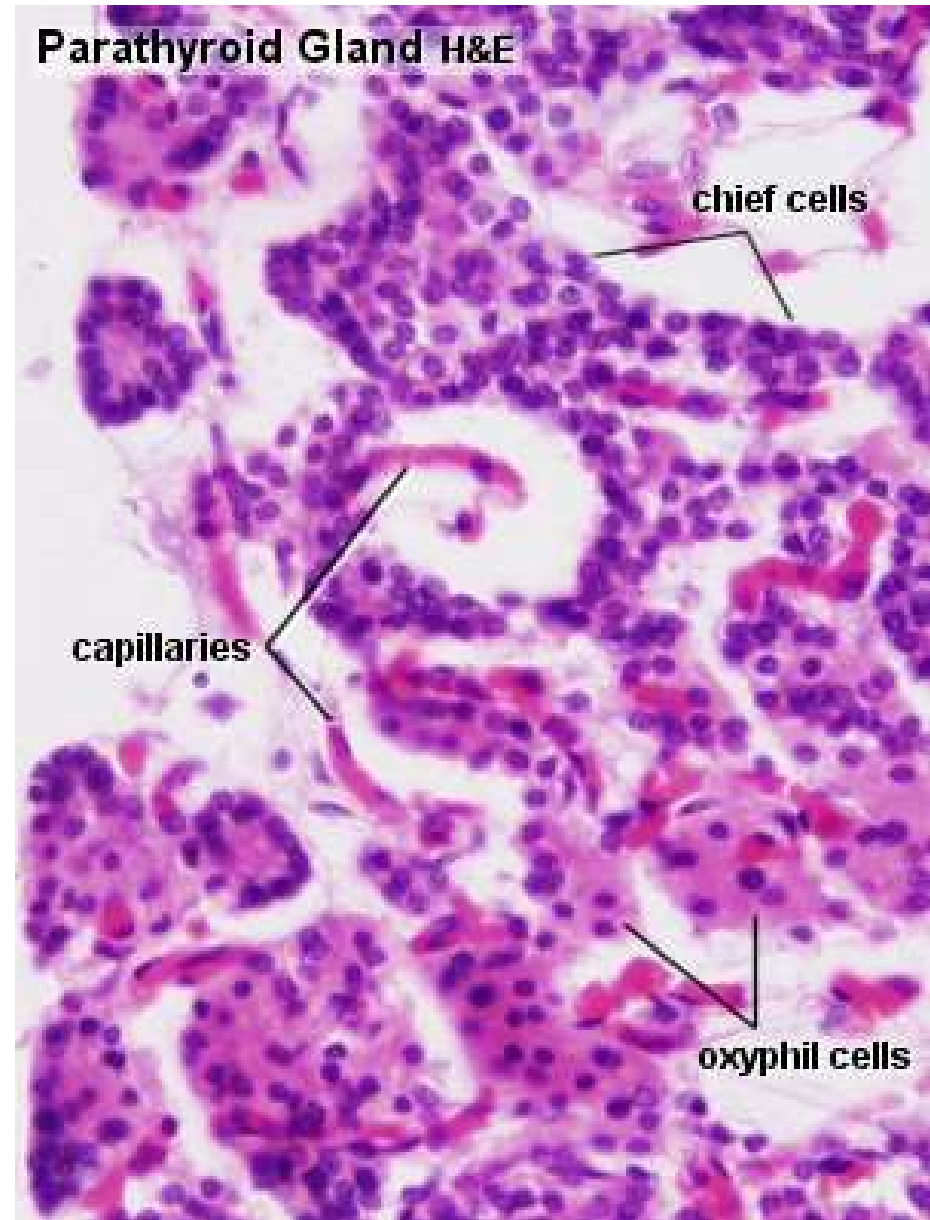
- Chief
- Oxyphilic
- Adipose



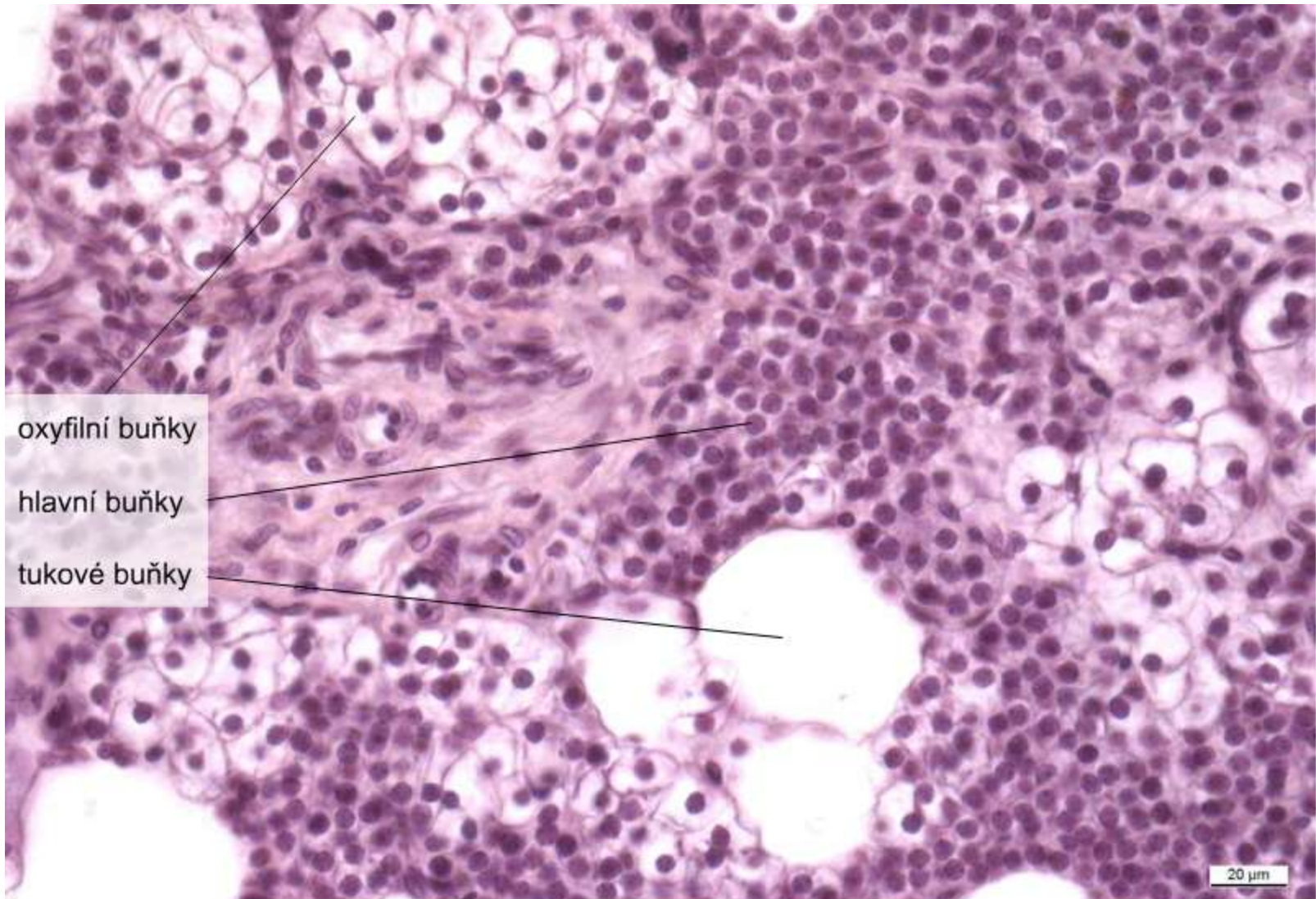
Parathyroid gland (gl. parathyreoidea)

- **Chief**
 - most abundant
 - small cells (7-10 μ m, big nucleus
 - mildly acidophilic
 - PTH – calcium metabolism

- **Oxyphylic**
 - large, polyhedral,
 - strongly acidophilic
 - round nucleus
 - glycogen

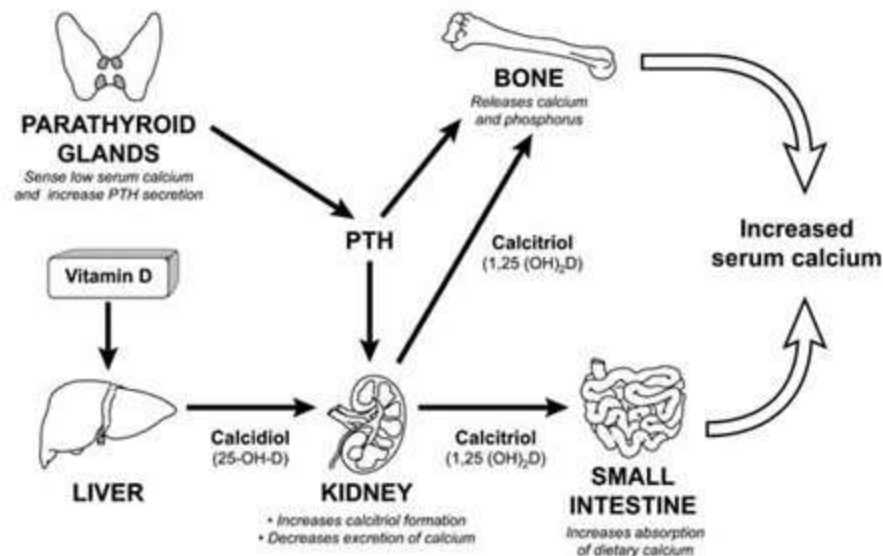
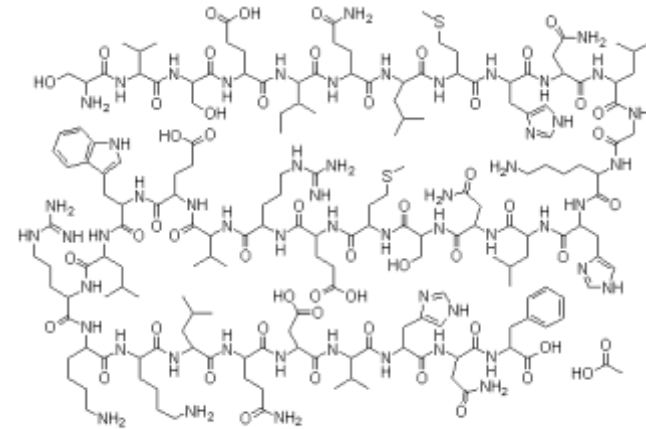


Parathyroid gland (gl. parathyreoidea)

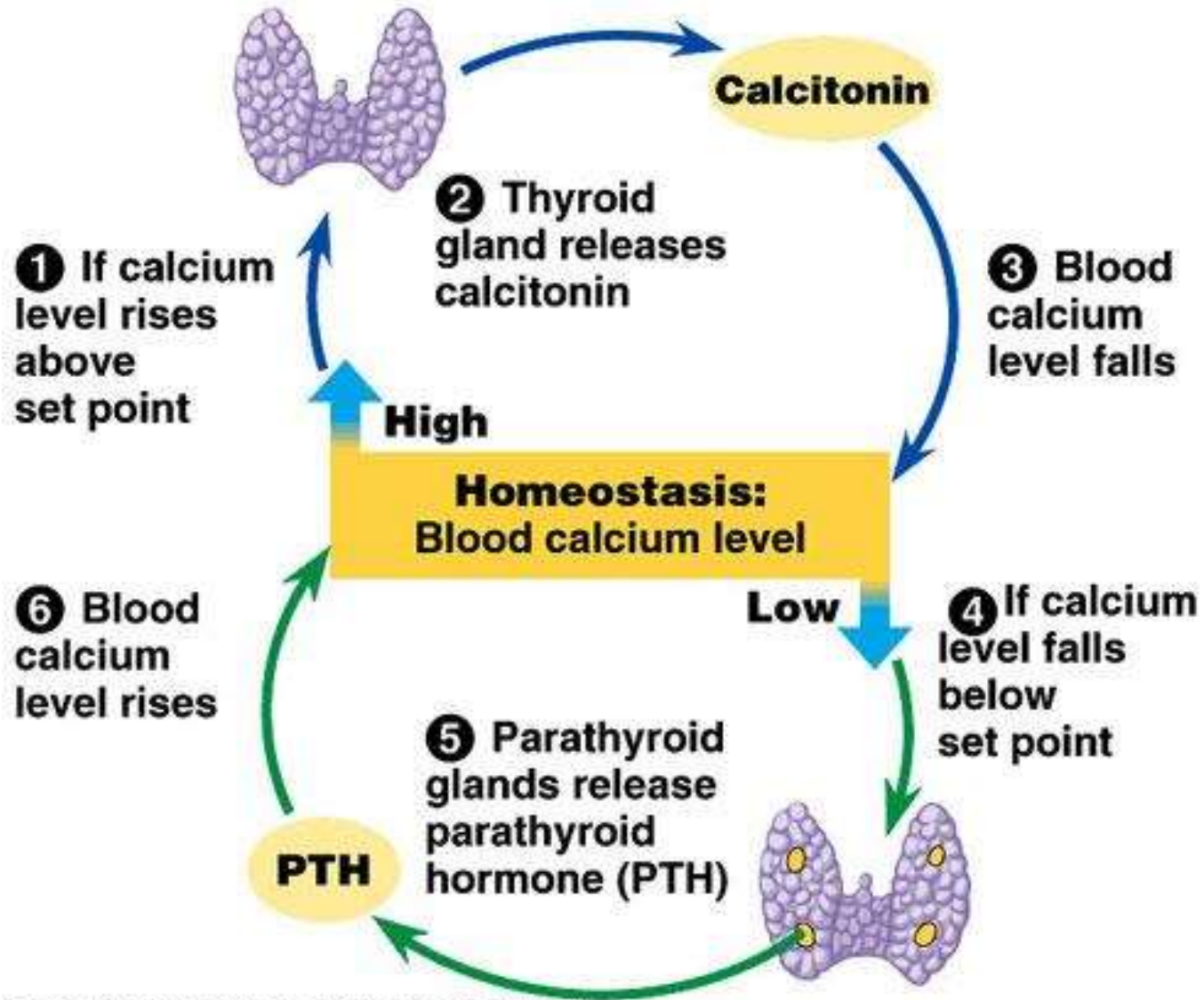


Parathyroid hormone (PTH, parathormone, parathyrin)

- 84 aminoacids
- stimulates resorption by osteoclasts
- enhances resorption of calcium and magnesium in distal tubules and thick ascending limb
- enhances absorption in the intestine (via vD3)



PTH vs. calcitonin

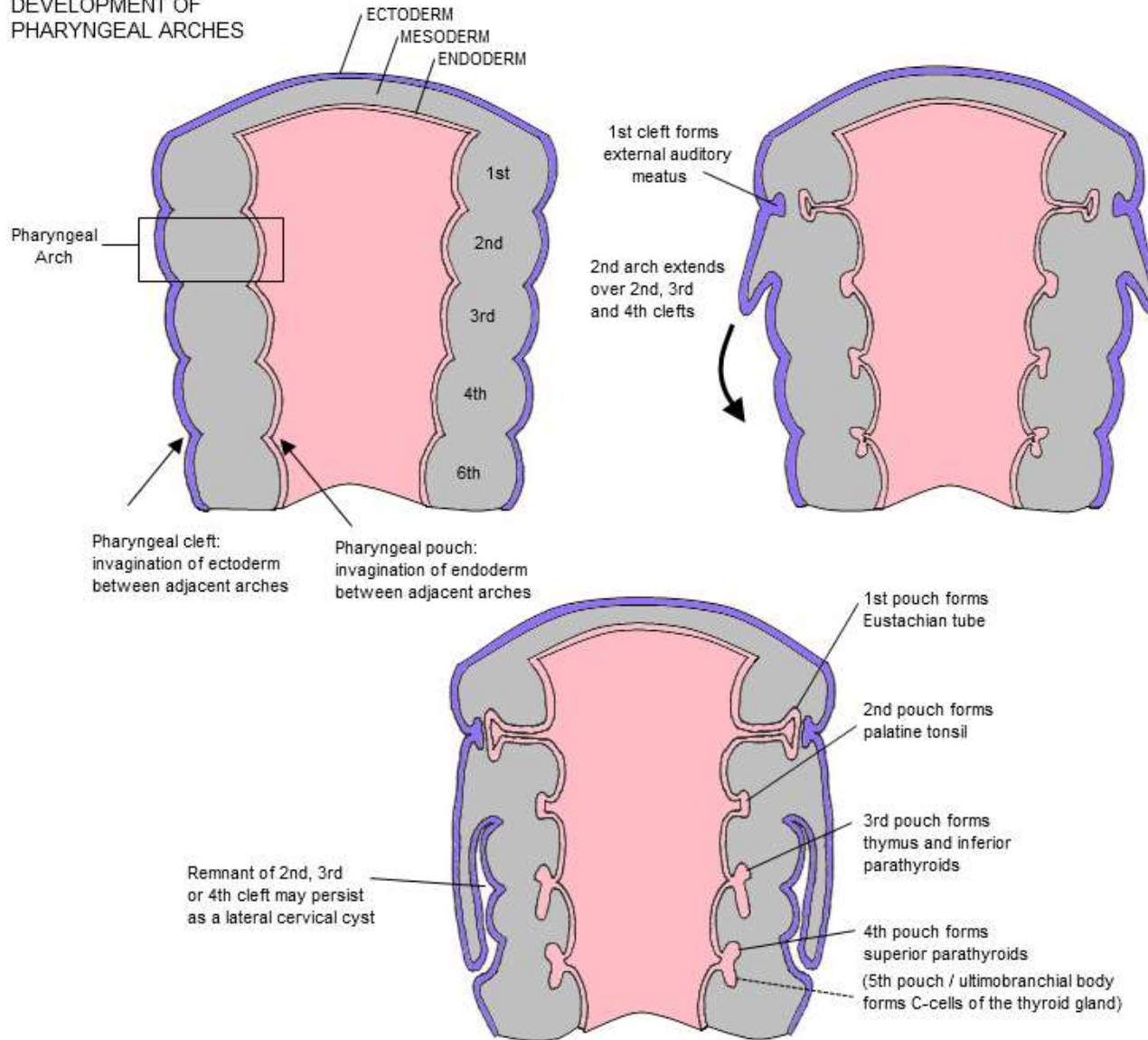


Embryonic development of parathyroid gland

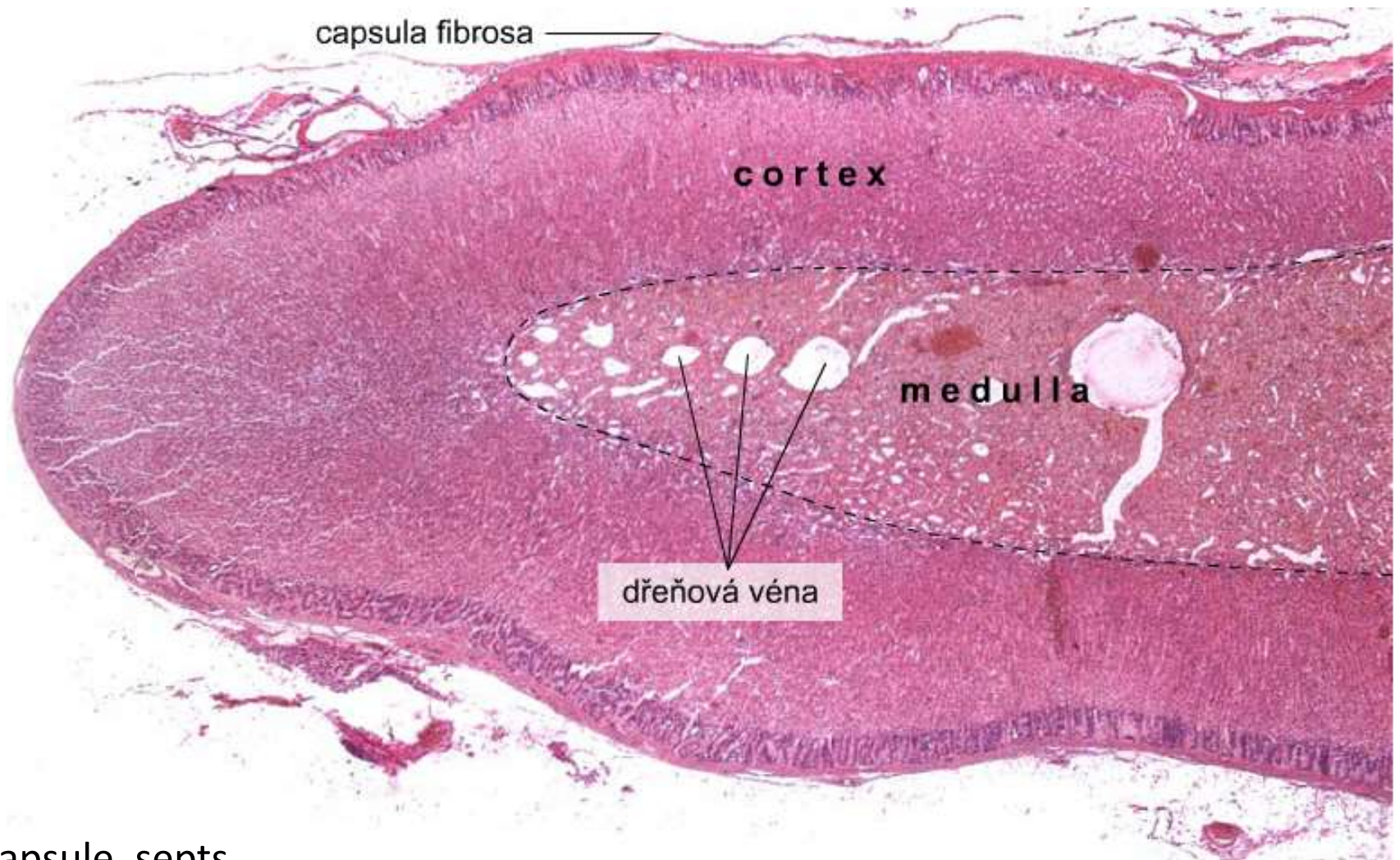
- glandulae parathyroideae superiores from endoderm of 4th pharyngeal pouch
- glandulae parathyroideae inferiores from dorsal process of 3th pharyngeal pouch
- together with thymus descend to lower poles of thyroid
- ectopic PTH gland in thymus or mediastinum

Embryonic development of parathyroid gland

DEVELOPMENT OF PHARYNGEAL ARCHES



Adrenal gland (*corpus suprarenale*)



c.t. capsule, septs

capillary plexus

Adrenal development

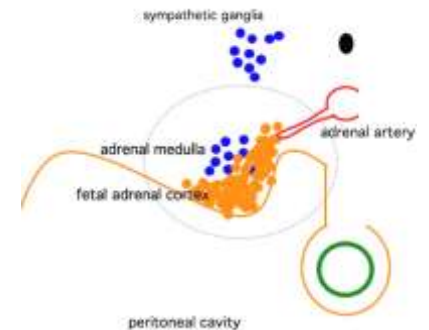
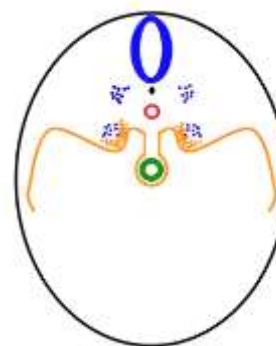
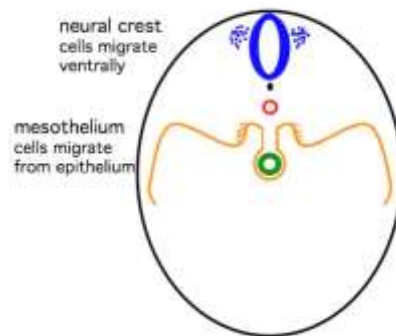
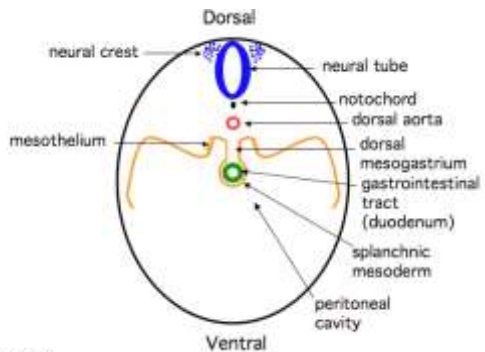
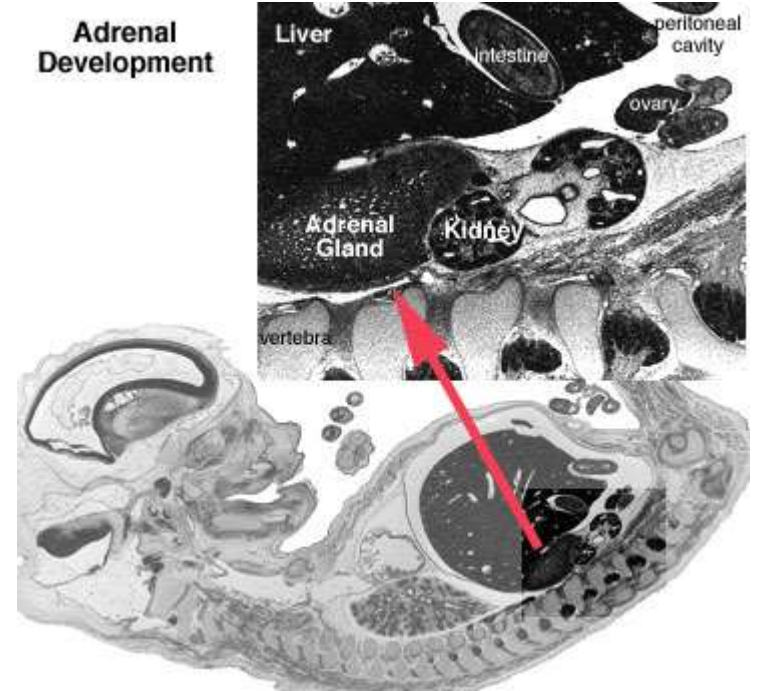
cortex

- mesoderm
- mesothelium, **coelomic epithelium**

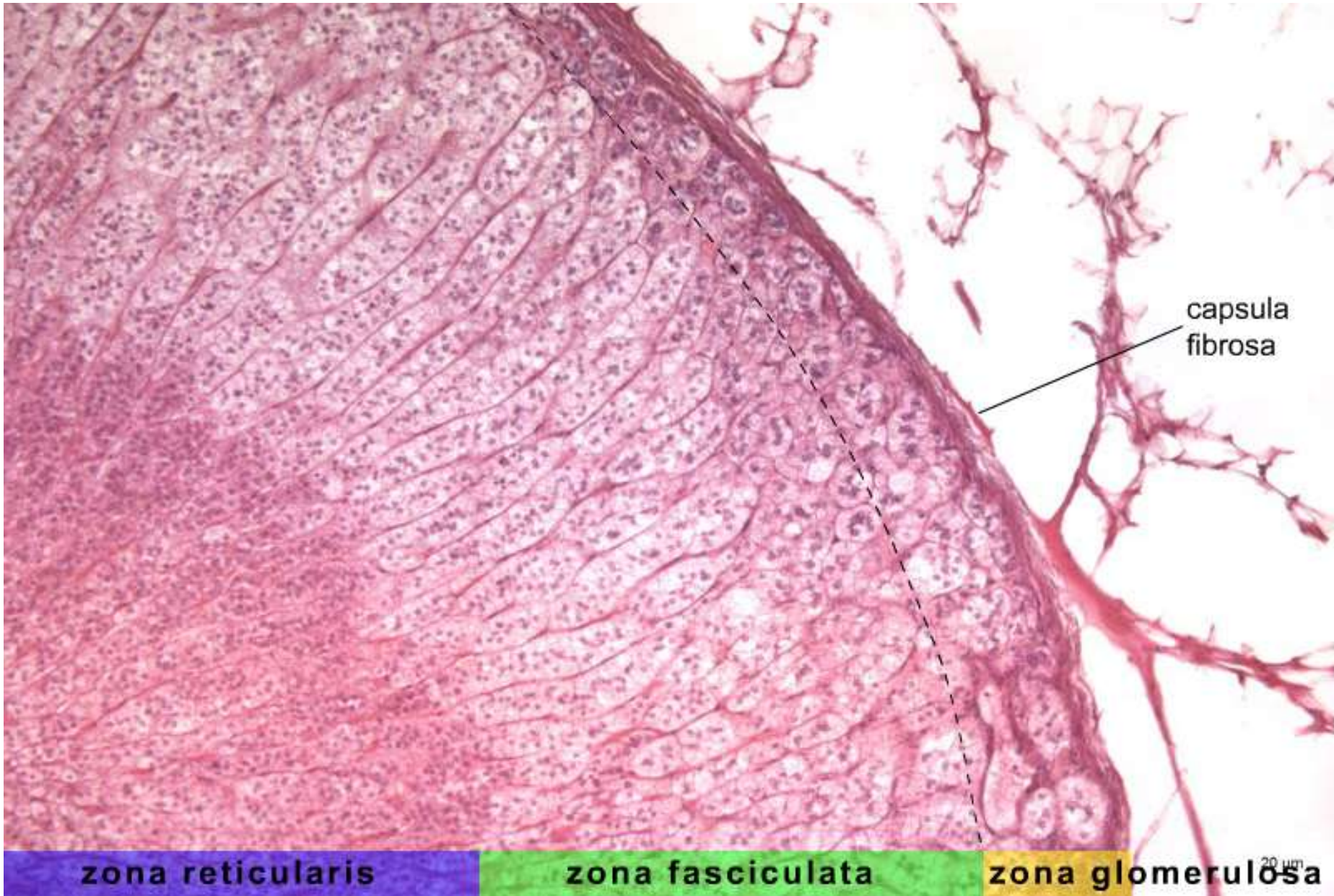
medulla

- **neural crest**

Adrenal Development

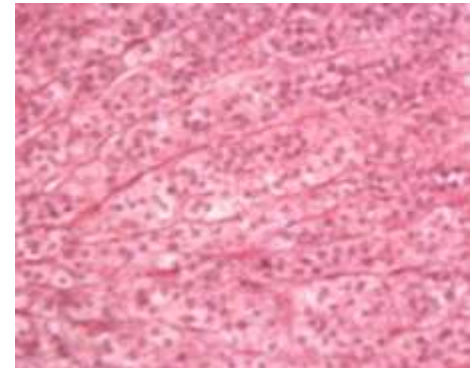
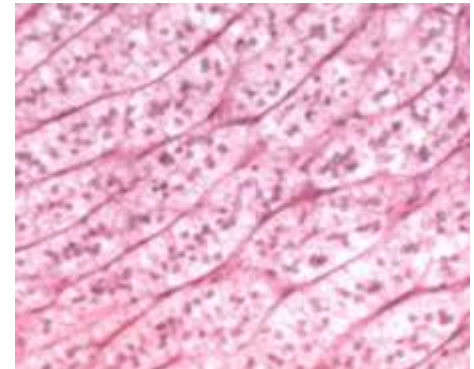
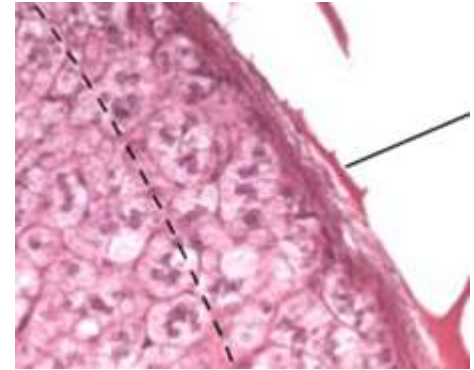


Adrenal cortex



Adrenal cortex

- **Zona glomerulosa (1/10)**
 - thin layer under capsule
 - relatively small cells in coiled glomeruli
 - not abundant lipid droplets
 - **mineralocorticoids**
- **Zona fasciculata (6/10)**
 - radially arranged trabeculae
 - lipid droplets in cytoplasm
 - **glucocorticoids**
- **Zona reticularis (3/10)**
 - branched trabeculae
 - small, acidophilic cells
 - lipofuscin
 - **androgen precursors**

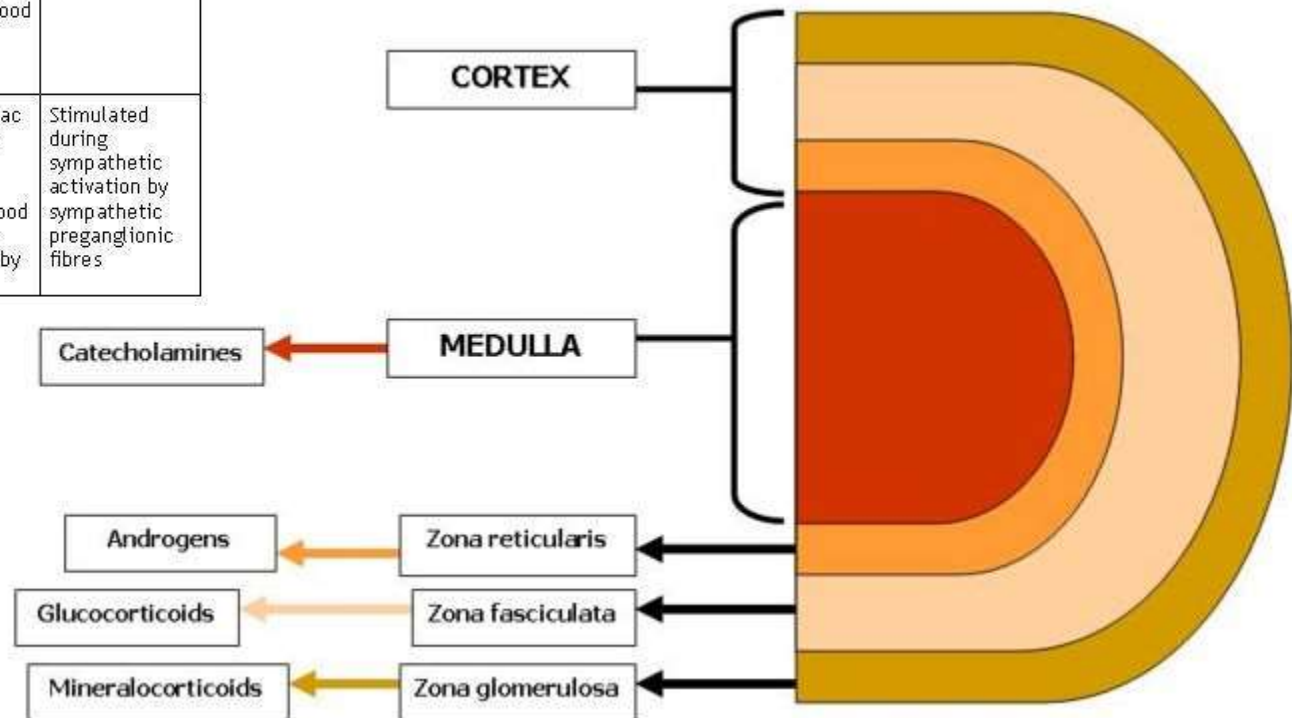


Adrenal cortex hormones

- Steroids produced in cortex = **CORTICOSTEROIDS**
- Steroidogenic cells
 - SER, lipid droplets, mitochondria
 - *mineralocorticoids*
 - *glucocorticoids*
- **Aldosteron** – *zona glomerulosa*
- **Cortisol** – *zona fasciculata*
- **Androgens**, estrogens, progesteron – *zona reticularis*

Adrenal cortex hormones

Region/ Zone	Hormone(s)	Primary Targets	Hormonal Effects	Regulatory Control
Cortex <i>Zona glomerulosa</i>	Mineralocorticoids (primarily aldosterone)	Kidneys	Increase renal reabsorption of Na ⁺ and water (especially in the presence of ADH and accelerate urinary loss of K ⁺)	Stimulated by angiotensin II, elevated plasma K ⁺ , or a fall in plasma Na ⁺ ; inhibited by ANP and BNP
<i>Zona fasciculata</i>	Glucocorticoids [cortisol (hydrocortisone), corticosterone]	Most cells	Release amino acids from skeletal muscles and lipids from adipose tissues; promote peripheral utilization of lipids; anti-inflammatory effects	Stimulated by ACTH from anterior lobe of pituitary gland
<i>Zona reticularis</i>	Androgens	Most cells	Not important in adult men; encourages bone growth, muscle growth, and blood formation in children and women	Stimulated by ACTH
Medulla	Epinephrine, norepinephrine	Most cells	Increases cardiac activity, blood pressure, glycogen breakdown, blood glucose levels; releases lipids by adipose tissue	Stimulated during sympathetic activation by sympathetic preganglionic fibres



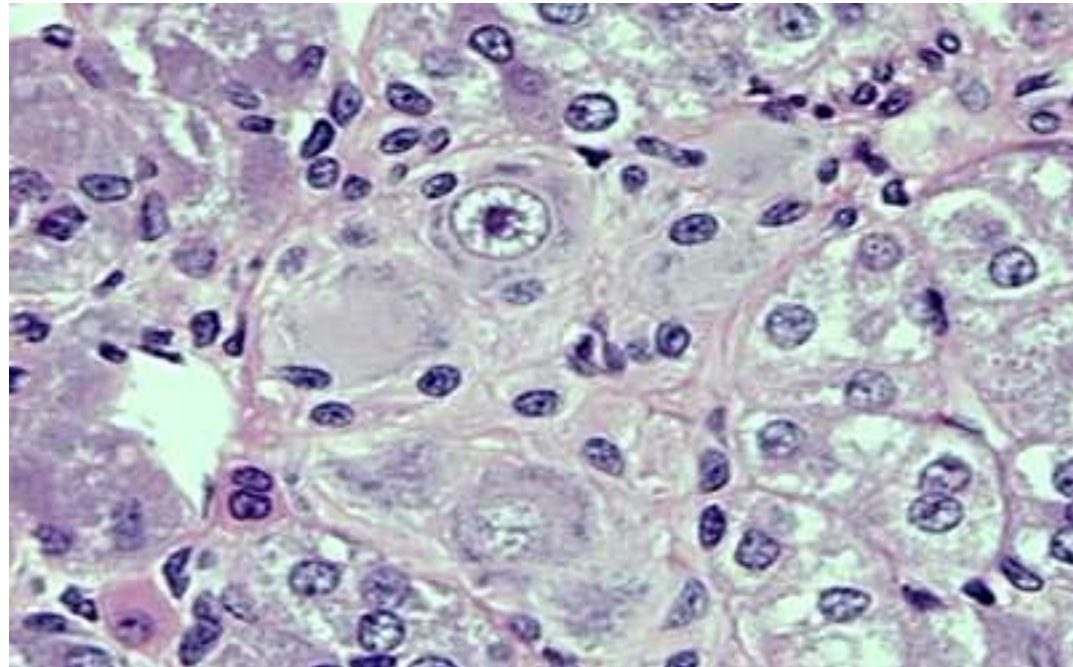
Adrenal medulla

Clusters of glandular cells in reticular c.t.

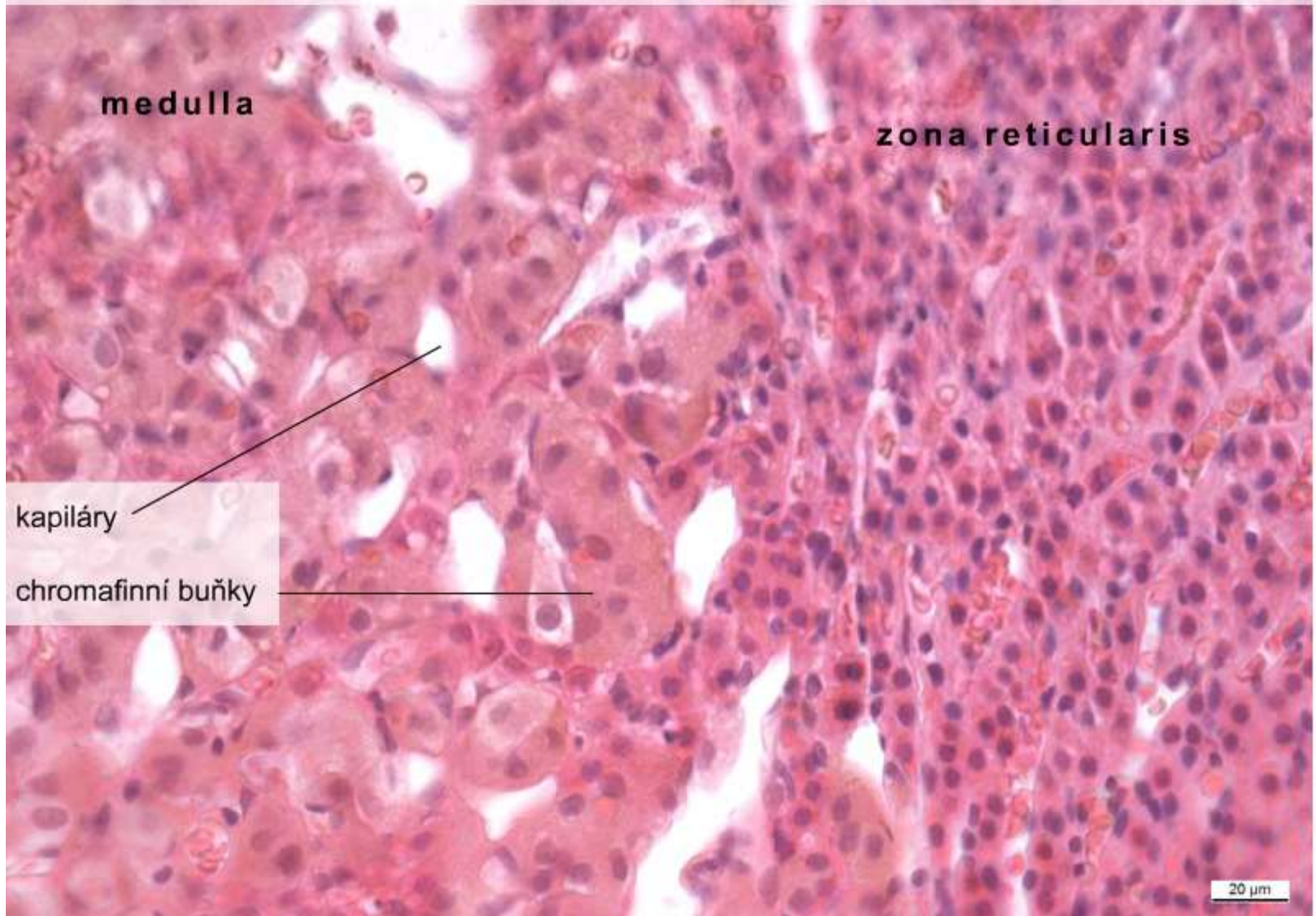
- chromaffin cells – modified postganglionic neurons
- ganglionic cells
- capillaries, venules, nerve fibers

- **adrenaline and noradrenaline**

Neural crest origin



Corpus suprarenale – medulla, (HE), objektiv 40×



medulla

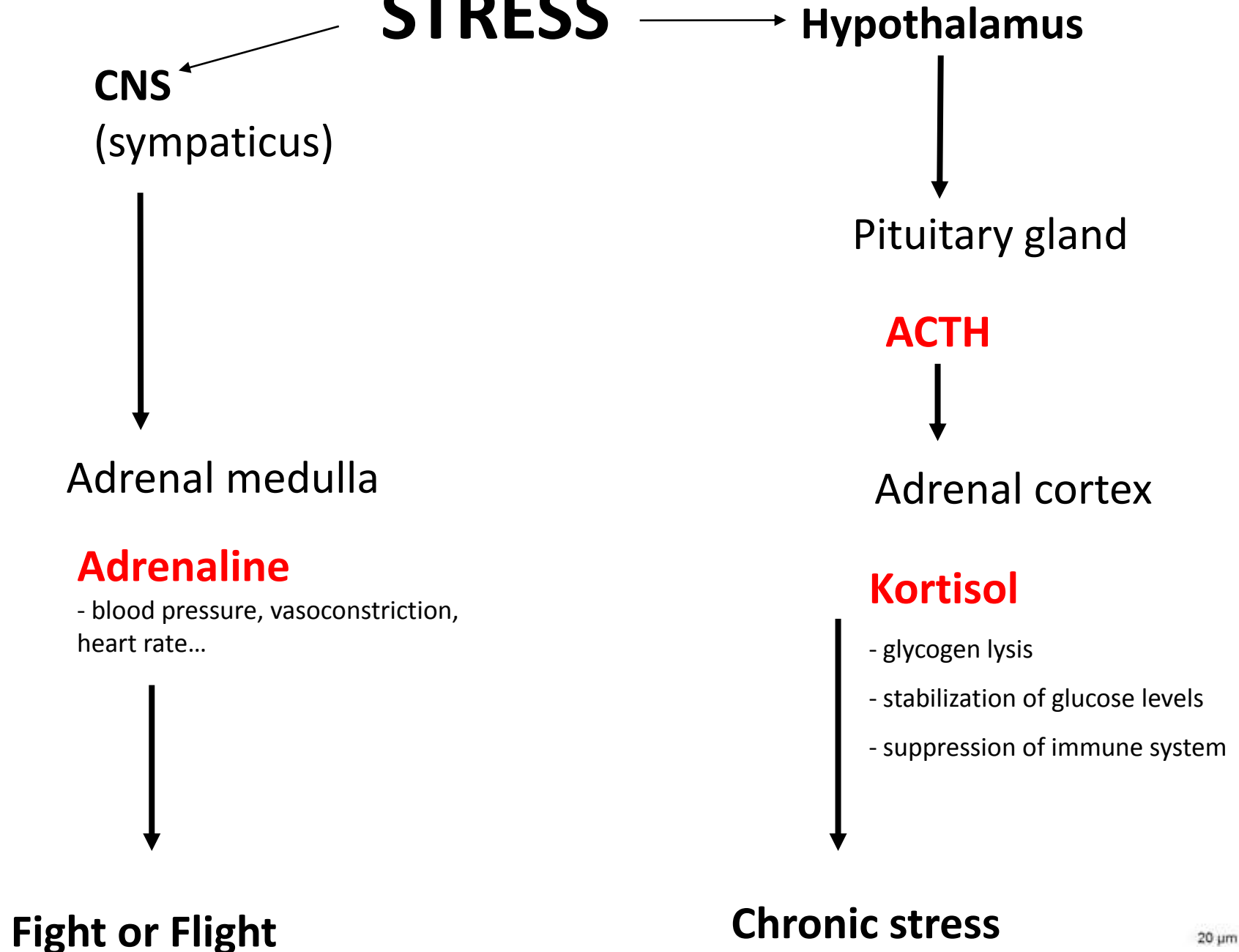
zona reticularis

kapiláry

chromafinní buňky

20 μm

STRESS



Thank you for attention

Questions and comments:
pvanhara@med.muni.cz