

Class I cavity

Location:

Fissures and pits (palatal surfaces of upper incisors – mainly the lateral incisors, buccal surface of lower molars and palatal surfaces of upper molars).

Materials:

Amalgam

Composite

Inlay

Glass ionomer cement in combination with composite

Indication for material selection

Amalgam: medium to large cavities.

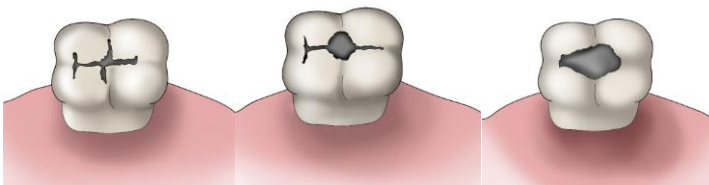
Composite: small to medium cavities, good oral hygiene and the possibility of securing a completely dry working field required.

Inlay: very large cavities, good oral hygiene required.

Glass ionomer cement in combination with composite: preventive filling, preparation and filling procedure will be taught in the clinical subjects.

Fig. 1: Extent of cavity on the occlusal surface

Small, medium and large caries in the fissure



PREPARATION

Amalgam:

Gaining access:

From the occlusal surface (caries in fissures), from oral surface (pits on upper incisors and upper molars). From vestibular surface (pits on the lower molars).

Tools for tooth preparation:

Tools for cavity outline:

Fissure bur, diamond pear-shaped bur or cylinder bur. The bur has a standard grit (blue code).

For finishing of the preparation:

A drill or pear-shaped bur for preparation of undercuts, a fine diamond bur (red code) for smoothing the edges of enamel.

The principle of preventive extension:

The shape of the cavity should correspond to the shape of the fissure. Crista obliqua and crista transversalis remain preserved as long as they are not undermined by dental carries.

The principle of retention:

A box-shaped cavity whose walls diverge in the pulpal direction – an undercut cavity.

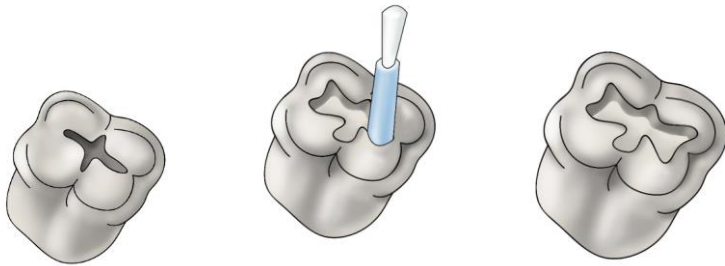
The principle of resistance:

An amalgam filling is minimally 2 mm high, the enamel is supported with dentin everywhere, all transitions are rounded with no sharp edges. Proximal marginal ridges must not be undermined (during preparation of undercuts we have to proceed with extreme caution, preferably we do not prepare them in the mesial and distal part of the cavity).

Fig. 2.

Guidance of the preparatory instrument and creation of cavity outline. The second lower molar is involved.

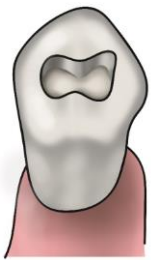We begin with preparation in the middle of the fissure and we guide the drill mesially and distally, orally and vestibularly in the fissure.



The shape of the individual cavities:

Fig. 3:

A cavity on the upper premolar



Crista transversalis is preserved in the first lower premolar. We thus prepare two isolated cavities.



Fig. 4:

The shape of cavities on upper molars. We usually prepare two isolated cavities in the first upper molar, in this way we preserve the crista obliqua.

Okomentoval(a): [Z1]: Nevím, co zde znamená v obrázku níže zkratka "mde", proto nechávám, v dalším textovém poli zůstávají dva červené otazníky z původního textu

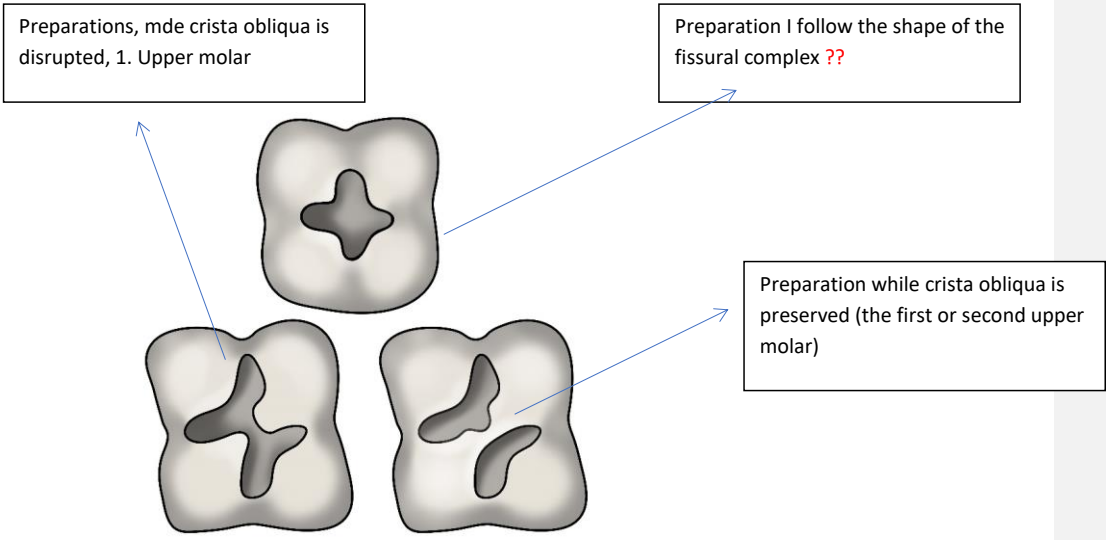


Fig. 5: The shape of cavities on lower molars

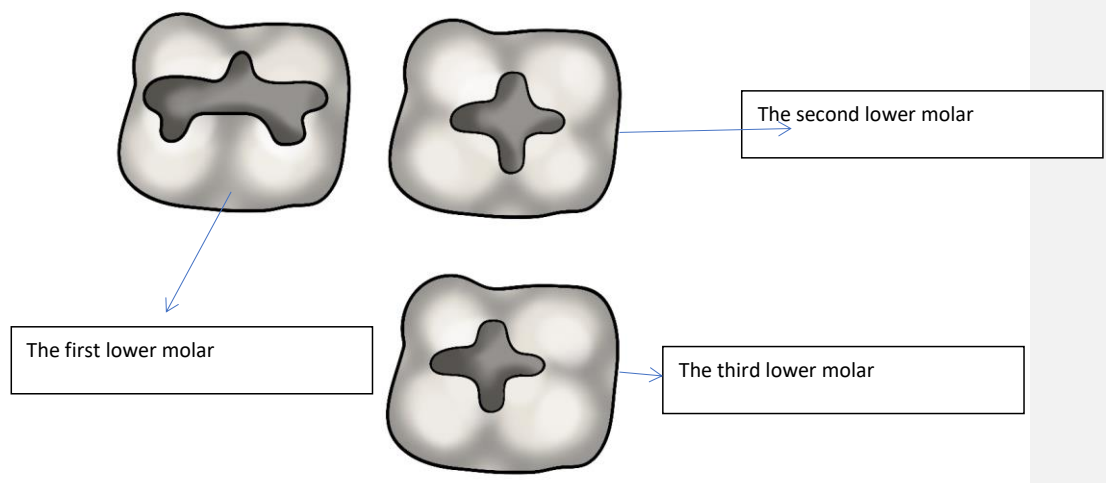


Fig. 6:

A cavity in the pit on the upper incisor – we prepare it in the extent of the carious lesion (palatal surface)

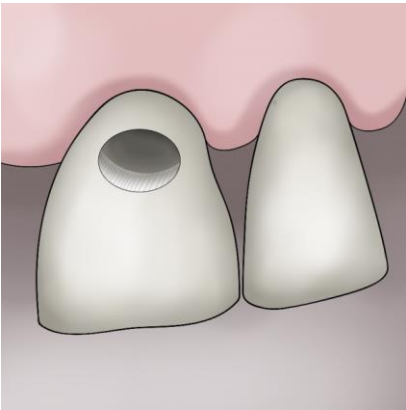


Fig. 7:

Caries in the pit on the first lower molar.

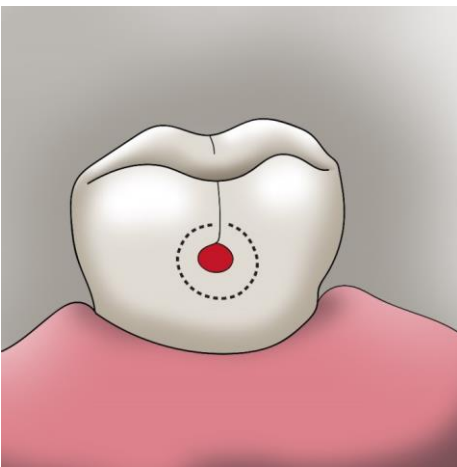
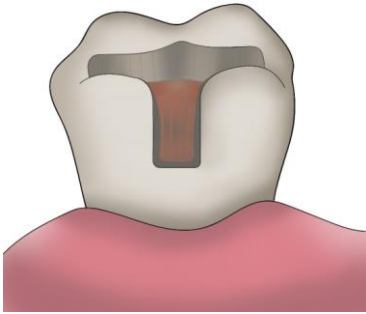


Fig. 8: If caries spreads in the direction towards the occlusal surface and undermines the enamel there, we prepare a composite cavity – we extend the preparation to the occlusal surface.



MAKING OF THE FILLING

Filling of the cavity:

A pad from zinc phosphate cement protects the pulp against thermic irritation and it also levels unevenness on the pulpal side.

We fill the cavity in parts and condense amalgam thoroughly.

We form the filling with carving tools and smoothen it (ball or rounded tools – tools for smoothening), in the next appointment we perform polishing (finishing, polishing, and rubber tools).

When smoothening the filling and during its following polishing, we proceed from the middle of the filling to its edges.

Composite:

Gaining access:

From the occlusal surface (caries in fissures), from oral surface (pits on upper incisors and upper molars). From vestibular surface (pits on lower molars).

Tools for tooth preparation:

Fissure of diamond bur (cylinder bur) with standard grit (blue).

Tools for cavity outline:

A fissure of diamond bur (cylinder bur) with standard grit (blue).

For finishing of the preparation: Diamond cylinder bur with fine grit (red code).

We do not bevel the enamel.

The principle of preventive extension:

Cavity is limited to the carious lesion. We open the fissures leading to the carious lesion and include them into preparation. We seal the carries of small extent.

The principle of retention:

We adjust the enamel and dentin by acid etching, we use primer and bond.

We do not prepare undercuts – they have no use and worsen the tension during polymeration (this may cause untightness in the filling attachment and cracks in the tooth tissue).

The principle of resistance:

The thickness of filling is minimally 2 mm, enamel is supported by dentin everywhere, all transitions are rounded with no sharp edges.

Inlay from metal alloy (we use dental precious metal).

Tools for cavity outline:

A fissure of diamond bur (cylinder bur) with standard grit (blue). It is of advantage to use a cone-shaped preparatory instrument which ensures the divergence of cavity walls.

For finishing of the preparation:

A fine diamond bur (red) for smoothening the edges of enamel. We bevel the enamel in a 45° angle in the outer half.

The outline of class I cavity on molars:

The principle of preventive extension

The cavity takes the whole fissure complex.

The principle of retention:

The surface friction and cement adhesiveness. The cavity is box-shaped, its walls extend occlusally.

The angle of the divergence is 6° to 15°.

The principle of resistance

The metal inlay is approximately 1.5 mm thick. The enamel must always be supported by dentin, all transitions are rounded.

Composite or ceramic inlay

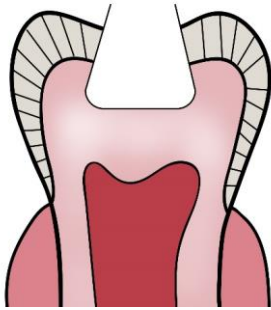
Unlike during the preparation for a metal inlay, we do not bevel the enamel.

Otherwise, the preparation is identical with the preparation for a metal inlay.

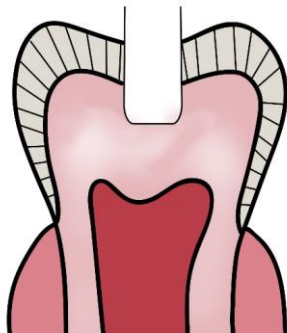We use composite cement and adhesive technology for cementing (similarly as when making the composite filling). This procedure will be taught in the clinical part of the studies.

Fig. 7: Basic differences in preparation:

a) amalgam



b) Composite



c) Inlay

