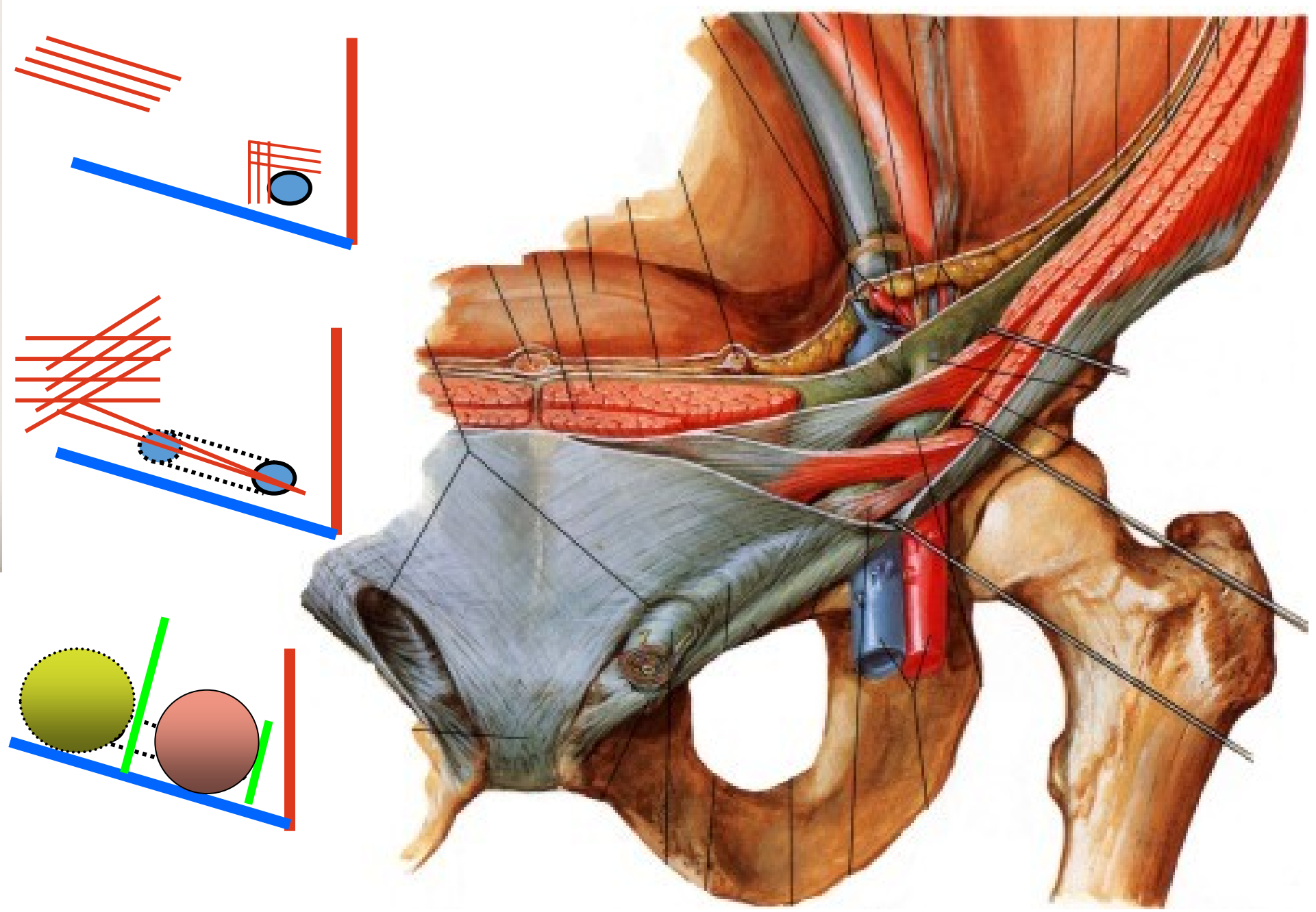
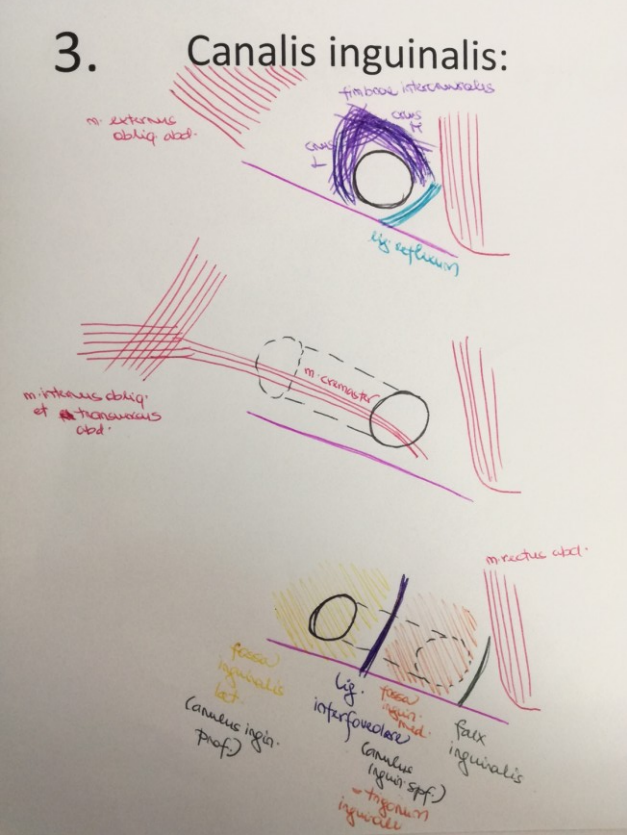
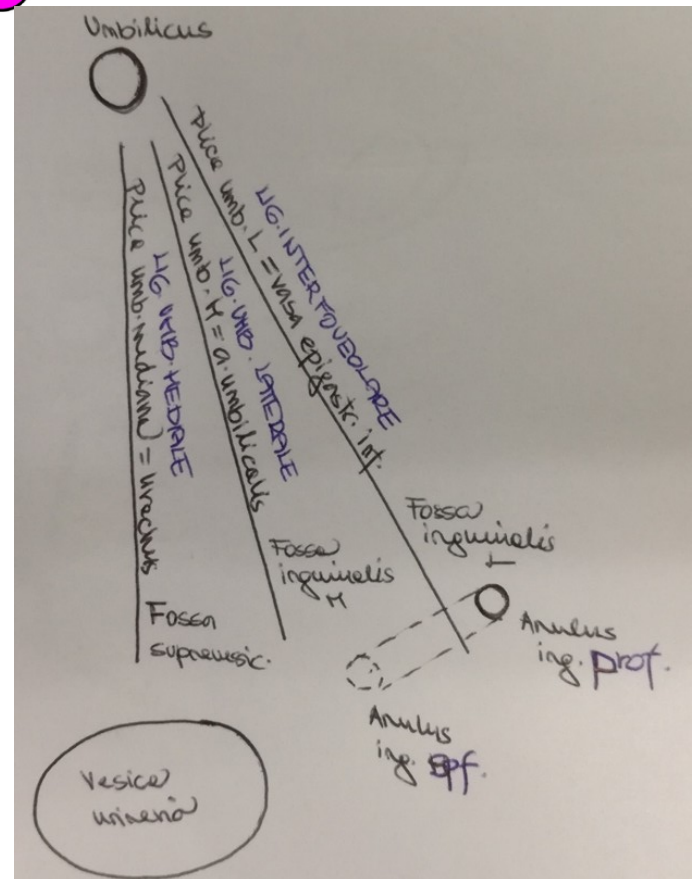
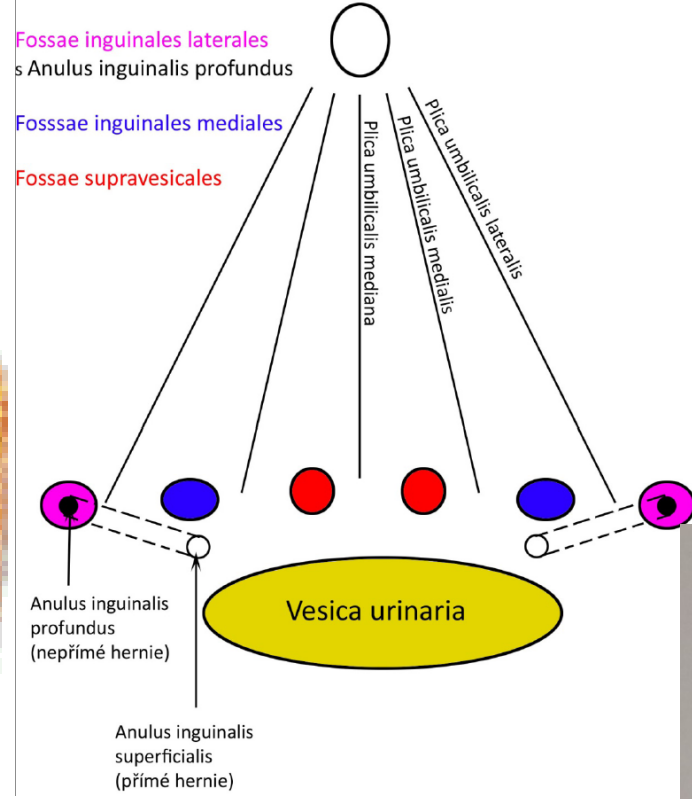
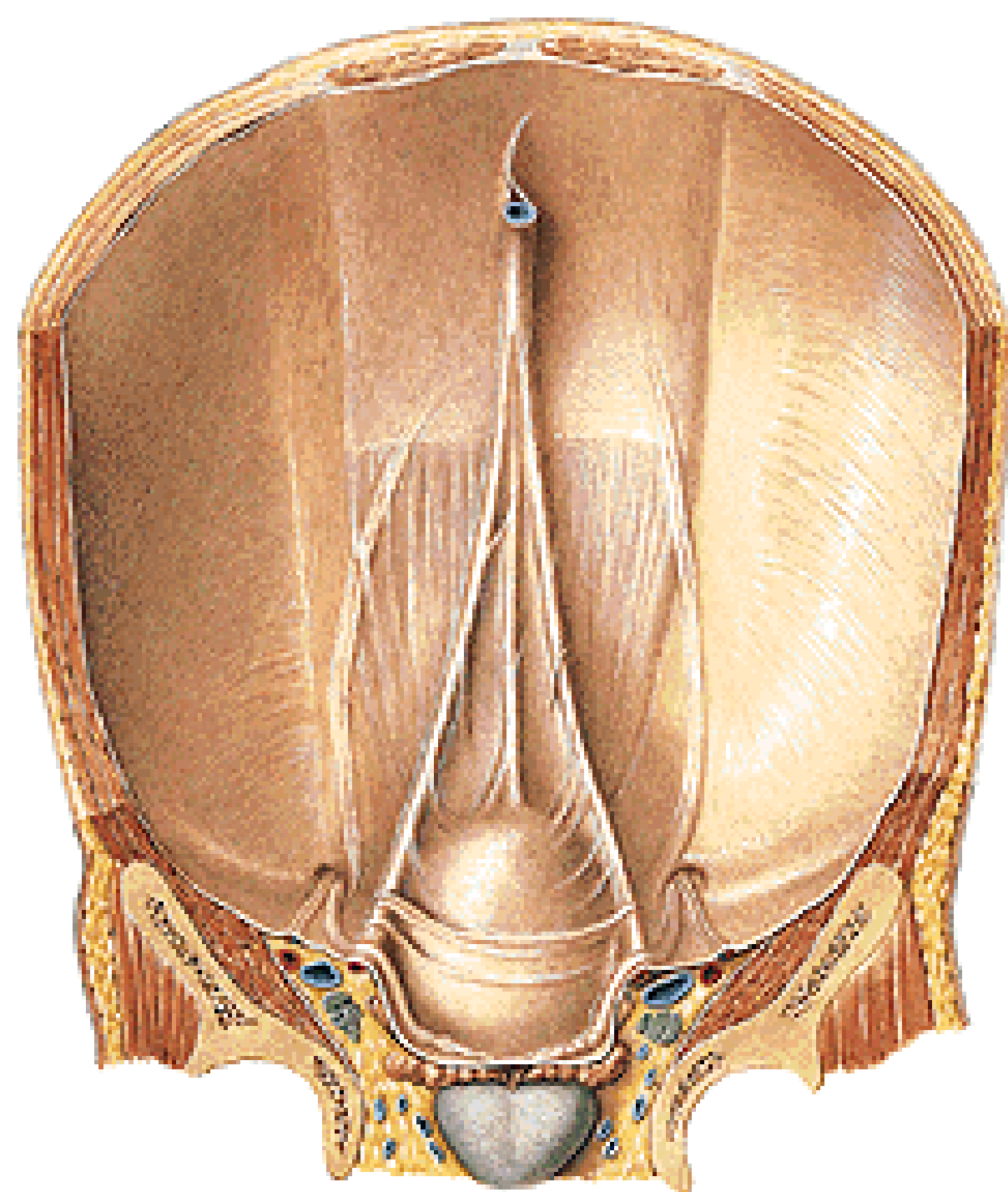


schémata

3. Canalis inguinalis:





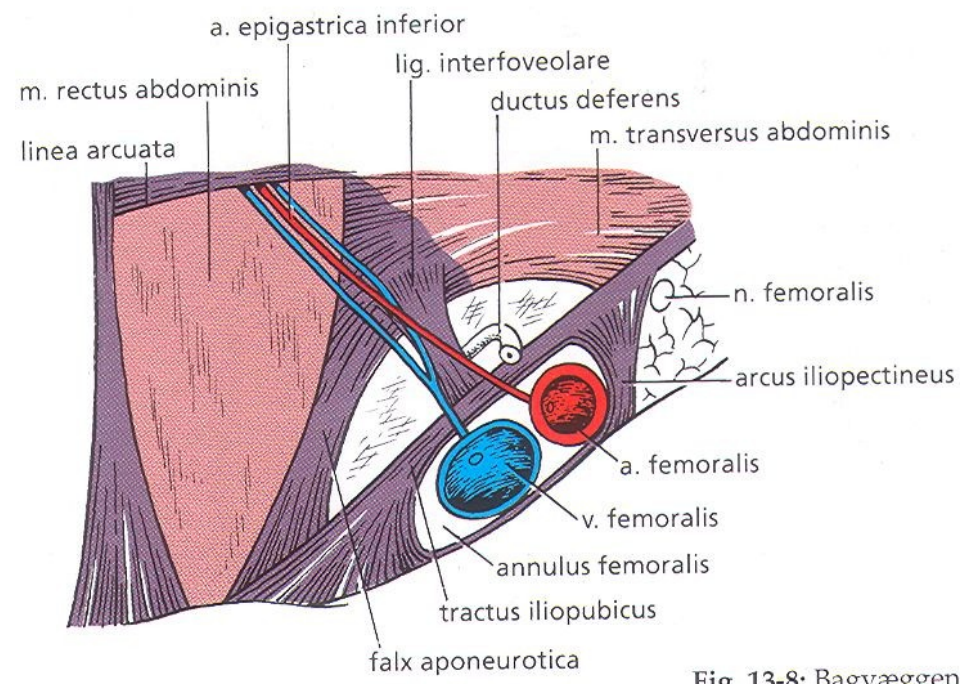
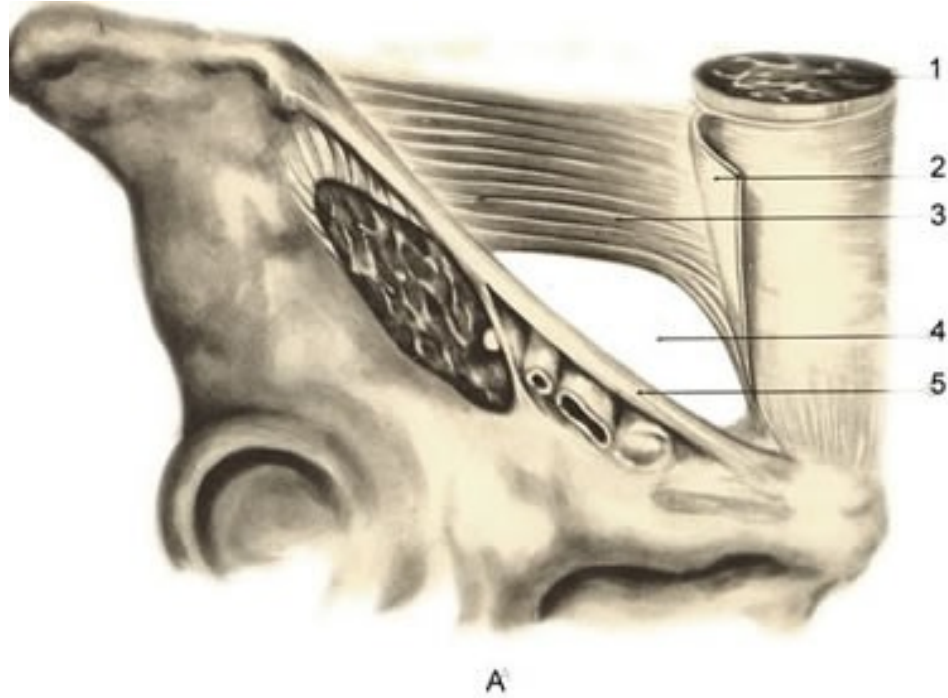


Fig. 13-8: Bagvæggen

