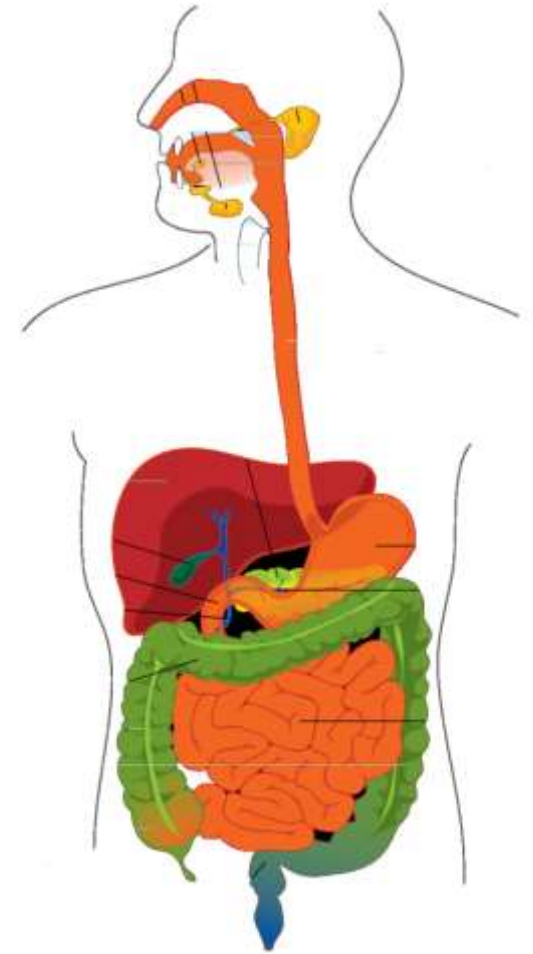


# GIT I

- Ústní dutina
- Vývoj obličeje
- Faryngový aparát



**Petr Vaňhara, PhD**

Ústav histologie a embryologie LF MU  
[pvanhara@med.muni.cz](mailto:pvanhara@med.muni.cz)

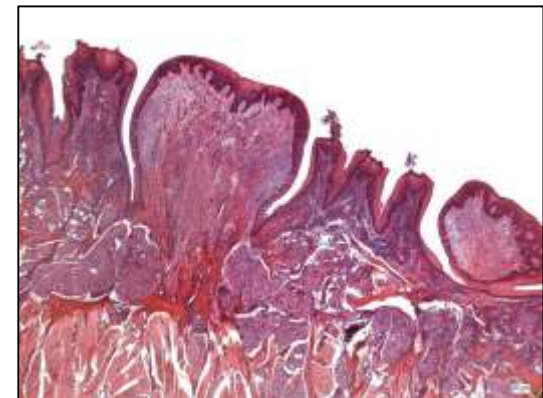
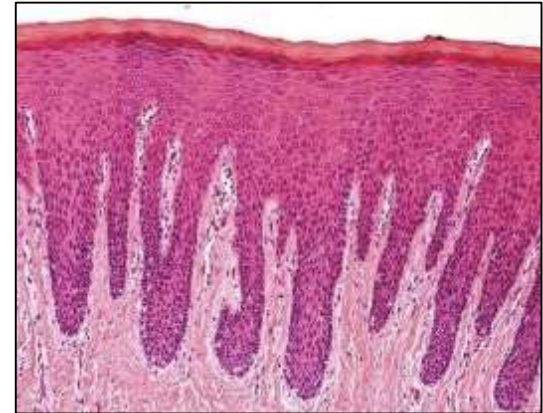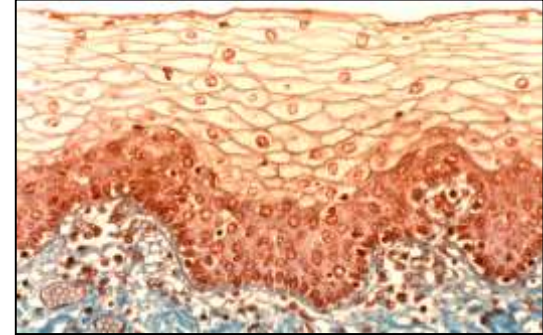
# ÚSTNÍ DUTINA

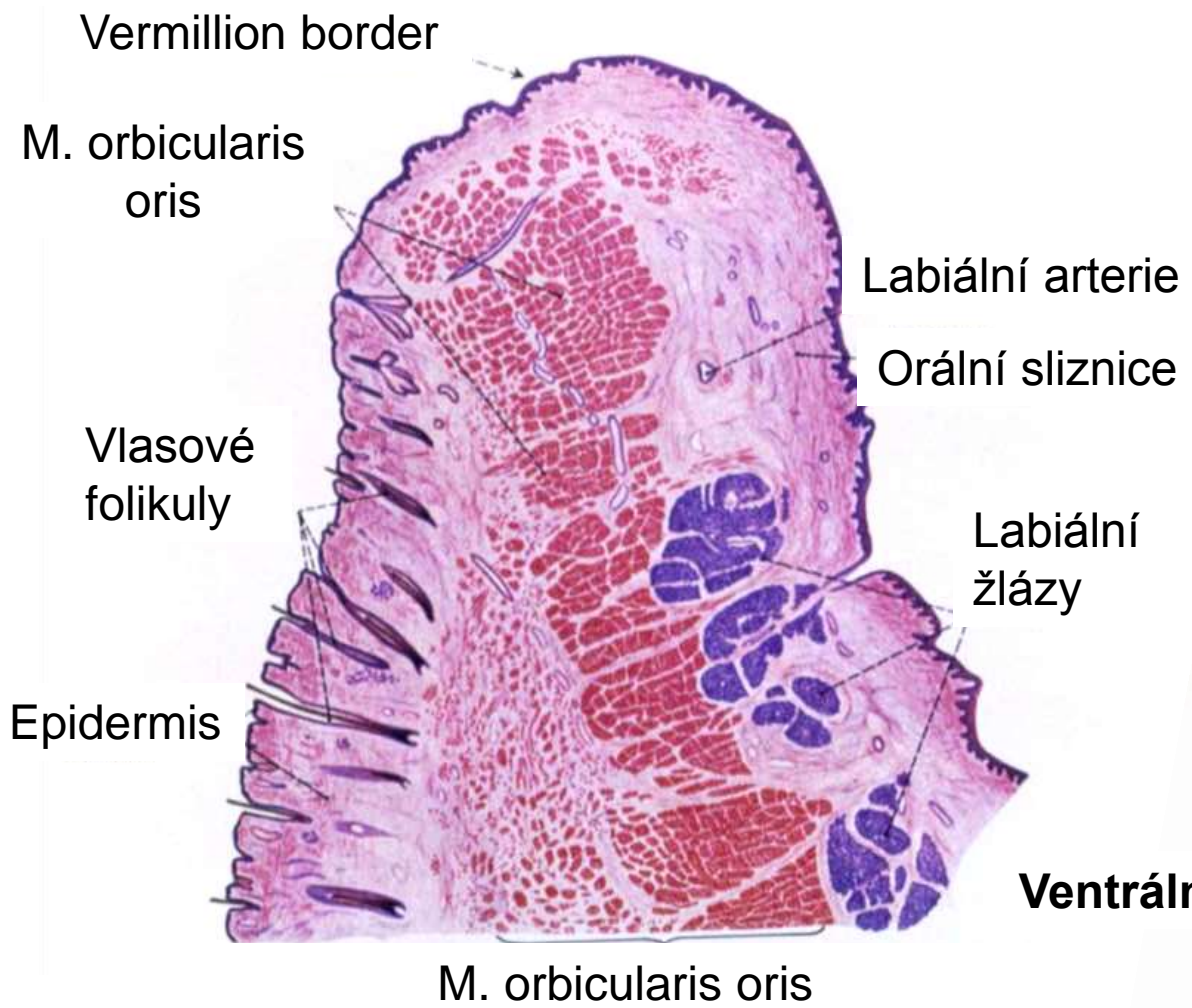
- Horní a dolní ret
- Vestibulum oris
- Tvrdé a měkké patro
- Zub
- Jazyk



## **vrstevnatý dlaždicový epitel** ***lamina propria mucosae***

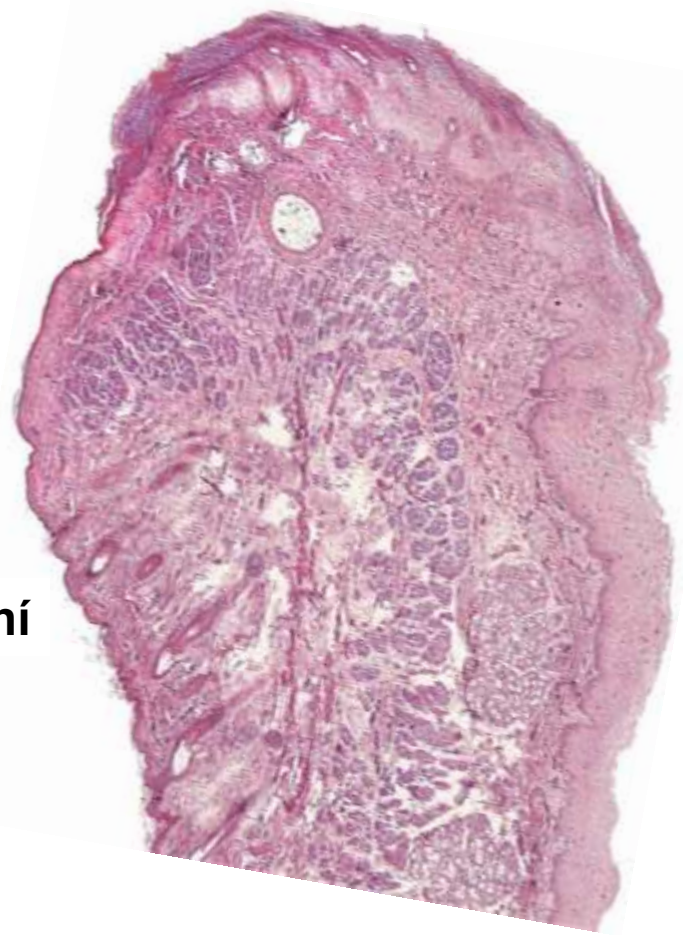
- **krycí** sliznice
  - slizniční a podslizniční vazivo
- **mastikační** sliznice
  - zrohovatělý epitel, lamina propria přechází v periost (mukoperiost)
- **specializovaná** sliznice
  - dorsum linguae





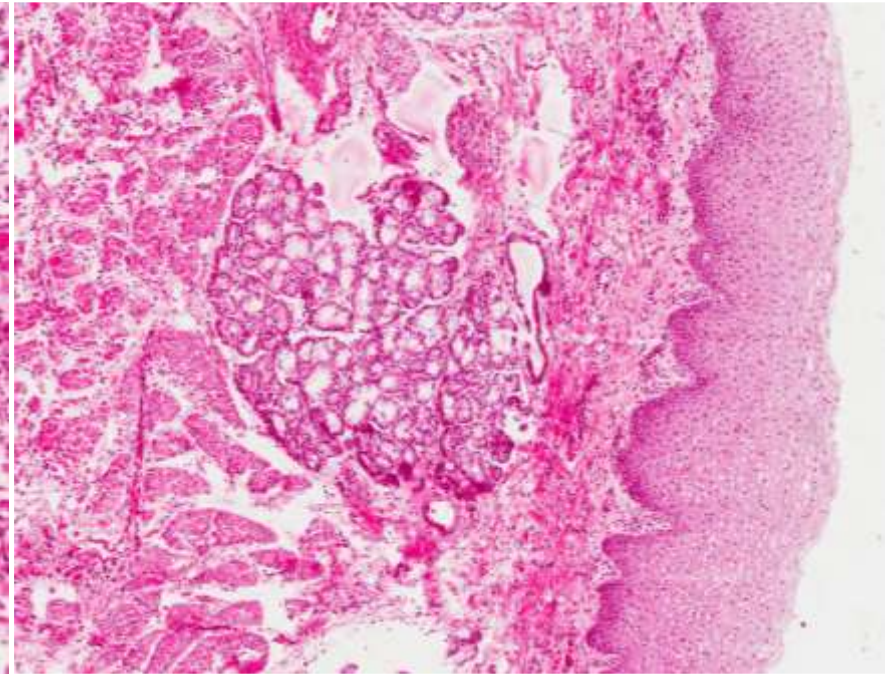
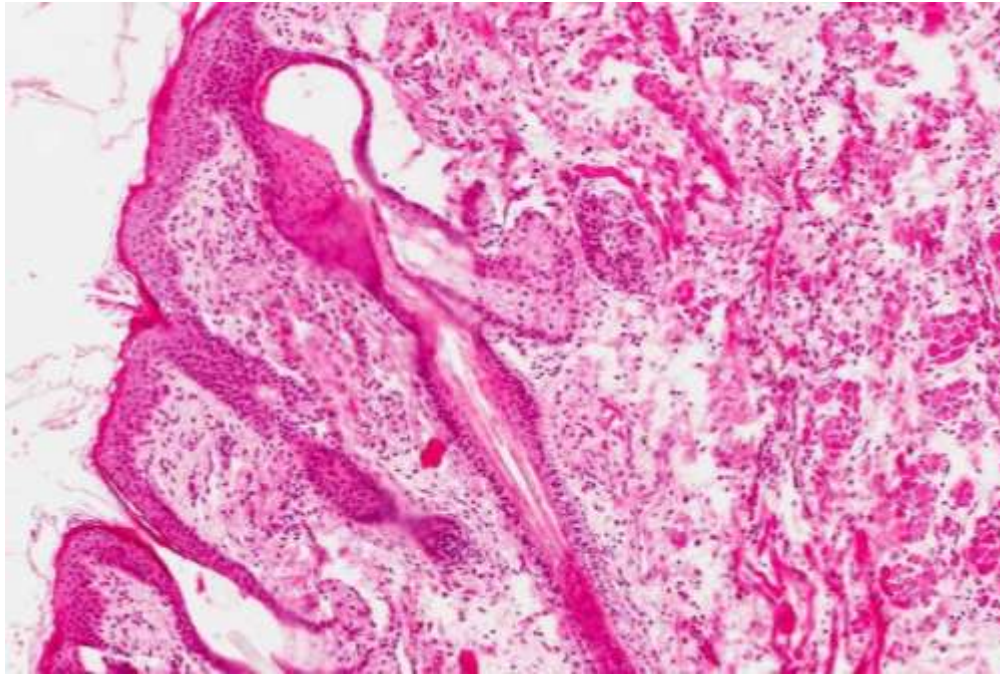
**Dorsální**

**Ventrální**



**Kožní aspekt (ventrálně)**

**Orální aspekt (dorzálně)**

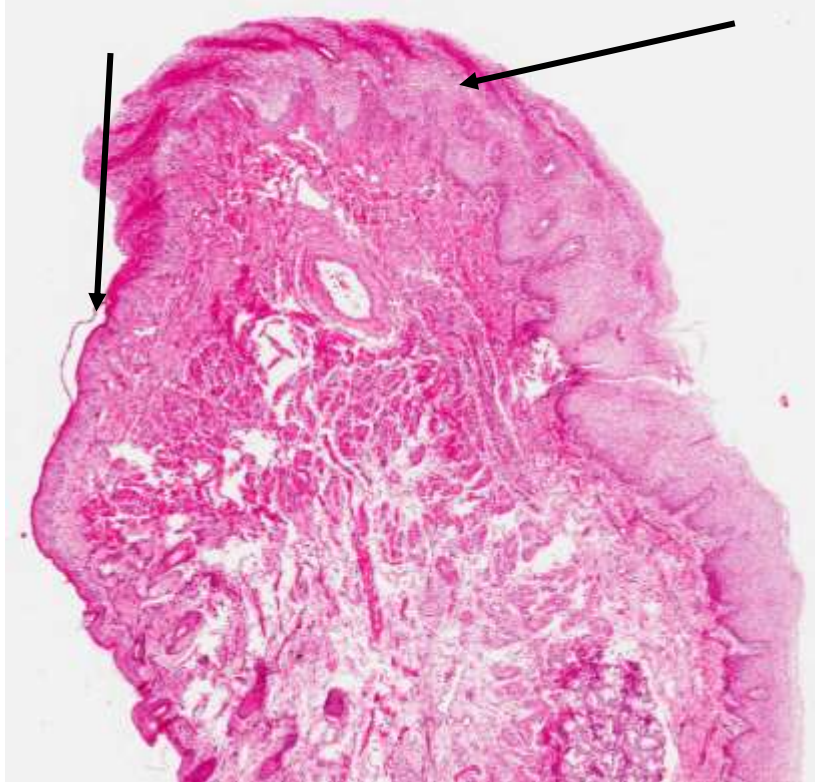

Epidermis  
Vlasové folikuly  
Mazové žlázy  
Potní žlázy

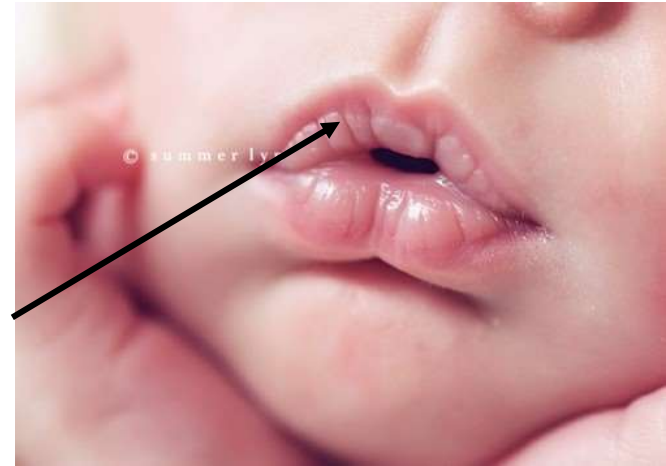Orální sliznice  
Malé slinné žlázy

pars glabra

pars villosa

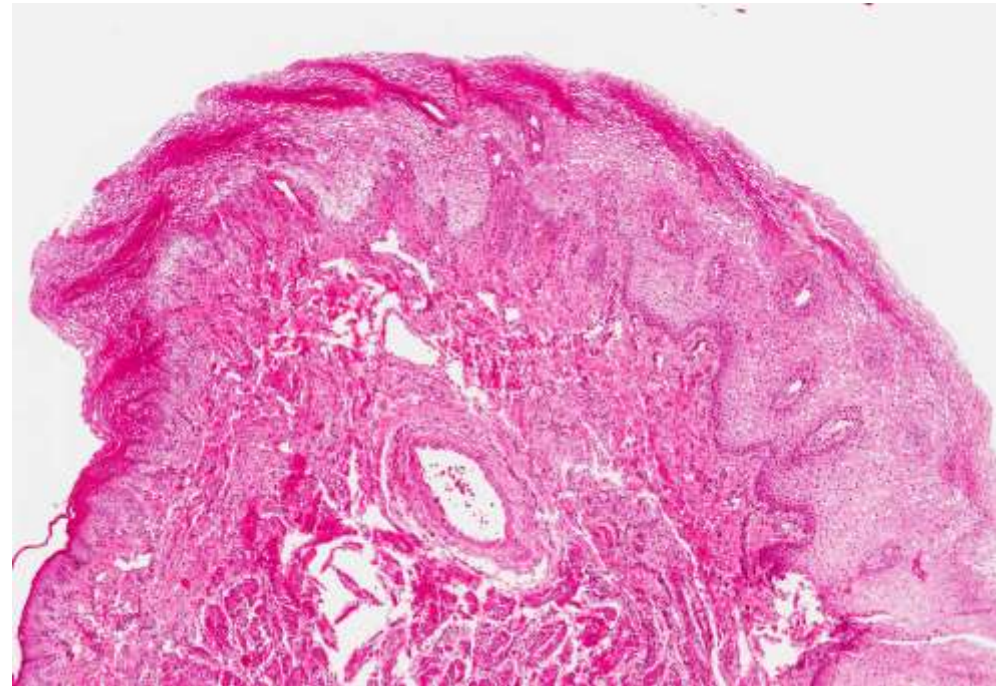


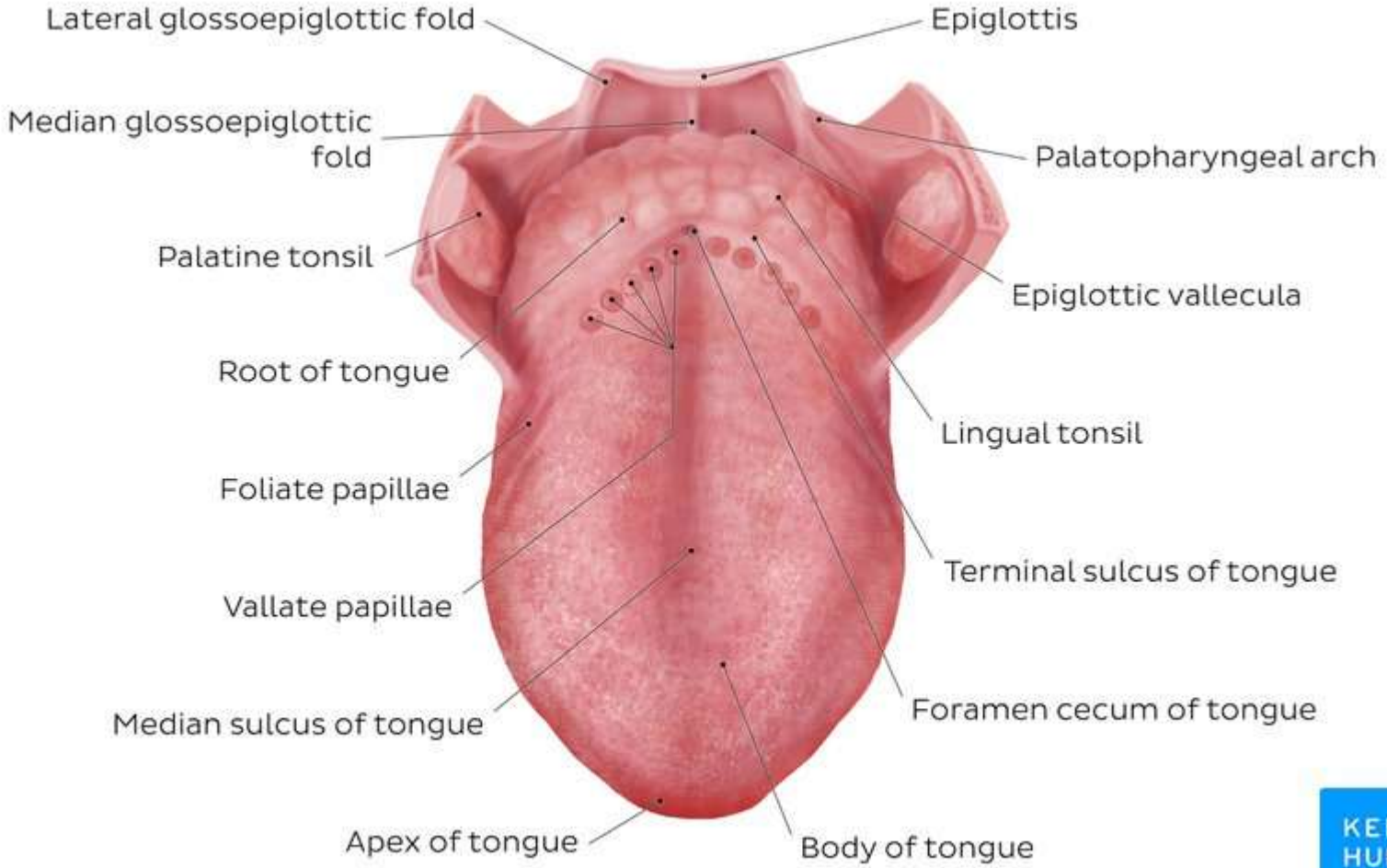
novorozenci  
torus labialis

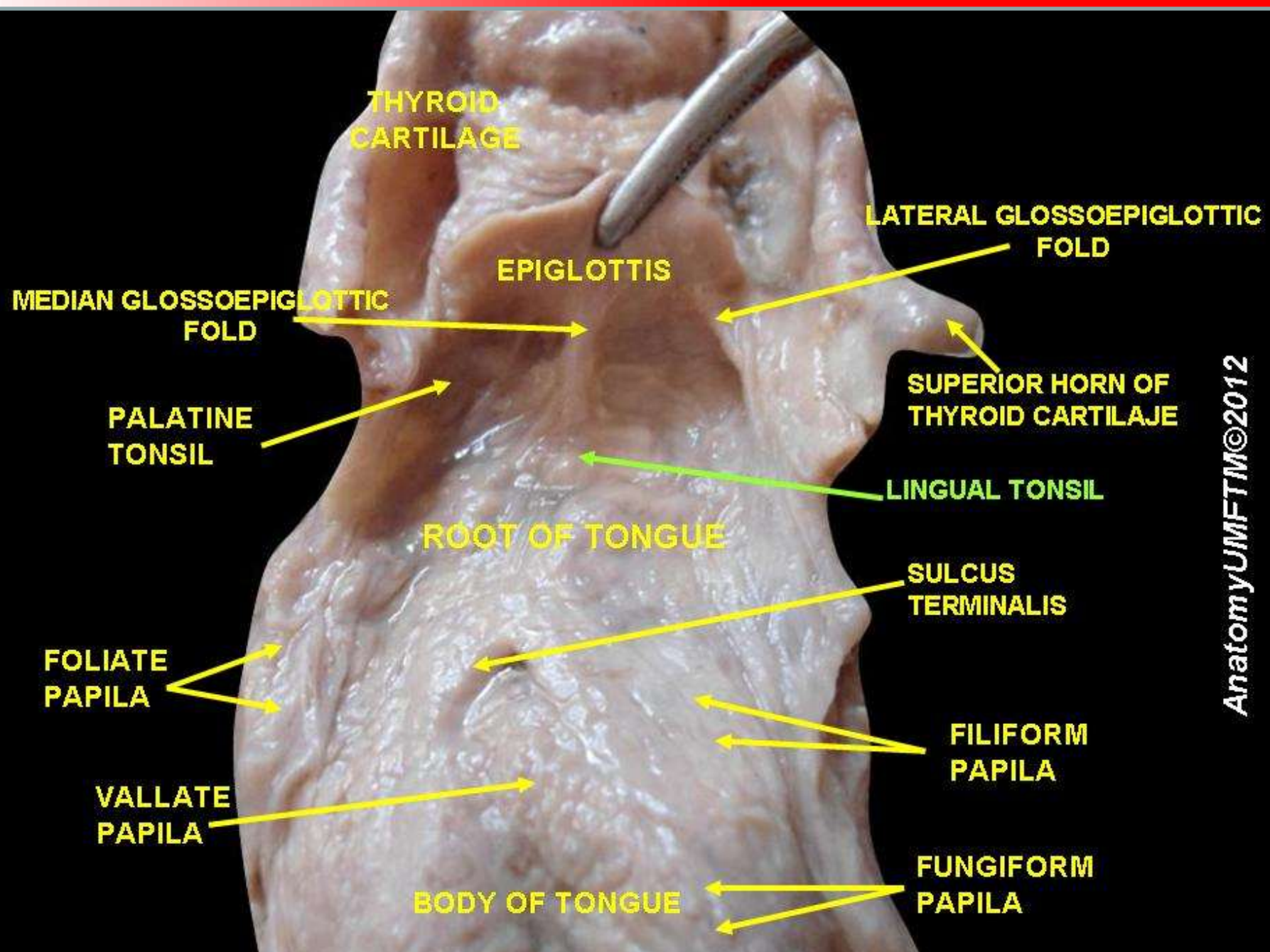


## Vermillion border

- Eleidin
- Absence slinných žláz, vlasových folikulů, potních žláz
- Vysoké vazivové papily, kapiláry
- Nervová zakončení, Meissnerova tělíska

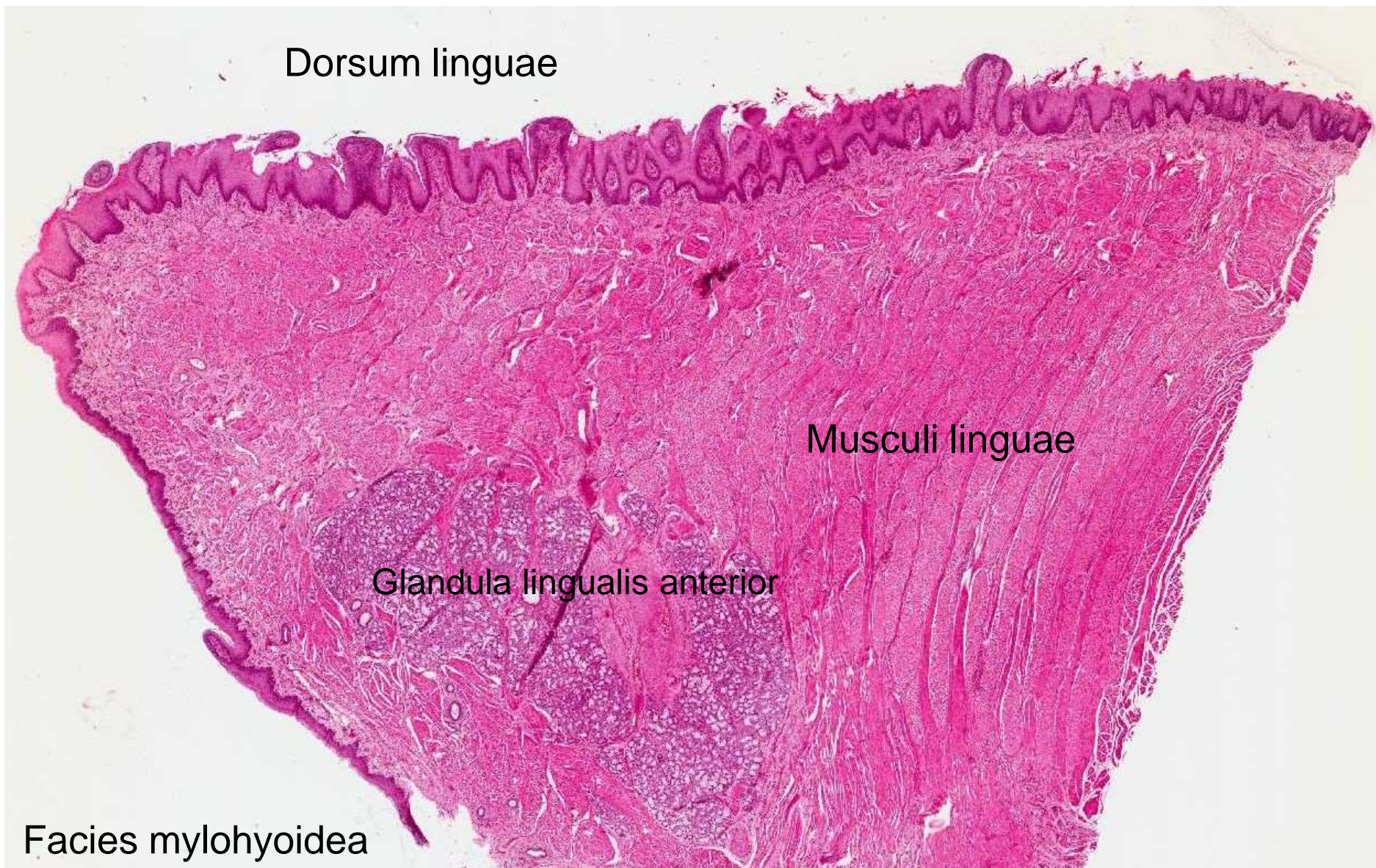








# JAZYK – APEX LINGUAE



Dorsum linguae

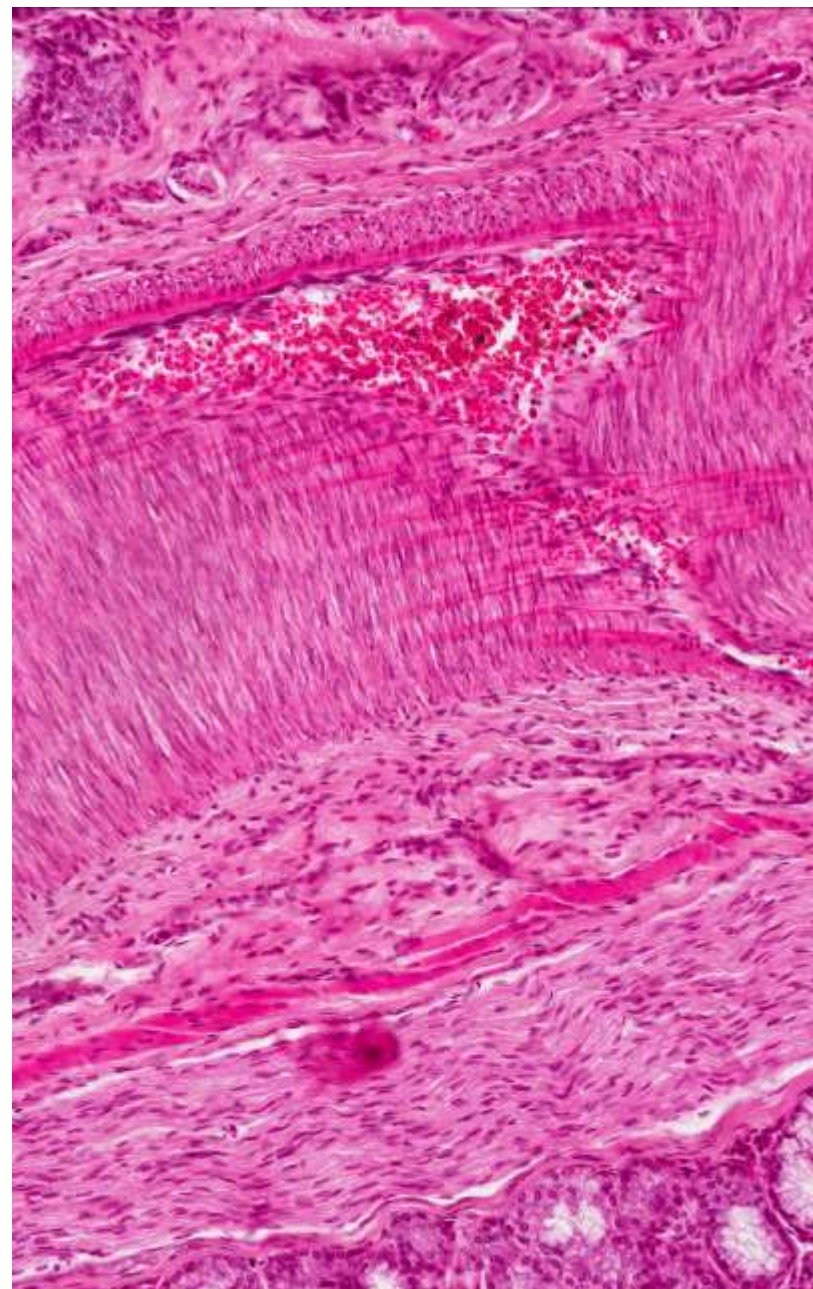
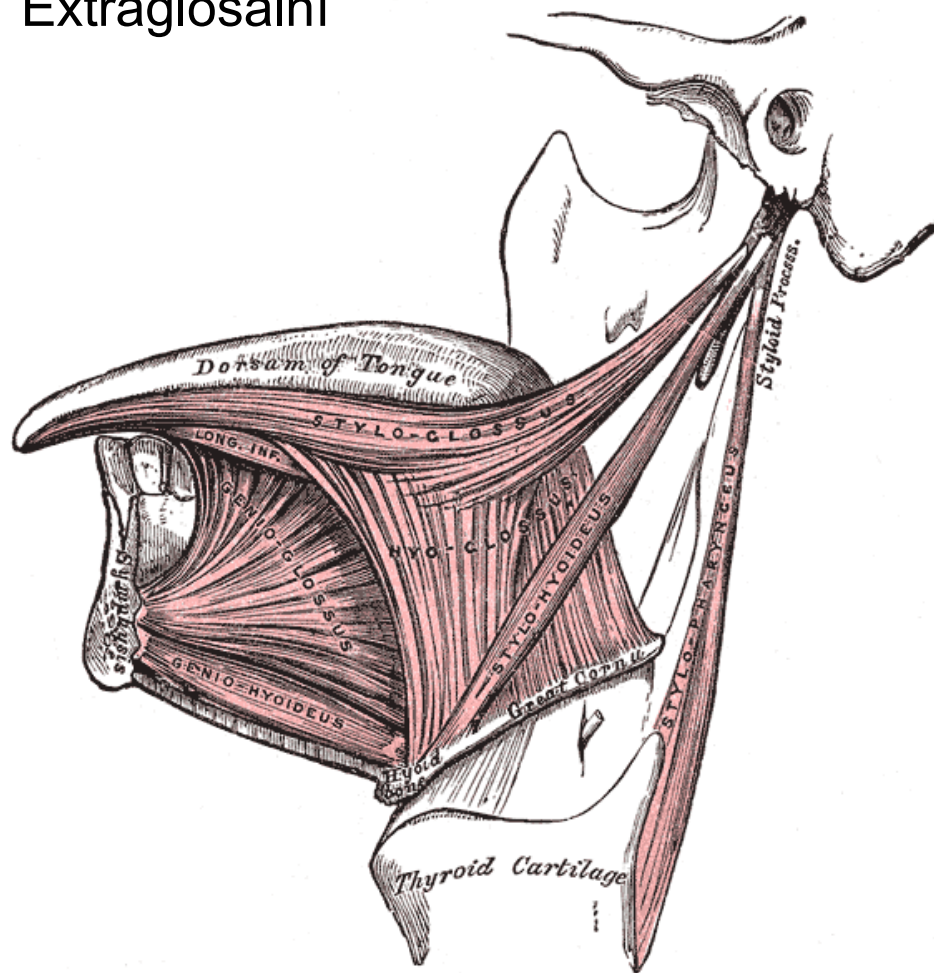
Musculi linguae

Glandula lingualis anterior

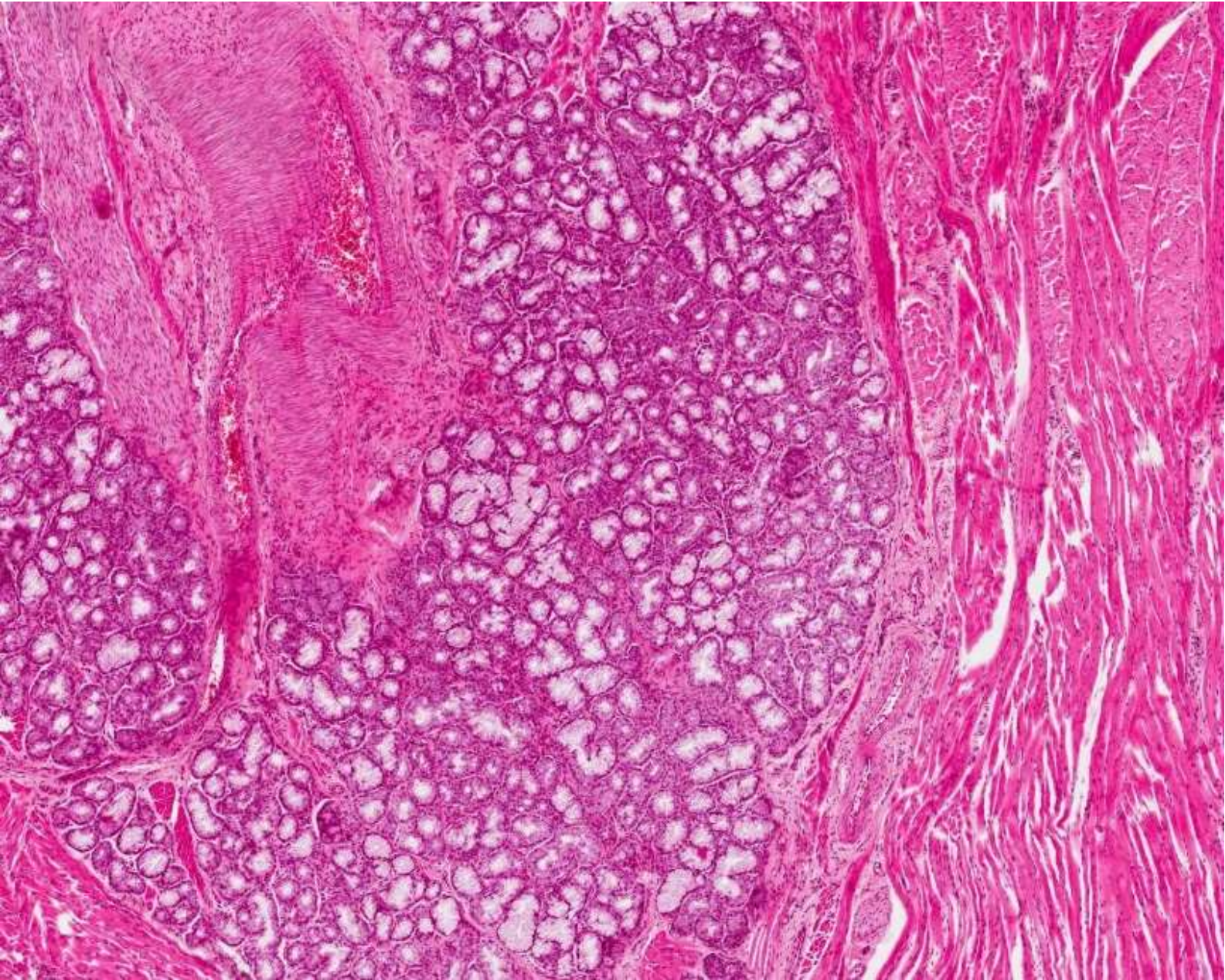
Facies mylohyoidea

# JAZYK - SVALY

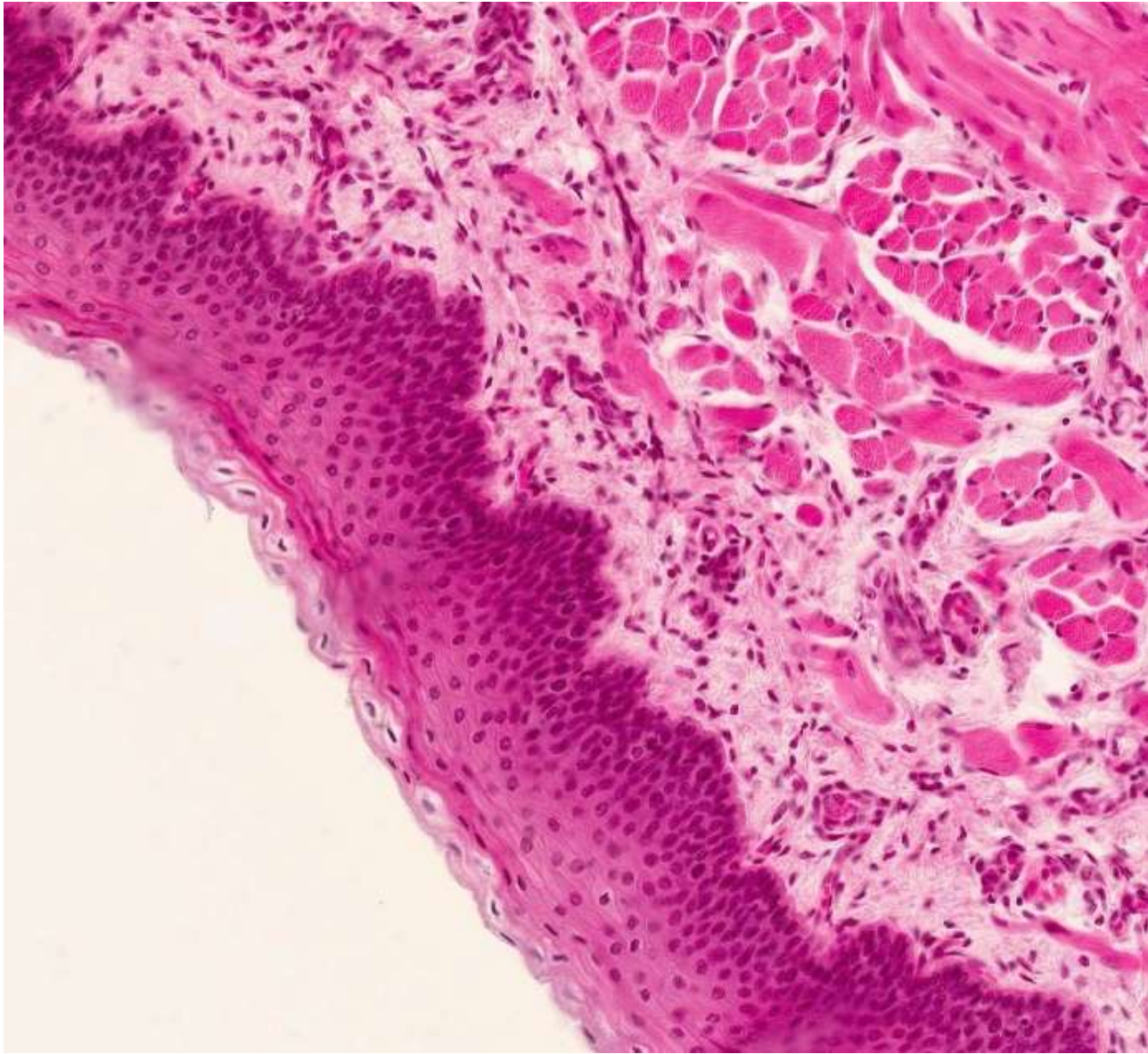
- Intraglosální
- Extraglosální



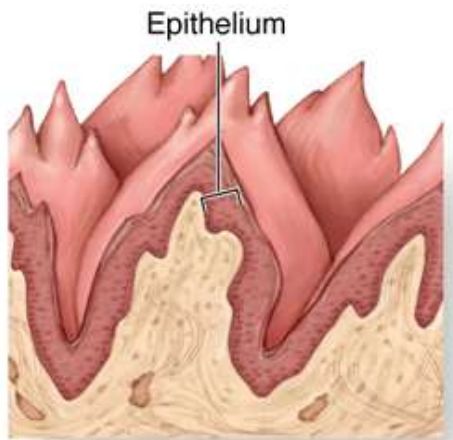
JAZYK - GLL. LINGUALES ANTERIORES (BLANDINI)



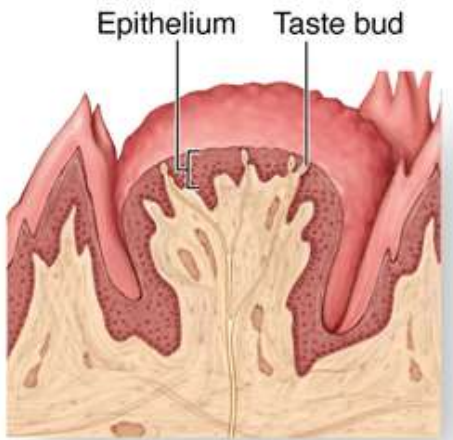
# JAZYK - FACIES MYLOHYOIDEA



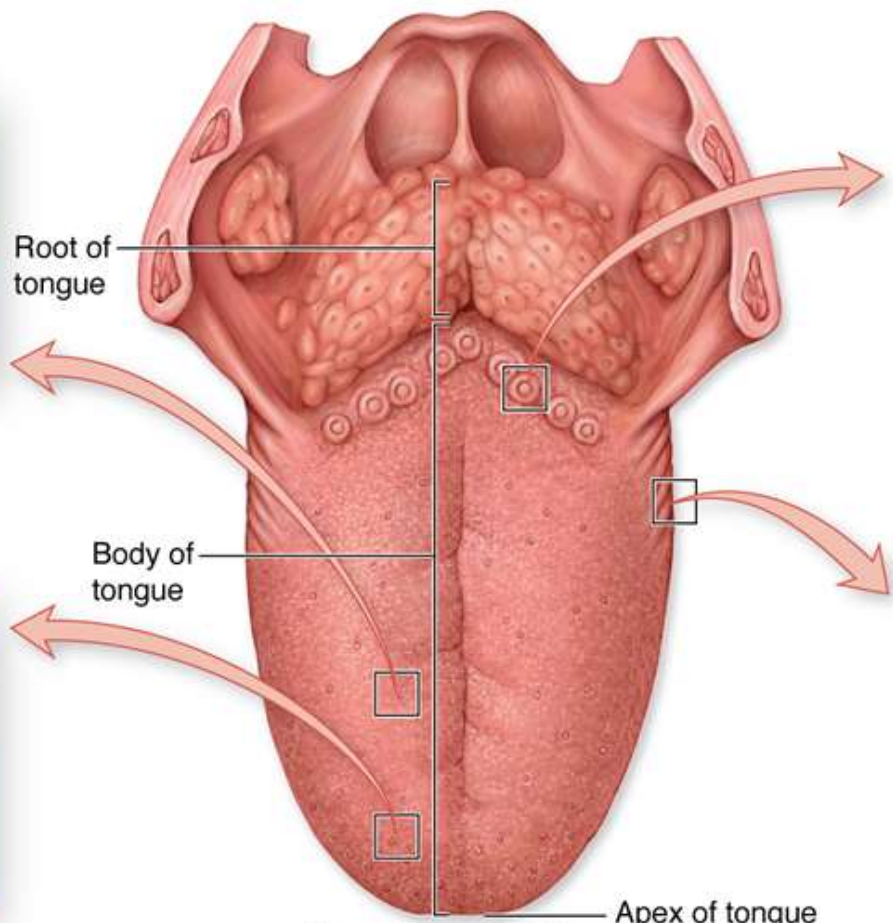
specializovaná slizniční struktury - **papily**  
podslizniční vazivo chybí



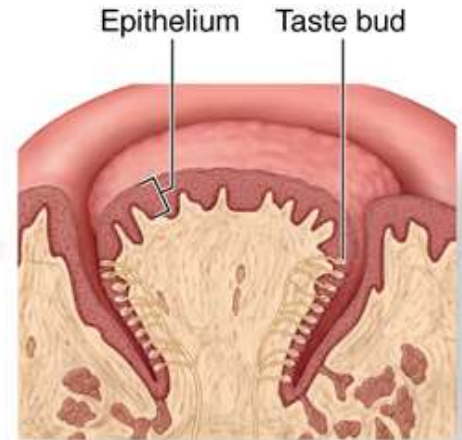
Filiform papilla



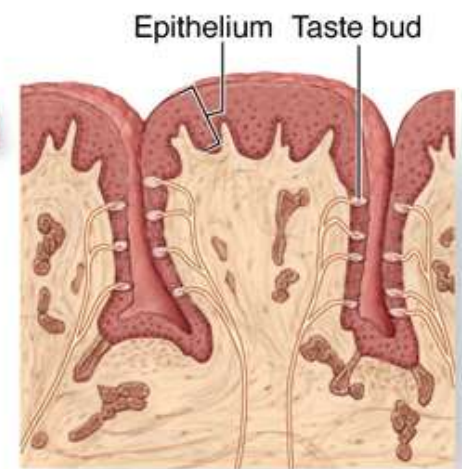
Fungiform papilla



Dorsal surface of tongue

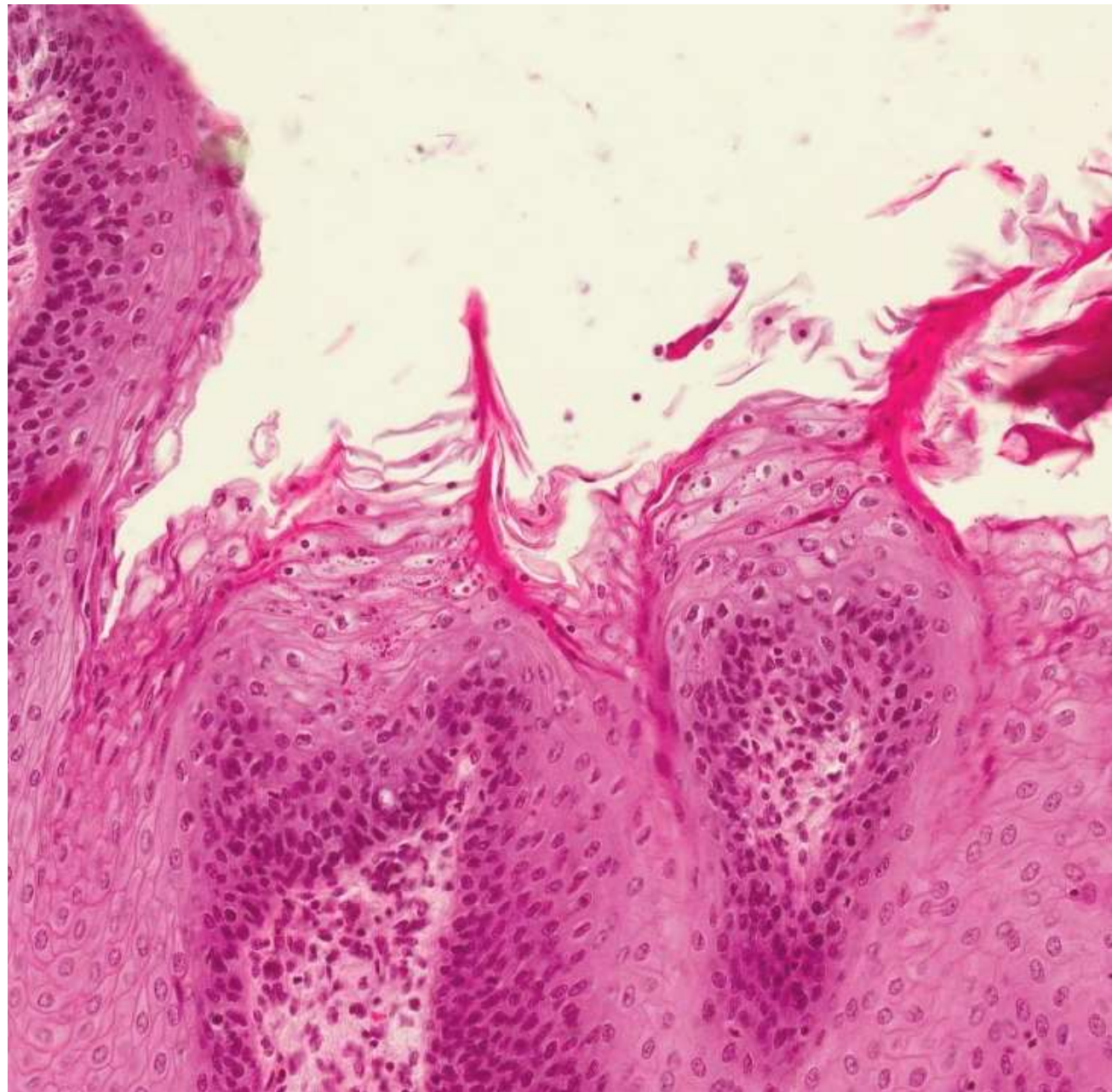
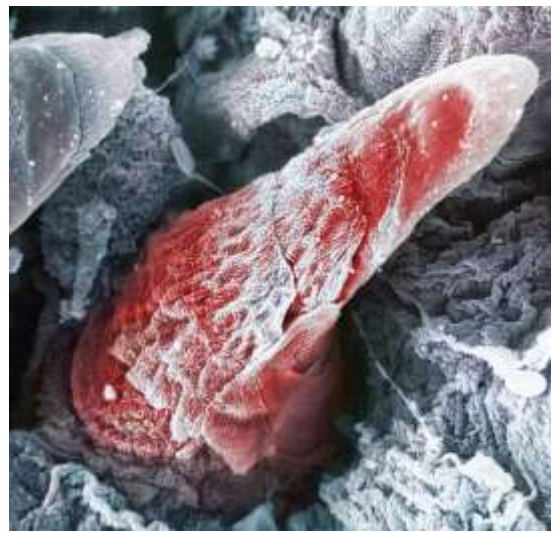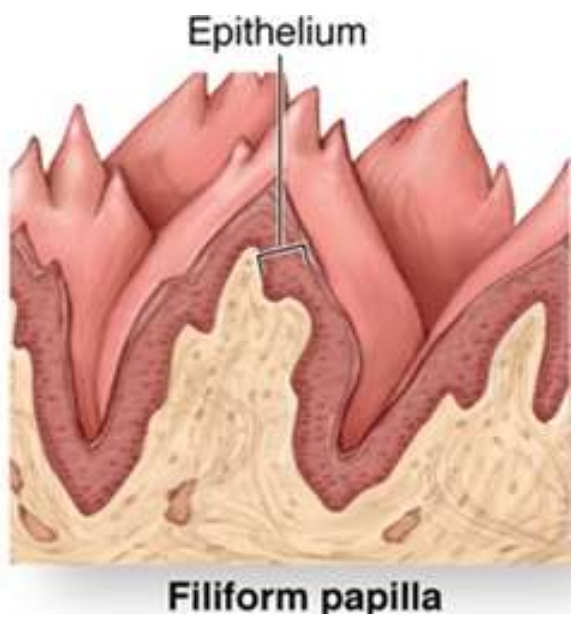


Vallate papilla

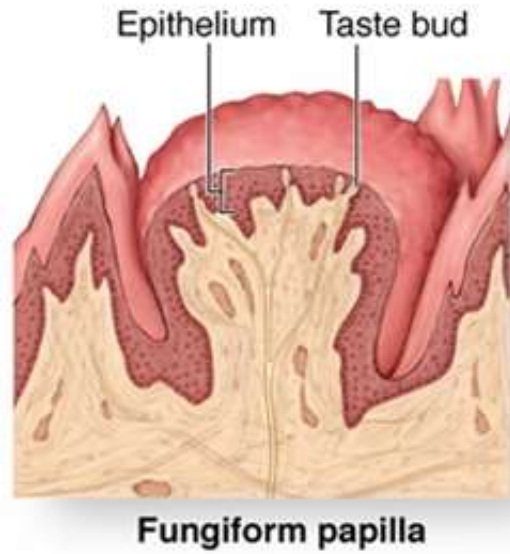
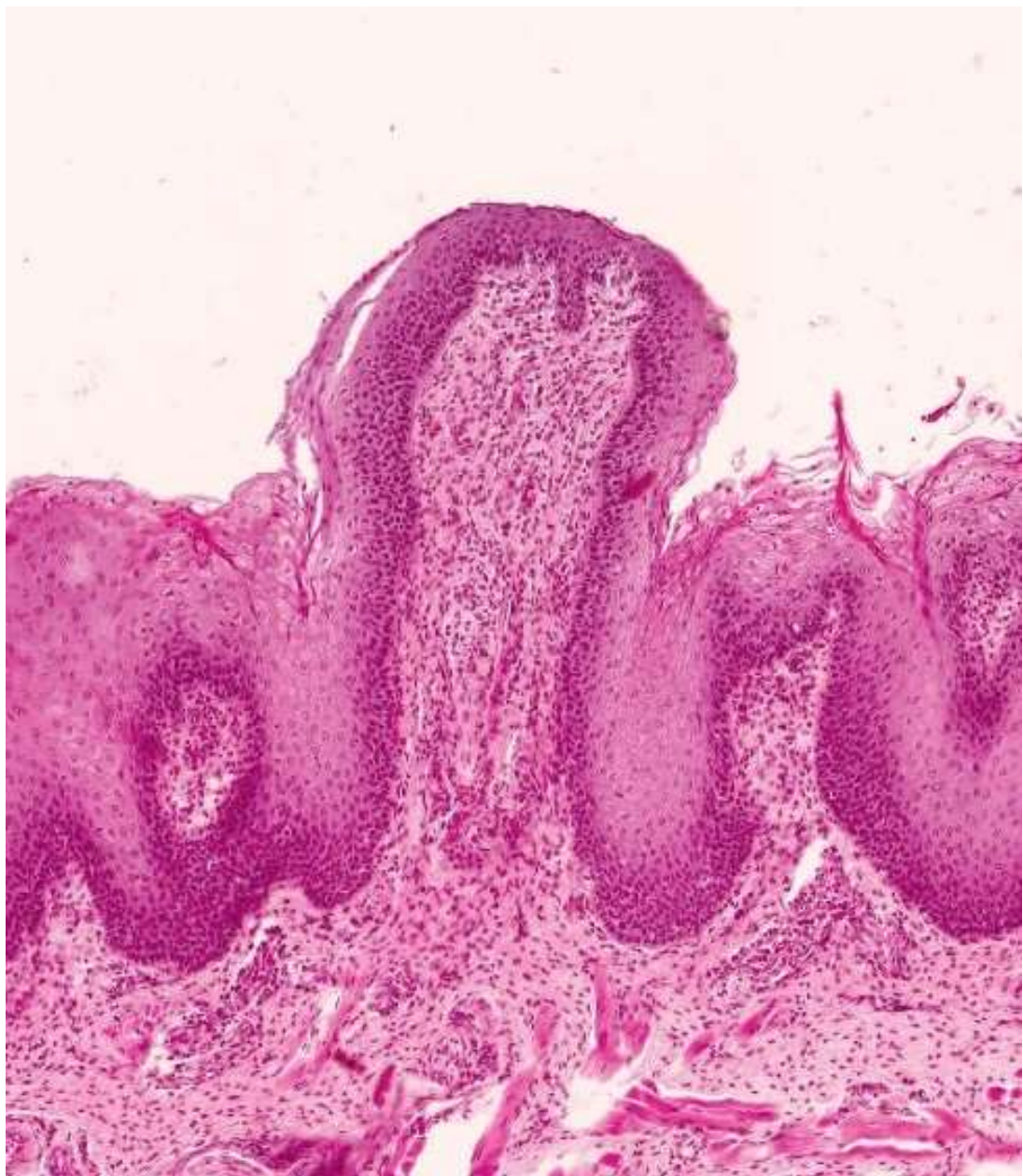

Foliate papilla

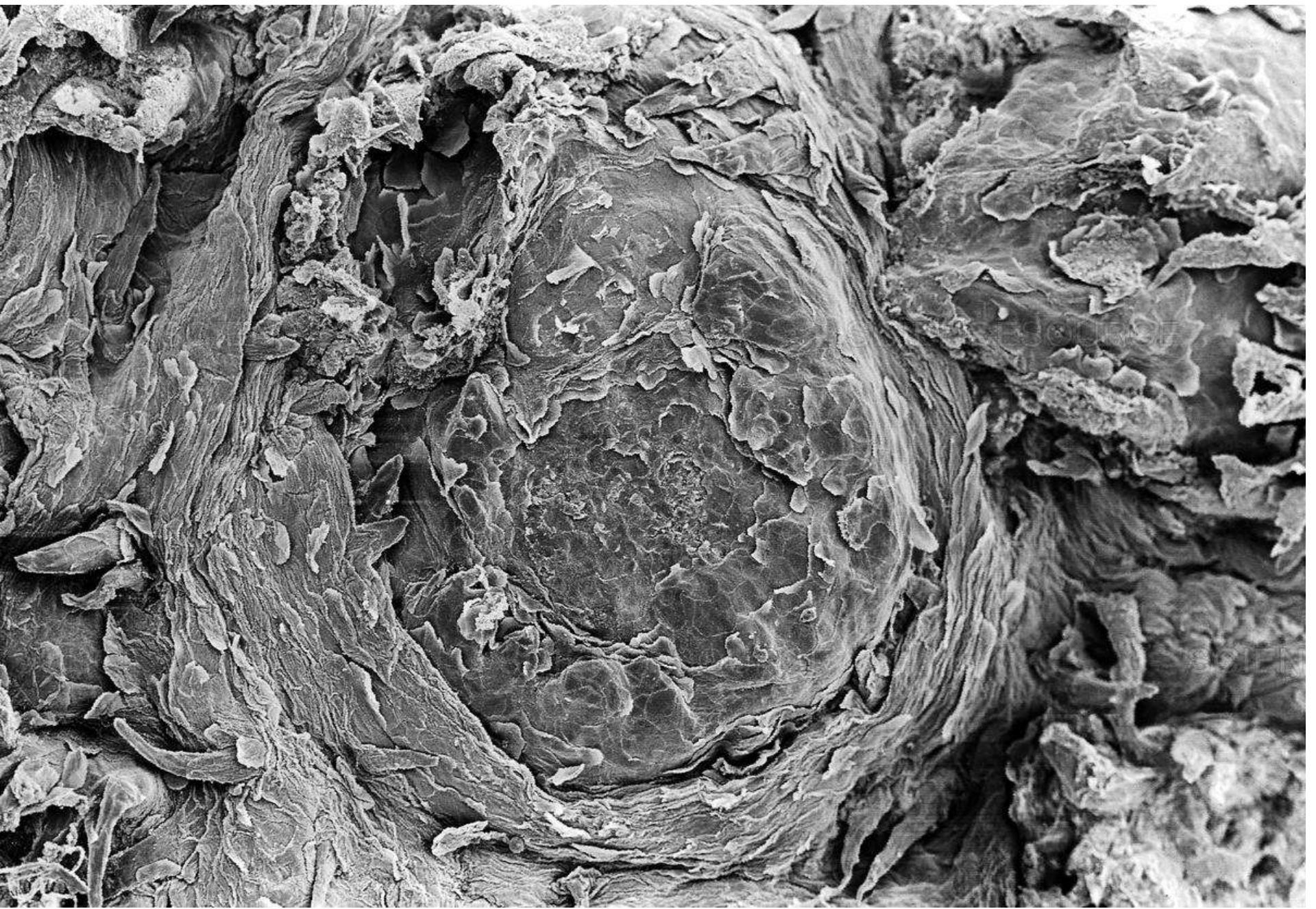
# JAZYK – FILIFORMNÍ (NITKOVITÉ) PAPILY



# JAZYK – FUNGIFORMNÍ (HOUBOVITÉ) PAPILY

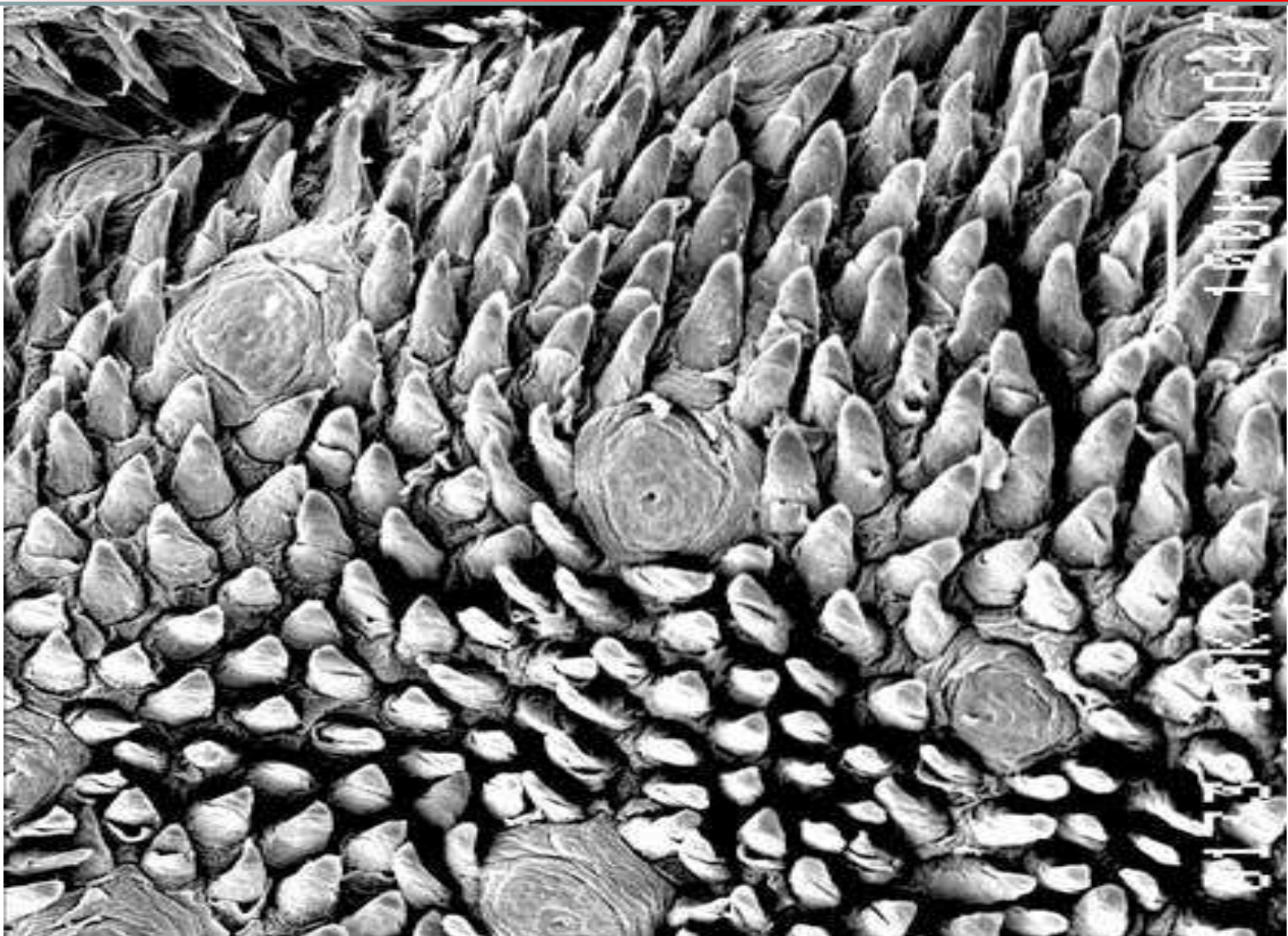


# JAZYK – FUNGIFORMNÍ PAPILY

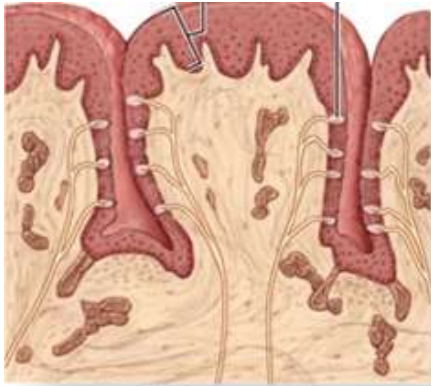




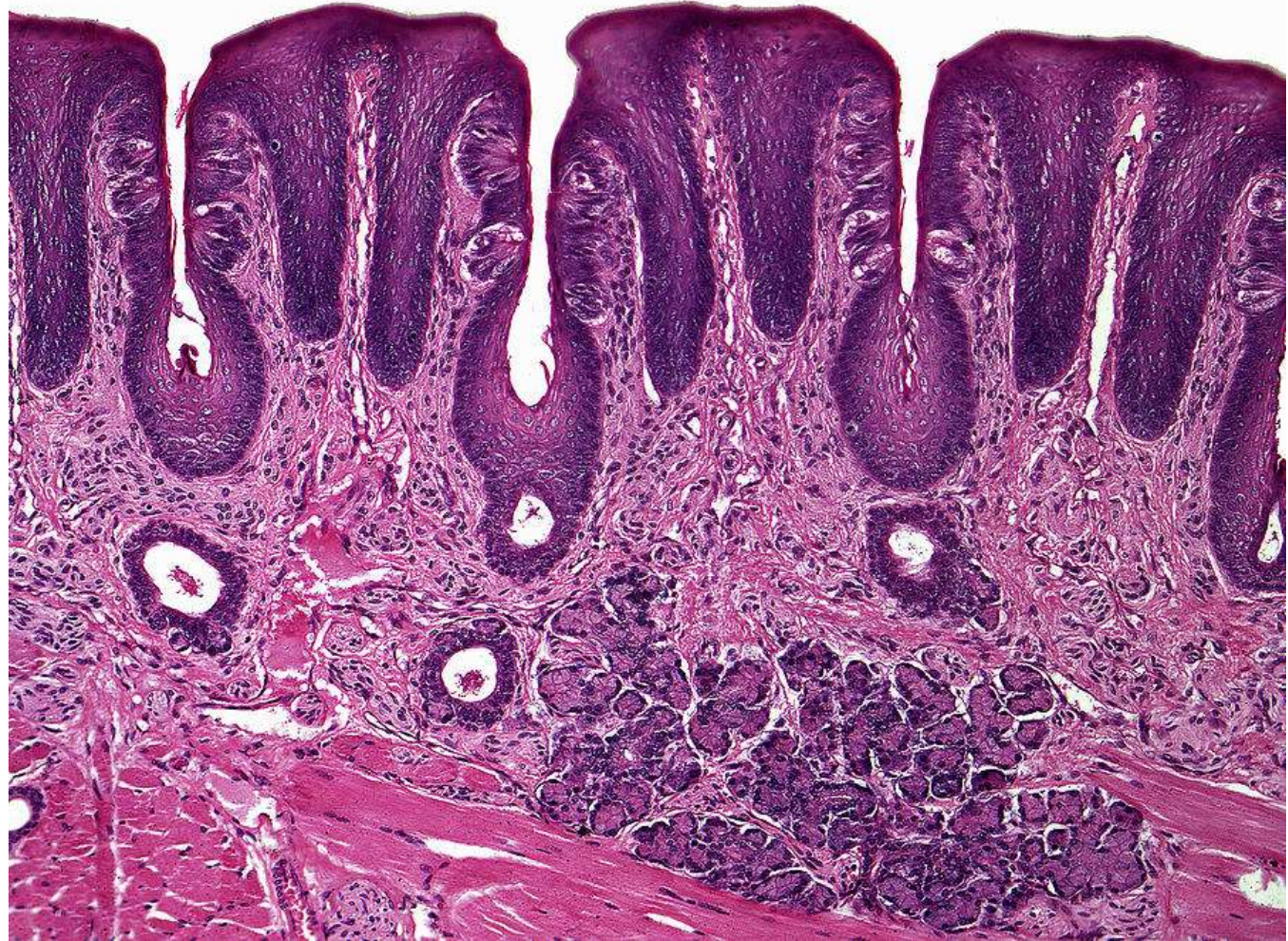
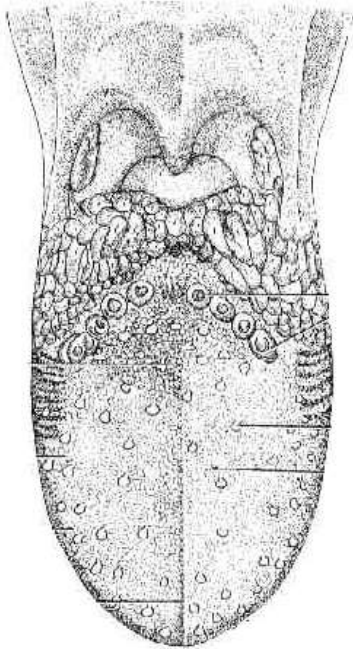
# JAZYK – FILIFORMNÍ A FUNGIFORMNÍ PAPILY



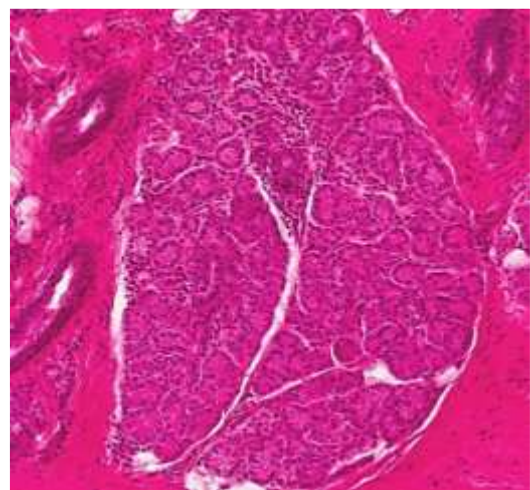
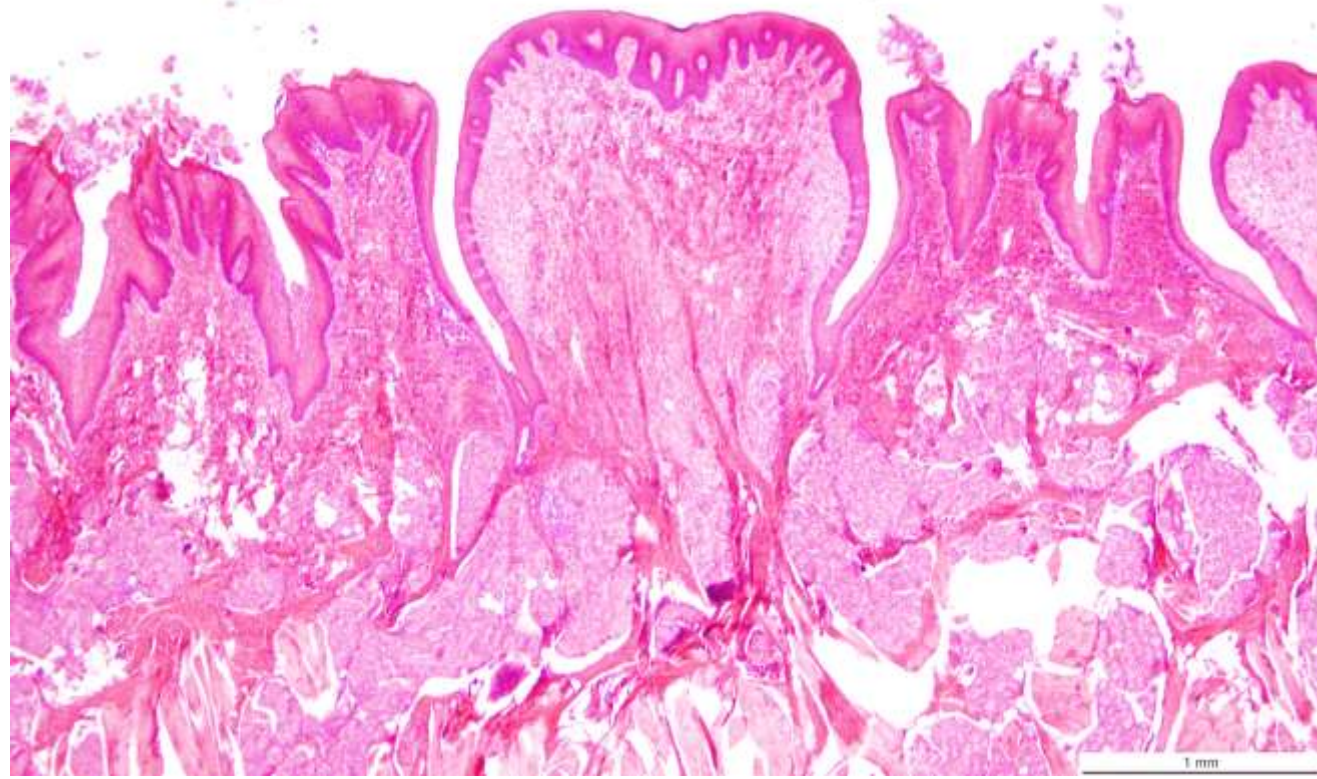
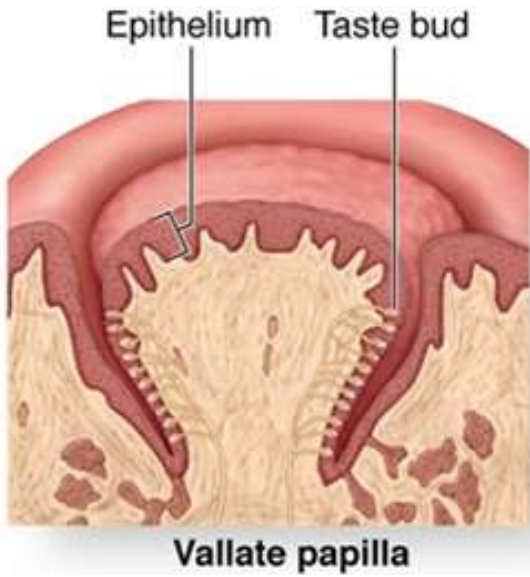
# JAZYK – FOLIÁTNÍ (LISTOVITÉ) PAPILY



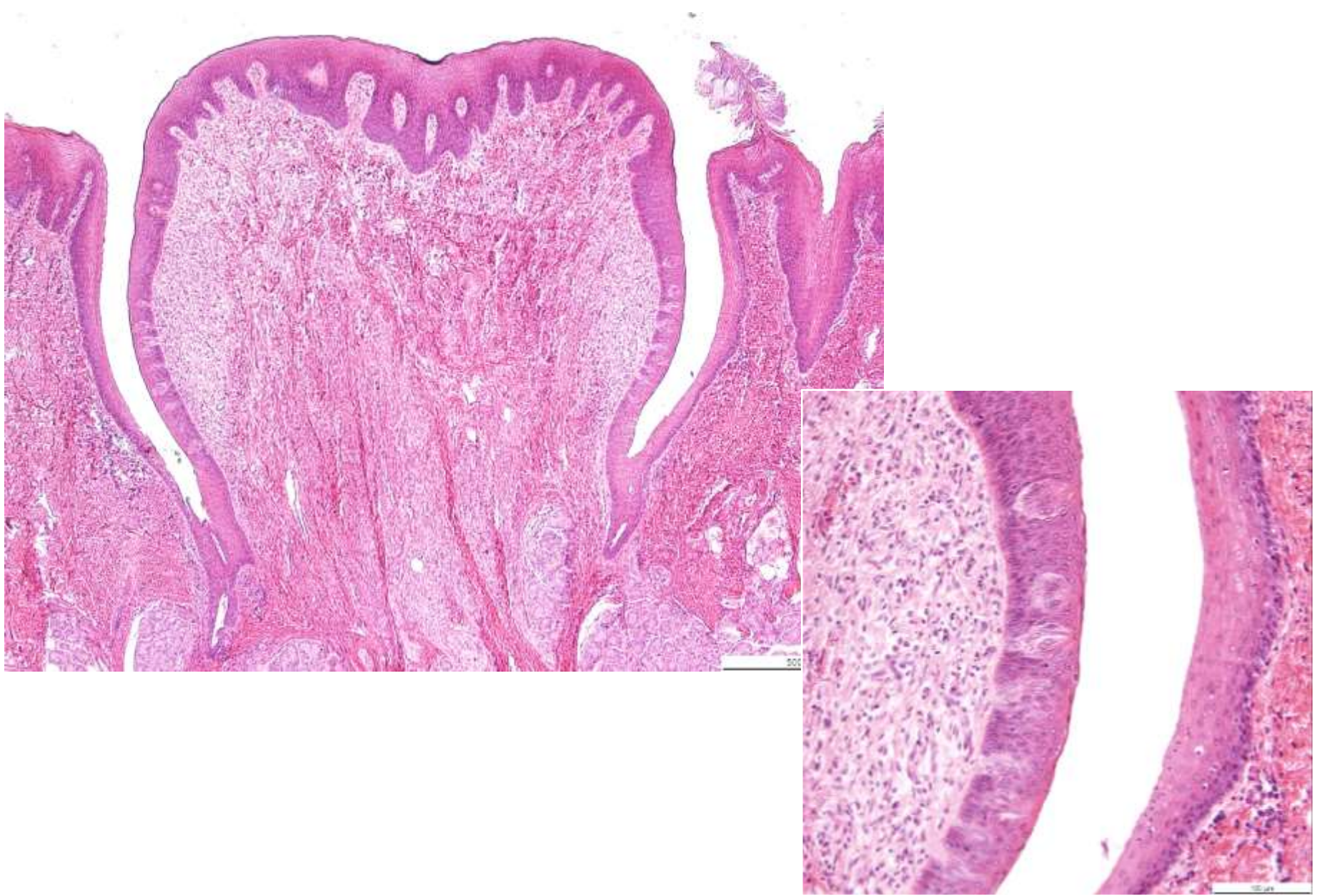Foliate papilla



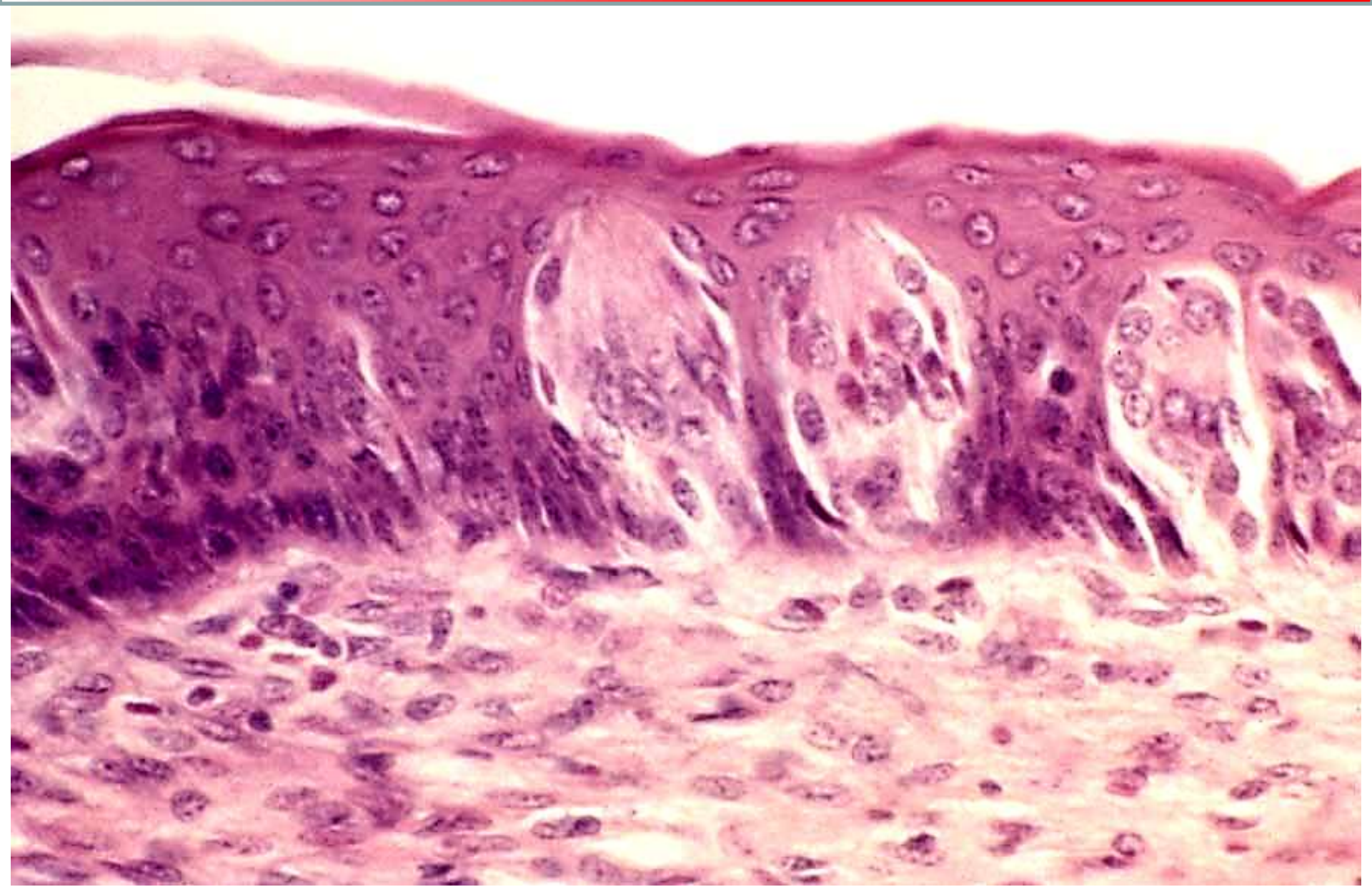
# JAZYK – VALÁTNÍ (HRAZENÉ) PAPILY



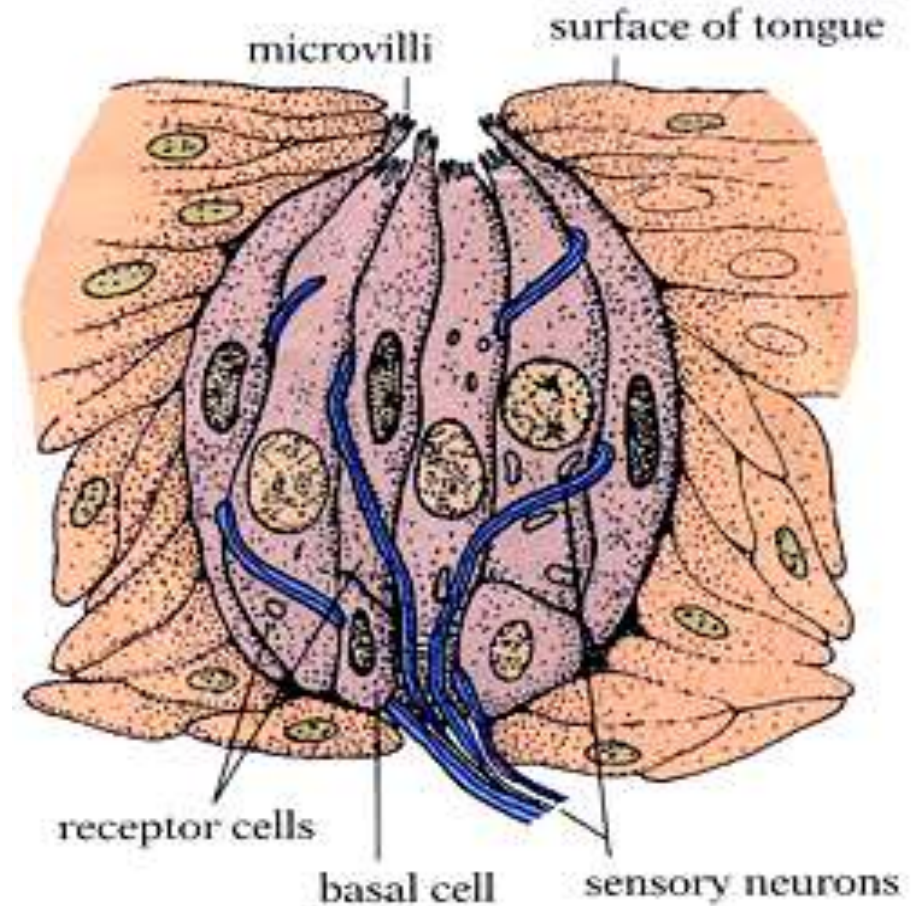
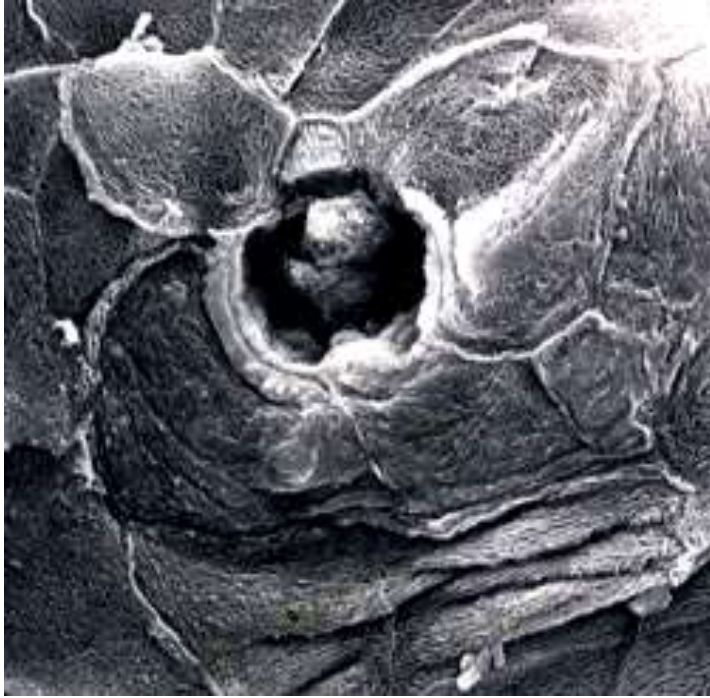# JAZYK – VALÁTNÍ (HRAZENÉ) PAPILY



# JAZYK – CHUŤOVÉ POHÁRKY

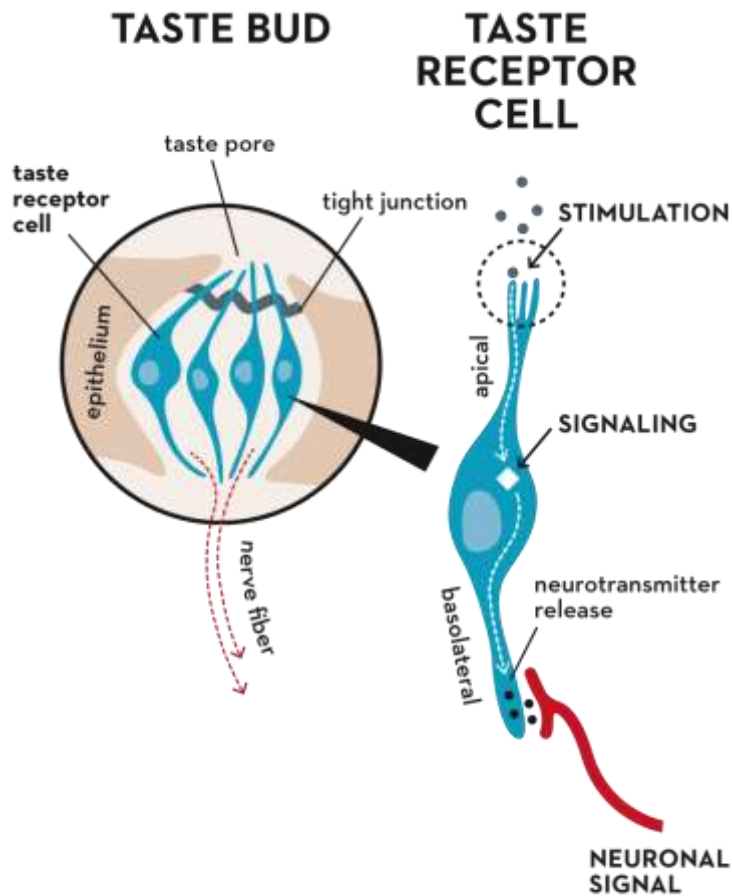


# JAZYK – CHUŤOVÝ POHÁREK



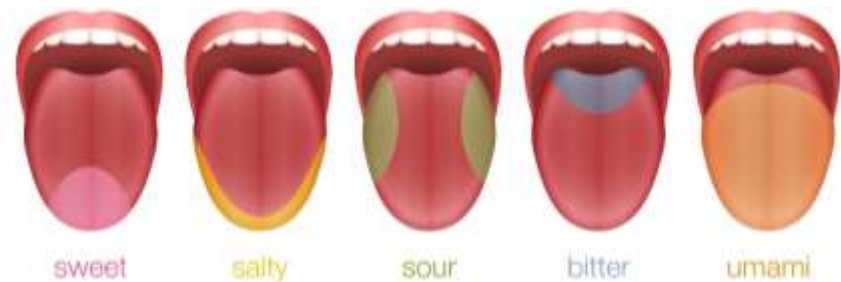- intraepiteliální
- porus gustatorius
- 2000-8000 v ústní dutině
- 60-80 buněk
- 70-80  $\mu\text{m} \times 30\text{-}40 \mu\text{m}$
- mikrokly na smyslových buňkách
- nervová vlákna

# JAZYK – CHUŤOVÝ POHÁREK

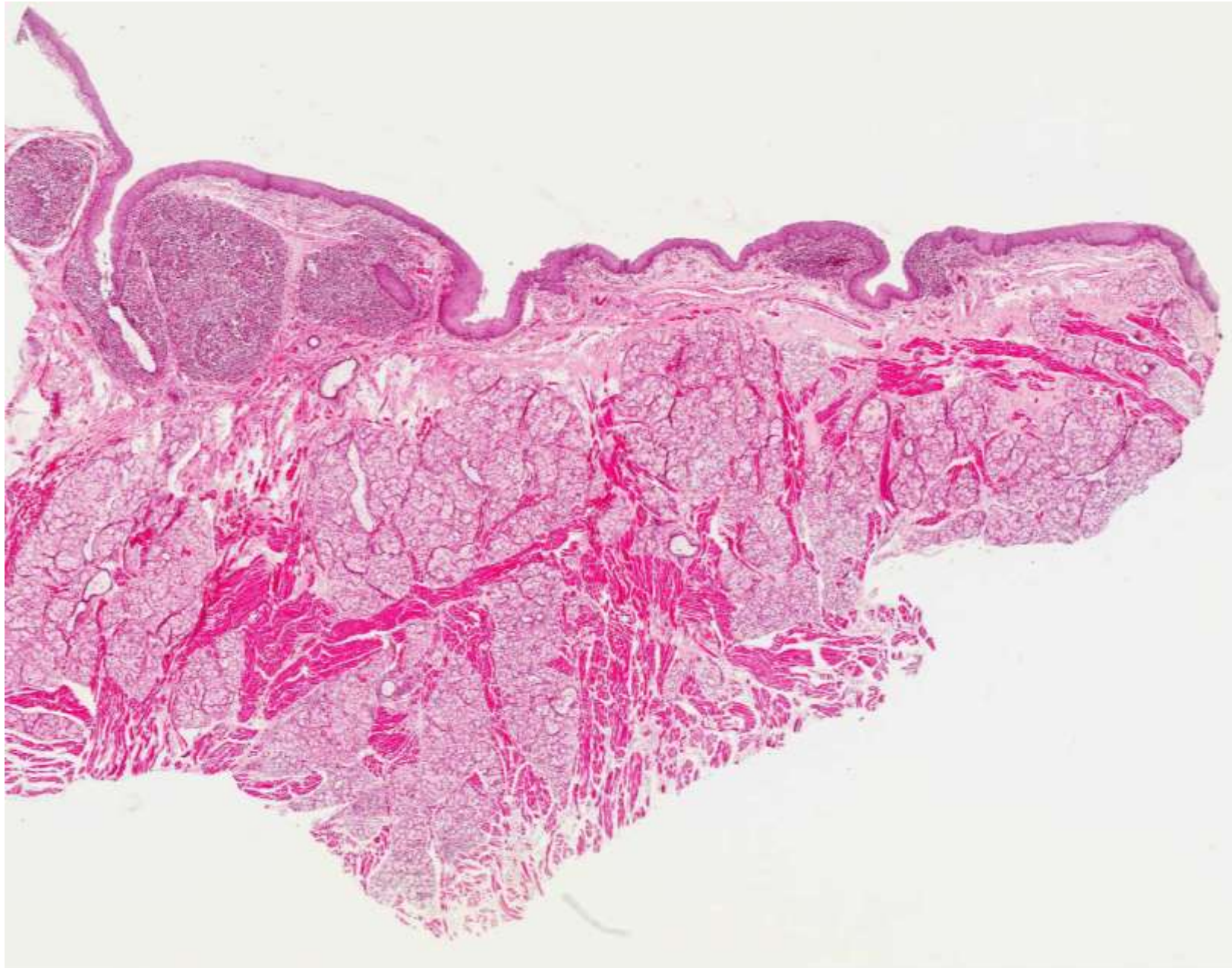

- hořké
- sladké
- umami (glutamát)
- G-proteiny asociované s receptory
- slané
- kyselé
- iontové kanály
- CD36
- fatty acid transporter

- na vnímání chuti se podílí i čichový epitel

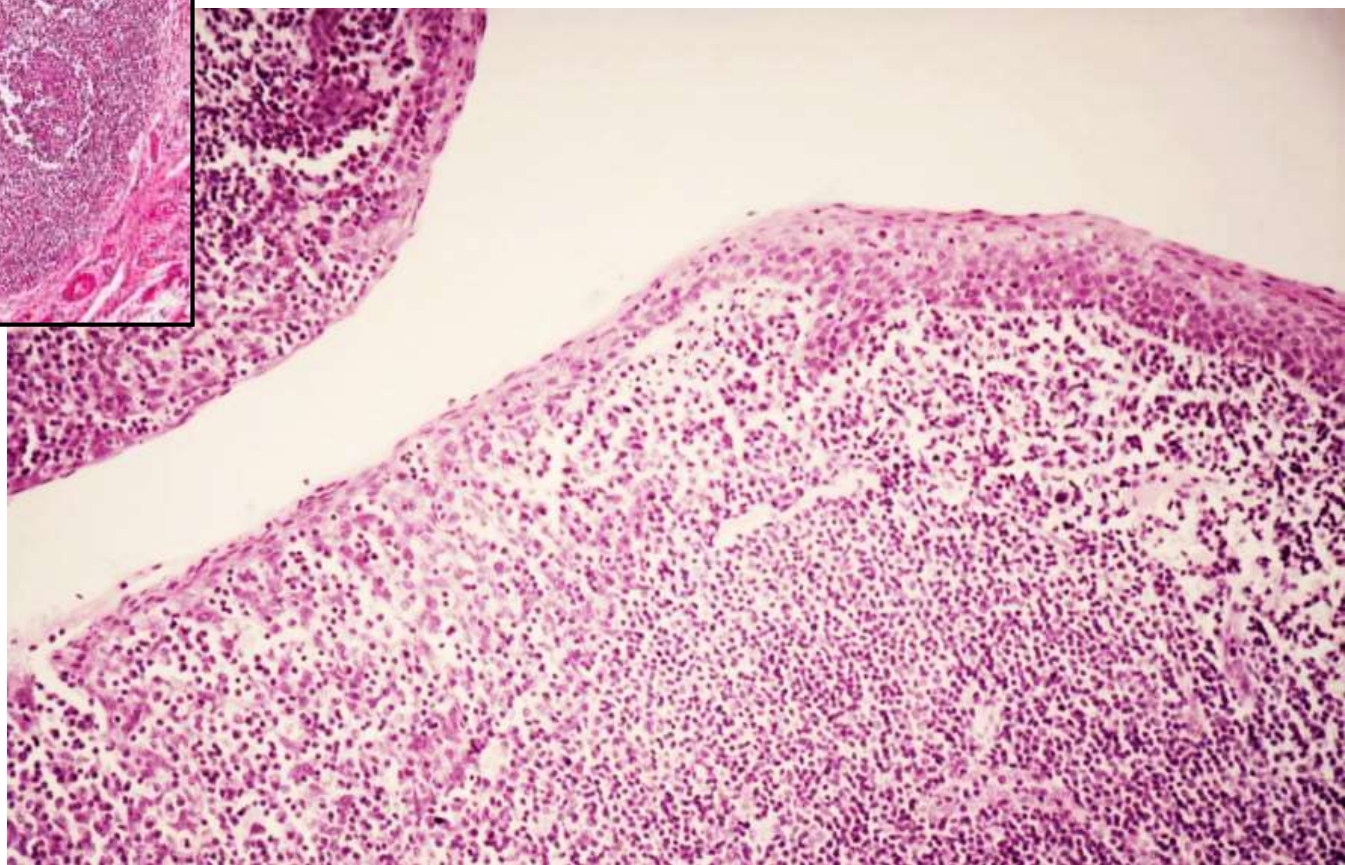
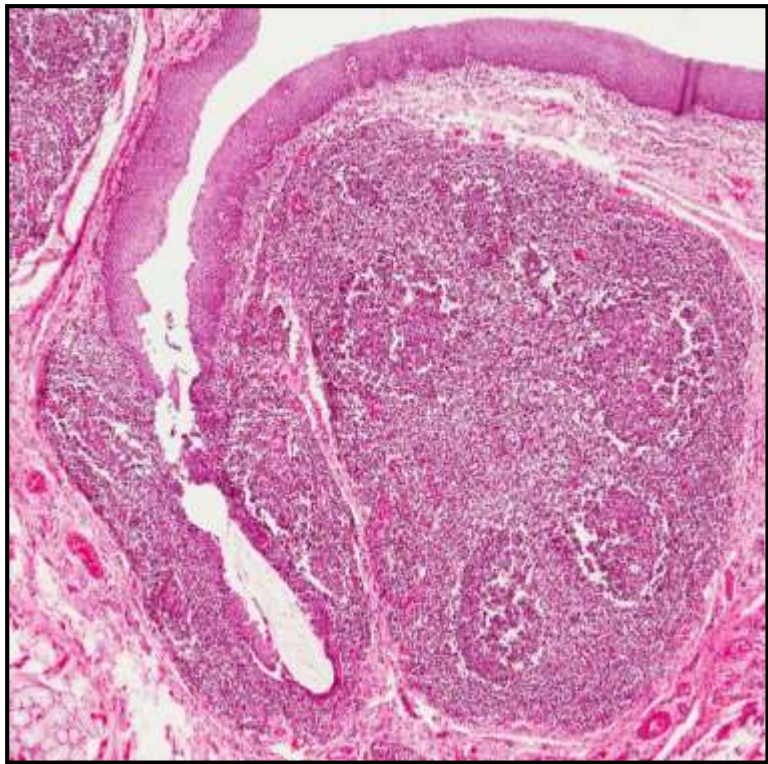


JAZYK – RADIX, TONSILLA LINGUALIS

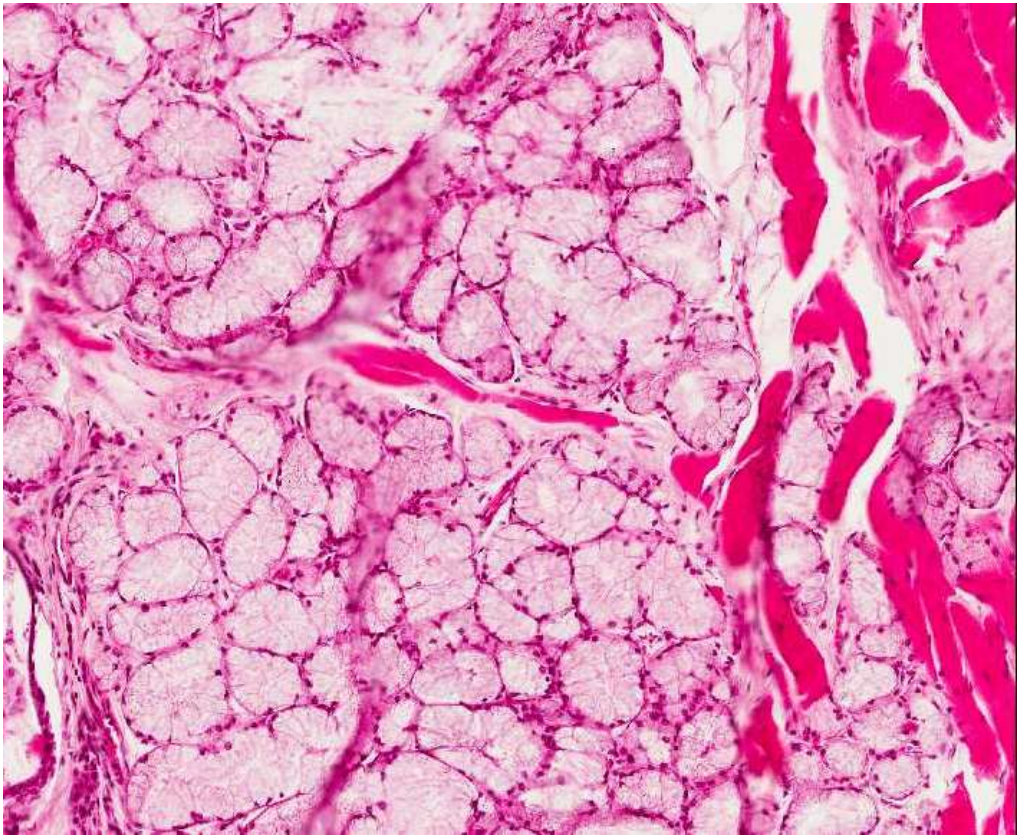
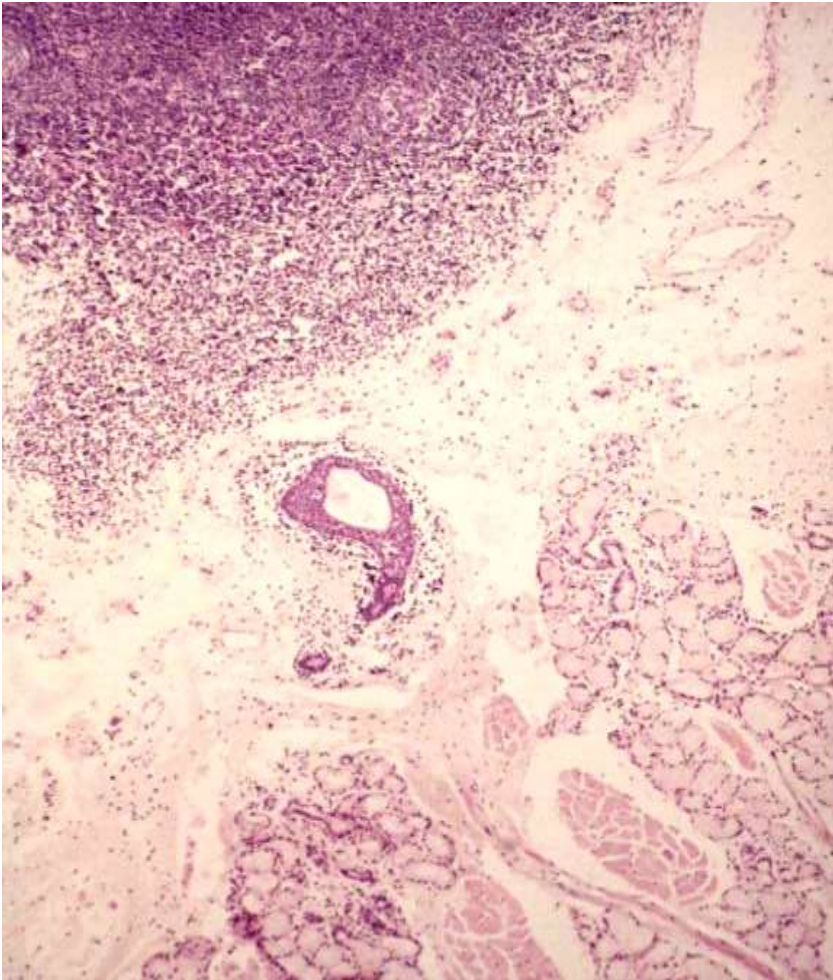




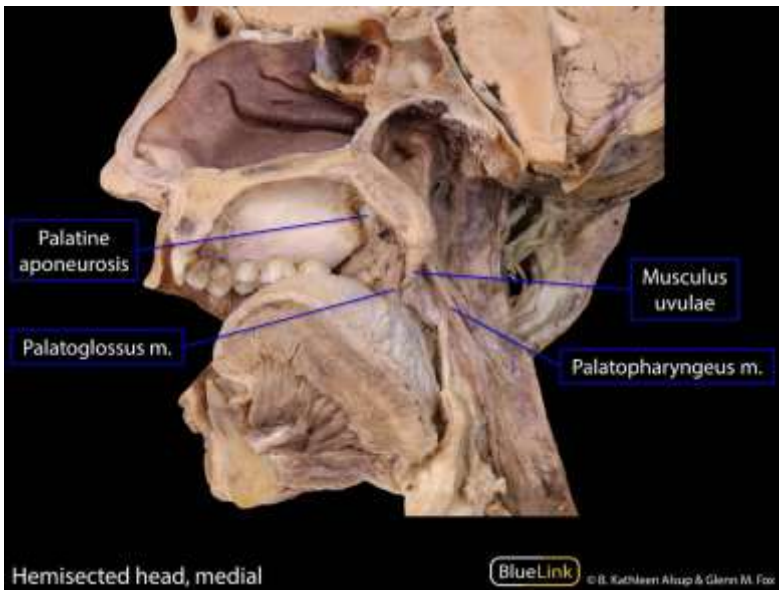
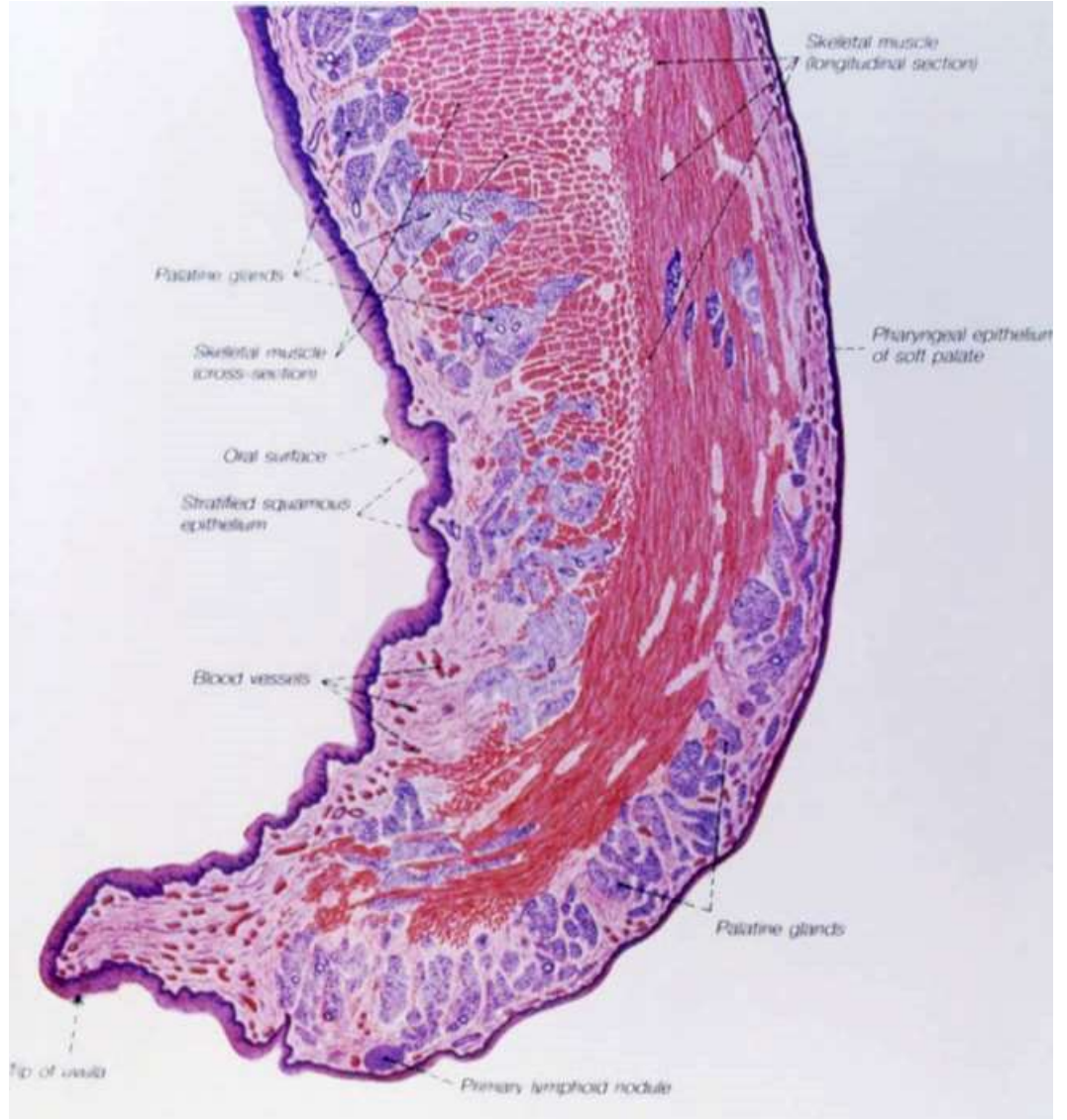
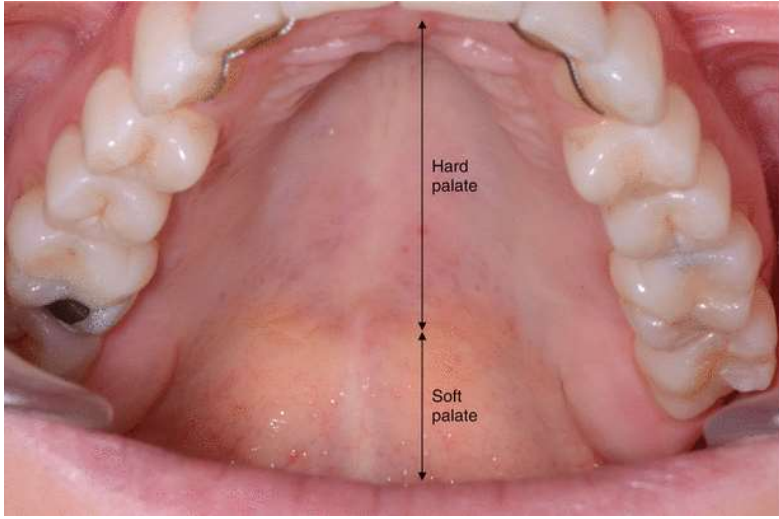
JAZYK – RADIX, TONSILLA LINGUALIS - KRYPTY



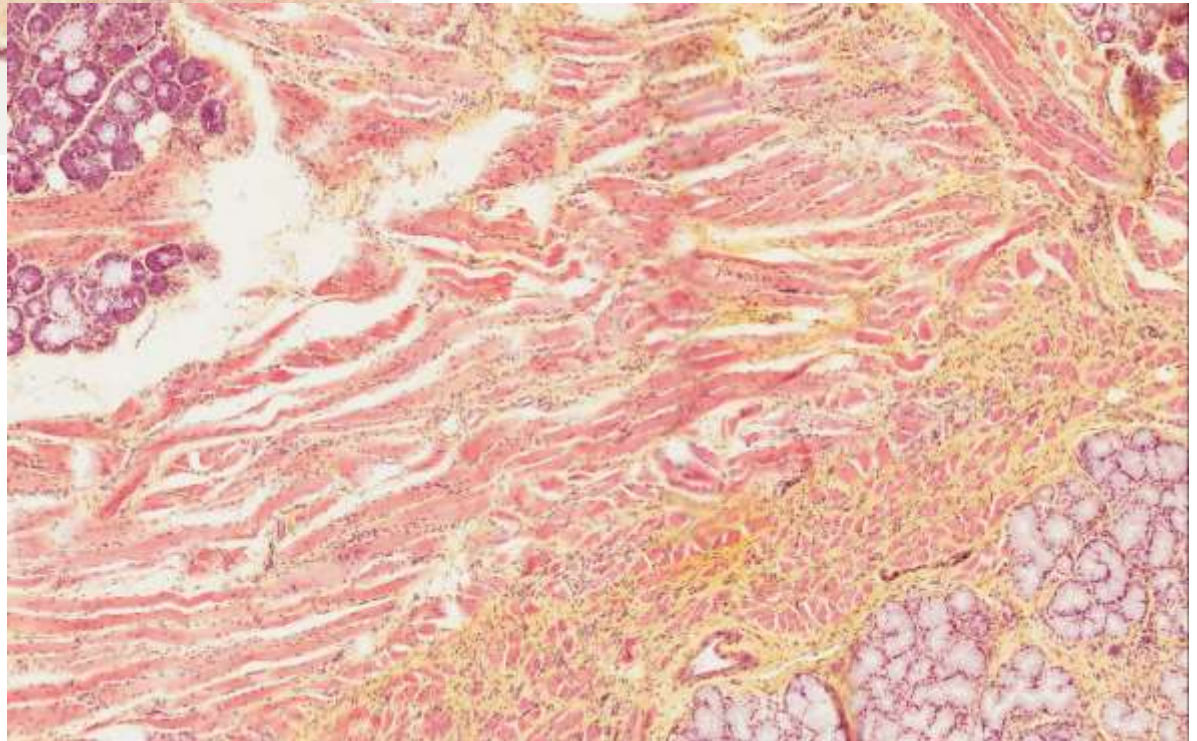
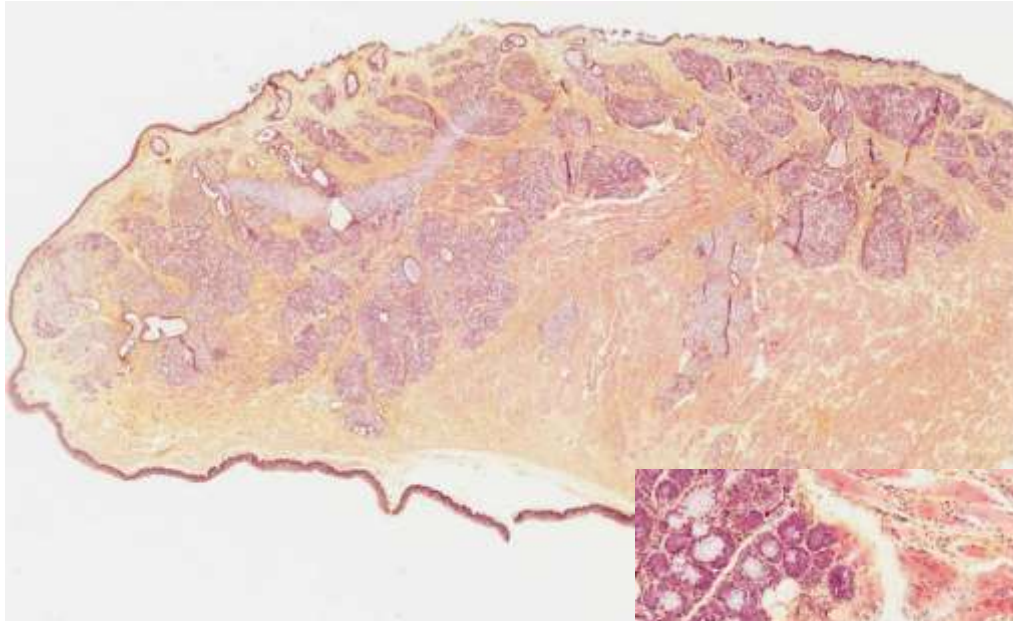
JAZYK – RADIX, TONSILLA LINGUALIS A WEBEROVY ŽLÁZY



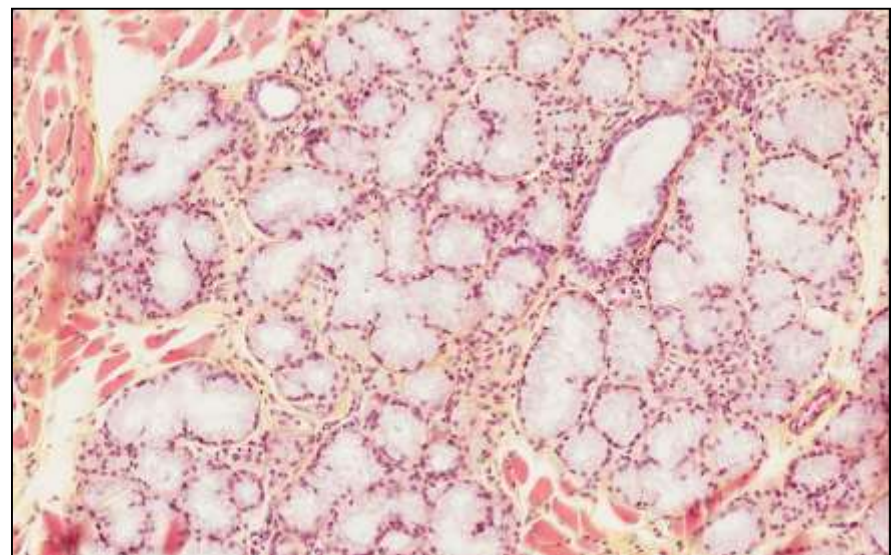
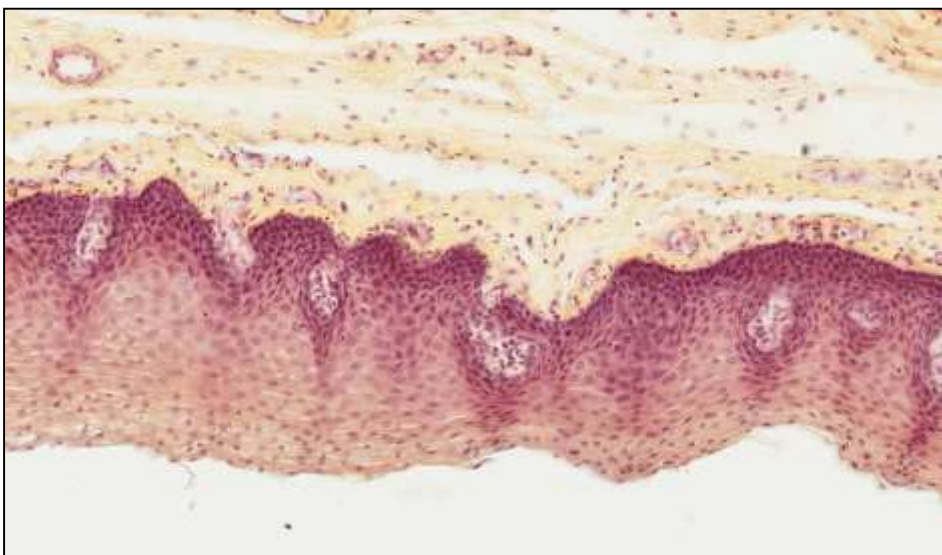
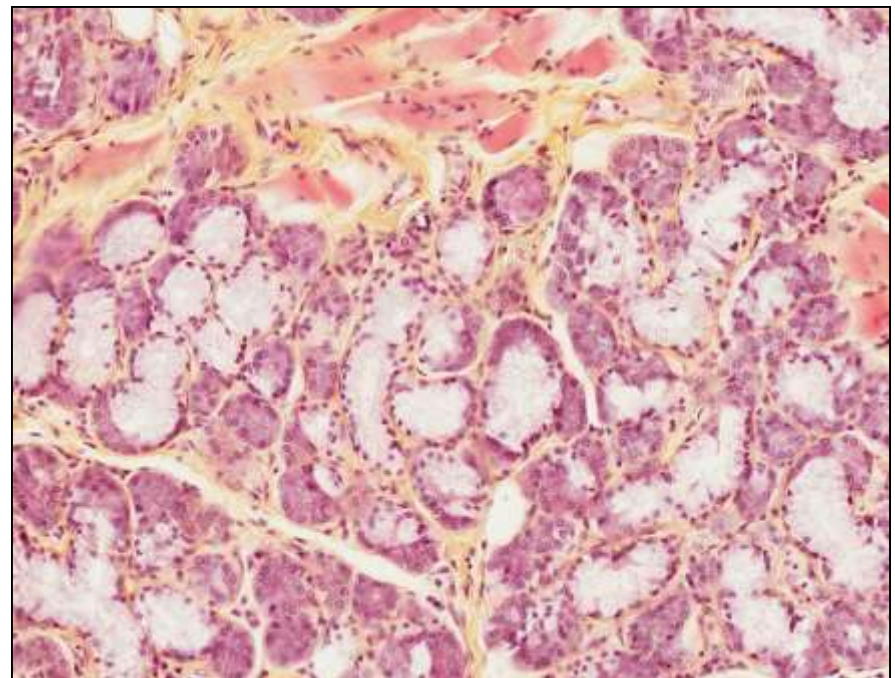
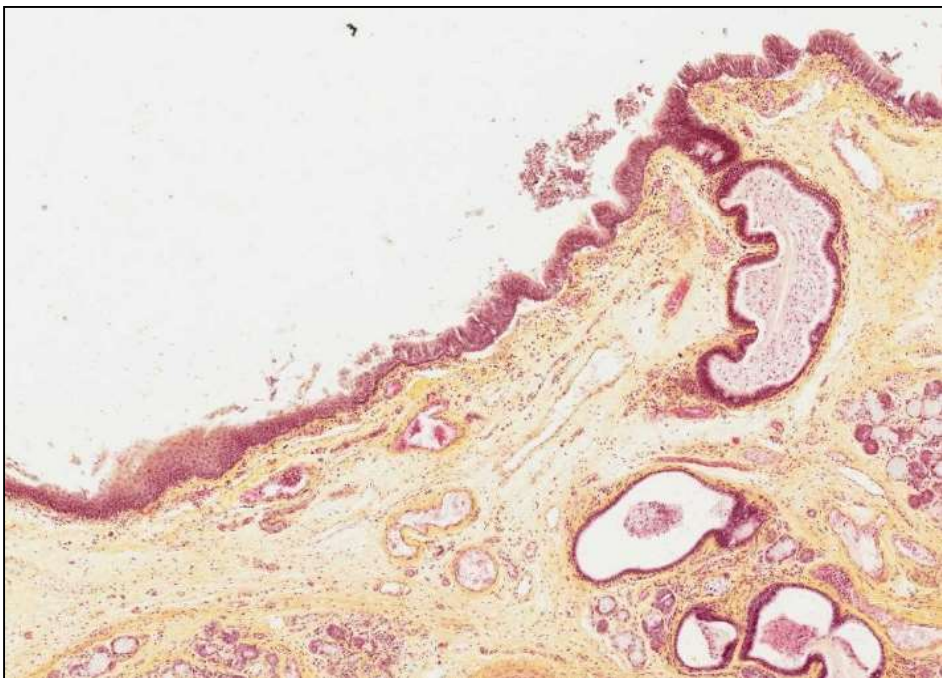# PATRO



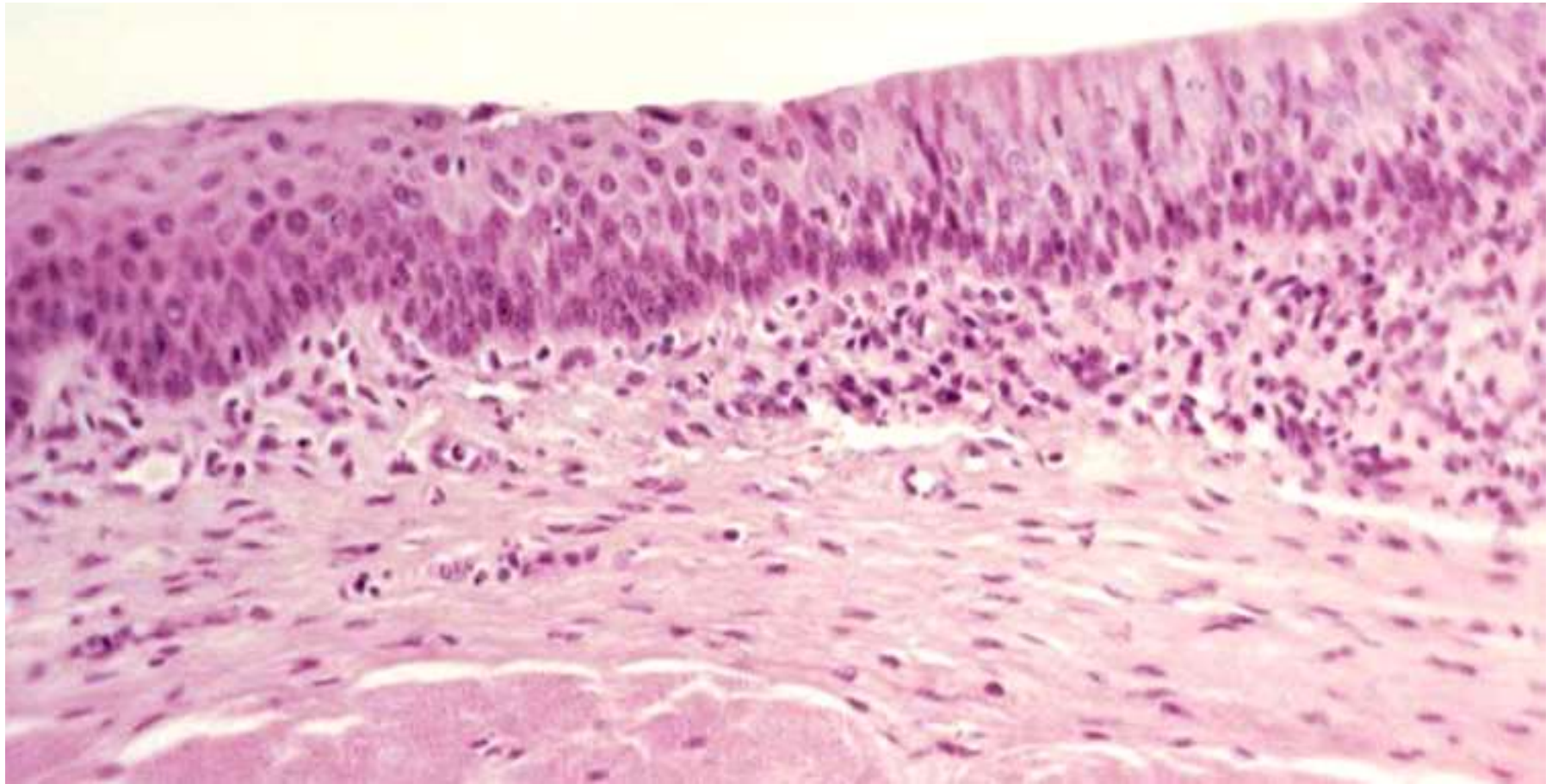
# MĚKKÉ PATRO



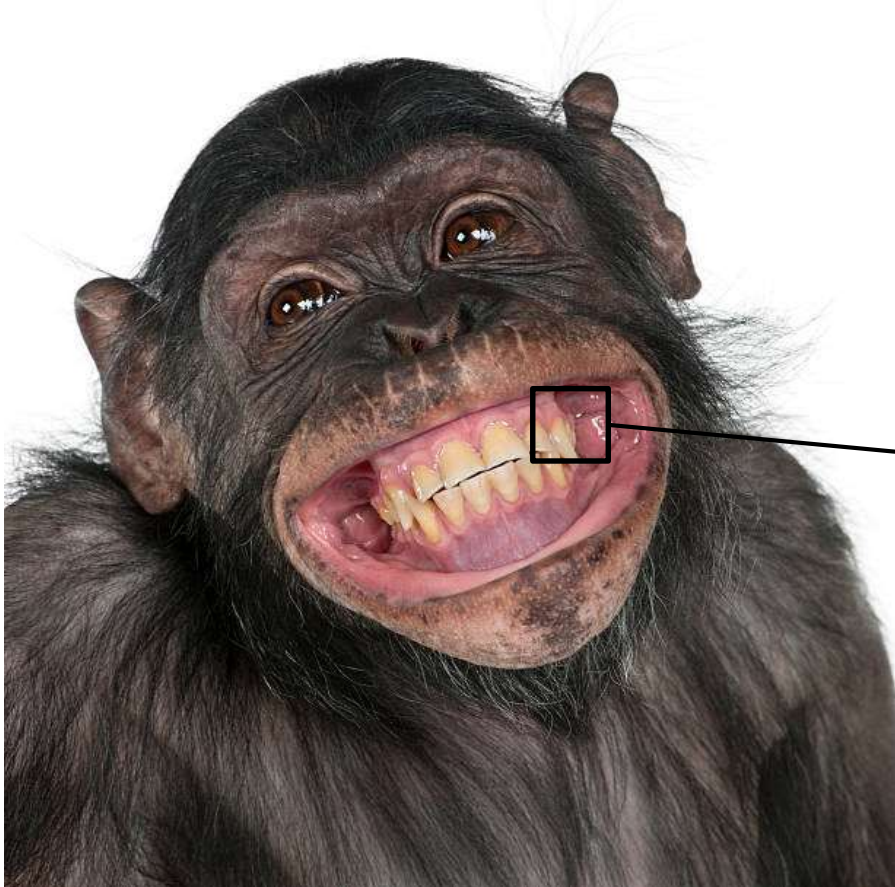
# MĚKKÉ PATRO



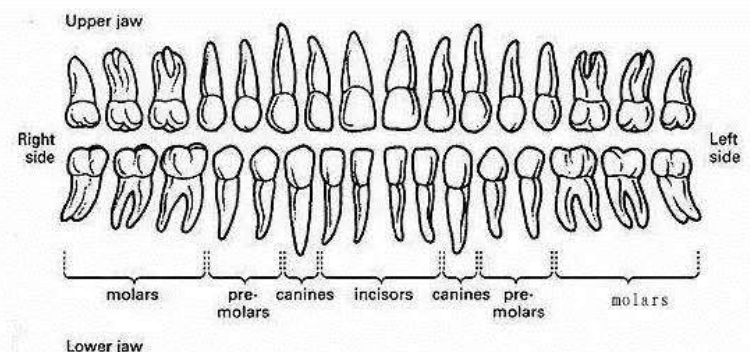
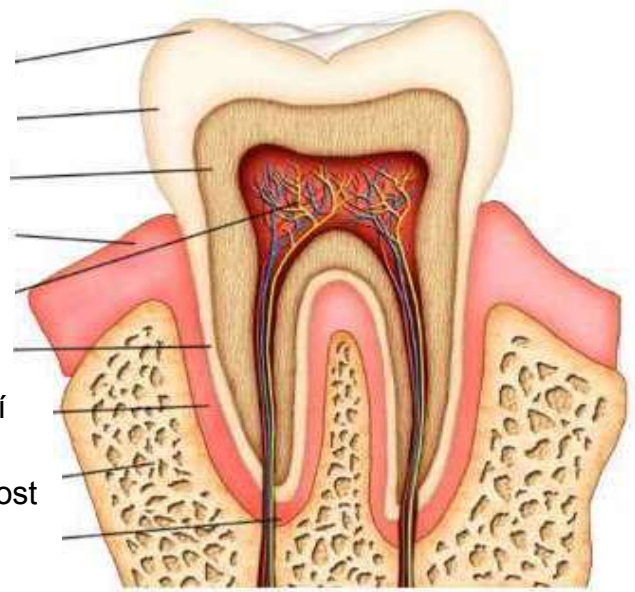
# MĚKKÉ PATRO - PŘECHOD EPITELŮ



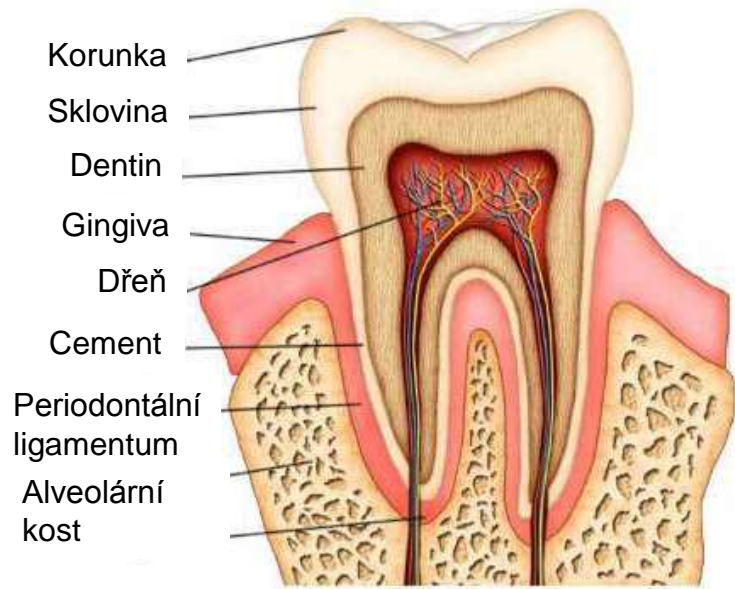
# ZUB



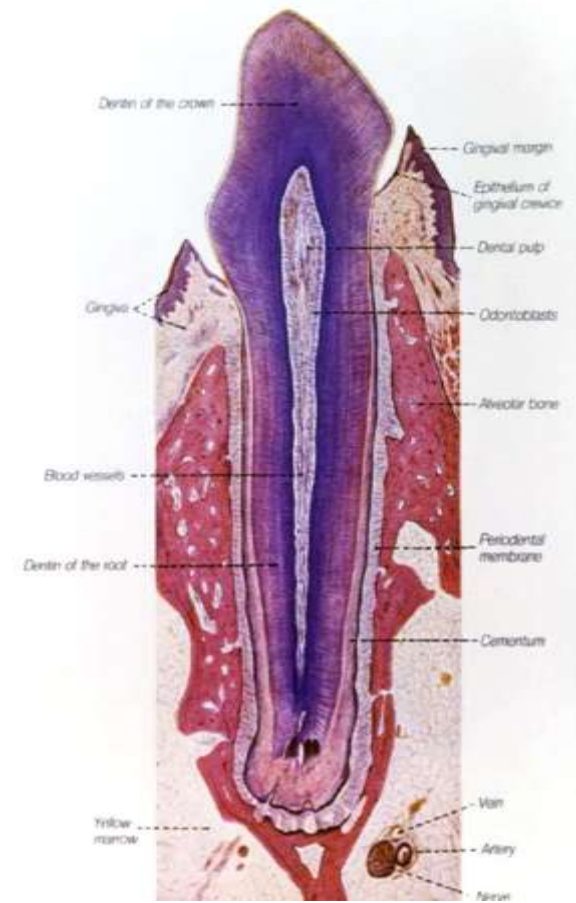
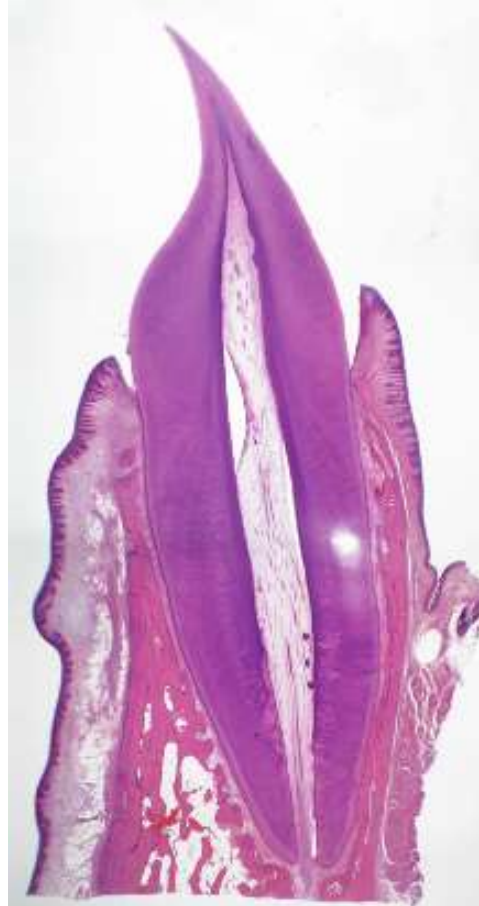
- Korunka
- Sklovina
- Dentin
- Dáseň
- Dřeň
- Cement
- Periodontální ligamentum
- Alveolární kost



# ZUB

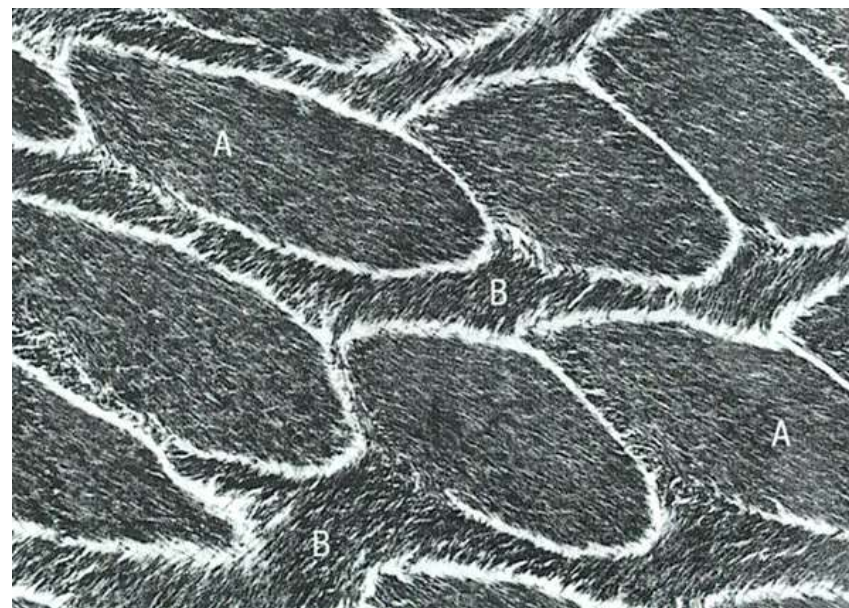
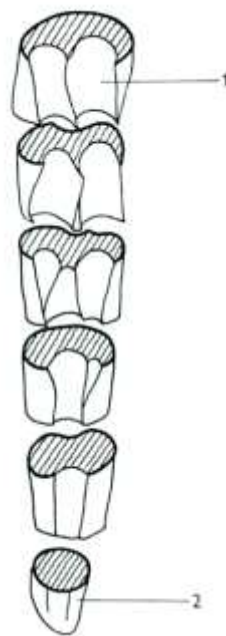
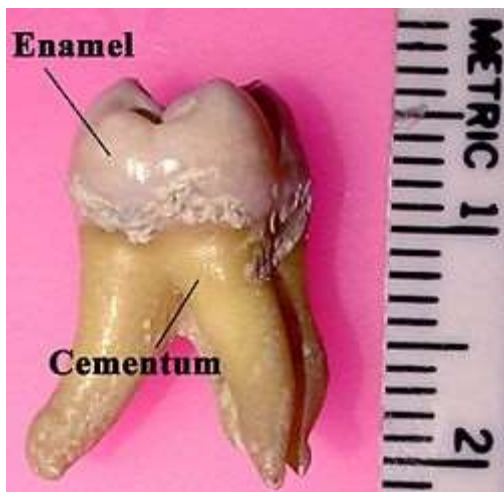

- Anatomická × klinická korunka
- Krček
- Kořen





# ZUB - ZUBNÍ SKLOVINA A CEMENT

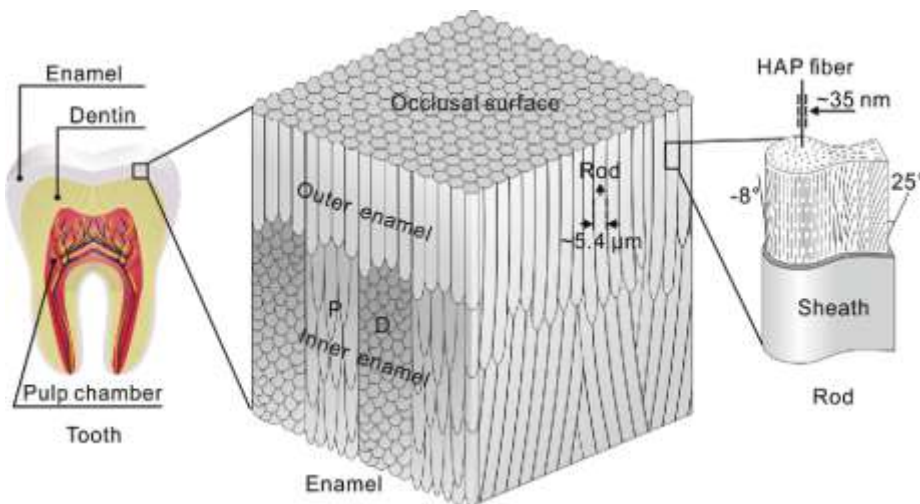


## Cement


- Cementoblasty
- Regeneruje
- 50% Ca-hydroxyapatit
- Kolagen I, III, XII, GAG, proteoglykany
- Sharpeyova vlákna - zubní alveolus

## Sklovina

- Ameloblasty
- Neregeneruje
- 96% Ca-hydroxyapatit, prizmata
- Enameliny, amelogeniny, ameloblastiny



# ZUB - ZUBNÍ SKLOVINA



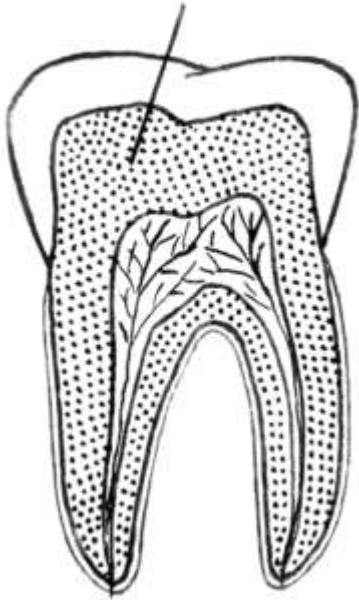
Research Paper

**Giant panda's tooth enamel: Structure, mechanical behavior and toughening mechanisms under indentation**

Z.Y. Weng<sup>a</sup>, Z.Q. Liu<sup>a,b\*</sup>, R.O. Ritchie<sup>b</sup>, D. Jiao<sup>a</sup>, D.S. Li<sup>a</sup>, H.L. Wu<sup>a</sup>, L.H. Deng<sup>a</sup>, Z.F. Zhang<sup>a,c</sup>

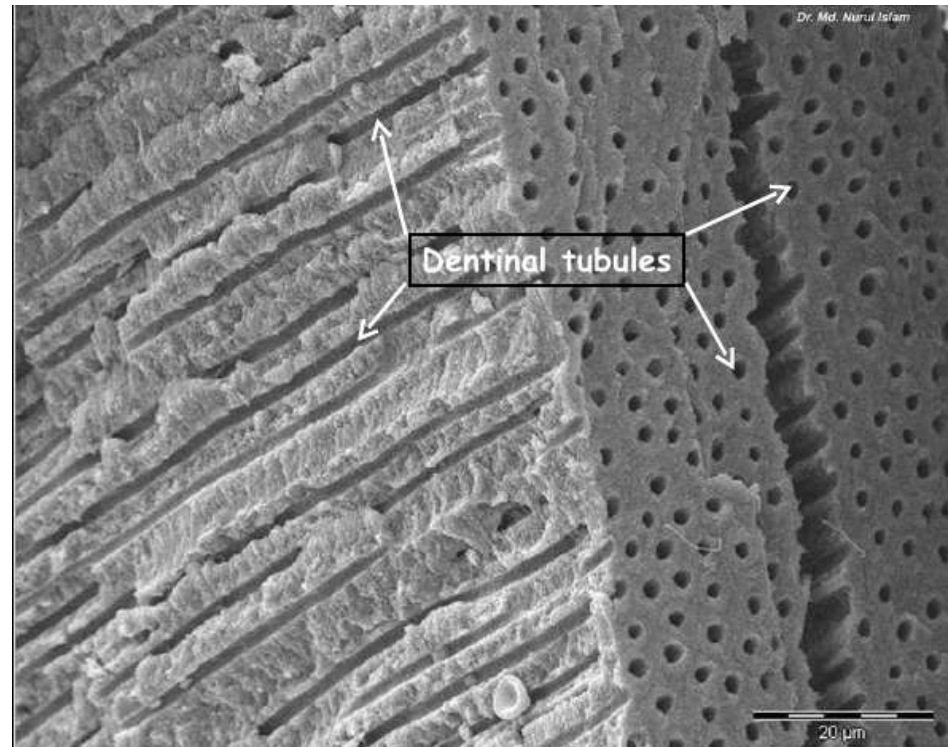
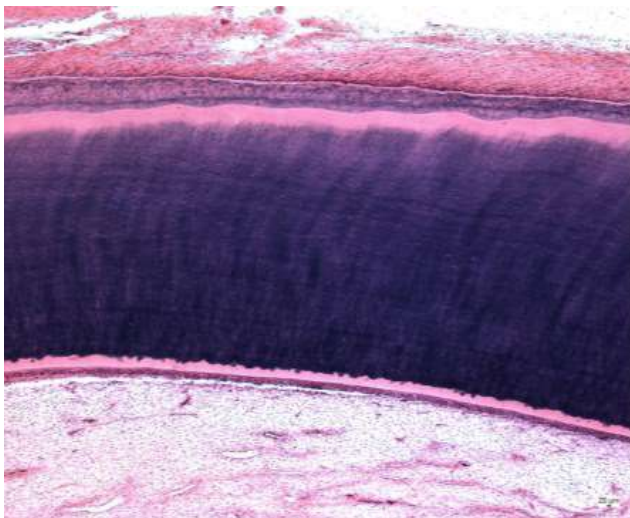


## DENTIN

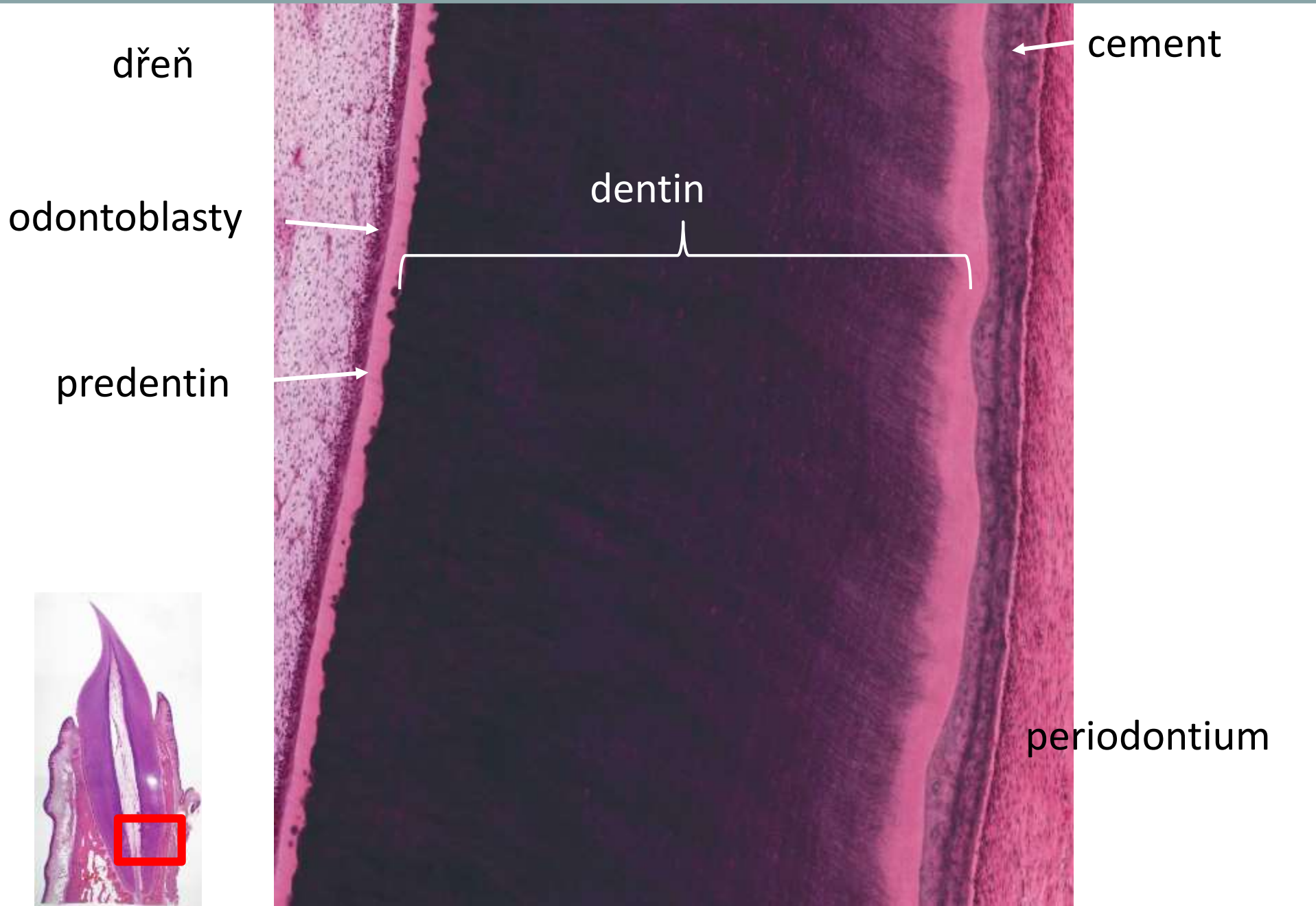


### Dentin

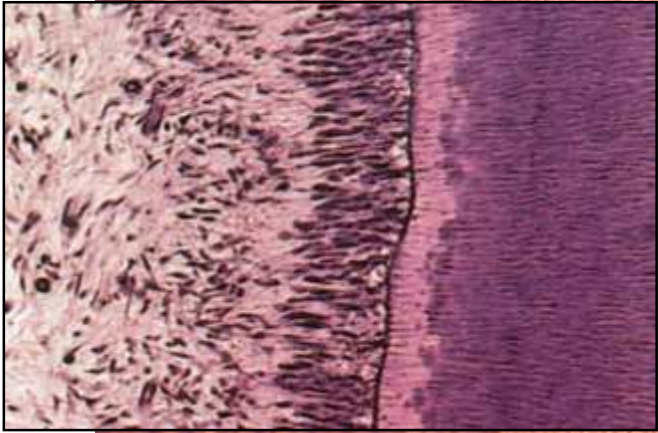
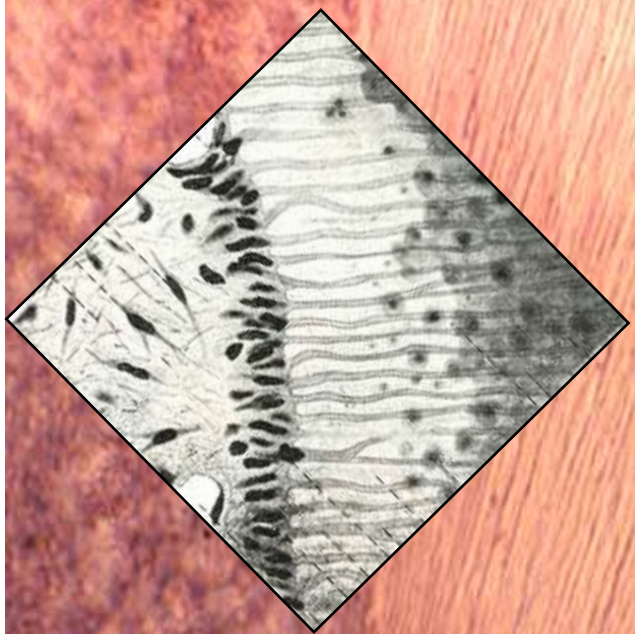
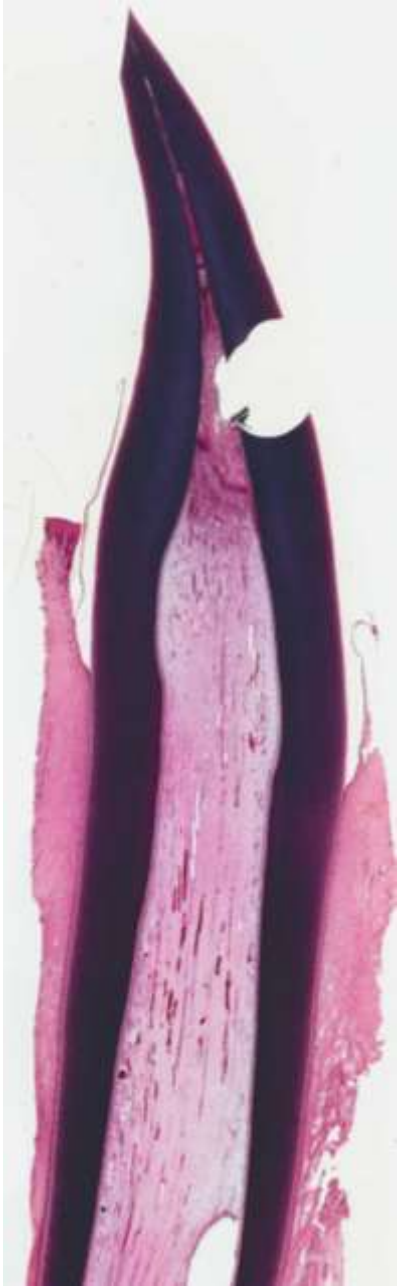
- Odontoblasty
- Regeneruje
- 70% Ca-hydroxyapatit
- Kolagen I, glykoproteiny, proteoglykany
- Výběžky odontoblastů - Tomesova vlákna
- Owenovy linie
- Nervová vlákna



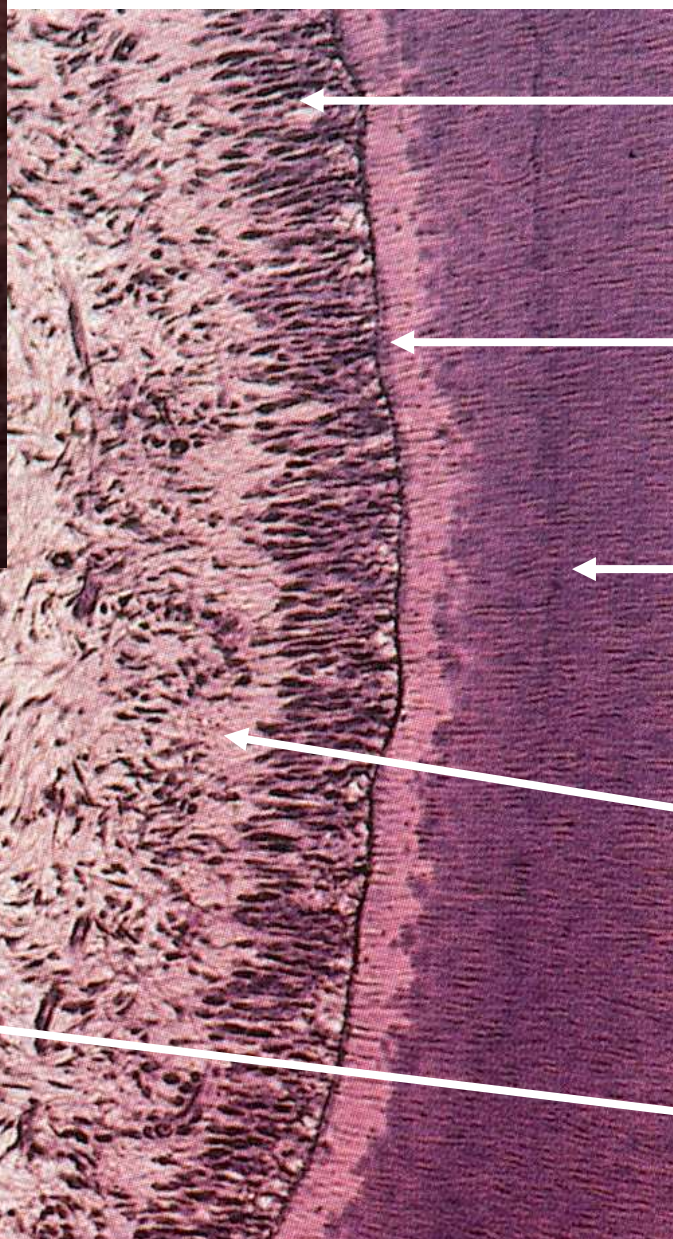

# ZUB - DENTIN



# ZUB - ODONTOBLASTY



# ZUB - ODONTOBLASTY



odontoblasts

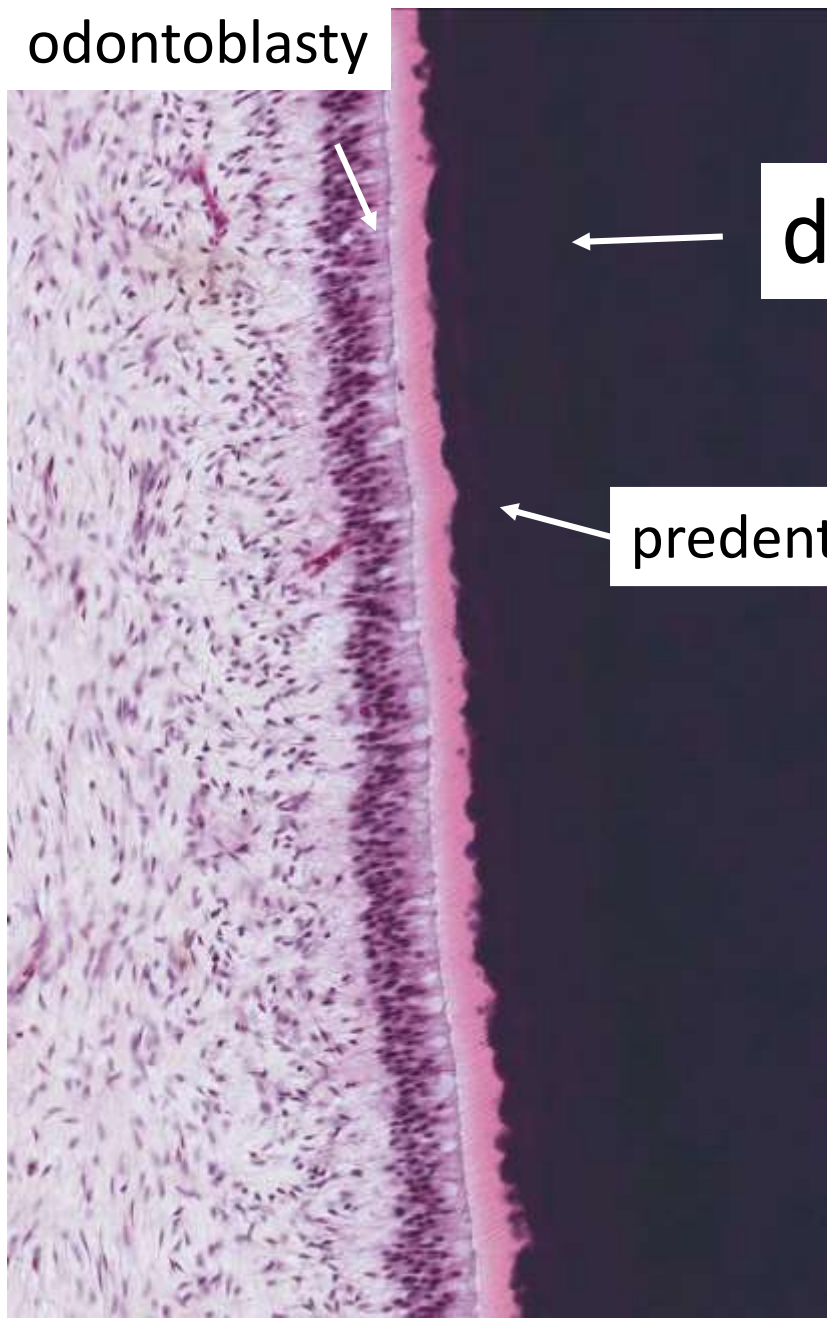
predentin

dentin

subodontoblastic zone

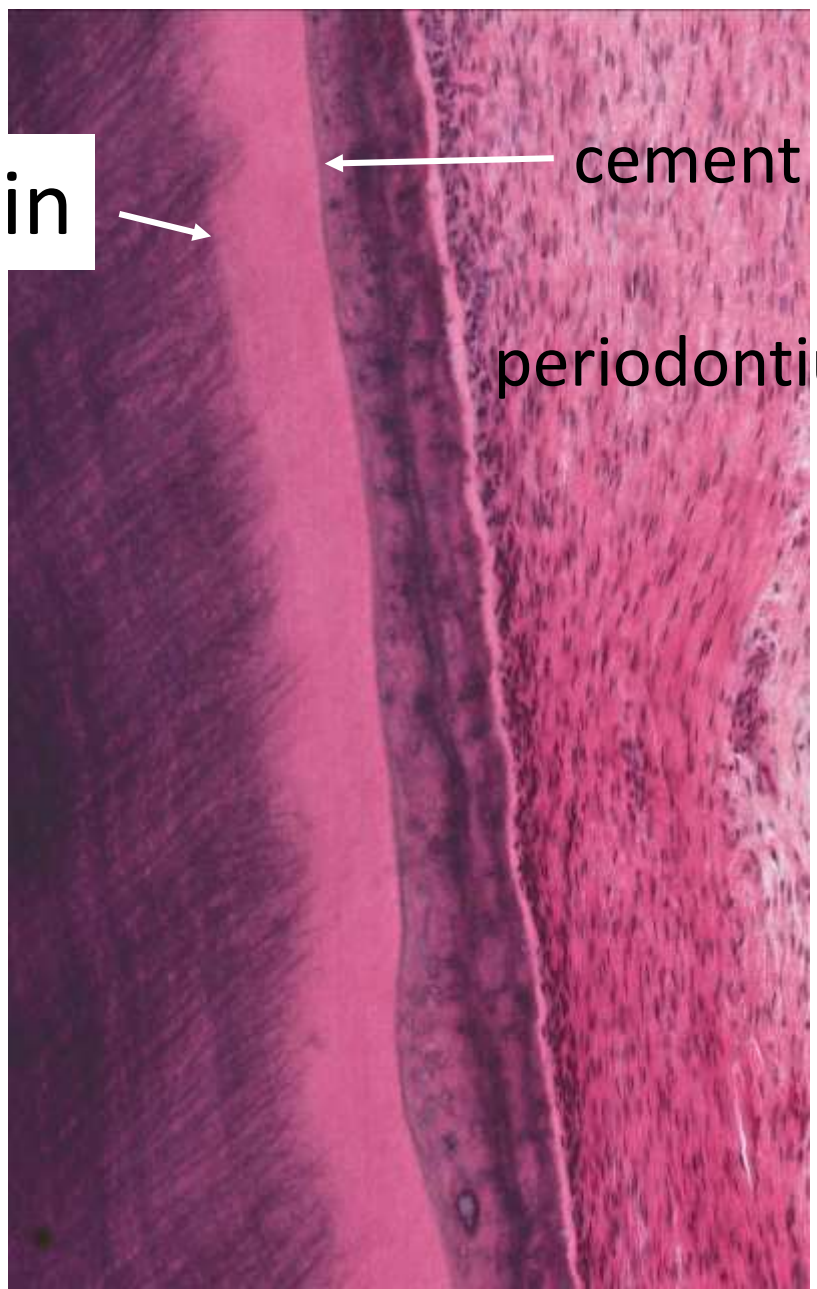
pulp

odontoblasty



dentin

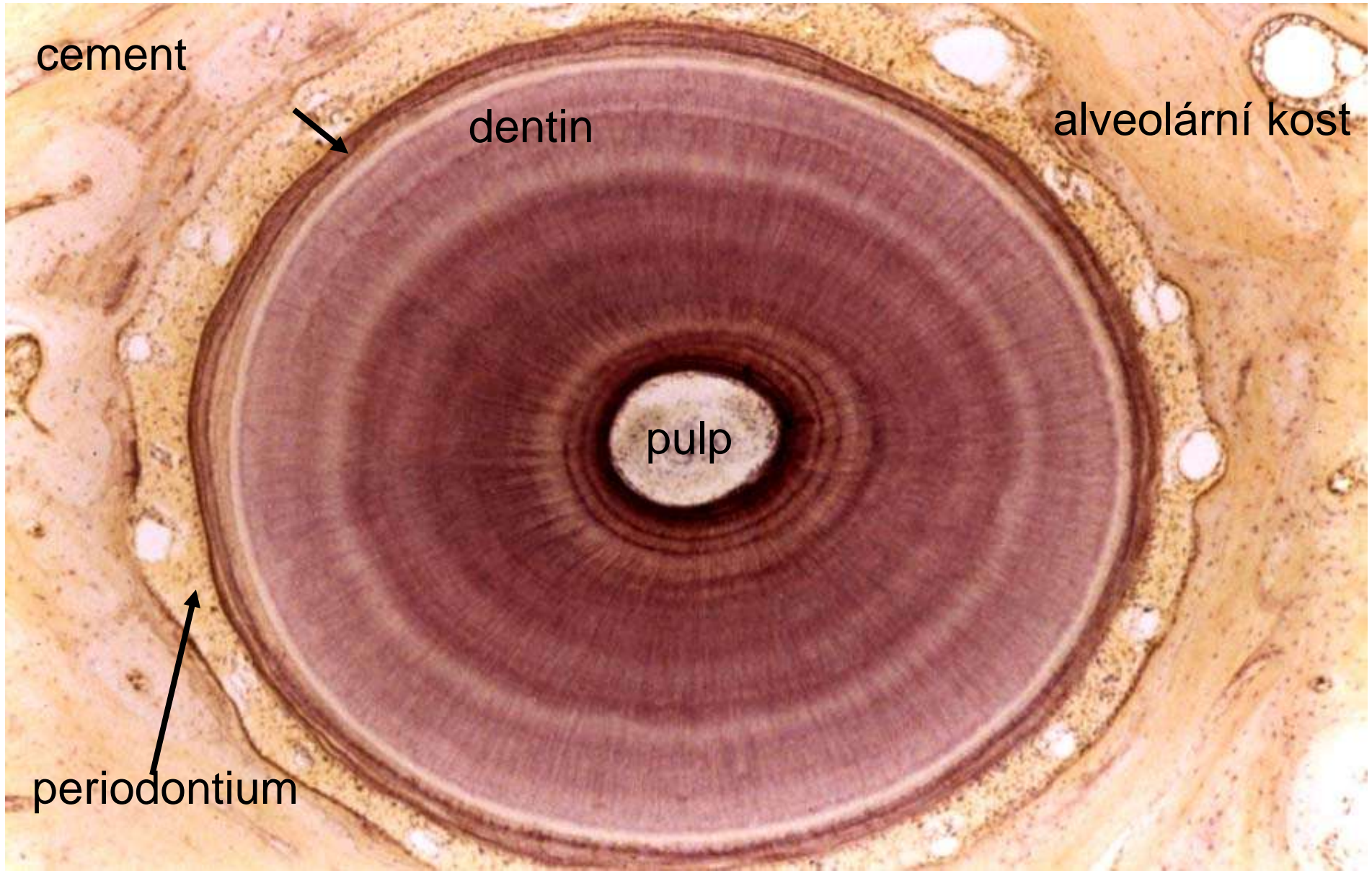
predentin



cement

periodontium

ZUB



cement



dentin

alveolární kost

pulp

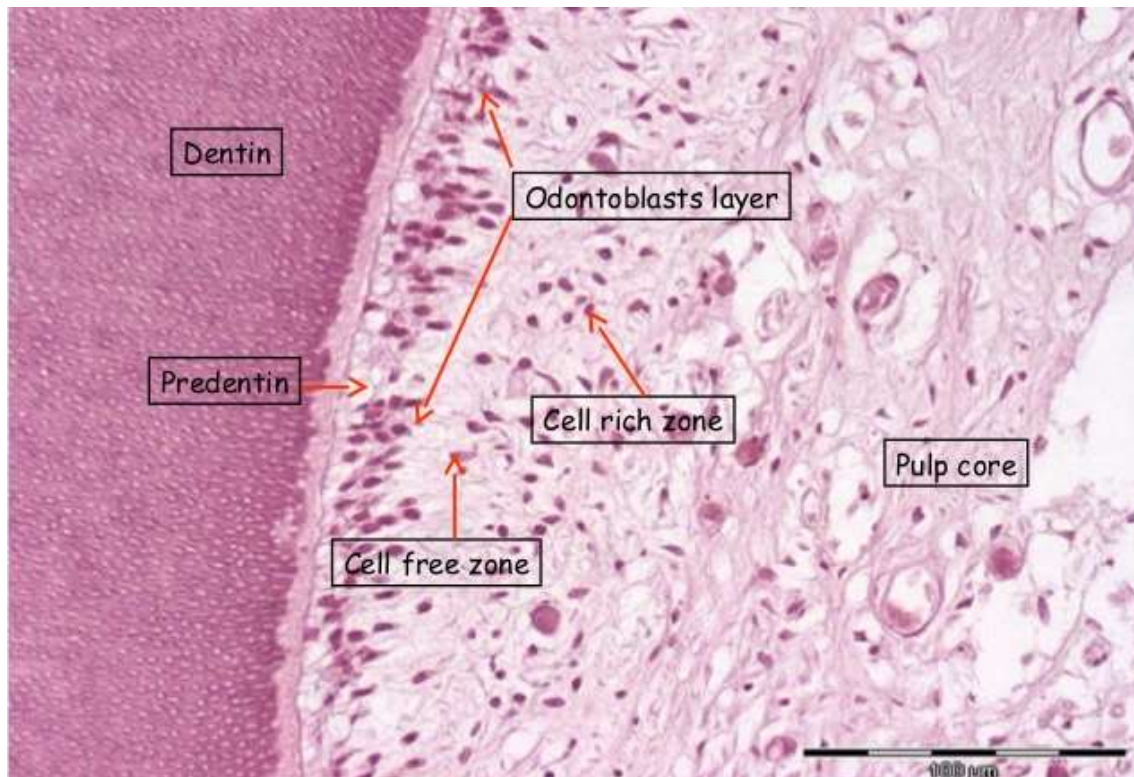
periodontium





# ZUB - DŘEŇ (PULPA)

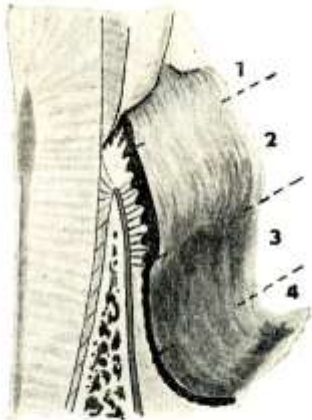
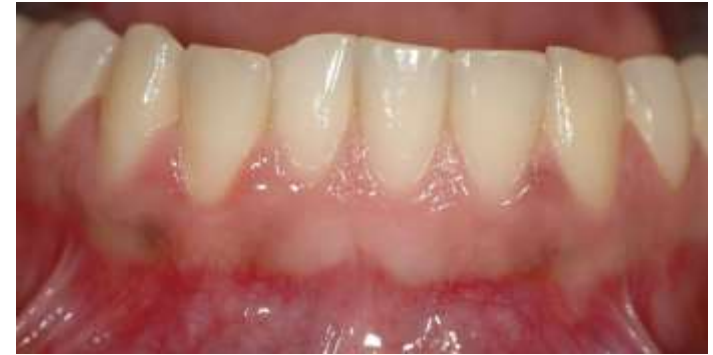- rosolovité vazivo podobné embryonálnímu mesenchymu
- bohatá vaskularizace a inervace
- korunková dřeň a kořenový kanálek
- foramen apicale - periodontium
- odontoblasty
- nociceptivní nervová vlákna (plexus Raschkowi)



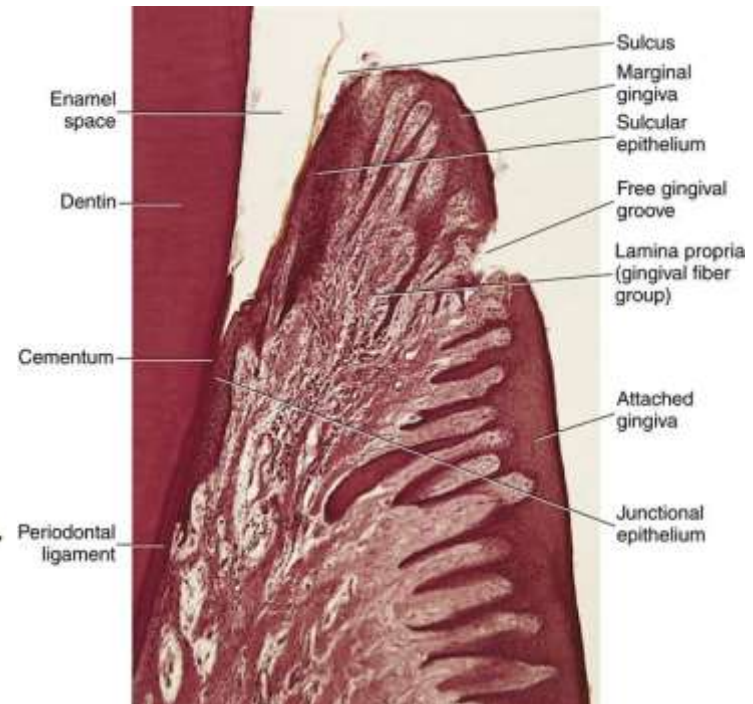
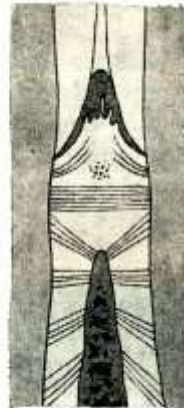<https://www.slideshare.net/hesham63/pulp-15597098>

## Dáseň

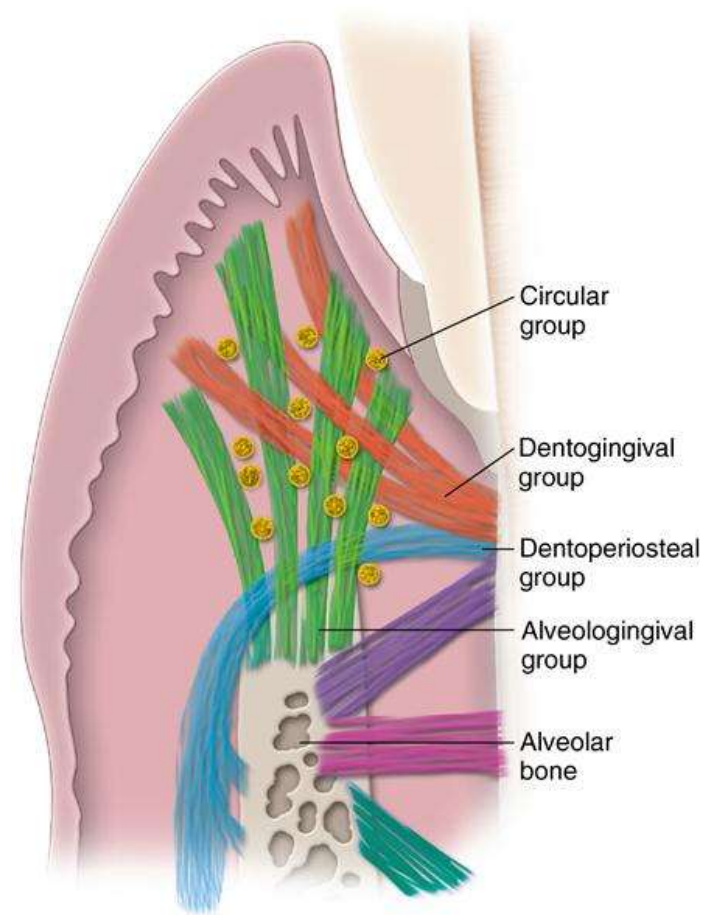
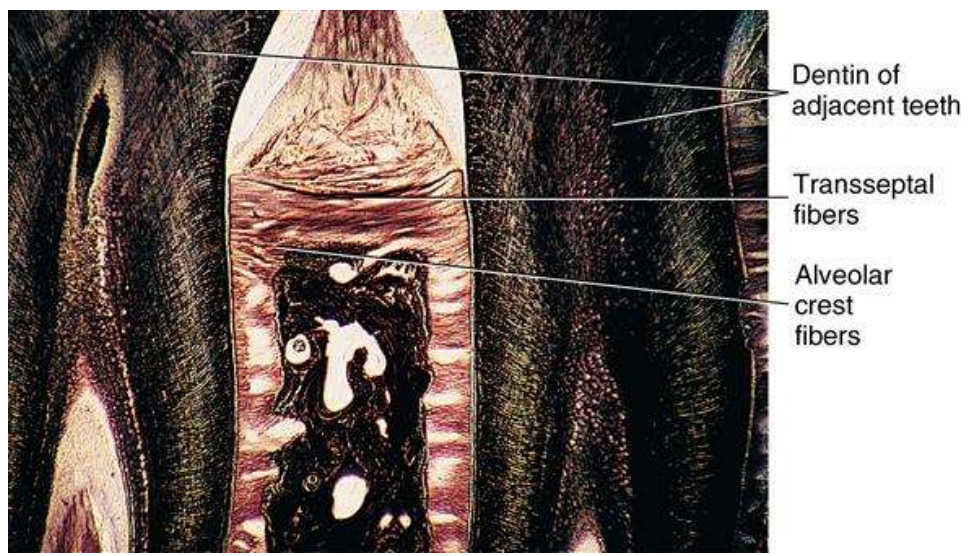
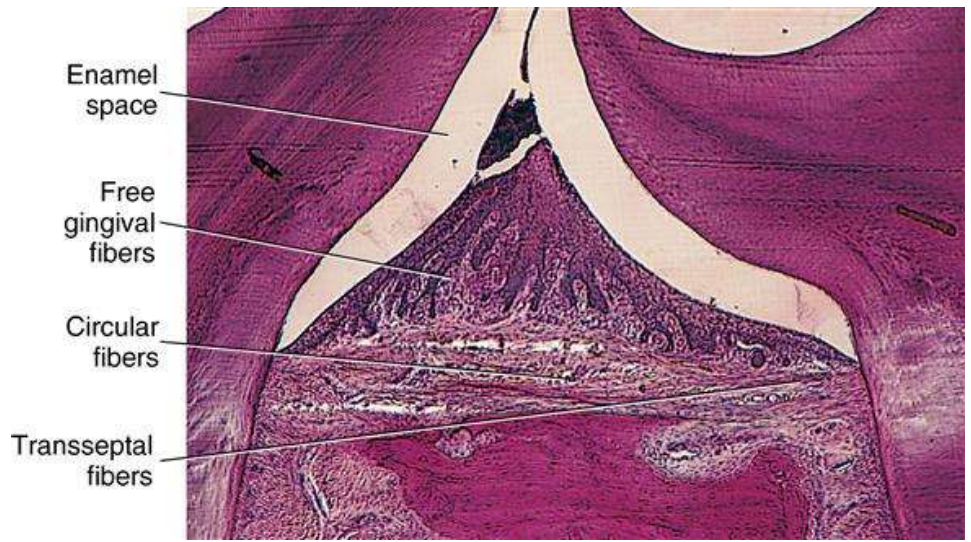
- volná (marginální, g. libera)
  - připojená (g. affixa)
  - paramarginální rýha (zevní gingivální žlábek)
  - sulcus gingivalis
  - gingivodentální uzávěr
- 
- vrstevnatý dlaždicový epitel
  - lamina propria mucosae – husté kolagenní vazivo



Obr. 8. Schéma gingivy. 1 — volná gingiva, 2 — připojená gingiva, 3 — alveolární sliznice, 4 — vestibulární sliznice

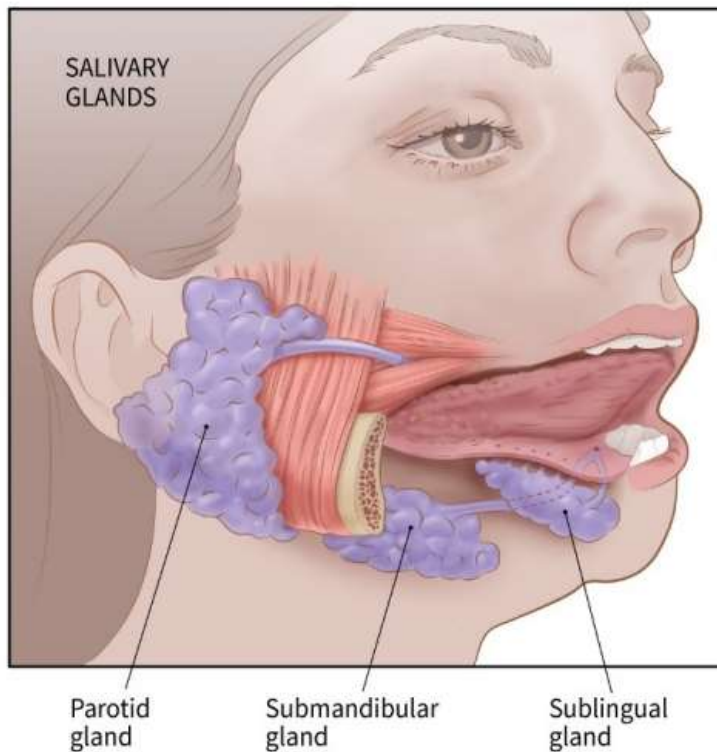


# ZUB – PERIODONTIUM A GINGIVA



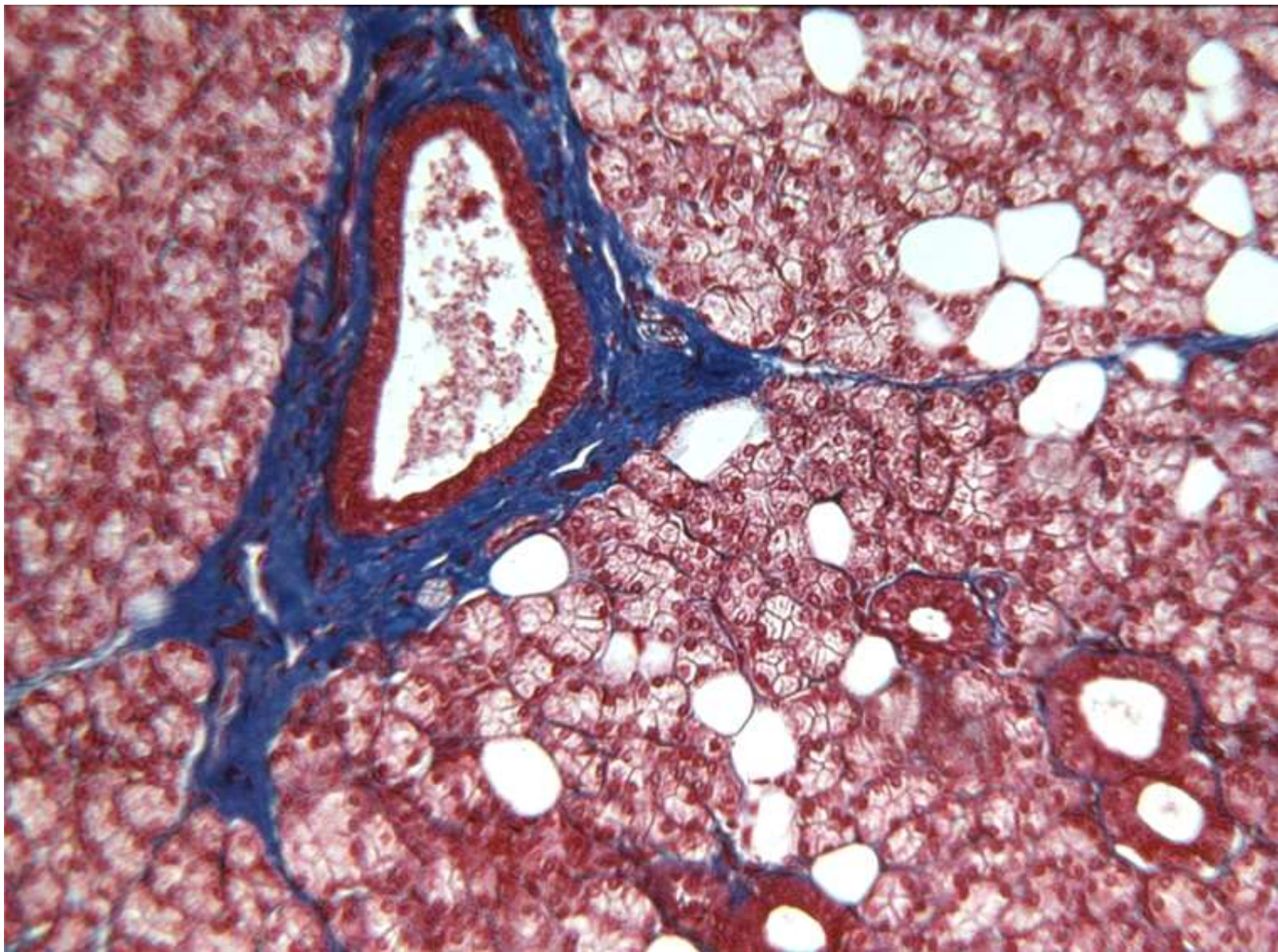
# SLINNÉ ŽLÁZY

- malé (gll. labiales, buccales, retromolares, palatinae, gll. lingualis anterior - Blandini, gll. Ebneri, gll. Weberi)
- velké (gl. parotis, gl. submandibularis, gl. sublingualis)

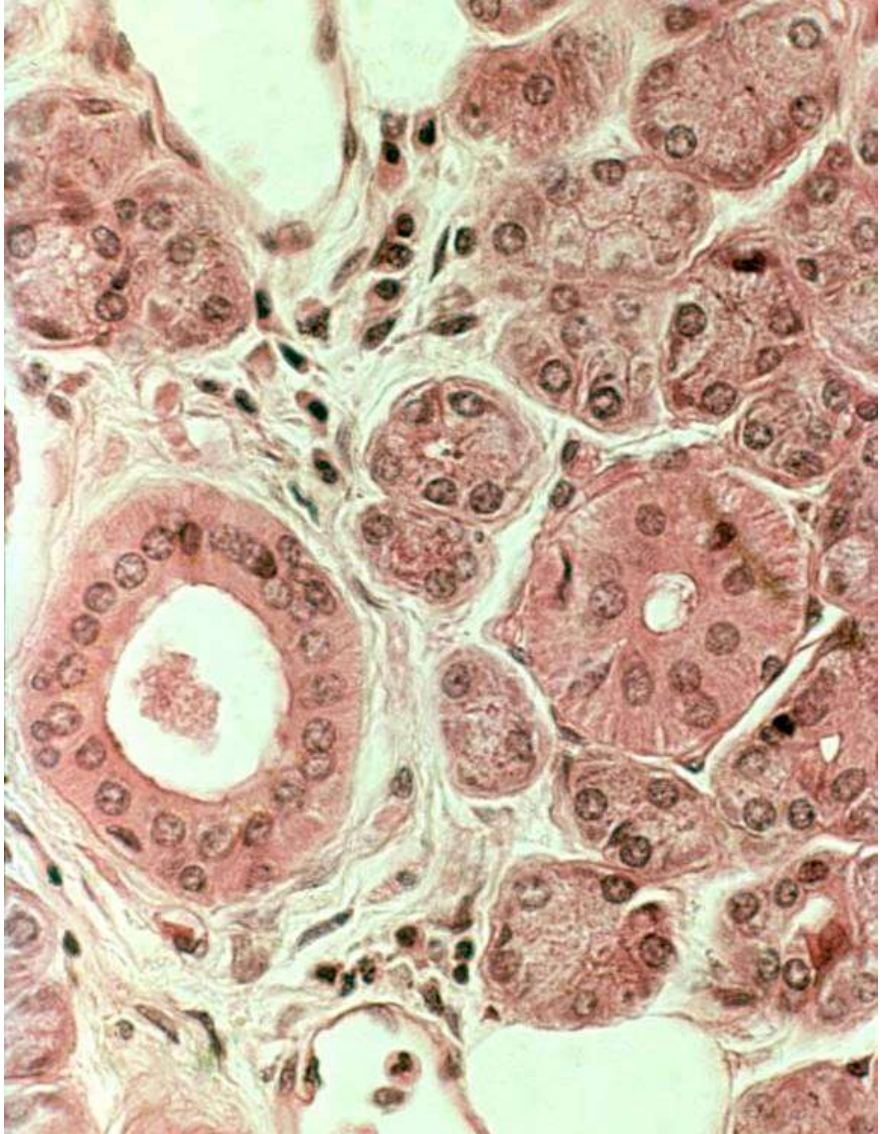
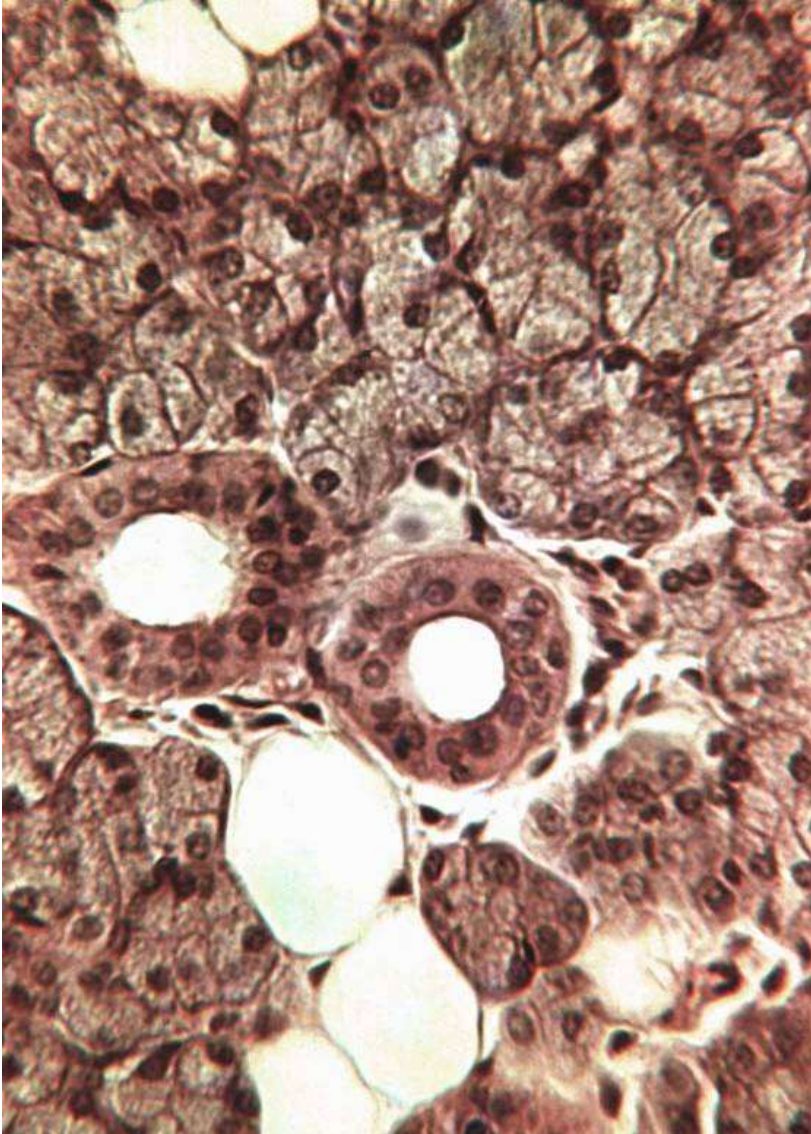


viz GIT 3

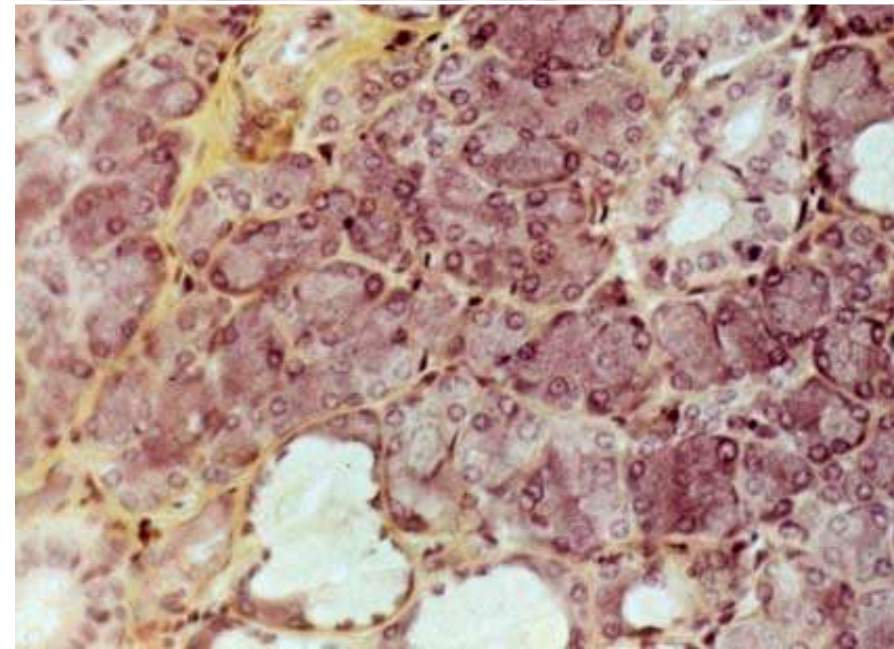
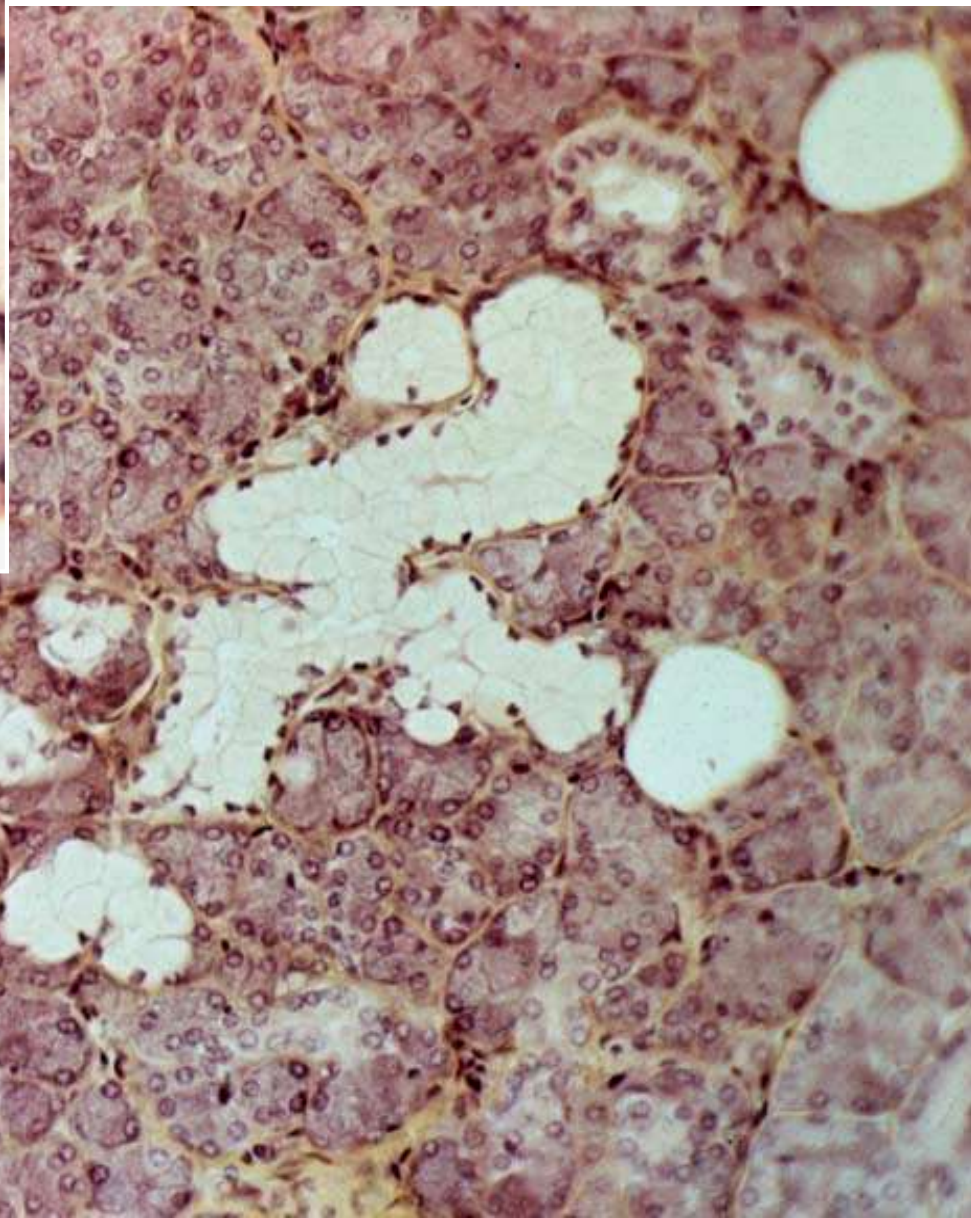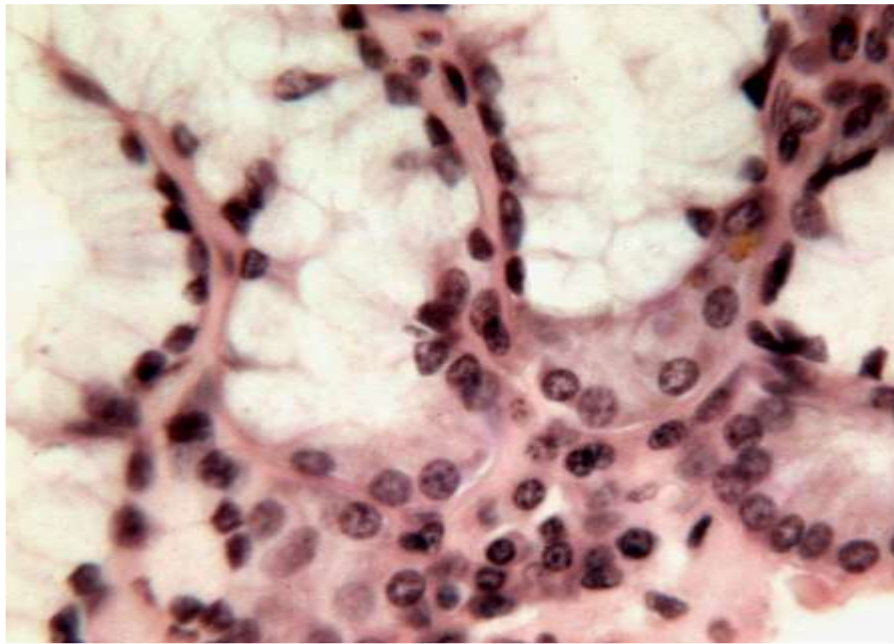
# SLINNÉ ŽLÁZY – GL. PAROTIS



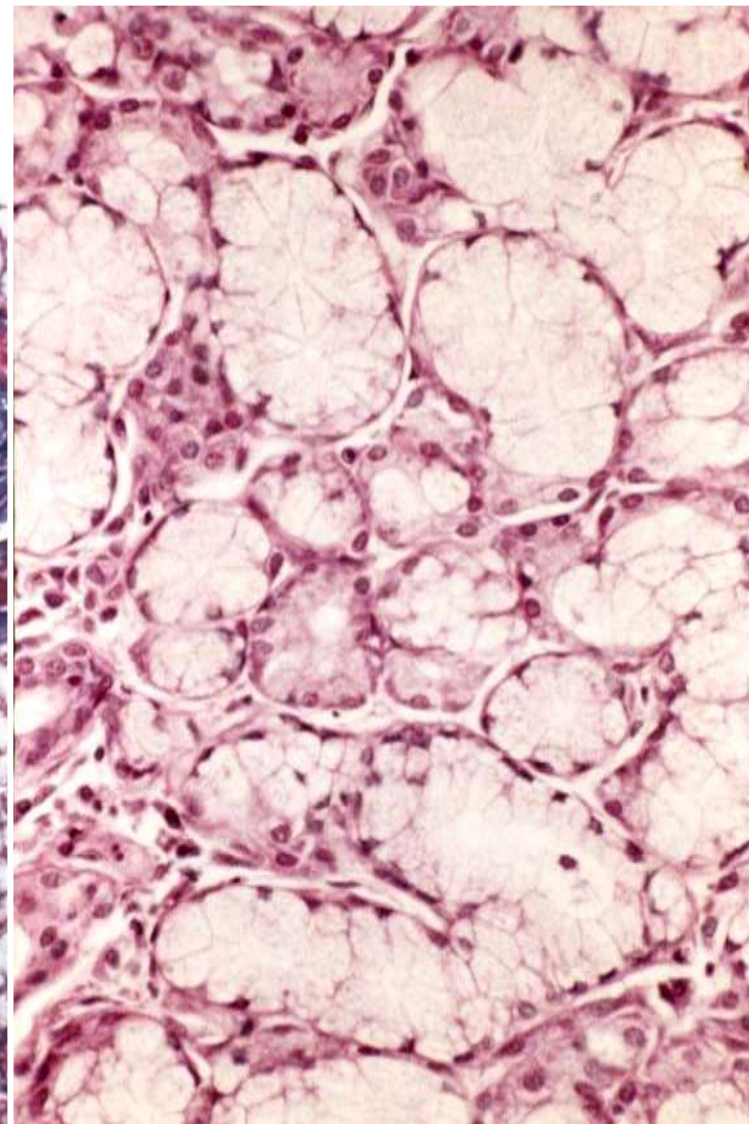
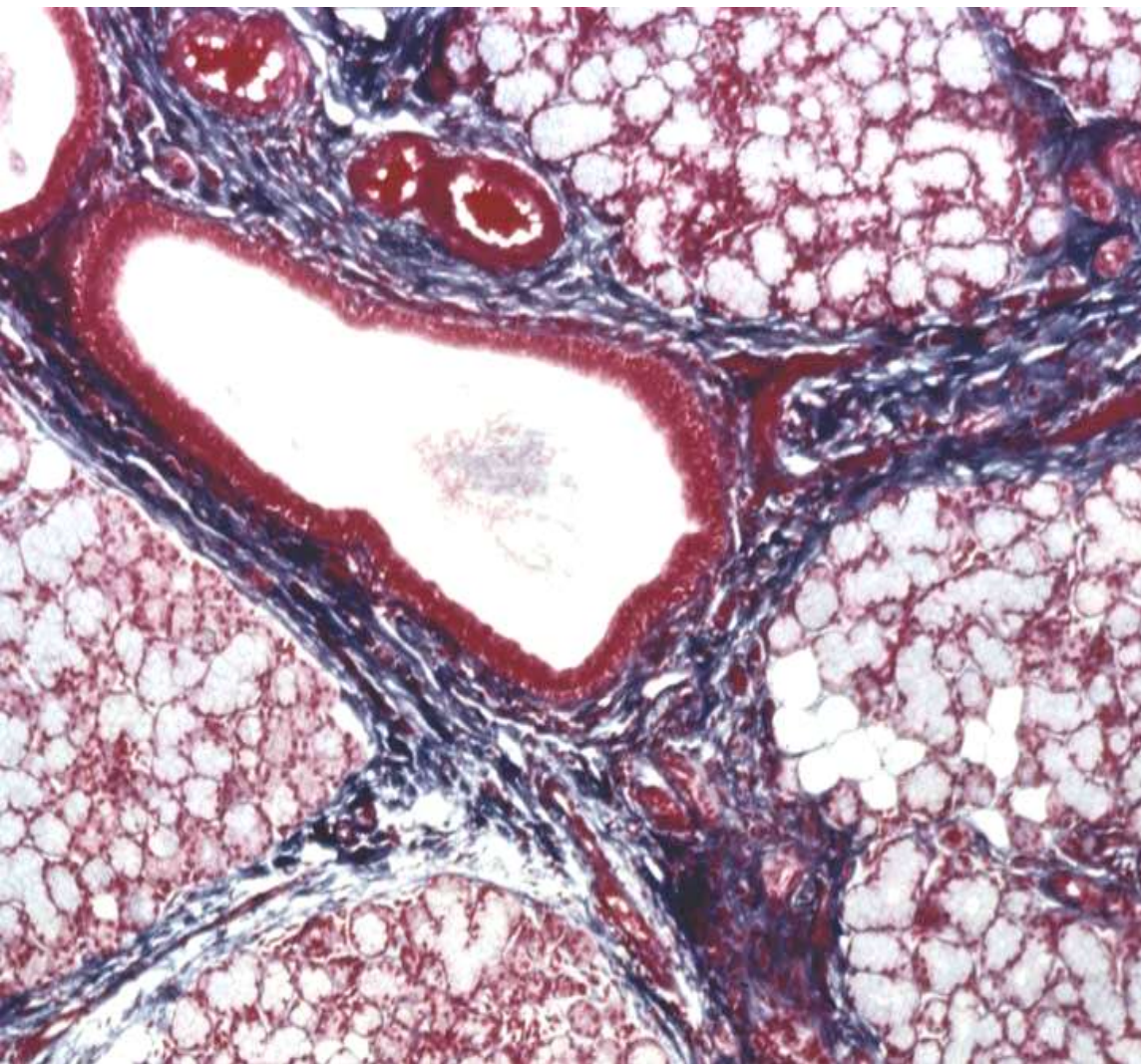
# SLINNÉ ŽLÁZY – GL. PAROTIS



# SLINNÉ ŽLÁZY – GL. SUBMANDIBULARIS

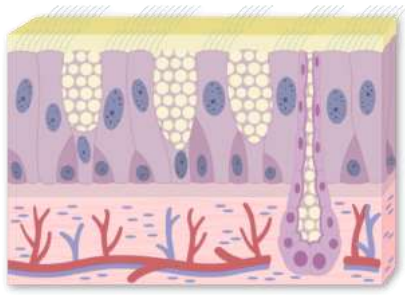
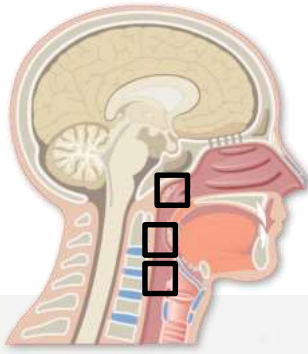


# SLINNÉ ŽLÁZY – GL. SUBLINGUALIS

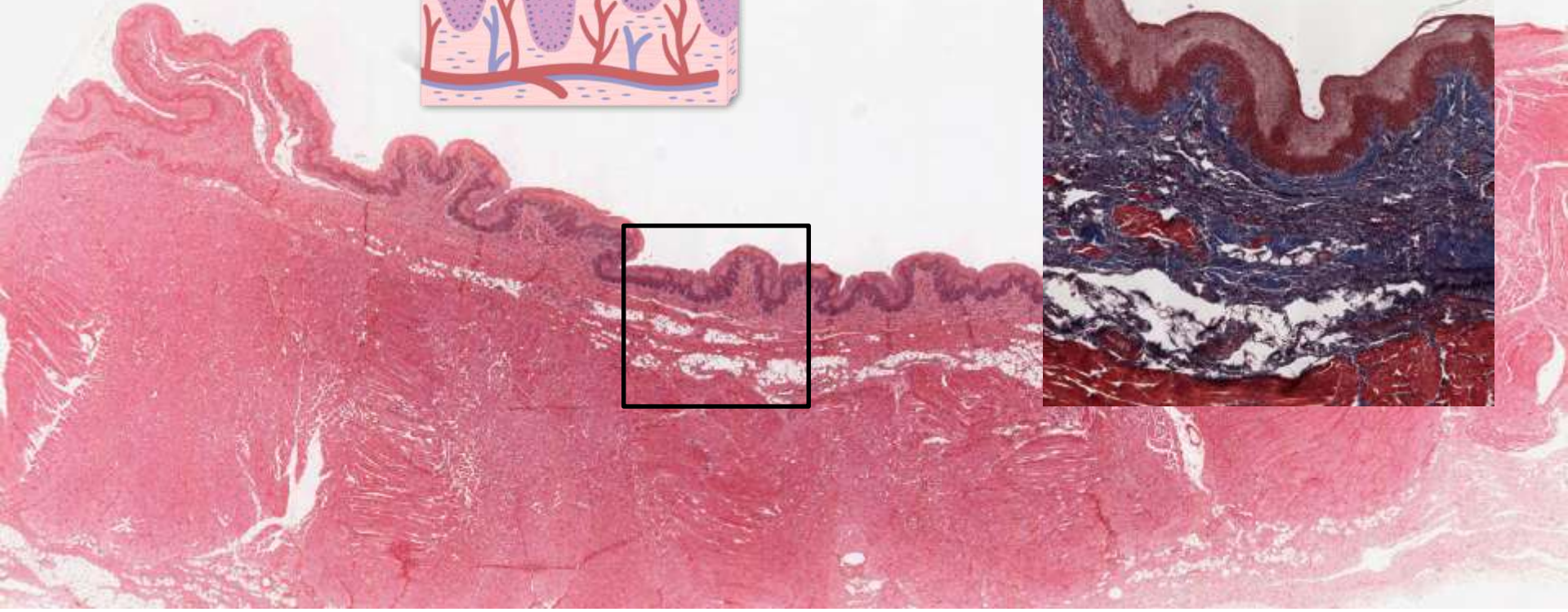




# PHARYNX



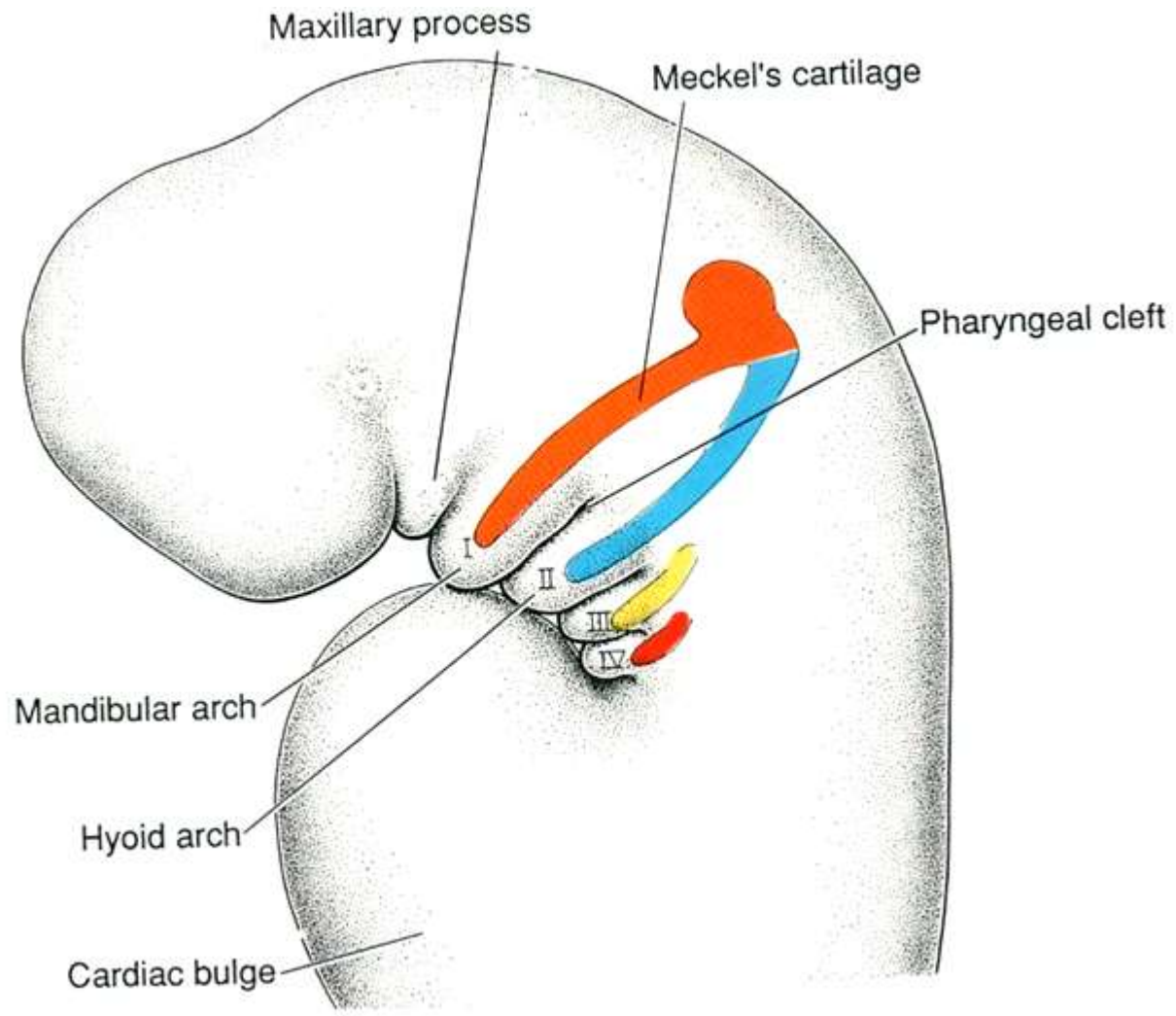
- nasopharynx
- oropharynx
- laryngopharynx



Coffee  
BREAK



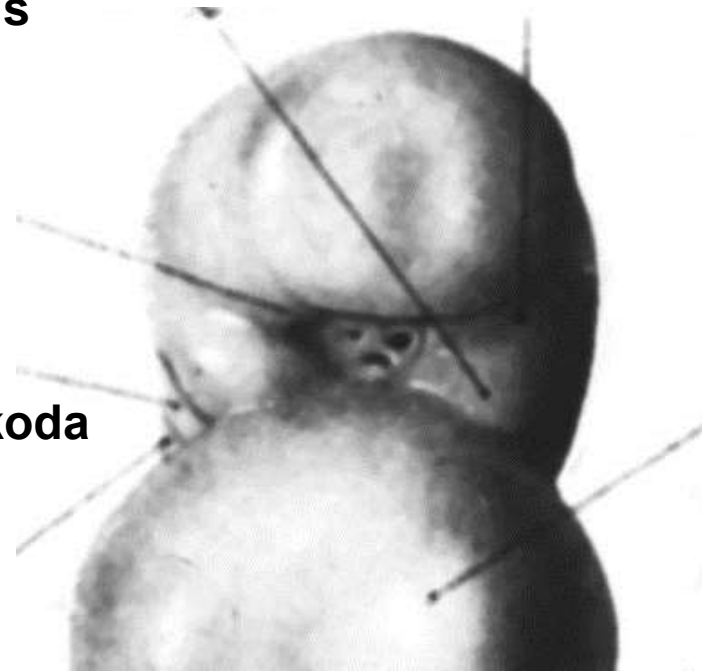
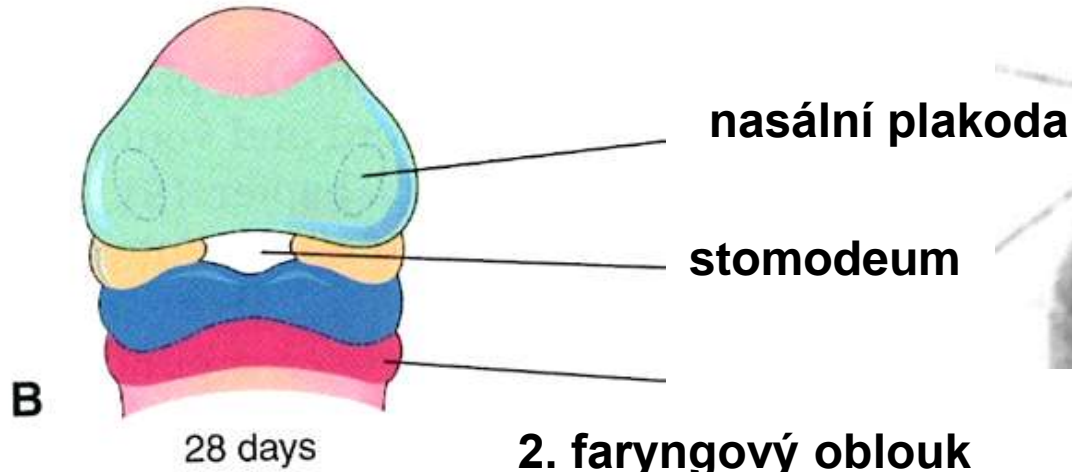
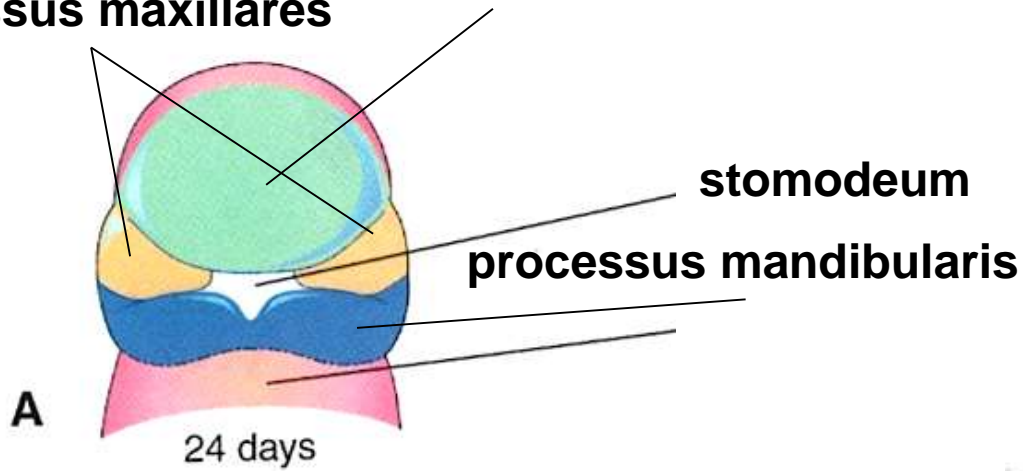
# VÝVOJ OBLIČEJE



# VÝVOJ OBLIČEJE

processus frontonasalis

processus maxillares

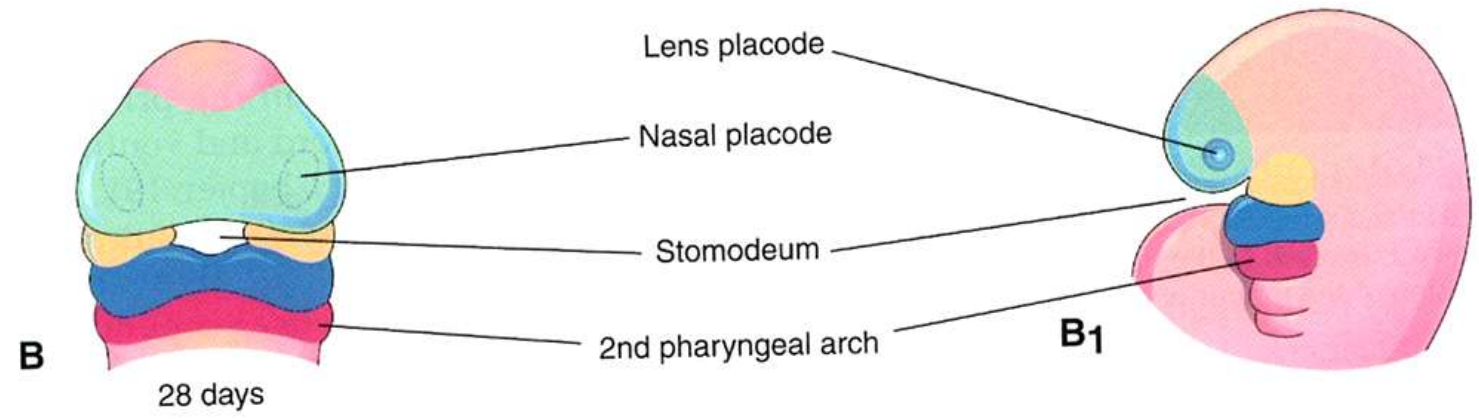
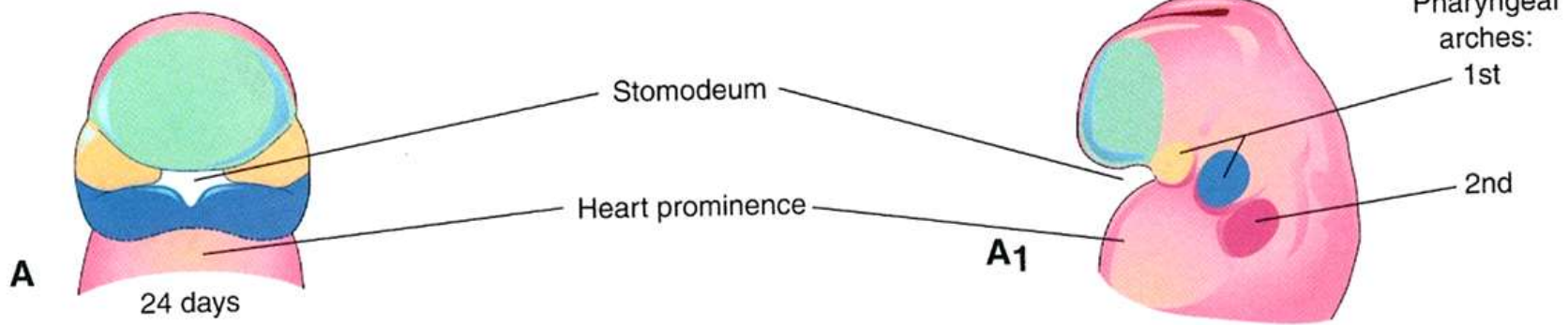


# VÝVOJ OBLIČEJE

Frontonasal prominence

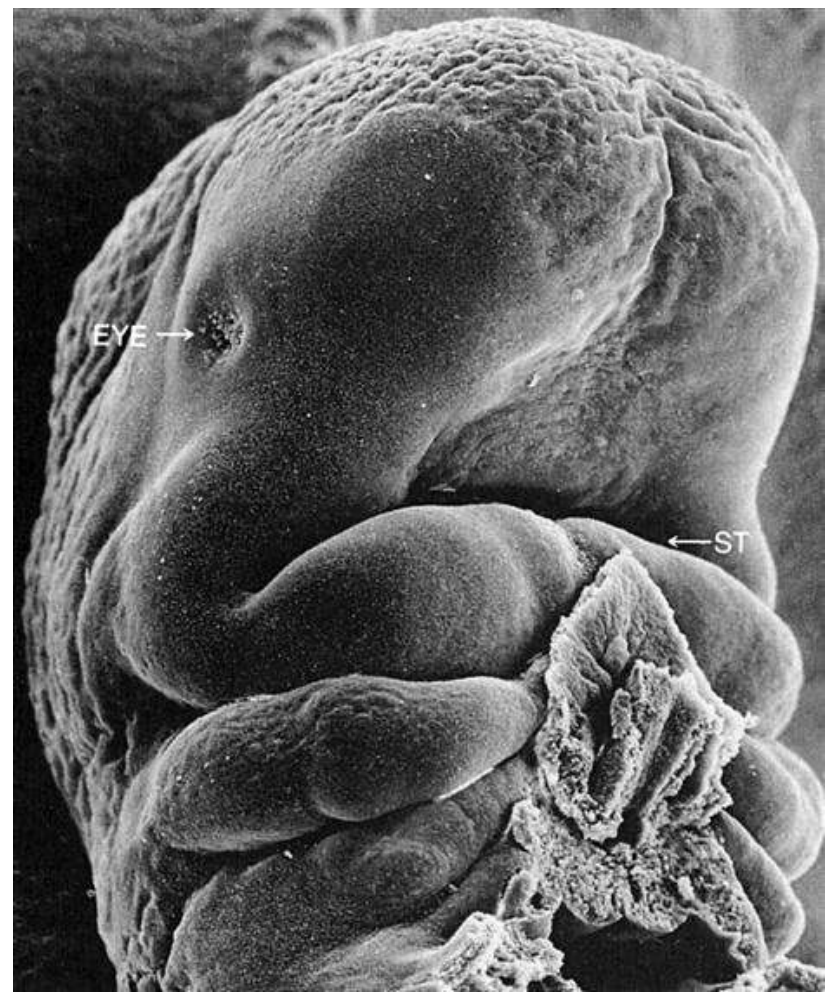
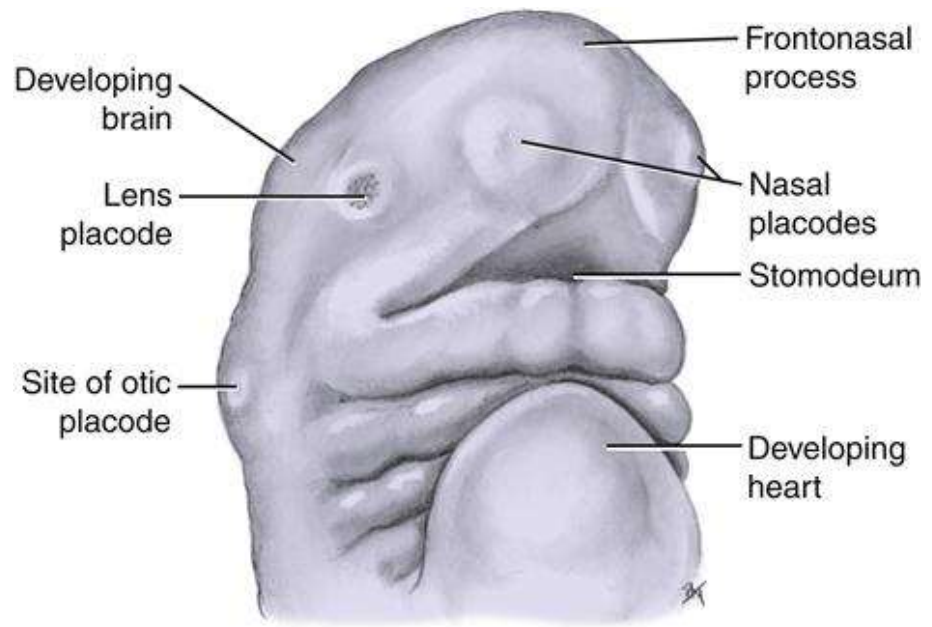
Maxillary prominence

Mandibular prominence

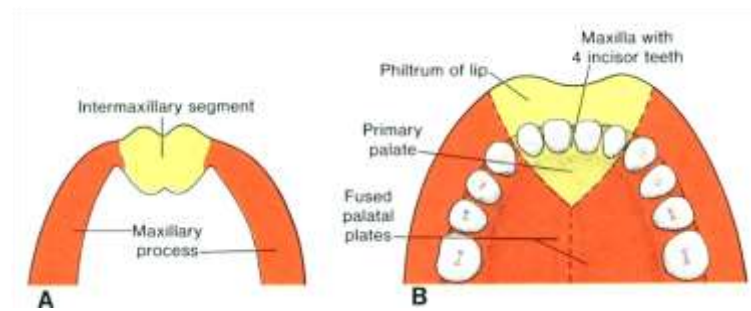
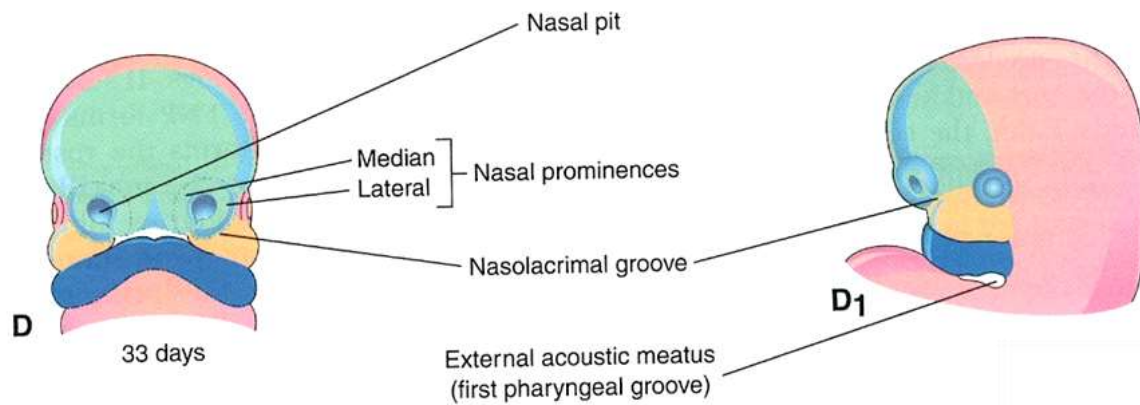
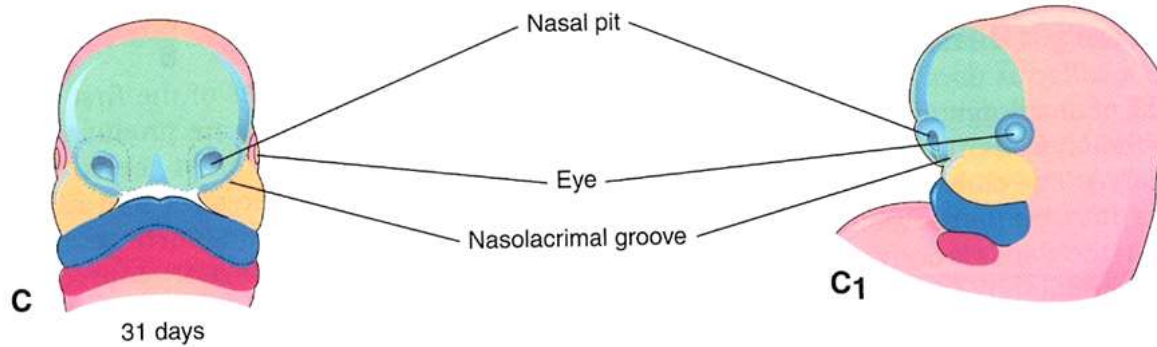


# VÝVOJ OBLIČEJE

4th week

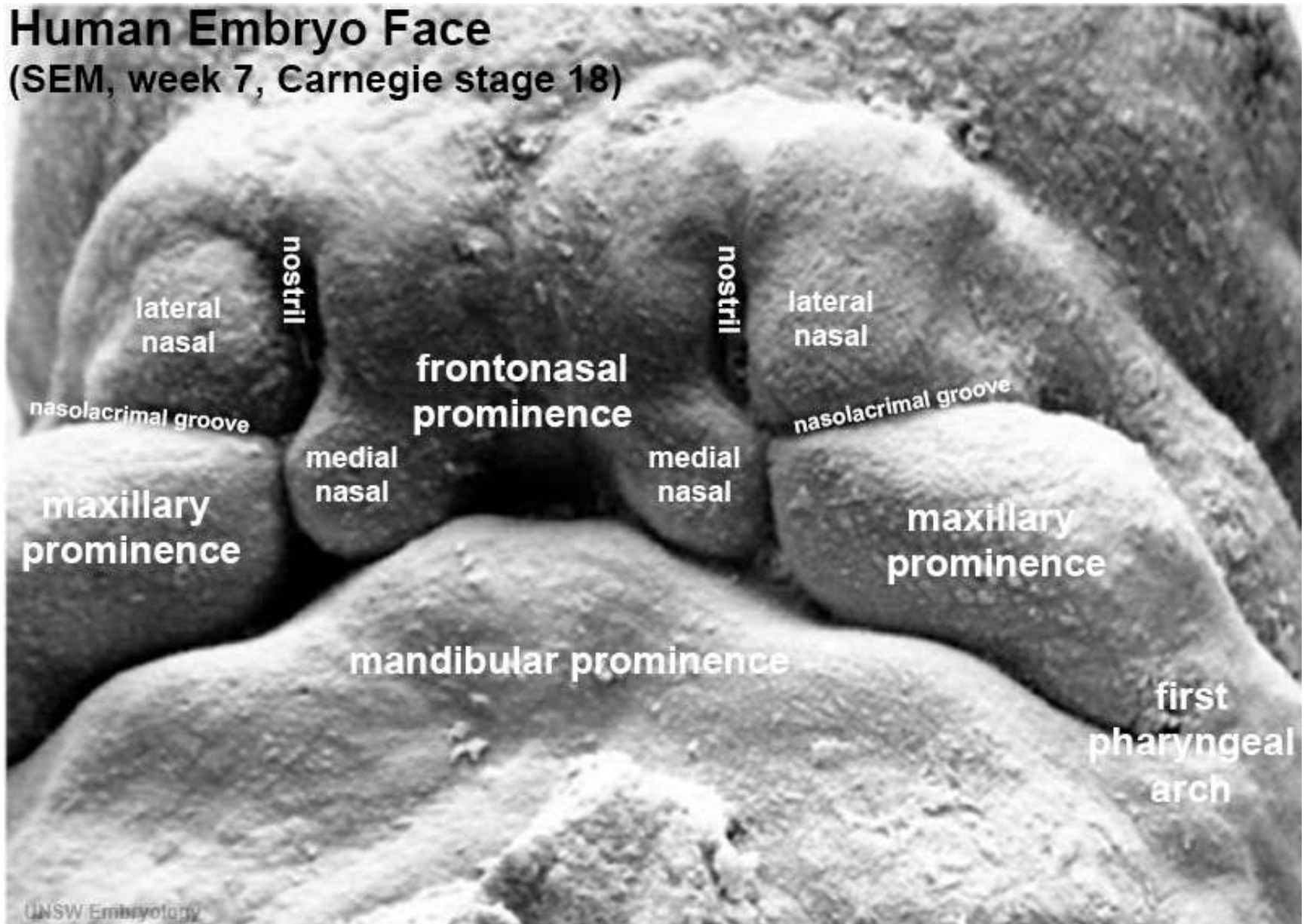


# VÝVOJ OBLIČEJE



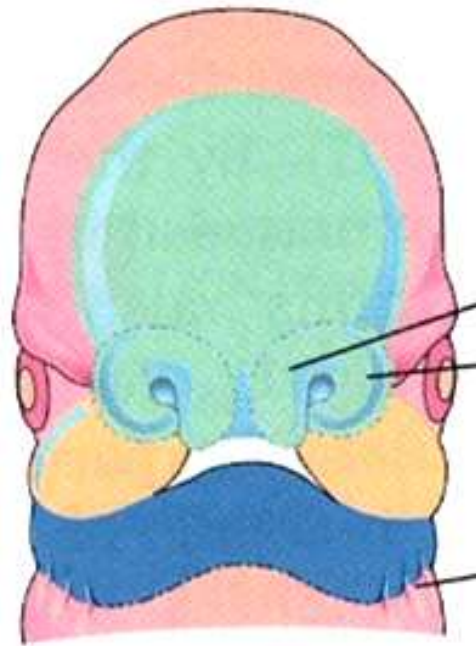
- čichové jamky jsou ohraničeny vally – **mediální a laterální nosní vally**
- zbytek čelního valu vytvoří **area triangularis** (základ pro hřbet a hrot nosu)
- mediální nosní vally spolu srostou a vsouvají se mezi maxilární výběžky jako **intermaxilární segment** (dávají vznik střední části horního rtu, části horní čelisti v oblasti řezáků a části patra – primární patro)

# Human Embryo Face (SEM, week 7, Carnegie stage 18)

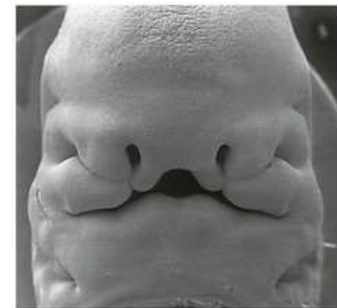
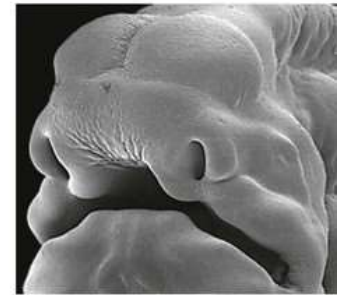
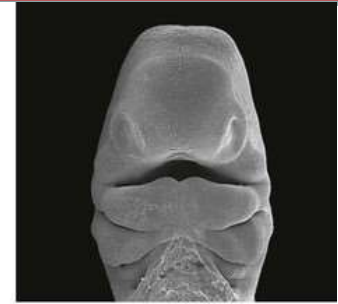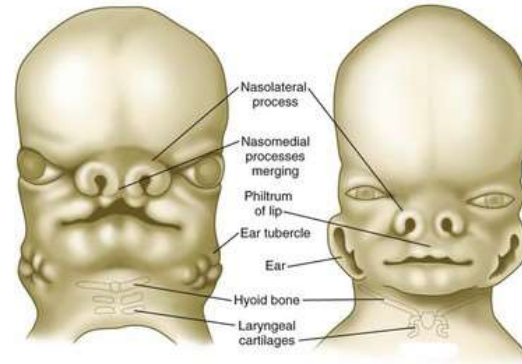
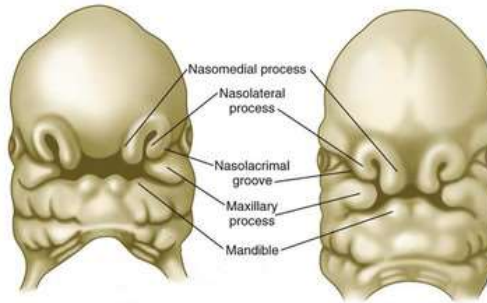
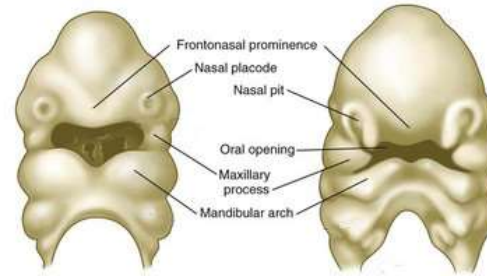




# VÝVOJ OBLIČEJE

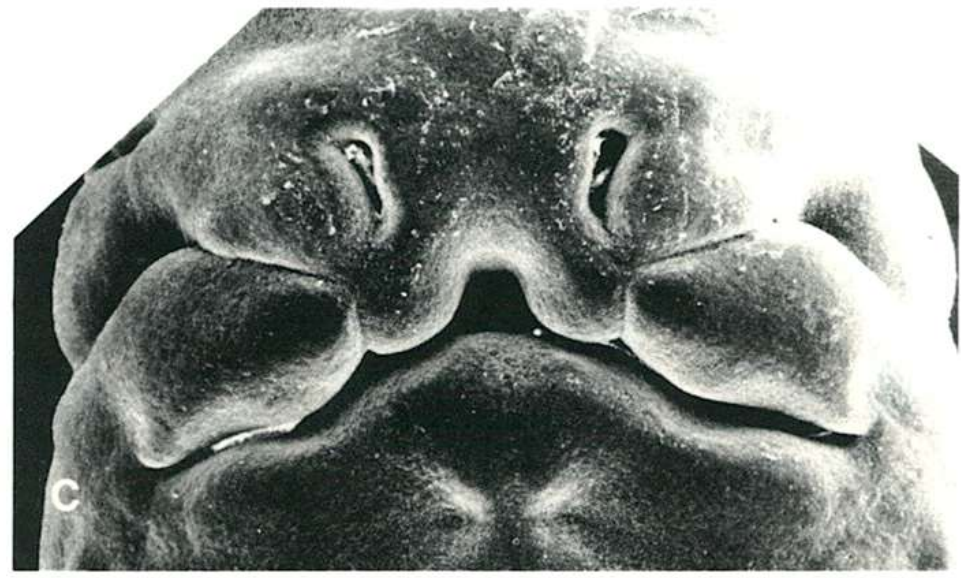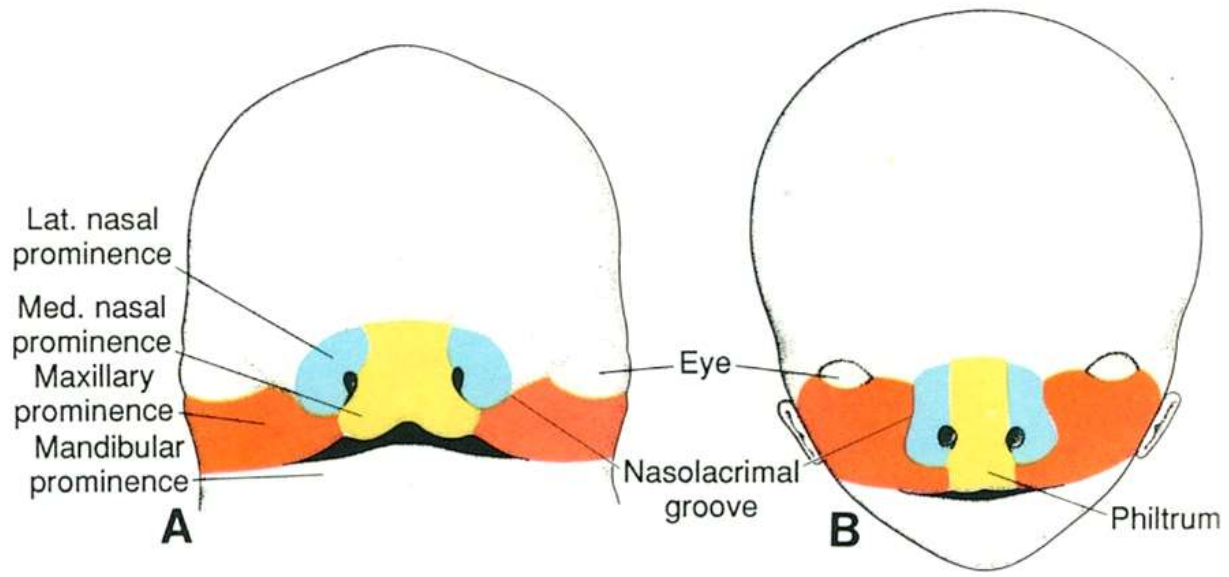


35 days



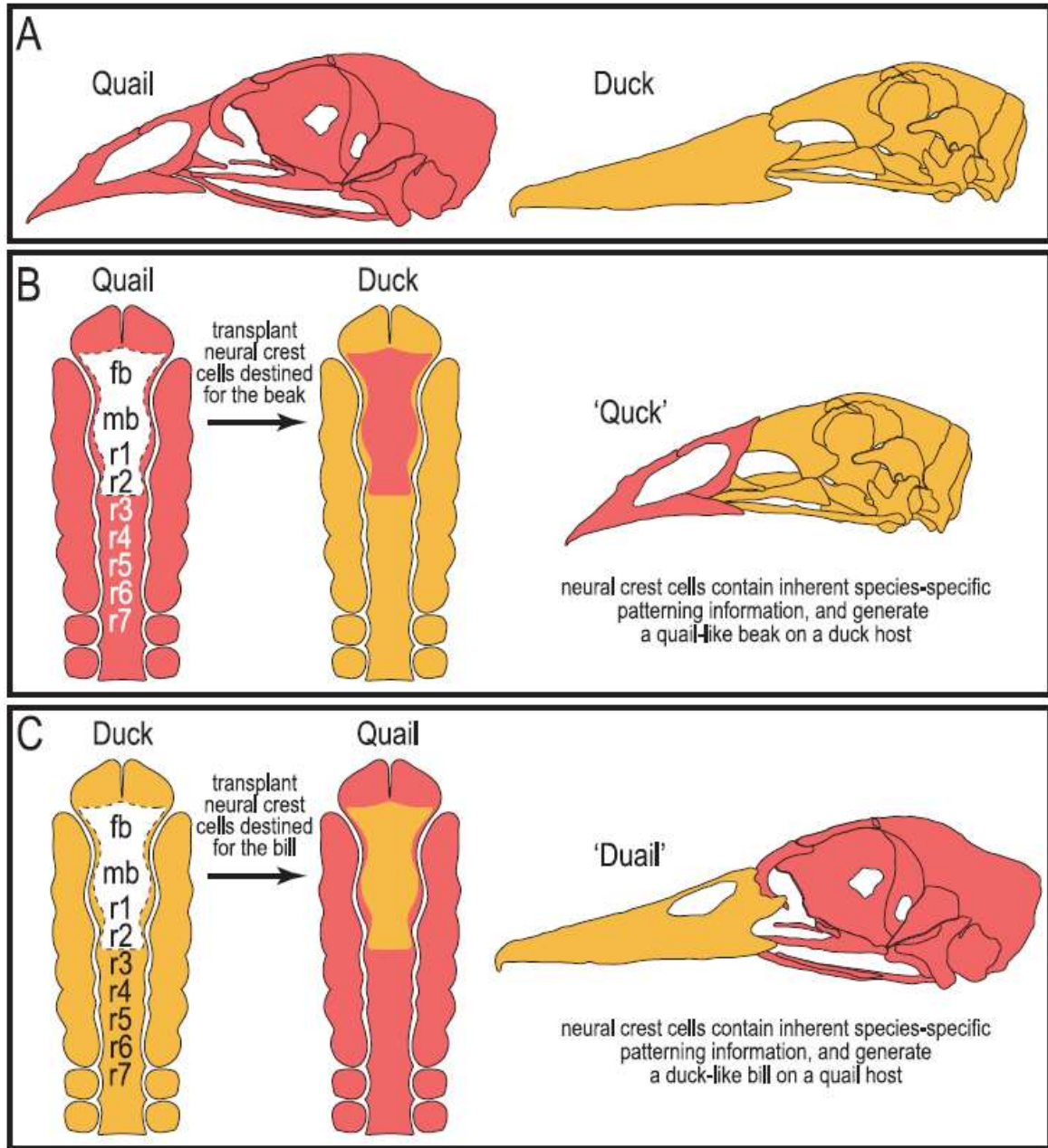
- **maxilární výběžky** srostou
  1. s **intermaxilárním segmentem** (vytvoření horní čelisti a rtu)
  2. s **laterálními nosními valy** – (zbytek horní čelisti a křídla nosu)
- laterální nosní valy jsou od maxilárních zpočátku odděleny rýhou – sulcus nasolacrimalis, která se uzavře a vytvoří slzný kanálek

# VÝVOJ OBLIČEJE


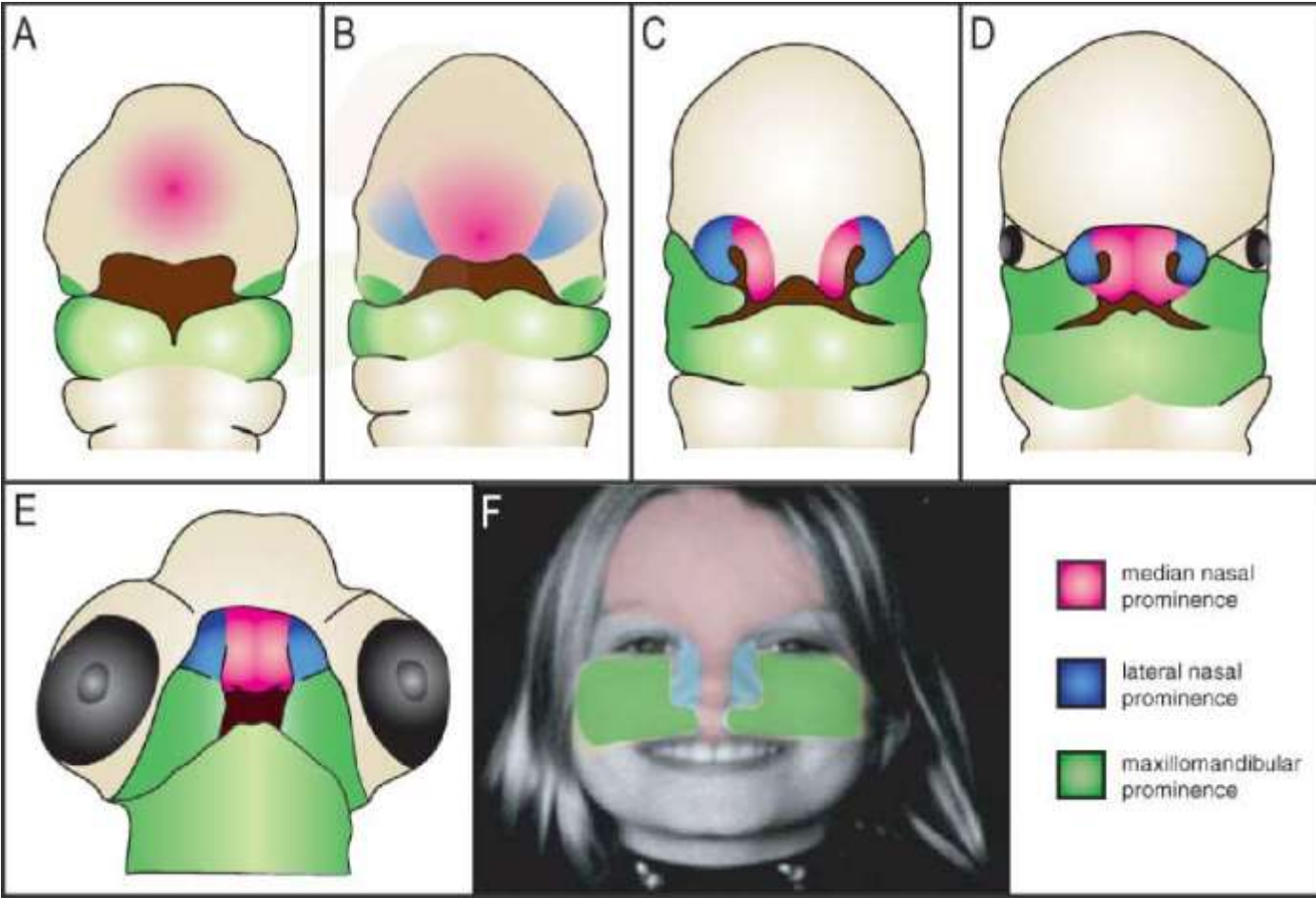


7. týden

# VÝVOJ OBLIČEJE – GANGLIOVÁ LIŠTA



# VÝVOJ OBLIČEJE



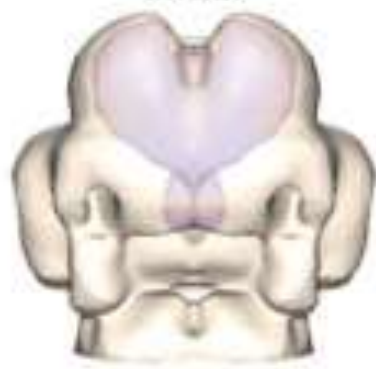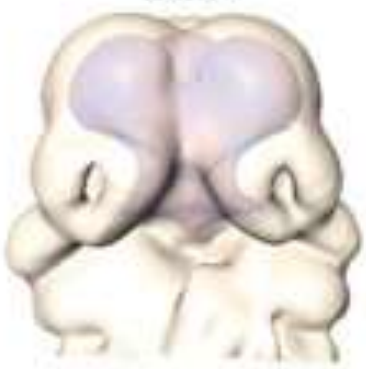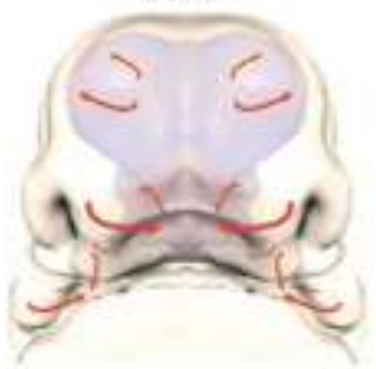Shh a FGF

# VÝVOJ OBLIČEJE - SHH

Human  
CS16

Mouse  
E10.5

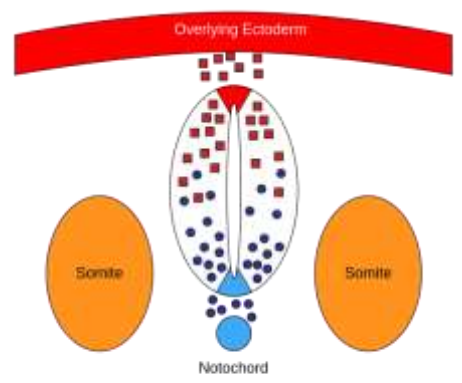
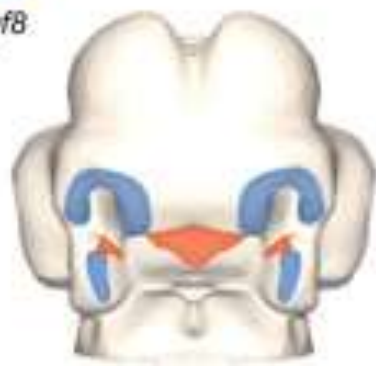
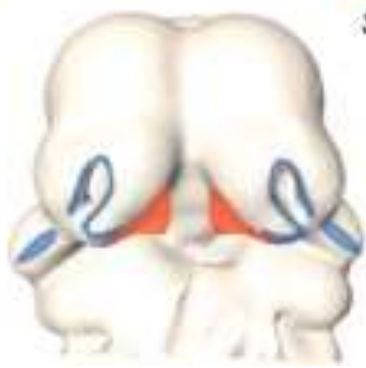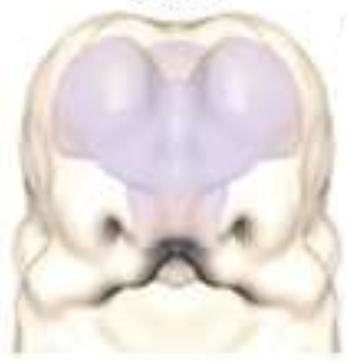
Chick  
HH22



CS17

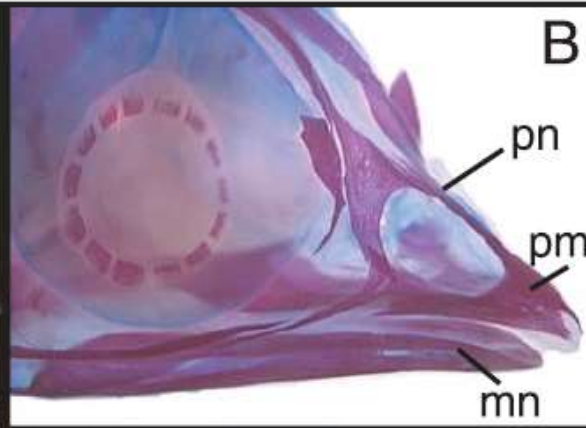
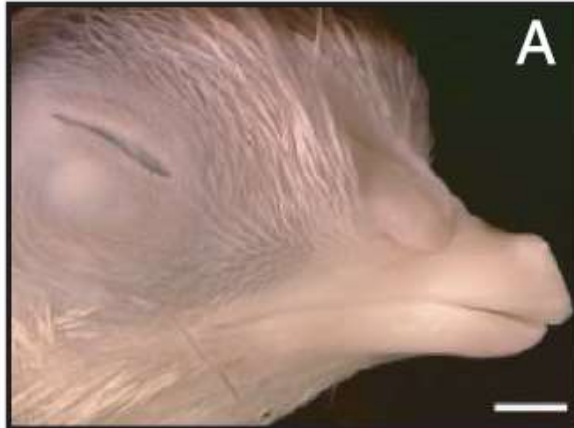Brain

Shh Fgf8

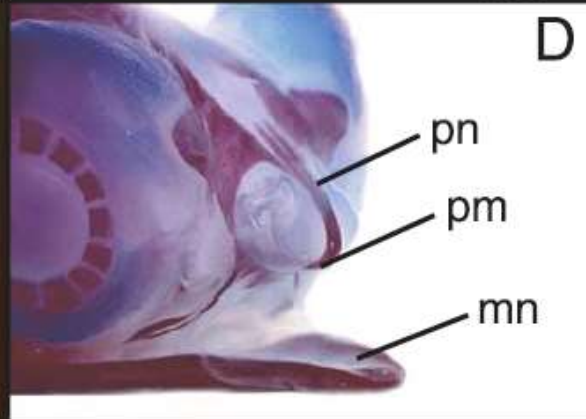


- Sonic hedgehog protein
- BMP protein
- Sonic hedgehog producing cells
- BMP producing cells

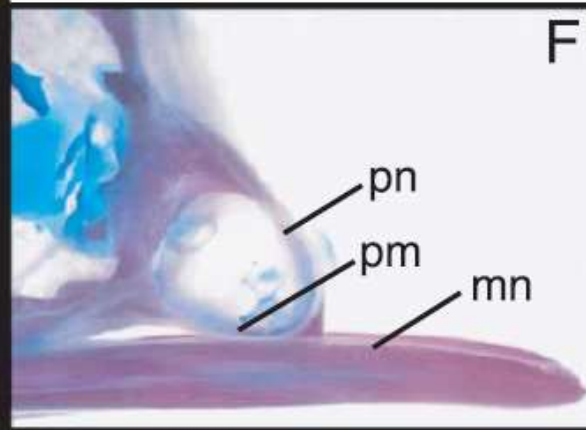
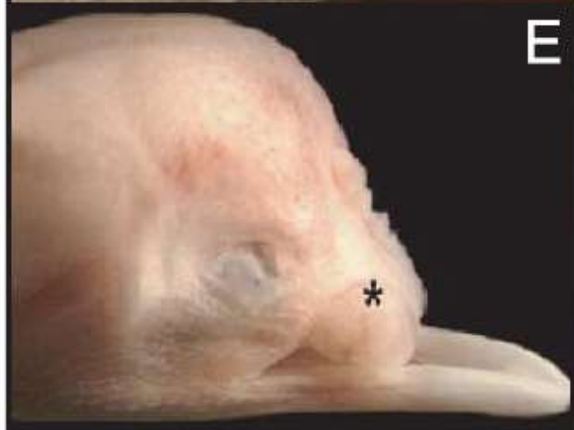
# VÝVOJ OBLIČEJE



Normální



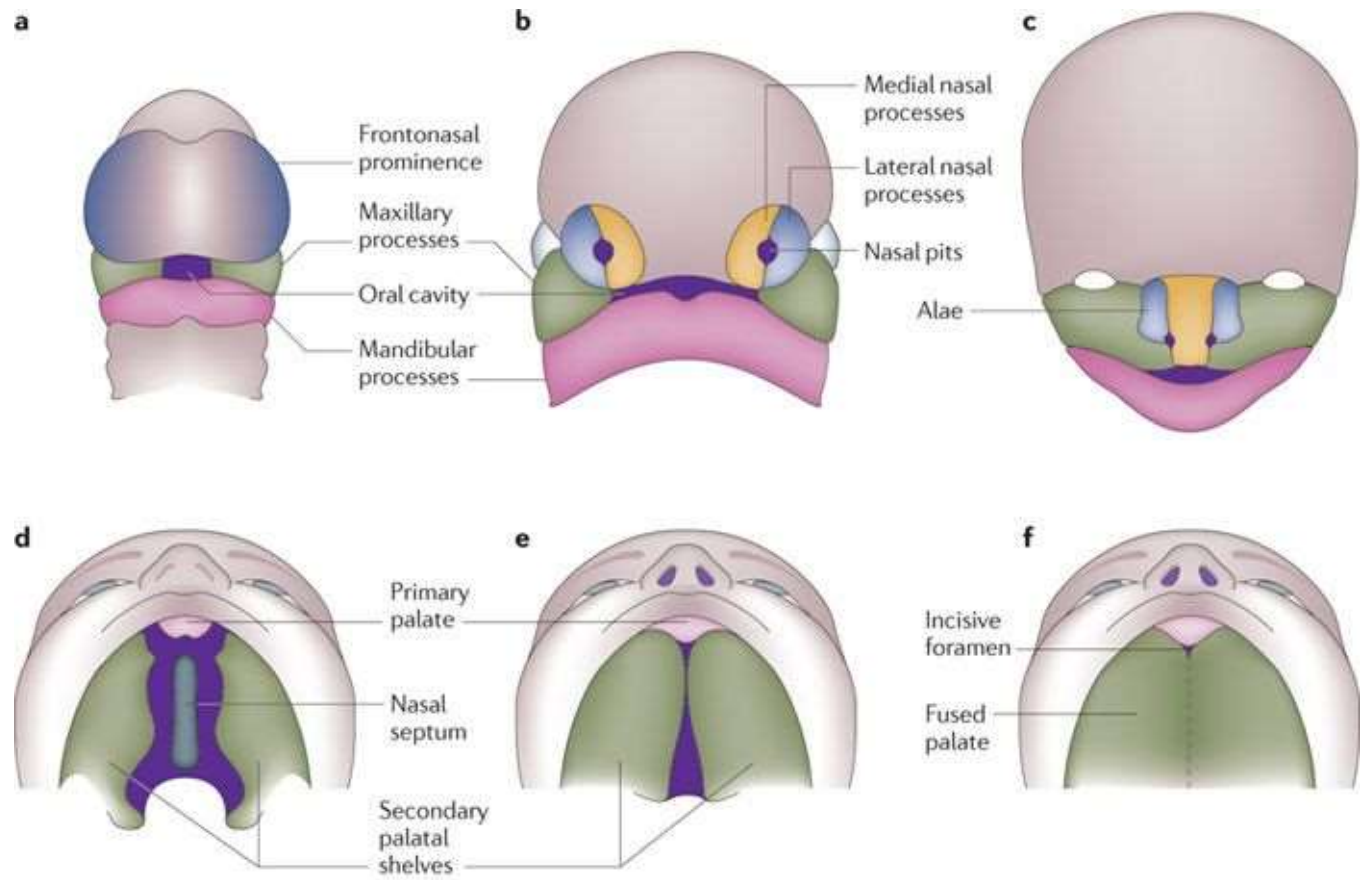
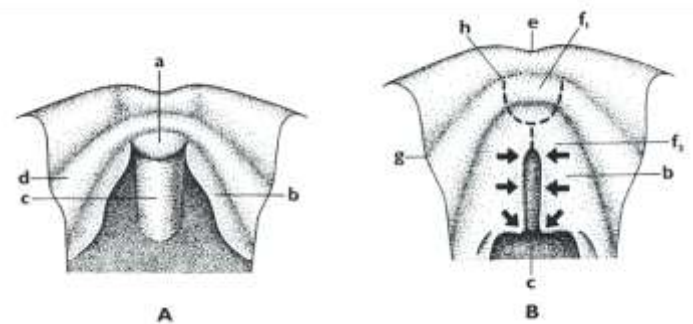
Cyclopamine (teratogen)



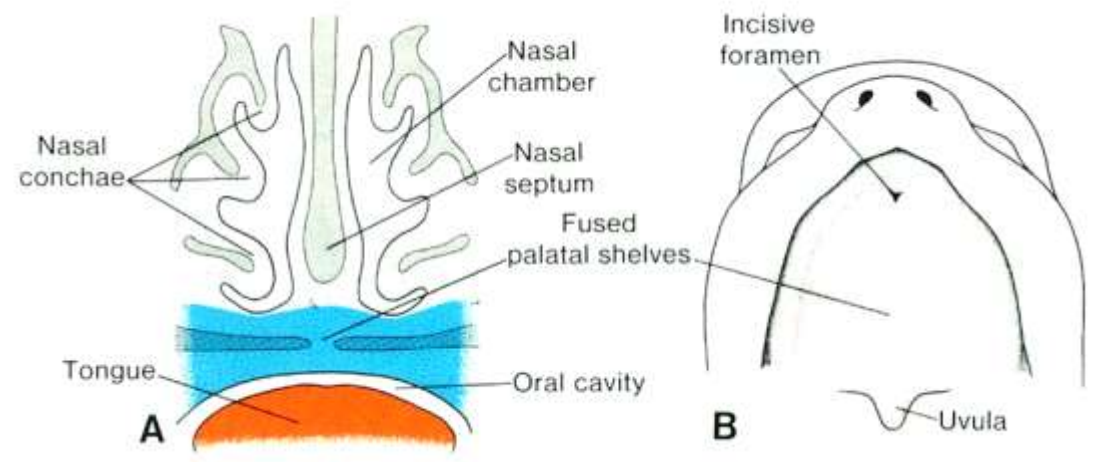
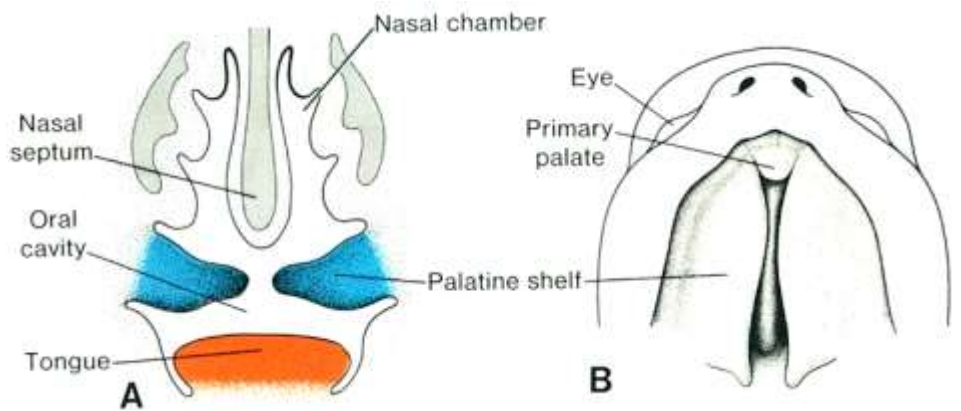
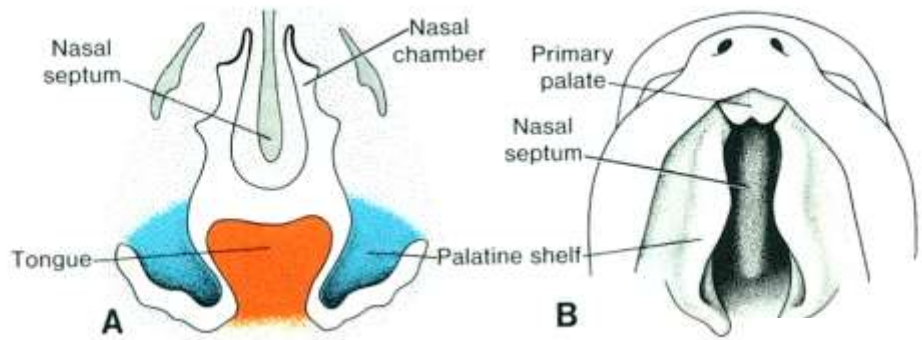
anti-SHH Ab

# VÝVOJ OBLIČEJE - PATRO

- **primární patro** (intermaxilární segment)
- **sekundární patro** (laterální patrové ploténky)



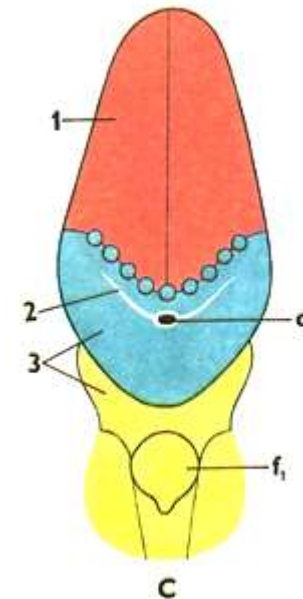
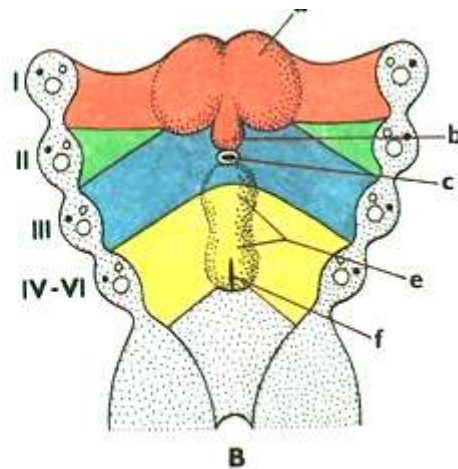
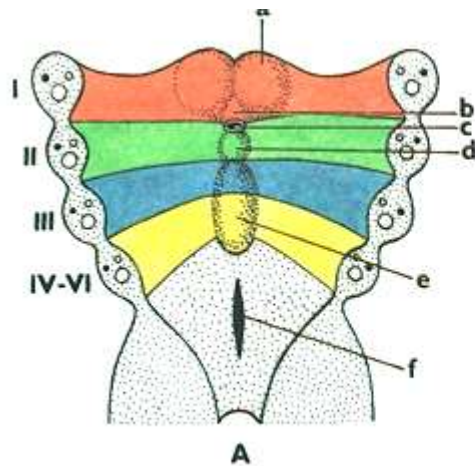
# VÝVOJ OBLIČEJE - PATRO





## Faryngové oblouky

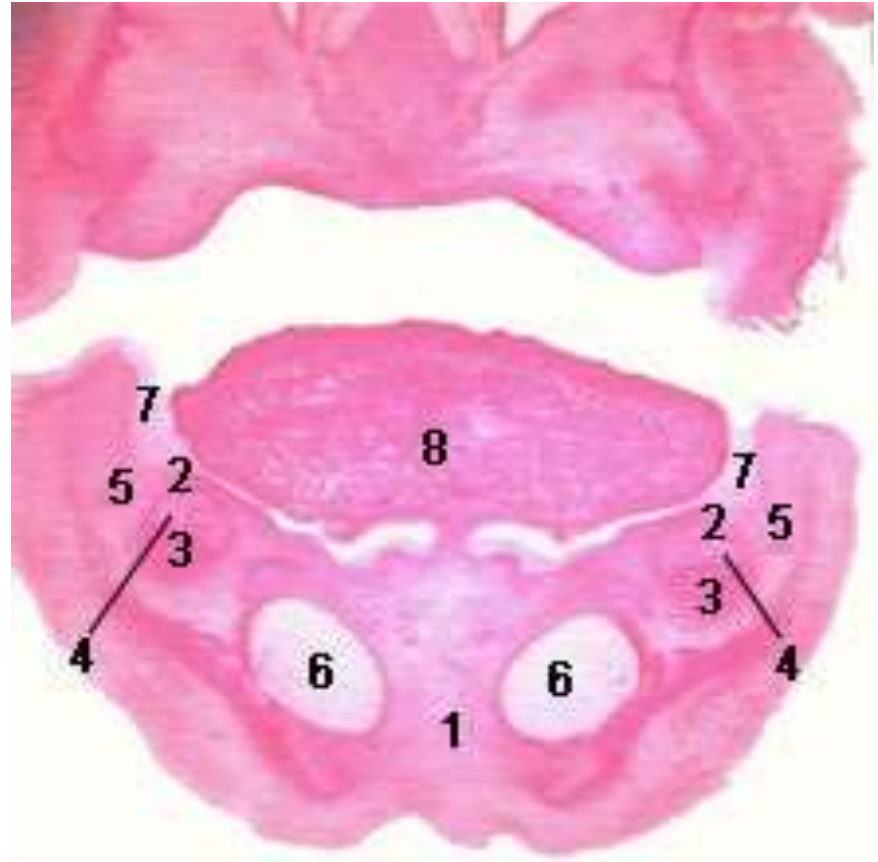
- I. tuberculum linguale laterale (dx. et sin.) + tuberculum impar  
(linguale mediale) → **apex a corpus**
- III-IV. copula + eminentia hypobranchialis → **radix**



## Vestibulární lišta

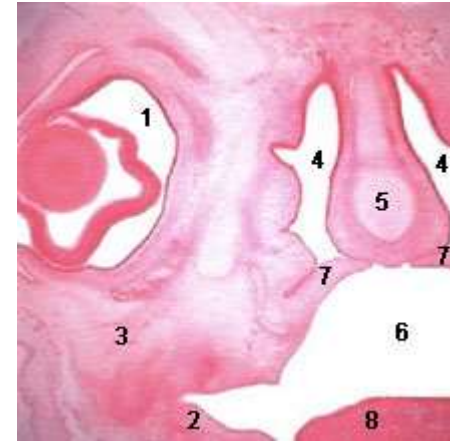
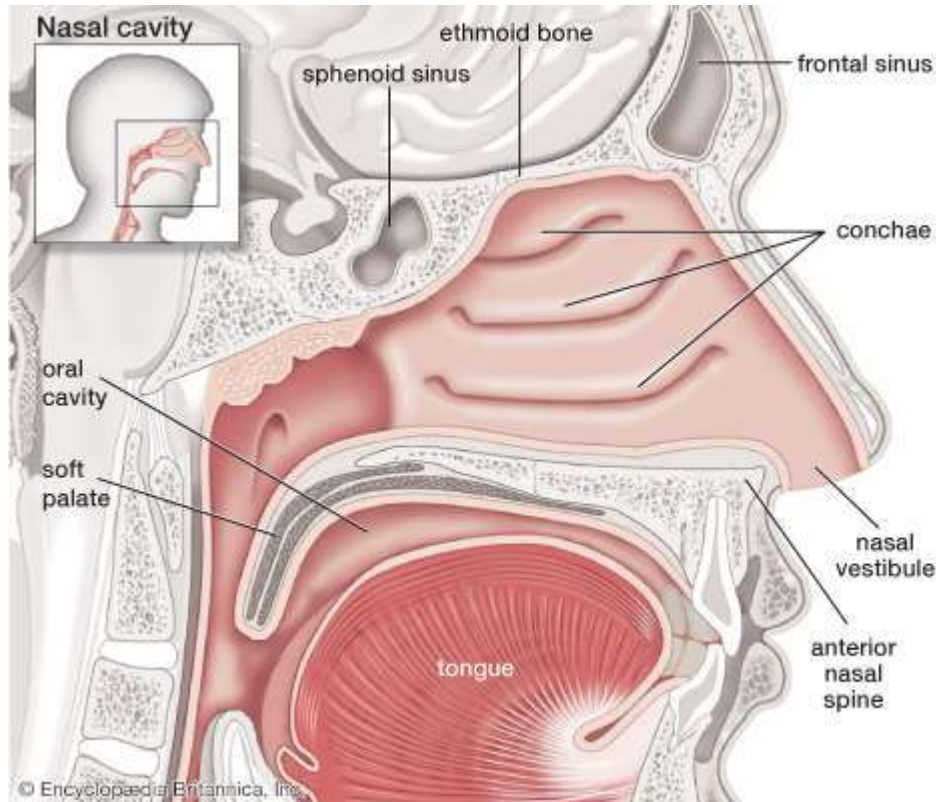
- definitivní ret
- gingivální val

1. Mandibula
2. Dentální lamina
3. Dentální papilla
4. Orgán skloviny
5. Labiogingivální lamina
6. Meckelova chrupavka
7. Orální epitel
8. Jazyk



# VÝVOJ VESTIBULUM NASI

- **Nazální kanálky** – primitivní choany
- **Nazální septum** z area triangularis – splývá se sekundárním patrem



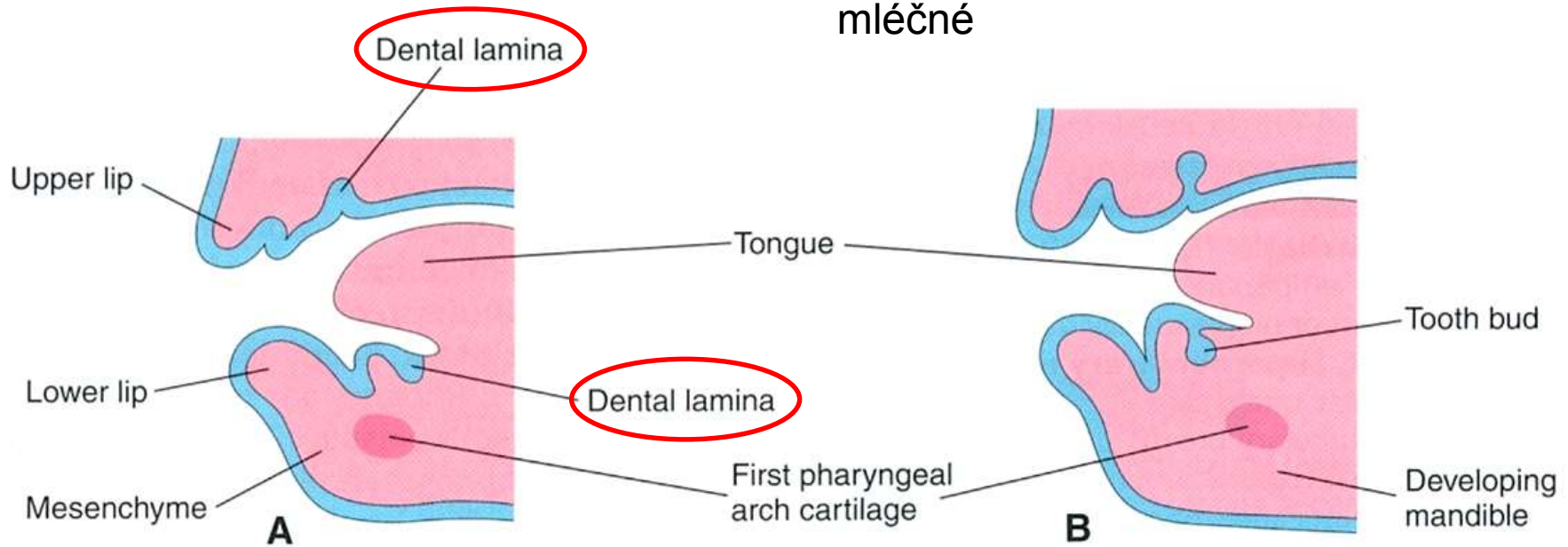
1. Oko
2. Mandibula
3. Maxila
4. Dutina nosní
5. Nosní septum
6. Dutina ústní
7. Patrové výběžky
8. Jazyk



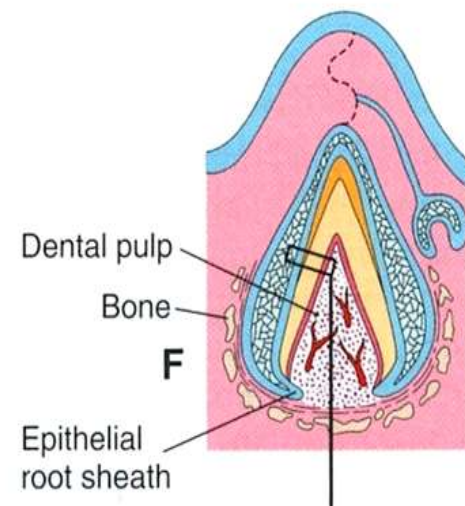
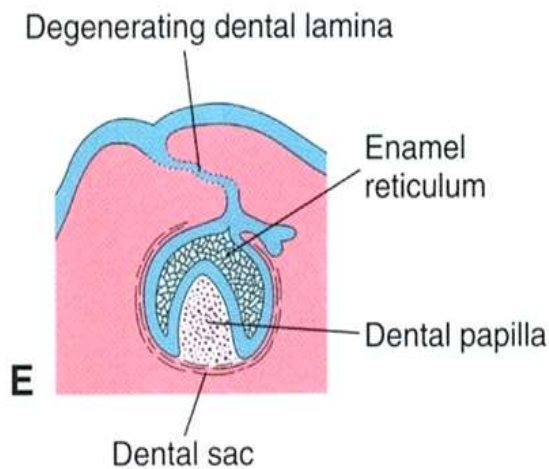
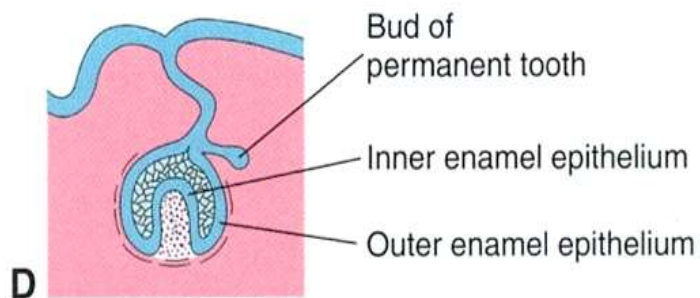
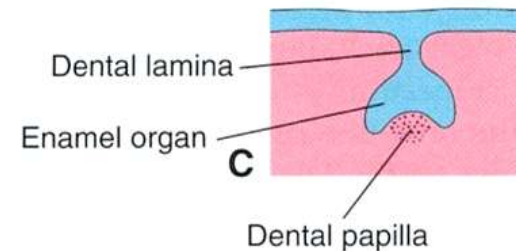
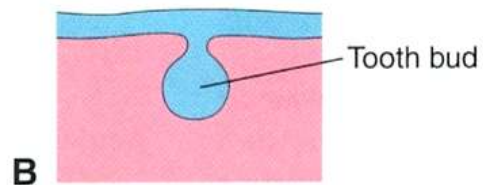
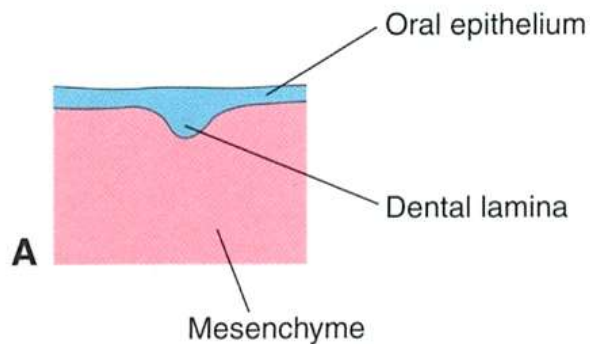
## Interakce ektodermu a mesenchymu

- dentální lamina (zubní lišta) – 10 zubních primordií **x 2**

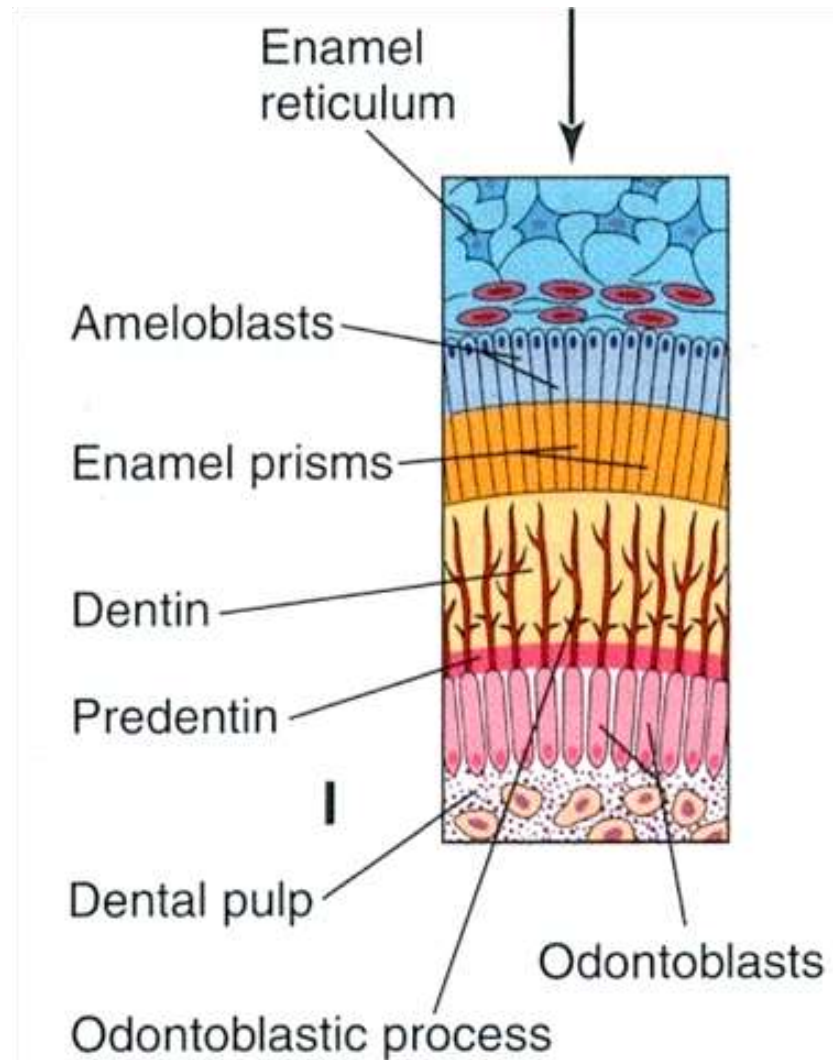
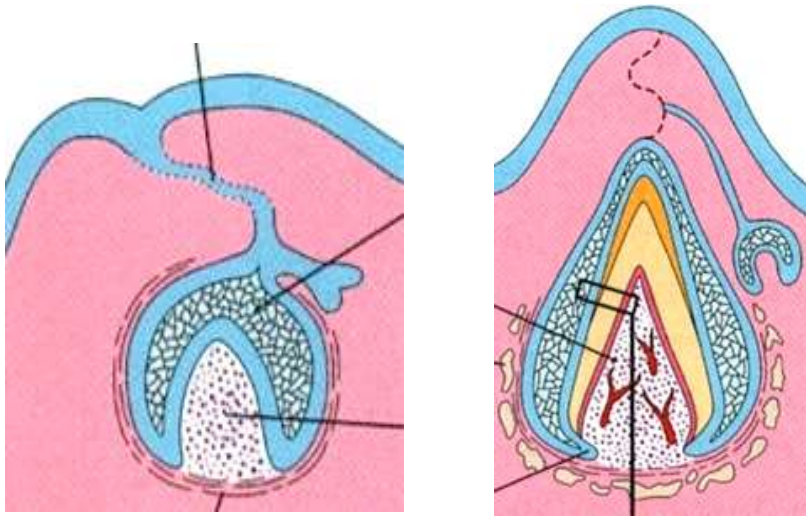
mléčné



# VÝVOJ ZUBU



# VÝVOJ ZUBU

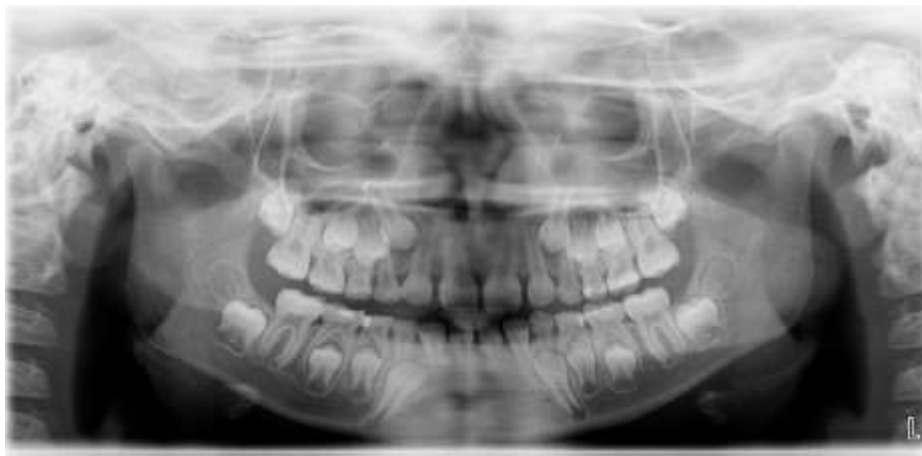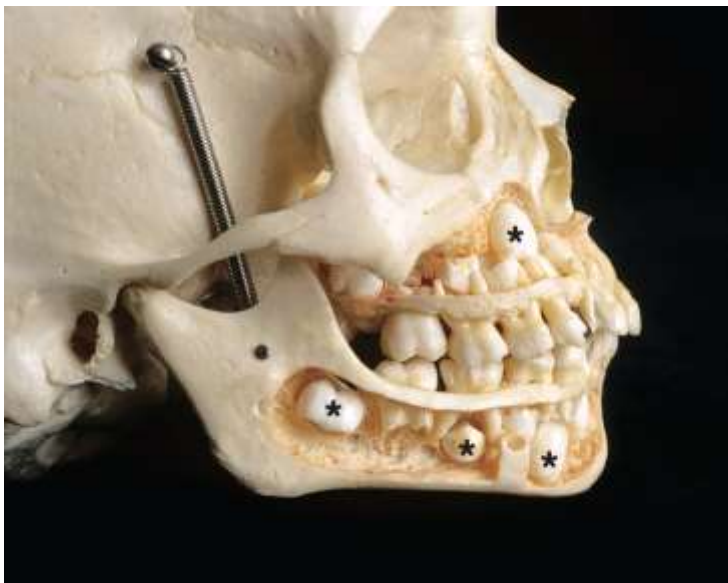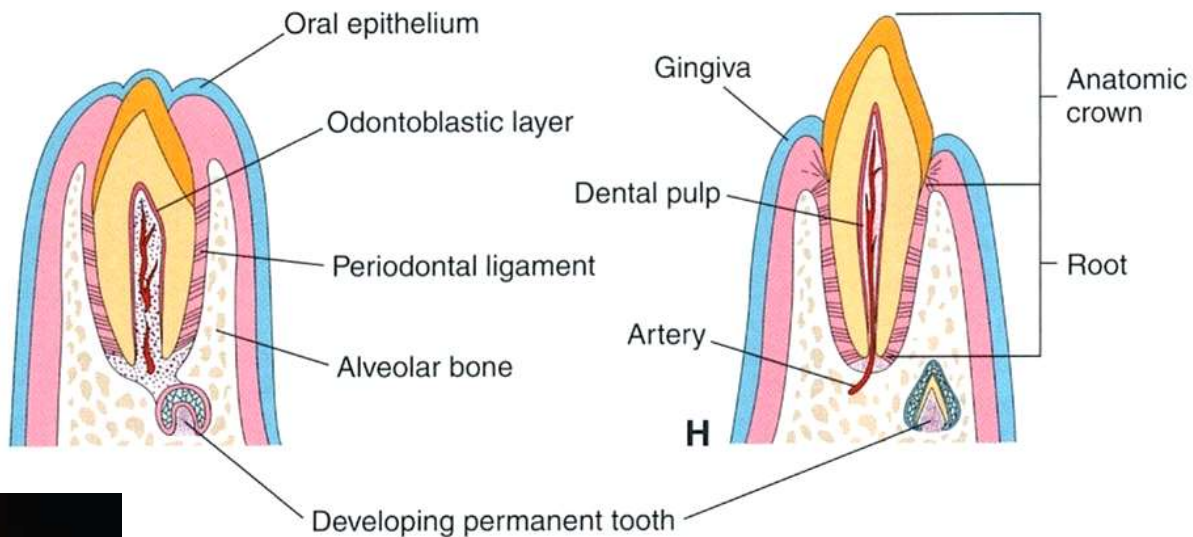
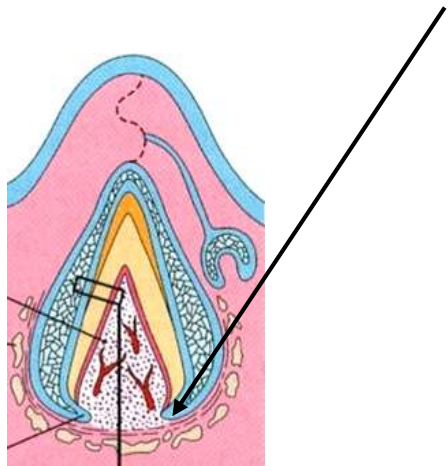


- orgán skloviny (zevní a vnitřní ameloblasty, pulpa skloviny – sklovinné retikulum) - produkce sklovinných prizmat
- diferenciacie odontoblastů - ukládání dentinové matrix
- výběžky odontoblastů: Tomesova vlákna

# VÝVOJ ZUBU

vývoj kořene – prořezání zubu

cervikální klička → Hertwigova kořenová pochva





# PROŘEZÁVÁNÍ A VÝMĚNA DENTICE

## Dentes decidui - mléčné

Spodní I1	6-10 měsíců	6-7 let
Horní I1	8-12 měsíců	6-7 let
Horní I2	9-13 měsíců	7-8 let
Spodní I2	10-16 měsíců	7-8 let
Horní M1	13-19 měsíců	9-11 let
Spodní M1	14-18 měsíců	9-11 let
Horní C	16-22 měsíců	10-12 let
Spodní C	17-23 měsíců	9-12 let
Spodní M2	23-31 měsíců	10-12 let
Horní M2	25-33 měsíců	10-12 let

## Dentes permanentes

Spodní I1	6-7 let
Horní I1	7-8 let
Spodní I2	7-8 let
Horní I2	8-9 let
Horní M1	6-7 let
Spodní M1	6-7 let
Spodní C	9-10 let
Horní P1	10-11 let
Spodní P1	10-12 let
Horní P2	10-12 let
Spodní P2	11-12 let
Horní C	11-12 let
Spodní M2	11-13 let
Horní M2	12-13 let
Horní M3	17-21 let
Spodní M3	17-21 let

Vzorec mléčného chrupu:

$m_2$	$m_1$	$c$	$i_2$	$i_1$	$i_1$	$i_2$	$c$	$m_1$	$m_2$
$m_2$	$m_1$	$c$	$i_2$	$i_1$	$i_1$	$i_2$	$c$	$m_1$	$m_2$

Vzorec definitivního chrupu:

$M_3$	$M_2$	$M_1$	$P_2$	$P_1$	$C$	$I_2$	$I_1$	$I_1$	$I_2$	$C$	$P_1$	$P_2$	$M_1$	$M_2$	$M_3$
$M_3$	$M_2$	$M_1$	$P_2$	$P_1$	$C$	$I_2$	$I_1$	$I_1$	$I_2$	$C$	$P_1$	$P_2$	$M_1$	$M_2$	$M_3$



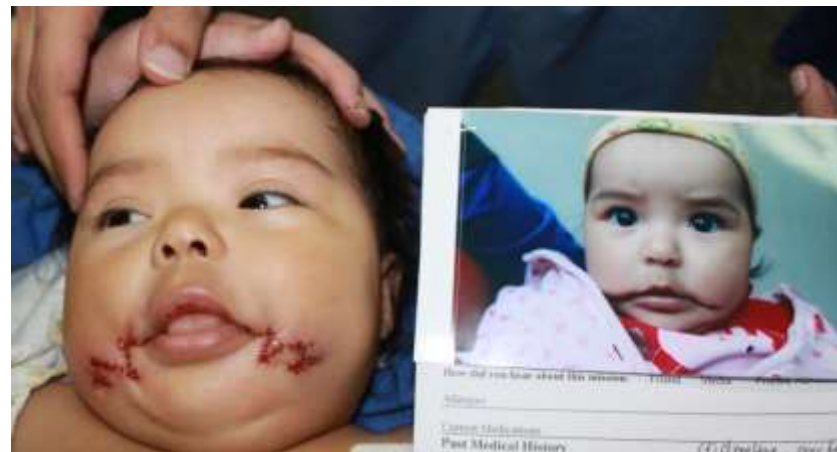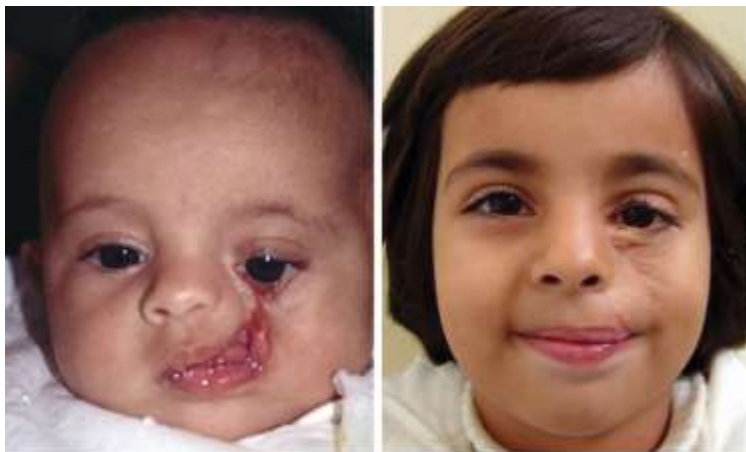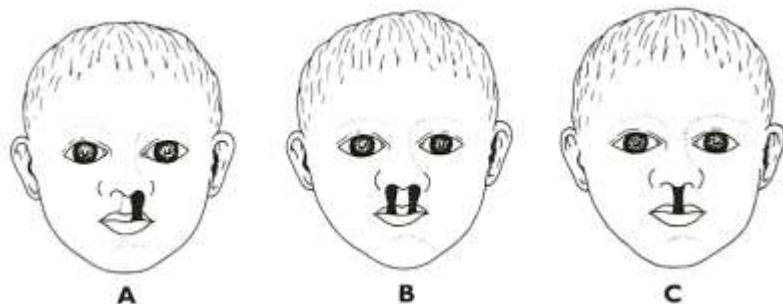
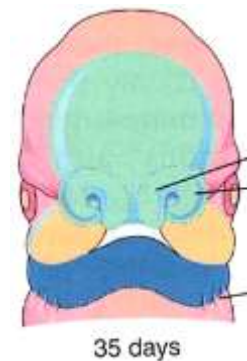## Early Tooth Development: *Bud, Cap and Bell Stages*

### **Klíčové termíny**

- zubní pupen
- zubní zvonek
- zubní papila
- odontoblasty
- vnitřní a vnější sklovinný epitel
- ameloblasty
- hvězdicové retikulum
- zubní uzel
- cervikální klička
- Hertwigova kořenová pochva

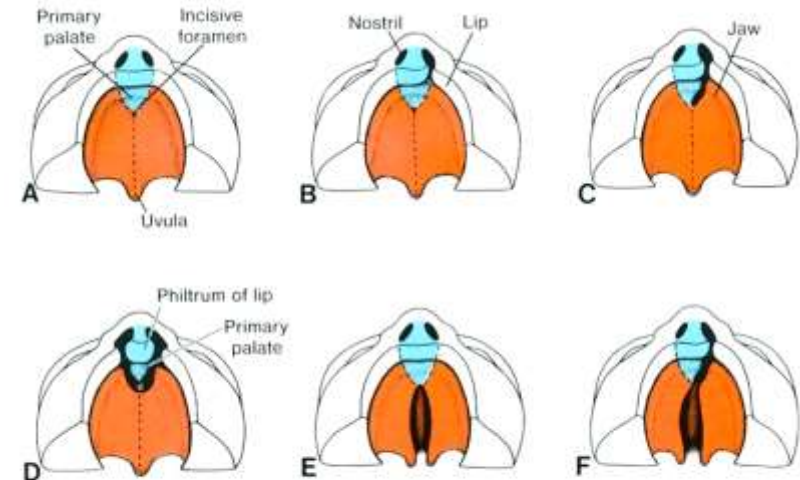
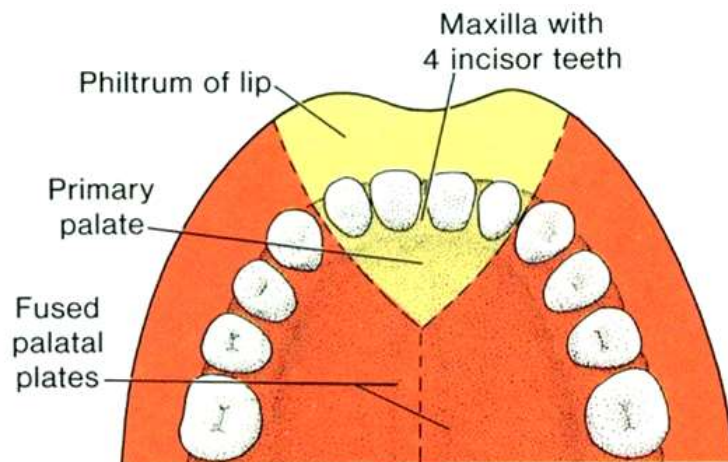
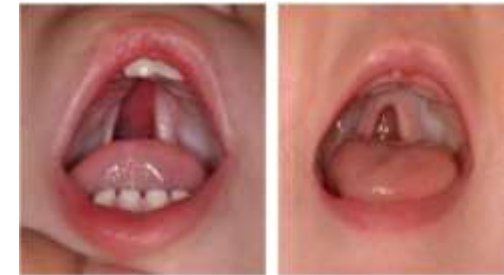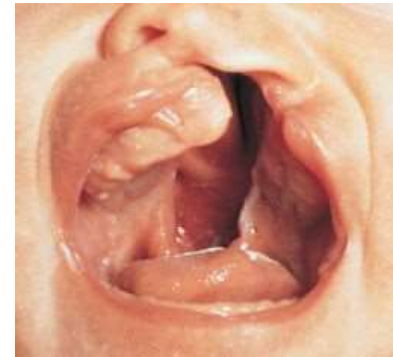## Rozštěp měkké tkáně

- rozštěp horního rtu (*cheiloschisis*) – laterální (uni, bi), mediální
- rozštěp dolního rtu – mediálně, kombinovaný s dalšími vadami (čelist, jazyk) – *gnathoschisis et cheiloschisis inf.*
- šikmý rozštěp (*fissura orbitofacialis*)
- příčný rozštěp (*fissura transversa*)

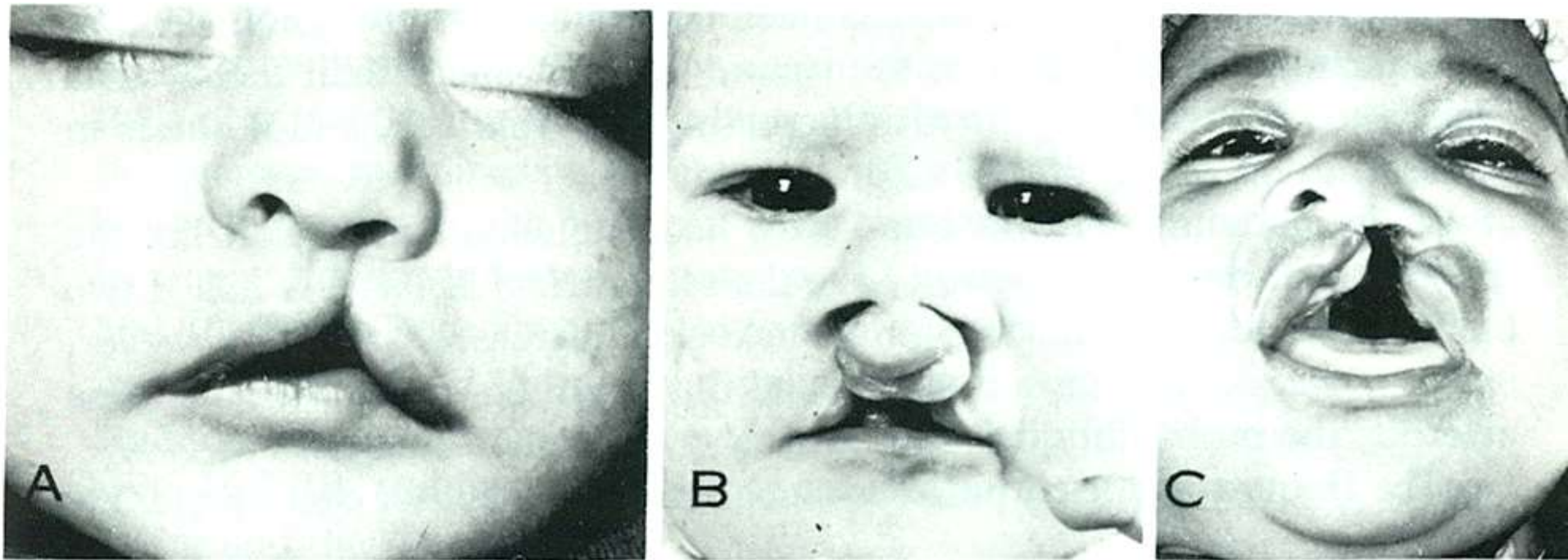


## Rozštěp tvrdé tkáně

- horní čelist
  - mezi špičkem a 2. řezákem
  - unilaterálně nebo bilaterálně
  - kombinována s rozštěpem patra (*cheilognathoschisis*)
- patro (*palatoschisis*)
  - primární (před foramen incisivum)
  - sekundární (za foramen incisivum)
- sdružené vady: *cheilognathopalatoschisis*

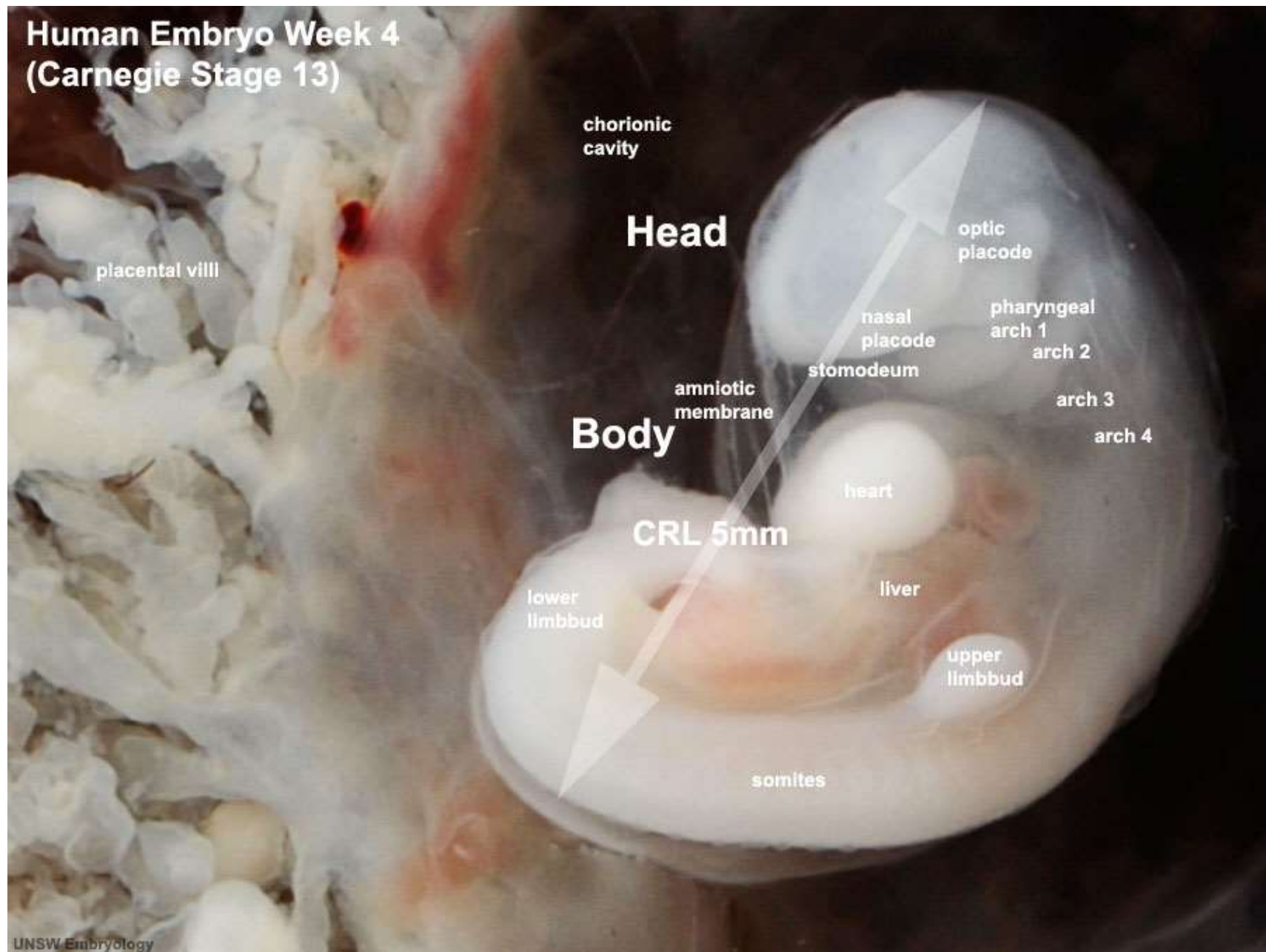


**Figure 16-25.** Ventral view of the palate, gum, lip, and nose. **A.** Normal. **B.** Unilateral cleft lip extending into the nose. **C.** Unilateral cleft involving lip and jaw, and extending to incisive foramen. **D.** Bilateral cleft involving lip and jaw. **E.** Isolated cleft palate. **F.** Cleft palate combined with unilateral anterior cleft.



**Figure 16-26.** Photographs of incomplete cleft lip (A), bilateral cleft lip (B), and cleft lip, cleft jaw, and cleft palate (C). (Courtesy Dr. M. Edgerton, Department of Plastic Surgery, University of Virginia.)

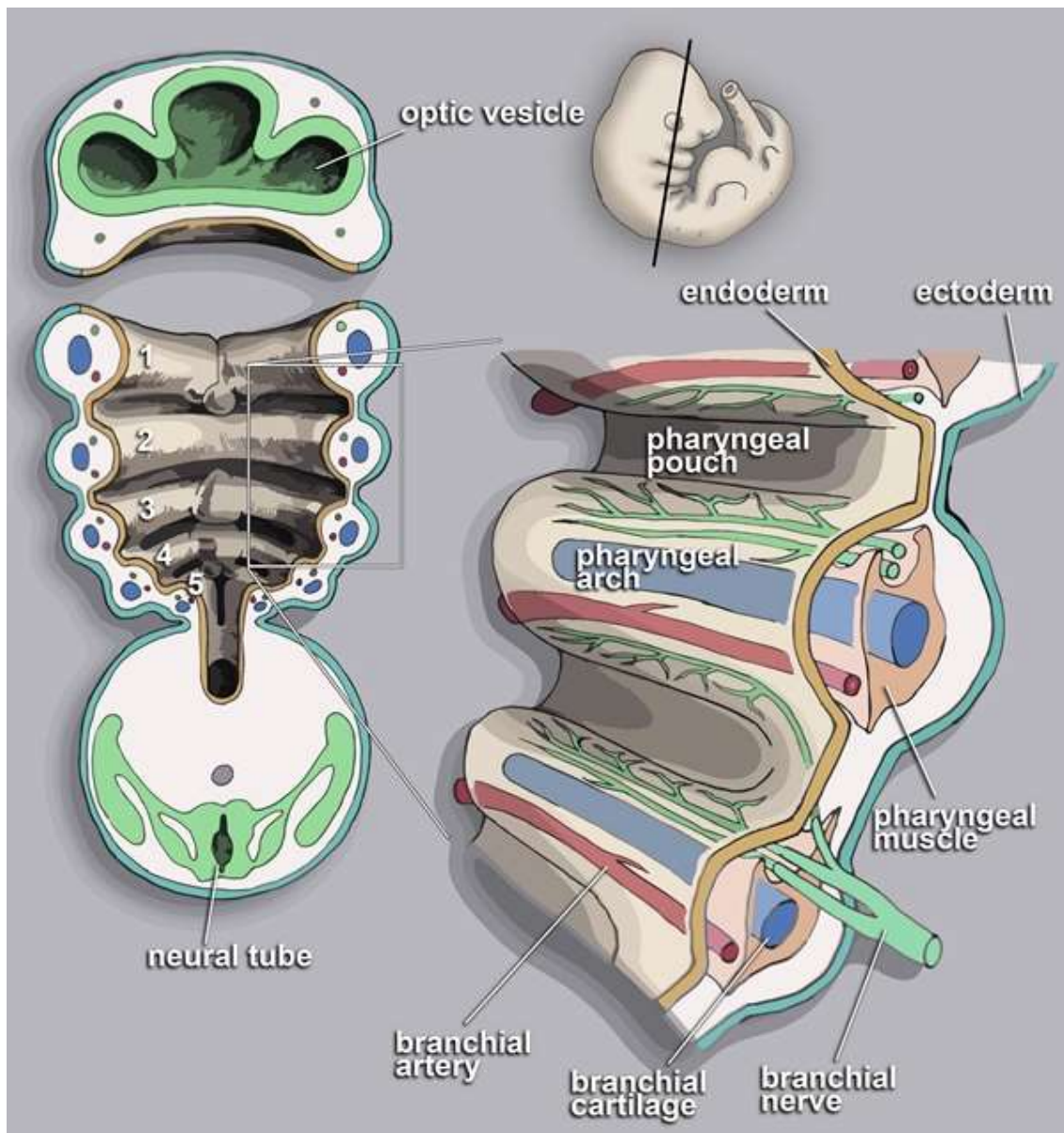
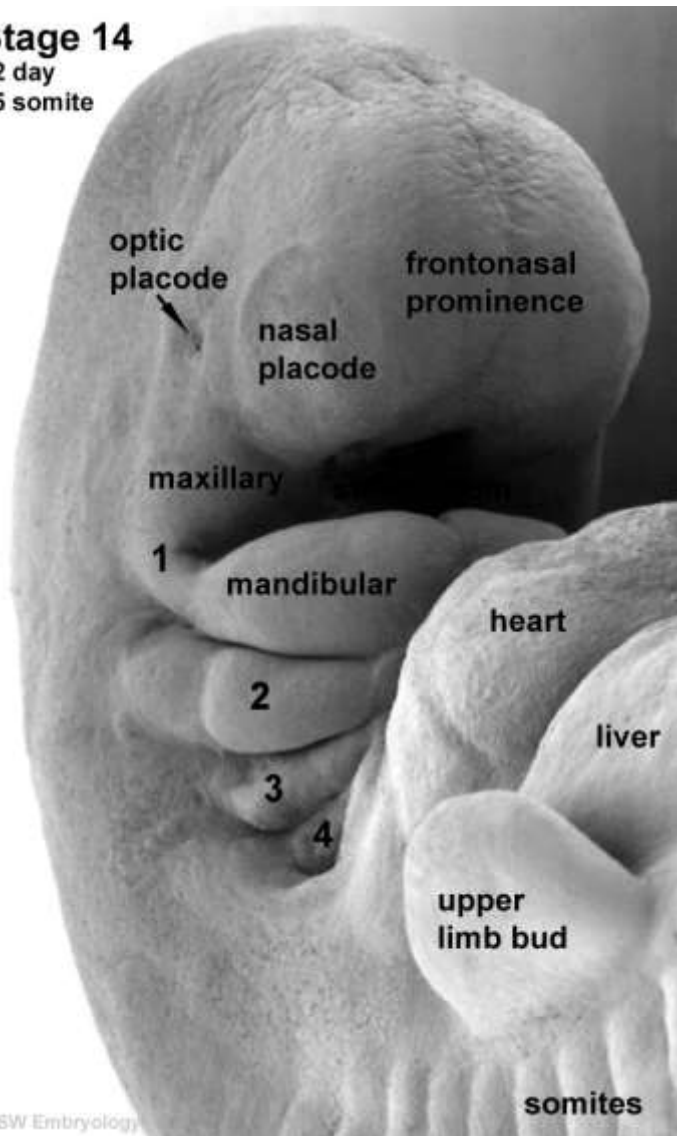
# FARYNGOVÝ APARÁT



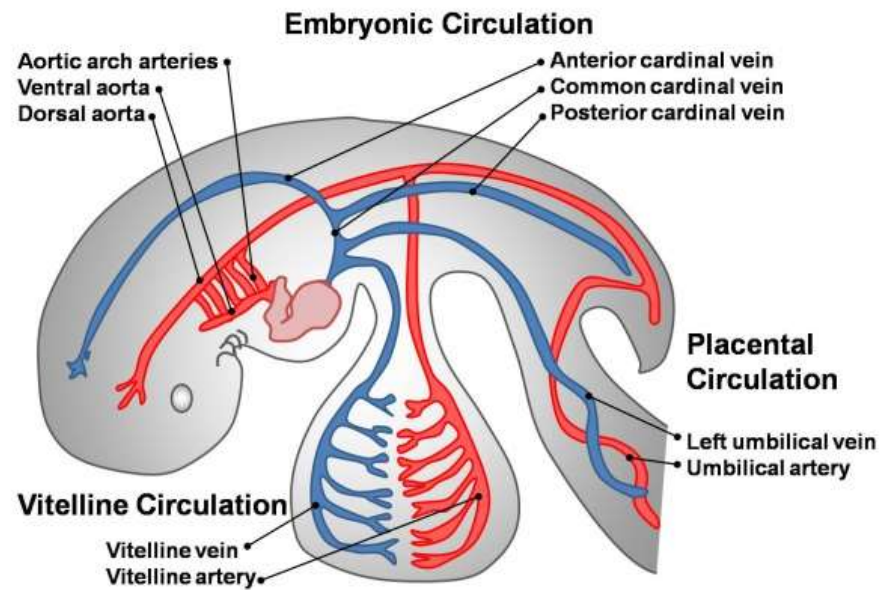
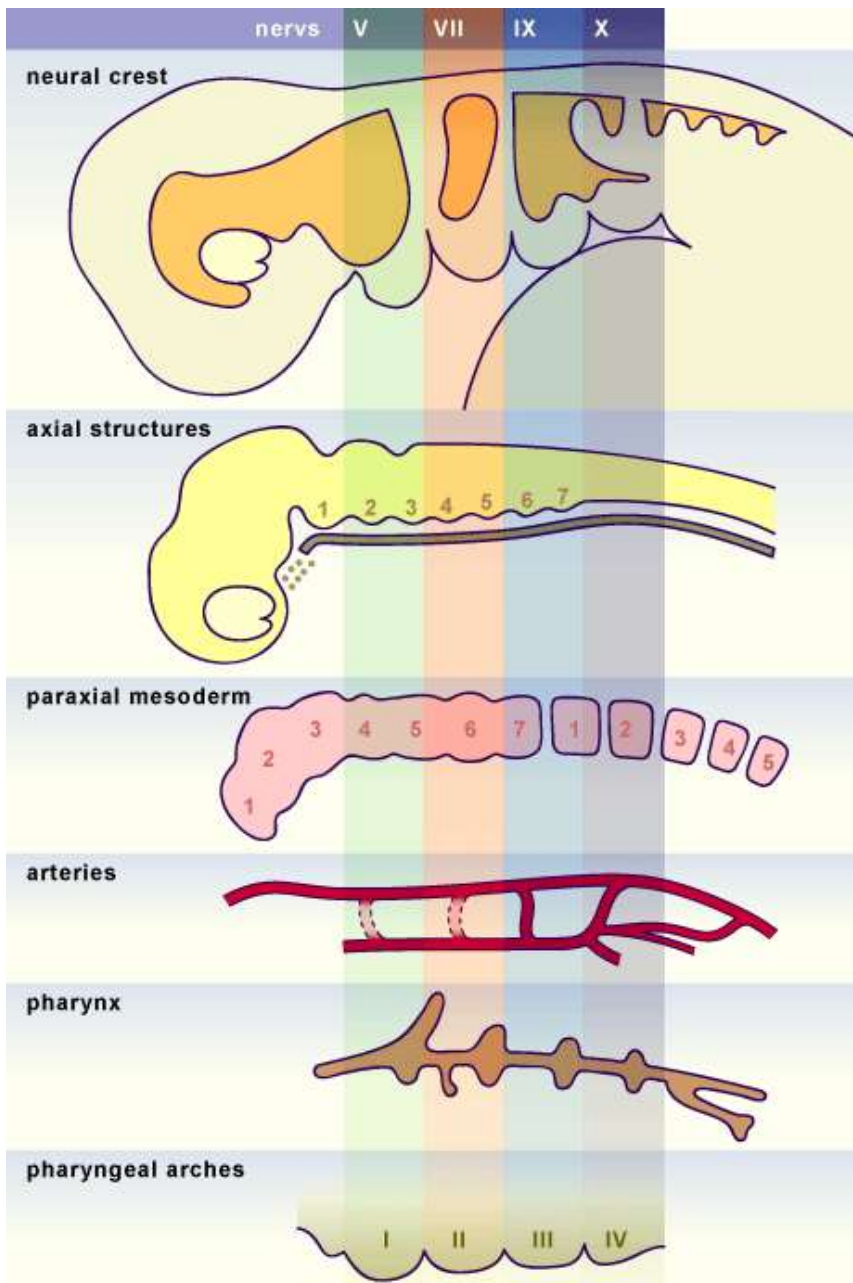
# FARYNGOVÝ APARÁT

## Stage 14

32 day  
35 somite

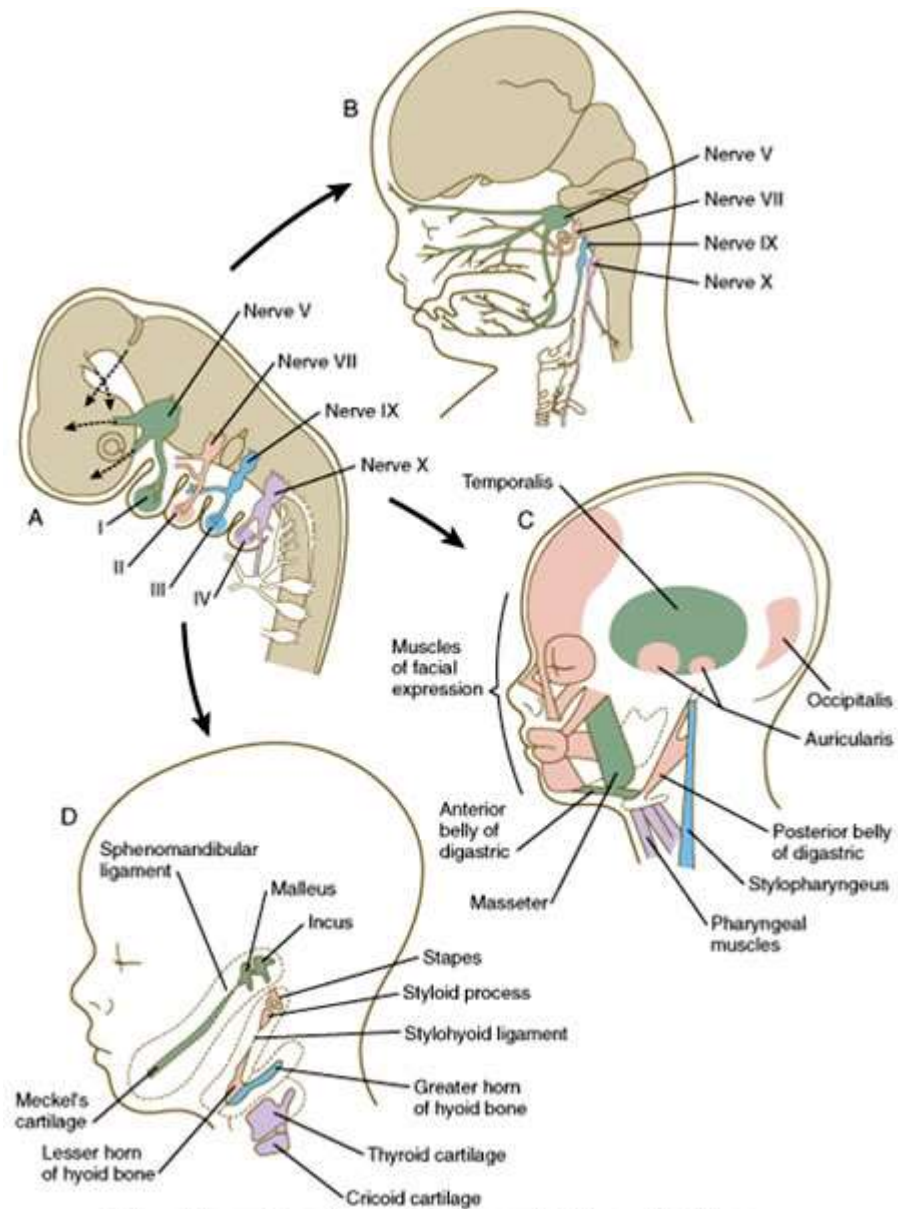


# FARYNGOVÝ APARÁT



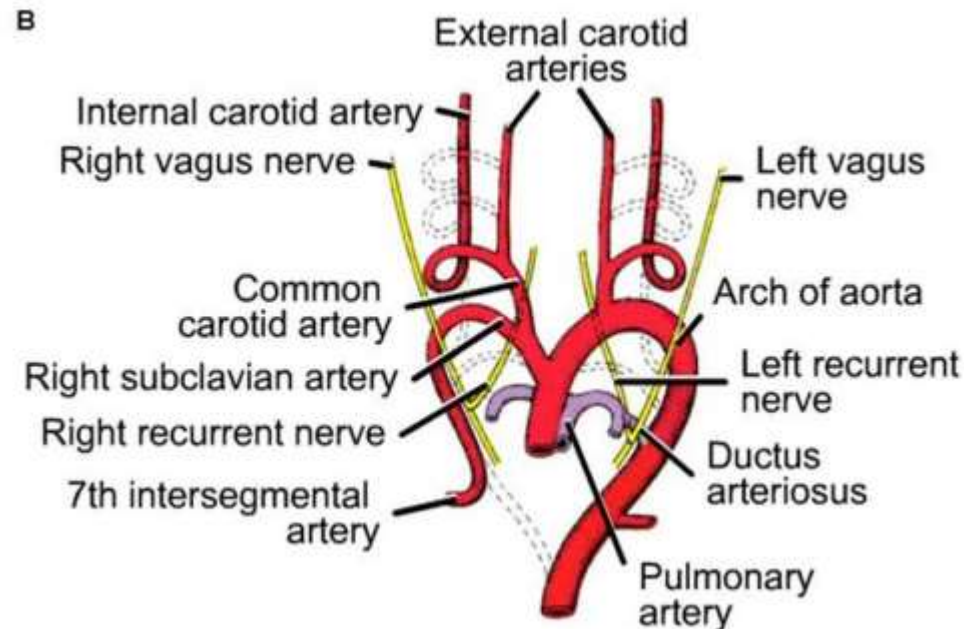
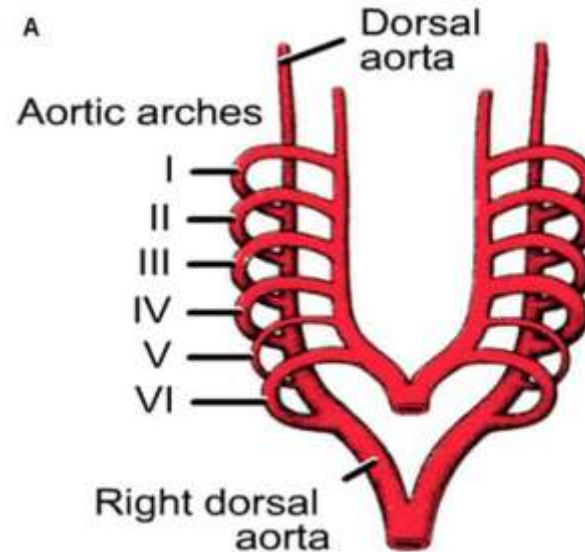


# FARYNGOVÝ APARÁT



## Aortální oblouky

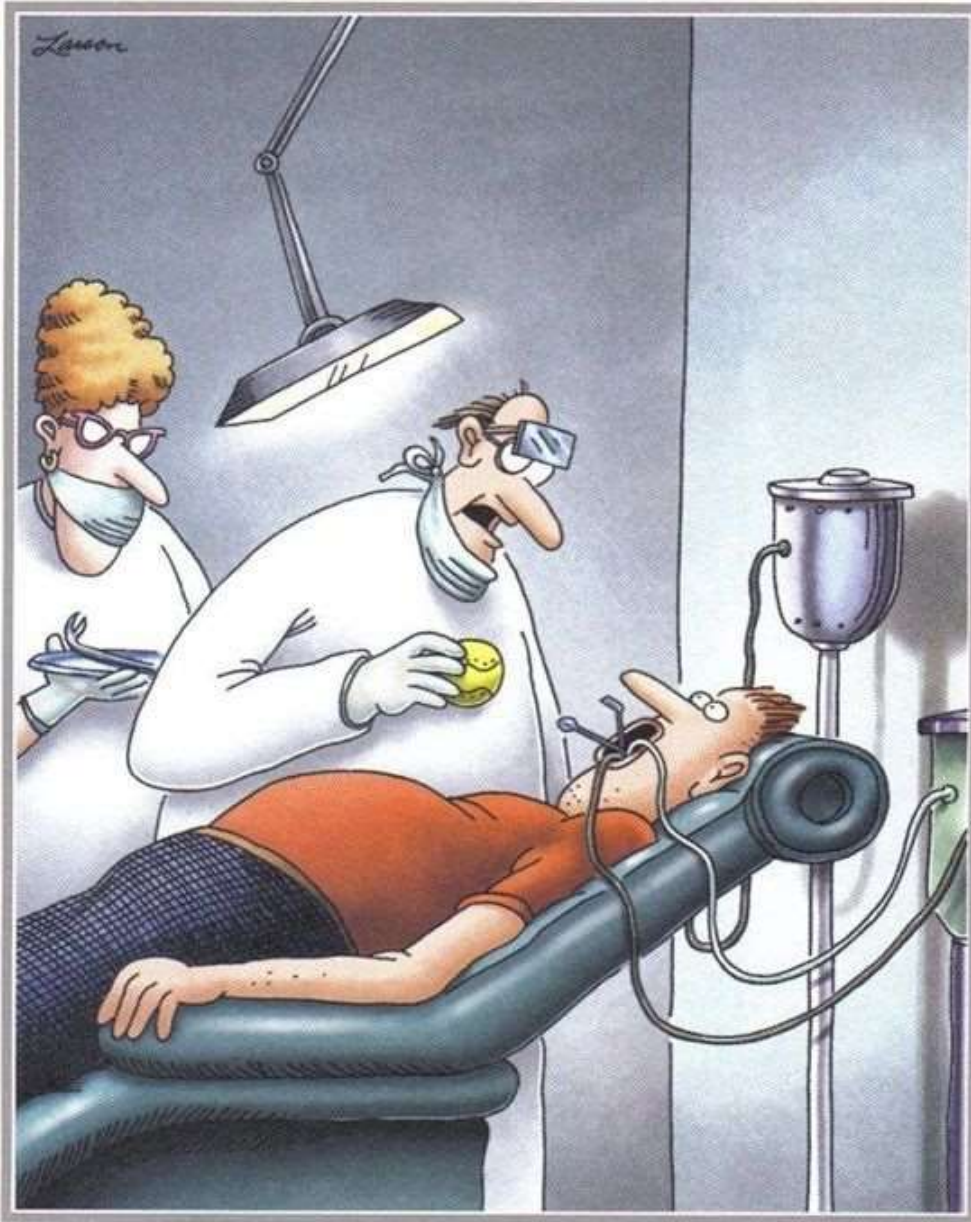
- 1 zaniká, přispívá k a. maxillaris, a. carotis ext.
- 2 zaniká, přispívá k a. stapedia, a. hyoidea
- 3 a. carotis interna
- 4 pravý: proximální část a. subclavia dextra  
levý: arcus aortae
- 5 zaniká
- 6 pravý: proximální část: a. pulmonalis dextra,  
distální vymizí  
levý: proximální část a. pulmonalis sinistra,  
distální část ductus arteriosus





# FARYNGOVÝ APARÁT A JEHO DERIVÁTY - SHRNUÍ

Derivát ektodermové brázdy	Faryngový oblouk	Aortální oblouk	Kraniální nerv	Příklad branchiomerních svalů	Deriváty skeletu	Deriváty entodermové výchlípký
vnější zvukovod	1 mandibulární	a. maxillaris	V trigeminus	žvýkáčí	kladívko, kovadlinka lig. sphenomandib. Meckelova chrupavka	středoušní dutina, tuba auditiva
zanikají / sinus cervicalis	2 hyoidní	a. stapedia a. hyoidea	VII facialis	mimické	třmínek proc. styloideus, hyoidní chrupavka	fossa tonsillaris
	3	a. carotis interna	IX glossopharyngeus	m. stylopharyngeus	hyoidní chrupavka	thymus, příštítná tělíska (inf.)
	4	a. subclavia dx. arcus aortae	X vagus	svaly faryngu a laryngu	laryngeální chrupavky	příštítná tělíska (sup.)



"Now open even wider, Mr. Stevens. ...  
Just out of curiosity, we're going to see if we can also cram in this tennis ball."

Thank you for  
attention



pvanhara@med.muni.cz

<http://www.med.muni.cz/histology/education/>