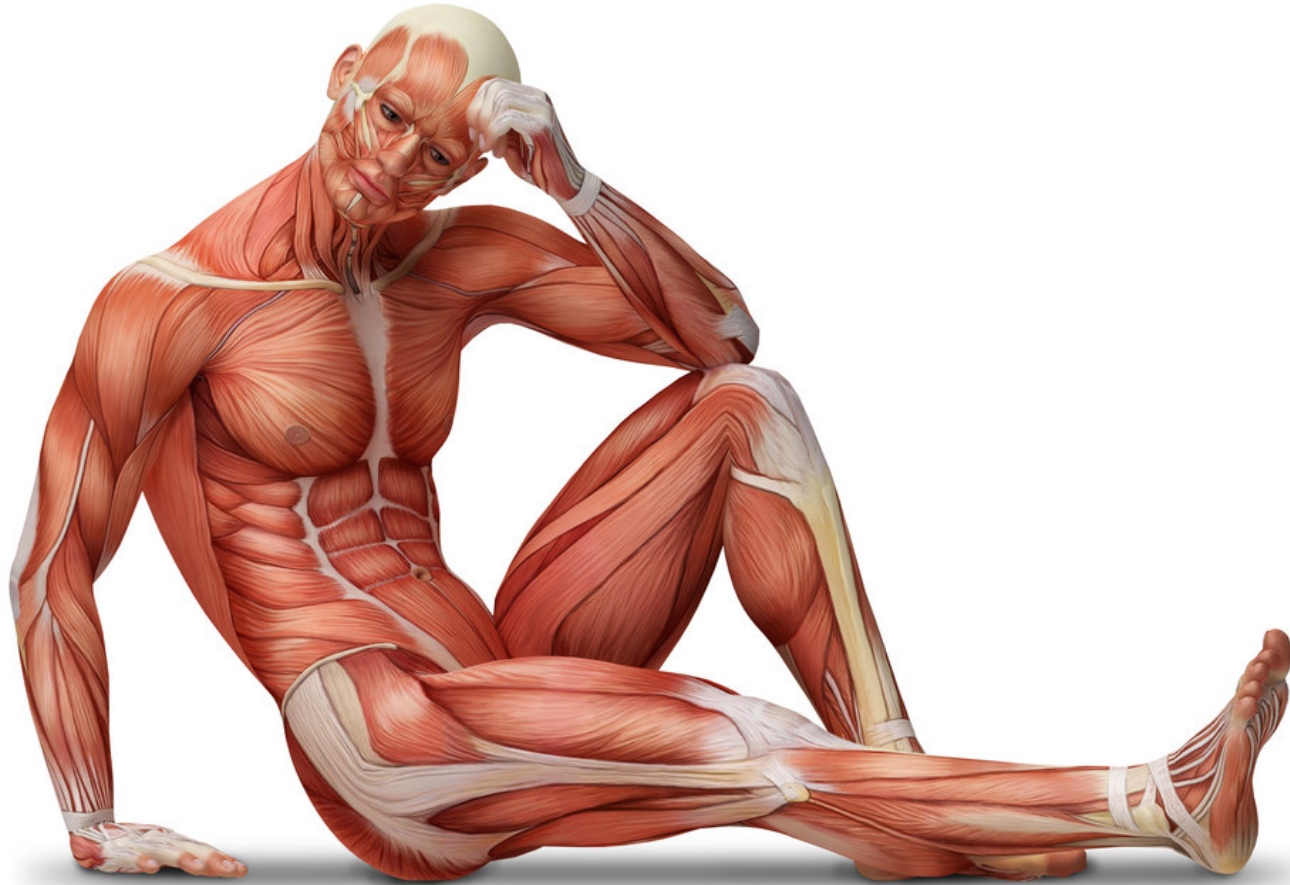


- **GENERAL MYOLOGY**



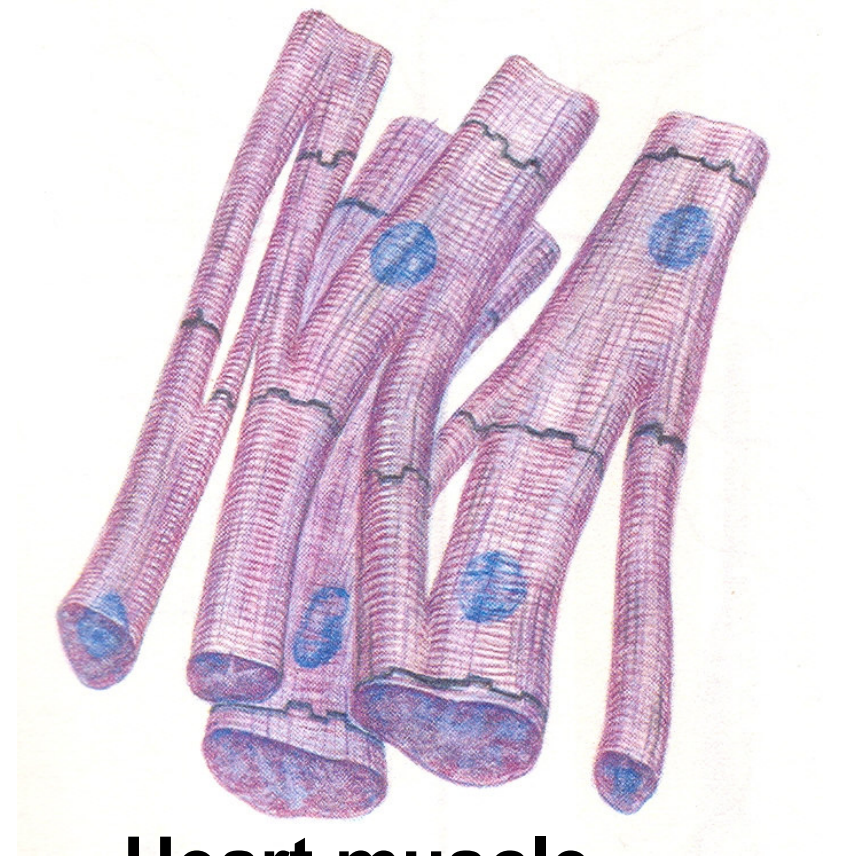
MUSCULAR SYSTEM

basic unit- muscle = musculus

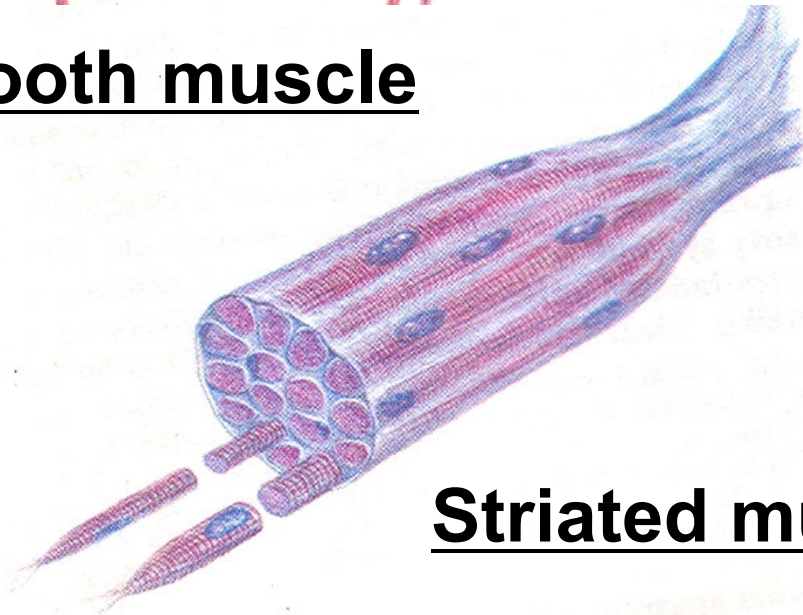
- **Active component of the locomotor system- it is controlled by nerves**
- The main demonstration of mechanical function of muscle fibers (on the base of excitations coming through the motor nerve fibers) is their shortening—**contraction** (movement)
- Contractile proteins myosin and actin form the basis of myofibrils of muscle fibers



Smooth muscle



Heart muscle



Striated muscle

Function of the muscular system

- **motion** function – muscular system represent an active component of the locomotor system
- **shape** function - musculature forms exterior (external shape) of a man
- **termoregulation** – it is releasing heat
- It helps **blood circulation**
- It keeps **basic muscle tension**

ATTACHMENT

To the bones: skeletal muscles- mm. sceleti- over 600 in the body, mostly paired, they form 1/3-1/2 of entire body weight

To the skin: skin muscles- mm. cutanei- mainly on head and neck

Relationship to organs: organ muscles (sphincters)

To the articular capsules: mm. articulares

The internal structure of striated muscle

- 1) Striated muscle tissue (myosin and actin)- muscle fiber

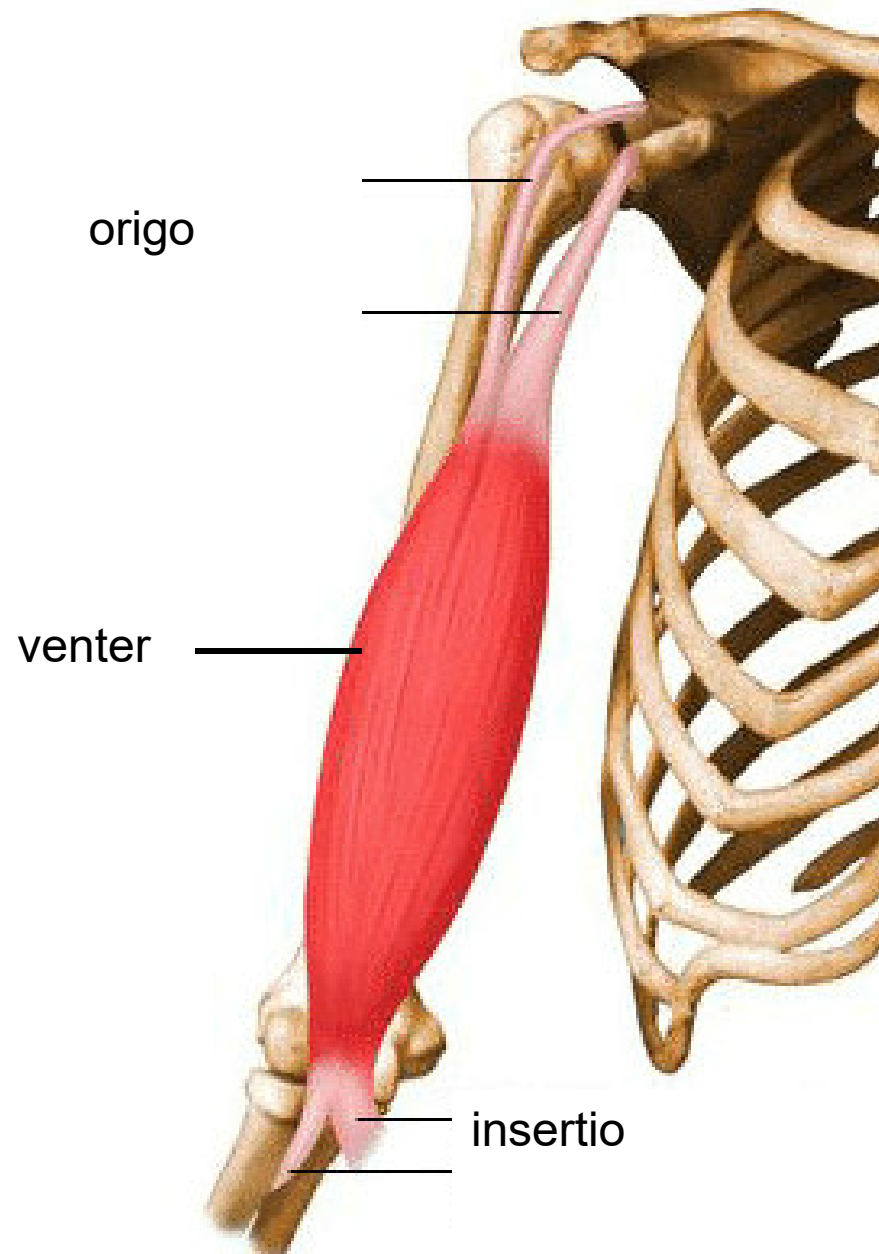
- 2) Fibrous tissue (it covers the muscle fibers, primary and secondary fasciculi – important for metabolism between muscle fiber and blood circulation of muscle, on the surface, there is coherent covering fascia = fascia, the muscle **tendon** is also created by fibrous tissue

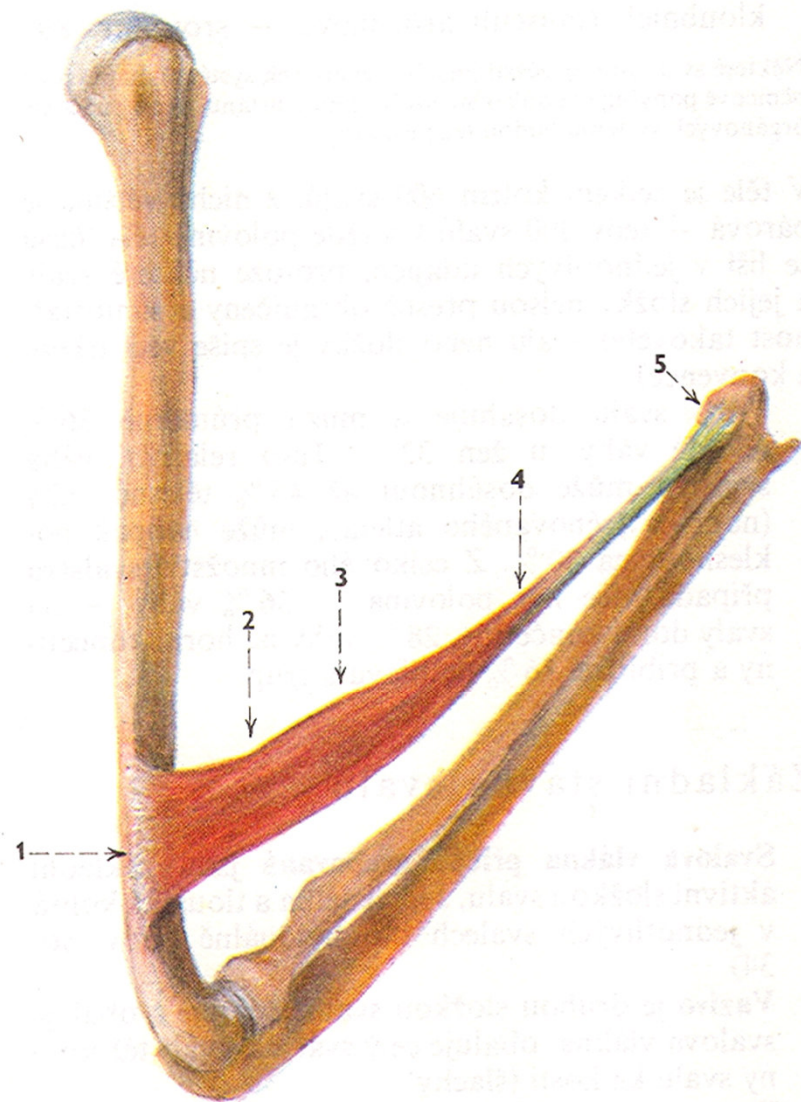
- 3) Logistic components (vessels and nerves)

- 4) Special apparatus

EXTERNAL STRUCTURE OF MUSCLE

- **origin (*origo*)**: part of the muscle that runs from bone (or skin); it is the place, where the muscle doesn't change its position during contraction (so-called: fixed point- **punctum fixum**), it is usually formed by tendon
- **belly (*venter*)**: fleshy part of muscle, its beginning is called **caput** (head), its end is called **cauda** (tail)
- **insertion (*insertio*)**: is formed by tendon; it is the place, where the muscle changes its position during contraction (so-called: mobile point- **punctum mobile**), the tendon attaches usually to a bone, sometimes to skin or organ





337. SVAL A JEHO ÚSEKY

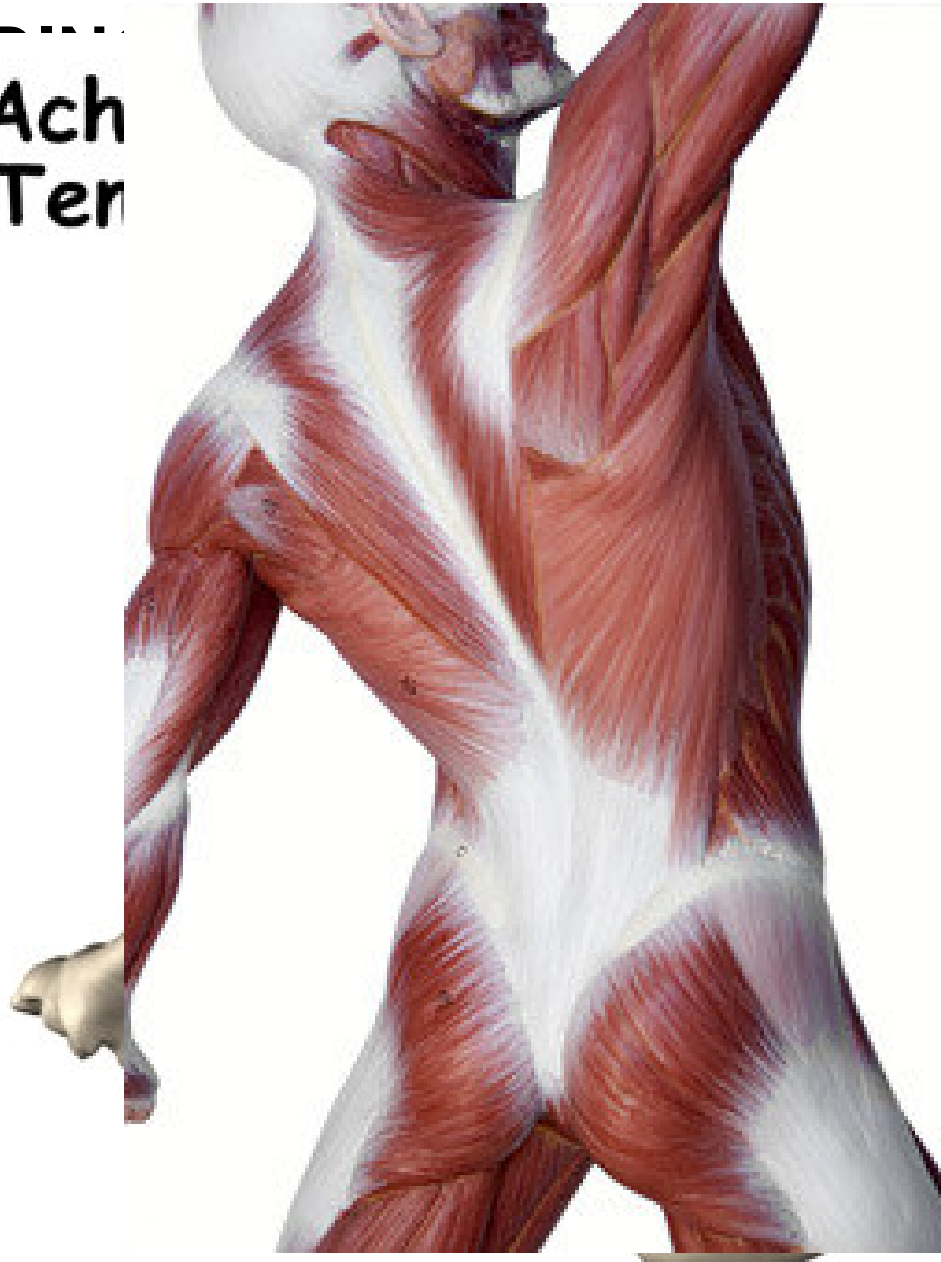- 1/ začátek svalu – origo
- 2/ hlava svalu – caput musculi
- 3/ břicho svalu – venter musculi
- 4/ (ohon svalu – cauda musculi)
- 5/ úpon svalu – insertio

CLASSIFICATION OF MUSCLES

1. ACCC

Ach
Ter

- Long tendon
- Short tendon
- Flat muscle aponeurosis
- Round muscle opening

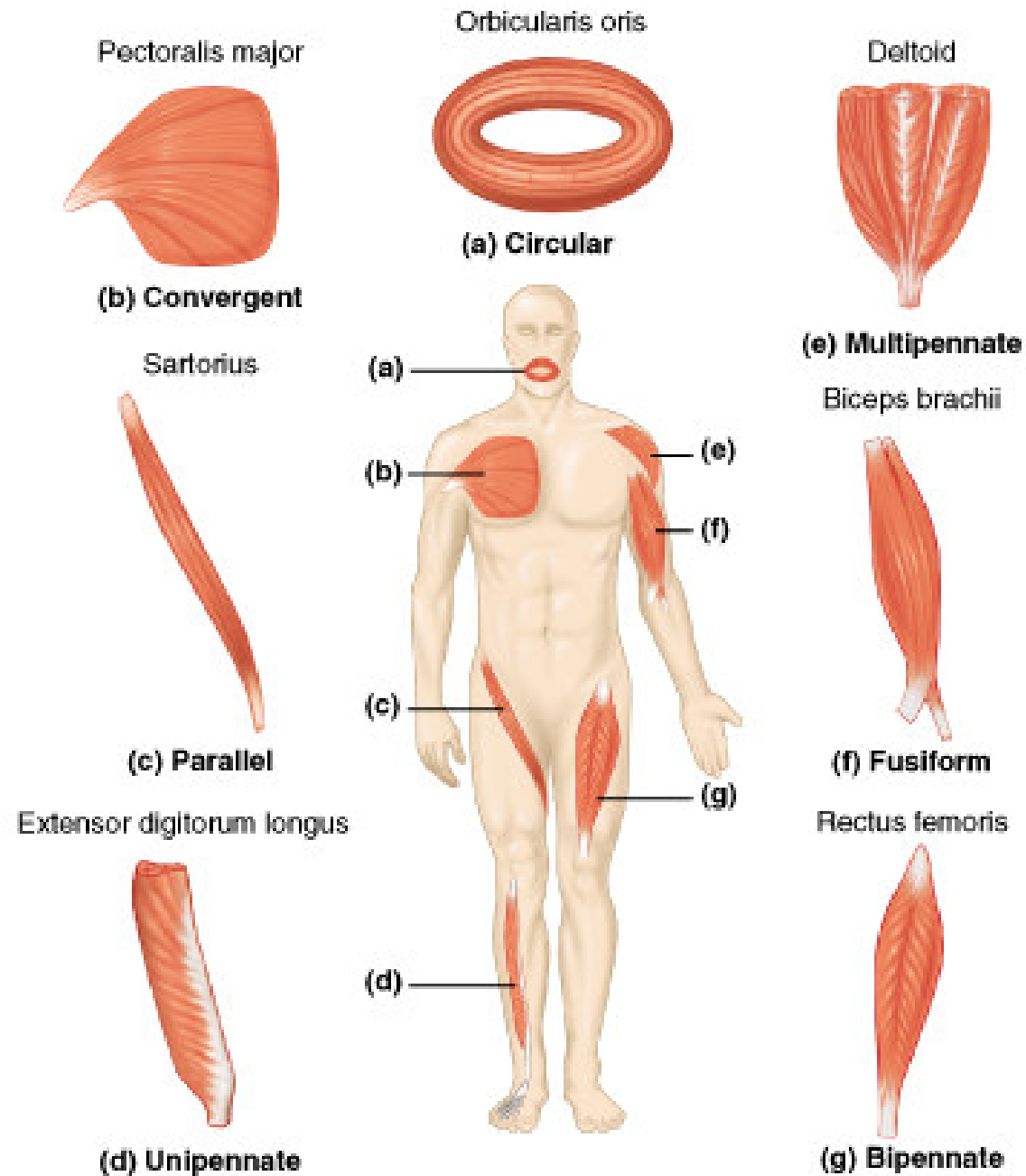


or rope-like

or rope-like

flat tendons=

encircle some
contraction



3. ACCORDING TO A NUMBER OF HEADS

- **Muscles with one head**: one head
- **Muscles with more heads**: more heads (more origins), which connect into one muscle belly. (musculus biceps, musculus triceps, musculus quadriceps)

4. ACCORDING TO A NUMBER OF BELLIES

- **With one belly**: only one belly
- **With more bellies**: two or more consecutive bellies, which are separated from each other by tendons (*tendo intermedius*)



Contraction

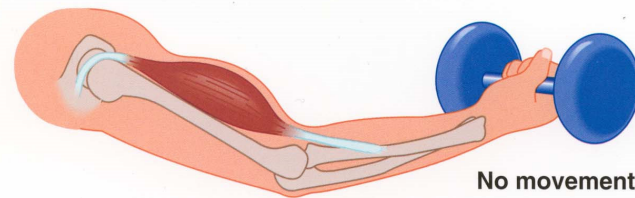
Isotonic: change of length **concentric**: shortens

excentric: extends

Izometric: change of tension

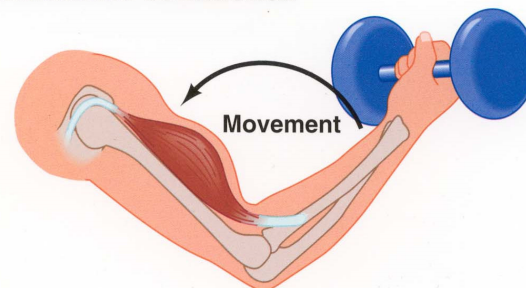
Isometric contraction

Muscle contracts
but does not shorten



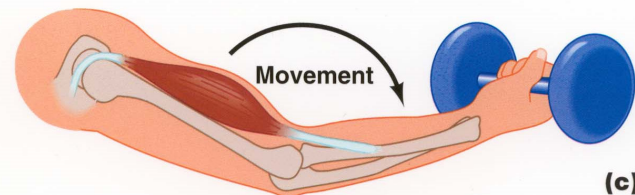
(a)

Concentric contraction



(b)

Eccentric contraction



(c)

SPECIAL APPARATUS

1. Fascia (*fasciae*): fibrous membranes, which cover one whole muscle or group of some muscles.

Septa intermuscularia- separates single groups of muscles, they are attached to a bone

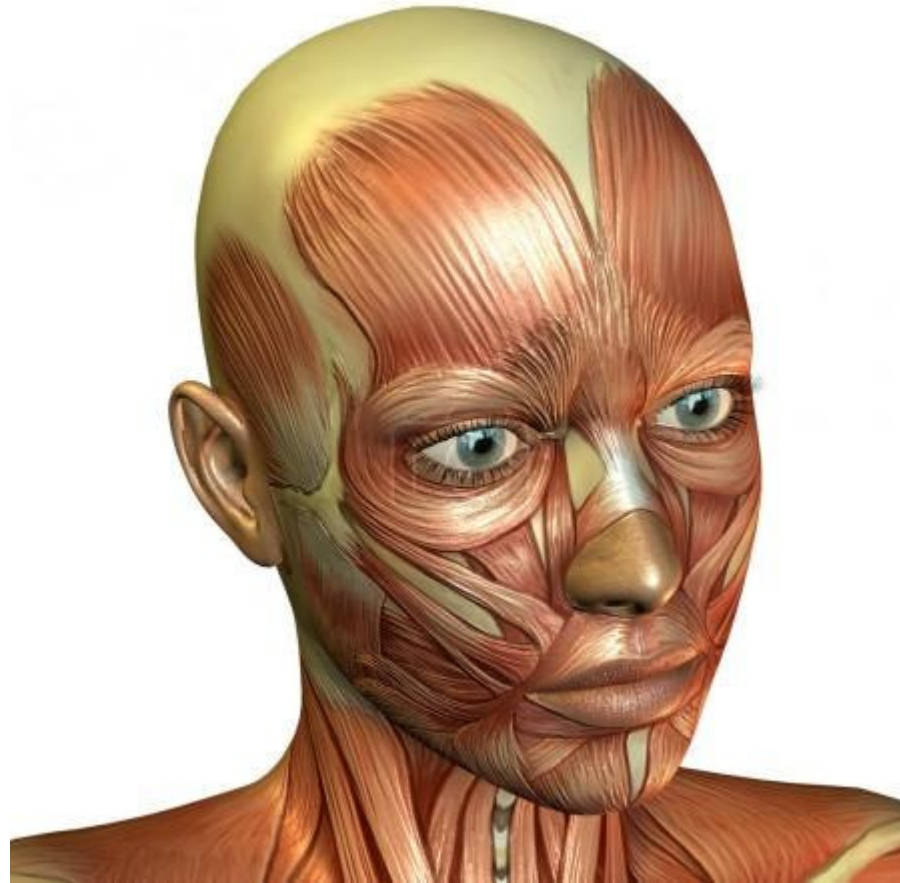Retinacula- eyelets, which holds muscle tendons to a bone.

2. Synovial bursae(*bursae synoviales*): pouches around the joint, derivatives of the joint capsule, in the places, where tendons and muscle lie directly on the bone

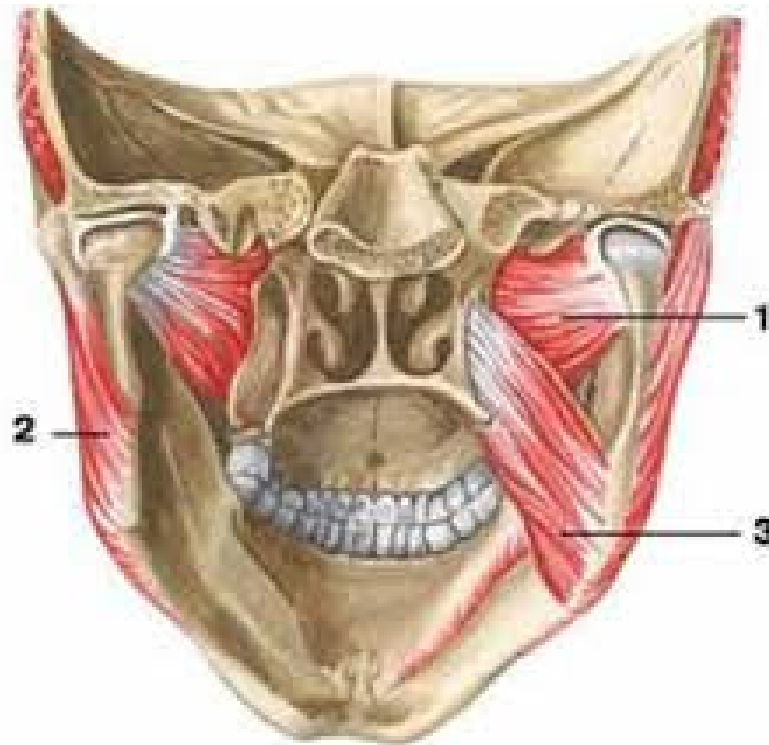
3. Synovial sheath (*vaginae tendinum*): cover long tendons of muscles in areas exposed to mechanical loading.

Layer- superficial- vagina fibrosa- **peritenonium**
- deep- vagina synovialis- **epitenonium**

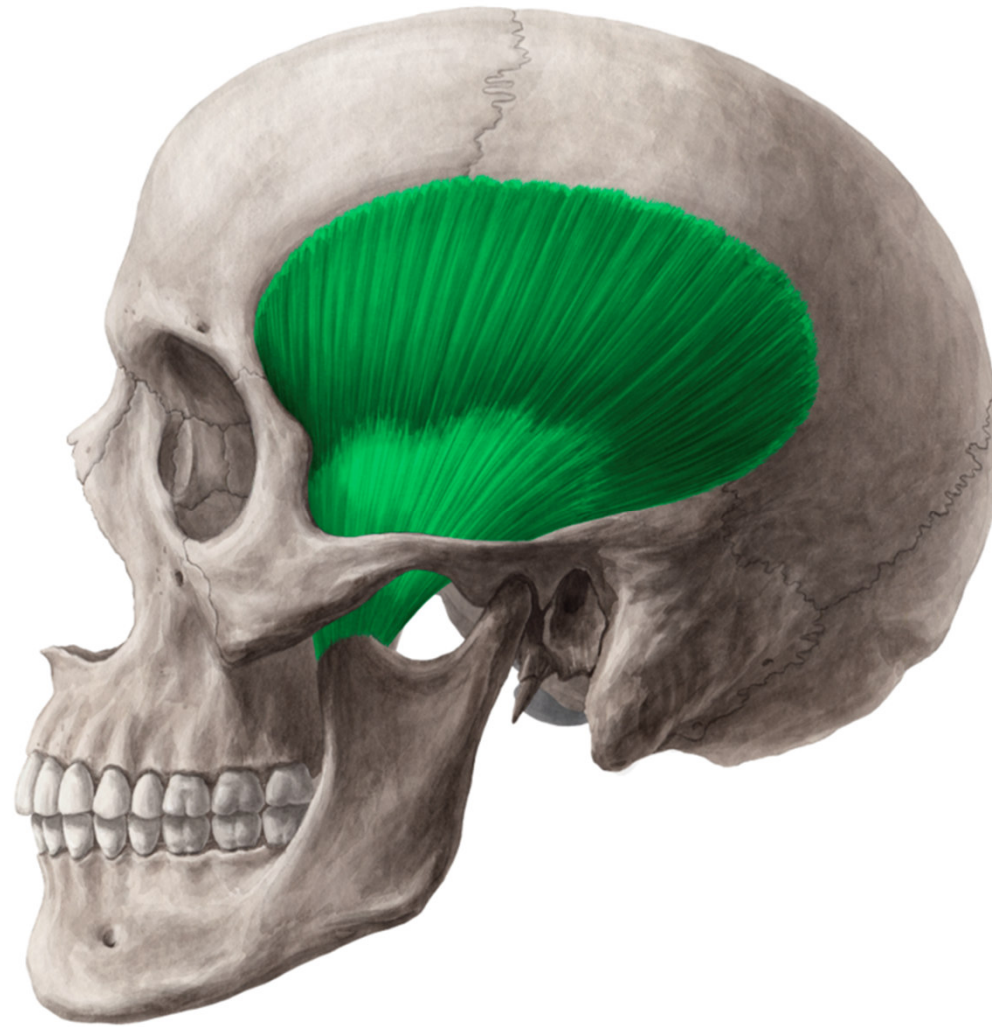
Muscles of the head



Mm. masticatorii



M. temporalis



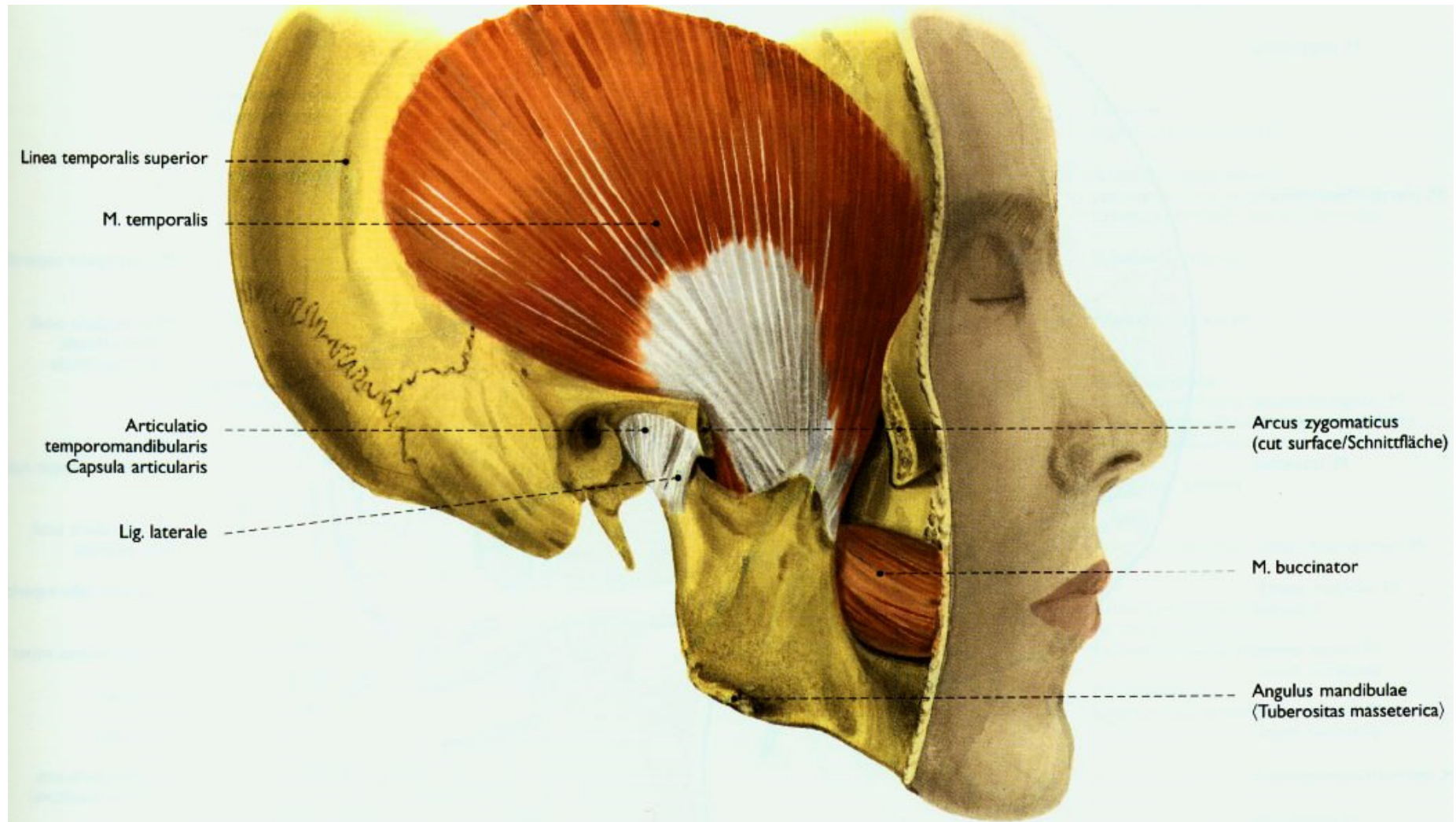
M. temporalis

origin: linea temporalis inferior, temporal fascia

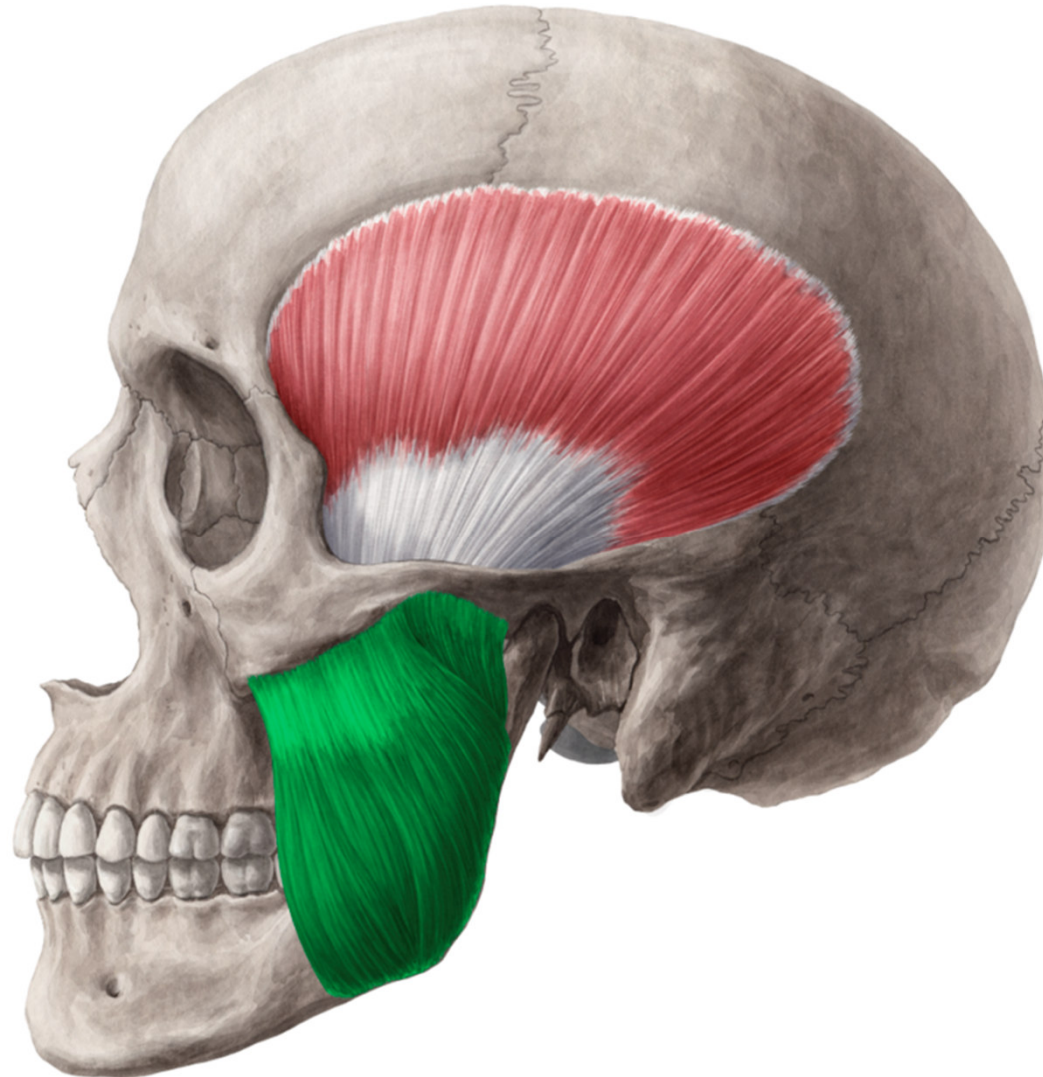
insertion: processus coronoideus mandibulae

innervation: N. trigeminus (nn. temporales profundi from 3rd branch)

function: elevation, partly retraction of mandible



M. masseter

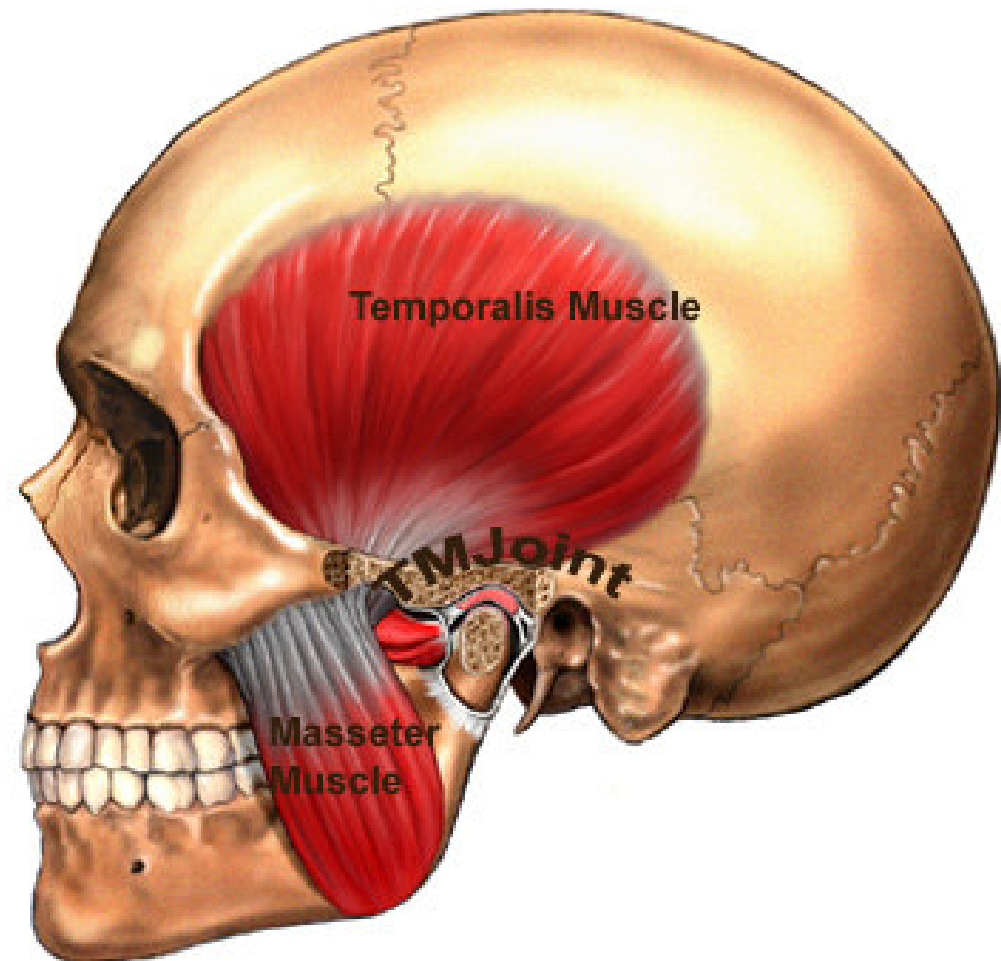


origin: arcus zygomaticus
and os zygomaticum

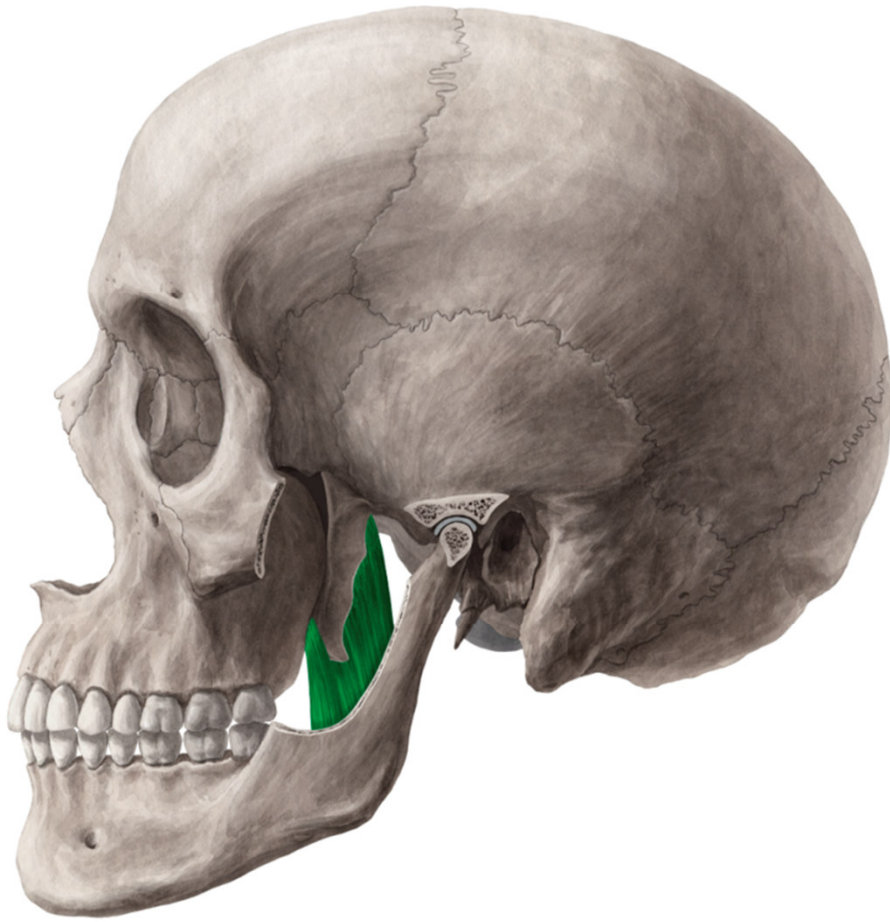insertion: tuberositas
masseterica

innervation: N. trigeminus
(n. massetericus from 3rd
branch)

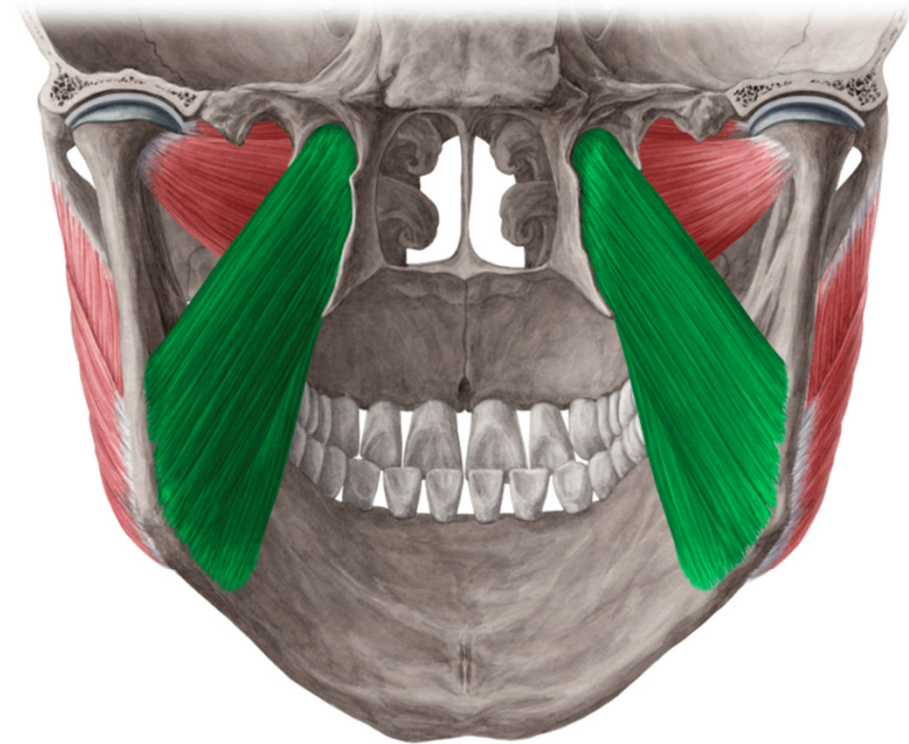
function: elevation of
mandible, chewing
movements



M. pterygoideus medialis



kenhub.com

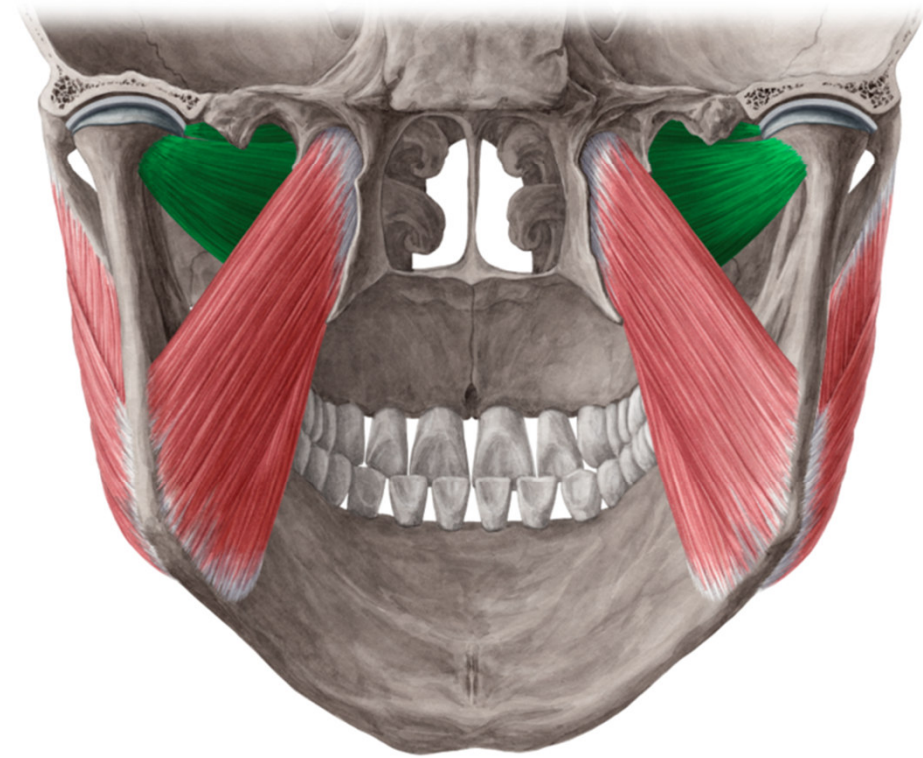
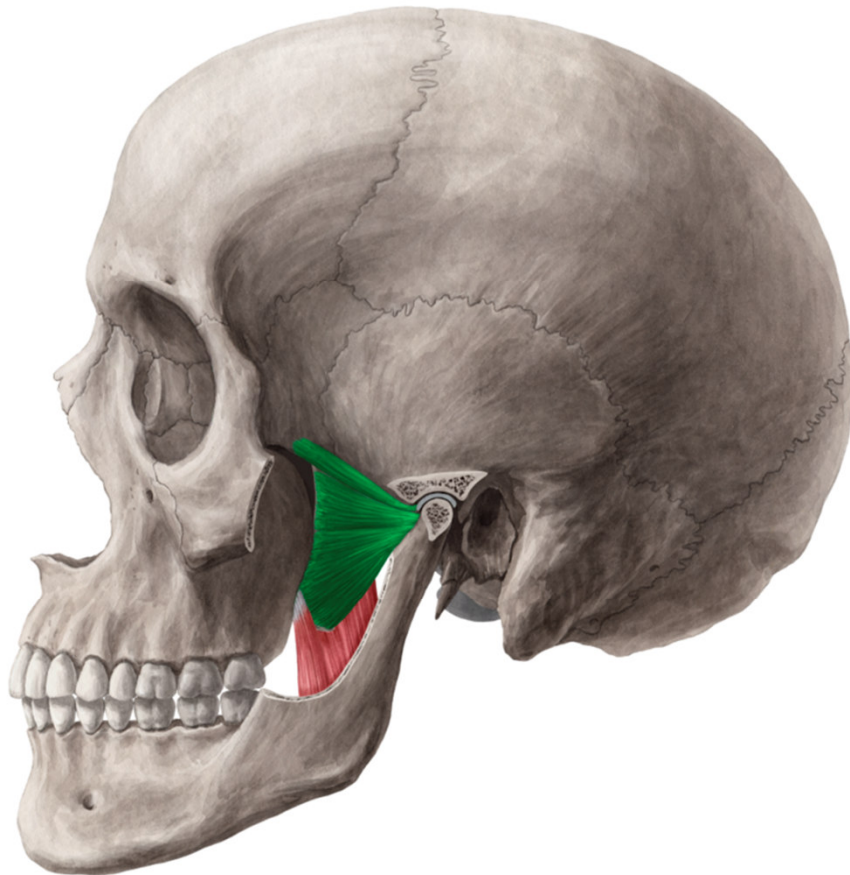


www.kenhub.com

kenHub

kenHub

M. pterygoideus lateralis



3) **M. pterygoideus medialis**

origin: fossa pterygoidea and tuber maxillae

insertion: tuberositas pterygoidea

innervation: N. trigeminus (n. pterygoideus medialis from the 3rd branch)

function: elevation of mandible

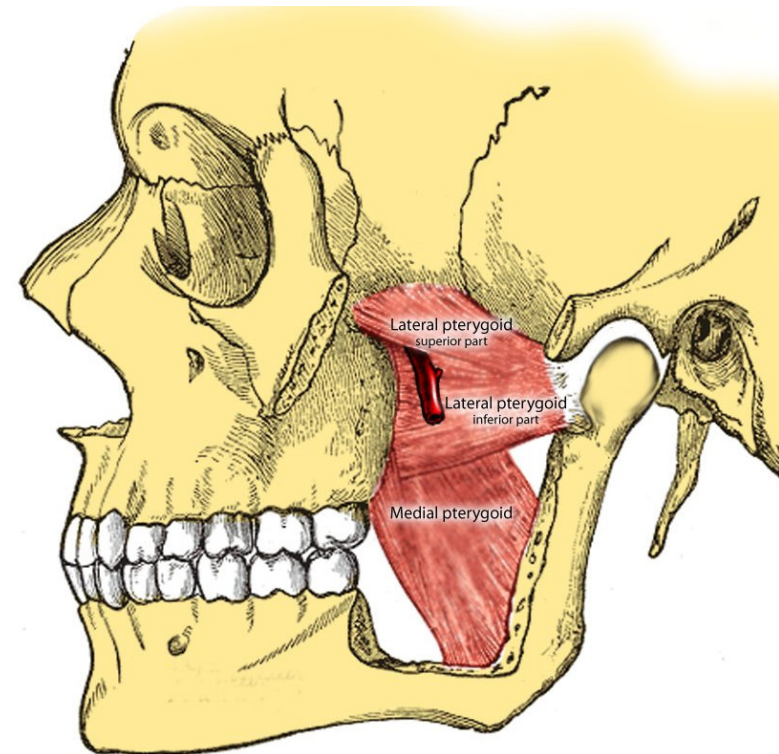
4) **M. pterygoideus lateralis**

origin: lamina lateralis processus pterygoidei, facies infratemporalis
 alae majoris ossis sphenoidalis

insertion: fovea pterygoidea mandibulae

innervation: N. trigeminus (n. pterygoideus lateralis from the 3rd branch)

function: by double-sided contraction: protraction of mandible



- **Mimic muscles**

Mimic muscles

m. occipitofrontalis

m. temporoparietalis

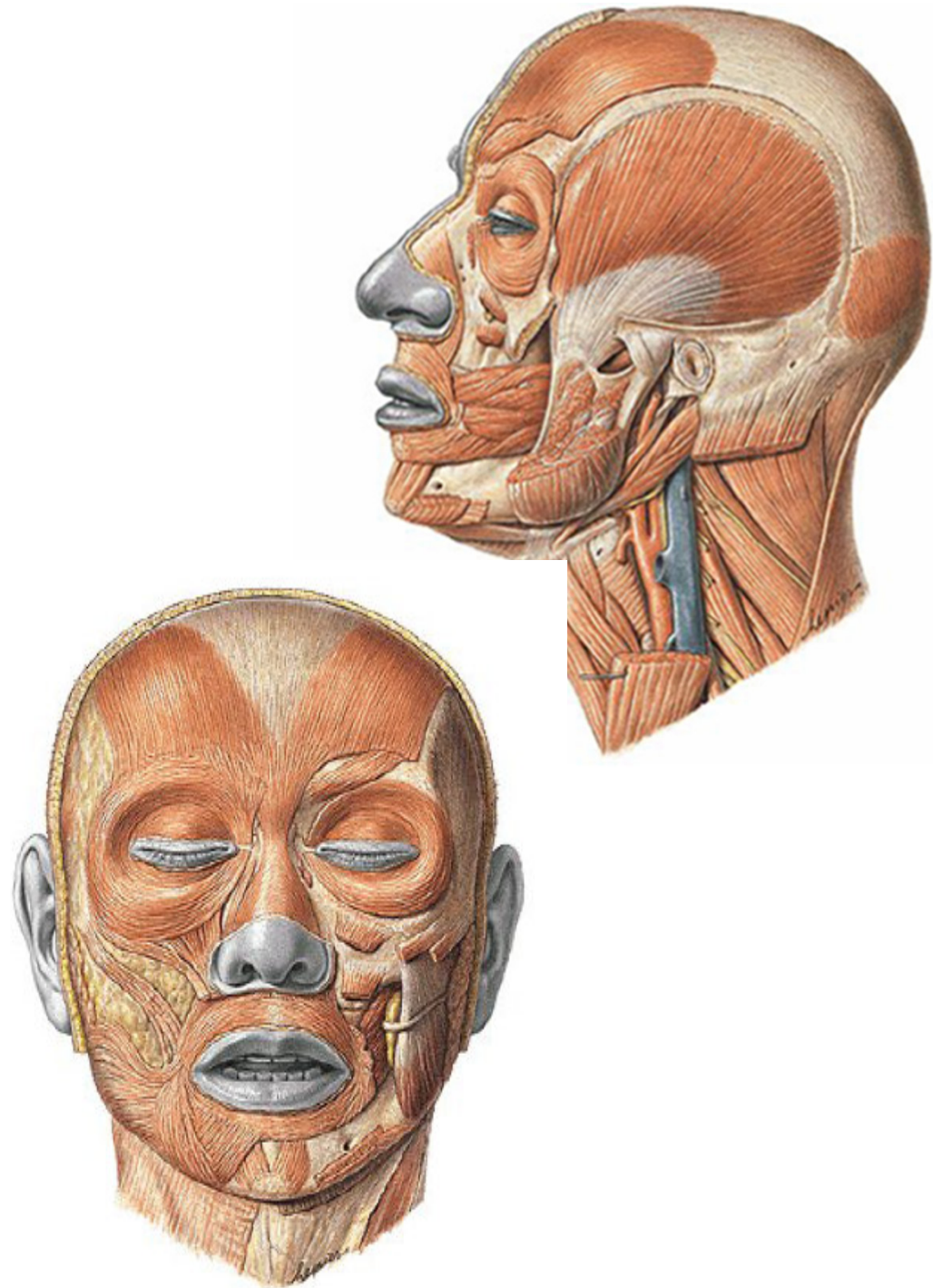
Muscles of palpebral fiss

m. orbicularis oculi

m. depressor supercilii

m. corrugator supercilii

m. procerus

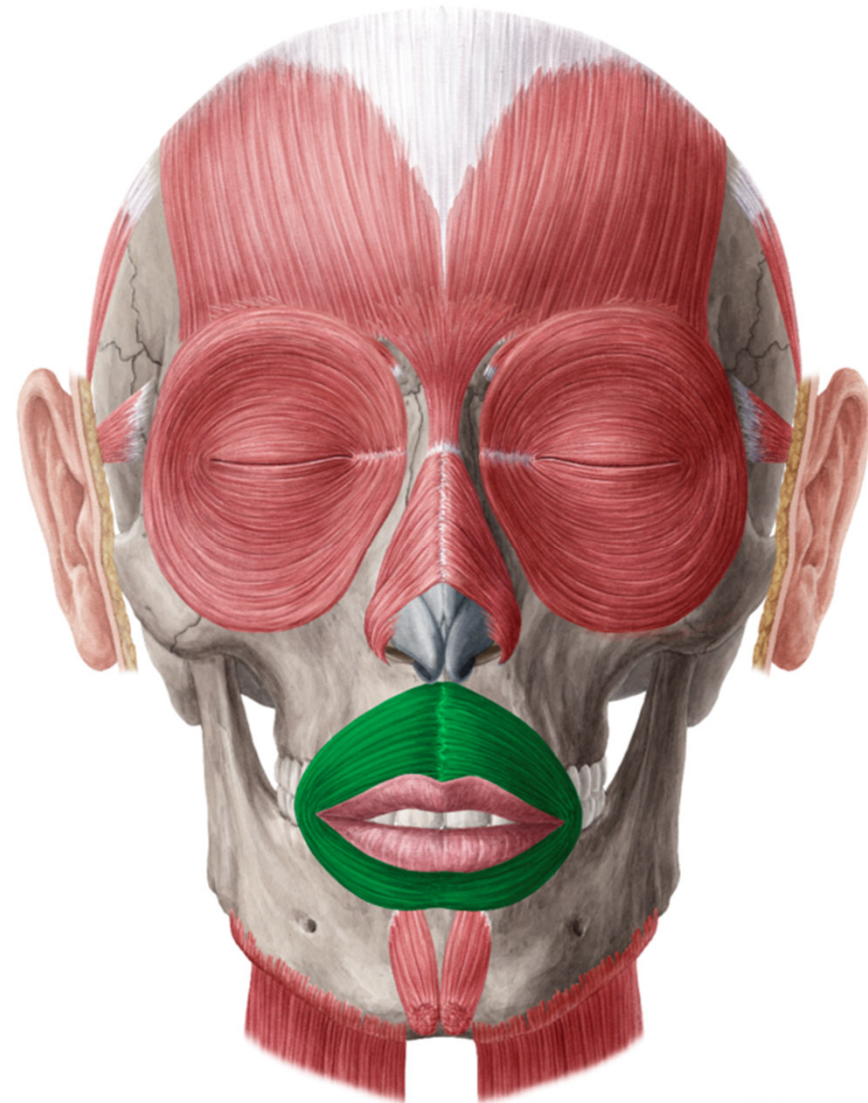


3) Muscles of the mouth

m. orbicularis oris
m. depressor anguli oris
m. depressor labii inferioris
m. risorius
m. levator labii superioris
 alaeque nasi
m. levator labii superioris
m. zygomaticus major
m. zygomaticus minor
m. levator anguli oris
m. buccinator
m. mentalis

4) Muscles of the nose

m. nasalis
m. levator labii superioris
 alaeque nasi



Head fasciae

Fascia temporalis

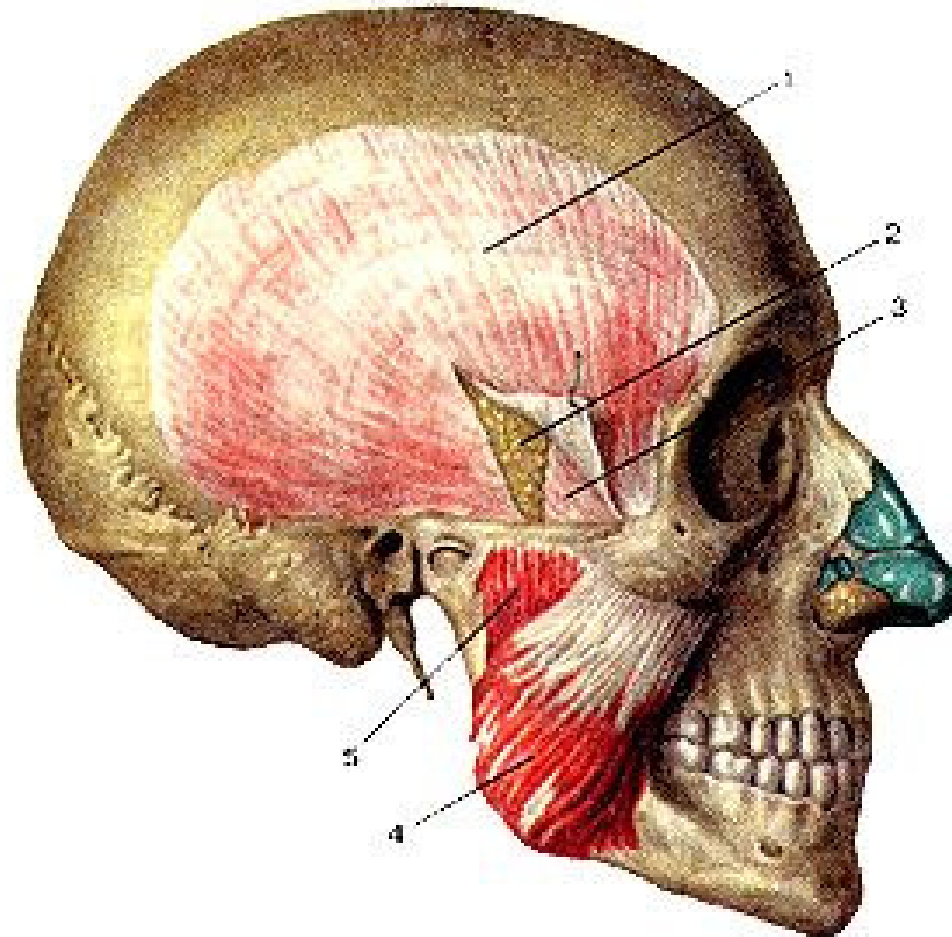
- together with skull bones, it creates a cavity for m. temporalis

Fascia masseterica

- continues as fascia parotidomasseterica (to the gland)

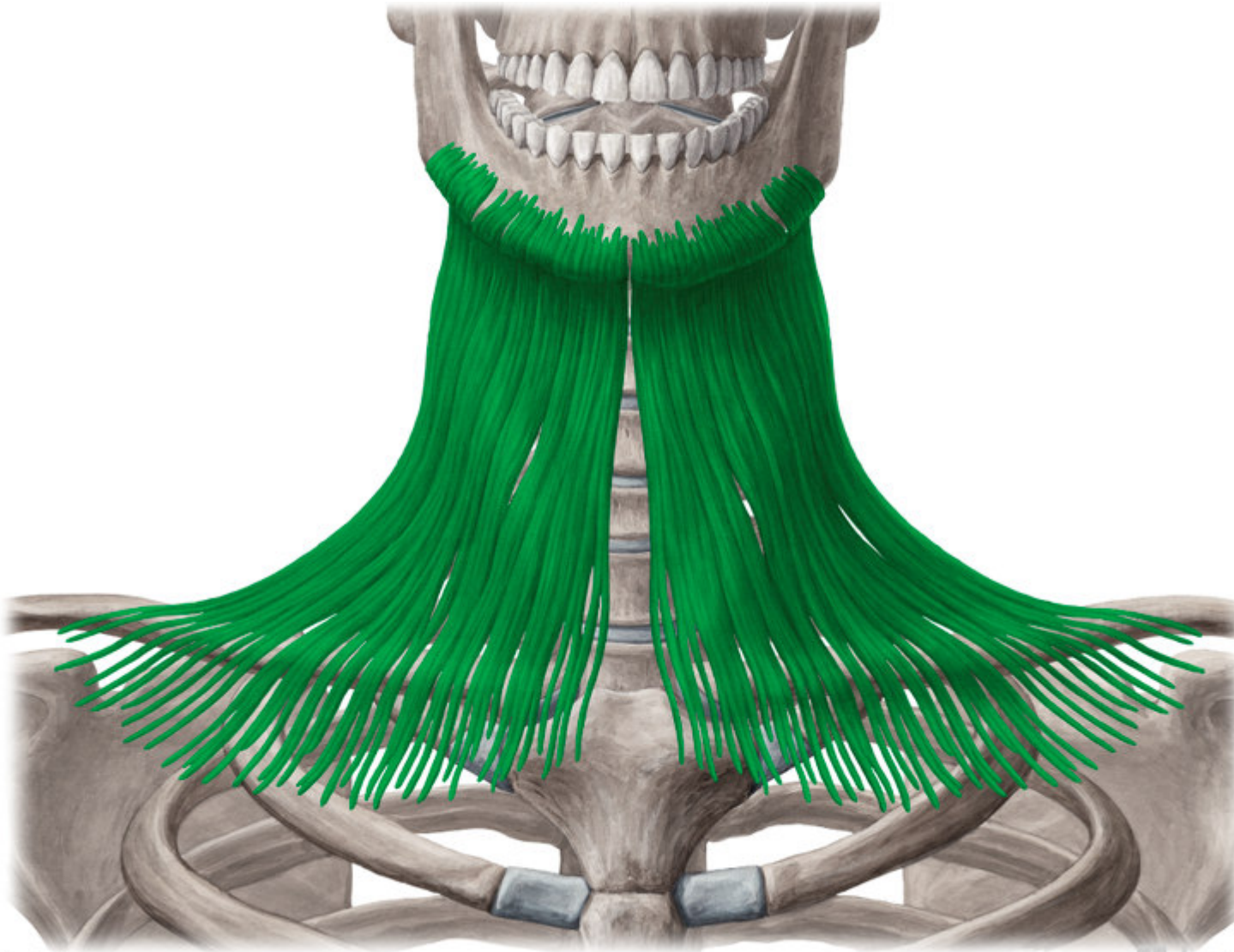
Fascia buccopharyngea

- from the lips to pharynx



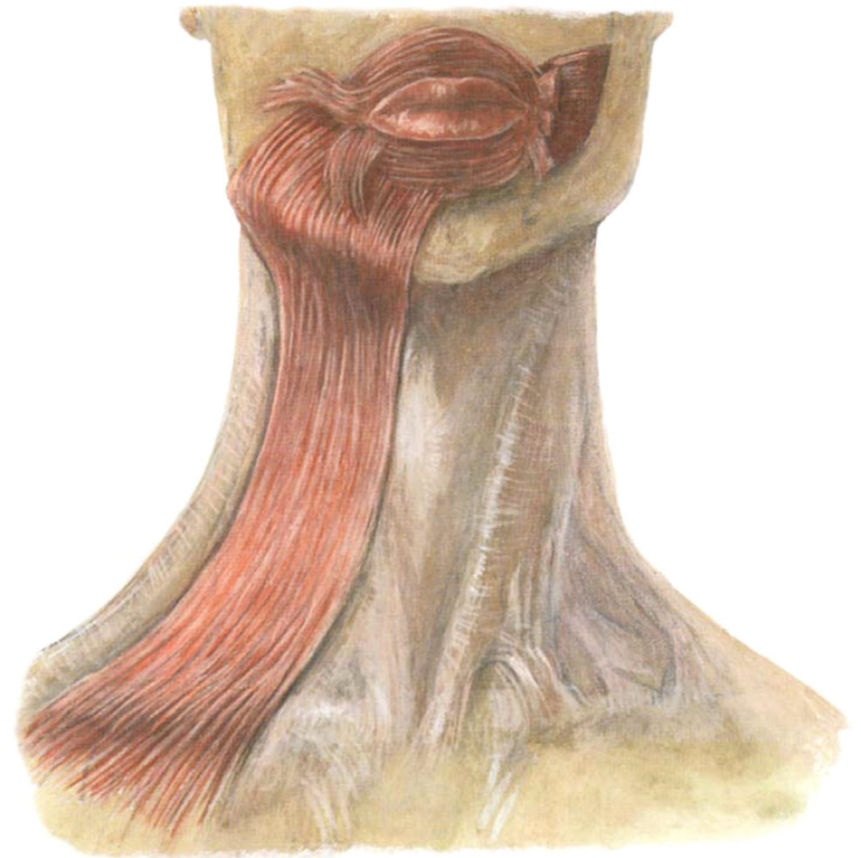
Musculi colli
(muscles of the neck)

M. platysma

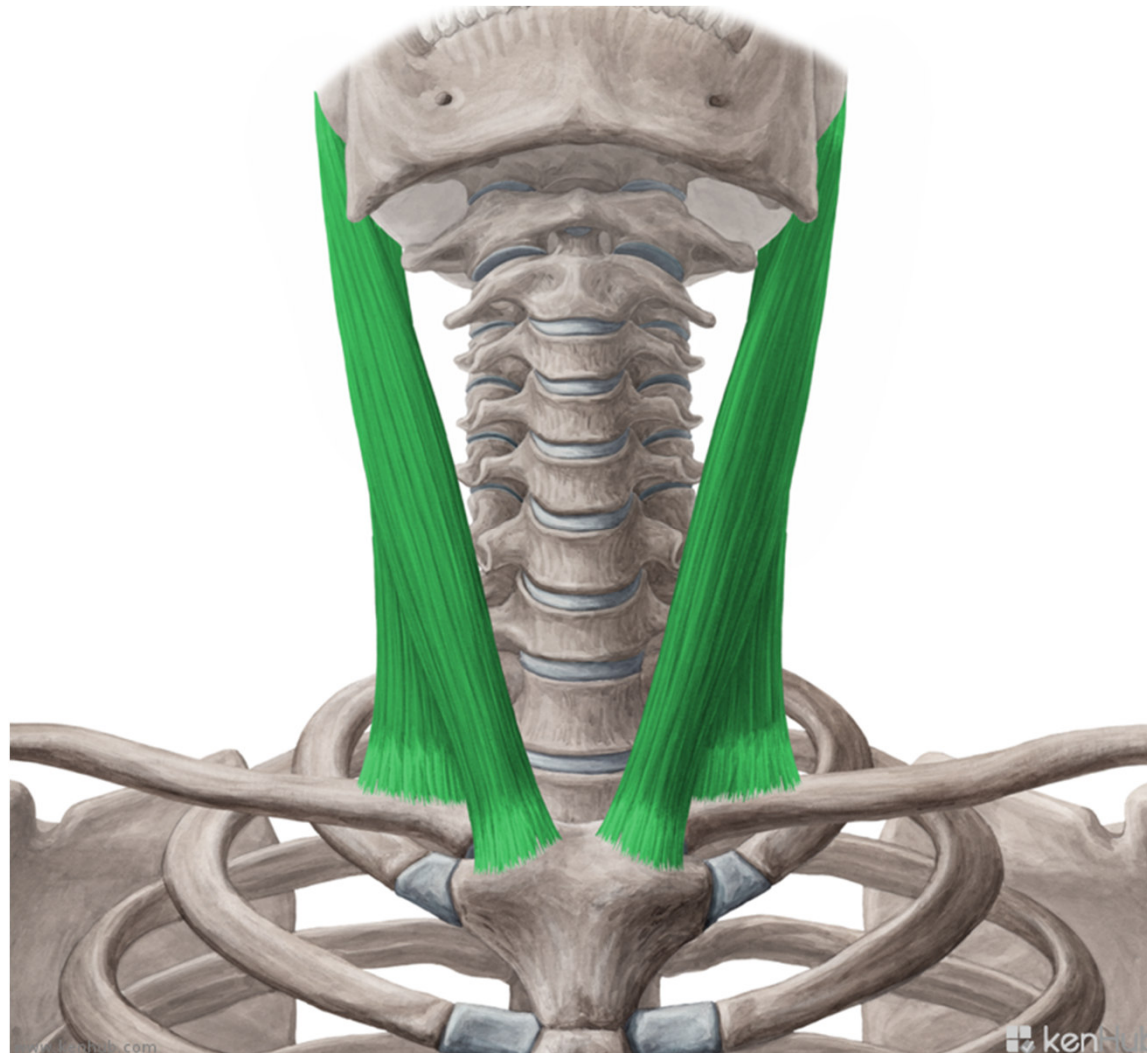


Platysma

- Subcutaneous muscle, on superficial cervical fascia from clavicle to the face
- O:** fascia pectorialis, fascia deltoidea
I: skin of the face
F: it stretches cervical skin
IN: ramus colli n. facialis



M. sternocleidomastoideus



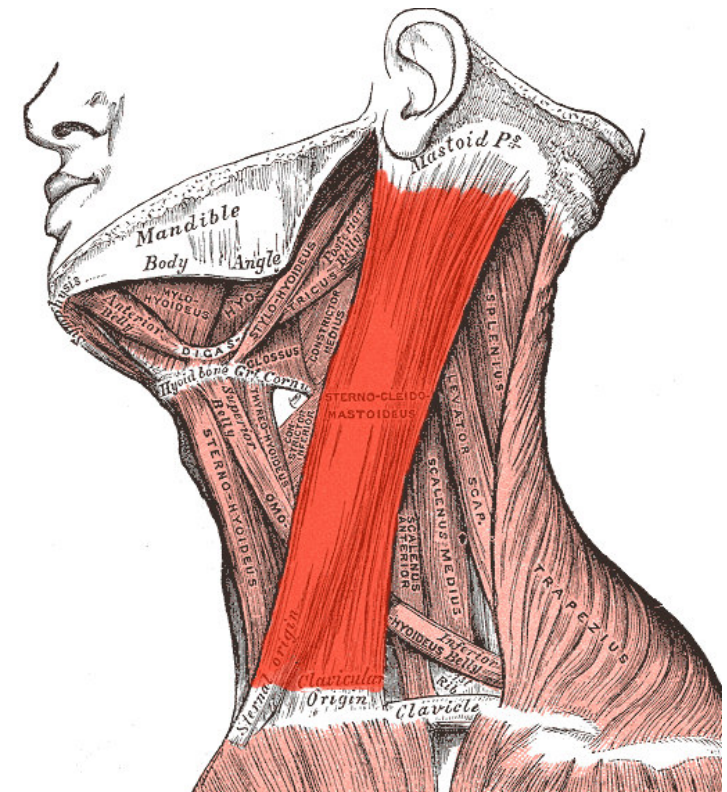
M. sternocleidomastoideus

O: manubrium sterni, sternal end of clavicle

I: processus mastoideus, external edge of linea nuchae superior

F: at unilateral contraction – lateroflexion, bilateral contraction – retroflexion, auxiliary inspiratory muscles (at fixed head and cervical spine)

IN: n. accessorius + C2 - C4



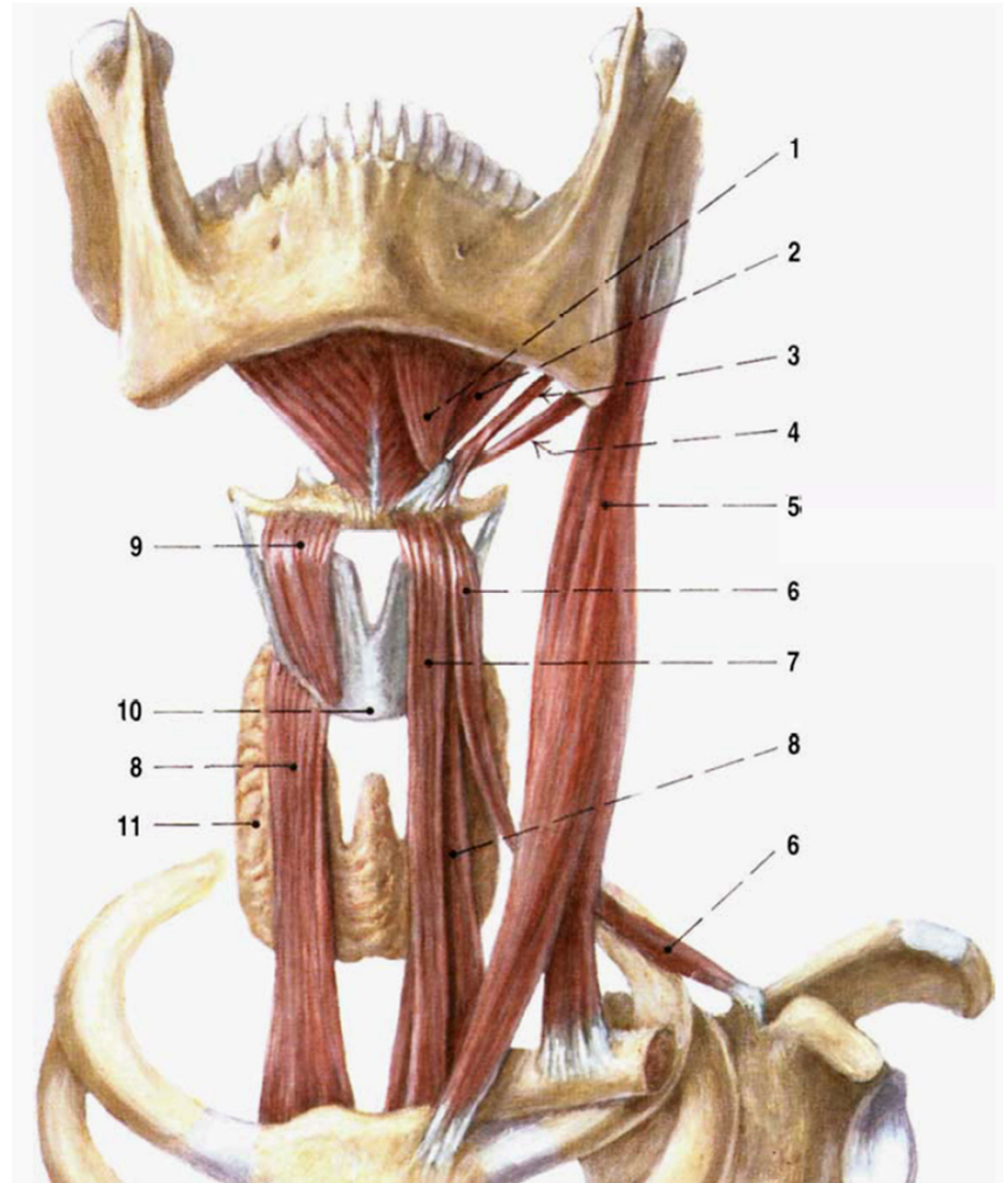
Musculi suprahyoidei

M. DIGASTRICUS

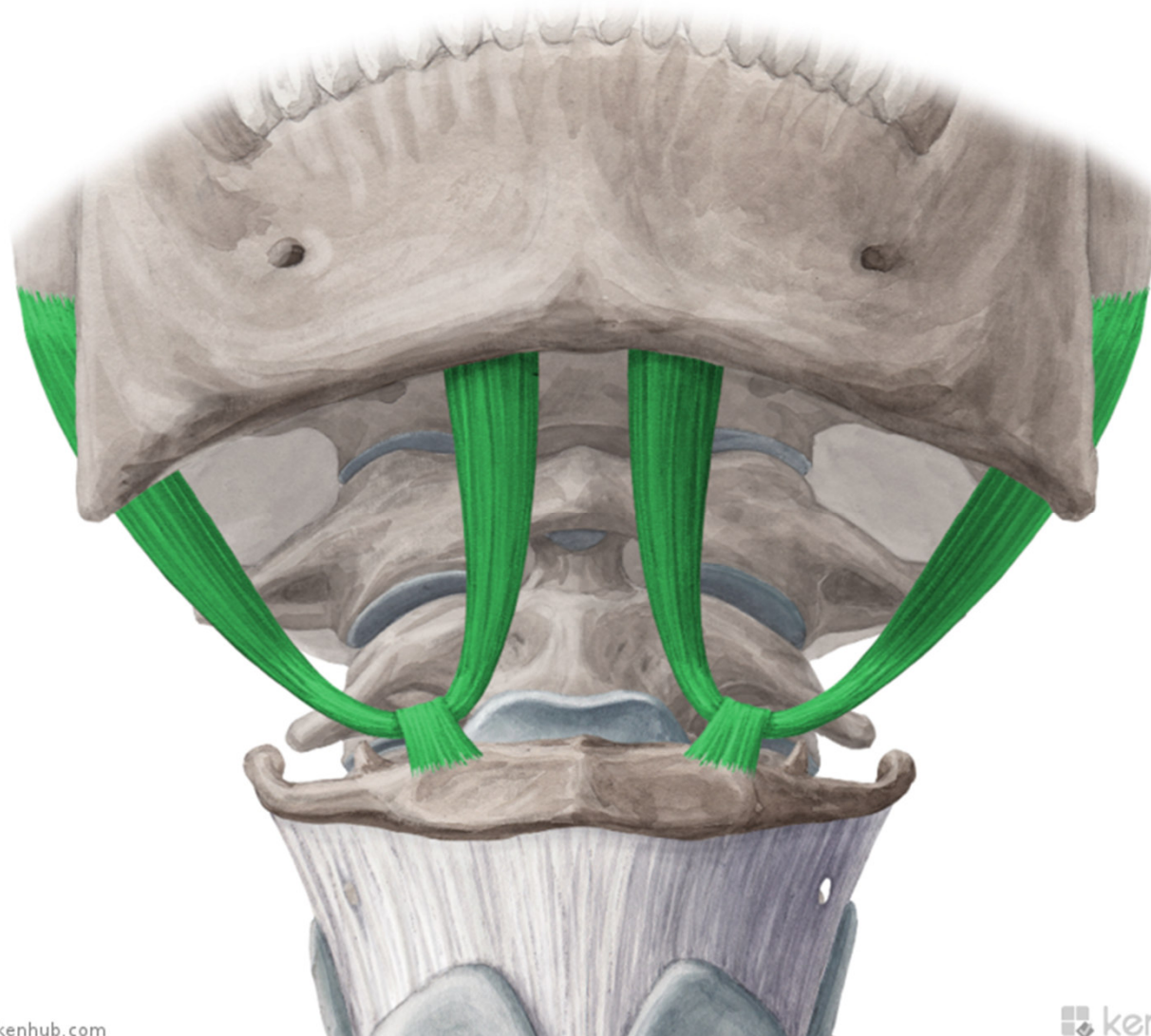
M. STYLOHYOIDEUS

M. MYLOHYOIDEUS

M. GENIOHYOIDEUS



M. digastricus



M. DIGASTRICUS

Muscle with two bellies

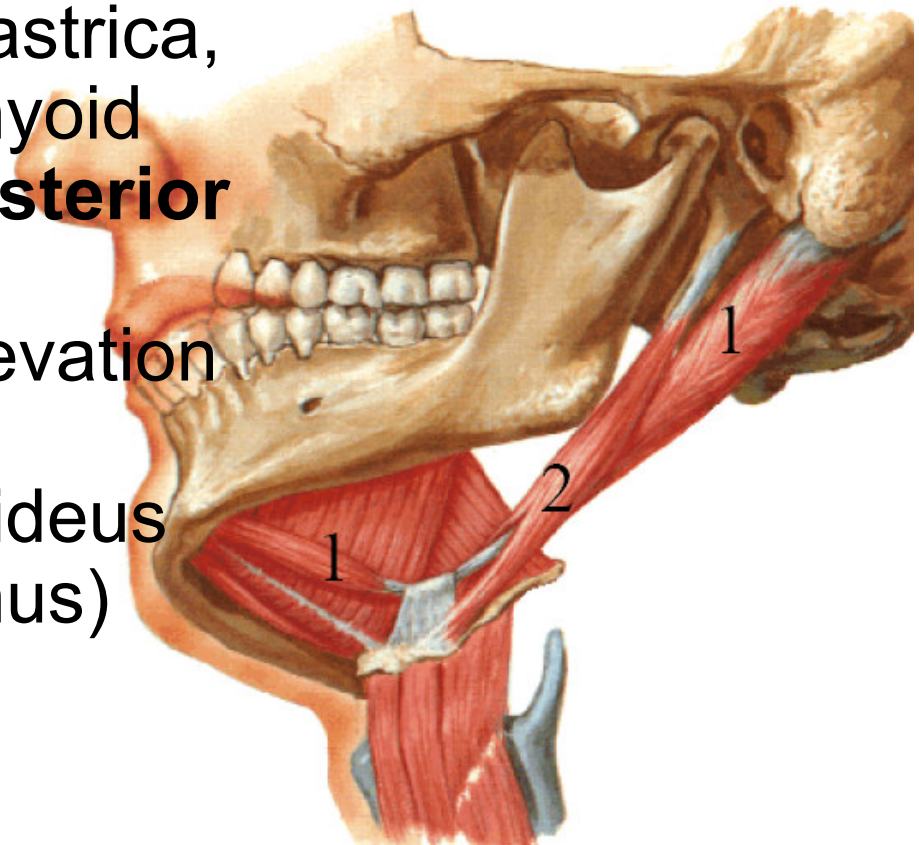
O: venter anterior: fossa digastrica,
it is changing into tendon on hyoid
bone, continues as **venter posterior**

I: incisura mastoidea

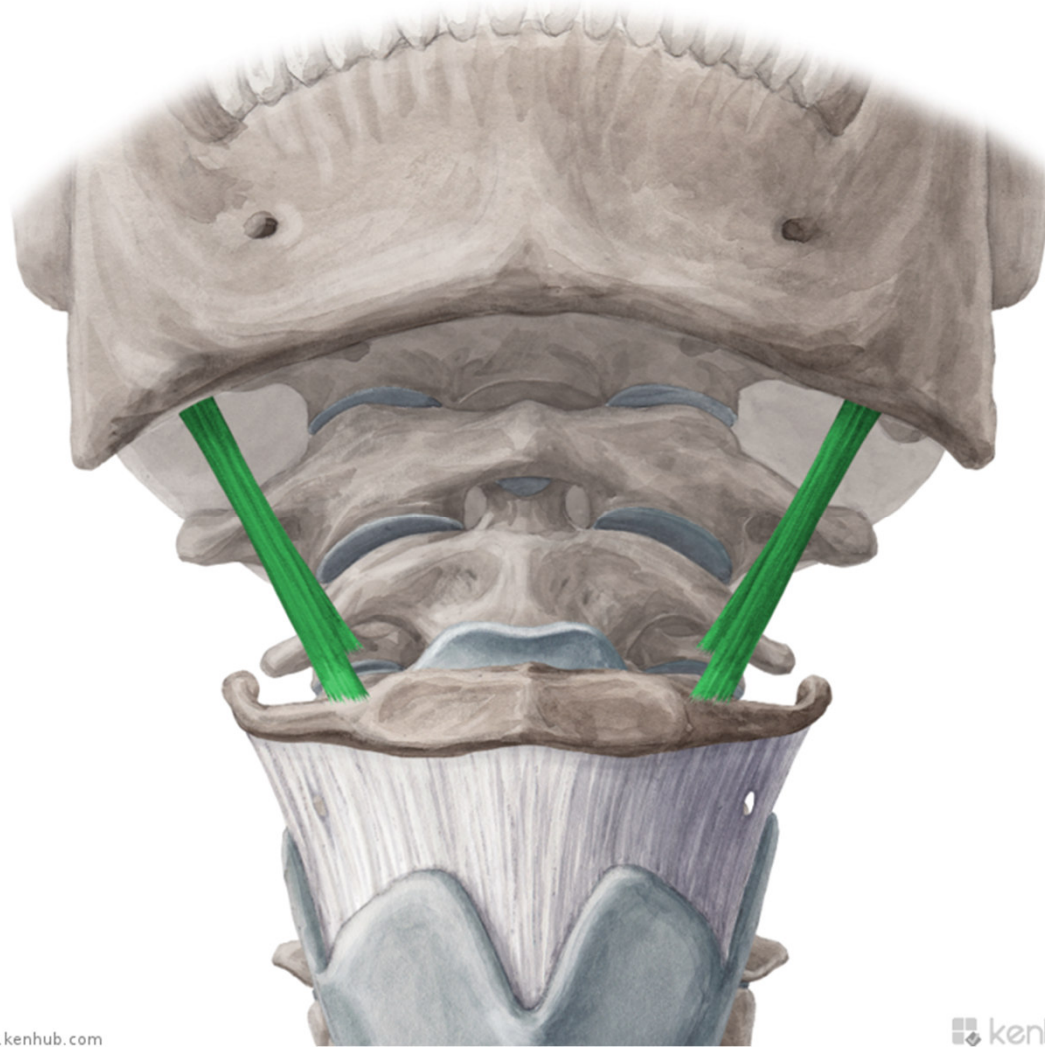
F: depression of mandible, elevation
Of hyoid bone

I: venter anterior - n. mylohyoideus
(n. trigeminus)

venter posterior - n. facialis



M. stylohyoideus



M. STYLOHYOIDEUS

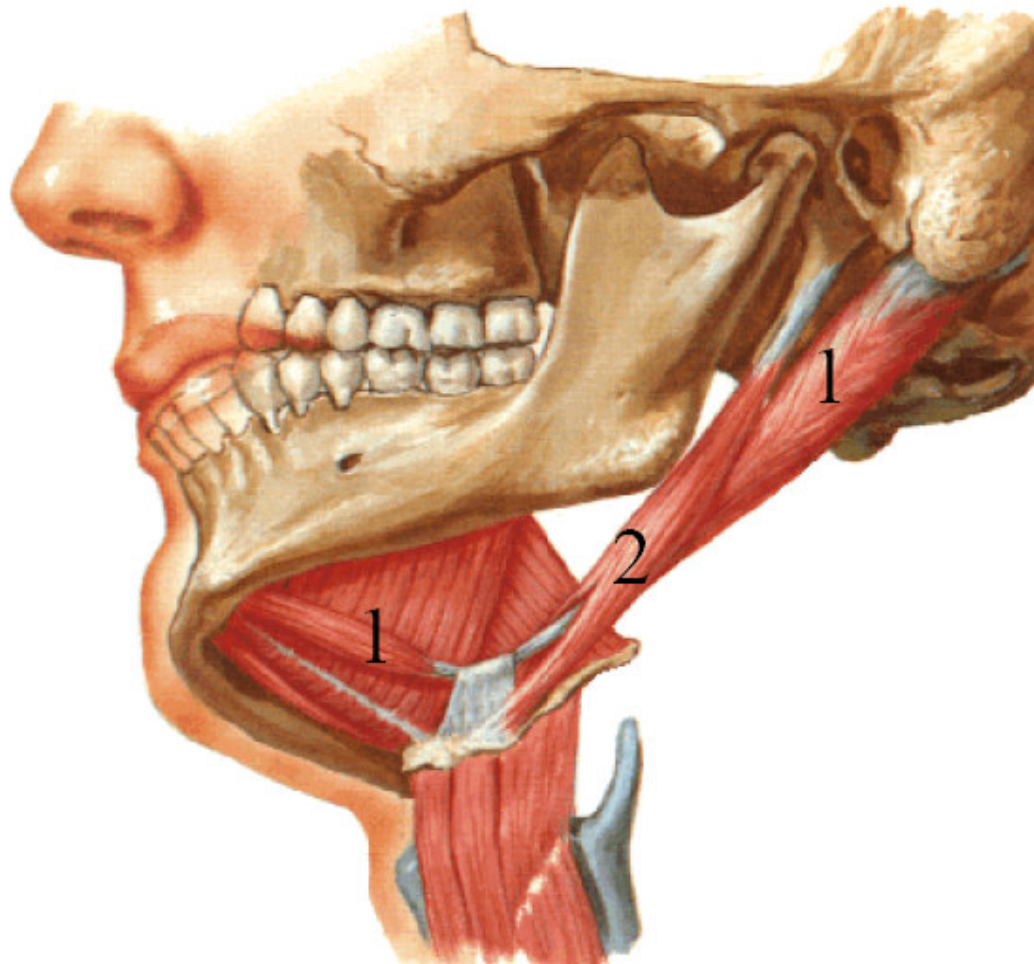
Through its cleft tendon m. digastricus passes

O: processus styloideus

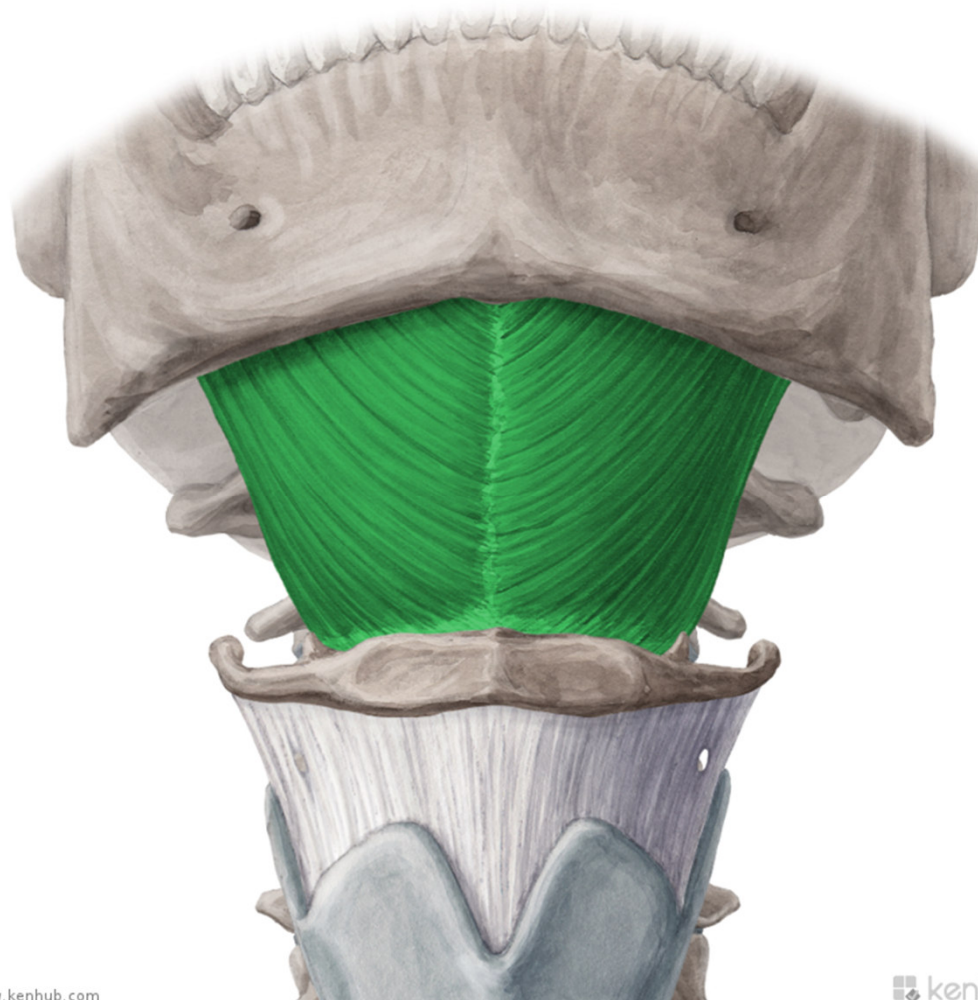
I: body of the hyoid bone

F: it elevates the hyoid bone during swallowing

I: n. facialis



M. mylohyoideus



M. MYLOHYOIDEUS

Forms the flexible bottom of the mouth- diaphragma oris

O: linea mylohyoidea

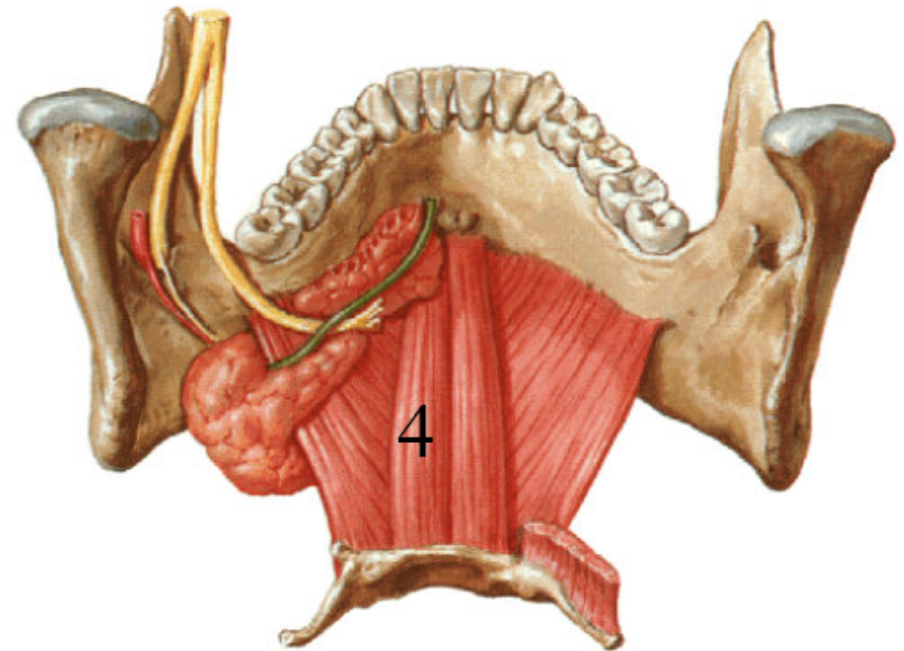
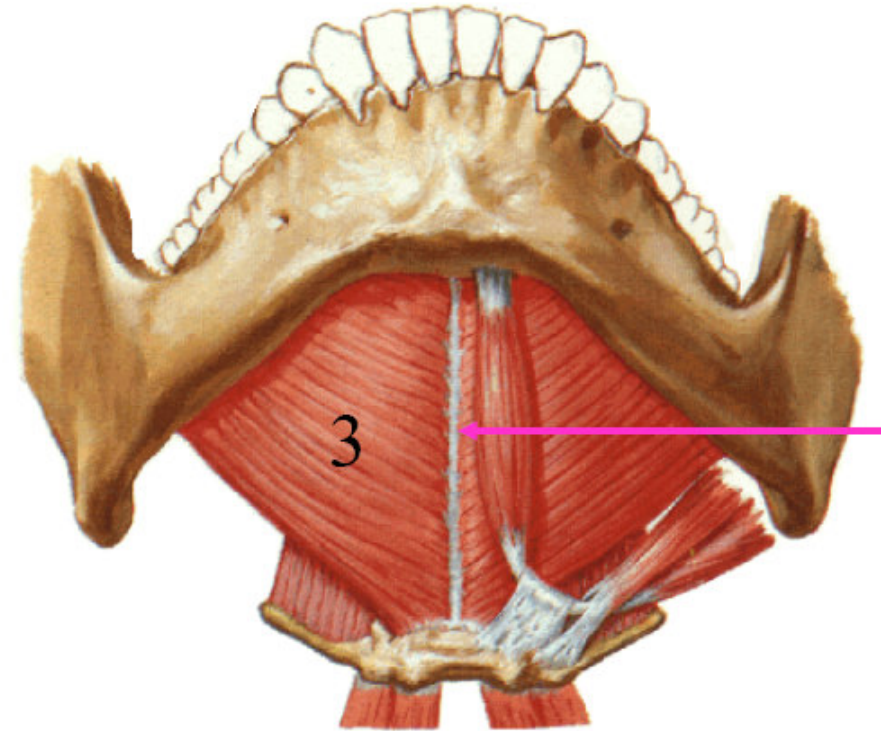
I: os hyoideum

raphe mylohyoidea -

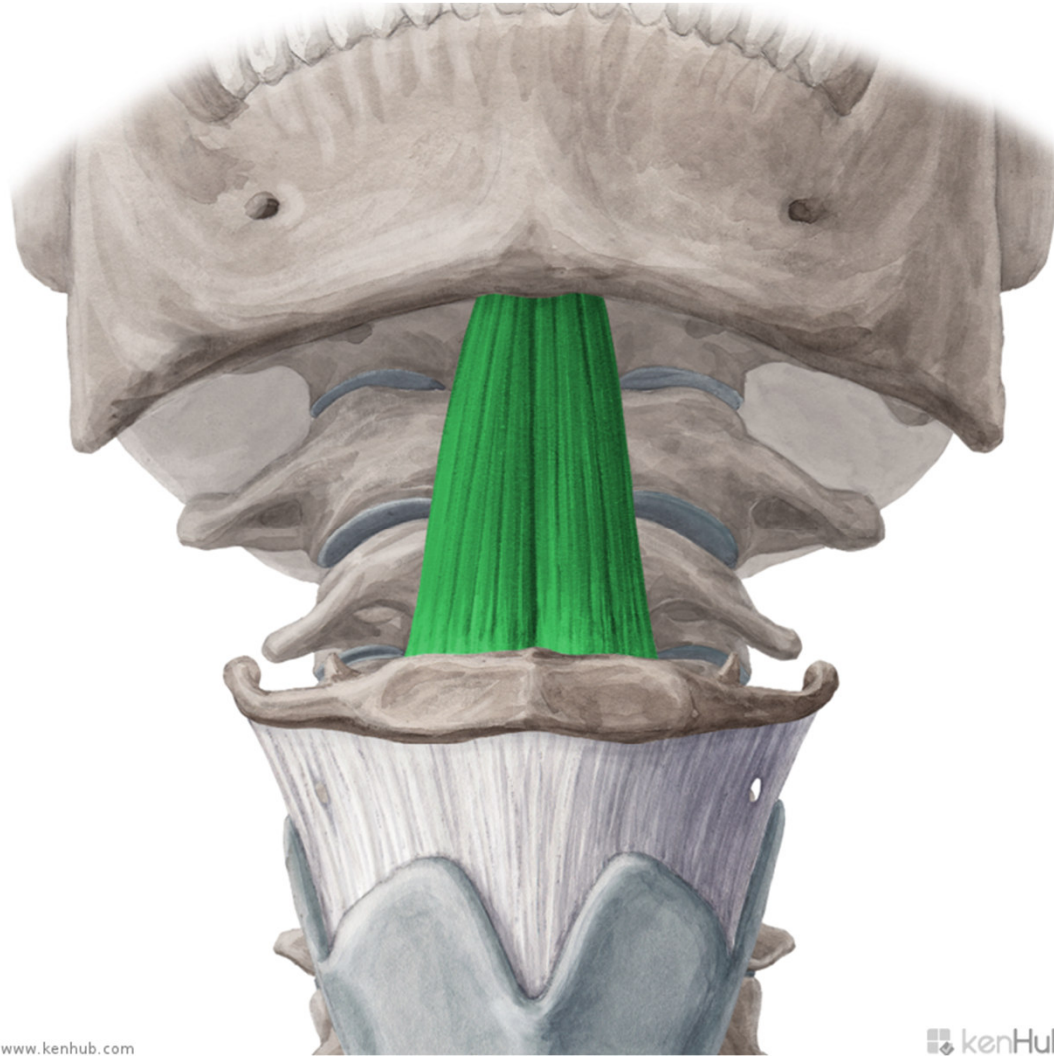
fibrous connection of both muscles

F: depression of mandible at fixed mandible, elevation of hyoid bone

I: n. mylohyoideus (n. trigeminus)



M. geniohyoideus



M. GENIOHYOIDEUS

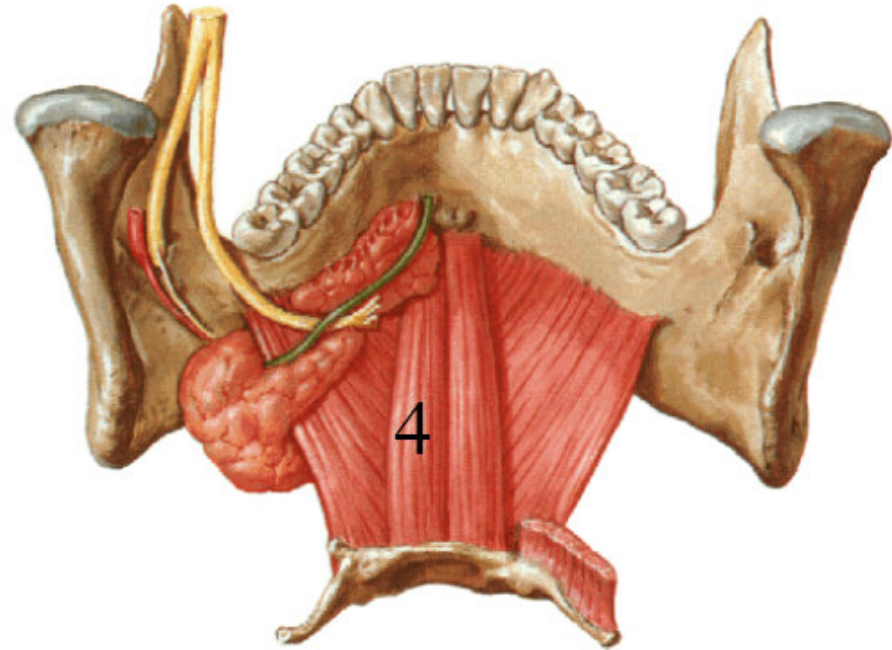
Above m. mylohyoideus

O: spina mentalis

I: body of the hyoid bone

F: it participates in forming
of the bottom of the mouth

I: fibers from C1

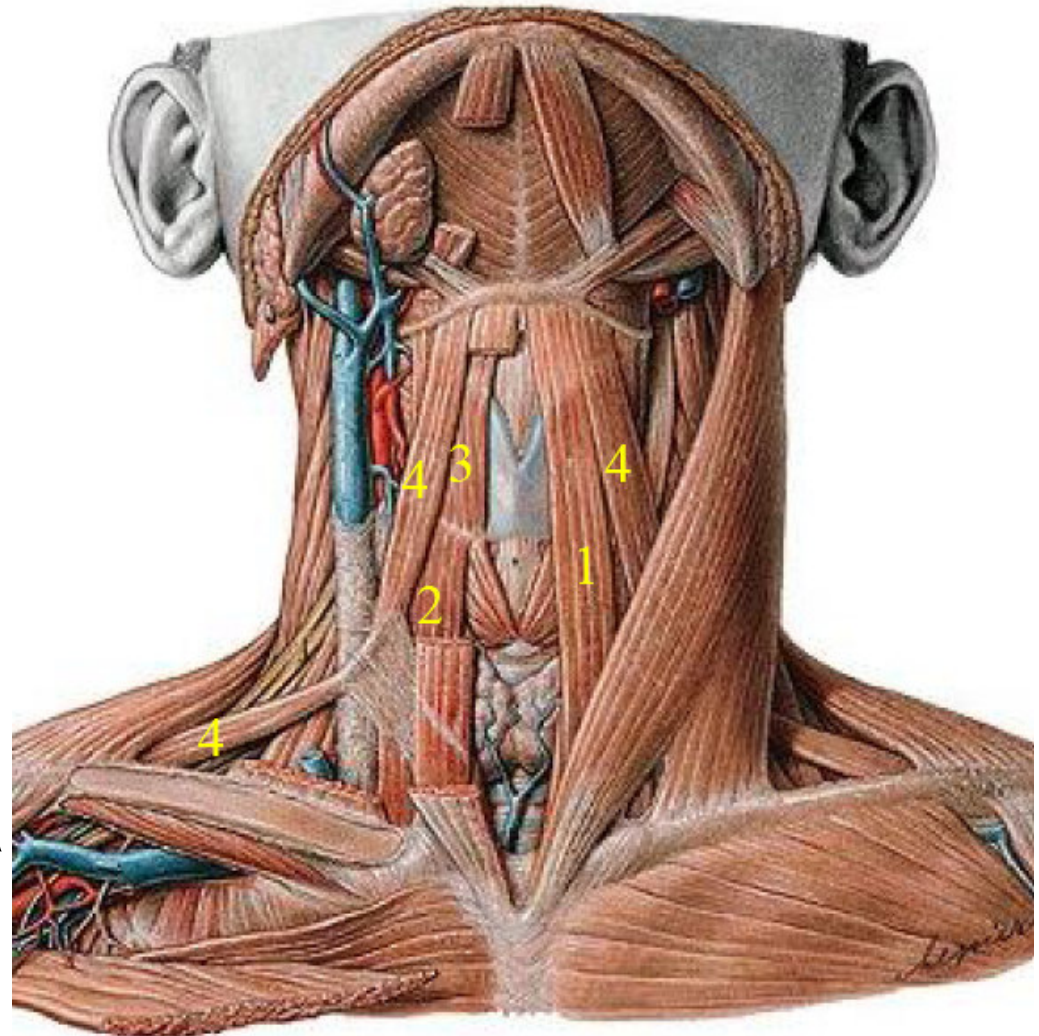


Mm. infrahyoidei

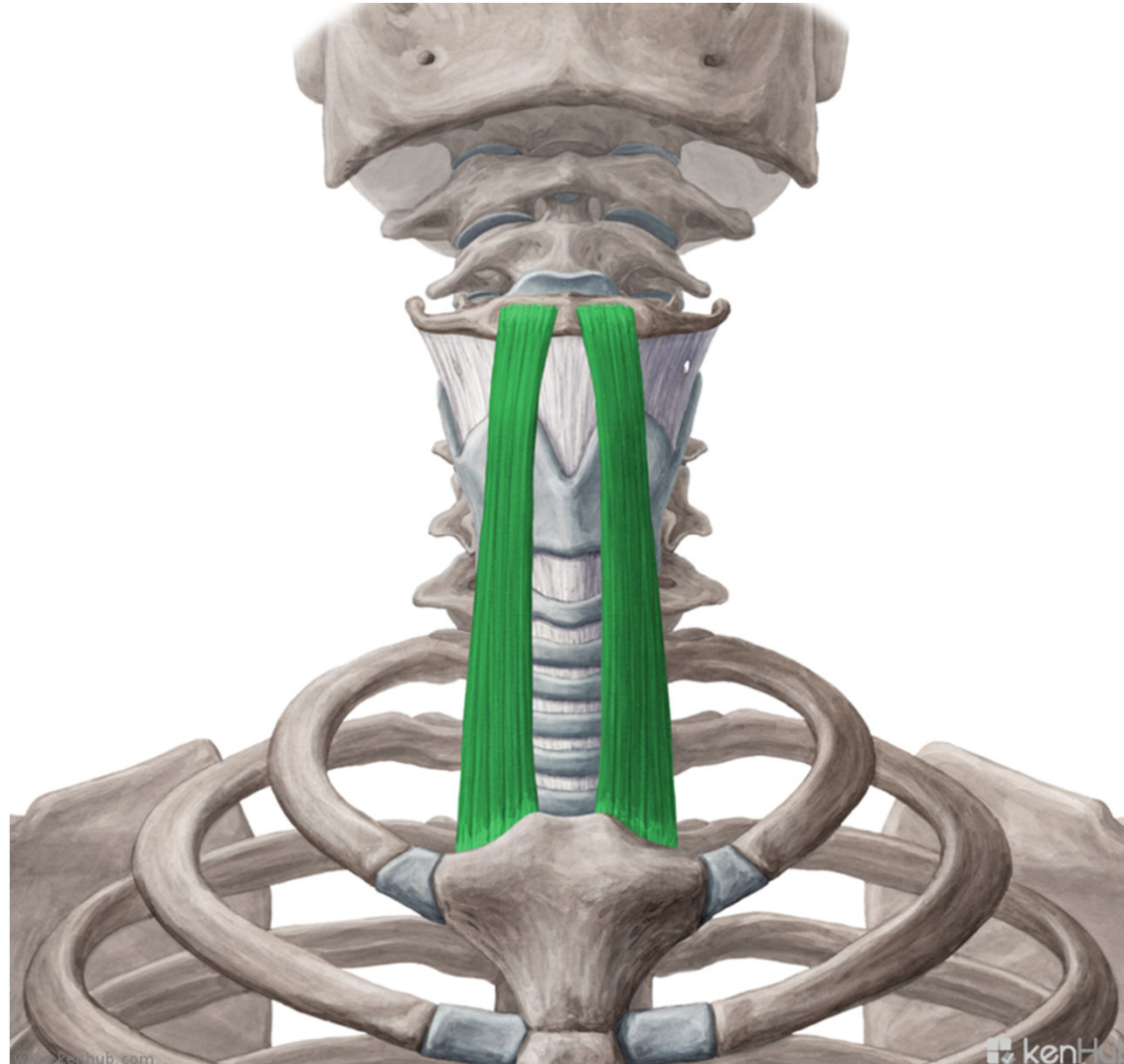
1. m. sternohyoideus
2. m. sternothyroideus
3. m. thyrohyoideus
4. m. omohyoideus

F: they fix the hyoid bone,
they participate in
swallowing reflex

I: ansa cervicalis profunda
C1 - C3 - except m.
thyrohyoideus -> C1



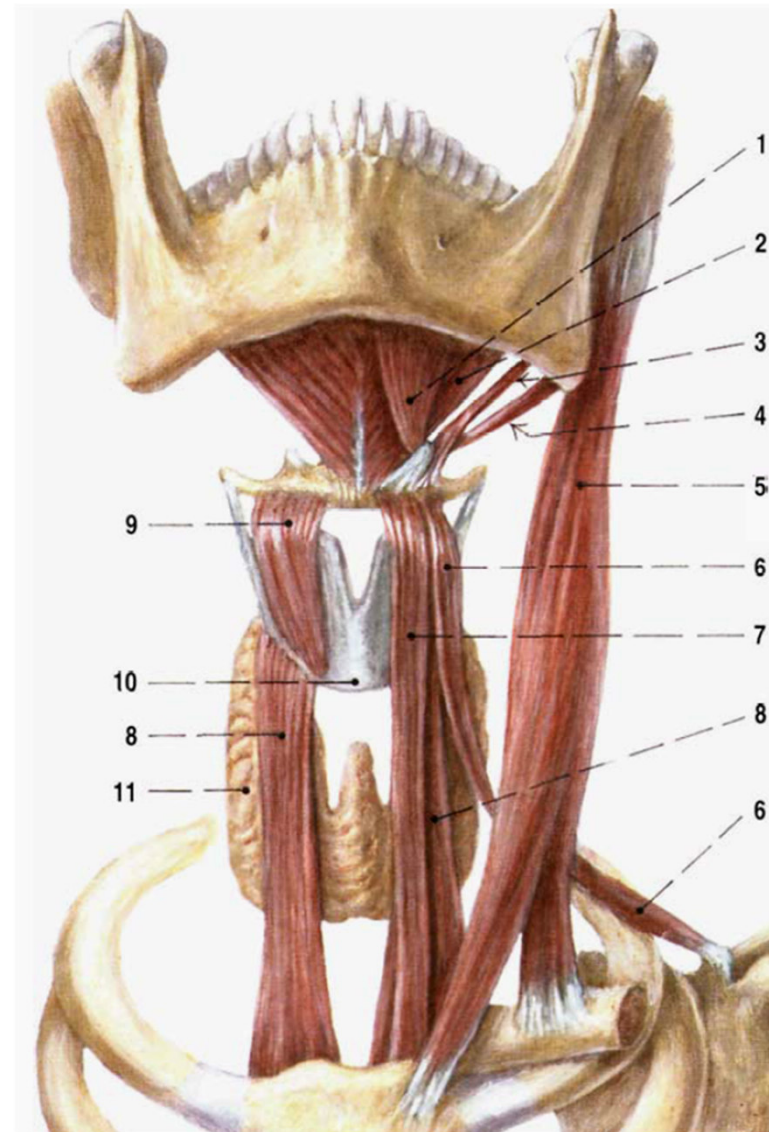
M. sternohyoideus



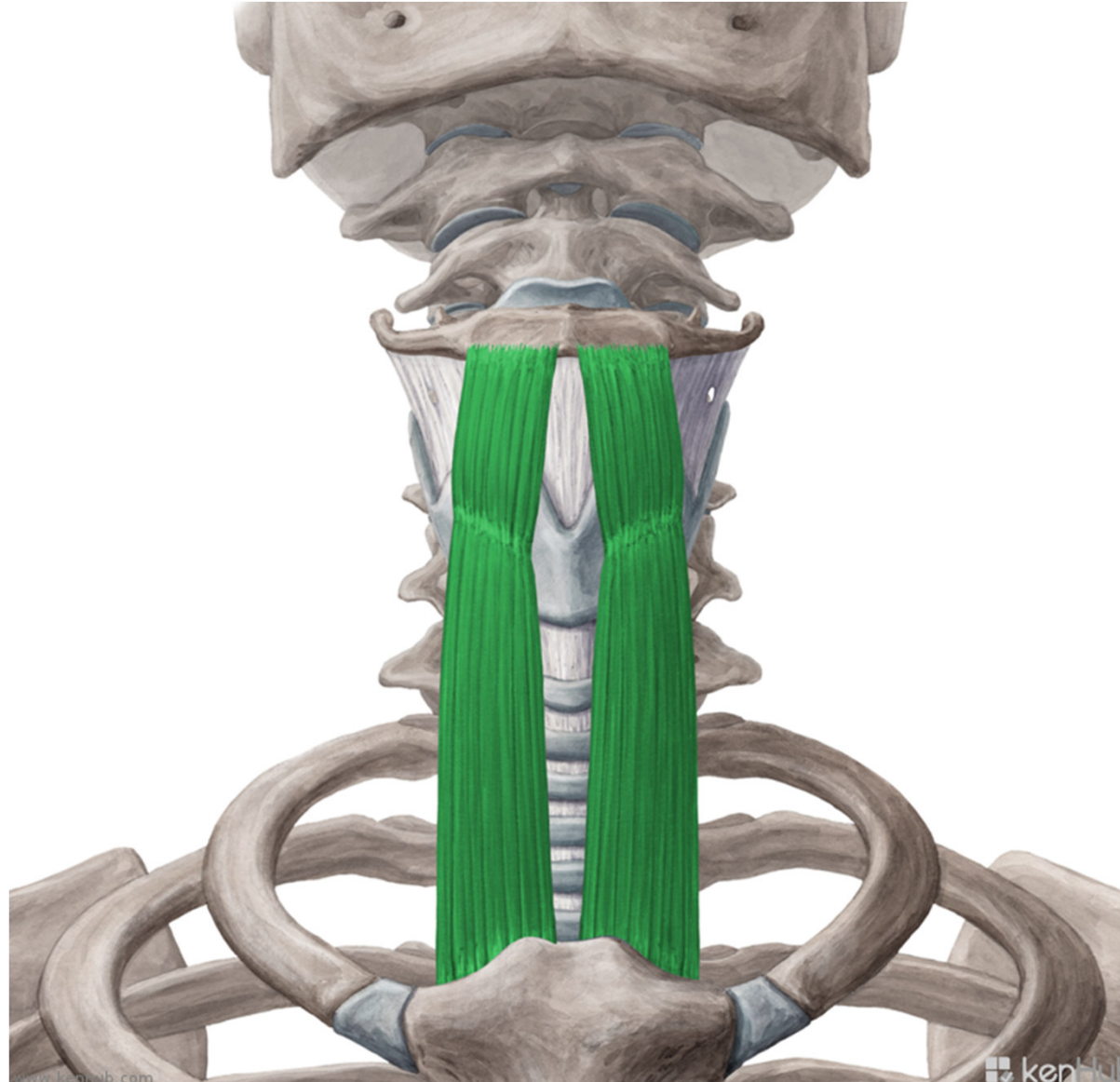
M. STERNOHYOIDEUS

O: dorsal surface of manubrium sterni + sternal end of clavicle

I: body of hyoid bone



M. sternothyroideus

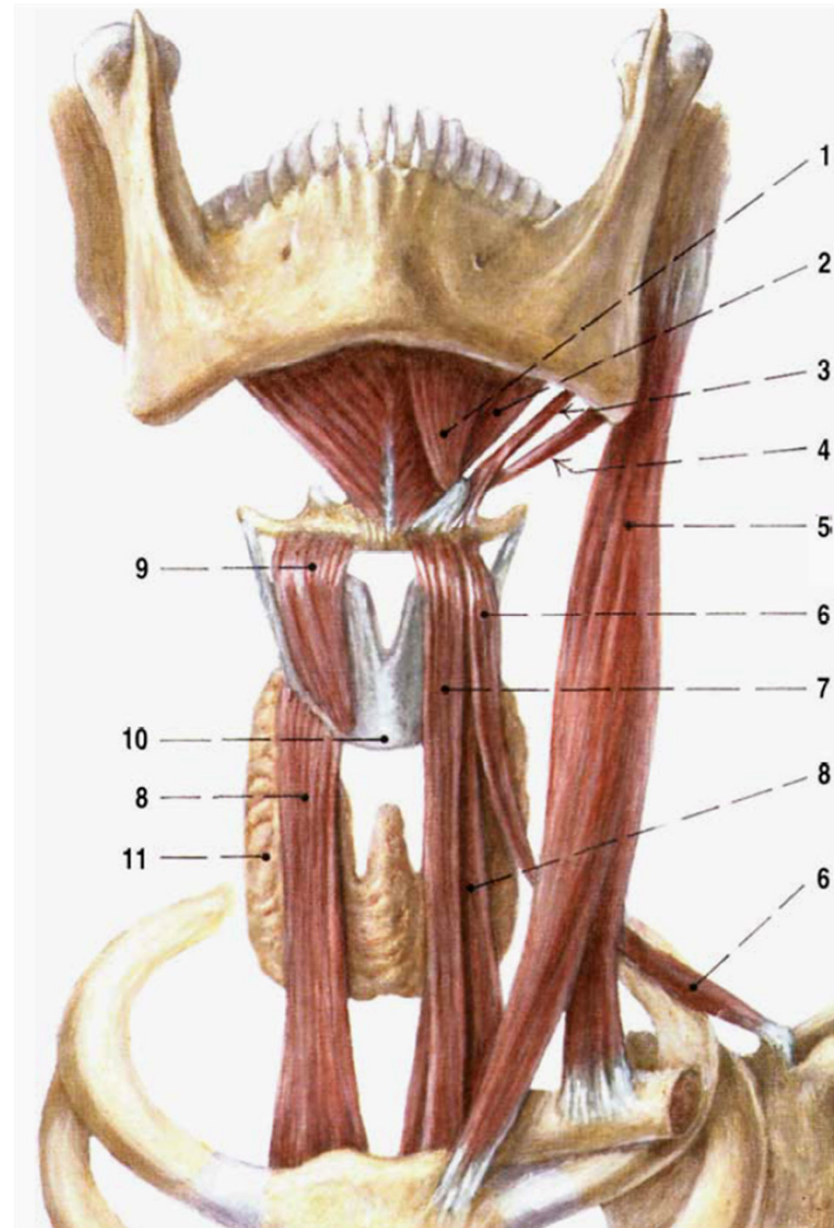


M. STERNOTHYROIDEUS

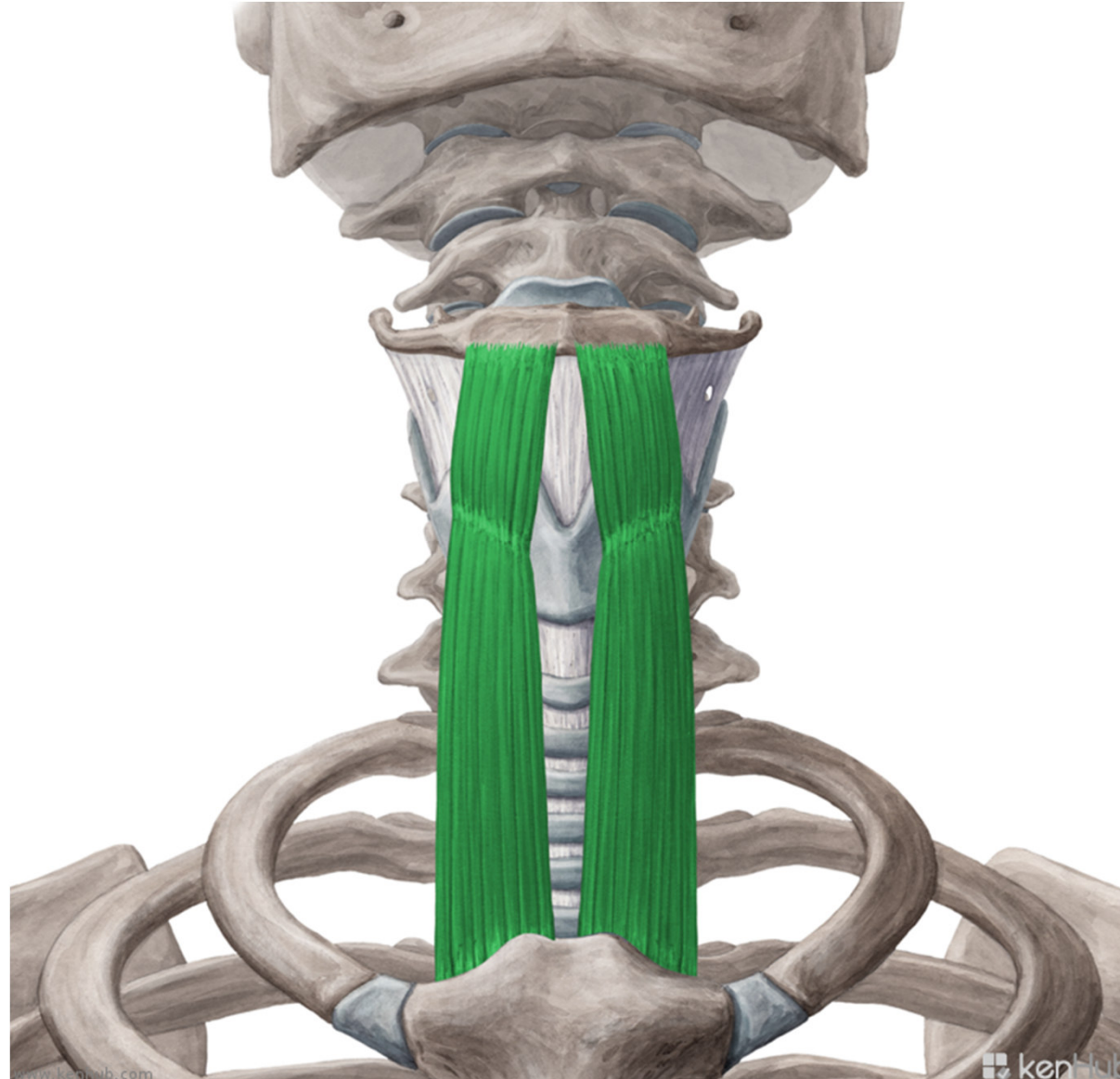
behind m. sternohyoideus and
more laterally

O: manubrium sterni and 1st rib

I: linea obliqua



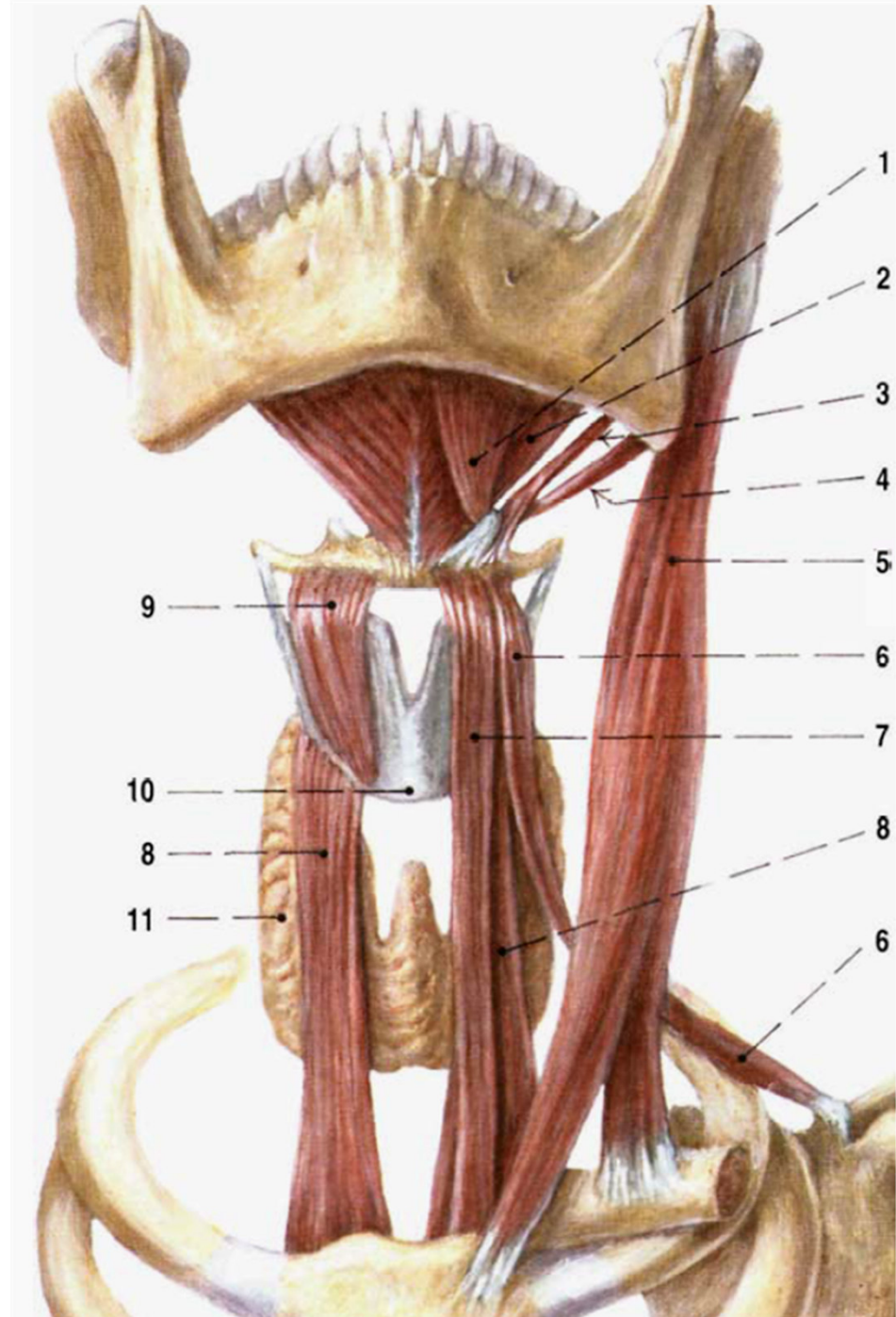
M. thyrohyoideus



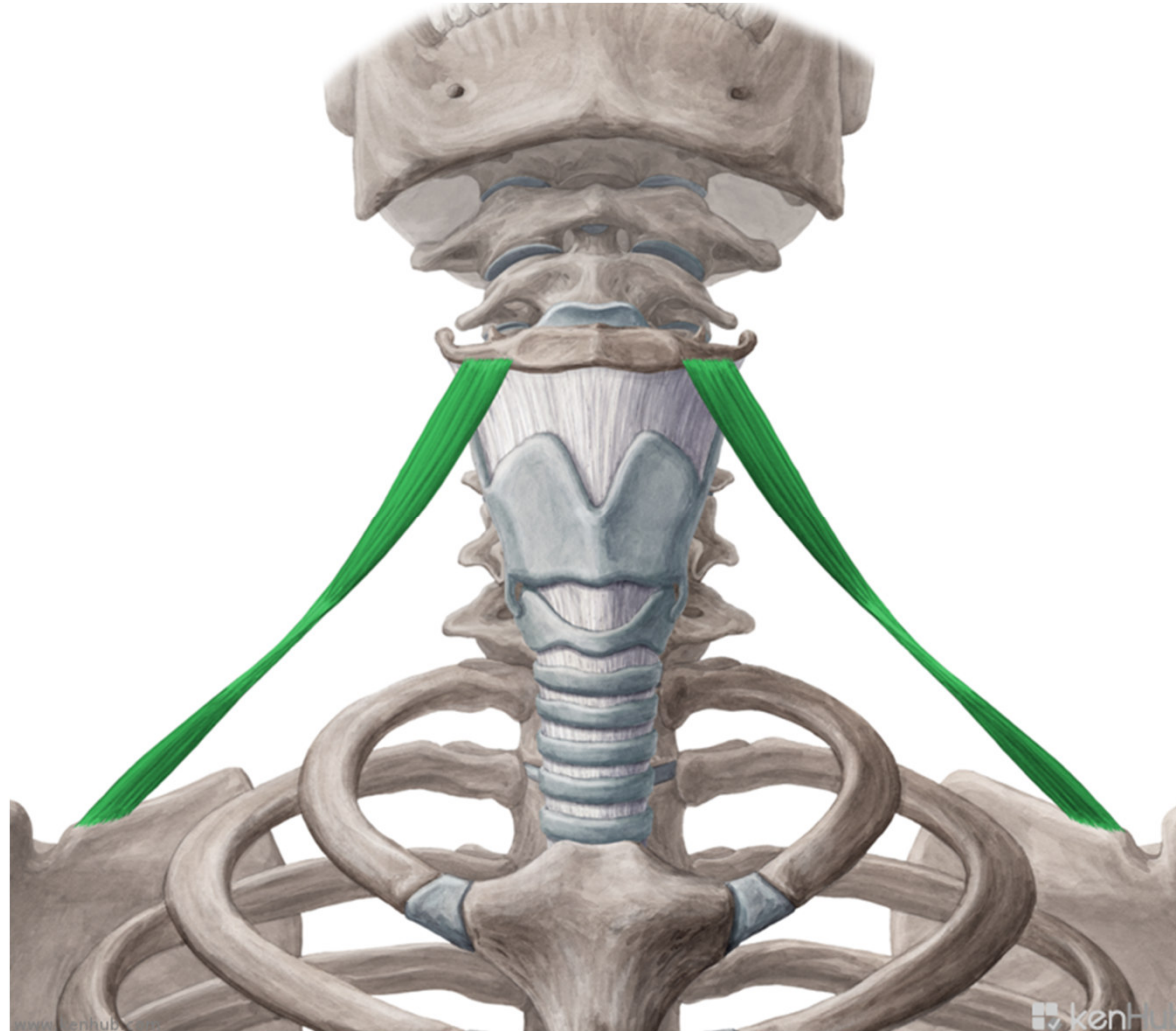
M. THYROHYOIDEUS

O: linea obliqua on cartilago thyroidea

I: cornu majus of hyoid bone



M. omohyoideus

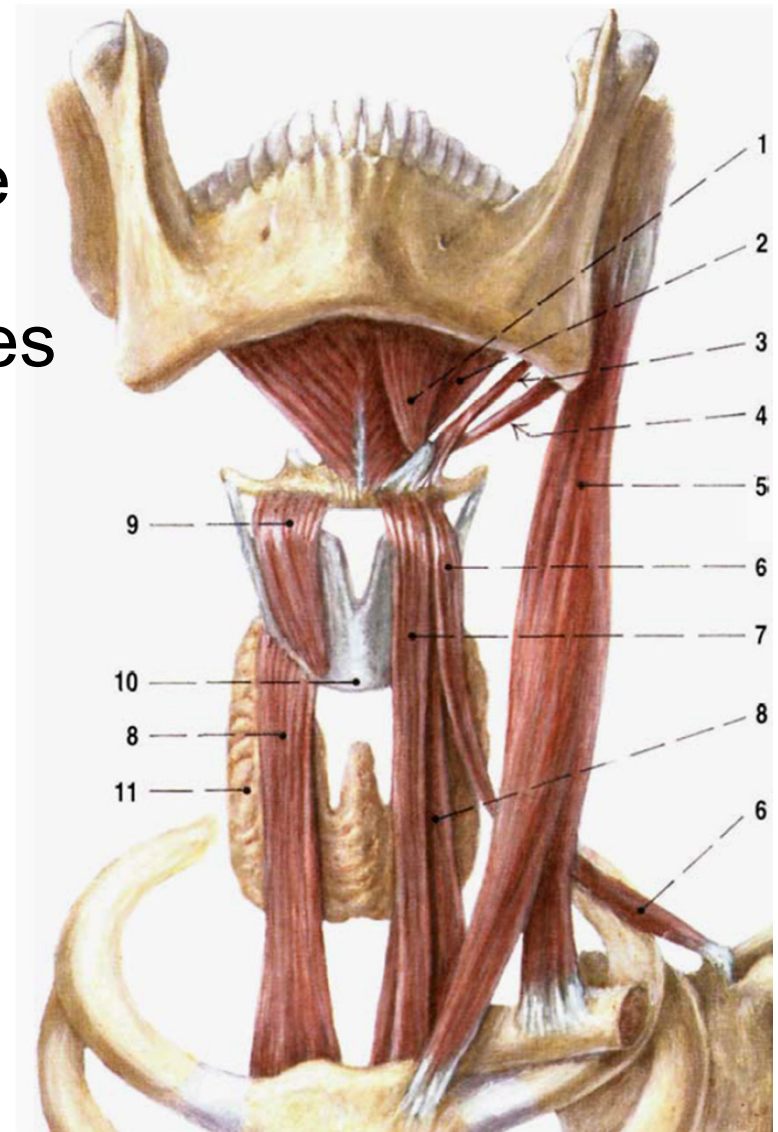


M. OMOHYOIDEUS

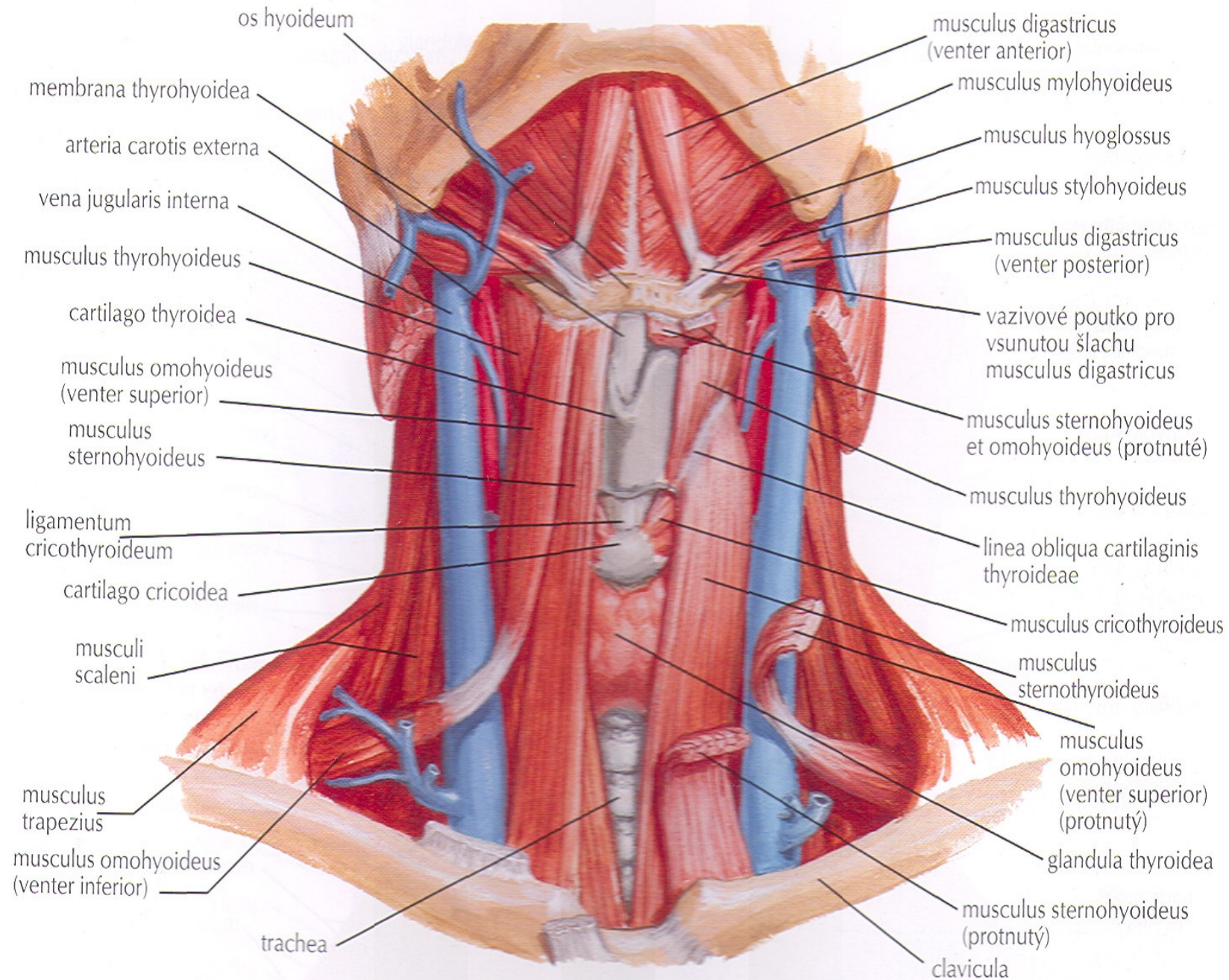
With two bellies

O: venter inferior- margo scapulae sup., bellow m. sternocleidomastoideus it continues as a tendon and then int chnages into venter superior

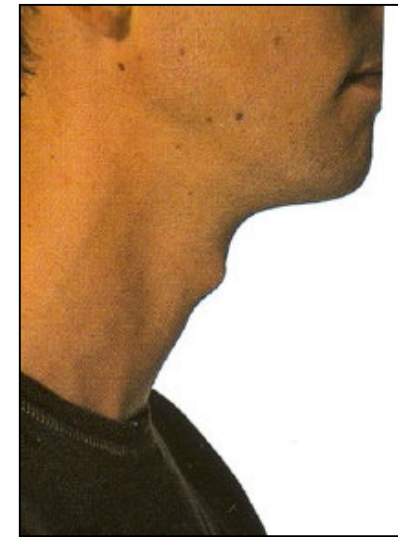
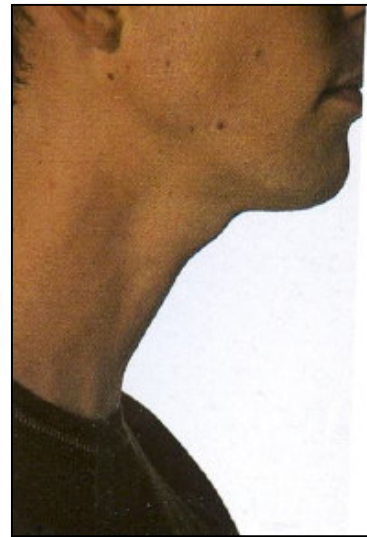
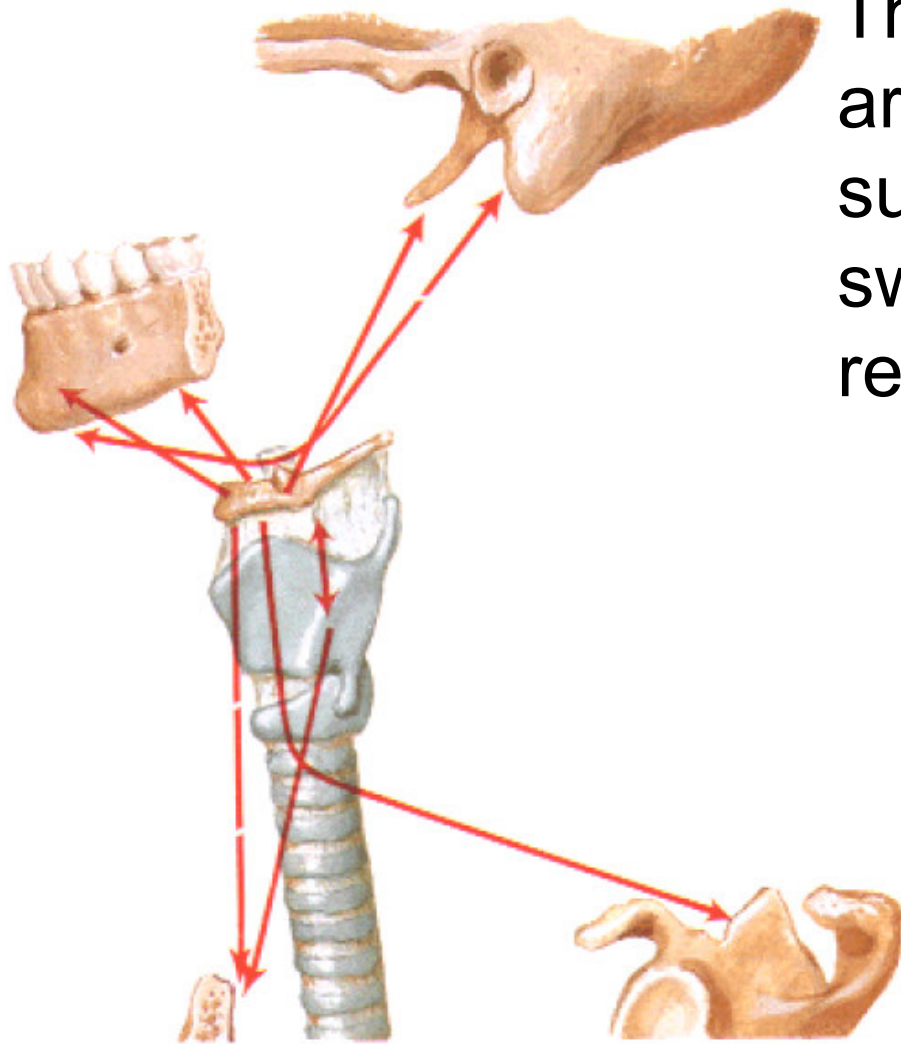
I: body of hyoid bone



mm. suprahyoidei et infrahyoidei



The larynx and the hyoid bone are elevated by the suprahyoid muscles during swallowing, infrahyoid muscles return them back



- Mm. scaleni

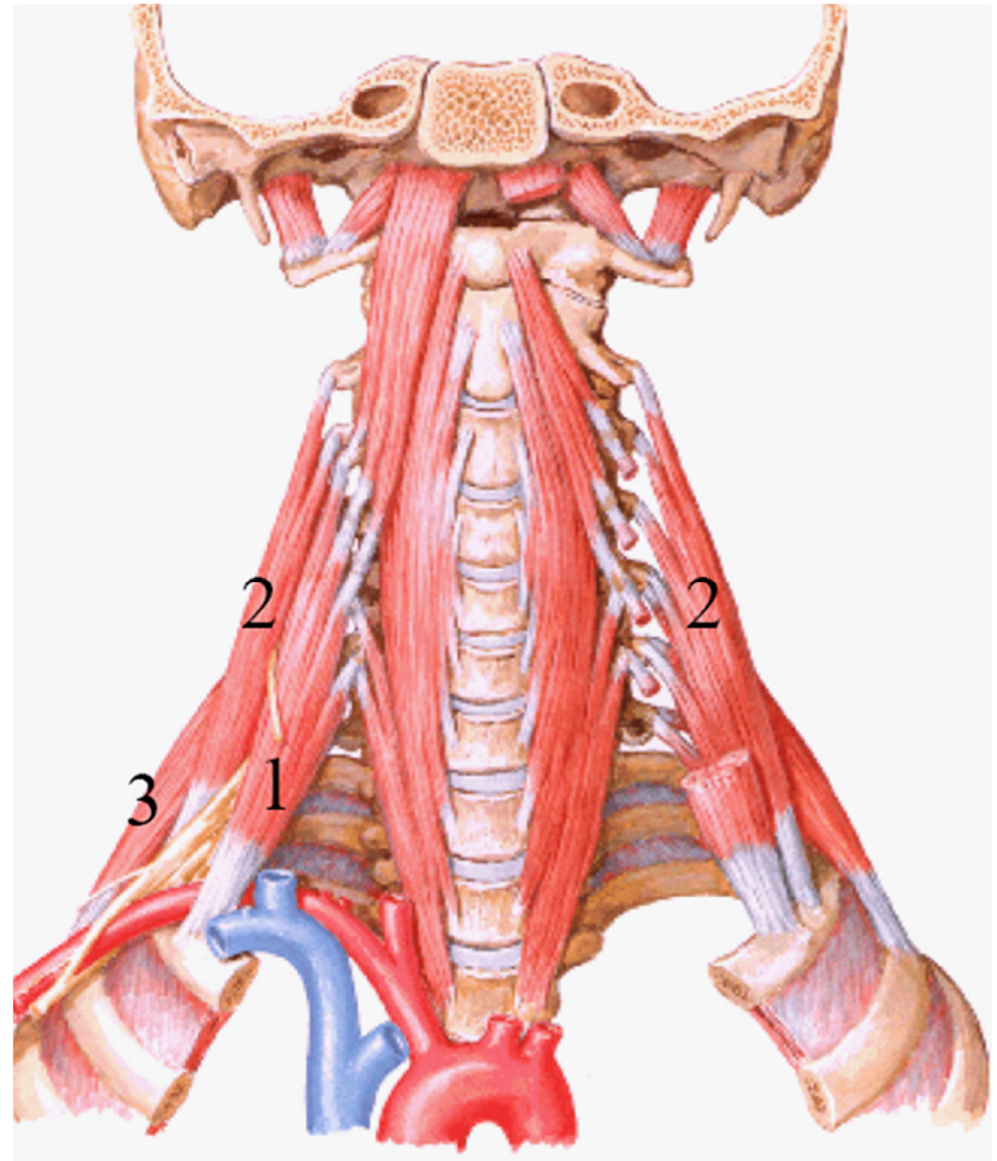
Musculi scaleni

Common function:

at fixed thorax, the muscles by unilateral contraction cause lateroflexion and rotation of the cervical spine, at bilateral contraction they cause anteflexion of cervical column

- auxilliary inspiratory muscles

/: rami ventrales of cervical nerves

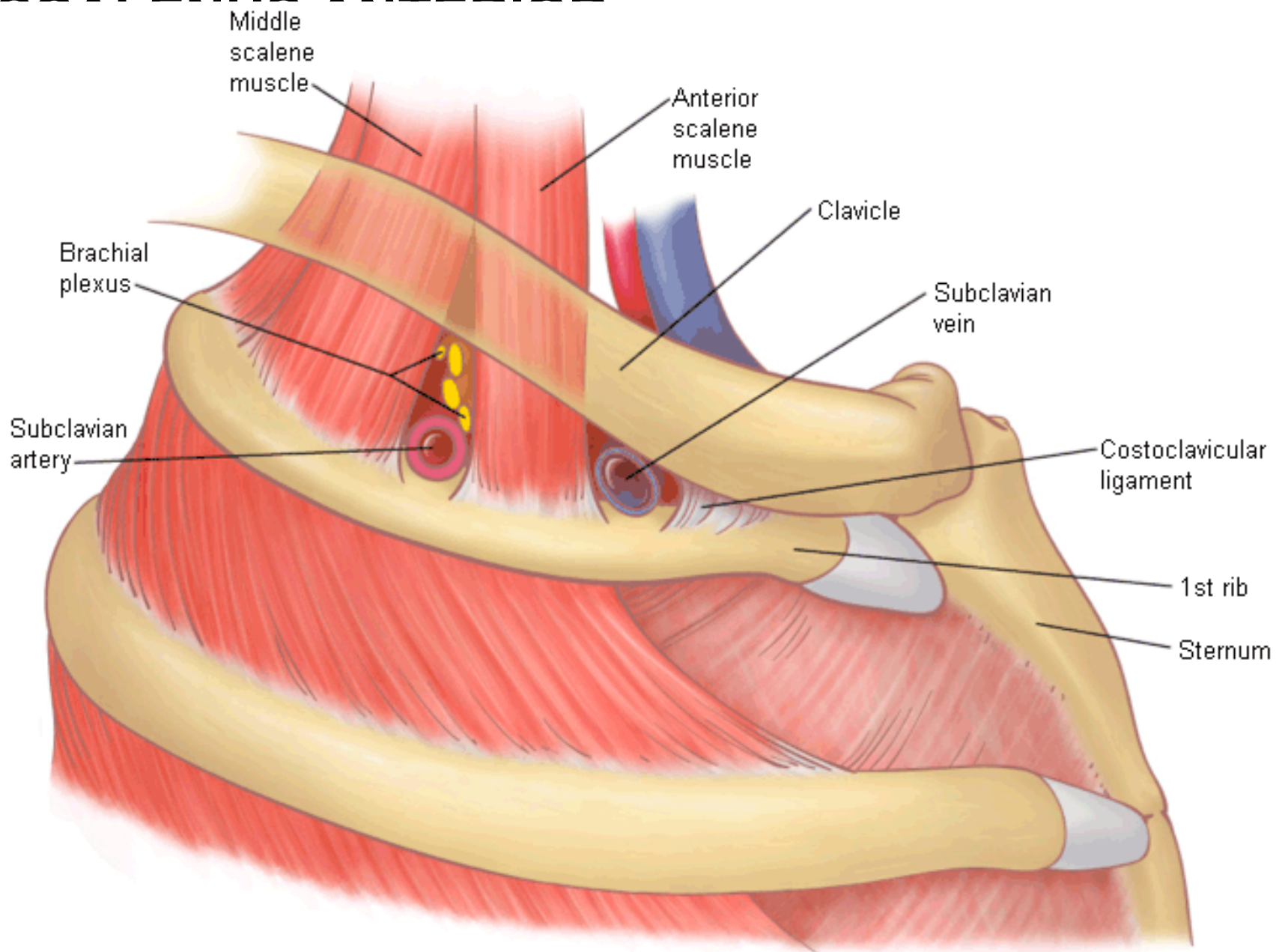


M. SCALENUS ANTERIOR

O:
I: tu

M.
O:
I: 1

M.
O:
I: 2



- Deep cervical muscles

Deep cervical muscles

IN: rami ventrales of cervical nerves

M. LONGUS CAPITIS

O: tuberculum ant. processus transversi C3 - C6

I: skull base

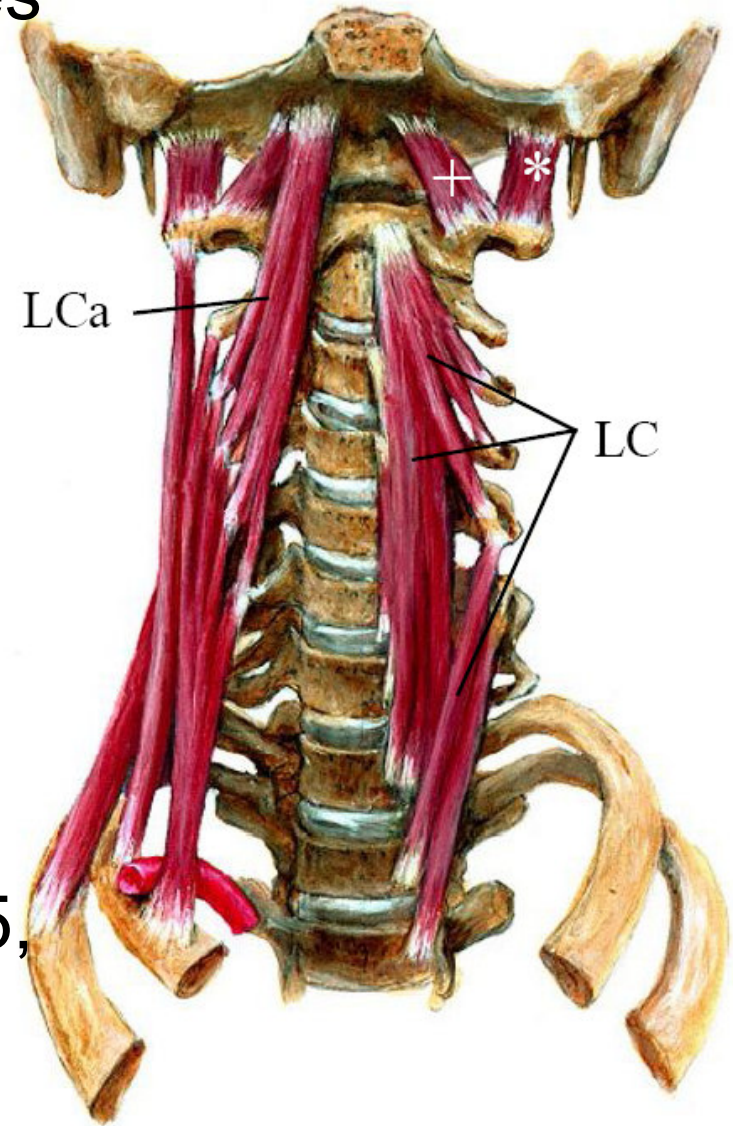
F: anteflexion of head

M. LONGUS COLLI

O: caudal cervical and cranial thoracic vertebrae

I: tuberculum anterius atlantis + tuberculum ant. proc. transversi C5, C6 + bodies of C2 – C4

F: flexion, lateroflexion, rotation of the head



M. RECTUS CAPITIS ANTERIOR

Z: processus transversus atlantis

Ú: skull base (behind m. longus capitis)

F: bilateral: anteflexion

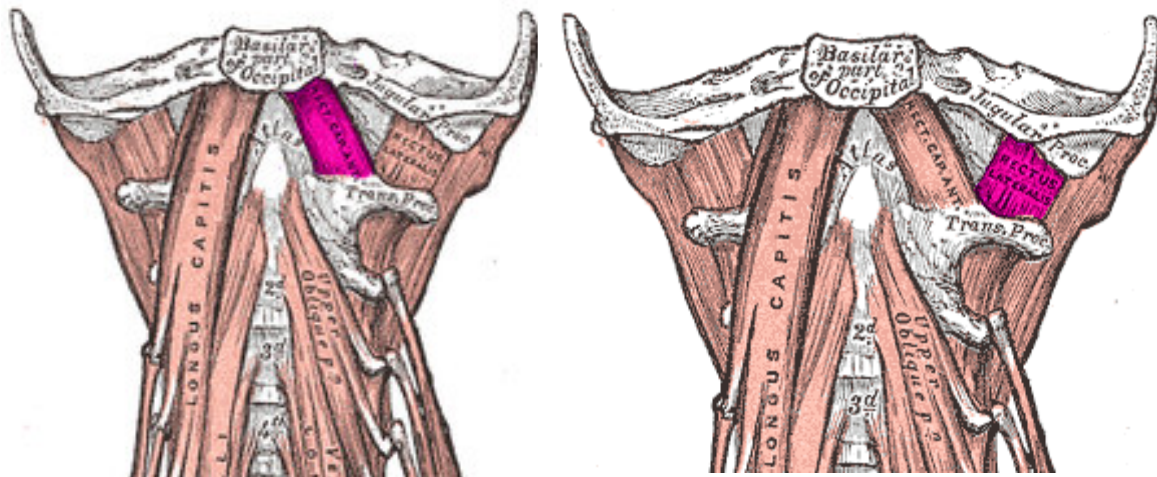
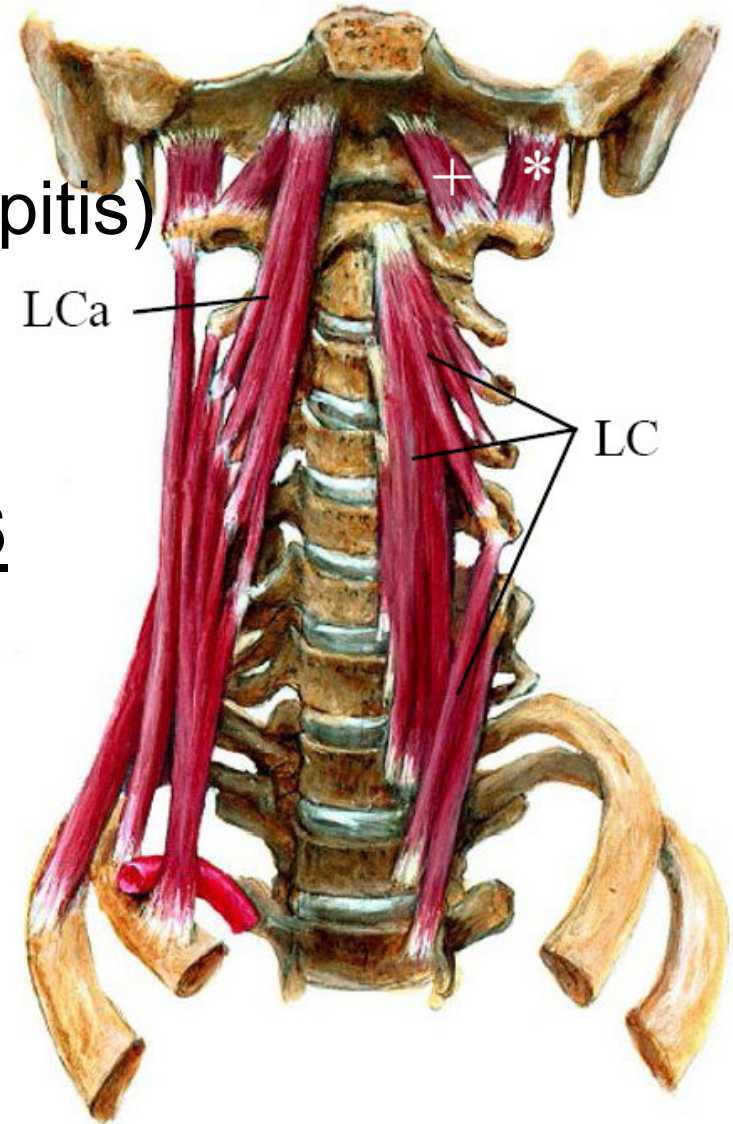
unilateral: lateroflexion

M. RECTUS CAPITIS LATERALIS

Z: processus transversus atlantis

Ú: skull base

F: lateroflexion

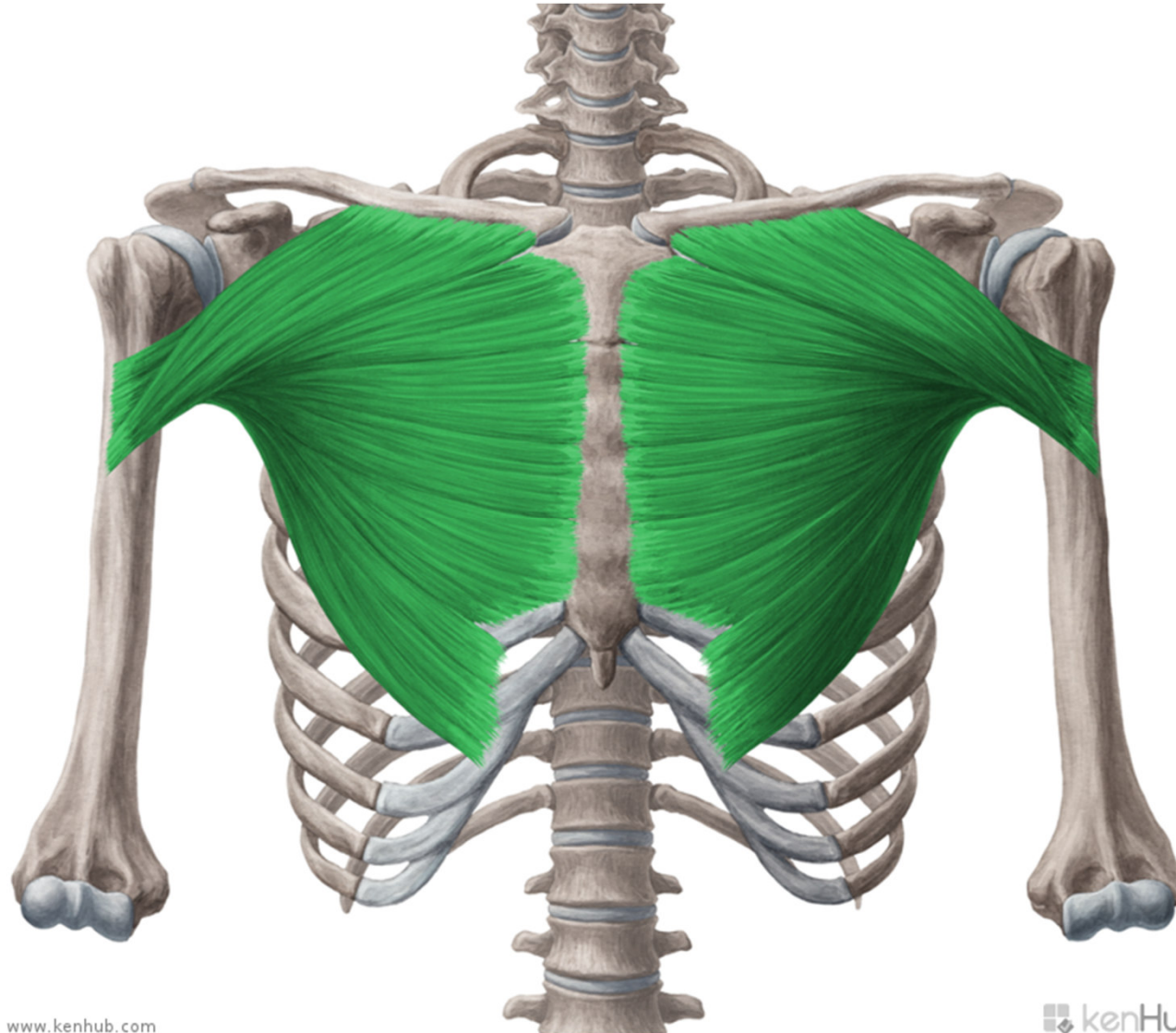


Musculi thoracis
(Thoracic muscles)

- Heterochtonous muscles of
thorax

(common innervation from pars
supraclavicularis plexus
brachialis)

M. pectoralis major



M. PECTORALIS MAJOR

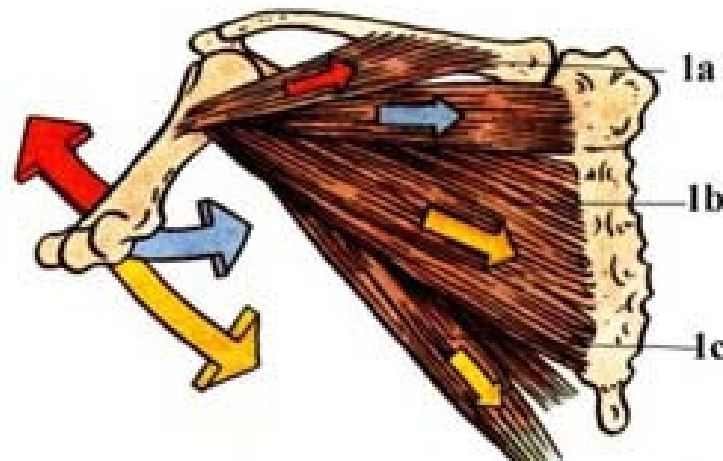
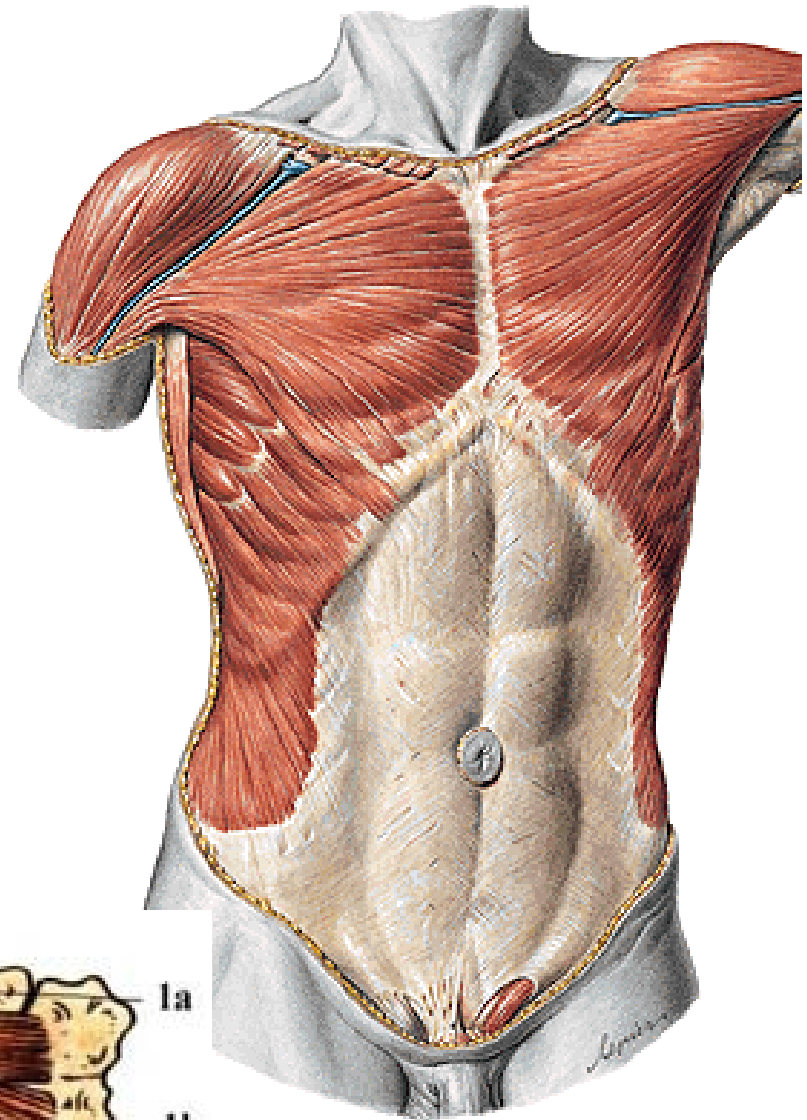
O: clavícula, sternum (+ adjacent parts of ribs 1st – 6th)

I: crista tuberculi majoris humeri,

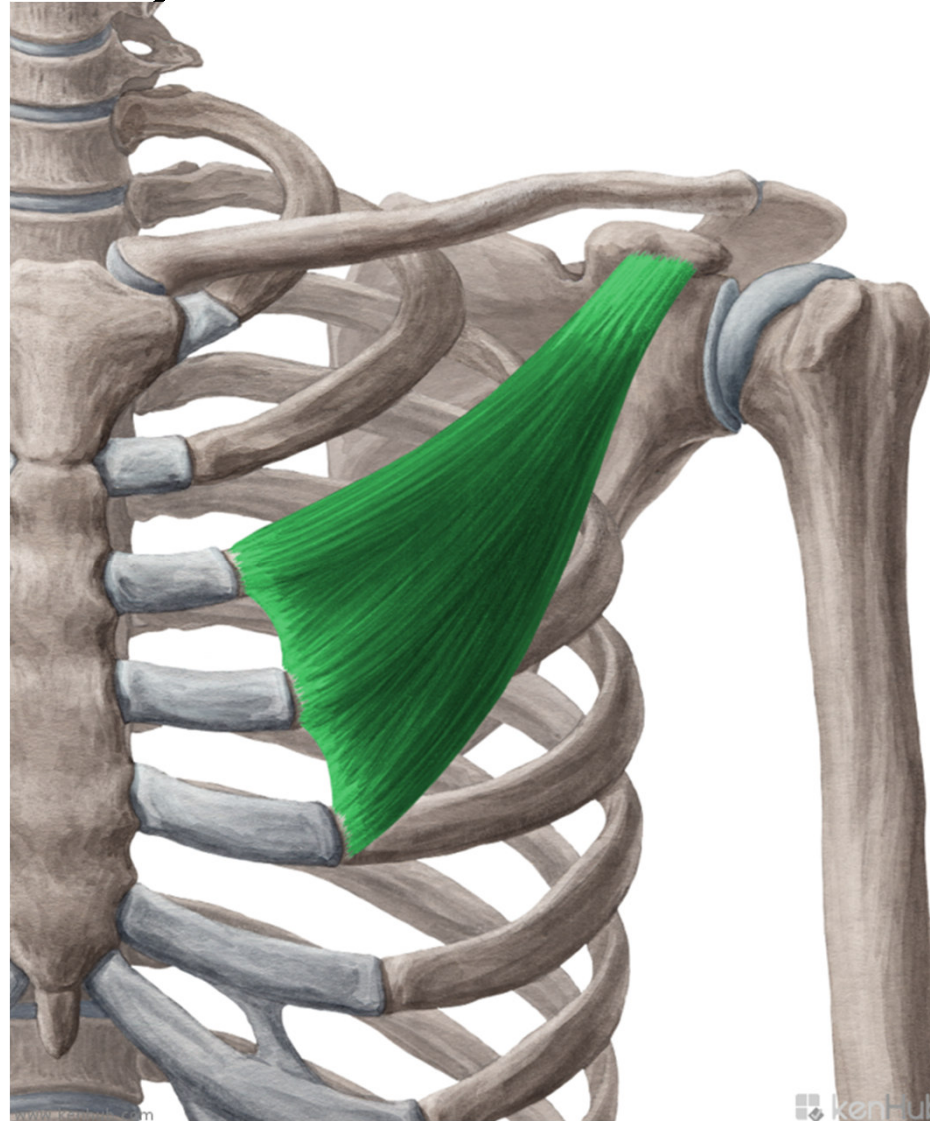
F: pars clavicularis – it helps at flexion of arm

pars sternalis and abdominalis

- addukce of arm, pronation



M. pectoralis minor

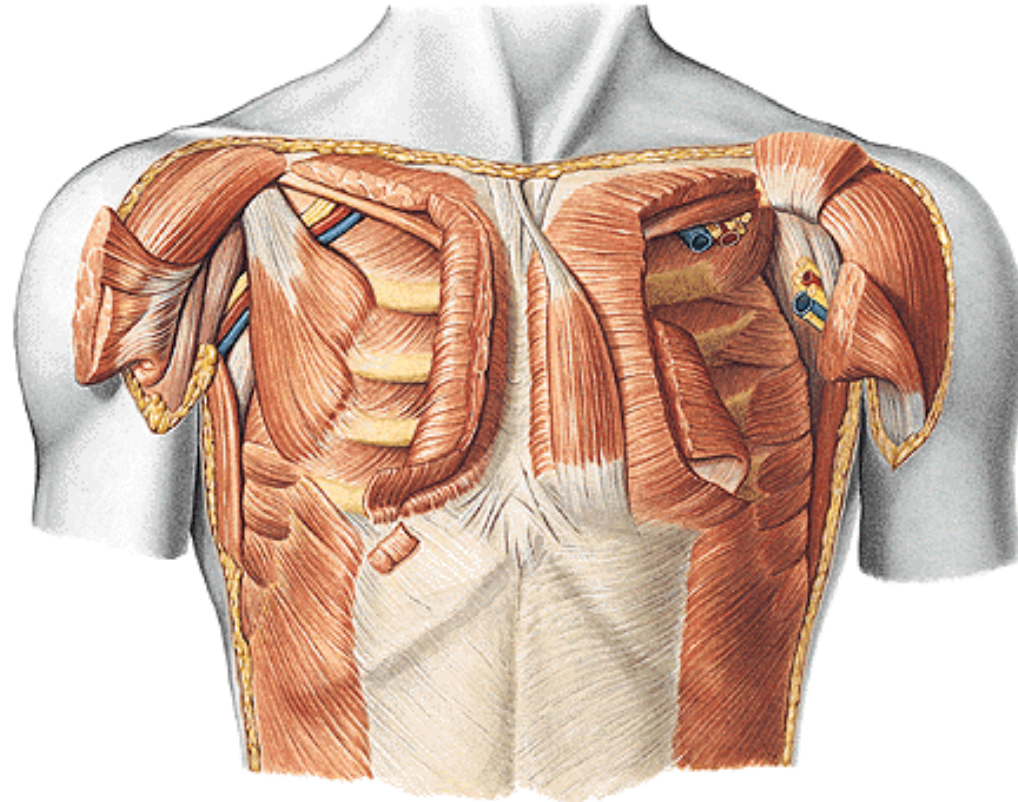


M. PECTORALIS MINOR

O: 3. až 5. žebro

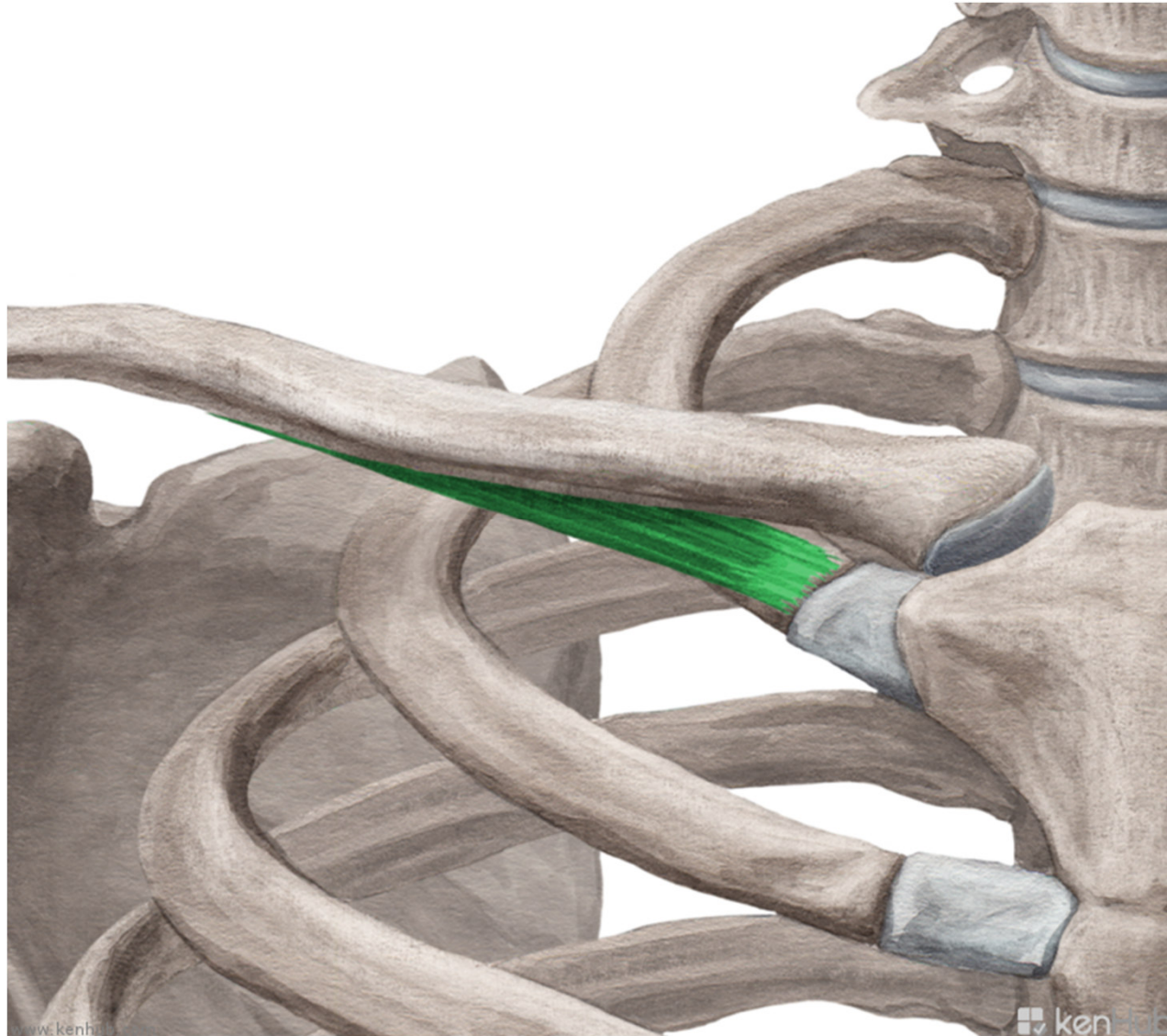
I: processus coracoideus

F: it pulls scapula forward and downward



F: auxiliary inspiratory muscles

M. subclavius

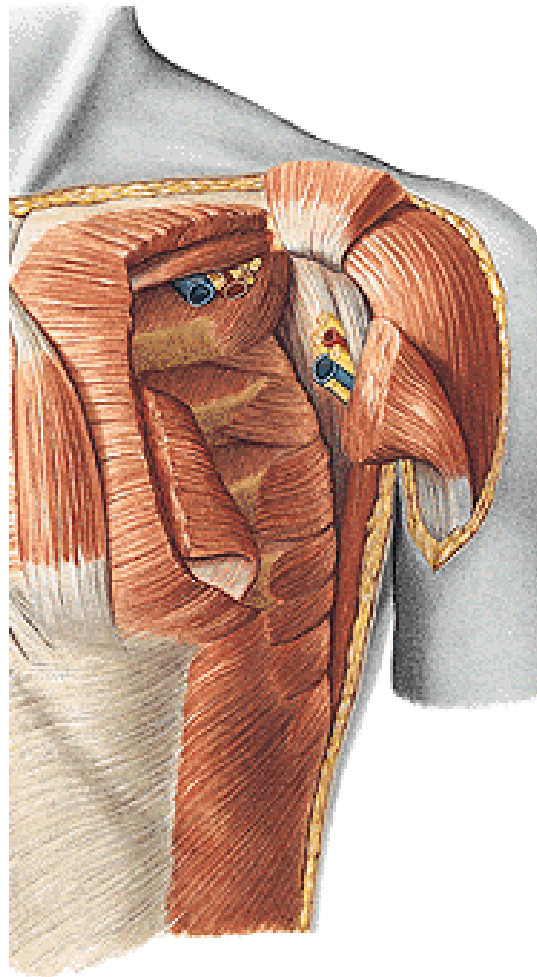


M. SUBCLAVIUS

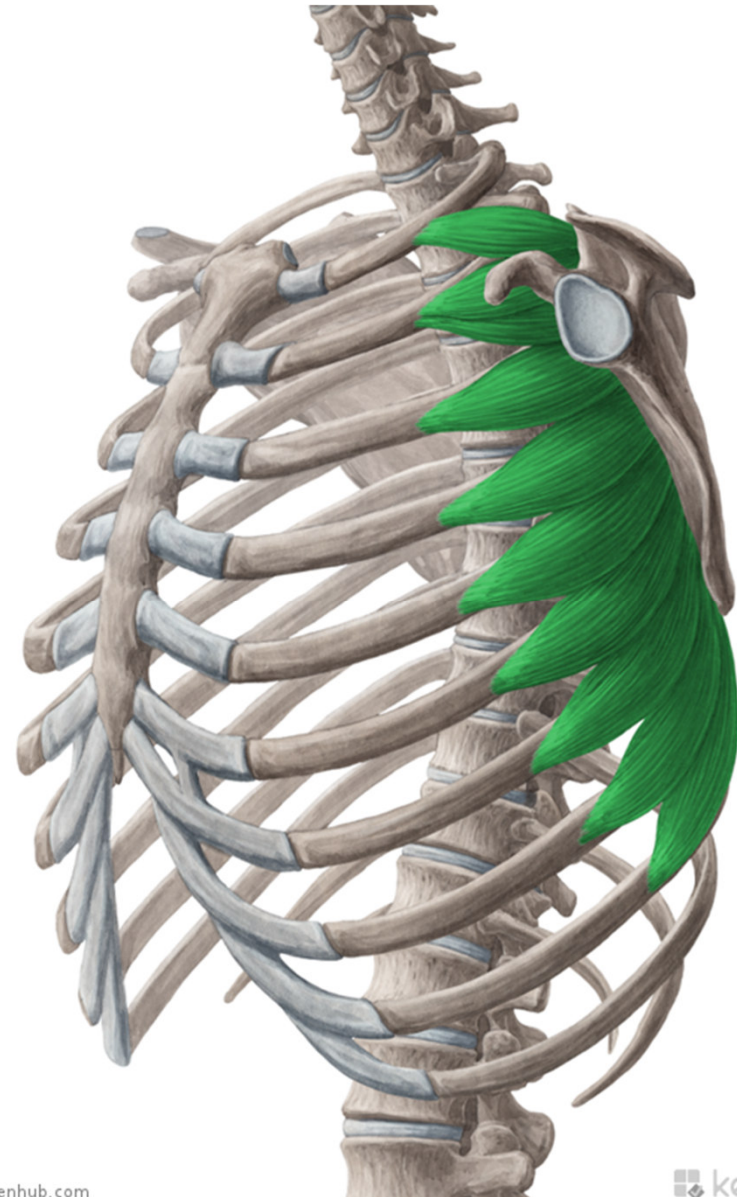
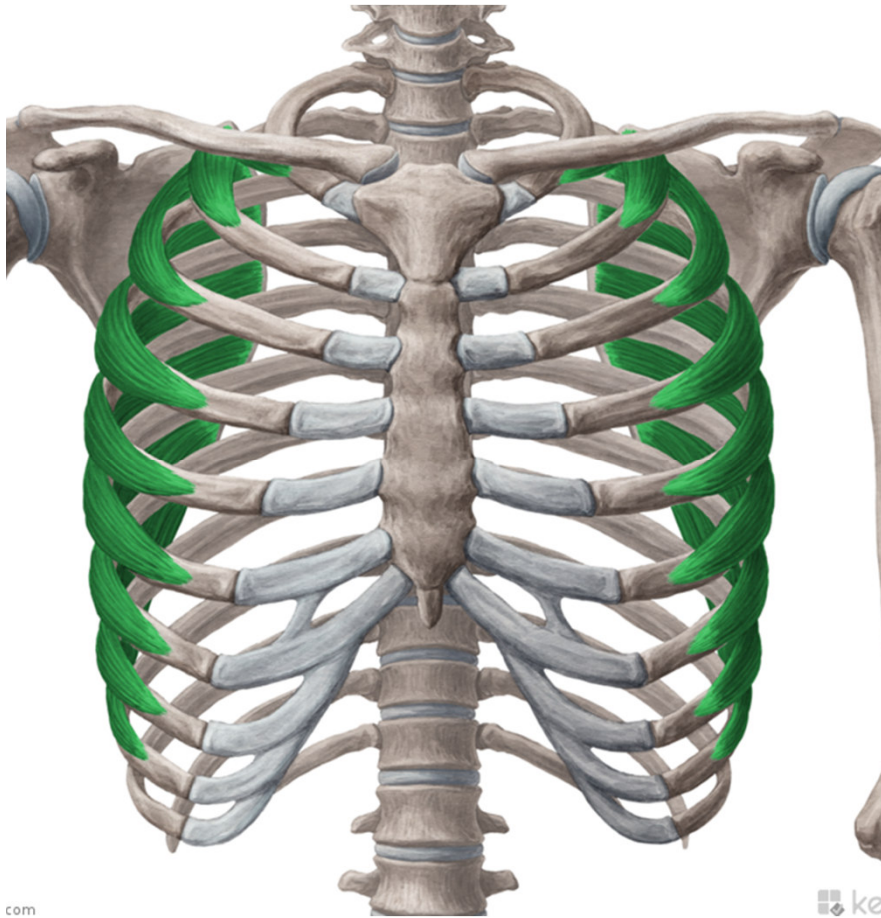
O: costa prima

I: sulcus m. subclavii

F: it pulls clavicle downward, it elevates the 1st rib



M. serratus anterior

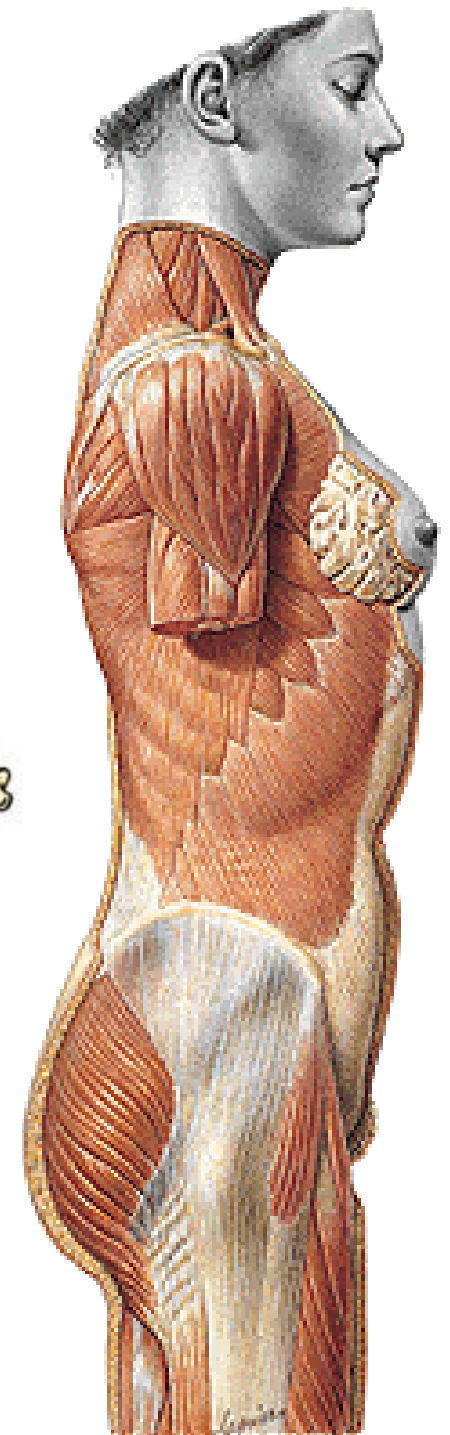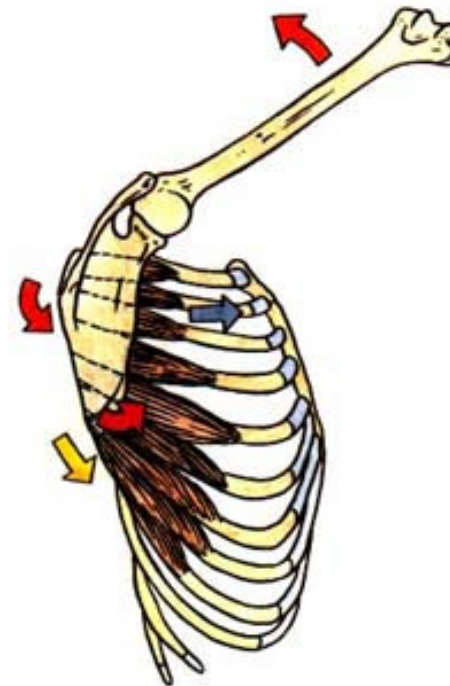


M. SERRATUS ANTERIOR

O: nine teeth at 1st-9th rib

I: medial edge of scapula and
angulus inferior

F: it holds scapula to the thorax,
it pulls angulus inferior scapulae
laterally



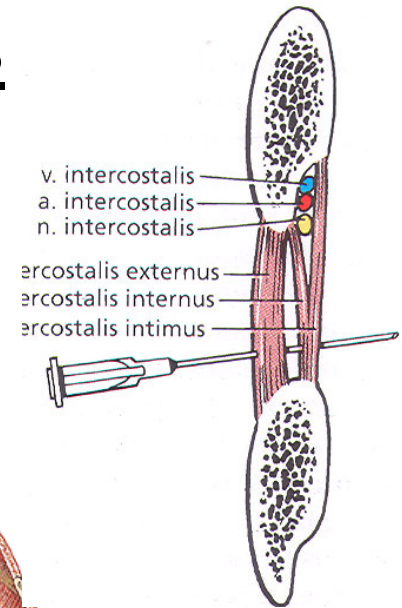
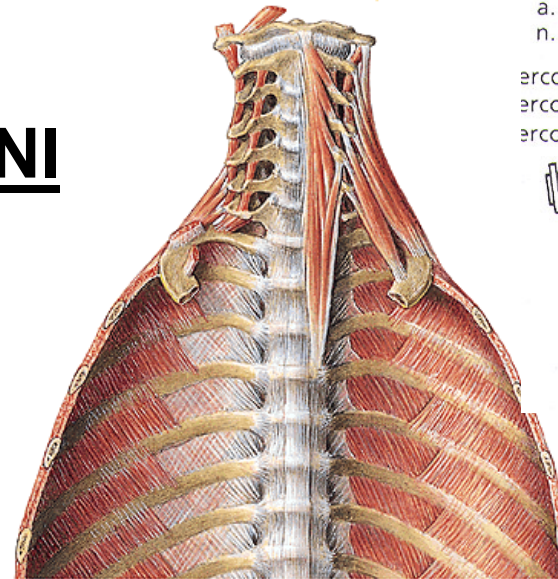
Autochthonous thorax muscles

Common innervation: nn.
intercostales I - XI

MM. INTERCOSTALES EXTERNI

external layer, they direct like hands into the pockets, they continue forward as **membrana intercostalis externa**

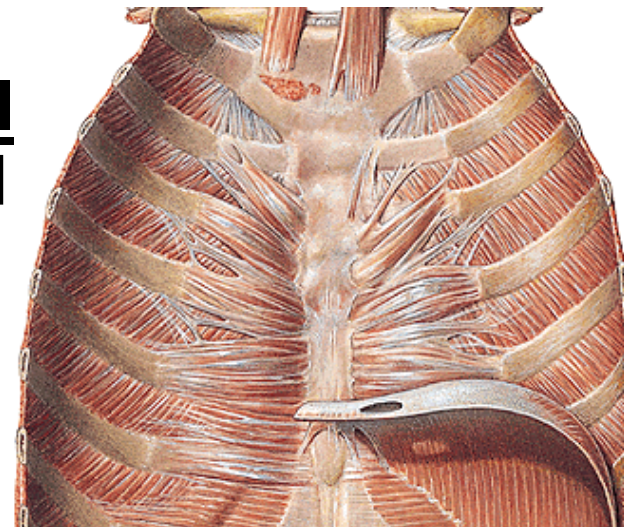
F: inspiratory muscles



MM. INTERCOSTALES INTERNI

middle layer, they direct like hand to the breasts, they continues backward as **membrana intercostalis interna**

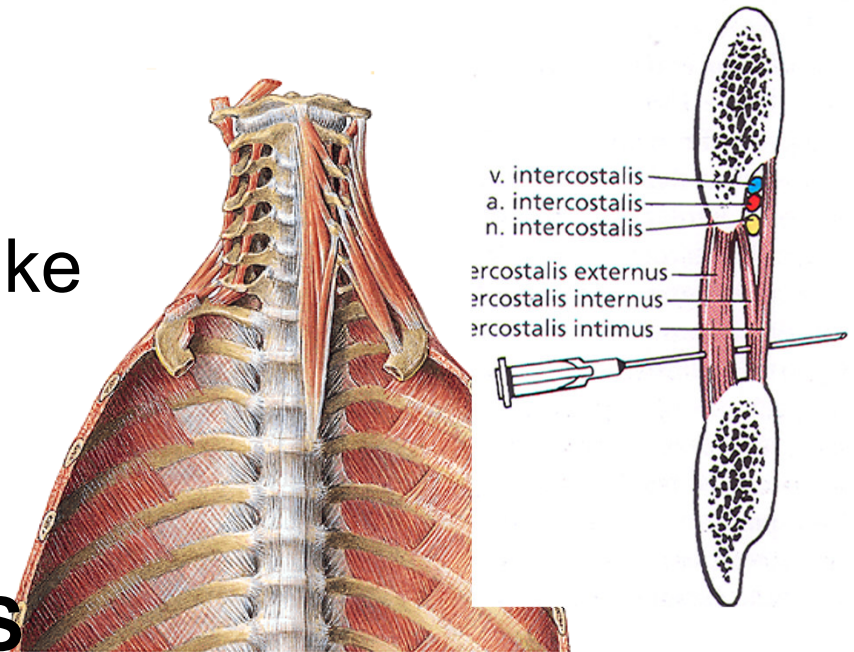
F: expiratory muscles



MM. INTERCOSTALES INTIMI

internal layer

the same course and function like
mm. intercostales interni

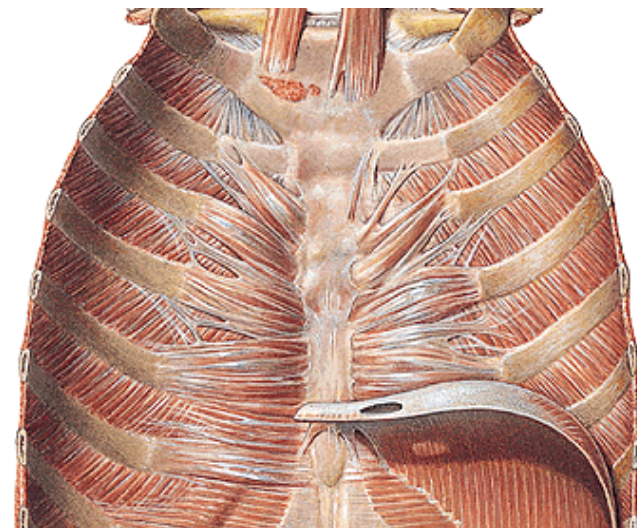


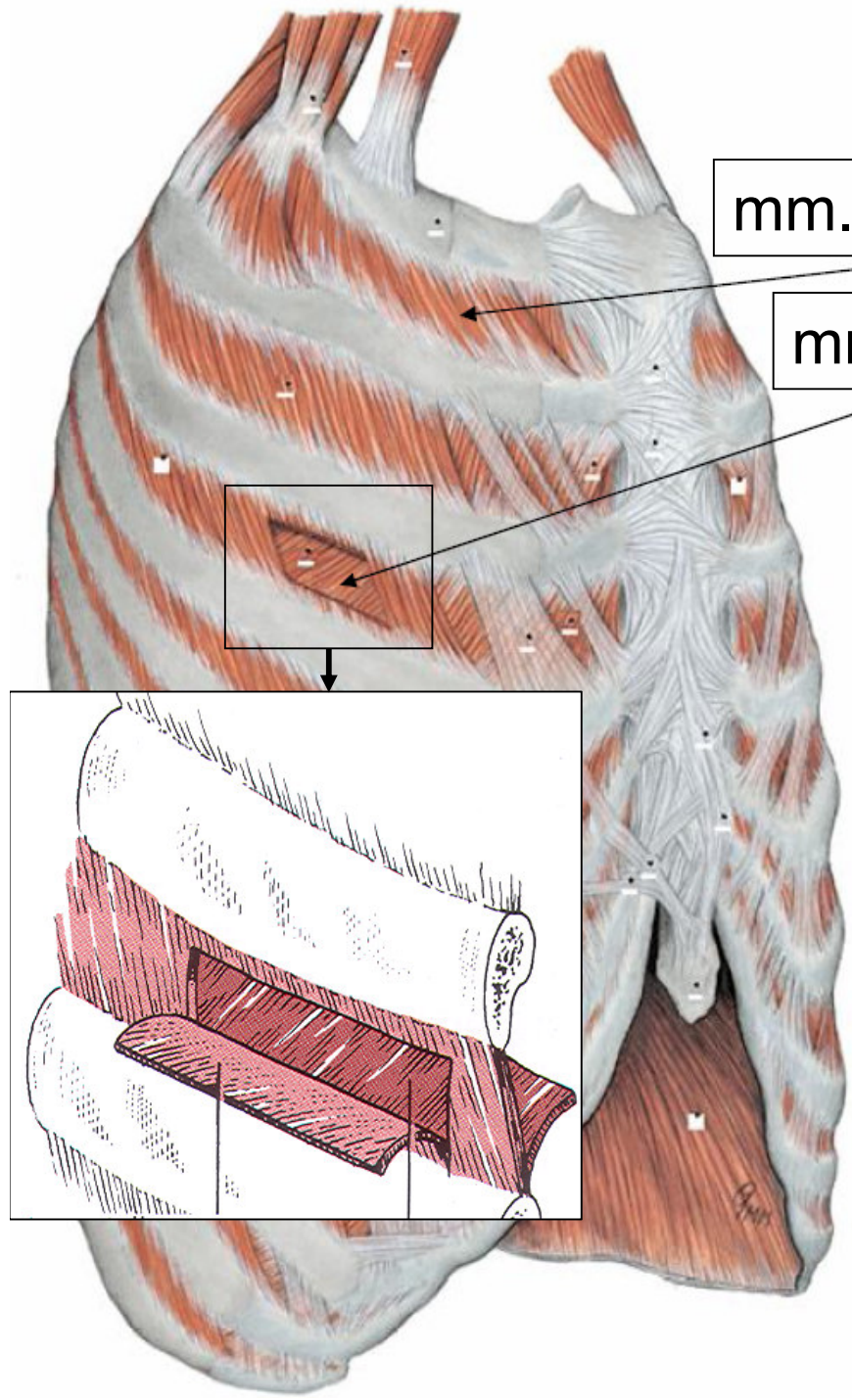
M. TRANSVERSUS THORACIS

flat muscle on the internal surface
of sternum

it is diverging in a ray-shaped form
cranially and laterally

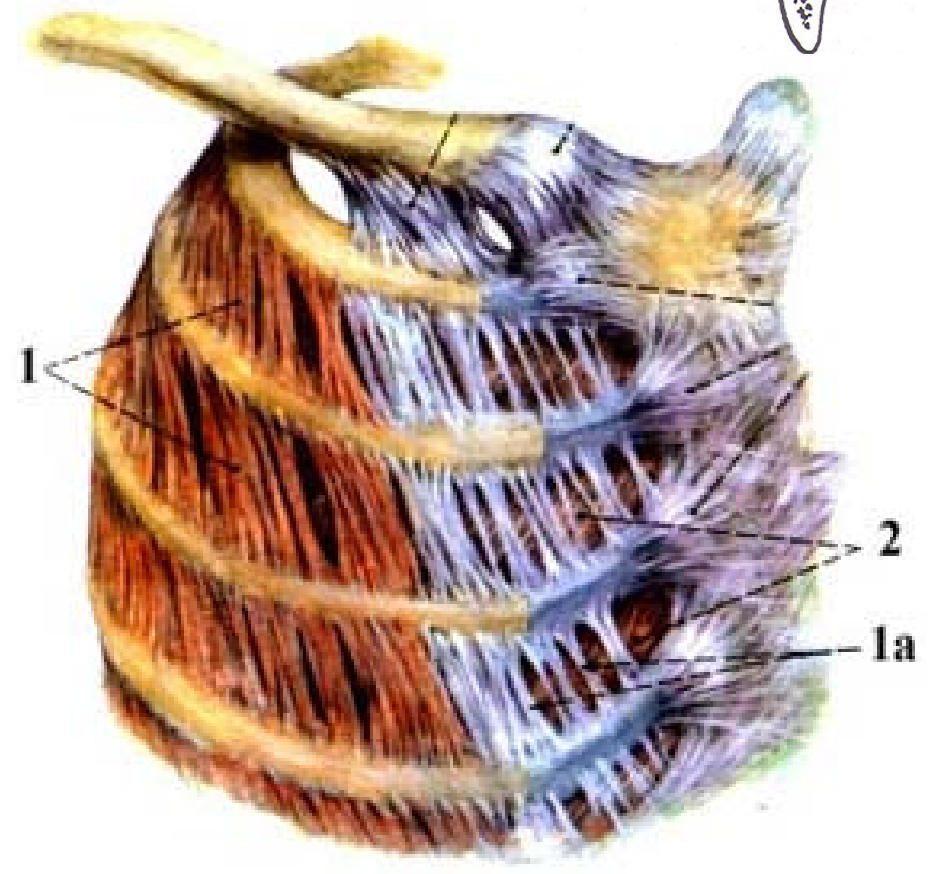

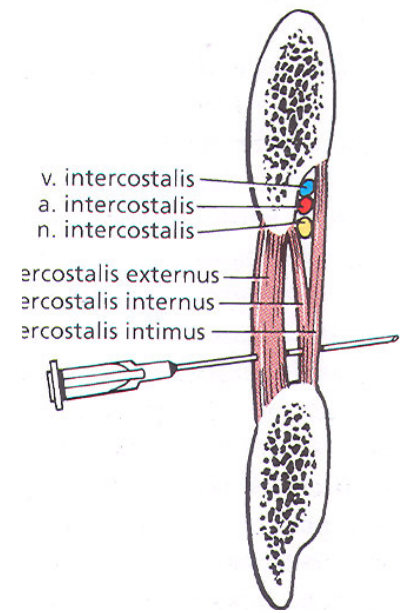
F: auxiliary inspiratory muscle





mm.intrecostales externi

mm.intercostales interni



1

2

1a

The diaphragm (*diaphragma*)

Flat muscle that separates the abdominal and thoracic cavity

The edges- muscle bundles, **centrum tendineum**

a) ***pars lumbalis***: starts from *lig. longitudinale anterius*, from lumbar vertebrae

b) ***pars costalis***: starts from 7th– 12th rib

c) ***pars sternalis***: starts from *processus xiphoideus sterni*

I: centrum tendineum

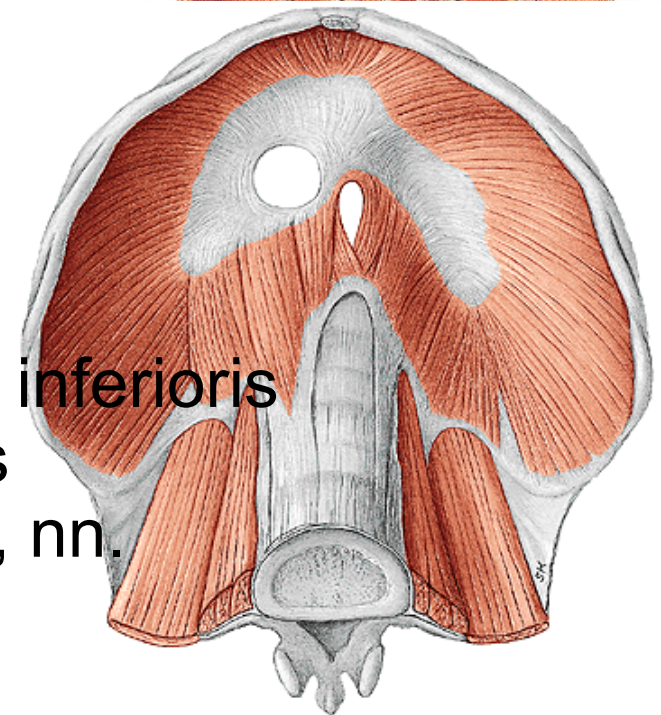
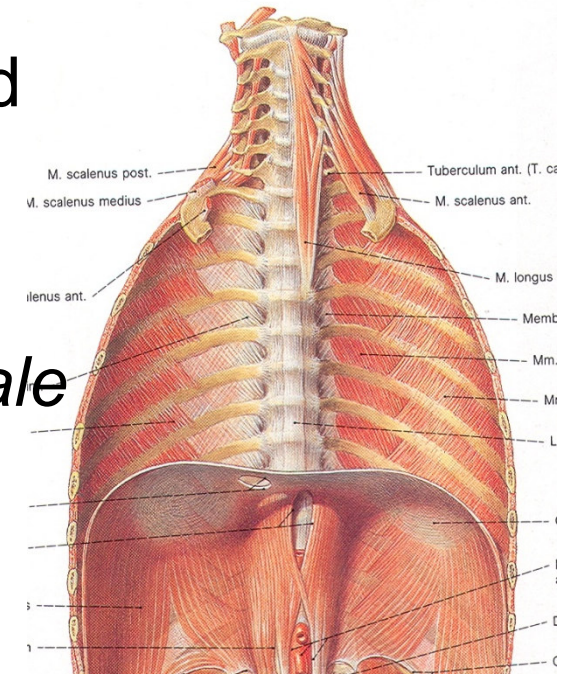
IN: n. phrenicus

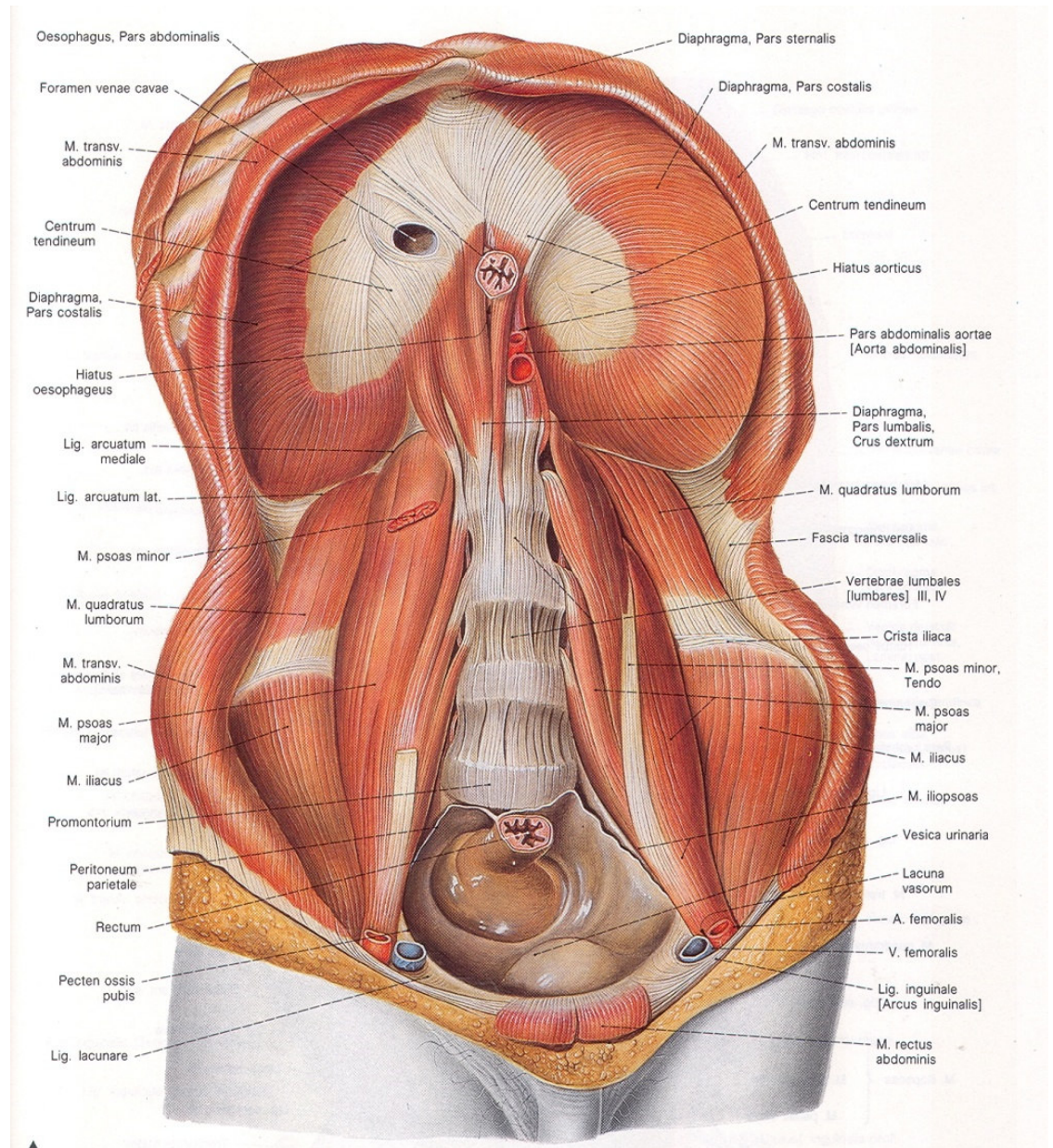
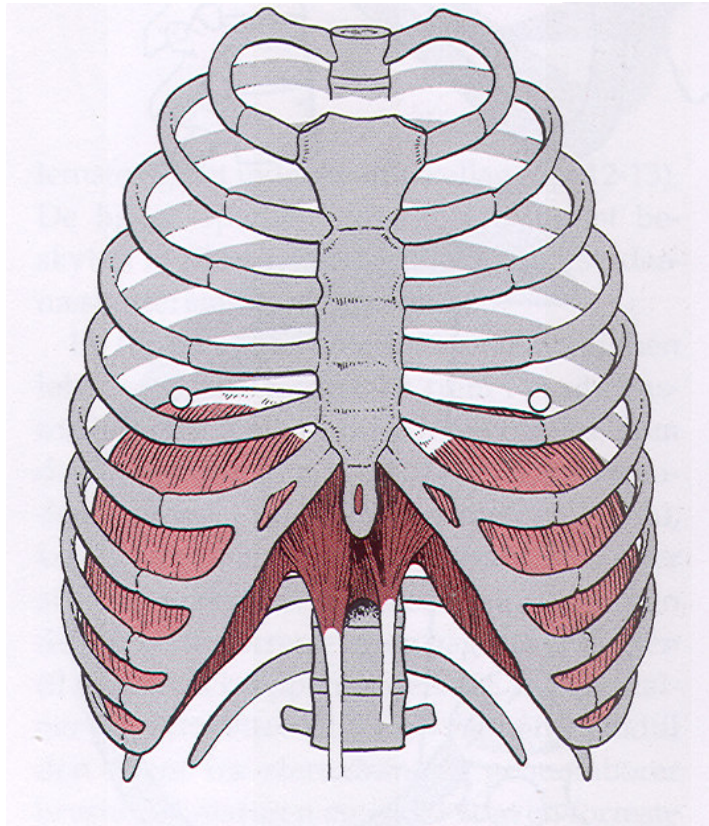
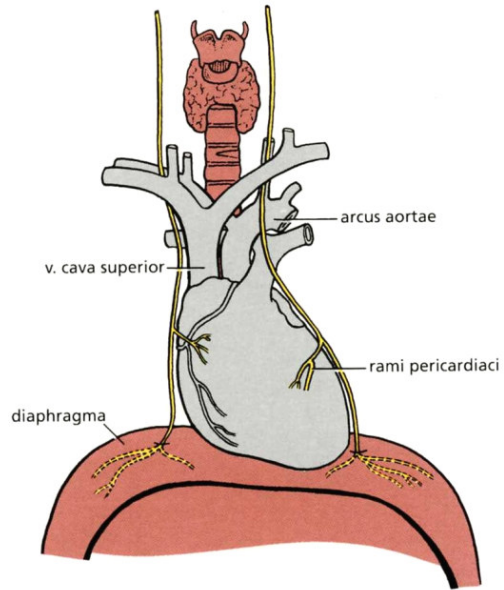
F: main inspiratory muscle

Openings:

In centrum tendineum: foramen v. caeve inferioris

In muscular part: hiatus aorticus (ductus thoracicus), hiatus esophageus (nn. vagi), nn. splanchnici, v. azygos





Fascie hrudníku

fascia pectoralis spfc.

fascia clavipectoralis
– fossa ovalis infraclavicularis

fascia endothoracica
(Sibsonova fascie)

