

## CONNECTIONS OF THE UPPER AND LOWER EXTREMITY

(juncturae ossium membri superioris et inferioris)

### Remembrance event for those who donated their bodies to the Department of Anatomy

Monday 11/4/2019 – 6 PM

Augustinian Abbey

Mendlovo náměstí 157/1  
603 00 Brno



### Articulatio cubiti (elbow joint)

Articulatio composita:

1. **Articulatio humeroradialis** (articulatio spheroidica)

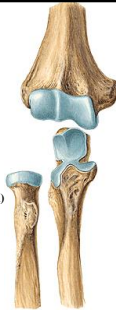capitulum humeri, fovea capitis radii

2. **Articulatio humeroulnaris** (articulatio trochlearis)

trochlea humeri, incisura trochlearis ulnae

3. **Articulatio radioulnaris proximalis** (articulatio trochoidea)

circumferentia articularis capitis radii,  
incisura radialis ulnae



### Articulatio cubiti

**Articulation capsule:**

Epicondyles of the humerus **EXTRACAPSULAR**, foveae of the humerus **INTRACAPSULAR**

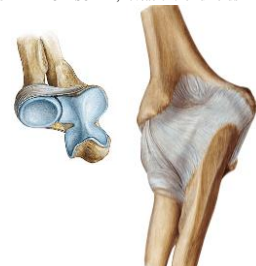
recessus sacciformis

**Apparatus:**

lig. anulare radii

lig. collaterale radiale

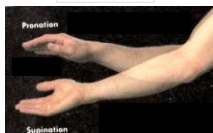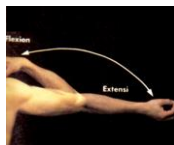
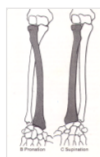lig. collaterale ulnare



### Articulatio cubiti - movements

flexion and extension

Pronation and supination of forearm



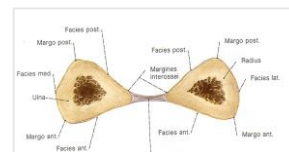
### Juncturae radioulnares

**Membrana interossea antebrachii**

Fixation of the radius and ulna, origin of the muscles

Limitation of supination

chorda obliqua



**Articulatio radioulnaris distalis**

**Facets:** incisura ulnaris radii, circumferentia articularis capitis ulnae

**Capsule:** thin and tough

**Apparatus:** ligamentum radioulnaris palmare, dorsale

**Type:** articulatio trochoidea

**Movements:** pronation and supination of the hand

**Articulationes manus**

- Articulatio radiocarpalis
- Articulatio mediocarpalis
- Articulatio ossis pisiformis
- Articulatio carpometacarpalis pollicis
- Articulationes carpometacarpales II-V.
- Articulationes metacarpophalangeales
- Articulationes interphalangeales

**Articulatio radiocarpalis**

**Facets:**  
 facies articularis carpalis radii, discus articularis  
 os scaphoideum, os lunatum, os triquetrum (lig. intercarpalia interossea)

**Morphologic and functional unit with articulatio mediocarpalis**

Common with mediocarpal joint:

- capsule
- apparatus
- movements

Type - articulatio elipsoidea

**Articulatio mediocarpalis**

**Facets:** proximal and distal row of the carpal bones except for os pisiforme

**Radial:**  
 head: os scaphoideum  
 pit: os trapezium, trapezoideum, capitatum

**Ulnar:**  
 head: os capitatum, hamatum  
 pit: os scaphoideum, lunatum, triquetrum

**Communication with art. carpometacarpalis II-V.**  
 (between os trapezium and trapezoideum)

**Articulatio mediocarpalis - apparatus**

- ligg. intercarpea dorsalia, palmaria et interossea
- lig. radiocarpum dorsale et palmare
- lig. ulnocarpum palmare et dorsale
- lig. carpi radiatum

**Articulatio mediocarpalis**

Functional unit with **articulatio radiocarpalis** - ellipsoid joint

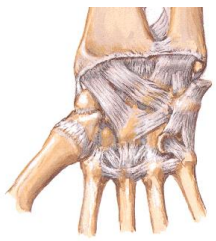
**Movements:**  
 palmar and dorsal flexion  
 radial and ulnar duction  
 circumduction

**Articulatio ossis pisiformis**

**Facets:**  
os pisiforme, os triquetrum

**Capsule:**  
Margins of the art. facets

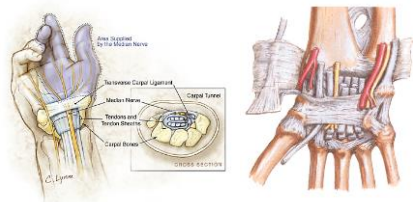
**Apparatus:**  
lig. pisohamatum  
lig. pisometacarpeum  
(m. flexor carpi ulnaris)



**Canalis carpi**

**Canalis carpi:** tendons of flexors and nervus medianus

**Canal of Guyon:** nervus et vasa ulnaria  
(between hamulus ossis hamati and os pisiforme, above retinaculum flexorum)



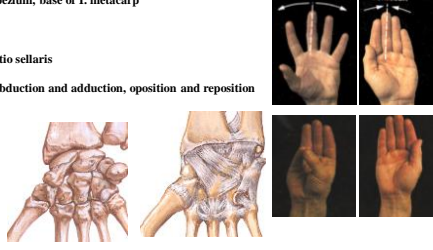
**Articulatio carpometacarpalis pollicis**

**Facets:** os trapezium, base of I. metacarp

**Capsule:** free

**Type:** articulatio sellaris

**Movements:** abduction and adduction, opposition and reposition




**Articulationes carpometacarpales II. - V.**

**Facets:** base of the II. - V. metacarpal bones with distal row of the capal bones adjacent metacarpal bones

**Capsule:** tough, communication with mediocarpal joint

**Apparatus:**  
ligg. metacarpea palmaria, dorsalia et interossea,  
ligg. carpometacarpea palmaria, dorsalia et interossea

**Type:** amfiarthrosis



**Articulationes metacarpophalangeae**

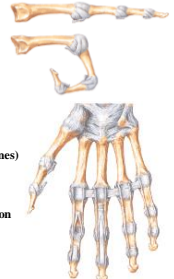
**Facets:** head of the metacarpal bones, base of proximal phalanges

**Capsule:** margines of the facets

**Apparatus:**  
laminae fibrocartilagineae palmares  
(thumb - 2 ossa sesamoidea)  
lig. collaterale radiale et ulnare  
lig. metacarpeum transversum profundum  
(palmar side of the heads of II. - V. metacarpal bones)

**Type:** articulatio ellipsoidea

**Movements:** flexion, extension, abduction, adduction



**Articulationes interphalangeae manus**

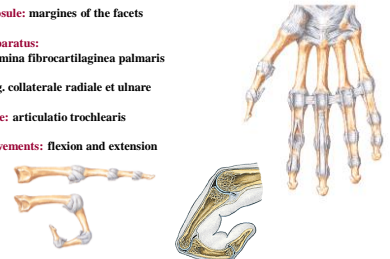
**Facets:**  
trochlea phalangis of the proximal and base of the distal phalanges

**Capsule:** margines of the facets

**Apparatus:**  
lamina fibrocartilaginea palmaris  
lig. collaterale radiale et ulnare

**Type:** articulatio trochlearis

**Movements:** flexion and extension



**Connections of the lower extremity girdle**  
(juncturae ossium cinguli extremitatis inferioris)

**Articulatio sacroiliaca**

**Symphysis pubica**

**Ligaments of the pelvis**

**Articulatio sacroiliaca**

**Facets:**  
 facies auricularis ossis sacri  
 facies auricularis ossis ilii

**Capsule:** tough, margins of the facets

**Apparatus:**  
 ligg. sacroiliaca ventralia, dorsalia, intersesca

**lig. iliolumbale**

**Type:** amfiarthrosis

**Movements:** limited

**Symphysis pubica**

symphrosis  
 discus interpubicus (4,5 – 5 cm)  
 eminentia retropubica.  
 lig. pubicum superius  
 lig. arcuatum pubis

**Ligaments of the pelvis**

Ligamentum sacrospinale  
 Ligamentum sacrotuberale  
 Foramen ischiadicum majus et minus  
 (foramen suprapiriforme et infrapiriforme)  
 Ligamentum inguinale  
 Membrana obturatoria (canalis obturatorius)

**Pelvis**

**Pelvis** - os sacrum, hip bones, symphysis pubica

**Linea terminalis** (promontorium, linea arcuata, upper margin of os pubis and symphysis)

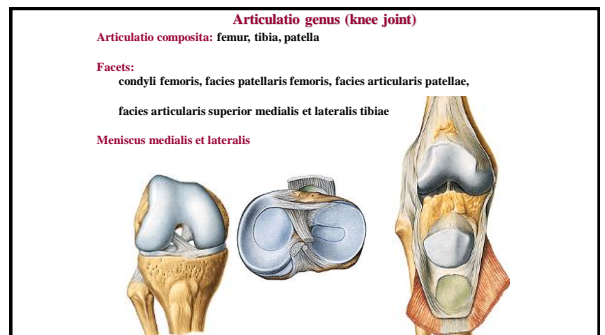
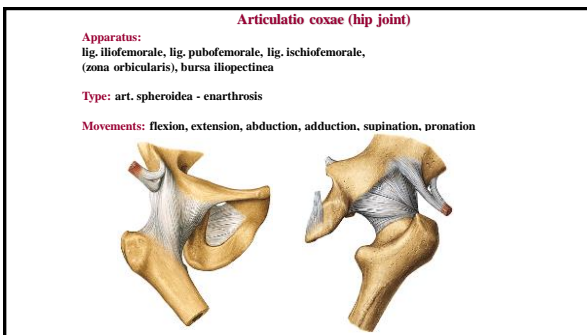
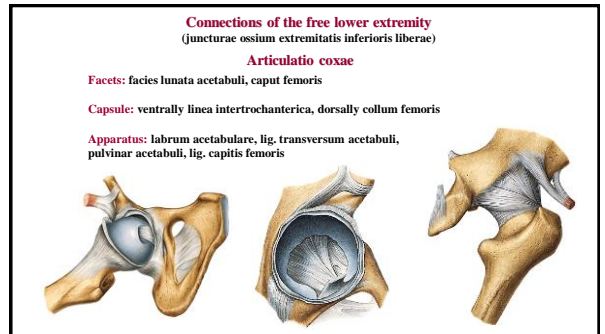
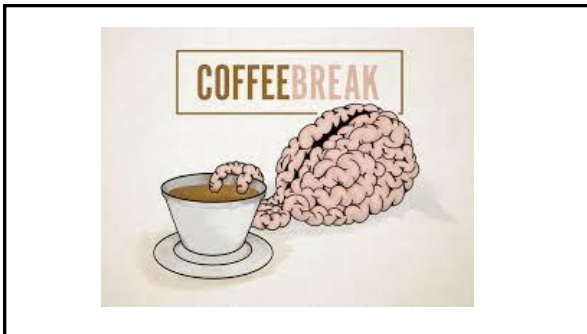
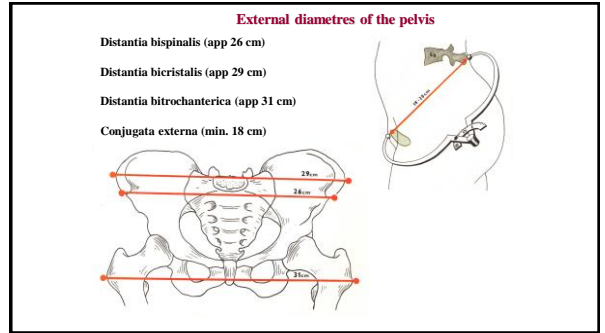
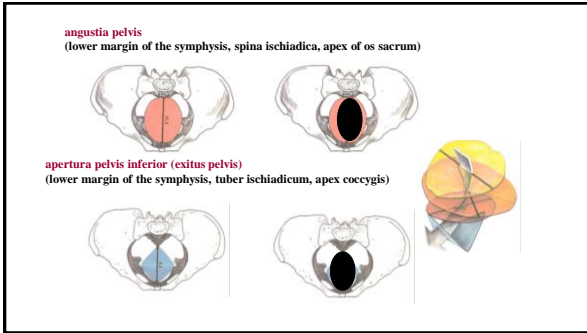
**Pelvis major et minor**

**Inclinatio pelvis**

**Pelvic planes**

**apertura pelvis superior (aditus pelvis)**  
 (promontorium, linea terminalis, upper margin of the symphysis)

**amplitudo pelvis**  
 (S<sub>2</sub> – S<sub>3</sub>, center of the acetabulum and symphysis)



**Articulatio genus - capsula articularis**  
 Attachment: margins of the facets, femur app 1cm proximally  
 Capsula fibrosa  
**Capsula synovialis** - plica synovialis patellaris, plicae alares (ligg. cruciata - EXTRACAPSULAR )

The diagrams show the knee joint from various perspectives: a lateral view of the capsule, a cross-section of the synovial sheath with labels for the anterior and posterior horns of the meniscus, and a posterior view of the joint.

**Meniscus medialis et lateralis**  
**Meniscus medialis** - „C“, area intercondylaris ant. et post. (connected with lig. collaterale med.)  
**Meniscus lateralis** - „O“, anteriorly and posteriorly from tuberculum intercondylare laterale (connected with m. popliteus)  
 (lig. transversum genus)

The diagrams illustrate the shape and position of the medial and lateral menisci. The medial meniscus is C-shaped and connected to the medial collateral ligament. The lateral meniscus is O-shaped and connected to the popliteus muscle. A diagram shows the ligamentum transversum genus connecting the two menisci.

**Ligamenta cruciata genus**  
**Lig. cruciatum anterius:** condylus lat. femoris – area intercondylaris ant. tibiae (Limitation of extension and medial rotation)  
**Lig. cruciatum posterius:** condylus med. femoris – area intercondylaris post. tibiae (Limitation of extension and keep the stability of the joint)

The diagrams show the knee joint from an anterior and a posterior perspective, highlighting the location and orientation of the anterior and posterior cruciate ligaments.

**Articulatio genus - ligaments**  
 lig. patellae  
 retinaculum patellae mediale et laterale  
 lig. collaterale mediale et laterale  
 lig. popliteum obliquum

The diagrams show the knee joint from multiple angles, illustrating the patellar ligament, the medial and lateral retinacula, the collateral ligaments, and the oblique popliteal ligament.

**Bursae synoviales**  
 Bursa suprapatellaris (mm. articulares)  
 Bursa praepatellaris (subcutanea)  
 Bursa infrapatellaris  
 Bursae mucosae under insertion of the muscles (m. biceps femoris, m. semitendinosus, m. semimembranosus, m. popliteus, m. gastrocnemius)

The diagram shows the knee joint with labels for the suprapatellar, praepatellar, and infrapatellar bursae, as well as the mucous bursae under the insertion of the biceps femoris, semitendinosus, semimembranosus, popliteus, and gastrocnemius muscles.

**Articulatio genus**  
**Type:** trochoginglimus  
**Movements:** flexion and extension, in flexion limited rotatory movements (50-60°), patella moves proximally and distally  
**Middle position:** mild flexion

The diagrams illustrate the knee joint in different positions, showing the range of motion for flexion and extension, and the position of the patella during these movements.



**Articulatio tibiofibularis**


**Facets:** facies articularis fibularis tibiae, facies articularis capitis fibulae

**Capsule:** margins of the facets

**Apparatus:** lig. capitis fibulae ant. et post.

**Type:** art. plana

**Movements:** sliding




**Membrana interossea cruris**  
margo interosseus tibiae and fibula

**Syndesmosis tibiofibularis**


**Connection:** distal end of fibula and tibia

**Ligg.:** Lig. tibiofibulare anterius et posterius

**Movements:** springy



**Articulationes pedis**




**Articulatio talocruralis**

**Facets:** facies articularis inf. tibiae, facies articularis malleoli med. et lat.

**Capsule:** margins of the facets

**Apparatus:**  
Lig. collaterale mediale (lig. deltoideum): pars tibiovascularis, pars tibiotalaris ant. et post., pars tibiocalcanea  
Lig. collaterale laterale: lig. talofibulare ant. et post., lig. calcaneofibulare

**Type and movements:** art. trochlearis, plantar and dorsal flexion, movements to the side



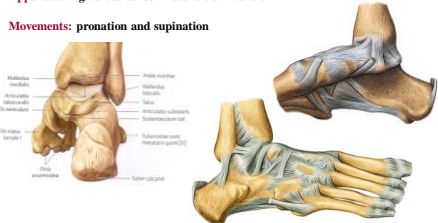
**Articulatio subtalaris**

**Facets:** facies art. calcanea posterior + facies art. talaris post.

**Capsule:** margins of the facets

**Apparatus:** lig. talocalcaneum laterale et mediale

**Movements:** pronation and supination

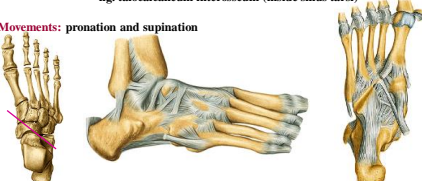


**Articulatio talocalcaneonavicularis**

**Facets:** facies art. calcanea media + ant. tali, facies art. talaris media + ant. calcanei, caput tali + proximal facet on os naviculare

**Apparatus:** lig. calcaneonavicularare plantare (fibrocartilago navicularis), lig. calcaneonavicularare (dorsale) - part of lig. bifurcatum, lig. talonavicularare, lig. talocalcaneum interosseum (inside sinus tarsi)

**Movements:** pronation and supination

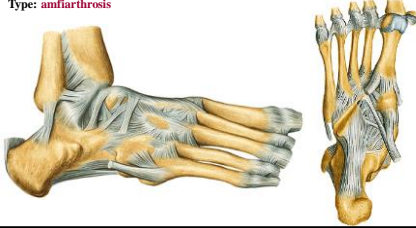

**Articulatio calcaneocuboidea**

**Facets:** facies artic. cuboidea calcanei, facies art. os cuboideum

**Apparatus:** lig. calcaneocuboideum plantare  
lig. plantare longum  
lig. bifurcatum = lig. calcaneocuboideum (dorsale)

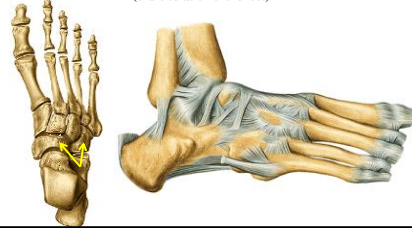
**Type:** amfiarthrosis



**Articulatio tarsi transversa (Chopart's joint)**

**Facets:** caput tali + os naviculare + os cuboideum and calcaneus

**Apparatus:**  
lig. bifurcatum: lig. calcaneocuboideum dor. and lig. calcaneonaviculare dor.  
(exarticulation of the foot)

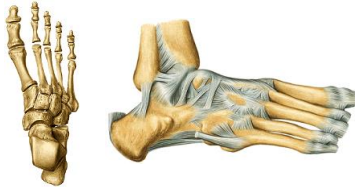

**Articulatio cuneonavicularis**

**Facets:** ossa cuneiformia and os naviculare

**Apparatus:**  
ligg. cuneonavicularia plantaria et dorsalia  
ligg. intercuneiformia dorsalia, plantaria et interossea

**Type:** amfiarthrosis



**Articulatio cuneocuboidea**

**Facets:** os cuneiforme laterale and os cuboideum

**Apparatus:** ligg. cuneocuboidea (dorsale, plantare et interosseum)

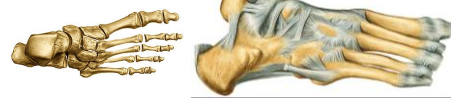**Type:** amfiarthrosis

**Articulaciones intercuneiformes**

**Facets:** cuneiform bones

**Apparatus:** ligg. intercuneiformia dorsalia, plantaria, interossea

**Type:** amfiarthrosis



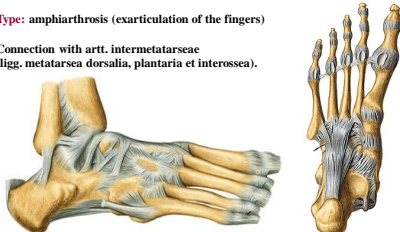
**Articulaciones tarsometatarsales (Lisfranc's joint)**

**Facets:** bases of the metatarsal bones, ossa cuneiformia, os cuboideum

**Apparatus:** ligg. tarsometatarsea dorsalia, plantaria et interossea

**Type:** amphiarthrosis (exarticulation of the fingers)

**Connection with art. intermetatarsee**  
(ligg. metatarsea dorsalia, plantaria et interossea).

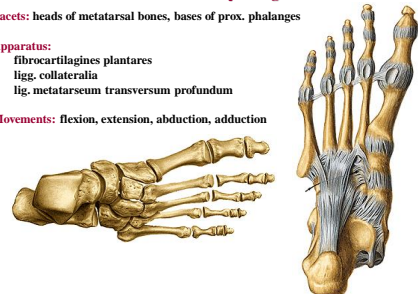


**Articulaciones metatarsophalangeae**

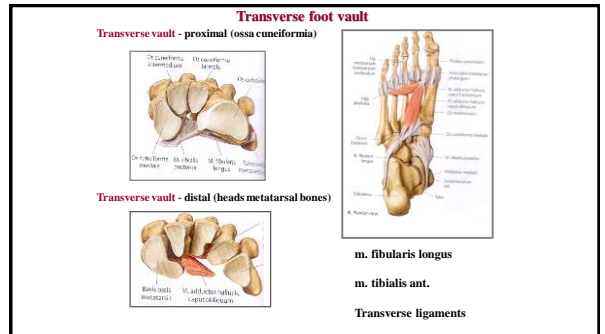
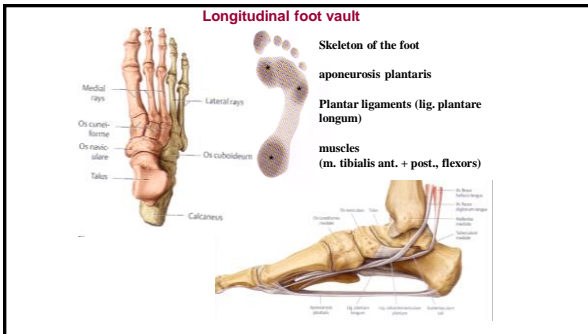
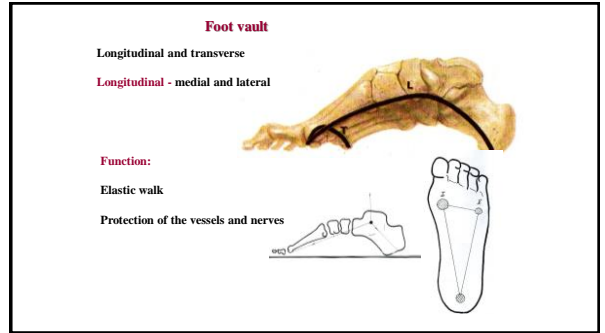
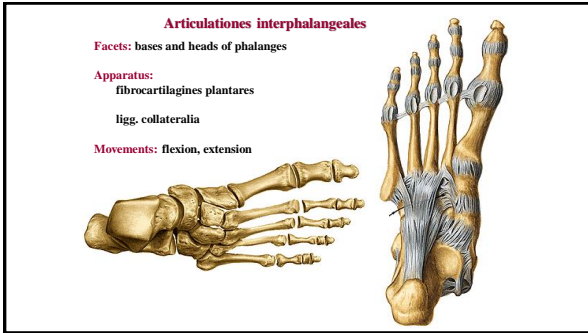
**Facets:** heads of metatarsal bones, bases of prox. phalanges

**Apparatus:**  
fibrocartilagine plantares  
ligg. collateralia  
lig. metatarsium transversum profundum

**Movements:** flexion, extension, abduction, adduction







**References:**

**Moore, K. L. (1992):** Clinical oriented anatomy. Third edition. Williams&Wilkins, A Waverly Company.

**Gilroy, A. M. et al. (2009):** Atlas of Anatomy. Thieme New York, Stuttgart.

**Putz, R. (2009):** Atlas of Human Anatomy Sobotta. Elsevier Books.

**Platzer, W., Kahle, W., Leonhardt H. (1992):** Locomotor system. Georg Thieme Verlag, Stuttgart, New York, 4th edition.

**Čihák, R. (1987):** Anatomie 1. Avicenum, Zdravotnické nakladatelství.