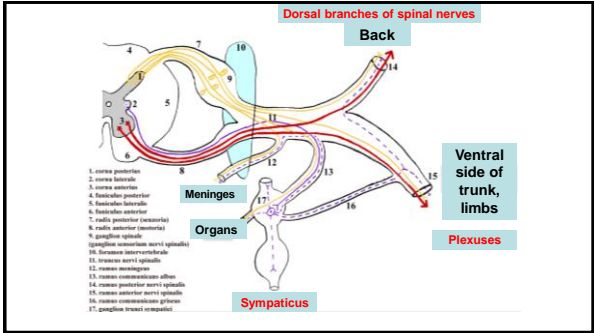


Dissection I

1



2

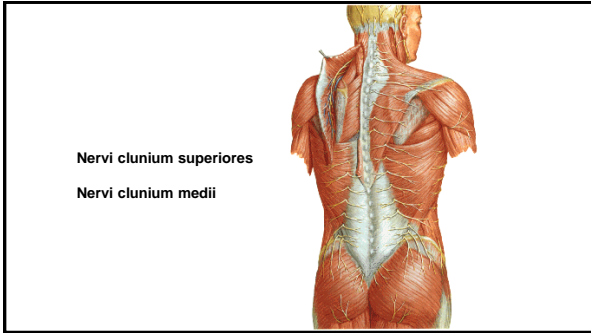
Dorsal branches of spinal nerves

- Segmental organization
- Medial and lateral branch
- Sensory and motor

3

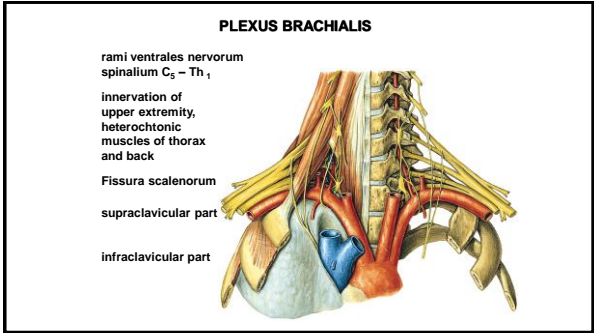
- N. suboccipitalis – C1
- N. occipitalis major – C2
- N. occipitalis tertius – C3

4



Nervi clunium superiores
Nervi clunium medii

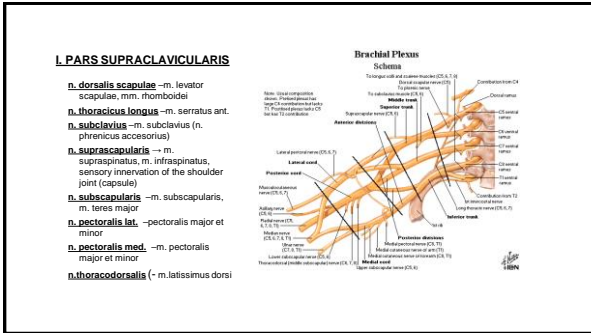
5



PLEXUS BRACHIALIS

rami ventrales nervorum
spinalium C₅ – Th₁
innervation of
upper extremity,
heterochtonic
muscles of thorax
and back
Fissura scalenorum
supraclavicular part
infraclavicular part

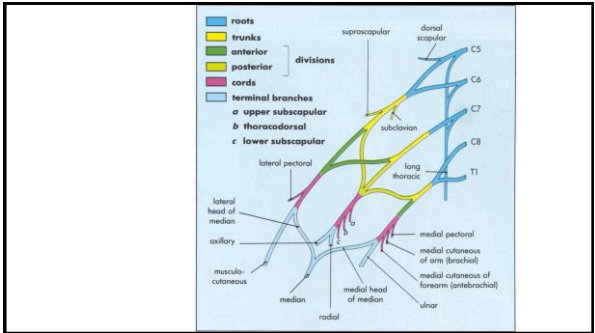
6



I. PARS SUPRACLAVICULARIS

- n. dorsalis scapulae** –m. levator scapulae, mm. rhomboidi
- n. thoracicus longus** –m. serratus ant.
- n. subclavius** –m. subclavius (n. plicatus accessorius)
- n. suprascapularis** –m. supraspinatus, m. infraspinatus, sensory innervation of the shoulder joint (capsule)
- n. subscapularis** –m. subscapularis, m. teres major
- n. pectoralis lat.** –pectoralis major et minor
- n. pectoralis med.** –m. pectoralis major et minor
- n. thoracodorsalis** (-m. latissimus dorsi)

7

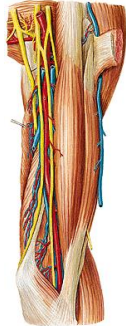


8

Medial cord:
 Nervus ulnaris
 Nervus cutaneus brachii medialis
 Nervus cutaneus antebrachii medialis
 Radix medialis nervi mediani

Lateral cord:
 Nervus musculocutaneus
 Radix lateralis nervi mediani

Posterior cord:
 Nervus radialis
 Nervus axillaris

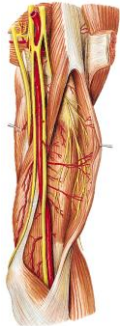


9

Fasciculus lateralis

n. musculocutaneus
 - rr.musculares
 - n. cutaneus antebrachii lat.

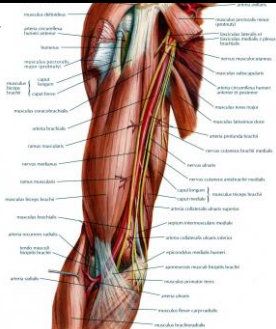
Radix lateralis nervi mediani



10

Fasciculus medialis

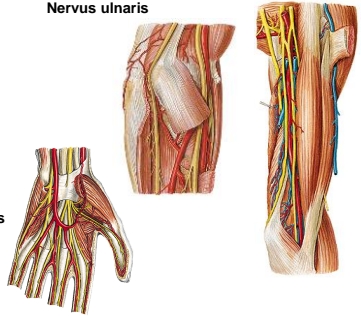
radix medialis n. mediani
n. cutaneus brachii med.
 -nn. intercostales II., (III.) – nn. intercostobrachiales
n. cutaneus antebrachii med.
 r. anterior et r. ulnaris



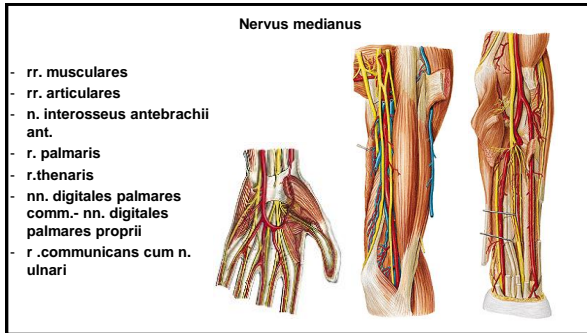
11

Nervus ulnaris

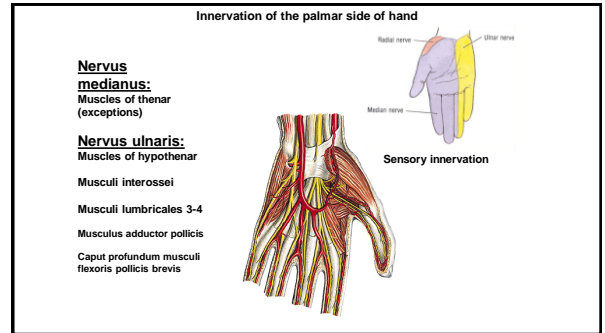
- rr.articulares
- rr.musculares
- r.dorsalis n.ulnari
- nn. digitales dorsales
- r.palmaris n.ulnaris
- r.superficialis
- r.muscularis
- 2 nn.digitales palmares communes et proprii
- r.profundus rr.musculares



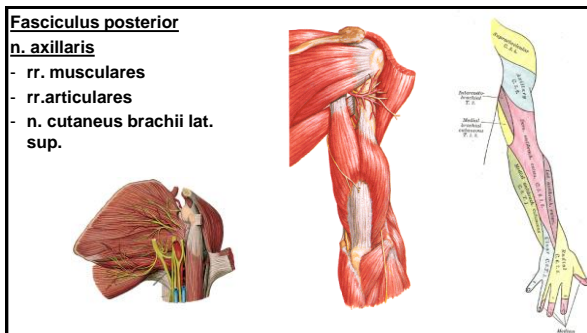
12



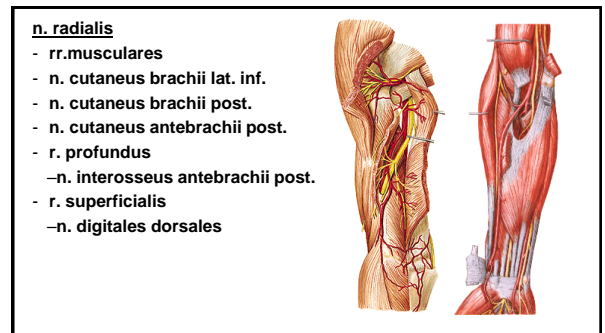
13



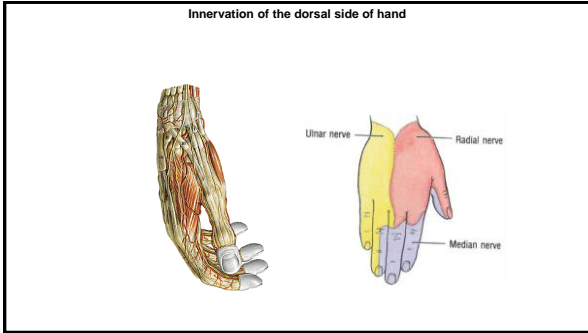
14



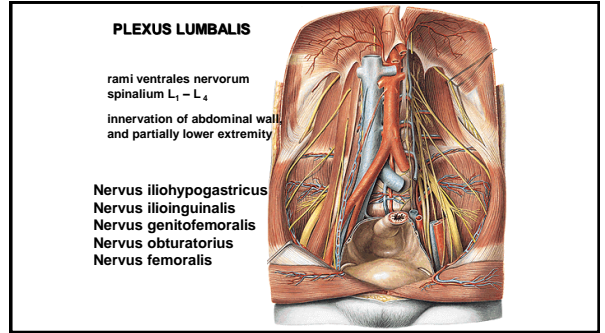
15



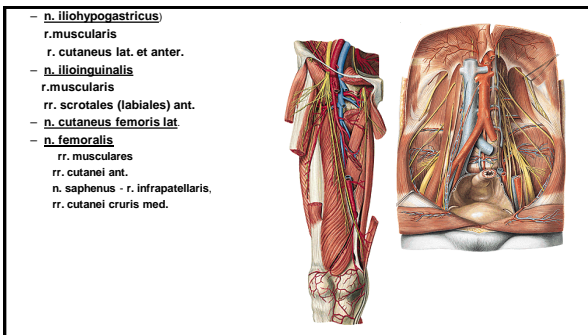
16



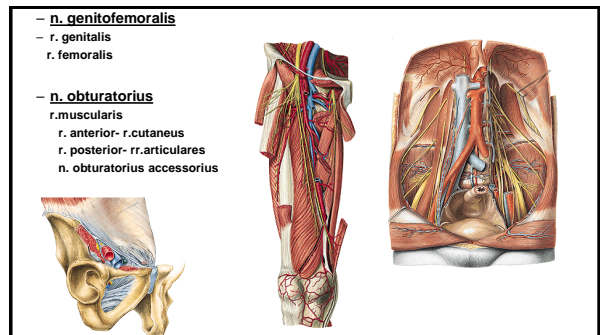
17



18



19

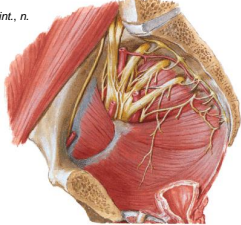


20

PLEXUS SACRALIS

rami ventrales nervorum spinalium L₄ – S₅

rr. musculares: n. piriformis, n. obturatorius int., n. quadratus femoris, mm. gemelli,
Nervus gluteus superior
Nervus gluteus inferior
Nervus pudendus
Nervus cutaneus femoris posterior
Nervus ischiadicus



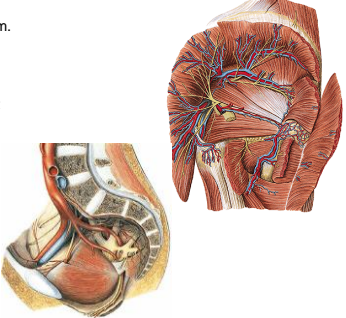
21

n. gluteus sup.
 - m. gluteus medius et minimus, m. tensor fasciae latae

n. gluteus inf. - m. gluteus maximus, joint capsule – hip joint

n. cutaneus femoris post-

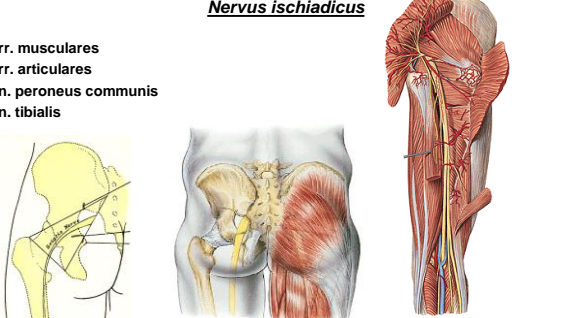
- **rr. perineales**
- **nn. clunium inf.**
- **rr. cutanei**



22

Nervus ischiadicus

rr. musculares
rr. articulares
n. peroneus communis
n. tibialis



23

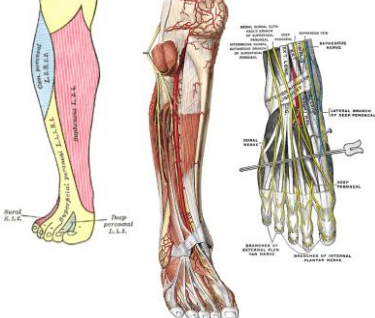
n. peroneus comm.

rr. articulares
n. cutaneus surae lat.-
suralis

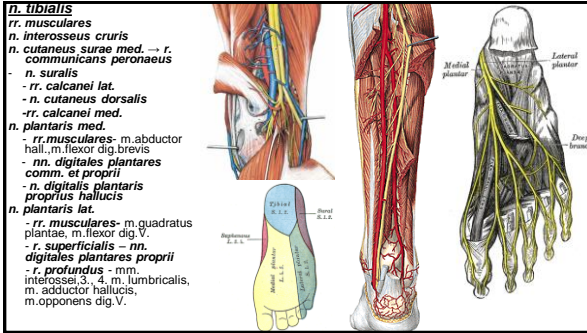
r. communicans peroneus → n. suralis

n. peroneus spfc.
 - **rr. musculares:**
 - **n. cutaneus dorsalis medialis** – **nn. digitales dorsales pedis.**
 - **n. cutaneus dorsi pedis intermedius** – **nn. digitales dors. ped.**

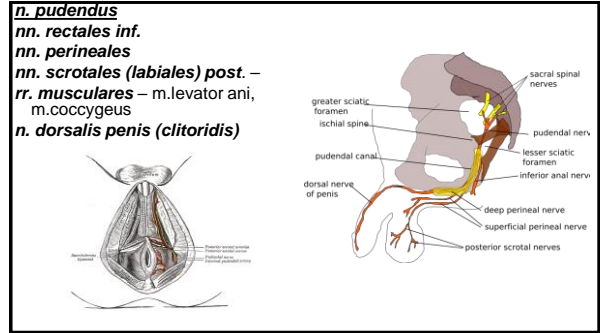
n. peroneus prof.
 - **n. digitalis dorsalis hallucis lat.**
 - **n. digitalis dorsalis digiti secundi medialis**
 - **rr. musculares**



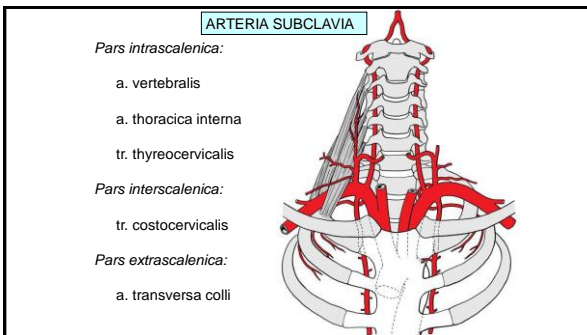
24



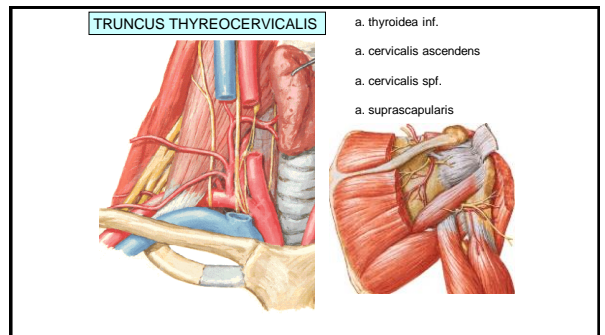
25



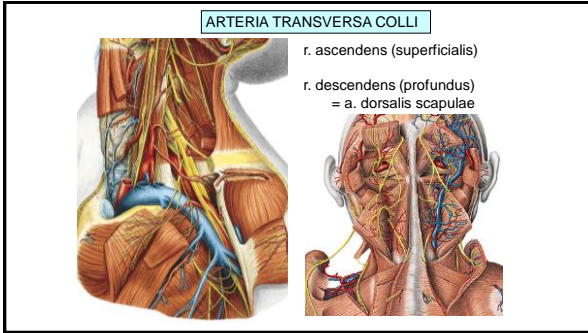
26



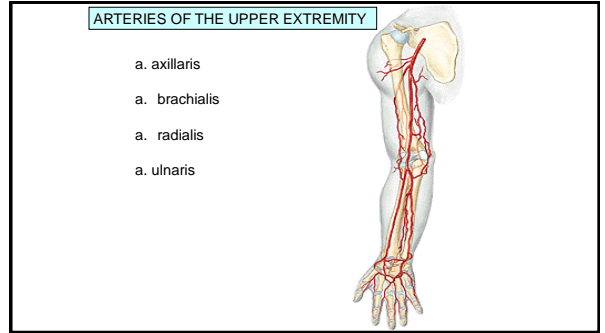
27



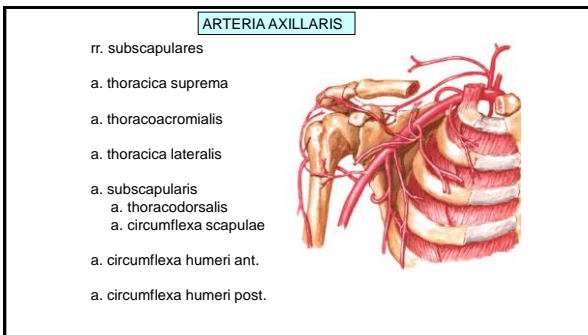
28



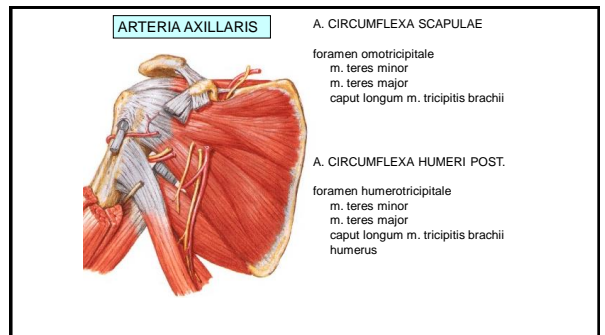
29



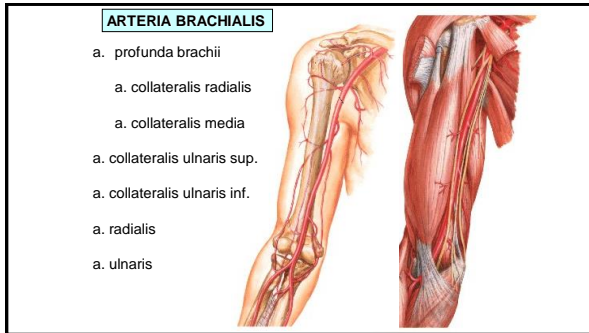
30



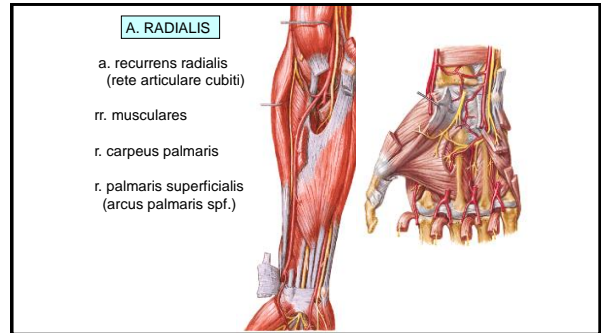
31



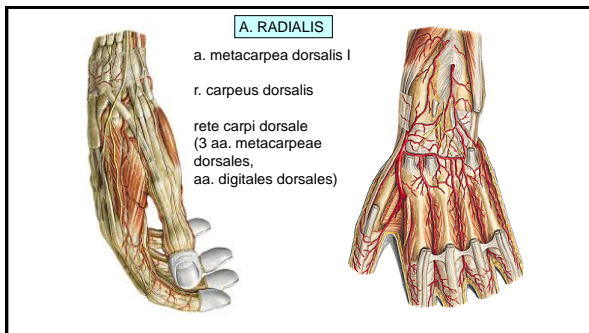
32



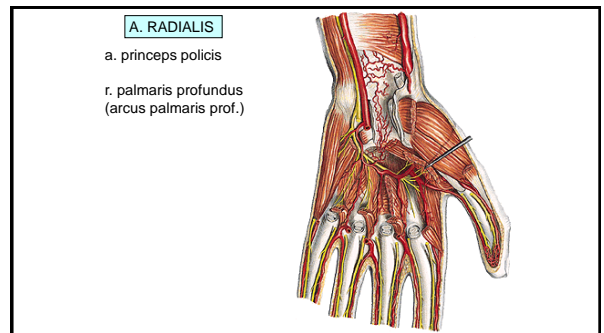
33



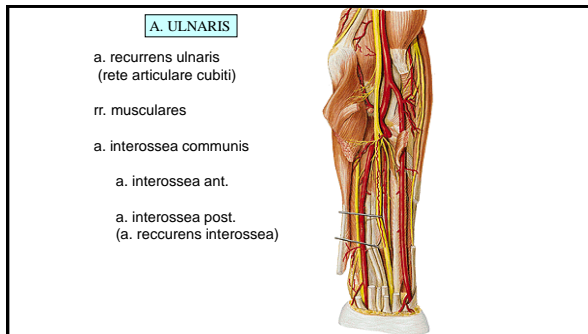
34



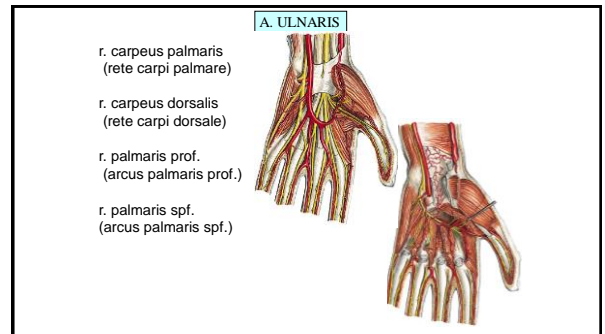
35



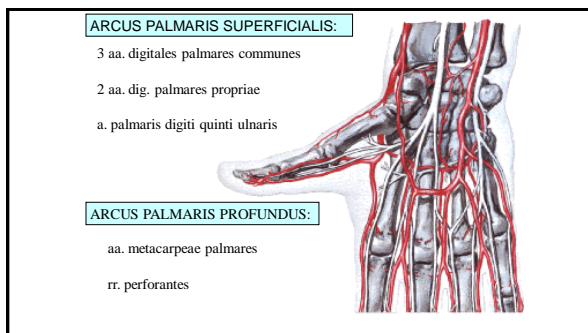
36



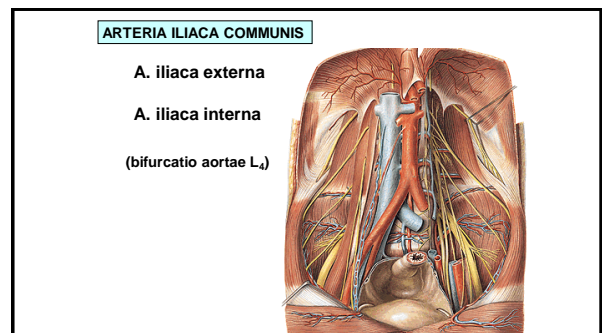
37



38



39

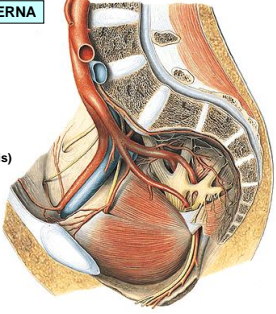


40

ARTERIA ILIACA INTERNA

Parietal branches

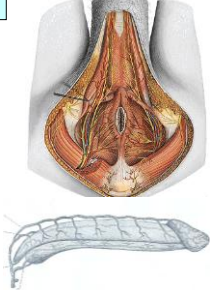
- a. iliolumbalis
- a. sacralis lat.
- a. obturatoria
(r. pubicus - corona mortis)
- a. glutea sup.
- a. glutea inf.
- a. pudenda interna



41

ARTERIA PUDENDA INTERNA

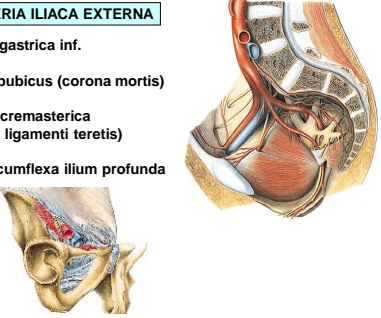
- a. rectalis inf.
- a. perinealis – rr. scrotales post.
(rr. labiales post.)
- a. penis (a. clitoridis)
 - a. profunda penis (clitoridis)
 - a. dorsalis penis (clitoridis)



42

ARTERIA ILIACA EXTERNA


- a. epigastrica inf.
- r. pubicus (corona mortis)
- a. cremasterica
(a. ligamenti teretis)
- a. circumflexa ilium profunda



43

ARTERIES OF THE LOWER EXTREMITY

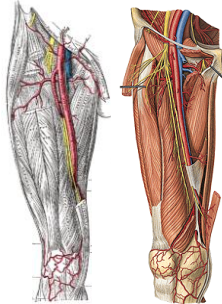
- a. femoralis
(lacuna vasorum, trigonum femorale, canalis adductorius, hiatus tendineus)
- a. poplitea
(fossa poplitea)
- a. tibialis anterior
(a. dorsalis pedis)
- a. tibialis posterior
(malleolus medialis, a. plantaris medialis, a. plantaris lateralis)



44

ARTERIA FEMORALIS

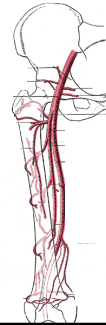
- A. epigastrica spf.
- A. circumflexa ilium spf.
- Aa. pudendae ext.
- A. profunda femoris
- Rr. musculares
- A. genus descendens



45

ARTERIA PROFUNDA FEMORIS

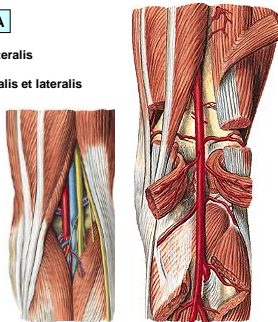
- A. circumflexa femoris medialis
(r. superficialis et profundus)
- A. circumflexa femoris lat.
(r. ascendens et descendens)
- A. perforans prima
(a. nutritia femoris sup.)
- A. perforans secunda
- A. perforans tertia
(a. nutritia femoris inf.)



46

ARTERIA POPLITEA

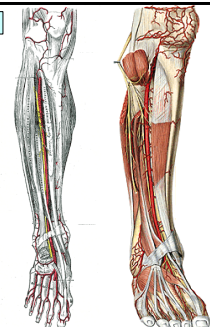
- A. suralis medialis et lateralis
- A. genus superior medialis et lateralis
- A. genus media
- A. genus inferior medialis et lateralis
- A. tibialis ant.
- A. tibialis post.



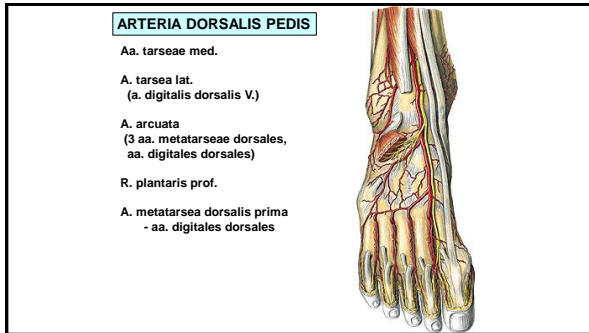
47

ARTERIA TIBIALIS ANTERIOR

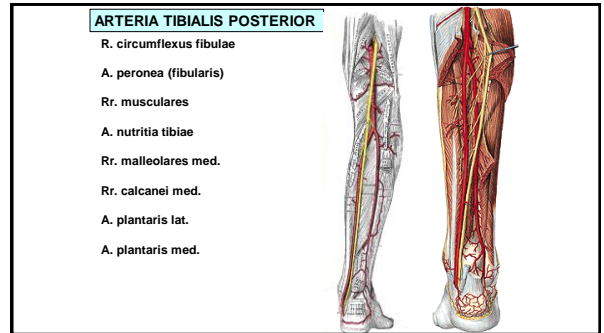
- A. recurrens tibialis post.
- A. recurrens tibialis ant.
- Rr. musculares
- A. malleolaris ant. med. et lat.
- A. dorsalis pedis



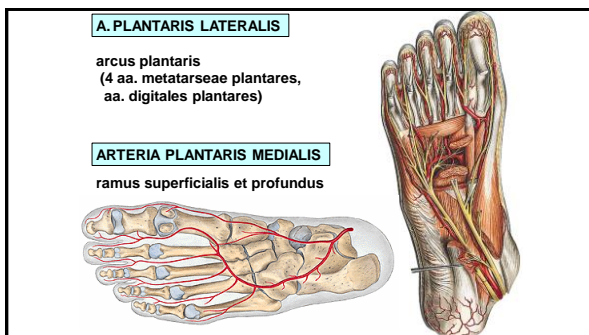
48



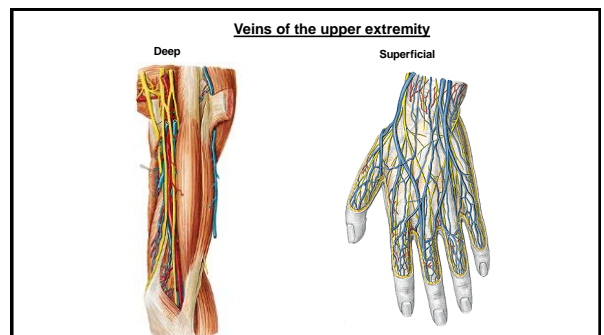
49



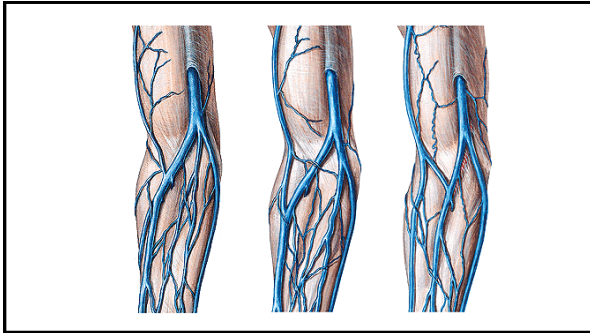
50



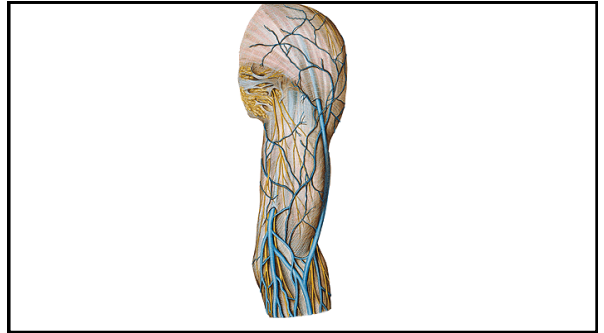
51



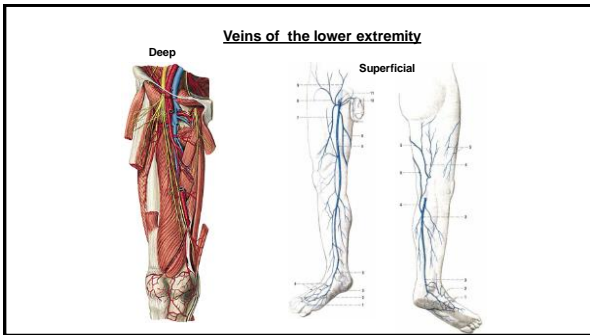
52



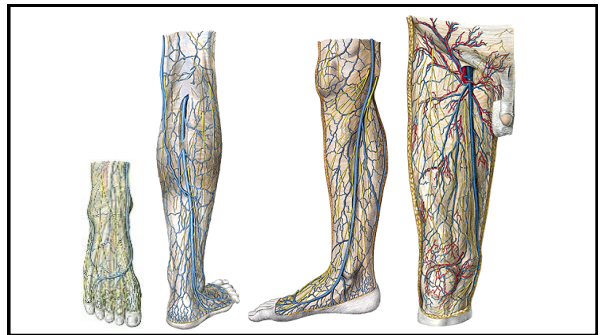
53



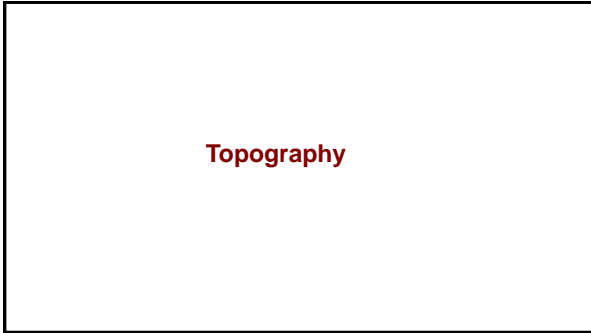
54



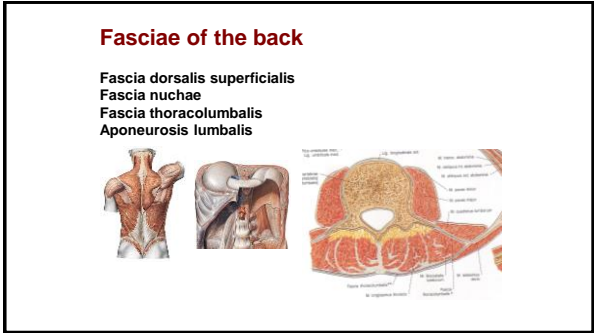
55



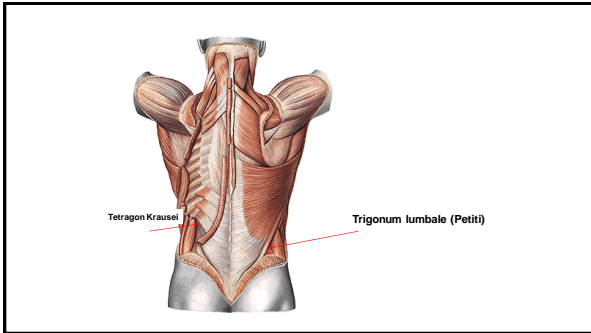
56



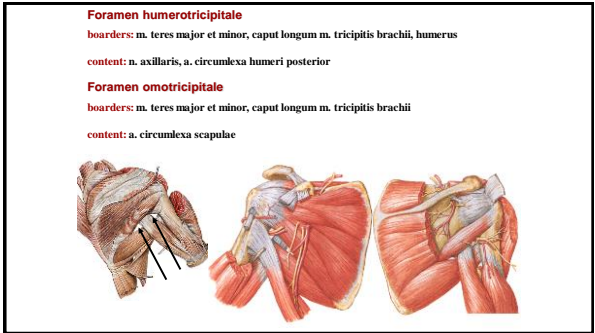
57



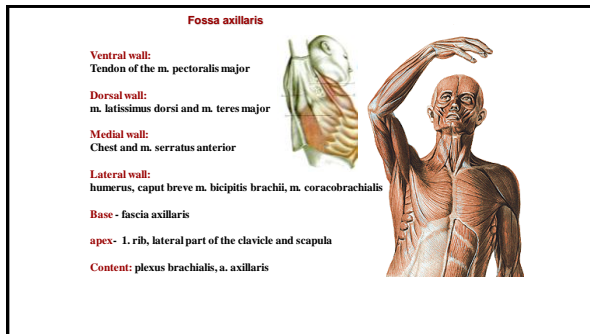
58



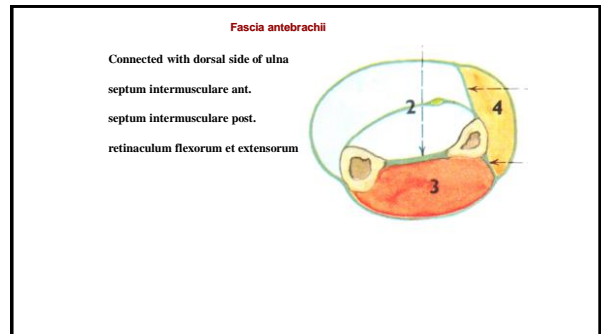
59



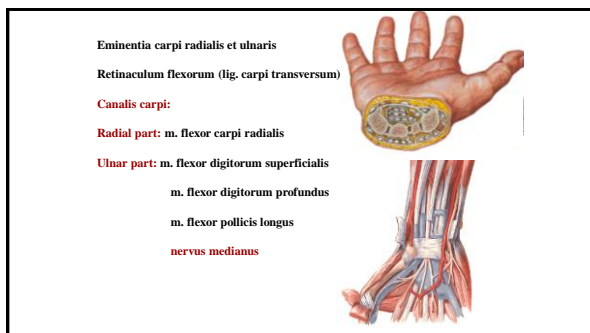
60



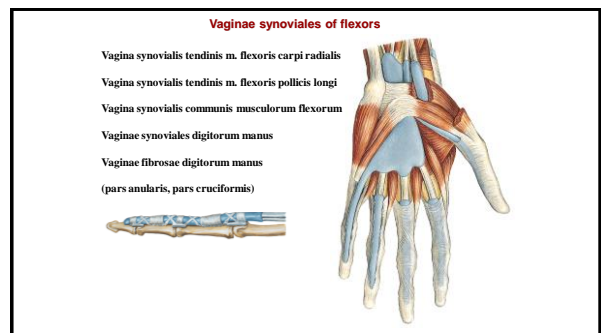
61



64



65



66

Vaginae synoviales of the extensors

Retinaculum extensorum (radius - os triquetrum a os hamatum)

1. m. abductor pollicis longus
m. extensor pollicis brevis
2. m. extensor carpi radialis longus et brevis
3. m. extensor pollicis longus
4. m. extensor indicis
m. extensor digitorum communis
5. m. extensor digiti minimi
6. m. extensor carpi ulnaris

67

Fasciae manus

- Fascia dorsalis manus superficialis
- Fascia dorsalis manus intertendinea
- Fascia dorsalis manus interossea
- Fascia palmaris superficialis - **aponeurosis palmaris**
- Fascia palmaris interossea
- Septum palmare radiale (3rd metacarpal bone)
- Septum palmare ulnare (5th metacarpal bone)
- Spatium palmare radiale, ulnare, medium**

68

Foramen suprapiriforme:
Content: vasa glutea superiora, nervus gluteus superior

Foramen infrapiriforme: nervus ischiadicus, nervus cutaneus femoris posterior, vasa glutea inferiora, nervus gluteus inferior, vasa pudenda interna, nervus pudendus

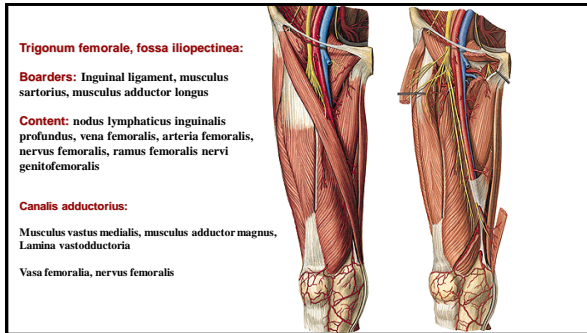
69

Inguinal ligament, arcus iliopectineus, os coxae

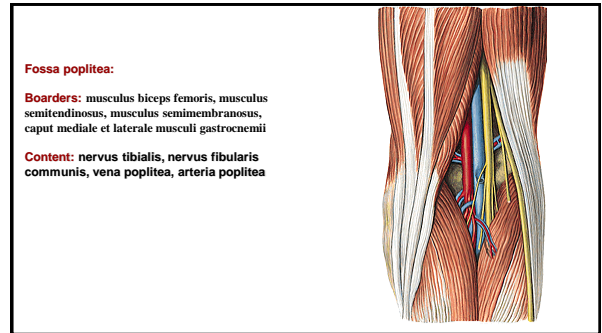
Lacuna vasorum:
Arteria et vena femoralis, ramus femoralis nervi genitofemoralis

Lacuna musculorum:
Iliopsoas, nervus femoralis, nervus cutaneus femoris lateralis

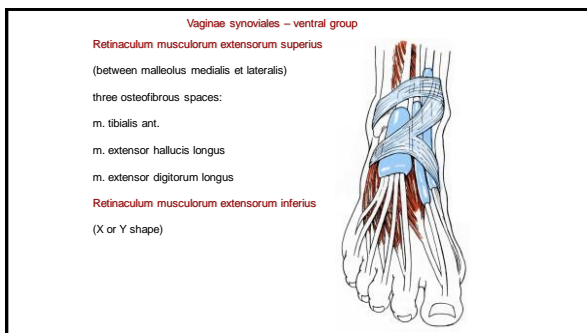
70



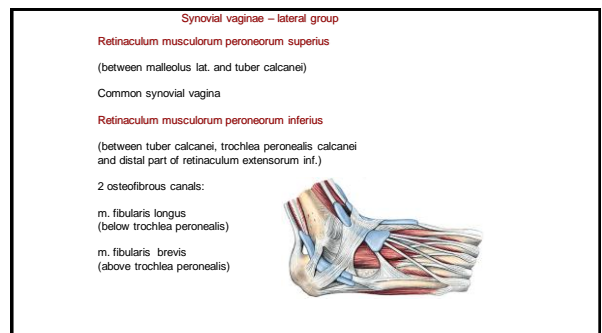
71



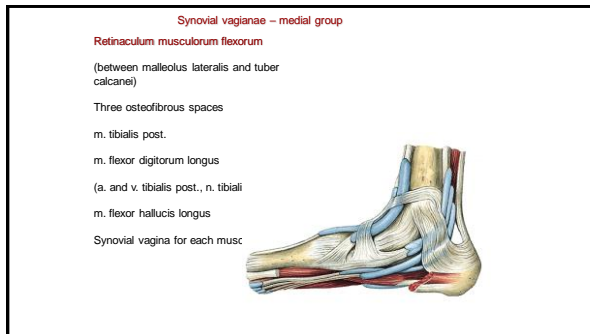
72



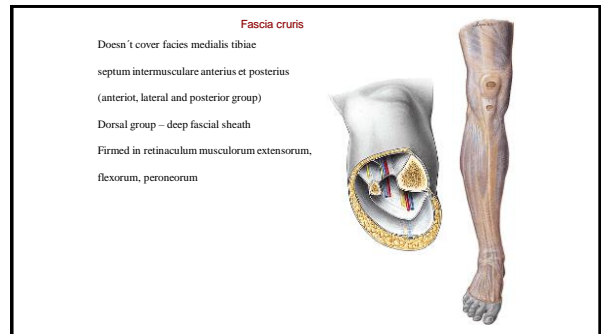
73



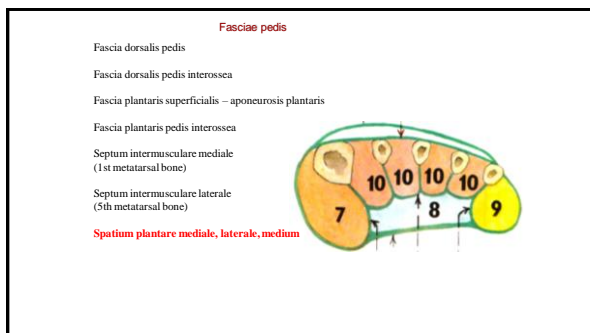
74



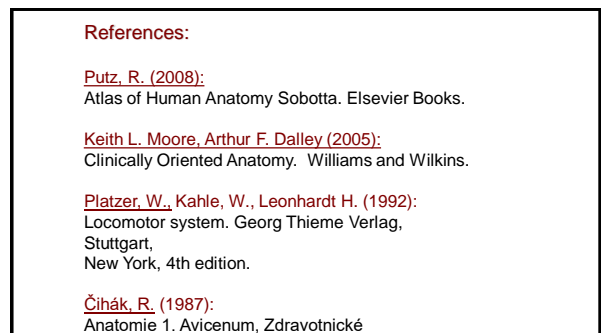
75



76



77



78