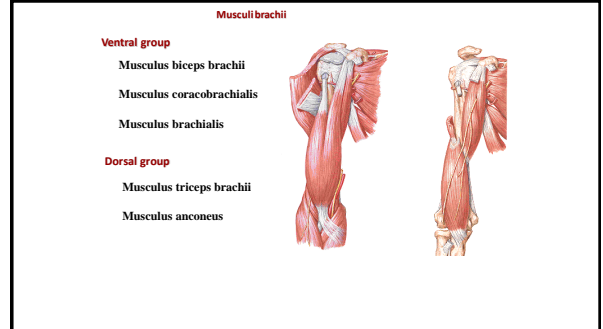
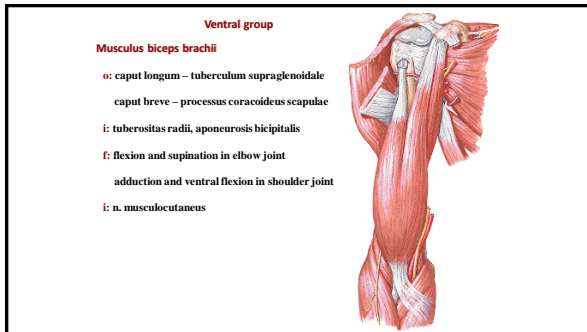


Muscles of the upper and lower extremity

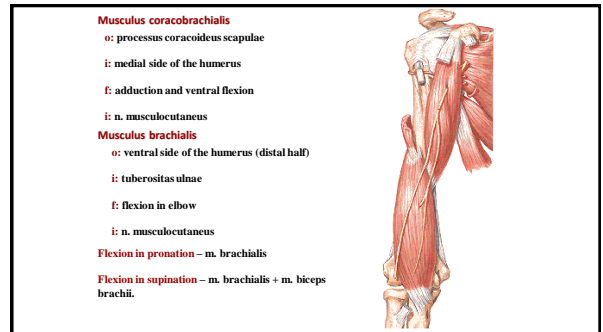
1



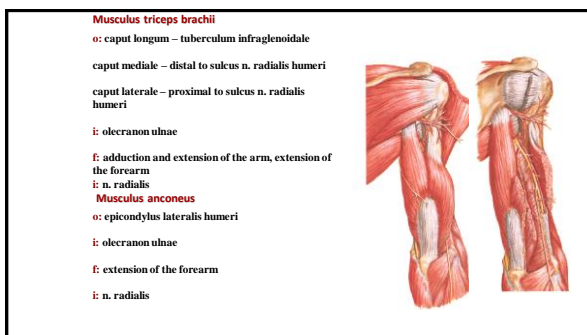
2



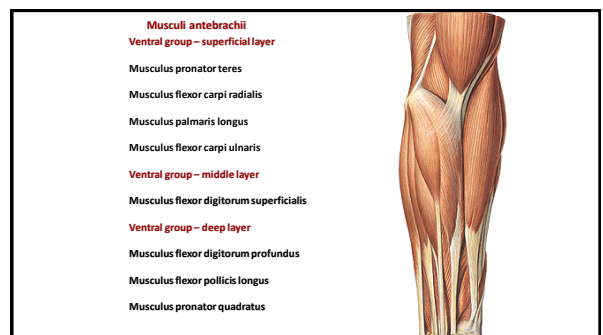
3



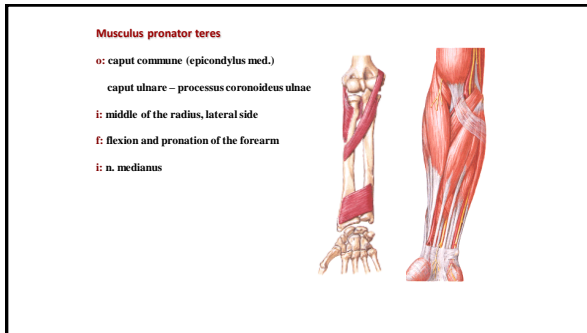
4



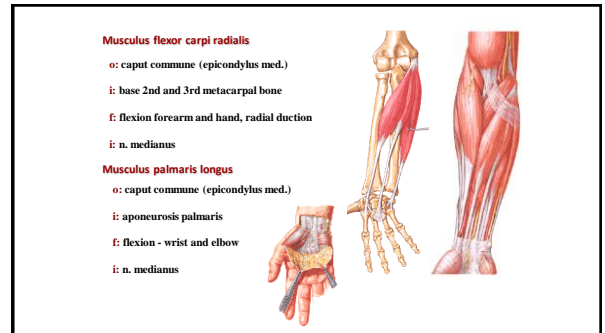
5



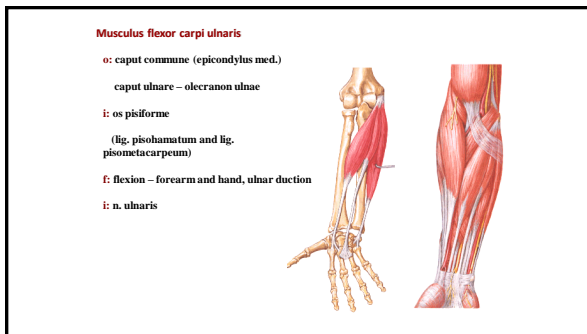
6



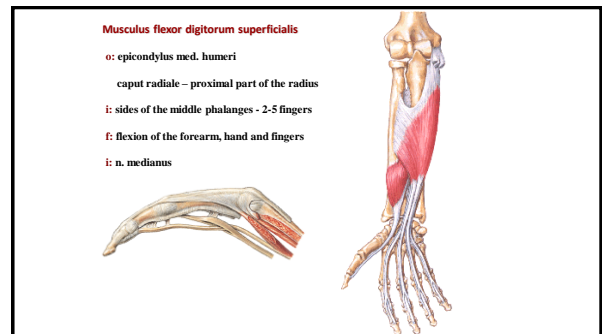
7



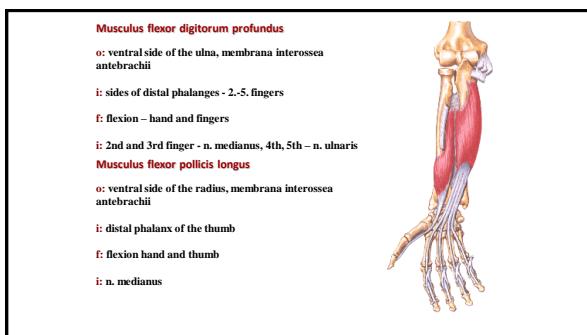
8



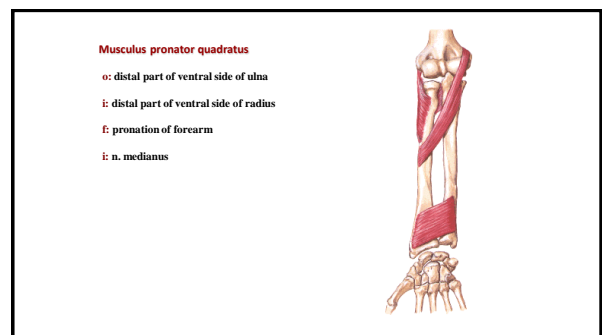
9



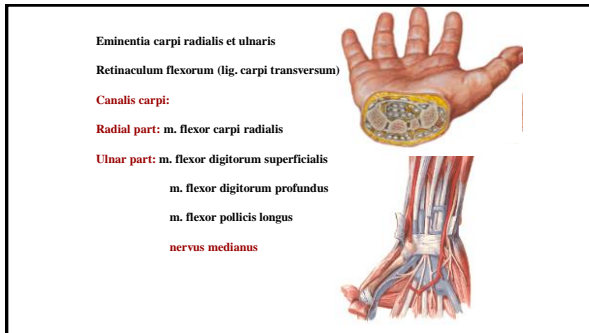
10



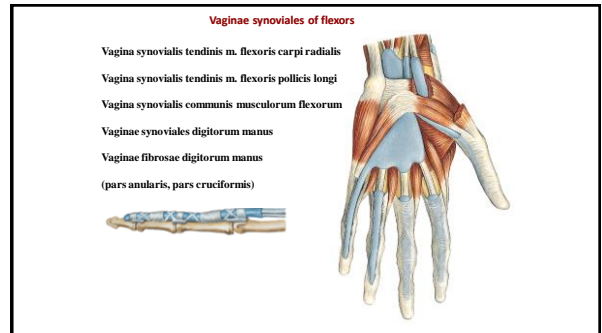
11



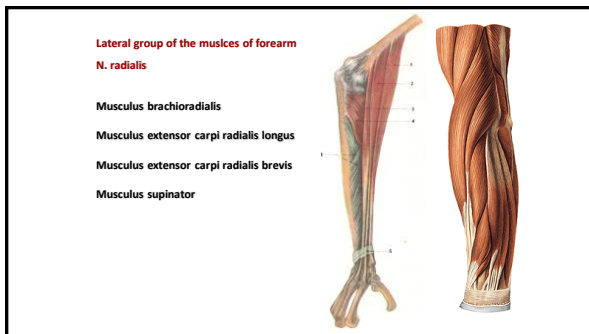
12



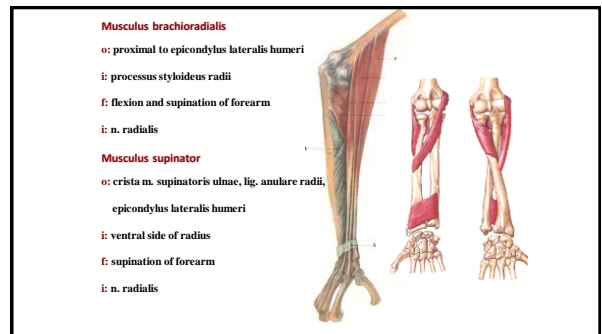
13



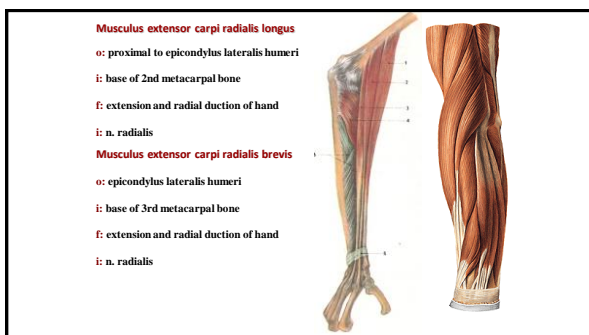
14



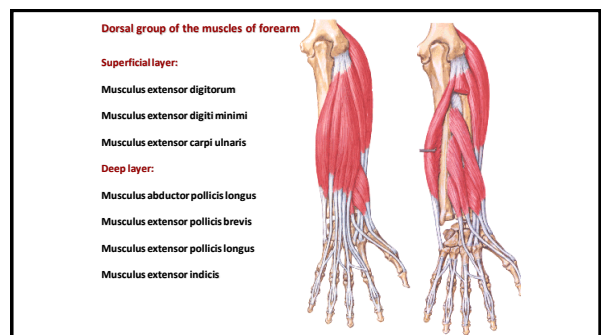
15



16



17




18

Musculus extensor digitorum
 o: epicondylus lateralis humeri
 i: dorsal aponeurosis of 2.-5. finger
 f: extension of the hand and fingers

Musculus extensor digiti minimi
 o: epicondylus lateralis humeri
 i: dorsal aponeurosis of 5th finger
 f: extension of the hand and 5th finger

Musculus extensor carpi ulnaris
 o: epicondylus lateralis humeri
 i: base of 5th metacarpal bone
 f: extension of hand and ulnar duction




19

Musculus abductor pollicis longus
 o: dorsal side of ulna and radius, membrana interossea antebrachii
 i: base of 1st metacarpal bone
 f: abduction of thumb

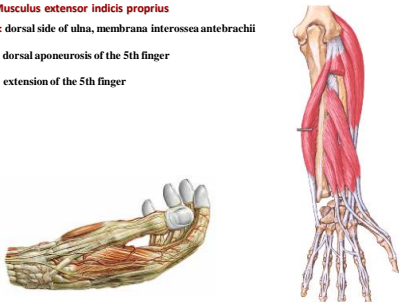
Musculus extensor pollicis brevis
 o: membrana interossea antebrachii, dorsal side of radius
 i: dorsalside of proximal phalanx
 f: extension and abduction of thumb

Musculus extensor pollicis longus
 o: membrana interossea antebrachii, dorsal side of ulna
 i: dorsalside of distal phalanx
 f: extension of thumb



20

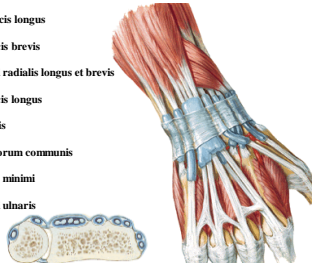
Musculus extensor indicis proprius
 o: dorsal side of ulna, membrana interossea antebrachii
 i: dorsal aponeurosis of the 5th finger
 f: extension of the 5th finger



21

Vaginae synoviales of the extensors
 Retinaculum extensorum (radius - os triquetrum a os hamatum)

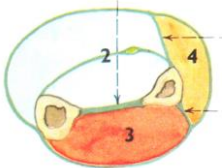
1. m. abductor pollicis longus
 m. extensor pollicis brevis
2. m. extensor carpi radialis longus et brevis
3. m. extensor pollicis longus
4. m. extensor indicis
 m. extensor digitorum communis
5. m. extensor digiti minimi
6. m. extensor carpi ulnaris



22

Fascia antebrachii

Connected with dorsal side of ulna
 septum intermusculare ant.
 septum intermusculare post.
 retinaculum flexorum et extensorum

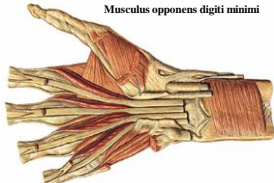


23

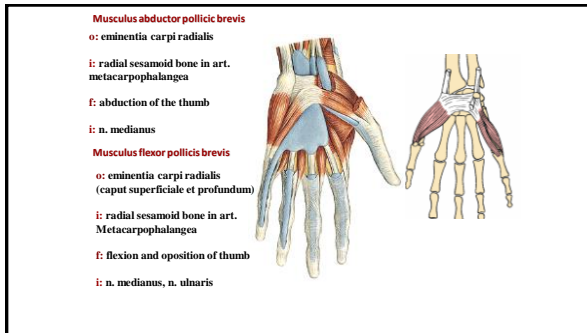
Musculi manus

Muscles of thenar:	Muscles of hypothenar:
Musculus abductor pollicis brevis	Musculus palmaris brevis
Musculus flexor pollicis brevis	Musculus abductor digiti minimi
Musculus opponens pollicis	Musculus flexor digiti minimi
Musculus adductor pollicis	Musculus opponens digiti minimi

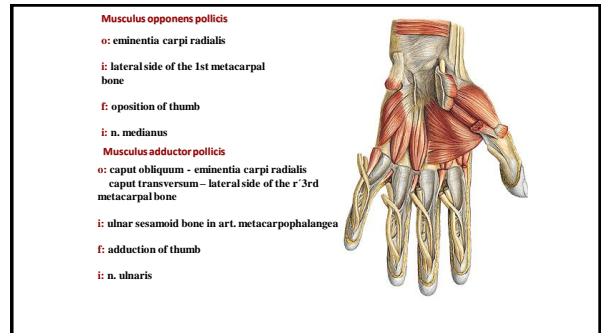
Middle group:
 Musculi interossei dorsales
 Musculi interossei palmares
 Musculi humbricales



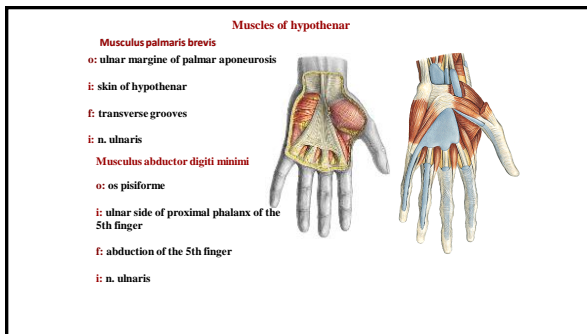
24



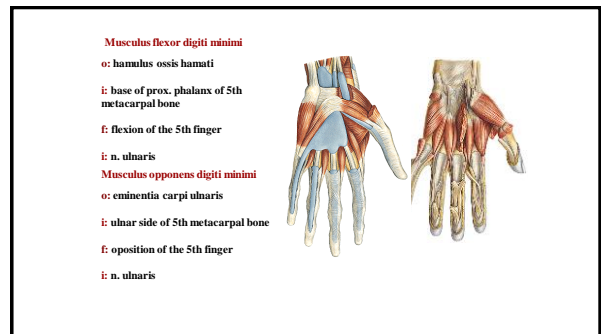
25



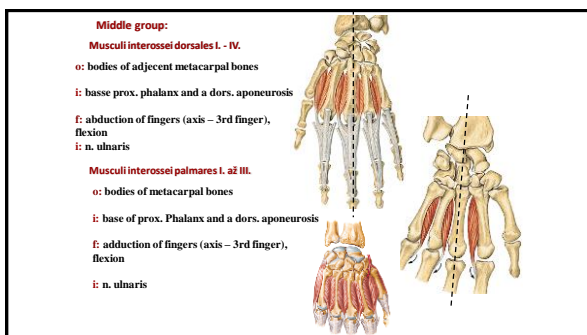
26



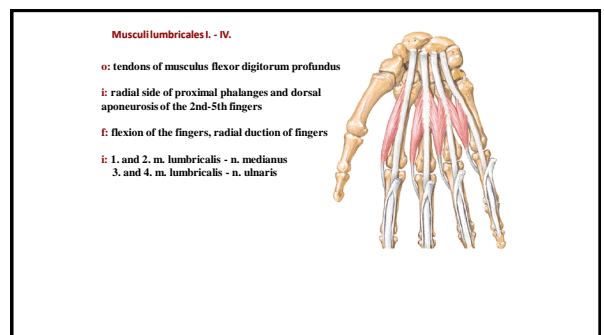
27



28



29



30

Fasciae manus

- Fascia dorsalis manus superficialis
- Fascia dorsalis manus intertendinea (Slachy extenzorii)
- Fascia dorsalis manus interossea
- Fascia palmaris superficialis – **aponeurosis palmaris**
- Fascia palmaris interossea
- Septum palmare radiale (3rd metacarpal bone)
- Septum palmare ulnare (5th metacarpal bone)
- Spotium palmare radiale, ulnare, medium

31

Musculi membri inferioris

32

Musculi coxae

Ventral group: Musculus iliopsoas

Dorsal group:

- Musculus gluteus maximus
- Musculus gluteus medius
- Musculus gluteus minimus
- Musculus tensor fasciae latae
- Musculus piriformis
- Musculus obturatorius internus
- Musculus gemellus superior
- Musculus gemellus inferior
- Musculus quadratus femoris

33

Musculus iliopsoas

Musculus psoas major

- o: disci intervertebrales et ligaments of the L

Musculus iliacus

- o: fossa iliaca

Musculus psoas minor (nekonstantni)

- o: medially to m. psoas major
- i: trochanter minor
- f: flexion in hip
- i: plexus lumbalis

34

Musculus gluteus maximus

- o: linea glutea post. ossis ili, os sacrum, fascia thoracolumbalis
- i: tractus iliotibialis, tuberositas glutea, labium laterale lineae asperae
- f: extension in the hip and knee
- i: n. gluteus inferior

Musculus gluteus medius

- o: linea glutea ant. a post., labium externum cristae iliacae
- i: trochanter major femoris
- f: pronation and supination, extension
- i: n. gluteus sup.

35

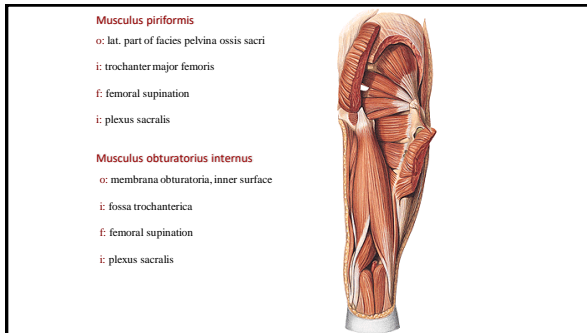
Musculus gluteus minimus

- o: linea glutea ant. a inf.,
- i: trochanter major femoris
- f: pronation and supination, abduction
- i: n. gluteus sup.

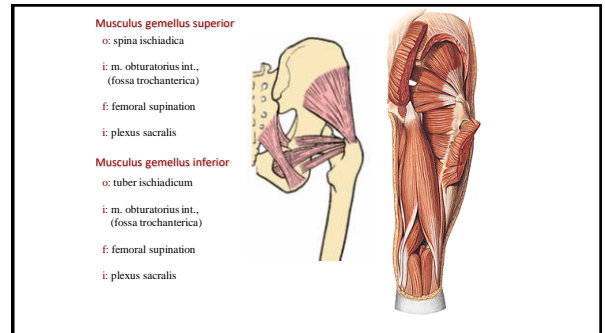
Musculus tensor fasciae latae

- o: spina iliaca ant. sup.
- i: tractus iliotibialis
- f: extension in knee
- i: n. gluteus sup.

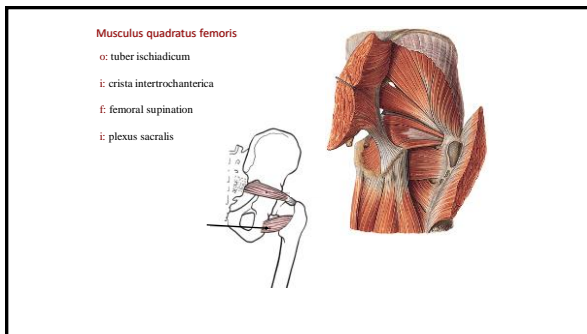
36



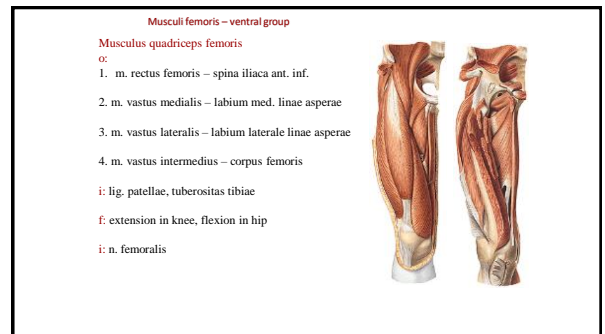
37



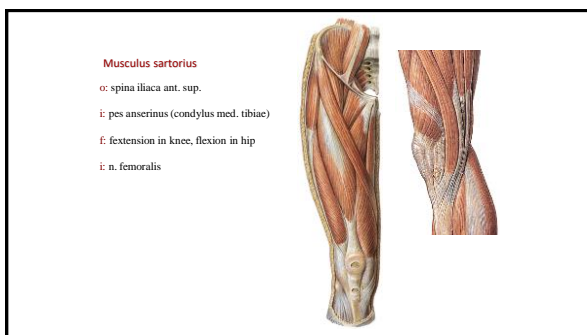
38



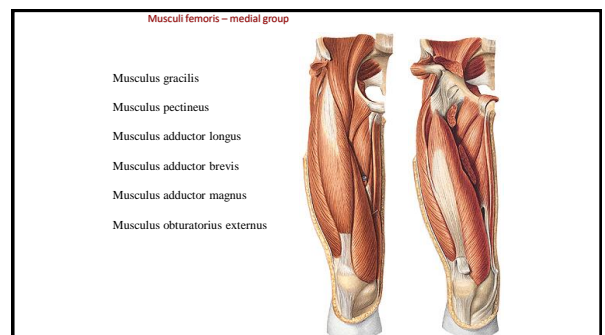
39



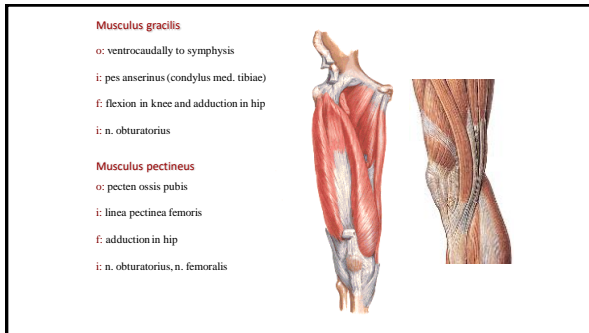
40



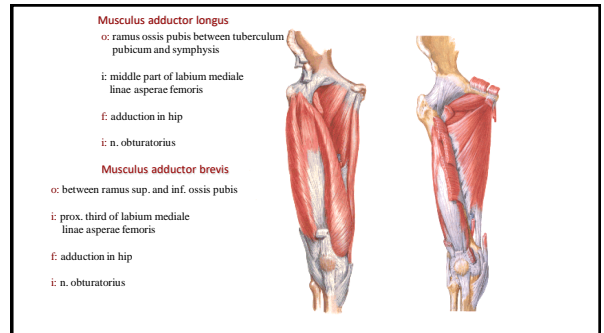
41



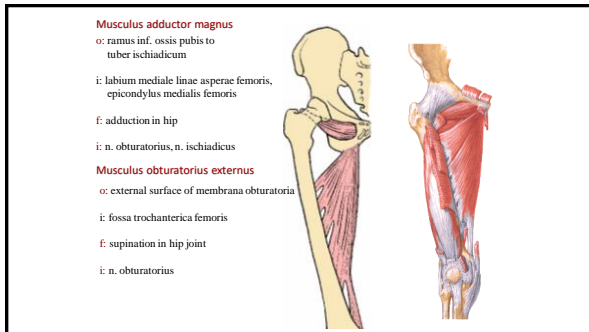
42



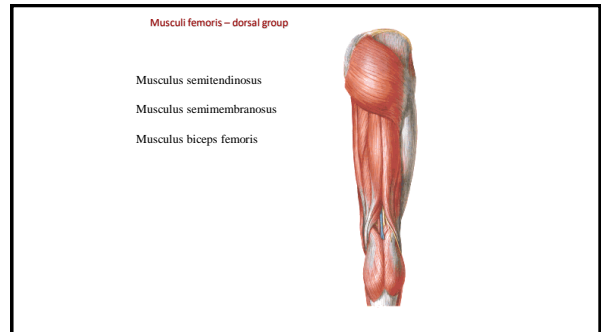
43



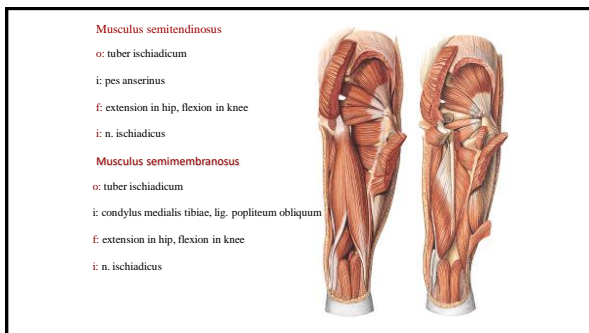
44



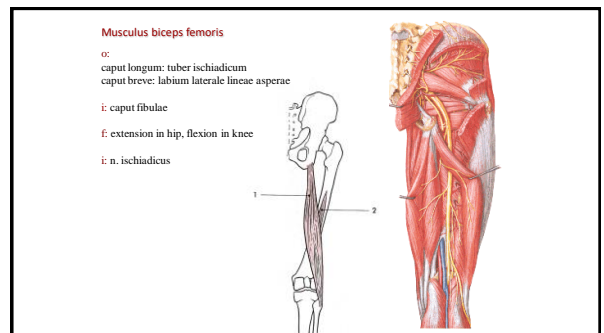
45



46




47



48

Musculi cruris – ventral group


Musculus tibialis anterior
 Musculus extensor hallucis longus
 Musculus extensor digitorum longus



49

Musculus tibialis anterior


o: lateral side of tibia, membrana interossea cruris
 i: os cuneiforme med., base of I. metatarsal bone
 f: dorsal flexion and supination of the foot, supports the foot vault
 i: n. fibularis prof.
Musculus extensor hallucis longus
 o: medial side of fibula, membrana interossea cruris
 i: dorsal aponeurosis of toe
 f: extension of toe and foot
 i: n. fibularis prof.



50

Musculus extensor digitorum longus


o: condylus lat. tibiae, proximal part of fibula, membrana interossea cruris
 i: dorsal aponeurosis of 2-5 fingers
 5th tendon on tuberositas ossis metatarsi V. (musculus fibularis tertius)
 f: extension of fingers and foot, pronation
 i: n. fibularis prof.



51

Vaginae synoviales – ventral group


Retinaculum musculorum extensorum superiorum
 (between malleolus medialis et lateralis)
 three osteofibrous spaces:
 m. tibialis ant.
 m. extensor hallucis longus
 m. extensor digitorum longus
Retinaculum musculorum extensorum inferiorum
 (X or Y shape)



52

Musculi cruris – lateral group

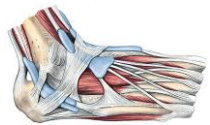
Musculus fibularis (peroneus) longus
 o: caput fibulae, prox. part of fibuly
 i: os cuneiforme med., base of 1st metatarsal bone
 f: plantar flexion and pronation, supports foot vault
 i: n. fibularis superficialis
Musculus fibularis brevis
 o: distal part of the lateral side of fibula
 i: tuberositas ossis metatarsi V.
 f: plantar flexion and pronation
 i: n. fibularis superficialis



53

Synovial vaginae – lateral group

Retinaculum musculorum peroneorum superiorum
 (between malleolus lat. and tuber calcanei)
 Common synovial vagina
Retinaculum musculorum peroneorum inferiorum
 (between tuber calcanei, trochlea peronealis calcanei and distal part of retinaculum extensorum inf.)
 2 osteofibrous canals:
 m. fibularis longus (below trochlea peronealis)
 m. fibularis brevis (above trochlea peronealis)



54


Musculi cruris – dorsal group

Superficial layer:

- Musculus triceps surae
- Musculus plantaris
- Musculus popliteus

Deep layer:

- Musculus tibialis posterior
- Musculus flexor hallucis longus
- Musculus flexor digitorum longus



55

Musculus triceps surae

musculus gastrocnemius and musculus soleus

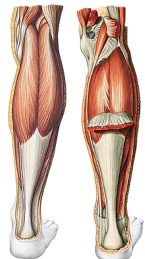
o:
musculus gastrocnemius:
 caput med. – epicondylus med. femoris
 caput lat. – epicondylus lat. femoris

musculus soleus:
 arcus tendineus m. solei

i: tuber calcanei (tendo calcanei seu Achilles)

f: flexion in knee, plantar flexion

i: n. tibialis



56

Musculus plantaris

o: epicondylus lateralis femoris

i: joins tendo Achilles

f: flexion in knee, plantar flexion

i: n. tibialis

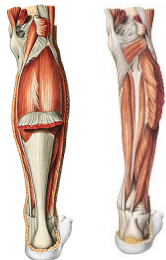
Musculus popliteus

o: epicondylus lateralis femoris

i: proximally to linea m. solei

f: flexion in knee

i: n. tibialis



57

Musculus tibialis posterior

o: posterior side of tibia, medial side of fibula, membrana interossea cruris

i: tuberositas ossis navicularis

f: plantar flexion, foot vault support

i: n. tibialis


Musculus flexor hallucis longus

o: dorsal side of fibula

i: distal phalanx of toe

f: flexion of toe and foot

i: n. tibialis



58


Musculus flexor digitorum longus

o: dorsal side of tibia

i: distal phalanges 2-5th fingers

f: flexion of fingers and foot

i: n. tibialis



59

Synovial vaginae – medial group

Retinaculum musculorum flexorum
 (between malleolus lateralis et tuber calcanei)

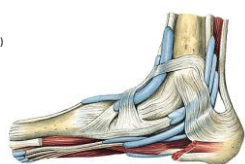
Three osteofibrous spaces

m. tibialis post.

m. flexor digitorum longus
 (a. and v. tibialis post., n. tibialis)

m. flexor hallucis longus


Synovial vagina for each muscle



60

Fascia cruris

Doesn't cover facies medialis tibiae
septum intermusculare anterius et posterius
(anterior, lateral and posterior group)
Dorsal group – deep fascial sheath
Firmed in retinaculum musculorum extensorum,
flexorum, peroneorum




61

Musculi pedis – dorsal group

Musculus extensor hallucis brevis
o: next to sinus tarsi
i: dorsal aponeurosis of toe
f: extension of toe
i: n. peroneus profundus

Musculus extensor digitorum brevis
o: next to sinus tarsi
i: dorsal aponeurosis of 2-4th fingers
f: extension of fingers
i: n. peroneus profundus

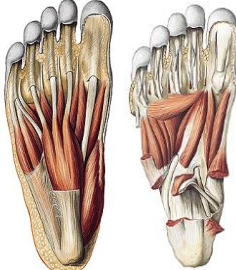


62

Musculi pedis – muscles of toe


Musculus abductor hallucis
o: processus medialis tuberis calcanei
i: med. sesamoid bone in art. metatarsophalangea hallucis
f: abduction and flexion of toe
i: n. plantaris med.

Musculus flexor hallucis brevis
o: plantar side of ossa cuneiformia
i: both sesamoid bones in art. metatarsophalangea hallucis
f: flexion of toe
i: n. plantaris med.



63

Musculus adductor hallucis
o: caput obliquum – plantar surface of tarsal bones
caput transversum – plantar surface of 3., 4., and 5. metatarsal
i: lat. sesamoid bone in art. metatarsophalangea hallucis
f: adduction and flexion of toe
i: n. plantaris lat.

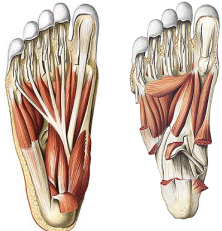


64

Musculi pedis – muscles of 5th finger


Musculus abductor digiti minimi
o: processus lat. tuberis calcanei
i: base of 5th metatarsal bone, base of prox. phalanx of 5th finger
f: abduction and flexion
i: n. plantaris lat.

Musculus flexor digiti minimi
o: plantar side of os cuboideum and base of 5th metatarsal bone
i: base of proximal phalanx of 5th finger
f: flexion
i: n. plantaris lat.



65

Musculus opponens digiti minimi
o: plantar surface of os cuboideum
i: body of the 5th metatarsal bone
f: opposition of 5th finger
i: n. plantaris lat.



66

