

Muscles of the upper and lower extremity

1

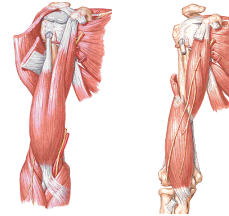
Musculi brachii

Ventral group

- Musculus biceps brachii
- Musculus coracobrachialis
- Musculus brachialis

Dorsal group

- Musculus triceps brachii
- Musculus anconeus

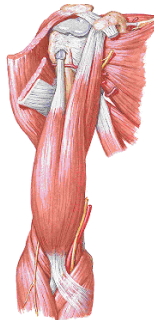


2

Ventral group

Musculus biceps brachii

- o:** caput longum – tuberculum supraglenoidale
caput breve – processus coracoideus scapulae
- i:** tuberositas radii, aponeurosis bicipitalis
- f:** flexion and supination in elbow joint
adduction and ventral flexion in shoulder joint
- i:** n. musculocutaneus



3

Musculus coracobrachialis

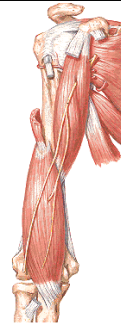- o:** processus coracoideus scapulae
- i:** medial side of the humerus
- f:** adduction and ventral flexion
- i:** n. musculocutaneus

Musculus brachialis

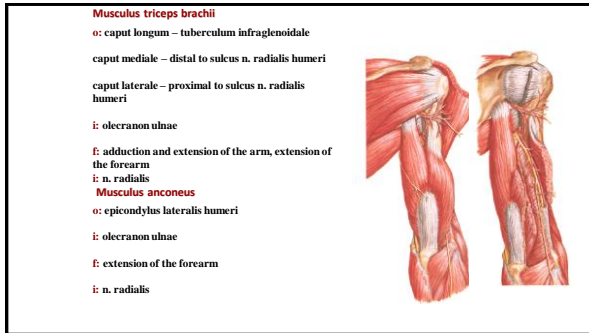
- o:** ventral side of the humerus (distal half)
- i:** tuberositas ulnae
- f:** flexion in elbow
- i:** n. musculocutaneus

Flexion in pronation – m. brachialis

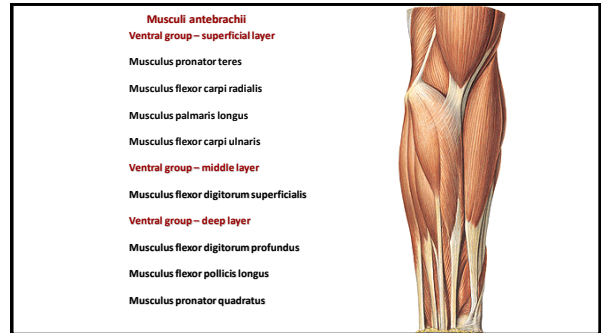
Flexion in supination – m. brachialis + m. biceps brachii.



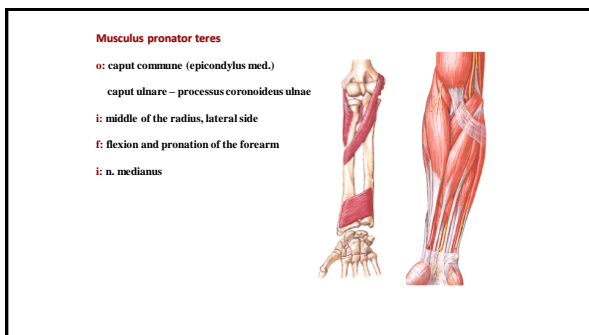
4



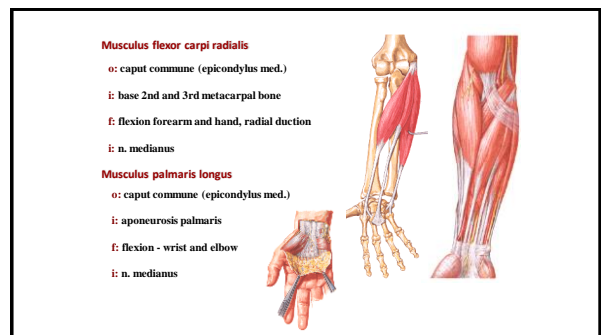
5



6



7



8

Musculus flexor carpi ulnaris

o: caput commune (epicondylus med.)

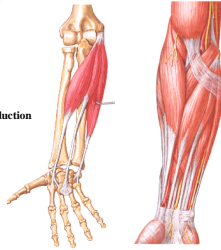
caput ulnare – olecranon ulnae

i: os pisiforme

(lig. pisohamatum and lig. pisometacarpum)

f: flexion – forearm and hand, ulnar duction

i: n. ulnaris



9

Musculus flexor digitorum superficialis

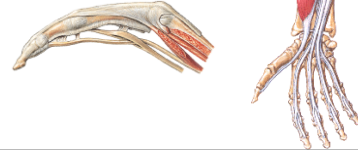
o: epicondylus med. humeri

caput radiale – proximal part of the radius

i: sides of the middle phalanges - 2-5 fingers

f: flexion of the forearm, hand and fingers

i: n. medianus



10

Musculus flexor digitorum profundus

o: ventral side of the ulna, membrana interossea antebrachii

i: sides of distal phalanges - 2.-5. fingers

f: flexion – hand and fingers

i: 2nd and 3rd finger - n. medianus, 4th, 5th – n. ulnaris

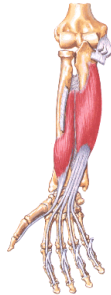Musculus flexor pollicis longus

o: ventral side of the radius, membrana interossea antebrachii

i: distal phalanx of the thumb

f: flexion hand and thumb

i: n. medianus



11

Musculus pronator quadratus

o: distal part of ventral side of ulna

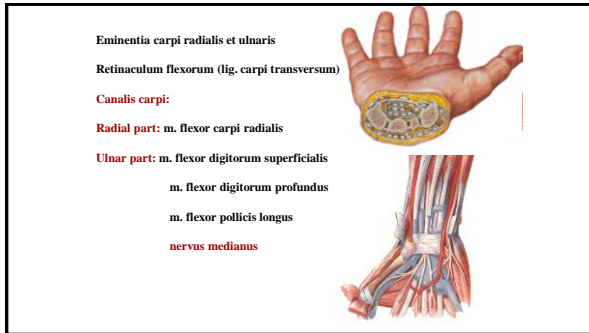
i: distal part of ventral side of radius

f: pronation of forearm

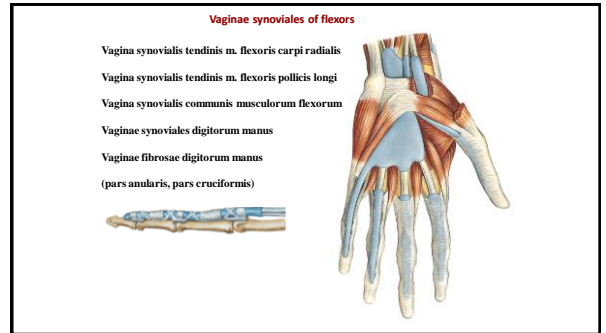
i: n. medianus



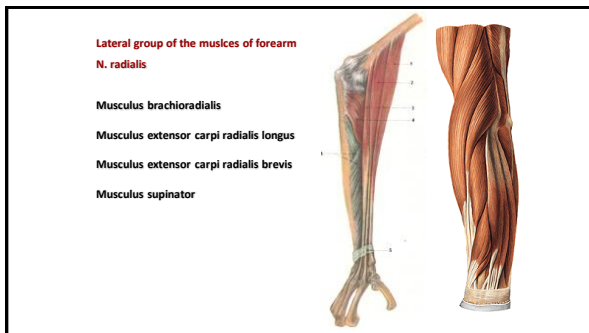
12



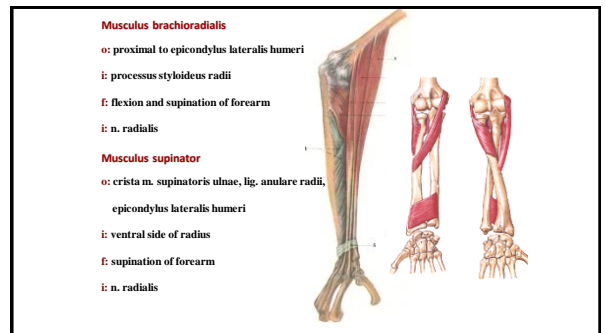
13



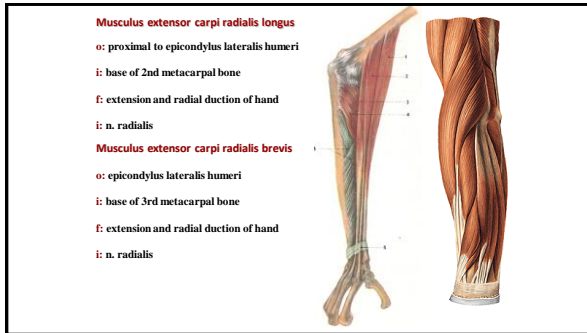
14



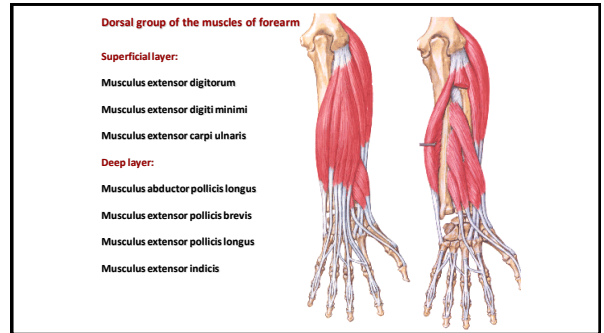
15



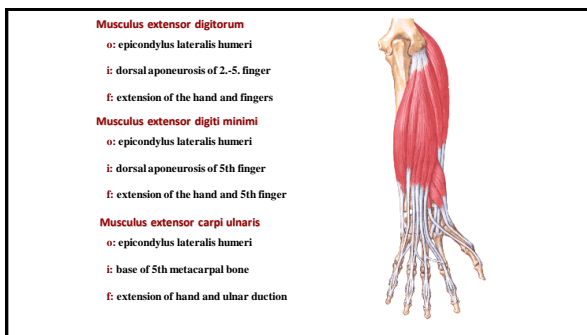
16



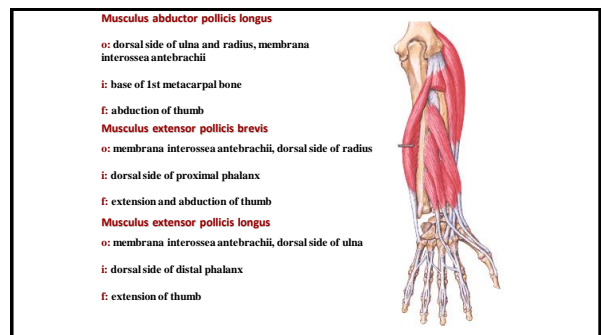
17



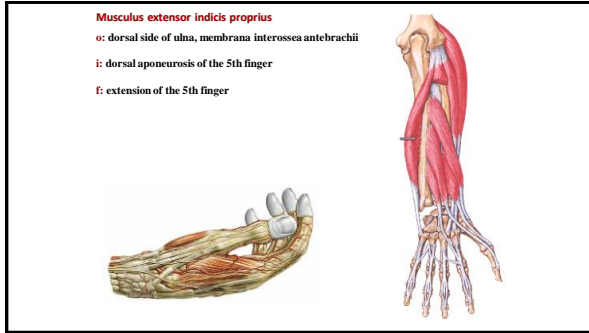
18



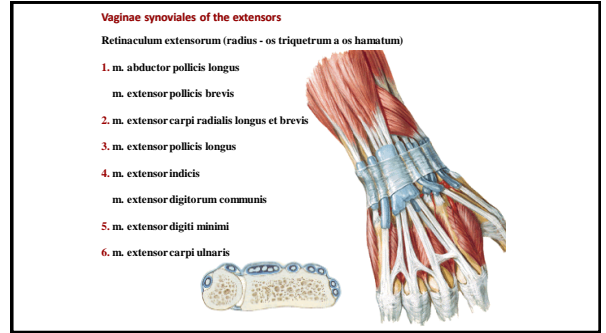
19



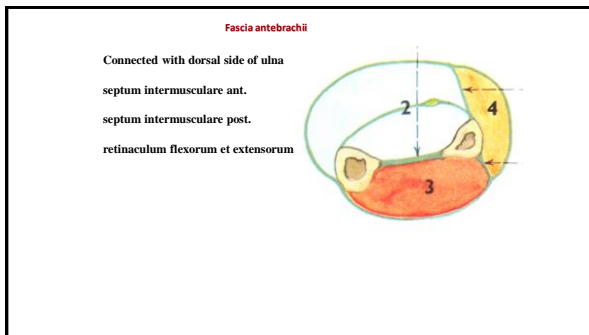
20



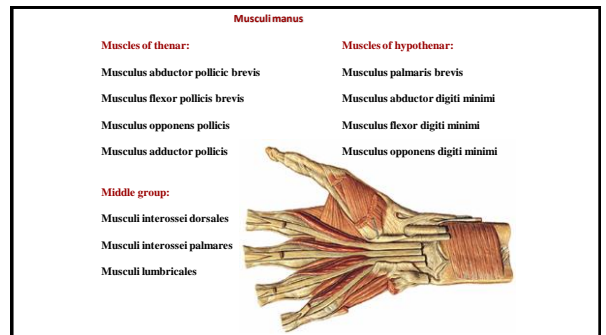
21



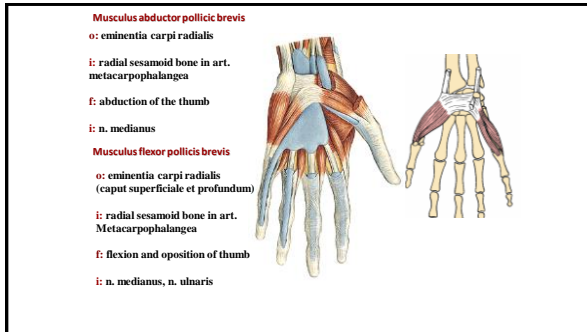
22



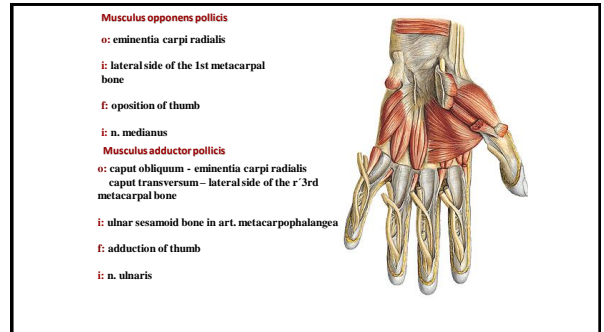
23



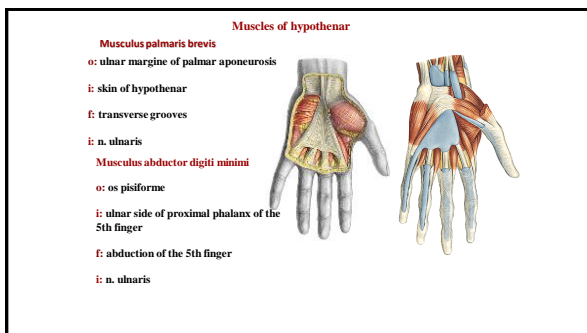
24



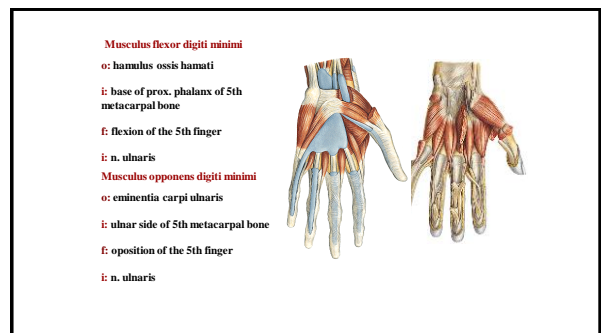
25



26



27



28

Middle group:
Musculi interossei dorsales I - IV.
 o: bodies of adjacent metacarpal bones
 i: base prox. phalanx and a dors. aponeurosis
 f: abduction of fingers (axis – 3rd finger), flexion
 i: n. ulnaris

Musculi interossei palmares I. až III.
 o: bodies of metacarpal bones
 i: base of prox. Phalanx and a dors. aponeurosis
 f: adduction of fingers (axis – 3rd finger), flexion
 i: n. ulnaris

29

Musculi lumbricales I - IV.
 o: tendons of musculus flexor digitorum profundus
 i: radial side of proximal phalanges and dorsal aponeurosis of the 2nd-5th fingers
 f: flexion of the fingers, radial duction of fingers
 i: 1. and 2. m. lumbricales - n. medianus
 3. and 4. m. lumbricales - n. ulnaris

30

Fasciae manus

- Fascia dorsalis manus superficialis
- Fascia dorsalis manus intertendinea (slachy extenzorů)
- Fascia dorsalis manus interossea
- Facia palmaris superficialis – **aponeurosis palmaris**
- Fascia palmaris interossea
- Septum palmare radiale (3rd metacarpal bone)
- Septum palmare ulnare (5th metacarpal bone)
- Spatium palmare radiale, ulnare, medium

31

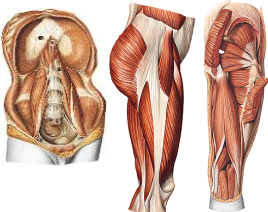
Musculi membri inferioris

32

Musculi coxae

Ventral group: Musculus iliopsoas

Dorsal group:
 Musculus gluteaeus maximus
 Musculus gluteaeus medius
 Musculus gluteaeus minimus
 Musculus tensor fasciae latae
 Musculus piriformis
 Musculus obturatorius internus
 Musculus gemellus superior
 Musculus gemellus inferior
 Musculus quadratus femoris



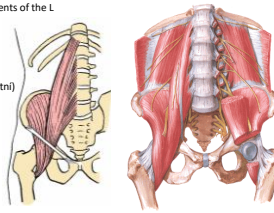
33

Musculus iliopsoas

Musculus psoas major
 o: disci intervertebrales and ligaments of the L

Musculus iliacus
 o: fossa iliaca

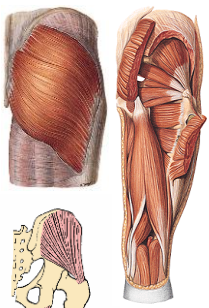
Musculus psoas minor (nekonstantni)
 o: medially to m. psoas major
 i: trochanter minor
 f: flexion in hip
 i: plexus lumbalis



34

Musculus gluteaeus maximus
 o: linea gluteae post., ossis ili, os sacrum, fascia thoracolumbalis
 i: tractus iliotibialis, tuberositas gluteae, labium laterale lineae asperae
 f: extension in the hip and knee
 i: n. gluteaeus inferior

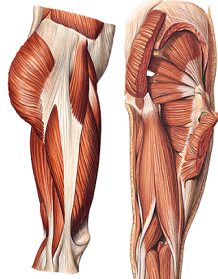
Musculus gluteaeus medius
 o: linea gluteae ant. a post., labium externum cristae iliaceae
 i: trochanter major femoris
 f: pronation and supination, extension
 i: n. gluteaeus sup.



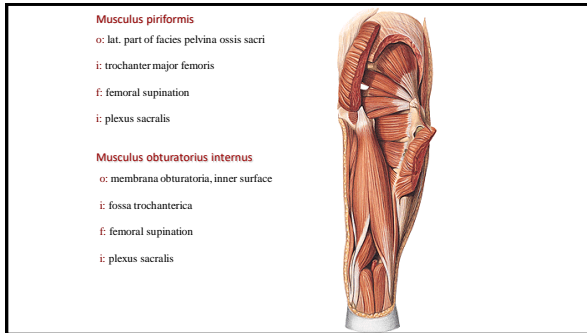
35

Musculus gluteaeus minimus
 o: linea gluteae ant. a inf.,
 i: trochanter major femoris
 f: pronation and supination, abduction
 i: n. gluteaeus sup.

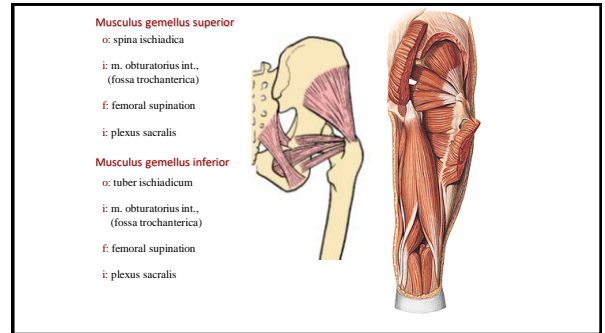
Musculus tensor fasciae latae
 o: spina iliaca ant. sup.
 i: tractus iliotibialis
 f: extension in knee
 i: n. gluteaeus sup.



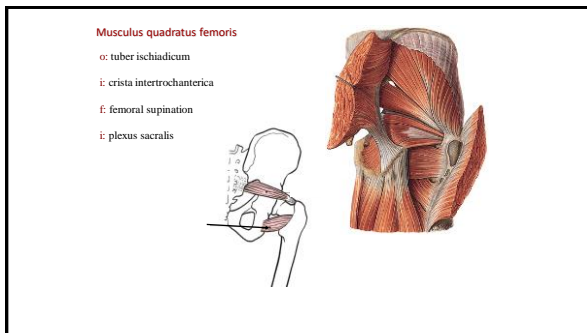
36



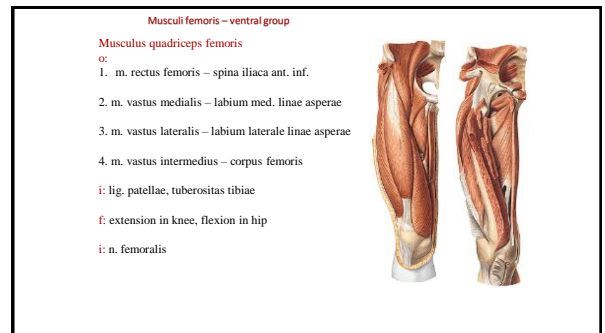
37



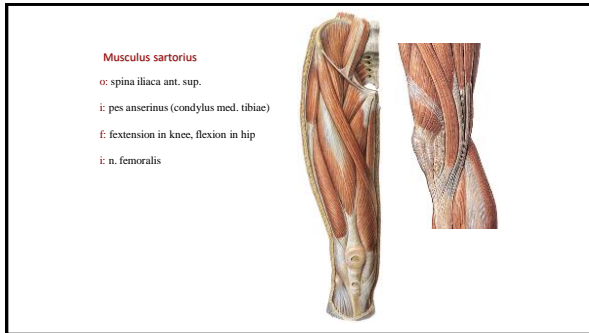
38



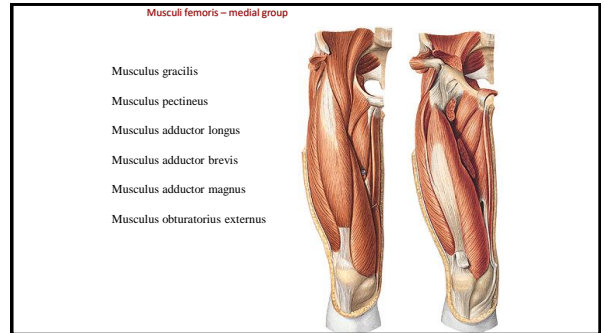
39



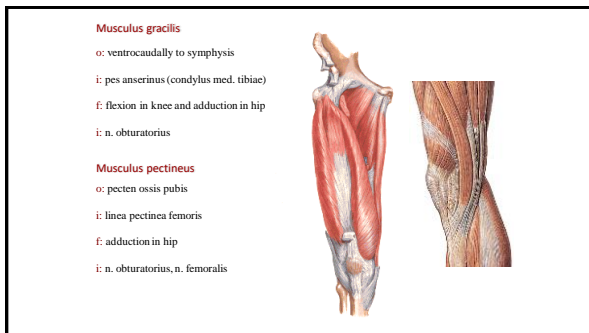
40



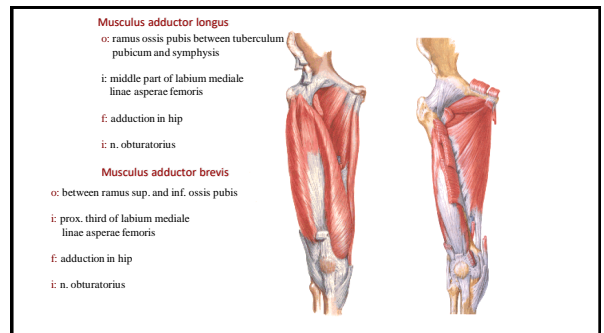
41



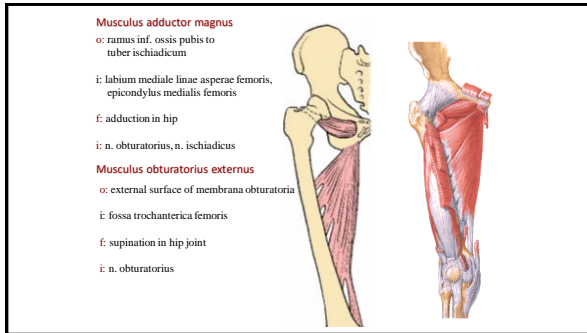
42



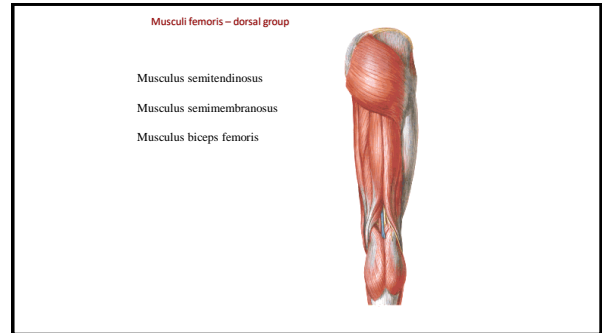
43



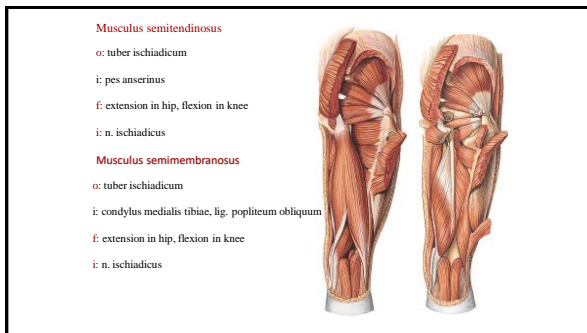
44



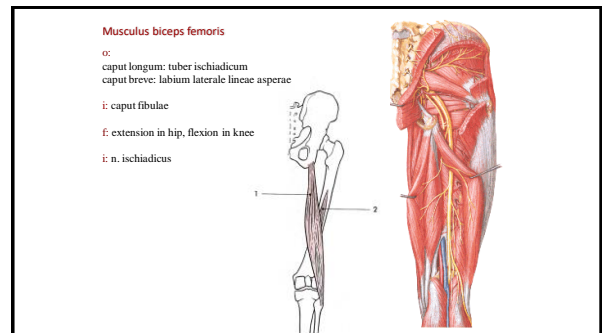
45



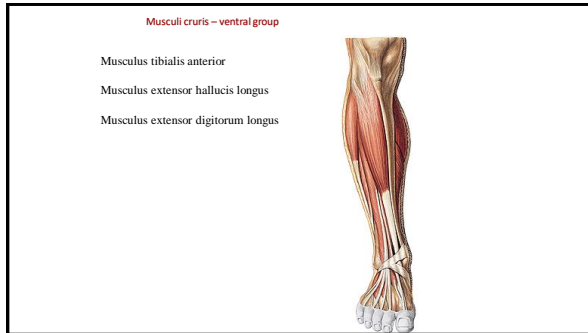
46



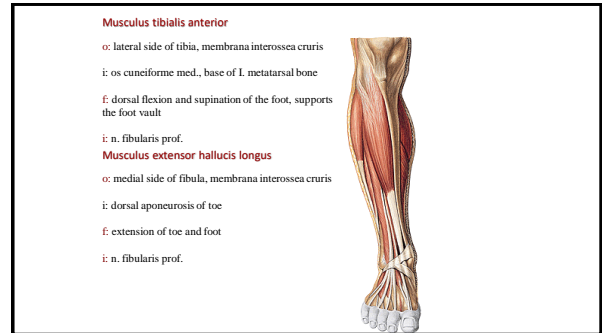
47



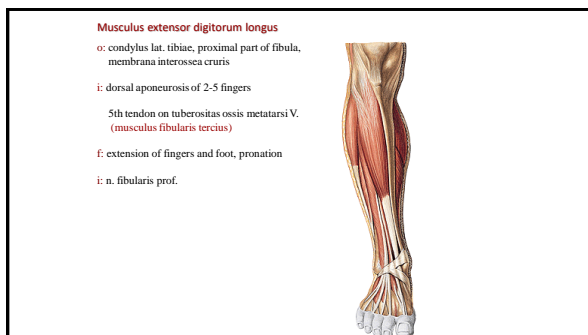
48



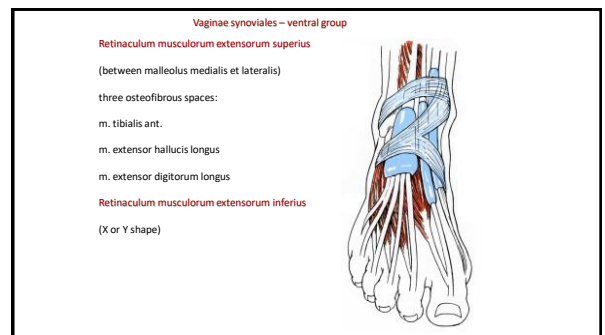
49



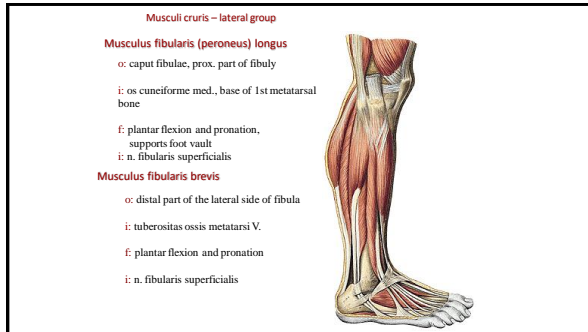
50



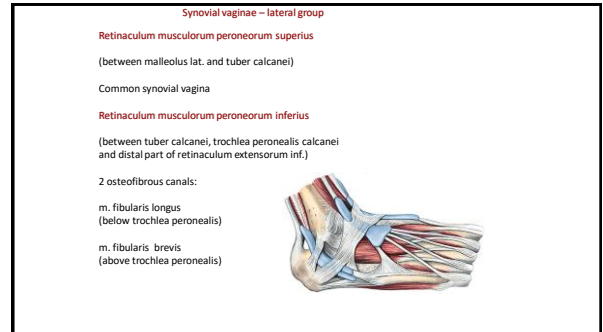
51



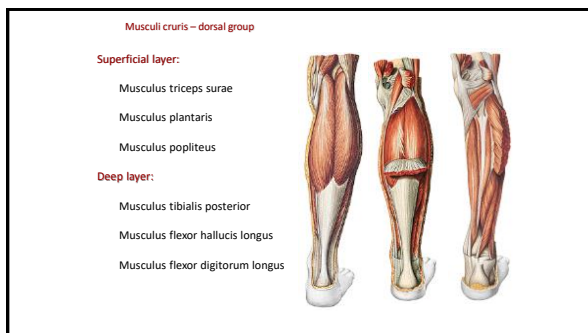
52



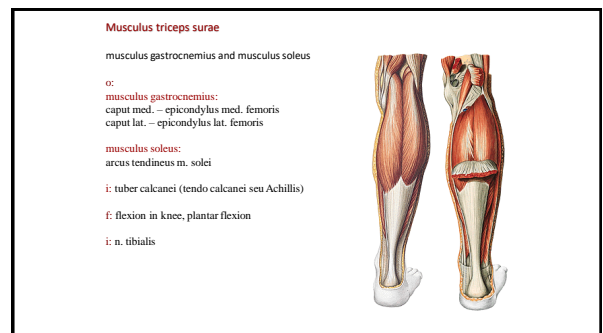
53



54



55



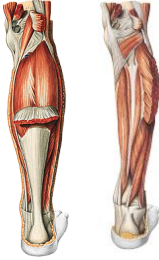
56

Musculus plantaris

- o: epicondylus lateralis femoris
- i: joins tendo Achillis
- f: flexion in knee, plantar flexion
- i: n. tibialis

Musculus popliteus

- o: epicondylus lateralis femoris
- i: proximally to linea m. solei
- f: flexion in knee
- i: n. tibialis




57

Musculus tibialis posterior

- o: posterior side of tibia, medial side of fibula, membrana interossea cruris
- i: tuberositas ossis navicularis
- f: plantar flexion, foot vault support
- i: n. tibialis

Musculus flexor hallucis longus


- o: dorsal side of fibula
- i: distal phalanx of toe
- f: flexion of toe and foot
- i: n. tibialis



58

Musculus flexor digitorum longus

- o: dorsal side of tibia
- i: distal phalanges 2-5th fingers
- f: flexion of fingers and foot
- i: n. tibialis



59

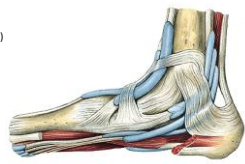
Synovial vaginae – medial group

Retinaculum musculorum flexorum
(between malleolus lateralis and tuber calcanei)

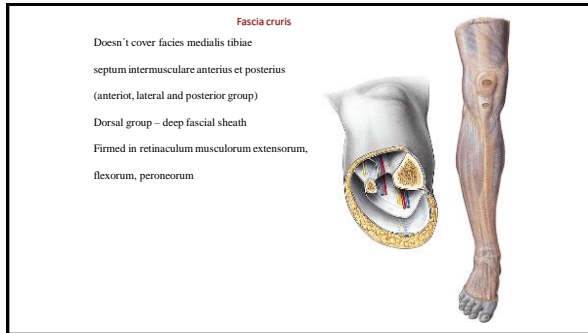
Three osteofibrous spaces

- m. tibialis post.
- m. flexor digitorum longus
- (a. and v. tibialis post., n. tibialis)
- m. flexor hallucis longus

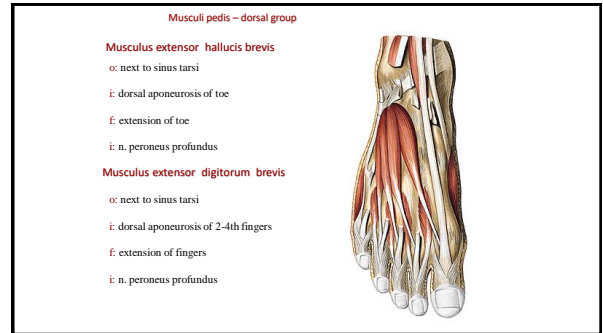
Synovial vagina for each muscle



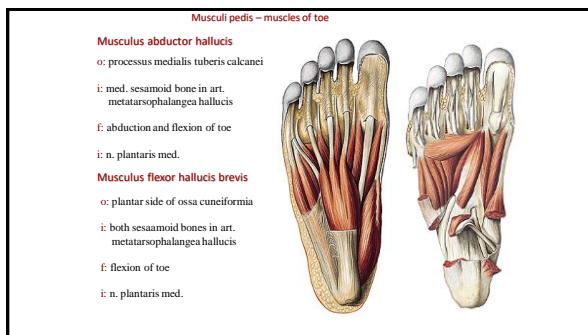
60



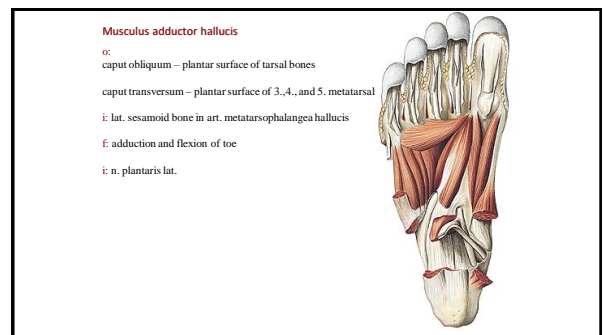
61



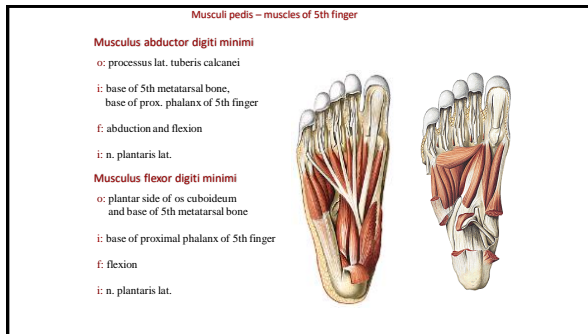
62



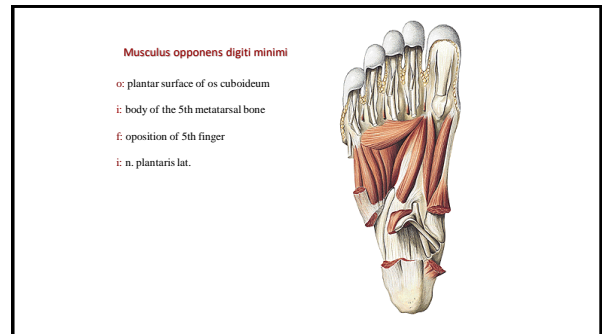
63



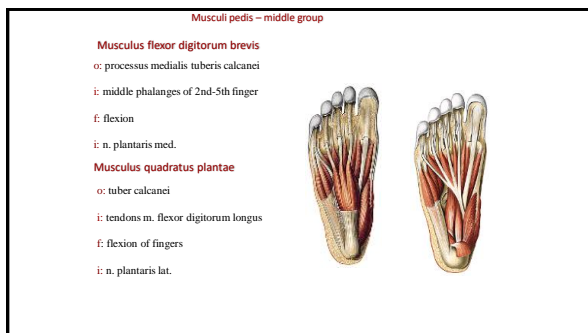
64



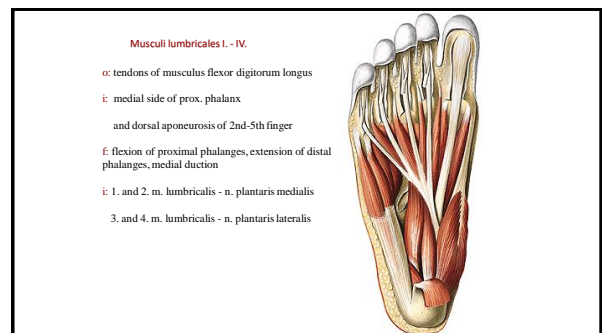
65



66



67




68

Musculi interossei dorsales

- o: bodies of adjacent metatarsal bones
- i: base of prox. phalanges and dors. aponeurosis
- f: abduction of fingers (axis through 2nd), flexion of proximal phalanx, extension of distal
- i: n. plantaris lat.

Musculi interossei plantares

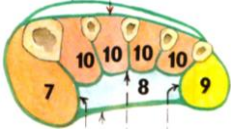
- o: tibial side of bodies of 3.-5. metatarsal bones
- i: base of prox. phalanges and dors. aponeurosis
- f: adduction of (axis through 2nd), flexion of proximal phalanx, extension of middle and distal
- i: n. plantaris lat.



69

Fasciae pedis

- Fascia dorsalis pedis
- Fascia dorsalis pedis interossea
- Fascia plantaris superficialis – aponeurosis plantaris
- Fascia plantaris pedis interossea
- Septum intermusculare mediale (1st metatarsal bone)
- Septum intermusculare laterale (5th metatarsal bone)
- Spatium plantare mediale, laterale, medium



70

References:

Putz, R. (2008):
Atlas of Human Anatomy Sobotta. Elsevier Books.

Keith L. Moore, Arthur F. Dalley (2005):
Clinically Oriented Anatomy. Williams and Wilkins.

Platzer, W., Kahle, W., Leonhardt H. (1992):
Locomotor system. Georg Thieme Verlag, Stuttgart, New York, 4th edition.

Čihák, R. (1987):
Anatomie 1. Avicenum, Zdravotnické nakladatelství.

Netter, F. H. (1997):
Interactive Atlas of Clinical Anatomy. Novartis, USA.

71