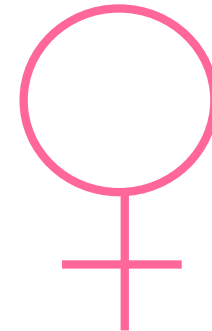


The female reproductive system

Aleš Hampl

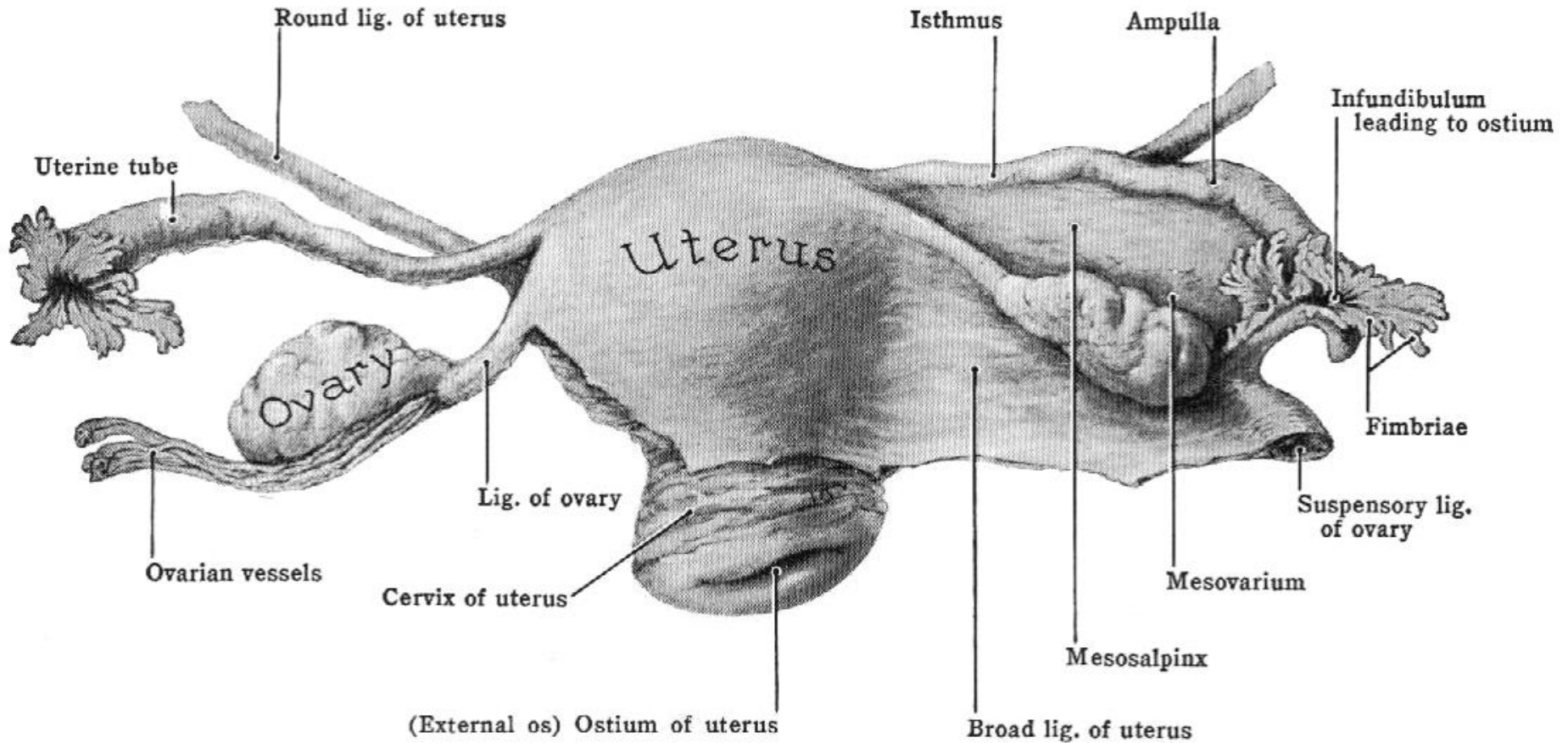
November 2019



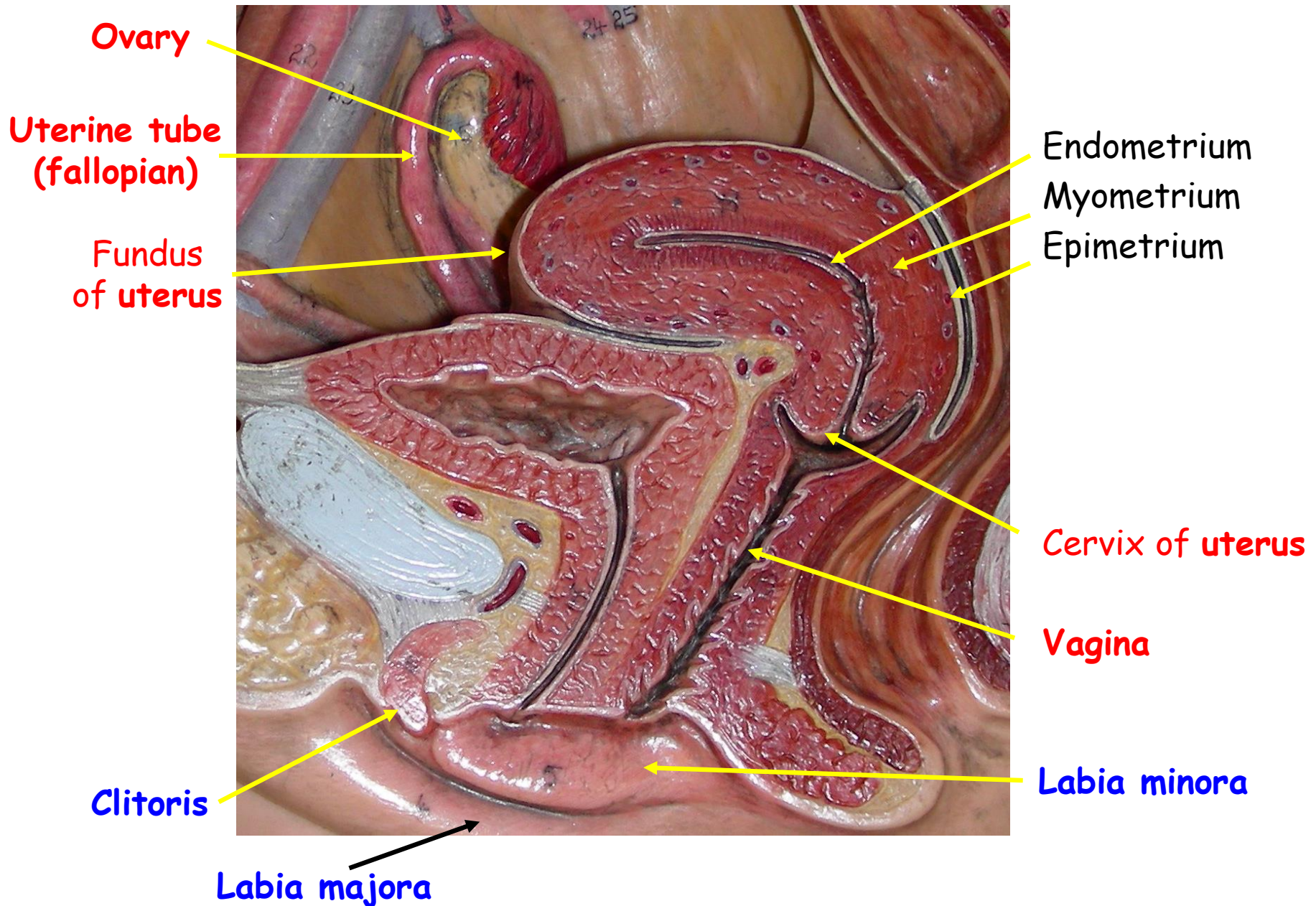
Functions of the female reproductive system

1. **Oogenesis**
2. **Copulation** - receives sperm from male
3. **Hormone production**
4. Provides sites for egg **fertilization, implantation, and development**
5. Acts as **birth canal**

Female genital organs - Gross anatomy 1

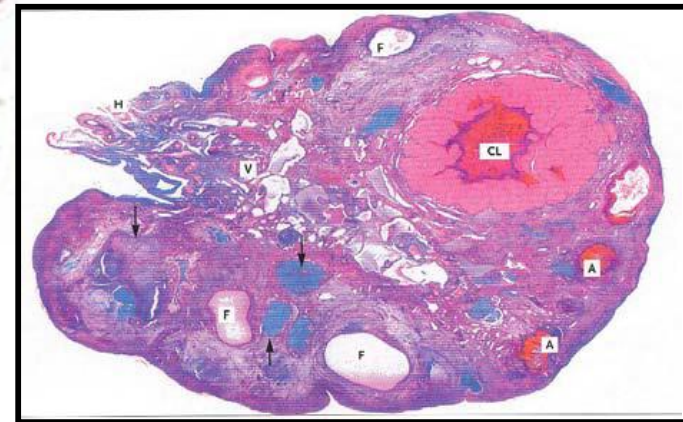
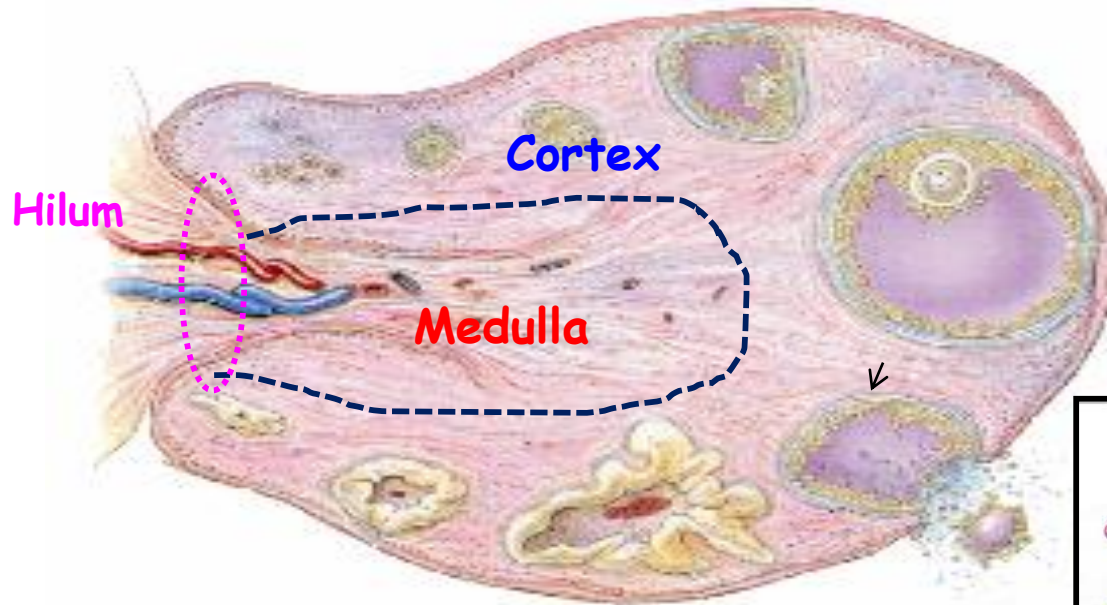


Female genital organs - Gross anatomy 2



Length - 3 cm
Width - 1.5 cm
Thickness - 1 cm

Ovary - Overall structure



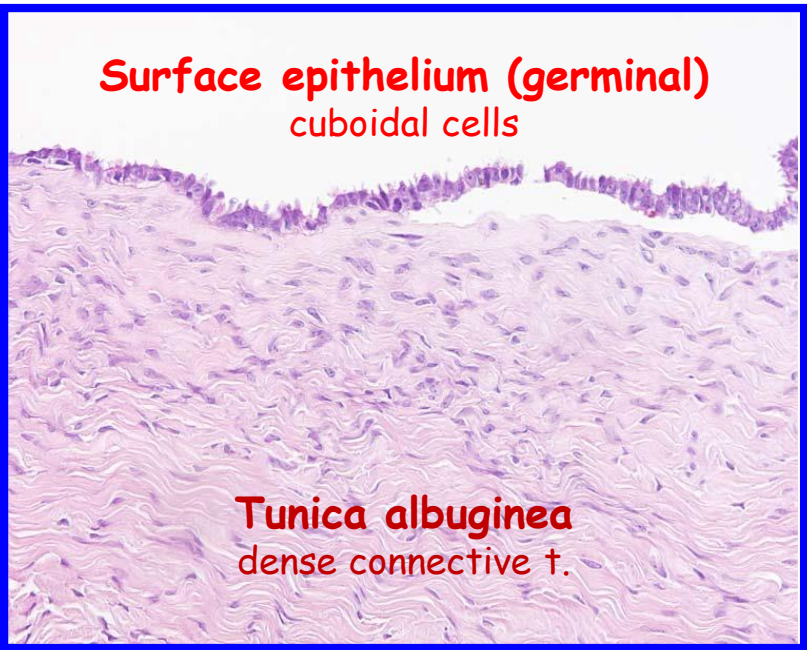
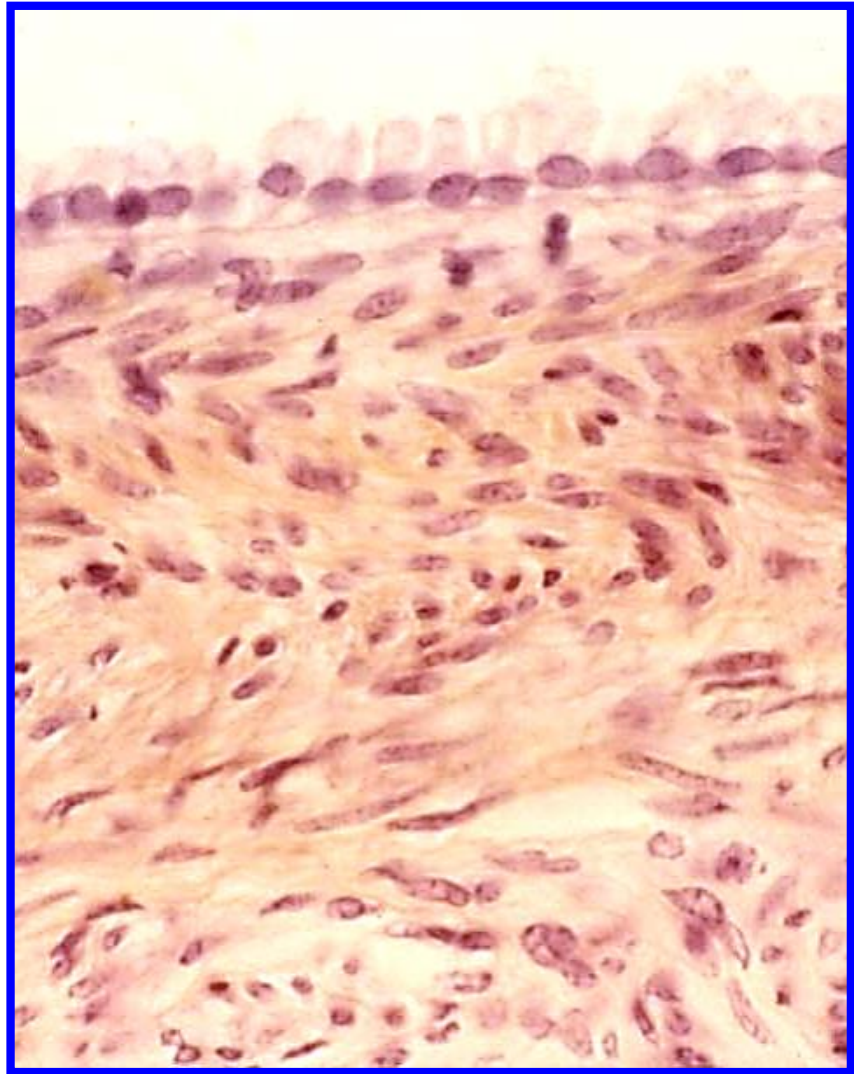
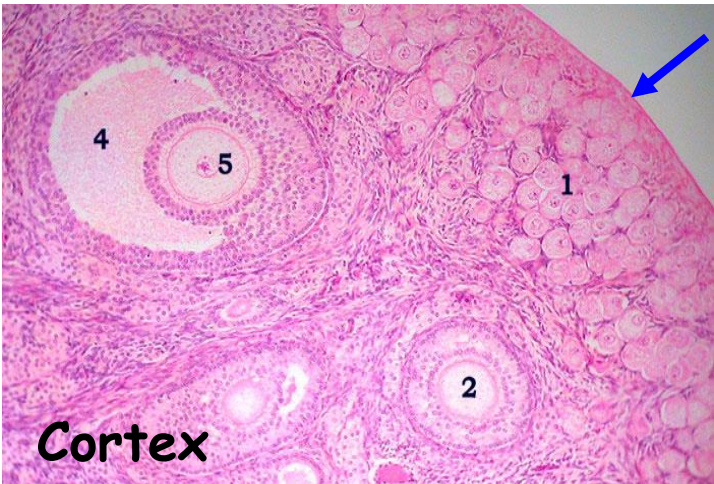
Cortex

- Follicles
- Highly vascularized stroma

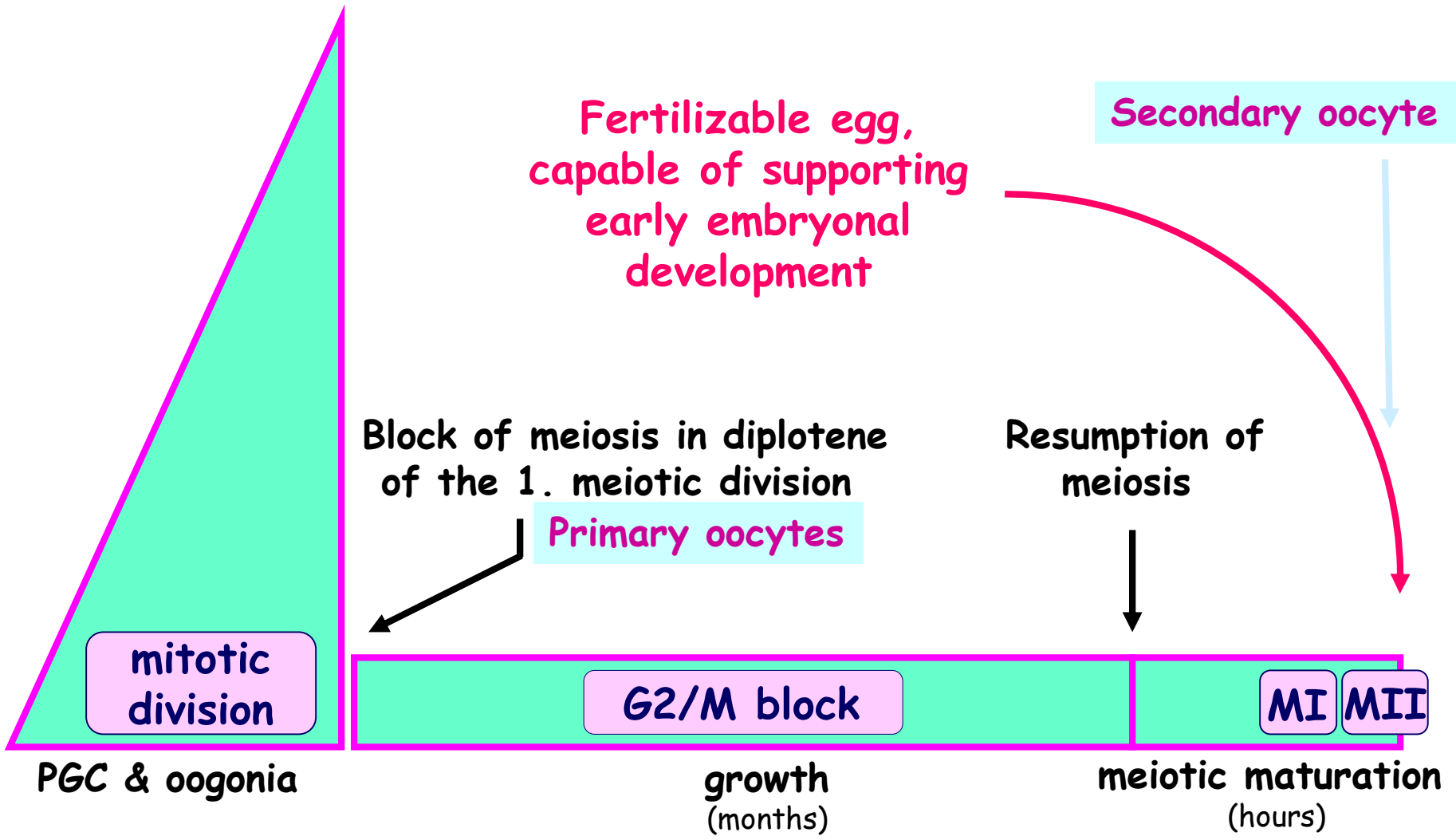
Medulla

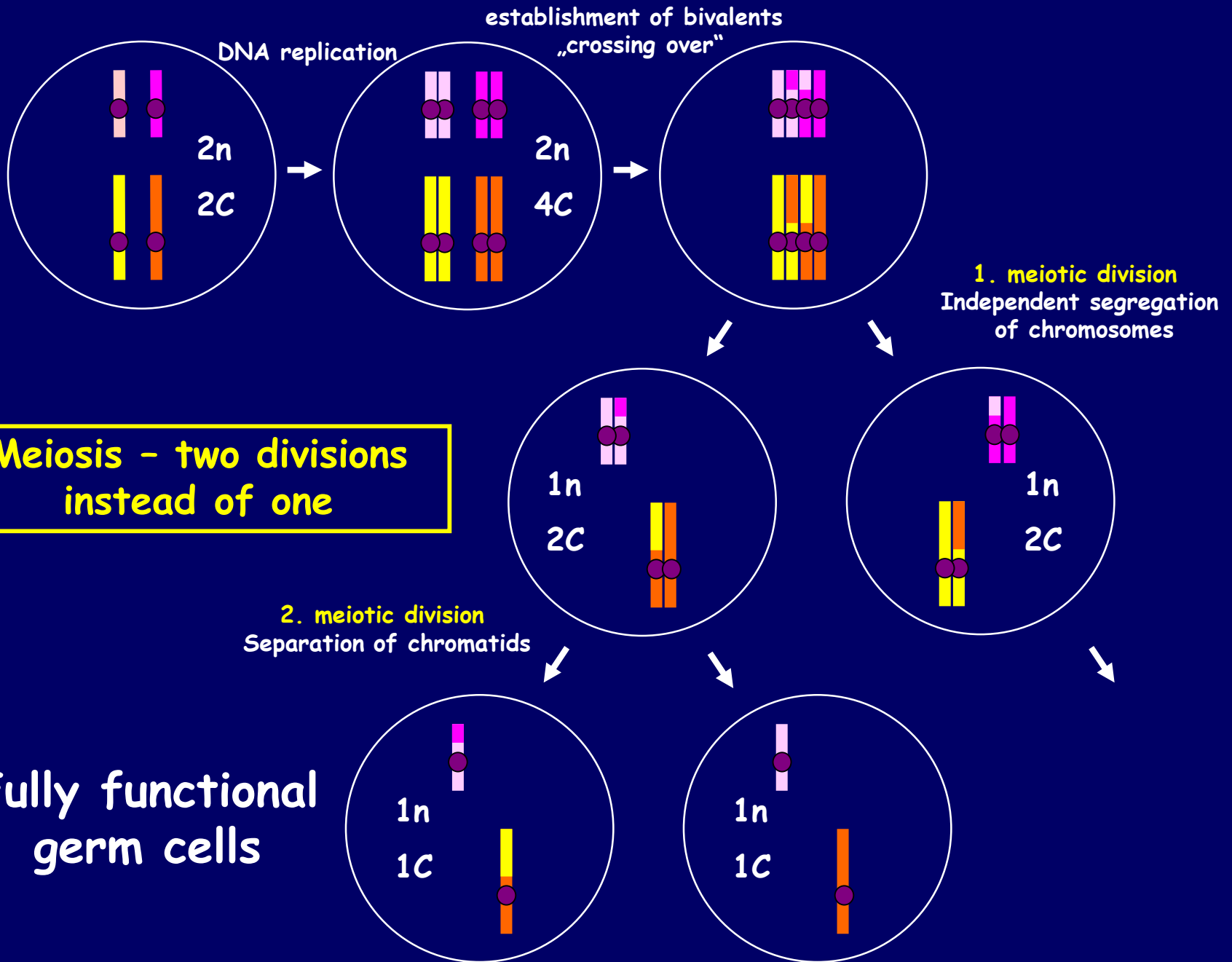
- Vessels
- Loose connective tissue

Ovary - Surface



Oogenesis - Key periods





Oogenesis - Lifetime summary

At the end of 6 month of fetal development
~ 6 - 7 millions of primary oocytes



Atresia

At the time of birth
~ 500 thousands of primary oocytes

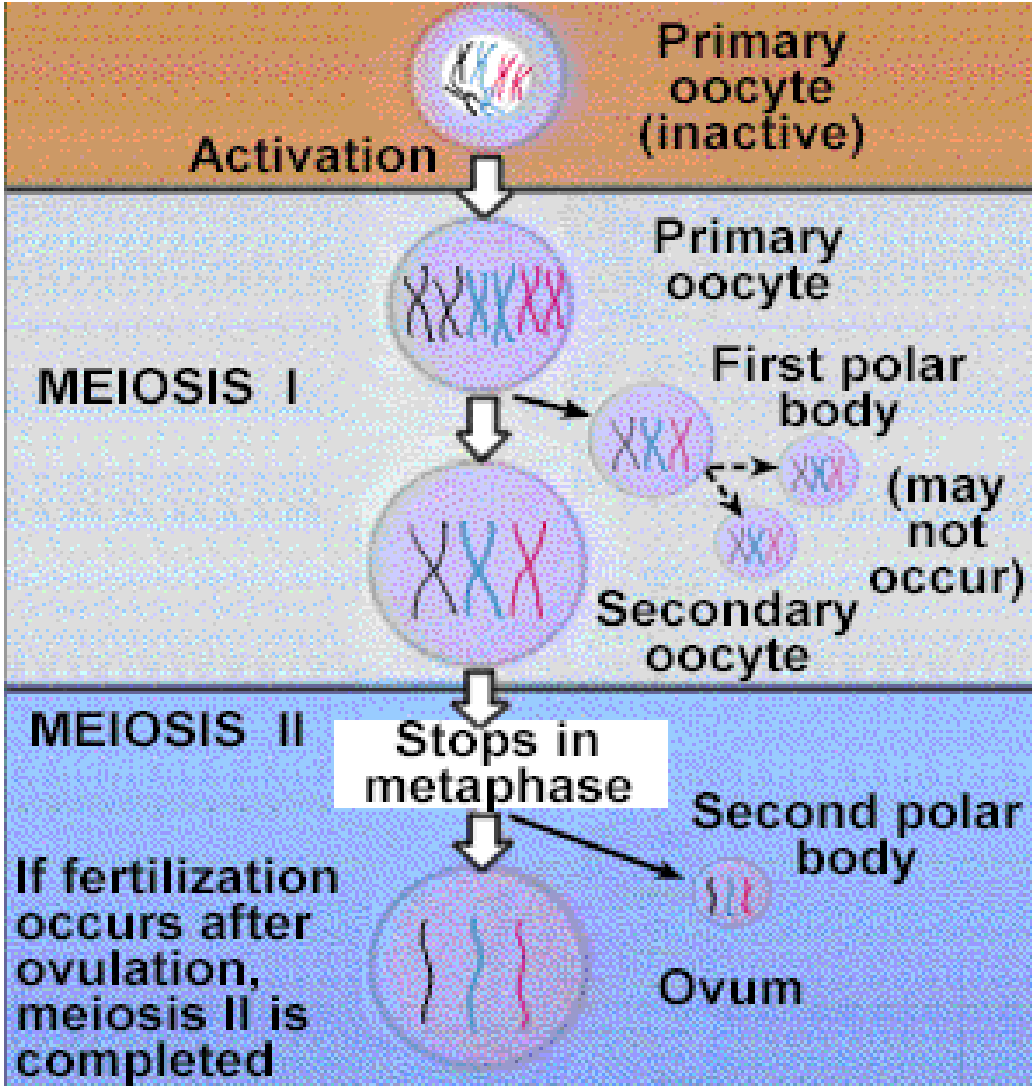


Atresia

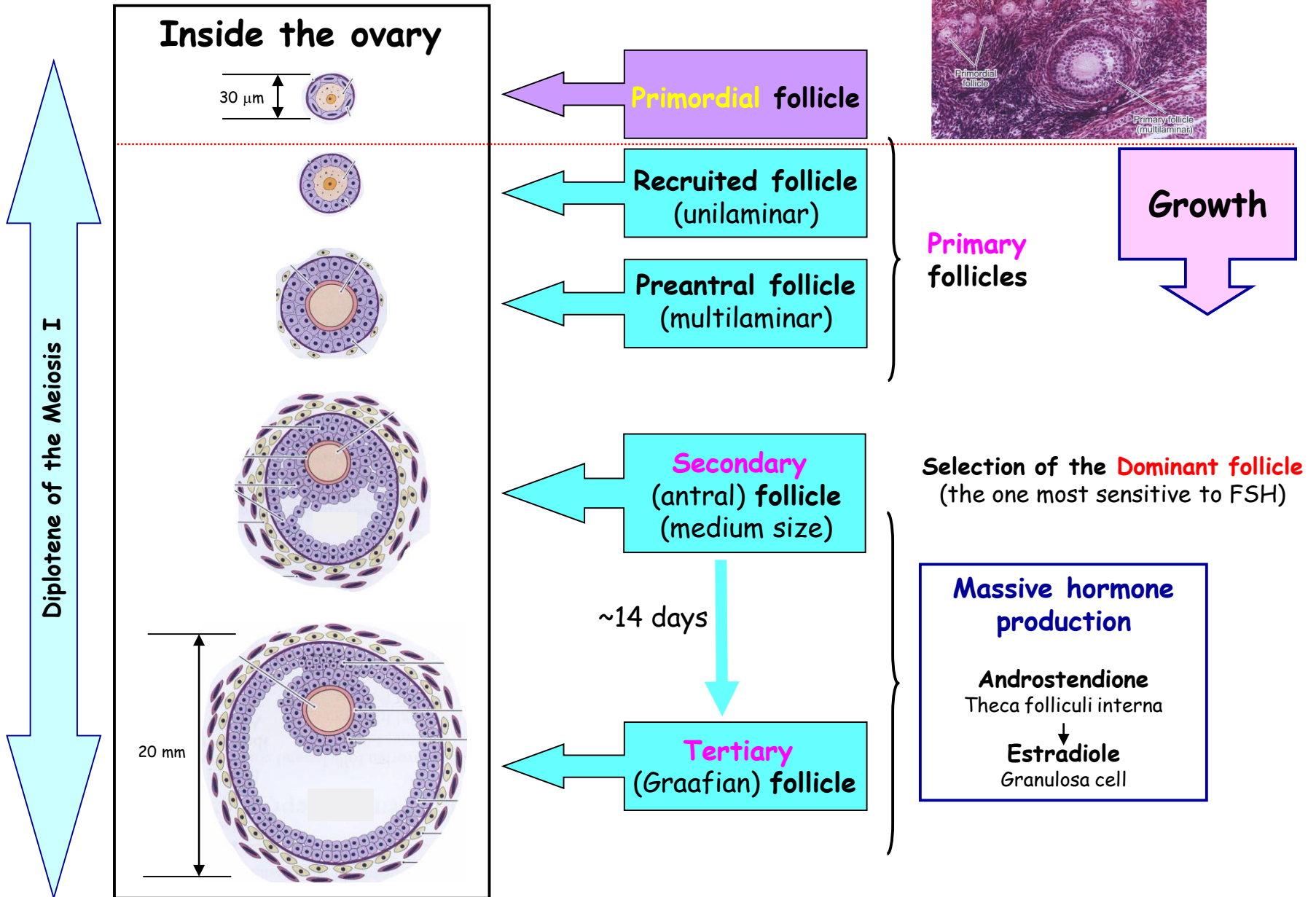
Ovulation (~ 500 oocytes)

At the time of menopause
max. 100 - 1000 remaining oocytes

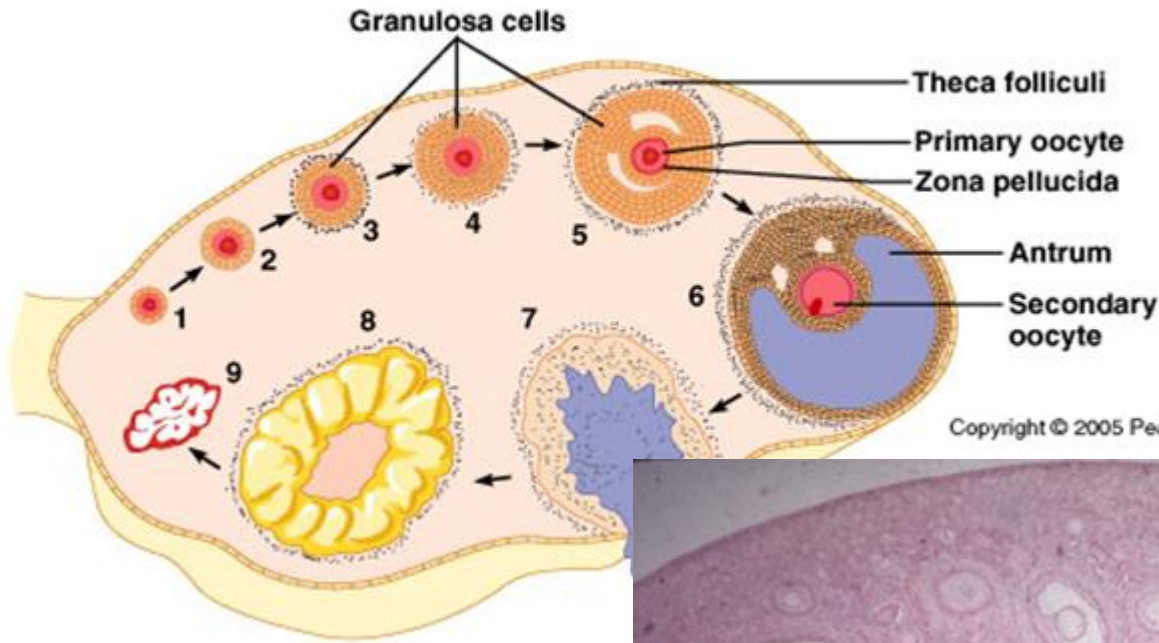
Oogenesis - Polar body production



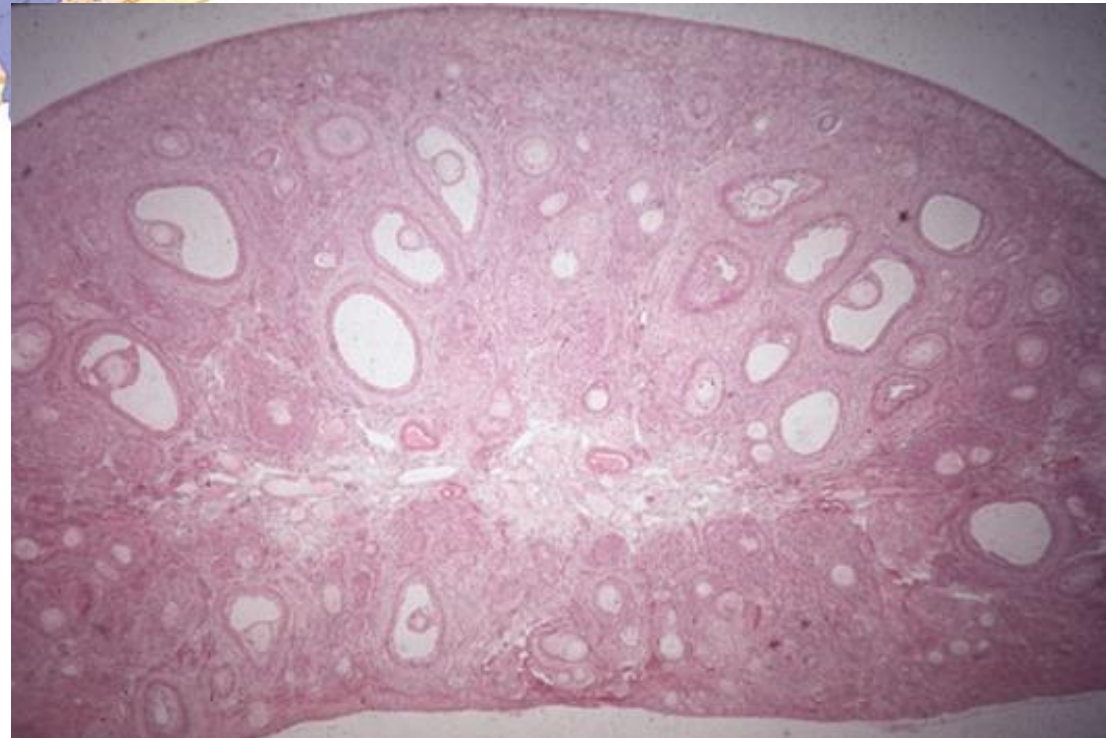
Oogenesis - stages of the oocyte development



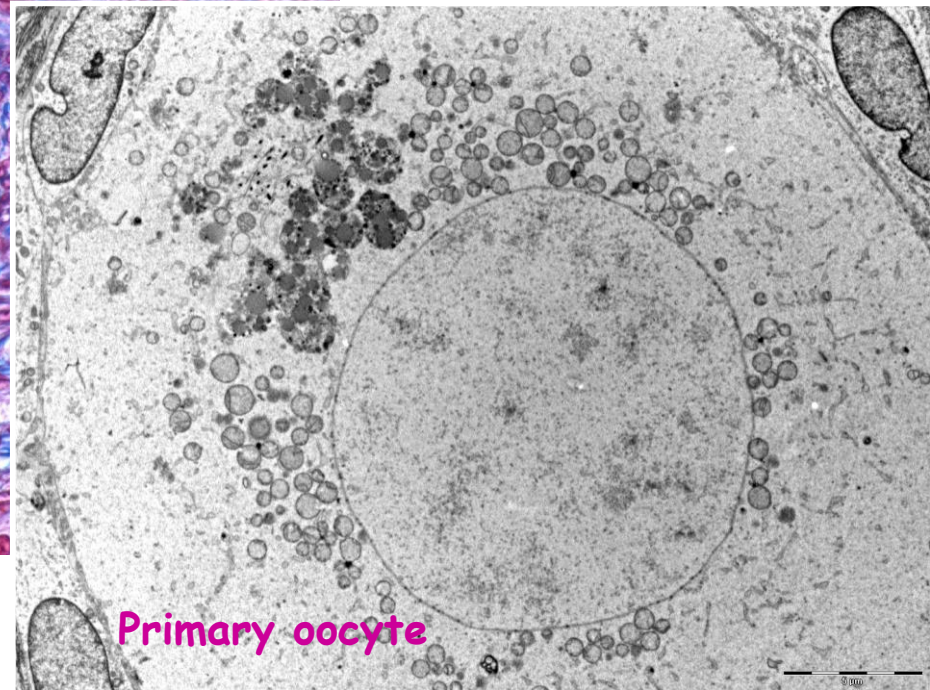
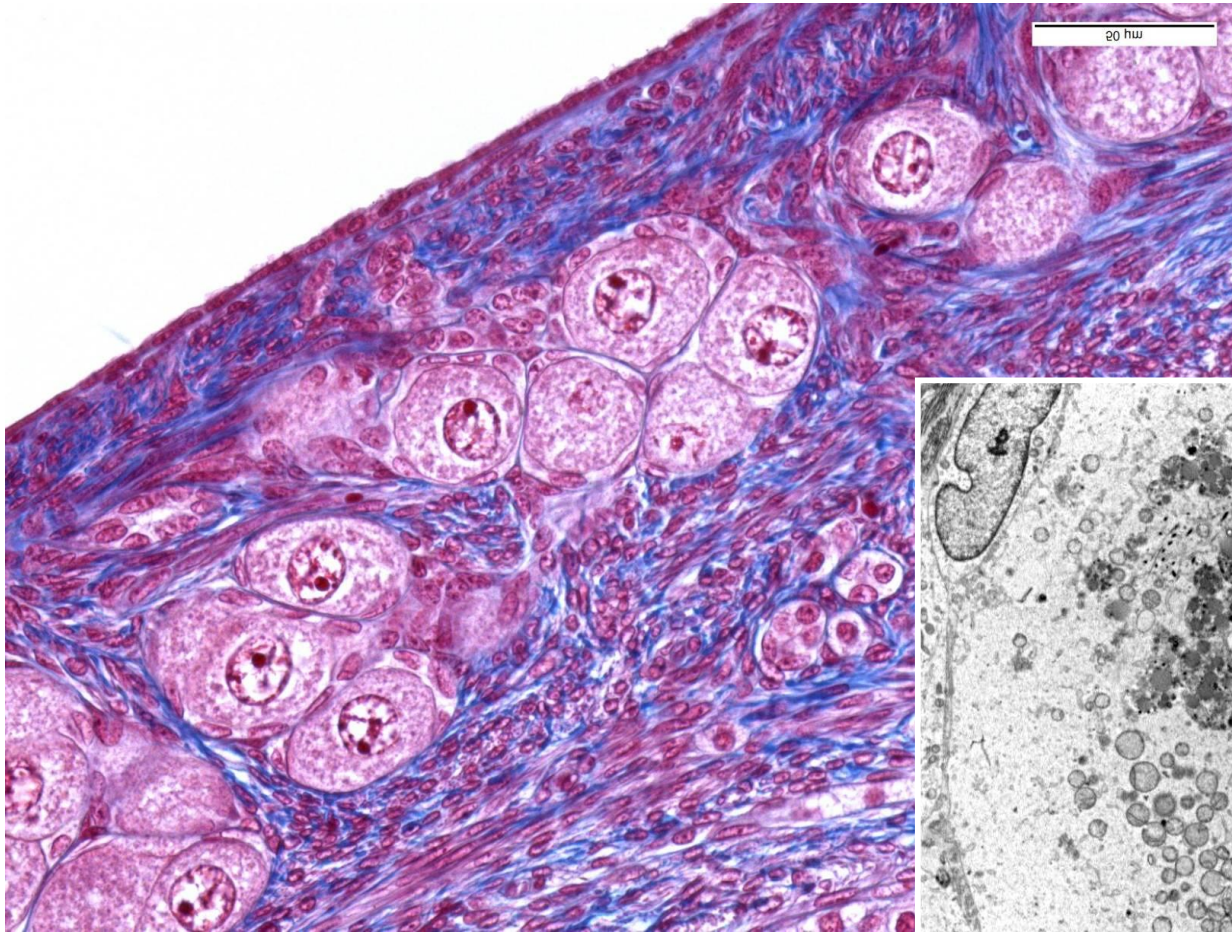
Oogenesis - Overall picture inside the ovary



Copyright © 2005 Pearson Education, Inc., publishing as Benjamin Cummings.

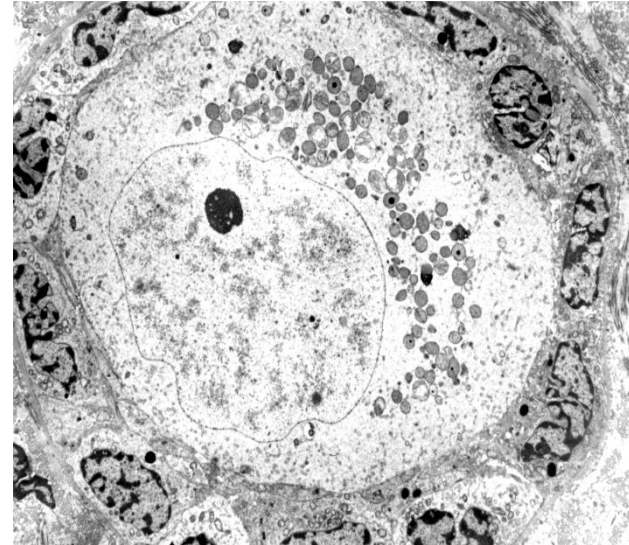
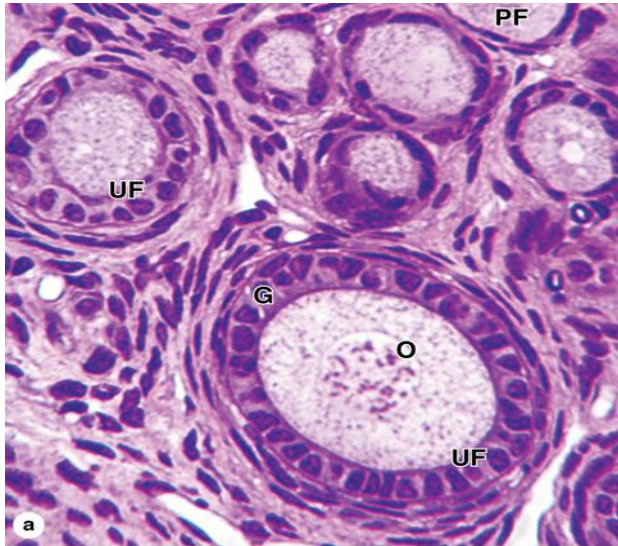


Oogenesis - Primordial follicles

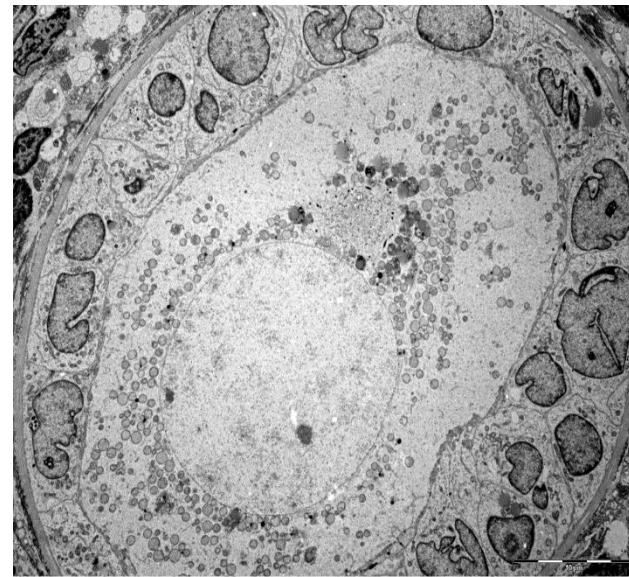
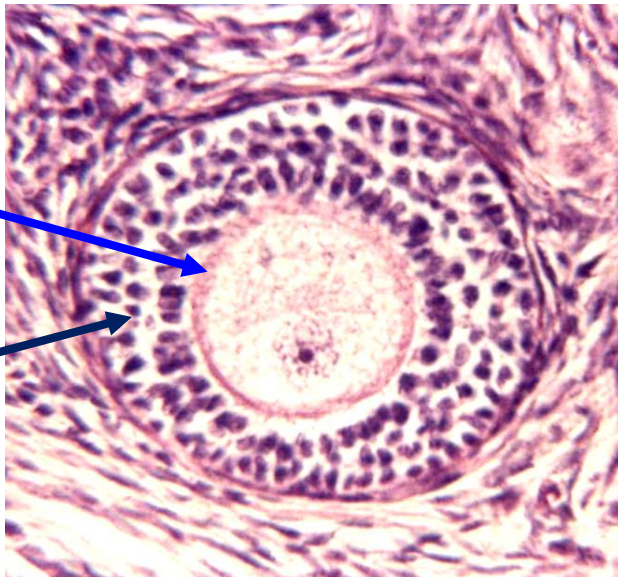

- Organelles around nucleus
- Abundant mitochondria
- Abundant RER

Oogenesis - Primary follicles

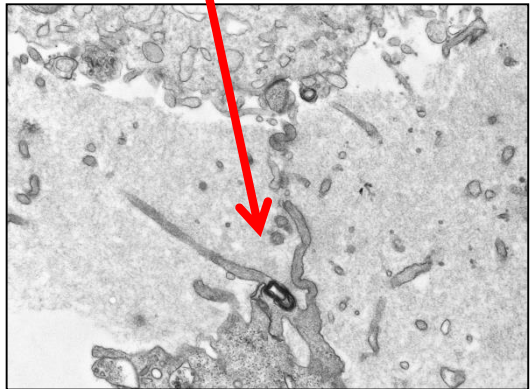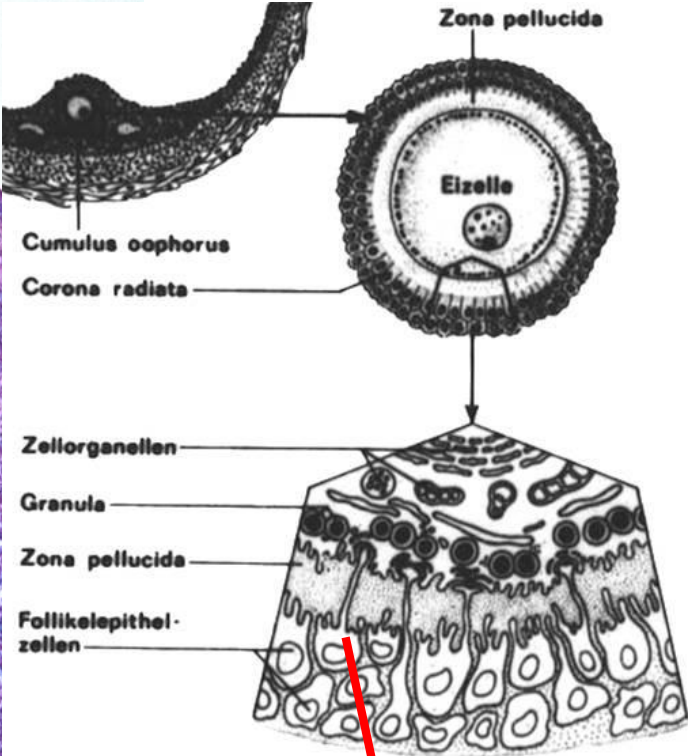
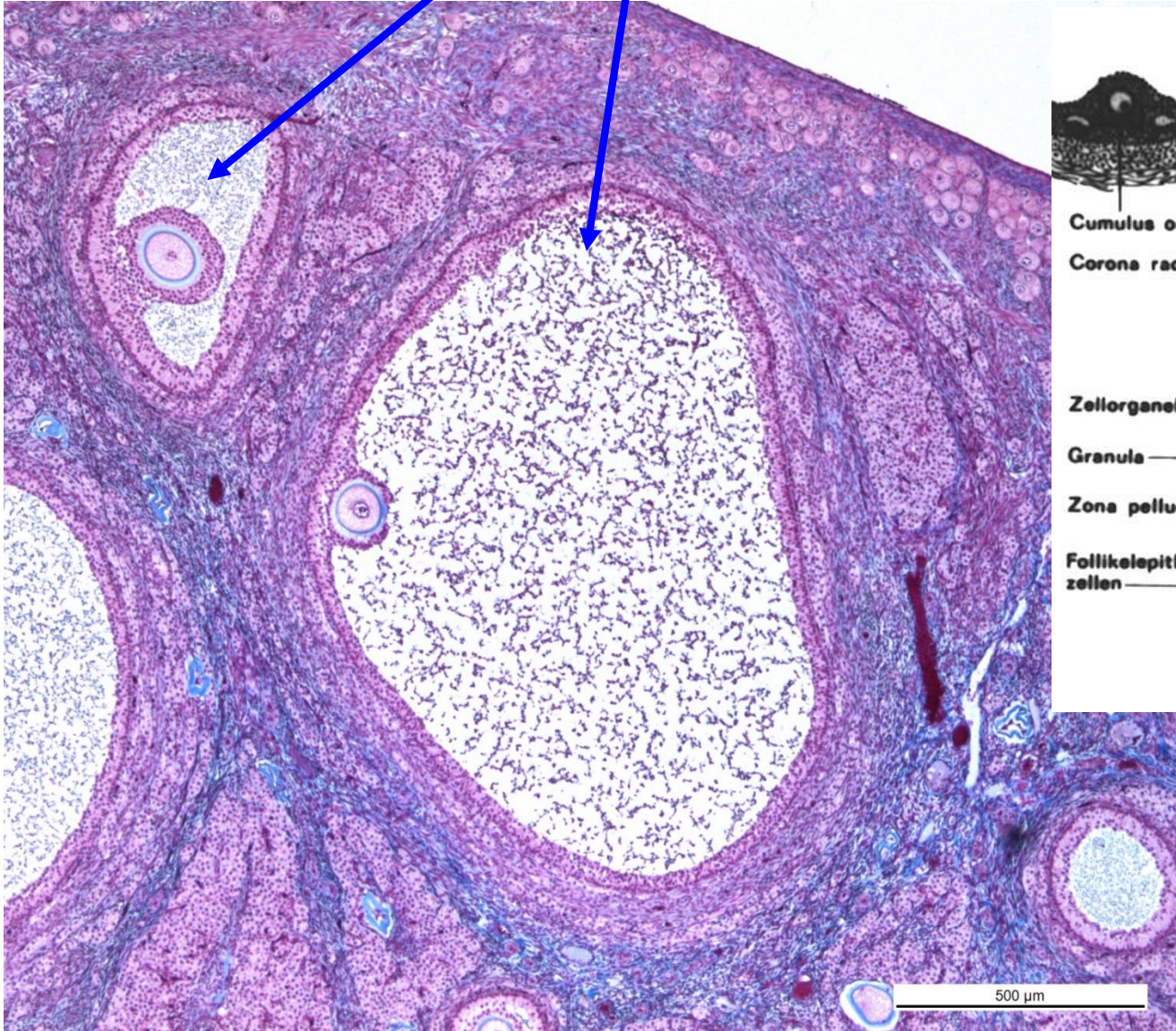


Unilaminar

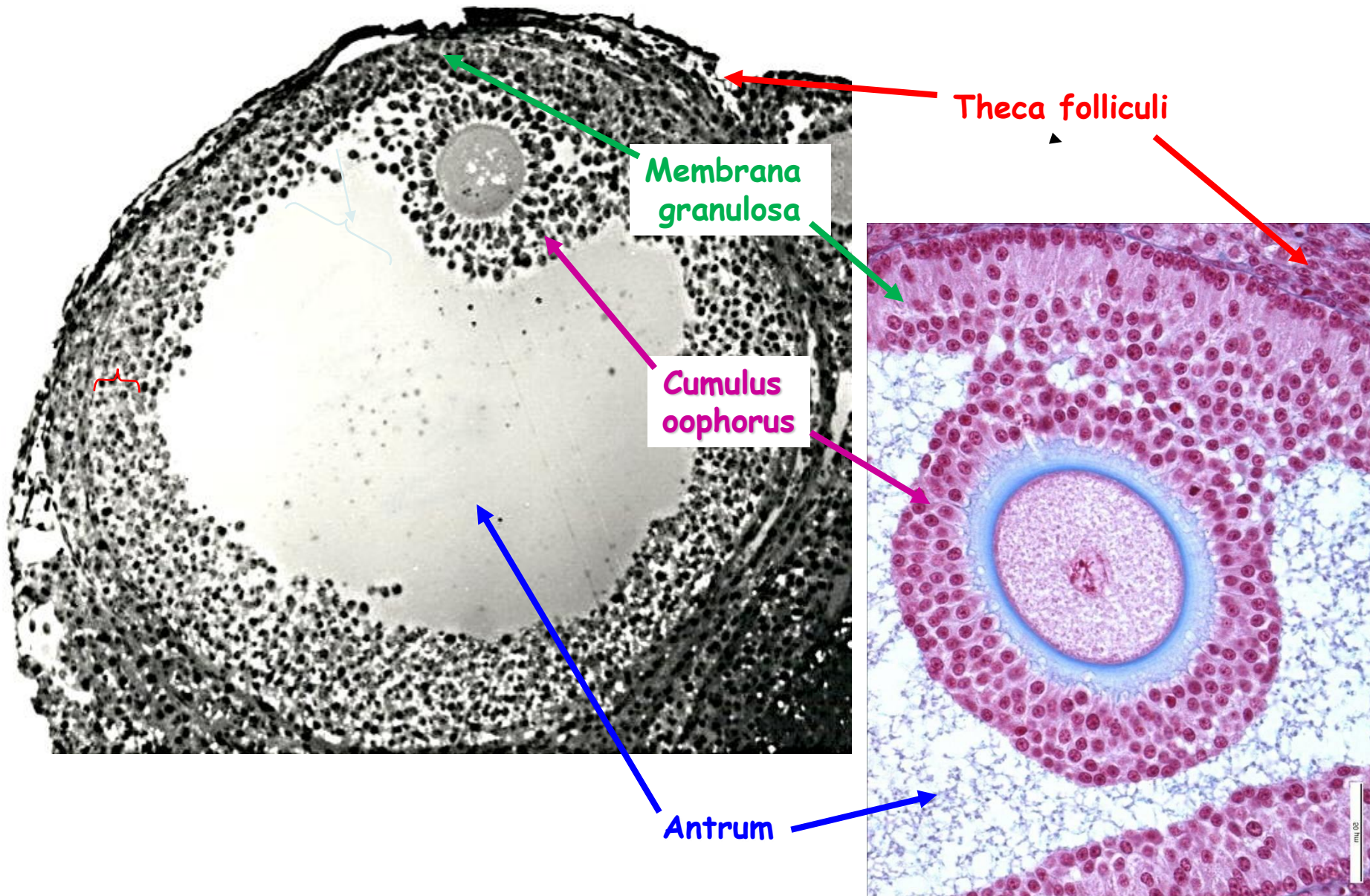


Multilaminar

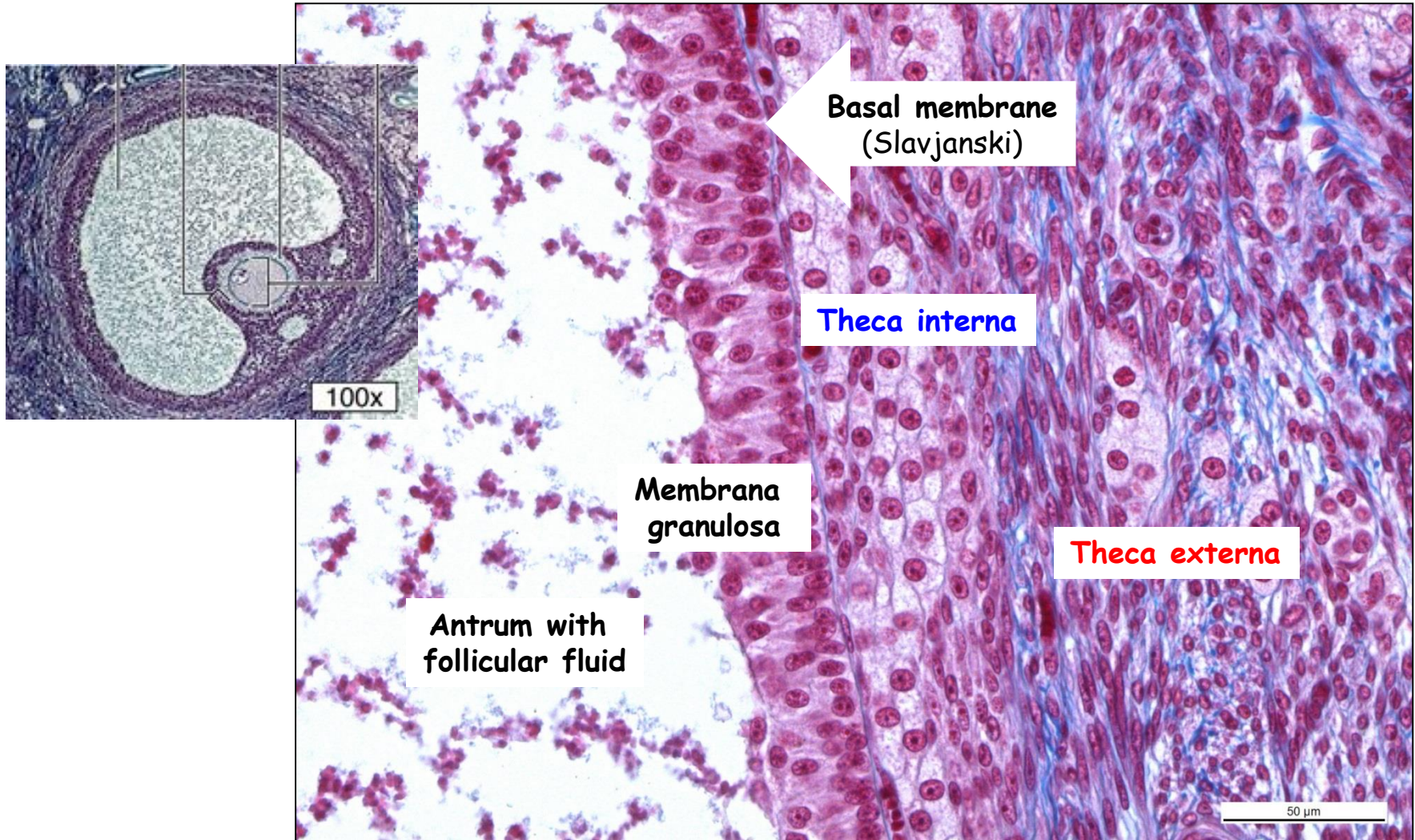
Oogenesis - Secondary (antral) follicles



Oogenesis - Tertiary (Graafian, preovulatory) follicle



Oogenesis - Wall of tertiary follicle



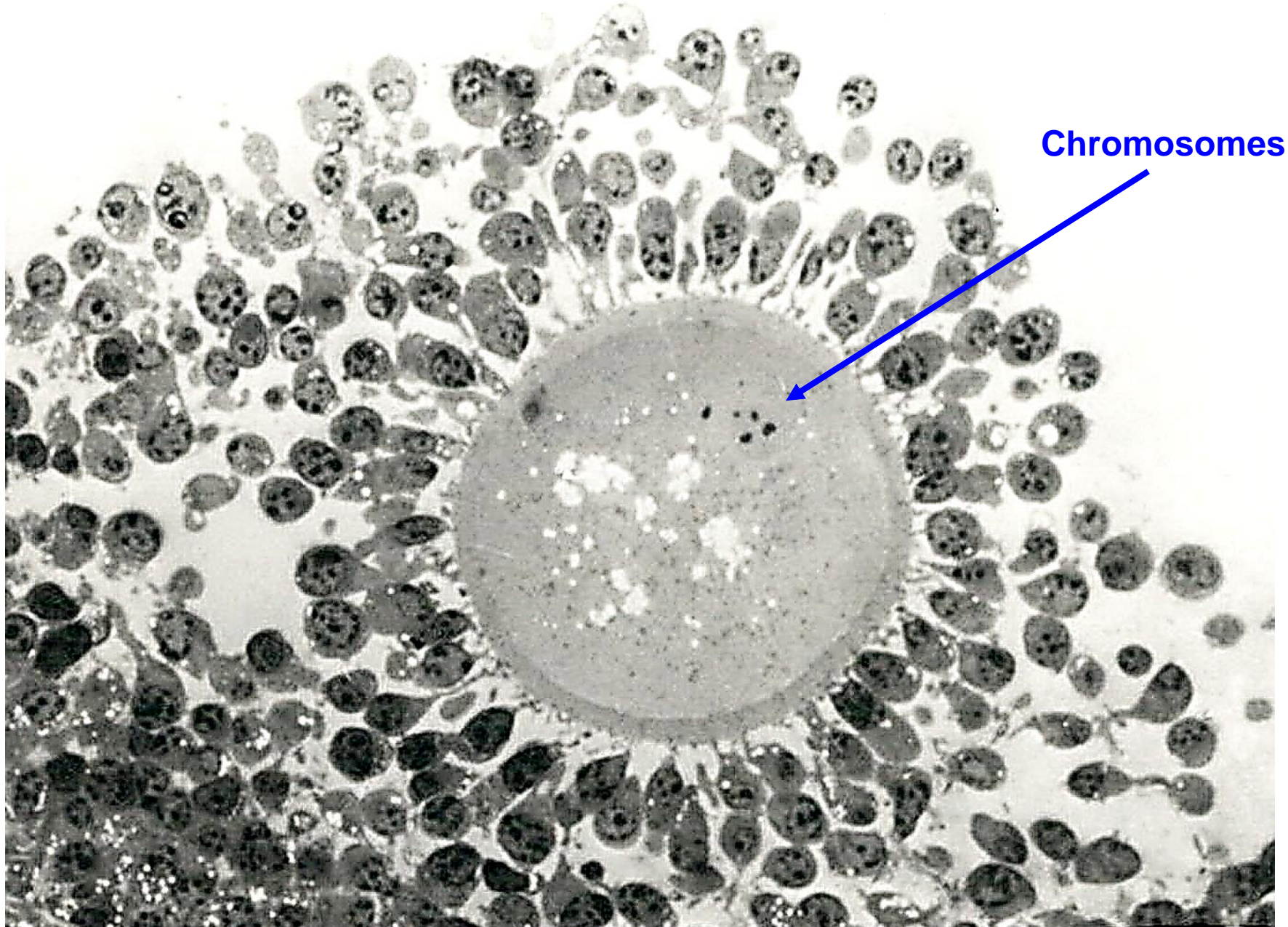
Theca interna

- Vascularized
- Androstendione to granulosa cells - estradiol

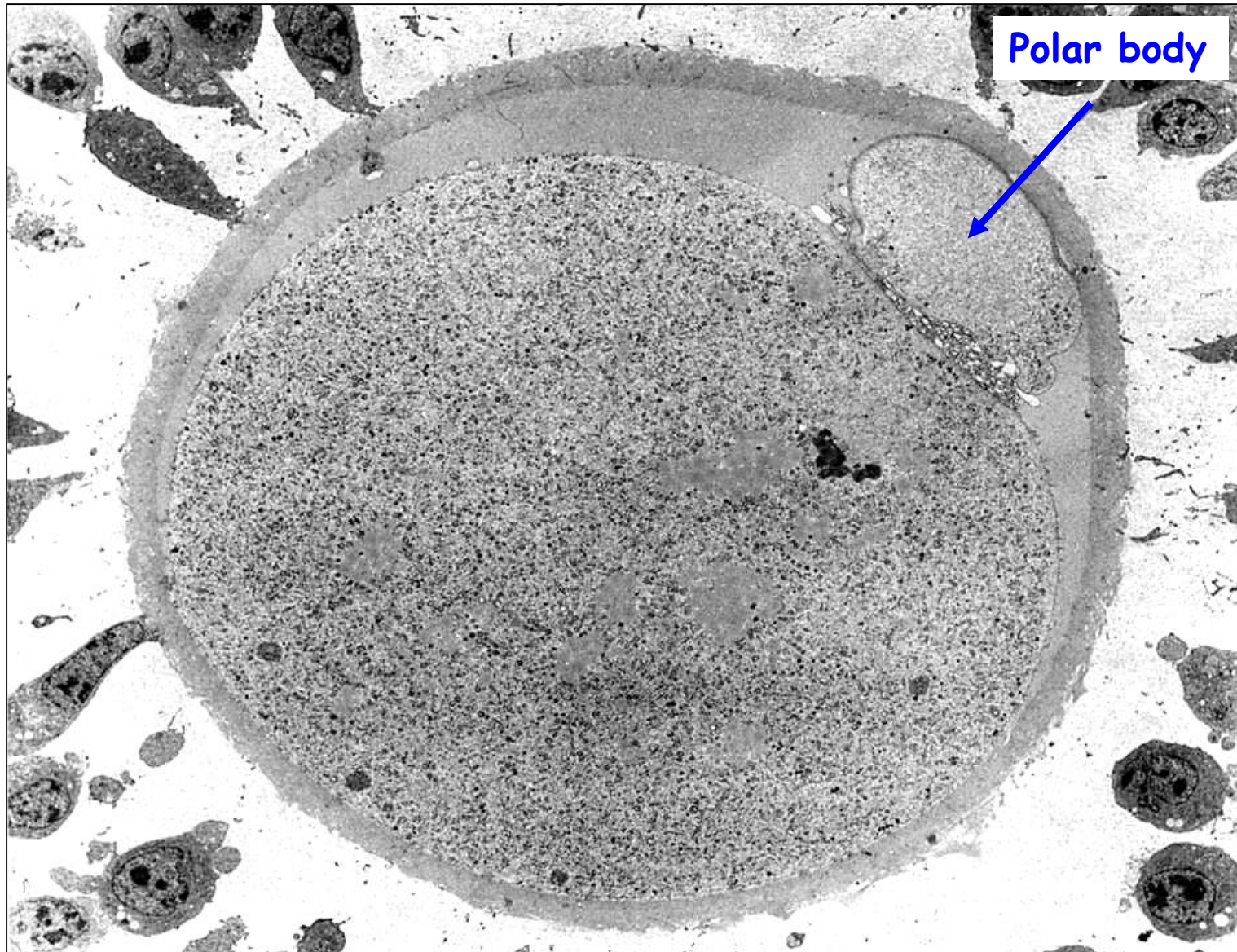
Theca externa

- Fibrous with smooth m. cells

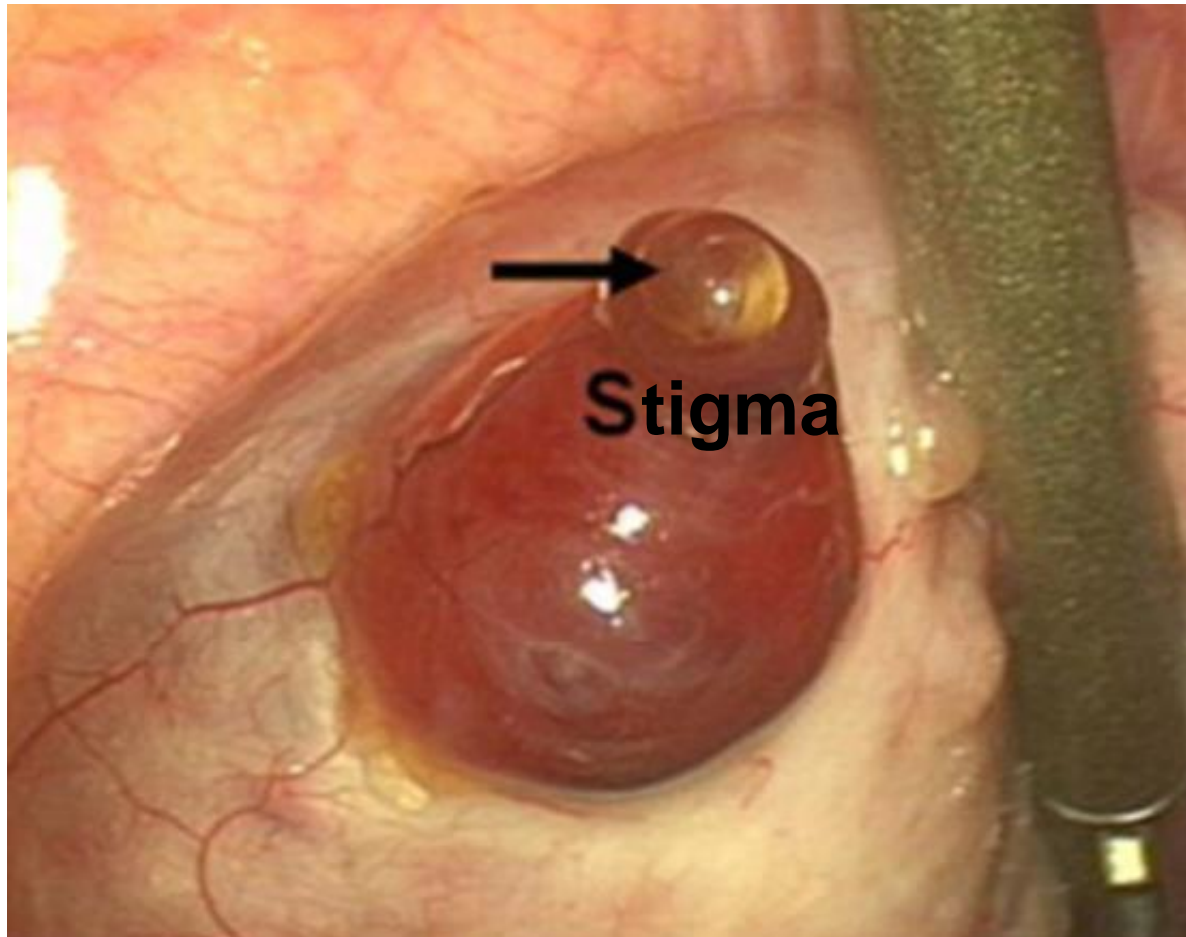
Oogenesis - MI phase oocyte surrounded by corona radiata



Oogenesis - MII phase oocyte

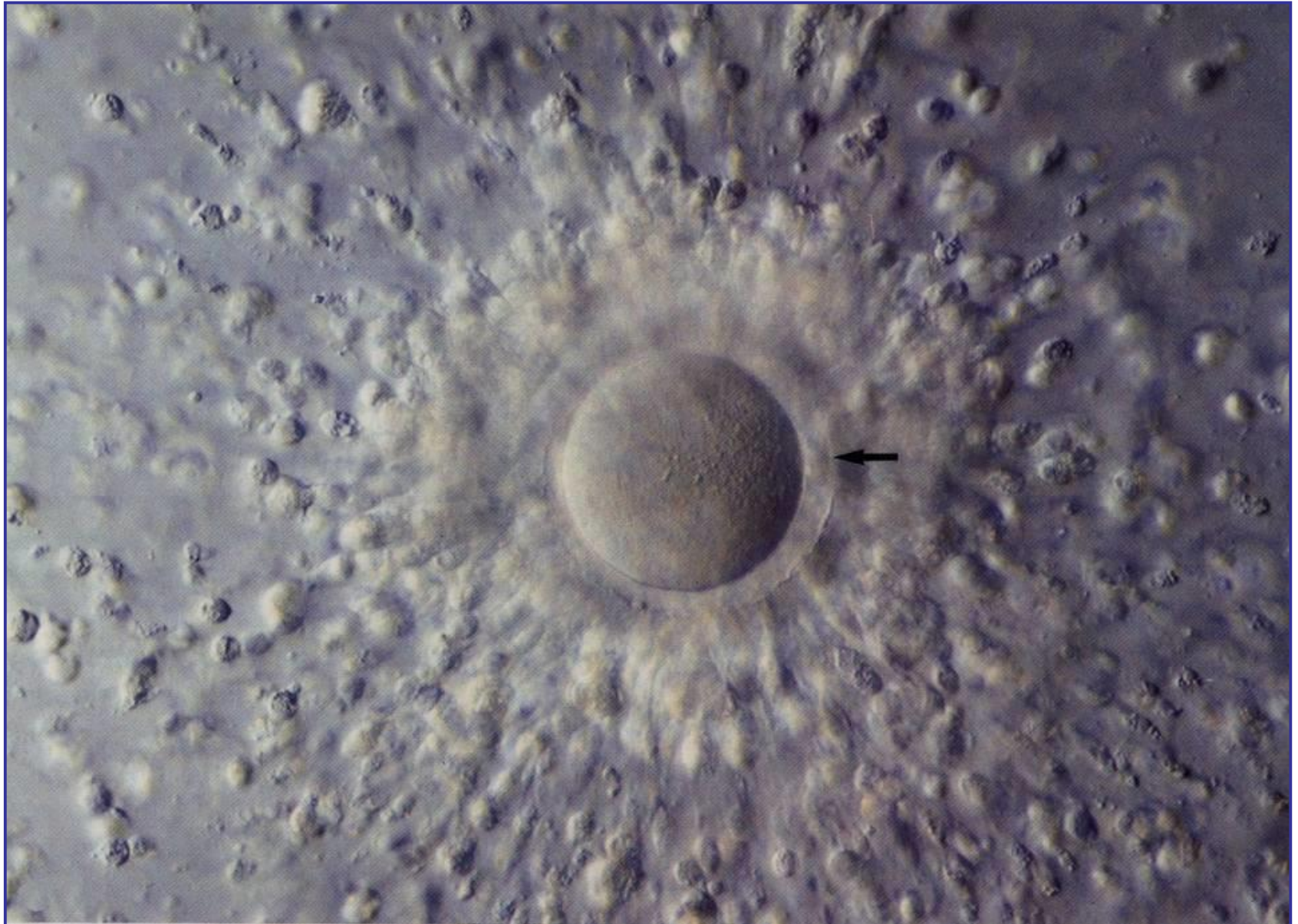


Oogenesis - Ovulation

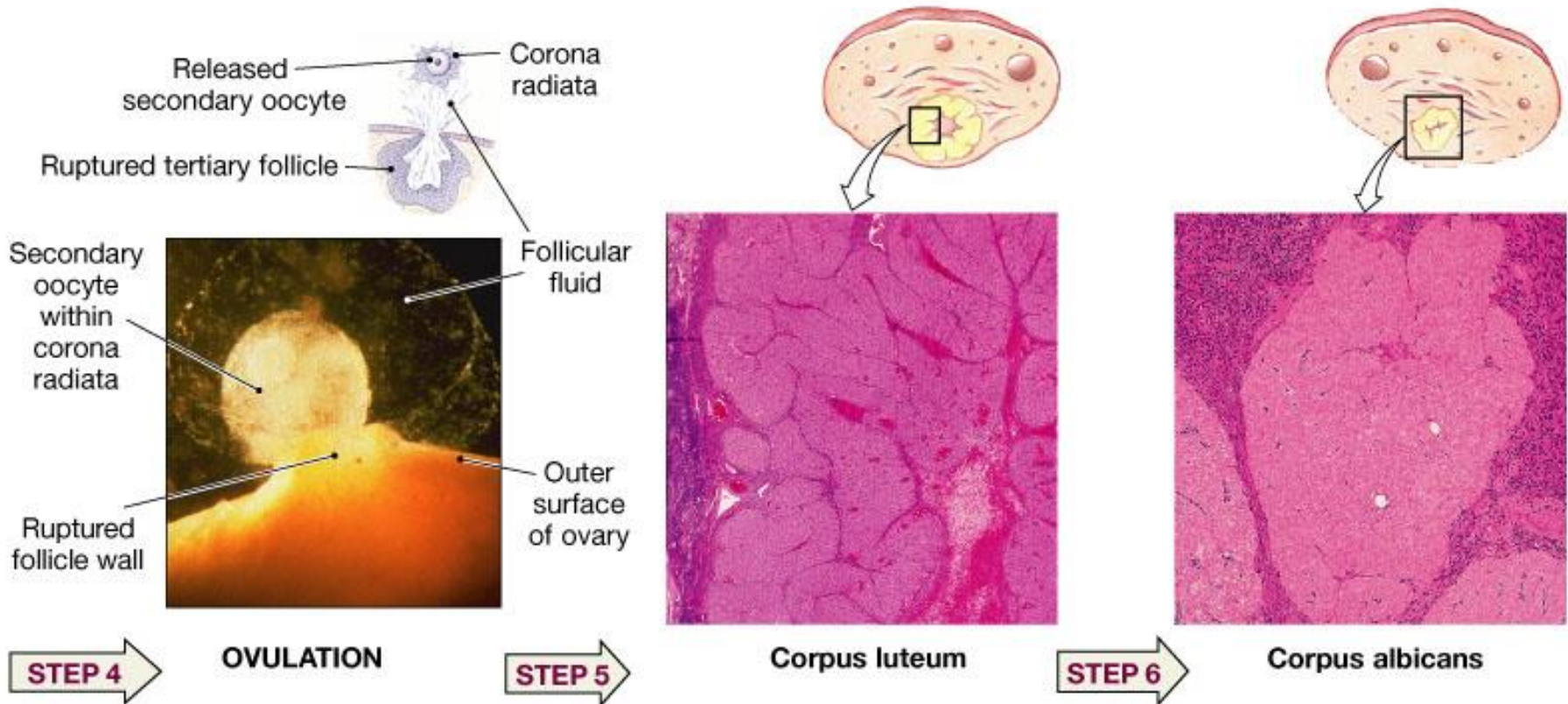


- initiated by LH surge
- no blood flow at stigma - ischemia
- smooth muscle contractions - theca f. externa

Oogenesis - Ovulated oocyte



Corpus luteum 1



Copyright © 2004 Pearson Education, Inc., publishing as Benjamin Cummings.

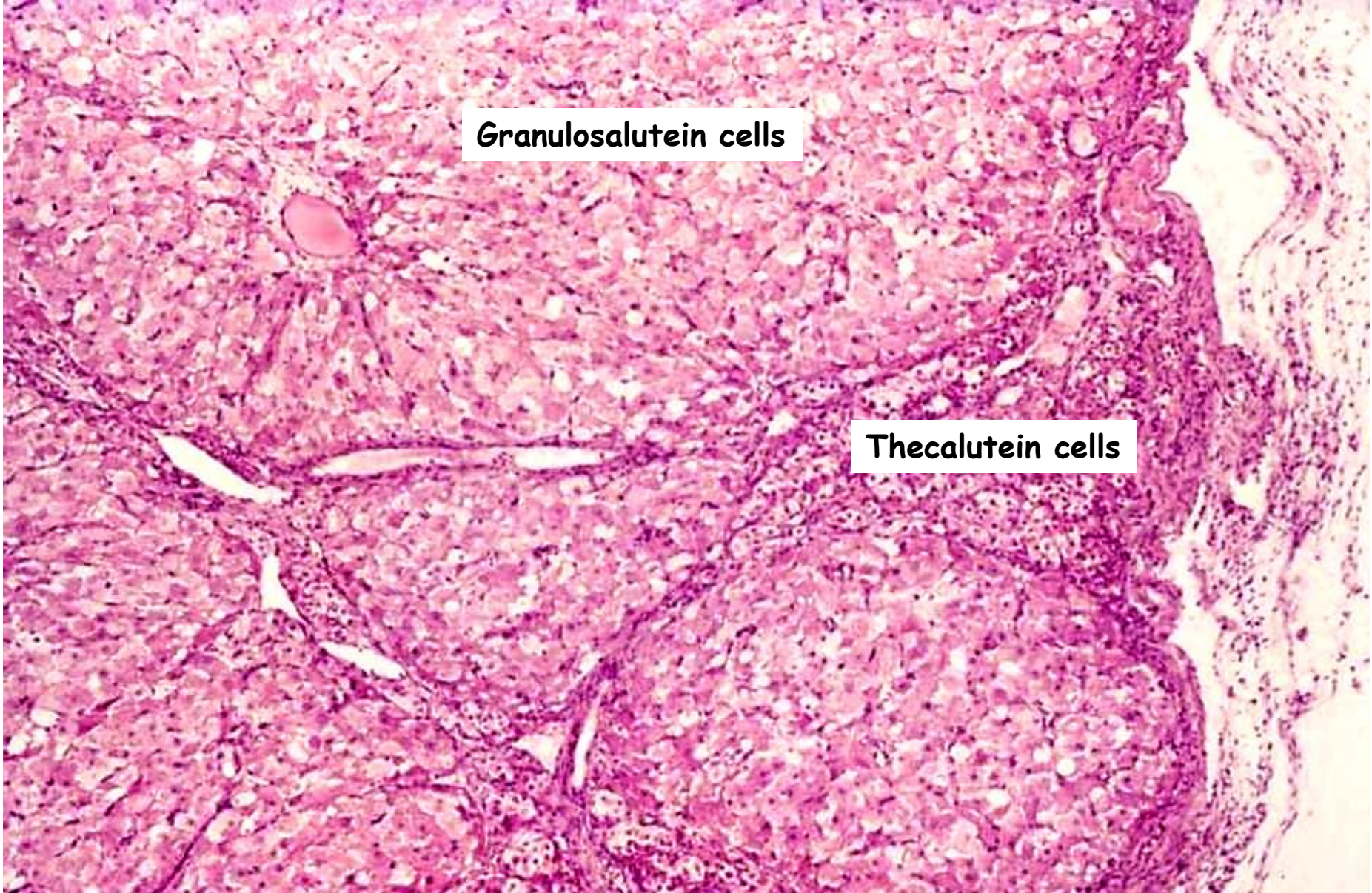
Granulosa cells - Granulosa lutein cells

- large (20-30 μm)
- 80 % of CL
- convert androstendione to progesterone and estradiol

Theca interna cells - Theca lutein cells

- smaller (10-15 μm)
- production of steroids
- vascularized - fenestrated caps.

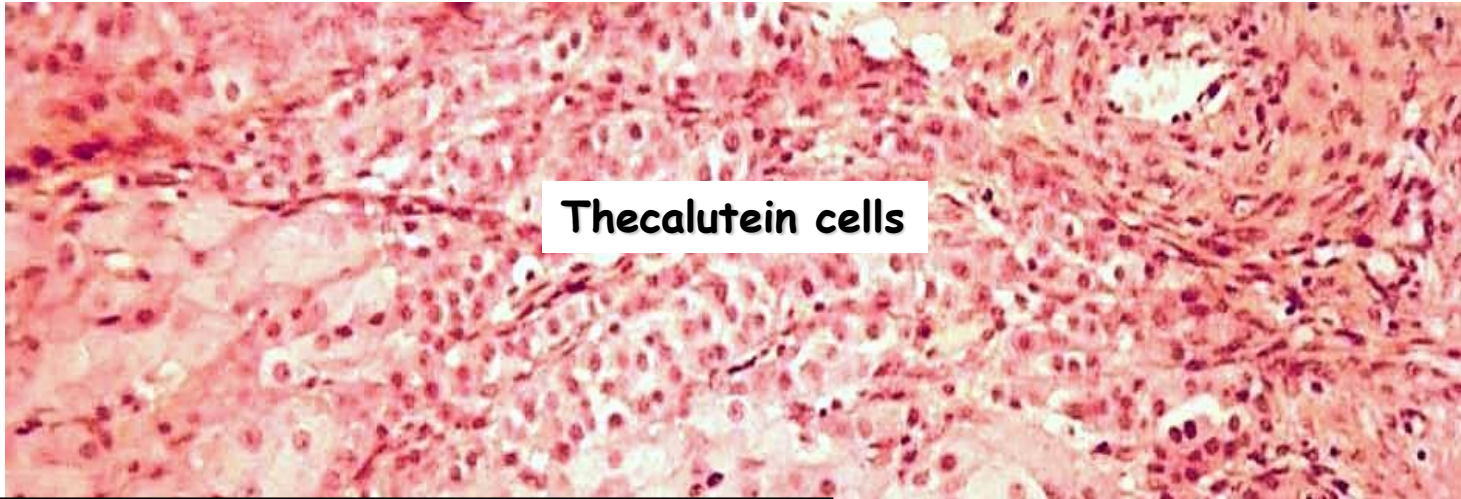
Corpus luteum 2



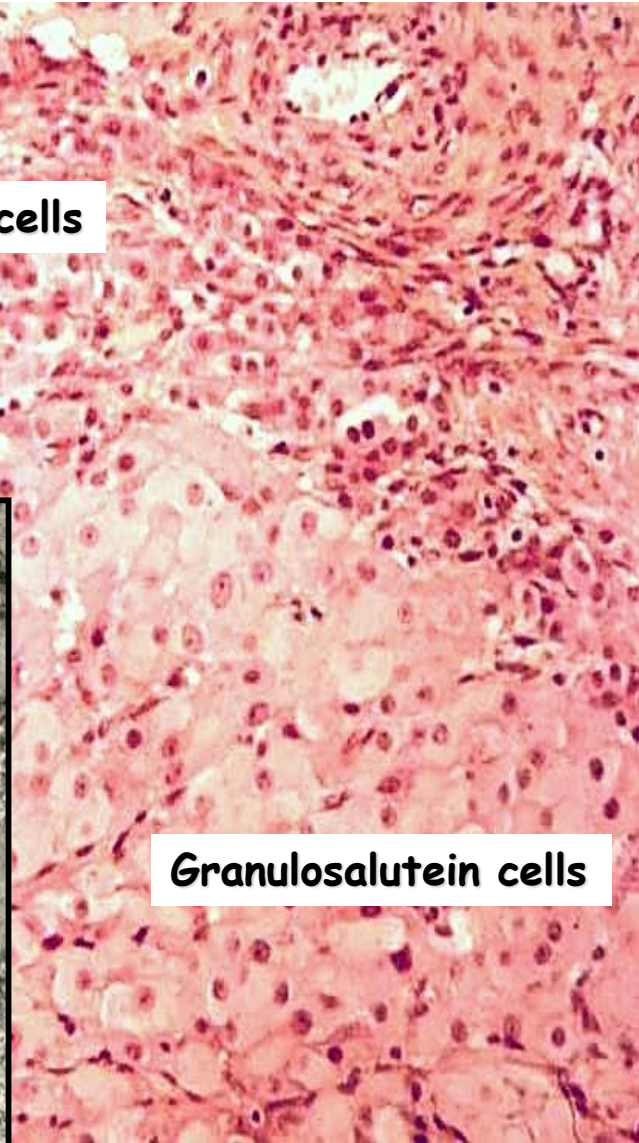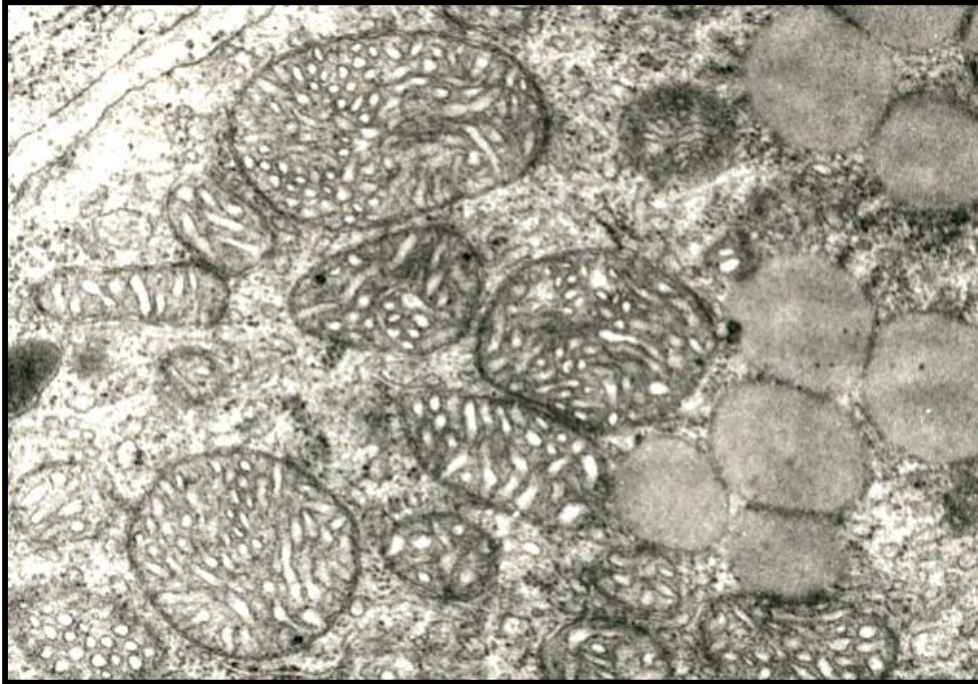Granulosalutein cells

Thecalutein cells

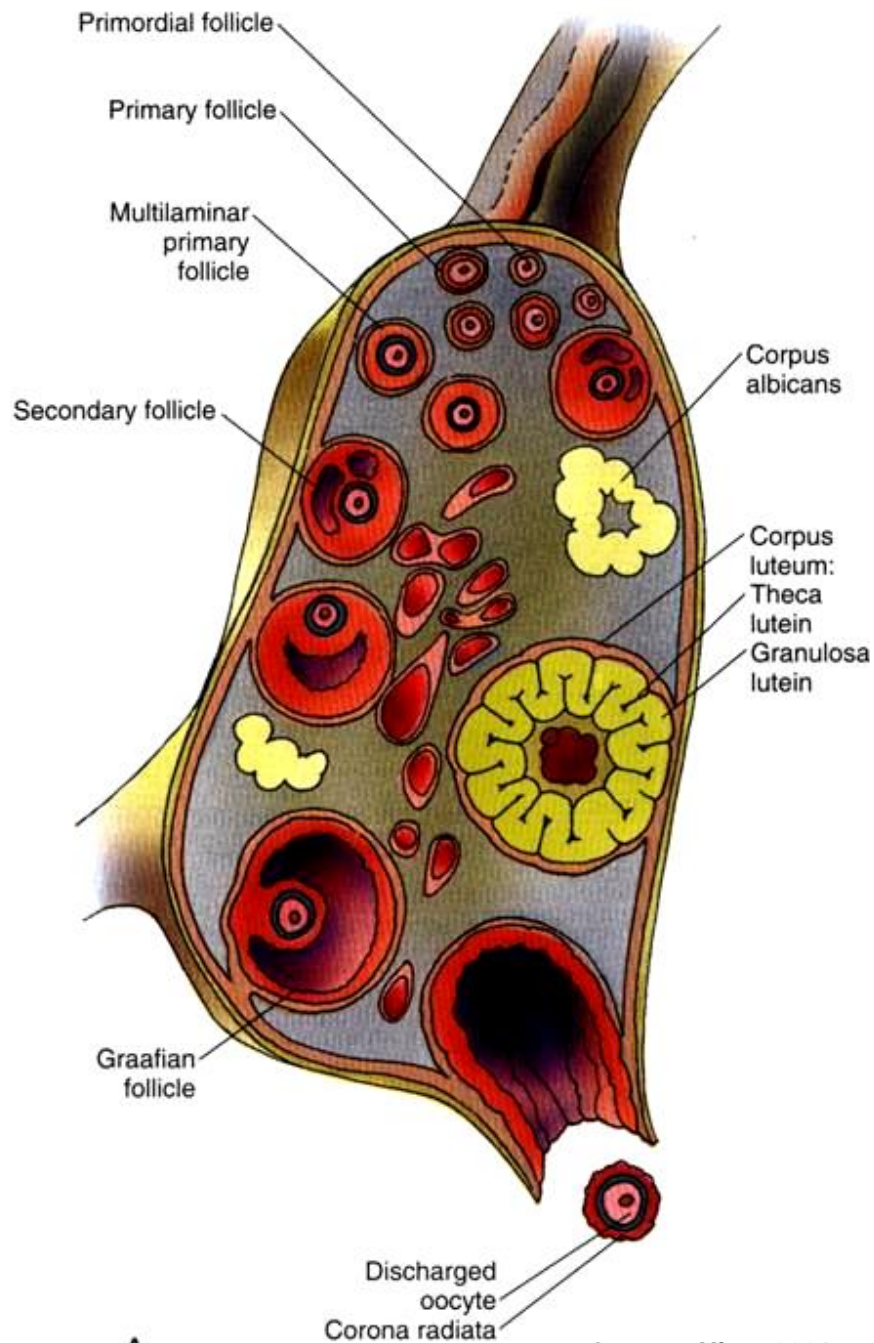
Corpus luteum 3



Thecalutein cells



Granulosalutein cells



A.

Gartner, Hiatt, 2001

Corpus luteum 4

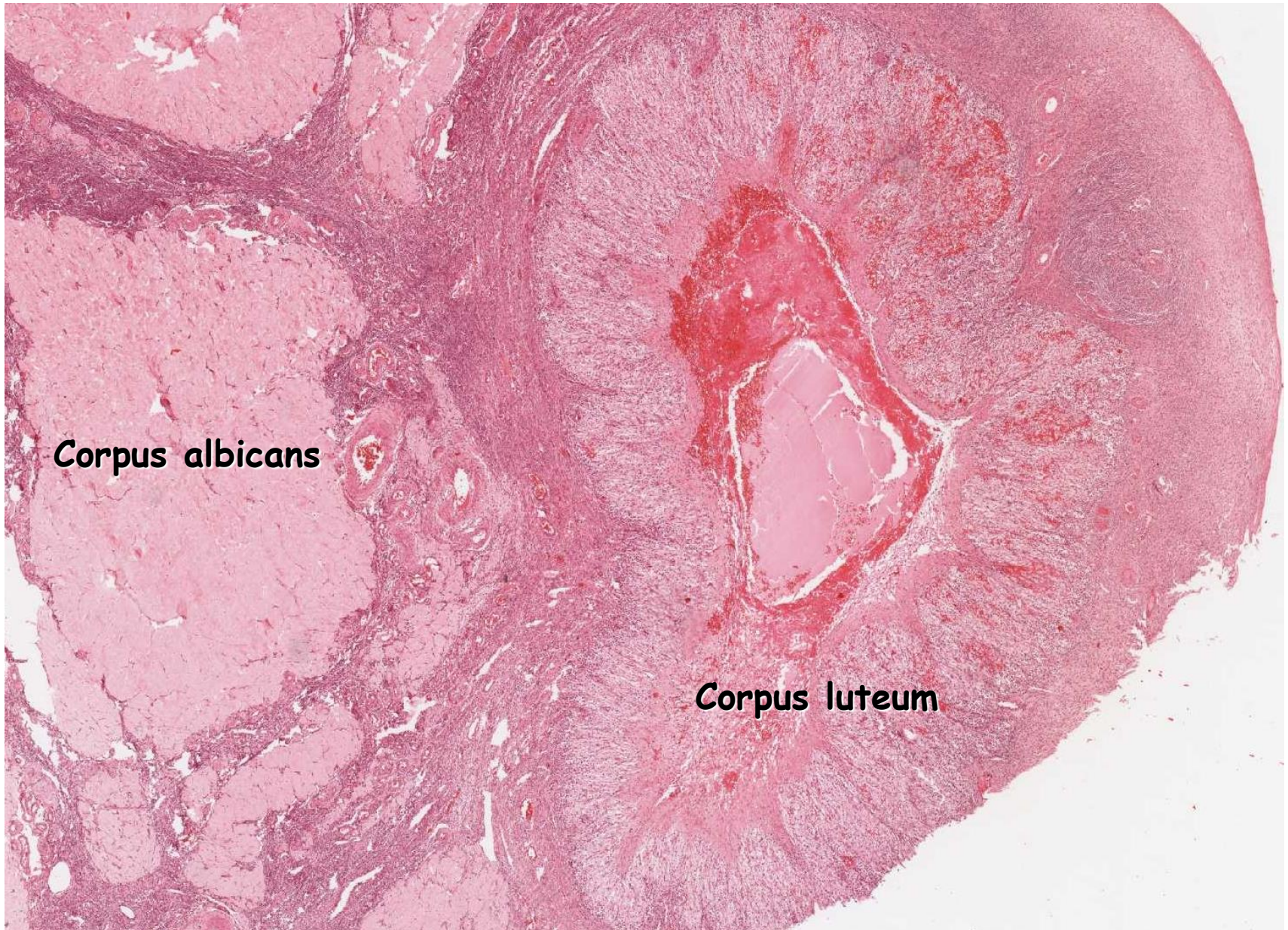
CL graviditatis

- diameter 2 - 3 cm
- maintains pregnancy
- maintained by chorionic gonadotropin (HCG)
- maximal at 2 months
- changes to c. albicans at month 4-5

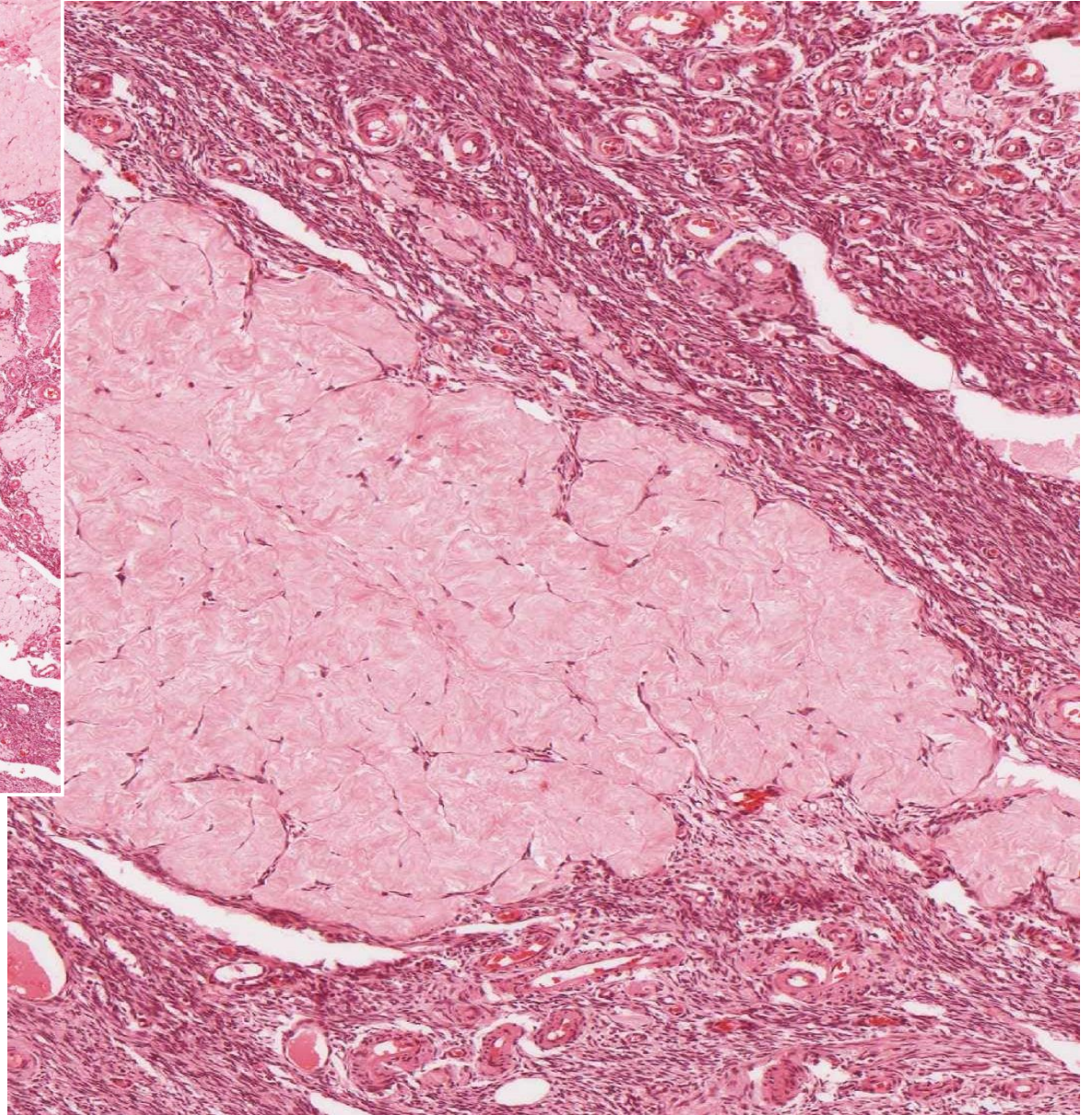
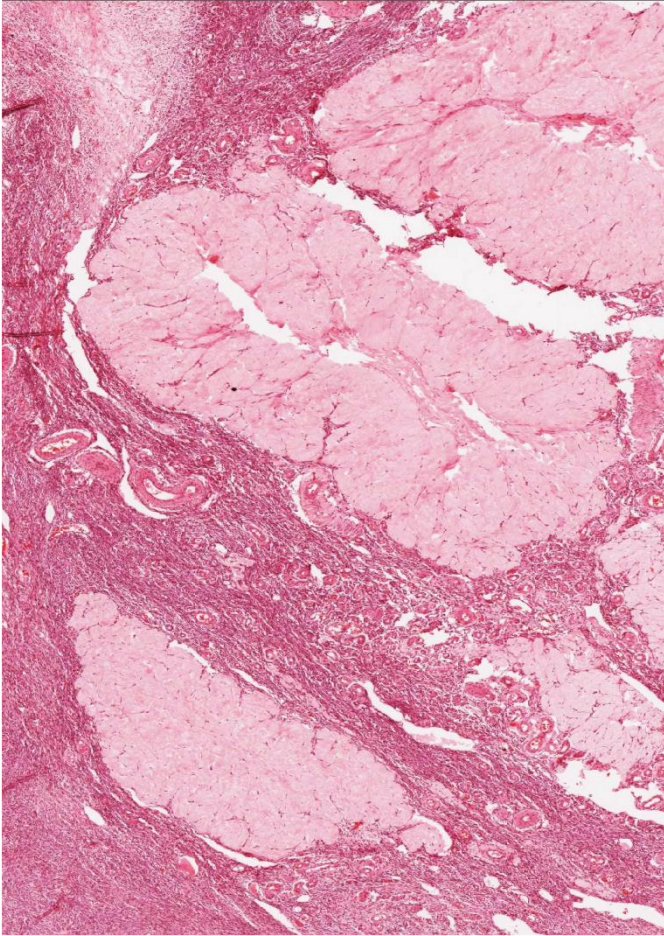
CL menstruationis

- 10 - 12 days
- changes to c. albicans
(dense connective tissue - collagen + fibroblasts)

Corpus luteum & albicans

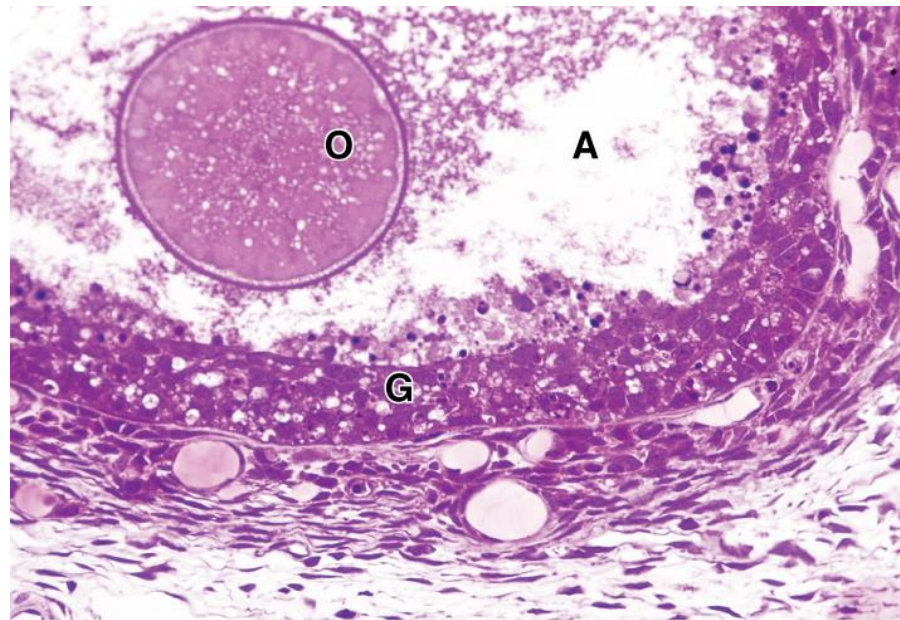
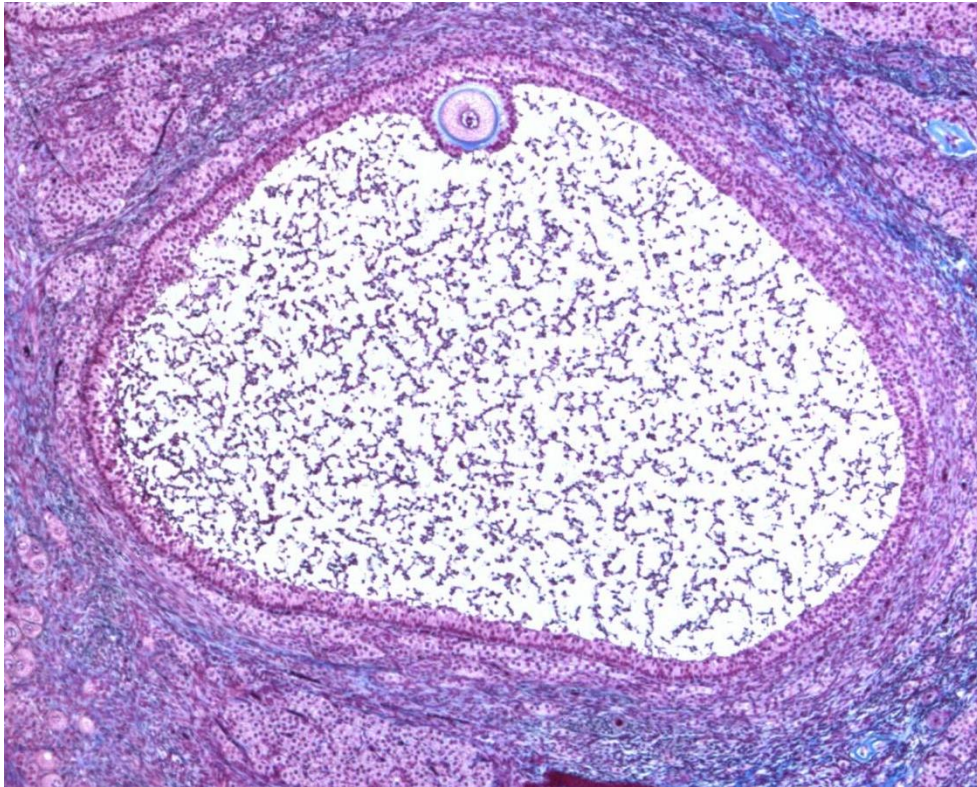
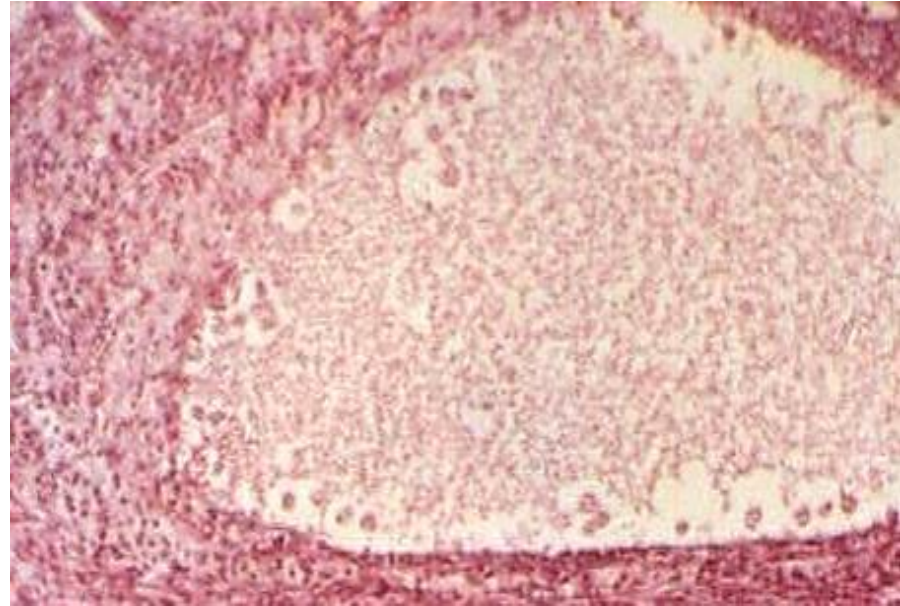


Corpus albicans



Follicular atresia

- all types of follicles
- apoptosis of follicular cells
- autolysis (autophagy) oocytes
- phagocytosis by macrophages
- zona pellucida and basal lamina persist the longest time



Ovarian cycle - 28 days

Preovulatory phase

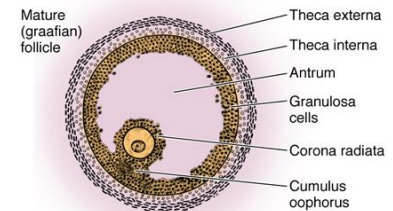
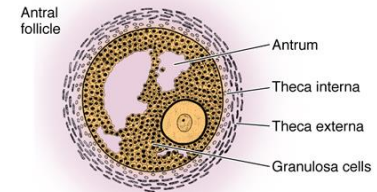
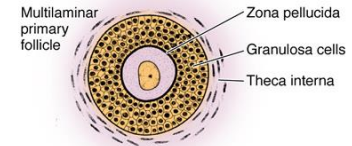
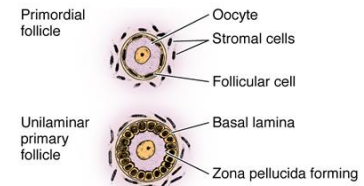
- days 1 to 14
- growth and maturation of follicles
- production of steroid hormones

Ovulation

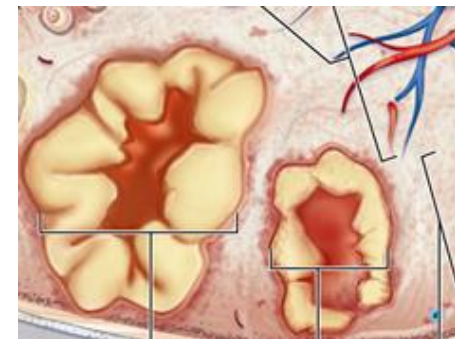
- at day 15

Postovulatory phase

- days 16 to 28
- corpus luteum
- production of progesterone

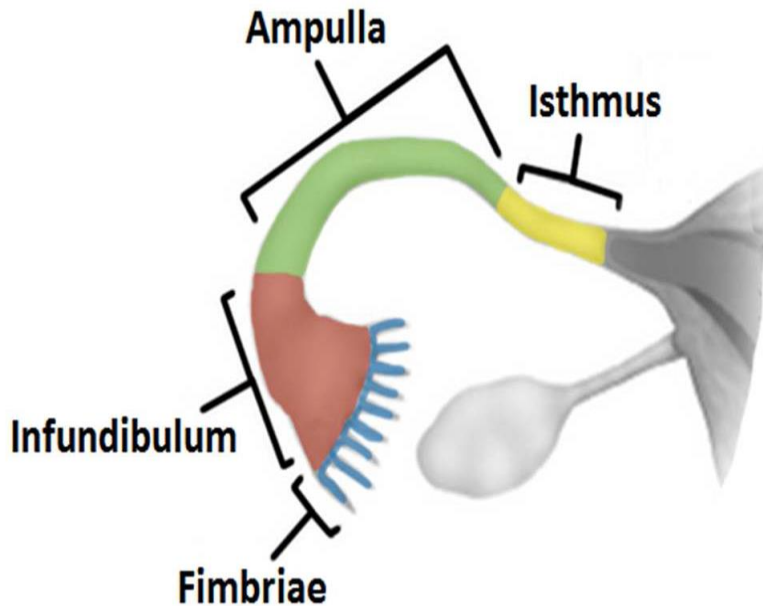


Mescher, 2010

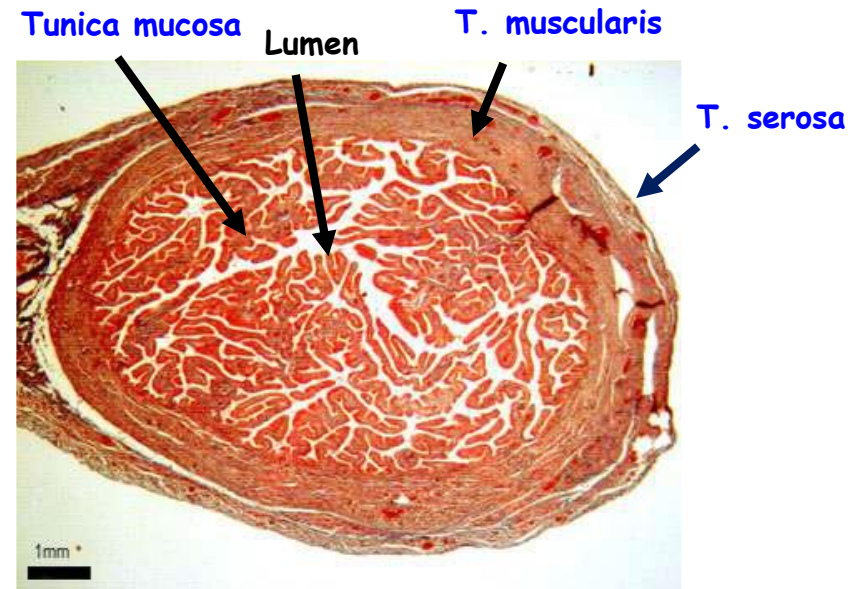


Uterine tubes = Fallopian tubes = Oviducts

- connect the ovaries to the uterus
- 12 to 15 cm long x 0.7 to 5 cm in diameter
- location of fertilization and early embryonic development

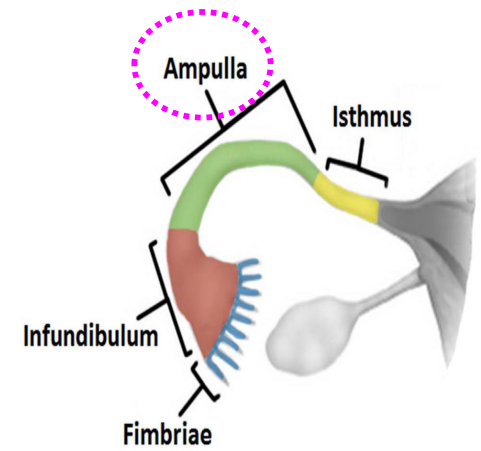
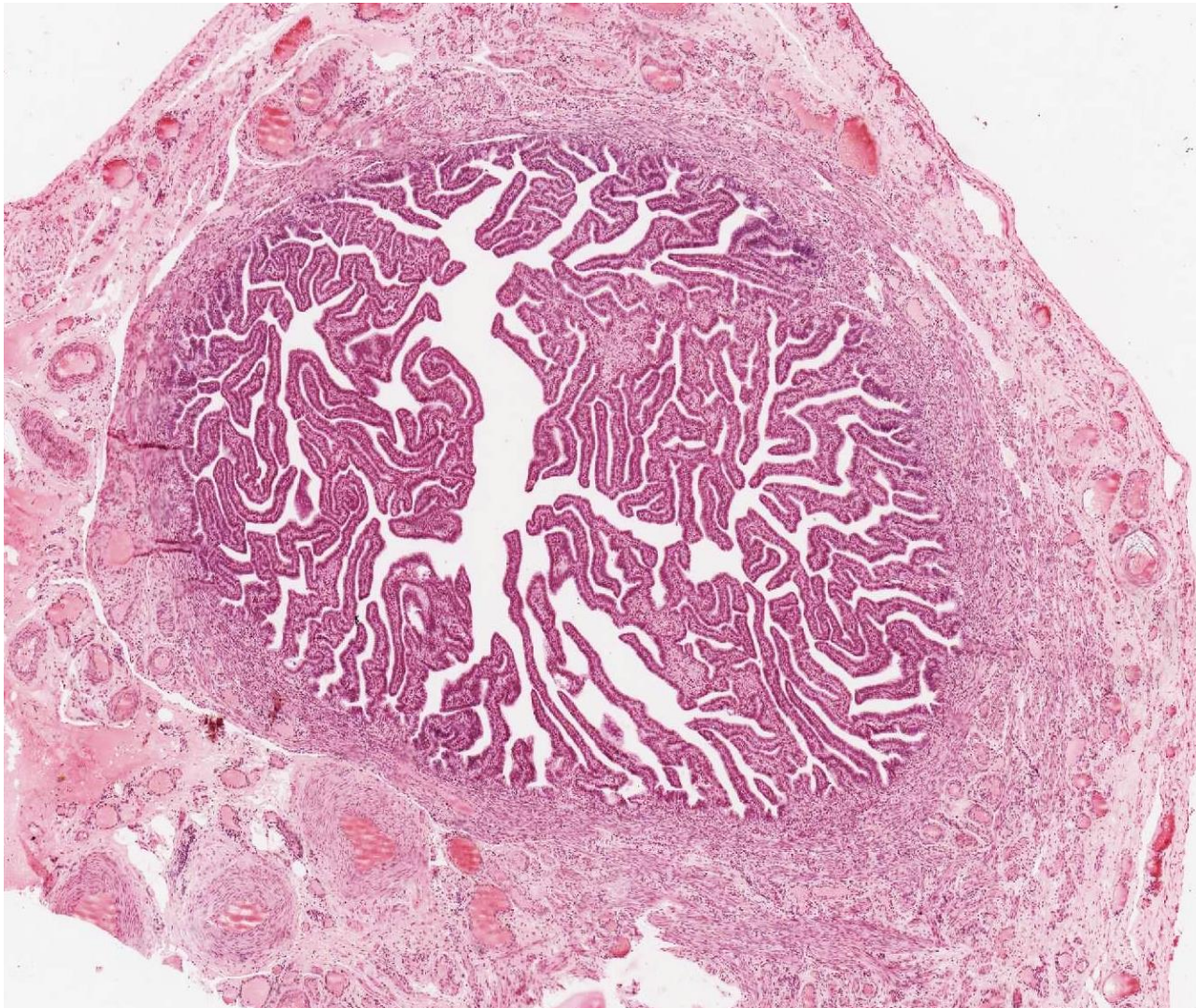


Teachmeanatomy.info



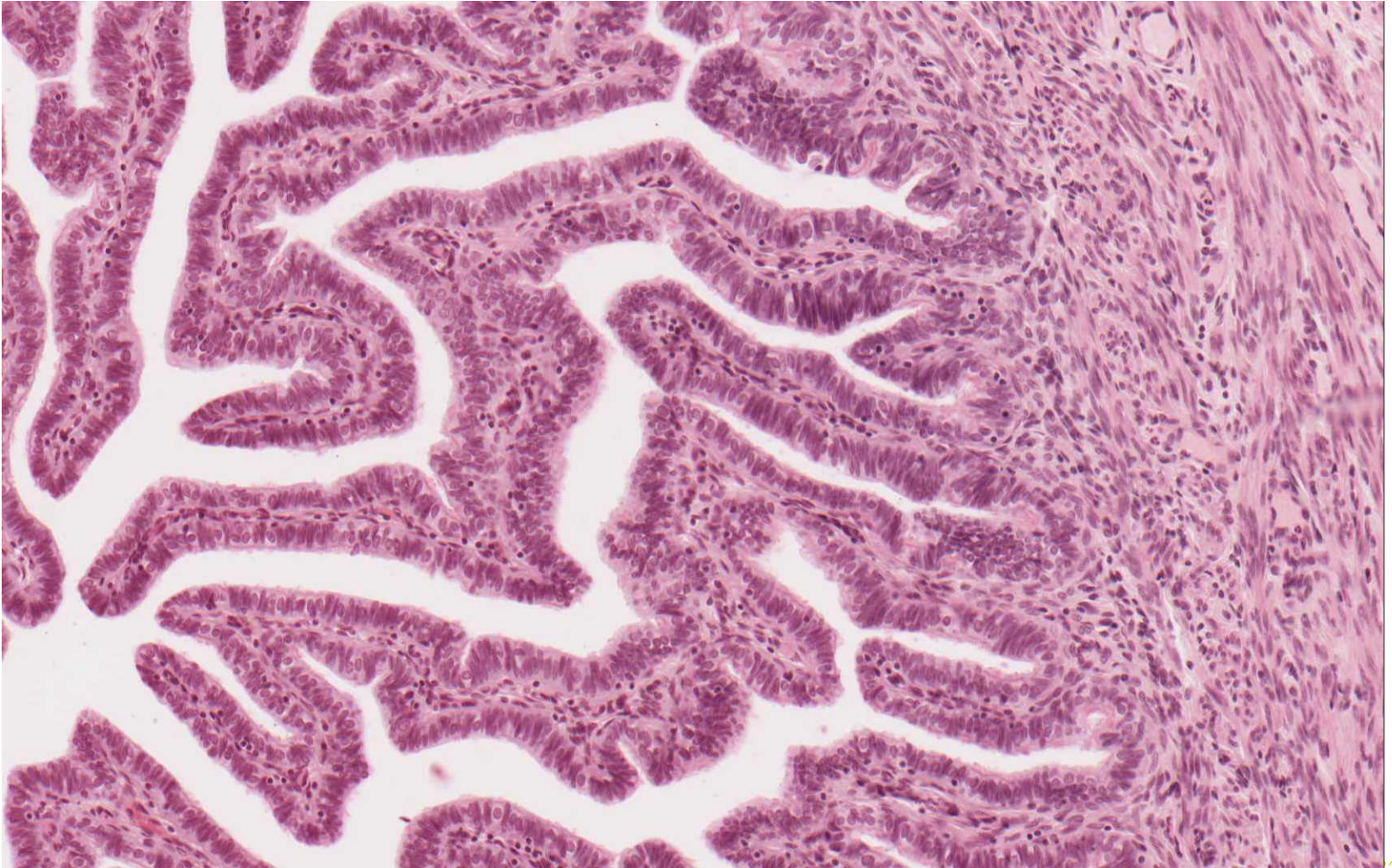
University of Leeds Histology, histology.leeds.ac.uk

Oviduct - Ampulla

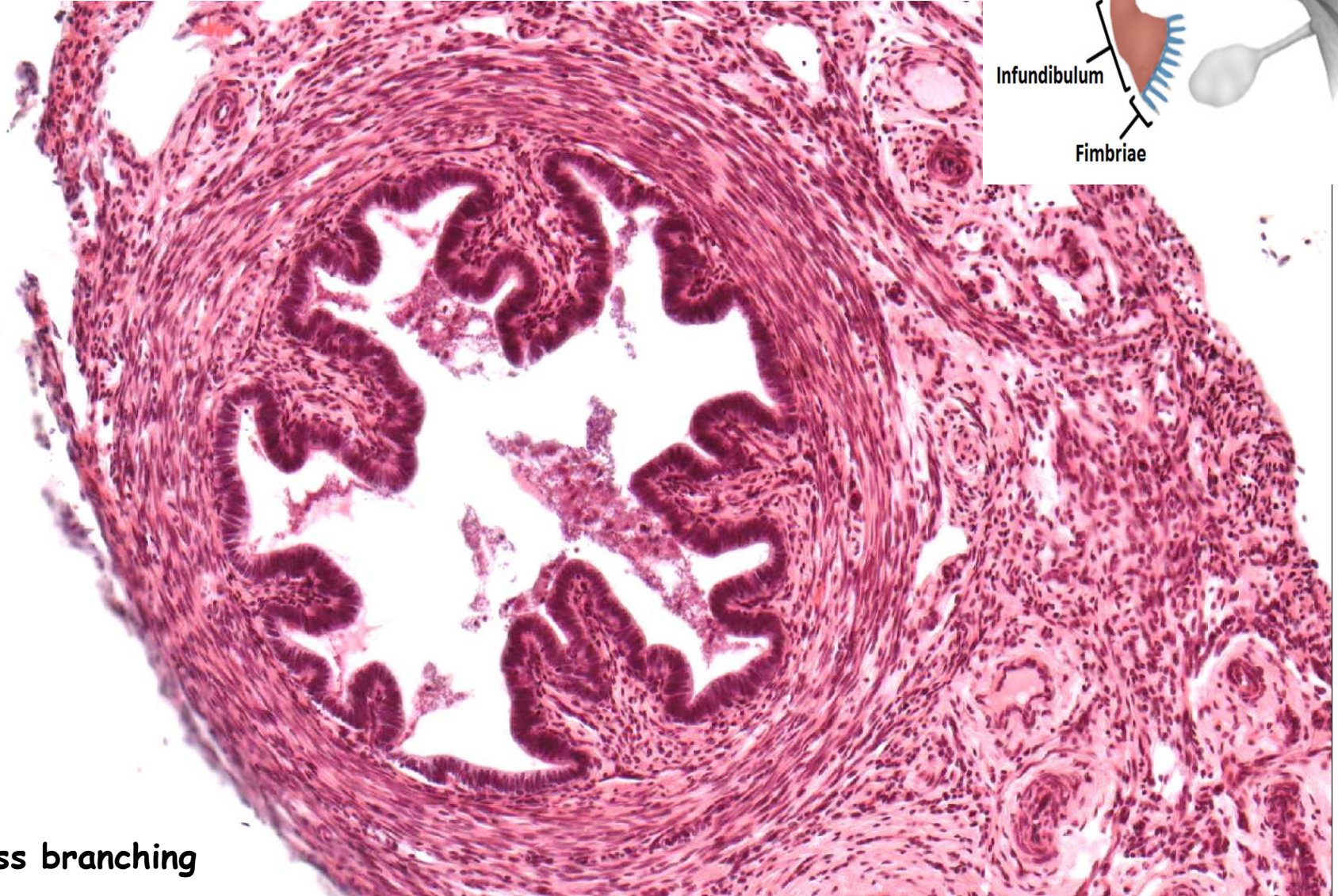
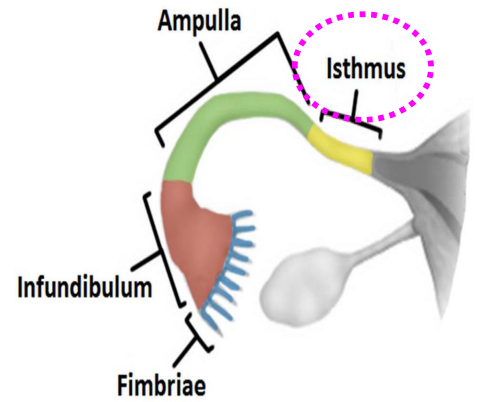


- highly branched mucosa
- longitudinal folds
- labyrinth

Oviduct - Ampulla

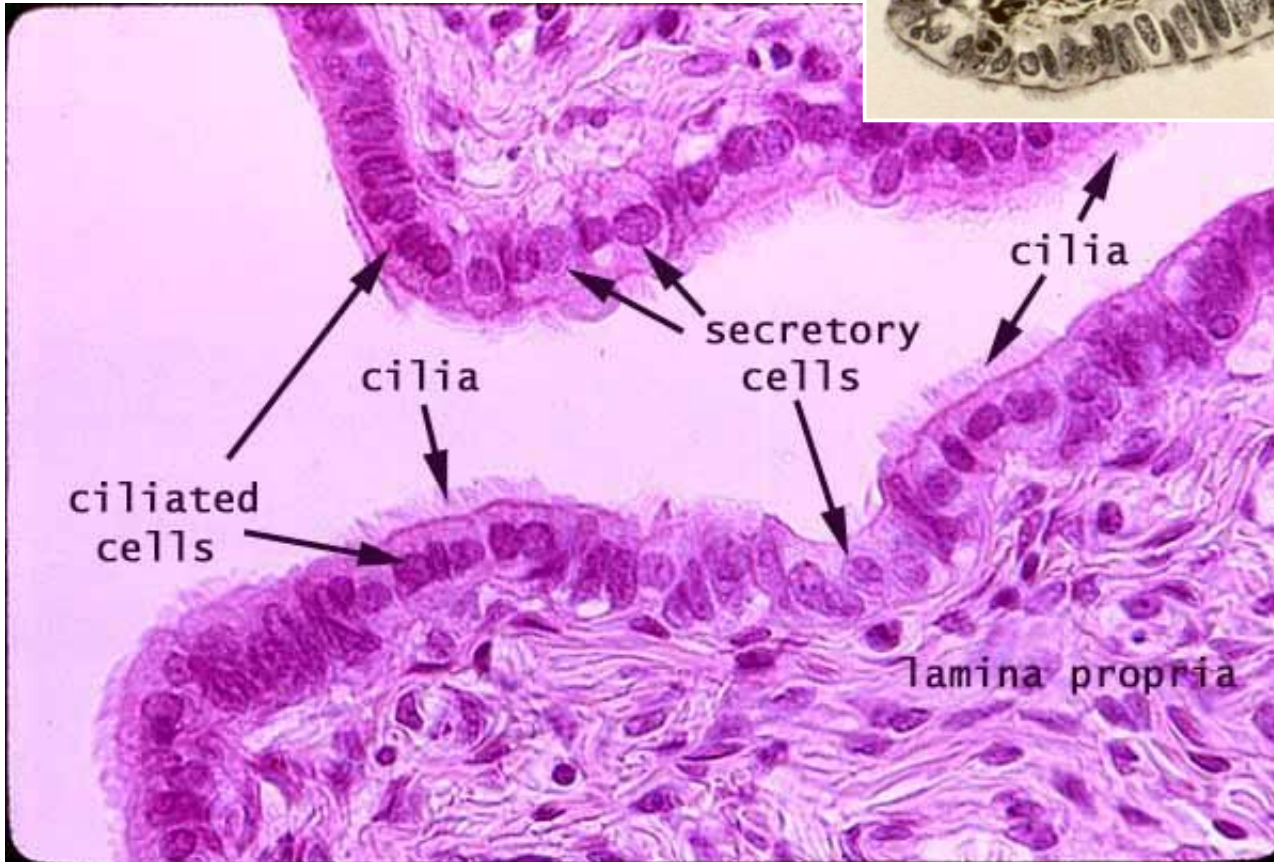


Oviduct - Isthmus



- less branching

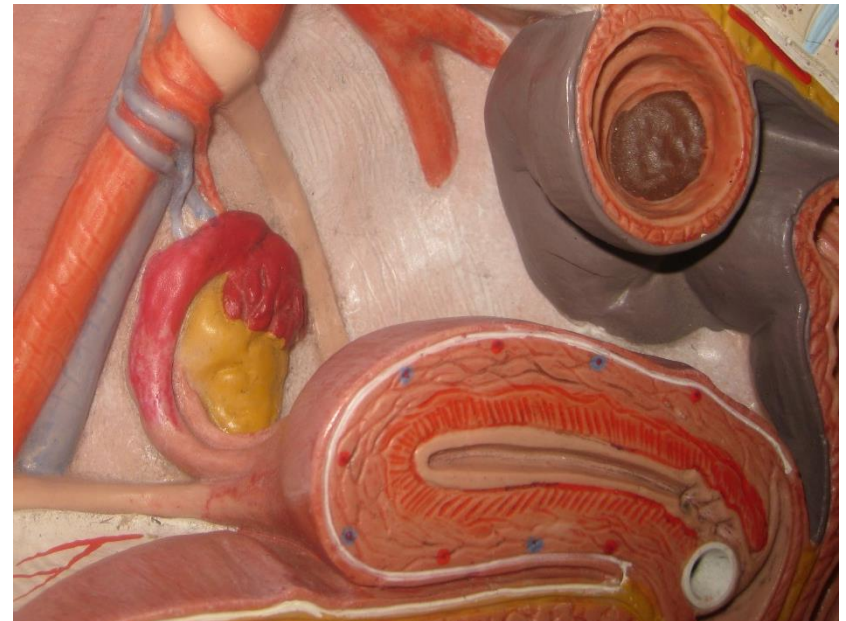
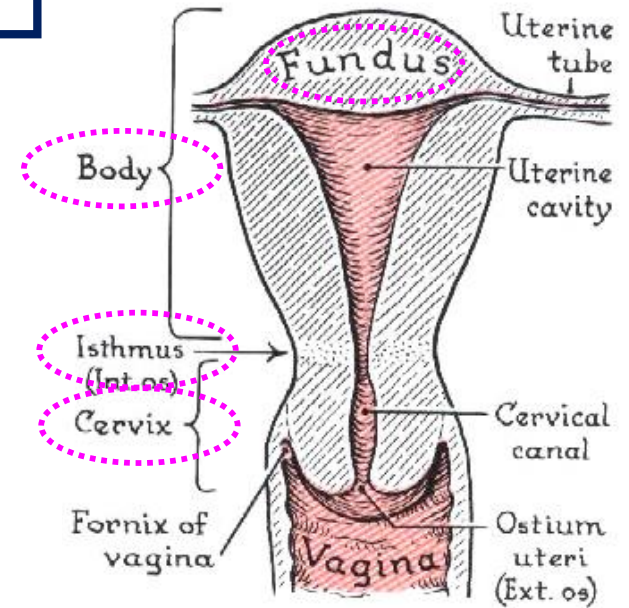
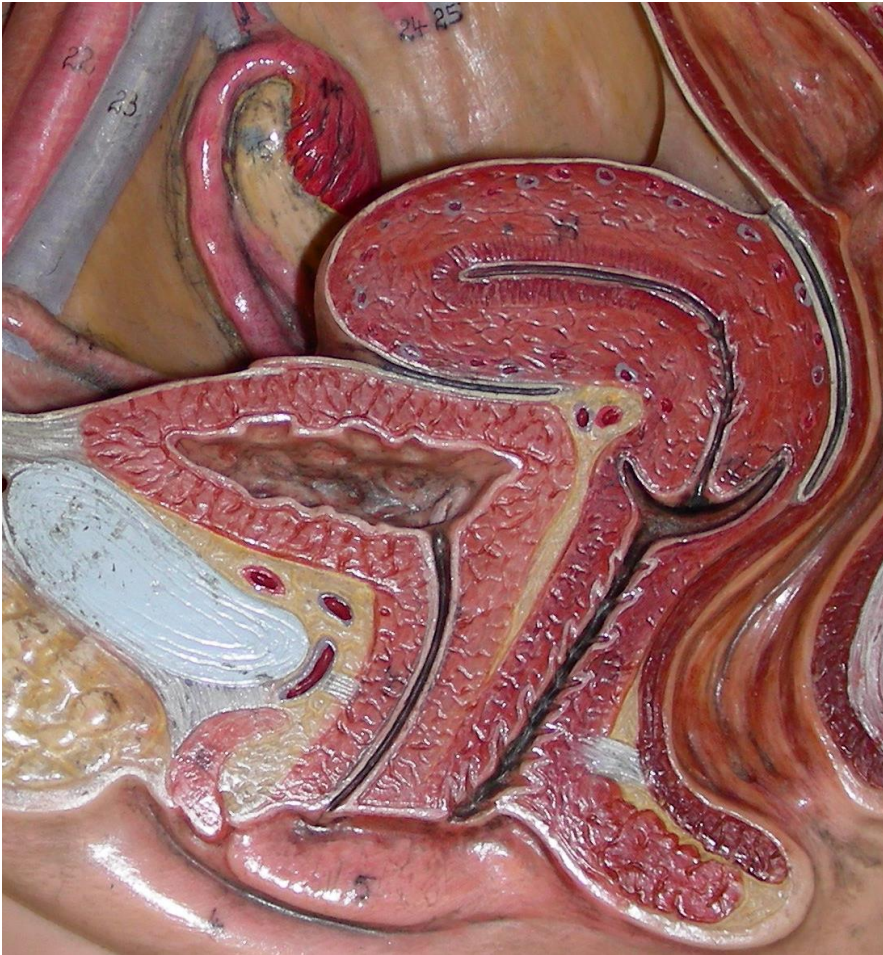Oviduct



Tunica mucosa

- *lamina epithelialis* - simple columnar epithelium
 - 1.) **CILIATED CELLS** - possess many cilia- transport of the ovum and embryo
 - 2.) **SECRETORY CELLS (PEG)** - secrete a nutrient rich medium
- *lamina propria* - loose connective tissue (is richly vascularized!)

Uterus 1

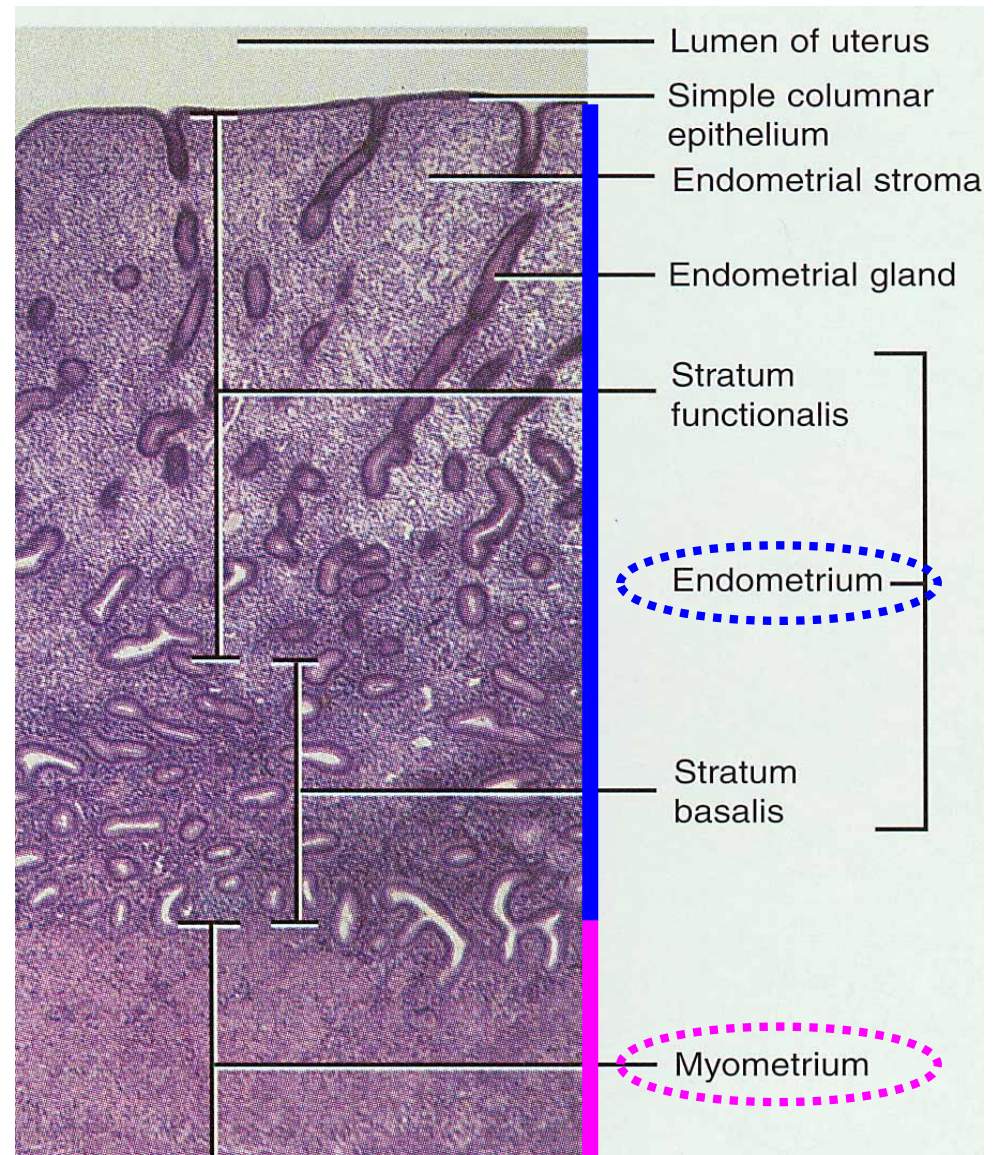


- **Mechanical protection and nutritional support to developing embryo**
- **Bends anteriorly (anteflexion)**
- **Stabilized by broad, uterosacral, round, and lateral ligaments**

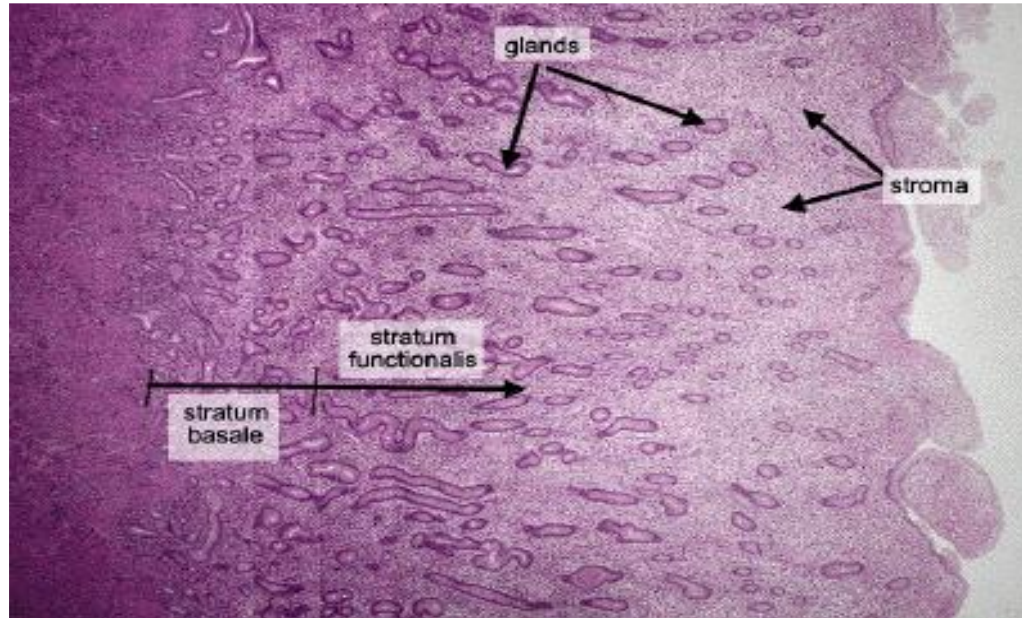
Uterus 2

Uterine wall ~ 1.5 - 2 cm

1. Endometrium - *T. Mucosa*
2. Myometrium - *T. muscularis*
3. Perimetrium - *T. Serosa*



Uterus - Endometrium 1



Dartmouth Medical School, Virtual Histology
<http://www.dartmouth.edu/~anatomy/Histo>

- consists of *lamina epithelialis* and *lamina propria*
- epithelial lining - simple columnar epithelium containing secretory and ciliated cells
- lamina propria - loose connective tissue with many stellate fibroblasts, contains abundant amorphous ground substance → uterine glands - simple tubular glands (covered by simple columnar epithelial cells)

1. Stratum functionalis (~ 5 mm)

- exhibit dramatic changes during menstrual cycle every month (hormone-driven)
- shed during menstruation !

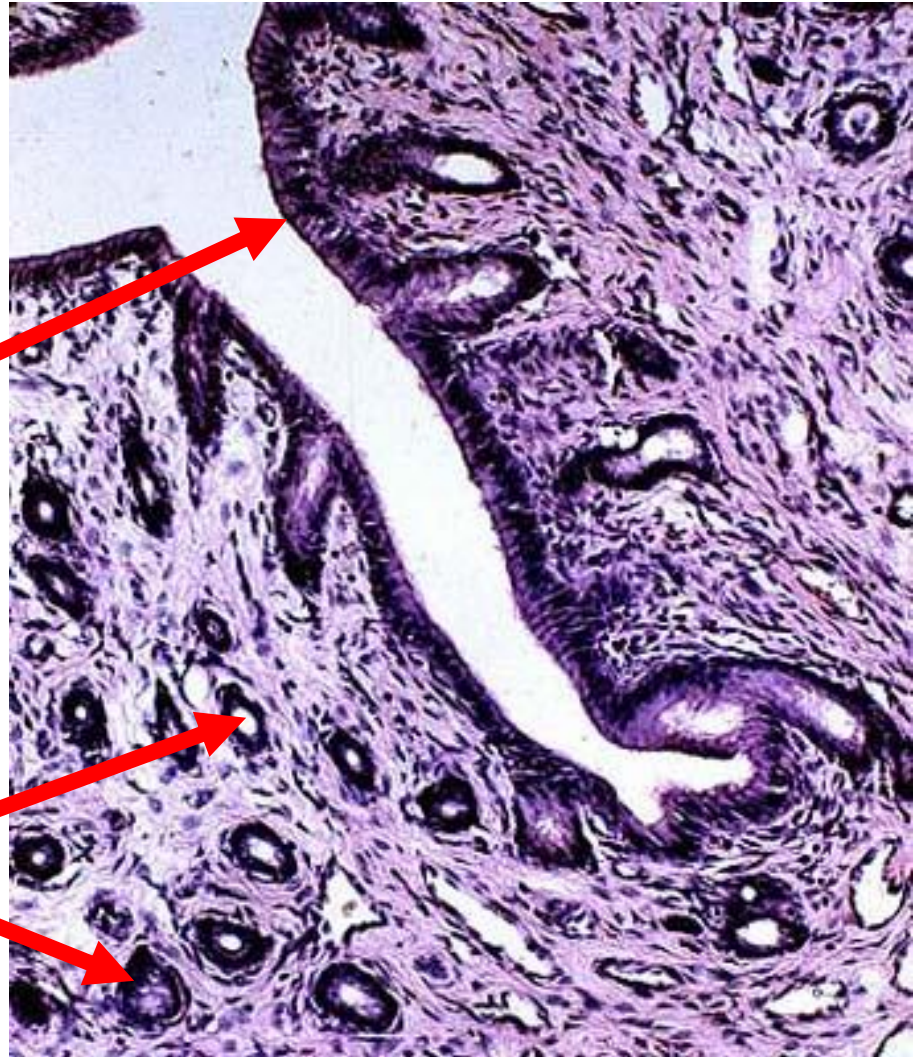2. Stratum basale (~ 1 mm)

- undergoes little changes during the menstrual cycle
- not shed during menstruation !
- provides a new epithelium and lamina propria for the renewal of the endometrium!

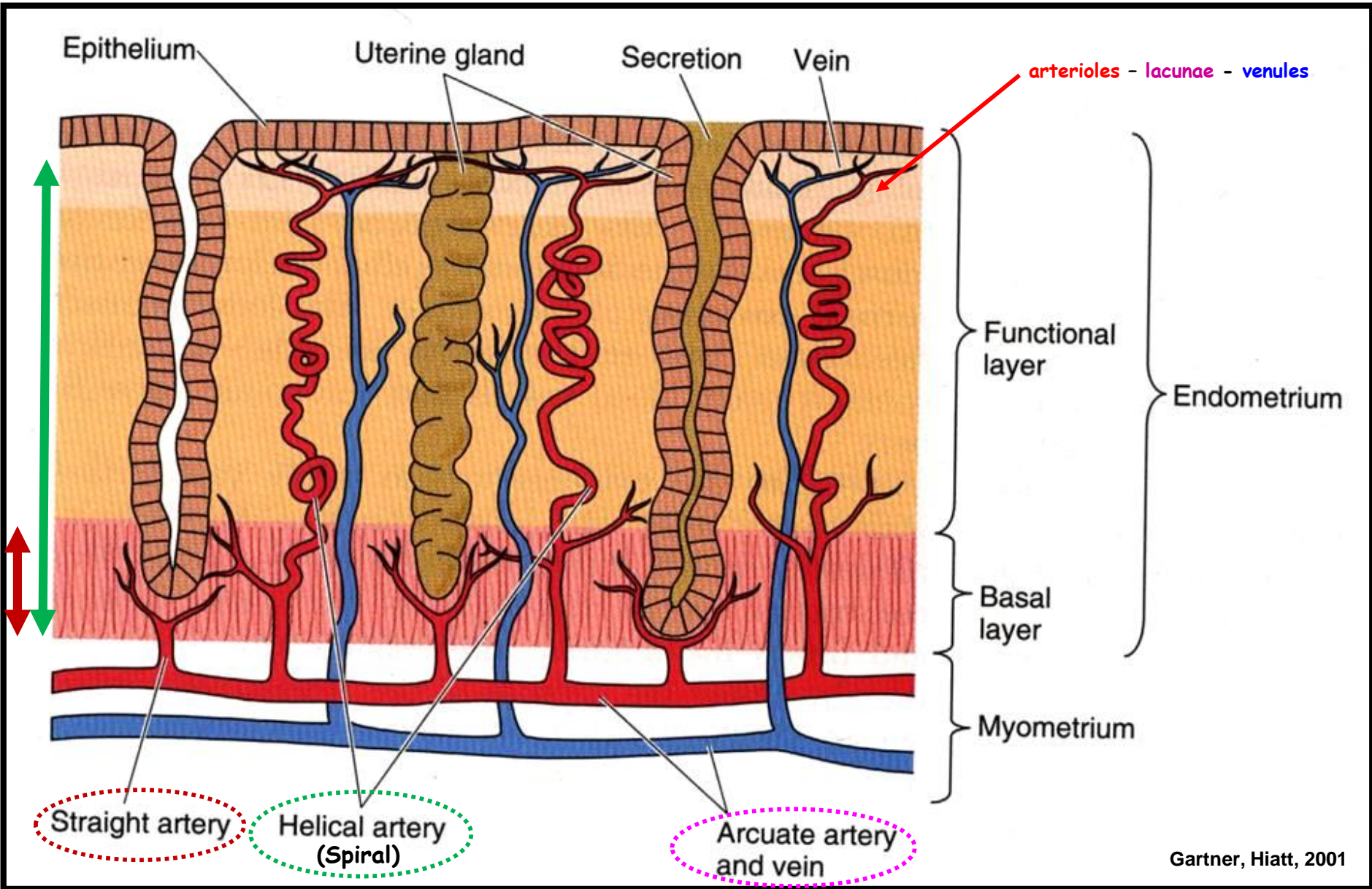
Uterus - Endometrium 2

Simple
columnar
epithelium

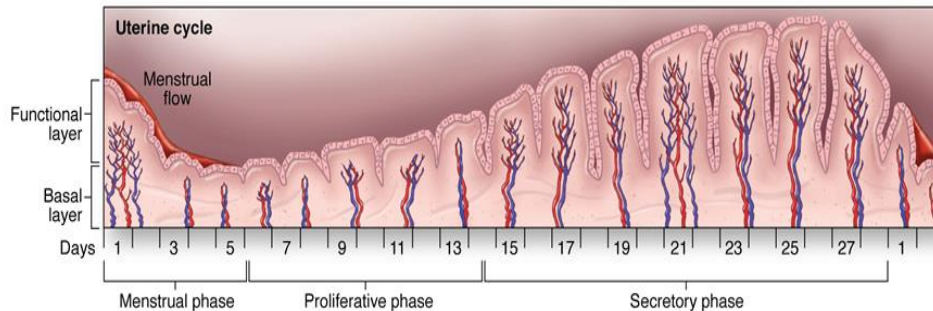
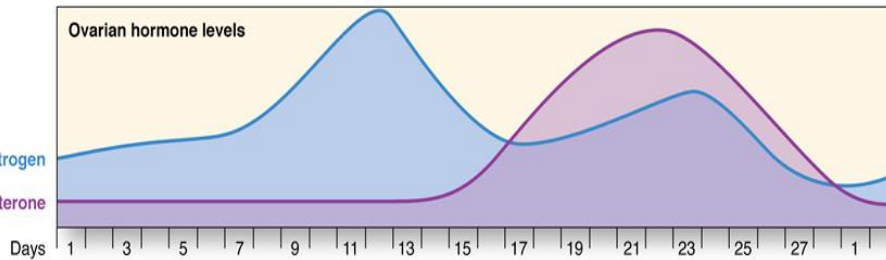
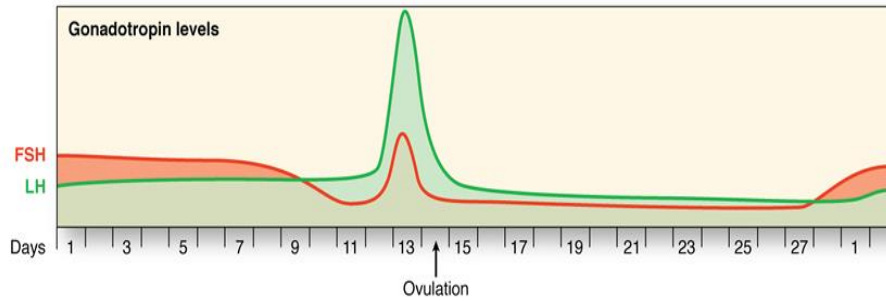
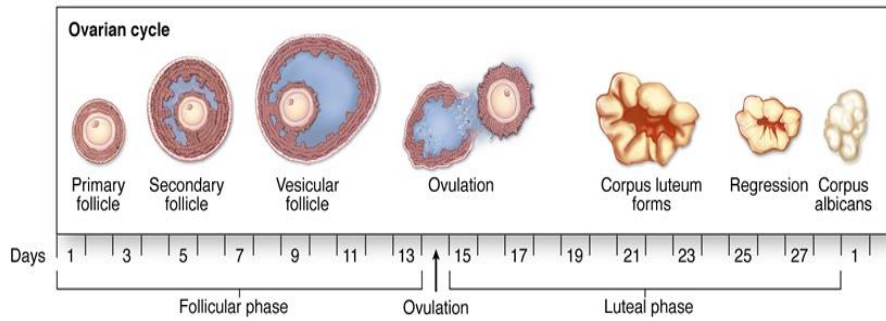
Endometrial
glands



Uterus - Endometrium - Blood supply



Uterus - Menstrual cycle (28 days)



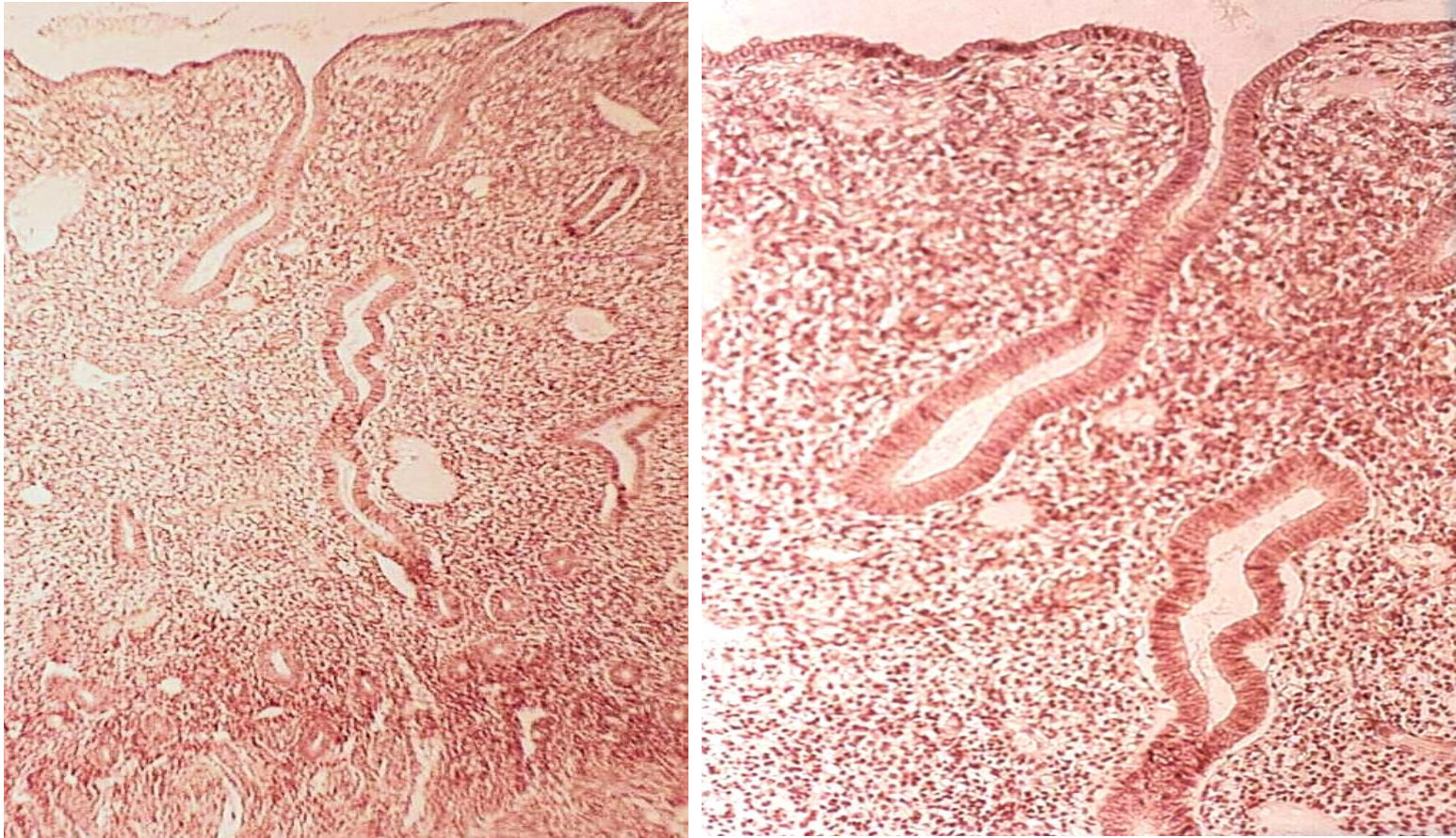
Menstrual phase (days 1 - 4)

Proliferative phase (days 5 - 15)
(driven by estrogens)

Secretory phase (days 16 - 27)
(driven by progesterone)

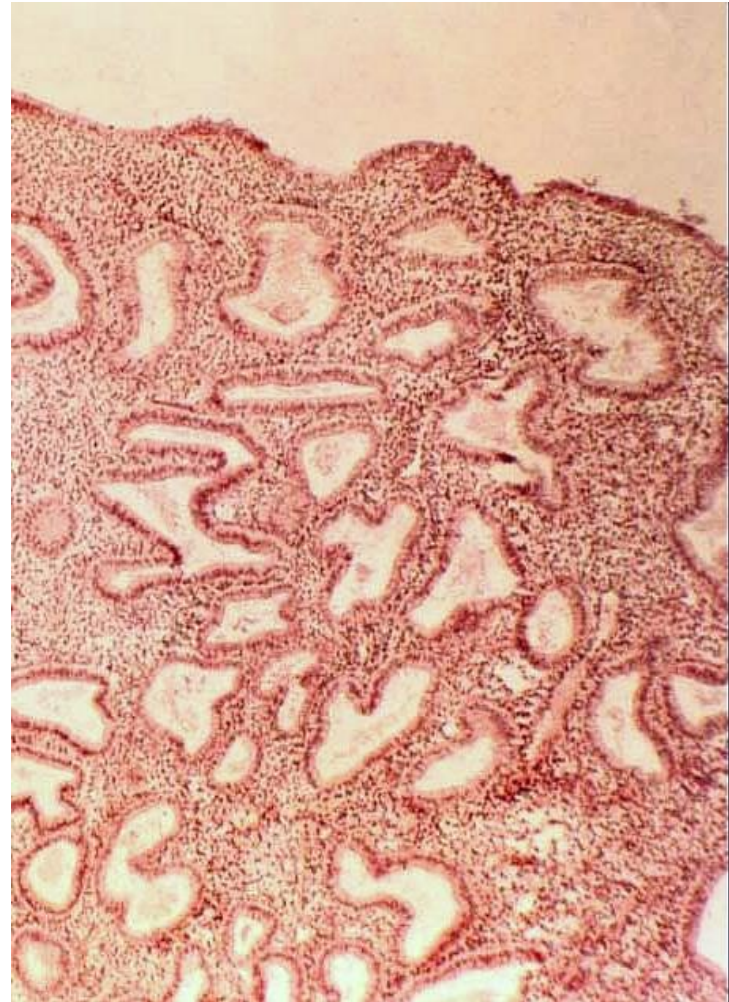
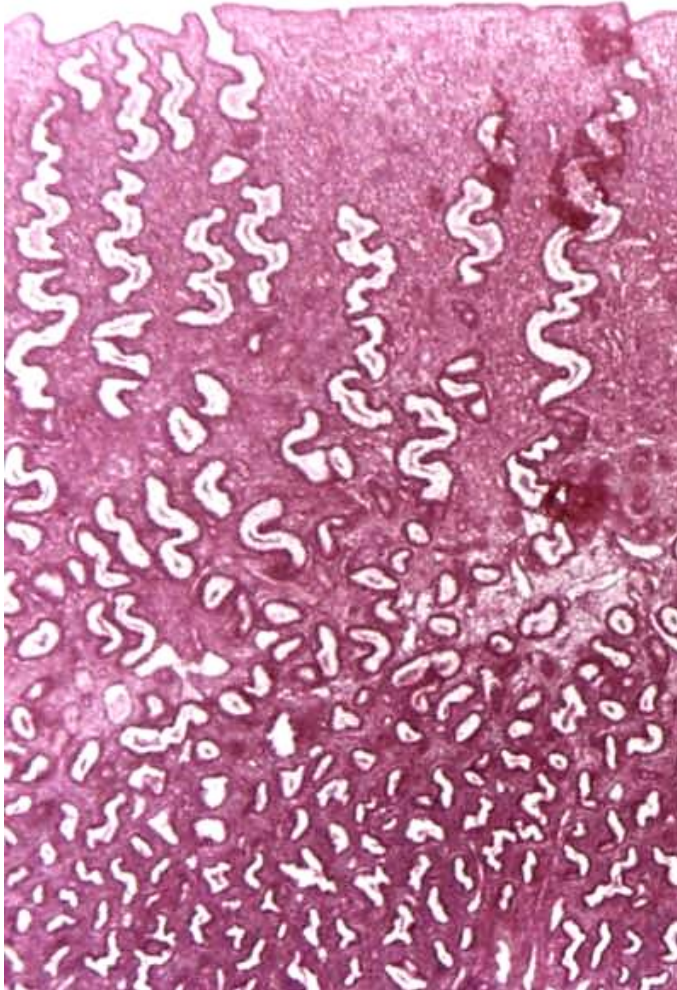
Ischemic phase (day 28)

Endometrium - Proliferative phase



- rising estrogen from the developing follicles
- the stratum basalis is regrowing the stratum functionalis - new glands form
- **long and straight uterine glands which are not yet functional**

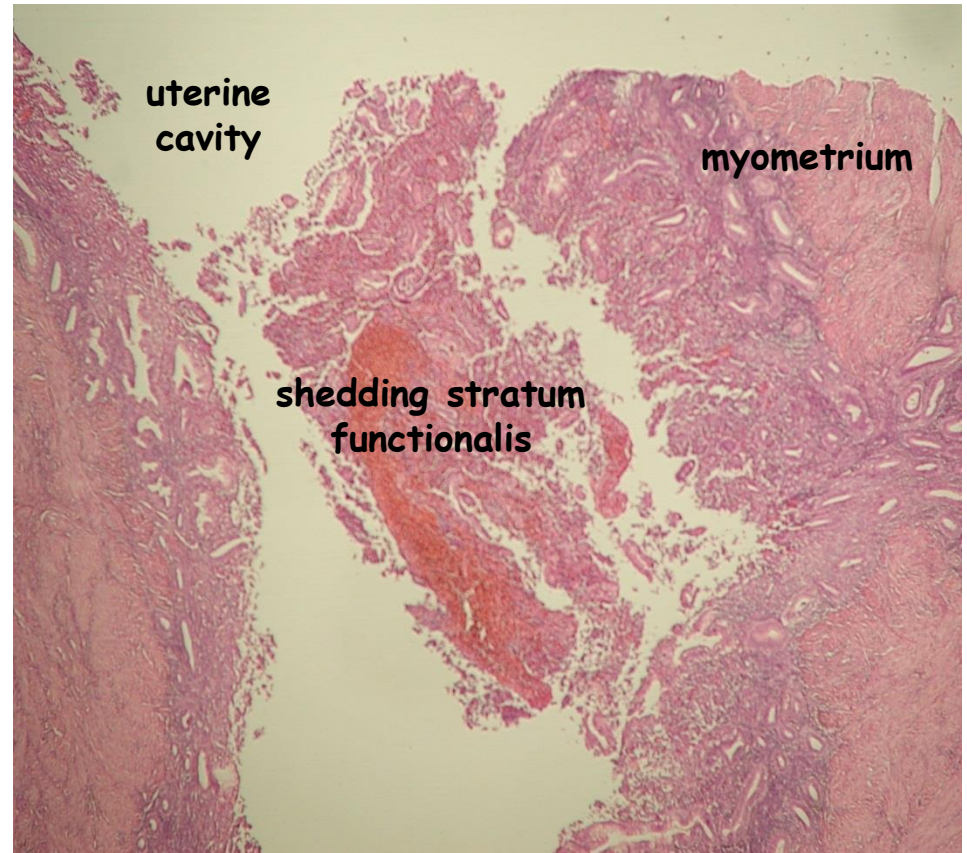
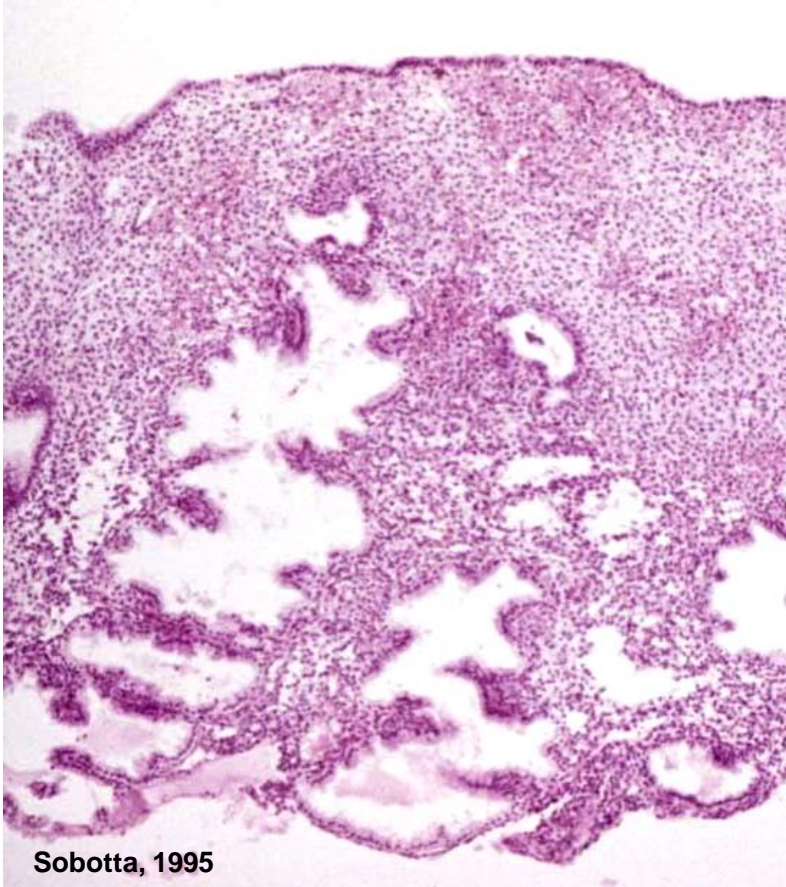
Endometrium - Secretory phase



Sobotta, 1995

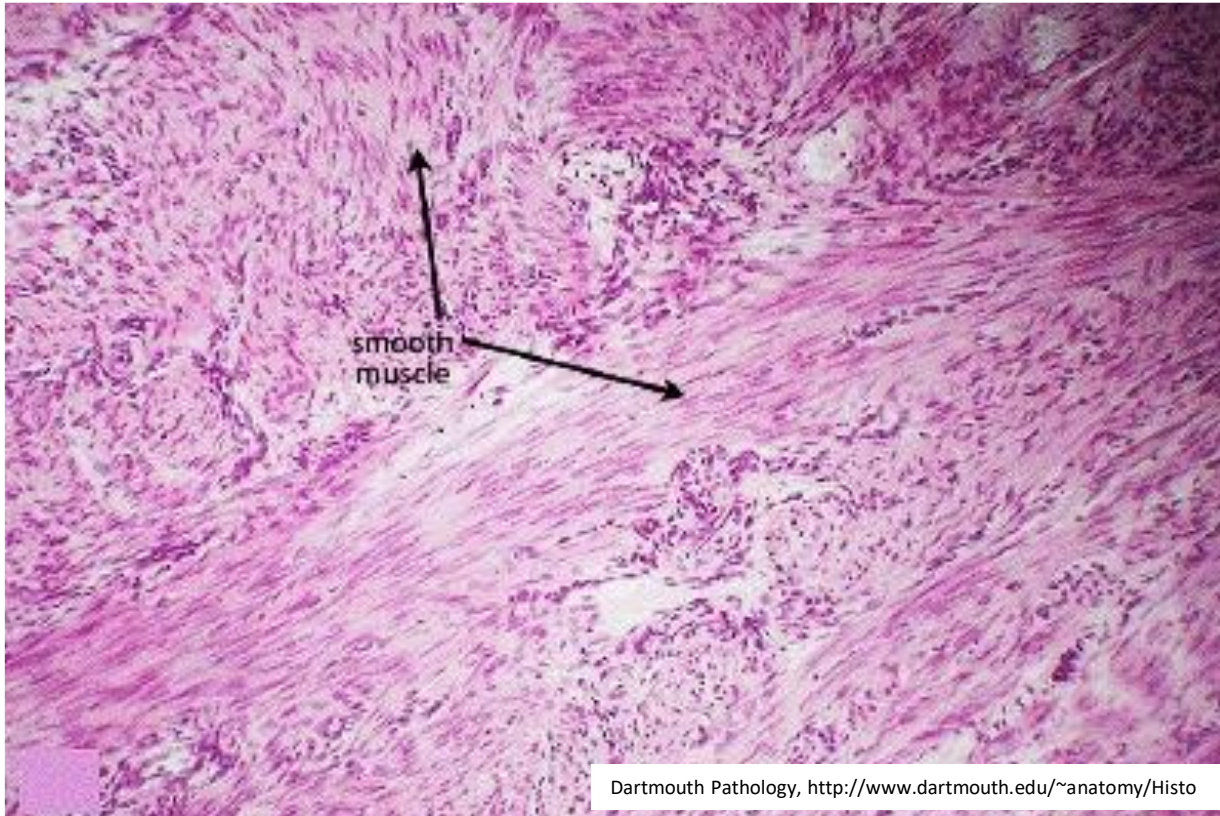
- under the control of estrogen and progesterone from the corpus luteum
- the uterine glands of the stratum functionalis begin to function, producing glycogen
- **the curvy and dilated glands and elongated spiral arteries**

Endometrium - Menstrual phase



- lack of estrogen and progesterone from the dead corpus luteum
- the stratum functionalis dies and loses its anatomical integrity, breaking loose and shedding from the stratum basalis

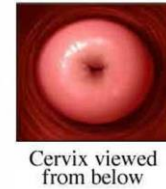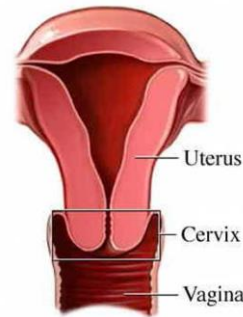
Uterus - Myometrium



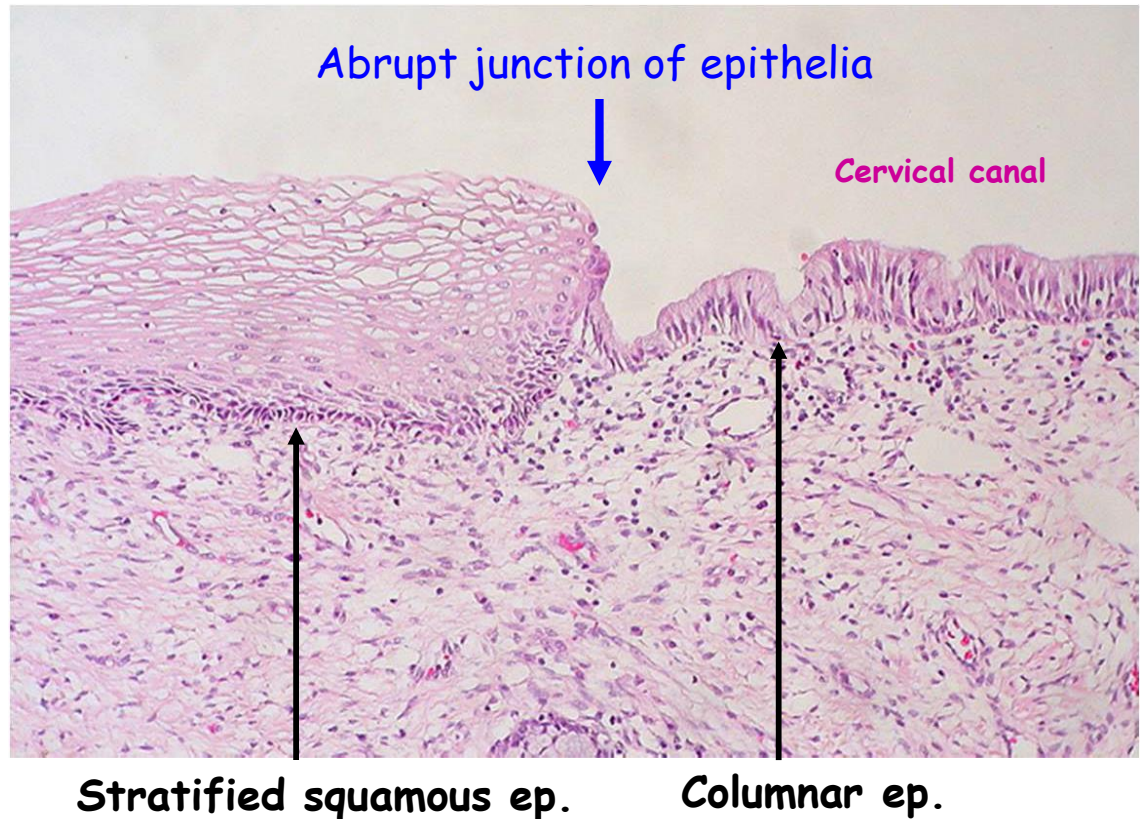
- **three interwoven layers** of smooth muscle
- during pregnancy - smooth muscle cell **hyperplasia + hypertrophy**
- contract in response to oxytocin during labor to expel the fetus from the uterus

The Cervix + Orificium externum uteri

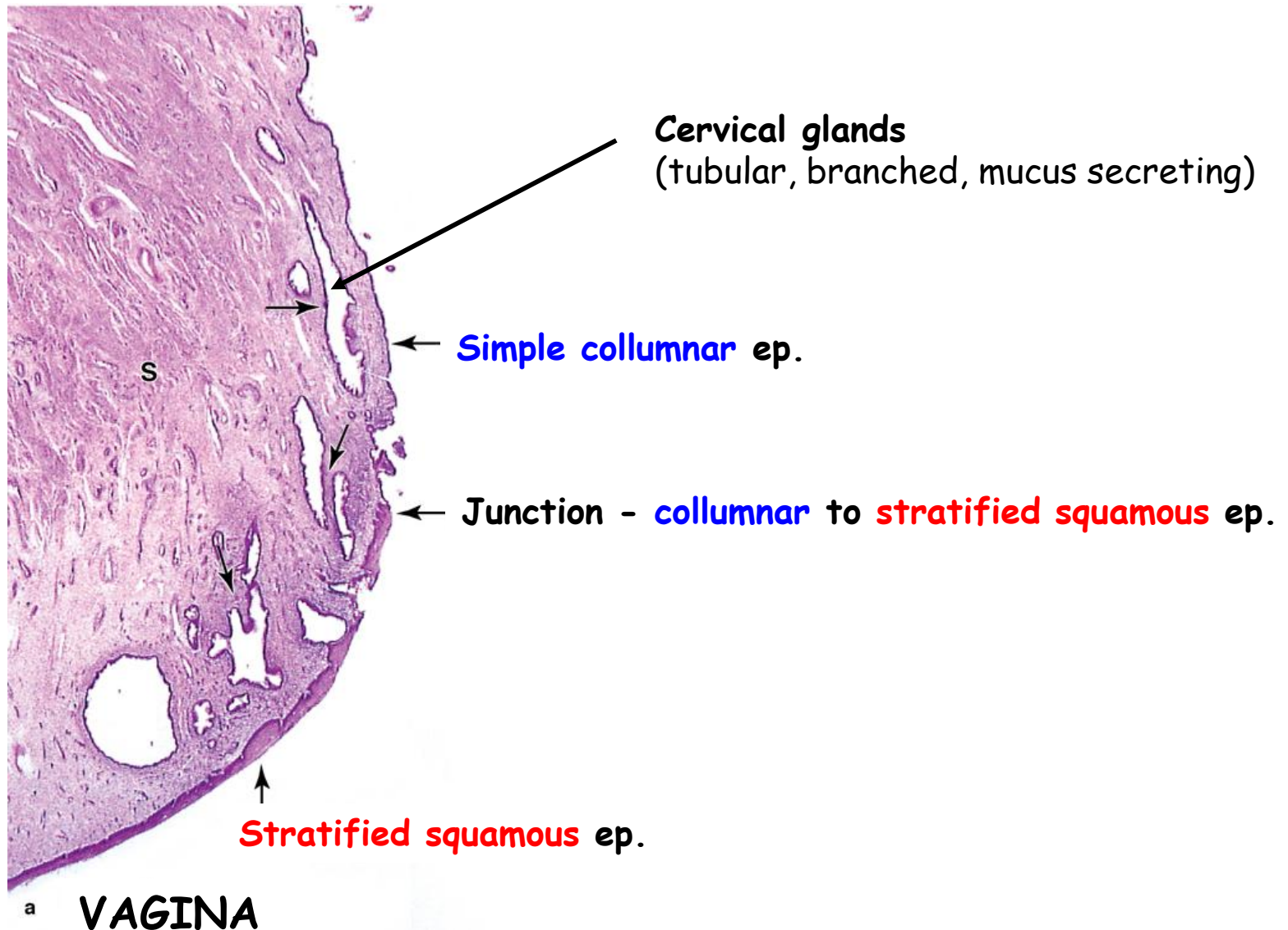
- 2-3 cm in length
- **cylindrical** shape
- cervical canal connects lumen of uterus to lumen of vagina
- numerous **mucous glands**
- changes thickness throughout ovulation cycle
- important for pregnancy and childbirth
- contributes to **capacitation**



uvahealth.com



The Cervix

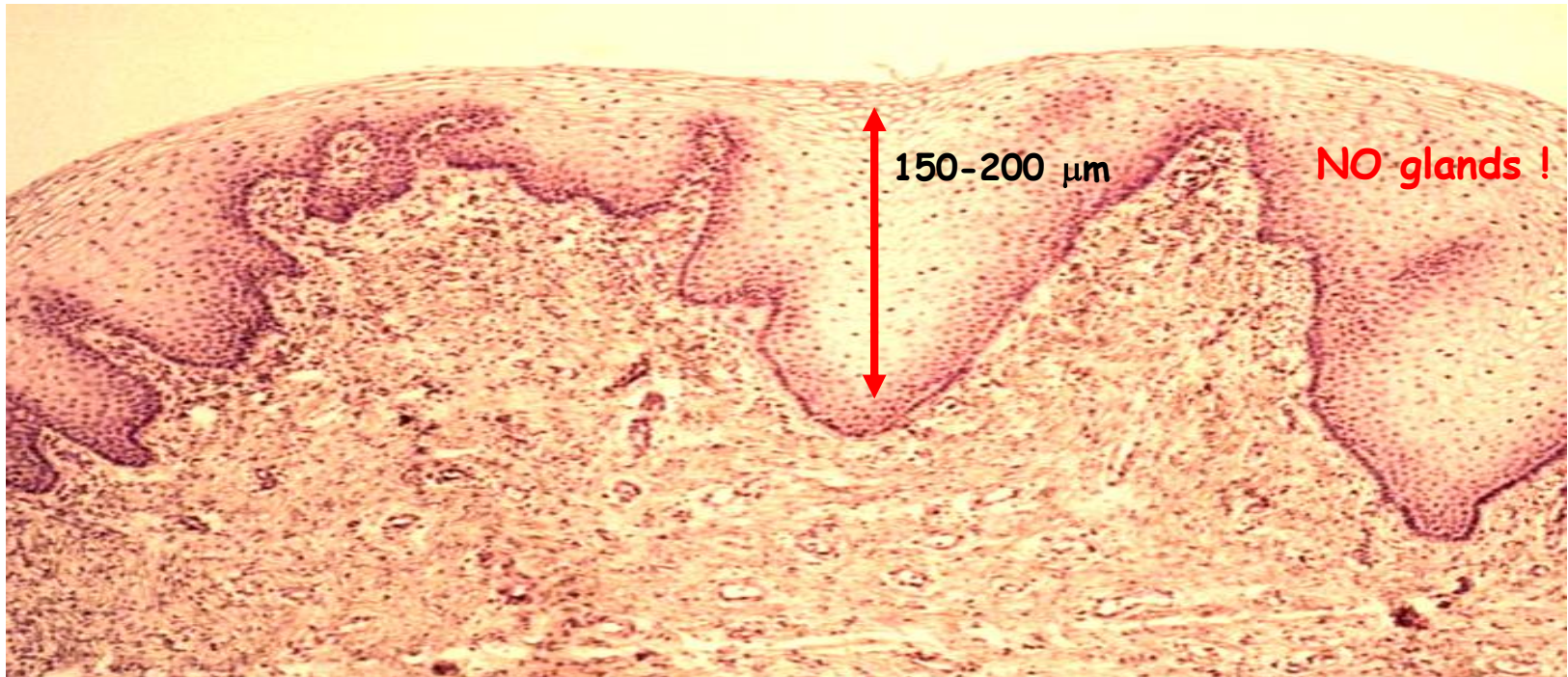


Vagina 1

- receives sperm during copulation
- serves as birth canal

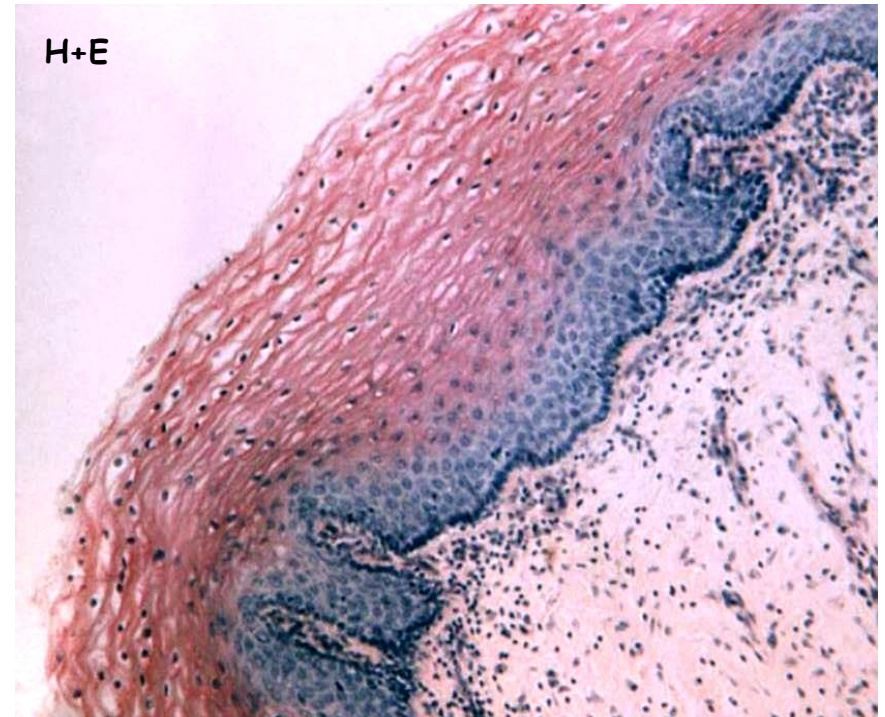
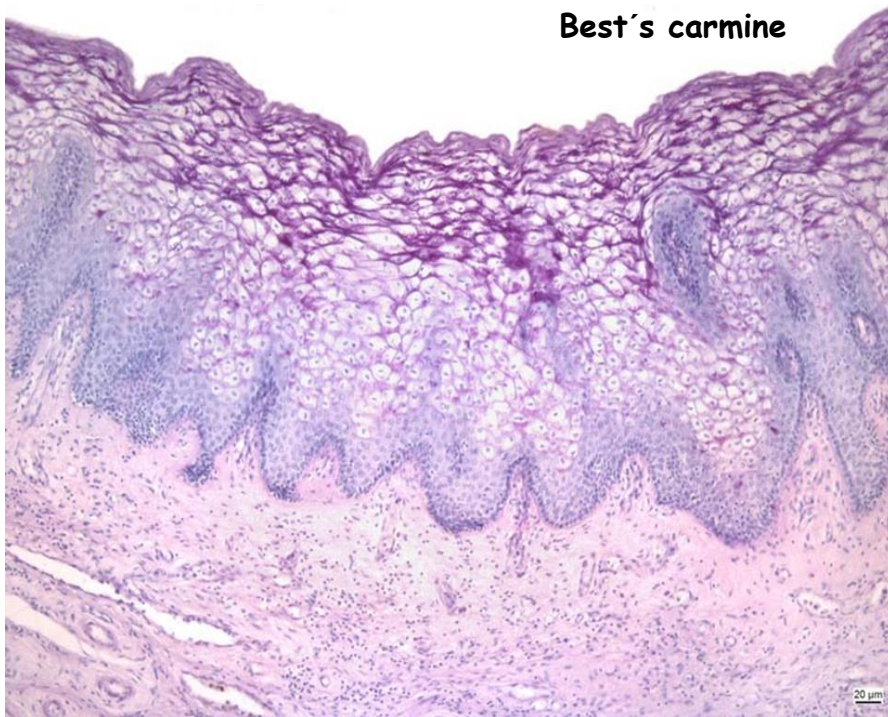3 tissue layers

- a) mucosal layer - inner layer; **non-keratinizing stratified squamous**
- b) muscular layer - middle layer; **smooth muscle in two layers**
- c) adventitia - outer layer; areolar connective tissue



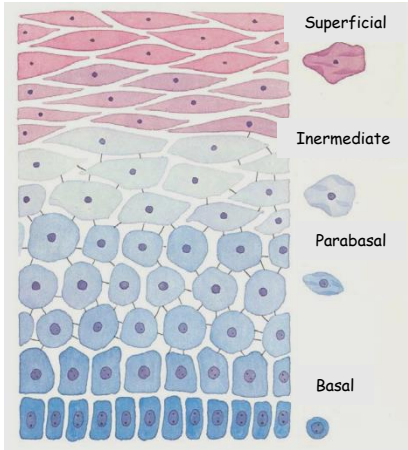
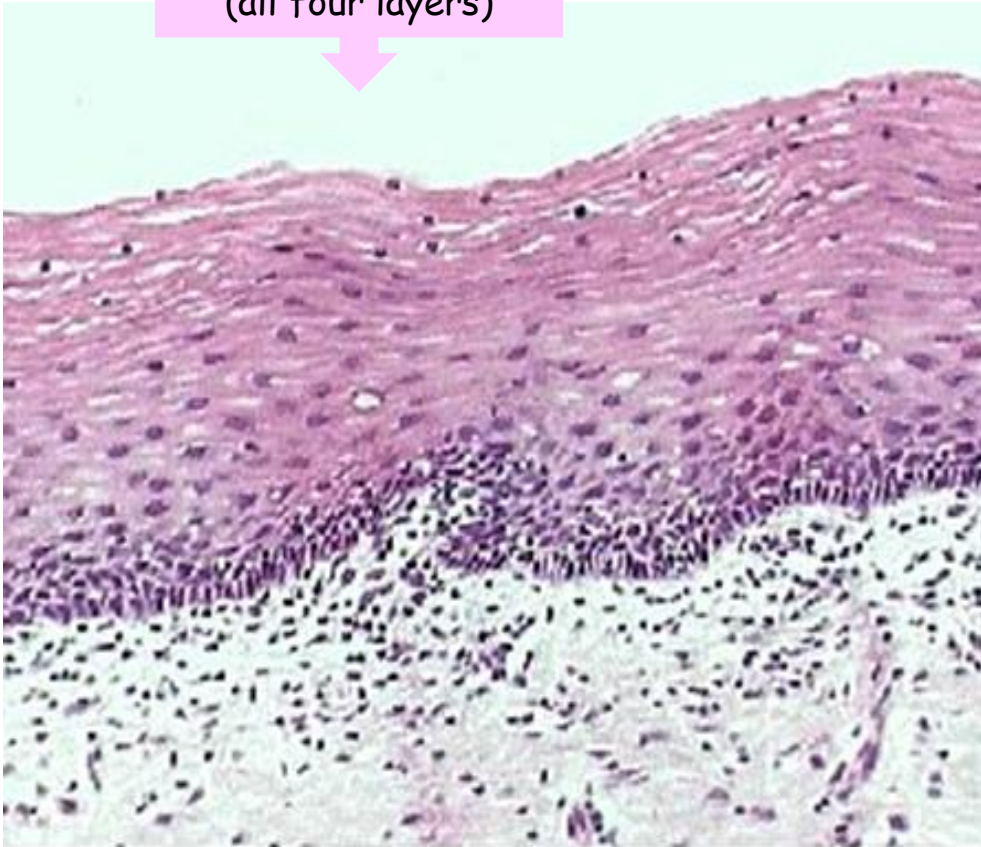
Vagina 2

Epithelial cells synthesize and accumulate **glycogen** (upon stimulation by estrogens)



Vagina 3

Preovulatory state
(all four layers)



Released after ovulation

- glycogen
- Lactobacillus
- acidification

Cervical smear - Giemsa staining

1 Contain glycogen

2

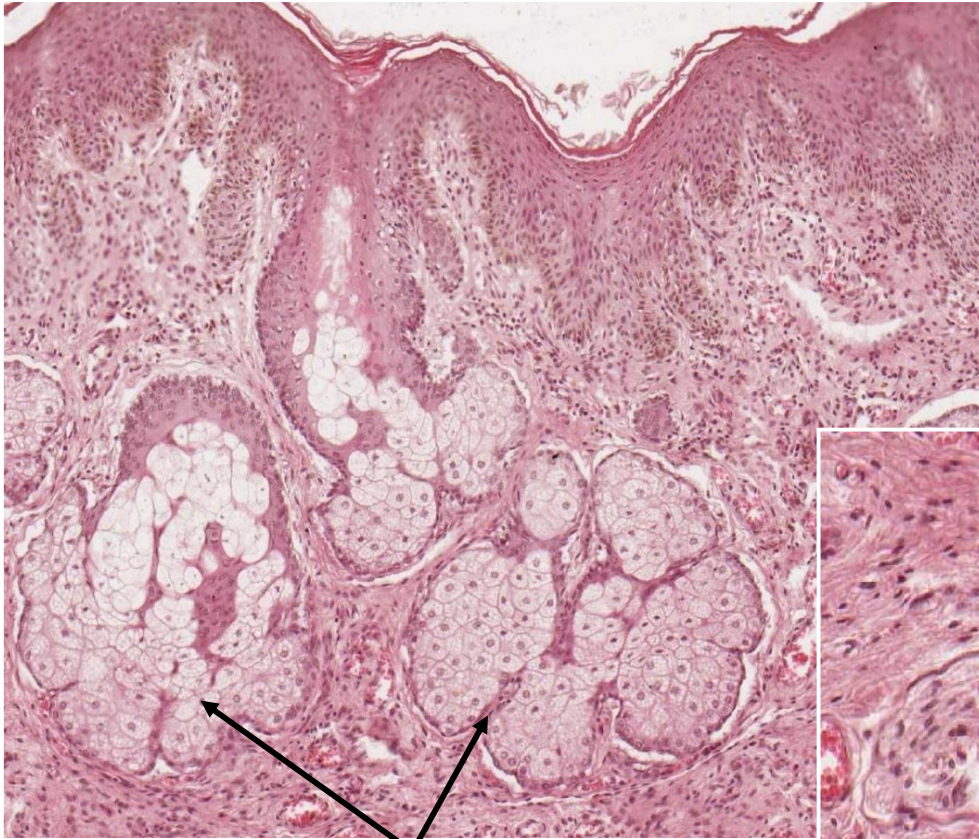
3

4

5

Labia minora

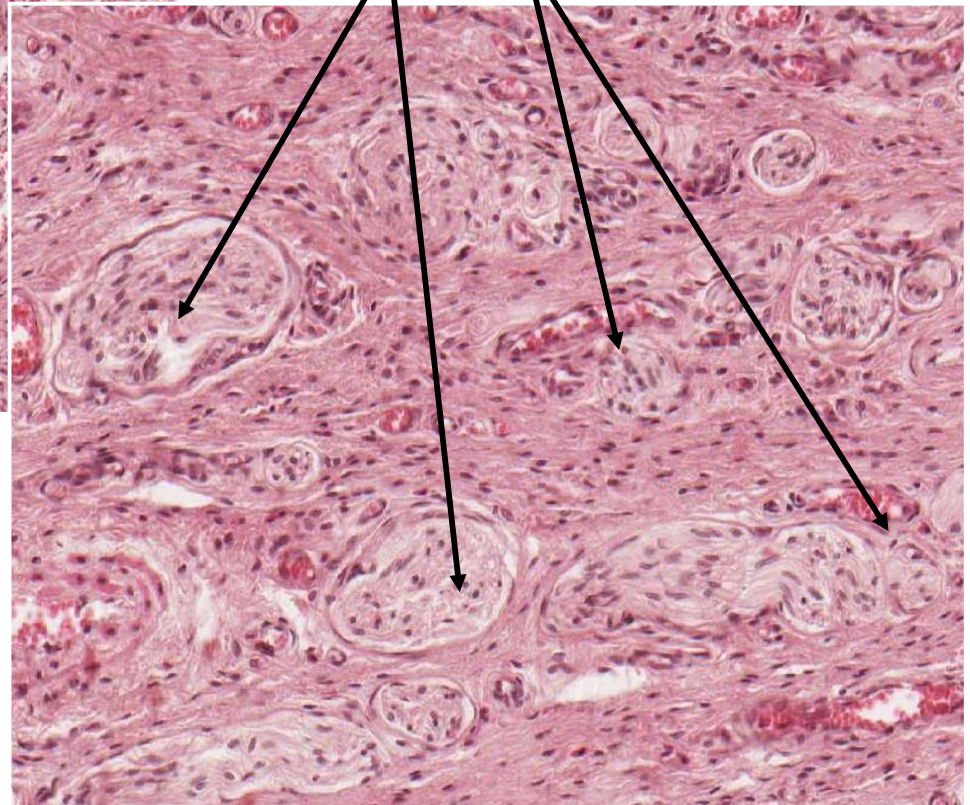
Covered by hairless skin



Sebaceous glands

Nerves

Veins



Placenta 1

Temporary organ

Functions

- 1) **transport** (water, oxygen, carbon dioxide, nutrients, antibodies, drugs, waste, ...)
- 2) **metabolism** (synthesis of glycogen, cholesterol, fatty acids)
- 3) **hormonal production**

steroids: progesteron, estrogen - maintenance of pregnancy

peptides: human chorionic gonadotropin, human placentar lactogen, relaxin, leptin, growth factors)

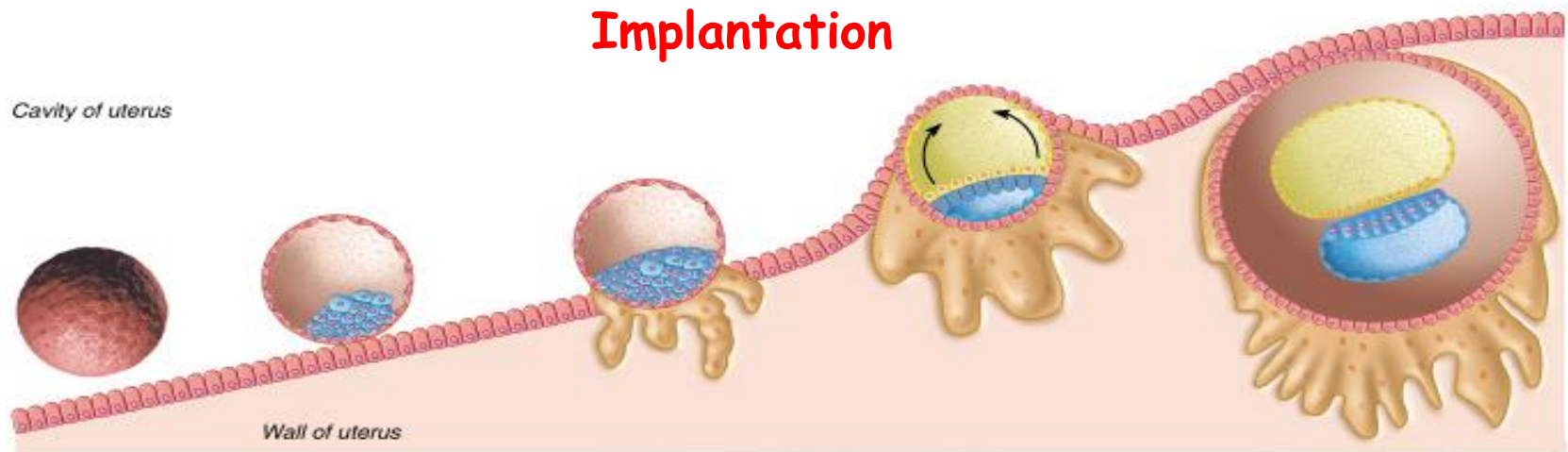
(a) Day 5

(b) Day 6

(c) Day 7

(d) Day 9

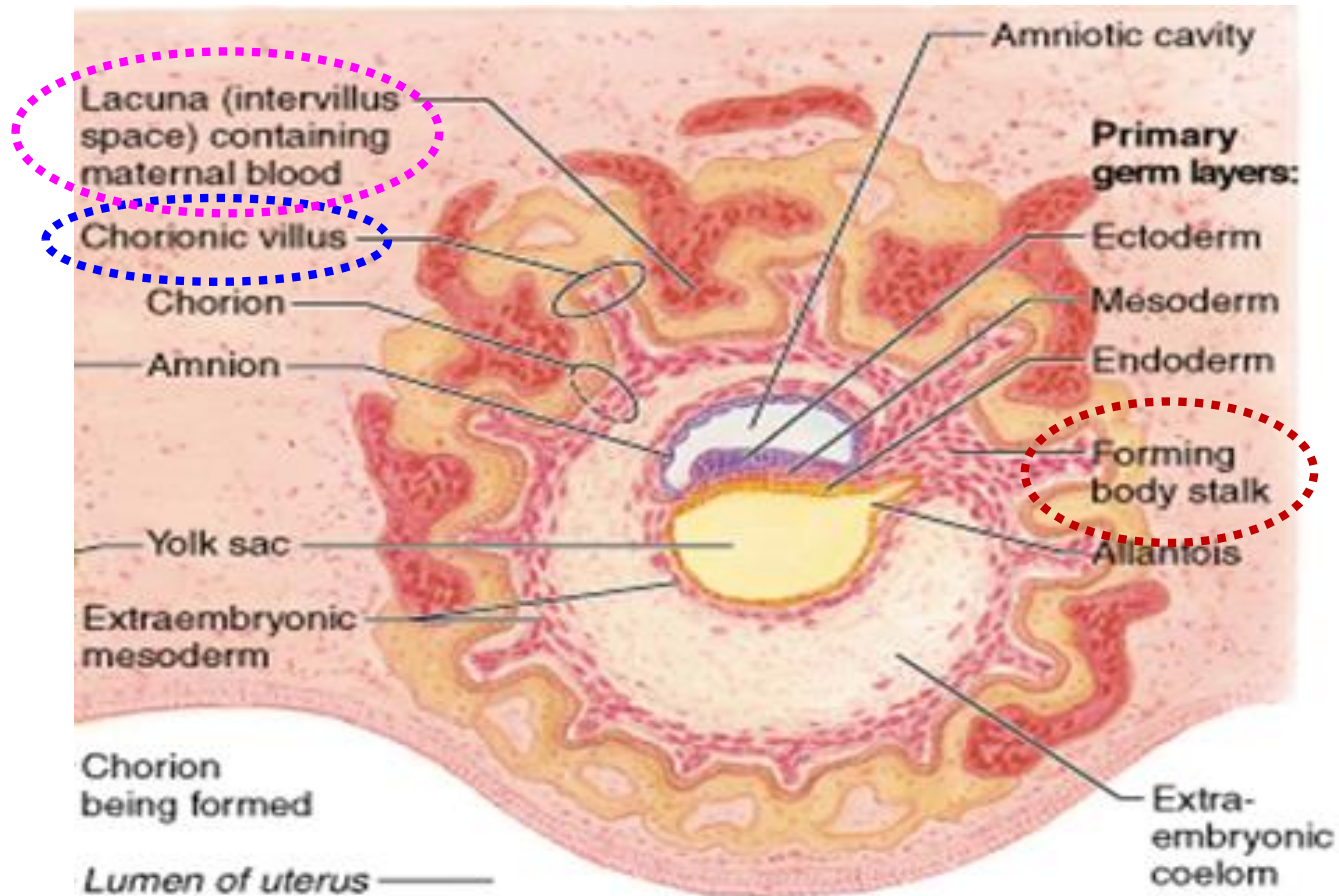
(e) Day 11



Copyright © Pearson Education, Inc., publishing as Benjamin Cummings.

Syncytiotrophoblast invades the surrounding stroma

Placenta 2



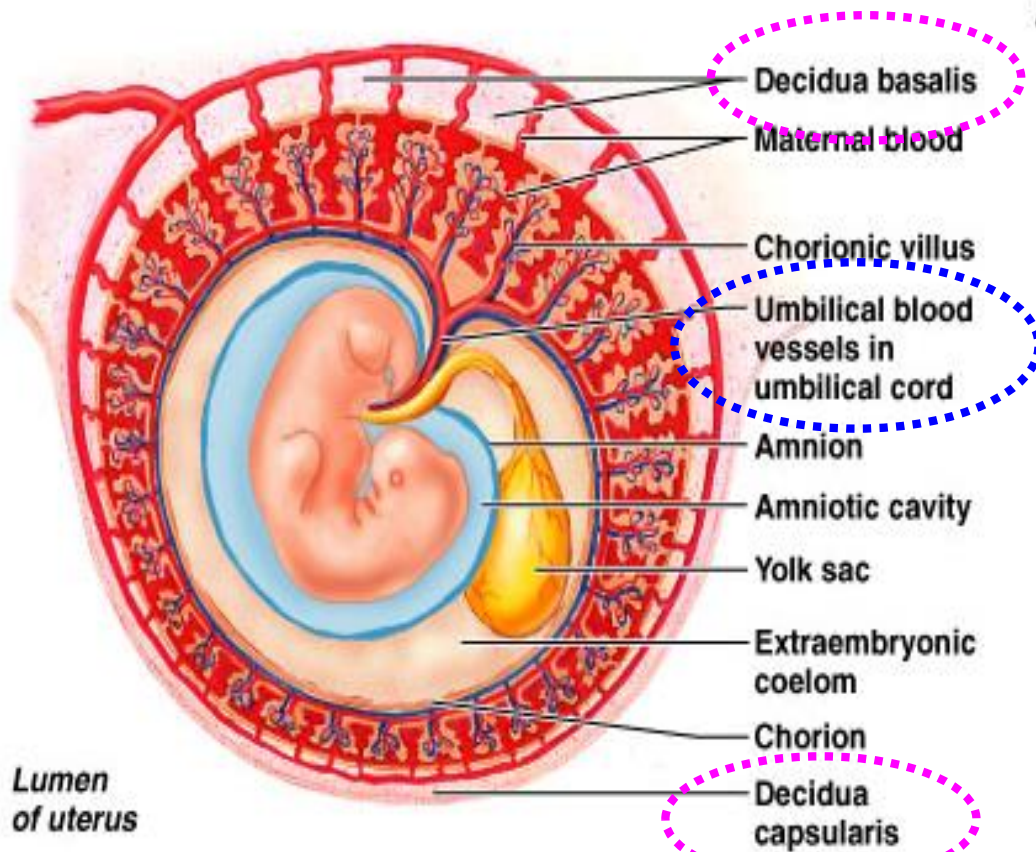
(c) 16-day embryo

Chorionic villi - finger like projection of embryonic tissue that come in contact with bleeding endometrium

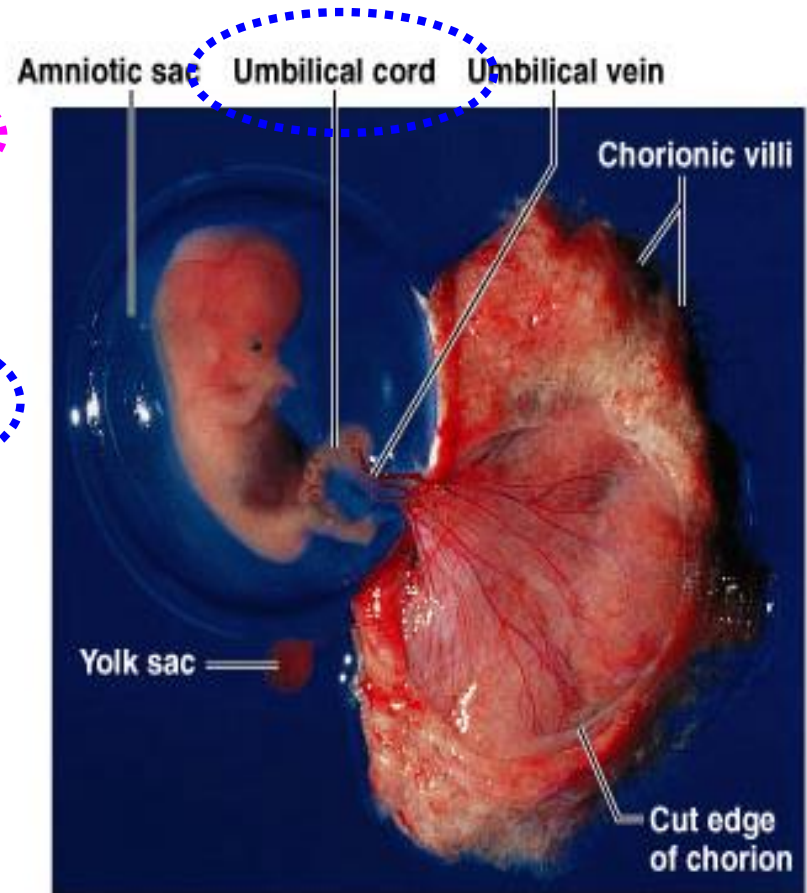
Decidual cells - fibroblast of endometrium (large, cuboidal, very active proteosynthesis)

Placenta - thick disk made by decidua and chorionic villi (formed at the start of month 4)

Placenta 3



(d) 4½-week embryo



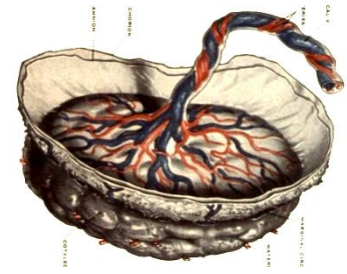
(e) 7-week embryo

Decidua basalis - between embryo and myometrium

Decidua capsularis - between embryo and the uterine lumen (thins as the embryo grows)

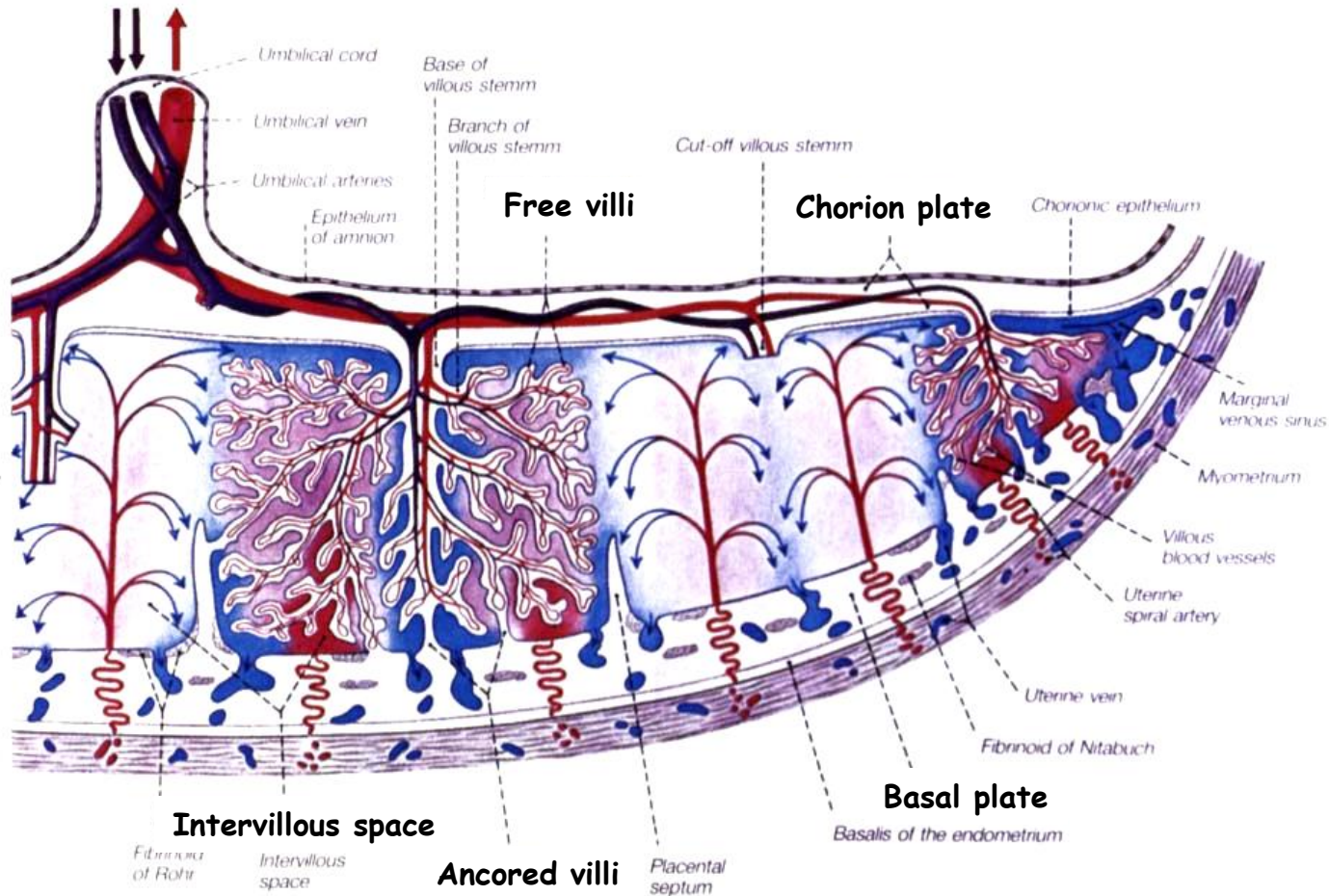
discoid
15 - 20 cm
400 - 600 g

Placenta 4

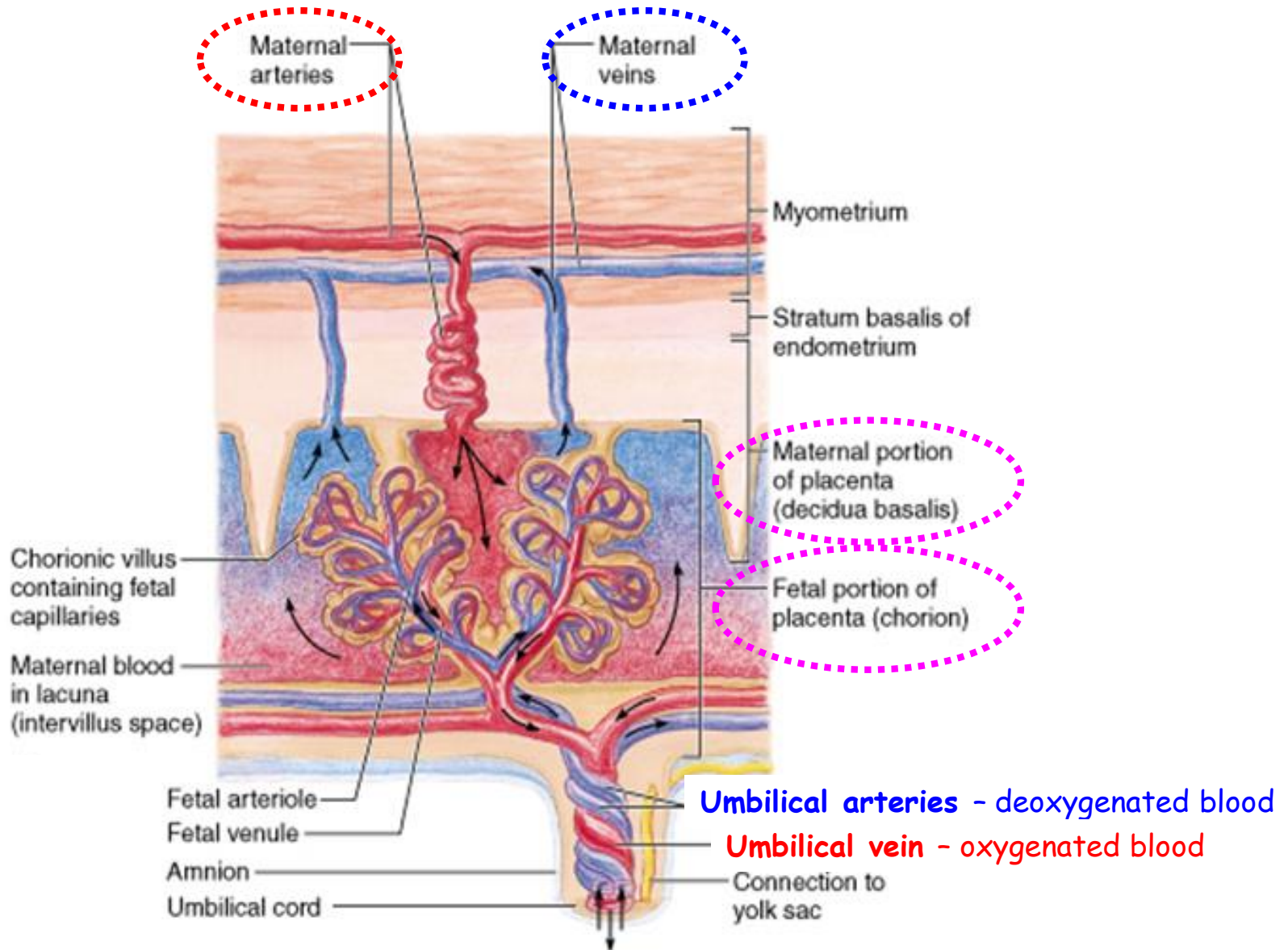


Discoidalis + Hemochorialis

- **pars fetalis** - chorion plate, chorion villi (anchored, free = terminal)
- **pars materna** - decidua basalis
- **intervillous spaces** - develop from lacunes



Placenta 5



Placenta 6

Ambiotic epithelium
(ectoderm)

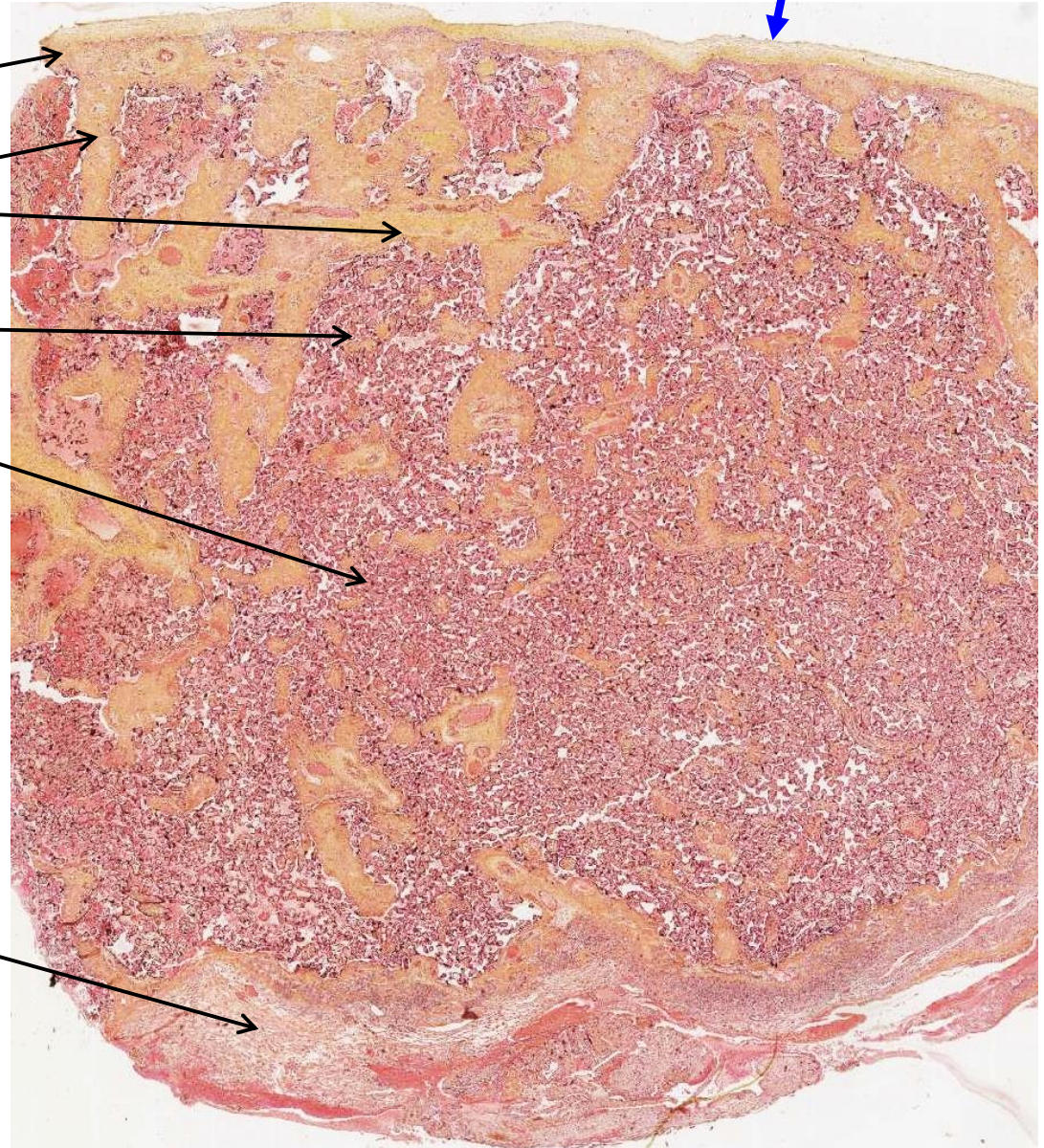
Pars fetalis

Chorion plate

Anchored villi

Free villi

Pars materna

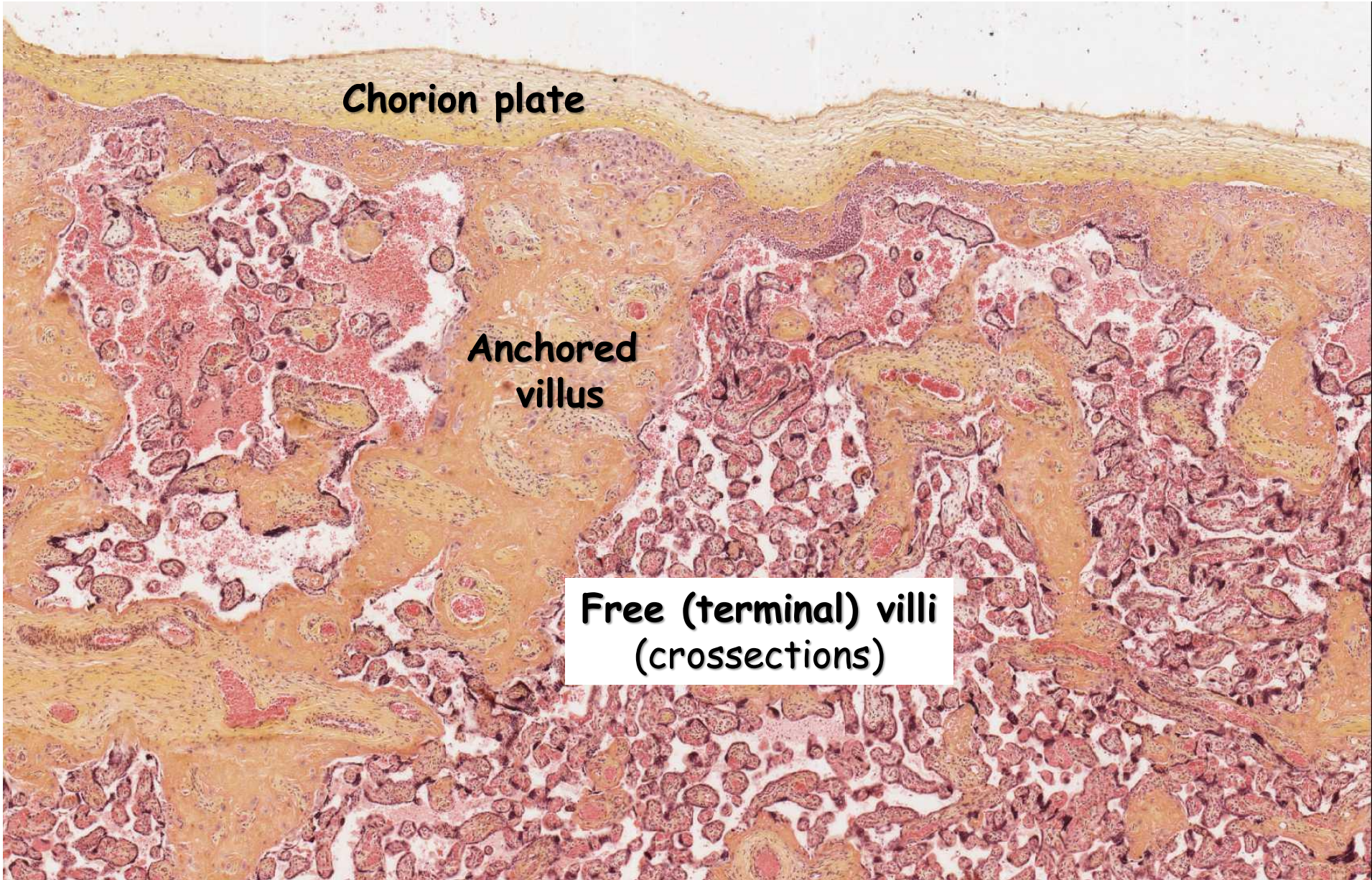


Placenta 7

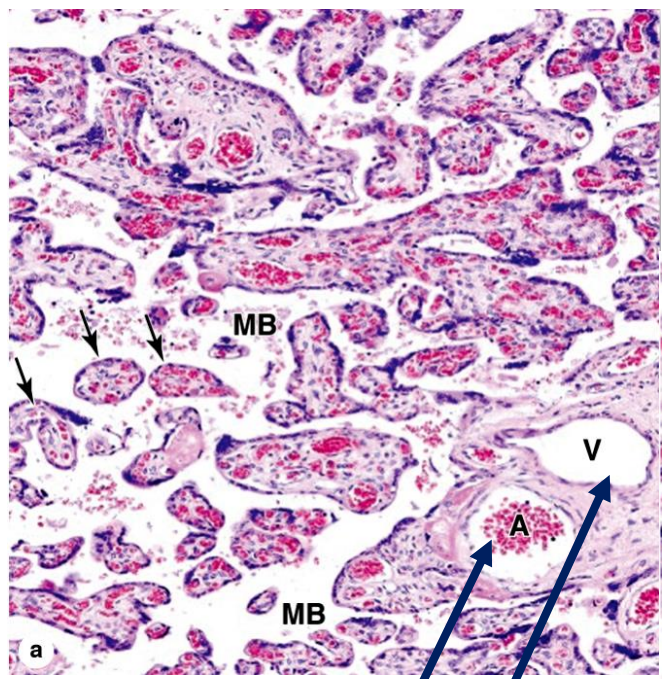
Chorion plate

Anchored villus

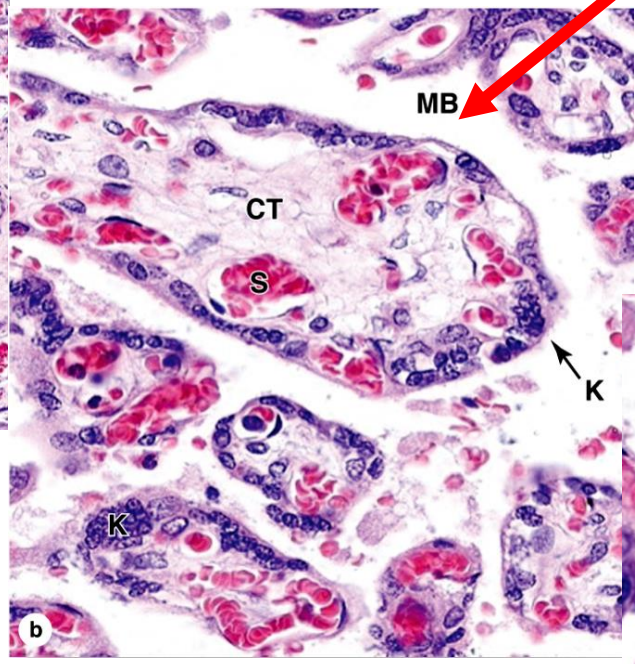
**Free (terminal) villi
(crosssections)**



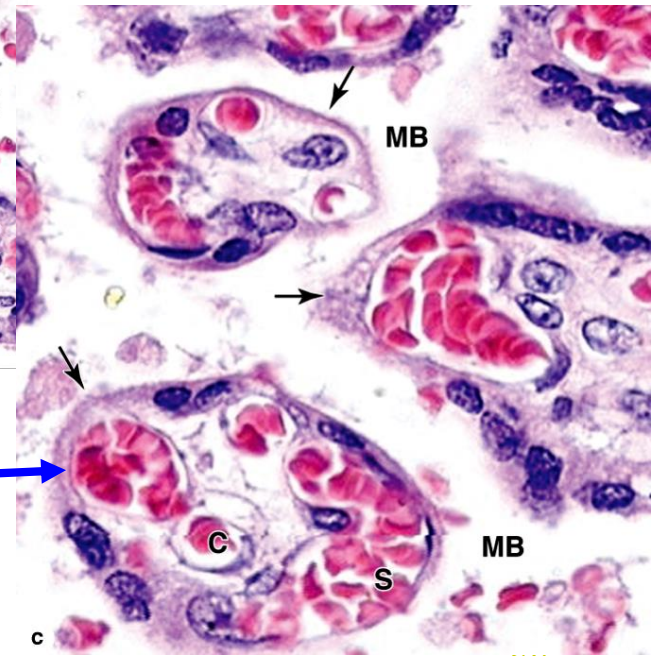
Placenta 8 - Free villi



Extraembryonic vasculature



Maternal blood

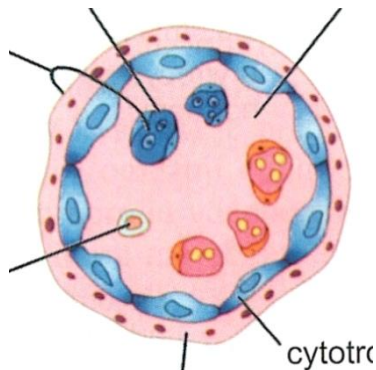


Syncytiotrophoblast

Placental barrier

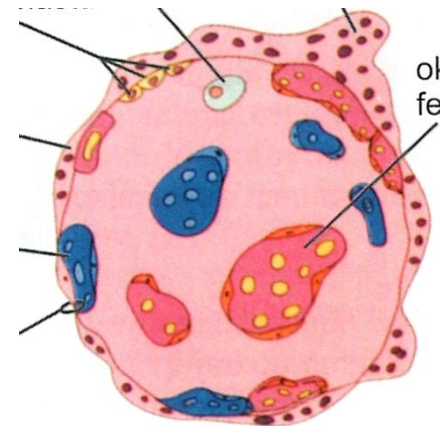
Until mid pregnancy

- capillary endothelium
- basal lamina of endothelium
- mucous connective tissue
- cytotrophoblast
- basal lamina of syncytiotrophoblast
- syncytiotrophoblast



Since month 5

- capillary endothelium
- basal lamina of endothelium
- basal lamina of syncytiotrophoblast
- syncytiotrophoblast



Umbilical cord

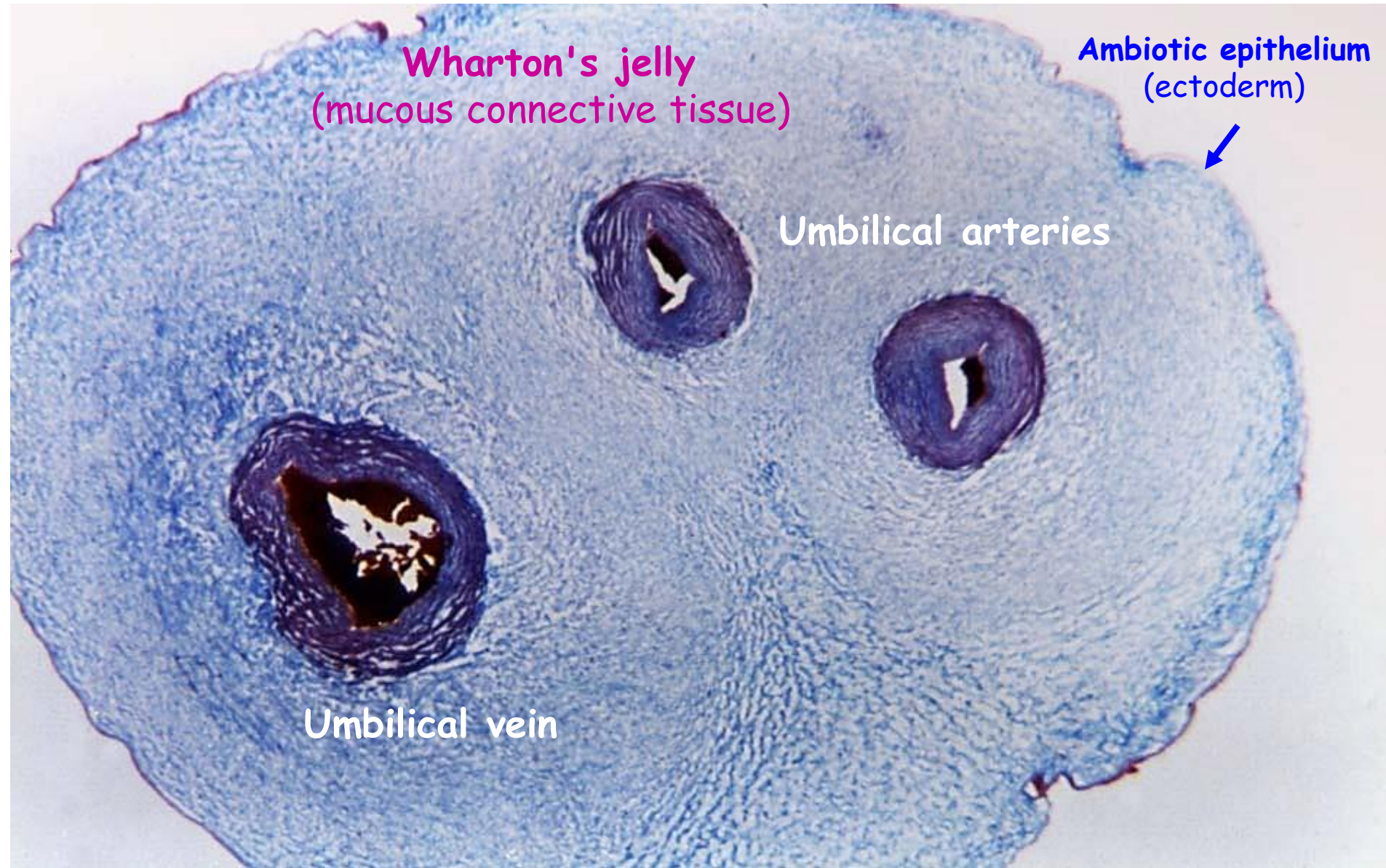
- links foetus to placenta
- about 55 cm in length

Wharton's jelly
(mucous connective tissue)

Ambiotic epithelium
(ectoderm)

Umbilical arteries

Umbilical vein



Thank you for your attention !

Questions and comments at:
ahampl@med.muni.cz