


Digestive system I.

Oral cavity – cavitas oris



Borders:

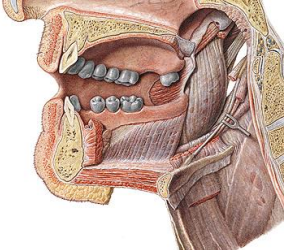
- Rima oris
- Isthmus faucium
- Lips, buccae
- Palatum
- Diaphragma oris

Content:


- Tongue
- Teeth

CAVITAS ORIS

vestibulum oris cavum oris proprium

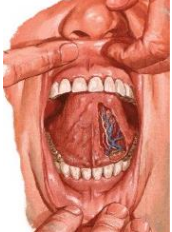




Vestibulum oris



Tremata
Trigonum retromolare
Papilla parotidea

Fornix vestibuli sup. (frenulum labii sup.)
Fornix vestibuli inf. (frenulum labii inf.)






Frenulum labii superioris
Frenulum labii inferioris

Glandulae labiales at buccales

Papilla parotidea

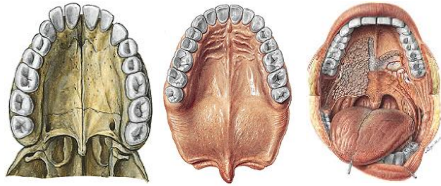
Proper oral cavity



Borders:

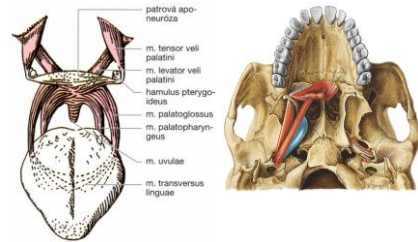
- Teeth
- Isthmus faucium
- Palatum
- Diaphragma oris

Palatum durum



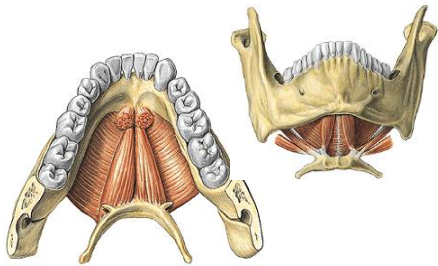
- Papilla incisiva (dustus incisivi, nervus nasopalatinus)
- Plicae palatinae transversae
- Glandulae palatinae

Soft palate

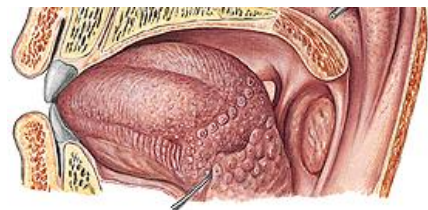


- patroviá apo-neuróza
- m. tensor veli palatini
- m. levator veli palatini
- hamulus pterygoideus
- m. palatoglossus
- m. palatopharyngeus
- m. uvulae
- m. transversus linguae

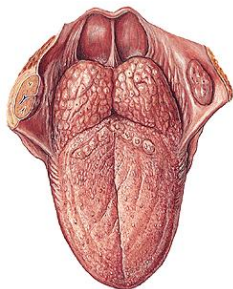
Diaphragma oris



Tongue (lingua, glossa)

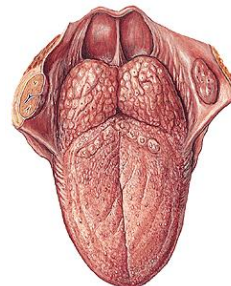


1. Pars oralis (corpus, apex)
2. Pars pharyngea (radix)

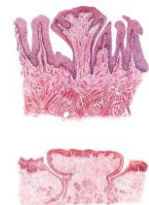


- Radix linguae
- Corpus linguae
- Apex linguae
- Sulcus terminalis
- Sulcus medianus
- Foramen caecum
- Margines linguae

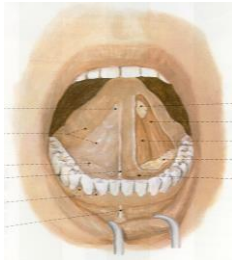
Dorsum linguae



- Papillae filiformes
- Papillae fungiformes
- Papillae foliatae
- Papillae vallatae

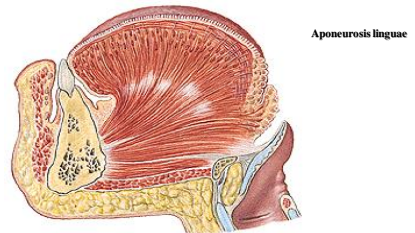


Inferior surface of the tongue

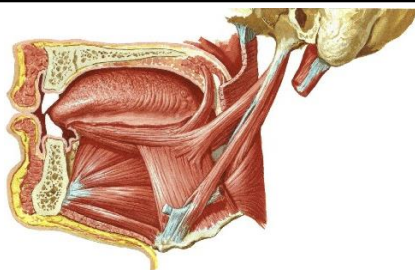


Plica fimbriata
Plica sublingualis
Frenulum linguae

Extraglossal muscles



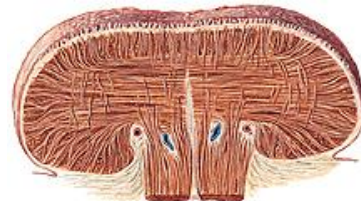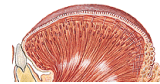M. genioglossus



Musculus hyoglossus
Musculus styloglossus
Musculus palatoglossus

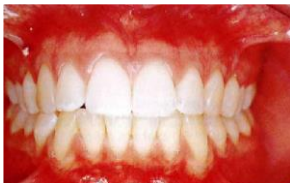Intraglossal muscles

M. longitudinalis sup. et inf.
M. transversus linguae
M. verticalis linguae



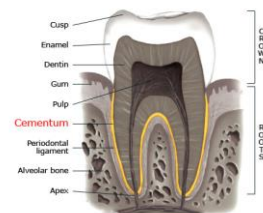
Septum linguae

Gingiva



Alveolar mucous membrane
Gingiva marginalis et alveolaris (paramarginal line)
Papillae gingivales, gingivodental closure, sulcus gingivalis

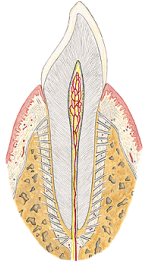
Teeth (dentes)



Cusp
Enamel
Dentin
Gum
Pulp
Cementum
Periodontal ligament
Alveolar bone
Apex

SECTUM
IM-ODM

Fixation of the teeth:



Type: Gomphosis

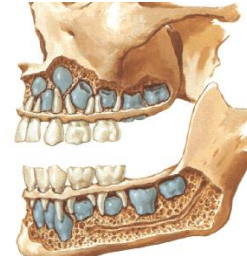
Periodontium (fixative ligaments):

(apical, alveolar, transeptal, gingival)

Parodontium:

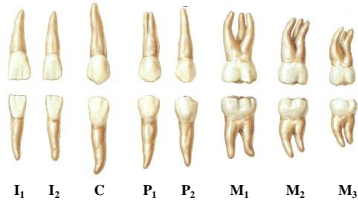
all of the fixative structures of the tooth (periost, periodontium, cementum, gingiva)

Dentes decidui



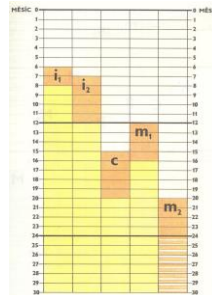
i₁ i₂ c m₁ m₂

Adult teeth



I₁ I₂ C P₁ P₂ M₁ M₂ M₃

Tooth eruption - primary teeth



Sequence:

First incisor (6 months)


Second incisor

First molar

Canin

Second molar (2-2,5 yrs)

Eruption - adult teeth



Sequence:

First incisor, first molar

Second incisor

First premolar

Canine

Second molar

Second premolar

Third molar

Salivary glands

GLANDULAE SALIVARIAE MINORES

glandulae labiales

glandulae buccales

glandulae palatinae

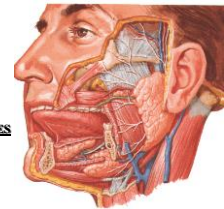
glandulae linguales

GLANDULAE SALIVARIAE MAJORES

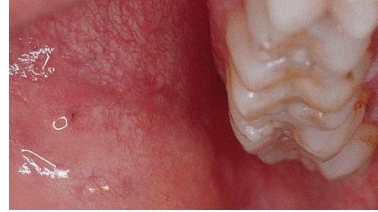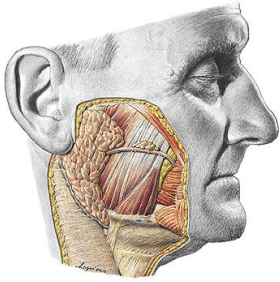
glandula parotidea

glandula submandibularis

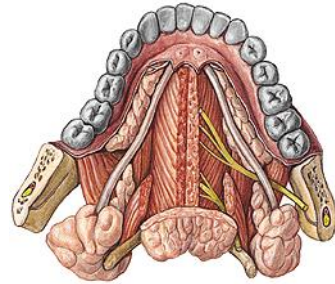
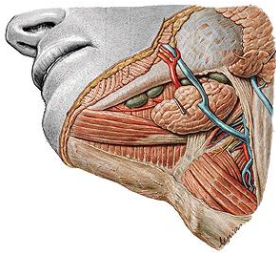
glandula sublingualis



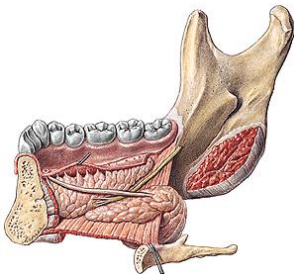
GLANDULA PAROTIDEA



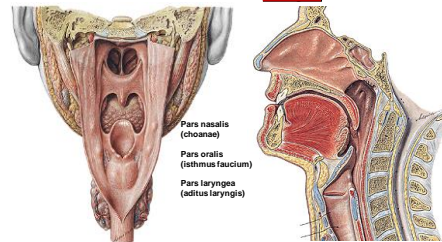
GLANDULA SUBMANDIBULARIS



GLANDULA SUBLINGUALIS

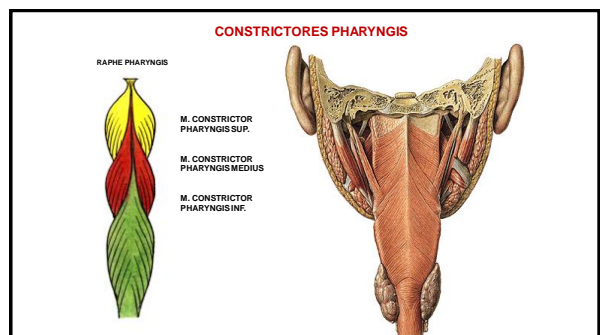
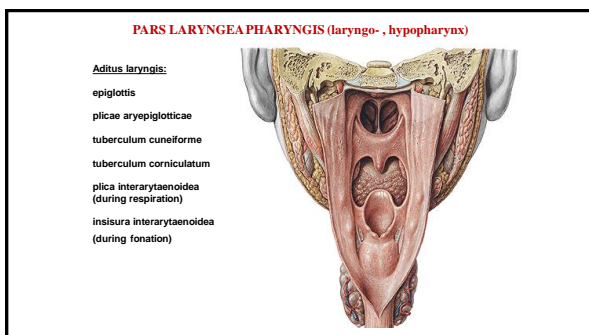
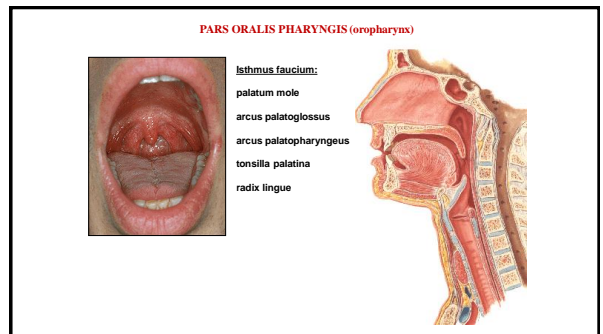
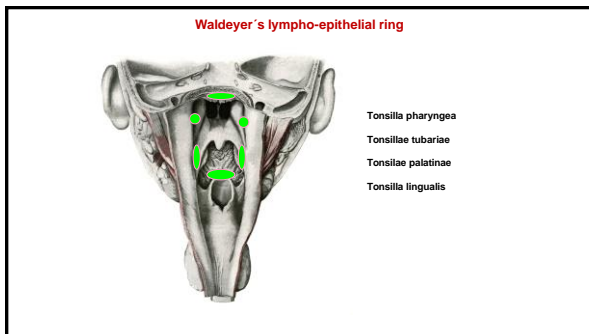
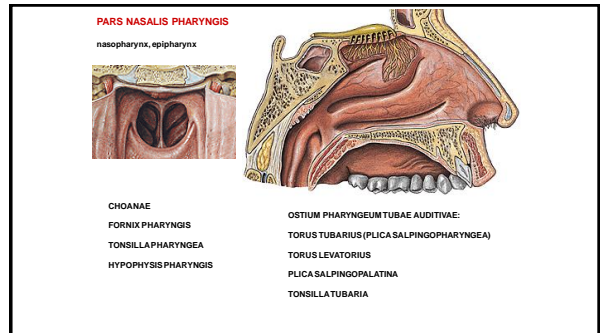
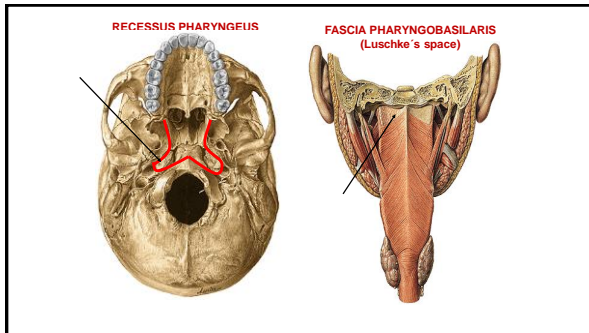


Pharynx

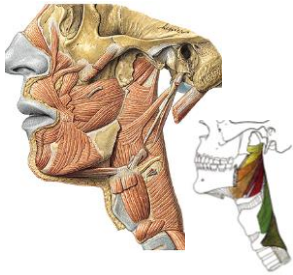


Base of skull - C6

cavum pharyngis
fornx pharyngis



CONSTRICTORES PHARYNGIS

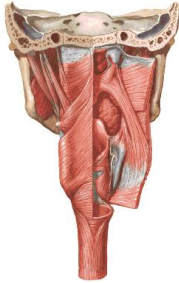


M. CONSTRICTOR PHAR. SUP.:
 PARS PTERYGOPHARYNGEA
 BUCCOPHARYNGEA
 MYLOPHARYNGEA
 GLOSSOPHARYNGEA

M. CONSTRICTOR PHAR. MED.:
 PARS CHONDROPHARYNGEA
 CERATOPHARYNGEA

M. CONSTRICTOR PHAR. INF.:
 PARS THYROPHARYNGEA
 CRICOPHARYNGEA

LEVATORES PHARYNGIS



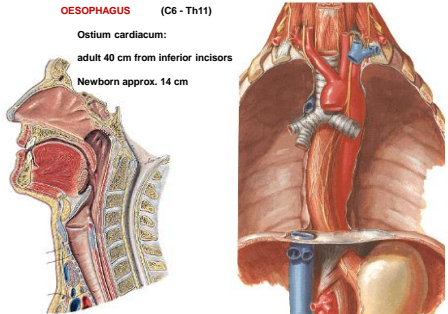
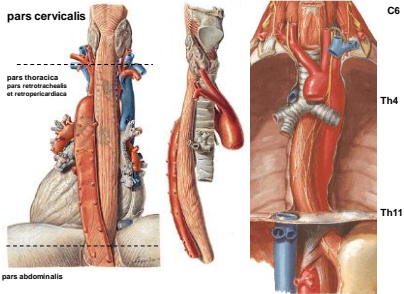
M. STYLOPHARYNGEUS
 (proc. styloideus)

M. SALPINGOPHARYNGEUS
 (tuba auditiva)

M. PALATOPHARYNGEUS
 (aponeurosis palatina)

OESOPHAGUS (C6 - Th11)

Ostium cardiacum:
 adult 40 cm from inferior incisors
 Newborn approx. 14 cm

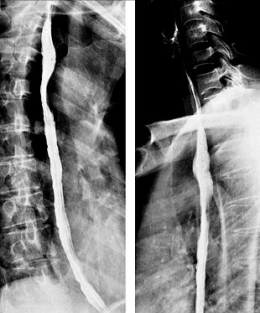
pars cervicalis

pars thoracica
 pars retrotrachealis
 et retropericardialis

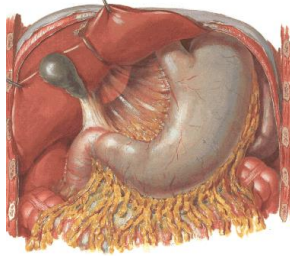
pars abdominalis

C6
 Th4
 Th11

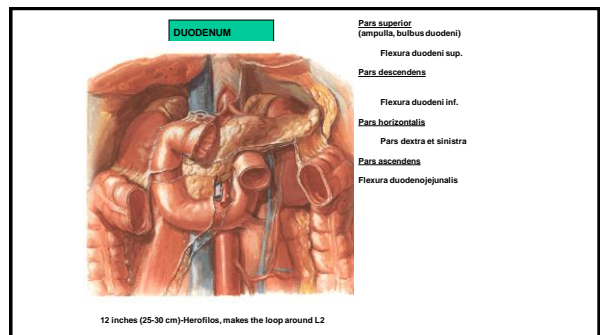
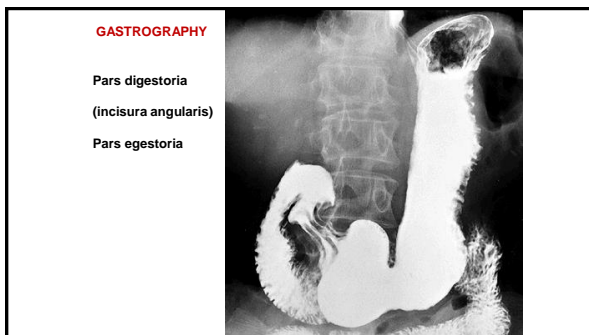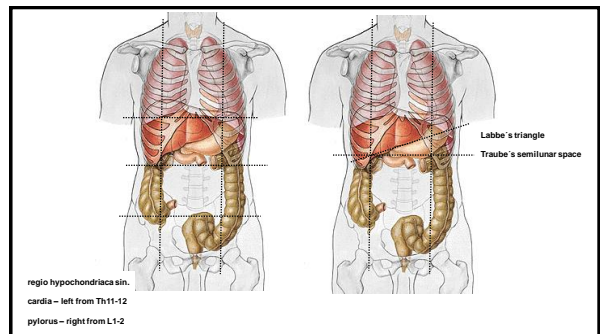
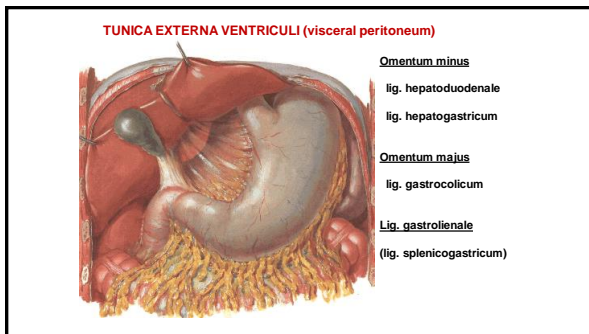
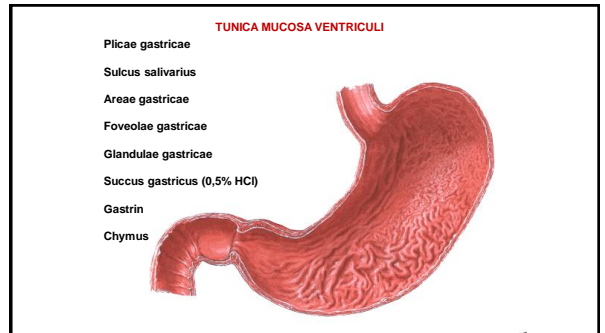
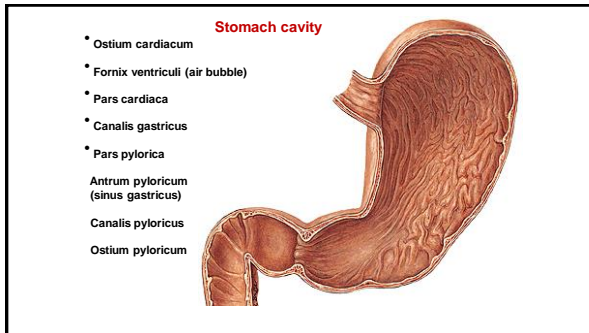
ESOPHAGOGRAPHY



Stomach



Cardia
 Fundus (forix)
 Corpus ventriculi
 Pars pylorica
 Pylorus
 Paries anterior
 Paries posterior
 Curvatura major
 Curvatura minor
 Incisura cardiaca
 Incisura angularis



Plica longitudinalis duodeni

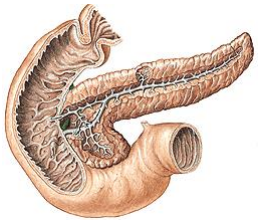
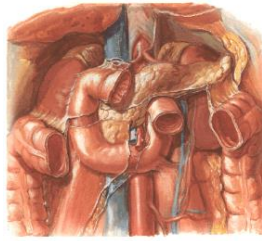
Papilla duodeni major (Vater)

ampulla hepatopancreatica
(m. sphincter papillae hepatopancreaticae, m. sphincter Oddi)

ductus choledochus
(m. sphincter ductus choledochi)

ductus pancreaticus major
(m. sphincter ductus pancreatici)


Papilla duodeni minor
ductus pancreaticus accessorius

Part sup. duodeni
- intraperitoneally
(lig. hepatoduodenale)

Other parts - secondary
in retroperitoneum


JEJUNOILEUM



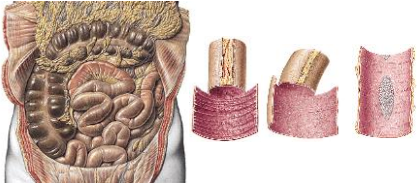
Ansae intestinales
Mesenterium
Radix mesenterii (12-15 cm)
Flexura duodenojejunalis
Ostium iliocaecale

Diverticulum ilei - Meckelii

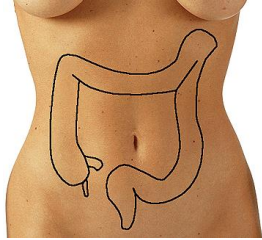
0,5 – 1m from the ostium iliocaecale
(ductus omphaloentericus = yolk stalk)



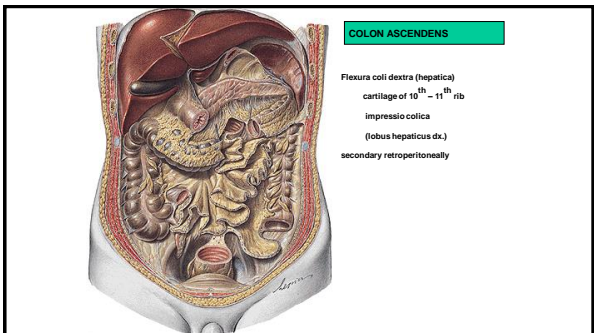
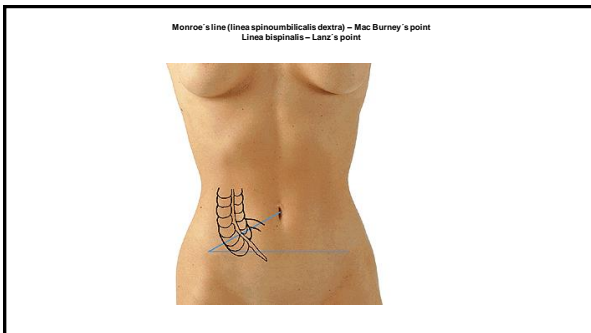
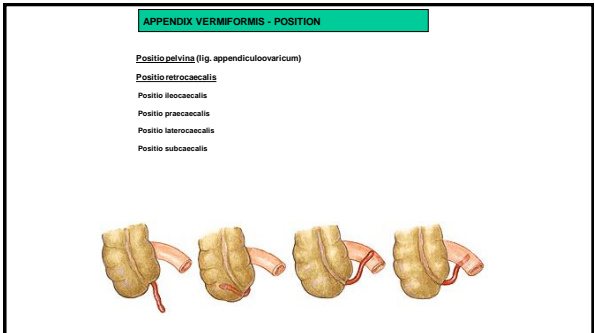
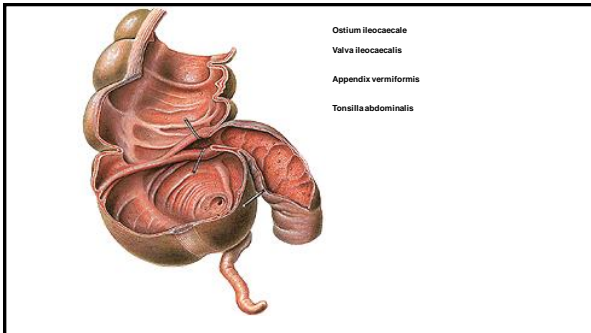
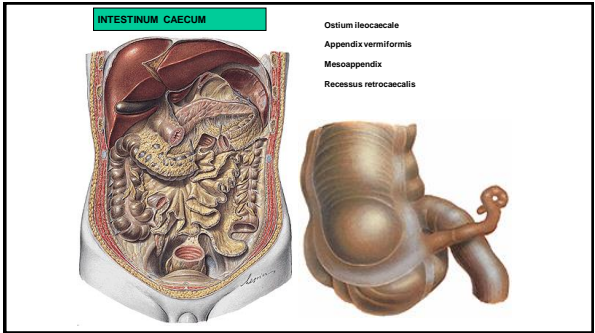
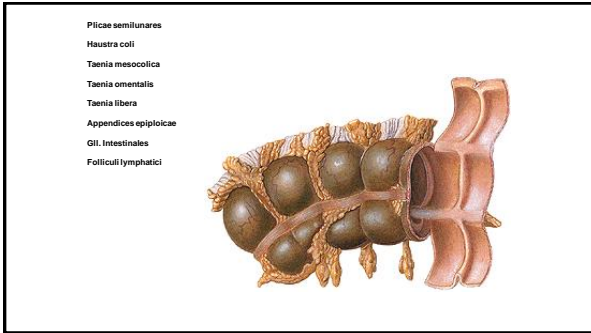
JEJUNUM	ILEUM
Upper left part of inframesocolic space	Lower right part of inframesocolic space
wider (3- 4 cm), 2/5 of length	narrower (2- 3 cm), 3/5 of length
Numerous circular folds	Less circular folds
1- 2 arterial arcades	2- 3 arterial arcades
folliculi lymphatici solitarii	folliculi lymphatici aggregati

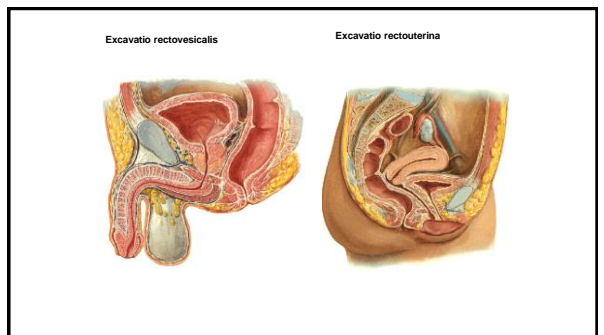
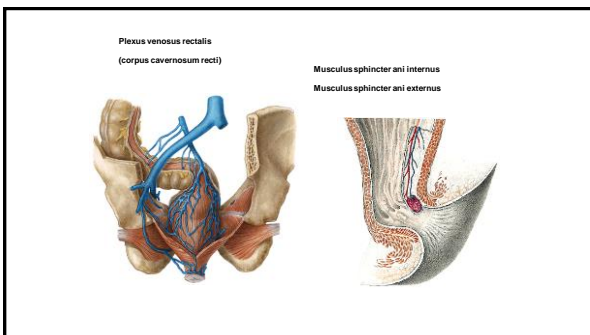
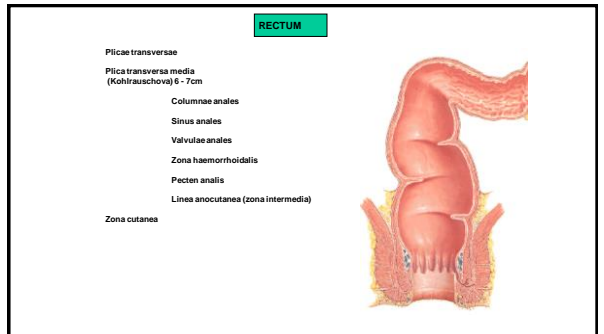
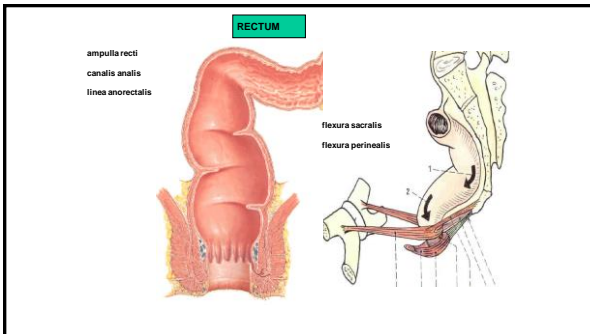
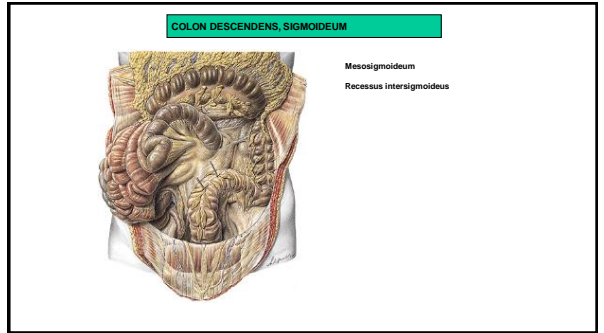
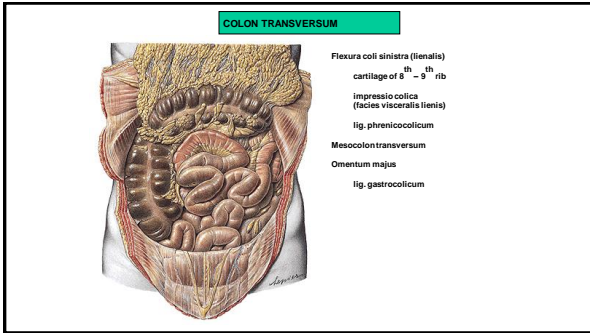


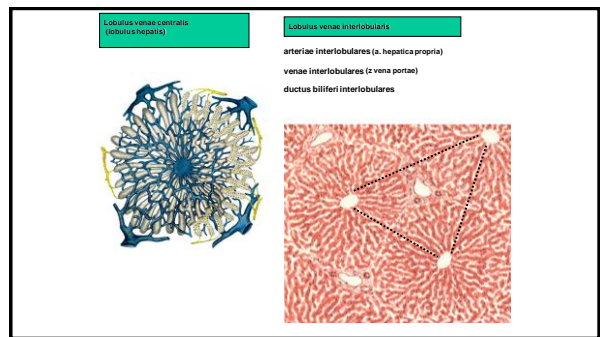
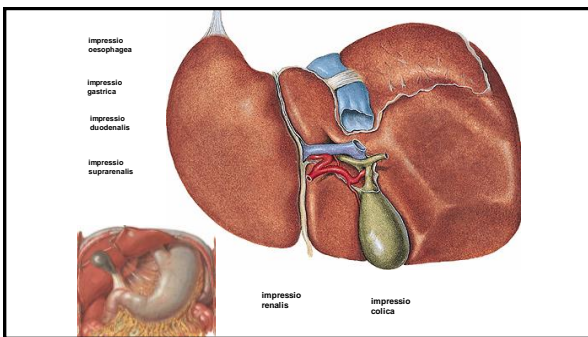
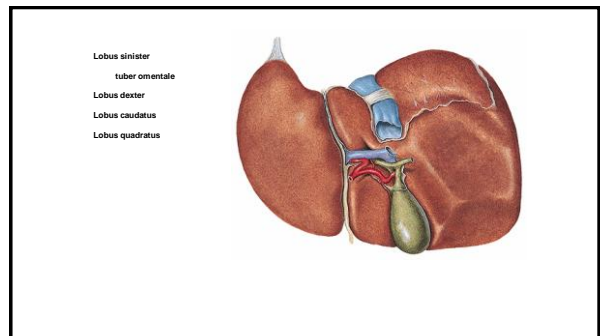
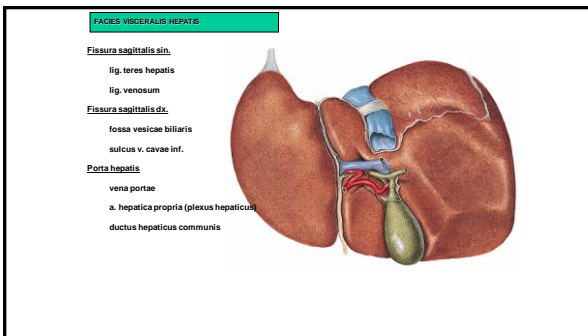
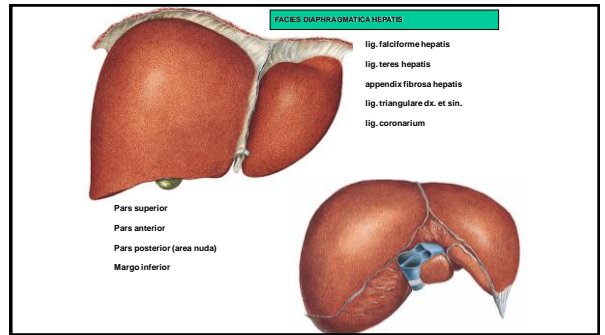
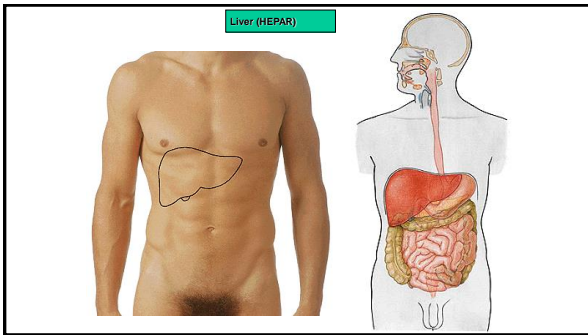
Large intestine

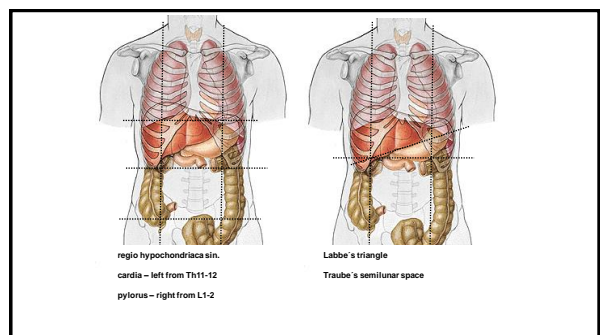
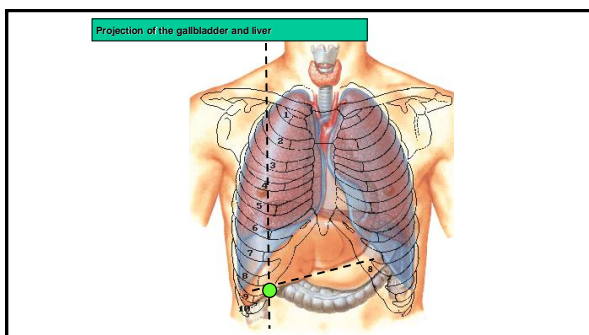
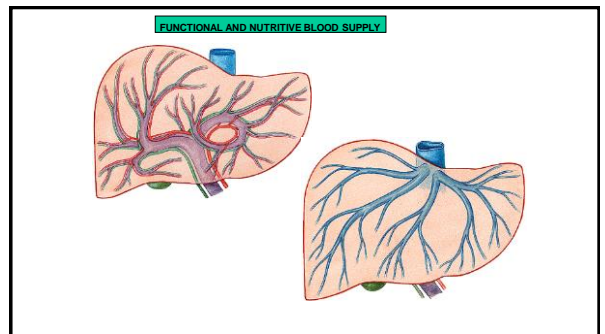
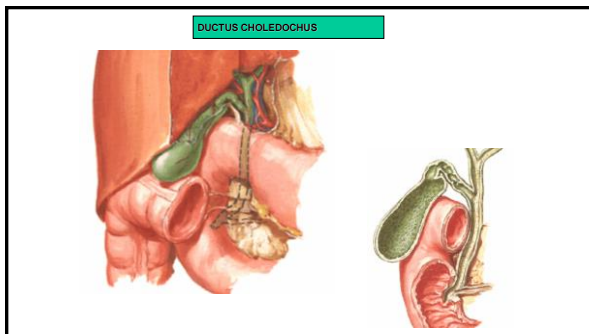
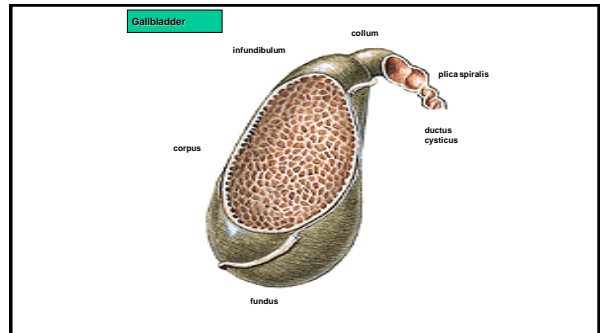
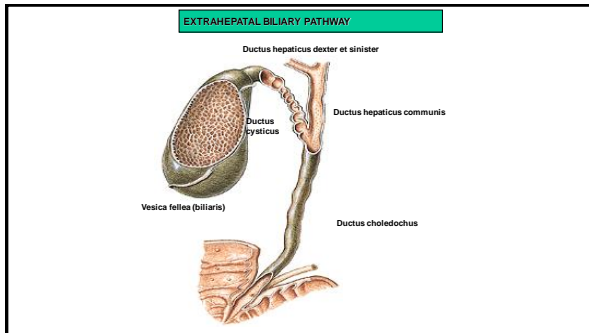


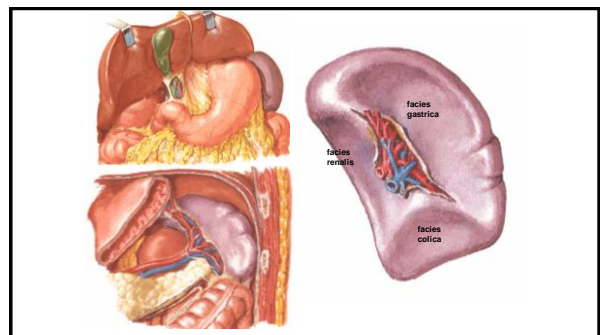
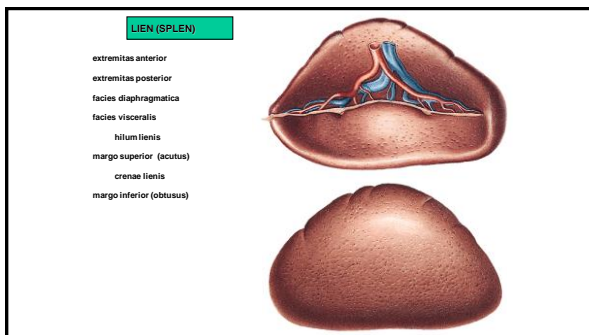
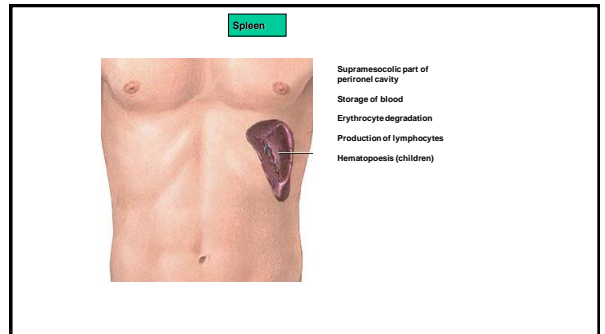
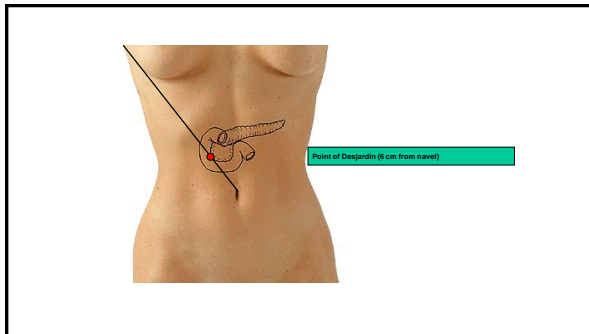
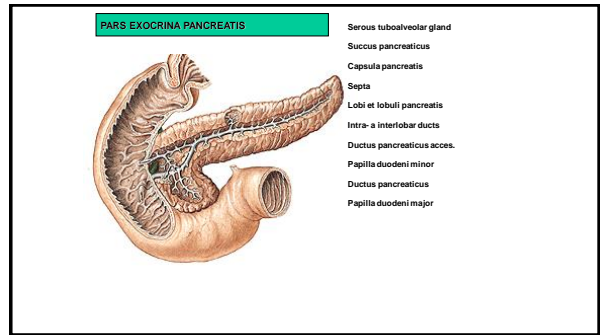
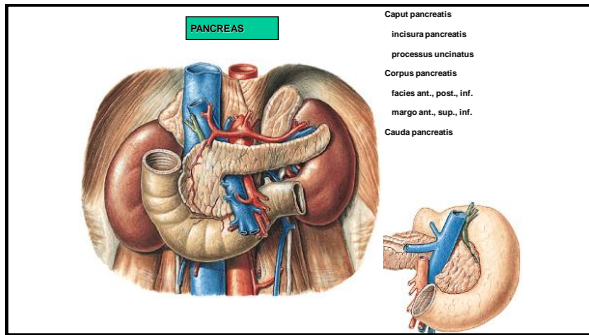
intestinum caecum
colon ascendens
flexura coli dextra (hepatica)
colon transversum
flexura coli sinistra (splenica)
colon descendens
colon sigmoideum
rectum

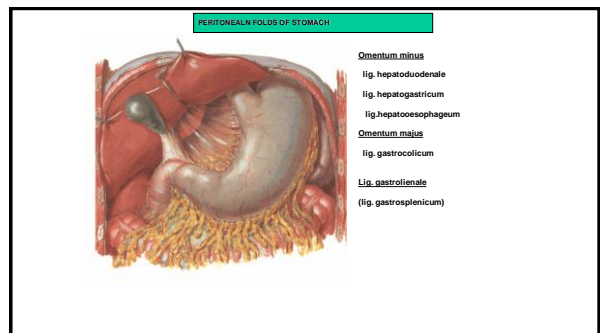
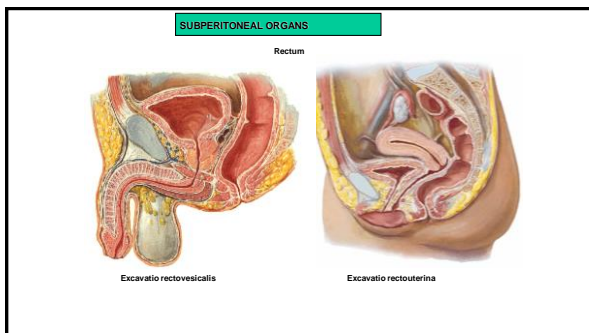
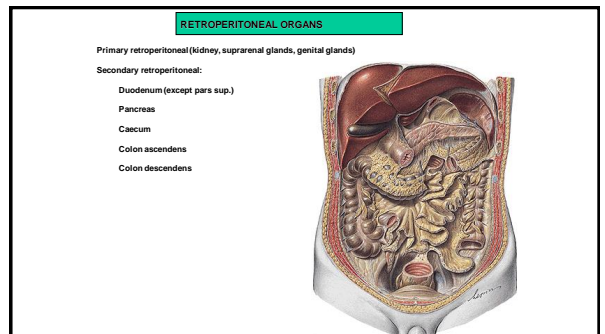
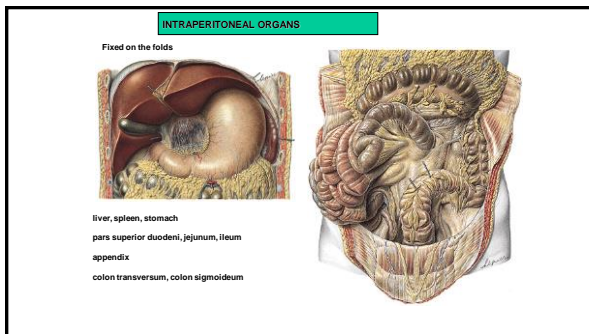
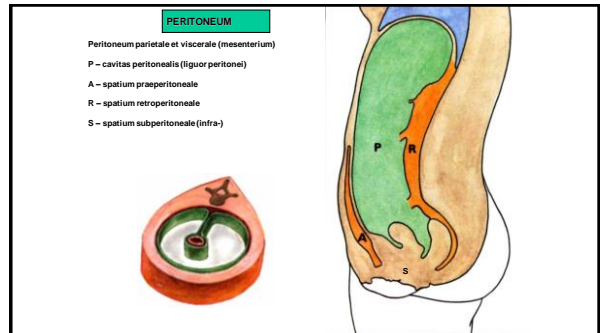
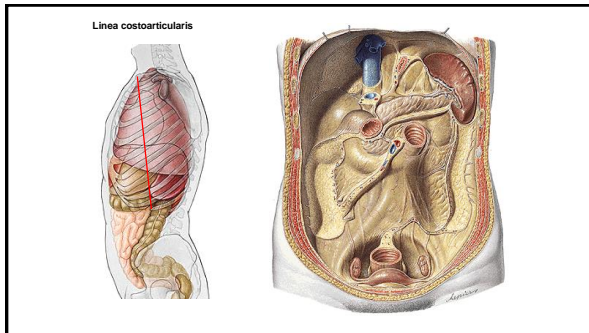


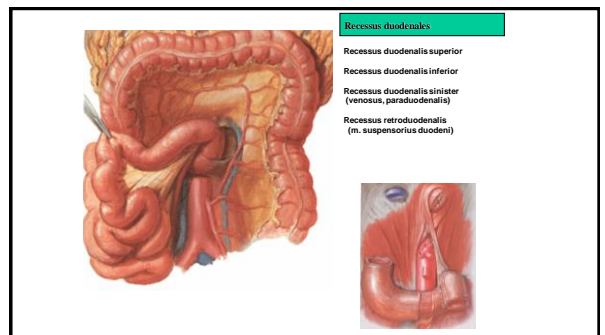
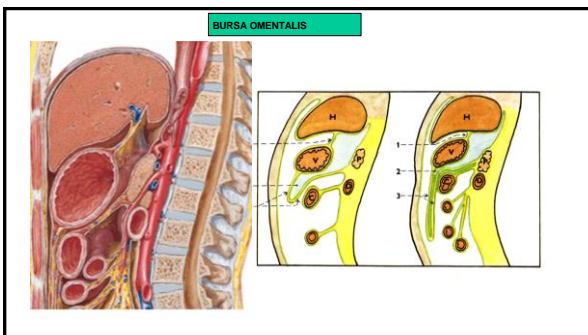
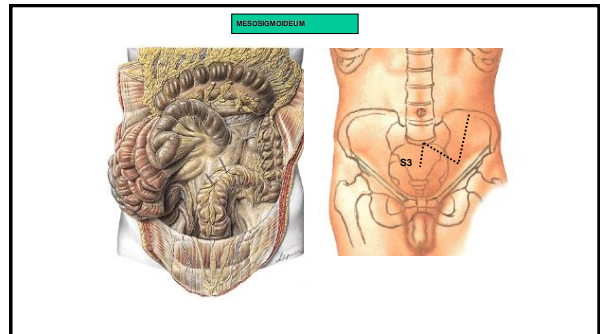
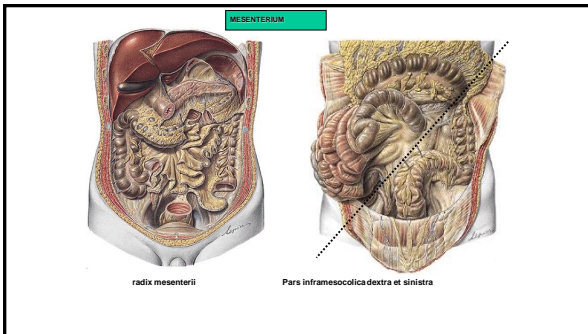
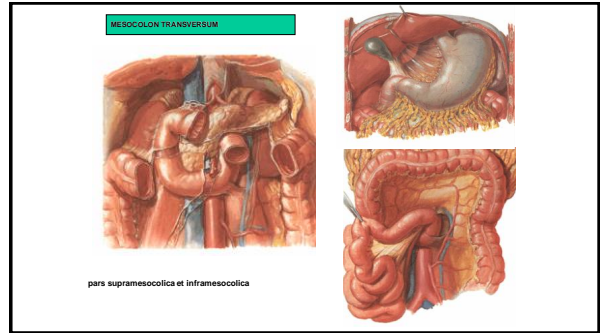
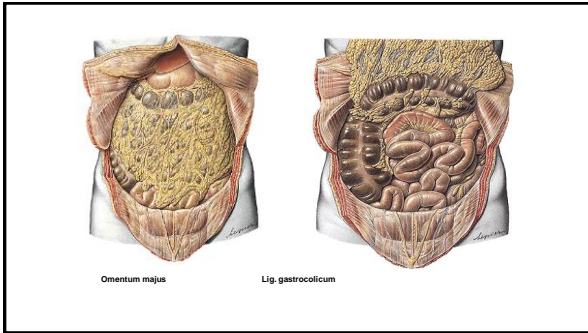


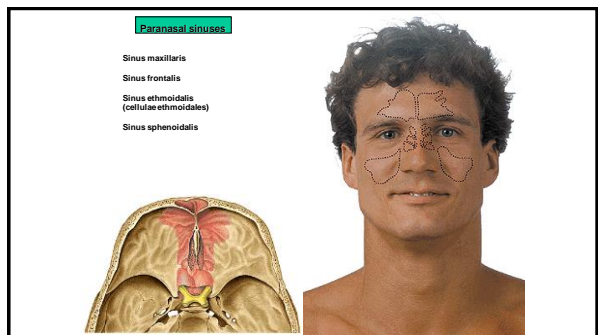
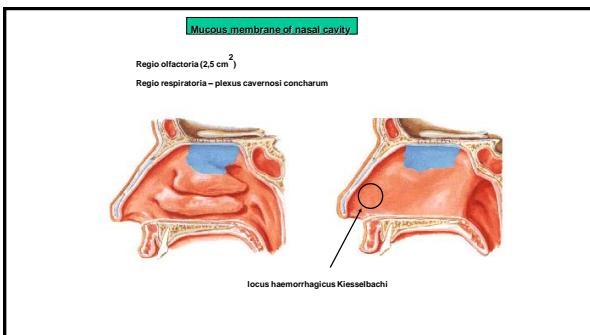
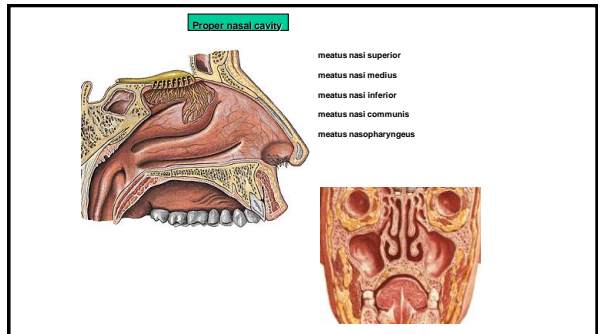
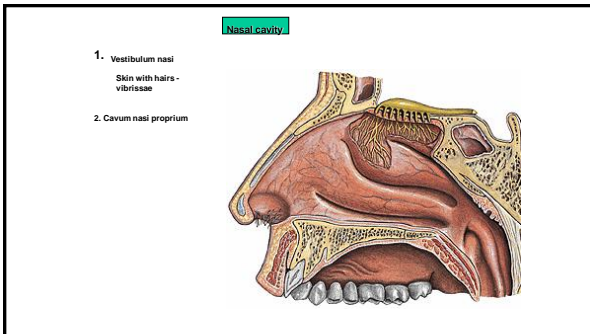
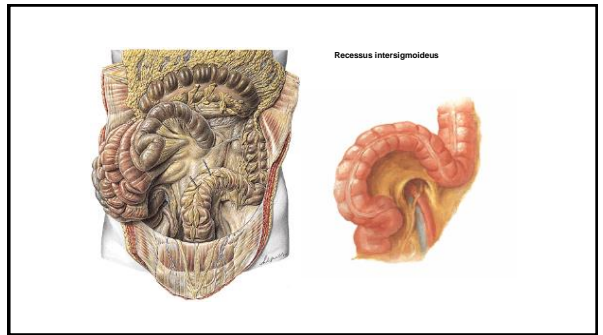
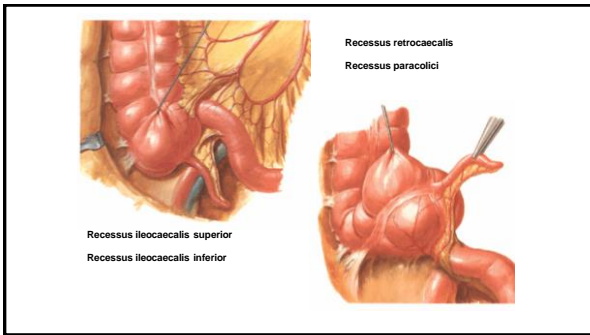


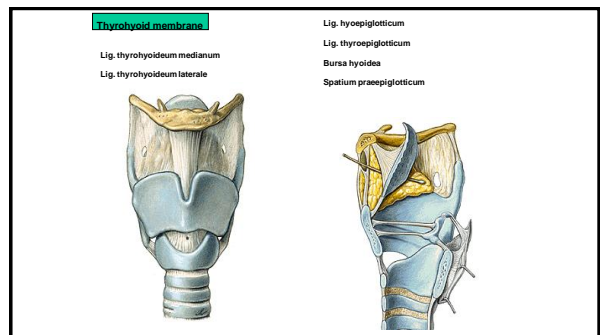
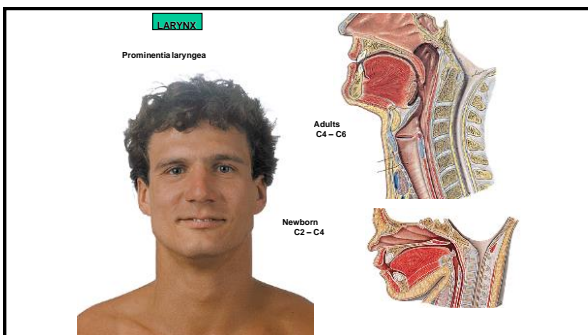
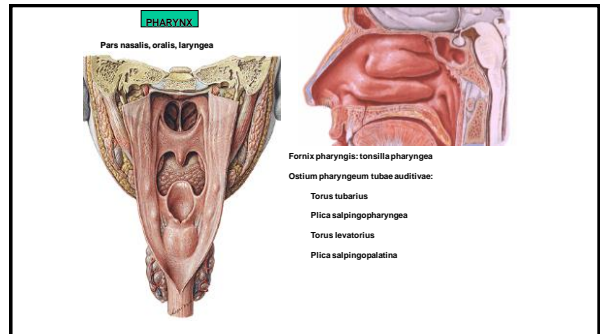
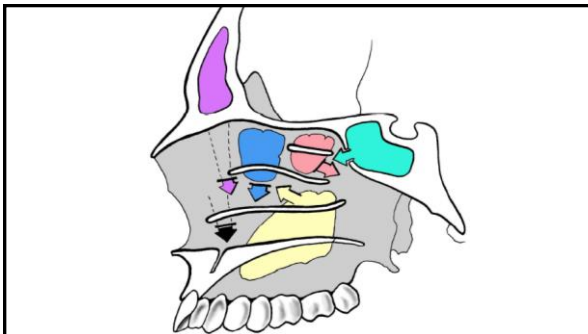
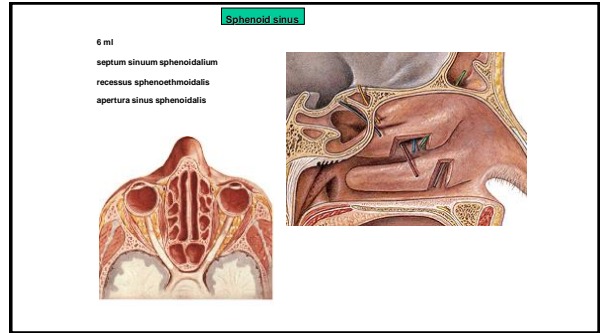
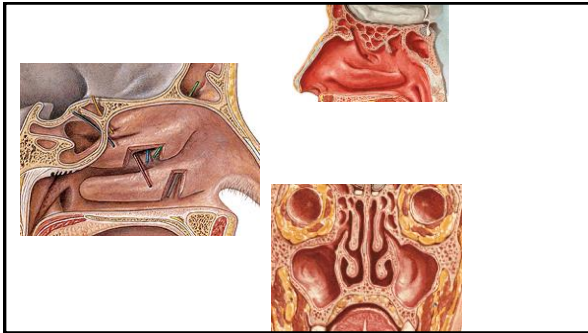


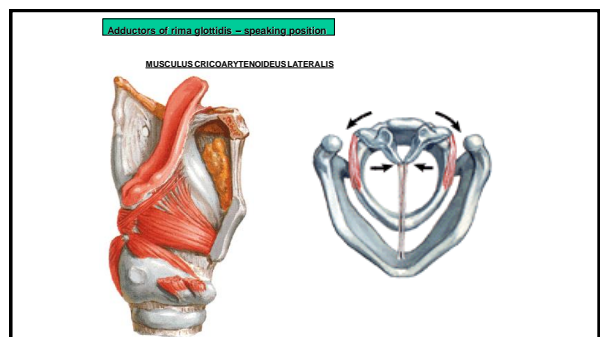
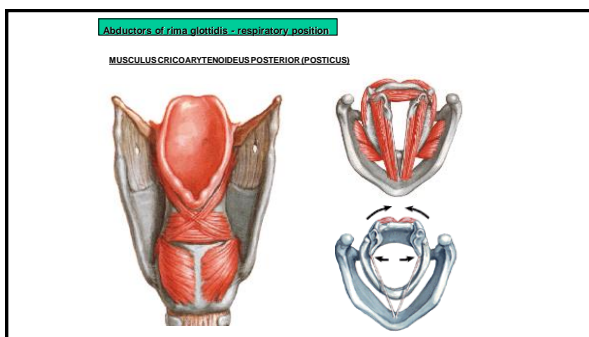
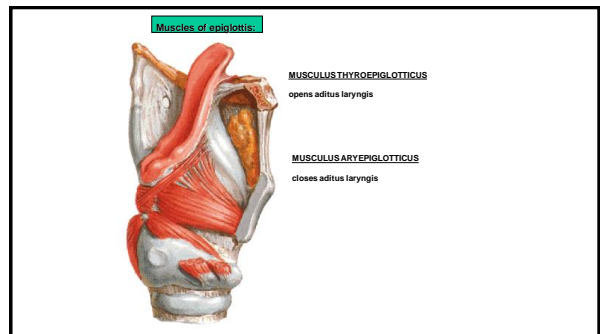
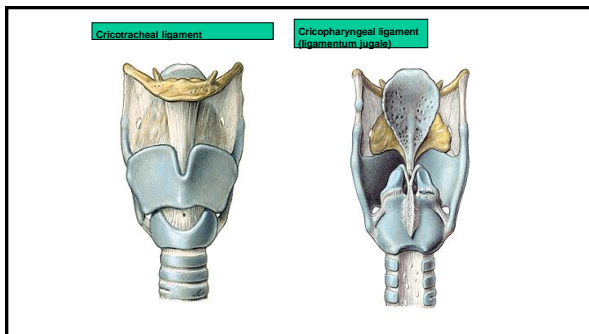
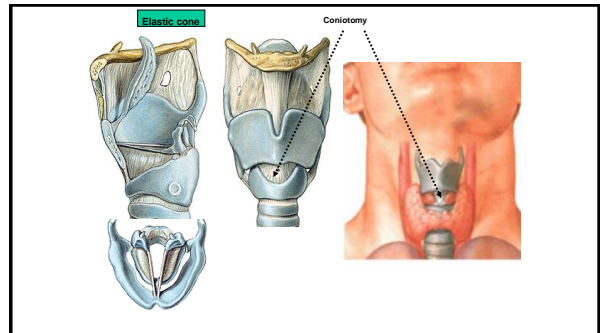
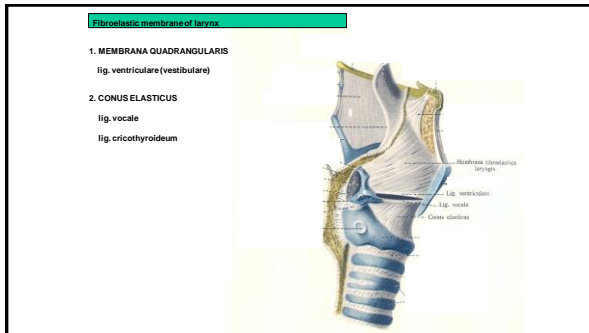


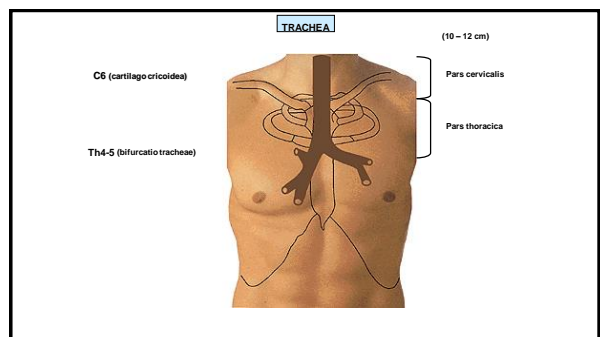
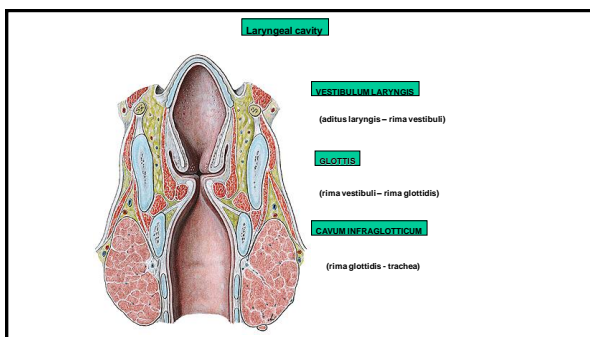
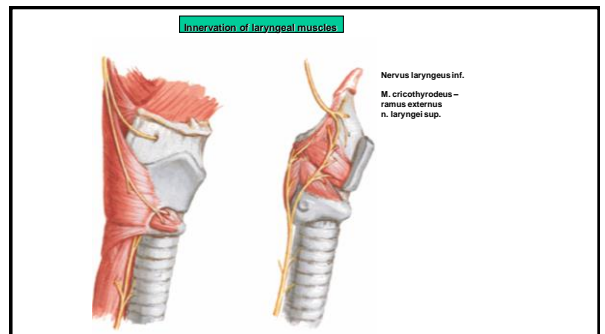
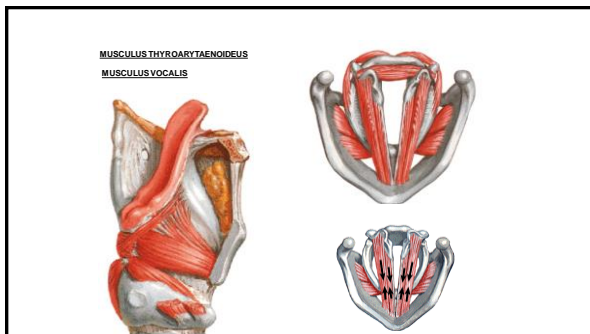
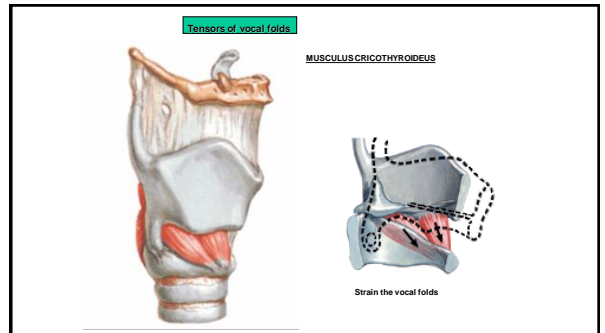
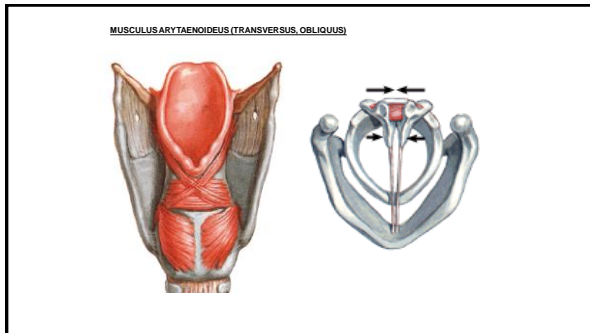


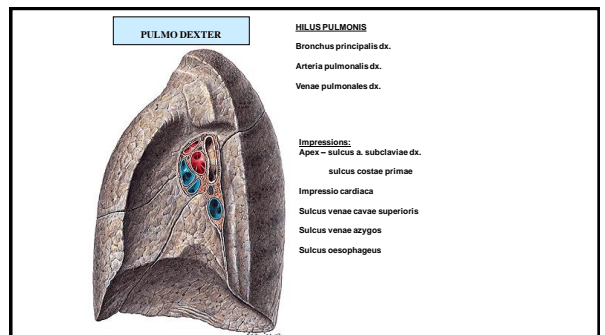
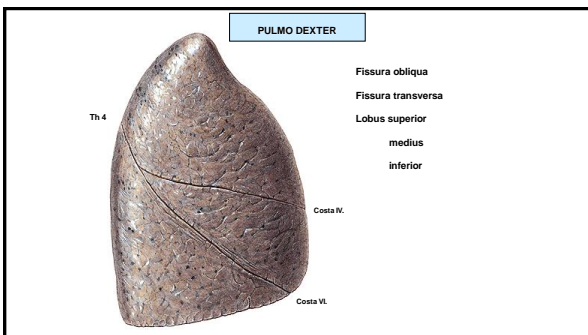
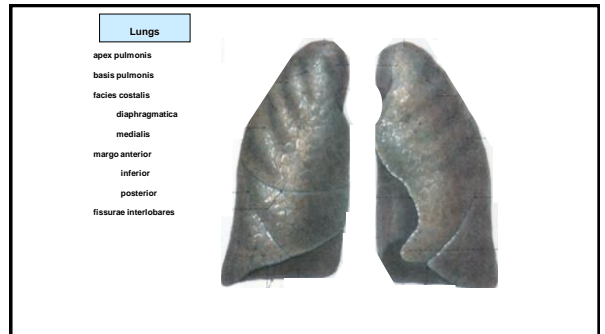
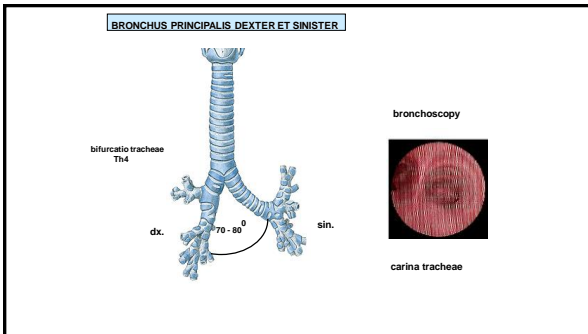
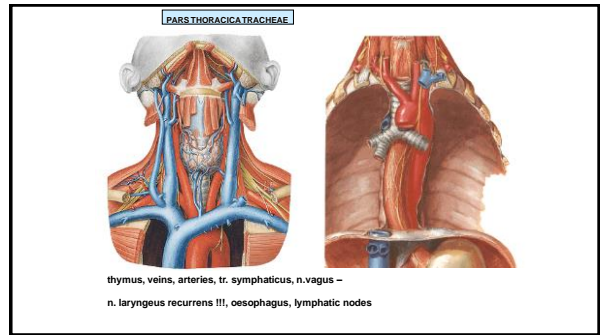
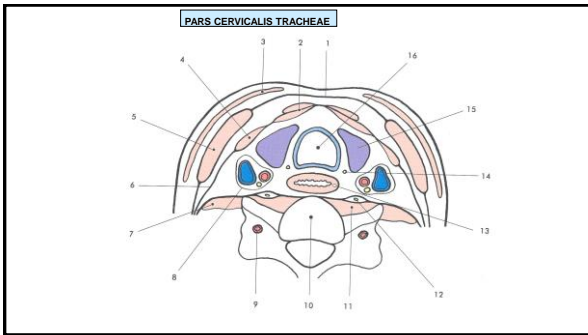


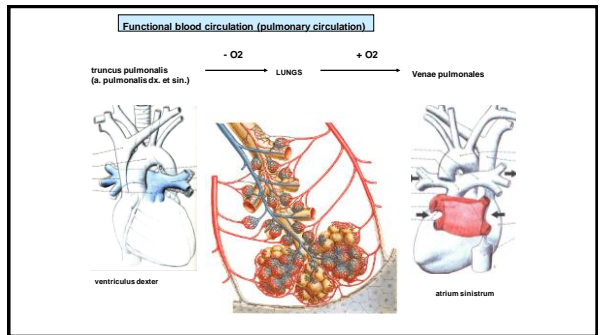
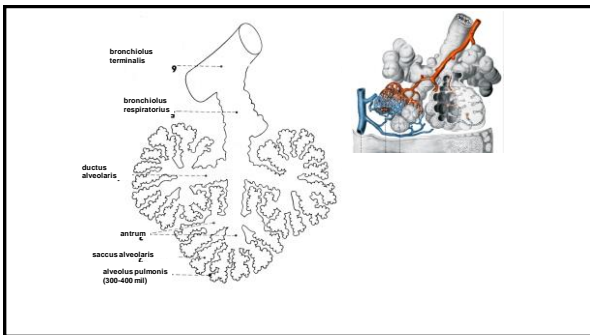
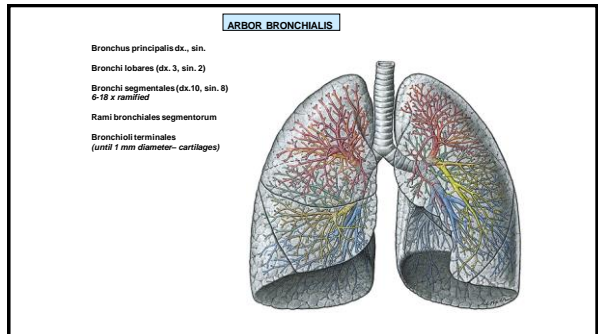
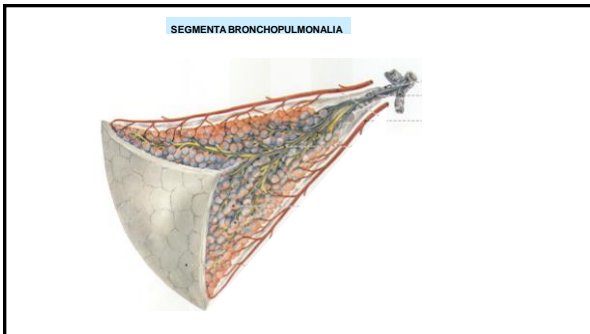
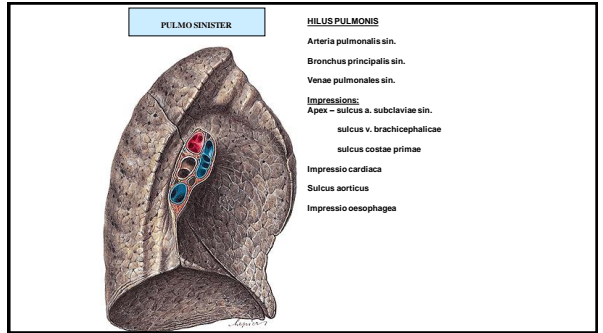
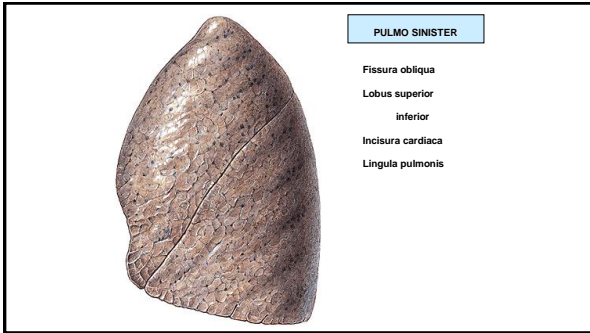


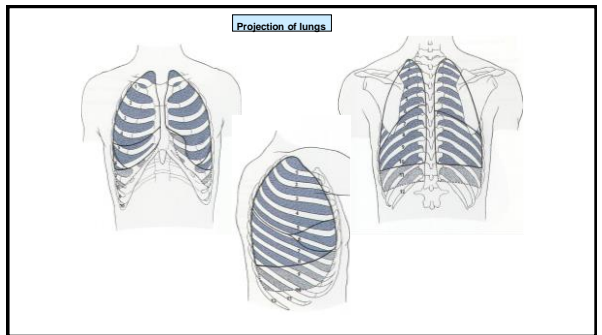
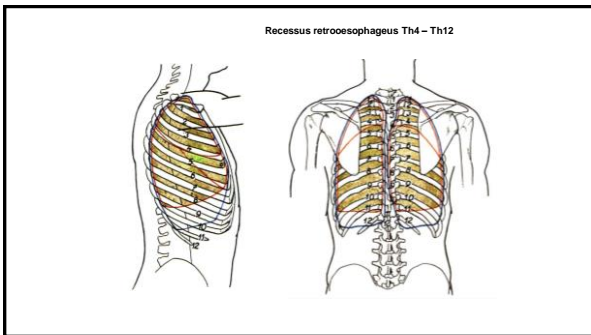
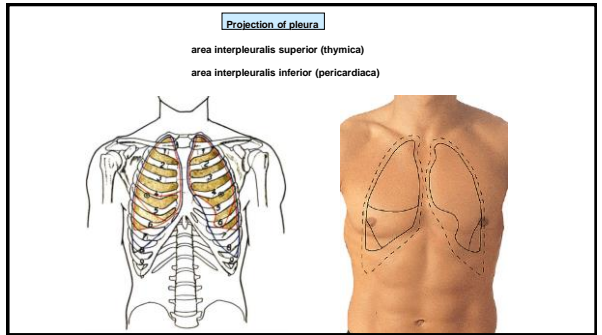
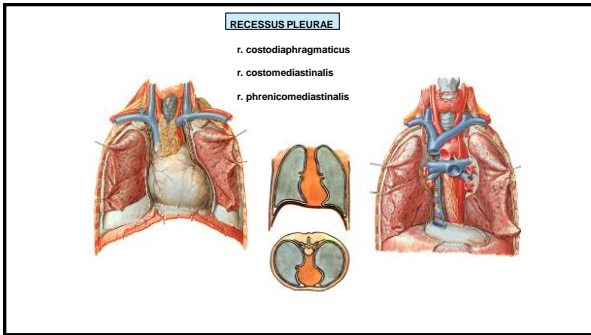
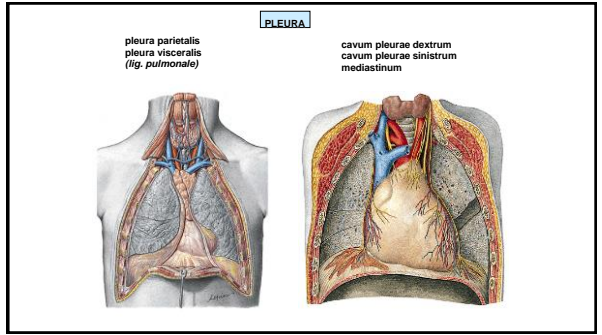
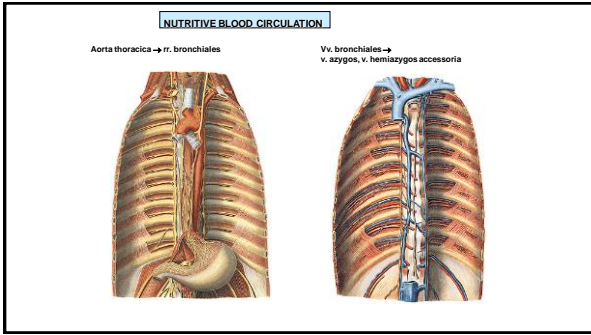


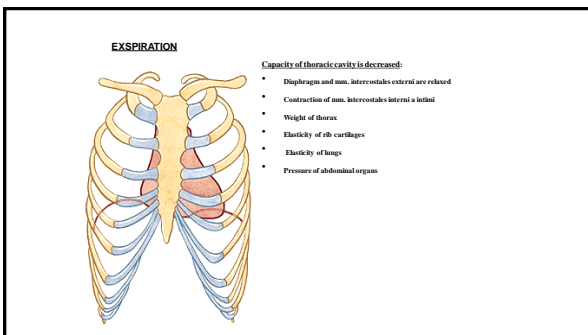
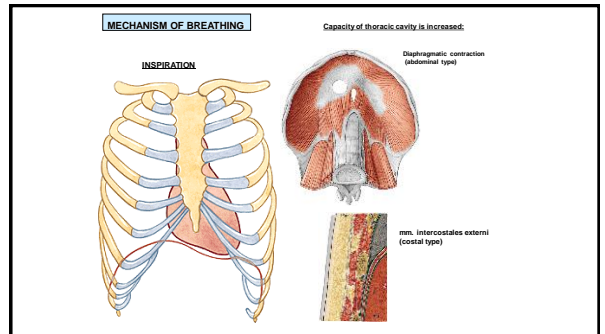
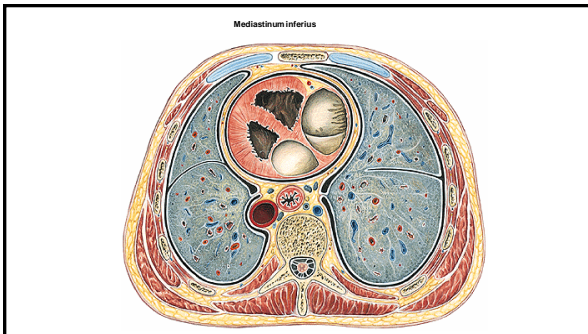
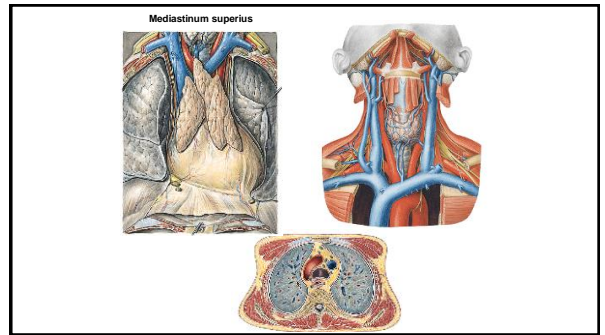
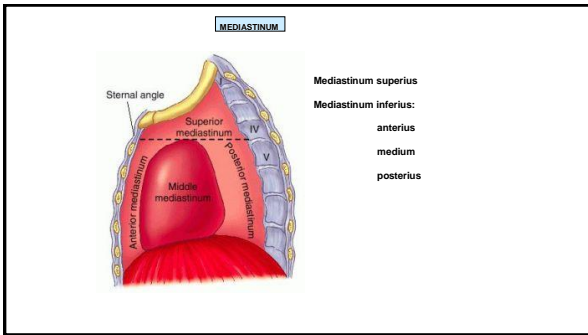












References:

- DATA, B. (2008):** Atlas of Human Anatomy Sobotta, Elsevier Books.
- KRIBBI, L., MOORE, Arthur F., DALLER (2005):** Clinically Oriented Anatomy, Williams and Wilkins.
- FLATNER, W., KAHLE, W., LEONHARDT II. (1992):** Locomotor system, Georg Thieme Verlag, Stuttgart, New York, 4th edition.
- ČIHÁK, R. (1987):** Anatomie I. Návčennum, Zdravotnická nakladatelství.
- NETTER, F.H. (1997):** Interactive Atlas of Clinical Anatomy, Novartis, USA.