Cardiology imaging for beginners

JAN KANOVSKY

Seeing is believing.
(Thomas Fuller, 1639)



- Source: Wikipedia

Imaging

- **Medical imaging** is the technique and process of creating visual representations of the interior of a body for clinical analysis and medical intervention, as well as visual representation of the function of some organs or tissues (physiology).

What is the easiest way to image heart?

- X ray
  - William Roentgen's wife hands
    - 22 December 1895



Source:Wikipedia

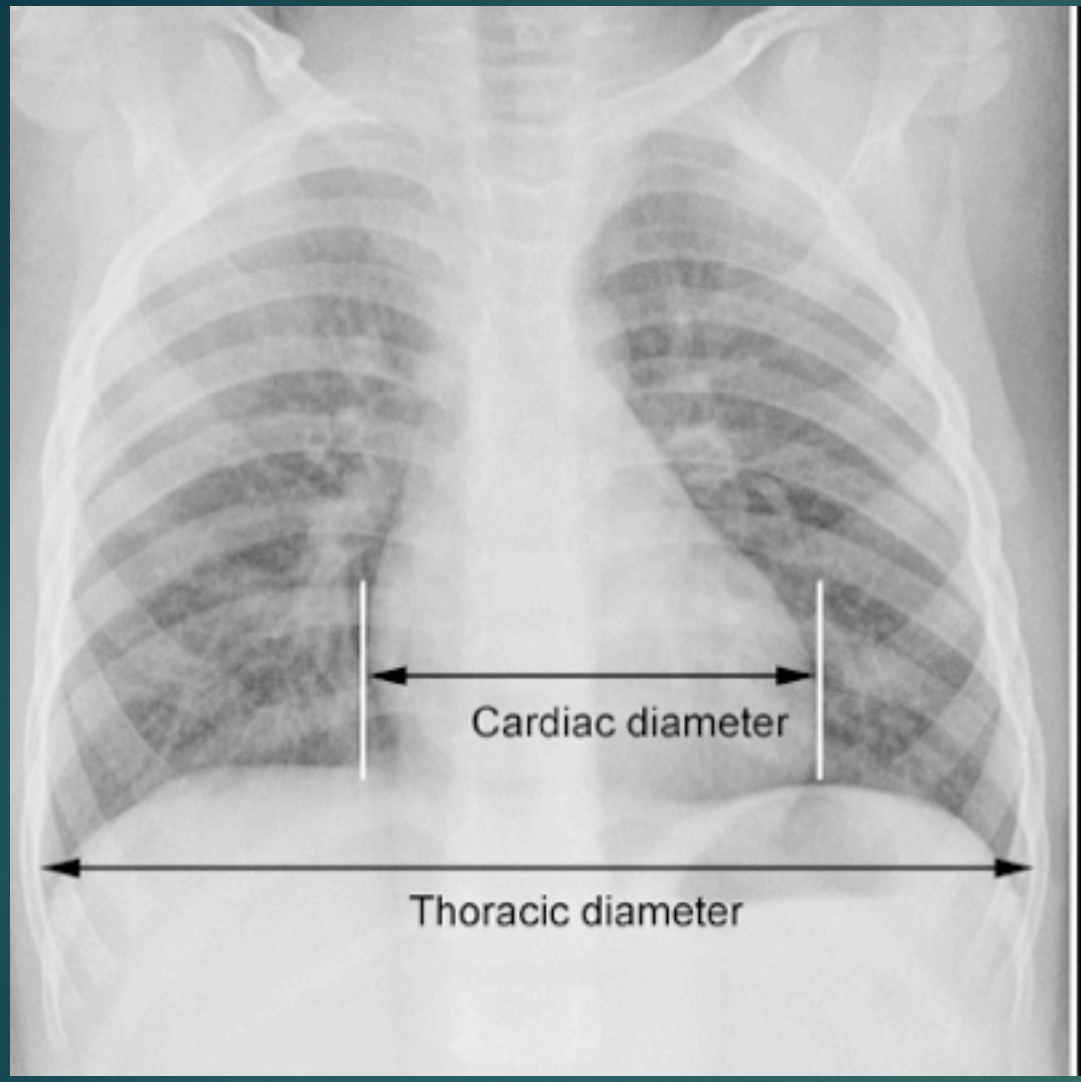

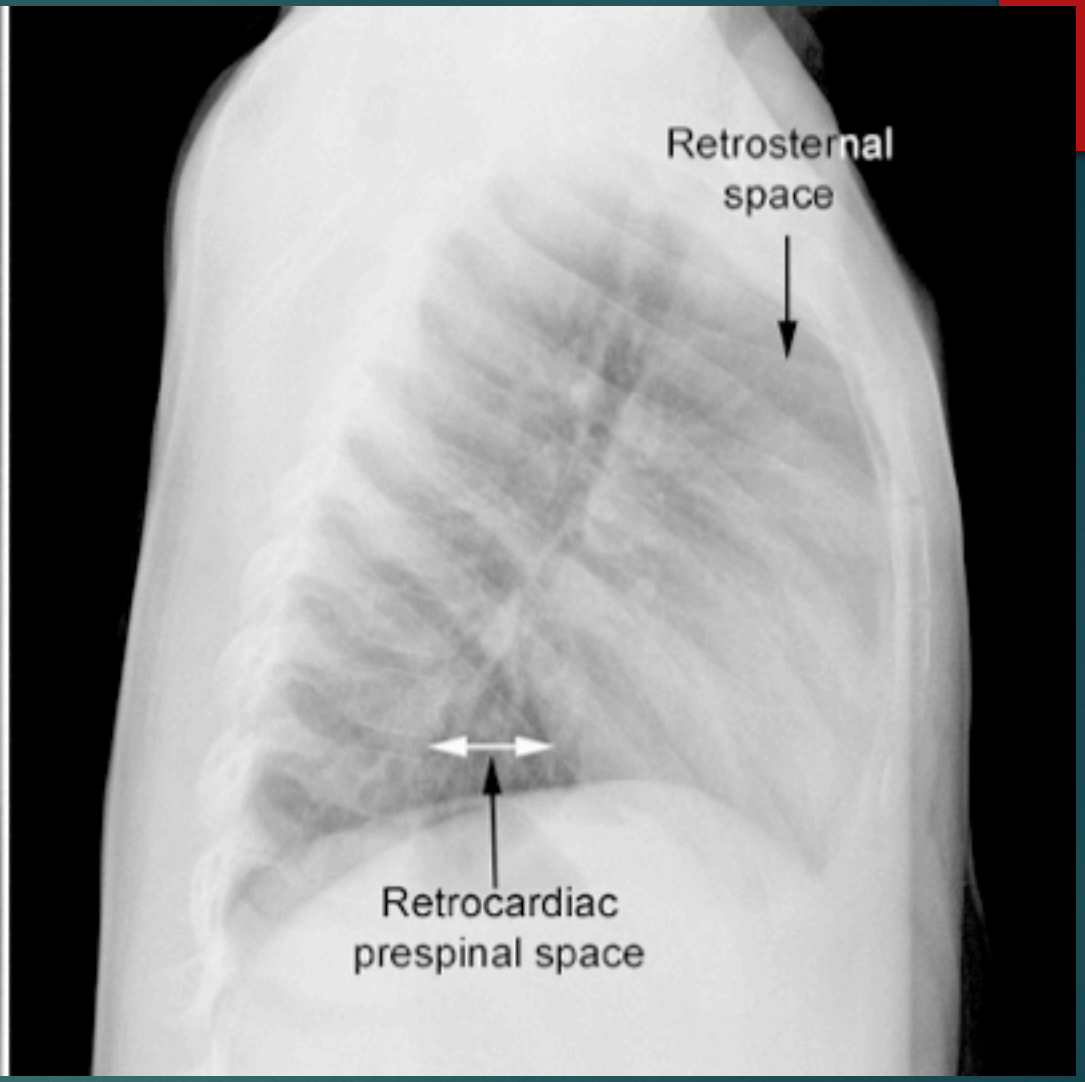

- Source: Radiology key

Anatomy – Cardiac Silhouette and Mediastinum

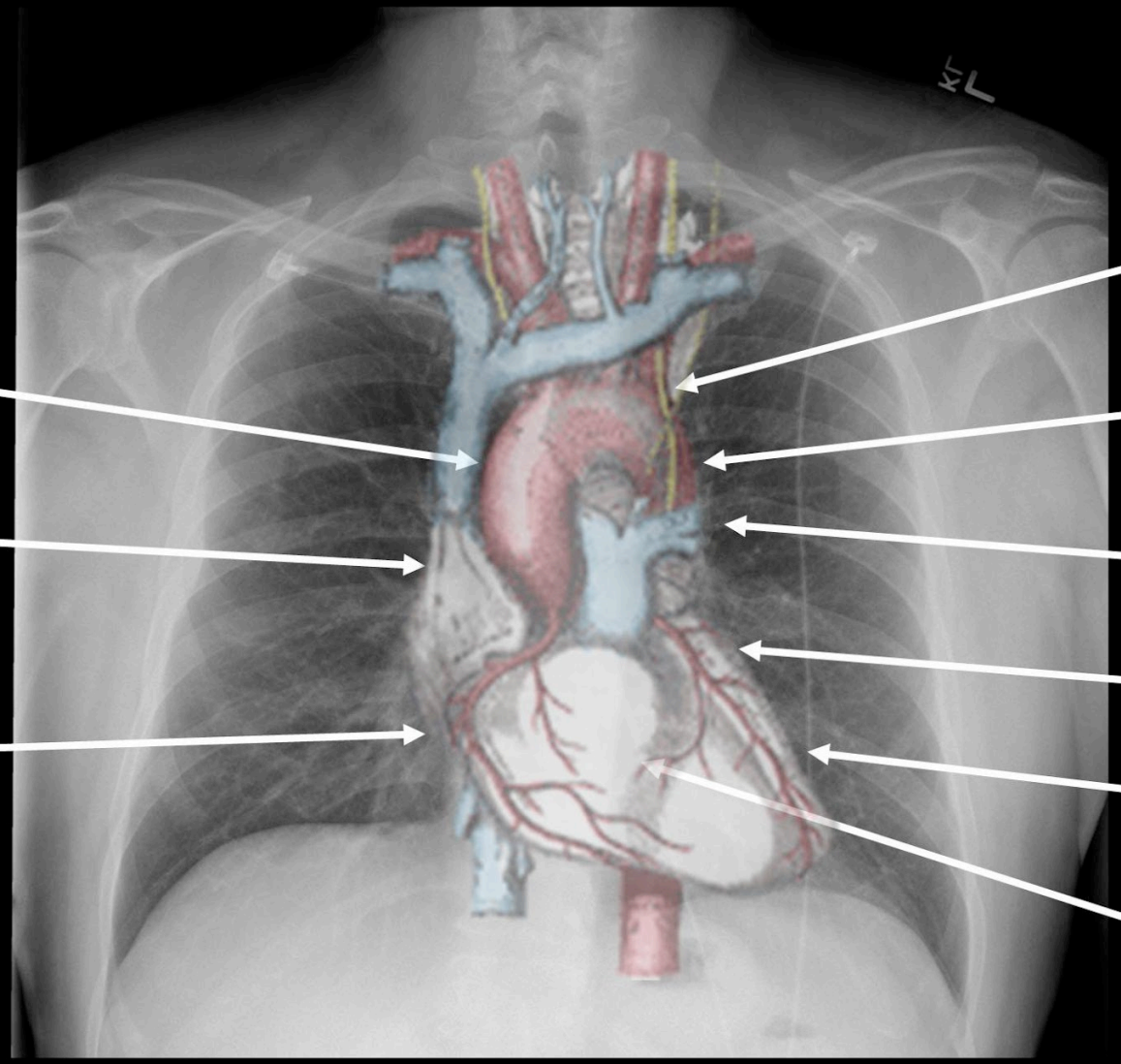

Ascending aorta

Right pulmonary artery

Right atrium

Aortic arch

Aortopulmonary window

Left pulmonary artery

Left atrium

Left ventricle

Descending aorta

Source: Wiki

Echocardiography

- Very first heart echocardiogram
- Inge Edler, Hellmuth Hertz 1953, Sweden
- One dimension, technically only information that "something is moving"

- Source: ww. med.lu.se

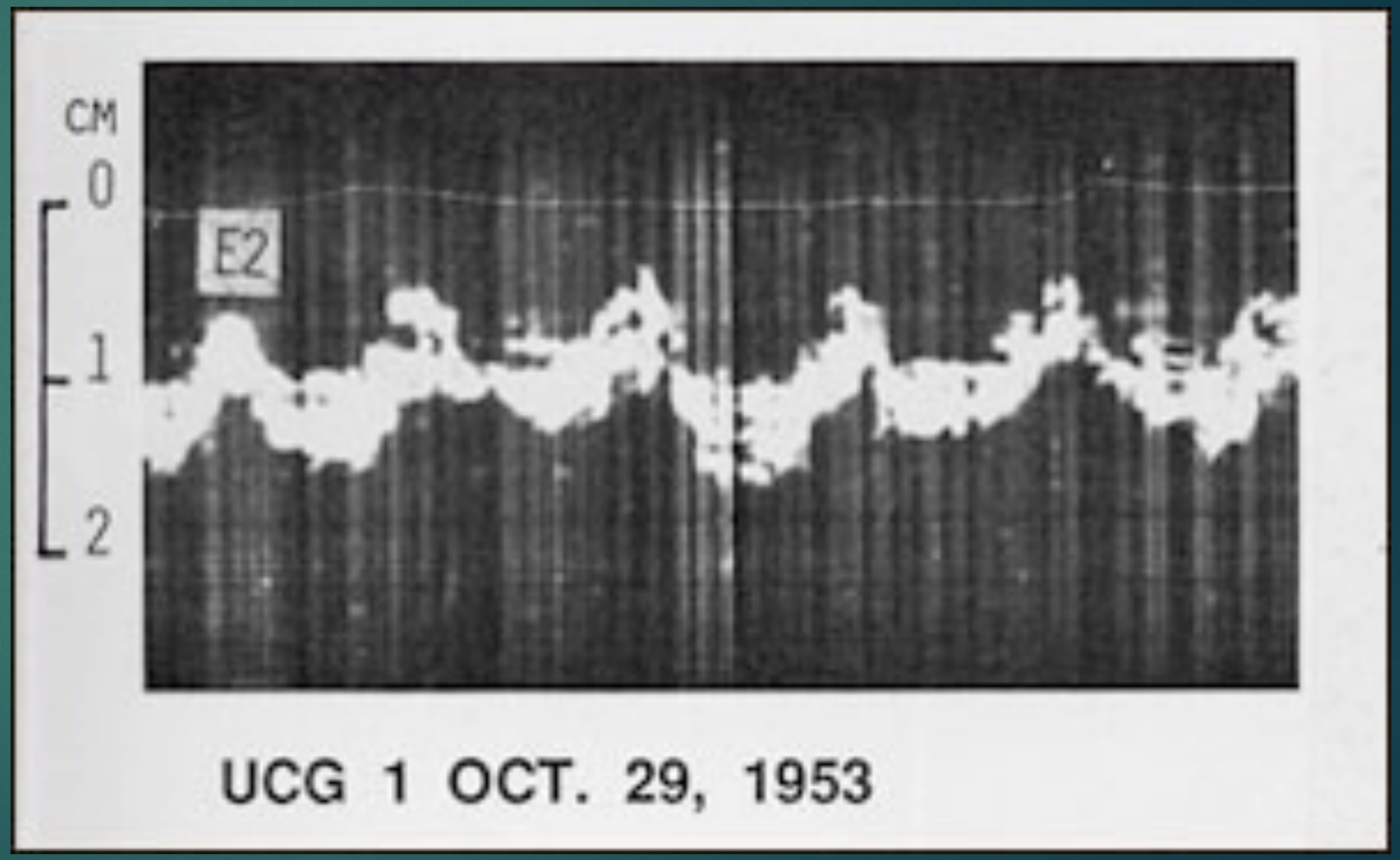

Echocardiography

- First line method at every cardiology department
- Basic knowledge, 300 ECHO needed for the cardiology board exam in Czech Republic

Echocardiography

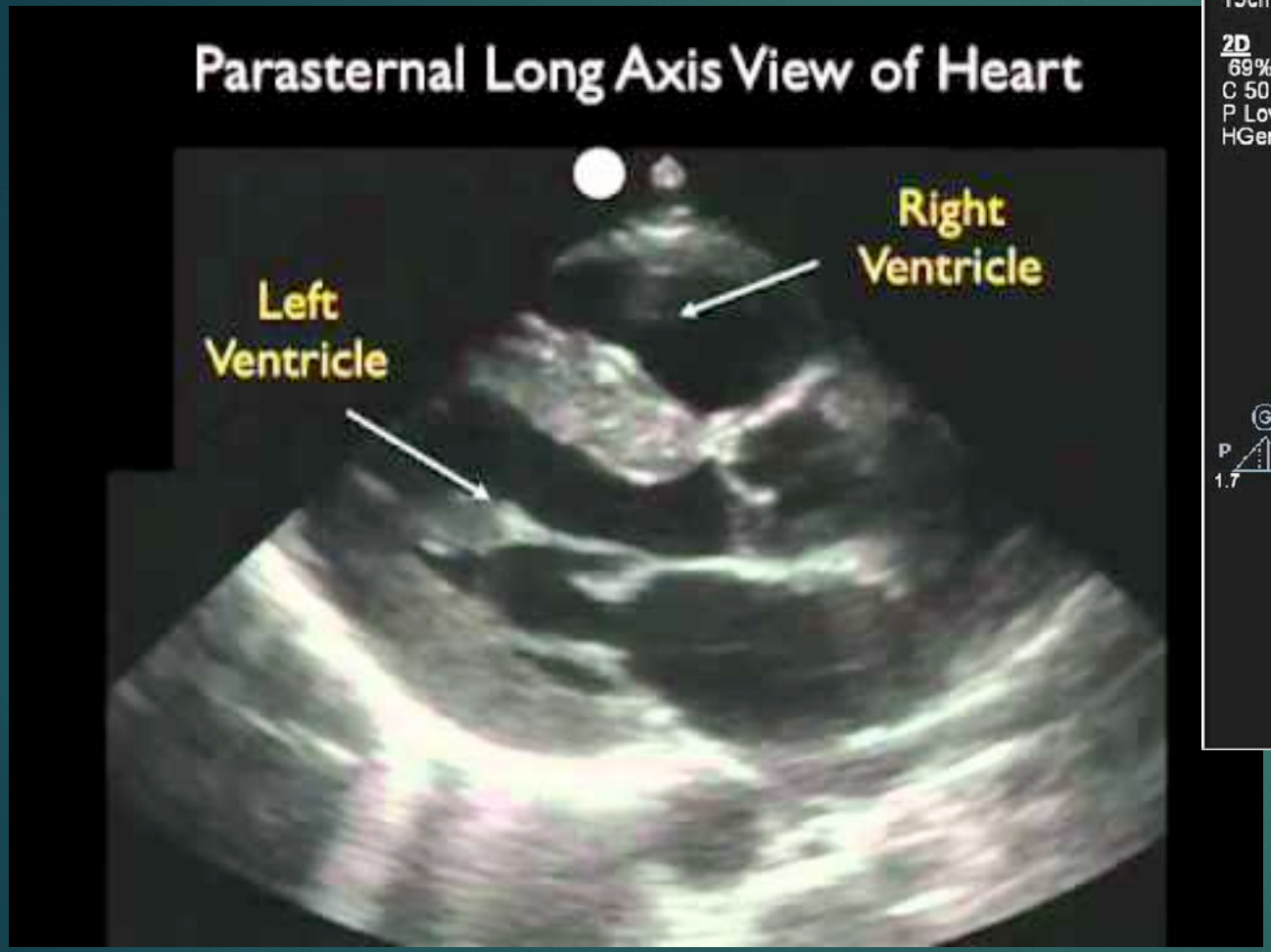

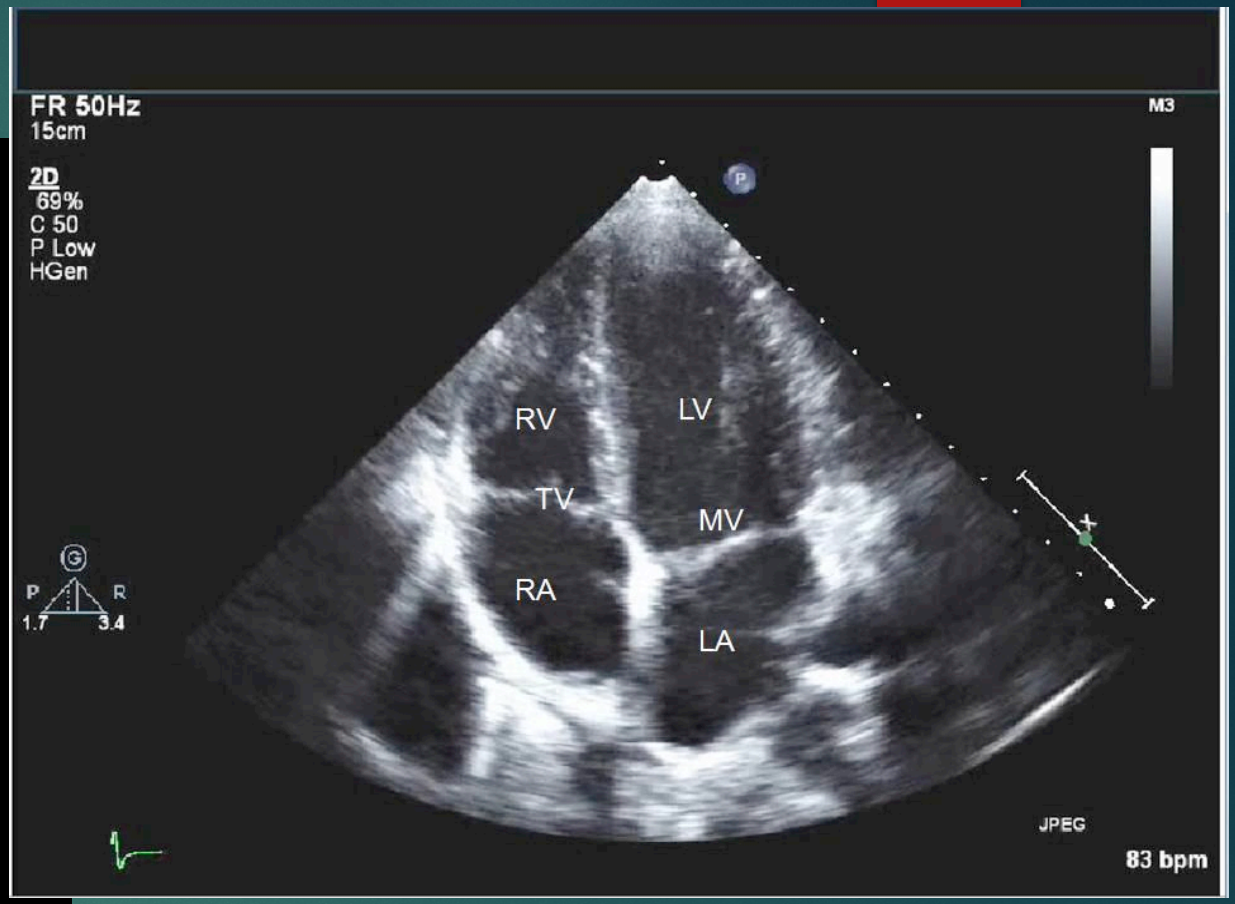

- wn.com, echocardiographer.com

Echocardiography

- Evaluation of morphology, kinetics, flow, valves, pericardium....

Stress echo

- Dobutamin in increased dose
- Comparing of kinetics in a different stages of stress test (different heart rates)

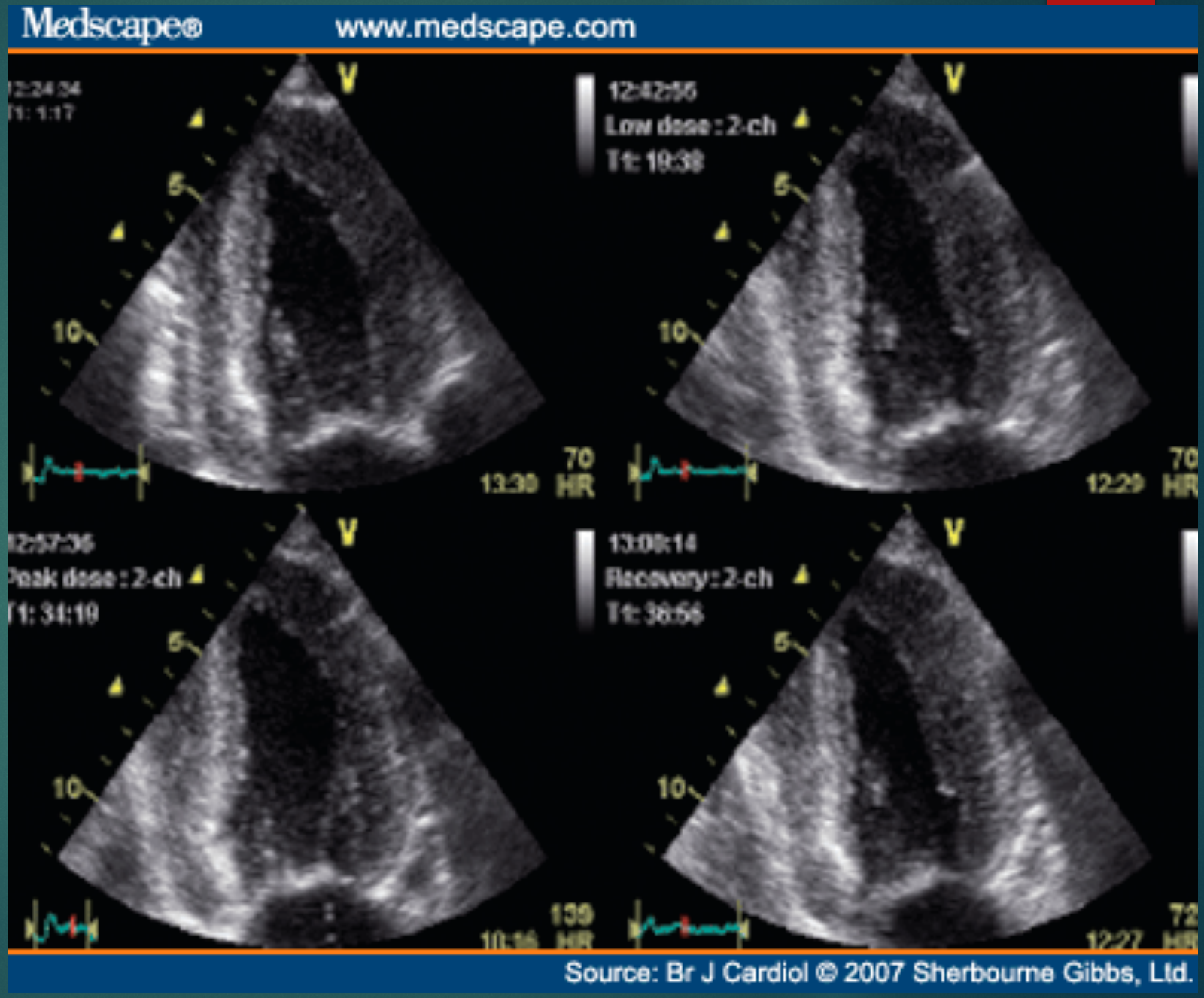

SPECT
- single photon emission computed tomography

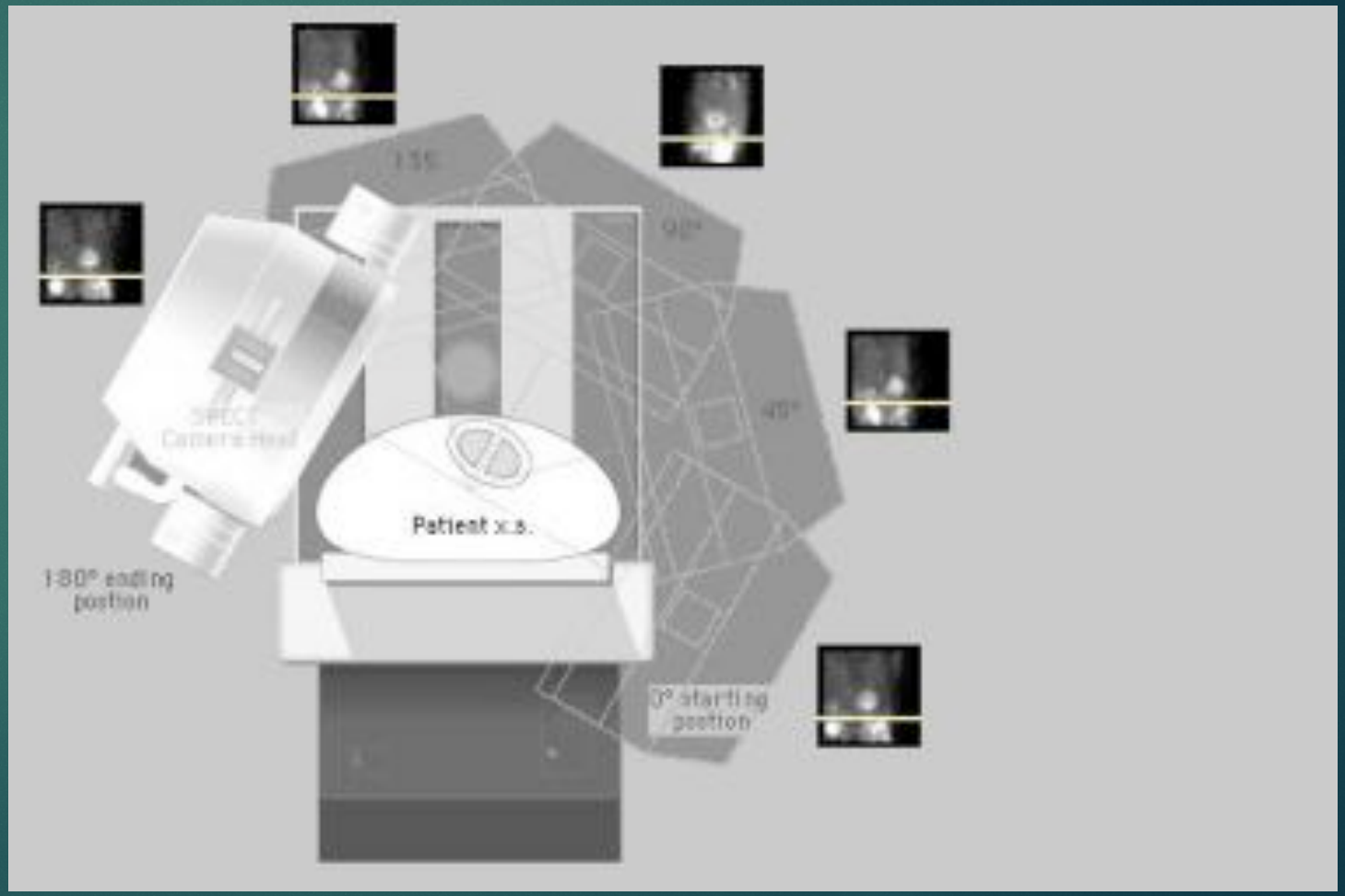

- Source: Medscape

SPECT

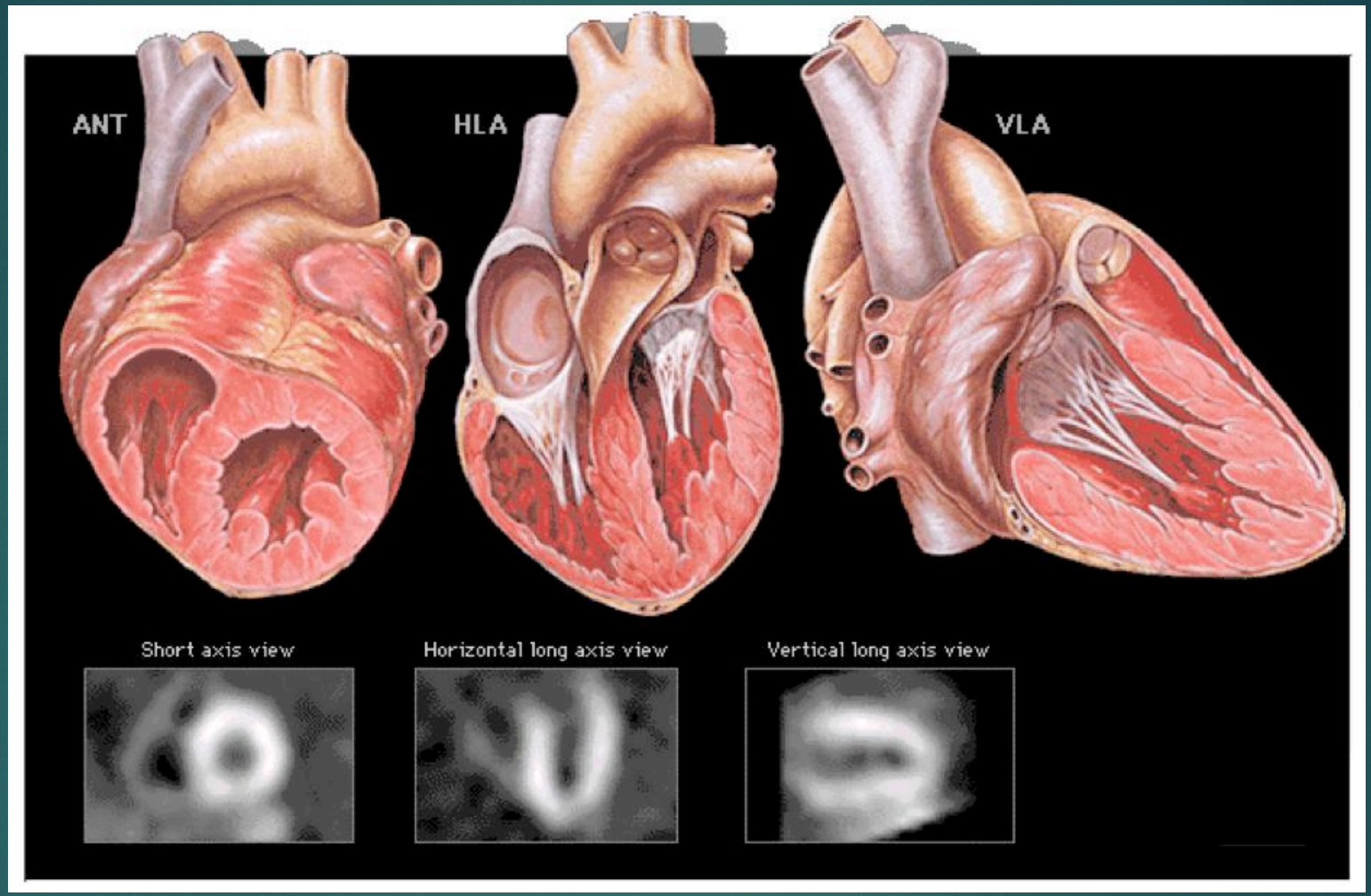

- Source: Medscape

SPECT

- Radionuclides used:
- Technecium 99m
- Thalium 201

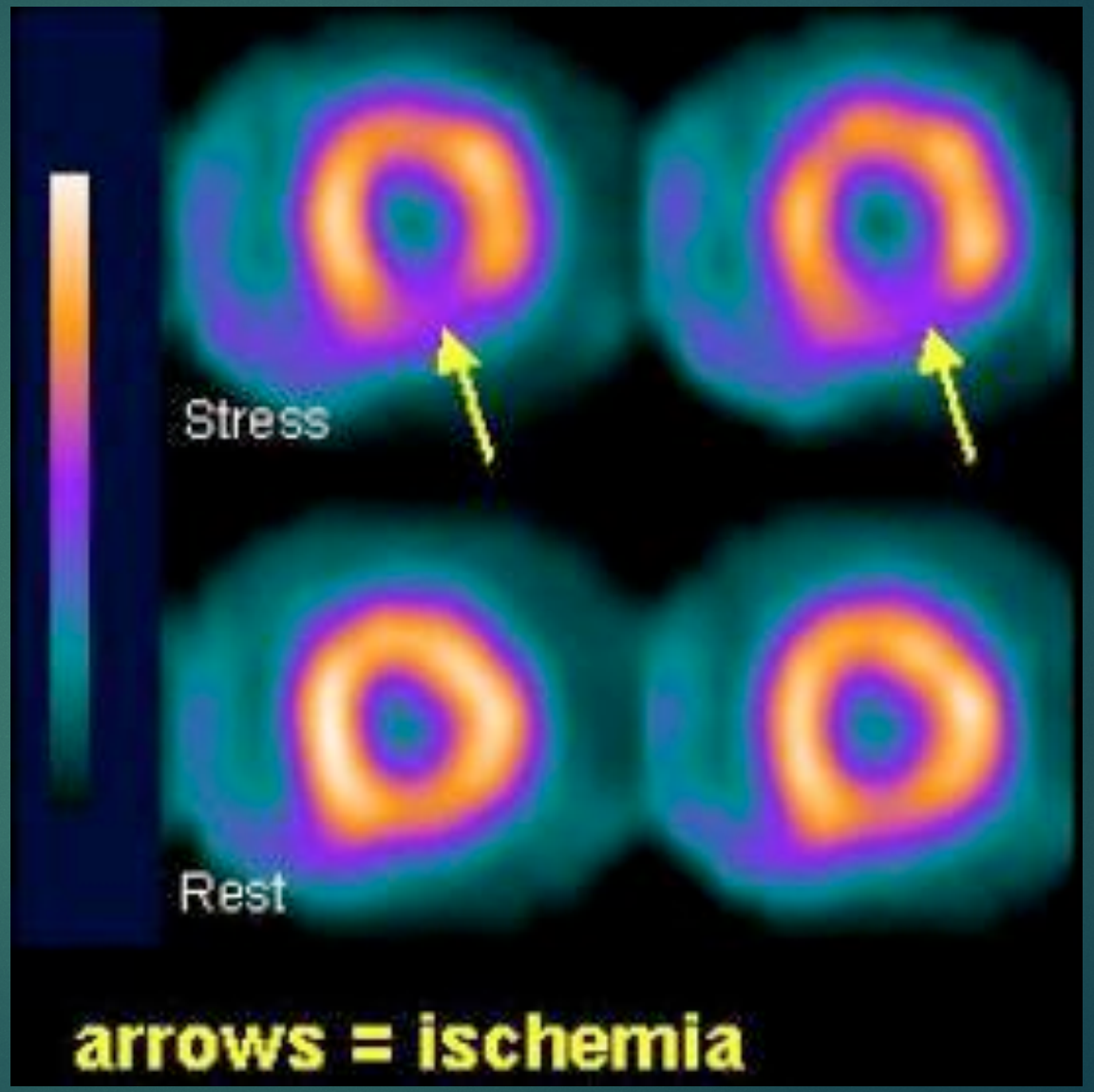

- Source: Medscape

SPECT stress test

- Aplication of dobutamine or adenosine for stress simulation
- Pros: very sensitive
- Cons: Radiation, emitter unstable - short halflife of emitter

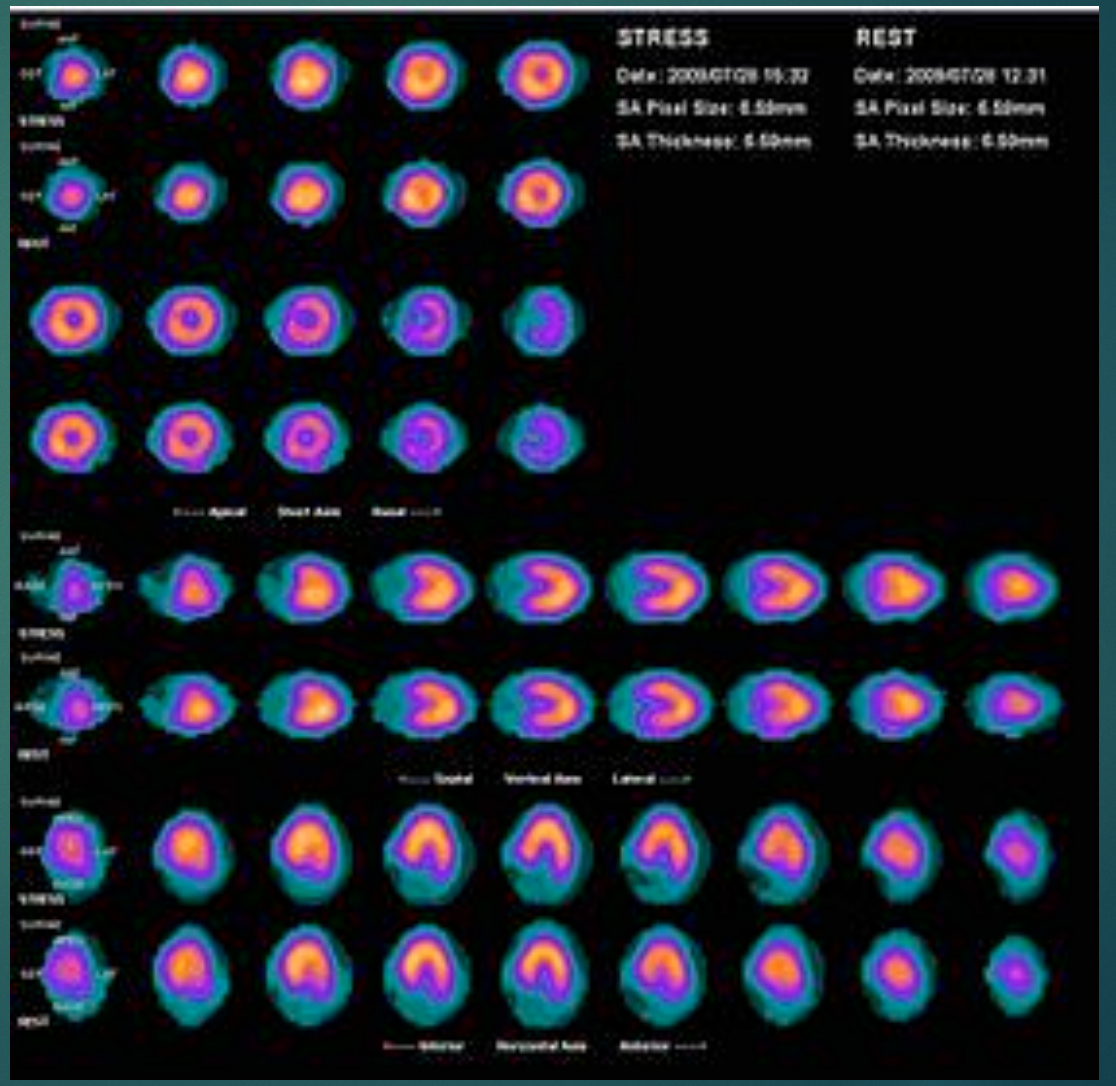

Cardiac CT

- Great resolution
- Indication: morphologic assessment, left atrium map, CT coronarography
- Cons: radiation, problems in tachycardia

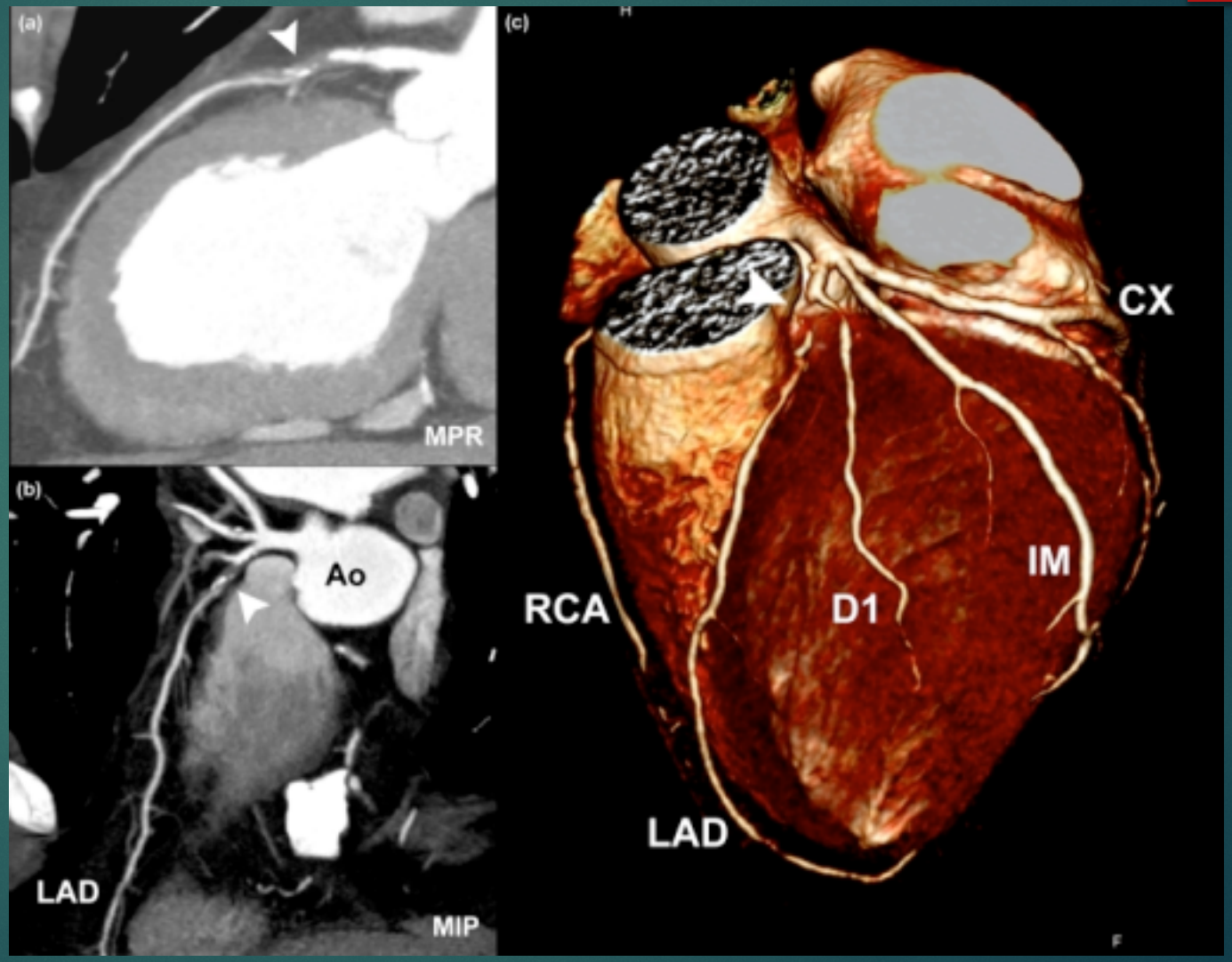

- Zdroj: researchgate.com

Cardiac CT

- CT 3D reconstruction of left atrium, fused with voltage map.
- Importance for radiofrequency ablations in EP procedures

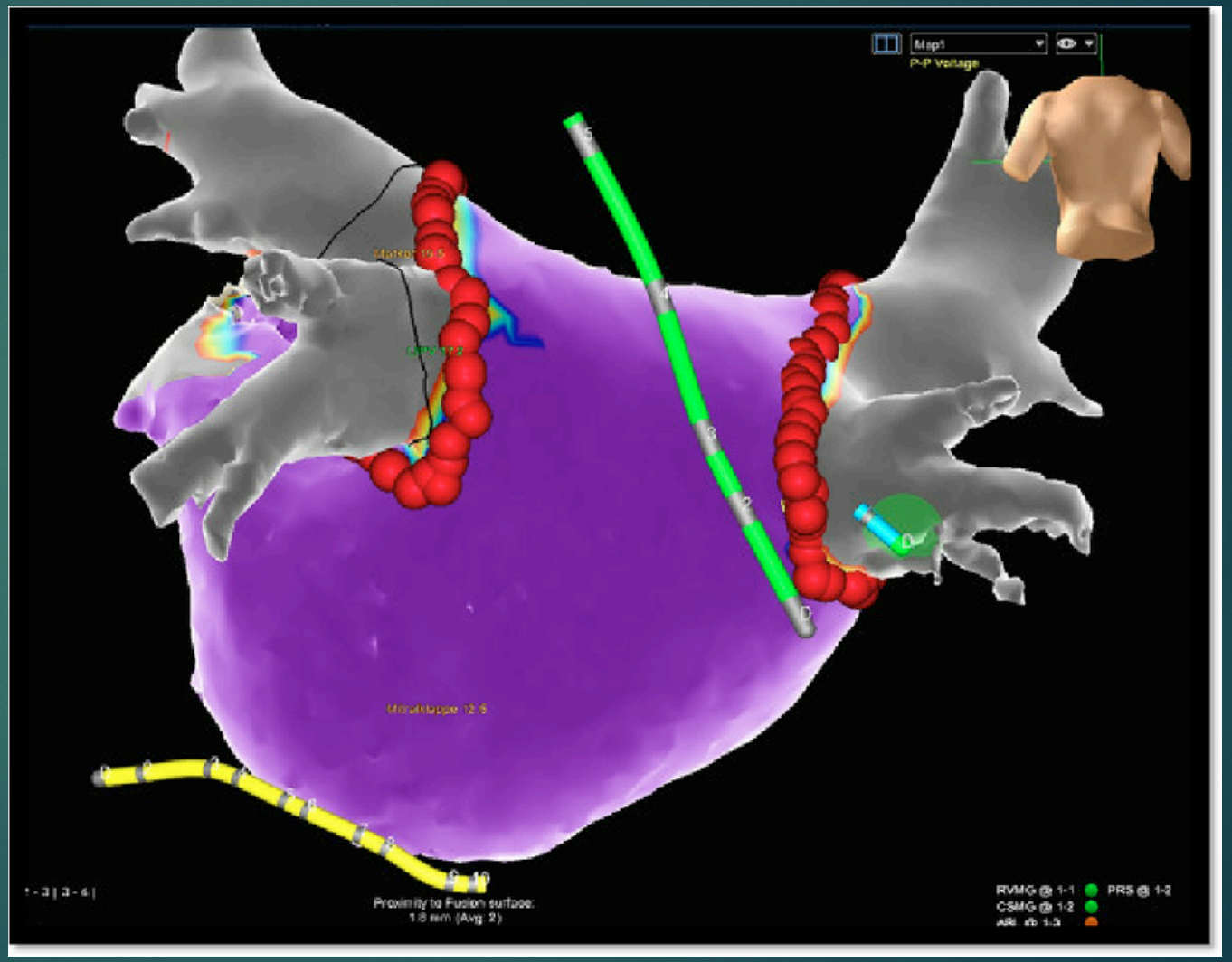

CT coronarography

- A
  - 3-Dimensional volume-rendered image
  - after left internal mammary graft to middle segment of left anterior descending coronary artery (arrowheads).
  - Operative clips are visualized parallel to course of graft.
  - venous coronary bypass graft can be seen between aorta and left circumflex coronary artery (arrows).
- B
  - Curved MPR image with sharp image filter reconstruction of right coronary artery in patient with percutaneous stent placement (arrowhead).
  - Lumen of stent (3.5-mm diameter) is patent.

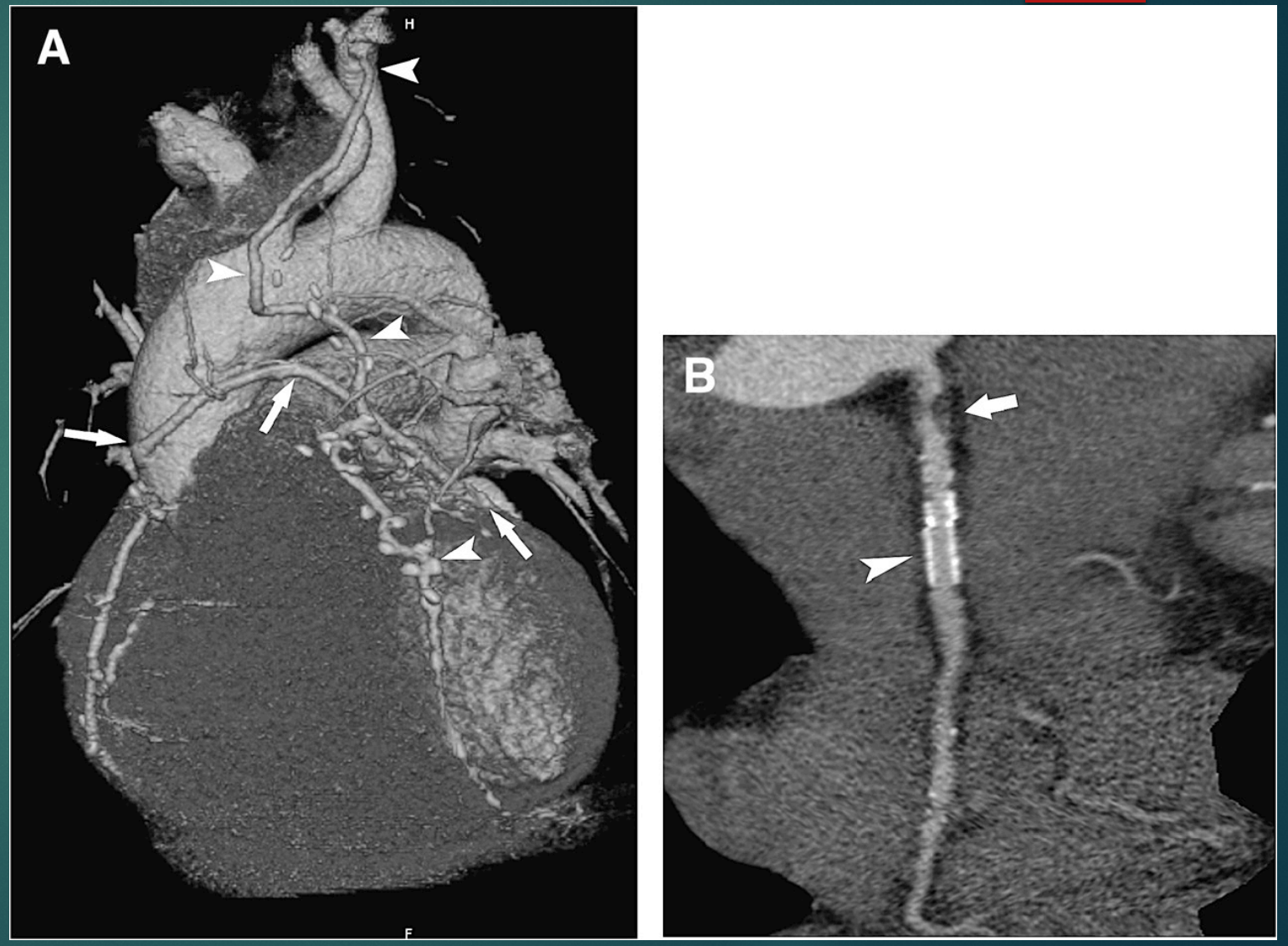

Cardiovascular MRI

- Good resolution, no radiation dose, evaluation of morphology, structure, viability, valves, flow
- Problems of MRI gating in tachycardia

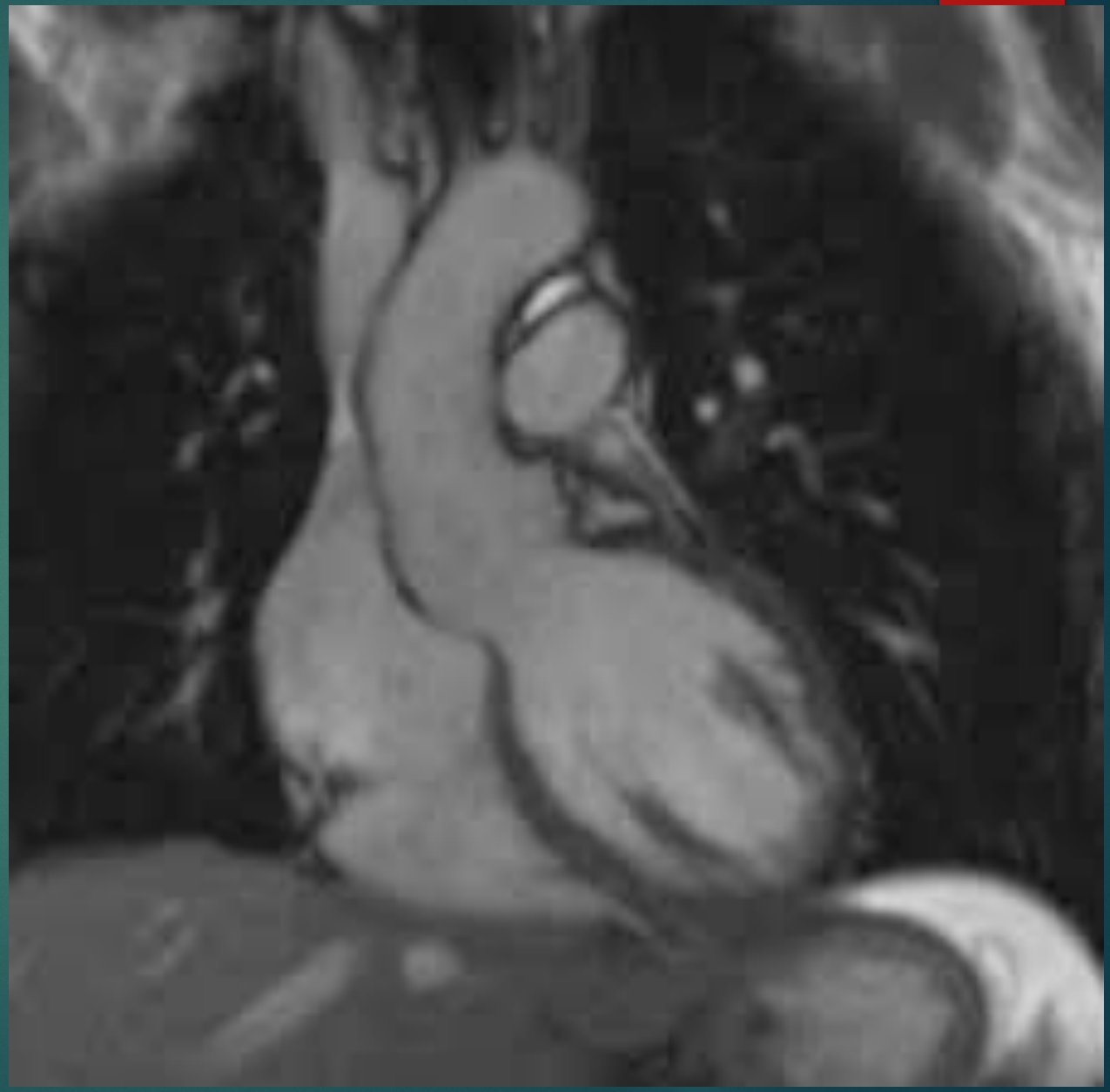

Cardiovascular MRI – stress test

- Adenosin continuous infusion for inducing maximum hyperemia
- Gadolinium contrast fluid
- Evaluation of differences in perfusion
- MRIquestions.com

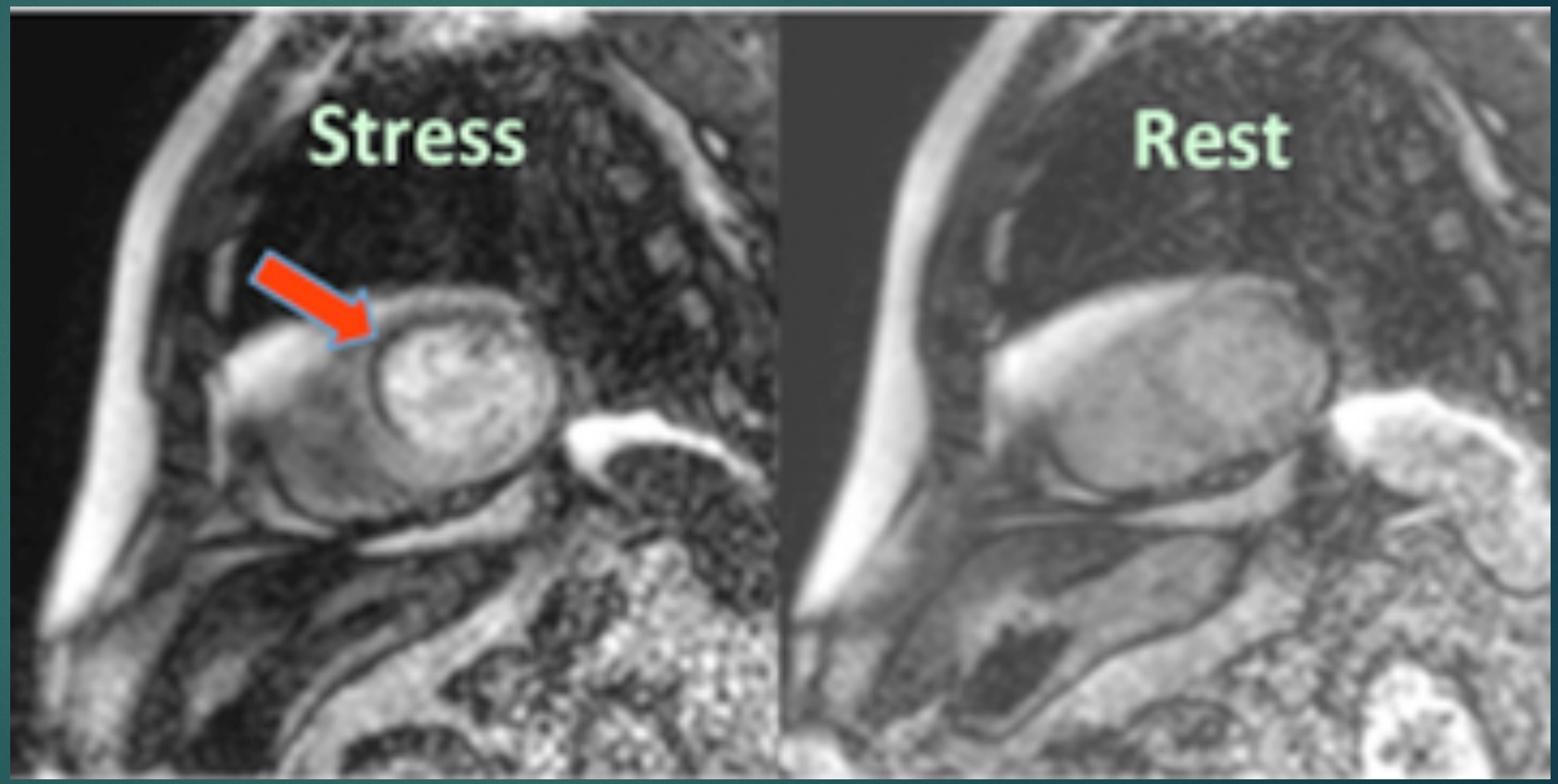

Cardiac Catheterization





Intravascular Imaging
IVUS – intravascular ultrasound

Normal Arterial Wall

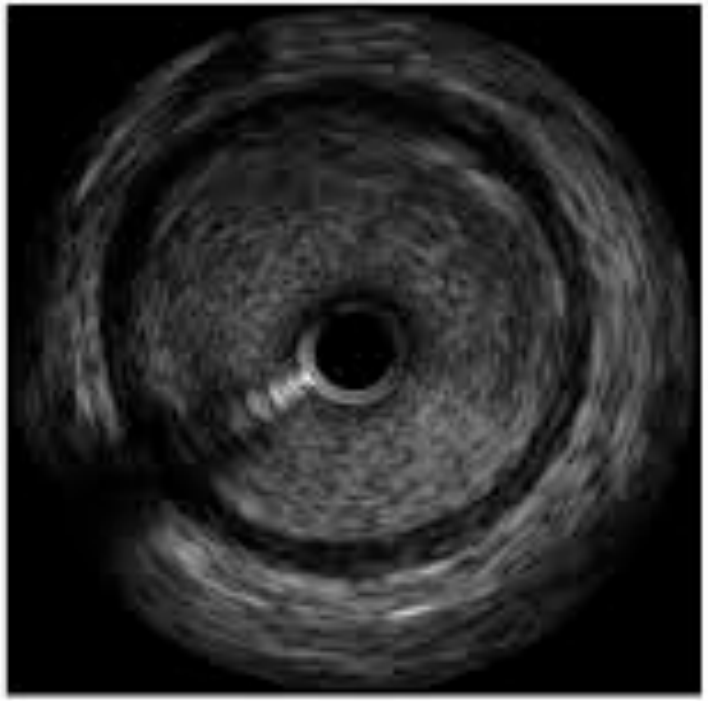

Stable And Vulnerable Plaques.

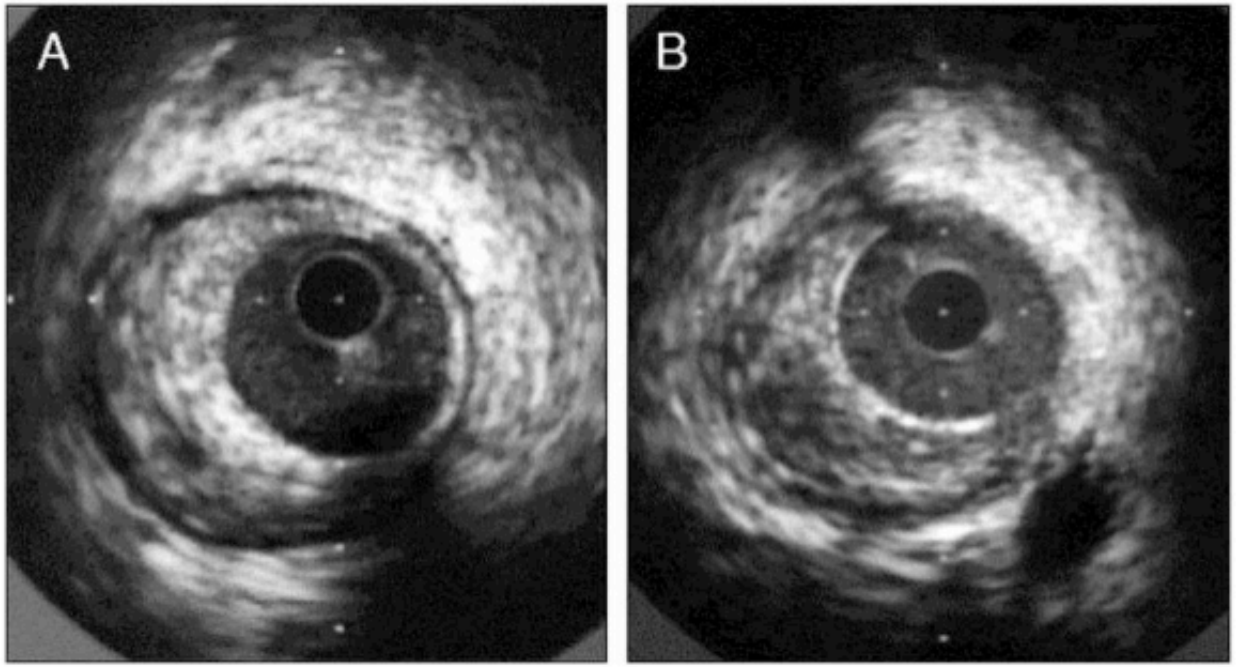

- Slideshare.net

Intravascular Imaging
OCT optical coherence tomography



Intravascular Imaging
OCT optical coherence tomography

- Analysis of the vessel pre-PCI
- Method with very high spatial resolution (10um)
- Excellent for guiding percutaneous coronary interventions

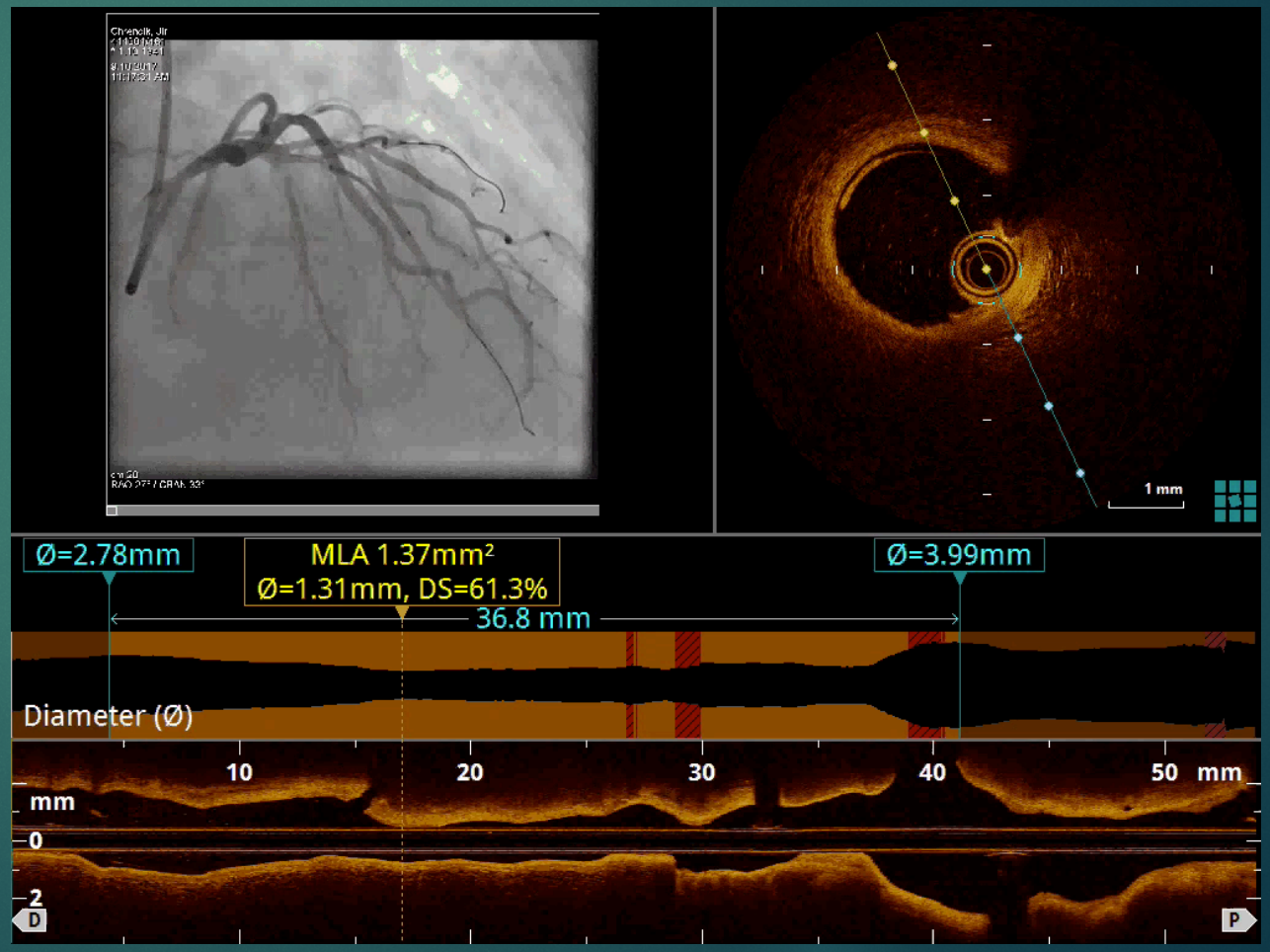

Intravascular Imaging
OCT optical coherence tomography

- Analysis of post-PCI stent deployment

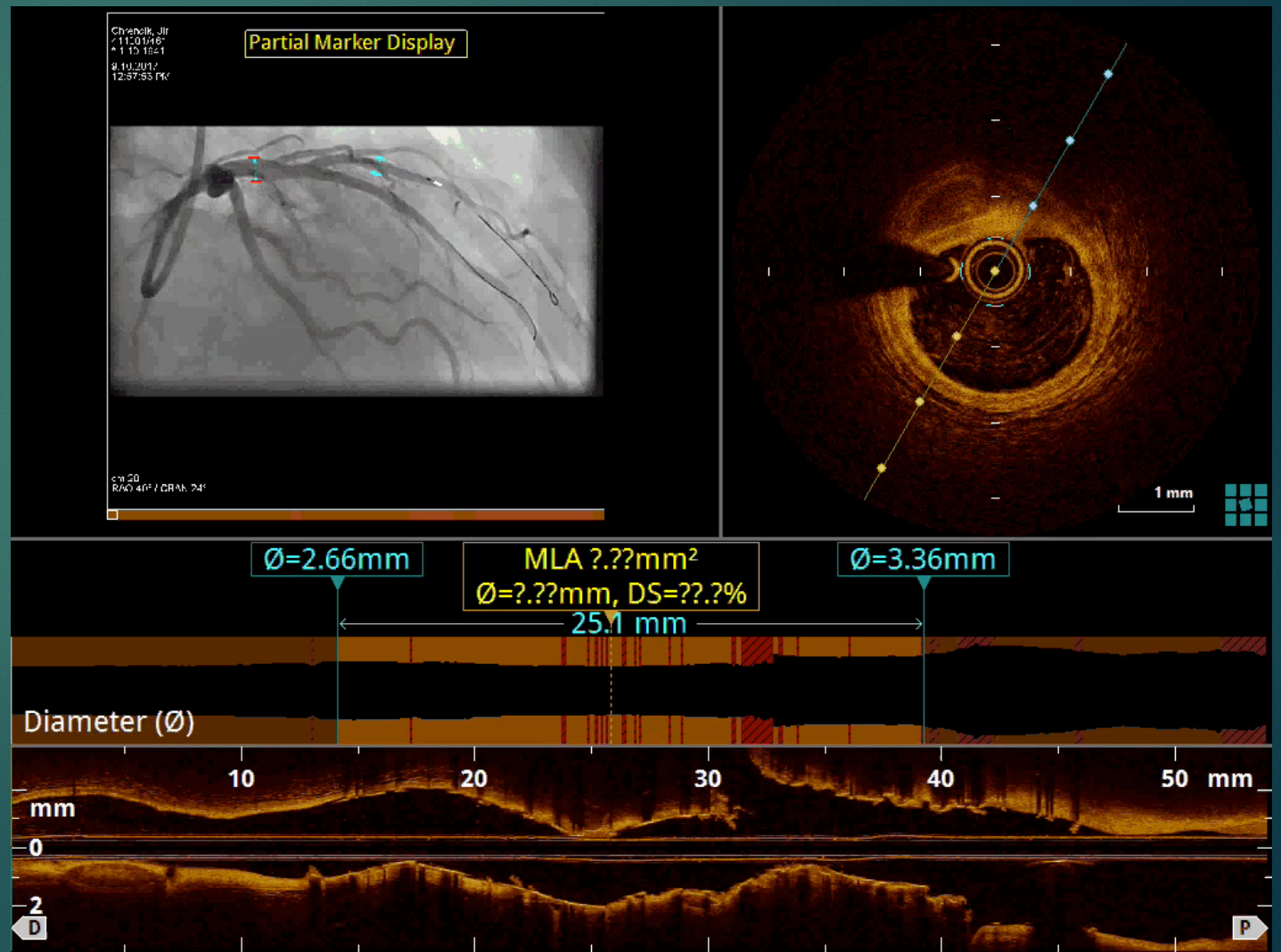

Intravascular Imaging
OCT optical coherence tomography

- 3D reconstruction

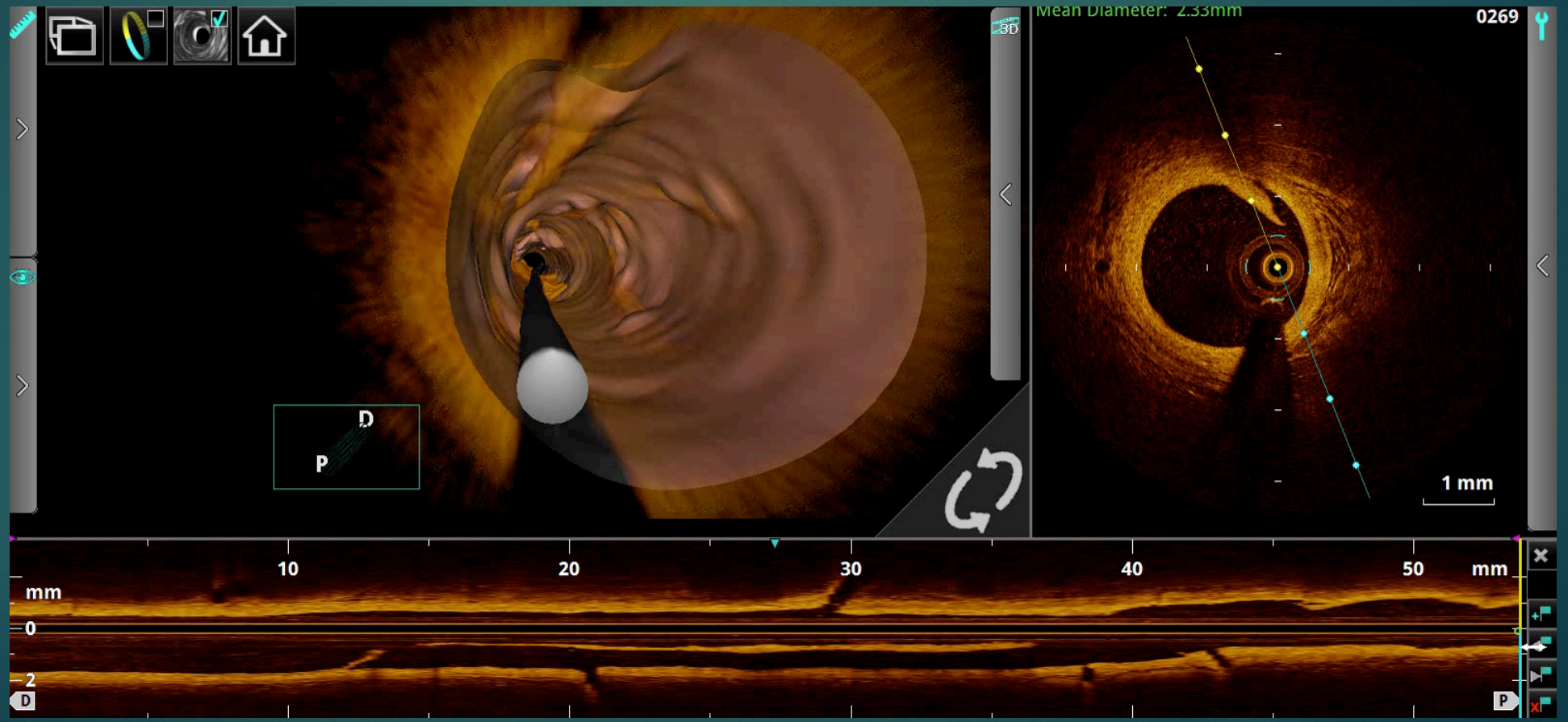

Thank you for your attention

