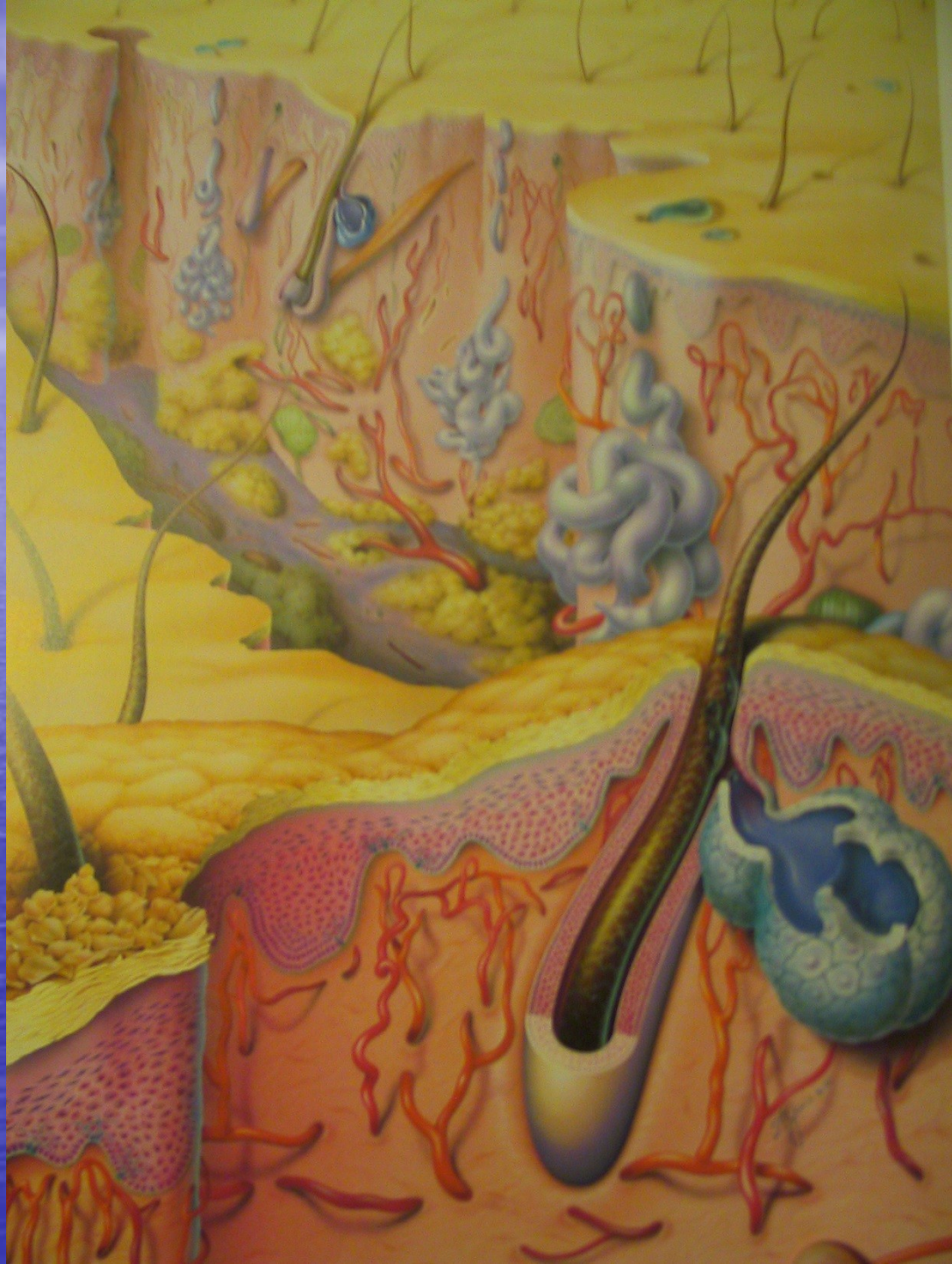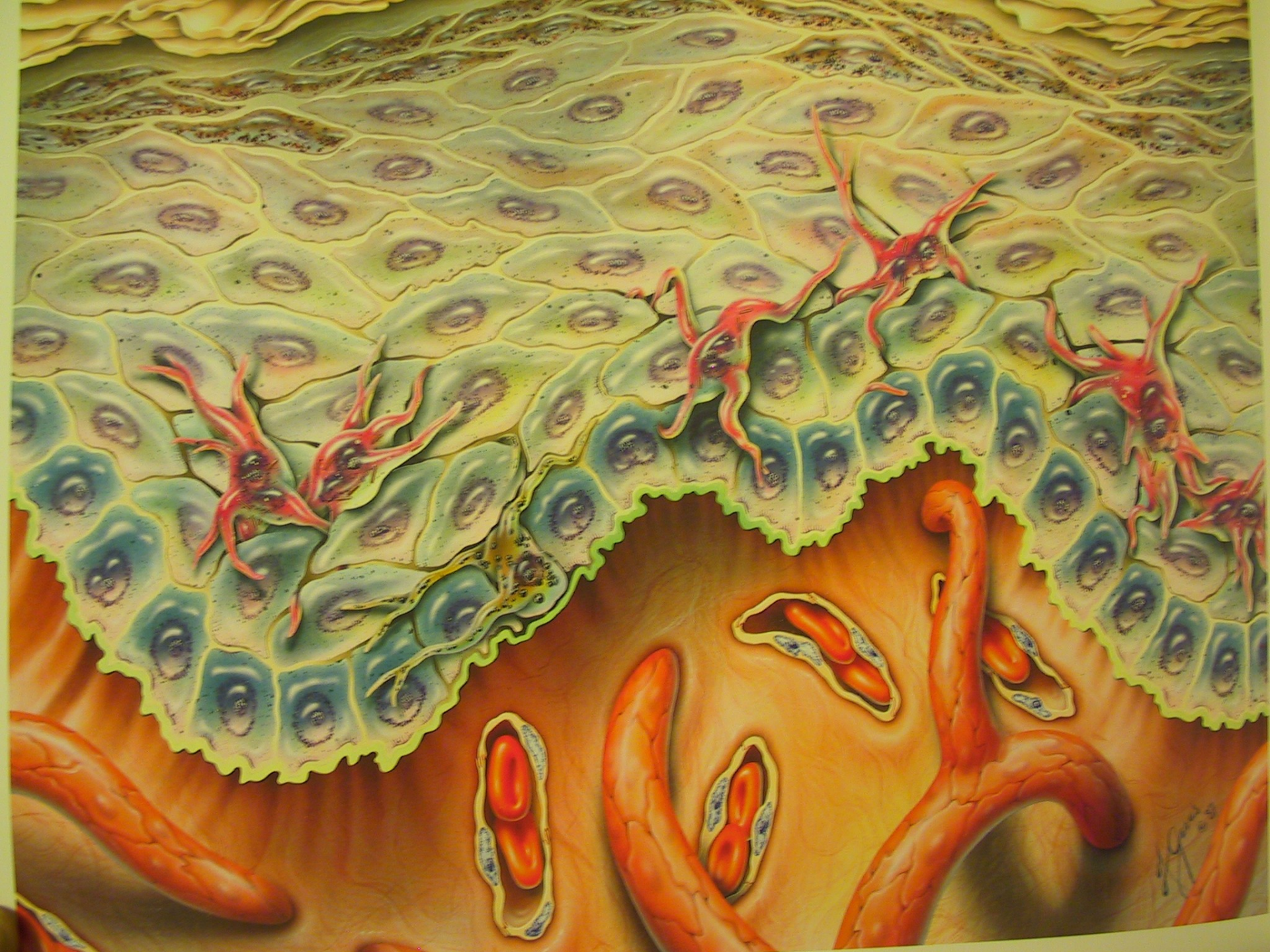
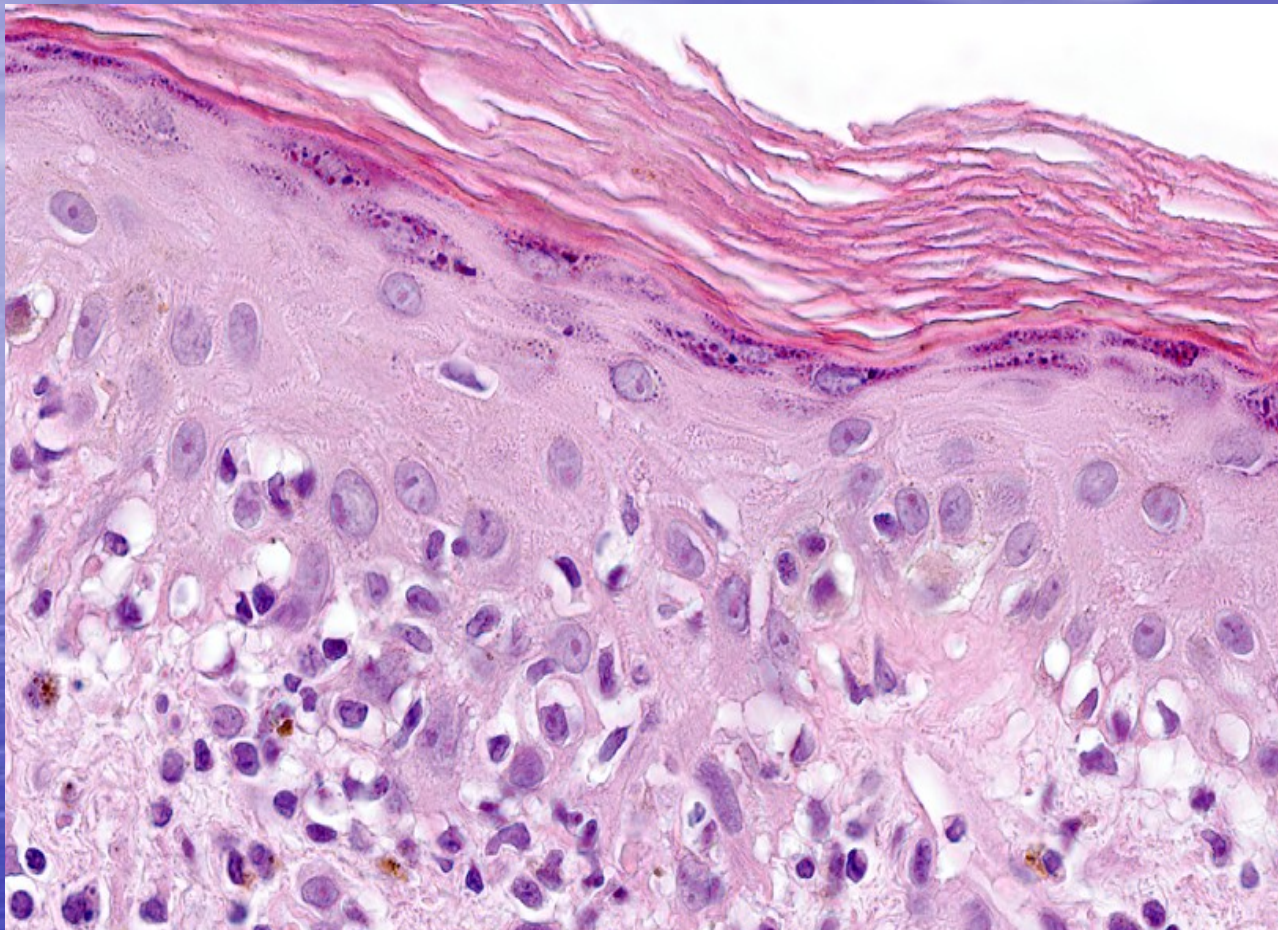


Morfologie kožních změn









<http://www.muni.cz/atlas>

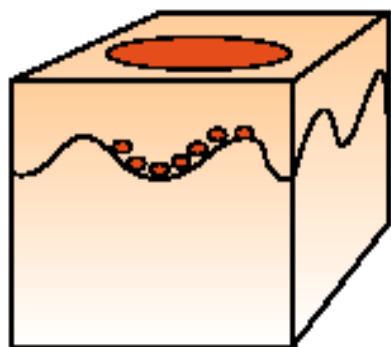
Morfy * Eflorescence * Výkvětky

- **Primární morfy**
- **Sekundární morfy**
- **Plošné změny**

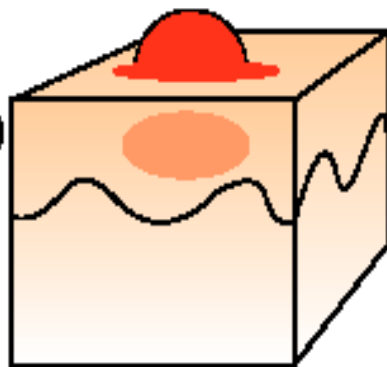
- Ložisko – vznik splýváním morf
- Exantém – generalizované, symetrické projevy
- Enantém – projevy na sliznici

Primární morfy

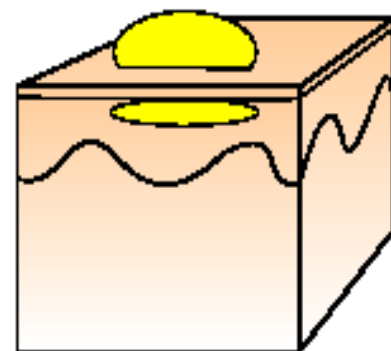
Makula
(Lentigo)



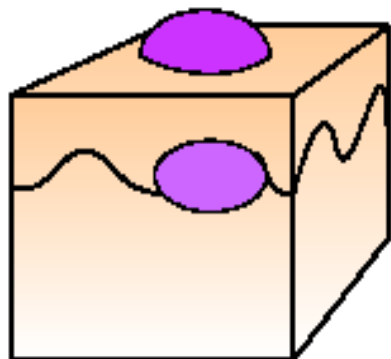
Papula
(Ekzémová)



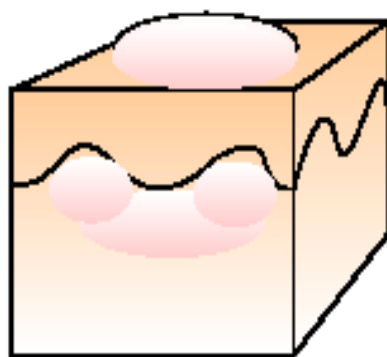
Pustula
(Subkorneální)



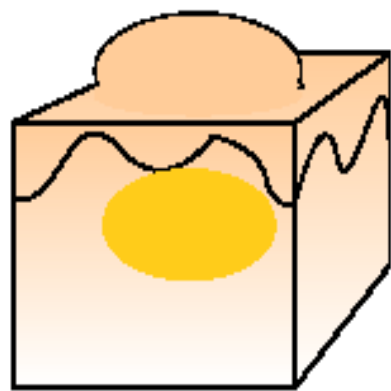
Vezikula

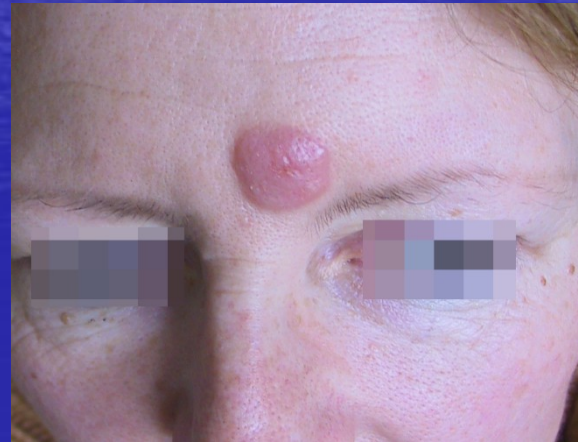
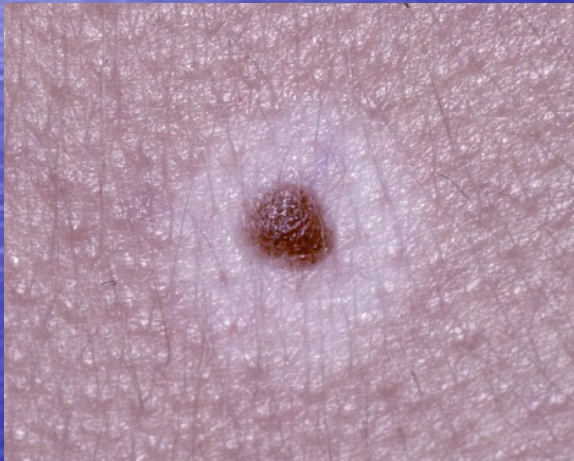
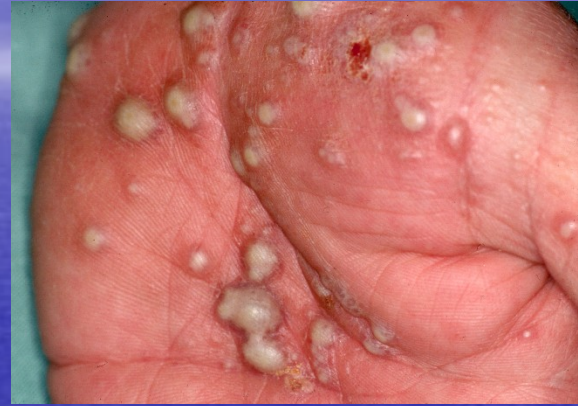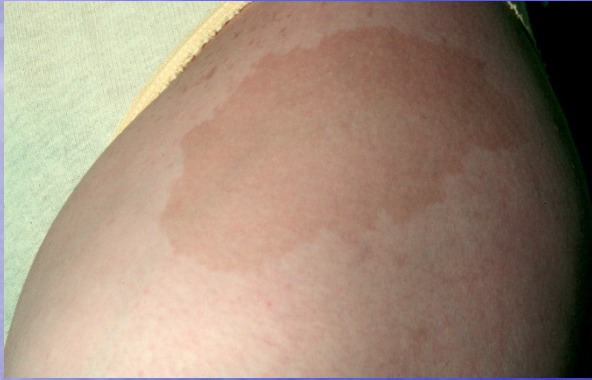Pomfuz



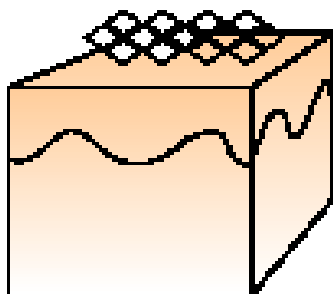
Tuber



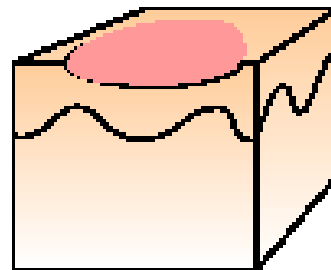


Sekundární morfy

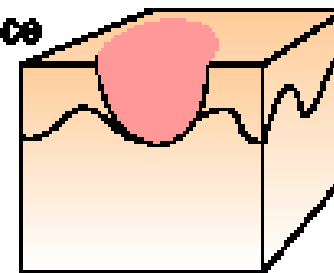
Šupina



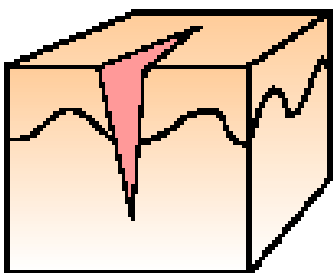
Eroze



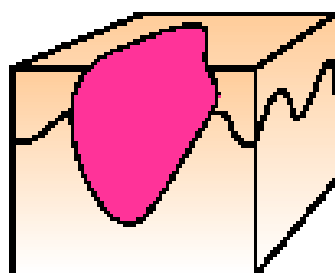
Exkorlace



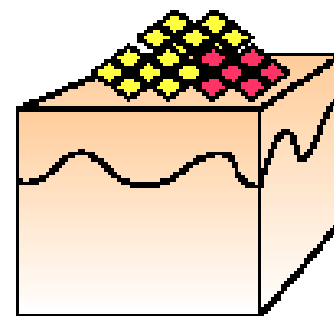
Ragáda



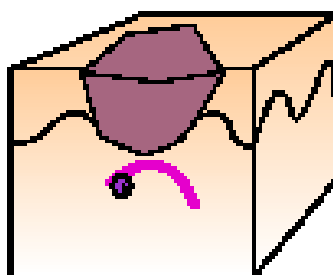
Ulkus

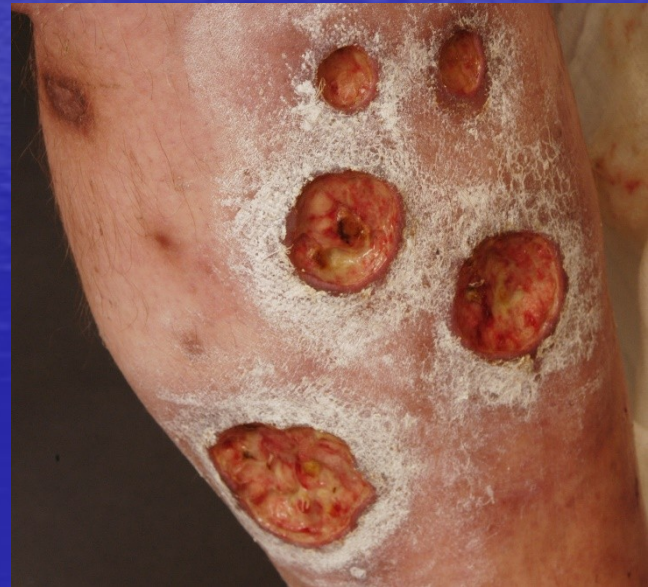
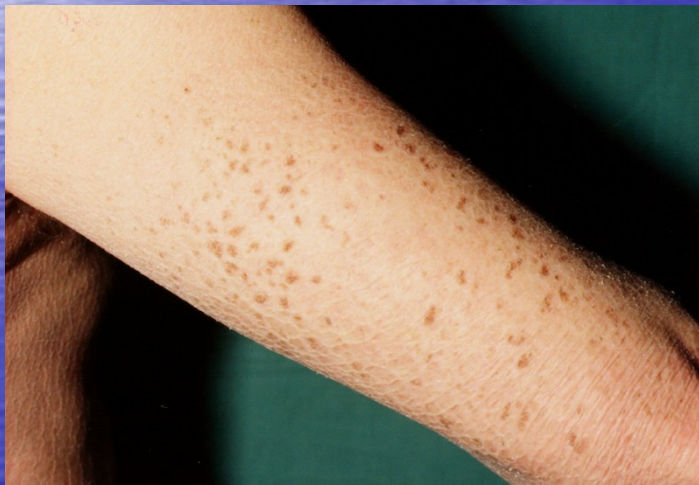
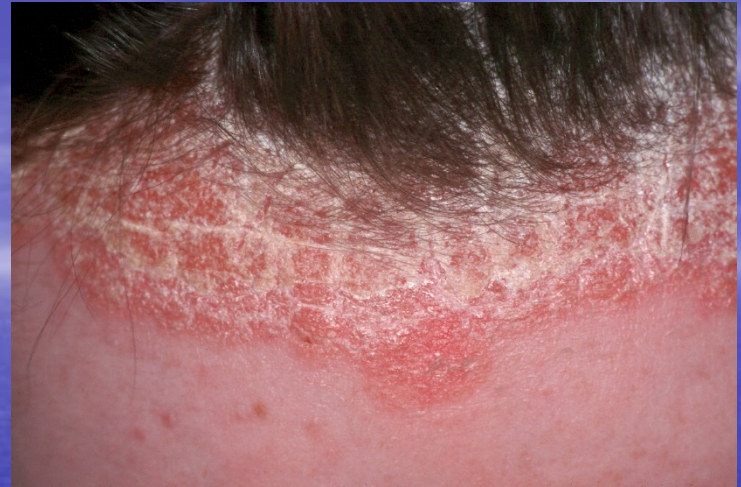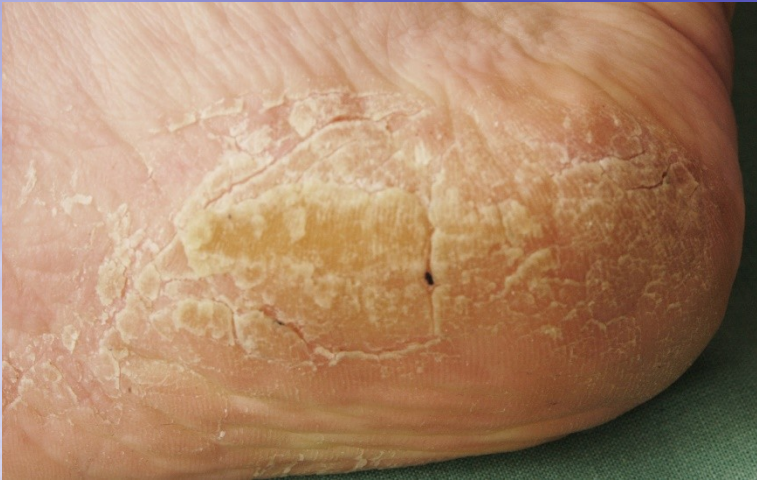Krusta



Eschara



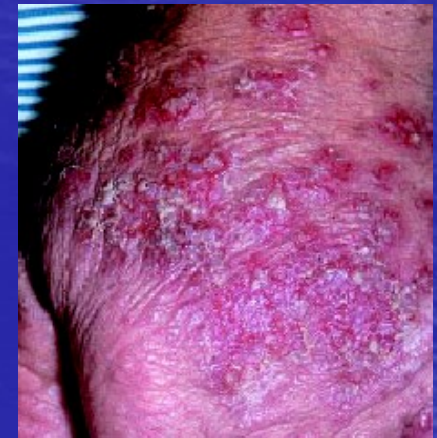
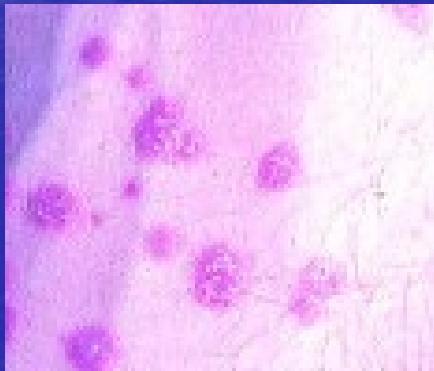
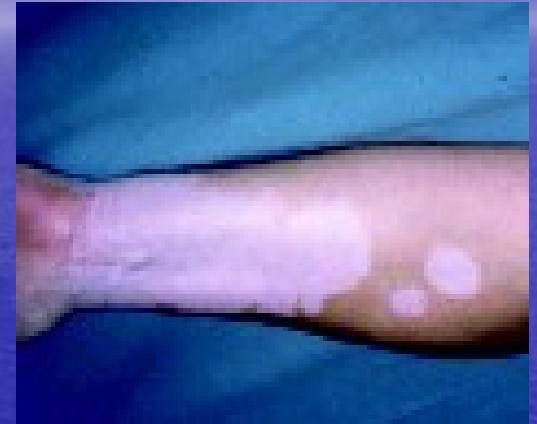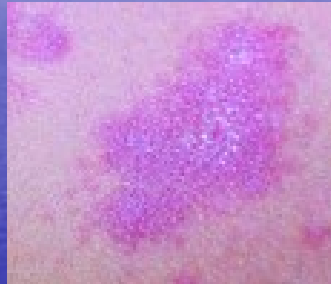Plošné změny

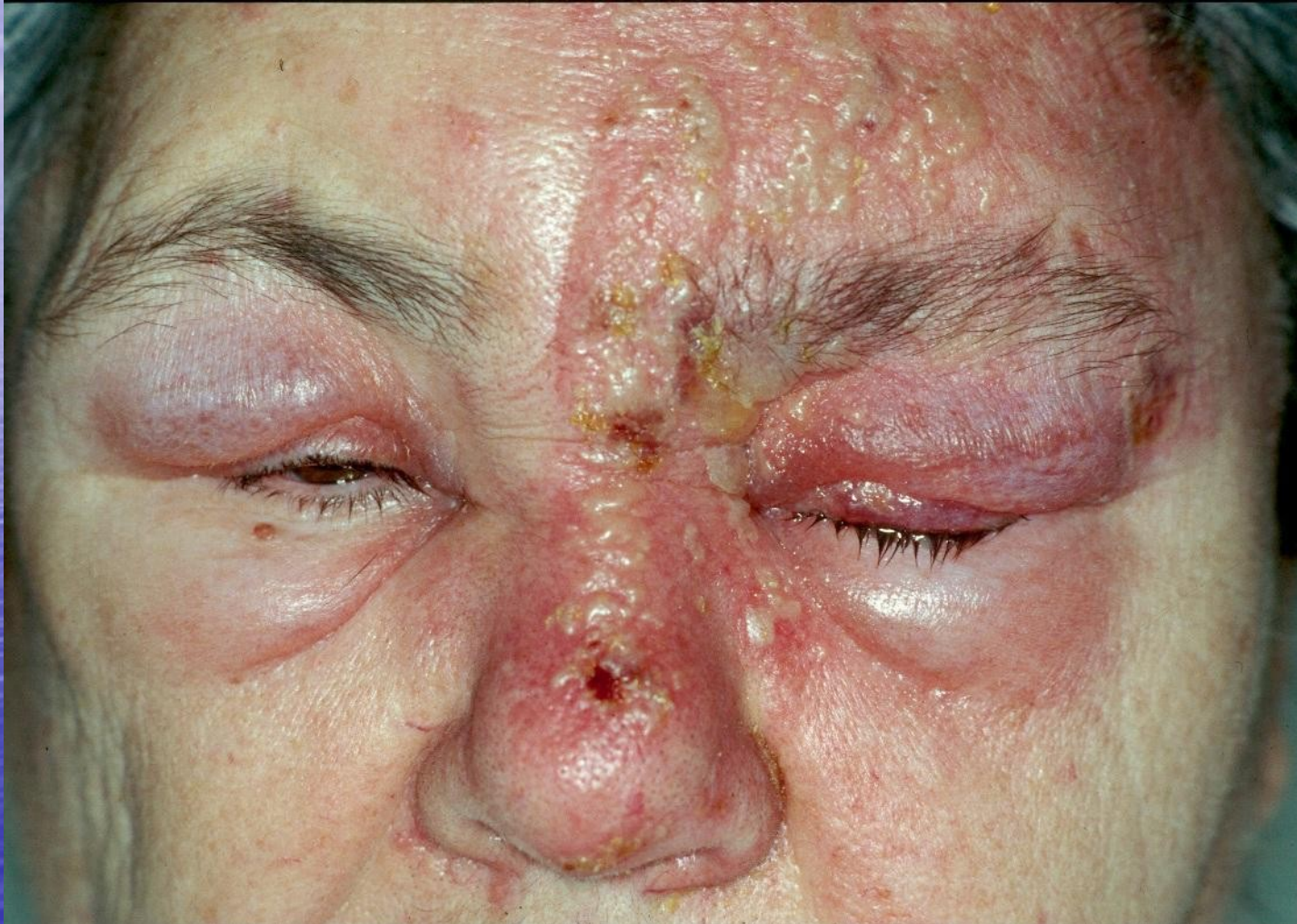- Erytém
- Lividní zbarvení
- Hyperpigmentace, depigmentace
- Atrofie, hypertrofie, jizva
- Skleróza
- Purpura
- Lichenifikace
- Poikilodermie

Popis lézí

- Velikost
- Barva
- Konzistence
- Ohraničení
- Povrch
- Pravidelnost

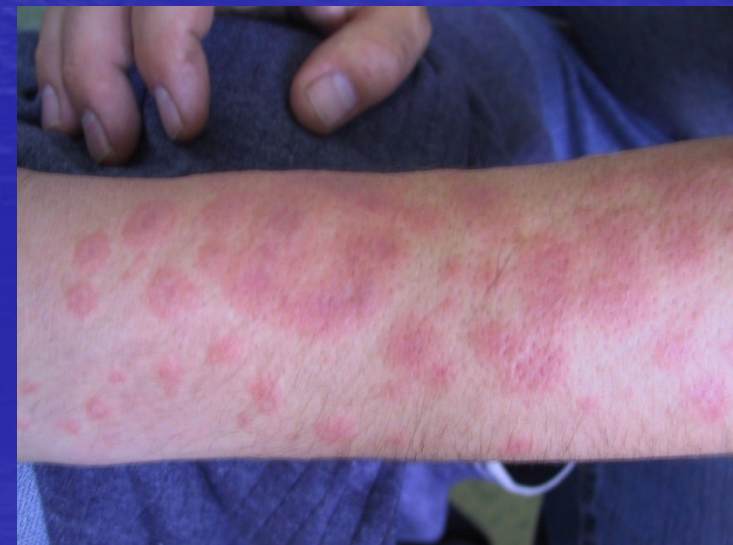
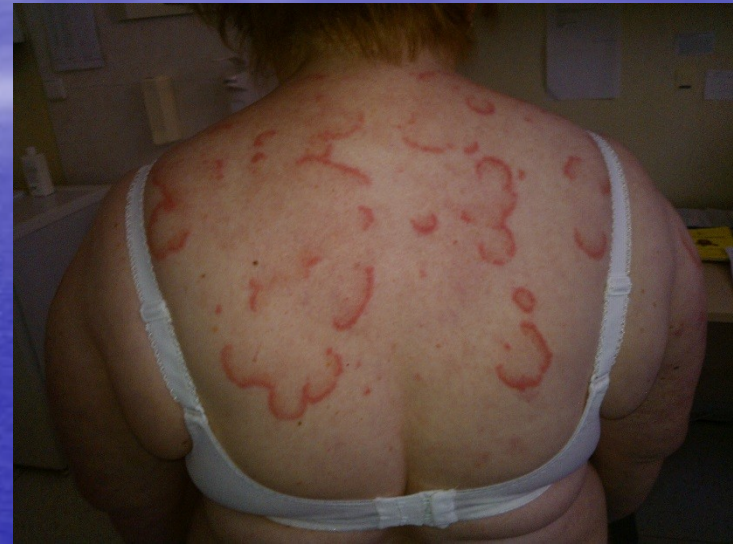
Herpes zoster ophthalmicus

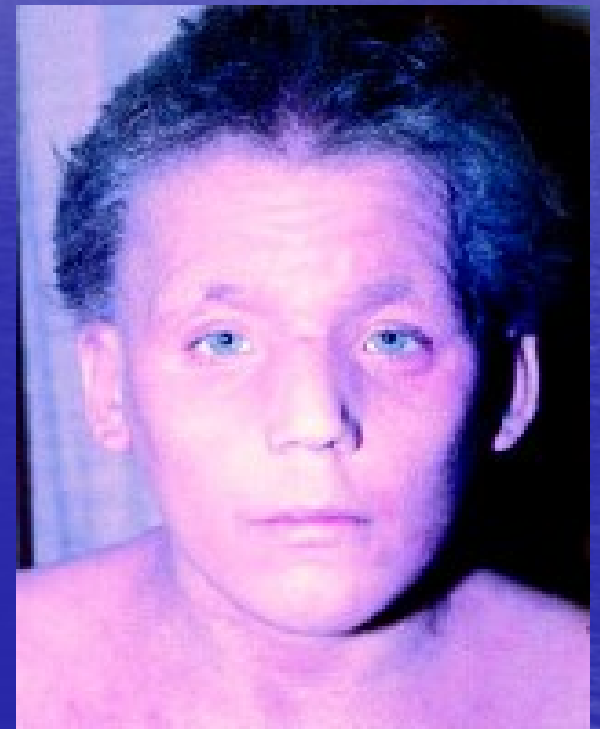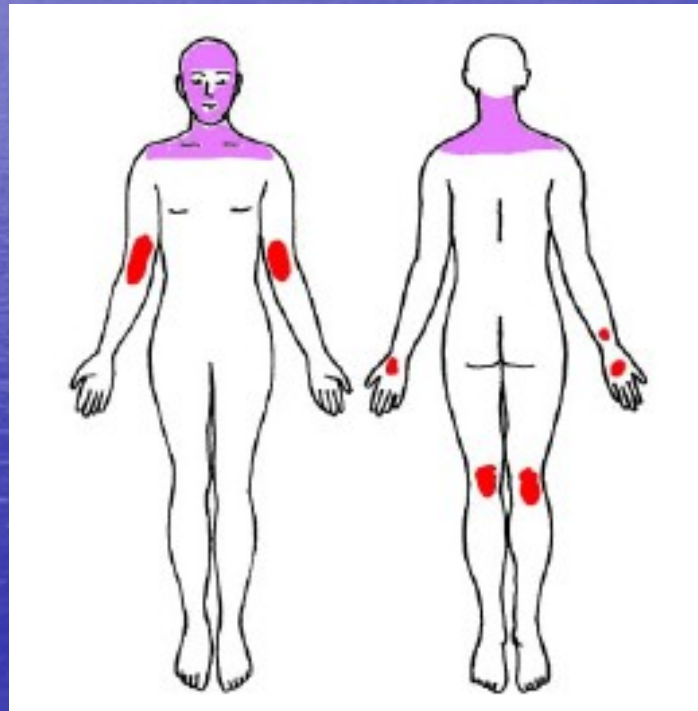



Konfigurace lézí

- Anulární, circinární
- Diseminované
- Ekzémové hromádky
- Folikulární
- Generalizované
- Geografické
- Herpetiformní
- Irisovité
- Lineární
- Kribriformní
- Numulární a diskoidní
- Serpiginózní
- Zosteriformní



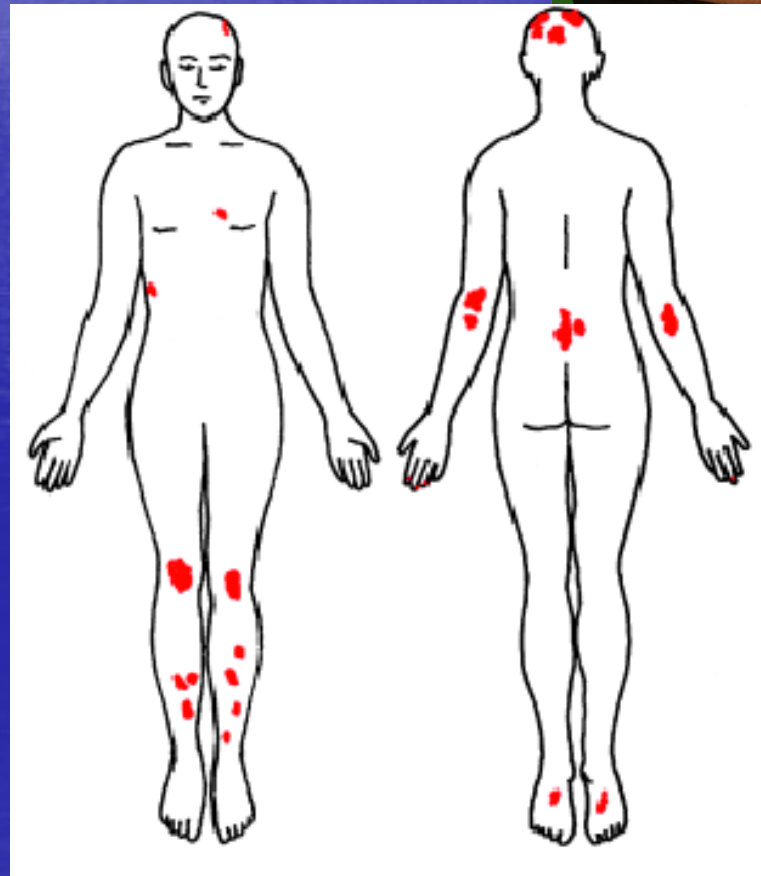
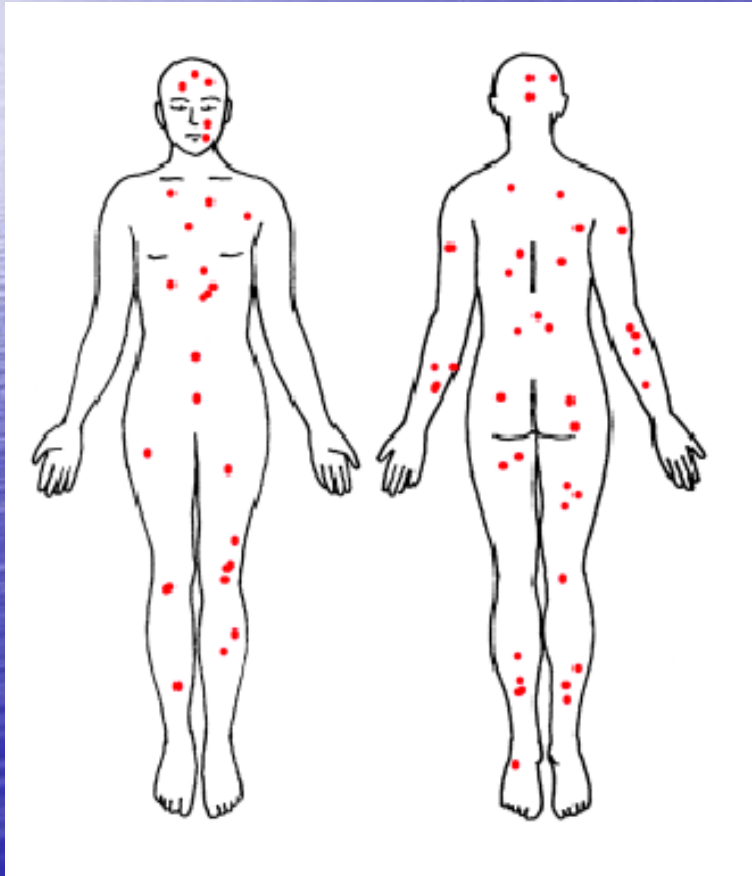
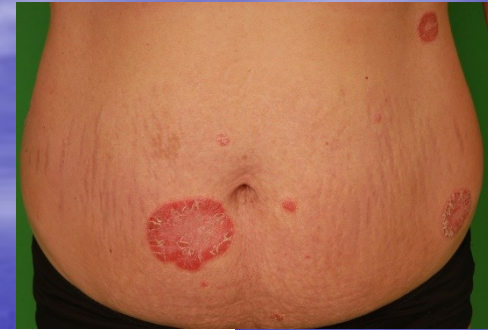Atopický ekzém - predilekce




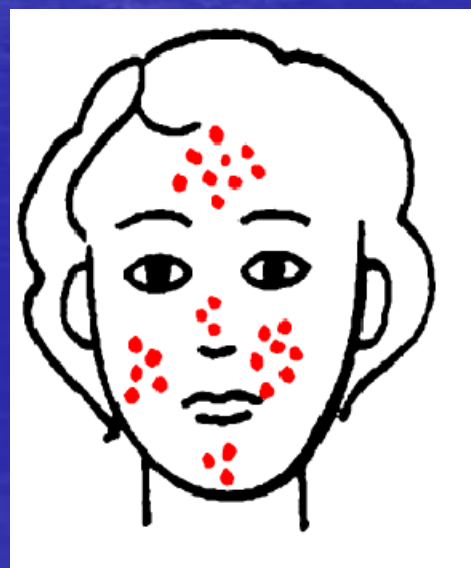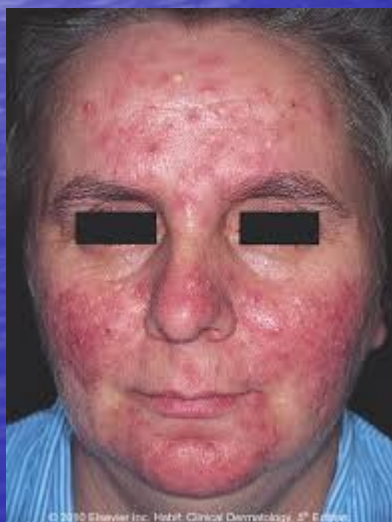
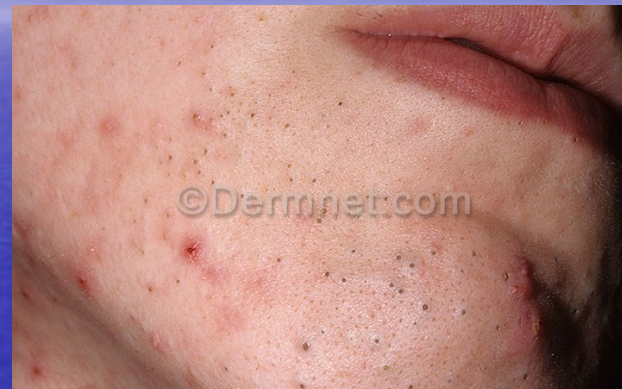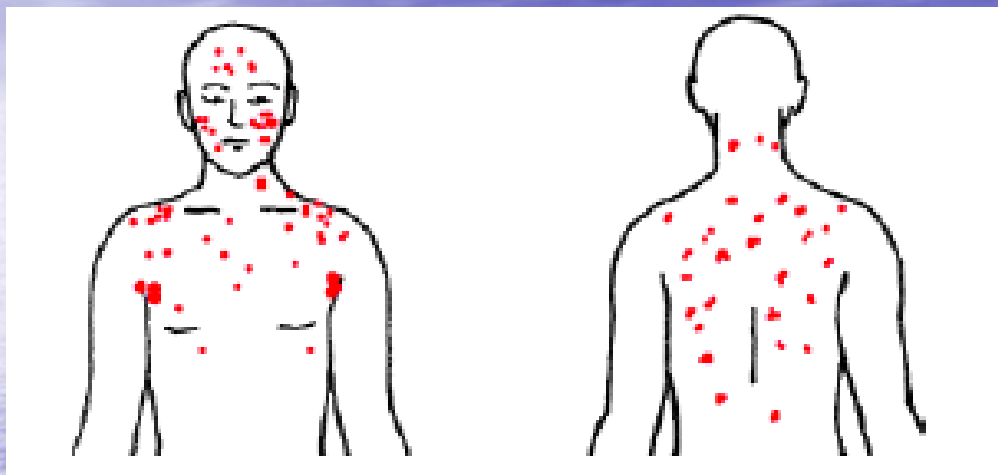
Psoriáza - predilekce

- Akutní -guttátní

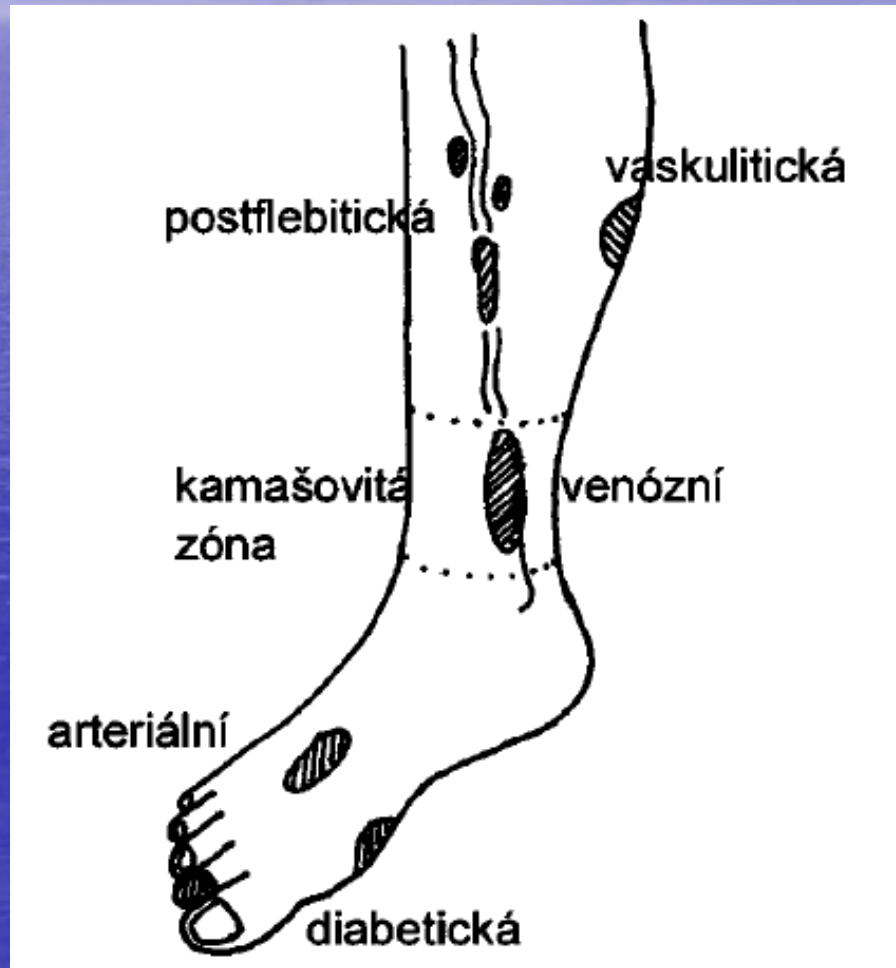
- Chronická

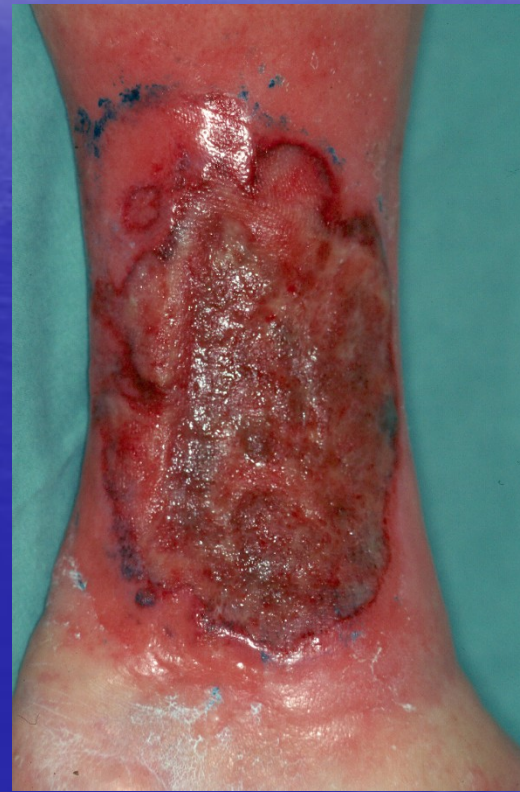
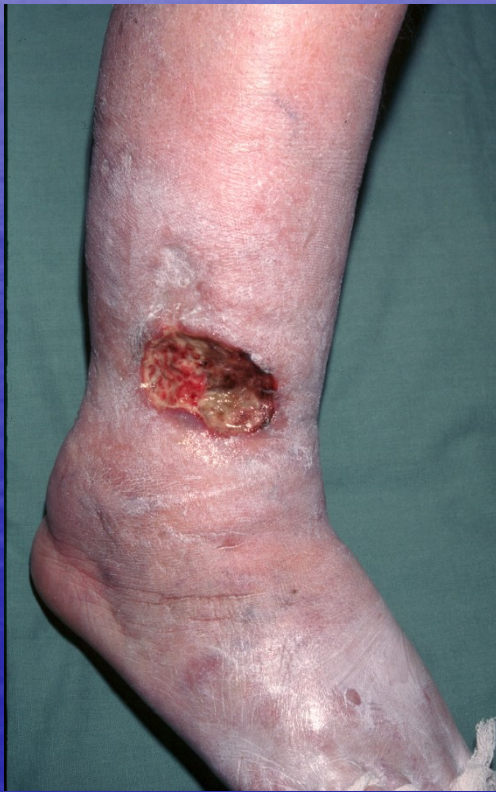
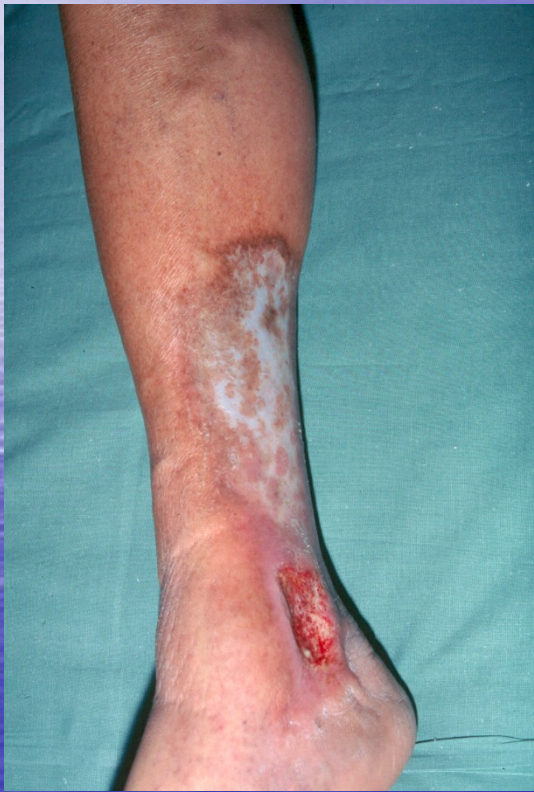Akne – rosacea * periorální dermatitis

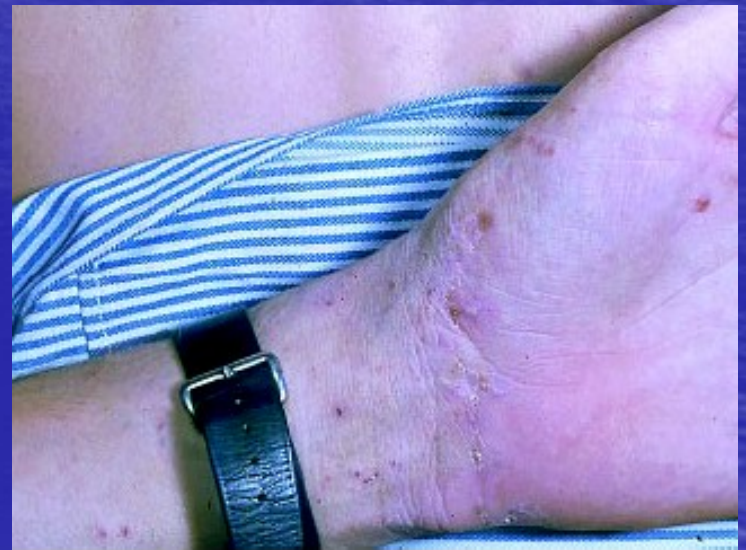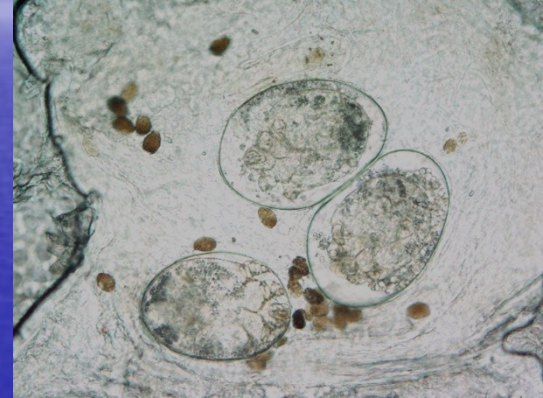
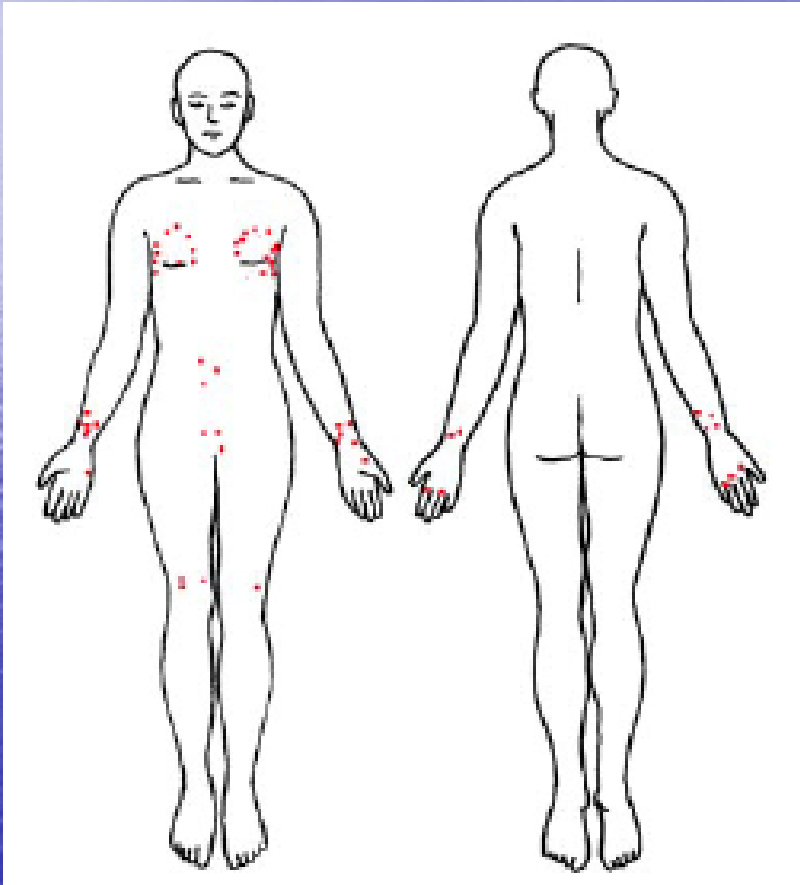


Lokalizace ulcerací na dolní končetině

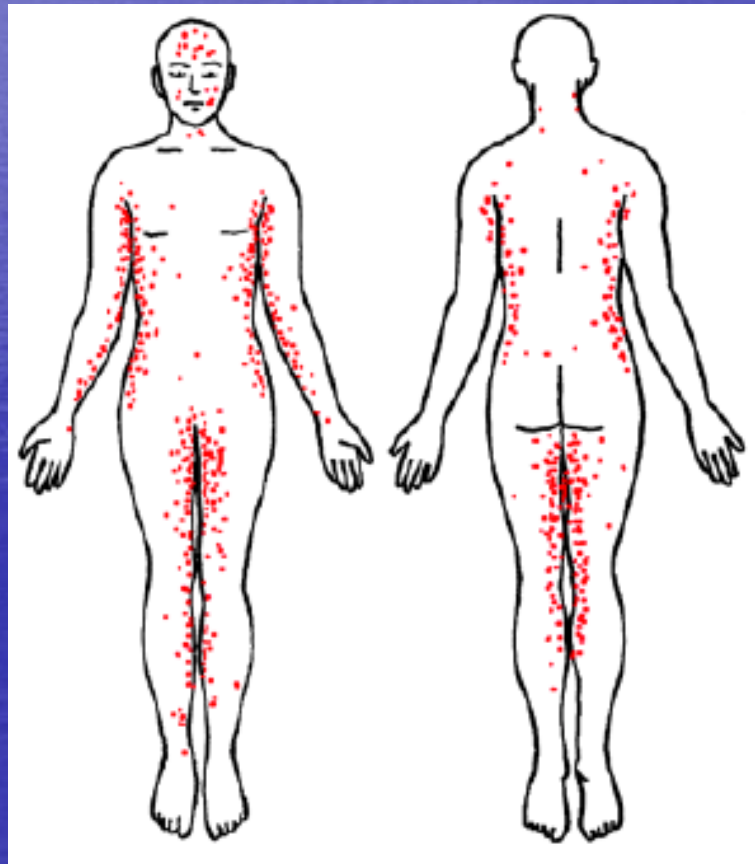




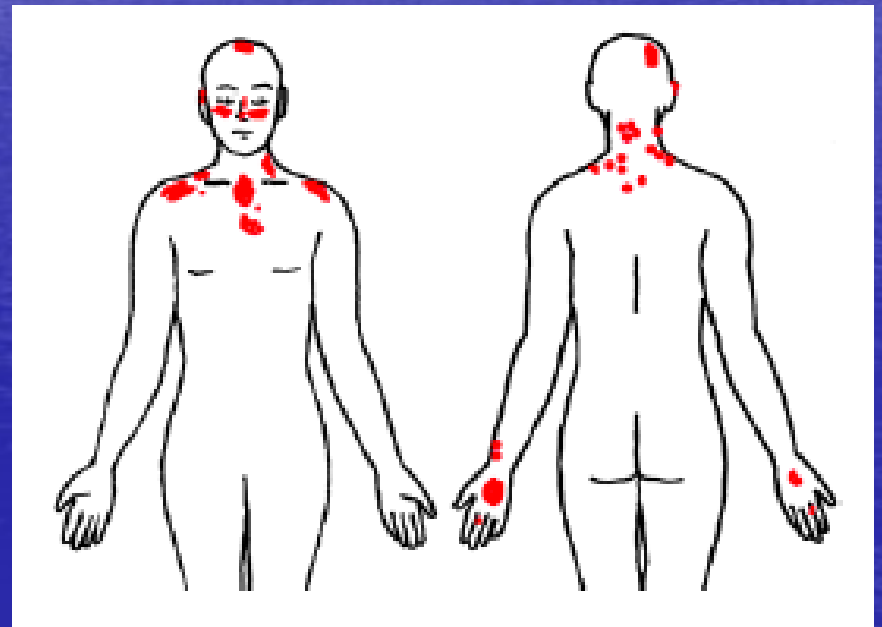
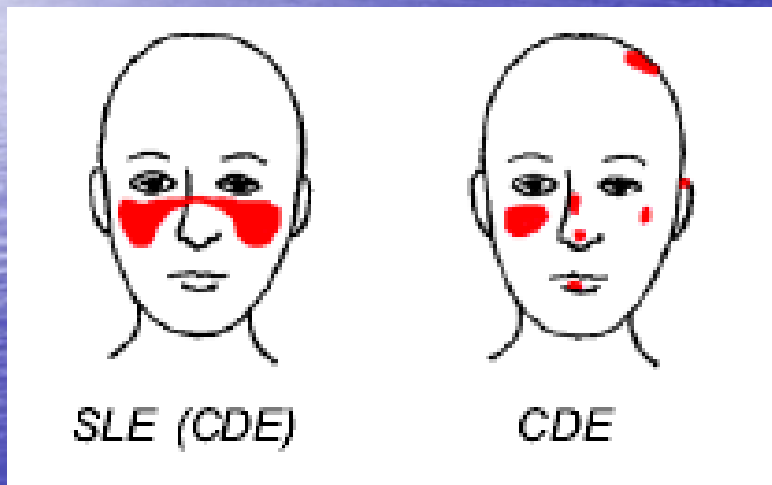
Predilekce - scabies



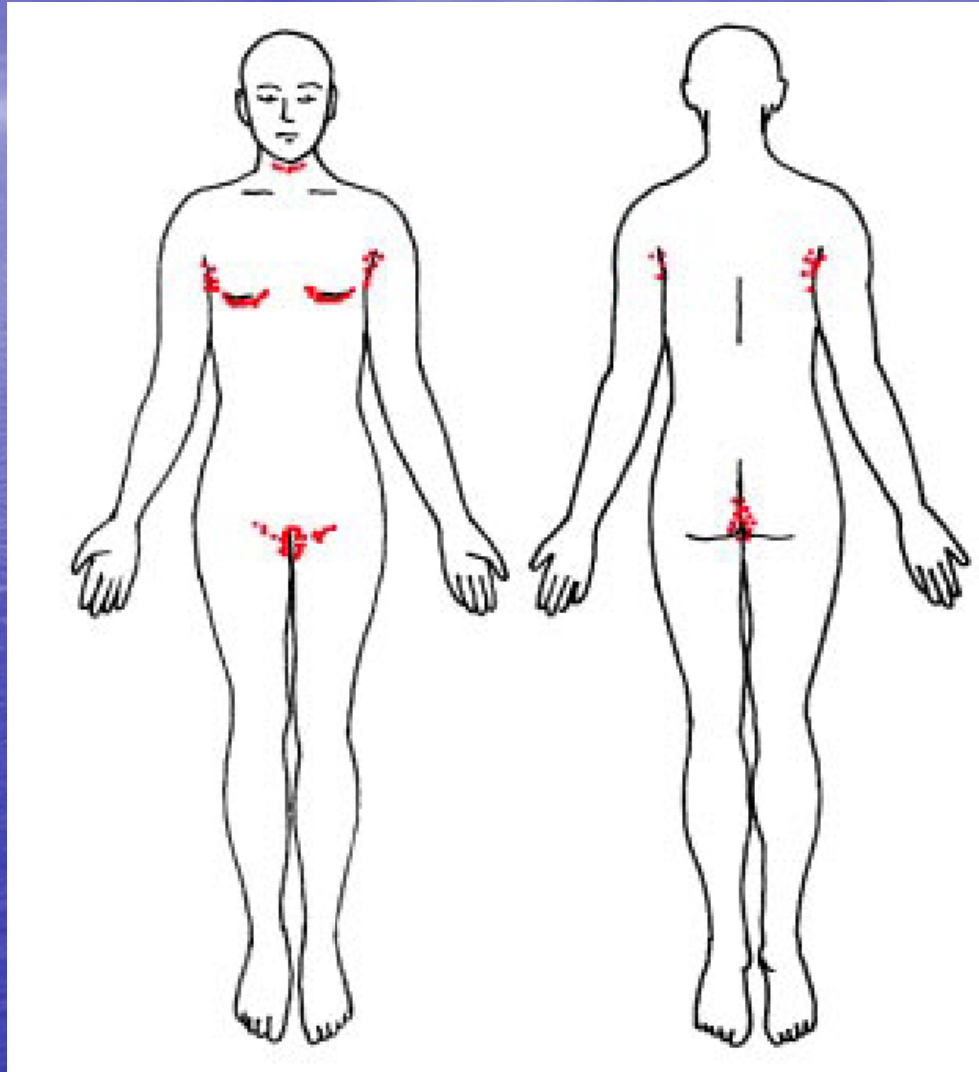
Embolizační lokalizace – lékové exantémy



Fotosenzitivní lokalizace



Intertriginózní lokalizace



Seborhoická lokalizace

